

---

**AVIAN MEDICINE:**  
**PRINCIPLES AND APPLICATION**

---



**RITCHIE, HARRISON AND HARRISON**



Caroline Keiken









---

# AVIAN MEDICINE: PRINCIPLES AND APPLICATION

---

■

**BRANSON W. RITCHIE, DVM, PhD**

Assistant Professor Avian and Zoologic Medicine  
Department of Small Animal Medicine  
College of Veterinary Medicine  
University of Georgia  
Athens, Georgia

**GREG J. HARRISON, DVM**

Director, The Bird Hospital  
Lake Worth, Florida  
President, Harrison's Bird Diets  
Omaha, Nebraska

**LINDA R. HARRISON, BS**

Editor, Journal of the Association of Avian Veterinarians  
Lake Worth, Florida



WINGERS PUBLISHING, INC.  
Post Office Box 6863, Lake Worth, Florida 33463-6863

Library of Congress Catalog Card Number: 93-60501

ISBN 0-9636996-0-1

Art Director/Designer: Kari W. McCormick  
Text Manager: Roy A. Faircloth  
Electronic Typographer: Richard Larson  
Proofreading: Virginia Skinner, DVM, Robin Berry  
Administrative Assistants: Gabrielle Jackson, Shirley Harlan, Chris Migliore

Color Separations: Color Trend, Inc., Boca Raton, FL  
Printing and Binding: Edwards Brothers, Ann Arbor, MI  
Anatomy Overlay Printing: Lithotype, San Francisco, CA  
Anatomy Overlay Binding: Curwood, Inc., Fremont, OH  
Legal Counsel: Terry Clyne

AVIAN MEDICINE: PRINCIPLES AND APPLICATION

ISBN 0-9636996-0-1

© 1994 by Wingers Publishing, Inc.

All rights reserved. No part of this publication may be reproduced, stored in a retrieval system or transmitted in any form or by any means, electronic, mechanical, photocopying, recording or otherwise, without prior written permission from Wingers Publishing, Inc. All inquiries should be addressed to Wingers Publishing, Inc., Post Office Box 6863, Lake Worth, Florida 33466-6863. Made in the United States of America. Library of Congress Catalog Card number 93-60501.

10 9 8 7 6 5 4 3 2 1



# Contents

Contributors . . . . .	9
Acknowledgements . . . . .	11
Foreword . . . . .	13
Preface . . . . .	15

Prologue	
AVIAN CONSERVATION: THE VETERINARIAN'S ROLE . . . . .	17
<i>Robert Groskin</i>	
Man and Birds . . . . .	18
Conservation Biology . . . . .	20

## SECTION ONE THE COMPANION BIRD

<b>1 THE AVIAN PATIENT . . . . .</b>	<b>26</b>
<i>Ross A. Perry</i>	
Selection of Companion Birds . . . . .	27
The Home Environment . . . . .	33
<b>2 THE AVIAN FLOCK . . . . .</b>	<b>45</b>
<i>Susan L. Clubb, Keven Flammer</i>	
Flock Preventive Medicine . . . . .	46
Evaluating and Treating Flock Problems . . . . .	59
<b>3 NUTRITION . . . . .</b>	<b>63</b>
<i>Randal N. Brue</i>	
Water . . . . .	65
Nutrient Interrelationships . . . . .	66
Methods for Determining Nutrient Requirements . . . . .	69
Current Nutritional Knowledge . . . . .	73
Essential Nutrients and Their Biological Functions . . . . .	78

<b>4 PERSPECTIVE ON PARROT BEHAVIOR . . . . .</b>	<b>96</b>
<i>Greg J. Harrison</i>	
Behavior in the Wild . . . . .	97
Companion Bird Behavior . . . . .	100
Training . . . . .	101
Behavioral Modification . . . . .	104
<b>5 DEFENSE MECHANISMS OF THE AVIAN HOST . . . . .</b>	<b>109</b>
<i>Helga Gerlach</i>	
Nonspecific Defense . . . . .	110
Specific Defense . . . . .	114
Disturbance of the Defense System . . . . .	119
<b>6 FUTURE PREVENTIVE MEDICINE . . . . .</b>	<b>121</b>
<i>Branson W. Ritchie</i>	
Overview of DNA and RNA . . . . .	122
DNA Probe Technology . . . . .	122
Vaccines . . . . .	126
Antimicrobial Therapy . . . . .	127

## SECTION TWO PATIENT EVALUATION

<b>7 PRACTICE DYNAMICS . . . . .</b>	<b>131</b>
<i>Cathy A. Johnson-Delaney</i>	
Getting Started . . . . .	132
Accommodating the Avian Patient . . . . .	136
Environmental Responsibility . . . . .	142
<b>8 MAKING DISTINCTIONS IN THE PHYSICAL EXAMINATION . . . . .</b>	<b>144</b>
<i>Greg J. Harrison, Branson W. Ritchie</i>	
Anamnesis . . . . .	145
Physical Examination . . . . .	147
<b>9 HEMATOLOGY . . . . .</b>	<b>176</b>
<i>Terry W. Campbell</i>	
Processing the Avian Hematologic Sample . . . . .	177
Interpretation of the Avian Hemogram . . . . .	188
Evaluation of the Hematopoietic Tissue . . . . .	191
<b>10 CYTOLOGY . . . . .</b>	<b>199</b>
<i>Terry W. Campbell</i>	
Sample Collection . . . . .	200
Evaluation of the Cytologic Sample . . . . .	205
Cytology of Commonly Sampled Fluids and Tissues . . . . .	208

<b>11 BIOCHEMISTRIES . . . . .</b>	<b>223</b>
<i>Manfred Hochleithner</i>	
Laboratory Considerations . . . . .	224
Reference Values - Reference Intervals . . . . .	225
Types of Testing . . . . .	226
Indices . . . . .	227
<b>12 IMAGING TECHNIQUES . . . . .</b>	<b>246</b>
<i>Marjorie C. McMillan</i>	
Technical Considerations . . . . .	247
Radiographic Interpretation . . . . .	249
Contrast Procedures . . . . .	256
Alternative Imaging . . . . .	260
Radiographic Anatomy and Abnormalities . . . . .	261
<b>13 ENDOSCOPIC EXAMINATION AND BIOPSY TECHNIQUES . . . . .</b>	<b>327</b>
<i>Michael Taylor</i>	
Clinical Applications of Endoscopy . . . . .	339
Biopsy Techniques . . . . .	347
<b>14 NECROPSY EXAMINATION . . . . .</b>	<b>355</b>
<i>Kenneth S. Latimer, Pauline M. Rakich</i>	
Necropsy Record . . . . .	356
Preparing for the Necropsy . . . . .	357
The Necropsy Examination . . . . .	358
Specimen Collection for Ancillary Testing . . . . .	376

## SECTION THREE TREATMENT REGIMENS

<b>15</b>	<b>SUPPORTIVE CARE AND EMERGENCY THERAPY</b> . . . . .	382	<b>17</b>	<b>ANTIMICROBIAL THERAPY</b> . . . . .	434
	<i>Katherine E. Quesenberry, Elizabeth V. Hillyer</i>			<i>Keven Flammer</i>	
	Emergency Stabilization . . . . .	383		Factors Influencing	
	Emergency Problems . . . . .	398		Selection of an Antibiotic . . . . .	435
<b>16</b>	<b>TRAUMA MEDICINE</b> . . . . .	417		Antibacterial Therapy . . . . .	443
	<i>Laurel A. Degernes</i>			Antifungal Therapy . . . . .	450
	Principles of Wound Management . . . . .	418	<b>18</b>	<b>FORMULARY</b> . . . . .	457
	Specific Traumatic Injuries and Their Management . . . . .	422		<i>Branson W. Ritchie, Greg J. Harrison</i>	
				Product Information . . . . .	458
				Therapeutic Agents . . . . .	470
				Drug Dosing Chart . . . . .	476

## SECTION FOUR INTERNAL MEDICINE

<b>19</b>	<b>GASTROENTEROLOGY</b> . . . . .	482	<b>25</b>	<b>ONCOLOGY</b> . . . . .	640
	<i>J.T. Lumeij</i>			<i>Kenneth S. Latimer</i>	
	The Beak . . . . .	484		Integumentary System . . . . .	641
	The Oropharynx and Salivary Glands . . . . .	485		Respiratory System . . . . .	645
	The Esophagus and Crop . . . . .	489		Circulatory System . . . . .	646
	The Proventriculus and Ventriculus . . . . .	498		Musculoskeletal System . . . . .	647
	The Small and Large Intestines . . . . .	506		Urogenital System . . . . .	650
	The Cloaca . . . . .	509		Digestive System . . . . .	655
	The Pancreas . . . . .	512		Endocrine System . . . . .	659
	The Pleuro-peritoneum . . . . .	514		Nervous System and Eye . . . . .	661
				Hemolymphatic System . . . . .	668
<b>20</b>	<b>HEPATOLOGY</b> . . . . .	522	<b>26</b>	<b>OPHTHALMOLOGY</b> . . . . .	673
	<i>J.T. Lumeij</i>			<i>David Williams</i>	
	Diagnostic Considerations . . . . .	523		Anatomy of the Eye . . . . .	675
	Liver Diseases . . . . .	532		Ophthalmic Disorders . . . . .	677
	Treatment of Liver Disorders . . . . .	536	<b>27</b>	<b>CARDIOLOGY</b> . . . . .	695
<b>21</b>	<b>NEPHROLOGY</b> . . . . .	538		<i>J.T. Lumeij, Branson W. Ritchie</i>	
	<i>J.T. Lumeij</i>			Evaluating the Avian Heart . . . . .	696
	Anatomy and Physiology of the Kidney . . . . .	539		Electrocardiology . . . . .	697
	Clinicopathologic Diagnosis of Renal Dysfunction . . . . .	543		Arrhythmias . . . . .	705
	Diseases of the Kidney . . . . .	550		Cardiovascular Diseases . . . . .	711
	Therapeutic Considerations . . . . .	553	<b>28</b>	<b>NEUROLOGY</b> . . . . .	723
<b>22</b>	<b>PNEUMONOLOGY</b> . . . . .	556		<i>R. Avery Bennett</i>	
	<i>Thomas N. Tully, Jr., Greg J. Harrison</i>			Neuroanatomy . . . . .	724
	The Respiratory Tract . . . . .	557		Neurologic Examination . . . . .	727
	Respiratory Physiology . . . . .	567		Diagnostic Techniques . . . . .	729
	Diagnostic Techniques . . . . .	571		Neuropathies . . . . .	731
	Aerosol Therapy . . . . .	573		Infectious Neuropathies . . . . .	741
	Specific Respiratory Diseases . . . . .	574		Congenital Abnormalities . . . . .	745
<b>23</b>	<b>ENDOCRINOLOGY</b> . . . . .	582	<b>29</b>	<b>THERIOGENOLOGY</b> . . . . .	748
	<i>J.T. Lumeij</i>			<i>Kim L. Joyner</i>	
	The Hypothalamus and Pituitary Gland . . . . .	583		Female Reproductive Anatomy and Egg Formation . . . . .	749
	Calcium Metabolism . . . . .	587		Male Reproductive Anatomy . . . . .	755
	The Thyroid Glands . . . . .	593		Female Reproductive Disorders . . . . .	758
	The Adrenal Glands . . . . .	597		Male Reproductive Disorders . . . . .	774
	Endocrine Control of Feather Formation . . . . .	601		Artificial Insemination . . . . .	776
	Diabetes Mellitus . . . . .	602		Non-disease Factors	
	Polyuria/Polydipsia (PU/PD) . . . . .	604		Affecting Reproduction . . . . .	777
				Artificial Incubation . . . . .	788
<b>24</b>	<b>DERMATOLOGY</b> . . . . .	607	<b>30</b>	<b>NEONATOLOGY</b> . . . . .	805
	<i>John E. Cooper, Greg J. Harrison</i>			<i>Keven Flammer, Susan L. Clubb</i>	
	Anatomy and Physiology of the Avian Integument . . . . .	608		Hand-raising Birds . . . . .	808
	General Diagnosis and Therapy . . . . .	621		Common Problems of Neonates . . . . .	820
	Specific Etiologies				
	of Generalized Dermatopathies . . . . .	623			
	Diseases of the Feathers . . . . .	633			

## SECTION FIVE DISEASE ETIOLOGIES

<b>31</b>	<b>MALNUTRITION</b> . . . . .	842	<b>33</b>	<b>BACTERIA</b> . . . . .	949
	<i>Patricia Macwhirter</i>			<i>Helga Gerlach</i>	
	Clinical Conditions			Gram-negative Bacteria	
	Associated with Malnutrition . . . . .	843		of Clinical Significance . . . . .	950
	Deficiencies of Specific Nutrients . . . . .	849		Other Gram-negative Rods . . . . .	964
<b>32</b>	<b>VIRUSES</b> . . . . .	862		Gram-positive Bacteria	
	<i>Helga Gerlach</i>			of Clinical Significance . . . . .	965
	Diagnostic Principles . . . . .	863	<b>34</b>	<b>CHLAMYDIA</b> . . . . .	984
	Avipoxvirus . . . . .	865		<i>Helga Gerlach</i>	
	Herpesviridae . . . . .	874		Diagnosis of Chlamydiosis . . . . .	990
	Papovaviridae . . . . .	885		Treatment of Chlamydiosis . . . . .	993
	Circoviridae . . . . .	894	<b>35</b>	<b>MYCOSES</b> . . . . .	997
	Adenovirus . . . . .	903		<i>Louise Bauck</i>	
	Parvoviridae . . . . .	908		Common Fungal Diseases . . . . .	998
	Hepadnaviridae . . . . .	909		Uncommon Fungal Diseases . . . . .	1005
	Reoviridae . . . . .	910	<b>36</b>	<b>PARASITES</b> . . . . .	1007
	Birnaviridae . . . . .	914		<i>Ellis C. Greiner, Branson W. Ritchie</i>	
	Coronaviridae . . . . .	914		Diagnosis of Parasites . . . . .	1008
	Togaviridae and Flaviviridae			Clinically Significant Parasites . . . . .	1013
	(Arbovirus A and B) . . . . .	915	<b>37</b>	<b>TOXINS</b> . . . . .	1030
	Rhabdoviridae . . . . .	920		<i>Genevieve Dumonceaux, Greg J. Harrison</i>	
	Paramyxoviridae . . . . .	920		Ingested Toxins . . . . .	1034
	Orthomyxovirus . . . . .	929		Iatrogenic Intoxications . . . . .	1045
	Retroviridae . . . . .	931		Airborne Toxins . . . . .	1047
	Picornaviridae . . . . .	937		Insecticides . . . . .	1049
	Diseases with Infectious		<b>38</b>	<b>MYCOPLASMA AND RICKETTSIA</b> . . . . .	1053
	Characteristics but Uncertain Etiology . . . . .	940		<i>Helga Gerlach</i>	
				Mycoplasmatales . . . . .	1054
				Rickettsia . . . . .	1061

## SECTION SIX SURGERY

<b>39</b>	<b>ANESTHESIOLOGY</b> . . . . .	1066	<b>41</b>	<b>SOFT TISSUE SURGERY</b> . . . . .	1096
	<i>Leslie C. Sinn</i>			<i>R. Avery Bennett, Greg J. Harrison</i>	
	Anesthetic Agents and Equipment . . . . .	1067		Surgery of the Skin . . . . .	1097
	Management of the Anesthetic Patient . . . . .	1074		Surgery of the Eye . . . . .	1100
<b>40</b>	<b>SURGICAL CONSIDERATIONS</b> . . . . .	1081		Surgery of the Respiratory System . . . . .	1105
	<i>R. Avery Bennett</i>			Surgery of the Gastrointestinal System . . . . .	1111
	Patient Evaluation . . . . .	1082		Surgery of the Reproductive Tract . . . . .	1128
	Instrumentation . . . . .	1085		Miscellaneous Surgical Procedures . . . . .	1132
	Postoperative Care . . . . .	1094	<b>42</b>	<b>ORTHOPEDIC</b>	
				<b>SURGICAL TECHNIQUES</b> . . . . .	1137
				<i>Howard D. Martin, Branson W. Ritchie</i>	
				Therapeutic Strategies . . . . .	1138
				Fracture Repair Techniques . . . . .	1145
				Surgical Approaches . . . . .	1153

<p><b>43</b> PASSERIFORMES . . . . . 1172  <i>Patricia Macwhirter</i>  Anatomy and Physiology . . . . . 1173  Avicultural Considerations . . . . . 1175  Special Considerations  in Managing Passerine Patients . . . . . 1180  Diseases . . . . . 1182</p> <p><b>44</b> COLUMBIFORMES . . . . . 1200  <i>Curt Vogel, Helga Gerlach, Mait Löffler</i>  Zoologic Taxonomy . . . . . 1201  Unique Characteristics  of Columbiformes . . . . . 1202  Husbandry . . . . . 1205  Reproduction . . . . . 1209  Clinical Examination . . . . . 1211  Diseases . . . . . 1214</p> <p><b>45</b> GALLIFORMES . . . . . 1218  <i>Christian Schales, Kerstin Schales</i>  Anatomy and Physiology . . . . . 1219  Husbandry . . . . . 1223  Nutrition . . . . . 1224  Reproduction . . . . . 1226  Restraint . . . . . 1233  Disease Considerations . . . . . 1233</p>	<p><b>46</b> ANSERIFORMES . . . . . 1237  <i>John H. Olsen</i>  Biology . . . . . 1238  Husbandry Practices . . . . . 1244  Reproduction . . . . . 1252  Restraint, Handling and Anesthesia . . . . . 1259  Diseases . . . . . 1262  Common Surgical Procedures . . . . . 1269</p> <p><b>47</b> RAMPHASTIDAE . . . . . 1276  <i>Hans Cornelissen, Branson W. Ritchie</i>  Diseases . . . . . 1280</p> <p><b>48</b> RATITES . . . . . 1284  <i>James S. Stewart</i>  Characteristics . . . . . 1285  Clinical Anatomy and Physiology . . . . . 1286  Adult Bird Management . . . . . 1297  Medical Disorders and Therapies . . . . . 1303  Hatchery Management . . . . . 1317  Chick Management . . . . . 1320</p>
---	---

---

<p>Appendix . . . . . 1329  Anatomy Overlay . . . . . follows 1352  Index . . . . . 1353</p>
--

# Contributors

---

**LOUISE BAUCK, BSc, DVM, MVSc**

Rolf C. Hagen, Inc.  
Hagen Avicultural Research Institute  
Montreal, Quebec, Canada  
*Mycoses*

**R. AVERY BENNETT, DVM, MS**

Diplomate American College of Veterinary Surgeons  
Chief Veterinarian  
San Francisco Zoological Gardens  
San Francisco, California  
*Neurology, Surgical Considerations, Soft Tissue Surgery*

**RANDAL N. BRUE, BS, MS, PhD**

Vice-president, Research and Development  
Kaytee Products, Incorporated  
Chilton, Wisconsin  
*Nutrition*

**TERRY W. CAMPBELL, DVM, PhD**

Staff Veterinarian, Sea World Orlando  
Orlando, Florida  
*Hematology, Cytology*

**SUSAN L. CLUBB, DVM**

Staff Veterinarian, Parrot Jungle  
Miami, Florida  
*The Avian Flock, Neonatology*

**JOHN E. COOPER, DTVM, MRCPPath, FIBiol, FRCVS**

Professor of Veterinary Medicine, Sokoine  
University of Agriculture, Tanzania  
Visiting Research Fellow, University of Kent  
United Kingdom  
*Dermatology*

**HANS CORNELISSEN, DVM**

Diplomate Internal Medicine of Companion Animals  
(Royal Netherlands Veterinary Association)  
Companion Animal Clinic Broerdijk  
Nijmegen, The Netherlands  
*Ramphastidae*

**LAUREL A. DEGERNES, DVM**

Assistant Professor in Non-domestic Avian Medicine  
Department of Companion Animals  
and Special Species Medicine  
College of Veterinary Medicine  
North Carolina State University  
Raleigh, North Carolina  
*Trauma Medicine*

**GENEVIEVE DUMONCEAUX, DVM**

Zoo Medicine Resident  
University of California  
Davis, California  
*Toxins*

**KEVEN FLAMMER, DVM**

Associate Professor in Non-domestic Avian Medicine  
College of Veterinary Medicine  
North Carolina State University  
Raleigh, North Carolina  
*Antimicrobial Therapy, Neonatology, The Avian Flock*

**HELGA GERLACH, Prof. Dr. med. vet. Dr. habil. (retired)**

Formerly: Institut für Geflügelkrankheiten  
Ludwig-Maximilians-Universität München  
Oberschleißheim, Germany  
*Defense Mechanisms of the Avian Host, Viruses, Bacteria,  
Chlamydia, Mycoplasma and Rickettsia, Columbiformes*

**ELLIS C. GREINER, PhD**

Professor of Parasitology  
Department of Infectious Diseases  
College of Veterinary Medicine  
University of Florida  
Gainesville, Florida  
*Parasites*

**ROBERT GROSCHIN, DVM**

Director, Englewood Animal Hospital  
Englewood, New Jersey  
*Prologue*

**GREG J. HARRISON, DVM**

Director, The Bird Hospital  
Lake Worth, Florida  
President, Harrison's Bird Diets  
Omaha, Nebraska  
*Perspective on Parrot Behavior, Making Distinctions in the  
Physical Examination, Formulary, Pneumonology, Dermatology,  
Toxins, Soft Tissue Surgery*

**ELIZABETH V. HILLYER, DVM**

Free-lance Medical Writer and Editor  
Oldwick, New Jersey  
*Supportive Care and Emergency Therapy*

**MANFRED HOCHLEITHNER, DVM**

Private Practitioner  
Tierklinik Strebersdorf  
Vienna, Austria  
University Lektor Vet. Med.  
University of Vienna, Dr. med. vet.  
*Biochemistries*

**CATHY A. JOHNSON-DELANEY, DVM**

Coordinator, Primate Supply Information Clearinghouse  
Research Literature Analyst, Primate Information Center  
Regional Primate Research Center  
University of Washington  
Seattle, Washington  
Associate Veterinarian, Exotic Pet and Bird Clinic  
Kirkland, Washington  
*Practice Dynamics*

**KIM L. JOYNER, DVM, MPVM**

Staff Veterinarian, Mariana Aviaries  
Co-director Guatemala Psittacine Research Project  
Guatemala City, Guatemala  
Assistant Professor  
School of Veterinary Medicine  
North Carolina State University  
Raleigh, North Carolina  
*Therigenology*

**KENNETH S. LATIMER, DVM, PhD**

Diplomate American College of Veterinary Pathologists  
 Professor of Pathology  
 Director, Histopathology Laboratory  
 Director, Zoo and Exotic Animal Pathology  
 Department of Veterinary Pathology  
 College of Veterinary Medicine  
 University of Georgia, Athens, Georgia  
*Necropsy Examination, Oncology*

**J.T. LUMEIJ, DVM, PhD**

Diplomate Internal Medicine Companion Animals (RNVA)  
 Head Division Avian and Exotic Animal Medicine  
 Department of Clinical Sciences of Companion Animals  
 Faculty of Veterinary Medicine and Sciences  
 Utrecht University, The Netherlands  
*Gastroenterology, Hepatology, Nephrology,  
 Endocrinology, Cardiology*

**MAIT LÖFFLER**

Veterinary Student  
 Leipzig, Germany  
*Columbiformes*

**PATRICIA MACWHIRTER, BVSc (Hons), FACVSc**

Principal, Highbury Veterinary Clinic  
 Burwood, Victoria, Australia  
*Malnutrition, Passeriformes*

**HOWARD D. MARTIN, DVM**

Veterinarian  
 Studio City Animal Hospital  
 Studio City, California  
*Orthopedic Surgical Techniques*

**MARJORIE C. McMILLAN, DVM**

Diplomate American College of Veterinary Radiology  
 Director, Windhover Veterinary Center  
 Walpole, Massachusetts  
*Imaging Techniques*

**JOHN H. OLSEN, DVM**

Director of Veterinary Services  
 Busch Gardens Tampa  
 Tampa, Florida  
*Anseriformes*

**SUSAN E. OROSZ, PhD, DVM**

Assistant Professor  
 Department of Environmental Practice  
 University of Tennessee  
 Knoxville, Tennessee  
*Anatomy Consultant*

**ROSS A. PERRY, BSc, BVSc, FACVSc**

Western Suburban Animal Hospital  
 Homebush, New South Wales, Australia  
*The Avian Patient*

**KATHERINE E. QUESENBERRY, DVM**

Associate Staff  
 Exotic Animal Program  
 The Animal Medical Center  
 New York, New York  
*Supportive Care and Emergency Medicine*

**PAULINE M. RAKICH, DVM, PhD**

Assistant Professor of Pathology  
 Athens Diagnostic Laboratory  
 College of Veterinary Medicine  
 University of Georgia  
 Athens, Georgia  
*Necropsy Examination*

**BRANSON W. RITCHIE, DVM, PhD**

Assistant Professor Avian/Zoologic Medicine  
 Department of Small Animal Medicine  
 College of Veterinary Medicine  
 University of Georgia  
 Athens, Georgia  
*Future Preventive Medicine, Making Distinctions in the  
 Physical Examination, Formulary, Cardiology, Parasites,  
 Orthopedic Surgical Techniques, Ramphastidae*

**CHRISTIAN SCHALES, Dr. med. vet.**

Wissenschaftlicher Mitarbeiter  
 Institut für Geflügelkrankheiten  
 Ludwig-Maximilians-Universität München  
 Oberschleißheim, Germany  
*Galliformes*

**KERSTIN SCHALES, Dr. med. vet.**

Institut für Geflügelkrankheiten  
 Ludwig-Maximilians-Universität München  
 Oberschleißheim, Germany  
*Galliformes*

**LESLEY E. SEALING, DVM, MS**

Sealing Illustration  
 Englewood, Colorado  
*Medical Illustrations, Acetate Overlay*

**LESLIE C. SINN, DVM**

Assistant Professor  
 Program Head, Veterinary Technology  
 Northern Virginia Community College  
 Loudoun Campus  
 Sterling, Virginia  
*Anesthesiology*

**JAMES S. STEWART, MS, DVM**

Owner, Ostrich Consultation Services  
 Co-owner, West Coast Ostrich Company  
 San Ramon, California  
*Ratites*

**MICHAEL TAYLOR, DVM**

Director, Avian and Exotic Animal Clinic  
 Amherst Veterinary Hospital  
 Scarborough, Ontario, Canada  
*Endoscopic Examination and Biopsy Techniques*

**THOMAS N. TULLY, Jr., DVM, MS**

Assistant Professor  
 Department of Veterinary Clinical Sciences  
 and Laboratory Animal Medicine  
 Louisiana State University  
 School of Veterinary Medicine  
 Baton Rouge, Louisiana  
*Pneumonology*

**CURT VOGEL, Dr. med. vet., Fachtierarzt**

Emeritus, formerly Wissenschaftlicher Mitarbeiter  
 Friedrich-Loeffler-Institut für Virusforschung Insel Riems  
 Chief Veterinarian, KIM Enterprise  
 Königs Wusterhausen, Germany  
*Columbiformes*

**DAVID WILLIAMS, MA, VetMB, MRCVS**

Beaumont Animal's Hospital  
 London, England  
*Ophthalmology*

## Acknowledgements

---

---

**E**normous cooperation and support from many individuals are required for a project of this magnitude. It has truly been an honor to coordinate the efforts of so many dedicated authors, and we appreciate their giving of their personal time in participating in this undertaking.

We especially want to thank Dr. Lesley E. Sealing, who was extremely committed to the tedious and long-term effort of developing the medical illustrations, including the anatomy overlay of the cockatoo.

We are indebted to the international authors, particularly Helga Gerlach and Sjeng Lumeij, for their immense contribution to the book (some of these authors had to write in a “foreign” language — all scrutinized the world’s literature and brought a fresh perspective to this work); additionally, John Olsen, Kenneth Latimer and Avery Bennett contributed beyond their initial commitment.

Deep appreciation is extended to those whose lives and schedules were disrupted by the time commitment of the editors: the research team, staff and students at the University of Georgia, including Cheryl Greenacre, Ken Latimer, Frank Niagro, Phil Lukert, Denise Pesti and Michelle Weatherly; the staff and clients of The Bird Hospital and Harrison’s Bird Diets; and the staff, board of directors and members of the Association of Avian Veterinarians.

The outstanding color reproductions of hematology cells from Lucas and Jamroz’ originals were produced by Alex Webber from the Educational Resource Center at the University of Georgia. Joey C. Rodgers and Stacy Koffman from the Education Resource Center produced the exceptional quality black and white prints. Color endophotographs were made possible through the support of Karl Storz Veterinary Endoscopy - America. The color separation skills provided by Color Trend, Inc. were responsible for the quality of the color prints.

We are grateful for other colleagues who were willing to share portions of their previous works through this

medium: Karen Hicks, John Wade, Murray Fowler, Alice Blue-McClendon, Peter Stettenheim, Irene Pepperburg, Charles Munn and Ken Fletcher; and for the radiographs, illustrations and photographs from Stephen A. Smith, Bonnie J. Smith, Maria-Elisabeth Krautwald-Junghanns, Murray Fowler, Brett Hopkins, Busch Gardens Tampa, Jane Turrell, Apalachee River Aviary, R. Korbel, Robert Schmidt and Ellman International Manufacturing, Inc.

In addition to the authors, the editors would like to thank Martin Orr, Robert Clipsham, Nina Ungerechts, J. Richmond, Priscilla B. Wyrick, W.T. Atyeo, Michael Lutz, K. Göbel, Exotic Animal Medical Products, Mark Spreyer, D. Brückner, Curt Vogel, S.W. Jack, David Ley, Richard Cambre, Louis Filipich, Cheryl Greenacre, R.J. Montali, Michael Murray, L. Karpinski, Jean Paré, K.C. Barnett, S. West, Dan Wolf, Isabel Taylor, W.S. Steffens, Jean Sanders, Bob Dahlhausen, Carol Partington, Elizabeth Watson, Ramiro Issaz, John Randolph, and Avian Research Associates for providing photographs used in this book. Others who contributed to the graphic aspects include Lauri Maniccia, Lynda Hare and Tom Elfers.

We appreciate the comments of colleagues who received early manuscripts: Jim Stunkard, Christopher Murphy, James Harvey Johnson, Don Harris, Louise Bauck, James Harris, Michael Murray, and for technical support from Vicki McConnell, Carrie Reynolds, Donna Hurd Smith, Mamie Watson, Randi Gilbert, Chris Migliore, Shirley and Bob Harlan.

For extra and continued support, without which this book would not have been possible, we thank Terry Clyne, Helga Gerlach and Marion Litonski, Dana O’Donoghue, Harrison’s Bird Diets, and Irving Cowan for his support of avian health.

And finally, our deepest thanks to the staff of Wingers Publishing for transforming our concepts into reality.





## Foreword

---

**A**vian medicine has been an integral part of veterinary medicine for a long time, but still relatively few veterinarians include members of the avian species among their patients. This is rapidly changing as companion birds become increasingly popular. The economic and emotional value of these pets is significant. Veterinarians who have adequate education and talent to provide services for companion and aviary birds have a competitive advantage in private practices.

*Avian Medicine: Principles and Application* fills a critical need for a reference and medical text capable of raising the standard of veterinary care for birds. It can be predicted that users of this text will become more competent, provide improved service to their patients and clients and, realizing their limitations, understand when to refer cases to colleagues with more expertise. The scope of this work is comparable to that of other reference texts that have been available for many years for most of the other animal species with which veterinarians practice their art and science. For companion avian practitioners, the book documents the scientific basis for veterinary practice that benefits these animals. *Avian Medicine: Principles and Application* also marks a stage in the maturity and acceptance of avian species as patients for veterinary practitioners.

Veterinarians and other scientists interested in the avian species will recognize the considerable efforts that the editors and authors have made. *Avian Medicine: Principles and Application* is rooted in fact and made relevant to practice by the experience of the

contributors. These experiences, when combined with scientific facts derived from dispersed literature sources as a foundation, plus the excellent illustrations, come together in a way that makes *Avian Medicine: Principles and Application* a powerful tool for education.

Education in avian medicine is expanding in some of our veterinary colleges. Some colleges have strong, internationally recognized programs in poultry and/or companion avian medicine. These programs are likely to provide centers of excellence for all veterinary students interested in birds. This book will be a resource to stimulate and enhance that student interest.

Avian medicine has a great future. New standards based on comprehensive scientific information are available. In the past, much empirical or clinical experience information was held by relatively few practitioners. Their experiences, while shared through traditional continuing education programs and some publications, were not widely accepted as having a strong scientific foundation. This book provides critical linkage between scientific data and clinical experience. Time will prove the acceptance and usefulness of the efforts of the editors and authors. I commend them for their contribution to veterinary medicine and appreciate having this opportunity to provide a few introductory thoughts.

Oscar J. Fletcher, Dean  
College of Veterinary Medicine  
North Carolina State University  
Raleigh, North Carolina



# Preface

---

---

**W**ith the increased need for competent avian practitioners and the formation of avian specialty programs worldwide, clinicians as well as academicians will be required to have a more comprehensive understanding of applied anatomy, physiology, internal medicine, pharmacology, disease management and preventive medicine.

*Avian Medicine: Principles and Application* has evolved to reflect this change and provides its readers with a definitive reference text that blends the science of health with the art of clinical medicine.

This book was designed to provide relevant information for every reader: it introduces the beginner to avian medicine; it provides a learning opportunity for the veterinary student; it stimulates the seasoned practitioner to expand and deepen his diagnostic and therapeutic skills; and it heightens the awareness of the avicultural community to state-of-the-art medical care.

By applying the information presented in this book, the competent avian practitioner will be able to effectively provide the highest quality care for his patients and guide the companion bird client or aviculturist in implementing an effective preventive health program.

Beginning practitioners can learn basic evaluation, support and surgical techniques while developing an expanded understanding of advanced procedures that can be performed by specialists in avian medicine and surgery.

Most of the principles in this book have been detailed with respect to psittacine birds. In general, these principles can be applied to the care of other avian species. For example, information presented in the endocrinology, theriogenology, cardiology and flock management sections of the book may be applicable to ratites, pheasants or waterfowl.

With the restriction of bird imports, it is now necessary for aviculturists to produce all companion birds in the United States. The success of this endeavor will depend on continued exchange of knowledge be-

tween the aviculturist and the veterinarian. It is hoped that this book will emphasize the importance of this liaison, even if in a consulting capacity.

According to philosopher Emmet Fox, "The mere acquisition of fresh knowledge received intellectually makes no change in the soul." Likewise, scanning the book for drug doses will not improve the quality of one's avian practice. A commitment to studying and applying the principles set forth in this book will.

Readers may be encouraged to approach this book, especially some of the comprehensive "core" chapters, from a new perspective. For example, study groups may be developed to systematically examine the individual chapters and discuss their application to the care of birds.

No matter how the book is approached — from group study, individual investigation or as reference for a clinical case, the challenge to the reader is to improve the health of birds by fully applying the information provided in this text.

Advancement in the field of avian medicine will require all interested individuals and allied industries to provide the means necessary to advance our understanding of birds through sound, well designed, clinically relevant research. It was the intention of the authors and editors of this book to stimulate its readers to become actively involved in the advancement of avian medicine.

Although the amount of information concerning the care of companion and aviary birds is increasing at incredible speeds, there are times when one has to concede that, with regard to avian medicine we don't even know what we still don't know. This paradox can only be resolved by constantly investigating the unknown, and applying newly derived information to the resolution of identified problems.

Branson W. Ritchie, DVM, PhD  
Greg J. Harrison, DVM  
Linda R. Harrison



## Prologue

---

---

# Avian Conservation: The Veterinarian's Role

Robert Groskin

What is the role of the avian practitioner in avian conservation? How can a conservation philosophy be integrated into veterinary practices? What are the current issues in avian conservation science?

A conservationist is an individual who advocates for the planned preservation of natural resources. The roots of conservation can be found with early man, who lived at a time when there was ample food and land. A hunter's success was believed to be based not on his skill, but on his ability to show ample respect for his prey, whereupon his prey would present itself to him. In return, the hunter would perform a ceremony, releasing the animal's spirit. In this way the animal could return to replenish the herds of antelope or schools of fish. Joseph Campbell characterizes this concept as the beginning of religion.<sup>3</sup> Perhaps it was also the beginning of conservation.

Early Native Americans correctly saw no difference between man and animals. They believed that all beings were brothers and sisters. All creatures had knowledge to impart. Man, being the youngest creature, had the most to learn. The Plains Indians considered the two-legged creatures (eg, man, birds, bears) to be healers, and these creatures needed to work together to correct the imbalances of nature.<sup>4</sup> By demonstrating humility and respect toward their brothers, man believed the other animals would share their knowledge.<sup>4</sup> The three concepts of 1) oneness with nature, 2) humility and respect for nature and 3) a desire to care for and protect one's brother or sister have become fundamental ideas of contemporary conservation philosophy and stewardship.

---

---

*"In the end we will  
conserve only what we  
love, we will love only  
what we understand,  
we will understand  
only what we are  
taught."*

*Baba Dioum, Senegal*

---

---

Modern conservation philosophy is expressed in many of the ideas of Aldo Leopold, forester, writer and conservationist. He recognized man's increasing isolation from nature and his need to relate in some way to nature and to life on earth, from both an evolutionary and ecological perspective (defining to some extent the human-animal bond).<sup>12,14</sup> Leopold had a strong love and respect for the forest, and as a landowner maintaining his property, he had to choose which trees needed to be felled. To him, the best definition of a conservationist was "written not with a pen, but with an axe. It is a matter of what a man thinks about while chopping, or while deciding what to chop. A conservationist is one who is humbly aware that with each stroke he is writing his signature on the face of his land. Signatures of course differ, whether written with axe or pen, and this is as it should be."<sup>14</sup>

As avian practitioners, what do we think about when we are treating our patients? Are we aware of the connection between ourselves and our patients? When we treat our avian patients, do we see them as brothers and sisters? Do we demonstrate humility and respect for them such that we in our role as healers may learn from them? Do we see our role as stewards extending beyond the examination table? How can we help ourselves, each other and our clients develop an ethic "to correct the imbalances in nature" that we have created?

## Man and Birds

---

Humans have related to birds primarily as consumers, using birds for recreation, as food and as religious symbols.

### Historical Affinity

---

In Medieval times, falcons were symbols of authority and were used for recreation and hunting. In the 18th and 19th centuries as European cities grew, wealthy landowners wanted their estates to resemble more "natural" settings. They collected live birds, especially waterfowl, and established private mini-zoological gardens.

Colonialism exposed wealthy Europeans to birds from other continents, and large outdoor aviaries

were built for non-indigenous species. Commercialization of trade in live birds for indoor and outdoor exhibits and bird products (eg, skins, feathers, eggs) grew during this period. In the mid-19th century, curators were hired to manage some of the largest collections of bird skins. Their studies heralded the emergence of ornithology as a separate biological science.<sup>11</sup>

Ornithology attracted considerable attention among the scientists of that time. Some of the basic questions that were asked in the early 1800's dealt with the distinction between varieties and species, what determined the distribution of the various species, and what was the relationship between extinct and living species. The discussion of these topics set the framework for much of Darwin's hallmark thesis, "The Origin of Species."<sup>9</sup>

The consumption of birds purely for collection still exists today, but on a much more limited basis. As avian veterinarians, one of our primary responsibilities is to educate our clients about the responsibility of individual companion bird stewards and to discourage the "collection" mentality.

The ornithological community is currently debating the need for collecting and killing birds for scientific study.<sup>7</sup> Some ornithologists have captured new species to study them in the laboratory and later released the birds back into the wild.<sup>8</sup>

### Modern Relationships

---

The common thread for recreational use of birds today, which includes hunting, falconry, watching and photographing activities, feeding, pet ownership, rehabilitation and aviculture, is the individual's desire to contact nature. People seek to contact their roots and appreciate the oneness of life around them. Conservation reflects a "state of harmony of man and the world he lives in."<sup>14</sup> It provides an understanding of man's past and present roles on earth, which guides the future roles. The recreational uses of birds can enhance conservation when they increase that understanding. Recreational uses of birds have the greatest value when they do not impact on free-ranging bird populations.

Bird watching, photographing and feeding have minimal effects on bird populations and benefit both humans and birds.

Approximately 34% of Americans either photograph birds or watch birds. Bird watchers have been re-

## PROLOGUE

sponsible for the collection of large databases concerning bird populations, habitats, breeding sites and numbers, migratory patterns and other biologically related statistics.<sup>20</sup> As a result of their amateur wildlife research, bird watchers provide invaluable scientific information and simultaneously enhance their own appreciation for the integrity of our entire ecology.

A 1989 survey of non-hunting recreational activities revealed that 46% of Americans feed birds either in parks or at backyard feeders.<sup>9</sup> This activity helps children develop an appreciation for wildlife and a conservation ethic. Seasonal group bird counts and surveys provide demographic data regarding wintering species.<sup>20</sup>

### Rehabilitation

Because of their interest in birds, avian veterinarians are often called upon to treat injured native birds. Assisting injured wildlife offers an opportunity for the veterinarian to expand the public's understanding of avian conservation. Many native birds are protected by federal and state laws and permits are required for veterinary care and even short-term possession of these species. Developing a relationship with a qualified rehabilitator could be helpful to both the rehabilitator and the veterinarian. The care of certain native species, ie, endangered or threatened species, should be undertaken only by veterinarians experienced in the care of these birds and with suitable facilities. Wildlife rehabilitation centers are always in need of volunteers. Clients who have demonstrated a strong interest in wildlife should be encouraged to volunteer at these facilities.

### Hunting

Hunting as a recreational use of birds consists of two categories: hunting free-ranging wildlife and hunting stocked species. In terms of conservation ethics, hunting stocked wildlife is similar to the consumptive use of birds for food. Contemporary hunting of free-ranging birds initially was useful as a conservation management tool. Bag limits today, however, function to preserve the species, not to help reduce excess populations. Hunting has conservation value when the hunter appreciates both his prey and the environment of the animal. With the use of high-tech equipment, the hunter has become more isolated from his prey; consequently, the experience provides less conservation value. Some hunting groups (eg, Ducks Unlimited) are actively engaged in habitat preservation.

Falconry is one of the oldest recreational uses of birds. Falconers have been successful in breeding and reintroducing falcons. Of the 566 raptors bred in captivity in the United States in 1988, 25% were used for reintroduction programs, 50% for falconry and 25% were returned to captive-breeding programs.<sup>6</sup>

### Aviculture

Aviculturists support avian conservation by using birds already in captivity for their breeding programs to decrease the need for importation. The chicks they produce for the companion bird market will further reduce the pressure on wild populations. In addition, the knowledge they gain from captive breeding efforts is used by field biologists to more effectively evaluate and manage native populations. Avian veterinarians can bridge the gap between aviculturists, biologists and conservationists by encouraging the sharing of knowledge and experience.

The success of the Peregrine Falcon, California Condor and Whooping Crane breeding programs is due, in part, to the commitment of aviculturists to conducting in-depth studies of a single species. This focus saves time and money and prevents the dilution of energies that often occurs with aviculture programs that involve a variety of different species.

Some areas of the United States seem to be better suited for the breeding of some species. The concept of focusing avicultural efforts on bird species that breed well in a certain geographic region needs to be carefully considered.

### Companion Birds

The recreational use of birds as pets has had a profound and permanent effect on the population of many free-ranging bird species.<sup>6</sup> From a conservation perspective avian veterinarians should encourage clients to continue to buy domestically raised or ranched birds, thereby supporting captive breeding and sustained harvesting, and thus relieving pressures on native populations.

In addition, clients should be educated about the physical and emotional needs of their companion birds, thereby ensuring the health and welfare of the birds and increasing the involvement of the owners with their bird. The goal is to change the nature of the relationship from one of consumptive ownership to a companionship/stewardship relationship.

## Conservation Biology

Conservation is a science as well as a philosophy. Avian populations, especially psittacines, have experienced recent dramatic declines. Of the nearly 330 Psittacidae species that are seriously threatened or at risk of extinction, most are a result of habitat loss and the pet trade.<sup>6</sup> Considerable efforts are being made by conservation biologists to halt these losses. Figure 1 summarizes the current approaches to parrot conservation.<sup>14</sup> Many of these methods are equally valuable to other species.

One of the key approaches to conservation of neotropical parrots involves aviculture. Working with the aviculturist, veterinarians can help provide healthy birds for the pet trade. The advances in avian theriogenology, neonatology and pediatrics discussed in this text are not only useful for the pet trade but are essential for the success of species survival plans (SSP) for endangered species, sustained harvesting of parrots and reserve management. Some species exist today only in captivity. Maintaining a viable genetic pool of these birds is essential.

There are many questions regarding captive breeding. Are the progeny of these birds releasable in their native habitat or non-native habitats? Are there genetic changes that result from captive breeding that might affect the ability of captive-bred birds to survive in the wild? What are the risks of introducing diseases to native populations or altering the ecology of the habitat with the introduction of captive-bred birds?

### Domestication of Companion Bird Species

With the exception of budgerigars, cockatiels, canaries, pigeons and lovebirds, the psittacine birds we see in practice today are a blend between free-ranging and domestic. As a consequence of domestication, there are behavioral and anatomic changes which become evident within the first few generations. The behavioral changes include three major characteristics: docility, curiosity and a disrespect of species barriers.<sup>15</sup> All three of these characteristics are considered neotenic, ie, youthful, traits.

In an avicultural setting, individuals displaying neotenic behavioral characteristics would most likely be favored by the aviculturist.

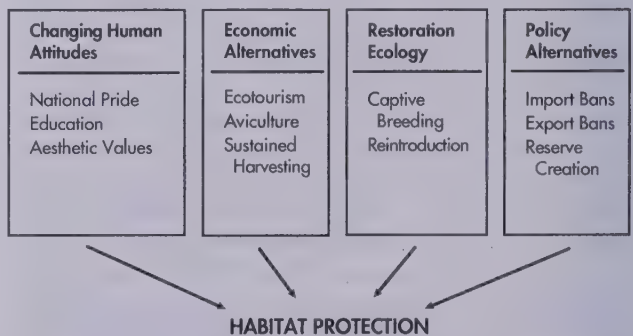
What effects does domestication have on resistance to disease? Younger animals tend to have an increased susceptibility to disease. Will domestication and the favoring of neotenic traits also lead to an increase in disease? Are more diseases being found in companion birds than in their free-ranging counterparts because companion birds are more easily studied, or is the effect of captivity and domestication increasing susceptibility or exposure to disease?

Infection is difficult to assess in free-ranging birds. The relationship between parasite and host is carefully balanced in nature. What effect will domestication have on this relationship? Will, for example, subclinical parasites such as *Haemoproteus* sp. become more significant diseases with increased domestication?

Are the reproductive problems associated with cockatiels a result of their domestication? Why are there so few flocks of budgerigars and cockatiels found in non-native habitats? Escape from homes is very common, yet flocks of these birds are established only in limited areas. Have these domesticated birds lost much of their ability to survive?

Research on White-naped Crane eggs has shown that the microclimate surrounding these large eggs is actually a substantial thermal gradient. Incubated eggs do not have any temperature gradient. Is this microclimate essential for successful hatching of

#### APPROACHES TO PARROT CONSERVATION



**FIG 1** A general scheme of approaches to conserving neotropical parrots (courtesy of Bessinger SR, Snyder N (eds): *New World Parrots in Crisis*. Washington DC, Smithsonian Institution Press, pp xiii, 1992).





**FIG 2** Preservation of native habitat is a major challenge in the conservation of bird species.

large eggs? Does this thermal gradient have a specific function? How is the phylogeny of incubator-hatched birds being affected?<sup>17</sup>

Over a century ago, Darwin and Wallace proposed conflicting views about the origin and function of prominent male secondary sexual features and their effects on the female's choice of a mate. Research and debate on this subject is still very intense today.<sup>18,19</sup> How are genetics, resistance to disease and reproductive strength of avian species being altered when birds are artificially paired? How large a flock is needed to allow mate selection and adequately protect the genetic pool? Is valuable genetic stock being removed by hybridization of easily bred species? Should this practice be discouraged in order to preserve as much of the gene pool as possible?

Aviculturists who intend to provide birds for reintroduction programs will need to establish specific flocks for this purpose that are separate from birds intended for pet trade purposes. These birds must be maintained and managed differently from companion birds to minimize the effects of domestication. Individuals who have committed themselves to such

an endeavor face difficult economic and scientific obstacles. As avian veterinarians, we need to acknowledge, encourage and support these valiant efforts.

### ■ Harvesting

Avian veterinarians will need to play a significant role in the sustained harvest, or ranching, of birds. Ranching differs from captive breeding in that the breeder flock is not removed from its native habitat. The number of offspring "harvested" is based on the local site biological data.

Parrots appear to have considerable potential as a sustainable harvest. They can be harvested as nestlings (low reproductive value) and require minimal captivity time before reaching the market. Both large and small landowners can participate, and there is considerable potential to increase harvests through existing management techniques.

Because habitat protection is an integral part of successful ranching, this method of conservation has the

potential to protect not only the species being ranched but the entire ecology.

Some of the problems associated with harvesting include the social and political structures needed to allow for the lawful export of the harvest, protection of the birds from poaching and over-exploitation, fluctuations in demand for birds, ensuring that importation of these birds does not increase the level of young taken from the wild and the need to develop adequate data upon which to base harvesting levels.

Avian veterinarians may play an important role in the prevention of disease on the ranch and during the collecting and shipping stages. The use of herpesvirus and poxvirus vaccines and DNA probes to detect birds subclinically infected with PBFV virus or polyomavirus are examples of contributions avian veterinarians can make to enhance sustained harvesting.

### ■ Captive Breeding and Reintroduction

When faced with imminent extinction, captive breeding with the goal of reintroduction remains the only alternative for preservation of a species. The conservation community is not in full agreement about captive breeding of endangered and threatened species because of the many scientific, economic and political considerations involved.

However, before a captive breeding program for a species can be established, several questions need to be asked. What is the appropriate time to start a program? How many founding members are needed to ensure an adequate gene pool? Where will this program be based and is the institution willing to provide sufficient economic and administrative commitment to sustain such a program for the period of time needed for reintroduction? If not based in a public institution, does sufficient cooperation and accountability exist among private breeders to ensure a successful breeding program? How has the issue of ownership of progeny been resolved?

Although many technologies exist to aid these programs, the species that require captive breeding assistance often have a poor level of reproductive success in captivity. As mentioned above, genetic changes in captive breeding may develop within the first few generations, necessitating reintroduction as soon as possible to ensure the maintenance of wild-type breeding stock.

The potential for introducing diseases common in captive populations into native populations as a result of releasing birds is a significant consideration. To prevent losses, the flock must be divided into viable groups, managers must be attentive to husbandry and sanitation and movements must be restricted between populations. Avian veterinarians will be important members of the management teams.

With a decrease in available habitat, all the factors for disease transmission among free-ranging birds (eg, nutrition, increased proximity, stress) become more significant. Conservation biologists are concerned that these aspects not be neglected.<sup>22</sup> The role of the avian veterinarian will become more important in helping to assess disease in free-ranging avian populations.

Psittacines have the potential for reintroduction once appropriate criteria have been met. Factors that contributed to the decline of the native population must be modified sufficiently in order for the newly released birds to survive. Habitat protection, predator control, harvest of free-ranging birds and reduction of human activity, both recreational and commercial, must also be considered. Until we have a greater understanding of how these and other factors affect populations, release of captive-bred psittacine birds may not be an effective conservation method.

Under some circumstances it may be preferable to establish new populations in previously non-native but suitable habitats. The impact of these introductions needs to be thoroughly evaluated to minimize any risks to the native species and habitat.

### ■ Treaties and Legislation

Trade in neotropical parrots has played a significant role in the decline of these species, affecting perhaps as many as 17% of the endangered neotropical parrots. Trade and habitat destruction affects an additional 36% of these species.<sup>23</sup> Attempts to control this trade include legislation designed to decrease or eliminate the import and export of these species. The Convention on International Trade in Endangered Species (CITES) is the most important international treaty affecting avian conservation. The 1992 CITES meeting in Japan focused on the issue of bird trade. New procedures enacted at that meeting allow the Standing Committee of CITES to immediately halt trade in an Appendix II species (species for which careful management is required to ensure that trade

remains sustainable) or to stop trade altogether from a treaty member of CITES. These changes have the potential to significantly improve the situation for these endangered and threatened species.

Until 1992, all United States legislation effecting trade in wild-caught birds was at the state level. In 1984, New York State was the first state to enact legislation banning the importation and sale of wild-caught birds. This ground-breaking law sought to establish importation restrictions that would be enforceable, not result in an increased rate of smuggling or diseased birds and allow for the growth of the avicultural industry. One of the major impacts of this type of legislation was to increase the public's awareness of avian conservation.

### Wild Bird Conservation Act

Ultimately the conservation community, aviculturists and the pet industry realized it was in the interest of all parties' to ensure the continued survival of wild bird species. After several years of discussions and negotiations, the Wild Bird Conservation Act of 1992 was enacted. This is the most significant legislation affecting the importation into the United States of wild-caught birds. Avian veterinarians contributed to the passage of this act. Provisions of this act require certification of foreign breeding facilities by the U.S. Fish and Wildlife Service. Input by avian veterinarians will continue to be needed in this area.

One important goal of these types of legislation is to help ensure protection for wildlife in foreign countries equal to the protection we provide for our own wildlife.

No single act will have as much influence on the avian practitioner as the Wild Bird Conservation Act. What will be the effect of domestic breeding on the population of companion birds? What will be the effect on diseases of pet birds as a result of their increasing domestication? How will the pet bird differ from the wild bird? With a shrinking habitat and increasing human population, almost all species are feeling the presence of humans, both directly and indirectly. By watching carefully the effects of domestication on "wild" species of birds, we might be able to anticipate and prevent those changes in other species we want to keep "wild." The avian veterinarian is observing in practice what ecologists in the field have only been able to theorize. These observations can be of extreme importance to the conservation of many species.

In summary, conservation is both a science and a philosophy. Only when avian veterinarians have defined their own conservation ethic, can they help companion bird clients and aviculturists better understand their roles in conservation biology. Avian veterinarians can work together with conservationists, aviculturists and biologists to continue to improve the welfare of all birds.

### References and Suggested Reading

1. **Bessinger SR, Bucher EH:** Sustainable harvesting of parrots for conservation. In Bessinger SR, Snyder N (ed): *New World Parrots in Crisis*. Washington DC, Smithsonian Institution Press, 1992.
2. **Budiansky S:** *The Covenant of the Wild*. New York, William Morrow and Co, 1992.
3. **Campbell J:** *The Power of Myth with Bill Moyers*. New York, Doubleday, 1988.
4. **Caduto MJ, Bruchac J:** *Keepers of the Animals*. Golden, Fulcrum Publishing, 1991.
5. **Collar NJ, Juniper AT:** Dimensions and causes of the parrot conservation crisis. In Bessinger SR, Snyder N (ed): *New World Parrots in Crisis*. Washington DC, Smithsonian Institution Press, 1992.
6. **Clubb S:** Private Aviculture in Conservation of Neotropical Psittacines. In Bessinger SR, Snyder N (ed): *New World Parrots in Crisis*. Washington DC, Smithsonian Institution Press, 1992.
7. **Clutton-Brock J:** *A Natural History of Domesticated Mammals*. Austin, University of Texas Press, 1987.
8. **Collar NJ, Andrew P:** Birds to Watch, the ICBP World Checklist of Threatened Birds. Washington DC, Smithsonian Institution Press, International Council for Bird Preservation Tech. Publ No. 8, 1988.
9. **Darwin C:** *The Origin of the Species*. New York, Penguin Group, 1958.
10. **Derrickson SR, Snyder N:** Potentials and limits of captive breeding in parrot conservation. In Bessinger SR, Snyder N (ed): *New World Parrots in Crisis*. Washington DC, Smithsonian Institution Press, 1992.
11. **Farber PL:** The Emergence of Ornithology as a Scientific Discipline: 1760-1850. Dordrecht, Holland, D. Reidel Publishing Co, 1982.
12. **Flader SL, Callicott JB:** *The River of the Mother of God and Other Essays by Aldo Leopold*. Madison, Wisconsin, The University of Wisconsin Press, 1991.
13. **Keller SR:** Human-Animal Interactions. In Rowan AN (ed): *Animals and People Sharing the World*. Hanover, University Press of New England, pp 137-175.
14. **Leopold A:** *A Sand County Almanac*. New York, Oxford University Press, 1949.
15. **McLennan DA, Brooks DR:** Parasites and Sexual Selection. *Quarterly Review of Biology* 66(3): 255-286, 1991.
16. **Nettles Jr VF:** Wildlife diseases and population medicine. *J Am Vet Med Assoc* 200(5):648-658, 1992.
17. **Rennie J:** Living Together. *Scientific American*, Jan, 1992.
18. **Scott M:** The Impact of Infection and Disease on Animal Populations. *Conservation Biology* 2(1):40-56, 1988.
19. **Simon I:** New York's Crusade for Exotic Birds. *Defenders*, Nov/Dec, 1990, pp 26-30.
20. **Socha LO:** *Birding for the Amateur Naturalist*. Chester CT, The Globe Pequot Press, 1989.
21. **Wall Street Journal:** April 11, 1989, pB1(W).

---

## CHAPTERS

### 1 THE AVIAN PATIENT

Ross A. Perry

### 2 THE AVIAN FLOCK

Susan L. Clubb  
Keven Flammer

### 3 NUTRITION

Randal N. Brue

### 4 PERSPECTIVE ON PARROT BEHAVIOR

Greg J. Harrison

### 5 DEFENSE MECHANISMS OF THE AVIAN HOST

Helga Gerlach

### 6 FUTURE PREVENTIVE MEDICINE

Branson W. Ritchie

---

---

**I**

---

---

## SECTION ONE

# THE COMPANION BIRD

---

---

**I**



CHAPTER

---

# 1

## THE AVIAN PATIENT

---

Ross A. Perry

**V**eterinary medical decisions are often made by comparing the similarities and differences that occur between individual patients and an established animal model.

This comparison concept is functional because of the relative similarity between a collie and a poodle, or a Persian and a Siamese, or a holstein and an angus. Any respective difference in anatomy or physiology or in an animal's response to a drug or infectious agent is easy to qualify when compared to a generic species model.

Not so, with the avian patient. In a single day, an avian practitioner may be presented with patients that belong to five different orders. Each of these orders is unique, having evolved specific anatomic, physiologic and behavioral characteristics that allow effective competition in a specific ecological niche. Which of the numerous avian genera will serve as an appropriate comparative model (ie, generic bird patient)?

The avian clinician can be most effective by disposing of the philosophical handicap of basing medical decisions on a generic companion bird. Instead, the veterinarian must look for the natural differences that exist in patients from such diverse geographic locations as a rain forest and an African savannah.

There is not a wealth of scientifically derived information available, particularly with respect to variances in avian dietary adaptations, behavioral characteristics and response to drug preparations and infectious agents. The clinician must compensate by applying a broad medical checks-and-balances system based on the use of numerous diagnostic and therapeutic tools. Medical management decisions for a particular genera within an order must be based on the interpretation of several changes that indicate that an abnormality is truly an abnormality. For now avian veterinarians will continue to be required to diagnose and treat many medical problems subjectively until results from avian research efforts begin to satisfy the demand for information.

In developing a health plan, clients and veterinarians must strive to view the world from the bird's perspective, and, in so doing, caretakers will have greater empathy for the emotional as well as the medical needs of the bird. If the complete needs of a bird are not met (nutritional, environmental and psychologic), disease will inevitably follow. The veterinarian must prescribe health, not drugs. By being familiar with the behavioral attributes and species-specific medical problems that may occur, a veterinarian is more likely to recognize early signs of disease in an individual bird of a given species.

## Selection of Companion Birds

Birds are remarkable life forms with individual behavioral and personality characteristics. These characteristics are the result of a complex and often changing interaction of environmental influences that include food availability, seasonal weather conditions and flock dynamics. From a companion bird's perspective, flock dynamics involve the interaction of family members with each other and with the bird.

In providing exceptional care and management advice, the veterinarian can become a model for responsible companion bird ownership. Unfortunately, many individuals obtain a bird for the wrong reasons (Table 1.1), instead of for the purpose of adding an intelligent, sensitive being to the family.

**TABLE 1.1 Misguided Reasons for Choosing Birds as Pets**

- Entertainment
- Amusement
- Admiration
- Material acquisitions
- Self-admiration ("He says my name!")
- Toys for adults
- Toys for the children
- Didn't want to see it suffer in the pet shop.

Some clients rarely handle their birds, even if they do not bite. To highly social birds, this forced isolation must be a fate worse than death. Most clients are very appreciative of some supervised training from their veterinarian on how to handle their bird, but may be reluctant to ask for guidance (see Chapter 4).

## Bird Attributes

Individual clients are likely to differ as to which attributes of companion birds are desirable and which are undesirable. Before choosing a companion bird, a client may want to give careful consideration to the following questions:

- Is it possible to tame and touch this bird?
- How big does its enclosure need to be?
- How much exercise does it need? Can it take care of all of its exercise needs within the enclosure?
- Does this species bond to one person and resent others, or is it likely to allow and enjoy companionship from several people?
- What are its dietary requirements and what is involved in daily maintenance?
- Are its eating habits and droppings messy?
- What is its expected life-span? 3-5 years? 5-10 years? Over 20 years?
- Does this species have a tendency to pick its feathers?
- How susceptible is this species to disease?
- Does this bird have singing ability?
- What is the potential of this species for screeching, screaming or chewing?
- Is this species known for its talking (mimicking) ability? (Table 1.2)
- Does this individual fulfill expectations for physical beauty in a bird?
- Will this bird be a source of disease for family?
- How expensive is the bird to buy and maintain?
- How much time does the bird require?

**TABLE 1.2 Species With Potential Mimicking Ability**

- African Grey Parrots - male, individual variability
- Mynah bird
- Double Yellow-headed Amazon
- Yellow-naped Amazon
- Blue-fronted Amazon
- Macaws - genus Ara
- Eclectus Parrot
- Budgerigar

By learning more about the characteristics of individual species, the client is able to make a more informed decision. Avian veterinarians and aviculturists should also strive to match the correct personality of a bird with the personality of an owner. For example, Table 1.3 presents a brief reference guide to some well known characteristics of popular companion bird species. Bird clients who understand

the “uniqueness” of avian species are usually happy with their birds’ qualities (Figure 1.1).

### Wild-trapped and Imported Birds

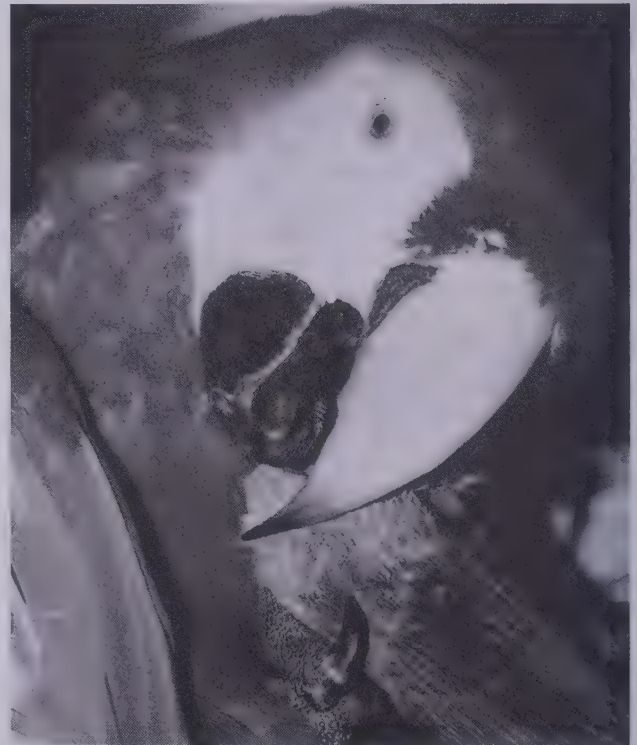It is the belief of the author and editors that to be effective messengers for conservation and responsible stewardship, every avian veterinarian and aviculturist must strive to understand the damage induced by the harvesting of wild-caught birds, and to take every perceivable opportunity to stop these activities. If companion birds are to be relinquished to flightlessness, they should be individuals that were produced in captivity as companion birds and have never understood flight. Additionally, the trappers, brokers, dealers and consumers that trade (illegally, in most instances) in rare and endangered animal life (frequently under the guise of avian conservation) should be viewed by the community with great disdain. Protecting dwindling habitat should be the focus of individuals truly concerned with avian conservation.

Additionally, the international movement of wild-caught birds undoubtedly results in the spread of infectious agents that could have far-reaching and devastating effects on indigenous avifauna. Wild-caught birds that escape into suitable habitats can establish viable populations that irreversibly alter the habitat of native species (eg, European Starlings, Common House Sparrows). Captive breeding programs can more than sufficiently supply consumers with the bird species that make the best companions.

### Captive-bred, Hand-raised Birds

Captive-bred, properly hand-raised birds make better pets than their wild-trapped conspecifics; however, malnutrition, candidiasis, stunting and various leg, toe, nail and beak deformities can occur in captive-raised birds. This is especially true if the birds are cared for by novices or in large breeding aviaries where caretakers lose sight of the needs of the individual neonate. Bonding and breeding behavior in captive-bred and hand-raised birds (eg, masturbation, bizarre courting and behavioral rituals, excessive feather plucking and self-mutilation) can occur in improperly socialized birds as they reach sexual maturity. Male birds rubbing their backside and leaving “water” on their owner’s hand is a common and notable example. Some clients will not accept that the bird is masturbating and needs behavioral modification support (see Chapter 4).

Some species such as Rose-breasted Cockatoos, large macaws, conures, Monk Parakeets and Sulphur-



**FIG 1.1** Important behavioral characteristics to consider when selecting companion birds are their tolerance for handling, their tendency toward destructive behavior and their likelihood to scream. In general, hand-raised Umbrella Cockatoos tend to seek affection from multiple family members and are relatively quiet. Larger macaws are beautifully colored and playful, but they can be quite loud, tend to be destructive and usually develop a relationship with an individual family member.



**TABLE 1.3 Profiles of Common Companion Birds (Some characteristics are rated on a scale from 1 to 10, with 10 being the highest value.)**

<p><b>African Grey Parrots (Africa)</b> Excellent talkers - individual variability (9) Extremely intelligent - high-strung Prolific breeders once initiated Require attention (10) Relatively playful (8) Tend to form individual bonds</p> <p><b>Amazon parrots (Mexico to South America)</b> Few enjoy "petting" Excellent talkers (9) species-dependent Extroverted personalities Aggressive during breeding season Tend to form individual bonds Require attention (9)</p> <p><b>Budgerigars (Australia)</b> Gregarious - easily tamed (10) Good talkers but require work (7) Quiet and nondestructive Wild-type are most disease-resistant Relatively gentle (7)</p> <p><b>Canaries (Australia and Africa)</b> Color mutations are genetically weak Breed prolifically in captivity Males are vocal singers Tidy and easy to care for Do not like to be handled</p> <p><b>Cockatiels (Australia)</b> Excellent companion birds (10) Easily tamed and gentle (9) Quiet and nondestructive (8) Good whistlers - limited talkers Mutations - weak</p>	<p><b>Cockatoos (Australia, New Zealand, South Pacific Islands)</b> Require attention (10) Scream if neglected Crave physical contact (10) Hand-raised Umbrella Cockatoos are extremely gentle (9) Intelligent, easily house-trained Produce abundant powder (10) Can be noisy; destructive; must be socialized Mate aggression is common, particularly in Sulphur-crested group</p> <p><b>Conures (Mexico to South America)</b> Species variability Smaller species are gregarious and playful (9) Enjoy and seek attention (9) Noisy and destructive (7) Generally poor talkers</p> <p><b>Eclectus Parrots (Australia and South Pacific Islands)</b> Generally lethargic and unplayful Dimorphic (males=green, females=red) Males are more gentle than females Tend to form individual pair bonds</p> <p><b>Finches (Australia and Africa)</b> Melodious songs Short-lived</p> <p><b>Lories, lorikeets (Australia, South Pacific Islands)</b> Colorful, playful, active Noisy and limited talking ability High-carbohydrate liquid diet; messy Frequently bathe</p>	<p><b>Lovebirds (Africa)</b> Relatively nondestructive, quiet Hand-raised birds are calm Parent-raised birds are difficult to tame</p> <p><b>Macaws (Mexico to South America)</b> Extremely intelligent Require attention (10) Can be destructive Require large living space Tend to be noisy (10) Aggressive during the breeding season Blue and Gold most family-oriented Hyacinth - least noisy and most mellow</p> <p><b>Mynahs (India)</b> Prefer not to be handled Good talkers (7) Loose, messy droppings Nondestructive</p> <p><b>Pionus parrots (Mexico to South America)</b> Small and quiet May hyperventilate when disturbed Highly stressed High altitude species cannot tolerate heat and humidity</p> <p><b>Toucans (South America)</b> Quiet and antic Prefer some live food (rodents) Highly territorial Messy, loose droppings</p>
---	---	--

crested Cockatoos are particularly prone to excessive bonding and self-mutilation secondary to separation anxiety. Other species may become suddenly aggressive toward a family member. Excessively bonded Bare-eyed Cockatoos (Little Corellas) can become quite "spiteful." These pets are less appropriate in families where the bird will remain alone for long periods. The "mini" macaws, smaller Amazon parrots, Pionus parrots, *Poicephalus* species and Umbrella Cockatoos are less likely to develop these traits. These problems can be prevented in most birds by an effective socialization program when the bird is young. Repeated generations of captive birds become increasingly docile and more adaptive to captivity.

### Taming Companion Birds

Young, hand-raised Psittaciformes adapt readily to new surroundings and handling procedures. They should be exposed early in life to novel situations (eg, car travel, hospital visits, multiple visitors in the household, other household pets) so that they are well adjusted to these events. Older birds, especially wild-caught adults, are usually very difficult to tame. Patience, self-discipline, a sense of ritual, food brib-

ery and reward are necessary to tame some adult birds (see Chapter 4). Even then, they are rarely trustworthy and may bite without provocation.

### Genetic Factors

The physical and psychological characteristics of a bird are influenced by genetic factors interacting with aspects of management and disease. Some attributes are common to most individuals within a species. Others are peculiar to particular strains of birds that have been selectively bred over many generations in captivity.

Determining the physical and behavioral attributes of related birds, especially the parents and siblings, can be of value in selecting a companion bird. It should be noted that large Psittaciformes have the capacity to live as long as humans, and adding a large psittacine bird to the family should be undertaken as a life-long commitment. Knowing the genetic background and characteristics of the relatives of a bird is particularly critical when choosing a pair of breeding birds.

### Color Mutations

Color mutations are highly valued by many aviculturists. The specific genetics involved in establishing these color mutations are discussed in a number of avicultural publications. It should be noted that mutations in color are generally the result of continued inbreeding. In selecting for particular color mutations (eg, lutino cockatiels), scant priority is placed on other important attributes, so that decreased disease resistance, disorders, reduced longevity and birth defects often result. In Australia, clinical impressions suggest that there is a higher incidence of PBFV virus in the color mutations of Peach-faced Lovebirds than in wild-type green lovebirds.

### Conformation and Size

Conformation of birds is influenced by genetic factors. This is most apparent when comparing the different breeds of canaries and budgerigars. Currently, show budgerigars are approximately twice the mass of their free-ranging conspecifics. Attempts to produce larger birds has also led to numerous undesirable characteristics including feathering that impairs flight, interferes with normal ambulation, accumulates excrement pericloacally and protrudes across and sometimes into the cornea.

### Longevity

Longevity, the potential maximum duration of life for a species, has little relevance to exhibition or show bird breeders (who discard imperfect nestlings and older breeding birds) but should be of critical importance to the companion bird client. Some highly bred strains of birds may have life expectancies one-third to one-tenth the duration of "wild-type" or less highly inbred individuals of the same species. For example, it is believed that inbreeding has contributed to the reduction in the life expectancy of cockatiels from a record of 32 years to the present-day average of four to six years. When seeking a healthy companion bird that has the greatest potential of reaching its full life expectancy, clients should avoid highly inbred birds in favor of the wild-type characteristics.

Currently, the available information on the population dynamics of free-ranging birds and those maintained as pets is sparse. It is doubtful that the longevity for many companion bird species is known because of a lack of scientifically derived diets and less-than-ideal management parameters; however, some general working guidelines with respect to longevity are listed in Table 1.4. An increase in longevity data will require that aviculturists and avian veteri-

narians keep and compile information from accurate and long-term records.

TABLE 1.4 Suggested Longevity of Selected Companion Species

Bird	Maximum	Average
Gouldian Finch	unknown	4
Zebra Finch	17	5
Canary	20	8
Mynah	8	3
Toucan	unknown	4
Budgerigar	18	6
<i>Agapornis</i> sp.	12	4
Neophema	10	5
Cockatiel	32	5
Rainbow Lorikeet	15	3
Rosella	15	3
Eclectus Parrot	20	8
Galah	20	5
Bare-eyed Cockatoo	40	15
Sulphur-crested Cockatoo	40	15
African Grey Parrot	50	15
Pionus parrot	15	5
Amazon parrot	80	15
Macaw	50	15
Conure	25	10
Grey-cheeked Parakeet	15	8
Superb Parrot	36	6
Domestic pigeon	26	15

### Selected Species Recommendations

The Grey-cheeked Parakeet, Dusky and Maroon-bellied Conures and Monk Parakeets are reputed to be relatively resistant to common diseases and are longer-lived than most cockatiels, budgerigars and lovebirds. Grey-cheeked Parakeets have been described as quiet but playful; the conures are not as quiet, yet they can be tame and affectionate; and the Monk Parakeet is considered docile, quiet and relatively nondestructive (chewing). Other bird species that are considered relatively quiet include the Ring-necked Parakeet, Pionus species, Hawk-headed Parrot, Caique, Dusky-crowned Conure, Senegal Parrot, Jardines Parrot, Cape Parrot, Meyer's Parrot, Red-bellied Parrot and Brown-headed Parrot.

An individual wishing to obtain a companion bird should be patient. Developing a relationship with an aviculturist or pet retailer and checking several references are well worth the effort. Some unscrupulous

pet retailers (particularly traveling dealers) will use dyes and bleaches to make common inexpensive birds look like less-common, more-expensive birds in the same genus. This is a frequent practice with Amazon parrots that enter the United States from Mexico and some South American countries. The consumer should be wary of strange and exotic color mutations.

### ■ Choosing a Healthy Bird

Parameters that may increase the likelihood of adding a healthy, mentally stable companion bird to the family are:

- Obtaining the bird from a reputable breeder who specializes in the particular species or genus of bird that is desired and has a closed flock.
- Obtaining the bird from a reputable source who works in close liaison with an avian veterinarian.
- Obtaining a young, recently fledged, parent- or hand-raised bird.
- Obtaining a well adapted companion bird from an individual who is no longer able to provide for the pet (due to age, moving, finances).
- Obtaining a bird that has normal-appearing feathers and droppings, a good appetite, appears to be bright, alert and responsive to its environment, and has not been exposed to birds from other sources.

Parameters that increase the likelihood of adding a diseased, unhappy bird to the family are:

- Obtaining a wild-trapped bird.
- Obtaining a recently imported bird.
- Obtaining a bird suspected of being smuggled.
- Obtaining a bird with an asymmetrical beak, excessively scaly legs, twisted digits, missing toes, a blocked nostril, slight swelling around the eyes, deformed eyelids, stained feathers above the nostrils, stained feathers around the vent, tail bobbing, fluffed appearance, soiled vent, poor feather quality, diarrhea, yellow urates, increased urine production, pectoral muscle atrophy, abdominal distention, fault lines and depigmented feathers (eg, black or yellow where normally green plumage occurs).

Identifying an overtly ill bird in a retail outlet should caution the consumer to purchase a bird from another source. Birds that are unusually inexpensive for the species may have a sordid past that can

include specific diseases or exposure to pathogens that may cause problems when the birds are introduced to a home or aviary. Wild-caught birds, particularly those that are likely to be illegal imports (smuggled), should always be avoided.

### Health Checks

A veterinarian is well advised to seek legal advice in developing a form to be used as a certificate of examination. The term “health certificate” should be avoided because it is impossible to certify “health.” It is possible only to certify that no abnormalities were detected using a particular battery of tests. The expectations of a dealer or client regarding a veterinary examination may be quite different, and requirements and liabilities are likely to vary among countries and states.

Clients should always be offered state-of-the-art diagnostic, medical and surgical services that are available on a national level. It is then the client's choice to determine what level of care they desire for their pet. It is important to note in a patient's medical record what services were offered to a client and which of those services were chosen, in order to prevent accusations of negligence. A state-of-the-art health examination for birds can include a physical examination, CBC, biochemistries, radiographs, endoscopy, Gram's stain of the feces and rostral choanal slit, *Chlamydia* sp. screening and (where available) DNA probing for psittacine beak and feather disease (Pbfd) virus and polyomavirus. Because the results of a single diagnostic test are not absolute, the practitioner must combine the values reported by the laboratory with his assessment of a bird's overall condition, diet and environment.

When all the data on a patient is collected and evaluated, the practitioner can state only that in his opinion, there were no detectable abnormalities at the time of testing. Table 1.5 lists some disease conditions that are frequently diagnosed in popular companion bird species.

### Transporting the Bird

Clinicians will need to evaluate a bird's excrement for the day or two before an examination; therefore, a bird's enclosure should not be cleaned for the two days before it is taken to the veterinarian. If the bird's enclosure is too large to move (in most situations it should be), then clean butcher's wrap or any non-absorbent paper should be placed on the bottom of the bird's enclosure for 12 to 24 hours before an

TABLE 1.5 Common Diseases in Companion Birds by Species\*

<b>African Grey and Timneh Grey Parrots</b>	Coccidiosis	Feather picking, barbering and self-mutilation
Feather picking	Splay leg in juveniles	PBFD virus
Rhinoliths (bacterial, fungal, secondary to malnutrition)	Cere abscesses	<b>Major Mitchell's Cockatoos</b>
Oral abscesses	Hepatopathy	PBFD virus
Hypocalcemia syndrome	Pancreatic insufficiency	Aspergillosis
Hypovitaminosis A	<b>Canaries</b>	Sinusitis
Resistant bacterial infections - <i>Klebsiella</i> , <i>Pseudomonas</i> , <i>E. coli</i> , <i>Staphylococcus</i>	Feather cysts	Metabolic bone disease in juveniles
Aspergillosis	Obesity - lipoma	Pododermatitis and leg calluses
Neoplasms (apparent higher incidence than other species)	Alopecia syndrome	Feather picking and barbering
Tapeworm infestation (imported birds)	Straw feather syndrome	<b>Rosellas</b>
Blood parasites (occasionally imported birds)	<i>Knemidokoptes</i> sp. mite infection	PBFD virus
Reovirus	Air sac and tracheal mites	Feather picking
PBFD virus	Canary pox	Aggression toward people and other birds
Hematuria syndrome in infants	Dry gangrene of extremities	Flightiness
Non-regenerative anemia (neonates)	Myeloproliferative disease	Pododermatitis (often severe)
Neuropathic gastric dilatation	Egg binding, egg-related peritonitis	Motile protozoa (fatal intestinal disease)
<b>Amazon parrots</b>	Dyspnea (acute, inhaled seeds)	<b>Conures</b>
Bumblefoot	Yolk emboli	Black splotches in feathers (malnutrition, hepatopathy)
Hematuria with metal poisoning (Zn, Hg, Pb)	Lymphocytosis	Pacheco's disease virus carriers (probably no more so than other South American species)
Egg-binding	Eosinophilia with inflammation	Polyomavirus
Chronic sinusitis, pharyngitis, tracheitis	Cataracts	Bleeding syndrome (erythemic myelosis)
Hypovitaminosis A	<i>Plasmodium</i> sp. and toxoplasmosis	Screaming
Chlamydiosis - rhinitis, sinusitis, enteritis	<b>Cockatiels</b>	Feather picking (severe)
Polyomavirus	Giardiasis (in USA)	Cannibalism
Malcolored feathers (hepatopathy or malnutrition)	Ascariidiasis in Australia	PBFD virus
Oral abscesses	Mycoplasmosis	Megabacteria
Lymphocytosis	Spirochetosis	Heat stress
Poxvirus infection (primarily imports)	Obesity	Neuropathic gastric dilatation
Mutilation syndromes	Idiopathic neurologic dysfunctions	<b>Eclectus Parrots</b>
Cloacal papillomatosis	Diabetes mellitus	Lead poisoning, biliverdinuria
Epilepsy in Red-lored Amazons (idiopathic)	Egg-binding and egg-related peritonitis	Female aggressiveness
Neoplasia (especially liver adenocarcinomas)	Dyspnea (acute, inhaled seed)	Annular toe deformities
Herpesvirus-induced tracheitis	Yolk emboli	Feather picking
Coagulopathies	Eosinophilia with inflammation	Cataracts
<b>Budgerigars</b>	Upper respiratory sinusitis, conjunctivitis	PBFD virus
Neoplasm (lipoma, testes, ovary, liver, kidney)	Paralysis of lower eyelid, weak eye blink	Polyomavirus
Goiter	Mouth and tongue paralysis (esp. neonates)	Hypovitaminosis A
Hypothyroidism (not documented)	Yellow feathers in lutinos (hepatopathies)	<b>Finches</b>
Polyomavirus	Pancreatitis	Air sac mites - Gouldians
Unilateral leg paralysis - renal or gonadal neoplasia	Liver failure - fatty liver, cirrhosis, neoplasia	Tapeworms
<i>Knemidokoptes</i> sp. mites infections	<b>Cockatoos</b>	Trichomoniasis
Feather mites and lice in Australian budgies	Self-mutilation (feathers, skin)	Bacterial infections (particularly susceptible)
Retained feather sheaths	Psychotic behavior	Egg binding
Overgrowth of beak and nails (malnutrition or hepatopathy)	Idiopathic liver cirrhosis	Lymphocytosis
Egg-binding	Tapeworm infestation (wild-caught)	Foreign body constrictive toe necrosis
Pododermatitis	Blood parasites (recently imported)	Dry gangrene of extremities
Gout	Proliferative foot lesions (herpesvirus)	<b>Frogmouths, Tawny (Australian captive)</b>
Trichomoniasis	Pododermatitis	<i>Erysipelas</i>
Obesity	Cere hypertrophy and occluded nares	Subcutaneous white worms
Diabetes mellitus	Oral abscesses	Nutritional deficiencies (vitamin B complex-responsive neurologic signs)
Hyperglycemia secondary to neoplasms	Trematode infestation (imported birds)	Fatal pandemic convulsive syndrome
French Molt (acute PBFD or polyomavirus)	Obesity	Obesity
Polyfolliculosis	Lipomas (Rose-breasted and Sulphur-crested)	<b>Grey-cheeked Parakeets (<i>Brotogeris</i> sp.)</b>
Chlamydiosis (usually chronic low grade)	Cloacal prolapse (idiopathic)	Sarcoptiform mange ( <i>Metamicrlichus nudus</i> )
Giardiasis	Microhepatia	Chronic active hepatitis ( <i>E. coli</i> )
Megabacteria	<b>Corella, Short-billed and Long-billed</b>	Normally high AST values
Mycoplasmosis	Acute and chronic PBFD virus	Mycobacteriosis
Salpingitis	Malnutrition	Chlamydiosis
Ovarian cysts	Upper respiratory tract infections	Feather picking refractory to therapy
Stroke (older budgerigars)	Bumblefoot and leg calluses	Resistance to disease and stress
	Anti-social behavior	Screaming
	Jealousy and aggression (breeding season)	Nail trimming lameness
	<b>Gang Gang Cockatoos</b>	
	Malnutrition	
	Metabolic bone disease (juveniles)	

TABLE 1.5 Common Diseases in Companion Birds by Species (continued)

<b>Kakariki</b> <i>Knemidokoptes</i> sp. (new species in feathers) PBFDF virus	Self-mutilation "stress dermatitis" axillae, patagium and base of tail	Chronic active hepatitis Combination hepatopathy Heart disease
<b>Kookaburra</b> Obesity and fatty liver syndrome (excess fat) Vitamin B complex-responsive neurologic disorders Gapeworm	<b>Macaws</b> Avian viral serositis Neuropathic gastric dilatation Sensitive to doxycycline, trimethoprim, gas anesthetics Behavioral problems Capillaria and ascarid infestation (imported birds) Feather cysts in Blue and Golds Oral and cloacal papillomatosis Feather picking and mutilation Herpesvirus feet lesions Sunken eye sinusitis Annular toe deformities in young macaws Pancreatic dysfunctions Cataracts Polycythemia in Blue and Golds Sensitive to vitamin D <sub>3</sub> Uric acid gout in young Blue and Golds Upper respiratory tract infection and sneezing Malcolored feathers (turn black in Blue and Golds and miniature macaws) Polyomavirus Microhepatia Coagulopathies	Eye diseases (corneal scratches, keratitis, chronic keratoconjunctivitis) Epilepsy (idiopathic)
<b>King Parrots (Australia)</b> Acute PBFDF virus (juveniles) Chlamydiosis		<b>Pionus Parrots</b> Obesity Malnutrition Respiratory infections Poxvirus infection
<b>Lorikeets</b> Hepatopathy PBFDF virus Fungal infections Coccidiosis Ascariasis Cestodes Bacterial infections Injuries Necrotic enteritis (possibly clostridial)		<b>Toucans</b> Hepatopathies Bacterial infections Giardiasis Coccidiosis Beak injuries Diabetes mellitus (Toco Toucans) Iron storage disease
<b>Lovebirds (<i>Agapornis</i> spp.)</b> Aggression Cannibalism PBFDF virus Polyfolliculitis Megabacteria Heat stress Lovebird pox Epilepsy (idiopathic) Viral infections Obstetrical problems (egg binding) Bilateral clenched foot syndrome Capillariasis	<b>Magpies, Australian</b> Soft pliable beaks and bones in juveniles (parathyroid gland dysfunction) Spiruroid throat worms Scaly leg mite ( <i>Knemidokoptes</i> -like)	*This list is a guide to the most commonly reported clinical problems. All species discussed are susceptible to malnutrition, bacterial infections, fungal infections and toxicities. All Psittaciformes are susceptible to <i>Chlamydia</i> sp. to varying degrees. Unless a species has a particular propensity or a characteristic presentation, these problems are not mentioned.
	<b>Mynahs</b> Hepatopathies Iron storage disease Cirrhosis of liver	Diseases mentioned may be common in some localities or bird populations, whereas the same diseases are rarely encountered in other localities or populations.

appointment. The paper should then be brought with the bird to the veterinarian.

A clean, padded cardboard box or carrying crate with adequate ventilation is suitable for most short periods of transportation. The bird should be maintained at an ambient temperature of 70° to 80°F and should never be left unattended. Containers that have been previously used to transport birds must be cleaned and sterilized before reuse (see Figure 2.17). Carrying containers constructed of wood should be used only once, because they are impossible to disinfect. Most birds travel quite well in dark, cool enclosures and do not require, nor should they be given, tranquilizers (see Chapter 7).

For safety, the bird should remain in some type of secure enclosure in the veterinarian's waiting room. A bird that flies in the reception area is subject to substantial injuries.

## The Home Environment

### Quarantine

If a client already has companion birds, any new additions to the household should be isolated (quarantined) for six to eight weeks. The purpose of the quarantine period is to allow sufficient time for newly acquired birds to exhibit clinical signs of disease and to prevent transmission of disease to other birds. During this quarantine period, the bird should be examined by a veterinarian and any identified problems should be corrected. It should be noted that many avian infectious diseases involve a carrier state (eg, PBFDF virus, polyomavirus, Pacheco's disease virus) and that quarantine alone is insufficient to ensure that one of these diseases is not introduced to a home. As diagnostic tests become available to detect

subclinically infected birds, they should be integrated into the post-purchase examination procedure (see Chapter 6).

## Enclosures

Enclosures for birds come in numerous shapes, sizes, styles and materials. Many are designed primarily to appeal aesthetically to the client but fail dismally to address the needs of the bird. The materials or designs of some enclosures may actually create a health hazard for a bird (Table 1.6).

**TABLE 1.6 Inappropriate Enclosure Designs**


- Bubble-shaped (domed plastic, usually with peat substrate)
- Small, rectangular or cuboidal shape
- Short or tall cylindrical shapes of small diameter (< 2 meters)
- Bamboo construction
- Highly convoluted enclosures (ornately designed)
- Multiple crevices and hard to clean areas
- Enclosures that prevent full extension of the wings
- Stacked perches that result in fouling of the lower perch
- Perches placed so the bird fouls its water or food container
- Galvanization (lead/zinc poisoning)
- Metal water containers soldered at the seams (lead poisoning)
- Copper fittings (copper poisoning)
- Internal hooks (trauma), sharp objects or sharp edges
- Fine, easily chewable mesh construction
- Little room to hop (preferably to fly) between two perches
- Overcrowded with toys and food containers (obesity)
- Difficult to clean or service
- Unpolished welds/brass "beads" (foreign body ingestion)
- Difficult access to the bird (small door)
- Insecure door latches.

Enclosures for companion birds should be as spacious as possible, with emphasis on length more than depth or height (Figure 1.2). The minimum size would allow a bird to spread its wings without touching the

sides of the enclosure. The enclosure should be clean and easy to service and should be constructed of a durable, nontoxic material. Enclosures should be used to house the bird when no one is home and at night; therefore, the enclosure should be secure and free of potential traps. Gaps between sections of the enclosure can entrap toes, beaks or wing tips and should be minimal in a well designed enclosure (Figure 1.3). Newspaper, paper towels or paper bags appear to be the best substances for the bottom of the enclosure. They are inexpensive, easy to clean and do not promote the growth of pathogens as do wood chips or ground corncob. Cedar, redwood and pressure-treated wood chips should not be used for substrate or nesting material in birds. The design of the enclosure should minimize the likelihood and possibility of a bird having access to its own or other birds' droppings.

## Position of Enclosure

A bird's enclosure should be positioned so that at least some of the perches allow the bird to be at or above eye level of standing family members. Birds are generally more secure at this level than lower and are less likely to develop dominant or aggressive tendencies than if they are placed at higher levels. The enclosure should be positioned so that it partially receives direct sunlight on a daily basis and offers a shaded area. Because a bird's normal hormonal cycles are influenced by photoperiod, it is best for the enclosure to be placed near natural lighting. The need to avoid drafts is exaggerated. Covering birds is discouraged because fresh air is more important than being exposed to home lights. A bird is best kept in the dark for sleeping.



**FIG 1.2** Enclosures that are long and provide some room for exercise are preferable to enclosures that are extended in height. The extra height of the enclosure creates no advantage for the bird. Doweling-type perches should be replaced with clean, nontoxic hardwood perches of variable size (courtesy of Ross Perry).



**FIG 1.3** Enclosures with gaps (particularly those that have a “spring” action) should be avoided. These areas of the enclosure can entrap toes, beaks or wings and result in fractures, concussions or death. Note the damage to the enclosure bars, indicating that this wire was not of sufficient strength for the Amazon parrot it housed.

It is ideal for a companion bird to have a large outdoor enclosure in which it can be placed on a regular basis for exercise and exposure to fresh air and sunlight. An outdoor enclosure for a companion bird should be protected from extremes in weather as well as from predators and rodents. The enclosure should be securely placed on its fittings to prevent movement, and food and water supplies should be protected from contamination by free-ranging birds.

### Perches

Perches should be made from selected branches of clean, nontoxic hardwood trees and shrubs that have never been sprayed with pesticides or chemicals and are free from mold and wood rot. Variably sized perches should be provided; those with small diameters allow the toes to almost touch when wrapped around the perch and those with large diameters cause the feet to be flattened. The branches should be irregular in cross section, as opposed to cylindrical, to decrease the pressure placed on any one point of the foot and reduce the potential for bumblefoot. Bumblefoot is believed to be induced primarily by malnutrition but may be aggravated by inappropriate or fouled perches. Providing chew toys may prevent some birds from destroying a perch as quickly.



**FIG 1.4** Perches should not be positioned over each other or over the food and water containers. Note the excrement contaminating the lowest perches and the water containers. Additionally, this enclosure does not have a grate, allowing birds access to their own excrement (courtesy of Ross Perry).

Perches should be replaced frequently, especially if fouled by feces. Perches should not be positioned above each other or above the food and water containers (Figure 1.4). The use of concrete perches in combination with wood perches is becoming increasingly popular and appears to be safe as long as the diet is balanced and natural perching is also available. Sandpaper perches should never be used in a bird's enclosure. They have no effect on nail length and may predispose a bird to foot problems.


### Accessories

Overcrowding the enclosure with toys and food containers can be detrimental. Some birds will use and seem to enjoy a swing but it should be placed so that

it does not obscure a flight or jumping path. If there is insufficient room for both proper perching and a swing, the swing should be removed. Food and water containers should be placed in the enclosure to encourage and maximize activity in a healthy bird; the water container should be placed high at one end of the enclosure, and the food container low at the other end of the enclosure. If a bird is ill, food and water containers should be easily accessed with a minimal expenditure of energy.

### Toys

Any toys available to a bird must be free of toxic metals, hooks, sharp objects or small, easily consumed components. Various gadgetry can be placed in a psittacine's enclosure to stimulate activity and satisfy its natural tendency to chew. It is best to have a collection of different toys that are changed on a daily basis to keep a bird from becoming bored with any one type of toy. There is no quality control for the avian toy market, and the client must be acutely aware of potentially dangerous toys. Toys designed for small birds should not be used with larger birds. In general, there is not one multiple-part toy that is 100% safe. There are some common toy components that are more dangerous than others. These include snap-type clasps, open chain lengths and bell clappers that can be removed and swallowed. Safer toys have a screw-type clasp with closed chain links (Figure 1.5). Most toys with a thin rope or substantial length of sheet chain should be provided to a bird only while it is under direct supervision. If left in an enclosure, a bird can become easily entangled in these toys and die from asphyxiation (Figure 1.6). The most suitable toys for unsupervised birds include natural foods such as grass runners (eg, kikuyu, buffalo grass), various seed pods (eg, melaleuca, hakea, eucalyptus, callistemon and especially banksia for larger cockatoos), liquid amber, pine cones, vegetables, apple cores, clumps or tufts of grass freshly sprayed with water and short lengths of soft wood with bark attached (especially if live beetle larvae or borers are present). Any natural plant materials provided to birds must not have been sprayed with pesticides, chemicals or fertilizers. Fresh-cut branches from unsprayed fruit trees or vines with the bark intact are favorite treats for birds.



**FIG 1.5** Unsafe toys have snap-type clasps, open chain links and easily consumable toxic components. Toys that are safe for a bird under supervision have screw-type clasps and closed chain links. Toys with long ropes or chains should not be left in the enclosure of an unsupervised bird.

### Mirrors

Many smaller birds housed alone are offered mirrors. Some mirrors contain mercury, which is toxic if consumed. Some properly made and designed glass and plastic mirrors are suitable for small birds but can be readily demolished and consumed by large Psittaciformes. Polished stainless steel mirrors are more suitable for large birds. Sexual regurgitation of food onto the mirror is common. If regurgitated debris is allowed to accumulate on or near the mirror, the debris may become a source for exposure to fungus or mycotoxins. Windows and large mirrors in rooms



**FIG 1.6** Some publications discuss the use of leg chains to restrain companion birds. Chains can cause lacerations, fractures, concussions or death and should never be used with companion birds (courtesy of Ross Perry).



where birds are allowed to exercise should be covered to prevent inexperienced or startled birds from flying into these fixed objects causing severe head and neck trauma.

### Hygiene and Sanitation

With a companion bird, it is better to be fanatical with cleanliness rather than to rely on disinfectants to prevent disease transmission in a dirty, contaminated environment. Good hygiene involves the frequent cleaning of a bird's enclosure and is far more important in the prevention of disease than the use of disinfectants. Organic debris (food, excrement, feathers) must be physically removed before a disinfectant will be effective. Water and food containers should be physically scrubbed or placed in the dishwasher on a daily basis to prevent the accumulation of slime and algae.

Multiple layers of butcher's paper, recycled computer paper or newsprint can be used in the bottom of the enclosure. The soiled layer should be removed each day and the entire enclosure should be thoroughly cleaned and dried in sunlight on a weekly basis. Clients should be advised to avoid the inhalation of mold spores and dried, aerosolized particles of excrement.

There has been some discussion of an increased risk of lung disease in clients that are exposed to companion birds. The primary problems that have been reported are in association with the keeping of pigeons in loft-type enclosures where fecal and food debris are allowed to accumulate. One report that discussed an increased risk of lung cancer in association with the keeping of companion birds did not address the type of birds or adjust for exposure to cigarette smoke. However, clients that maintain any type of pet in the home should keep the pet's living space clean and should ensure a fresh supply of air at all times. The addition of electrostatic-type air filters to a central air system can also reduce the amount of animal-related debris that is circulating in the air. Clients should always be encouraged to inform their physicians that they have companion birds. This information may be of value in diagnosing and treating some zoonotic diseases.

When disinfectants are necessary, chlorine or glutaraldehyde preparations are effective for most avian pathogens (see Chapter 2). Many disinfectants emit toxic fumes and should be used only with adequate ventilation and never near a bird. Disinfectants should be thoroughly rinsed from an enclosure to prevent the bird from contacting residual compounds.

### Home Hazards

Birds that are allowed unrestricted access to the home can encounter numerous physical dangers or toxins (see Chapter 37).

### Mixed Aviaries

Many species of birds are highly territorial or aggressive toward other species of birds and would not be suitable for a mixed aviary. Others may be compatible except during the breeding season. The dietary preferences of some birds change during the breeding season such that they may predate eggs and nestlings from other birds. Some birds may appear quite compatible during the day but become active and possibly predatory at night.

The birds in established mixed flights develop a pecking order or hierarchy that is likely to be upset by the introduction of another bird, even if it is of a compatible species. This introductory period causes a substantial "stress" in the flock and may precipitate subclinical disease problems. It is best to plan well in advance the number and species of birds intended for a mixed aviary and to introduce all the birds to the facility at the same time. Almost certainly there will be a need for multiple feeding and drinking stations, each of which can be easily cleaned and accessed by the aviculturist. At least some of these feeding stations should be situated within smaller "trap-type enclosures" constructed within the large flights. The trap door is normally secured in an open position, but can be used to safely catch a particular bird with minimal disturbance of the other birds. Mixed flight aviaries should be provided with a variety of sight barriers and retreat areas for those individuals low in the pecking order. Each bird needs to have an area in which it can rest and feel secure.

### Feeding and Watering Techniques

Healthy birds should always have a supply of clean, fresh, uncontaminated water. There is frequent discussion concerning the use of chlorhexidine in the water to reduce bacterial growth; however, in addition to reducing bacteria in water, this agent also alters the normal microbial population of the gastrointestinal tract (see Chapter 5). The routine addition of any disinfectant to a bird's water should be discouraged. Water that has been "sitting" in plastic or copper pipes can accumulate toxic levels of some chemicals, and pipes should be flushed for several minutes before collecting drinking water. During the

summer months, some city municipalities add disinfectants and algae inhibitors to the water that can be toxic to birds and fish.

Many companion birds will readily adapt to a water bottle, which is easier to clean and keep free of contaminating food and excrement than a water bowl. The use of water bottles is encouraged in birds that will use them and not destroy them (see Figure 2.9). In general, medication should not be added to drinking water; this is particularly true when water bottles are used. If a medication settles out of solution, it will settle to the bottom of the bottle, which could result in a bird consuming toxic levels of a medication (see Chapter 17).

Birds should be provided fresh food in clean bowls on a daily basis. A combination of formulated diets (70%) supplemented with some fresh fruits and vegetables (30%) appears to keep a bird in the best health (see Chapter 31). Some companion bird clients allow their pets to eat at the dinner table, by serving the bird from its own plate or by allowing the bird to roam the table and sample whatever it chooses from the plates of family members. Other clients may hold food in their lips and allow a companion bird to nibble at the food. This practice should be discouraged. High levels of salt and ingestion of some foods (chocolate, avocado) can be toxic (see Chapter 37).

### Grit

Whether or not to provide soluble shell grit and insoluble coarse sand grit to a bird is controversial. This practice is viewed with disfavor in the United States, especially if given free choice, which may lead to over-consumption and obstructive gastritis. In Australia, grit is frequently offered to companion birds with few ill effects; however, birds fed formulated diets are unlikely to need either insoluble or soluble grit. As a compromise, a cockatiel-sized bird can be offered five grains of grit biannually; a cockatoo-sized bird can be offered a half-teaspoon of grit biannually. Cuttlefish bone may be provided as a supplemental source of calcium; however, with the widespread availability of formulated diets, these agents are no longer required to provide supplemental calcium. Additionally, cuttlefish bone may accumulate high levels of toxins (particularly heavy metals), and with the severe and continued degradation and pollution of the environment, this product may pose a health hazard to birds (see Chapter 37).

Seed bells that have been fashioned with wood glue should not be offered to birds. Additionally, these

products may contain a wire loop or hook that is a potential health hazard. Mite protectors are not effective for birds, and the constant exposure to the aerosolized toxins in these products may be a health hazard. Effective therapy is available for the occasional bird that develops a mite infection (see Chapter 36). In nature, birds will sometimes be observed feeding from sun-bleached, uncooked bones. Charcoal may be consumed by a bird when it is offered; however, it has been shown that charcoal can cause a vitamin B deficiency and it should not be offered on a regular basis.

## Preventive Care

### Wing Clipping

Advantages and disadvantages exist for each of several methods for clipping the wings. The clinician should determine the client's expectations of the appearance and the reduced flight capacity of the bird prior to performing a wing clip. The client should authorize the trimming or removal of any feather that will alter the appearance or function of the bird, particularly with respect to show or racing birds. It is important to identify and avoid any pin feathers (blood feathers, blood quills), as a developing feather that is cut below the pulp cap will bleed profusely.

The goal of clipping the wings is to prevent the bird from developing rapid and sustained flight and *not* to make a bird incapable of flight (Figures 1.7, 1.8). A bird that is unable to gain any lift with the wings becomes a free-falling object if it jumps from a high location. Excessive wing trims can result in fractures of the legs, wings or lacerations of the keel (see Color 8).

A bird will require additional trimming eight to twelve weeks after the start of a molt cycle. Wing clipping has been loosely associated with feather picking and self-mutilation in species that are prone to this behavior (Gang Gang Cockatoos, Major Mitchell's Cockatoos, Moluccan Cockatoos, Rose-breasted Cockatoos or rosellas); however, the role that feather clipping plays is unsubstantiated. In smaller athletic birds, both wings may require clipping to reduce flight capacity.

### Nail Clipping

Healthy birds usually have strong, sharp nails that can be uncomfortable to the client when the bird is perching on the arm or shoulder. A short length (usually about 2 mm) of the nail can be removed by trimming or grinding without causing pain or bleeding (Figure 1.9). Sandpaper perches are contraindicated.



**FIG 1.7** During the wing trimming process, the wing is held at the shoulder with the humerus in a fixed, extended position. Each individual feather is depressed with the scissors and cut below the covert, being sure to miss any pinfeather shafts to avoid bleeding. An aesthetically pleasing wing trim can be performed by pushing a feather to be cut ventrally and then clipping the quill at a level under the wing covert feathers.



cated for birds and are not an alternative to nail trimming. Short-blade podiatric nail clippers can be used to trim the tip of the nail with minimal risk of accidentally cutting adjacent toes.

Alternatively, a motor driven hobby grinder (preferably with a rheostat foot switch) with a cone-shaped stone may be used for filing and shaping nails and beaks (Figure 1.10). When using a grinder, it is easy to slowly reduce the length of the nail or beak and to stop at a point just before bleeding might occur. Any bleeding that does occur is best controlled with a bipolar radiosurgical unit (beak), silver nitrate stick (nails) or Monsel's solution (both). It is best not to use a silver nitrate stick around the beak. The silver nitrate deposited at the wound site can remain active and cause caustic burns to the tongue or oral mucosa.

The dust created by grinding the nails and beak is a health hazard and should be exhausted. The grinding stone and nail clippers should be sterilized between birds.

### Bathing

Many birds enjoy a bath or shower and should be given the opportunity to determine the degree and duration of exposure to moisture. Frequent misting encourages normal grooming activity, which is critical to proper feather maintenance. After bathing, birds should have access to a warm, draft-free area to preen and dry. Some birds like a shallow container in which to bathe, while others prefer a fine spray (clean misting bottle). Some smaller birds prefer to bathe in a wet clump of grass or wet salad greens. Some like to fly onto and off the client's shoulder or head while the client is having a shower.

Very few birds like to be physically placed in bath water and washed. The few indications for manually bathing a bird include the removal of oils, greases, waxes, paints, dirt and dried medications. Unless a material contaminating the plumage is toxic, it can be removed a little at a time with repeated baths of short duration. This prevents the bird's exposure to excessive quantities of soaps and detergents (see Chapter 15). It may take months for birds that have



**FIG 1.8** In larger birds, clipping the secondaries and all but the most distal two or three primaries generally results in a bird that has some flight capabilities that allow it to float to the ground in a spiral fashion. In smaller athletic birds, both wings may require clipping to reduce flight capacity.

been washed in soaps and detergents to regain the normal color and water resistance of their plumage.

Medications or food particles that have dried and become encrusted on the feathers around the mouth are removed by pre-moistening the material, then gently washing with a cloth a few minutes later.

## ■ Identification Methods


### Leg Band Removal

Open leg bands should always be removed from companion birds. Some closed leg bands aid in the identification of a bird and may suggest that the bird was captive-bred; however, they can constitute a health hazard. Potential band-induced problems include entrapment of the leg in the enclosure accessories or the accumulation of a constrictive ring of keratin (usually associated with malnutrition or *Knemidokoptes* mites) between the band and the leg that can lead to impaired circulation and necrosis (Figure 1.11). Flat bands that are often too wide to comfortably ride on the tarsal bone can lead to traumatic exosteal bone formation. Any details on the leg band should be recorded in the bird's record prior to removal. The client's consent should always be obtained before the band is removed. A highly prized breeding bird could be rendered almost valueless if its leg band is removed and no other form of identification (such as a microchip) is available. A band that is removed should be given to the client.

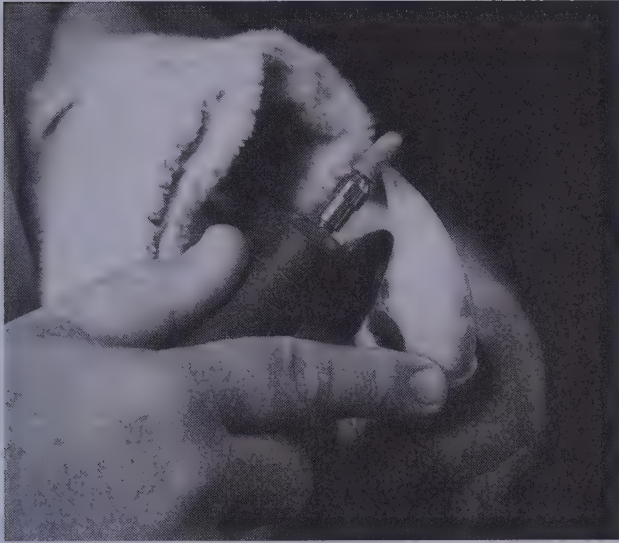Bands are easiest to remove before they begin to constrict the tissues. It is generally recommended to

anesthetize a bird with isoflurane to ensure that a band is safely removed. This prevents the bird from suddenly moving during the band removal process, which can result in lacerations or fractures of the leg depending on the type of removal device used. In removing any band, it is important that forces be applied to the band itself; pressure must not be applied from any direction to the leg.

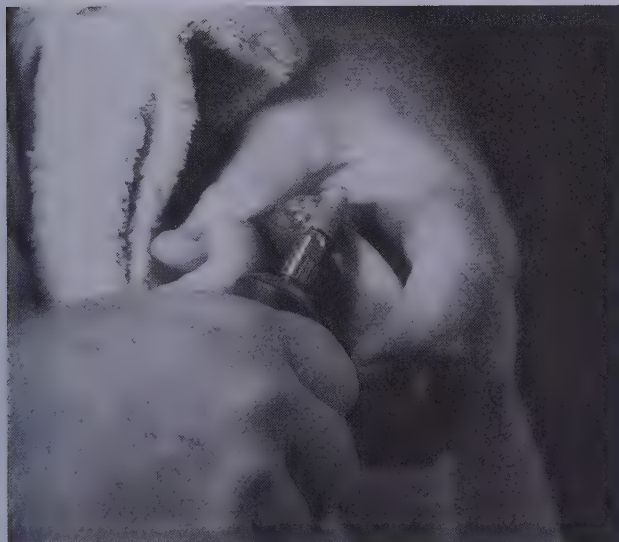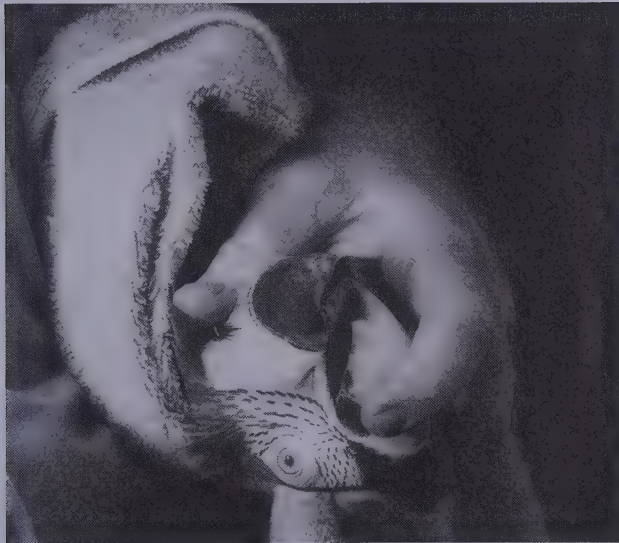Small closed bands made of plastic or aluminum can be easily transected with Heath-type stitch removing scissors (Figure 1.12). Two diagonally opposing cuts are made and the band falls off in two halves. Large



**FIG 1.9** Nail trimming is most easily achieved using a motor driven hobby tool.



**FIG 1.10** Beak trimming can best be accomplished using a motor driven hobby tool. Resting a finger on the beak or head can facilitate control when trimming the upper beak. The lower beak can be most easily trimmed by placing the tip of the upper beak inside the lower beak.



split bands are easiest to remove by using two pairs of locking pliers to apply opposing force at the site of the opening. Attempting to cut large, open import bands can result in collapse of the band against the leg, resulting in bruising, lacerations or fractures (Figure 1.13). Additionally, the force placed on the band becomes uncontrolled at the point where the cutters fully penetrate the band, and undue stress is placed on the leg.

Bands that are associated with constrictive accumulations of keratin (in-grown bands) can best be removed by using a variable speed hobby tool and a fine tip cutting bit. The bird should be anesthetized and the leg should be held by the individual using the hobby tool to prevent slipping of the tool or leg, which can result in severe laceration (Figure 1.14). The constrictive rings of accumulated keratin should be removed by moistening them with skin softeners or aloe vera gel and gently peeling them away. A bandage or light splint may be necessary to support the bone if it has been weakened by the constricting material.

Closed bands are applied to developing neonates to indicate that the bird is captive-bred; however, this is not reliable identification because closed bands may also be placed on free-ranging neonates in the nest, or chicks of free-ranging species can be close-banded after their eggs were stolen from the nest and carried illegally to other countries. Closed leg bands can be of different colors and may have imprinted on them a variety of coded information. They are designed to be worn permanently by the bird but can create problems in some situations.

### Tags

Numerous shapes and sizes of tags have been applied with varying degrees of success to the wings, the patagial membrane or backs of birds. This method of identification is used by field biologists in the study of free-ranging birds and is rarely encountered with companion birds.

### Tattoos

Specific information placed in the skin of a bird by tattoo rarely remains legible. In practice, tattoos are




**FIG 1.11** Closed bands that are too small can cause constrictive lesions or can lead to the accumulation of keratin debris under the band, which results in constriction. The leg of an Amazon parrot after removal of a band shows the constriction of the soft tissue (arrow), and bruising and swelling of the distal limb (open arrow).

generally restricted to indicating the gender of a bird following endoscopic evaluation of the gonads. By convention, tattoo ink injected into the left patagial membrane indicates a female and in the right patagial membrane indicates a male (see Color 8). The tattoo ink used should be sterilized to prevent the ink from serving as a nidus for bacterial granulomas.

### Microchips

Microchips are small electronic devices that are injected into the musculature (usually, the pectoral muscle of birds) to provide permanent identification. A radiograph can establish the presence and location of a chip (Figure 1.15). The microchips are coded and the code can be read by use of an appropriate transponder (see Figure 2.1). Microchips are of particular use for establishing proof of ownership of



**FIG 1.12** Stitch removal scissors and flush cutting or diagonal cutters can be used to remove small aluminum or steel bands, respectively.



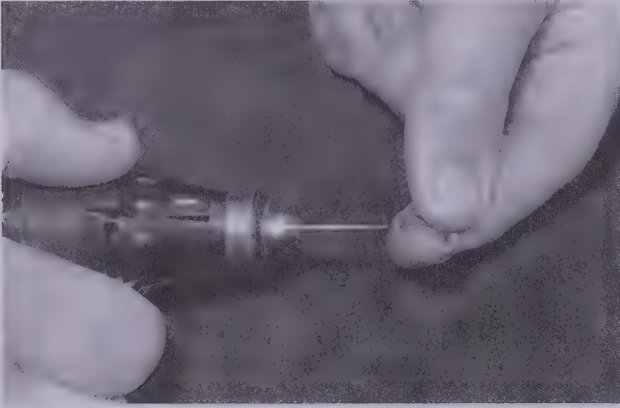
**FIG 1.13** The easiest and safest way to remove open steel bands is to use two pairs of locking pliers to control the opposing force of the band's opening. Attempting to use large bolt cutters to remove these bands can cause lacerations or fractures. Note that gaining sufficient purchase on the band with the cutters places opposing force on the leg (arrow).

birds that are likely to be stolen. The use of microchips is hindered only by their cost and the restricted availability of transponders (readers). Unfortunately, there is no industry standard, and a single transponder model cannot read all available microchips. Microchips can be injected into the pectoral muscle of most birds without sedation or anesthesia, although given the option, the author prefers to perform the procedure in an anesthetized bird. The public awareness of the implantation of microchips into endangered birds or other populations that are susceptible to illicit trapping may act as a deterrent to illegal collection and movement of these birds.

### DNA Fingerprinting


DNA fingerprinting offers a technique for accurately identifying an individual bird and, with proper samples, identifying the bird's immediate relatives. Storage banks for DNA collected from Psittaciformes are currently available in some countries. Collecting and storing the information is relatively inexpensive, but the manipulation or evaluation of the data is relatively expensive.

DNA fingerprinting may be of particular value in studying free-ranging birds for government officials involved in the monitoring of local and international bird trade or for establishing genetic information on birds in large aviaries or zoologic collections. In sev-



**FIG 1.14** A hobby tool with a fine cutting bit is best for removing closed bands that are constricting tissue. The patient should be anesthetized for the removal process and fluids should be constantly flushed over the band to prevent it from heating during the cutting process.

eral legal cases, DNA fingerprinting was used to evaluate the lineage of birds. In one case in Europe, this technology was used to prove that a group of birds had been illegally imported, resulting in the proper criminal prosecution of a smuggler. In another case, DNA fingerprinting was used to disprove that



**FIG 1.15** Radiographic appearance of a microchip implanted in the pectoral muscle of a companion bird.

a pair of supposedly proven breeding birds had not been the parents of a neonate.



**C**hanging attitudes and regulatory pressures are transforming the companion bird industry. Birds for pets and aviculture are being increasingly supplied by domestic breeding programs, and the importation of wild-caught birds is no longer necessary or acceptable for most species. As aviculture advances, veterinarians must play a major role in maintaining the health and increasing the productivity of individual pairs and flocks. The quality of avian medicine available for individual birds has advanced tremendously in recent years. The successful growth of aviculture will require simultaneous advances in the knowledge and application of preventive medicine from the veterinary community.

Avicultural medicine differs from clinical care of individual companion birds in several very important ways. In general, the health of the flock is of primary concern, and establishing a diagnosis or preventing exposure of the flock to an infectious agent is usually more important than providing supportive care for the individual ill bird.

The economics of the companion bird industry are also changing. As production increases, sale prices for individual captive-bred birds decline. The commercial producer, as is the case with any livestock producer, often operates on a slim margin of profit, which can be profoundly affected by disease or management problems. Understanding the economics of the companion bird industry is vital for a successful avicultural practice.

---

CHAPTER

2

**THE AVIAN FLOCK**

---

**Susan L. Clubb**  
**Keven Flammer**

## Flock Preventive Medicine

### The Veterinarian / Aviculturist Relationship

To be of service to the aviculturist, a veterinarian must understand some of the principles of aviculture as well as the principles of medicine and disease. A knowledgeable avian veterinarian will serve as part of a well coordinated aviary team. Table 2.1 lists routine veterinary services that are beneficial to aviculturists.

Veterinary/client confidentiality is of utmost importance for the avicultural client. Inappropriate discussions concerning disease problems in an avicultural facility can permanently and irreparably damage a facility's reputation. The clinical staff must be counseled in strict professional behavior to ensure that they also maintain client/doctor confidentiality.

**TABLE 2.1 Veterinary Services of Benefit to Aviculture**

- Perform new bird examinations
- Perform resident bird examinations
- Assist in establishing and maintaining records
- Establish a preventive medicine program
- Offer husbandry advice
- Provide emergency care for aviary birds
- Take appropriate action in the face of disease outbreaks
- Evaluate reproductive failure
- Assist with incubation and pediatric problems

### Commercial Breeder vs. Hobbyist

The primary goal for the commercial breeder is to produce young companion birds at a profit. Rare or endangered species, species that inherently make poor pets, species that reproduce poorly in captivity or species that have extraordinary housing requirements are not advisable for the commercial breeder. The true economic advantages and disadvantages of a particular-sized facility should be carefully evaluated. Increases in housing density may be economical but can also contribute to the incidence and severity of disease outbreaks, necessitating a detailed monitoring system to prevent health hazards. The commercial breeder should select species that are easy to produce in captivity, that adapt well to the environment in which they will be kept and are popular, acceptable companion birds.

Hobbyists may specialize in a species, or group of species, in order to produce birds for exhibition, for the pure pleasure of aviculture or for the more altruistic goal of establishing or preserving a species in captivity. Hobbyists typically sell offspring to recover the costs of maintaining their collection or to allow them the freedom of devoting more time to aviculture. Profit is not typically the primary motive of a hobbyist breeder. Many aviculturists may start as hobbyists and turn that hobby into a profitable business as they gain expertise and appropriate species of birds.

### Flock Monitoring Team

The veterinarian should work closely with the aviculturist to establish an effective preventive medicine program. Quarantine procedures, parasite control techniques, pest control, identification systems, first aid procedures and subclinical disease testing (chlamydia, PBFV virus, polyomavirus) should be discussed. A healthy, pre-existing aviculturist/veterinarian relationship ensures fast action if a disease outbreak occurs.

Aviculturists must be viewed as the veterinarian's eyes and ears. They see and evaluate their birds daily and must be willing to discuss even the slightest changes in behavior, appetite, stance or excrement output with the attending veterinarian. The aviculturist must respect the veterinarian's medical judgement and strictly implement any and all suggestions. If the advice of the veterinarian is not sought after and respected, a new veterinarian should be engaged.

### Aviary Visits

Veterinarians and their staff should be aware of potential biosecurity hazards to avoid being mechanical vectors for disease transmission between individual patients or avicultural facilities. The veterinarian should visit only one avicultural facility a day, preferably in the morning prior to entering the hospital. If this is not feasible, it is best to have each facility maintain coveralls, scrubs and shoes that can be worn while evaluating that facility. These clothes then remain at the facility for laundering.

When it is necessary to handle a bird in the aviary, it is important to remove the bird from its enclosure with a minimal amount of disturbance. This can be achieved by having all necessary equipment and supplies readily available, with the least number of people involved and minimal noise. The number of assis-

tants and visitors that a veterinarian uses while making any aviary call should be minimized.

### Selling Birds

Offering a liberal warranty may be used as a method to sell birds. However, long-term guarantees given on the health or life of birds, especially unweaned neonates, can be complicated. Pre-sale testing for selected infectious diseases such as polyomavirus, PBFD virus or chlamydiosis, may help assure the buyer of good health. The best guarantee of good health would logically stem from a stable flock of known health history and good husbandry practices. Pet retailers and breeders often require a veterinary examination within a certain period of time in order to activate a guarantee.

A suggested guarantee may last for 14 to 30 days post-purchase as long as the buyer has the bird examined within seven days. An immediate refund should be considered if the buyer's veterinarian determines that a bird has a health problem. The veterinarian must practice good judgement in recommending return, and not reject birds for frivolous or unsubstantiated reasons.

## The New Bird

### Acquisition

Initially, most aviculturists have little concept of which species they will ultimately be breeding. They often acquire, and later sell, many pairs or individual birds before determining which species are best for their aviary. Proper selection of a species for breeding will increase reproductive success, be personally satisfying and will provide better financial return. Choosing species that can easily adapt to the climatic conditions of a region will usually increase breeding success. For example, species that inhabit dry, high altitude environments may be unduly stressed and more susceptible to disease when housed in outdoor aviaries in a warm humid climate; likewise, species from lowland tropical forests may not thrive in dry desert areas.

Ideally, the aviculturist should attempt to envision what he or she would ultimately like to accomplish before establishing an aviary collection.

Sources of birds for captive breeding include imported wild-caught birds, captive-bred juvenile birds and surplus birds, either wild-caught or captive-bred, from other aviculturists or pet owners.

In the past, aviculturists have relied principally upon wild-caught birds for the majority of their breeding stock. A program was established in 1992 for phasing out the importation of wild-caught birds; the availability of these birds is limited to aviculturists who are willing to participate in cooperative breeding programs. As importation ceases, so too does the exposure of immunologically naive birds to previously unencountered pathogens. This provides the veterinary preventive research community with the time necessary to control some of the diseases that have already been introduced to the aviary through previous importation programs.

The purchase of captive-bred birds for breeding stock is a logical alternative for many species. Many psittacine and passerine species have adapted well to captivity and breed prolifically in properly designed aviaries. The psittacine species that have proven to be difficult to breed in captivity will require further work. In some cases, hand-fed neonates are not thought to produce well in captivity, while in other cases these birds reach sexual maturity at a much younger age than expected and readily reproduce.

Although the purchase of culled breeders from another aviculturist should be viewed with suspicion, moving a pair of healthy, unproductive birds to a new environment frequently initiates breeding activity.

Care must be taken to avoid the purchase of smuggled birds. Bargain-priced birds should always be viewed suspiciously. The addition of illegally imported (smuggled) birds to a collection has both unacceptable disease and legal risk.

The buyer should attempt to obtain as much information as possible about the seller and the bird before

### CLINICAL APPLICATIONS

- Veterinary/client confidentiality is of utmost importance for the avicultural client.
- A healthy, pre-existing aviculturist/veterinarian relationship ensures fast action if a disease outbreak occurs.
- The level of husbandry advice provided by the veterinarian must be adjusted to compensate for the experience of the aviculturist.
- If a bird leaves a facility for any reason and is exposed to any other birds, it should be considered contaminated and must be placed in quarantine before return to the aviary.
- An aviary must meet the physical and psychological needs of the birds. Healthy, happy birds breed. Healthy, unhappy birds may not breed.

purchase. The first question to ask the potential seller would be, "Why is this bird or pair being sold?"

The aviculturist should determine the original source of the bird. If the bird was wild-caught, it is wise to determine the country of origin and the importer. If the bird has changed owners several times, it is best to determine why. For captive-bred birds, it is advisable to determine where the bird was produced, when it was hatched and if the bird was parent-raised or hand-fed. If the bird is represented as captive-bred but is not closed banded, it is useful to know why. Determining the genealogical history of the bird, determining if any previous health problems have occurred and evaluating as much information as possible about the flock of origin can guide the aviculturist in making a wise choice in adding birds. A copy of all medical and reproductive records should be requested. If a proven pair is being sold, are the birds identified and are breeder's records available? Knowing when and how the gender was determined in a bird may help identify reasons for reproductive failure. Male cockatoos are frequently available for sale after they have killed their mate. If a seller is unwilling to freely provide any requested information, the buyer should be concerned about the validity of any claims that are made concerning a pair of birds.

### Evaluating a Prospective Purchase

The addition of new birds to an established aviary increases the potential for introducing an infectious disease. Additionally, new birds that are misrepresented (inaccurately sexed or sold, due to previous reproductive failure) represent a loss to the aviculturist by occupying space and requiring care that could be used for productive pairs. Examination of a breeding bird being considered for addition to the aviary should be more than a health exam. The bird's gender and the visual health of the reproductive tract should be confirmed by laparoscopy. Diagnostic testing should be based on the client's needs, species of birds, source of the birds and any questionable abnormalities detected on physical examination.

### ■ Quarantine

A routine quarantine program for new birds is vital to protect an established avicultural collection from the introduction of infectious diseases. The type of examinations performed, length of the quarantine period and preventive techniques vary according to the resources of the aviculturist, the species and source of the birds being added and the type of collection. If a bird leaves a facility for any reason and is

exposed to any other birds, it should be considered contaminated and must be placed in quarantine before being returned to its normal enclosure. Neonates that leave the nursery and come into contact with other birds should not re-enter the nursery.

### Quarantine Facilities

Facilities used for quarantine will vary among aviculturists. In many instances there is no opportunity for strict segregation of new arrivals, and in these cases it is prudent not to add new birds to a facility. Ideally, birds in quarantine should be housed separately from the remainder of the collection for a minimum of sixty days. Birds in quarantine should be attended by an individual who has no contact with the established collection, who takes care of established birds prior to servicing the quarantine facility or who showers and changes clothes after servicing the birds in quarantine. Quarantining birds off the aviary property (eg, a neighbor's home) is a practical means of providing an effective quarantine period.

Birds placed in separate rooms within a home provide a minimum amount of separation between new and established residents. Birds that are maintained in any enclosure (home or building) with the same air space should not be considered to be in quarantine. The bowls and all handling equipment used for birds in quarantine should not come in contact with the remainder of the birds in a collection.

### New Bird Examination

Birds should be examined at the beginning of quarantine to establish any pre-existing problems and again at the end of quarantine to detect any clinical changes that may have occurred (see Chapter 8).

It is critical for the aviculturist to understand that quarantine is only a "safety valve" in the prevention of infectious disease and does not ensure that a new bird is not an asymptomatic carrier of parasitic, bacterial or viral pathogens.


The new bird exam and quarantine testing program should be tailored to the needs and resources of the aviculturist and the species of bird. Suggested screening techniques would include a thorough physical examination, Gram's stain of feces and evaluation of a blood smear. Complete blood count, blood chemistry profile and cultures are useful to detect birds that require more extensive evaluation. By performing a complete CBC, biochemical profile and radiographs on each new bird in a facility, the veterinarian is able to establish a "normal value" for

a particular test in a particular bird. In essence, this testing allows the veterinarian to establish a “point-in-time” medical fingerprint for the individual bird. Specific diagnostic screening tests that should be considered include ELISA tests for chlamydia and DNA probes for polyomavirus and psittacine beak and feather disease virus (see Chapter 32). Direct and flotation examination of feces for internal parasites should also be considered in birds that were recently imported or that are in flights with access to the ground (see Chapter 36). Any thin birds, especially species susceptible to neuropathic gastric dilatation (formerly proventricular dilatation syndrome) should be examined radiographically. Some diseases that are characterized by an asymptomatic carrier state (Pacheco’s disease virus, giardiasis) are easily missed with routine testing.

### Identification

Each new bird should be permanently identified during its initial physical examination. Implantable transponders provide the least alterable identification with minimal risk to the bird.<sup>a-c</sup> The transponder number should be included in the medical, genealogical and breeding records to provide positive identification of the bird throughout its lifetime (Figure 2.1). Closed bands can be used as an adjunct to or replacement for transponders but are not ideal. Properly fitting closed bands are an indication (not proof) that a bird was bred in captivity.

Closed bands are currently required for export of captive-bred birds of CITES-listed species. Unfortunately, the numbers often wear off closed bands and large birds may collapse them, resulting in leg or foot injuries. In addition, bands can catch on loose enclosure wires. These disadvantages should not dissuade the serious aviculturist from closed banding nor should they encourage the veterinarian to remove those bands.



**FIG 2.1** Electronic transponders provide the most permanent, least alterable and safest method for identifying a breeding bird.



**FIG 2.2** A closed band on a bird may or may not indicate that the bird was domestically bred. Slightly oversized closed bands can be placed on the leg of most birds. Alternatively, a bird that was captive produced in another country and imported into the United States could have a closed band and an open import band. Such was the case in this macaw.

Open bands are the least desirable but are none the less an effective means of identification. The rolled steel bands used for identifying birds in USDA quarantine stations have sufficient tensile strength to preclude complete closure, increasing the risk of entanglement when compared to closed bands (Figure 2.2). An alternative to removal of these bands is to close them as tightly as possible, thereby reducing the risk of the gap slipping over enclosure wire. The numbers are typically more durable on steel open bands than on breeders’ closed bands, which are usually made of aluminum. Metal bands must be removed from the legs of birds exposed to sub-freezing temperatures, as they contribute to frostbite. The importance of individual identification was graphically demonstrated in the aftermath of Hurricane Andrew’s assault on South Florida in August 1992. Many birds escaped when their enclosures were damaged and could not be identified by the aviculturist to facilitate recovery.

The veterinarian can help the aviculturist establish a record system that is best for a particular facility, assist in developing and implementing effective identification systems and evaluate production records. Records that include all available medical information should be established at the time the bird enters the aviary.

Trends indicate an increasing interest in the establishment of stud books and cooperative breeding programs involving private aviculturists. The more information that is available for a particular bird, the

more valuable that bird is to captive reproductive programs.

### Acclimation

Birds should be acclimated to their new surroundings as soon as they arrive. Birds may refuse food for several days (small birds) or up to a week (larger species), especially if the bird was a previous pet. New birds should be weighed upon arrival and observed closely for weight loss. Gavage feeding should be used only if the weight loss is dramatic (20% of initial weight) in order to avoid unnecessary stress. A bird that is reluctant to eat can be maintained on the diet to which it is accustomed and slowly changed to the diet used by the aviculturist. Changes in the quality of water may cause temporary intestinal upset. A species that will be housed outdoors must be slowly acclimated to its new climatic conditions. Tropical birds can tolerate northern temperate climates if acclimated for several months before being exposed to winter temperatures. Exposure to direct sunlight can cause burns on the unfeathered portions of the face. Eye rings, facial patches in macaws and exposed skin in feather-plucked birds will eventually "tan" and show color changes indicative of melanization or deposition of other protective pigmentation. Biting insects may cause dermatologic reactions that can become quite severe in a new arrival (see Color 24). Housing of affected birds indoors until the severity of such reactions subsides may be helpful. The possibility of birds becoming sensitized (allergic) to pollens or resins of plants has been suggested.

### Preventive Husbandry Practices

The level of husbandry advice provided by the veterinarian must be adjusted to compensate for the experience of the aviculturist. Successful aviculturists frequently have vast experience in animal husbandry and carefully evaluate the behavior and condition of their birds on a daily basis. They often understand intuitively when problems are occurring that require veterinary assistance to identify, correct and prevent. If a veterinarian expects client compliance, recommended therapeutic programs must be designed to address the daily problems faced by the breeder and require minimum input of time, labor and resources. Minimal disruption of the collection may be the most important factor in maintaining a stable, healthy collection of breeding birds.

A routine preventive medicine program should be designed around a detailed health history for the collection. Fecal samples should be evaluated on an

annual basis and can be grouped (no more than three to five pairs/sample) to facilitate testing for parasites in a large aviary. Infected groups can then be screened on an individual basis and treated as needed.

Annual prophylactic treatment for chlamydiosis is often advocated even in the absence of a diagnosis of chlamydiosis. This may be beneficial in birds housed outdoors and exposed to free-ranging birds, especially pigeons. In most cases, the indiscriminate use of antibiotics is not recommended. Exposing birds in a flock to unnecessary or sub-therapeutic levels of antibiotics will create "super" strains of bacteria that are resistant to a particular antimicrobial agent. If birds are medicated, treatment should be delayed until the non-breeding season (the fall for most species). Egg production will typically decrease during treatment, and chicks that hatch from eggs laid during treatment may have developmental abnormalities.

Commercially available oil emulsion adjuvant vaccines for Pacheco's virus disease, pox and salmonella can be beneficial in populations at risk. These vaccines were developed for use in wild-caught imported birds to prevent catastrophic disease outbreaks. In an avicultural collection, the benefits of vaccination must be weighed against the potential for granulomatous reactions to oil emulsion adjuvants.

### Feeding Aviary Birds

Proper nutrition is vital to avicultural success. Diets should be complete and balanced for optimal health and reproduction. The goals in formulating diets for captive breeding birds include meeting the known or perceived nutritional requirements, maintaining good food hygiene, providing psychological enrichment by offering variety, and having a diet that is easy to prepare and minimizes labor, waste and expense. In general, breeding birds should receive a formulated diet, a variety of fresh fruits and vegetables and some seeds and nuts. In-the-shell peanuts should be avoided because of their potential for exposing a bird to aflatoxins. Establishing a species in captivity requires an understanding of the feeding habits of free-ranging conspecifics. Knowing what free-ranging birds consume will define dietary preferences, may suggest nutritional requirements and will help provide psychological stimulation that could enhance breeding success.

In captivity, birds are usually offered the same diet year-round. In contrast, free-ranging Psittaciformes must forage for food. In their quest for food, birds

typically ingest a varied diet that might include fruits, flowers, buds, pollen, seeds, grains, roots and some insects. Many of these foods will be seasonally available as dictated by the wet and dry seasons, which often control the reproductive cycles. The seasonal provision of extra soft foods prior to the onset of the breeding season may stimulate reproduction.

Birds that are housed outdoors are exposed to natural sunlight and should not require supplemental Vitamin D<sub>3</sub>. Macaws are especially susceptible to Vitamin D toxicity, which could be potentiated by unnecessary supplementation.

### Facility Design

An aviary should be designed to be easy to maintain while providing safety, security and sanitary conditions for its inhabitants. It must also meet the psychological needs of the birds. Healthy, happy birds breed. Healthy, unhappy birds may not breed. A part of making a bird feel secure is to provide it with a defensible space (its enclosure), which is rarely, if ever, violated. Additional factors in providing a secure environment include having visual barriers to separate the nesting areas of secretive birds, and keeping louder, more boisterous birds (eg, macaws) widely separated from quieter, more timid birds (eg, African Grey Parrots). Indoor/outdoor facilities provide the most natural conditions for the birds, but may be unsatisfactory in urban areas. In these situations, properly designed indoor facilities can be used to successfully raise birds.

- **Indoor Facilities:** Indoor housing has several advantages over outdoor facilities including improved pest control, the ability to manipulate lighting, temperature and humidity, and protection from inclement weather and theft. Routine care is not affected by seasonal changes, rainfall and weather conditions. Disturbance by nocturnal predators or other wildlife and the exposure to infectious agents through contact with free-ranging birds is eliminated.

Indoor aviaries also have disadvantages. They are generally more crowded than outdoor aviaries, the increased proximity of birds to each other potentiates the spread of infectious agents, and the lack of seasonal cycling of light and other unknown climatic factors may alter or prevent normal breeding behavior. The per-unit cost of building and maintaining indoor units is generally higher than an all-outdoor facility. Indoor areas require more frequent cleaning to prevent the accumulation of feces, food wastes and dust, all of which reduce the air quality and increase



**FIG 2.3** Birds can be successfully bred in indoor aviaries. However, these facilities are more labor-intensive and increase the likelihood of disease outbreaks. Indoor facilities should be easy to clean, provide adequate fresh air and must have a source of full spectrum light. **a)** This facility provides adequate light for each pair of birds but is impossible to clean with the exposed beam ceilings and open light fixtures. **b)** Newspaper is used to remove the bulk of droppings followed by rinsing of the concrete floors. The three-way hex-nut connectors are an easy way of putting conduit together to make the frame for enclosures.

the likelihood of a disease outbreak. The potential hazard that dust poses for human health should also be considered. Full spectrum light must be used to facilitate Vitamin D synthesis, which is necessary to maintain the general health of a bird. The concept of full spectrum light is confusing. In general, if a light source is not sufficient to induce “tanning,” then it should not be considered full spectrum from a biologic perspective.

The most important considerations when planning an indoor aviary are to avoid overcrowding and to ensure ease of cleaning and frequent air exchange. Walls and floors should be designed to allow pressure

cleaning, and floor drains should be of sufficient size to prevent blockage by debris or feed (especially seed that sprouts in drains). Floor drains should be covered to prevent pests, especially rats, from entering the facility. The facility should be designed to minimize any disturbance of the birds during cleaning activities (Figures 2.3).

The use of ventilation fans and air filters is necessary to ensure adequate air quality, to reduce stress and minimize the spread of infectious agents. The air in an indoor facility should be completely changed or filtered every two minutes. Tropical species may need additional humidity during dry winters.

- **Outdoor Facilities:** Site selection and preparation is the first step in outdoor aviary planning and construction. Considerations include location of aviaries in relation to support buildings, flow of traffic through the aviaries, source of water and electric power, the effects of noise on neighbors and potential disturbances from people, free-ranging animals and traffic. Drainage may be critical if aviaries are built in low-lying areas. The degree of protection from inclement weather should be evaluated. Natural or artificial windbreaks may be necessary in some parts of the country. The primary direction of wind and rain should be considered in the design of roofs in order to maximize protection of nest boxes and food bowls from rain (Figure 2.4). Privacy may be provided by the use of vegetation or fences or by placement of birds as far as possible from roads or houses. The need for shade will vary among species. Desert species may prefer a more sunny, open aviary while forest species may feel more secure in wooded or secluded aviaries.



**FIG 2.4** Outdoor facilities with a covered area to keep the food bowls and nest box dry can be used to breed birds in appropriate climates. The enclosure can be constructed over concrete pads with a drainage ditch to one side for ease of cleaning.

Outdoor aviaries should be designed to reduce the entrance of predators. Raccoons, opossums, foxes, rats and free-ranging cats and dogs may directly injure birds, frighten them into causing self-inflicted injuries or introduce infectious agents. Electric fences are helpful in excluding free-ranging predators from aviaries. Well behaved, properly trained dogs can be used in an attempt to exclude predators. Poorly trained, noisy or excitable dogs may affect production by disturbing or frightening the birds. A fenced “kill zone” that is patrolled by dogs should reduce the entrance of pests and predators into the aviary grounds.

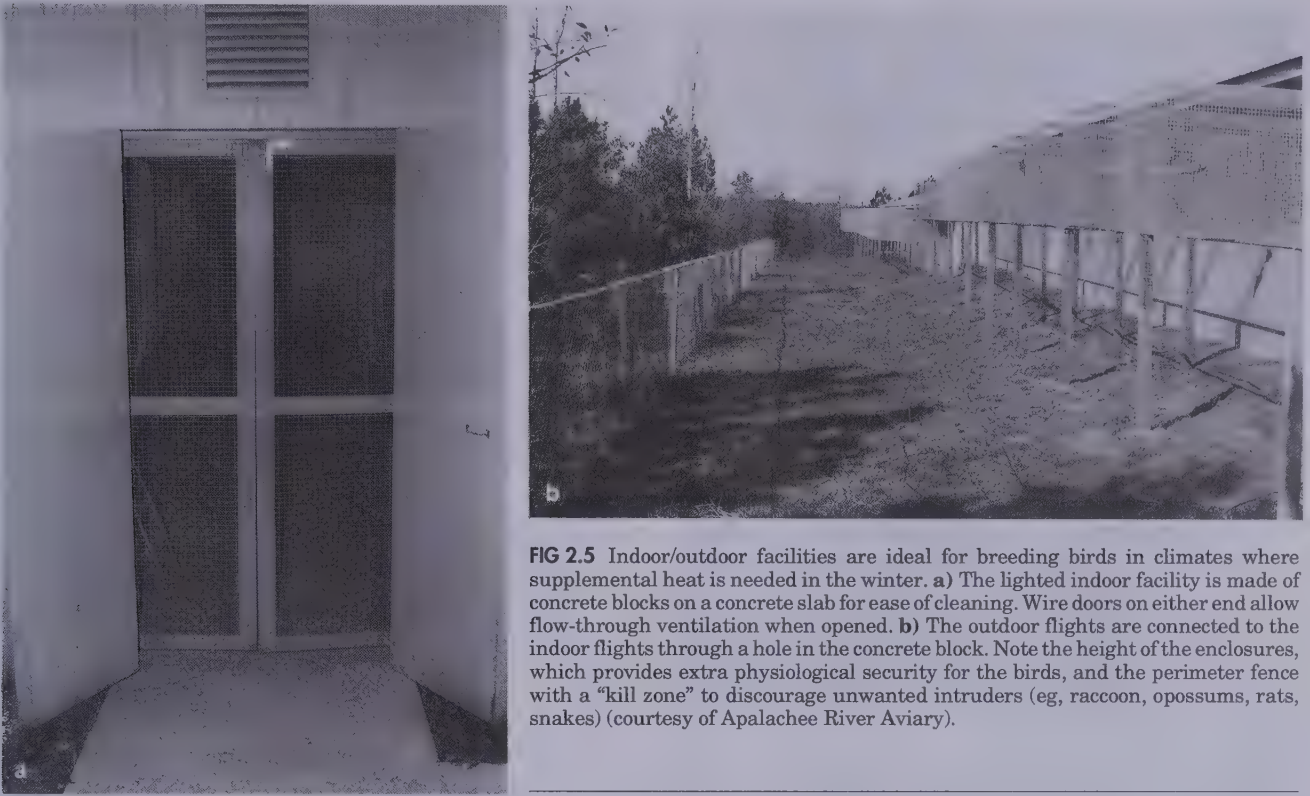Outdoor aviaries are common in the southern United States, and offer natural conditions and constant exposure to fresh air and sunlight. The per-unit cost of this type of facility is usually lower than an indoor facility. Exposure to natural, seasonal variations in weather may stimulate reproduction.

Disadvantages to an outdoor breeding facility include the inability to control inclement weather, increased difficulty in pest control, the potential of noise irritation to neighbors and increased risk of theft. Some birds may be bothered by biting insects or aerosolized allergens.

- **Combination Indoor and Outdoor Facilities:** Heated indoor facilities that are attached to outdoor flights are ideal for breeding birds in areas where the birds cannot remain outdoors year round. One facility that might be used as a model was designed to hold up to 24 pairs of birds and was completely constructed for less than \$25,000 (Figure 2.5). A concrete slab was poured for the base of the indoor building. The concrete floor was sealed with a waterproofing agent to make cleaning easier and more effective. The slab was constructed with a 15-20% slope to one end. Two, covered four- to six-inch drainage pipes that drain water outside the perimeter fence were placed in each end of the building, and an easily removable sink was installed in one end. The sides of the building were made of concrete block with holes to the outside placed at the desired height (bottom of the bird’s cage floor) and at numerous horizontal intervals (the number would depend on the width of the interior and exterior enclosures).

The ceiling was made of exterior grade plywood, and the walls and ceiling were sealed with an industrial-grade epoxy paint that can withstand pressure cleaning. A strip of florescent lighting was positioned down the center of the building. A central heating unit was installed in the attic of the building with four evenly





**FIG 2.5** Indoor/outdoor facilities are ideal for breeding birds in climates where supplemental heat is needed in the winter. **a)** The lighted indoor facility is made of concrete blocks on a concrete slab for ease of cleaning. Wire doors on either end allow flow-through ventilation when opened. **b)** The outdoor flights are connected to the indoor flights through a hole in the concrete block. Note the height of the enclosures, which provides extra physiological security for the birds, and the perimeter fence with a “kill zone” to discourage unwanted intruders (eg, raccoon, opossums, rats, snakes) (courtesy of Apalachee River Aviary).

spaced registers and a centrally located return. Insulation was placed in the attic to reduce heat loss in the winter and keep the buildings cooler in the summer. The lights were placed on a timer and are adjusted seasonally to correlate with the natural changes in photoperiod.

The interior enclosures are suspended from beams in the attic. Alternatively, individual enclosures may be placed on pipe racks attached to the concrete floor; however, these are more difficult to clean. The thermostat for the heating system is placed at a level even with the enclosure perches and maintained at 50°F in the winter. By placing the thermostat at this position, a bird’s living space is heated to the desired temperature while the area below the outdoor entrance hole (bottom of the enclosure floor) remains unheated.

### Enclosures

The two primary styles of enclosures used in breeding aviaries are suspended wire enclosures and flights. A suspended enclosure is separated from the ground and is not entered by aviary personnel. Suspended enclosures are easy to construct, clean, modify or move, and are relatively inexpensive and secure. Birds have reduced exposure to their feces and accumulated food, simplifying disease and parasite

control. These enclosures should be placed so that the perches are above eye level of aviary personnel to contribute to the security and contentment of the birds housed within (Figure 2.6).

Enclosures should be spaced far enough apart to prevent any physical contact between birds in adjacent housing. In general, the larger the size of the enclosure, the better (Table 2.2). Obese birds rarely breed, and larger enclosures provide for improved exercise. Suspended wire enclosures may not be advisable for toucans or some aggressive species that need ample room to escape from attacking mates.

Most enclosures for Psittaciformes are constructed from appropriate gauge welded wire (10 ga for larger macaws, 14 to 16 ga for cockatoos and Amazon parrots). Wire that is galvanized after welding is superior in strength to wire that is galvanized before welding. The galvanized coating that is used on welded wire does contain heavy metals. This wire should be thoroughly scrubbed with acetic acid using a wire brush and rinsed immediately to remove loose galvanizing material. “Weathering” the wire (ie, the practice of leaving rolls of wire in the open for six months to a year before use) does not reliably remove heavy metals (see Chapter 37).



**FIG 2.6** Suspended enclosures provide an advantage over walk-in flights in being easier to clean and less expensive to construct and in reducing the birds' access to contaminated food or droppings. Enclosures should be placed as high as possible to increase the inhabitants' feeling of security. Note that the African Grey Parrots in this picture are completely unconcerned about the photographer. The perches in this bird's enclosure are about seven feet above ground level (courtesy of Apalachee River Aviary).

Flight enclosures extend to the floor or ground. Large flights are aesthetically pleasing to people and provide more space for exercise and normal behavior. However, these enclosures are difficult to clean and to maintain pest- or parasite-free. Additionally, aviary personnel walking from one enclosure to the next can serve as mechanical vectors for the transmission of infectious agents.

Enclosures should be designed with access locations that allow the capture of birds with minimal chasing. Escape proofing is suggested and may be accomplished by safety aisles or suspended safety netting. In outdoor facilities without safety aisles or netting, a portable safety cage or drape can be suspended over the door, surrounding the handler in order to reduce the chance of escape.

Containers to hold the food bowls should be designed to reduce dumping, to prevent or reduce perching on the bowls and to keep the food dry. Food bowls should be positioned away from perches to reduce excrement contamination of the food and water containers (Fig-


**TABLE 2.2** Suggested Minimum Sizes for Suspended Enclosures and for Nest Boxes

	Enclosure	Nest Box
Large macaws	6'x6'x12'	48"x16"x16"
Large cockatoos, medium macaws, obese Amazons	4'x4'x8'	36"x12"x12"
Amazons, African Grey Parrots	2'x2'x6'	24"x12"x12"
Pionus, mini-macaws	2'x3'x8'	24"x12"x12"
Conures, caiques	2'x2'x6'	18"x12"x12"
Small conures, cockatiels	2'x2'x3'	16"x10"x10"
Lovebirds, parrotlets, budgerigars	2'x2'x2'	8"x8"x24"

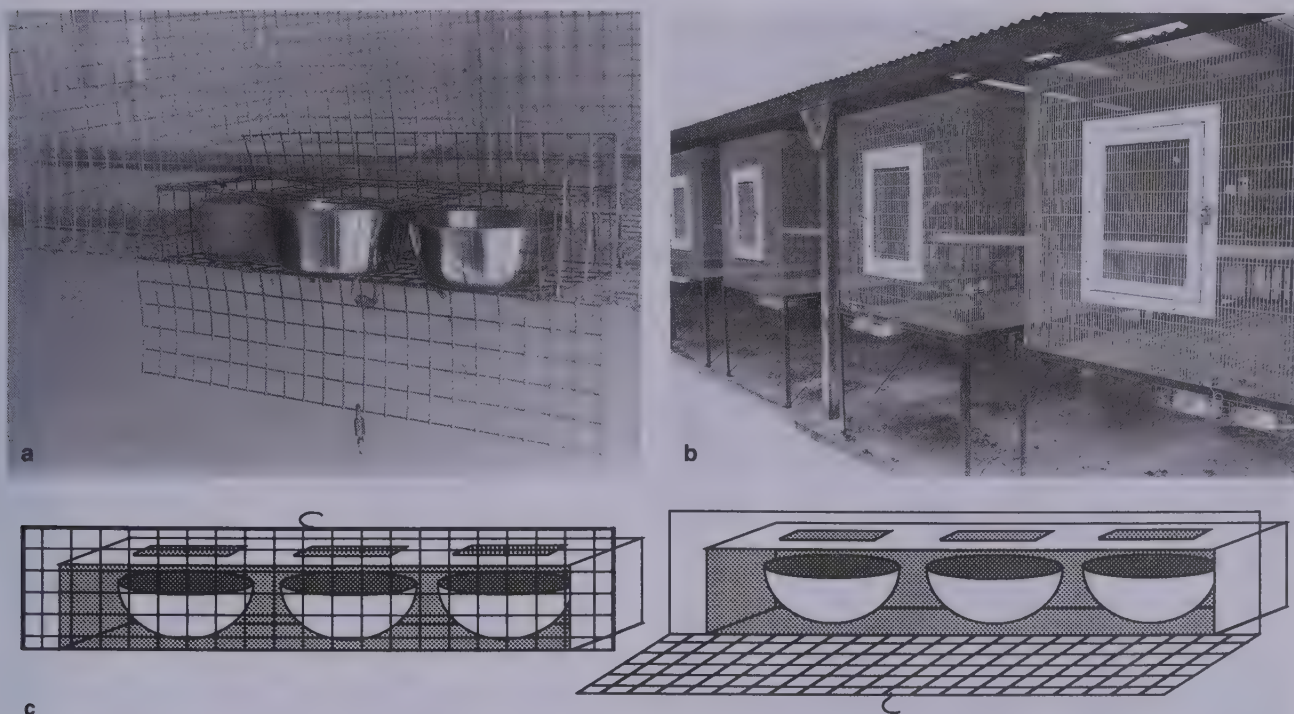
\* Enclosure and box dimensions are height x width x depth

ure 2.7) Alcove-type feeding troughs are ideal for preventing food and water bowls from being turned over. Alcove servicing also prevents escapes because an enclosure door is not opened to gain access to the food and water containers. These alcoves can be designed to slide onto the floor or to fit under the floor of the enclosure. In either case, the access to the food bowls should be covered by a hinged, locking flap that provides two to three inches of coverage on each side of the alcove opening (Figure 2.8). Some aviculturists are finding that the use of bottles serves as an effective method of maintaining a constant supply of clean, fresh water at all times (Figure 2.9). However, birds in a dry climate that are incubating eggs must have access to a bowl of water in which to bathe to help control egg humidity.

Perches must be secure and non-movable in order to provide an optimal site for successful copulation.



**FIG 2.7** Food and water containers should be positioned away from perches or nest box openings to reduce excrement contamination. In this case, the feeding alcove was placed directly under the nest box, resulting in continuous excrement contamination of the food and water. Note also that these unproductive breeding birds were on an all-seed diet. The incidence of recurrent enteritis in the breeding adults and gram-negative bacterial septicemia in the neonates was high in this breeding facility.




**FIG 2.8** Alcove-type feeding trays can be placed **a**) on the bottom of the enclosure (courtesy of Apalachee River Aviary) or **b**) under the enclosure. This type of feeding tray allows easy access to the food and water containers without opening a door to the enclosure that could allow an inhabitant to escape. Note that both of these alcove designs are lockable and have a flap that sufficiently covers the opening to the alcove. Note also the use of stainless steel or hard plastic food and water containers. **c**) Diagrammatic illustration of an alcove-type feeder.

Wood perches that vary in diameter and surface texture provide the most natural standing surface. For larger psittacine birds, these perches should be made of manzanita, Australian pine or oak to prevent their rapid destruction. Excessively large or flat perches may cause pressure lesions on the ventral surfaces of the hocks. More permanent perches can be constructed of PVC, steel pipe or some synthetic materials. These should be used only in combination with some type of natural wood perch. Having wooden perches in an enclosure provides psychological stimulation (chewing) and will help maintain beak health. Some foot and leg problems may be associated with continuous perching on hard surfaces, especially in cold climates where chilling of the feet or frostbite may occur.

### Nest Boxes

Nest boxes should be placed in or on the enclosure in such a way as to allow easy and frequent examination. Placing nest boxes on the same end as the feeding and watering station allows simultaneous feeding and nest box examination (Figure 2.10). Shy birds are more likely to use a nest box that is secluded from high traffic areas. Nest boxes must be water-


proofed or placed so they do not get wet during heavy rains. The nest boxes should also be shielded from direct sunlight, which may cause overheating of the occupants. Some aviculturists believe that certain species such as Amazon parrots require visual isolation around the nest box, while other species such as cockatoos are less affected by visual contact with conspecifics. These differences may arise from flock-



**FIG 2.9** Many aviculturists are finding that bottles are an effective way to ensure a clean, fresh supply of water. Both a bowl and a bottle should be used during the transition phase to bottles. Changes in feeding or watering techniques are best performed after, not before or during the breeding season.




**FIG 2.10** Nest boxes can be made of wood or metal depending on the degree of destructive behavior exhibited by a particular pair. Nest boxes should be positioned so that they are easy to inspect and stay dry and cool (courtesy of Apalachee River Aviary).



**FIG 2.11** Attempts to protect wooden nest boxes by covering them with wire can result in ragged metal edges that can cause severe lacerations, broken bones or death. In extremely destructive birds, metal nest boxes that are protected from extremes in temperature are superior to wooden or plastic boxes. This wooden nest box from a pair of prolific Umbrella Cockatoos was replaced with a metal box with no change in productivity (courtesy of Apalachee River Aviary).

ing behavior and the existence or lack of communal nesting behavior in a particular species.

Nest boxes may be constructed of many materials, with plywood being the most common. Pressure-treated plywood contains numerous toxins and should not be used to construct nest boxes. Lining the nest box with wire will decrease chewing damage; however, chewed wires can produce dangerous projections that can cause injuries to the chicks or adults (Figure 2.11). Plastic or metal barrels are more per-



**FIG 2.12** Large hardwood or aspen chips are best for use in Psittaciforme nest boxes (courtesy of Apalachee River Aviary).


manent than wooden boxes and can be disinfected; however, they are more susceptible to extreme temperature fluctuations. Nesting materials can contribute to disease problems. The use of potting soil, corn cob bedding, eucalyptus leaves or hay may contribute to fungal growth. There is a high incidence of cancer in laboratory rodents that are maintained on pine or cedar shavings. Assuming that long-term exposure to these nesting materials could have adverse effects on companion birds, it is best to use large hardwood or aspen chips in the nest box (Figure 2.12).

#### Health Maintenance Program

The health maintenance program should be designed to address problems common in a species as well as endemic problems for a particular aviary. For example, Old World Psittaciformes housed in outdoor aviaries in southern coastal states must be protected from opossums to prevent an inevitable outbreak of sarcocystosis (see Chapter 36). Mosquito populations are high in the same geographic regions, and susceptible species of birds should be protected from poxvirus by vaccination.


Physical examinations and aviary repairs should be planned for the non-breeding season, typically in the fall.

Good hygiene is vital to good health; however, the level of hygiene must be balanced with the level of disturbance that it creates. Enclosure designs should be easy to clean with minimal labor, cost and disturbances (which, in the aviary, can reduce the chances of successful reproduction in shy birds). Frequent disinfection of enclosures is not necessary if birds are healthy, organic debris is not allowed to build up in the enclosure and the food and water bowls are changed daily.



**FIG 2.13** Food hygiene is critical to prevent the spread of food-borne pathogens. All open food containers should be stored in sealable containers to prevent infestation by flies, roaches or rodents. Unopened food containers should be stored in a dry, cool environment (courtesy of Apalachee River Aviary).

**FIG 2.14** Fresh frozen vegetables should be stored in the freezer until opened for use. In addition, the dry, powdered formula used for neonates should also be stored in the freezer in a sealed container (courtesy of Apalachee River Aviary).



Exceptional food hygiene is vital to prevent the spread of food-borne pathogens or the spoilage of moist foods within an enclosure. Opened food cartons should be stored in sealable containers to prevent infestation by insects or rodents (Figure 2.13). Food stuffs have been frequently blamed for flock outbreaks of bacterial enteritis. In reality, formulated foods designed for companion birds are usually of excellent quality, and bacterial contamination is more likely to occur from improper food handling (allowing food to get wet or be infested by rats or insects) than from milling-related contamination. By comparison, foods designed for gallinaceous birds (eg, chick starter, chicken scratch) frequently have large numbers of gram-negative pathogens and should not be used in association with companion birds. Hygiene is especially important when dealing with soft or fresh foods in which spoilage is rapid (Figure 2.14). Bean sprouts are considered highly nutritious and are thought to stimulate breeding by many aviculturists. However, sprouts can be a source of bacterial or fungal pathogens, and they should be avoided or rinsed thoroughly with dilute hypochlorite, chlorhexidine or peroxide solutions prior to feeding. Fruits or vegetables that remain on the floor of an enclosure can be a source of bacterial and fungal pathogens and should be removed daily, especially in warm climates. The use of a commercial coleslaw

machine to grind and blend vegetables allows for easy removal of uneaten food by simply washing the remaining food bits out of the enclosure.

Birds should have potable, fresh water provided in a clean bowl daily. Vitamins should not be added to the drinking water; they oxidize rapidly and provide a growth media for bacteria and fungus. Water should be collected directly from a tap that is run for 30-45 seconds before filling a container. *Pseudomonas* sp. can frequently be cultured from garden hoses and from PVC pipe systems. Automatic watering systems reduce labor, ensure that birds have a clean fresh supply of water at all times and prevent food or fecal contamination of the water supply. Water should be flushed through the lines daily as part of the maintenance routine. Weekly flushing of water lines with hypochlorite or iodophores is necessary to keep the lines free of bacteria and algae. Automatic watering systems should be checked daily to ensure that they are working properly. Mortality levels could be high if a watering system fails and it is not detected immediately.

The use of foot baths is frequently discussed as vital in the management of infectious diseases. Realistically, they are probably of minimal value as long as aviary personnel are not entering flight enclosures.

More attention should be focused on the cleanliness of objects that come in direct contact with the birds, such as clothing, nets and hands. The veterinarian must take precautions when going from one premise to another to avoid transmission of pathogens on contaminated foot wear. Having a pair of rubber boots that remain on each premise is the best way to prevent disease transmission. Any equipment that comes in contact with a bird should be disinfected, rinsed and thoroughly dried before it is used again. Nets and equipment that are not disinfected between birds can serve as fomites.

Air conditioners and ventilation systems may serve as foci for bacterial or fungal growth in an indoor facility. They can also harbor aerosolized viral particles. In a finch breeding facility, recurrent bacterial infections were traced to an air conditioner filter that supported the growth of *Aeromonas* sp. In another facility, *Aspergillus* sp. was believed to have been harbored and disseminated through an air conditioner filter that was not changed frequently.

Food and water bowls should be made of stainless steel, hard plastic or crockery and should be washed daily. Bowls can be washed in soap and water and returned to the same enclosure. If cleaned as a group, the bowls should be disinfected (with Clorox) before reuse (Table 2.3). For ease of washing, a series of tubs can be set up as follows: detergent and hot water, rinse, immersion for at least 30 minutes in a properly diluted disinfectant solution (Clorox), a second rinse and air drying on a rack. A commercial dishwasher is a viable alternative to hand-washing techniques as long as organic debris can be adequately removed (Figure 2.15).



**FIG 2.15** Food and water bowls used in the aviary should be cleaned and allowed to dry daily. Use of a commercial dish-washer is an excellent way to maintain bowl hygiene in larger facilities.

The dark, damp interior of a nest box can provide an ideal environment for the proliferation of or dissemination of pathogens. Nest boxes should, at a minimum, be thoroughly cleaned on an annual basis, and nest material should be changed after each clutch if chicks were allowed to hatch in the nest. Nest boxes constructed of wood or other porous material should be destroyed if the inhabitants develop a viral or bacterial infection. Embryos may die in the shell or septicemic chicks may occur if an egg becomes moist in the nest box, allowing bacterial agents to pass through the shell pores.

- **Disinfectants:** All aviary facilities should be clean and sanitary. Organic debris must be removed from a surface before disinfecting. Disinfectants should

**TABLE 2.3** Commonly Used Disinfectants in an Aviary

	Sodium Hypochlorite (Clorox bleach)	Quaternary Ammonium (Roccal)	Phenol (One-Stroke)	Chlorhexidine (Nolvasan)
<b>Bacteria</b>	Most	Most	Most	Not <i>Pseudomonas</i> sp.
<b>Mycobacterium</b>	Ineffective	Ineffective	Effective	Ineffective
<b>Chlamydia</b>	—	Recommended	—	—
<b>Candida</b>	—	—	Effective	Less effective
<b>If organic debris present</b>	Ineffective	Ineffective	Less effective	Less effective

All disinfectants are toxic and should be used in a conservative fashion for the specific purpose of preventing exposure to infectious agents. There is no such thing as a safe disinfectant. If it is safe, it does not kill any microbial agents. The least toxic agent that will effectively meet the disinfecting needs should be chosen. In most cases, a 5% dilution of sodium hypochlorite is the safest and most efficacious with the least potential for leaving toxic residues. Materials should always be cleaned before they are disinfected, because few disinfectants are effective in the presence of organic debris. Only household chlorine bleach should be used. Granulated chlorine products release toxic levels of chlorine gas. Birds should not come in direct contact with disinfectants, and it is best if they are not exposed to disinfectant fumes as well. Either decreasing the pH or increasing the temperature will increase the efficacy of Clorox. As a general disinfectant, bleach is mixed at a rate of 200 ml/4 liters of water.

always be used according to the manufacturer's recommendations. Stronger solutions are not more effective and may be toxic. The constant use of powerful disinfectants in the absence of a disease threat is not beneficial, and continuous contact with these chemicals can be detrimental to the birds and aviary personnel. Chlorine bleach should be used only in well ventilated areas, and a 5% solution is effective for most uses.

### Pest Control

▪ **Insects:** Insects and rodents are potential vectors for disease and parasites. They also may irritate and disturb the breeding birds. Cockroaches that eat contaminated opossum feces can transmit *Sarcocystis falcatula* by defecating in a bird's food or by being eaten by a bird. Control of roaches, especially in outdoor facilities in southern coastal climates, is challenging, if not impossible. Insecticides alone are usually not effective and are potentially dangerous to the birds. Biological control of roaches is preferable to insecticides. Clean, sealed facilities reduce hiding places for roaches. Insectivorous animals (gecko lizards or chickens) can be used to consume the insects. The use of flightless silky chickens is recommended to prevent the chickens from roosting on the aviary enclosures.

Ants can transmit some parasites such as the proventricular worm *Dispharynx*. Ants may reduce food consumption by swarming food bowls or may build nests in the nest boxes. Control procedures should include baiting of nests and trails, keeping facilities clean and avoiding foods with high sugar and fat content, which attract ants. The incidence of mites and lice is low in captive psittacine birds but they may be introduced into an aviary by free-ranging birds. The red mite (*Dermanysis gallinae*) can be troublesome in some avicultural situations. This mite is nocturnal and hides in crevices in the aviary and nest boxes during the day. These mites are blood feeders and can kill chicks by exsanguination. For the control of mites inhabiting nest boxes, five percent carbaryl powder has been used successfully without apparent harm to chicks or adults. Mosquitos can also be a problem for chicks in the nest box.

▪ **Rodents:** Rats may enter an aviary at night and spread infectious agents, disturb nesting birds or actually kill some smaller species. In a survey on one breeding farm in South Florida, 50% of resident rats were found to be carrying *Salmonella* sp.

In Southern coastal areas, rat populations seem to rise in the fall. Biological control methods start with constructing a facility that discourages nesting in or around the aviary. For example, in outdoor aviaries, concrete slabs are frequently used to provide additional cleanliness under suspended cages; however, rats almost invariably tunnel and nest under these slabs. Enclosures suspended on poles can be fitted with rat guards, or the poles can be greased to prevent climbing. Sheet metal guards can be wrapped around trees to prevent nesting. Bait boxes should be used as needed and with caution. Snap traps baited with small quantities of ground meat are particularly effective.

▪ **Snakes:** Snakes will occasionally enter enclosures and consume small birds, but will rarely attack larger Psittaciformes. If an aviculturist is breeding small birds (canaries, finches, budgerigars, lovebirds) outdoors, the enclosure should be constructed with small wire or screen to prevent entry of snakes.

## Evaluating and Treating Flock Problems

### Emergency Care

An experienced aviculturist is usually the first individual involved in providing emergency care to a sick or injured bird. The client should be well schooled in providing first aid and recognizing signs of illness that require veterinary intervention. The veterinarian should assist the aviculturist in preparing a first aid kit, in being prepared to provide post-examination nursing care and in having the necessary supplies to safely and effectively transport a sick bird (Table 2.4) (Figure 2.16). The experienced aviculturist should know how to administer stabilizing therapy (SQ fluids, tube-feeding, hemostasis) that can be used if the veterinarian cannot immediately attend to an ill bird. Helping the aviculturist handle emergency problems will encourage the involvement of a veterinarian in the management of the collection (Figure 2.17).

The aviculturist should visually evaluate each bird every day during routine feeding procedures. In addition to the health, behavior and attitude of the bird,


**TABLE 2.4 Avicultural First Aid Considerations**

- Quiet, isolated area with appropriate enclosure
- Enclosure that will provide heat, humidity and preferably oxygen
- Balanced electrolyte solutions
- Feeding tubes and syringes
- Syringes and needles
- Emergency medications (to be prescribed by the veterinarian)
- Bandage materials - non-stick elastic bandage material, adhesive tape, non-stick wound pads, antibiotic ointment, hydrogen peroxide or iodine solutions
- Scissors and forceps
- Coagulants for bleeding nails
- Disinfected container for transporting sick or injured birds


the aviculturist should also evaluate the enclosure for signs of bleeding and feather loss that may indicate a traumatic episode. Fresh excrement should be evaluated for color, consistency and amount of feces, urine and urates (see Chapter 8).

### Managing Disease Outbreaks

Rapid action early in a disease outbreak can prevent catastrophic losses. Isolation and appropriate therapy is warranted with an individual sick bird. In an avicultural setting, maintaining flock health must be the priority, and containing an infectious agent, determining its source and implementing control procedures are mandatory. The more complete the medical examination (blood work, cultures, radiographs, endoscopy), the more likely the veterinarian is to be able to identify the problem and to make specific recommendations to prevent further illness in the flock. Sick birds should be immediately removed from the collection and a thorough diagnostic evaluation performed. If the bird dies, a complete necropsy



**FIG 2.16** The advanced avicultural client should have a readily available supply of routinely used culturing, blood collection and selected medical supplies (courtesy of Apalachee River Aviary).



**FIG 2.17** An attending veterinarian should help the avicultural client maintain first aid supplies including clean, disinfected containers for safe transport of sick or injured birds to the hospital (courtesy of Cathy Johnson-Delaney).

with collection of representative tissues from all organ systems is critical. The speed with which histopathology results can be obtained is also critical. Many state diagnostic laboratories have free or relatively inexpensive fees for histopathology services. However, the period of time that elapses before these results can be obtained may allow an infectious agent to spread through a collection. When histopathology results are needed quickly, it is best to advise the aviculturist to spend the extra money and send samples to a private laboratory. Following an infectious disease outbreak, all materials that cannot be properly cleaned (eg, perches, wooden nest boxes) should be removed and destroyed. The remainder of the facility should be steam-cleaned several times. In any given medical situation, repairing management flaws and using biological control measures are superior to drug therapy.

An easily and completely cleanable isolation area for new and sick birds should be available, and protocols should be established for managing this area. Storage for medical supplies and equipment should be discussed.

### Evaluating Reproductive Failures

#### Resident Bird Examination

Annual examinations of all birds in a collection can be used to detect flock problems, establish and confirm the accuracy of identification systems and collect data that may lead to the removal of unproductive individuals. The efficacy of husbandry practices and the plane of nutrition can be determined by assessing the physical condition of the birds.



The causes of reproductive failure may be multifactorial and illusive (Table 2.5). The veterinarian working in unison with the aviculturist may be able to determine correctable physical, hormonal, nutritional, behavioral and psychological causes of reproductive failure.

A review of the potential health problems identified during the previous breeding season and appropriate testing of nonproductive birds can provide information that is critical to identifying the source of a problem (see Chapter 29). Estimating the age of a bird may be helpful in understanding reproductive failure.

**TABLE 2.5 Evaluation of Reproduction Failure**

- Obtain detailed histories
- Review health and production records
- Perform complete physical examination including cloacal mucosa
- Perform diagnostic tests as dictated by the findings
- Use laparoscopy to verify gender and visually evaluate the reproductive system and other organ systems
- Evaluate husbandry practices
  - Is diet appropriate, balanced and accepted?
  - Are enclosures appropriate in design and size?
  - Are nest boxes secure, dry, clean, free of pests and placed properly in the enclosure?
  - Are secure perches available for copulation?
  - Is the pair protected from environmental extremes?
  - Are aviary disturbances (visitors, pests) minimized?
- Evaluate behavior
  - Is one bird in a pair or in a colony exhibiting excessive aggression?
  - Does the pair exhibit a strong pair bond?
  - Has the pair been observed copulating?
  - Does the pair show any interest in or inspect the nest box?
  - Do the birds exhibit signs of stress, fear or unrest in the present location?
  - Do birds quarrel with, or display to, birds in adjacent enclosures?

### Culling


Culling is a vital technique to improve the quality of captive breeding stock. Decisions to remove a bird from a breeding program can be emotionally difficult, especially when dealing with tame birds that are considered pets and with species that are endangered. In reality, maintaining breeding birds that are not vigorous, that fail to adapt to captivity or that are of poor genetic lineage is a detriment to the future of aviculture and to the species. While no birds should be considered disposable, in the breeding situation the aviculturist must be aware of the necessity of selective breeding to the overall success of an aviary.

The purchase of culled breeding stock, especially birds represented as proven breeders, carries with it a degree of risk. Birds are often culled because they failed to breed, and the novice aviculturist frequently adds someone else's problems to his collection. Birds purchased as part of an entire collection that is being dissolved may be less risky.

Dealing with birds that are to be removed from a collection can challenge the ethics of the veterinarian. Euthanasia of valuable birds due to poor reproductive success or due to poorly understood medical problems (such as cloacal papillomatosis) is unacceptable to many people. Resale of these birds without full disclosure of their problems is equally unacceptable and can strain the client/veterinarian relationship. It is never advisable for the same veterinarian to represent both the buyer and the seller in a bird transaction.

### Incubation and Pediatrics

Veterinarians should be involved in evaluation of incubation failures and management of the psittacine nursery. Successful incubation entails extensive experience, and subtle problems in egg handling, especially prior to or in early incubation, can result in developmental abnormalities that may not be expressed until hatching (Figure 2.18). A definitive cause of embryonic mortality is often illusive. Ideally, all fertile eggs that fail to hatch should be examined in an attempt to detect patterns of mortality, which



**FIG 2.18** The avicultural veterinarian should have a thorough understanding of the incubation process and how to determine the cause of embryonic or early chick mortality. Every embryo that fails to hatch should be necropsied and submitted for histopathology to help identify management or disease problems in the flock. A fertile six-day-old Red-bellied Parrot egg is being candled in the nest (courtesy of Isabel Taylor).

may be helpful in identifying problems associated with incubation (see Chapter 29).

A veterinarian who is experienced in nursery management can provide advice and management recommendations that could prevent the occurrence of clinical disease related to husbandry or nutritional problems of neonates (see Chapter 30).

#### ■ Products Mentioned in the Text

- a. Infopet Identification Systems, Inc., Burnsville, MN
- b. American Veterinary Identification Systems (AVID), Norco, CA
- c. Destron IDI, Boulder, CO

#### ■ References and Suggested Reading

1. **Alderton DA:** The Atlas of Parrots. Neptune City, TFH Publications, 544 pages, 1991.
2. **Fowler ME:** Sanitation and disinfection. In Fowler ME (ed): Zoo and Wild Animal Medicine. Philadelphia, WB Saunders Co, 1992, pp 31-34.
3. **Low R:** Parrots, Their Care and Breeding. Poole, England, Blandford Press, 654 pages, 1980.
4. **Jordan R:** Parrot Incubation Procedures. Pickering, Ontario, Canada, Silvio Mattacchione and Co, 141 pages, 1989.
5. **Silva T:** Psittaculture, The Breeding, Rearing and Management of Parrots. Pickering, Ontario, Canada, Silvio Mattacchione and Co, 328 pages, 1991.
6. **Schubot RM, Clubb KJ, Clubb SL:** Psittacine Aviculture. Loxahatchee, Florida, Avicultural Breeding and Research Center, 335 pages, 1992.
7. **Snyder NFR, Wiley JW, Kepler CB:** The Parrots of Luquillo: Natural History and Conservation of the Puerto Rican Parrot. Los Angeles, Western Foundation of Vertebrate Zoology, 384 pages, 1987.
8. **Voren H, Jordan R:** Parrots, Hand-feeding and Nursery Management. Pickering, Ontario, Canada, Silvio Mattacchione and Co, 1992.
9. **Woolham F:** The Handbook of Aviculture. Poole, England, Blandford Press, 1987.

**T**he feeding of companion birds has become a true art form with as many theories and practices suggested as there are those feeding birds. This feeding “art” has evolved out of necessity brought about by a lack of valid scientific information on the nutritional needs of these birds. Most current nutritional beliefs stem from years of “trial and error” feeding practices that are perceived as successful for the individual. A number of these practices have gradually been passed on, modified and eventually accepted as status quo by aviculturists. Their endorsement has come through the realization of certain improvements over previous feeding standards (such as the addition of fruits and vegetables to an all-seed diet), with the conclusion being that this small degree of improvement represents an end. These feeding practices may be deeply instilled in the bird enthusiasts’ anthropomorphic views (ie, “humanizing” the pet and perceiving all of its needs through the eyes of the owner). There is often a belief that nothing can be too good for the bird, and it is provided with an incredible variety of often not-so-nutritious foods. Theory in companion bird nutrition has also been inundated with self-proclaimed experts, trying to achieve personal gain or recognition through their emphatic and frequently unsupported recommendations of certain feeding programs.

As aviculture has advanced over the past decade through the efforts of truly dedicated aviculturists, sound feeding practices that are based on the eating habits of long-lived birds or on sustained reproductive successes have begun to emerge. Although most of this information is still anecdotal, there appear to be valid principles to support many of these practices. Some of these dietary theories are based on what a particular species of bird is perceived to eat in the wild. Placing too much emphasis on this rationale can be deleterious. There is only a moderate understanding of what free-ranging birds eat, partly because their diets vary widely with the seasons. The majority of companion and aviary birds are considered opportunistic omnivores; that is, they will eat a large number of the foods that are available to them at any specific time. In most cases, this includes a wide array of vegetative material and a variety of animal products, as well as the consumption of soil and mineral deposits. Even a relatively accurate analysis of 90% of a bird’s intake may not be truly reflective of the total nutrient profile of the diet,

---

CHAPTER

3

NUTRITION

---

Randal N. Brue

because items consumed in trace amounts are difficult to quantitate and can have a significant impact on the bird's overall nutritional status. Additionally, most free-ranging birds do not live to their full genetic potential. This is due not only to predation and disease exposure, but also to the frequency of malnutrition caused by seasonally insufficient supplies of nutrient-adequate foods.

### **Nutritional Research Potential**

The science of feeding companion birds has lagged behind that of most other pet species, due largely to historic perception that the diets available were not nutrient-deficient. The lack of financial incentives for either university or industry to employ nutritionists to study these species, and the expense and difficulty of studying nutrient requirements in a variety of species and metabolic conditions have further delayed avian nutritional research.

It has been only in the last decade that nominal research has begun on the nutritional needs of companion bird species, and it will take several decades to establish a partially accurate picture. Fortunately, however, general nutritional principles apply to nearly all vertebrates, with a few notable exceptions. Additionally, the most studied living species from a nutritional standpoint has been the domestic chicken. Although they are obviously not identical to each other in all ways, the domestic chicken does share similar physiologic parameters with popular companion Psittaciformes and Passeriformes. The greatest difference among these species is the fact that Galliformes are precocial (the neonate is mobile and generally self-sufficient at only a few hours of age). In addition, domestic poultry have been genetically selected and modified over the course of several hundred generations of domestication to thrive on commercially produced diets. Nonetheless, domestic poultry provide a starting point for the study of companion bird nutrition. It is at this point that the anecdotal nutritional information that pervades aviculture becomes of great significance. Subtle differences among the species have become obvious, as several species on a dietary regime will perform adequately, while another species on the same diet will do poorly. These observations suggest that species-specific nutritional requirements exist, but because many species of a genus or class perform similarly on a certain diet, it can be assumed that the variations in nutritional requirements are minor.

### **Poultry Adaptations**

Current nutrient recommendations for companion birds are derived from an extrapolation of the nutritional requirements for commercial poultry, the application of general nutritional principles that are fairly constant among all vertebrates, an evaluation of ornithological information (eating habits in free-ranging birds, the role of ecological niches, any known anatomic or physiologic differences) and information that has been generated through the years of trial and error feeding, which has resulted in certain species-specific or family-specific feeding practices. The culmination of this multifaceted approach has resulted in a general estimation of the nutrient needs for companion birds that can be shown to be successful in growth studies and long-term feeding trials. It does not, however, determine the specific requirement of an individual nutrient or necessarily produce a diet that is totally optimized. It also fails to elucidate any species-specific problems, but rather attempts to compensate for them.

To optimize health, longevity and production of companion bird species, a great deal of nutritional research will be required. It is doubtful that the nutritional needs of either the Psittaciformes or Passeriformes, not to mention of a specific individual species, will ever be fully known. Even today, after almost a century of research in chickens and rats, the entire nutritional picture has not been completely elucidated for these species. There are substantial data on the nutrient requirements for the growing animal, but there are still many questions as to the requirements for optimal reproduction, optimal health and maximal longevity. The latter tends to be of little concern in any commercial species, but does have eminent importance for companion animals. The knowledge base of canine and feline pet nutrition is well over 50 years ahead of its companion bird counterpart. Although research in this area involves only two species and is strongly supported by universities and hundreds of competitive manufacturers, the science of canine and feline nutrition is still rather limited and is rapidly evolving.

### **Role of Nutrition in Bird Health**

Nutrition itself is a critical link between the management practices provided for a bird and the bird's good health. Figure 3.1 illustrates a simple building block approach to the final goal of bird health. The foundation of the entire pyramid is the genetic background of the individual, which is largely responsible for the

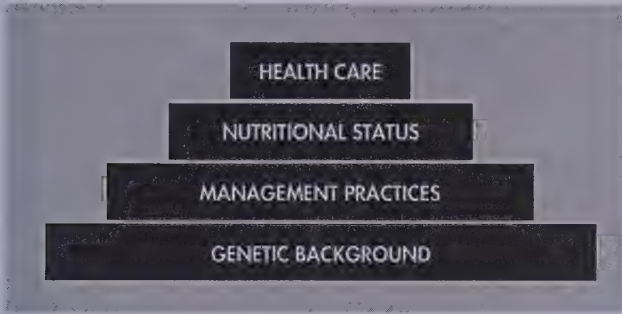


FIG 3.1 Factors contributing to bird health.

nutrient needs. It can also predispose the individual to health problems and may even have implications for management techniques. Pet owners, nutritionists and veterinarians seldom have any impact on genetic background because it is predetermined at conception. The breeder, however, can impact this area through selection of breeding stock. Regrettably (especially in larger birds), the genetically poorer individual is frequently kept for breeding. These individuals may be physically, emotionally or behaviorally abnormal and are abandoned as companion birds and relegated to breeding. This is a counterproductive process, because the breeder may unknowingly be selecting for undesirable traits. The selection of certain unusual traits or the practice of heavy breeding within a very small gene pool will ultimately accentuate both desirable and undesirable characteristics represented in the original genotype. This has created considerable problems in budgerigars, cockatiels, canaries and finches.

Without good, sound management techniques (see Chapter 2), an otherwise genetically strong and nutritionally sound bird will not maintain its good health. Finally, a properly balanced diet and a professionally administered health care program must be provided to ensure the long-term health of a bird.

Just as providing complete, thorough veterinary care is impossible without proper training, so is the formulation of a properly balanced, complete diet. The formulation, development and production of a diet is surprisingly complex due to the large number of nutrient interactions, the differing bioavailabilities of nutrients from different ingredients and the difficulty of procuring and administering micronutrients into the diet. A well formulated, properly balanced diet represents a precise combination of over 40 nutrients, sometimes provided by just as many different ingredients.

## Water

Although not a nutrient per se, water is essential to the body for cooling and for the maintenance of intracellular and extracellular fluids. It is the medium in which digestion and absorption take place, nutrients are transported to cells and metabolic waste products are removed.

The quality of water provided to companion birds should be of utmost concern to both the client and the veterinarian. Water and "soft foods" (foods containing high moisture content over 20%) are frequently implicated in exposures to high concentrations of bacteria. An open water container that becomes contaminated with fecal material or food will promote rapid bacterial proliferation. In water containing added vitamins, there can be a 100-fold increase in the bacterial count in 24 hours. Changing the water and rinsing the container will obviously decrease the bacterial load, but an active biofilm remains on the container walls unless it is disinfected or washed thoroughly. Contamination in the water container, in addition to the aqueous medium and compatible environmental temperatures, provides all the requirements for microorganisms to thrive. Likewise, high-moisture foods such as egg foods, nestling foods, cooked foods, sprouts, fruits and vegetables provide excellent growth media for microorganisms. At warm environmental temperatures, these types of foods can become contaminated in as little as four hours.

Water intake will be greatly influenced by the type of diet provided. Most birds can derive the majority of their water requirement from foodstuffs when the diet consists primarily of fruits, vegetables or moist foods. Processed diets tend to increase the bird's water intake over that typical for a seed diet because they generally are dry, lower in fat and tend to have overall higher nutrient levels. Slightly moister feces are often observed in birds on a formulated diet.

## Nutrient Interrelationships

There exists a vast array of interrelationships between the different nutrients. Ideally, these must all be evaluated to protect against nutrient imbalances and interferences, and to ensure that the proper amounts of nutrients are being both consumed and absorbed by the bird. One of the most frequent misinterpretations is to judge the nutrient adequacy of a diet strictly on the total amount of a nutrient in the food. It is critical to go beyond this quantitative approach and evaluate both the quality of the nutrient and the animal's actual intake of the nutrient. By evaluating the intake level and the quality (bioavailability), the total body uptake can be determined. A simplistic example of nutrient intake miscalculation is the baby bird being hand-fed recommended volumes of a well balanced, high-nutrient diet that is prepared excessively dilute. In this situation, the nutrient uptake is insufficient to support growth.

### The Effective Energy Content of Food

It is important that the individual nutrient levels be balanced with respect to the energy content of the food, because the food intake by the animal is largely dependent on the total caloric density of that food. In the case of very low caloric density foods, the gastrointestinal tract capacity can become a limiting factor for adequate caloric intake. Conversely, if the dietary caloric density is extremely high, the appropriate feedback systems that regulate satiety may not have time to respond before the caloric needs are exceeded, resulting in overconsumption.

Energy content of the diet, or specifically fat content, also has an influence on the rate of food passage through the system. As the fat content of a diet increases, the rate of passage is slowed. This not only has an effect on the bird by prolonging satiety, but also improves digestibility of most nutrients in the food by increasing the length of exposure to digestive enzymes and the time for absorption. This improved absorption, however, is generally not very dramatic. An example of this relationship is given in Table 3.1. This shows how some moderate increases in dietary protein and rather small increases in dietary calcium are required to balance the daily intake levels between a low and a very high fat diet. Although there is a substantial difference in the metabolizable en-

**TABLE 3.1** The Effect of Dietary Energy Level on Intake and Proper Nutrient Density

	Diet A Approx. 4% Fat	Diet B Approx. 22% Fat
Energy Content, kcal/kg	3,015	4,020
Intake, grams	30.0	22.5
Energy Intake, kcal	90.5	90.5
Protein Content, %	15.0	20.0
Protein Intake, g	4.5	4.5
Calcium Content, %	0.5	0.7
Calcium Intake, g	0.15	0.15

ergy values of these two diets, the daily intake of protein and calcium is identical with respect to the energy content of the diet. Consumption of 30 grams and 22.5 grams of diets A and B, respectively, both provide 90.5 kilocalories to the bird. This example illustrates how some seemingly dramatic differences in nutrient levels can actually give very similar results in the animal.

### Mineral Interrelationships

There are a vast number of different mineral interrelationships, with every mineral affected by at least one other. The most critical in companion bird nutrition, and in most species, is the relation between calcium and phosphorous. For proper growth, bone maintenance and health, a ratio of calcium to available phosphorous should be 1.5:1 to 2:1. In these proportions, both minerals are most effectively absorbed in the gastrointestinal tract as well as metabolized within the body. The widest tolerable range of calcium to phosphorous ratio should be considered to be 0.8:1 to a maximum of 3.0:1 (3.3:1 produces rickets and leg abnormalities) Additionally, excess levels of calcium can precipitate deficiencies of magnesium, iron, iodine, zinc and manganese if these are only marginally supplied.

### Vitamin Interrelationships

The most obvious example of vitamin interrelationship is the effect of the absorption of fat-soluble vitamins, in which an excess of one would decrease the absorption of the others due to competition for binding sites in the intestinal mucosa. For this reason, it is necessary that all the fat-soluble vitamins be balanced with respect to one another to assure proper absorption of them all.

There is also an interrelationship in the metabolism of folic acid and choline (and the amino acid, me-

thionine) as they relate to the metabolism of single carbon units (ie, methyl groups). This metabolic role is also dependent on vitamin B<sub>12</sub> as part of the enzyme system.

### ■ Vitamin and Mineral Interactions

Although there are many cases of interactions between vitamins and minerals, certainly the most significant metabolically is the relationship of calcium, phosphorus and vitamin D<sub>3</sub>. It is obligatory for adequate vitamin D<sub>3</sub> to be available for the proper absorption of both of these minerals to take place. Inadequate vitamin D<sub>3</sub> levels in the body can cause calcium deficiency symptoms in an otherwise calcium-adequate diet. Conversely, excess levels of dietary vitamin D<sub>3</sub> can produce hypercalcification even in a diet normally considered to be marginally sufficient in calcium.

The other critical vitamin/mineral interaction is that between vitamin E and selenium, in which their biologic functions are essentially the same, but occur in different parts of the cell (lipid-based and aqueous, respectively). Even though they act in different parts of the cellular structure, a generous supply of one tends to spare a marginal supply of the other by quickly scavenging the additional free radicals that are produced (because of the lack of one nutrient) as they migrate throughout the cell structure, coming into contact with both the aqueous and lipid phases of the cell.

Another example of a mineral and vitamin interrelationship is the increased absorption of iron in the presence of ascorbic acid.

### ■ Amino Acid/Vitamin Interactions

In addition to several of the vitamins' direct roles in enzyme systems that are involved in protein synthesis and metabolism, there are also interactions between amino acids and vitamins that may have an effect on the absolute requirements of each other.

The most notable interrelationship between a vitamin and an amino acid is the relationship of niacin and tryptophan. In fact, a significant portion of the niacin requirement can be spared by an excess of tryptophan in the diet over what is required for necessary protein biosynthesis. This bioconversion is most efficient when levels of both niacin and tryptophan are low in the diet. The ultimate efficiency of this conversion is determined by the liver enzyme,

picolinic acid carboxylase, which catalyzes the breakdown of the immediate precursor of niacin. This enzyme activity is species-dependent, affecting the animal's potential use of tryptophan to satisfy the niacin requirement. Additionally, several of the reactions in the bioconversion require riboflavin and pyridoxine-dependent enzyme systems. Protein, energy and hormonal status also play roles in this series of reactions.

Choline is an example of a vitamin that can directly spare the requirement of an amino acid, namely methionine. This occurs through its ability to act as a methyl donor in a fashion similar to methionine, thereby limiting the specific role that methionine would serve if an otherwise insufficient level of methyl donors existed.

### ■ Nutrient Antagonists (Anti-nutritional Factors)

There are a number of nutrient antagonists that can be present in foodstuffs. Many of these are natural compounds within the food, some of which can be tolerated in limited amounts. Others can be treated commercially to minimize their impact on the animal. Some compounds, most notably mycotoxins (the toxic metabolic byproducts of molds) can be produced when field or storage conditions are less than ideal.

#### Enzyme Inhibitors

Enzyme inhibitors are present in a large variety of foods, and most can be largely inactivated by thorough cooking. The largest group of enzyme inhibitors are the protease inhibitors, which inhibit the digestive enzymes trypsin and chymotrypsin and others. Fortunately, these inhibitors are thermosensitive and readily inactivated by cooking. Ingestion of a diet high in active inhibitors results in poor protein digestion and pancreatic hypertrophy, stimulated by the direct inactivation of digestive enzymes or the effect of limited bioavailability of methionine (decreasing the synthesis of digestive enzymes).<sup>35</sup> Protease inhibitors are present to some degree in all plants, with significant levels found in all of the legumes (mature beans), barley, beets, buckwheat, corn, lettuce, oats, peas, peanuts, potatoes, rice, rye, sweet potatoes, turnips and wheat. Potatoes are extremely high, with a large percentage (15%) of protein comprised of inhibitors.

Tannins, found in a variety of plant sources, can bind protein, inhibit digestive enzymes and reduce the bioavailability of iron and vitamin B<sub>12</sub>. At high levels, they can cause liver and epithelium damage. These

polyphenolic compounds found in most plants are associated with an astringent taste and cause the normal browning on fruits and vegetables when they are cut or bruised. Tannins are found at high levels in acorns, carrots, rape seed, milo, grape seeds, tea, coffee, chocolate, bananas, grapes and raisins, lettuce, spinach, rhubarb and onions.

Some of the other enzyme inhibitors include amylase inhibitor in beans, wheat, rye and sorghum; plasmin inhibitor (inhibiting blood clotting) in some beans; kallikrein inhibitor in potato (decreases antibody formation); and cholinesterase inhibitors in asparagus, broccoli, carrots, cabbage, celery, radishes, pumpkin, raspberries, oranges, peppers, strawberries, tomatoes, turnips, apples, eggplant and especially potatoes.

### Mineral Antagonists

Oxalate (oxalic acid) is an organic acid that efficiently binds calcium and other trace minerals, making them unavailable to the animal. The highest levels of oxalate is found in tea, spinach and rhubarb, with lower levels found in peas, beets and beet greens, lettuce, turnips, carrots and berries. Potentially toxic levels are found in the leaves of rhubarb and the common house plant, *diffenbachia*. High levels of oxalates can cause vomiting, diarrhea, poor blood clotting and convulsions. Lower levels can result in decreased growth, poor bone mineralization and kidney stones.

Phytate or phytic acid is a complex of phosphoric acid and sugar, and is very effective at chelating minerals such as zinc, iron and calcium, resulting in an unavailable complex. Phytates are most commonly found in nuts, legumes, cereal grains (germ and bran) and, in lesser quantities, in green beans, carrots, broccoli, potatoes, sweet potatoes and berries.

### Vitamin Antagonists

Thiaminase is a naturally occurring enzyme that destroys thiamine. Thiaminase is most often associated with raw fish, but it can also be found in a number of fruits and vegetables such as beets, brussel sprouts, red cabbage and berries, some organ meats and as a product of certain microorganisms that can inhabit the gastrointestinal tract.

A compound found in flax seed (and therefore linseed meal) acts as an antagonist to pyridoxine (vitamin B<sub>6</sub>). This compound apparently is an amino acid-type compound that forms an unavailable complex with pyridoxine.

### Natural Plant Toxins

Although not nutrient antagonists as such, lectins or phytohemagglutinins can cause kidney, liver and heart damage, destruction of gastrointestinal epithelium, red blood cell agglutination and cell mitosis interference. These compounds occur in legumes, especially the castor bean and black bean, and in lower levels in other plant seeds.

When saponins are consumed in high amounts, diarrhea and vomiting can occur. They are found in soybeans, alfalfa, spinach, asparagus, broccoli, potatoes, apples and eggplant.

There are several foods that have goitrogenic properties that could cause symptoms mistaken for iodine deficiency, or that could exacerbate a marginally iodine-deficient diet. Goitrogens are contained in soybean, peanuts, pine nuts and the entire brassica family (turnips, rutabaga, broccoli, brussel sprouts, cabbage, cauliflower, kale, kolrabi and mustard). They are also found to a lesser degree in carrots, peaches, pears, radishes, strawberries and millet. Low-protein diets increase the effects of goitrogens (anti-thyroid effects).

Other natural toxins or nutrient antagonists present in foods include gossypol, cyanogenic glycosides, photosensitizers and a variety of alkaloids and phenolic compounds. The significance of these compounds in most species is questionable. Many have shown beneficial effects in the body when provided at low amounts, but at higher amounts they may be toxic or carcinogenic. Low exposure to these items should never be considered to be dangerous, but the inclusion of any of them at high amounts in the diet, particularly in the raw form, should be avoided.

### Mycotoxins

Mycotoxins are compounds that are produced under certain conditions as metabolic by-products of molds. There have been nearly 100 mycotoxins identified since their initial recognition in the 1960's. They possess varying degrees of toxicity, some of which are carcinogenic. Mycotoxins are not associated with all molds, nor are they always produced by mycotoxin-producing species. The difficulty with mycotoxins is that they are totally undetectable by sight, smell and taste. Any product that is known to be moldy should not be fed due to the possibility of mycotoxins, as well as nutrient degradation and decreased palatability. Toxins, sources and pathology are shown in Table 3.2.



TABLE 3.2 Sources of Exposure and Pathology Related to Mycotoxin Ingestion

Mycotoxins	Common Feed Sources	Agent	Pathology
Aflatoxins	Corn, peanuts, cottonseed	<i>Aspergillus flavus</i> <i>A. parasiticus</i>	Liver damage Hepatomegaly Immunosuppression Kidney damage
Ochratoxin	Corn, barley, oats, wheat	<i>A. ochraceus</i> <i>Penicillium viridicatum</i>	Kidney and liver damage Hemorrhaging
Zearalenone	Corn, wheat	<i>Fusarium roseum</i> <i>F. graminearum</i>	Production of estrogen-like compounds
Trichothecenes (T <sub>2</sub> toxin)	Corn, wheat, barley, oats, forages	<i>F. tricinatum</i> <i>F. roseum</i> <i>F. graminearum</i>	Oral inflammation and lesions Neural disturbances Immunosuppression Hemorrhaging
Vomatoxin (2-deoxynivalenol)	Corn, sorghum, wheat	<i>F. roseum</i> <i>F. graminearum</i>	Gastrointestinal inflammation Vomiting
Ergot	Rye, barley, wheat, oats	<i>Claviceps purpurea</i>	Tissue death Kidney and liver damage

Mycotoxins can have a broad range of effects on the body ranging from a toxic dose with mortality in two to three days to chronic exposure of moderate levels where decreased disease resistance is encountered along with lesions in the liver, kidneys, nervous system, reproductive system and integument. Carcinogenic, mutagenic or teratogenic effects may also be exhibited. The type of effect and response is related to the exposure level and duration.

Mycotoxins are some of the most carcinogenic compounds known, with chronic exposure of levels in parts-per-billion causing cellular transformation. Species differ considerably as to their susceptibility, with ducklings being among the most susceptible. The LD<sub>50</sub> ranges from 0.5 mg/kg (duckling) to 60 mg/kg (mouse).<sup>13</sup>

Aflatoxin levels in food must be controlled by good harvesting, handling and storage procedures. Peanuts and corn are considered to be the human population's largest source of aflatoxin. The United States Food and Drug Administration does not allow any peanuts to be used in human food products with levels greater than 20 parts per billion of aflatoxin. This is also the level used by the livestock industry as the safe, allowable level in grain products. Certain crops, depending on the climatic conditions during the growing season and at harvest (peanuts, hay, corn, wheat), may be considered the most common sources of aflatoxin.

Mycotoxin contamination usually occurs when fungus is able to penetrate a seed hull or protective coating and reach the kernel. Because molds are ubiquitous, spores will always be present on un-

treated crops. Plant damage such as drought, stress and insect damage will increase the incidence of mold penetration into the seed and the possibility of mycotoxin production. After inoculation, warm and humid conditions help promote the mold growth and toxin development. Unfortunately, mycotoxins are very stable to heat and typical processing methods.

Some of the mycotoxins (trichothecene or T<sub>2</sub> toxin) are among the most potent protein synthesis inhibitors known. It has also been found that T<sub>2</sub> toxin reduces the plasma level of vitamin E by affecting micelle formation in the gastrointestinal tract.<sup>11</sup>

Similarly, aflatoxin increases the dietary requirement for vitamin D<sub>3</sub> and lowers the vitamin A stores in the liver. In addition, many of the mycotoxins, particularly aflatoxin, the trichothecenes (T<sub>2</sub> toxin) and ochratoxin, have metabolic effects in the body that impair the defense mechanisms.<sup>32,33</sup>

## Methods for Determining Nutrient Requirements

### Growth Requirements

There are a number of approaches for determining the requirement of a specific nutrient in a bird. The simplest and probably most effective way is to examine the nutrient's influence on growth. Diets that are identical in all aspects, except the experimental nutrient, are provided to groups of experimental birds. By feeding specific diets (each of which contains an incrementally larger level of the test nutrient), growth and other parameters are measured. The point at which no further statistically significant increase in growth is observed would be considered to be the requirement of that particular nutrient in that particular diet, under those specific experimental conditions. If this result is consistently reproducible, it can be considered valid. This method is relatively accurate, and a single study can be performed rather quickly. This experimental design is most often used to evaluate nutrient requirements for growth, but it

may also be used to evaluate a nutrient's influence on egg production, antibody production and bone strength.

Because growth is the period in which most nutrients are required at their highest levels, this type of study can establish the upper end of the suggested nutrient range. The use of these levels for adults would certainly provide a level far greater than the true metabolic need but, in most cases, these would still be within the safe range. The determination of the requirements for adults is very difficult, complex and in many cases impractical. Additionally, the differing requirements for each separate strain within a species is often different. Because of this, the accepted practice in humans has been to establish a minimum daily allowance, which is designed to meet or exceed the estimated requirement of 97.5% of the entire population, or approximately two standard deviations above the mean. This approach compensates for the great degree of biological variability within the entire species, as well as bioavailability in foods, variability of absorption efficiency, health status, environmental conditions and genetic background. (*Editor's note: The correlation of growth rate and health has not been established for companion birds.*)

### Evaluating Nutrient Status

The nutrient status of an individual is most easily accessed by carefully evaluating the adequacy of the diet provided. Considering the current feeding practices of many bird owners, it is likely that basic deficiencies can be discovered with very little effort. If simple dietary evaluation is not possible, or seems inconclusive, further testing is possible (however, somewhat difficult and inconclusive). The only practical method for further testing is through serum or plasma samples. These samples are ideally taken after a fast to reduce the presence of nutrients that were recently absorbed from a meal. Additionally, the circulating levels of many nutrients are tightly controlled, and, therefore, only show levels outside the normal range when body stores are severely depleted or exceeded. The matter is further complicated by the lack of reliable normal ranges (or in some cases, no information at all) and the high cost of certain nutrient assays. Many laboratories, however, are equipped to run plasma retinal or carotene levels (for vitamin A), plasma alkaline phosphatase (an indicator of vitamin D status), prothrombin time or clotting time (indicator of vitamin K status), serum calcium, phosphorous, electrolytes, trace minerals (although they may inaccurately reflect status) and parameters for the evaluation of lipids and proteins.

### Estimation of Nutrient Requirements

There is a severe need to set dietary guidelines to serve as a reference point that can be used as a standard for testing. Safe guidelines are needed to help aviculturists and companion bird owners who choose to feed a widely varied diet, to guide the commercial food manufacturers in producing diets that can assure longevity and good health, and to help veterinarians assess a patient's diet and educate the client in proper feeding methods. Because of the extreme difficulty in accurately determining the requirement of all nutrients, even for a single species, documented studies and specific requirements will not be available for decades, if ever. It is therefore necessary to derive these nutrient recommendations from other species that are better understood. Extrapolation from known species, if done wisely, can provide a reasonable starting point from which to base diets and efficacy studies. With subsequent evaluation of this derived nutrient profile and long-term monitoring to assess overall nutrient status, recommendations or allowances can be generated for a particular genus, species or strain that may be unique with regard to dietary requirement, digestive efficiency or other physiologic differences. This methodology does not look at "minimums" but rather at nutrient levels that would attempt to optimize all experimental parameters by providing more generous nutrient allowances. Table 3.3 lists the possible minimum requirements (an extrapolation from poultry species) and the dietary recommendations for companion bird species.<sup>7</sup>

### Nutrient Needs During Different Life Stages

#### Embryonic

An egg produced by a hen fed a nutrient-adequate diet is normally a rich source of the essential amino acids, energy, linoleic acid and all of the required vitamins and minerals for normal cell division, growth and maturation. If a hen is fed a nutrient-deficient diet that will allow production, embryo development may progress, but will be abnormally affected. This most often is observed as early embryonic death, usually with the formation of a blood ring after approximately three days of development (vitamin A deficiency), losses immediately prior to hatch due to an embryo with insufficient strength to complete the hatching process (riboflavin, biotin, folic acid and vitamin B<sub>12</sub> deficiencies) or embryonic malformation (zinc and manganese deficiencies).

**TABLE 3.3 Recommended Nutrient Allowances for Companion Bird Diets<sup>7,29</sup>**

These allowances can be used as general dietary guidelines for most psittacines and the commonly kept passerines. Species differences do occur, but have not been listed due to insufficient research. The anticipated minimum requirement (as extrapolated from other species) is included for comparison. These values do not compensate for nutrient bioavailability, genetic variability and other conditions.

Nutrient	Anticipated Minimum Requirement	Recommended Allowance for Maintenance <sup>1</sup>
Protein, %	10.00	12.00*
Fat, %	—	4.00*
Energy, kcal/kg	—	3000.00
<b>VITAMINS</b>		
Vitamin A, IU/kg	2500.00	5000.00*
Vitamin D <sub>3</sub> , IU/kg	500.00	1000.00*
Vitamin E, IU/kg	15.00	20.00*
Vitamin K, ppm	0.80	1.00
Thiamine, ppm	2.00	5.00
Riboflavin, ppm	4.00	10.00
Niacin, ppm	40.00	75.00
Pyridoxine, ppm	4.00	10.00
Pantothenic acid, ppm	12.00	15.00
Biotin, ppm	0.15	0.20
Folic acid, ppm	1.00	2.00
Vitamin B <sub>12</sub> , ppb	5.00	10.00
Choline, ppm	750.00	1000.00*
Vitamin C	No requirements demonstrated <sup>4</sup>	
<b>MINERALS</b>		
Calcium, %	0.30	0.50*
Phosphorus (available), %	0.15	0.25*
Phosphorus (total) approx., %	0.30	0.40*
Sodium, %	0.10	0.15
Chlorine, %	0.10	0.15
Potassium, %	0.30	0.40
Magnesium, ppm	500.00	600.00
Manganese, ppm	60.00	75.00
Iron, ppm	60.00	80.00
Zinc, ppm	40.00	50.00
Copper, ppm	6.00	8.00
Iodine, ppm	0.30	0.30
Selenium, ppm	0.10	0.10
<b>AMINO ACIDS</b>		
Lysine, %	0.45	0.60
Methionine, %	0.20	0.25
Tryptophan, %	0.10	0.12
Arginine, %	0.50	0.60
Threonine, %	0.35	0.40
Other essential amino acids are sufficient in common diets.		

1. The recommended allowances will support normal maintenance of companion birds and have been demonstrated to be adequate during long-term feeding. These levels, however, may not be sufficient for optimized health under varying conditions and will not be adequate for breeding and growth, which may require higher levels of certain nutrients.

\* Increased levels are suggested for growth/breeding diets due primarily to high requirements for adequate chick growth as opposed to increased demands for low-level breeding.

## Growth

Shortly before hatch, the embryo absorbs the remaining portion of the yolk sac into its abdominal cavity. At hatch, the absorbed yolk sac serves as a temporary energy reservoir. This may be adequate to supply the chick with nutrients for the first one to three days, depending on the species. As the chick's digestive system becomes fully functional, the period of rapid growth begins. Due to the high metabolic rate and the rapid division and growth of cells, the amino acid, energy, linoleic acid, vitamin and mineral requirements are at the highest point of the animal's normal life. Furthermore, if brooding temperatures are not sufficient, there is a further increase in the energy demand to maintain adequate body temperature. The requirement for amino acids are further increased during the period of feather development. These feathers, which are comprised of more than 90% protein (on a dry matter basis), can approach up to 10% of the total body weight in the young bird.

Under normal situations, the absolute nutrient requirements decrease throughout the growth phase, since the level of growth proportional to body weight declines with age. If optimal nutrient levels are not present at an earlier growth phase, but are present in excess of requirement towards the end of the growing cycle, the bird will display compensatory growth (compensating for an earlier lack of normal growth). Compensatory growth is characterized by both the flattening and extension of the normal growth curve, with the end result of a chick that reaches normal adult weight, but requires a longer time to do so. This is often observed when a baby is fed a nutritionally marginal diet (see Chapter 30). As the chick advances through the growth period, at some point the once marginal diet becomes adequate and eventually may even provide a generous proportion of nutrients relative to the requirement at that time. The compensatory growth phase is generally marked by a temporary increase in feed efficiency and rate of gain when compared to normal chicks of the same age.

## Maintenance

Requirements for the maintenance of an adult bird are the lowest for the entire life cycle. The bird's greatest need at this time is to provide adequate energy to maintain body temperature, metabolic functions and the appropriate activity level. Protein requirement is minimized, because the primary need is for the replacement of dead cells or of amino acids used in various metabolic systems (ie, enzymes). Similarly, the need for vitamins and minerals is to replace those that were lost through metabolic proc-

esses. In nearly all cases, these needs are considerably lower than for the growth period (or any other stage of production) due to the lower rate of cell formation and overall metabolic rate. Any increase in activity level, ambient temperature outside of the thermoneutral zone, molting and the exposure to any type of stress will alter the minimum nutrient levels required for maintenance.

### Breeding

The increased requirements by the hen for breeding can be divided into two general categories: those required for egg production and those required for maximum hatchability of the embryo. On a dry matter basis, the egg (without the shell) consists of approximately 45% fat and 50% protein. Additionally, the shell, which comprises approximately 10% of the total egg weight, is approximately 94% calcium carbonate (38% calcium). These three constituents represent the largest increase in nutrient needs in order for the hen to produce eggs. Because birds generally eat to meet their energy demands, increasing the energy content of the diet is not generally necessary. The diet does, however, require higher levels of protein, particularly of the sulfur amino acids (eg, methionine) and lysine. Calcium levels in the diet should be increased to minimize the decalcification of the bone and to prevent the formation of soft egg shells. Other nutrients that improve egg production (in poultry) when present at levels higher than the minimum maintenance requirement are vitamins A, B<sub>12</sub>, riboflavin and zinc. Vitamin D<sub>3</sub> levels slightly over the requirement will tend to improve egg shell characteristics, with larger amounts having no additional benefits.<sup>19</sup> To maximize hatchability of the embryo, increased levels of vitamin E, riboflavin, pantothenic acid, biotin, folic acid, pyridoxine, zinc, iron, copper and manganese are required over what is adequate for egg production.

Much of the reason for dramatically increasing the nutritional plane of a breeding bird's diet is to provide adequate dietary components for the chick to be fed. Psittacine and passerine birds are relatively low egg producers and their increased demand for nutrients required for egg production is transient. With adequate body stores through proper daily feeding, a diet designed specifically for egg production is not necessary (such as a diet that will meet the immediate need for calcium during the days of production). Instead, a moderately high plane of nutrition that will optimize body stores, allow ready repletion of depleted stores and provide adequate nutrition for chick growth is probably the simplest and safest

means of dietary management. This will allow for adequate chick growth and satisfactory levels of all nutrients for egg production. Calcium can be quickly repleted without the risk of over-supplementing by providing an "egg production" diet during the breeding season. Feeding for optimal chick growth not only decreases the duration in the nest of parent-raised chicks, but also promotes rapid recycling of the hen (repletion of body stores and physiologic preparation for returning to nest).

### Geriatric Nutrition

To date, there has been no research on the nutritional needs of geriatric psittacine birds. This is due largely to the relative scarcity of geriatric birds in aviculture or as companion animals. Because of the historically poor diets offered to these birds and their subsequent shortened life-span, the mean population age of companion birds is low with respect to the potential. As the husbandry and veterinary care of these species continue to improve, proper geriatric nutrition will become a concern. Based primarily on geriatric research (in humans, rats, dogs and cats), it can be assumed that the geriatric bird should be provided with a highly digestible diet that maintains proper weight while providing slightly reduced levels of proteins, phosphorous and sodium, and levels of other vitamins and minerals similar to those received earlier in life. Slight increases in vitamins A, E, B<sub>12</sub>, thiamine, pyridoxine, zinc, linoleic acid and lysine may be helpful to overcome some of the metabolic and digestive changes accompanying old age.

### Stress

Companion and aviary birds are possibly subjected to more stresses than any other animals maintained in captivity. Stresses are both psychological and physical. Whether the bird is imported from the wild or is one of the most "domesticated" species, captivity alters its innate behaviors. The caretaker is often viewed as a threat, and the natural social interactions (flocking, mate selection) are inhibited. Crowding, handling, exposure to unusual pathogens, unsanitary conditions and malnutrition may all be considered stress factors. Stresses tend to be cumulative, and a single stress often has very little clinical effect on the bird. However, when one or more additional stress is applied, the bird may be weakened to the point of clinical illness or death. Stress in young birds results in a decrease in weight gain and, if left uncorrected, weight loss and morbidity may occur.

The body's response to stress is the "flight or fight" syndrome, and the immediate response is to mobilize

and produce glucose for the increased energy need. After carbohydrate stores are depleted (within approximately 24 hours), protein and fat stores are broken down, with the breakdown of skeletal muscle supplying amino acids for gluconeogenesis. The changes in metabolism also affect the normal metabolism or levels of vitamin A, C, calcium, zinc, iron, copper and magnesium. Attempts to restore these nutrients through special dietary modifications are probably futile. Instead, adequate diets should be provided to ensure the normal presence of sufficient body stores, which will also allow for satisfactory repletion of stress-depleted stores.<sup>44</sup>

### Disease

There has been very little research done on the specific effects of diseases on the requirement and metabolism of each nutrient, and how these might affect the total requirement of individual birds. As the body enters the disease state, it rapidly begins to conserve nutrients in order to maintain needed functions. The most critical nutrient for the body to maintain during illness is water (see Chapter 15).

Secondly, the necessary energy supplies to the body must be maintained. Because of the increased metabolic rate during illness, there is a higher energy need. In humans, it has been found that the basal energy requirement will be exceeded by 50-120%, depending on the severity of the stress response. Although much of this energy demand still falls within the normal maintenance requirement, it is critical to maintain or exceed the typical energy intake, which can be provided via carbohydrates, fats or protein.

Dietary protein is the third most critical component to be provided to the debilitated patient. With the increased metabolic rate, there is a subsequent increase in body protein turnover, much of which is recycled by the body and not lost. Because this degradation and resynthesis is not completely efficient, an increase in metabolic rate results in an increased amino acid requirement. There is also increased demand for amino acids because of the need for additional immune components and tissue repair. Without adequate amino acid intake, labile protein stores (plasma, liver, muscle) are degraded for the process of gluconeogenesis. There may also be a decreased efficiency in the utilization of proteins, thereby further increasing the needs and importance of an adequate protein diet. The exceptions to increasing the protein in the diet are during the acute phase of liver or renal disease.

**TABLE 3.4** Changes in Need for Nutrients During Periods of Debilitation

<b>Vitamin C</b>	The debilitated animal may not be able to adequately synthesize enough vitamin C, especially in the case of hepatic damage. Increased vitamin C in other species exposed to a number of different types of stresses has shown to improve production and health criteria.
<b>Vitamin D</b>	In diseases affecting the liver and kidneys, the enzymes required to produce the metabolically active form of vitamin D <sub>3</sub> will be impaired. In these situations, or in the case of a marginally deficient animal, it may be beneficial to provide vitamin D <sub>3</sub> therapy.
<b>Vitamin K</b>	For animals that have undergone extensive antibiotic therapy and are being maintained on an unsupplemented or marginally supplemented diet, it may be necessary to provide vitamin K because of its decreased synthesis by normal intestinal flora.
<b>Vitamin B complex</b>	In the case of an anorectic animal, it may be beneficial to supply additional B vitamins, especially thiamine. Other water-soluble vitamins such as riboflavin, pyridoxine and folic acid are particularly important in protein and energy metabolism; therefore, these vitamins have increased importance in the disease state.
<b>Zinc</b>	In a nutritionally compromised animal, zinc will improve healing and is an important component in protein synthesis; therefore, zinc is necessary for the maintenance of the immune system and phagocytic activity.

There is a lack of consistent studies in the literature indicating increased vitamin or mineral requirements in the debilitated animal. Supplying nutrients at recommended levels is probably sufficient in most cases; an increase in certain vitamins and minerals may be prudent, however (Table 3.4).

## Current Nutritional Knowledge

### Protein Needs

There have been few scientific studies conducted to investigate the nutritional needs of companion and aviary birds. Most of the beliefs on nutrition stem from observations in clinical and avicultural settings. Two of the best scientifically conducted studies that have been published investigated the total protein requirement and lysine requirement of the growing cockatiel. Chicks performed best and reached the

weaning stage earliest on a 20% crude protein diet. Those fed a 10% or 15% crude protein diet grew considerably slower, with stunting and slightly increased mortality occurring in the group fed 10% protein. On 5% crude protein diets, chicks were severely stunted, with subsequent mortality. Those fed a 25% crude protein diet performed similar to the 20% group, but developed behavioral problems marked by meal refusal and increased aggressiveness. Those provided with a 35% protein diet displayed slight growth depression and further increased signs of aggression.<sup>21,40,41</sup>

### Lysine Needs

The requirements for lysine were estimated by providing purified diets that were equal in all respects except lysine levels. In two experimental trials, diets supplying 0.1, 0.4, 1.0 or 2.0% lysine and 0.2, 0.4, 0.6, 0.8 or 1.2% lysine were provided. Cockatiel chicks showed the best growth responses when given diets in the range of 0.8 to 1.2% lysine. At lower levels, growth was proportionately depressed, displaying a typical nutrient-to-growth-response curve. The two lowest levels of dietary lysine resulted in little growth and high mortality. Performance on the 2% lysine diet was slightly poorer than the 1% diet, most likely due to the creation of a marginal amino acid imbalance at the higher level. Unlike poultry species, which exhibit feather depigmentation (the formation of feathers lacking melanin pigment) during a lysine deficiency, all cockatiels, even those on the most severely deficient diet, had normal feather pigmentation. This suggests a metabolic difference between poultry and altricial birds (at least the cockatiel).<sup>38,39</sup>

### Energy

Energy requirements have been estimated in a variety of companion bird species. The approximate daily metabolizable energy (ME) needs for budgerigars appear to be between 12 and 16 kilocalories (kcal) per day in a normal maintenance situation.<sup>7,17,47</sup> Canaries require approximately 12 kcal/day<sup>7,24</sup> if maintained at 70°F. A 350 g Amazon parrot would require an intake of 100 kcal/day, and a 1000 g macaw would require 220 kcal/day. Temperatures above or below 70°F would result in lower or higher needs, respectively.<sup>9</sup>

### Current Beliefs on Nutrient Requirements

Based on avicultural and clinical observations, there have been a number of hypotheses developed regarding species-specific differences in nutrient requirements. These have not been scientifically tested, but

many have been substantiated by repeated reports in a variety of situations. It is difficult, however, to distinguish between the actual increased requirement of a nutrient in a specific species and species-specific differences in the manifestation of clinical deficiency signs. That is, on a marginal diet, one species may not display overt deficiency signs, while another on the same diet (same nutrient intake) could possibly show distinct clinical changes. In a clinical situation, the overall adequacy of the diet should be evaluated before additional supplementation is suggested for the species (Table 3.5).

### Vitamin Differences

It has been suggested that several species may have increased needs for vitamin A over most other commonly kept species. Those most frequently seen to respond to "higher" levels are Eclectus Parrots, conures<sup>20</sup> and certain Amazon parrots, most notable the Blue-fronted Amazon. The increased need for vitamin A in Amazon species is often linked to increased immunity against viral disease (poxvirus). This could well be an example of the variation in needs to maximize specific metabolic functions. Generally, the amount of a nutrient required to maximize a production parameter (such as growth or egg production) is often not sufficient to maximize immune response or other parameters. Limited research on vitamin A requirements indicates a need of 7,000 IU/kg feed in budgerigars. Clinically, a level equivalent to 5000 to 10,000 IU per kg in the diet has proven successful in preventing deficiency symptoms.<sup>15</sup>

Certain neonatal macaw species, especially the Blue and Gold Macaw and Hyacinth Macaw, seem more prone to the development of hypervitaminosis D<sub>3</sub> than other psittacine chicks. When a cross section of large psittacine babies was fed a moderately high level of vitamin D<sub>3</sub> (2500 International Chick Units [ICU]/kg *dry mix*; 1.0% Ca), Blue and Gold Macaws were the only species to develop mild signs of hypervitaminosis D<sub>3</sub>, characterized by enlarged kidneys and mild, early calcification of the renal tubules.<sup>5</sup> Similar findings have been reported on a hand-feeding diet containing between 1000 and 4000 ICU/kg (the range due to the variable addition of vitamin supplementation), which resulted in crop stasis, increased serum uric acid levels and the presence of articular gout and regurgitation after feeding. Radiographically, the kidneys were found to be enlarged, with areas of calcification in the kidneys and proventriculus. Subsequent necropsy showed widespread soft tissue calcinosis.<sup>46</sup> In both reports, other species fed similarly on the same diets were not affected.

TABLE 3.5 Potential Toxic Effects of Nutrients

<b>VITAMIN A</b> (20-100 times required) <sup>43</sup>	<b>CHOLINE CHLORIDE</b> (2 times required)
Weight loss	Increased mortality
Decreased food intake	Decreased use of vitamin B <sub>6</sub>
Swelling/crusting eyelids	
Inflammation of mouth	<b>CALCIUM</b> (2.5% of diet) <sup>45,48</sup>
Inflammation of nares	Nephrosis
Decreased bone strength	Visceral gout
Dermatitis	Renal gout
Hepatopathy	Hypercalcemia
Hemorrhaging	Hypophosphotemia
	Decreased food intake
<b>VITAMIN D</b> (4-10 times required)	<b>MAGNESIUM</b> (20 times required)
Increased calcium absorption	Decreased growth
Increased bone resorption	Decreased egg production
Hypercalcemia	Decreased egg quality
Decreased PTH	
Mineralization of soft tissues	<b>MANGANESE</b> (20-50 times required)
Nephrocalcinosis	Iron deficiencies
Polyuria	
<b>VITAMIN E</b> (100 times required)	<b>SELENIUM</b> (50 times required)
Decreased growth	Decreased weight gain
Anemia	Weight loss
Increased prothrombin time	
Decreased bone mineralization	(100 times required)
Decreased liver storage of vitamin A	Decreased egg weight
	Decreased hatchability
	Dermatitis
<b>VITAMIN K (Menadione)</b> (1000 times required)	(Severe excesses)
High mortality	Blind staggers
Anemia	Pulmonary congestion/edema
Hyperbilirubinemia	Liver cirrhosis
Toxicity unlikely	
Thiamine (rapidly excreted by kidneys)	<b>COPPER</b> (50 times required)
Riboflavin (rapidly excreted by kidneys)	Decreased growth
Pantothenic acid	Hepatopathy
Folic acid	Accumulates in liver
Cyanocobalamin	Death
Vitamin C	
<b>NIACIN</b> (10 times required)	<b>ZINC</b> (10-20 times required)
Flushing - vasodilation	Gastroenteritis
Pruritus	Decreased food intake
Gastroenteritis	Anemia
	Decreased bone mineralization
	Depression
<b>PYRIDOXINE</b> (50 times required)	
Decreased egg production	
Infertility	

See text for toxic effects associated with excesses of phosphorus, potassium, sodium, chloride, iron and iodine.

High levels of vitamin D<sub>3</sub> frequently result in the occurrence of gout.<sup>18</sup>

It has also been suggested that conures have a higher requirement for vitamin K, due to the bleeding disorder often seen in this species. This theory may not be

valid because incidence of the syndrome has not been reported on a nutritionally adequate diet. This bleeding syndrome has also been alleviated by calcium supplementation and a generally improved diet, empirically verifying the importance of calcium status for blood clotting and suggesting that the syndrome is not dependent on vitamin K alone.<sup>37</sup>

### Minerals

Cockatiels have been noted to be particularly sensitive to high calcium or high calcium and vitamin D<sub>3</sub> levels in the diet. Adult diets containing over 1% calcium, particularly when accompanied by generous levels of vitamin D<sub>3</sub> (over 2000 ICU/kg dry diet) have been found to be excessive in long-term feeding studies.<sup>2</sup> Normal egg production criteria have been satisfied at dietary calcium levels as low as 0.3 and 0.35%.<sup>6,41</sup>

Research in adult poultry has indicated that normal bone mineralization, plasma calcium and alkaline phosphatase levels can be maintained at below 0.05% calcium in the diet.<sup>28,42</sup> This is supported by a similar observation in cockatiels,<sup>41</sup> and is consistent with dietary levels of unsupplemented seeds, which have sustained birds for decades, although poorly. Levels for optimal health would seem to be considerably higher.

### Energy

Large macaws, particularly the Hyacinth, appear to perform better on a higher fat diet than other species. This does not seem surprising considering the predominance of oil-based foods in the native diet of some of these species. An increase of approximately 25% fats over that adequate for other species has been found to be necessary to support maximum growth.<sup>8</sup>

A number of species are more prone to obesity than others. This can be a result of lower metabolic needs (ie, more energy efficient), better energy absorption, lower energy expenditures (ie, more sedentary in nature) or poor satiety biofeedback to the hypothalamus (overeating). Rose-breasted Cockatoos (galahs) and budgerigars are very prone to obesity and are probably examples of birds with slightly lower energy requirements. Amazon parrots frequently become obese due to their sedentary behaviors. In all birds, the likelihood of becoming overweight is increased as the bird ages and its metabolic rate decreases. Reducing the caloric density of the diet or limiting intake (by reducing food quantity or feeding duration) and

encouraging additional activities are essential in these cases.

### Differences in Nutrient Metabolism and Requirements Based on Evolutionary Diversion

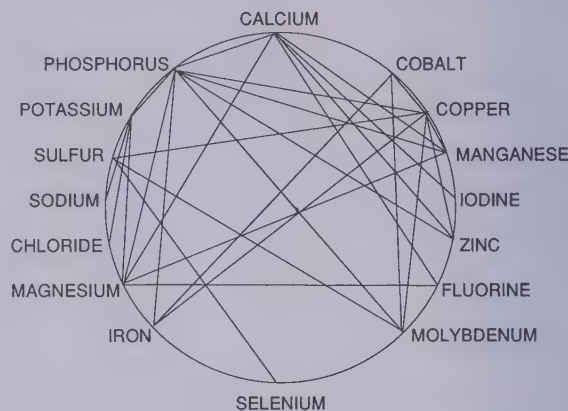
There is no generic companion bird with respect to nutritional requirements. It is highly likely that there will be distinct species' differences verified as the base of nutritional knowledge of companion birds increases. Based on the ecological diversity in which species have evolved, differences can be expected. For instance, budgerigars, cockatiels and a number of the grass parakeets and finches range into the vast, arid interior of Australia. These birds are expected to have developed biological adaptations allowing them to conserve both nutrients and water for existence in this sparse habitat. The sensitivity of cockatiels to calcium and vitamin D<sub>3</sub> levels that apparently have no negative impacts on other psittacines may be an example of such an adaptation. In the wild, these birds exist on a diet primarily of seeds,<sup>50</sup> which tend to be only a moderate source of many nutrients. Conversely, psittacines of the neotropics tend to consume a wide variety of foodstuffs, including an abundance of fresh vegetative matter, providing a less seasonally dependent, higher plane of nutrition. Birds in this environment have not had the need to develop any nutrient-conserving mechanisms, and may, therefore, have somewhat higher needs.

### Nutritional Labeling of Commercial Products

Commercial labeling is frequently misunderstood, particularly with respect to the guaranteed analysis. All pet foods are required by law to list levels of crude protein, crude fat, crude fiber and moisture. These are not precise numbers, but rather guarantees of either the minimum or maximum amounts contained in the product. Protein and fat are listed as minimums, because they are of specific nutritional value and are among the most expensive components of food. The food should not contain less than the guaranteed level, but may contain any amount in excess of this minimum. In a processed food, these levels are generally close to the guarantee because of the significant added cost in oversupplying these nutrients.

The protein guarantee is analytically quantitative, being determined from the amount of nitrogen in the product (usually calculated as % crude protein = % nitrogen x 6.25). It provides no estimation of protein quality (ie, the product's amino acid profile). Indeed, non-protein nitrogenous sources will be reflected in the crude protein value.

## MINERAL INTERRELATIONSHIPS



**FIG 3.2** A well formulated, properly balanced diet represents a precise combination of over 40 nutrients, sometimes provided by just as many different ingredients.

Fiber and moisture are required to be listed as maximum amounts in the product, because both are traditionally considered of little nutritional importance and can, at higher levels, create quality problems. Manufacturers will often list the highest possible value that might occur in order to avoid violations, unless of course there is a negative consumer impression associated with the high value, in which case the manufacturer will guarantee a value with a narrower margin of safety.

Other nutrient guarantees are optional, except when the product specifically states that it is supplemented with certain nutrients (or category of nutrients), in which case those nutrients must be guaranteed. This law exists to ensure that all nutrient supplements are adequately labeled and the consumer is protected and informed about the product that they are buying. In the case of products that claim "vitamin-enriched" or other similar statements, those nutrients must be guaranteed so that a knowledgeable consumer can differentiate among the class of products (eg, diet, supplement, concentrate). In general, regulatory officials discourage the guaranteeing of vitamins, minerals and amino acids due the difficulty of ensuring compliance. Unless a product expiration date is listed on the package, the guarantees are stated for the life of the product. Due to normal loss of vitamin potency, a product that is not sold quickly may eventually fall



below the levels guaranteed. These nutrients often are expensive to analyze; therefore, regulatory officials are limited in the extent to which they can verify product compliance.

Complete nutrient listings may encourage the purchase of a product with unnecessarily high nutrient levels. Because of the typical philosophy that “more is better,” number comparison between products will often result in the decision to purchase the product with the highest level. This may be particularly dangerous, especially in light of the relative lack of information regarding companion bird diets. Because of the lack of reference values, incorrect decisions can be expected to be the norm and should not be encouraged by listing numbers that may be relatively “meaningless.”

### Ingredient Statement

Companies are required to list the ingredients contained in the food in their order of dominance, (eg, in order from highest to lowest concentrations). This order is very difficult to police and is essentially left to the manufacturer to, in good faith, provide accurate information to the consumer. While still maintaining accuracy in labeling, manufacturers may opt for labeling techniques that become vague or “hide” ingredients that have poor consumer perception. Instead of listing each ingredient by its full, approved term, “collective” terms can be used to group similar products together under an umbrella term. Therefore, the collective term “grain products,” can be used to describe the product’s total content of cereal grains (corn, wheat, oats, barley), regardless of its form (whole, ground, heat processed). Likewise, the term “animal protein products” can be used to reflect a wide variety of ingredients such as meat meal, blood meal, dried milk, hydrolyzed feathers or fish residue. If the manufacturer chooses this method of terminology, all major ingredients must be listed in the collective manner. This gives manufacturers the opportunity to make major changes within general ingredient categories in order to take advantage of least-cost formulation.

Multiple ingredients serving the same functional purpose are sometimes used so that each ingredient can be listed in a lower position on the ingredient statement. For example, corn syrup, honey, sugar, dextrose or fructose could all be used as sources for natural sweeteners and could be combined in a product to make an individual ingredient appear very low on the ingredient listing, while maintaining a very high level of the functional compound (ie, sugars).

TABLE 3.6 Control of Product Oxidation

1. **Environmental control** - Lowering the product temperature to decrease the rate of oxidation (refrigerating), or modifying the atmosphere to remove the available oxygen (packing in nitrogen), minimizes the amount of oxidation.
2. **Rapid product use** - Oxidation is minimized by using the product as quickly as possible after the ingredients are mixed and processed. This is particularly critical with a complete, processed food that does not contain antioxidants, because the presence of trace minerals acts as a catalyst for the oxidation process.
3. **The use of antioxidants** - Either natural or chemical antioxidants can be used. Natural antioxidants such as vitamin E (and other tocopherols) and vitamin C tend to have a limited antioxidant life and do not give the product the length of protection that is possible with chemical antioxidants. Chemical antioxidants (ethoxyquin, BHT, BHA) provide the longest period of protection. There are no scientific studies detailing the effects of any preservatives on the long-term health of companion birds.

Chemical antioxidants are assumed to be safer than the carcinogenic compounds that are known to be produced through oxidative rancidity.

This type of ingredient selection can make the product, through the labeling, more consumer-appealing.

### Antioxidants

Some form of protection against product oxidation is essential to maintain nutritional adequacy of the product, to ensure a high level of palatability and to prevent the formation of oxidative by-products, some of which are carcinogenic. Oxidation of formulated diets can be minimized through a number of techniques (Table 3.6).

### Grit

Grit is not required in the normal, healthy psittacine or passerine bird. Grit, defined as a granular, dense, insoluble mineral material (generally granite or quartz) is required in birds that consume whole, intact seeds. Examples of birds that require grit are pigeons, doves, free-ranging gallinaceous species and Struthioniformes. These species naturally eat whole grains as a varying portion of their diet. Because of the inert nature of the fibrous coating of many seeds (particularly corn, peas), digestive enzymes are relatively ineffective against them. Grit in the ventriculus acts to grind the whole seeds, thereby providing a substrate on which the digestive enzymes can act. Psittacine and passerine birds normally remove this fibrous hull, allowing the ingested portion to be easily acted upon by the digestive enzymes. It is likely, however, that in the case of a bird with a pancreatic

dysfunction or other problems involving the physical digestion of food, grit could provide a benefit by enhancing the surface area for digestive enzymes to act. There have been numerous examples of birds not having grit for 15 to 20 years and still not showing any signs of decreased performance or poor digestion. Amazon parrots that did not receive grit for over five years still maintained high digestibility of ingested sunflower seeds, showing the unimportance of grit in the healthy bird.<sup>1</sup> There have been numerous reports of birds, especially with health problems and depraved appetites, consuming copious quantities of grit and developing crop or gastrointestinal impactions. Considering the small chance of benefit and the potential risk, ad libitum feeding of grit should be avoided.

### Food Selection

Psittacines, in particular, have individual preferences for foods based on previous experience (or habit), food placement (position in the cage), particle size, fat content, texture, shape, color and taste. These preferences can be strong, and most clients encourage them by providing what the bird is most likely to readily eat. Some owners even interpret these avid habits as an “addiction” to a certain food (often sunflower seeds or peanuts) because the bird refuses to eat anything else by its own volition. This type of limited feeding pattern can result in severe nutrient deficiencies if the selected food is not nutrient-complete and balanced. This is especially likely if the poor eating habits are left unchecked for an extended length of time. It must be emphasized that these preferences are individualized, especially in the larger psittacines, with some individuals having very distinct preferences. This can be illustrated by the choice of food based on color. Some individuals have no color preferences whatsoever, while others have distinct biases for certain colors (eg, red, yellow, brown).<sup>3</sup> Birds must be trained to eat new foods. This is best accomplished by providing limited portions, or meals, to encourage consumption of everything offered, as opposed to a virtual ad libitum feeding program where the bird can reach satiety by eating only one or two of its favorite ingredients. Providing a large variety of foods immediately pre- and post-weaning is a very effective way to develop good eating habits that will tend to persist throughout life. This will result in a healthier, less finicky companion bird.

## Essential Nutrients and Their Biological Functions

Essential nutrients are those that are required to properly drive biochemical reactions within the body. These nutrients may be required as a specific energy source, as structural components or as factors and cofactors in specific biochemical reactions or processes (Table 3.7).

### Energy

The total amount of energy, or the gross energy contained within the feed, is broken into several fragments as it is metabolized in the body. During the process of digestion, potential energy sources are lost through the feces, urine and urates. What remains is the metabolizable energy (ME), or what is available for the body's metabolic processes. A portion of the ME is lost as heat (the heat increment). The remaining energy (net energy value of the food) is available for maintenance of the bird. Any energy that remains after satisfying the basic maintenance requirements is available for production activities such as growth of body mass and feathers, deposition of fat, production of eggs and for exercise.

The bird derives energy from proteins, fats and carbohydrates in the diet. Of these, protein is the least efficient source of energy, because the body must deaminate the amino acid, excrete the nitrogen as uric acid and then use the remaining carbon skeleton for glucose or fat synthesis. The average gross energy of protein is 5.65 kilocalories/gram. After the losses through deamination and subsequent metabolic reactions, protein yields a net of 4.1 kcal/g.

Carbohydrates are the most important energy source for the body because they are the only energy form that the brain can use. Of the carbohydrate family, energy is derived from starches (digestible polysaccharides), disaccharides (sucrose, maltose) and the simple sugars or monosaccharides (glucose, fructose, mannose, galactose). Lactose, the disaccharide contained in milk, is a very poor energy source for avian species because of an inefficient supply of lactase in birds to hydrolyze lactose into its components of glucose and galactose. Carbohydrates are efficiently metabolized with an ME value of 4 kcal/g.

**TABLE 3.7 Relative Nutrient Content of Commonly Used Food Sources<sup>4,30</sup>**

NUTRIENT	EXCELLENT (Over 20 times requirement)		GOOD (Over 2 times requirement)		ADEQUATE (1/2 - 2 times requirement)	
<b>VITAMINS</b>						
Vitamin A	Fish liver oil Liver Alfalfa meal Carrots Sweet potato	Greens (spinach, parsley, kale, dandelion, turnip greens) Red peppers	Dried milk Cheese	Egg	Fish meal Corn	Peanuts
Vitamin D <sub>3</sub>	Fish liver oil Liver (depending on levels fed)	Fish oil	Eggs (especially yolk)		Dried milk	
Vitamin E	Safflower oil	Sunflower oil	All vegetable oils Alfalfa meal Sunflower seeds Safflower seeds	Soybeans Wheat germ meal Corn gluten meal and germ	Cereal grains Dried milk	Fish products
Vitamin K			Parsley Cabbage Brussel sprouts	Spinach Cauliflower	Lettuce Broccoli Carrots Liver	Turnip greens Milk Eggs Fish meal
Thiamine	Dried brewer's yeast		Wheat germ meal Rice bran Sunflower seeds Soybeans Wheat middlings Corn germ (and by-products)	Peas and beans Dried whey Wheat Oats Peanuts Millet Carrots	Soybean meal Eggs Alfalfa meal Dried milk	Fish meal Liver Most whole grains Potatoes
Riboflavin			Brewer's yeast Dried whey Dried milk Wheat germ Liver	Eggs Fish and fish by-products Alfalfa meal	Millet Peas Beans	Wheat Corn
Pyridoxine (B <sub>6</sub> )			Brewer's yeast Eggs Whey Liver Alfalfa meal Black strap molasses Peanuts	Sunflower and safflower Peas Soy products Alfalfa meal Wheat germ Fish by-products	Flax Millet Milo	Buckwheat Wheat Other whole grains
Niacin			Yeast products Sunflower seeds	Meat & fish by-products	Peanuts Corn by-products Wheat germ Alfalfa meal	Wheat Barley Corn
Pantothenic Acid	Royal jelly		Yeast products Eggs Whey and dried milk Liver	Alfalfa meal Peanuts Sunflower and safflower seeds Wheat germ meal	Peas Millet Wheat	Oats Corn Other whole grains
Folic Acid			Yeast products Alfalfa Soybeans	Wheat germ Liver	Beans Wheat Oats Peanuts	Other whole grains Beets Spinach
Biotin			Safflower Liver Eggs Molasses Dried milk and whey Soybean products	Alfalfa meal Milo Oats Peas Peanuts Corn gluten meal	Barley Beans	Flax Wheat
B <sub>12</sub>	Fish and meat by-products		Eggs Dried milk	Yeast products		
Choline			Fish and meat by-products Yeast products Rape seed Dried whey	Wheat germ Sunflower and safflower seeds Soybean products Peanuts	Alfalfa meal Most whole grains Beans	Peas Eggs

**TABLE 3.7 Relative Nutrient Content of Commonly Used Food Sources (cont.)<sup>4,30</sup>**

NUTRIENT	EXCELLENT (Over 20 times requirement)		GOOD (Over 2 times requirement)		ADEQUATE (1/2 - 2 times requirement)	
<b>MINERALS</b>						
Calcium	Calcium carbonate (incl. cattle- bone, egg shell)	Bone meal Dicalcium phosphate	Fish and meat meals Kelp	Alfalfa meal Whey	Dried milk Cheese	Oil-type seeds Most nuts
Phosphorous	Dicalcium phosphate	Bone meal	Fish and meat meals Brewer's yeast Dried whey Wheat germ meal	Peanuts Pumpkin seeds Most oil seeds Nuts	Corn gluten meal Cereal grains	Egg
Magnesium					Kelp Bone meal Sunflower, safflower and other oilseeds	Nuts Alfalfa meal Brewer's yeast Wheat germ meal
Sodium	Salt	Bone meal	Dried whey and milk	Dried parsley Fish meal	Dried leafy vegetables Dried carrots	Alfalfa meal Eggs
Chlorine	Salt		Molasses Meat and fish products Dairy products	Alfalfa meal Dried parsley Carrot	Egg Green leafy vegetables	Broccoli Cereal grains
Potassium			Dried peppers Whey Dried carrot Alfalfa meal Molasses Soybean products Dried apricots	Bananas Brewer's yeast Oil seed products Legumes Oil seeds Wheat germ meal	Nuts Dried fruits and vegetables	Oil-type seeds Cereal grains
Manganese			Dicalcium phosphate	Calcium carbonate Wheat germ meal	Hemp seed Wheat products Soy products	Oat products Nuts
Iron	Bone meal		Dried parsley Fish and meat meals Calcium carbonate Corn gluten meal	Alfalfa meal Dried whey Soybean meal Brewer's yeast	Most cereal grains (especially millet, barley, oats, canary grass seed)	Oil-type seeds Nuts Dried carrots
Copper			Dried whey Molasses Brewer's yeast	Oil seeds Corn gluten meal Nuts	Fish and meat products Peas	Alfalfa meal Cereal grains
Zinc			Fish and meat meals Wheat germ meal	Wheat middlings Bone meal	Oil-seed products Soybean meal Nuts	Wheat Oats Corn gluten meal
Iodine	Dried whey		Fish and meat meals	Molasses	Egg Cheese	Brewer's yeast
Selenium	Fish meal		Brewer's yeast Corn gluten meal Wheat middlings Oil seeds Alfalfa meal	Wheat germ meal Rice Dried parsley and spinach Oats	Cheese Egg Soybean meal	Cereal grains (depending on soil)
<b>AMINO ACIDS</b>						
Lysine			Fish and meat meals Soybean meal Dried parsley and spinach	Brewer's yeast Wheat germ meal Peas Dried whey	Oil-type seeds (especially sunflower and safflower) Corn gluten meal Alfalfa meal	Nuts Oats Canary grass seed Barley Buckwheat Millet
Methionine			Corn gluten meal Fish and meat meals Brewer's yeast Soybean meal	Canary grass seed Sunflower Wheat germ meal Dried whey	Oil seeds Millet Peas Alfalfa meal	Nuts Wheat, oats, barley & other cereal grains

Carbohydrates also form the fiber fraction of the diet, broadly classified as undigestible carbohydrate. This fraction consists mainly of cellulose, which is essentially undigested because of the bird's lack of the enzyme cellulase. Also included are the hemicelluloses and lignin, all of which are poorly digested. These fibrous agents generally minimize the absorptive space in the gastrointestinal tract. The hemicellulose, psyllium, is an exception, as it acts to increase absorption. The required dietary fiber intake of varying species of companion breeds is undetermined.

Dietary fat is not only an important source of energy but it is the primary storage form of energy in the body. The ME in fat is concentrated with a value of 9 kcal/g, 2.25 times greater than that of either carbohydrates or protein. Fat is also easily absorbed into the body via the gastrointestinal tract, with its digestibility being dependent on the fatty acid composition.

### Essential Fatty Acids

Animals and birds have no requirement for fat per se, but they do have a requirement for the individual fatty acids that make up fat. Fatty acids are characterized based on their length (ie, the number of carbon atoms contained in the chain), the degree of saturation (the number of double bonds in the chain, commonly referred to as saturated, unsaturated or polyunsaturated) and the location of the initial double bond.

The primary essential fatty acid for animals and birds is linoleic acid. This compound cannot be synthesized in the body so it must be provided through the diet. Arachidonic acid is sometimes considered to be an essential fatty acid; however, it can be synthesized from linoleic acid.

The predominant fatty acid compounds in bird tissues are oleic acid, palmitic acid and linoleic acid. Body fat composition will be somewhat influenced by dietary fatty acid content because of the absorption and subsequent deposition of some intact fatty acids. Common vegetable oils are generally high in linoleic acid (eg, corn oil, soybean oil, peanut oil = 50%; sunflower oil = 60%; safflower oil = 75%). Tropical oils, such as coconut oil, contain substantial amounts of medium chain fatty acids, and are therefore poorer sources of linoleic acid.

Absorption of these fatty acids varies depending on the type, the form (free or as part of a triglyceride),

the ratio of unsaturated to saturated fatty acids in the diet, other dietary constituents and the intestinal microflora. Generally, oleic and linoleic acids are the most efficiently absorbed by the bird. This occurs because of the ease with which these fatty acids form mixed micelles with the bile salts, thereby improving their digestion by pancreatic lipase. In this manner, they will also enhance the absorption of other less efficiently absorbed fatty acids when they are present together.

The essential fatty acids are used as structural components in the cell with particular importance in the cell membranes. They are also precursors of prostaglandins.

Based on the general requirements for most other species, it can be safely predicted that the linoleic acid requirement for companion and aviary birds is 1.0 to 1.5% of the diet. In seed-based diets, this would rarely fall short, but in a processed, low-fat diet there could be a marginal deficiency.

### Amino Acids and Protein

Amino acids are the building blocks of the protein chain. The type of protein synthesized depends on the complex genetic process of transcription and translation between the DNA and RNA of the body. A specific protein is created by the shaping of the polypeptide chain into its unique three-dimensional structure based on interactions between the individual amino acids of the chain.

The protein chain can contain up to 22 different amino acids. Of these, ten cannot be manufactured by the body, so they must be routinely provided by the diet (essential amino acids). They are lysine, arginine, histidine (basic amino acids), methionine (sulfur-containing), tryptophan (heterocyclic), threonine, leucine, isoleucine, valine (aliphatic) and phenylalanine (aromatic). Three other amino acids (cystine, hydroxylysine and tyrosine) are formed through modification of an essential amino acid (methionine, lysine and phenylalanine, respectively). These are not considered essential per se, but they may affect the total amount of the essential amino acid required, depending on their level in the diet. There are nine additional amino acids that are nutritionally nonessential because they are manufactured from other compounds in the body.

The quality of a protein is determined by two primary factors. The first is the balance of amino acids within

that protein. To be optimally utilized, the protein should have an amino acid profile similar to that of the animal's body. If this occurs, each individual amino acid will be present in approximately the right proportion that the body needs with no major excesses or deficiencies of any one amino acid. This profile is achieved only in a few foods, most notably in eggs and in milk. It seems obvious that these two protein sources would fit the profile of the body, because they provide the only source of food during early periods of rapid growth.

Very few ingredients have an amino acid profile that approaches ideal; therefore, it is preferable to choose individual ingredients for the diet that complement each others' amino acid profile. With proper selection, the ingredients work together in a synergistic manner to enhance the overall performance of the mixed diet. By dividing the percentage of a specific amino acid in the protein of an ingredient by the percentage of that amino acid in an ideal protein, an evaluation of the degree of amino acid adequacy can be determined. Doing this to all the essential amino acids for an ingredient will determine the limiting amino acid, or that essential amino acid that is present in the lowest proportion of ideal. This amino acid will have to be supplemented by either adding an ingredient that is particularly high in this amino acid or by supplying the specific amino acid in a purified form. Similarly, this kind of evaluation can be performed on the entire diet to determine the adequacy of the amino acid profile. These values would be reflected in the amino acid requirement of the animal at its particular stage of life.

The second criteria that affects protein quality is the availability of the amino acids within the foodstuff. Certain ingredients have structural characteristics or contain chemical compounds that will decrease the bioavailability of an amino acid. A typical example of this would be the interaction between lysine and dietary simple sugars resulting in a chemical complex that makes lysine unavailable to the animal. Another example would be the trypsin and chymotrypsin inhibitors in unprocessed soybeans that prevent normal proteolytic activity of these digestive enzymes, thereby decreasing digestibility. The specific structure of an amino acid chain can also render a protein undigestible. This occurs due to secondary and tertiary structural characteristics preventing the enzymatic hydrolysis of the amino acid chain in the body. An example of this is the extremely poor digestibility of keratin and the other fibrous proteins.

After a protein source is consumed, it is initially processed by the combination of pepsin and hydrochloric acid secreted by the glandular stomach (proventriculus). The resultant polypeptide chains are then further degraded by a series of enzymes from the pancreas (trypsin, chymotrypsin, carboxypeptidases), aminopeptidases and finally dipeptidases. The individual amino acids that result from this series of enzymatic hydrolyses are then absorbed in the small intestine, predominantly in the jejunum, although all sections of the small intestine are involved in absorption.

## ■ Vitamins

The vitamins are chemically unique but share similar metabolic roles and modes of action and are therefore grouped together.

Generally, vitamins are defined as natural food components that are present in minute quantities, are organic in nature and are essential for normal metabolism and health. They will cause specific, characteristic deficiency symptoms when they are severely limited in the diet. Metabolism will generally be affected to a degree proportional to the level of the deficiency; therefore, in the case of mild deficiency, the symptoms are usually vague and nonspecific, such as poor performance or compromised health. Vitamins are generally not synthesized by the body in amounts sufficient to meet the physiologic requirement.

Vitamins are now subcategorized into two general groups based on their solubility characteristics. The fat-soluble vitamins are comprised of vitamins A, D, E and K. The water-soluble vitamins include thiamine (vitamin B<sub>1</sub>), riboflavin (vitamin B<sub>2</sub>), niacin, pyridoxine (vitamin B<sub>6</sub>), pantothenic acid, biotin (vitamin H), folic acid (vitamin M), vitamin B<sub>12</sub> (cyanocobalamin), choline and ascorbic acid (vitamin C). Other vitamin compounds that are generally not considered to be required by higher animals include lipoic acid (occurs widely in natural foodstuffs), inositol (synthesized by higher animals and widely distributed in most foodstuffs), and para-aminobenzoic acid (required by microorganism for the synthesis of folic acid).

### Vitamin A

Vitamin A occurs in several forms: retinol (alcohol), retinal (aldehyde) and retinoic acid, all having different metabolic activity. Plants do not contain active vitamin A, but instead contain vitamin precursors.

These exist in the form of carotenoid plant pigments, with the carotenes being the most important of the pro-vitamin A compounds. In the avian species studied, beta carotene is the most active of the carotenoid compounds, yielding the equivalent of 1667 international units (IU) of vitamin A activity per milligram. The sum of the vitamin A content (expressed in retinol equivalents or IU) and the contribution from carotene represents the total vitamin A activity of the food.

The most well understood function of vitamin A is its role in vision, but the most impactful action of vitamin A in avian medicine is its effect on the growth and differentiation of epithelial tissues, with deficiencies resulting in keratinization of the tissue. It is in this function that vitamin A is obligatory for normal disease resistance because it is required for the maintenance of adequate mucous membranes and for the normal functioning of secretory tissues (eg, the adrenal glands for the production of corticosteroids).

Vitamin A is also required for normal mucopolysaccharide formation and apparently affects the stability of cell membranes and of the subcellular membranes (such as the mitochondria and lysosomes). A major metabolic function of vitamin A may be the maintenance of the structural integrity and the normal permeability of the cell membrane. Vitamin A also functions in the proper growth of bones and in the maintenance of normal reproduction.<sup>34</sup>

It is generally accepted that vitamin A improves the immune function of the body; however, its mode of action has not been totally elucidated. Vitamin A apparently acts by the increased production and differentiation of immune related cells, while the carotenoids possibly improve the activity of lymphocytes. Obviously, this function is also significantly influenced by the importance of vitamin A in maintaining healthy mucosal membranes.

The liver will typically contain over 90% of the total body stores of vitamin A with the preferential storage form being retinyl palmitate. Additional supplies are also contained in the kidneys, lungs, adrenals and blood. As vitamin A is required by the body, it is mobilized from the liver by the hydrolysis of the retinyl esters to free retinol by the enzyme retinyl ester hydrolase.

Vitamin A is usually considered safe up to approximately ten times the requirement in monogastrics (including poultry). Experimentally, vitamin A toxicities have been achieved by feeding over 100 times the

daily requirement for extended periods of time. Probably an excess of 1000 times requirement would be necessary to induce an acute intoxication. Carotenoids in the diet do not contribute to potential vitamin A toxicity, because they are not converted to retinol unless there is a metabolic need for vitamin A. At excessive levels, they may result in a temporary yellow pigmentation of the skin and fat.

### Vitamin D

There are two predominant forms of vitamin D: ergocalciferol (vitamin D<sub>2</sub>), a plant derivative, and cholecalciferol (vitamin D<sub>3</sub>), produced exclusively in the bird's body. In all of the birds studied, vitamin D<sub>3</sub> is considered to be 30 to 40 times more potent than vitamin D<sub>2</sub> as a source of vitamin D activity. Therefore, plant sources of vitamin D are essentially disregarded when providing vitamin D to birds. Vitamin D<sub>3</sub> levels are quantified in International Chick Units (ICU) as a way to differentiate it from vitamin D<sub>2</sub> or total vitamin D. Unlike most other vitamins, the active form of vitamin D<sub>3</sub> can be synthesized in the body by the conversion of 7-dehydrocholesterol in the skin and sebaceous secretions by irradiating with ultraviolet rays. Early studies in poultry showed that sufficient Vitamin D<sub>3</sub> could be formed to prevent rickets in growing chickens and maximize growth with 11 to 45 minutes of sunshine (not filtered by glass) each day.<sup>22</sup>

The cholecalciferol formed in the skin is then transported by the blood to the liver, where it is hydroxylated by a liver microsomal enzyme (to a lesser extent, the reaction may also occur in avian kidneys). This new compound is then transported to the kidney, where it is again hydroxylated to the metabolically active form. When the renal levels of calcium and phosphorus are normal and parathyroid hormone (PTH) is being secreted, an inactive form is produced. Unlike other vitamins, the active metabolite actually acts as a hormone in the body being transported to the intestines, bones and other target organs where it exerts its role in the metabolism of calcium and phosphorus (see Chapter 23).

The most important physiologic role of vitamin D is the homeostasis of calcium and phosphorus levels in the body. There is also evidence that the active form has additional roles, eg, induction of cell differentiation and immune system regulation.<sup>12,36</sup>

The active metabolite also acts in the body in a manner similar to a steroid hormone, acting on a specific receptor protein in the target organ. The

vitamin D receptor is located in the nucleus of the intestinal mucosal epithelial cells.

### Hypervitaminosis D<sub>3</sub>

In a prolonged feeding study with cockatiels on a diet containing 1.0% Ca, 0.5% P and 4000 ICU vitamin D<sub>3</sub> (18% crude protein and 3150 kcal/kg), high egg production for approximately one year was followed by a rapid decline in reproductive performance, concurrent with the onset of polyuria in all birds. Most had signs of anorexia and lethargy, with some exhibiting signs of diarrhea or lameness. Radiographs indicated the presence of nephrocalcinosis. These signs were exacerbated with the onset of subsequent reproduction. Several females were lost, with necropsies showing extensive soft tissue mineralization, especially of the kidneys. The onset of reproduction and subsequent increasing hormonal activity (presence of prolactin) and related increases in calcium uptake in females were found to enhance the problem. Males were affected to a much lesser extent, with all clinical signs disappearing after the birds were removed from the experimental diet.<sup>2</sup>

### Vitamin E

Vitamin E is a compound of plant origin with eight active forms derived from four tocopherols and four tocotrienols. The compound of the greatest biologic importance in the avian species is alpha-tocopherol. Vitamin E is essentially a biologic antioxidant that functions at the intercellular and intracellular level by preventing the oxidation of saturated lipid compounds in the cell, thereby maintaining membrane integrity.

Free radicals, the highly reactive breakdown products from reactions such as the oxidation of polyunsaturated fatty acids to fatty hydroperoxides, can be extremely damaging to the cell. Free radicals occur in the body through normal oxidative metabolism, cytochrome activity and from stimulated phagocytes. These free radicals can then attack the polyunsaturated fatty acids of membranes, creating additional radicals, producing a chain reaction that can continue until all of the polyunsaturated fatty acids in the membrane are oxidized. Vitamin E acts to scavenge these radicals, thereby preventing the initiation as well as interrupting propagation of peroxidation.

Working in conjunction with vitamin E are several metalloenzymes, which block the initiation of peroxidation in the aqueous phase of the cell. These enzymes incorporate manganese, zinc, copper, iron and selenium as active components. Glutathione peroxi-

dase (GSHp) is probably the most important of these metalloenzymes because of its integral relationship with vitamin E. This selenium-containing enzyme is very active in the destruction of peroxides before they cause membrane damage. Because of their similar activity, selenium and vitamin E tend to have a sparing effect on each other. Exudative diathesis, the condition observed in poultry, generally appears only when both selenium and vitamin E are limited in the diet. Additionally, sulfur-containing amino acids can exhibit a similar sparing effect on vitamin E because they are precursors of GSHp.

Vitamin E has been suggested to be active in several other metabolic systems: 1) cellular respiration; 2) normal phosphorylation reactions (eg, ATP metabolism); 3) cofactor in the synthesis of ascorbic acid; and 4) sulfur amino acid metabolism.<sup>43</sup> There is also considerable evidence in poultry that levels higher than those required for optimum growth can increase immunity, as evidenced by decreased mortality after challenge of treated birds by *E. coli*.<sup>27</sup> This protective effect occurs by increasing phagocytosis and antibody production as well as stimulating the activity of macrophages and lymphocytes.

Vitamin E is absorbed through passive diffusion and is dependent upon normal lipid digestion requiring proper micelle formation and the presence of bile salts and pancreatic juices. Any malabsorption syndrome will decrease uptake. Vitamin E is absorbed predominantly as a free alcohol in the small intestine. Vitamin E enters the portal circulation in association with chylomicra, but is readily transferred to plasma lipoproteins for transportation to the liver. Initial storage occurs in the liver, being released primarily in the high density lipoproteins, and to a lesser degree, the low density lipoproteins and very low density lipoproteins. Liver and plasma stores of vitamin E are the most readily accessible to the body in times of need. Vitamin E stores of the body tend to be relatively stable and may not be effective in preventing a vitamin E deficiency from occurring. It appears that lipolysis of fatty stores may be required for vitamin E to be released.

Vitamin E is abundant in plant materials (particularly those high in oil) and in plant leaves. In cereal grains, vitamin E is concentrated in the germ. Alfalfa leaves are a particularly high source of vitamin E.

### Vitamin K

Vitamin K actually represents a large number of related compounds that possess widely varying de-



grees of anti-hemorrhagic characteristics, all being forms of the compound naphthoquinone. Vitamin K comes from three sources: 1) green plants (phyloquinones -  $K_1$  series), 2) bacteria (menaquinones -  $K_2$  series) and 3) synthetic forms (menadione -  $K_3$ ). The microbial synthesis of vitamin  $K_2$  is significant in most species. It is generally difficult to produce a vitamin K deficiency without the use of germ-free animals, the use of antibiotics to kill intestinal flora or the prevention of coprophagy (the ingestion of excreta).

Natural vitamin K compounds require the presence of dietary fats and bile salts for proper absorption from the gastrointestinal tract; therefore, altered micelle formation (eg, decreased pancreatic and biliary function) will impair the normal absorption of vitamin K. Menadione salts are fairly water-soluble so they are less reliant on micelle incorporation. Absorption of the  $K_2$  and  $K_3$  forms occurs by passive diffusion throughout the intestines and also in the colon, while  $K_1$  is absorbed via an active transport process in the proximal small intestine. Vitamin K then enters the portal circulation and, in association with a chylomicron, is transported to the liver. Generally, vitamin K is stored only briefly in the liver before it is released into the body and transported to all tissues via lipoproteins. It is believed that menadione is well absorbed but poorly retained, while phyloquinone is rather poorly absorbed but retained much longer in the body. Vitamin K absorption has been observed to range from 10 to 70%, depending on the form of vitamin.

A number of plasma clotting factors (eg, prothrombin) are dependent on vitamin K for their synthesis. This occurs by activating inactive protein precursors that occur through the action of an enzyme; this is found predominantly in the liver, but also in lung, spleen, kidney, bone and skin. The bone also contains a vitamin K-dependent protein (osteocalcin), which acts in the regulation of calcium phosphate incorporation into bone.

### Thiamine (Vitamin B<sub>1</sub>)

Thiamine is fairly common in food sources, but generally at only low concentrations. In plants, thiamine exists as the free vitamin, while in animal tissue it is present in its phosphorylated form, thiamine pyrophosphate. Several compounds in nature possess anti-thiamine activity, many of which exhibit competitive inhibition with thiamine based on their structural similarities. An example of this is amprolium, which inhibits thiamine absorption from

the intestine and prevents thiamine phosphorylation.<sup>26</sup> Another well known compound is thiaminase, a thiamine-splitting enzyme contained in some raw fish and produced by certain types of bacteria. Other thiamine antagonists include caffeic acids, chlorogenic acid and tannic acid, (often found in deeply pigmented fruits and vegetables such as blueberries or beets as well as coffee and tea). These compounds react with thiamine to prevent its absorption. Sulfites, a frequently used food preservative, can also destroy thiamine under certain conditions.

Thiamine is readily available from natural sources when normal amounts of gastric hydrochloric acid are present. Thiamine is absorbed both by an active transport system and at high luminal concentrations, by passive diffusion. After absorption, thiamine is transported via the portal vein to the liver, predominantly bound to serum albumin. Thiamine is not stored for any length of time in the body. It is excreted primarily through the urine and in lesser amounts through the feces. About 80% of thiamine in the body is present as thiamine pyrophosphate. The remaining fraction exists as the triphosphate, monophosphate and free forms.

### Riboflavin (Vitamin B<sub>2</sub>)

In foods, riboflavin is generally bound to proteins in the form of flavin mononucleotide (FMN) or flavin adenine dinucleotide (FAD). Riboflavin contained in plant materials is generally less available than from animal sources because of decreased digestibility of the flavin complexes in plants.

In the gastrointestinal tract, the phosphorylated forms of riboflavin are hydrolyzed. The free riboflavin enters the mucosal cells via an active transport system in the proximal small intestine. In the intestinal mucosa, riboflavin is rapidly phosphorylated, producing FMN. Both free riboflavin and FMN then enter the portal circulation, predominantly bound to plasma albumin (and to a lesser degree to globulins and fibrinogen). These compounds are then transported to the liver and other tissues, where riboflavin enters the cell in the free form.

Very little riboflavin is stored in the body; the highest concentrations are found in the liver, kidney and heart. Unlike other tissues, the egg contains predominantly free riboflavin. Laying chickens have been found to have specific riboflavin-binding proteins in the plasma. These are produced in the liver under the influence of estrogen and are believed to be involved in the transovarian passage of free riboflavin.

Riboflavin as part of the coenzymes FMN or FAD (flavoproteins) act in a large number of enzyme complexes that are responsible for essential reactions in the utilization of carbohydrates, fats and proteins. The flavoprotein enzyme complexes often contain a metal ion (eg, iron, molybdenum, copper) and function to help regulate cellular metabolism, the metabolism of carbohydrates, the breakdown of amino acids, the formation of uric acid, the formation of ascorbic acid, fatty acid biosynthesis and degradation, oxidation of various substrates in drug metabolism and other functions.

Riboflavin toxicity is very unlikely due to the fact that it is rapidly excreted, and when fed at high levels, the transport system across the gastrointestinal mucosa becomes saturated, thereby limiting the amount absorbed.

### Niacin

Niacin exists in two major forms, nicotinic acid and nicotinamide. Niacin is widely distributed in foods, but that found in plants has low bioavailability. It is also not uniformly distributed within the feedstuff so milling often removes the fraction with the highest content. Therefore, in diet formulation, the natural content of niacin in plant materials is generally ignored. Bioavailability in animal products tends to be very high. Niacin can also be synthesized from the essential amino acid tryptophan; however, the amino acid's preferential use is for protein synthesis, so only tryptophan in excess of the animal's needs will be available for bioconversion to niacin.

Plants generally contain protein-bound nicotinic acid while animal sources are present as NAD and NADP. These forms are digested by the body, releasing nicotinamide that is then absorbed by diffusion. The greatest concentrations of niacin compounds are in the liver, but no true storage occurs.

The coenzymes NAD and NADP are important components in carbohydrate, fat and protein metabolism, being especially important in the energy-yielding reactions of the body. These functions are critical to the generation of energy for the body as well as for normal tissue integrity, especially of the skin, alimentary tract and the nervous system.

### Pyridoxine (Vitamin B<sub>6</sub>)

Vitamin B<sub>6</sub> refers to the group of three compounds: pyridoxal, pyridoxamine and pyridoxal phosphate. Pyridoxal is the form predominantly found in plants, the other two are found mainly in animal tissues.

Large amounts of vitamin B<sub>6</sub> in foods are bound to proteins or complexes, some of which have very low bioavailability. After digestion to free the vitamin from these protein complexes, vitamin B<sub>6</sub> is absorbed by passive diffusion throughout the entire small intestine and is transported to the liver. The various forms are then converted and phosphorylated to the predominate tissue form, pyridoxal phosphate, which requires both niacin (as NADP) and riboflavin (as FMN) for the enzyme systems. Pyridoxal phosphate and lesser amounts of pyridoxal are found in the circulation associated with plasma albumin and erythrocyte hemoglobin. Minimal amounts of the vitamin are stored in the body, primarily as pyridoxal phosphate and secondarily as pyridoxamine phosphate. Storage occurs predominately in the liver, brain, kidney, spleen and muscle.

The metabolically active form of vitamin B<sub>6</sub>, pyridoxal phosphate, is involved in a number of enzyme systems as a coenzyme. It is required in essentially all major areas of amino acid utilization, the synthesis of niacin from tryptophan and in the formation of antibodies. It is required in the decarboxylation of glutamic acid to form gamma-aminobutyric acid (GABA), the lack of which has been shown to cause seizures. A deficiency of pyridoxine creates a deficiency of many other important metabolites and hormones such as serotonin and histamine. Evidence also suggests that it may play a role as a modulator of steroid hormone receptors.

### Pantothenic Acid

Pantothenic acid is a structural component of coenzyme A (CoA). Pantothenic acid is present in feeds in both the bound form (predominantly CoA) and free forms. During the digestive process, the free form is liberated prior to absorption. Pantothenic acid is then absorbed via a saturable transport system and at high levels, simple diffusion also occurs. The free form is then carried via the plasma to the rest of the body. Tissues convert pantothenic acid to coenzyme A (predominantly), with the greatest concentrations found in the liver, adrenals, kidneys and brain. The majority of the pantothenic acid in the blood is found as CoA in the erythrocytes. CoA is one of the most critical coenzymes in tissue metabolism, forming the compound acetyl CoA. Acetyl CoA acts as the entry point into the citric acid cycle for carbohydrate metabolism, a point of entry for amino acid degradation and as an essential component in fatty acid biosynthesis and degradation, the synthesis of triglycerides and phospholipids, as well as in the formation of

compounds such as acetylcholine, mucopolysaccharides, cholesterol, steroid hormones and many more.

### Biotin

Biotin is widely distributed in foods but generally at low concentrations. A relatively large portion of naturally occurring biotin is present in a protein-bound form with varying degrees of biological availability. There is evidence that suggests that the synthesis of biotin by intestinal microflora is important in an animal. Microbial-derived biotin would be manufactured and absorbed in the large intestine.

Intestinal proteases help free the bound biotin prior to absorption. Free biotin is then absorbed, apparently both by facilitated and simple transport systems. It is carried to the tissue through the plasma, possibly in conjunction with a biotin-binding protein (identified in both yolk and plasma of laying chickens). The largest concentrations of biotin in the body are found in the liver; however, this storage site seems to be poorly mobilized during times of biotin deprivation.

Biotin is an active part of four different carboxylase enzymes in the body, and is responsible for the fixation of carbon dioxide (carboxylation). These enzymes have important functions in the metabolism of energy, glucose, lipids and some of the amino acids.

### Folic Acid (Folacin)

Folic acid is the compound pteroylmonoglutamic acid. Additionally, there is a large group of modified folic acid compounds, referred to collectively as folates. At one time, PABA was believed to be essential in the diets of vertebrates, but it has since been determined that if the requirement for folic acid is met, PABA provides no additional benefit.

Folates are generally widely distributed in foods and are present as the polyglutamic derivatives of folic acid. These are converted by hydrolysis to free folic acid and absorbed by both an active transport system and passive diffusion in the duodenum and jejunum. The absorption process is only moderately efficient (<50%).

Folic acid's primary metabolic role is in the transfer of single-carbon moieties in a wide variety of reactions. This function is particularly important in amino acid metabolism, in the bioconversion of amino acids and in the biosynthesis of nucleotides.

Because of folic acid's requirement in the synthesis of three of the four nucleic acids, a deficiency results in

impaired cellular division and an alteration of protein synthesis. This is particularly noticeable in the young growing animal. Additionally, due to impaired cell mitosis in a deficient bird, females do not physiologically prepare for breeding, as noted by a lack of oviduct hypertrophy in the presence of estrogen. Further, there is an effect on normal red blood cell maturation, resulting in the characteristic macrocytic anemia. Similarly, deficiencies result in immune system impairment due to the effects on cell replication and protein synthesis. Folic acid is involved in the formation of uric acid, so there is an increased requirement when high-protein diets are provided. Folic acid is required for the production of white blood cells and a severe deficiency can reduce immunologic response through decreased WBCs or reticuloendothelial cells.

In some species, a deficiency of zinc has been found to impair the utilization of dietary sources of folic acid. A zinc deficiency decreases the absorption of folic acid because of impaired activity of the mucosal enzyme that creates an absorbable form of folic acid. Enzyme inhibitors are present in a number of foods such as cabbage, oranges, beans and peas (in the seed coat) and brewer's yeast. These inhibitors are generally destroyed by processing since they are heat-labile. Sulfa drugs (eg, sulfanilamide) may increase the requirement of folic acid since they will compete with structurally similar PABA in the bacterial synthesis of folic acid.

Vitamin C and iron may improve the bioavailability of folates in food.

### Vitamin B<sub>12</sub>

Vitamin B<sub>12</sub> or cyanocobalamin is a product of bacterial biosynthesis and therefore must be obtained by consuming a bacterial source or animal tissues that accumulate the vitamin. The only exceptions are a few plants, such as peas, beans, spirulina and kelp, that may be able to synthesize minute amounts of this vitamin, although this accumulation is likely due to their close symbiotic association with bacteria.

Naturally occurring vitamin B<sub>12</sub> occurs in the coenzyme form bound to protein. This complex is broken, primarily through the normal action of pepsin and trypsin. Free vitamin B<sub>12</sub> is absorbed by the intestinal tract via an efficient active transport system involving a vitamin B<sub>12</sub> specific-binding protein. At very high levels, simple diffusion occurs throughout the small intestine.

Most of the vitamin B<sub>12</sub> in the body is found in the liver with secondary stores in the muscle. Lesser

amounts (but high concentrations) are contained in the pituitary gland, kidney, heart, spleen and brain. Vitamin B<sub>12</sub> is stored efficiently, with a long biological half-life (approximately one year in humans).

Vitamin B<sub>12</sub> is a critical component of a large number of metabolic pathways. It interacts with several other nutrients such as folic acid, pantothenic acid, choline and methionine. Similar to folic acid, most of the metabolic reactions of vitamin B<sub>12</sub> involve single carbon units and are very important in the synthesis of nucleic acids and protein as well as carbohydrates and fats.

Like folic acid deficiencies, vitamin B<sub>12</sub> deficiencies result in an impairment of protein synthesis causing failure or delay of normal cell division. This affects growth rate and feed intake, may result in nervous disorders and poor feathering, perosis, anemia, ventricular erosion and fat accumulation in the heart, liver and kidneys. Deficiency of vitamin B<sub>12</sub> can also create a folic acid deficiency.

Some research indicates that vitamin B<sub>12</sub> absorption is decreased in the presence of protein, iron or vitamin B<sub>6</sub> deficiencies or by dietary tannic acids.<sup>23</sup>

### Choline

Natural sources of choline are widely distributed and occur primarily in the form of phosphatidylcholine (lecithin). It is also present as free choline, acetylcholine and in other phospholipids, such as sphingomyelin.

Phosphatidylcholine is readily hydrolyzed in the intestinal lumen and is absorbed by the mucosa via both active transport and passive diffusion, depending on luminal concentrations. Of the free choline that is ingested, up to two-thirds may be metabolized by intestinal microorganisms. The remainder is absorbed intact. Choline is found in all tissues as a part of the membrane phospholipids, with the greatest concentrations in organs such as the brain, liver and kidney (as phosphatidylcholine and sphingomyelins).

Choline can be synthesized in the body but in the avian species tested to date, it cannot be synthesized at high enough levels to meet the needs of the young bird. It appears that with age, the synthetic abilities improve, thereby meeting most of the body's needs. This is especially true when choline-sparing compounds such as methionine, betaine and myo-inositol are present in the diet. Dietary sulfates can also have a sparing effect on choline by helping to spare methionine.

Choline has four general metabolic functions: 1) As a component of phospholipids, choline is an essential part of the cell membrane and is required for maintaining cell integrity; 2) Choline is required for maturation of the cartilage matrix of bone; 3) Choline is involved in fat metabolism of the liver by promoting fatty acid transport and utilization, and is therefore necessary to prevent hepatic lipidosis in the normal bird; 4) Choline is acetylated to form the neurotransmitter acetylcholine.

Because of their interrelated functions, the requirement for choline is dependent upon the levels of folic acid and vitamin B<sub>12</sub> available to the animal. Excess protein increases the choline requirement, as do diets high in fat. Dietary levels of choline chloride (the normal supplemental form) should not exceed twice the requirement.

### Vitamin C (Ascorbic Acid)

Vitamin C has not been demonstrated to be a required nutrient for any of the avian species, except for a few highly evolved, largely frugivorous species (Willow Ptarmigan and Red-vented Bulbul).<sup>10</sup> Vitamin C is easily manufactured in birds with the enzyme L-gulonolactone oxidase. This enzyme works on a substrate generated from glucose producing an intermediate that is then converted to L-ascorbic acid. This process occurs in the liver in most passerine species, and in the kidneys of psittacines and other older phylogenetic orders of birds. Biosynthesis of ascorbic acid can be inhibited by deficiencies of vitamin A, E and biotin.

Vitamin C occurs in the forms of ascorbic acid and dehydroascorbic acid, with both forms having similar biological activity. Vitamin C is found in the highest concentration in fruits, vegetables (but not seeds) and organ meats (particularly the liver and kidney).

Dietary sources of vitamin C are absorbed by passive diffusion in those species that do not have a specific dietary requirement. Absorption appears to be relatively high when fed at normal levels. Decreased absorption occurs as the physiologic dose is exceeded. The highest concentrations of vitamin C are found in the pituitary and the adrenal glands followed by the liver, spleen, brain and pancreas. Vitamin C also tends to accumulate around healing wound sites. The metabolic functions of vitamin C are related to its ability to act in oxidation and reduction reactions. Its best understood role is in the synthesis of collagen, where it is involved in the hydroxylation of procollagen residues. Collagen, the major component of skin

and connective tissue and also the single most abundant protein in the body, is critical for proper cell structure and integrity. In species requiring vitamin C in their diet, the breakdown of this function produces the classic deficiency symptoms (scurvy, capillary fragility, gum and bone alterations and poor healing).

Vitamin C is also an excellent antioxidant, acting to neutralize free radicals that are produced in the body. Ascorbic acid can also regenerate vitamin E (the active lipid antioxidant).

Based on their scientific orders, evolutionary status and limited testing, psittacine and passerine birds appear to have no requirement for vitamin C. In other species with no specific requirement (eg, domestic poultry), there have been documented benefits of providing a dietary source of vitamin C to birds at certain stages of life or under certain conditions. Stressful conditions that have been shown to improve with supplemental vitamin C are: 1) dietary deficiencies of energy, protein, vitamin E, selenium or iron; 2) high production or high growth rates (the newly hatched chick has a slower rate of ascorbic acid synthesis); 3) management stresses, eg, handling, insecure environment, transportation, crowding; 4) extreme temperature variations from normal; 5) health stresses: fever and infection reduce blood ascorbic acid and diseases with liver involvement decrease synthesis while increasing overall requirement for ascorbic acid.<sup>25</sup> Supplemental ascorbic acid has been shown to increase total sperm production in turkeys<sup>14</sup> and improve broiler fertility and hatchability, due to decreased early embryonic mortality.<sup>31</sup>

Considering the normal stresses that companion and aviary birds experience, it seems reasonable that a supplemental source of vitamin C may be of some benefit during certain situations. This may be even more important considering that many birds lack proper diet and health care. Fresh food sources should be considered as the most important way to supplement the diet because of the vitamin's general instability in manufactured products.

## Minerals

Minerals are essentially classified in one of two groups: macro minerals and trace or micro minerals. The macro minerals can be classified based on their use in the body. Calcium and phosphorus act primarily in the body's skeletal structure, while sodium, potassium and chlorine (along with phosphates and

bicarbonates) function to maintain homeostasis in the body (acid/base balance and proper osmotic pressures). The required trace minerals are magnesium, manganese, zinc, iron, copper, iodine, selenium and, in certain situations, cobalt and molybdenum. These trace elements have their primary function as parts of enzymes, hormones or as enzyme activators. Additionally, in purified diets, there have been beneficial effects achieved by the addition of some of the other trace elements such as fluoride, nickel, silicone, tin, vanadium and chromium. These benefits have usually been seen only in sterile conditions with extreme environmental controls. At this time, they should not be considered as dietary essentials because of a lack of conclusive evidence regarding their essentiality and the poor understanding of their metabolic function.

As the normal digestion process breaks food into its components, the minerals are liberated, and the cationic elements are converted to chloride salts in the presence of gastric hydrochloric acid. Once in the intestinal tract, they are able to easily dissociate and be absorbed. There is also considerable complexing with other minerals or chelating agents. An example of this is the calcium and phosphorus precipitate that is formed by excess levels of these minerals while in the alkaline conditions of the small intestine. This complex can then adsorb manganese or zinc, causing excretion of the trace mineral, and subsequently, an increased requirement.

Mineral (particularly trace mineral) concentrations of foodstuffs are largely dependent on the original mineral source. Concentrations in plant products are dictated by the soil mineral content, while those of animal products are dependent on the diet consumed.

### Calcium

Calcium is the predominant mineral in the body (approximately 1.5% of body weight) with primarily skeletal system containment. Calcium is also contained in the body fluids, where it plays an essential role in blood coagulation and membrane permeability, and maintains normal excitability of the heart, muscles and nerves. Several enzyme systems are also activated by calcium. Ionic calcium ( $\text{Ca}^{++}$ ) is the physiologically active form. Low  $\text{Ca}^{++}$  concentrations result in a decrease in electrical resistance and an increase in membrane permeability (to sodium and potassium) of nerve tissue, which causes hyperexcitability of neural and muscle tissue and can result in spontaneous fiber discharge.

Calcium absorption occurs predominantly in the upper small intestine by an active transport system involving a calcium-binding protein. This is regulated by the active metabolite of vitamin D<sub>3</sub> in response to low plasma calcium levels. A lesser amount of absorption also occurs in the lower small intestines through passive diffusion. High-protein diets and acidification of the intestines aid calcium absorption. Compounds such as phytate (in cereal grains), oxalates (in spinach, rhubarb and related vegetation) and phosphates will decrease absorption of calcium due to the formation of complexes. Similarly, high intestinal concentrations of free fatty acids (from very high-fat diets or because of impairment in fat digestion) will result in the formation of insoluble calcium soaps. Once absorbed, calcium is carried by the plasma as ionized calcium, protein-bound calcium and a small amount of chelated calcium (chelated with citrate and phosphate). Regulation of calcium metabolism involves parathyroid hormone, calcitonin and vitamin D<sub>3</sub> (see Chapter 23).

The calcium content of dried, fat-free bone is approximately one-third of the total weight, predominantly present in the form of calcium phosphate, with lesser amounts of calcium carbonate. In egg shells, calcium carbonate is the structural compound. For maintenance of proper bone tissue, the calcium to available phosphorus ratio should be approximately 2 to 1. A range of 0.5:1 to 2.5:1 can be tolerated. The further this ratio deviates from the ideal level, the more critical proper vitamin D<sub>3</sub> levels become. Vitamin D<sub>3</sub> is essential to regulate absorption and metabolism of calcium and phosphorus, especially when dietary levels are unbalanced. During growth of most species, ratios of approximately 1:1 are required to support adequate growth, 1.5:1 to maintain normal serum calcium and phosphate and alkaline phosphatase values, and 2:1 to achieve maximum bone density. High egg-producing hens (poultry) may be provided with dietary ratios in excess of 10:1 in order to support daily shell production. This must not be confused with the significantly lower needs of a hen (most companion birds) that produces a periodic clutch of eggs. This ratio is based on the amount of phosphorus available to the bird, not the total phosphorus content of the diet. As much as 70% of the phosphorus in certain ingredients can be present in a form that is unavailable to the bird. Therefore, an estimation of the diet's available phosphorus is essential in order to balance these two minerals.

Levels of over 1.0% calcium in the diet have been observed to decrease the utilization of proteins, fats,

vitamins, phosphorous, magnesium, iron, iodine, zinc and manganese. Where there are marginal intakes of one or more of these nutrients, increased calcium intake can induce a deficiency state.

### Phosphorus

In addition to being an important bone constituent, phosphorus is also a component of proteins, carbohydrates and lipid complexes that perform vital functions in the body. Phosphorus has a wider range of biological functions than probably any other element.

Phosphorus is widely distributed in nature, occurring as phosphates, orthophosphoric acid salts and organophosphates. Absorption of phosphorus in the orthophosphate form takes place primarily in the duodenum, with efficiency of adsorption being dependent on the metabolic requirement and affected by a number of factors such as its source, calcium:phosphorus ratio, intestinal pH and dietary levels of vitamin D, potassium, magnesium, manganese, iron and fat. Once absorbed, it is readily incorporated into bone and other tissues, with bone acting as the metabolic reservoir. Like calcium, circulating levels are regulated by parathyroid hormone and calcitonin, with plasma levels being inversely related to plasma calcium levels. Excretion of excess amounts of phosphorus takes place primarily through the kidneys.

In plant sources, phosphorus is often complexed with phytin, making it unavailable to all monogastric animals because of their lack of the enzyme phytase. When the diet consists predominantly of high-phytin foods, phytase-producing microorganisms may colonize the gastrointestinal tract and provide a modest improvement in the phosphorus availability. This is low, however, because the amount of phytate hydrolysis is limited by the rapid transit time through the avian gut, with poor absorption of the liberated phosphorus due to hydrolysis occurring primarily in the distal portion of the tract. As a general rule, phosphorus from animal products or inorganic supplements is almost completely available, while that from plant sources is generally considered to be approximately 30% available. These typical values can be used to generate an estimation of the available phosphorus in the diet.

When kept within the range of acceptable calcium:phosphorus ratios, moderately higher phosphorus does not create a significant problem. Amounts of phosphorus outside these acceptable ratios, however, will cause decreased performance and will interfere with the absorption of calcium from the gastrointes-

tinal tract. Additionally, high serum phosphorus levels can induce nutritional secondary hyperparathyroidism by suppressing serum calcium, resulting in stimulation of the parathyroid. In some species, increased excretion results in the development of urolithiasis. It is estimated that the level of available phosphorus, when balanced with calcium and vitamin D, can be supplied at approximately two times the requirement without adverse effects. Amounts greater than this level have resulted in increased mortality in a number of species.

### Magnesium

Most of the body's magnesium is present in the bone, complexed with calcium and phosphorus. In the body fluids, the majority of magnesium is found in the blood cells, whereas calcium is predominantly associated with the plasma. Magnesium (like potassium) is found at the highest concentrations in soft tissue cells (intercellularly) such as liver, striated muscle, kidney and brain. In these tissues, magnesium serves as an activator for many of the enzymes involved in phosphate transfer and metabolism.

Magnesium is absorbed in a manner similar to calcium and phosphorus, with the efficiency of absorption dependent on the concentration in the gastrointestinal tract. With low levels, absorption tends to be very efficient, with decreasing efficiency as levels become higher. Most of this mineral appears to be absorbed in the small intestine. Levels of calcium and phosphorus in a diet affect the magnesium requirement, with high levels of either of the former tending to increase the requirement of the latter.

Magnesium generally functions in enzyme systems by catalyzing the reaction through the formation of a metal-enzyme complex, where the magnesium ion is loosely associated with the enzyme.

### Potassium

Potassium is widely distributed in most foods, making deficiencies unlikely in adult animals. Unlike sodium, potassium is located primarily intracellularly, and is found at the highest levels in muscle, erythrocytes, brain and liver. Potassium is the primary intracellular cation, affecting acid-base balance and osmotic pressure. It is also involved in protein biosynthesis, cellular uptake of amino acids and as a cofactor in a number of enzyme systems. In the extracellular fluids, potassium reduces muscle contractility and induces relaxation, therefore having the opposite effect of calcium.

Potassium is absorbed predominately in the upper small intestine by passive diffusion, although absorption occurs to a lesser extent throughout the entire intestinal tract. Excess potassium is excreted through the kidneys under the influence of sodium and aldosterone levels. Severe stress can create hypokalemia because of an increase in renal potassium excretion caused by elevated plasma proteins. This hypokalemia can be extended during the adaptation to the stress as potassium stores are replenished in the muscle and liver.

The minimum requirement of potassium is influenced by the dietary levels of sodium, total chlorides, the energy content of the food and possibly the protein content.

Potassium toxicity is not likely due to the capacity of the unimpaired kidney to excrete large concentrations of the mineral. Excesses of three times the required amount have presented no problems in avian species.

### Sodium

Sodium is the primary cation of the extracellular fluid, and is predominantly responsible for the regulation of the body's acid-base equilibrium by associating with either chloride or bicarbonate. Sodium is critical in the maintenance of the proper osmotic pressure in the body, protecting against excessive fluid losses. It is also involved in the transmission of nerve impulses, the permeability of cells and acts to inhibit mitochondrial enzyme systems that are otherwise activated by the intercellular ions, potassium (K<sup>+</sup>) or magnesium (Mg<sup>++</sup>).

Sodium salts are readily and efficiently absorbed by the body (primarily in the ileum), and can be efficiently conserved when the dietary supply is limited. Excess sodium, on the other hand, can be efficiently excreted through the kidneys by an increase in water consumption. Sodium retention is regulated by the adrenal hormone, aldosterone, which maintains proper plasma sodium levels and regulates sodium excretion.

Depending on the species, bone will contain between 25 and 50% of the total body sodium, which is bound to the inorganic matrix of the bone. The rest of the sodium is predominantly found in the extracellular fluid of the body, with highest concentrations in plasma, nervous tissue and muscle tissue. Nearly all the species investigated show a sodium plasma content of 3.3 to 3.4 g/l. Total body sodium content is similar in all animals, ranging from 0.11 to 0.13%.

The body has a specific mechanism for concentrating sodium in the extracellular fluid while concentrating potassium in the intracellular fluid. This high concentration gradient is maintained by the sodium-potassium/ATPase pump system. This system transports  $\text{Na}^+$  out of the cell, while transporting  $\text{K}^+$  in. This is an energy-requiring process that uses intracellular ATP as an energy source. Intracellular sodium activates the enzyme system, which uses  $\text{Mg}^{++}$  as a cofactor.

In the presence of chronic renal disease, especially when the animal is in acidosis, sodium levels are depleted because of poor tubular resorption and the use of sodium for the buffering of acids. Both renal disease and diarrhea may cause sodium depletion. This will often be followed by a rapid loss in weight due to dehydration.

Moderate increases in dietary sodium are relatively nontoxic providing adequate (low sodium) water is provided for renal excretion. Levels of five to ten times the requirement can be provided before there is a decrease in growth and loss of appetite in a young bird. At all stages of life, there will be a considerable increase in water intake resulting in looser droppings. Higher levels of sodium intake result in poor feathering, polydipsia, polyuria, nervousness, edema, dehydration and mortality.

### Chlorine

Chlorine, metabolically active as the chloride ion, is closely associated to sodium in foods, in the body and in metabolic processes, and both will be excreted under the same conditions. Chloride is also essential in maintaining the body's acid-base balance, osmotic pressure and water balance. It is a component of the hydrochloric acid that is produced by the body as a primary gastric secretion. In the body, chloride is concentrated in spinal fluid and blood.

It is critical to evaluate the overall dietary sodium, chlorine and potassium levels together. In the diet there must be a balance of the total sodium and potassium content with the total chloride and sulfate content in order to maintain the proper acid-base balance in the blood. This becomes particularly important with the addition of relatively high levels of dietary supplements that are complexed with one of these ions (such as high levels of choline chloride or lysine hydrochloride), especially when the chloride or sulfate form increases the acidity of the diet.

Toxicity of chloride alone is seldom a problem, but excess dietary chloride (in conjunction with unbal-

anced cations) can result in cartilage anomalies in chicks. Correction of the acid-base balance alleviates this symptom.

## Essential Trace Minerals

### Iron

The functions of iron in the body are almost entirely related to the cellular respiration processes. In the body, iron exists as heme iron (which is chelated with a porphyrin group) and non-heme iron (which is found bound to proteins). Iron is present in the body at approximately 50 to 100 parts per million.

Iron is unique in that body reserves are conserved and recycled very efficiently with negligible excretion. The primary method of iron depletion is through bleeding. Any iron found in the feces is generally a result of unabsorbed iron from the diet. Because the body has no normal pathway for the excretion of excess iron, intestinal absorption is carefully controlled to prevent accumulation. Under normal situations, the absorption of iron from the gastrointestinal tract is poor, however, if the body becomes marginally deficient, the absorption is improved until the situation is corrected.

Normally, heme iron (from animal sources) is considered to be approximately 20-25% available to the animal, while nonheme, vegetative sources are usually less than 5% available. Additionally, the non-heme iron present in most foods is in the ferric form ( $\text{Fe}^{+++}$ ), which is poorly absorbed. This can be present either as the free ferric ion or loosely associated with an organic compound. In order for proper absorption to take place, ferric iron must be reduced to the ferrous state ( $\text{Fe}^{++}$ ). In the ferrous form, iron becomes more soluble and therefore absorption is improved. This can be accomplished by any reducing compound in the food, with ascorbic acid being one of the more efficient agents. Proteins also enhance absorption, probably by forming soluble amino acids chelated with the iron. Additionally, absorption may be improved by dietary organic acids (eg, citrate, lactate), fructose and vitamin E, as well as by diets low in phosphorus. Normal gastric secretion is necessary to solubilize iron and increase its availability. Total iron absorption from a variety of mixed diets has been observed to range from 2 to 20% across a number of species. The deficient state can increase these efficiencies by over three-fold.

In the normal, healthy animal there should be no toxicity symptoms from moderate excesses of dietary



iron because of the efficient controls the body has over iron absorption and metabolism. Excess iron can reduce performance, however, by creating interactions with a number of nutrients. Examples of this would be reducing phosphorous absorption through the formation of an insoluble iron phosphate compound or the adsorption of vitamins or other trace minerals, preventing absorption into the body. Chronically high iron intake can result in elevated blood levels, increased tissue concentrations (especially of the liver and spleen) and the eventual development of hemosiderosis and possibly hemochromatosis (skin pigment changes). Liver damage and sometimes pancreatic fibrosis occur in this condition, which in other species is most often due to a genetic anomaly (extremely efficient absorption). Iron storage diseases have been predominantly seen in mynahs and toucans, possibly being caused by a combination of genetic and dietary factors.<sup>16,49</sup>

### Copper

The copper content in the bodies of most species is approximately two parts per million. The largest concentrations are in the liver. Copper is a component of several proteins, enzymes and certain natural pigments. It is required for hemoglobin synthesis, proper collagen (bone), elastin and keratin formation and maintenance of the nervous system.

Copper is well distributed in normal feedstuffs, so the likelihood of a copper deficiency on a mixed, practical diet is not great. Availability can be affected by the chemical form as well as the copper status of the animal, with more efficient absorption occurring when the animal is deficient or when the dietary concentration is low.

### Zinc

Zinc is critical to the animal for growth, reproduction and normal longevity because of its involvement in tissue repair and wound healing. It functions in a number of reactions in protein and carbohydrate metabolism, cell division and mucopolysaccharide formation. It also functions in the mobilization of vitamin A from the liver. Zinc is required in a large variety of enzymes, either as an enzyme activator or as a component of certain metalloenzymes.

Zinc is widely distributed in foodstuffs, but generally is not present in adequate supply to fill the needs of the young or producing animal. In plant sources, phytate can actively bind with inherent zinc, producing varying degrees of zinc availability. Some high-phytate ingredients, such as wheat bran or buck-

wheat, may also bind zinc from other dietary sources. Additionally, zinc requirements are increased with added calcium in the diet.

### Manganese

Manganese is present in most plant sources at moderate to poor levels. Compounding the problem of marginal levels is its relatively poor availability. The formation of chelates appears necessary for the proper absorption of manganese, which occurs throughout the intestinal tract. Bile salts are important in the absorption, excretion and reabsorption of this mineral. Recycling appears to occur several times before the mineral is finally excreted in the feces. In addition to the constantly recycling pool in the intestines, the primary storage sites for manganese are bone, kidney and liver. High concentrations are also seen in the pituitary and pineal glands. At the cellular level, the mitochondrion is the principal site for manganese uptake. With high dietary intakes, the skin and feathers will accumulate large quantities of this element.

Manganese has several functions in the body. It is essential for normal bone structure, being required for the formation of the organic bone matrix through involvement in the synthesis of chondroitin sulfate (at two separate points in its synthesis).

### Iodine

Iodine's sole metabolic function is for the biosynthesis of the thyroid hormones. Thyroid hormone functions to control the rate of energy metabolism in cells. In this way it influences growth and tissue differentiation or maturation, with resultant effects on other endocrine glands, neuromuscular function, skin and tissue development and nutrient metabolism.

Iodine is easily absorbed from the gastrointestinal tract in the reduced iodide state. Iodide is transported by loose attachments to plasma proteins. A large portion of the ingested iodide is excreted by the kidney, while the remaining amounts are taken up primarily by the thyroid gland. Small amounts can also be found in the salivary glands, stomach and other locations. The iodide uptake by the thyroid is stimulated by thyroid stimulating hormone (TSH) produced by the pituitary (see Chapter 23).

Moderate increases in dietary iodine do not present a problem because of the efficient excretion process in the body. Prolonged intake of high dietary levels of iodine causes reduced iodine uptake by the thyroid with antithyroidal or goitrogenic effects. Levels of

about 1000 times requirement are required before effects on growth, egg production or hatchability are seen in poultry.

### Selenium

To a greater degree than other trace minerals, selenium content in foods is largely dependent upon the soil selenium content in which they were grown. Fortunately, some of the most productive agricultural states (for livestock foods) are in regions with adequate-to-high selenium soils (namely, the Great Plain states).

Because the consumption of "accumulator" plants by grazing animals caused blind staggers and death within a few days, this mineral was originally considered to be only toxic. Its essentiality was not recognized until 1957, when it was accidentally found to prevent liver necrosis in rats and exudative diathesis in chicks when studies were being conducted to determine minimum toxic intake levels.

The absorption of selenium is dependent upon its chemical form. The bioavailability of selenium in most plant products ranges from 60 to 90%, while in animal products it is less than 25%. Of the different chemical forms of selenium, selenite has the highest availability followed by selenomethionine, selenide and lastly, elemental selenium. The efficiency of absorption is also dependent upon the levels in the diet, with absorption higher during a deficiency situation. Once absorbed, selenium is carried in association with plasma proteins and transported to all tissues. Although selenium is distributed throughout the body, it is found in the highest concentration in the kidneys, pancreas, pituitary and liver. Other than the enzymatic form, there are no stores of selenium, making the selenium pool quite labile.

Selenium's metabolically active form is as a component of glutathione peroxidase. This enzyme is located in the aqueous phase of the cell and is responsible for oxidizing reduced glutathione, allowing it to act as a biological antioxidant. Reduced glutathione

serves to protect membrane lipids and other cellular constituents by preventing oxidative damage by neutralizing any hydrogen peroxide and fatty acid hydroperoxides that are formed in the body.

Vitamin E and selenium are interdependent, each having the ability to spare the other. Selenium is important to the vitamin E status by preserving pancreatic integrity, maintaining normal fat digestion, micelle formation and vitamin E absorption. Selenium, as a part of glutathione peroxidase, destroys peroxides and prevents them from attacking the polyunsaturated fatty acids in cell membranes. This reduces the amount of vitamin E that is required to maintain the integrity of these membranes. Finally, selenium helps retain vitamin E in the blood plasma.

Conversely, vitamin E spares selenium by helping to prevent selenium loss from the body through its own antioxidant properties. By limiting the chain reaction destruction of membrane lipids, vitamin E minimizes the production of hydroperoxides, which would later require glutathione peroxidase to neutralize.

It is through these methods of sparing one another that selenium and vitamin E work together in the prevention of exudative diathesis. This disease is characterized by generalized edema (first appearing on the breast, wing and neck) due to abnormal capillary permeability, resulting in the leaking and accumulation of fluid. This is accompanied by decreased growth, leg weakness and mortality. Exudative diathesis has not been shown to occur except when both vitamin E and selenium are deficient.

The protection of lipid membranes from exposure to free radicals is not only important for the cell membrane, but also for the membranes of the mitochondria and microsomes. Because these act to both fuel and protect the cell, it is necessary for adequate vitamin E and selenium to be present for the cell to maintain its defense mechanisms.

## References and Suggested Readings

1. **Brue RN:** The use of grit in psittacine and passerine diets. *Kaytee Technical Bulletin*, Chilton, Kaytee Products, Inc, 1987.
2. **Brue RN:** Chronic calcium and vitamin D toxicity in cockatiels during long-term feeding studies. *Kaytee Technical Bulletin*, Chilton, Kaytee Products, Inc, 1988.
3. **Brue RN:** Food selection criteria in psittacines. *Kaytee Technical Bulletin*, Chilton, Kaytee Products, Inc, 1988.
4. **Brue RN:** Nutrient composition of common foods in aviculture. *Kaytee Technical Bulletin*, Chilton, Kaytee Products, Inc, 1989.
5. **Brue RN:** Development of mild hyper-vitaminosis D in juvenile macaws and the effect of food intake. *Kaytee Technical Bulletin*, Chilton, Kaytee Products, Inc, 1990.
6. **Brue RN:** Nutritional impact on a variety of reproductive criteria. *Kaytee Technical Bulletin*, Chilton, Kaytee Products, Inc, 1990.
7. **Brue RN:** Nutrient allowance recommendations for pet birds. *Kaytee Technical Bulletin*, Chilton, Kaytee Products, Inc, 1991.
8. **Brue RN:** Dietary energy levels in infant feeding formulas. *Kaytee Technical Bulletin*, Chilton, Kaytee Products, Inc, 1991.
9. **Brue RN, Hawley SB:** The impact of environmental temperature on the development of obesity in Amazona species. *Kaytee Technical Bulletin*. Chilton, Kaytee Products, Inc, 1992.
- 9a. **Cannon CE:** Observations on the food and energy requirements of rainbow lorikeets *Trichoglossus haematodus* (Aves:Psittacidae). *Aust Wildl Res* 6:337-46, 1979.
10. **Chaudhuri CR, Chatterjee IB:** L-ascorbic acid synthesis in birds: Phylogenetic trends. *Science* 164:435-436, 1969.
11. **Coffin JL, Combs GF Jr:** Impaired vitamin E status of chick fed T<sub>2</sub> toxin. *Poult Sci* 60:385-392, 1981.
12. **Cook ME:** Nutrient modulation of the avian immune response. *Maryland Nutr Conf*, 1989, p 6-16.
13. **Cristensen CM, Mirocha CJ, Meronuck RA:** Molds, Mycotoxins and Mycotoxins. *Univ Minn Agric Exp Stn Misc Rep* 142, 1977.
14. **Dobrescu O:** Vitamin C addition to breeder diets increases turkey semen production. *Feedstuffs* 54(9):18, 1987.
15. **Dorrestein GM, et al:** Metaplastic alterations in the salivary glands of parrots in relation to liver vitamin A levels. *Proc 1st Intl Zoo & Avian Med Conf*, 1987, pp 69-73.
16. **Dorrestein GM, et al:** An induced iron storage disease syndrome in doves and pigeons: A model for hemochromatosis in mynah birds? *Proc Assoc Avian Vet*, 1992, pp 108-112.
- 16a. **Drepper K, et al:** Untersuchungen zum Protein und energiebedarf adulter Wellensittiche (*Melopsittacus undulatus*) in Käfighaltung. [Summary of protein and energy requirements of adult budgerigars kept in cages.] *Kleintierpraxis* 33:57-62, 1988.
17. **Earle KE, Clarke NR:** The nutrition of the budgerigar (*Melopsittacus undulatus*). *J Nutr* 121:S186-192, 1991.
18. **Ekstrom DD, Degernes L:** Avian gout. *Proc Assoc Avian Vet*, 1989, pp 130-138.
19. **Garlich JD, Wyatt RD:** Effects of increased vitamin D<sub>3</sub> on calcium retention and egg shell calcification. *Poult Sci* 50:950-956, 1971.
20. **Gerlach H:** Protein and vitamin A deficiency. *J Assoc Avian Vet* 4:156, 1990.
21. **Grau CR, Roudybush TE:** Protein requirement of growing cockatiels. *Proc 34th West Poul Dis Conf*, 1985, pp 107-108.
22. **Heuser GF, Norris LC:** Rickets in chicks III: The effectiveness of mid-summer sunshine and irradiation from a quartz mercury vapor arc in preventing rickets in chickens. *Poult Sci* 8:89-98, 1929.
- 22a. **Hochleithner M:** Convulsions in African grey parrots (*Psittacus erithacus*). *Proc Assoc Avian Vet*, 1989, pp 78-81.
23. **Hoffmann-La Roche:** Roche Technical Bulletin - Vitamin B<sub>12</sub>. Nutley, NJ, Hoffmann-La Roche, Inc, 1984.
24. **Kamphues J, Meyer H:** Basic data for factorial derivation of energy and nutrient requirements of growing canaries. *J Nutr* 121:S207-208, 1991.
25. **Kolb E:** Metabolism of ascorbic acid in livestock under pathological conditions. *In* Wegger I, Tagwerker FJ, Moustgaard J (eds): *Ascorbic Acid in Domestic Animals*. Copenhagen, The Royal Danish Agricultural Society, 1984, pp 162-175.
26. **McDowell LR:** Vitamins in Animal Nutrition. New York, Academic Press, 1989.
27. **Nackels CF:** Protective effects of supplemental vitamin E against infection. *Fed Proc* 38:2134-2138, 1979.
28. **Norris LC, et al:** Effect of quantity of dietary calcium on maintenance of bone integrity in mature white leg-horn male chickens. *J Nutr* 102:1085-1092, 1972.
29. **National Research Council:** Nutrient Requirements of Poultry 8th ed. Washington, DC, National Academy Press, 1984.
30. **National Research Council:** United States-Canadian Tables of Feed Composition 3rd rev. Washington, DC, National Academy Press, 1982.
31. **Peebles ED, Brake J:** Relationship of dietary ascorbic acid to broiler breeder performance. *Poult Sci* 64:2041-2048, 1985.
32. **Pestka JJ, Bondy GS:** Alteration of immune function following dietary mycotoxin exposure. *Can J Physiol Pharmacol* 68:1009-1016, 1990.
33. **Pier AC, Richard JL, Thurston JR:** The influence of mycotoxins on resistance and immunity. Interactions of Mycotoxins in Animal Production. Washington, DC, National Academy of Sciences, 1979, pp 56-66.
34. **Porter SB, Ong DE, Chyil F:** Vitamin A status effects chromatin structure. *Intl J Vit Nutr Res* 56:11-20, 1986.
35. **Rackis JJ, Gumbmann MR:** Protease inhibitors: Physiological properties and nutritional significance. *In* Ory RL (ed): *Anti-Nutrients and Natural Toxicants in Foods*. Westport, F & N Press, 1981, pp 203-237.
36. **Reinhart TA, Hustmyer FG:** Role of vitamin D in the immune system. *J Dairy Sci* 70:952-962, 1987.
37. **Roskopf WJ:** Conure bleeding syndrome. *J Assoc Avian Vet* 4:158, 1990.
38. **Roudybush TE:** Growth, signs of deficiency, and weaning in cockatiels fed deficient diets. *Proc Assoc Avian Vet*, 1986, pp 333-340.
39. **Roudybush TE, Grau CR:** Lysine requirement of cockatiel chicks. *Proc 34th West Poul Dis Conf*, 1985, pp 113-115.
40. **Roudybush TE, Grau CR:** Food and water interrelations and the protein requirement for growth of an altricial bird, the cockatiel (*Nymphicus hollandicus*). *J Nutr* 116:552-559, 1986.
41. **Roudybush TE, Grau CR:** Cockatiel (*Nymphicus hollandicus*) nutrition. *J Nutr* 121:S206, 1991.
42. **Rowland LO, et al:** Calcium requirement for bone maintenance of aged non-laying hens. *Poult Sci* 52:1415-1418, 1973.
43. **Scott ML, Nesheim MC, Young RJ:** Nutrition of the Chicken. Ithaca, Scott and Associates, 1982.
44. **Selye H:** The Stress of Life. New York, McGraw-Hill Book Company, 1976.
45. **Shane SM, Young RJ, Krook L:** Renal and parathyroid changes produced by high calcium intake in growing pullets. *Avian Dis* 13:558-567, 1969.
46. **Takeshita K, Graham DL, Silverman S:** Hypervitaminosis D in baby macaws. *Proc Assoc Avian Vet*, 1986, pp 341-345.
- 46a. **Ullrey DE, et al:** Formulated diets versus seed mixtures for psittacines 1,2. *Amer Inst of Nutr*, S193-205, 1991.
47. **Underwood MS, et al:** Short term energy and protein utilization by budgerigars (*Melopsittacus undulatus*) fed isocaloric diets of varying protein concentrations. *Proc Assoc Avian Vet*, 1991, pp 227-237.
48. **Urbanyi L:** Chicken feeding trials with diets containing sufficient phosphorus and increasing amounts of calcium carbonate. *Nutr Abstr* 30:691, 1960.
49. **Worell A:** Serum iron levels in rhamphastids. *Proc Assoc Avian Vet*, 1991, pp 120-130.
50. **Wyndham E:** Environment and food of the budgerigar. *Austr J Ecol* 5:47-61, 1980.

CHAPTER

---

# 4

## PERSPECTIVE ON PARROT BEHAVIOR

---

■  
Greg J. Harrison

**V**eterinarians who treat companion birds must be knowledgeable about not only avian medicine and husbandry, but also behavior. Every year many birds are euthanized, sent to zoos or breeding facilities, released, abused or ignored because a client is not able to tolerate or change a bird's abnormal behavior.<sup>1,6</sup> Fortunately, most companion birds are loving, valued family members that are well adjusted to a captive environment. In order to understand the difference between a well adapted bird and one with behavioral problems, dozens of variables must be analyzed, including species, age, past history, health, diet, environment and the client's lifestyle.

Parrots appear to have a complex communication system. Vocalizations were found to be distinct among pairs of Puerto Rican Amazon Parrots and in parrots within Peru's Manu Biosphere Reserve. Differing vocalizations were used to signal danger, food or to greet another bird.<sup>14,31</sup>

To understand the behavior of companion birds, it is necessary to remember that many captive-bred birds are only one generation removed from the wild and thus retain many of the characteristics of their free-ranging conspecifics. This, coupled with their relatively high level of intelligence, can make them challenging pets.

Some species of free-ranging parrots have been noted to spend all waking hours flying, eating, preening and vocalizing with their mates. For such intensely social birds, life in an enclosure with no companionship must be the ultimate "psychological torture."<sup>14</sup> It has been suggested that large birds, especially macaws, should never be kept as a single bird unless the client can meet their extensive needs for social interaction.

## Behavior in the Wild

### From Hatching to Weaning

Even before hatching, communication appears to occur between parent and embryo. Some parents segregate infertile eggs, sometimes discarding them from the nest. Incubation studies have shown that hatching may be synchronized and that pipping sounds may actually encourage the hatching of other chicks.

The newly hatched chick is primarily concerned with staying warm and eating. The parent bird will use its beak to stimulate a feeding response by gently stroking the soft caudolateral part of the chick's beak. Some chicks (eg, Lady Gouldian Finches) have brightly colored spots in the roof of the mouth that are thought to strengthen the parents' feeding instincts. The neonate gapes (opens the mouth fully), and the parent positions its beak so that not a morsel of food is lost during transfer. In harmony with the neonate, a pumping rhythm is established as the parent regurgitates food into the chick's oral cavity. Clutch mates often pump on each other.

It has been shown that parents tend to feed the strongest beggar first. If food is in short supply, this pumping activity tends to weaken smaller chicks, ensuring the survival of stronger clutchmates. It has been estimated that as many as 80% of a clutch of neonates from free-ranging parents may not survive past the first few days or weeks of life. In nesting macaws, it was found that out of 20 nests, 7 failed completely, and only 15 to 25 young were raised from 100 pairs of nesting birds.<sup>14</sup>

As the neonate matures, the sound of the parent at the nest opening will stimulate begging sounds, first hissing and later crying. When the eyes open, the visual areas of the brain begin to map who the bird is and what it accepts as normal. This process is closely associated with the pin feather development. If the bird is in a nest and experiences only its natural parents, it "imprints" as that type of bird. It is usually quite robust and carefree about life up to that point, but once it has imprinted, strange objects may cause it to freeze in alarm.

As the chick approaches weaning, strange sights cause cries of fear and often panic behavior (eg, fluttering, thrashing, flipping backwards). Macaw neo-

nates are particularly prone to flip onto their backs when disturbed. The parents start to ignore the chicks begging to be fed, and an urge to exercise the wings starts to override the desire to be fed. Wing exercise results in a loss of weight and toning of muscles in preparation for sustained flight. The trim lines of the adult replace the bulgy abdomen of the infant, and the neonate starts to fly.

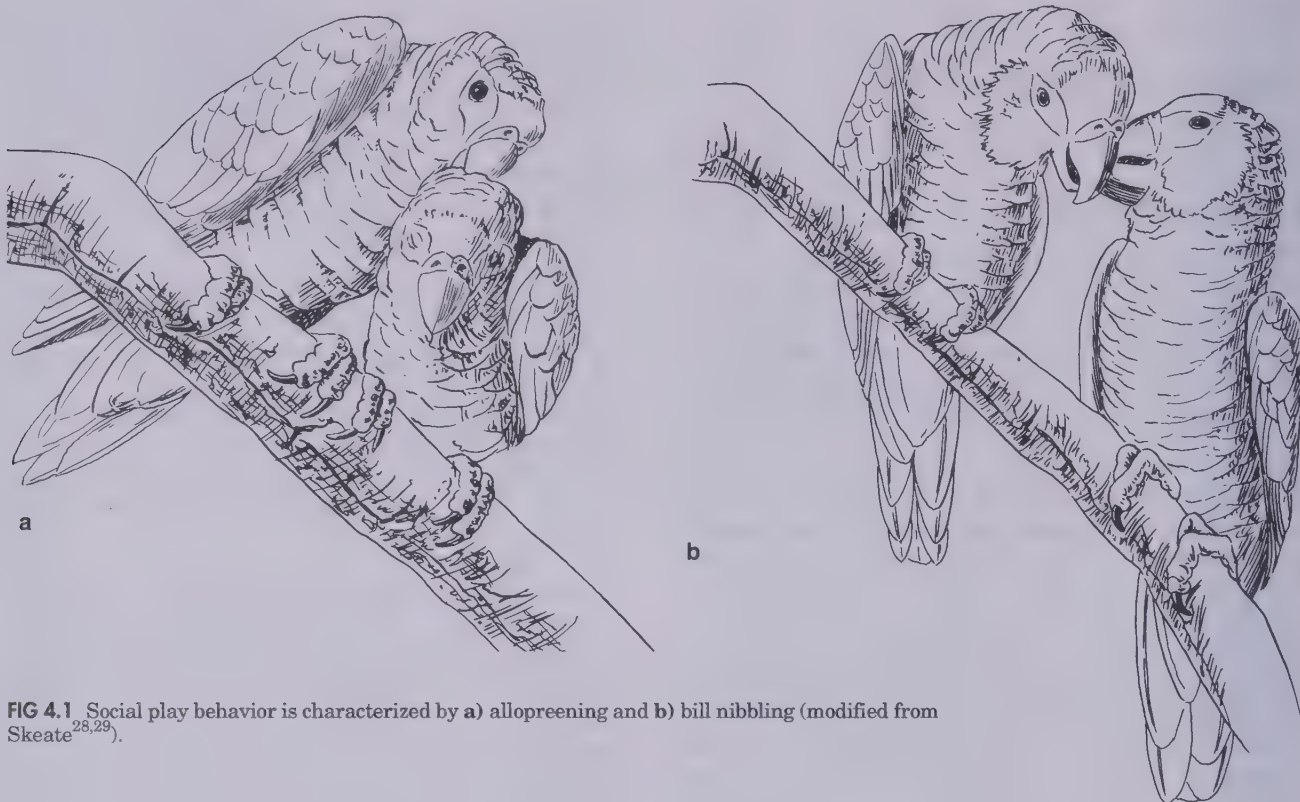
Once the bird leaves the nest (fledges), it becomes versed in the flock experience. Weaning is nearly complete as the parents feed larger, more natural sizes of food, often presenting them to the mouth rather than placing them in the pharyngeal area. In some cases, food for the neonate is placed on the nest or perch to stimulate food gathering behavior. The chick will model its eating habits after those of the parents.

In one field observation of a trio of Black Cockatoos, the parents would fly from branch to branch tearing open pine cones one after the other, ignoring the constant cries of the fully sized and adeptly flying youngster. After 30 minutes of begging and crying, the neonate finally ingested the edible parts of several pine cones unassisted. In some species, this stage of weaning is complete within weeks, while with others, it may take up to a year.

### Flock Socialization

As juvenile parrots mature in a flock, they become socialized. If the leader moves, the flock moves. Free-ranging macaws have been observed congregating in large numbers in the trees around a clay lick and waiting for the first bold pair to move onto the ground. The birds then squabble to secure an ideal position on the ground, while an alert bird stays in the tree tops as a lookout. At the slightest hint of danger, the sentry "gives an exceedingly loud alarm squawk, where upon all the parrots take off".<sup>14</sup> Young parrots also learn to submit to the leader. If they try to share the leader's food or perch they are bitten and chased away.

The White-fronted Amazon Parrot was studied over a period of two years to map the normal social behavior patterns termed playing.<sup>12,17</sup> Those behaviors deemed strictly "play" included play solicitation (moving into the other bird with head and body lowered), play biting or play fighting (slowly and gently biting the tarsi and toes of each other, and foot clawing — opening and closing the raised foot directed at the opposing bird.



**FIG 4.1** Social play behavior is characterized by **a**) allopreening and **b**) bill nibbling (modified from Skeate<sup>28,29</sup>).

Other play behaviors were associated with pair bonding and included allopreening (grooming one another's feathers), bill nibbling or gently locking bills while flicking tongues together, and pseudo-copulation (Figure 4.1). Other play behaviors were considered agonistic and included foot lifting, attack sliding and neck stretching. True aggressive behavior consisted of rapid jabs of the beak, usually directed at the head.

### **Courtship and Breeding**

Courtship activities initially involve allopreening (see Color 8). In Amazon parrots, lovebirds and the genus *Melopsittacus* the preening is confined to the head and neck region, while in *Aratinga*, *Brotogeris*, *Ara* and *Cacatua* the area preened includes the head, wings and tail.<sup>12,14</sup> Solicitation is performed by lowering the head towards the mate and assuming a ruffled appearance (Figure 4.2). As a pair bond is formed, the two birds begin traveling together and sleeping side by side. Males feeding females helps to develop this bond, but is not considered a sexually motivated activity because it occurs year round in some Amazon parrots, conures, lovebirds and Grey-cheeked Parakeets.

An older juvenile male (eg, Amazon parrots) may court submissive males until he is old enough to court an adult female in breeding condition. After several years of practice, the juvenile develops the courage to challenge a dominant male. As breeding season approaches, the dominant males establish their own territory on the perching sites and chase other birds away. The males begin eating less and the females, more. The female is often fed by the male.

Posturing for copulation begins with the female fanning her tail, leaning forward and making various vocal sounds. Mounting attempts by the male occasionally end in rolling and what appears to be fighting until finally the female allows the male to complete copulation for several days in a row. Amazon parrot and macaw males stand to the side of the soliciting female, placing one foot on her back (Figure 4.2). In cockatiels, lovebirds, conures, lorries and *Brotogeris*, the male stands with both feet on the female's back.

The pair chooses a nest site and becomes increasingly protective of the territory. Some birds (eg, Amazon parrots, macaws, Sun Conures and occasionally cockatiels) will fly at and attack intruders. In the case of most Amazon parrots, no other female is



**FIG 4.2** a) Sexual solicitation is characterized by lowering the head toward the mate and assuming a ruffled appearance. b,c) Allopreening and the male feeding the female are indications of a successful pair bond. d,e) During copulation, Amazon parrot and macaw males stand to the side of a soliciting female and place one foot on her back (modified from Skeate<sup>28,29</sup>).

allowed in the area, while in some species of cockatoos (eg, Moluccans), conures and macaws other females may approach the nest area.<sup>30</sup> Other species such as Monk Parakeets and Queen of Bavaria Conures are communal nesters, with several pairs assisting in nest building. In the case of macaws, conures and cockatiels, both genders incubate the eggs, whereas male Amazon parrots seldom go in the nest.

Many aviculturists believe that the sounds of one pair of birds courting and mating act as a stimulus to cascade breeding activity among a group of aviary birds. Some cockatoos seem inhibited by the visual presence of other birds, while limited visual interaction and opportunities for simulated combat are considered stimulating to others (Amazon parrots).

Some birds become obsessed with driving competitive birds out of their territory and breeding does not occur. This competitive behavior has also been noted in free-ranging birds when the number of birds in a flock exceeds the carrying capacity for an area. The Puerto Rican Amazon Parrot has lost so much habitat that the breeding birds must heavily compete for nest sites. This competition has been shown to prevent a pair from breeding. In addition, life-threatening physical injuries may occur from any territorial defense interactions.<sup>31</sup>

In the case of large macaws, the flock creates a buffer zone with the non-breeding birds on the fringes of the territory to warn against intruders. Several pairs of birds are involved in what appears to scientific observers as preparation of the nesting area, and only one out of several pairs breeds at any one time. Estimates of only one-third of a macaw flock breeding during any one season have been made. Thus, the number of birds in a macaw flock may be important to breeding success, and removing adult birds from an established breeding group may be extremely disruptive to other pairs within the flock (aviary).<sup>12</sup>

During incubation, some birds exhibit an aggressive walk, which is interpreted as an intraspecific threat display. Amazon parrots, pionus, conures, lorries and Hawk-headed Parrots have been observed performing this parade-like walk.

It is commonly believed that some birds such as Amazon parrots mate for life, but this theory does not always prove correct. Free-ranging male Amazon parrots have been noted to challenge a nesting male, drive it away and then breed with the female.<sup>31</sup>

In a group of breeding cockatiels, one male was found to incubate eggs, while a second male would guard the nest and help feed the young. Both males would take turns breeding the female with one male preening the hen while the other male was involved in copulatory activity.

## Companion Bird Behavior

Birds have been shown to be capable of discrimination, tool use, numerical competency and problem solving involving simple labeling and intermodal associations. They have further been shown to be able to transfer learned information and thus are considered to have abstract thought. An excellent insight into avian intelligence and learning ability is presented by an African Grey Parrot that has been shown to comprehend certain number-related concepts at a fairly advanced level.<sup>17,19</sup>

One companion bird was observed to cache food in the folds of its enclosure cover. A Blue and Gold Macaw learned to smack a stick of wood on the table, imitating the owner in an effort to discourage the house cat from coming near its enclosure.<sup>11</sup> A Boat-tailed Grackle, after repeated unsuccessful attempts to kill a frog with its beak, was video-taped using a stick to impale and kill the frog. Free-ranging birds have been filmed using sticks to remove bugs from dead trees.

### Hand-raising

Birds raised by human foster parents will imprint as people, not birds. As they mature, their natural instincts to choose a mate may cause objectionable behaviors (eg, feather picking, screaming) (Figure 4.3). An imprinted bird will spend all of its time attempting to drive unwanted individuals, other pets or objects out of its territory, while trying to find one chosen person with whom to mate.

Molding a companion bird's behavior should begin when it is a neonate. It should be raised in an area where there is lots of activity and opportunity for new experiences. It should be handled and fed by different people using a variety of feeding methods. Chicks that are exposed to different situations are more stable as adults. Chicks raised "en masse" in boxes





**FIG 4.3** A diagnosis of psychological feather picking should be reserved for cases in which no other medical cause for the abnormality can be identified. Psychological feather picking is particularly common in African Grey Parrots but can occur in any species.

without a variety of socializing experiences will be less tolerant and more fearful of new situations as adults. These birds rarely enjoy handling or close contact with people.

Weaning is an important part of early training, and it is crucial that human foster parents understand that begging and whining are a natural part of the weaning process. Some birds, especially Umbrella Cockatoos and lorries often go through a prolonged crying time as they approach weaning. Overindulgent clients can inadvertently teach the chicks that screaming, begging and throwing food will get the results they are seeking (eg, food or attention).

The weaning area should be free of perches, toys and other distractions so that the new food will be the entertainment. A flat plate covered with the formulated diet and several kinds of soft vegetables and fruit can be placed on the bottom of the enclosure. When the bird begins to reject hand-feeding, the

midday feeding should be eliminated. As it begins eating more on its own, the other feedings can be gradually decreased in volume, with the evening feeding being the last to be eliminated.

When a healthy baby is refusing food but begging constantly, it is often overly client-dependent (eg, “spoiled”). In these cases, it may be necessary to have an experienced aviculturist complete the weaning process, because the chick will not beg so intensely from a stranger. Varying the type of feeding utensil (eg, spoon, syringe), adding small chunks of whole food to the formula, or gradually moving the utensil from the bird to the feeding dish may help. It is a common practice by some aviculturists to offer foods from the hand or mouth; however, it should be noted that as a bird becomes older it is capable of seriously injuring the lips or face of the feeder.

### Preventing Behavioral Abnormalities

Successful weaning is only the beginning of molding the behavior of a companion bird. In order for the bird to recognize that it is a bird, not a human, it must understand its boundaries. Clear, consistent communication through words and actions will make the bird feel secure and realize that it is the follower, not the leader.

Herd and flock animals are guided by natural desires to lead or to follow. If a bird is allowed to lead, it will determine who can and cannot enter its territory. It may choose the person it perceives as the leader in the household, especially if that person is a good communicator of boundaries. It will also demand that certain foods or items be present in its territory. As it matures sexually, the demands increase and it becomes more and more frustrated, if allowed to lead.

## Training

### Model-Rival Training

Free-ranging parrots use other members of the flock as models for behavior. This natural learning process can be used by clients in a model-rival training program to teach birds what is and is not acceptable behavior.<sup>12</sup> This program involves the use of one per-

son as the trainer, while a second person acts as the bird's rival, and models both good and bad behavior.

For example, the goal of a training session for the African Grey Parrot, Alex, was to review and improve his pronunciation of the label "five." To accomplish this goal, two trainers, **A** and **B**, were used in a model-rival training program. The dialogue included:

- **A** (acting as trainer): "Bruce, what's this?"
- **B** (acting as model/rival): "Five wood."
- **A**: "That's right, five wood. Here you are.. five wood." **A** hands five wooden popsicle sticks to **B**, who begins to break one of the popsicle sticks apart in a manner similar to that of Alex.
- Alex: "I wood."
- **B** (now acting as trainer, quickly replaces broken stick and presents them to Alex): "Better."
- Alex: "No!"
- (**B** turns from Alex to establish visual contact with **A**.)
- **A**: "What's this?" (presents sticks)
- Alex (now acting as model/rival): "I wood."
- **B**: "Better." (Turns, then resumes eye contact): "How many?"
- **A**: "FIVE wood." (Takes wooden sticks.) "Five wood." (Now acts as trainer, directs gaze to Alex and presents sticks to him.) "How many wood?"
- Alex: "Fife wood."
- **A**: "OK, Alex, close enough. Fivvvvve wood. Here's five wood." (**A** places one stick in the bird's beak and the others within his reach.)<sup>19</sup>

### Goals and Reinforcers

A list of goals for desirable behavioral attributes for a companion bird might include: be loving and gentle, be quiet, be clean, be willing to consume a balanced diet, come when called, stay where placed, allow wings and feet to be handled, get on a perch, be controllable and be house trained. Once the behavioral goals for a bird have been established, they can be taught by using positive reinforcers.

A primary positive reinforcer is any item or action that will stimulate a behavior to recur. Trainers have traditionally used highly desirable food items, praise or affection as primary reinforcers, but it has been suggested that the use of object rewards increases the speed of learning.<sup>19</sup> The bird is allowed to play with a variety of items until it chooses a favorite. That object is then used as a reward for that day's lessons. Using the same reward every day causes boredom and slows learning. In talking lessons, it is best to use the item being taught as the reward. For example, to teach the word "strawberry," a strawberry should be the reward.

The intensity and amount of interaction with the reinforcer, or the most desirable item of the day

should be varied. The first positive response should elicit a large positive reinforcement, and each succeeding response would be a little less dramatic and much less time-consuming.

After choosing a highly desired item as a primary reinforcer, it is a good idea to also choose a secondary reinforcer. These are items or events that, through repetition, have become associated with the primary reinforcer. The advantage is that they can be interchanged with each other. For example, a sound such as a kiss, a bell, a whistle, or a clicker, can be given as a secondary reinforcer. Each time the primary reinforcer is offered, the bird develops a Pavlovian response to the secondary reinforcer. This is important because it is not always easy or appropriate to offer the primary reinforcer. The bird may be doing a series of actions and rather than stop to offer a primary reinforcer, the sound can be offered and the bird knows the desired action has occurred and is likely to repeat the performance.

### Negative Reinforcement

A negative reinforcer is something that a bird is willing to work to avoid and can be used to diminish or extinguish unwanted behavior. Negative reinforcement should be used only as a last resort after the bird has successfully completed as much of the positive training program as it is able; it is the trainer's responsibility to make certain the tasks given the bird were not too difficult. Frequently, clients try negative reinforcement first, and the bird learns that negative actions get attention. Intelligent birds consider the negative reinforcers as a form of entertainment. Especially violent negative reinforcement may destroy the bird's will to learn and cause it to reach a permanent learning plateau. Birds that are frightened may behave, but they would not be expected to seek interactions with the client or enjoy learning.

As with positive reinforcement, negative reinforcement must be given at the exact time the negative event occurs. Immediately placing the bird in a small "timeout" enclosure on the ground is an effective negative reinforcement. Neither the traveling enclosure nor the regular enclosure should be used as a negative reinforcing area. A sturdy cardboard box works well. Other possible negative reinforcers include spraying the bird with water, leaving the room and scolding.

Verbal negative reinforcers should be presented fairly, using commanding, not violent, tones. Identifying certain shapes or colors the bird dislikes may be useful. Merely showing a disliked item from a nonthreatening distance at the moment a negative action is beginning may be a deterrent. Perhaps the use of a remote or voice-activated shocking perch would be effective for feather picking and screaming.

### ■ Initiating Training

When training a chick, a commitment of at least 15 minutes, three times a week, for three to six months is a minimum. Training sessions should be uninterrupted, and begin and end at the same time each day. They should be held in an unfamiliar place, away from the bird's play or living area. Training of juvenile birds should begin with simple, one-word commands given over and over to elicit a chosen response. The command must be the same each time, and the bird's response must be the same each time in order for the bird to receive reinforcement. Commands should be issued in a command tone that is sharp, louder than a normal talking voice and delivered with authority.

During the early part of training, the minimal effort on the bird's part must be rewarded, and every time the desired action is repeated it is reinforced. Timing of reinforcement is critically important. The reinforcing event must occur at the exact second that the positive action has been completed. This makes it easy for the bird to understand what is being reinforced and increases the possibility of a repeat performance.

After the desired behavior is established it is recommended to attempt two performances to get reinforcement, then three, four and so on until ten behaviors in a row are performed for one reinforcement. At that point, the reinforcement should be changed from a predictable schedule (ten behaviors = one reinforcer) to a random schedule. Thus, a reinforcer may require 10 behaviors one time and two the next. It takes a while to establish random scheduling, but once established it will produce the strongest performance.

### ■ Teaching Commands

In order to be good companions, birds should respond to a minimum of six or seven commands such as "come," "up," "stay," "wing," "foot," "hood" and "go potty."

Training should begin while the neonate is still being hand-fed and the pin feathers are just beginning to

open. In order to teach the bird to come, a desired item should be presented to it while giving the command, "come." Beginning with a feeding utensil first thing in the morning often works well, especially if no food has been left in the enclosure overnight. The "stay" command should be taught second, while placing a hand in front of the bird in a stop-sign fashion.

With the bird already on a perch, the "stay" command should be given. While the trainer's hand remains in a stop-sign fashion, a second perch is presented to the bird. The "up" command is given and the bird is encouraged to step up onto the perch.

The "wing" command is accomplished by gently taking each wing from the folded to the open position. Repetition and reinforcement may be needed for ten to twelve weeks. By the time of the emergence of the first pin feathers, the bird should be able to lift its wing on command. Once fledging age is reached, the primary feather tips may be easily clipped one portion at a time by using the commands "stay" and "wing."

Likewise, "stay" and "foot" commands are taught for nail trimming. Over a period of weeks, the bird learns to present its foot and allow the nails to be filed.

For ease of mouth examination, "stay," and "tongue" commands are used. The bird can be taught to allow its tongue to be held for up to ten seconds.

By covering the head with a hood, most birds can be easily handled for nail and wing clips and even minor surgery. This has been shown to be an effective way of calming pious parrots, cockatiels, conures, cockatoos, some Amazon parrots and macaws. A doll bonnet can be modified by stitching a length of cloth to the brim and inserting a draw string in the bottom edge, making a sort of bee keeper's bonnet. Towels and plastic trash liners have also been used successfully. The hood should be slowly introduced during play time, making sure it does not frighten the bird. Gradually, over several play sessions, the hood can be placed on the bird's head. Hooding time can be extended to accommodate long periods of time such as those that occur with travel. Hooding prior to anticipated times of stress (eg, visits to the veterinarian) is a good way to prevent fear reactions.

### ■ House Training

Many birds have a natural inclination to keep the nest clean. They will defecate over the edge or in an area away from the nest. Companion birds usually defecate when they are aroused first thing in the

morning. Other common times are when first picked up and every few minutes thereafter on a fairly predictable schedule. With some patience, ingenuity and reinforcement, most birds can be house trained. Each time the bird is picked up, it should be held over the "toilet" area and the "go potty" command should be given. Signs of impending defecation such as legs apart, squatting and leaning back are cues for moving the bird to the "toilet" and issuing the command. Some larger psittacine birds can be trained in a week, but smaller species make less obvious preparation for defecation and are somewhat more difficult. Nervous birds can be expected to go more often and should be presented with the opportunity to do so.

### ■ Diet Changes

The first step in changing a bird's behavior is a thorough physical examination to detect any sub-clinical disorders. It is difficult to change behavior in a bird that is ill. Included should be a blood panel for liver function and CBC, Gram's stain, possibly radiographs and cultures. If the bird is on a seed diet, the injection of vitamins, minerals and oral lactulose should precede diet change by three weeks.

For many large birds, offering a highly palatable diet alone for 24 hours is sufficient. If they refuse to eat, mixing the new diet in the old seed diet or adding a treat such as popcorn, fruit juice, cheese or other sweet or fatty items may help. Table food may also be mixed with the new diet for several days, and then gradually decreased. Frequently, the biggest obstacle in correcting an improper diet is the client. Most birds will switch to the new diet within five days if they are placed in a different environment separate from the client.

Many birds are so accustomed to seeds and the familiar surroundings in their enclosure, that adding anything new is stressful. A bird may sit on the opposite side of its enclosure for weeks after a piece of carrot or a new toy has been added. For these birds, a diet change is often more successful if food is not the only change made. The bird is placed in a box, aquarium, bath tub or travel enclosure with no bowls, toys or perches. The food is sprinkled on the floor of its new enclosure, and after several hours of walking on the food, the fear is gone. The natural picking curiosity returns and the food is eaten. Placing food over a mirror on the floor may also help. Use of a bird already on the diet as a model is often rewarding.<sup>9</sup>

A number of formulated diets are available today based on nutritional requirements of various companion bird species. Some are more readily accepted than others. As a general rule the extruded diets are more palatable than pelleted diets. Several studies have shown that birds tend to choose a diet most like the diet available in nature.<sup>21,24</sup> Subtle shades of black, brown, yellow and green (naturally occurring colors of food) have been shown to be most acceptable. The use of dyed grains has been found to decrease the acceptance of food in several studies.<sup>10,16</sup>

Birds are able to taste, which is supported by the presence of taste receptors. Preference testing experiments that showed responses to sweet, bitter, acid and salt solutions.<sup>3,5,8,29</sup> Sugar or fat can be added to a diet to facilitate its acceptance; however, the continued use of 10% sugar and 15% fat by weight in a formulated diet has been shown to be detrimental. Birds have been shown to avoid foods treated with pesticides if given a choice.<sup>11,13,22,23</sup>

## Behavioral Modification

Although it is ideal to train birds when they are young, adult birds with behavioral problems can also be trained. The quickest route to an obedient bird is to let the bird know it must depend on you for leadership.

A hand-held perch and portable stand perches of several heights (all shorter than the handler's shoulders) are required for the training sessions. Plastic jugs or buckets can be cut to scabbard the arm, keeping the bird off the arm and shoulder and also preventing biting, while a hand cover may be cut from a sheet of dark plastic or a garbage can liner. A hood should also be available.

The bird's favorite color may be discovered by using children's beads or other toys that are similar in size and shape but of different colors. The color the bird chooses to play with is considered a favorite and should be used on perches, clothes and reinforcers. The training routine and the commands used must remain consistent. The same stands, perches and reinforcers should be used at each session, and the trainer should even wear the same uniform (eg, a favorite hat or shirt in the bird's favorite color) (Figure 4.4).



**FIG 4.4** To be the most effective, training sessions should occur at the same time each day and there should be consistency with respect to the routine. In this case, an adult Blue and Gold Macaw is being taught to step onto a perch and to allow itself to be stroked. The bird appears to prefer blue colors and the perch and clothing of the trainer reflect this preference. A perch is presented and the command is given to “step up.” A blue plastic bag is used to facilitate contact with the bird as the initial step to acclimate the bird to being stroked.

Only one person should be the trainer for at least the first three to four weeks, but a tape recorder, video camera or coach may help monitor communication between the trainer and the bird. Methods for training problem birds are similar to those for neonates. Simple, one-word commands in a relatively strong, authoritative voice should be given only once and only when in training. The trainer must be ready to demonstrate appropriate behaviors and must have positive reinforcers chosen and ready to be delivered. To be effective, behavior correction sessions must occur four times each week for a minimum of 15 minutes for each session. Practice sessions should take place in the training area only and should be uninterrupted.

### Specific Behavioral Problems

Companion birds are frequently presented to the avian practitioner with behavioral problems. Birds exhibit a variety of negative behaviors including biting, screaming, feather picking, favoring one person and an unwillingness to go in or come out of an enclosure. Training steps that can be used to correct many of these problems are listed in Table 4.1. Many of these problems can be prevented by encouraging the client to carefully select a companion bird based on specific attributes (see Chapter 1).

#### Biting

A good way to overcome negative behavior is to avoid it. A biting bird should receive no affection (eg, pet-

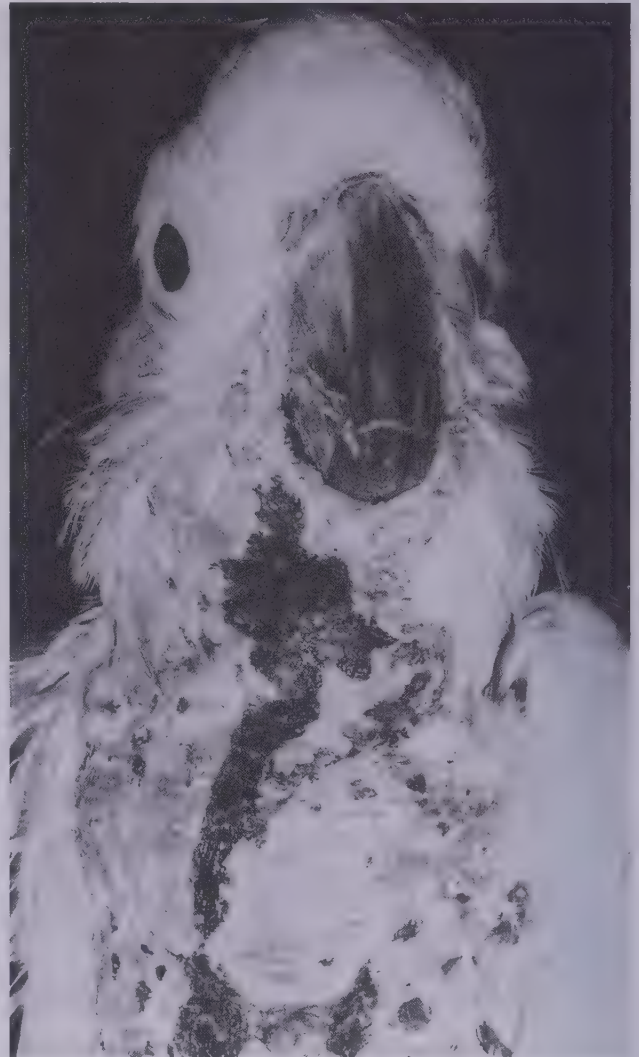**TABLE 4.1 Steps to Behavior Modification**

- Stage 1** During the first week of training, the bird should learn to stay on command. To do this, it needs to identify the word, "stay" with some negative visual signal (eg, holding the hand up with the flat palm facing the bird, or holding a large black object in front of the bird). If the bird tries to move or bite, the visual signal is offered with the word "stay". If the bird responds (a response in this case is lack of movement), it should be verbally praised. When the "stay" command is mastered and the bird has successfully responded ten times in a row, the training can move to Stage 2.
- Stage 2** The bird is ready to be picked up with a perch on command. First issue the "stay" directive, even as the hand-held perch is being presented (without the "up" command). Hesitate to see if the bird steps up on its own. If so, present the negative visual signal but do not repeat "stay." Then give the "up" command. If the bird does not step up, gently slide the perch closer into the bird's abdomen to force it to step up on the perch. Reinforce (verbally praise) the bird for stepping up. Repeat the process, going from the hand-held perch to a stand perch using the same commands, "stay" (with the stop sign) and "up" for moving to the perch (at the discretion of the trainer, not the bird). The bird can then be trained to "stay" on the perch stand, for increasing periods of time.
- Stage 3** Using a feather or a stick, the wing is slightly opened away from the bird's body, while the command, "wing" is given. The bird is praised, and the steps are repeated. The same series of exercises can be performed to enable the bird to lift a foot on the "foot" command. Eventually, the bird will respond comfortably so the wings and nails can be trimmed without restraint.
- Stage 4** When "stay," "up," "wing" and "foot" are performed successfully, the bird is ready to receive a hood. A large soft article of an acceptable color (towel, piece of opaque plastic, etc) is gently draped over the bird's body while the command "hood" is given. The article is left on for only a few seconds at first, gradually increasing the time of each phase as the material is maneuvered up over the head. The size is gradually decreased so a small "hood" is actually placed over the head, obscuring the bird's vision. The hood is then removed at intervals. Stages 1 through 3 should be repeated with the hood over the bird's head. Over time, the trainer should be able to touch and walk around with the hooded bird on the hand-held perch, and even trim the wings or nails and transfer the bird to a new person without incident. Additional challenges should be added from time to time to keep the bird interested and the bird/trainer relationship strong.

ting, holding) for one to two months. If the bird is biting out of fear the trainer must first gain its confidence. If it is biting because it is "spoiled" or needs to show dominance, it must first be trained to respect the client. If the bird runs up the perch and bites the trainer's hand, a section of PVC pipe placed over a portion of the perch so it will spin if stepped on, can be used as an effective barrier.

### Screaming

Screaming is a serious behavioral problem, especially in cockatoos and macaws. The time of day and circumstances associated with screaming should be charted for several weeks in order to arrange training or play sessions for the time just before the



**FIG 4.5** Some cases of psychological feather picking can progress to the point of self-mutilation.

screaming behavior usually begins. If that is impossible, the bird may be hooded or taken to a dark time-out location prior to screaming periods. The remainder of the training is routine, with special emphasis placed on the trainer leaving the room for increasing periods of time during the stay command. If the bird screams during training, the trainer should leave the room, and if it continues, the bird should be hooded or placed in a time-out location until it stops. Yelling back at a bird is never useful, as it will quickly learn that screaming is a good way to get attention. The trainer should always wear ear protection when working with a screaming bird.

### Feather Picking

Feather picking may be caused by pathologic and psychologic conditions, and the first step in solving the problem is a thorough physical examination. Once medical causes of feather picking have been ruled-out, psychologic causes should be explored. The two most common primary causes of feather picking in the author's experience are frustrated mating instincts and lack of proper training (Figure 4.5).

Sexual frustration is common in birds, especially in cockatoos and many domestically bred birds. Programmed in the wild to be constantly with a mate, a bird becomes distraught when its "person mate" is gone much of the day. It may also become jealous of other family members or maladjusted following a change in environment (eg, change of enclosure location, a new dog or child). Even the client's emotional state can affect the bird's behavior.

Training is the first step in solving psychological feather picking, with correction of any dietary deficiencies being a critical part of the therapy. Birds that feather pick often consume pin feathers as if they are attracted to the taste of blood. A craving for the minerals, protein and fat of mature feathers may even be the cause for this pica. Birds given a balanced diet tend to feather pick less and spend less time chewing plants and perches. Many birds pick when first left alone, so early training in anticipation of the problem may be an effective preventive. Once feather picking is established, training may decrease the severity of the feather picking but will rarely stop the habit (see Chapter 24).

### Favoring One Person

A bird that fiercely favors one person should be given the basic training, and when the training is finished, several other people should become involved in giving the commands and continuing the training interactions. Sexual stimulation such as stroking, playing with favorite toys and hiding in dark places should be avoided (Figure 4.6). When other people are present, the bird should be kept away from areas it wants to defend, such as shoulders and its enclosure. Sexually induced regurgitation, masturbatory behavior and pulling ears and jewelry can be corrected using preventive measures, basic training and finally, negative reinforcement.

### Going In and Out of Enclosure

A bird that refuses to leave its enclosure should be fed just outside the enclosure door. The food should be left out for 15 minutes and then removed. Once the



**FIG 4.6** Masturbatory activity is common in imprinted adult birds that accept a client, enclosure furniture or toys as a mate.

bird is accepting food in a bowl placed on the outside of the enclosure, it should be made to eat a portion of each day's meals from a spoon. With a perch stand placed near the enclosure door, the bird should be taught the "come" command while the trainer holds the food for several minutes. If this is repeated several times a day, the bird will gradually learn to perch outside the enclosure and can then be moved to other eating areas away from the enclosure.

A bird that refuses to go back into its enclosure may be trained in the same manner by placing food in the enclosure for 15 minutes. If the bird enters within that time period, it is allowed to eat for a few minutes before the food is removed and the door is closed.

A bird that has psychogenic polydipsia may respond to a similar behavioral modification program. Consumption of water is restricted to two ten-minute periods a day. These birds should be examined for possible disease.

### Support Groups

Veterinarians, bird trainers, behaviorists and bird clubs have begun to offer group support for prevention and correction of bird behavior problems. Some resources for behavior modification are: Chris Davis, PO Box 1067, Sierra Madre CA 91025; 818-355-2267; Eddie Callahan, 5770 Lake Worth Road, Lake Worth FL 33463; 407-964-2121; Parrot Responsive, PO Box 66 Dept. RHH, Riverside IL 60546; 708-442-8081; Parrot People, PO Box 1650, Bellaire TX 77402-1650; 713-447-6622.

## References and Suggested Reading

1. **Anonymous:** Avian Swingers: What should you do about sex and the single bird? *Pet Health News*, 1992, pp 18-19.
2. **Bennett RS, et al:** Influences of agriculture pesticides on food preference and consumption by ring-necked pheasants. *J Wildl Mgmt* 45:74-82, 1981.
3. **Brindley LD:** Taste discrimination in bobwhite and Japanese quail *Am Behav* 13:507-512, 1965.
4. **Bryant, Robel RJ, et al:** Discrimination among colored and flavored extruder-produced food morsels by Harris' and tree Sparrows. K State U Division of Biology, submitted for publication 1992.
5. **Dalzell R:** Hoods in birds. *Assoc Avian Vet Newsletter* 5(3): 1984.
6. **Duncan CJ:** The sense of taste in birds. *Ann Appl Biol* 48:409-414, 1960.
7. **Gibru M:** IME 653 Avoiding imprinting problems. *Assoc Avian Vet Newsletter* 5(3): 1984.
8. **Grau CR, Roudybush TE:** Sunflower seeds for psittacines. *Exotic Bird Report*, Dept Avian Sci, U CA Davis, 1987, pp 32-36
9. **Grieg-Smith PW:** The importance of flavor in determining the feeding preferences of bullfinches for the buds of two pear cultivars. *J Appl Ecol* 22:29-37, 1985.
10. **HBD, Inc:** Trainer Bird literature. Pawnee City, NE, 1991.
11. **Kalmbach ER:** Birds, rodents and colored lethal baits. *Trans N Am Wildl Conf* 8:408-416, 1943.
12. **Leuang N:** Personal communication Lake Worth FL, 1990.
13. **Levinson ST:** The social behavior of the white-fronted amazon (*Amazona albifrons*). Conservation of New World Parrots. Proc ICBP Parrot Working Group Meeting St. Lucia, Washington DC, Smithsonian Inst Press, 1980, pp 403-417.
14. **Lorenz K:** Studies in Animal and Human Behavior Vol 1. Cambridge, Harvard University Press, 1970.
15. **Munn C:** The real macaws. *Animal Kingdom Mag*, New York Zoological Park, New York, 91:5, 1988.
16. **Patterson DK, et al:** A comparison of human and parrot phonation: Acoustic and articulatory correlates of vowels. (Manuscript in preparation for correspondence contact IM Pepperberg Dept Ecology & Evoi Biol U AZ, 85721.)
17. **Pank LR:** Effects of seed and background colors on seed acceptance by birds. *J Wildl Mgmt* 40:769-774, 1976.
18. **Pepperberg IM:** Evidence for conceptual quantitative abilities in the african grey parrot: labeling of cardinal sets. *Ethology*, 75:37-61, 1987.
19. **Pepperberg IM:** An interactive modeling technique for acquisition of communication skills: Separation of "labeling" and "requesting" in a psittacine subject. *Appl Psychol* 9:59-76, 1988.
20. **Pepperberg IM:** Some cognitive capabilities of an African grey parrot (*Psittacus erithacus*). In Slater PJB, et al (eds): *Advances in the study of behavior*. New York, Academic Press 1990, pp 357-409.
21. **Pepperberg IM, et al:** Solitary sound play during acquisition of english vocalizations by an African grey parrot (*Psittacus erithacus*): Possible parallels with children's monologue speech. *Appl Psychol*, 12:151-178, 1991.
22. **Robinowith V:** The role of experience in the development and retention of seed preferences in zebra finches. *Behavior* 33:222-236, 1969.
23. **Robel RJ, et al:** Effects of carbamates on bobwhite food intake, bodyweight and locomotor activity. *Arch Environm Contam Toxicol* 11:611-615, 1982.
24. **Robel RJ, et al:** Chronic effects of a prescribed field application of a carbamate insecticide on bobwhites. *J World Pheasant Assoc* 10:47-64, 1985.
25. **Robel RJ, et al:** Discrimination among colored and flavored extruder-produced food morsels by harris' and tree sparrows. *KSU Div Biol Manual*, 1992.
26. **Scott ML:** Nutritional principles as a guide to optimum maintenance, development and reproduction in captive birds. *Proc 1st Intl Birds in Captiv Symp*, Seattle, 1978, pp 121- 137.
27. **Staff P:** The magic of behavior modification. *Am Cage Bird Mag* 64(2):9-13, 1992.
28. **Skeate ST:** Courtship and reproductive behaviour of captive white-fronted amazon parrots (*Amazona albifrons*). *Bird Behav* 5:103-109, 1984.
29. **Skeate ST:** Social play behaviours in captive white-fronted amazon parrots (*Amazona albifrons*) *Bird Behav* 6:46-48, 1985.
- 29a. **Taylor I:** Results of aviculture survey. *Birds Eye View*, Newsletter of the Smokey Mountain Cage Bird Society, Saluda NC, 1988.
30. **Warren R, et al:** Taste discrimination in great tit (*Parus major*) *J Comp Physiol Psychol* 56:910-913, 1963.
31. **Wiley JW:** The Puerto Rican parrot (*Amazona vitta*): Its decline and the program for its conservation. Conservation of New World Parrots, Proc ICBP Parrot Working Group Meeting St. Lucia, pp 133-159, 1980.
32. **Wiley JW:** Personal communication. USDI Fish and Wildlife Service's Puerto Rican Amazon Luquillo Forest Aviary, 1986.



**T**he defense mechanisms of avian species are generally comparable to those of mammals despite fundamental differences in the structure of the system. Detailed information is available only for the chicken, which serves as the model for studying the development of bursa- and thymus-derived lymphocytes. Conclusions concerning the immune system of other avian species from information derived from the chicken may or may not be valid. Initial comparisons among the immune systems of chickens, ducks and geese indicate substantial similarities. The strength and functionality of the defense system is genetically determined, and in free-ranging birds is based on natural selection. Likewise, birds from arid or arctic environments are not exposed to the same pathogens as birds from temperate or tropical areas, and consequently have developed adaptations to a different group of pathogens. Birds indigenous to one environment that are moved to a different environment may have no immediate protection against the new group of microorganisms they would encounter. Many captive birds have been inbred for color mutations. This inbreeding may weaken the immune system and cause these birds to be more susceptible to disease than their free-ranging relatives (Figure 5.1).

The purpose of the defense system is not only to protect the individual against invasive organisms, but also to eliminate abnormal body cells. These include cells with minor structural or antigenic deviations, such as old cells, virus-infected cells and transformed (cancer) cells. The defense system also functions in the recognition of foreign cells, as is observed in graft rejection phenomena. For this system to function properly, it is mandatory that the body be able to distinguish between normal body cells (self antigens) and those antigens that are unlike self (foreign antigens). If the body becomes intolerant of its own cells, then an autoimmune disease occurs.

The defense system consists of several integrated components: nonspecific defense, and specific defense, which includes the humoral immune system, cell-mediated immune system and tolerance.

---

CHAPTER

---

5

**DEFENSE  
MECHANISMS OF  
THE AVIAN HOST**

---

**Helga Gerlach**




**FIG 5.1** In general, inbreeding only to obtain specific color mutations can be expected to weaken a bird's immune system compared to its wild-type relatives. Cockatiels with color mutations have a reduced life-span and increased infectious disease problems. Few color mutation cockatiels approach the 15- to 20-year longevity that their wild-type relatives enjoy. For the health of the individual animal, inbreeding should be discouraged.

Each component of the defense system is intricately connected to the other components through the interaction of cells and hormone-like mediators or secretions. These mediators are responsible for activating or suppressing other components of the system, keeping the defenses in proper balance. It is essential for the avian clinician to have an understanding of the importance and interaction of the important components of the defense system.

## Nonspecific Defense

### Epithelial Surfaces

The primary barriers that any animal has in preventing pathogen access to the body are the skin and the mucosal linings of the intestinal, respiratory, urinary and reproductive tracts. In the normal host, this is achieved by establishing environments that are suitable exclusively for the best-adapted microorganisms with a low pathogenicity or none at all, which effectively inhibit colonization by other, less well adapted and frequently more pathogenic organisms. This is achieved by adhesion of bacteria to the epithelial cell, eg, by pili or fimbria, by production of bacteriocins and by tolerance of environmental conditions (Figure 5.2). The skin serves, among other things, as a physical barrier to potentially invasive microorganisms.



**FIG 5.2 a)** The normal mucosal surface of the intestinal tract is covered with local immune factors (IgA) and autochthonous bacterial flora to provide a barrier that prevents microbes from gaining access to the host. **b)** If the mucosal barrier is damaged by exposure to toxins, malnutrition or primary pathogens, secondary pathogens may colonize the gastrointestinal tract or enter the body and cause systemic disease (courtesy of WS Steffens).

The native flora of the skin is specified and regulated by factors such as desquamation, desiccation and a relatively low pH.<sup>10</sup> Changes in local environmental factors can damage the flora and allow invasion by other microorganisms.

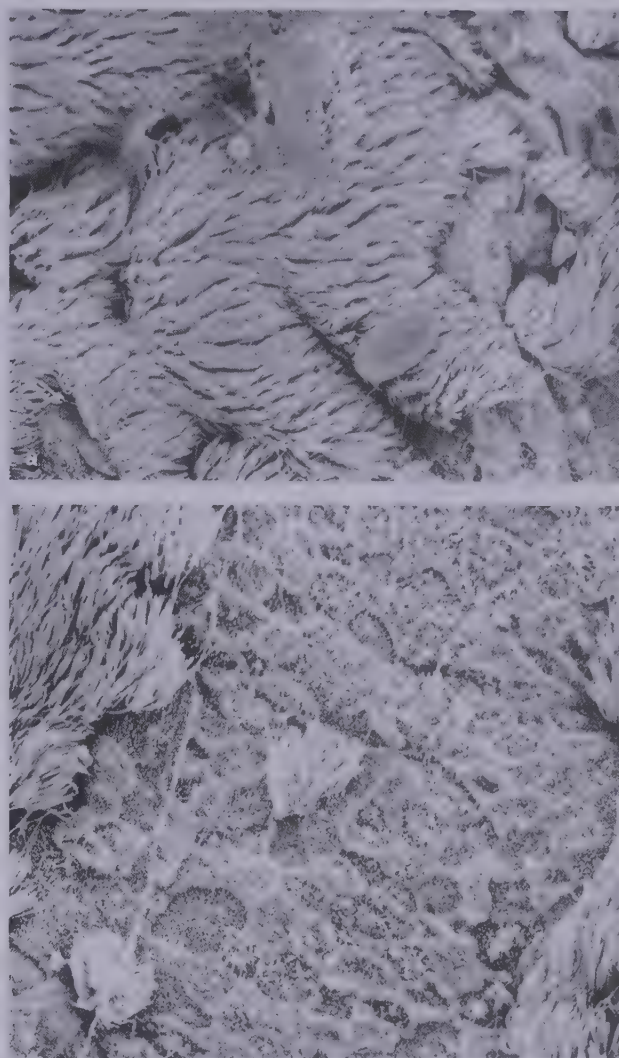
### Autochthonous Flora

The normal or autochthonous flora of the intestinal tract is developed in the newly-hatched chick during the first three to four weeks of life. This flora is species-specific, and its composition is governed by the prevailing physical and chemical conditions in the lumen. The acquired flora takes up the available space, occupies receptors and acts competitively against invaders by various mechanisms such as inhibitory metabolic products, bacteriocins and production of a low pH environment. A practical example of the protective nature of resident bacteria in the gastrointestinal tract is the inhibition and expulsion of *Enterobacteriaceae* by lactobacilli. This inhibition is particularly important in birds in which *Enterobacteriaceae* are not considered to be normal components of the intestinal flora. The natural development of the immune system also depends on continuous antigenic stimulation by the autochthonous flora. Mucosa-associated lymphatic tissue forms the so-called lymphoepithelial system, which appears to function by capturing and processing antigens from the mucosal surface.

The mucosa of the respiratory, urinary and reproductive tracts of birds is similarly colonized by specific flora whose compositions are relatively unknown; however, thus far it has been shown that none of these mucosal surfaces normally contain *Enterobacteriaceae*. The mucosal surfaces contain goblet cells that secrete a tenacious mucus. The mucus serves to cover cellular receptors for bacteria or viruses. This mucus also contains lysozyme (which has antibacterial and antiviral activities) and immunoglobulin (Ig) A. In addition, the respiratory mucosa to the level of the secondary bronchi is equipped with cilia that transports foreign material collected from material suspended in the inspired air back out of the system (Figure 5.3).

### Myeloid System

The cellular (myeloid) system provides the next line of defense against any pathogens or foreign materials that succeed in penetrating the epithelial or mucosal barriers. This system consists of three cell types that all originate from the bone marrow: polymorphonuclear granulocytes (the most important of which is the heterophil), thrombocytes and mononuclear cells, which differentiate into macrophages.



**FIG 5.3** a) The normal tracheal mucosa is covered with a mucociliary blanket that serves to remove foreign material that enters the trachea and also serves as a barrier that prevents microbes from entering the circulation. b) When the mucociliary blanket is damaged, the patient becomes increasingly susceptible to infectious agents. In this case, the mucociliary blanket has been destroyed by indiscriminate exposure to disinfectant fumes (courtesy of Jean Sanders).

### Leukocytes

Generally speaking, the nucleus of the avian heterophil is multi-lobulated when it leaves the bone marrow. Therefore, the left shift seen in mammals is difficult to ascertain. Heterophils are rather short-lived (a few hours or days), and their granules are packed with a variety of enzymes (peroxidases, proteases, hydrolases) and lactoferrin. Lactoferrin serves to bind free iron, which is a required growth factor for many bacteria. The main function of heterophils is to phagocytize and destroy "foreign" mate-

rial or damaged cells without having to process them as antigens for presentation to the immune system. The ability of heterophils to ingest some pathogens depends on their being coated with opsonins. Several blood proteins, including fibronectin, antibodies or C3b complexes derived from the complement cascade (in the case of the alternate pathway, this may occur independently of antibodies) can function as opsonins.<sup>15</sup> A depletion of fibronectins, induced by trauma or large numbers of bacteria can block the phagocytic cells and suppresses the nonspecific cellular defense system.

The second way in which heterophils eliminate bacteria is by producing  $\text{OCl}^-$ , hydroxyl radicals ( $\text{OH}^\bullet$ ), and singlet oxygen.  $\text{OCl}^-$  causes oxidation of bacterial capsular proteins, and the latter two substances are highly unstable and react with lipids to form toxic, bactericidal hydroperoxides. These reactions are called the "respiratory burst."<sup>15</sup> Animals genetically deficient in superoxide dismutase or myeloperoxidase lack this defense mechanism and frequently suffer from recurrent bacterial infections. Heterophils have only limited energy resources that cannot be replenished. They are consistently reproduced and serve merely as the first line of internal defense. When a pathogen is able to resist these defense systems, the macrophage system, with prolonged diversified functions, assumes the responsibility for protecting the host.

The information on avian eosinophils is still rather poor. Responses by eosinophils are at least partly species-specific. In contrast to mammals, birds are not generally thought to respond to parasitic invasion with an increase of eosinophils. The fact that avian eosinophils are difficult to distinguish from heterophils may explain some of the literature reports suggesting parasite-induced eosinophilia. It appears that avian eosinophils participate in hypersensitivity reactions. The degree of involvement is thought to be dependent on the species, inciting antigen and age of the individual.<sup>9</sup>

Avian basophils are morphologically and functionally identical to tissue mast cells. Their granules contain vasoactive amines and proteins, prostaglandins and activators for the coagulating cascade, as well as anticoagulants such as heparin. These cells function to accelerate inflammation at the site of antigen deposition.

### Thrombocytes

Unlike mammalian platelets, avian thrombocytes are capable of phagocytosis. It is currently undetermined if the phagocytic process is the same as that used by heterophils.

### Macrophages

All macrophages are derived from the bone marrow and enter the peripheral blood as monocytes. The morphologies of the macrophages vary according to their location and functional state (Table 5.1).

TABLE 5.1 Macrophage Morphology by Location

Morphology	Location
Monocyte	Peripheral blood
Histiocyte	Various tissues
Kupffer's stellate cell	Liver sinus
Multinucleated giant cell	Granulomatous tissue
Langhans' giant cell	Tuberculous granuloma
Epithelioid cell	Macrophages with intraplasmatic inclusion
Microglial cells	Brain

Cells corresponding to the alveolar macrophages of mammals have not been demonstrated in the avian lung. However, as a compensatory mechanism the entire epithelial surface in the parabronchi, atria and part of the infundibulum is capable of taking up particulate matter and transporting it into phagosomes, which are subsequently processed by interstitial macrophages. This defense system may partially explain the relatively high resistance of the avian lung to infectious agents<sup>6</sup> (see Chapter 22).

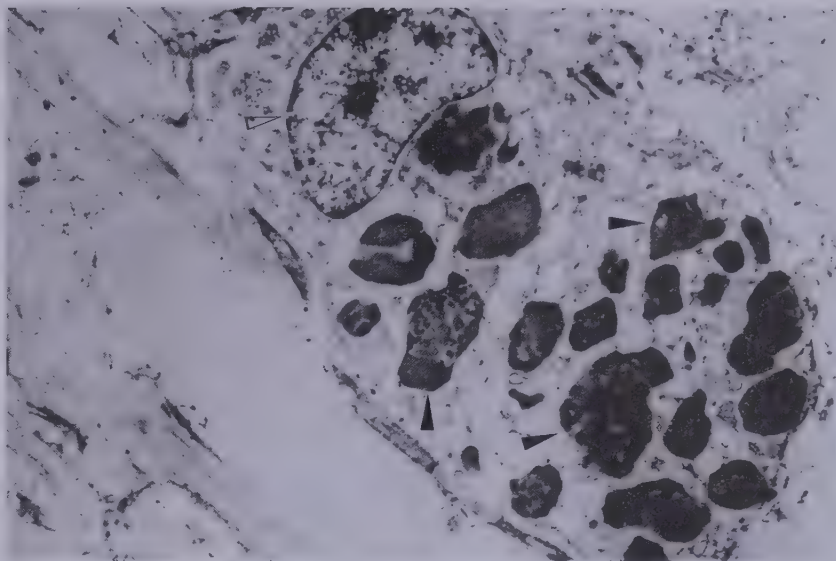
Macrophages have a long life-span unless they are destroyed by the material they ingest. They are equipped with lysosomes containing various substances that can be set free according to their respective functions. These substances are involved in phagocytosis, promoting fever (much rarer in birds than in mammals), inducing inflammation, processing antigens to stimulate an immune response and tissue healing. Phagocytosis is the fundamental process of macrophages. These cells possess receptors for complement factor (C) 3 and antibodies. Foreign particles that are opsonized (covered) with either of these substances can then bind to specific receptors on macrophages and be ingested. Functional macrophages isolate ingested material within a specialized intracytoplasmic compartment called a phagosome. These cells secrete a protein called interleukin 1 (IL-1), which seems to function in mobilizing hetero-

phils, altering host metabolism and inducing inflammation. Macrophages are activated by  $\tau$ -interferon released by T-lymphocytes. Activation causes macrophages to increase in size, mobility and metabolic activity. The phagosomes enlarge and produce increased amounts of hydrolytic enzymes. As a consequence, more IL-1 is secreted, causing intracellular microorganisms engulfed by phagosomes to be destroyed more easily. Some microorganisms are able to survive inside the macrophage.

Macrophages are active factors in the inflammatory process. They are chemotactically attracted to the site of microbial invasion where they help to eliminate the intruder. In addition, they secrete factors such as complement factors C2, C3, C4 and C5, enzymes such as lysozyme, elastase and collagenase and plasminogen activators. Cyclic AMP, prostaglandins and leukotrienes are also released. Macrophages also activate fibroblasts and stimulate wound healing. The ability of a host to survive an infection is usually dependent on the functional capacity of the macrophages (Figure 5.4) An increase of monocytes in the peripheral blood can therefore indicate that the host successfully resisted microorganisms.

Not all foreign material is totally ingested or destroyed in macrophages. Some antigen molecules remain on the cell surface for long periods of time. The surface of this macrophage subpopulation expresses special antigens (class II histocompatibility antigens: cell membrane antigens on macrophages, B-cells and activated T-cells) that regulate the interaction between the antigen-presenting macrophage and the antigen-recognizing cells (lymphocytes). If an antigen evades the macrophages and reaches the antigen-sensitive cells, then the host either will manifest a poor immune response or will be tolerant of the antigen.

Macrophage-like cells (called dendritic cells) are characterized by long, filamentous cytoplasmic processes and are distributed throughout the spleen and lymph follicles in the parenchymal organs. The dendritic cells have poor phagocytic activity, but they have surface receptors for complement, antibodies and class II histocompatibility antigens. They can



**FIG 5.4** The macrophage engulfs and processes foreign material that enters a bird. The macrophage then activates the immune response by stimulating the propagation of B-cells and T-cells. If a pathogen persists in the macrophage, then a bird's immune system will not be stimulated to destroy the invading pathogen. Such is the case with PBFD virus. The PBFD virus present within the intracytoplasmic inclusion bodies (arrows) in this macrophage is able to persist rather than stimulate an immune response. Nucleus = open arrow.

absorb antibody into their cytoplasmic filaments in such a way that antigens can be trapped. Antigens that are bound to dendritic cells are very powerful immunostimulants that may play a major role in anamnestic response to antigens.

### Immune Modulators

Several immune modulators, including adjuvants and paramunity inducers, function principally at the macrophage level. Adjuvants function in various ways to enhance the immune response to antigens. Many of them, such as aluminum hydroxide or some oils, function only to inhibit the resorption of antigens, causing a prolonged local antigenicity. Adjuvants are usually insoluble and provoke local inflammatory reactions (granulomas). The tissue inflammation (severe inflammation is an undesirable adverse response) increases the number of antibody-producing cells in the affected tissues. These cells then contribute a significant portion of the total antibody produced. Some adjuvants cause increased phagocytosis activity; in particular, Freund's adjuvant can activate the alternative complement pathway, leading to undesirable results. Some adjuvants enhance the "trapping" of lymphocytes in the spleen, ie, lymphocytes are rendered incapable of escaping from the spleen, causing an accumulation of lymphocytes and stimulation of the immune response. The

lymphocytes are released from the spleen approximately seven days later.

Paramunity inducers, especially those consisting of inactivated components from various poxviridae, can stimulate phagocytosis by macrophages and granulocytes, natural killer (NK) cells and, depending on the strain of poxvirus used, the production of  $\tau$ -interferon and the prostaglandins E and A. Complement and interleukins can also be activated. The activation of NK cells seems to be an important factor in the nonspecific defense mechanism, especially against virus infections and virus-induced tumor cells. NK cells destroy target cells by cytotoxicity.<sup>5</sup> They seem to play a distinct role in "genetic" resistance to virus-induced neoplasms. Very recent results show that the avian NK cells are independent of the thymus but have CD3 and CD8 antigens at their surfaces.

Antibiotics, especially some tetracycline preparations, inhibit the immune system to varying degrees. An indirect effect is a transient increase in the serum corticosterone level, which depresses macrophage activity. Direct effects include interference with protein synthesis, phagocytosis and antigen processing. Because of their potential side effects, antibiotics should be used only when absolutely necessary, particularly when treating secondary bacterial infections associated with viral diseases. Antibiotics should not be used prophylactically, but only when specifically indicated.

## Specific Defense

---

---

Nonspecific defense mechanisms function to destroy foreign material the moment it touches or enters the host. Specific defenses have a prophylactic quality in defending the host against ubiquitous microorganisms and recurrent infections. The specific defense mechanism relies mainly on antigen-sensitive cells, B- and T-lymphocytes, to recognize each antigenic epitope (antigenic determinant) and to produce organism-specific antibodies (humoral immune system), or to provoke cell-mediated reactions (cellular immune system). Depending on whether the host has been exposed to the particular antigen before or if it is an initial encounter, specific defense responses to

an antigen may be delayed for two to three or even five to ten days, respectively.

Antigens are the trigger for stimulating the specific defense response. For a substance to be immunogenic, it must be a structurally stable macromolecule and foreign to a host, and it must possess surface structures (epitopes) against which the immune response will be focused. The specific site on an antigen that reacts with antibodies is called an epitope and only comprises a few molecules (10 to 12 amino acids in proteins). Several epitopes may exist in each antigen molecule (approximately one epitope per 5,000 daltons). With such a defined antigenic site, the main portion of foreign macromolecule is nonantigenic, and the immune response of the host is dependent on recognizing defined epitopes as not "self." Individual hosts respond differently to the same epitopes. The type of reaction is mainly controlled by immune response genes, which code for regulatory proteins located on the surface of cells of the immune system. Epitopes may also stimulate a varying response depending on the manner in which the antigen is presented to the lymphocytes. Individual epitopes may induce antibody production, cell-mediated reactions, tolerance or immunosuppression. The immune response that follows natural infection is thus a mixture of responses (ie, polyclonal). Since epitopes are specifically defined and occupy rather small areas on an antigen, an antibody produced against one antigenic site may react with an epitope on another totally unrelated antigen. This cross-reaction between totally different antigens can create diagnostic problems in some serologic tests. It has been experimentally suggested that approximately ten million epitopes exist that can stimulate an immune response.

In addition to macromolecules, small molecules (called haptens) that are linked to a carrier may also provoke an immune response. Haptens of particular interest to the clinician are small, metabolized molecules of drugs, which may bind to serum (or other) proteins. These molecules are recognized as foreign and often induce hypersensitivity responses. Classical examples of hapten-induced reactions in mammals are reactions to penicillins and cephalosporins. Hypersensitivity responses appear to be less common in birds but have been linked to some antimicrobial sulfonamides. Responses to hapten-carrier molecules indicate that production of antibodies to epitopes of the haptens is possibly independent of the carrier molecule itself. Nevertheless, cell-mediated response may be initiated against the hapten-carrier as such, and is therefore called "carrier-specific." The latter

point is of practical importance, since binding of hap-  
pens to carriers is a common occurrence *in vivo*.

## ■ Humoral System

### Immunoglobulins

The primary function of the humoral immune system is the production of antibodies directed mainly against extracellular phases of antigens. Antibodies are immunoglobulins, with the major part of the molecule containing ligands for membrane receptors, complement activation and isotype-specific (antigenically unique) structures. Immunoglobins can be differentiated into isotypes (IgM, IgG, IgA and, in mammals, also IgD and IgE). No subclasses of any of the isotypes has currently been demonstrated in birds. In ducks and some geese, the predominant immunoglobulin is called IgN, a 5.7 S protein molecule that does not fix complement (which occurs in some fishes, turtles, marsupials and rabbits). Although the other avian isotypes are not the same as those in mammals, they do share the same functions and are termed similarly.<sup>1</sup> However, there are some biochemical differences between mammalian and avian immunoglobulin. Avian immunoglobulins aggregate in a 8% NaCl solution. This is in contrast to mammalian immunoglobulin, which will aggregate in a 0.8% NaCl solution. Although chicken complement is fixed by immune complexes, it is not affected by complement from the guinea pig. This means that the routine complement fixation test cannot be carried out in many avian species.

- **IgG:** (synonym IgY because of its structural and weight difference from mammalian IgG) is the most common antibody in the serum, and due to its small size (7 S), it can penetrate into tissue spaces and across body surfaces. IgG can opsonize, agglutinate and precipitate antigen.
- **IgM:** is the major isotype produced following the initial contact with an antigen. Because of its size (19 S), IgM is normally confined to the peripheral bloodstream and is more active than IgG in opsonization, agglutination, virus neutralization and complement activation.
- **IgA:** exists in both monomeric and polymeric forms and when coupled with a secretory component, is excreted onto the mucosal surfaces of the respiratory, genitourinary and digestive tracts. In the chicken, IgA also occurs in the bloodstream and in pigeons, this immunoglobulin is found in high concentrations in the crop milk.<sup>7</sup> IgA does not activate the comple-



**FIG 5.5** Neonatal birds depend on IgG absorbed with the yolk to protect them from environmental pathogens until they become immunocompetent. In some cases, improper hatching will prevent the egg-yolk from being absorbed and it must be surgically removed. Neonates that do not properly absorb the yolk sac are considered to be immunologically naive and are more susceptible to infectious disease.

ment cascade, nor can it act as an opsonin. It can agglutinate particulate antigens and neutralize viruses. Its major task is to prevent antigens from adhering to the mucosal surfaces of the body.

### Antibody Production

Although antibody production is the main feature of the humoral defense system, the concentrations of IgM and IgG in the serum are generally not indicators of immunity. As a rule, birds with high antibody titers against a certain infection are better protected than those with a low titer. However, there are many exceptions to this generality, particularly with respect to antibodies directed against bacteria. In many instances, an effective response requires the interaction of antibodies and components of the cell-mediated immune system. The fate of the antibody-antigen complex is either phagocytosis (binding to macrophages on the Fc fragment of the antibody) or lysis with the aid of the complement cascade. In the case of phagocytosis, the immunoglobulins can be recycled by virtue of the noncovalent complex bonds.

The humoral immune system requires time to respond to a pathogen and the respective lymphocytes responsible for humoral immunity do not migrate


into the secondary lymphatic organs (where they mature) until around the time of hatching. The newborn chick is, therefore, ill prepared to respond to all environmental antigens. For compensation, the newly hatched chicks receive maternally derived antibodies (IgG) transmitted via the yolk (Figure 5.5). The type and quantity of antibodies that the chick receives depend on the immunologic status of the hen. Vaccination (plus a booster) of the breeder hens with the appropriate antigens is carried out four to six weeks prior to the beginning of egg production in order to ensure significant levels of IgG in the yolk. The antibodies are absorbed from the yolk by the third day of life, and their purpose is to help protect the chick before it achieves immunological maturity around 20 to 25 days of age. The half-life of the maternally transmitted antibodies is four to six days. Neonates from hens vaccinated against PBFV virus were found to have HI antibody titers that decreased 20 to 45 days post-hatching, suggesting maternal antibodies may have a longer half-life in psittacine chicks.<sup>16</sup>

Maternal antibodies may present an obstacle to early vaccination programs by neutralizing the vaccinal antigen and, at the same time, depleting the chick's natural protection. Early vaccination successfully inhibits the production of immunoglobulins.<sup>15</sup> It is also known that IgM and IgA secreted by the oviduct diffuse from the albumen into the amniotic fluid where they are swallowed by the embryo, thus coating the surface of the intestine with a protective covering of these immunoglobulins.

### Lymphocyte Activity

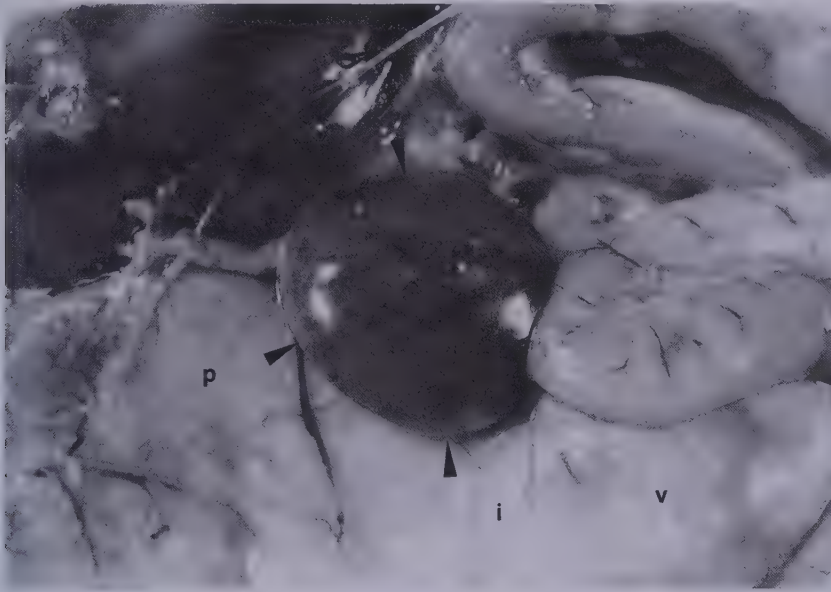
The cellular basis of humoral immunity is the B-lymphocyte, which is the antigen-sensitive cell. Precursor cells colonize and develop in the cloacal bursa during embryonic life. In chickens, the bursal microenvironment is established from the fourth day of incubation onward as a special outgrowth of the cloacal epithelium. The bursa is thought to attract lymphoid precursor cells through the secretion of bursin (and maybe other mediators from the bursal epithelial cells). The first antigen that is localized on B-lymphocytes is the histocompatibility complex class II antigen, followed by cells with surface IgM. Unlike in mammals, no pre-B-cells with intracytoplasmic  $\mu$ -chains have been described in chickens.<sup>12</sup> Between the 14th and 16th days of incubation, the first IgG- and IgA-carrying B-cells can be demonstrated within the bursa (Figure 5.6).

Around hatching time, the mature B-lymphocytes migrate in large numbers from the bursa into the secondary lymphatic organs (spleen, cecal tonsils, Peyer's patches, Meckel's diverticulum, lymph follicles in the various organs, paraocular and paranasal lymphatic tissue where they start to function. Here the Harderian gland is particularly important, and parts of the cloacal bursa, which act as a secondary lymphatic organ. There are some indications for the existence of extrabursal sites of B-cell differentiation (suggested to be gut-associated lymph tissue, Harderian gland, and bone marrow). Around hatching, the Harderian gland has already accumulated actively secreting plasma cells within the interstitial space prior to antigen exposure. By this point in



**FIG 5.6** a) The cloacal bursa is the site of B-lymphocyte differentiation and growth (arrows). The bursa is large in neonates (as in this five-week-old Umbrella Cockatoo) and decreases in size as the bird matures. b) The hollow bursa is located in the dorsal wall of the cloaca to which it connects (arrows). The bursa functions as an immunologic organ by taking up particulate matter from the cloaca and stimulating an immune response to the organisms that pass through the cloaca.





**FIG 5.7** Splenomegaly (arrows) is a common finding in birds. The proventriculus (p), isthmus (i) and ventriculus (v) are also noted.

development, neither hormonal treatment nor surgical bursectomy can suppress the infiltration of these plasma cells.

It has also been suggested that mediator-secreting cells migrate from the bursa into the germinal centers of the spleen and the cecal tonsils (probably also into other secondary lymphatic tissues that are capable of forming germinal centers) to monitor the microenvironment (Figure 5.7). It is also assumed that ellipsoid and ellipsoid-associated cells are derived from the mediator-secreting cells. Further studies, particularly of the spleen, have shown that the penicilliform capillaries possess stomata that allow particulate antigen (probably soluble antigen as well) to enter the ellipsoid cells, which are surrounded by ellipsoid-associated cells and dendritic cells. The latter bind the antigen to their surfaces and migrate to the appropriate T- or B-cell-dependent regions of the periarteriolar sheath. In birds, the cloacal bursa is colonized by developing B-lymphocytes until four to six weeks of age. Subsequently, those lymphocyte clones spread to populate the peripheral lymphatic organs. These lymphocyte cells are capable of restoring humoral immunity in the long term, but only as long as the various kinds of "reticular" cells representing the ellipsoid and ellipsoid-associated cells are intact.

The binding of antigen to the membrane of a B-cell stimulates proliferation of the cellular clones and


ends in the differentiation of two functional cell populations: plasma cells and memory cells. The proliferation of B-cells is rigorously controlled and occurs only if certain additional factors are present: 1) The antigen has to be presented fixed to the surface of certain cells, mainly macrophages (which secrete IL-1 and possess class II histocompatibility antigens); 2) T-helper cells must also respond to the same antigen and secrete soluble mediators.

The T-helper cells bind to the same macrophage (but not necessarily to the same epitope) as the B-cell. However, the T-cell binds not only with the antigen, but in combination with a class II histocompatibility antigen. The T-cell then secretes two proteins: the B-cell growth factor (IL-4) and IL-2. IL-2 binds to the IL-2 receptors

(produced under the influence of IL-1) on the B-cell, where it stimulates DNA synthesis and division. The B-cell differentiation factor (IL-5) secreted by T-helper cells regulates the switch of isotypes. This cascade results in two cell subpopulations: plasma cells and structurally unchanged memory cells, although the latter have switched their isotypes, mainly to IgG.

Plasma cells differentiate from B-cells to form a series of intermediates until they attain their typical morphology (eccentric wheel-like nucleus and copious cytoplasm). The specificity of the immunoglobulin is the same as in the B-parent cell. Plasma cells can produce up to 2,000 Ig molecules per second, and these antibodies are normally secreted by reverse pinocytosis. Plasma cells survive for only three to six days due to gradual catabolism of the immunoglobulins.

In order to maintain high serum immunoglobulin levels, it is necessary to expose a bird to a second dose of antigen to achieve a so-called booster effect. The memory cells, which survive for many months or even years (perhaps not strictly as individuals, but as clones), are stimulated by the proper antigen, inducing the production of more antigen-sensitive cells. The resulting immunoglobulin production is both faster and more vigorous than the initial response. The booster effect, the duration of antigenic exposure, the half-life of the serum antibodies and the expected age of an individual or flock dictate the



**FIG 5.8** The thymus is the site of differentiation and development of T-lymphocytes. In neonates, the thymus is present bilaterally with seven lobes each at the lateral sides of the neck (arrows).

intervals of vaccination and revaccination that are necessary to achieve a desired level of individual and flock immunity.

### ■ Function of the Cell-mediated System

The cell-mediated system is essential for protection against viruses, virus-infected cells, intracellular bacteria, foreign tissue grafts, parasites, fungi and some tumor cells. Thymus-derived lymphocytes (T-cells) also mediate the inflammatory response known as delayed hypersensitivity. T-cells form the basis of the cell-mediated system, but in contrast to the uniform B-cells, T-cells form many subgroups including:

- effector cells, which produce lymphokines provoking cytotoxicity
- helper cells, which produce lymphokines

- suppressor cells, which inhibit the responses of other B- or T-cells.

During development, avian T-lymphocytes differentiate and mature in the microenvironment of the thymus (Figure 5.8). At least part of the microenvironment may be provided by nurse cells. The thymus also functions as a gland in secreting several mediators that participate in the T-lymphocyte maturation process.

T-cell subpopulations are characterized by the expression of surface molecules, designated CD1 to CD11, and by the T-cell antigen receptor TRC.<sup>2</sup>

CD4 and CD8 molecules are associative recognition structures for the major histocompatibility complex (MHC) class II and class I molecules, respectively. Antigens have to be presented in association with these MHC molecules for them to be recognized by T-cells. All T-cells express the CD3 molecule, which is noncovalently associated with the T-cell receptor and which represents a signal-transducing structure.

As in a B-cell response, three mutually interacting cells are necessary for a cell-mediated immune reaction to occur: the antigen-presenting macrophage, the effector cell (carrying the CD8 antigen) and the CD4 helper cell. The epitope must be closely linked to the class I histocompatibility antigen in order for the effector cell to be able to recognize the antigen. Once an antigen is recognized, the helper cell secretes IL-2, causing T-cell proliferation and leading to the production of both effector and memory cells. The effector cells, somewhat larger than the parent cell and with an activated metabolism, are capable of performing various functions. They can secrete several lymphokines, or they can cause direct toxic reactions on contact with foreign or modified cells.

In addition to the cells listed above, vascular endothelial cells, keratinocytes, and cutaneous Langerhans cells have also been found to be capable of presenting antigen. They can take up antigen and synthesize IL-1 under the influence of interferon, and express the class II histocompatibility antigen. Langerhans cells play an especially important role in the development of skin allergies, delayed hypersensitivity reactions, and allergic contact dermatitis.

Lymphokines produced by effector cells can be divided into several groups:

- regulatory factors, such as IL-2, IL-3,  $\tau$ -interferon, IL-4, IL-5.

- inflammatory mediators that increase vascular permeability.
- macrophage activity modulators, such as migration inhibitory factor, leukocyte inhibitory factor, and macrophage fusion factor for inducing giant cell formation.
- cytotoxic factors, such as lymphotoxins, tumor necrosis factor, perforins,
- fibroblast stimulation factor.

### ■ Immune Tolerance

Tolerance is defined as a host's failure to respond to produce reactions against a specific antigen. The most important example of tolerance is the absence of antibodies against normal body components. Tolerance to self-antigens is established during embryonal life. The mechanism is not quite clear, but it may depend on the immature condition of the antigen-sensitive cells at the time of their first encounter with antigens. The same matured cell type is later fully responsive to antigens that it encounters for the first time. An embryo may develop tolerance to viruses or some bacteria that are egg-transmitted.

Tolerance in adults can be facilitated by administering either high doses of antigens (particularly polysaccharides) or very low doses of antigen, by giving antigen in the absence of antigen-presenting cells or by applying antigen that is free of aggregations.

The development of tolerance also implies a rigorous control mechanism to maintain balance between the various components of the defense system in order to avoid depressed immune reactivity (ie, increased susceptibility to infection and spontaneous tumors) or excessive immune reactivity (which results in autoantibodies, amyloidosis, lymphoid tumors and allergies). Immune response regulation is a complex mechanism.<sup>8,13</sup> Principally it can be divided into:

- genetic control by immune response genes located at the major histocompatibility complex B (which means that reactivity to antigens can be subject to genetic selection by a breeder),
- activity of T-suppressor cells bearing the CD8 antigen,
- control of B- or T-cell metabolism by insulin and/or prostaglandins and by adjusting the ratio of cyclic adenosine monophosphate and guanosine monophosphate,
- regulation by the amount and structure of the antigen,

- regulation by antibody or antigen-antibody complexes via a feedback mechanism.

## Disturbance of the Defense System

Both the nonspecific and the specific defense systems can be impaired at almost any site. Depending on whether a stimulatory or suppressing portion of the system is damaged, impairment can result in either deficiency or exaggeration of the system. In addition to the aforementioned immunosuppression caused by antibiotics, certain mycotoxins and many tumors, particularly the virus-induced tumors, can decrease the efficiency of the defense system.<sup>15</sup> A variety of viruses (Newcastle disease virus, several herpesviruses, adenovirus and reovirus) are known to inhibit the immune system. This inhibition is often at the level of the T-cells, resulting in a bird that is prone to secondary infections. Other viruses, such as PBFV virus and polyomavirus that frequently cause degeneration or necrosis in lymphatic organs are almost certainly also immunosuppressive.

Genetic defects of the immune system in birds are infrequently reported, possibly because of insufficient information concerning the immune system of birds. In chickens, hypo- or dysgammaglobulinemia have been described; in obese strain chickens, the first step in the cascade of events appears to be a dysfunction of immune regulation.

### ■ Autoimmunity

Autoimmune antibodies are directed against self-antigens. At a very low level they can be considered as normal, but in higher concentrations they may cause disease. Autoimmune diseases have rarely been reported in birds. This may be a result of our inability to recognize autoimmune disease rather than a resistance to autoimmune problems. The obese strain chickens produce antibodies against thyroid cells, thus causing hypofunction and thyroiditis.

### ■ Hypersensitivity

An excessive immunologic reaction can cause a type of inflammation called hypersensitivity. Four differ-

ent types of hypersensitivity reactions have been described in mammals. Type I, the mechanism of which is not fully clear, occurs rarely in birds, because birds do not have IgE, which is essential for the reaction in mammals. Nevertheless, birds have large numbers of mast cells in their lymphatic tissues, particularly in the thymus. The latter does not always become completely involuted in avian species.

Type I = immediate hypersensitivity. IgE isotypes can attach to mast cells (= basophils) by their Fc fragment. If antigen is fixed to such a cell-bound antibody, the basophil releases vasoactive substances (including histamine), which causes a local inflammation within minutes.

Type II = cytotoxic hypersensitivity. The destruction of cells can be carried out either by antibodies activating complement or by cytotoxic cells. Heterophils, macrophages and some lymphocytes have receptors for Fc immunoglobulin fragments and may, therefore, lyse target cells that are coated with immune complexes. Both forms of lysis release many biologically active products from the doomed cells, causing inflammation as is also seen in graft rejection.

Type III = immune complex hypersensitivity. Immune complexes are able to activate complement, even in tissues. The C5a component, which leads to vasoactive anaphylatoxins, is also a potent heterophil attractor. As these heterophils try to digest the immune complexes, they release proteolytic enzymes, thus causing tissue damage. This triggers a vicious circle: heterophil-activated plasmin activates the complement system, which causes aggregation of thrombocytes and the release of more vasoactive factors, while mast cell degranulation may be caused by anaphylatoxin. The end result is inflammation and tissue destruction. The Arthus phenomenon and immunogenic glomerulonephritis are common examples.

Type IV = delayed hypersensitivity. This reaction is caused by cell-mediated immune responses occurring at least 24 hours after antigen contact with sensitized T-cells. The local inflammatory response is caused by vasoactive lymphokines and substances released by mast cells. This type of reaction is caused by various bacterial antigens and virus-infected cells.

## Immune Complex Reactions

Chronic lesions caused by immune complexes can occur in the form of amyloidosis. In ducks, geese and swans, reactive amyloidosis is quite frequently associated with chronic suppurative disease processes. Although amyloids differ in their composition, the amyloid proteins share the common feature of having polypeptide chains arranged in  $\beta$ -pleated sheets. This uniquely stable molecular configuration renders the fibers virtually insoluble and almost completely resistant to proteolysis. As a consequence, amyloid is deposited in tissues and cannot be eliminated, resulting in a loss of parenchymal cells and tissue destruction.

Avian defense mechanisms are rather complex, and many of the intricacies of the systems have not been defined for poultry, much less for pet or aviary birds. Understanding the avian immune system is further complicated because of the involvement of hormonal and nutritional factors. Since antibodies and several of the mediators are proteins, deficiencies in essential amino acids may cause immunosuppression. Some of the vitamins, in particular vitamins A and C, influence both the epithelial nonspecific defense and the interaction between the humoral and nonspecific systems.<sup>12</sup> Of the trace elements, zinc is essential for one of the mediators in the thymus. Therefore, a well-balanced diet free of immunosuppressive mycotoxins is essential for birds that are to be capable of adapting satisfactorily to their environment with its multitude of infectious agents.

## References and Suggested Reading

- Benedict AA, et al: Special features of avian immunoglobulins. *In* Toivanen, Toivanen: Avian Immunology: Basis and Practice Vol I. Boca Raton, CRC Press Inc, 1987, pp 114-121.
- Chen CH, et al: Identification of cell surface molecules on chicken lymphocytes with monoclonal antibodies. *In* Toivanen, Toivanen: Avian Immunology: Basis and Practice Vol I. Boca Raton, CRC Press Inc, 1987, pp 138-148.
- Cihak J, et al: Characterization and functional properties of a novel monoclonal antibody which identifies a T-cell receptor in chickens. *Eur J Immunol* 18: 533-537, 1988.
- Eerola E, et al: Special features in the structural organization of the avian lymphoid system. *In* Toivanen, Toivanen: Avian Immunology: Basis and Practice Vol I. Boca Raton, CRC Press Inc, 1987, pp 10-17.
- Fahey KJ, et al: Cytotoxic activity of avian lymphoid cells. *In* Toivanen, Toivanen: Avian Immunology: Basis and Practice Vol I. Boca Raton, CRC Press Inc, 1987, pp 185-187.
- Fedde R: Structure and function of the avian respiratory system. Applications of basic principles to practical problems. *Proc 40th West Poult Dis Conf. Acapulco, Mexico 1991* pp 86-89.
- Greuel R: Untersuchungen zum parenteralen Immunglobulintransfer bei der Taube (*Columba livia*, Gmel), 1789, domestica. *Vet Diss, München*, 1988.
- Hraba T: Immune tolerance. *In* Toivanen, Toivanen: Avian Immunology: Basis and Practice Vol II. Boca Raton, CRC Press Inc, 1987 pp 14-19.
- Maxwell MH: The avian eosinophil: A review. *WPSJ* 43:190-207, 1987.
- Meyer W et al: Der "S" ureschutzmantel der Hautäunserer Haustiere. *Dtsch tierärztl Wschr* 98:167-170, 1991.
- Pardue SL, et al: Interaction of ascorbic acid and cortisol on humoral immunity in broilers. *Poultry Sci* 60:7, 1981.
- Ratcliffe MJH: The ontogeny and cloning of B cells in the bursa of Fabricius. *Immunol Today* 6:223-227, 1985.
- Reynaud C-A, et al: The chicken immune system: A minimum gene model. *In* Toivanen, Toivanen: Avian Immunology: Basis and Practice Vol I. Boca Raton, CRC Press Inc, 1987 pp 102-109.
- Ritchie BW: Antibody response to and maternal antibodies from an experimental psittacine beak and feather disease virus vaccine. *Am J Vet Res* 53:1512-1518, 1992.
- Tyzard I: *Veterinary Immunology: An Introduction* 3rd ed. Philadelphia, WB Saunders Co, 1987.
- Zschesche W, et al: Pathology of the animal amyloidosis. *Pharmac Ther* 41:49-83, 1989.

**T**raditional methods of detecting infectious disease agents have relied on recovering the inciting organisms from tissue samples, excretions or secretions, or indirect demonstration that an organism has been present in the body through the detection of a host immune response (principally antibody production).

All of these detection systems have inherent problems. Techniques that detect the presence of an organism (eg, electron microscopy, antigen ELISA, antigen immunodiffusion assays and histopathology) are either non-specific, relatively insensitive or both.

Many microbes cannot be propagated *in vitro* and are present in low numbers in secretions or excretions, making their antemortem detection difficult. *In vitro* propagation may require weeks, reducing the clinical value of the information obtained.

Documenting an infection through the host's production of antibodies requires a functional immune system. Additionally, paired serum samples collected two weeks apart must be tested to demonstrate a four-fold increase in antibody titer. The accurate detection of an infection, based on an acute and convalescent serum sample, is effective for documenting active infections, but the information is obtained too late to influence disease management. Determination of antibody titers may also be ineffective in detecting subclinical carriers, latently infected animals or slow infections.

Nucleic acid amplification and detection technologies will continue to improve and will compensate for many of the problems associated with other diagnostic techniques. Every clinician should have a rudimentary understanding of the methodologies, applications and problems associated with these test systems. Nucleic acid probe technology is currently being used to detect microorganisms, determine gender and detect genetic abnormalities.

CHAPTER

---

6

**FUTURE  
PREVENTIVE  
MEDICINE**

■  
**Branson W. Ritchie**

## Overview of DNA and RNA

The ability to selectively amplify and detect nucleic acid from pathogens is based on the fact that unique sequences of DNA or RNA are present in all living organisms. As a review, DNA is a polymer made of four units (bases): adenine (A), guanine (G), cytosine (C) and thymidine (T). RNA is a polymer made of four bases: adenine, guanine, cytosine and uracil (U). In the cell, the replication of DNA or RNA is catalyzed by specific enzymes (polymerases). Specifically derived heat-stable polymerases can be used *in vitro* to reproduce nucleic acid.

DNA generally exists in a double-stranded form (some viruses have single-stranded DNA or RNA). When double-stranded DNA is heated, the individual strands will separate (melt) from each other. When the strands are allowed to cool, the individual strands will rebind (reanneal) to their complementary strand of DNA, so that adenine from one strand binds to thymidine on the other strand, and cytosine on one strand binds to guanine on the other strand (Table 6.1).

If two single strands of DNA (for example, a synthetically produced DNA probe and a target sequence of pathogen DNA) bind together, the process is called hybridization (Figure 6.1). This hybridization process

is the basis of using pathogen-specific DNA sequences (probes) to detect the presence of an organism's nucleic acid in samples collected from a host.

## DNA Probe Technology

### Use of DNA Probes

The ideal diagnostic test would provide maximum sensitivity (no false negatives), specificity (no false positives) and rapid results. Advances in the understanding of molecular biology have led to the development of techniques that allow for the amplification (increasing quantities) and detection of organism-specific nucleic acid sequences. These test systems are based on the use of organism-specific DNA probes, and this new generation of tests most completely meets the requirements of an ideal method of detecting and identifying an organism (Figure 6.2).

The sensitivity and specificity of nucleic acid probe technology, the speed of obtaining results and the fact that the process can be used to detect organisms that will not replicate *in vitro*, may ultimately lead to nucleic acid probes replacing culture techniques as the gold standard in detecting pathogens.

With some microorganisms, DNA probes may be useful in detecting active as well as subclinical infections. The identification of subclinically infected animals requires that the reservoir site for the infectious agent be identified, and that samples be collected from the appropriate site at the correct stage of the infection. Depending on the organism and the host, these reservoir sites may be blood cells, hepatocytes, enterocytes, neurons or possibly any cell within the body. Samples that might be effective in detecting subclinical carriers could then include whole blood, liver biopsies or excrement (Figure 6.3).

Given the correct conditions, synthesized DNA probes will bind to specific, complementary target DNA (in a diagnostic test this is pathogen DNA), and the hybridization that occurs can be detected by using a number of visual indicator systems (eg, color change systems, radiographic sensitive systems).

An oligonucleotide DNA probe is a short sequence of nucleotide bases that is designed to detect a complementary strand of nucleic acid in a diagnostic sample

TABLE 6.1 Complementary Binding of DNA and RNA Bases

For DNA	For RNA
A is complementary (binds to) T	A is complementary (binds to) U
C is complementary (binds to) G	C is complementary (binds to) G

If two strands of single-stranded DNA with the complimentary sequences;

Single strand 1 = 3' TACGGACCTTACG 5'

Single strand 2 = 5' ATGCTTGAATGC 3'

are mixed together under the correct conditions they will bind together (hybridize) to form a double-stranded molecule.

Double stranded = 3' TACGGACCTTACG 5'

5' ATGCTTGAATGC 3'

If two strands of single-stranded DNA that do not have complimentary sequences;

Single strand 1 = 3' TACGGACCTTACG 5'


Single strand 2 = 5' ATGTTAAGCGGC 3'

they will not bind together (hybridize) and will remain as two single stranded molecules

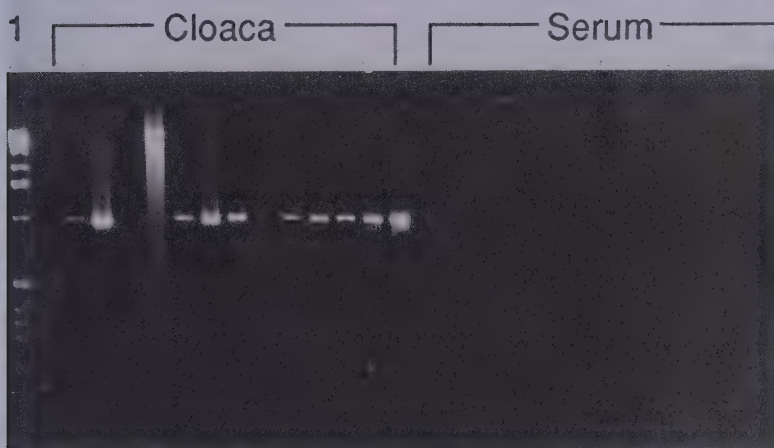
Single strand 1 = 3' TACGGACCTTACG 5'

Single strand 2 = 5' ATGTTAAGGATGC 3'

FIG 6.1 DNA hybridization process.



**FIG 6.2** The 96-well format is used to test for the presence of PBFD virus nucleic acid in birds' white blood cells using viral-specific DNA probes. Each black dot represents a positive test (courtesy of Avian Research Associates).



**FIG 6.3** For a DNA probe to be effective in detecting a subclinical infection in a bird, it is necessary to know where the pathogen is located in the body so that the correct sample can be collected and tested. In this case, viral-specific DNA probes were used to compare cloacal swabs and serum for detecting the presence of polyomavirus. Lane 1 is a control. The white bands present in the cloacal swab samples indicate the presence of polyomavirus nucleic acid. The absence of bands in the serum samples indicates that polyomavirus nucleic acid could not be detected in the serum of birds that were shedding polyomavirus.

(eg, tissue, sputum, blood, feces). For a DNA probe to be specific, it must be developed from a known genomic sequence of the organism in question. A probe designed from unknown sequence can create errors in interpretation.

For example, if a specific portion of the polyomavirus genome had bases arranged in the order:

5'...GGTACGTAACCTAAGGCCAATTCGGCCTCGG...3',

a DNA probe with the sequence

3' - TGAATTCGGTTAAGC - 5'

would be complementary to this sequence and would bind (hybridize) when the two nucleic acid strands were incubated in the proper conditions. This probe could be used to detect the presence of this specific polyomavirus genome sequence in infected liver tissue, saliva, urine or in a contaminated environment (if the nucleic acid from the virus were present in the sample).

Once a probe has bound to a target DNA molecule, the probe must be able to be detected. This detection can be accomplished by incorporating labels (eg, P<sup>32</sup>, S<sup>35</sup>, I<sup>125</sup>, alkaline phosphatase, digoxigenin, horseradish peroxidase) into the probe. Most commercial probes use alkaline phosphatase, digoxigenin, or horseradish peroxidase to avoid the management problems associated with radioactive isotopes.

For example, if a labelled DNA probe with the sequence

5' - AATCCGG - 3' Dig  
(a digoxigenin labelled probe for mycobacteria)

was mixed into a processed sample containing the mycobacterial nucleic acid sequence

.... 3' - GACGTATTAAGGCCTAGCAT.... 5'

then the probe would bind (hybridize) to the target sequence. Bound digoxigenin (on the probe) could then be detected by means of a routine series of reaction steps.

If on the other hand, the DNA probe was mixed into a processed sample that contained *E. coli* genome with the sequence

5' ... AGTAGCCTTAGGAC... 3'

and no mycobacterial nucleic acid sequence (target) then the probe with attached digoxigenin would not bind and would be washed away.

These examples illustrate that the key to a DNA probe detection system is to identify a pathogen-specific nucleic acid sequence and to synthesize nucleic

acid probes to bind specifically to this sequence. The specific nature of the probe prevents cross-reactions with other pathogens, imparts specificity and reduces false-negative results.

### ■ Specificity of Nucleic Acid Probes

Nucleic acid probes can be designed to be so specific that they can differentiate between two related organisms that are antigenically similar (induce production of similar antibodies) but have differences in nucleic acid sequence that alter the pathogenicity of the organism. As a hypothetical example, two adenoviruses that are antigenically similar could occur in a bird population. Because they are antigenically similar, these adenoviruses would be difficult to differentiate using an antibody-based diagnostic test. Clinical evidence suggests that in some cases, these adenoviruses are highly pathogenic with high levels of mortality, while in other cases, infected birds develop an immune response and remain subclinical.

By determining the DNA sequence of virus recovered from different birds, it might be discovered that the virus that causes high mortality has a different nucleic acid sequence than the virus that induces a subclinical infection. This difference might be:

5' ...ATTGCCATGGAATCCGATT... 3'  
for the pathogenic strain and

5' ...ATTGTTAGGCTAGCCGATT...3'  
for the nonpathogenic strain.

A DNA probe with the sequence

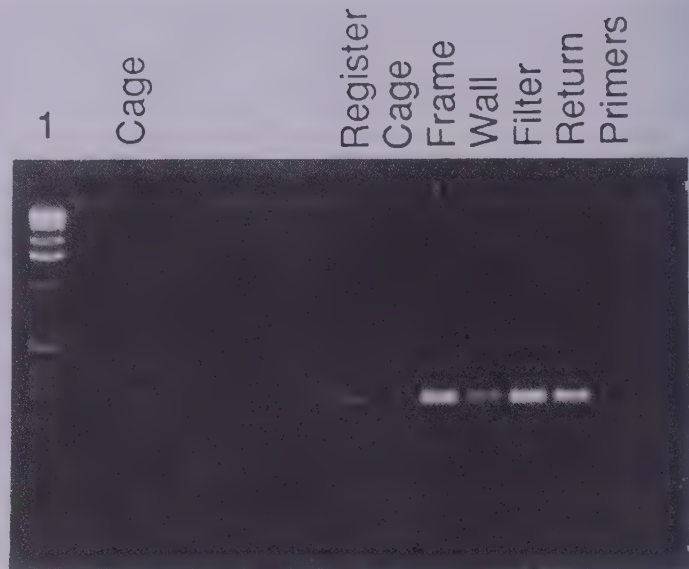
3'- AATCCGATC -5'

could then be used to specifically detect the non-pathogenic strain. A probe with the sequence

3'- GGTACCTTA -5'

could be used to detect the pathogenic strain.

From a diagnostic perspective, probes are extremely valuable because they can be developed for pathogens so that they are genera-, species- or strain-specific, depending on which portion of a nucleic acid sequence they are designed to detect. For example, a probe could be developed that would detect any *E. coli* or only an *E. coli* that had a unique biochemical function. In the following example three strains of *E. coli* exist: one is highly virulent, one is considered



**FIG 6.4** Pathogen-specific DNA probes can be used to determine if an area is contaminated with nucleic acid from an organism. Lane 1 is a control. The white bands indicate environmental samples that contain PBFV virus nucleic acid. In this case, the home of a client that had a bird with PBFV virus was screened for environmental contamination by the virus. Before cleaning, the enclosure was positive for PBFV virus nucleic acid (lane 3). After cleaning, the enclosure was negative for PBFV virus nucleic acid (lane 9); however, the registers, returns and filter associated with the heating system, as well as the wall and a picture frame in the room where the bird was housed were positive for PBFV virus nucleic acid.

normal flora in an animal and one is considered an environmental contaminant. The three strains have the nucleic acid sequences:

5'... GCTATGCTTAGGCCCTTA...3' virulent strain

5'... GCTATGCTTGCCGATAA...3' normal strain

5'... GCTATGCTTGATCGGTA...3' environmental strain.

An oligonucleotide probe with the sequence

3' CGATACGAA 5'

would detect all three of the *E. coli* organisms because it is designed to be complementary (and will hybridize) to a conserved sequence that is common to all three strains of *E. coli*. A probe with the sequence

3' CTAGCCA 5'

would detect only the strain of *E. coli* considered an environmental contaminant because this sequence is unique to that strain of bacteria (Figure 6.4).

Once a probe has been developed, it can be used to detect nucleic acid that is extracted from a sample and attached to a membrane, or it can be used to detect pathogen-specific nucleic acid in a section of paraffin-embedded, formalin-fixed tissue that has been processed for histopathologic evaluation (*in situ* hybridization).



*In situ* hybridization using pathogen-specific nucleic acid probes is particularly effective when a pathogen is present in relatively small numbers or produces a lesion that histologically resembles that induced by other pathogens. For example, the intranuclear inclusion bodies caused by polyomavirus can appear morphologically similar to the intranuclear inclusion bodies caused by PBFV virus or adenovirus (see Color 32). *In situ* hybridization using viral-specific DNA probes can quickly and correctly determine which of these viruses induced the identified inclusion bodies. When compared to antibody staining techniques for the identification of pathogens in tissues, nucleic acid probes are more specific and more sensitive than other pathogen detection techniques. They also detect organisms that may have been antigenically altered during processing.

In addition to confirming the presence of a pathogen in tissue, *in situ* hybridization can also be used to detect the type of cell infected and whether the pathogen's nucleic acid is present in the cytoplasm or nucleus of the host cell. This last finding is of particular importance in understanding the replication scheme of many viruses, which can be critical for understanding how infections can be treated or prevented.

### ■ Sensitivity of Nucleic Acid Probes

In infected tissues where high numbers of the organism are present, the use of DNA probes to detect the presence of an organism's nucleic acid is fairly straightforward. In contrast, detection of a pathogen in excretions or secretions where numbers of the organism may be small requires further processing. To increase the likelihood of finding an organism in a diagnostic specimen (increased sensitivity), a sample to be tested is often subjected to a group of reactions that will amplify (increase) the number of pathogen DNA molecules in the sample, thus improving the ability of the probe to detect the organism.

The most commonly employed technique for amplifying target nucleic acid is the polymerase chain reaction (PCR) (Table 6.2). Theoretically, when used in combination with pathogen-specific nucleic acid primers, PCR can use one copy of a nucleic acid sequence to produce 1,000,000 copies. The most important component of this process is the pathogen-specific oligonucleotide primers. It is these oligonucleotide primers that allow the process to preferentially increase the number of pathogen nucleic acid molecules without increasing the number of

all other contaminating nucleic acid molecules that would be present in a sample.

**TABLE 6.2 PCR Amplification of Nucleic Acid**

PCR amplification involves three phases:

- 1) separating (denaturing) ds DNA to create ss DNA
- 2) binding (annealing) pathogen-specific primers to the ss DNA target (pathogen) nucleic acid
- 3) synthesizing new strands of target (pathogen) nucleic acid

For example, a fecal sample collected for polyomavirus testing might contain 10 polyomavirus particles, 300 *E. coli*, 10,000 *Staphylococcus* spp., 150 host-derived WBCs (nucleated and containing DNA), 50 host-derived RBCs (also nucleated in birds and containing DNA) and 300 *Candida* spp. It would not be possible to detect only ten copies of the target (polyomavirus) DNA. By using primers designed specifically for the polyomavirus nucleic acid, the amount of target sequence (portion of polyomavirus DNA to be detected) can be increased from 10 copies to 10,000,000 copies, while the contaminating DNA from the *E. coli*, staphylococcus, WBCs, RBCs and candida remain the same and become dilutionally unimportant. The 10,000,000 synthesized copies constitute a quantity that can be easily detected.

A PCR cycle involves heating the target DNA (from the pathogen in a sample) to cause ds DNA to become ss DNA, thus exposing the target sequence on the pathogen's DNA to the oligonucleotide primers, where they can anneal to prime the generation of new sequence. The temperature of the reaction is then adjusted so that an enzyme (DNA polymerase) will synthesize a new strand of nucleic acid starting from one end (3') of the primer. At a specified time (determined for each pathogen-specific set of primers), the reaction is heated to stop the DNA polymerase and separate the created ds DNA into new target ss DNA.

This process is cyclic and is usually performed 40 times. The synthesized strands of ss DNA serve as new templates for the reaction, and each cycle results in an exponential increase in molecules (ie, one molecule makes two, two molecules make four, four molecules make eight).

From a simplified perspective, the two most critical components for the amplification and detection of nucleic acid from an organism are the pathogen-specific nucleic acid primers used to increase the sensitivity of the test (increases the likelihood of detecting only a few of the organisms) and the pathogen-spe-

cific nucleic acid probes used to ensure the specificity of the test (ensures the amplified sequence is that of the target organism).

### ■ Sample Collection

Minimal contamination of a diagnostic sample can be a problem with the amplification step that is used to increase the sensitivity of the test. A knowledgeable clinician can minimize contamination by practicing sound techniques in collecting any samples for DNA probe testing. The same degree of care must be exercised when collecting samples for bacterial culture. For example, if a clinician were testing a bird to determine the presence of PBFD virus in the blood, and the blood sample was collected from a toenail, a positive result may indicate the presence of PBFD virus either in the blood or on the bird's toenail. Washing the bird's nail before collection would not be expected to reduce the potential for contaminating the sample. A blood sample properly collected into a sterile syringe by venipuncture would be less likely to result in a contaminated sample.

## Vaccines

### ■ Conventional Vaccines

Modified live, killed or subunit vaccines are currently available for use in protecting animals from various infectious diseases. The function of a modified live vaccine is to produce an infection (thus inciting an immune response) without producing disease. Modified live vaccines have inherent risks including possible reversion to a virulent form or an attenuation that alters the antigenicity of the vaccine strain to such a degree that it is not protective against a field strain of a virus. Modified live vaccines may be virulent in animals that are immunosuppressed, may be immunosuppressive themselves, may cause a low level of morbidity that affects reproduction and must be handled with care to prevent inactivation.

Killed vaccines are produced by growing a pathogen *in vitro* and then inactivating it to prevent replication in the vaccinate. These vaccines require exposing the vaccinate to a large dose of antigen and frequently require the addition of harsh adjuvants that can cause unacceptable tissue reactions in the vaccinate.

### ■ Subunit Vaccines

To develop a subunit vaccine, the protein from a pathogen that induces a protective immunologic response in the host must be identified. The nucleic acid sequence (gene) that codes for this protein is then inserted (cloned) into a plasmid of an *E. coli* or other organism, which then produces the desired protein. The immunologic protein is then purified away from the producing organism and can be used as a vaccine. Subunit vaccines allow proteins that would protect an animal against different serotypes to be included in the same mixture.

Subunit vaccines represent only the portion of the viral protein that is responsible for eliciting an immune response and are completely safe because the vaccinate is not exposed to the nucleic acid of the pathogen (prevents replication of the organism in the vaccinate). This prevents potential problems associated with the conversion of attenuated vaccine strains of a virus into a virulent strain. It also eliminates the possibility that a vaccinate may be exposed to a virus that has not been killed.

Several subunit proteins from the same organism can be combined in a vaccine to increase the immunologic response (as is seen with a natural infection) without the risk of inducing disease. In the development of subunit vaccines, it may be advantageous to combine several proteins from the same pathogen in order to stimulate both virus-neutralizing and T-cell immune responses. Subunit vaccines also create the possibility for incorporating several proteins from numerous pathogens into one vaccine.

### ■ Other Vaccines

Many pathogenic bacteria have been found to have capsular polysaccharides that function as virulence factors and elicit immune responses. For some human pathogens, these capsular polysaccharides have been purified and conjugated to proteins, which elicit immunologic responses and protect the host from the target bacterium. A better understanding of the interaction between bacteria and the host immune system may lead to methods to prevent rather than treat bacterial infections. A similar increase in the knowledge concerning the host immunologic response to parasites will be necessary before parasitic infections can be prevented through vaccination.

## Adjuvants

The oil-emulsion adjuvants that are commonly used in mammalian vaccines have been shown to cause severe muscle necrosis in some species of birds (see Figure 32.8). One method of preventing these reactions is to use solid-matrix-antibody-antigen complexes in place of adjuvants. These complexes have been shown to be particularly effective in augmenting the immunologic response induced with subunit vaccines, and are being investigated for use in birds.

Liposomes have shown promise as carriers for immunogenic proteins that can be used for vaccination or immunotherapy. Injected liposomes are rapidly consumed by mononuclear phagocytes, particularly circulating macrophages.<sup>5</sup> In theory, any antigens present in these phagocytized liposomes would be processed and stimulate an immune response.

## Antimicrobial Therapy

Conventional antimicrobial therapy depends on using chemotherapeutic agents that selectively interfere with metabolic processes that are unique to bacteria, parasites or fungi, while having little or no effect on the metabolism of the host cell. While this is generally effective for bacteria, parasites and fungi, it is ineffective for most viruses and tumor cells, which use the host cell metabolic pathways for energy production and replication. Antiviral agents are generally designed to prevent uncoating of a virus particle, and thus stop a virus from replicating.

Liposomes have been shown to be effective in transporting agents with immunologic activity against antigen-expressing tumors into the affected cells. For treating cancer, this type of immunotherapy would be far superior to chemotherapeutic methods currently used, because immunotherapy could be targeted specifically for the cancer-producing cells with no effects on normal cells within the affected host. Liposomes can also carry chemical compounds such as muramyl-tripeptide-phosphatidylethanolamine, which increase macrophage activity.<sup>4</sup>

Monoclonal antibodies have been used as a therapeutic agent for some types of cancers with antigen presenting capabilities. By binding cytotoxic agents to the monoclonal antibodies, high concentrations of

therapeutic agents are delivered directly to the affected cells to which the antibodies bind.<sup>1</sup>

## Antisense RNA Therapy

In the process of replicating DNA, the cell produces a complementary copy of the DNA in the form of a messenger RNA. This mRNA is then used as a copy to make new DNA molecules. In the 1960's, a concept was developed of inhibiting the replication of DNA by introducing a nucleic acid sequence that would bind to the mRNA and prevent its use as a template for replication. This was termed antisense RNA therapy.

When fully implemented, antisense RNA therapy will revolutionize the way that neoplastic and viral diseases are treated. By binding specifically to mRNA, the antisense RNA would inhibit the replication of cancer cells or viruses, while having no adverse affect on unaffected host cells. Thus, antisense RNA would represent a safe, cell-specific therapy.

As a simplified example, the replication of a DNA virus may involve the initial nucleic acid sequence

5' ATGCGGCCTTACCATGCAT...3'

The mRNA template for this sequence (in RNA, uracil is found in place of thymidine) would be

3' UACGCCGGAUUGGUACUGUA...5'

If the antisense RNA sequence

5' - ATGCGGCCTT - 3'

was introduced to the infected cell, it could bind to the mRNA sequence and prevent it from serving as a template for viral replication.

To be clinically applicable in the treatment of viral and neoplastic diseases, antisense RNA technology must advance to the point where therapeutic nucleic acid sequences can be introduced to the body in such a way that they enter an affected cell, and subsequently interfere with replication of a virus or neoplastic cell. The use of antisense RNA therapy is likely to evolve into a useful therapeutic regimen over the coming decade.

## References and Suggested Reading

1. Byers VS, Baldwin RW: Therapeutic strategies with monoclonal antibodies and immunocjugates. *Immunology* 65:329-335, 1988.
2. Chernesky MA: An evolutionary change in diagnostic virology. *Yale J Bio Med* 62:89-92, 1989. (or 1984?)
3. Crumpacker CS: Molecular targets of antiviral therapy. *New Eng J Med* 321: 163-169, 1989.
4. Ho RJY, Burke RL, Merigun TC: Antigen-presenting liposomes are effective in treatment of recurrent herpes simplex virus genitalis in guinea pigs. *J Virol* 63: 2951-2958 (9 or 4?), 1989.
5. Post G, Kirsh R, Thomas K: The challenge of liposome targeting *in vivo*. In, G. G regoridis (ed) *Liposome technology*. CRC Press, Boca Raton, 1985, pp. 1-28.
6. Robbins JB, Schneerson: Polysaccharide-protein conjugates: A new generation of vaccines. *J Int Dis* 161: 821-832, 1990.
7. Wolcott, MJ: Advances in nucleic acid-based detection methods. *Clin Micro Rev* 5:370-386, 1992.

## CHAPTERS

- 7 PRACTICE DYNAMICS**  
Cathy A. Johnson-Delaney
- 8 MAKING DISTINCTIONS  
IN THE PHYSICAL EXAMINATION**  
Greg J. Harrison  
Branson W. Ritchie
- 9 HEMATOLOGY**  
Terry W. Campbell
- 10 CYTOLOGY**  
Terry W. Campbell
- 11 BIOCHEMISTRIES**  
Manfred Hochleithner
- 12 IMAGING TECHNIQUES**  
Marjorie C. McMillan
- 13 ENDOSCOPIC EXAMINATION AND  
BIOPSY TECHNIQUES**  
Michael Taylor
- 14 NECROPSY EXAMINATION**  
Kenneth S. Latimer  
Pauline M. Rakich

II

---

---

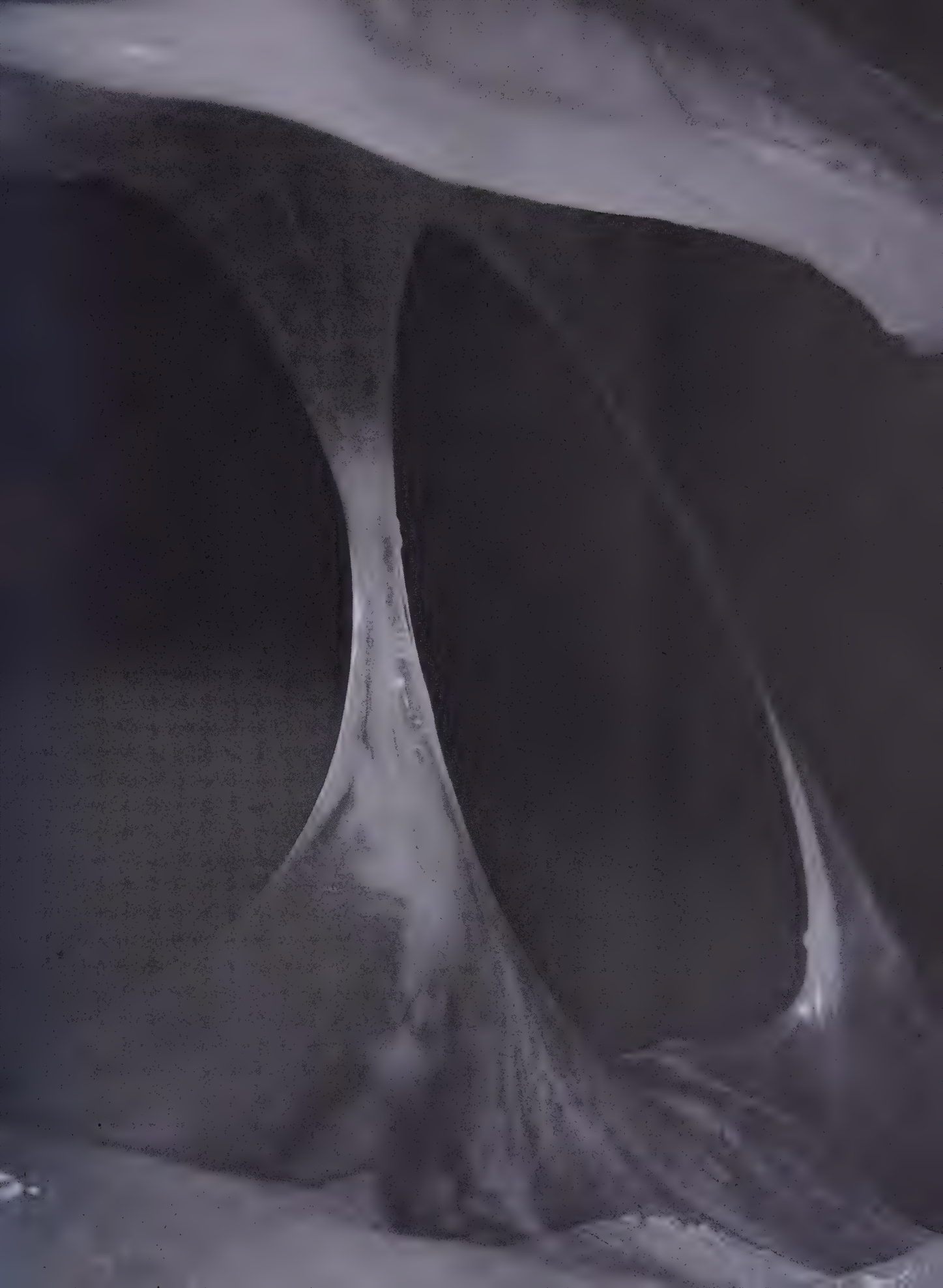
## SECTION TWO

# PATIENT EVALUATION

---

---

II





**F**or veterinarians with a strong interest in treating companion birds, the advantages of incorporating avian medicine into the small animal practice are numerous. With only minimal equipment additions and some intense continuing education with the desire to learn, the practitioner can increase patient diversity and practice volume and be introduced to the challenge of avian diagnostics and therapeutics.

Membership in the Association of Avian Veterinarians (AAV) and participation in conferences with carefully planned avian programs are necessary to keep abreast of the rapidly expanding information on the diseases and treatment of companion birds. The *Journal of the Association of Avian Veterinarians* and other journals and textbooks as well as popular bird magazines are essential reading for serious practitioners (Figure 7.1).

Within the extensive network of the AAV, there are many experienced members who are willing to share information and advice. Veterinarians with limited experience in treating birds should be realistic about their expertise and be ready to refer complicated cases that require advanced diagnostic, surgical or therapeutic techniques. A veterinarian may advertise a special interest in birds, but use of the word “specialist” is reserved for only those who are board certified in avian practice.

Attending aviculture seminars, visiting established avian practices and teaching bird handling skills to staff and colleagues are other good ways for beginning avian veterinarians to increase competence. Avian veterinarians in one city improved the care available to local avian patients by providing a training program and procedure manual for emergency clinicians in the area.<sup>17</sup>

---

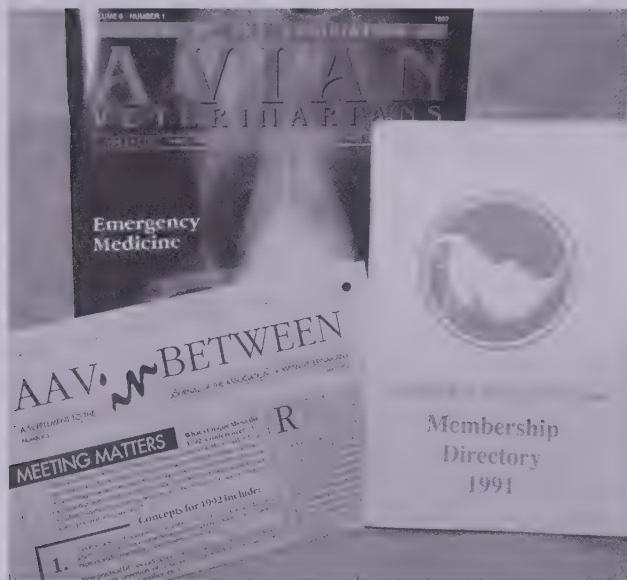
CHAPTER

7

PRACTICE  
DYNAMICS

---

Cathy Johnson-Delaney



**FIG 7.1** Membership in the Association of Avian Veterinarians is suggested for any veterinarian planning to work with birds. Reading the information published in the Journal and the Proceedings of the Annual Conferences is essential to stay abreast of rapidly evolving information (courtesy of Cathy Johnson-Delaney).

## Getting Started

There are many effective ways to attract avian clients, including adding birds to the logo on signs, stationery and business cards, placing avian magazines and client information in reception and exam areas, and decorating the clinic in an avian motif. Display of the AAV membership plaque, certificates presented by bird clubs and other organizations and newspaper clippings or articles help demonstrate a clinic's commitment to companion bird medicine (Figure 7.2).

Client education displays should include publications available from the AAV, diet manufacturers and other practitioners, as well as specific information sheets on such topics as diet, disease, husbandry, grooming and training. Some clinics find that establishing a library is well received by clients. Videotapes for in-clinic viewing can be made available and may include commercial tapes addressing avian management or training, as well as short demonstrations of wing and nail trimming, handling, restraint and treatment techniques. Videotaped "Nature" or "National Geographic" episodes dealing with birds or

conservation are instructive, entertaining and create an opportunity for the avian veterinarian to discuss the importance of habitat preservation and sound avian stewardship.

The sale of formulated diets, nutritional supplements and avian care accessories (hemostatic agents, grooming aids, carriers), helps to demonstrate the clinic's dedication to the total well-being of companion birds. Alternatively, local pet retailers may be informed of a veterinarian's recommendations for diets and other avian products, and clients may be referred to those shops whose policies and products meet with established standards (Figure 7.3).

Advertising in the yellow pages or other local business listings and supplying pet supply retailers with business cards and client education materials are also effective practice builders. Training sessions for pet store employees and clients create an opportunity for the veterinary staff to address specific questions and to stress the importance of preventive health programs. Establishing a post-purchase examination program that is paid for by the pet supplier will reinforce the reputation of a dealer for selling healthy birds and provide the veterinarian with an increased client base. Most pet shops and breeders appreciate veterinary surveillance of not only their birds, but also of their facility design (eg, quarantine and traffic flow), diets and use of disinfectants.

Avian veterinarians should establish a program for visiting aviaries or multiple-bird households to perform preventive health screenings and aviary management evaluation (see Chapter 2). Problems associated with diet or husbandry can be more easily determined in the birds' home environment than from descriptions provided during office visits. Fees for aviary management consultations, multiple-bird examinations and large-volume laboratory work should accurately reflect the time involved in collecting and interpreting samples, yet not be cost-prohibitive to the client.

Avian veterinarians also benefit from membership in local avian, exotic animal and wildlife organizations. Participating in the activities of bird clubs (meetings, newsletters, bird fairs) and volunteering to speak at school career days, civic groups and scout meetings are other excellent ways to achieve visibility and credibility with companion bird clients.

Many practitioners provide instructional sessions to acquaint new bird clients with their pets. One successful program is called "parrot kindergarten."<sup>16</sup>






**FIG 7.2** Providing an avian library, decorating in an avian motif and providing client information handouts and displaying professional awards or scientific publications (right) are all effective methods of keeping clients informed and communicating a hospital's interest in avian care (courtesy of Cathy Johnson-Delaney).

Sessions are conducted by a veterinarian, an aviculturist and a bird trainer to provide experienced insight into avian health care, management and psychological stimulation.

It is important for the beginning practitioner to become acquainted with local people who can serve as additional sources of information for individuals who keep birds. These people may include experienced aviculturists who are willing to share knowledge, “foster parents” who will temporarily take unwanted birds, zoo aviary keepers, experienced ornithologists, librarians and the curators of natural history museums.

Finally, it is easiest to build a referral practice by assuring local veterinarians that their clients' birds will be seen, but that their other pets will not. It is a good idea to send the referring veterinarian a “Thank you for the referral” card and a written synopsis of the diagnostic and treatment plan. It is especially important to maintain good communication with the referring veterinarian if a client lives in another area and the referring veterinarian will need to evaluate the effect of therapy or to provide further medications. Treatment and follow-up visits should be done locally whenever possible.



### Staff Responsibilities

Staff members play a major role in the success of any practice. They should be familiar with the clinic's general recommendations on diets, husbandry and preventive health care. Developing an office manual that includes job descriptions, client instructions, hospital protocol and general data on various species of birds will serve as a reference text for the entire staff. Veterinary assistants should be expected to keep the hospital clean, maintain a patient's food and water supply, fill prescriptions and perform routine procedures such as restraining, medicating and grooming birds. All staff members should be encouraged to have their own companion birds in order to better relate to the clients and their birds. It is critical that staff members' and clinic birds be screened for infectious diseases to prevent them from serving as a source of infection for clients' birds. Assistants should also be encouraged to attend continuing education seminars.



**FIG 7.3** Some veterinarians maintain a select group of avian diets and safe toys while others refer clients to pet supply retailers that meet established standards. Videotapes can be used in the reception area to teach clients how to better care for their pets. Client information brochures are available in the waiting room and in the examination room (courtesy of Cathy Johnson-Delaney).

### Communicating with the Client

When a client calls for an appointment, the receptionist must instruct the client on the proper way to transport the bird to the clinic so that an evaluation of enclosure management and diet can be made. The water dish should be emptied before transport, but enclosure substrates should not be changed so that droppings from the past several days can be evaluated. The client should also be instructed to collect several fresh fecal samples at home by placing plastic wrap under the perch. The samples should be folded in the plastic and refrigerated until transport to the clinic. A paper towel placed over the enclosure substrate will help identify fresh droppings produced during the trip to the hospital. The client should also bring previous medical records, samples of the normal diet and samples of any abnormal discharges.

If the bird is showing signs of illness, the client should be instructed to warm the enclosure interior to 85-90°F and to cover it in such a way that this


temperature may be maintained on the way to the hospital. Loose layers of plastic wrap under the regular enclosure cover may be helpful. If the ambient temperature is less than 60-75°F, it is recommended that the car be pre-warmed as well. Likewise, if ambient temperature exceeds 90°F, care must be taken to prevent hyperthermia.

A bird brought into the hospital on its owner's arm is an accident waiting to happen (Figure 7.4). Therefore, it should be hospital policy that all animals be maintained in an enclosure while in the reception area. If it is not possible to bring a bird's enclosure, a small animal carrier can be modified with the addition of a perch.

It is helpful for the staff to introduce themselves to new clients and to tell them what to expect during the office visit. The receptionist should give instructions for filling out the information forms. The technician should weigh the bird, discuss husbandry with clients and assist with restraint during the examination. At many clinics, a client can make an appointment with the veterinary technician for routine grooming procedures such as wing clips, weight monitoring and beak and nail trims.

An initial hospital visit will require extra time for filling out paperwork and providing a client with instructions concerning proper husbandry. Detailed information about the diet and home environment are crucial in evaluating the avian patient, as malnutrition and improper management are common causes of medical problems. The technician should take a Polaroid snapshot of the client and bird for the bird's medical record. The client should be provided a folder-type health record with a pocket to maintain receipts and examination certificates. This folder will serve as a reminder that birds need the same kind of routine preventive medical care as other pets.

For most psittacine birds, semi-annual examinations are recommended with emphasis on detecting sub-clinical problems (see Chapter 8). Many practices give the new client a "New Bird Kit" on the initial visit. This kit can include the health examination folder, client education materials, a hemostatic agent, a telephone sticker with the phone numbers of the clinic and recommended emergency clinic, samples of recommended avian foods and subscription information to bird magazines. Many clinics have customized bags with the clinic name, address, phone number and logo, as well as a space provided for the



**FIG 7.4** To prevent serious injuries to avian patients, the hospital policy should be that all birds are maintained in an enclosure while in the hospital. Additionally, birds being transported from one area of the hospital to another should be placed back in an enclosure to prevent accidental releases and injuries (right) (courtesy of Cathy Johnson-Delaney).

bird's name. This helps emphasize the clinic's commitment to personalized attention for each patient.

### Record Keeping

The medical record system used in most small animal clinics can be modified for avian patients. A problem-oriented checklist works well for avian cases. A copy of the initial history and examination form should be included in the folder sent home with the client. A certificate of veterinary examination is usually necessary when performing post-purchase examinations for aviaries or pet shops. Two copies should be made so that one remains in the clinic records and the other goes with the client.

The computerized record systems used in many small animal practices can be easily adapted for avian patients, including modifying reminder forms to list avian procedures. Diagnostic software packages for the avian patient are under development.

Another proven way to maintain a positive client relationship is by communicating with them through the use of "Welcome to the practice" cards, sympathy cards and clinic evaluation forms.

From the initial examination and identification of potential problems with diet and husbandry to daily assessment of a hospitalized bird's condition, communication with the client is essential. If a bird must be hospitalized, the client should be given a written estimate of the medical plan and costs, and a hospital consent form should be signed. The higher cost of

avian services as compared to those for dogs and cats reflects the increased amount of time avian patients require, as well as the increased training and expertise required by the veterinary staff.

### Hospitalization Protocol

Clients apprehensive about hospitalizing their birds may feel more at ease if they are introduced to the staff members who will be caring for the bird and shown where their bird will be housed. To avoid disturbing other patients, a videotape of the facility may be used. Sometimes it is enough to explain how the enclosure is set up and what enrichments are provided such as heat, light, music and visibility of humans. Visitation policies may vary on a case-by-case basis. A patient that is highly bonded

to its family and becomes depressed when separated (beyond its illness) may greatly benefit from regular visitation. The client may also be able to entice a reluctant patient to eat. On the other hand, if the bird has a contagious disease or is recovering from a serious injury or surgical procedure, the excitement and activity associated with a visit may be contraindicated. In any case, clients should be encouraged to call during specified times to receive updates on the condition of their pets.

Before a bird is discharged from the hospital, the technician should instruct the client on how to administer medications and provide the recommended care, including provisions for keeping the bird warm on the way home. It is usually advisable that written home care instructions, the hospital bill and the recheck appointment be discussed prior to reuniting the bird and the client to prevent the client from being distracted by the pet.

A phone call the day after discharge allows the veterinarian to evaluate the patient's condition and gives the client an opportunity to ask questions. A client evaluation form mailed several days following a visit may help reveal the client's perspective of the clinic's strengths and weaknesses. The survey should be short and include multiple choice questions and space for written comments regarding clinic facilities, staff, telephone courtesies, pricing and medical treatment. A return envelope will encourage client participation.

## Travel Considerations

---

Occasionally clients will request health certificates in order to transport birds between states or countries. Most airlines are now refusing to transport wild-caught birds, and many domestic carriers are refusing to ship companion birds on the grounds that it is difficult to differentiate between domestically raised and imported birds. Airlines that will ship companion birds within the United States will specify the type of carrier they will accept and the conditions of release from liability that must be authorized. According to aircraft manufacturers and airline engineers, temperature ranges in the cargo bins, which are designated for carriage of animals, vary from 40°F to approximately 70°F, depending upon the aircraft type used by the transporting airline. Newer-generation jets (eg, 757s) generally have warmer temperatures in the cargo bins and therefore are more comfortable for animals.

Carrier specifications for international shipment are set by the International Air Transport Association, and many airlines use these standards for domestic flights as well. It is advisable to be familiar with these carrier specifications and to contact the state veterinarian regarding what is considered a properly completed health certificate for a companion bird. Use of the term "health certificate" should be discouraged because it is impossible to determine from a physical examination if a bird is healthy. A complete evaluation requires extensive laboratory work and radiology, and even then it may be impossible to determine if the bird is latently infected with an infectious agent. Use of a "Certificate of Veterinary Inspection" to accompany the state regulatory form may be appropriate. An evaluation does not guarantee that a bird will remain healthy following transportation.

If a client plans to take a bird traveling by car, it is recommended that the bird first be given a full examination to detect subtle problems that might manifest during the stress of traveling. When possible, it is advantageous to place the bird in a familiar enclosure for travel. An adequate food supply should be carried, as not all diets are available in all areas. Clients should also consider weather, potential hazards (eg, animals, children) in homes or campgrounds where they will be staying, policies of hotels and motels, and if the disruption in daily routine will adversely affect the bird. For some birds, it is less stressful to be left at home or boarded. A brochure entitled "Traveling with Your Pet" is available from

the ASPCA Education Dept., 441 East 92nd St., New York, NY 10128.

Birds that are boarded at a veterinary clinic must be kept isolated (different air space with different caretakers) from ill birds as well as from other boarding birds from different households. Clinics with limited space may board birds from a single household at one time. Establishing a bird-sitting service using clinic staff or outside individuals works well and decreases the risk of exposing birds to infectious agents. If bird-sitters visit more than one household a day, they must take precautions to prevent disease transfer between homes.

## Accommodating the Avian Patient

---

---

In order to transform a traditional small animal clinic into an "avian friendly" clinic, a number of modifications should be considered. A separate avian waiting room would be ideal, but if that is not possible, an area that is not in direct contact with dogs, cats and children should be designated for bulky bird enclosures and carriers.

Furnishings for the avian practice should be comfortable, durable, washable and easily disinfected. Reception and exam room chairs should be of varnished, metallic or plastic finishes. The removable canvas backs and seats of director's-style chairs can be easily washed and disinfected and come in many colors and fabric designs.

## Safety Considerations

---

The areas of the hospital where birds will be handled outside of their enclosures should be bird-proofed, and appropriate nets for catching birds should be available. Ceiling fans are not recommended for avian hospitals. Wall fans, radiators, baseboard heaters, light fixtures and other electrical equipment must be shielded from direct contact. Open windows should be securely screened and be covered with blinds or draperies. Open shelves, bottles and jars may be viewed as perches by free-flying, frightened birds. Waste baskets should be placed in cabinets or

have fitted lids, cold sterile instrument trays should be covered, and counter tops should be kept clean.

Equipment in the exam room, including a gram scale, an auxiliary light source, a magnifying head loop, speculums, towels or restraint cloths, oxygen, heating pad, lamp and diagnostic and first-aid equipment should all be within easy reach. Furniture should be minimal, including chairs for the clients, sufficient table surfaces for enclosure security and a stool for the practitioner. Areas with minimal furniture are more secure and easier to keep clean.

### Housing

Appropriate enclosures for avian patients must also be considered. A separate avian housing area that can be maintained at 80-85°F is preferable, but not essential. Birds may be housed in aquariums with screened covers, intensive care units or converted small animal enclosures. Aquariums are relatively inexpensive and easy to clean and disinfect. Screen-covered tops provide good ventilation, while the aquariums themselves hold heat and reduce hospital contamination from discarded food and droppings. They also offer complete visibility and easy access to the patient. Heating pads placed under or along one side of the aquarium can raise the interior ambient temperature to 85-90°F. Surgical drapes or clean towels can be used to cover portions of the aquarium to retain additional heat and allow the bird a more private convalescent area. A five-gallon aquarium works well for small birds, a ten-gallon size for medium-sized birds and a twenty-gallon size for larger birds.

Commercial and custom-designed aquariums heated with warm water make excellent housing units for sick birds. Some hospitals use avian isolation units, complete with separate heat and ventilation.

Existing small animal kennels can be converted by installing a removable perch and lining the enclosure with brown wrapping paper or butcher paper. Newspaper print may stain the feathers of white birds. Heating pads or clamp-lamps provide supplemental heat, and towels, plastic wrap, acrylic or plexiglass sheets can be placed over the front of the enclosure to retain heat (Figure 7.5). Enclosure doors should be removed, scrubbed and soaked in disinfectant after each bird. Spraying a light coat of Pam cooking oil or silicone on the bars will facilitate the removal of excrement.

Avian enclosures should be easily viewed from across the room or through a window to minimize the need to approach the enclosure to evaluate a patient. The staff member who feeds, cleans and interacts with the bird should not be the same person who provides “threatening” medical treatment. The bird is less likely to be defensive around a non-threatening person, and a more accurate assessment of changes in its daily condition can be made.

### Preventing the Spread of Disease

Many avian pathogens can be spread through aerosol and feather particulates, and an efficient ventilation system of laminar flow design will minimize hospital contamination. As fresh air enters one side of the room, it passes across the examination area and is pulled outside by exhaust fans with vents placed approximately two feet above floor level in the opposite wall from the fresh air vent. Air filtration systems (purifiers) designed to decrease particulates and pathogens to the 0.1-1.0 micron range are recommended for use in the reception, examination, treatment and housing areas. The maintenance requirements and volume of air exchanged vary with each system. These units reduce aerosolized hair, dander, feathers, dust and contagions that would otherwise accumulate in the environment. In initially designing a hospital, areas with separate air flow systems should be incorporated to allow for the separation of patients that require routine care from those that may have infectious diseases. Hospital suites for housing sick birds should be divided into small, easily cleaned areas that also have separate air flow systems.



**FIG 7.5** A small animal hospital enclosure can be easily modified to house avian patients. Plastic curtain rod holders are glued to the sides of the enclosure to hold removable perches. Hard plastic containers are used for food and water, and the bottom of the enclosure is covered with butcher wrap (newspaper ink may stain some feathers) (courtesy of Cathy Johnson-Delaney).

All equipment used on avian patients should be thoroughly disinfected between patients. It should be stressed that all disinfectants are toxic and must be handled with care to prevent problems in hospital premises or patients. No disinfectant can work effectively in the presence of organic material (see Chapter 2). Food and water dishes, feeding devices, perches and other enclosure accessories should be free of food and excrement prior to being soaked for 30 minutes in a phenol or quaternary ammonia disinfectant. Disinfected items should then be put through an automatic dishwasher (hot water cycle), rinsed thoroughly and dried before re-use. Disinfected supplies should be stored in closed cabinets or containers away from areas where they may be exposed to aerosols and particulates from ill patients. Quaternary ammonia solutions (quats) are satisfactory for use as table washes or in cold sterilization trays, and can be used to clean enclosures and soak capture nets, dishes, perches and grooming tools. Because these solutions may be nephrotoxic to birds, equipment must be thoroughly rinsed after being soaked in quaternary ammonia compounds. Quats are the disinfectants of choice against chlamydia and have a wide range of effectiveness against many other pathogenic bacteria and viruses. A phenol-type disinfectant is recommended by the United States Department of Agriculture (USDA) for use in quarantine stations and other avian facilities. It has activity against the Newcastle disease virus and many other pathogens. Phenols may be used for cleaning enclosures and other equipment, but because they are irritating to skin, rubber gloves should be worn, and enclosures and instruments must be thoroughly rinsed prior to direct contact with birds.

Chlorhexidine has the advantage of being gentle to tissues and equipment and is effective against viruses and candida, but it is not effective against chlamydia and many other pathogenic bacteria. It can be used in some cases in the drinking water or as a wound or sinus irrigation solution or in liquid diets and hand-feeding formulas. Other types of disinfectants useful in the avian practice are isopropyl alcohol for cleaning surfaces and instruments; iodophores such as povidone iodine solutions (hand soaps, scrubs and wound irrigations) and chlorine bleach for cleaning non-metal surfaces, equipment and utensils. Good ventilation is important when using any disinfectant, and surfaces must be thoroughly rinsed and dried before coming in contact with birds.



Floors in the avian hospital should be vacuumed frequently to prevent the accumulation of feathers, dander and foodstuffs. Because vacuum cleaners, electric brooms and small portable cleaners tend to scatter viruses into the air, it is advisable to spray the bags prior to, during and after use with a disinfectant. In vacuums that do not use bags, the intake pieces, brush attachment and collection chambers must be disinfected thoroughly after each use. The exteriors of such appliances, as well as the exhaust vents, need to be kept clean and disinfected as well.

The order in which hospitalized avian patients should be maintained follows the same pattern as that for working with other animals: clean, feed and treat beginning with the healthiest and ending with the most highly contagious and critically ill. Any bird within the hospital that is sick for an unconfirmed reason should be considered highly contagious until proven otherwise. When working with a patient with a highly infectious disease, it is advisable for the attendant to wear a mask and hospital gown that can be changed. Attendants should also use a disinfectant spray on their clothing and hair between birds. Hospital counters, shelves and tables should be wiped down with disinfectants after each use.

### ■ Equipment

The specialized equipment needed to practice avian medicine is minimal. Many small animal practices already have isoflurane anesthesia (mandatory for avian practice), ophthalmic-sized surgical instruments and suture materials, an endoscope, a radio-surgery unit and radiographic equipment. Additional equipment acquisitions should include a high quality gram scale (Figures 7.6, 7.7), avian mouth speculums, gavage needles and a radiographic positioner. Bandaging and splinting supplies, protective collars and dental acrylics for orthopedics and beak repair are also necessary.

Other equipment required for an avian practice includes heavy ceramic bowls and a variety of perches that can be easily cleaned and disinfected (Figure 7.8). It is important that hospital perches be made of non-porous material such as heavy plastic or epoxy/resin composites. Perches of porous material (eg, wood) should be disposed of after use. Household fixtures (eg, towel racks, curtain rods, shower rods) and PVC pipe are good choices for perches (Figure 7.9).



### Diagnostic Equipment

Equipment necessary for basic in-house avian diagnostic tests includes a binocular microscope with oil immersion capability (1000x), hematocrit centrifuge, refractometer, hemacytometer, bacteriologic incubator, alcohol lamp or Bunsen burner, and basic laboratory supplies such as staining kits, coverslips, slides, hematocrit tubes, serum separators and culturettes (Figure 7.10).

Several serum chemistry testing systems are commercially available. Dry chemistry analyzers are fast, easy to operate and require very small sample sizes. Those currently used in avian practices are the




**FIG 7.6** An accurate gram scale is mandatory in the avian hospital (top left). Scales can be fitted with perches, or light-weight containers can be used to facilitate weighing (bottom left). Digital units that have an automatic tare feature are easiest and fastest to use (above) (courtesy of Cathy Johnson-Delaney).


Kodak DT60 Analyzer,<sup>a</sup> the VetTest 8008,<sup>b</sup> the Reflotron<sup>c</sup> and the Seralyzer.<sup>d</sup> Both the Kodak and the VetTest units can run a typical avian profile including AST, uric acid, glucose, calcium, total protein and albumin. The Kodak DT60 has the largest test menu and includes a full electrolyte panel. The VetTest includes software that provides some normal avian values and diagnostic information (Figure 7.11). Both machines have proven to be reliable, easy to operate and have demonstrated consistent results when used in avian practice.

“Wet chemistry” analyzers such as the Gemstar II Chemistry System<sup>e</sup> and the Analyst<sup>f</sup> also run tests applicable to avian patients but require larger sample sizes than do the dry chemistry analyzers. These machines have been shown to be reliable and provide good quality results in some clinics; however, the sample size needed may be prohibitive with some avian patients. The major advantage to the wet

chemistry systems is the significantly lower cost per test. Hematology, cytology and microbiology equipment, techniques and supplies are covered in depth in Chapters 9, 10 and 11.



**FIG 7.7** Mouth speculums and feeding tubes (either stainless steel or red-rubber type) are essential pieces of equipment in the avian practice (courtesy Cathy Johnson-Delaney).




**FIG 7.8** Food and water containers used in the hospital should be durable, noncorrosive and easy to disinfect. Stainless steel, hard plastic and crockery bowls work best.

Although many clinics perform in-house diagnostic tests, most find it necessary to use the services of consultants from time to time. Board certified radiologists and histopathologists who have had experience diagnosing avian cases are especially helpful. Commercial clinical pathology laboratories that specialize in avian and exotic patients are indispensable for isolation and identification of avian pathogens that require specialization beyond the capacity of most veterinary hospitals.

### ■ Submitting Samples to an Outside Laboratory

The decision regarding which tests to perform in-house and which to send to other laboratories depends on several factors: speed of desired results, effect of results on therapeutic decisions, staff ability to perform tests accurately and frequently enough for proficiency, the amount of staff time needed to perform a test, equipment sensitivity and suitability for sample volume, cost of equipment, staff training, consultation and trouble shooting. While it is frequently convenient to have results of tests available during the patient's visit or on weekends and holidays, the results have to be accurate and reliable, as well as cost-effective.

Considerations for choosing an outside laboratory include experience in avian diagnostics, types of services and tests available, sensitivity and specificity of the tests offered, policies regarding laboratory supplies and transport media, mailers, billing and invoice policies, direct fees for tests, turnaround time for results being reported and method of reporting (telephone, fax, computer, mail). A laboratory that is reporting sensitive data by fax should require that the clinician sign a release form stating that the fax



**FIG 7.9** PVC pipe can be used to construct low perches that are used for extremely ill birds. This material is easy to clean and disinfect but should not be used for long-term perching (greater than two weeks) to prevent foot and leg problems. The perch can be wrapped with a layer of self-adherent bandage material to improve traction. The bandage material is changed between patients (courtesy Cathy Johnson-Delaney).




is secure to receive confidential information. There are potential legal ramifications of laboratories reporting sensitive information regarding infectious diseases by phone, and high quality laboratories will provide this information only by mail or to a secure fax machine. It is important to become acquainted with laboratory submission and shipment protocol and methods of reporting results. Submitted samples should always be clearly identified and accompanied by a written report indicating the tests requested, a brief history of clinical signs, differential or tentative diagnosis and any medications being used. It is advisable to keep appropriate transport media and shipping containers in the hospital. Sources of dry ice, liquid nitrogen or cold packs should be identified before these products are required. Ideally, all samples submitted should meet the following criteria:

1. Baseline samples should be taken prior to administration of medication. Correct sample collection techniques should be used (free-flowing blood not nail clip for blood work).
2. Samples should be collected aseptically from anatomic sites likely to contain pathogens.
3. Samples should be taken during the acute phase of the disease rather than the chronic stage.
4. A relevant synopsis of the disease process or flock outbreak should be included.
5. Any pertinent background information and differential diagnoses should be provided.

Samples submitted for bacteriology, virology, chlamydia isolation or necropsy require special consideration. Direct communication with the laboratory prior to shipment is advisable. If the laboratory does not provide pick-up service, other couriers may be used. Shipments should be planned to arrive early in the day during the week.

Most samples for bacteriologic screening should be kept moist in an appropriate transport medium, refrigerated but not frozen and sent immediately with cold packs. Chlamydia isolation may be more successful if tissues are frozen and shipped with dry ice, rather than refrigerated immediately and then shipped on regular ice. Fecal samples or cloacal swabs in specific chlamydia transport medium may be submitted for antemortem diagnosis. Refrigerants must be sealed in leak-proof plastic bags, and dry ice should be packed to allow for the carbon dioxide to escape after sublimation, without contaminating the samples. Refrigerants should constitute about 50 percent of the weight of the contents of the package. Styrofoam-lined boxes with sturdy cardboard, wood or plastic exteriors are preferred for shipping refrigerated specimens. To comply with legal and medical

responsibilities, specimens should be packed with sufficient material to absorb any leaking fluid as well as to protect the specimen from damage.



**FIG 7.10** A binocular microscope and standard supplies for collecting culture samples should be available in the avian practice (courtesy of Cathy Johnson-Delaney).

## Pharmaceuticals

Very few pharmaceuticals are specifically licensed for use in avian species, but the Federal Drug Administration (FDA) has exercised discretion in enforcing extra-label drug use in companion animals to avoid the adverse impact on animal health that could result if the human drugs were unavailable for veterinary use. Avian practitioners should be aware that the promotion, distribution and use of human drugs in animals results in violation of the Federal Food, Drug and Cosmetic Act when:

1. A drug labeled for human use accompanied by labeling which prescribes, recommends, or suggests a use for animals, for which the product is not generally recognized as safe and effective, is an unsafe new drug under section 512(a) and is adulterated under section 501(a)(5) of the Act.
2. The use or intended use of a human drug in animals by a veterinarian causes such drug to be considered a misbranded drug under section 502(f)(1) of the Act.
3. A drug labeled for human use that is promoted, distributed or otherwise intended for animal use is misbranded under section 502(f)(1) of the Act if

its labeling fails to bear adequate directions for animal use.

4. The use of a human drug in food-producing animals may cause adulteration of the food. If the residue is a human drug, the food is adulterated under section 402(a)(2)(A) of the Act.

Regulatory action has not ordinarily been considered concerning the distribution of human drugs for use in companion or non-food-producing animals provided all of the following conditions exist:

1. Intended animal use of the human drug is not established by labeling, advertising, promotional activity or in any other overt manner.
2. There is no approved veterinary drug version of the human drug available.
3. The human drug does not represent a significant risk to the animal when prescribed, dispensed or administered by a veterinarian.

## Environmental Responsibility

In addition to medical care for individual pets, avian practitioners also have a responsibility to the global avian population because of their importance in the environment. Many of the species maintained as pets are threatened or endangered in the wild because of habitat destruction and capture for the pet trade. Most leading professional, avicultural and conservation-oriented organizations are actively promoting domestically raised, not wild-caught, birds for pets. Throughout the world there are increased legislative efforts to stop or at least control importation of wild-caught birds. The avian practitioner should promote the purchase of domestically raised birds and keep clients informed of conservation efforts.

Occasionally, the avian practitioner must try to determine the origin of a bird for medical purposes. Imported birds that have passed through USDA quarantine stations are banded with a stainless steel band with a code of three letters followed by three numbers. The quarantine system is designed strictly to prevent diseases of importance to the poultry industry from entering the United States. Quarantine procedures for imported birds include a 30-day stay in an approved quarantine facility, screening for Newcastle disease, and a 30-day treatment with



**FIG 7.11** Several types of “dry” and “wet” serum chemistries machines have been shown to be effective in the avian practice. These machines have the advantage of providing rapid, inexpensive test results (courtesy of Cathy Johnson-Delaney).

chlortetracycline for chlamydiosis. Random screening for *Salmonella enteritidis* phage type 4 is being conducted by the USDA to prevent this human pathogen from entering the United States. Quarantine procedures are being reviewed by the USDA, but major changes in the system will require time. Information concerning the importation and quarantine process, USDA regulations, ports of entry and health certificates for shipment of birds out of the country are available from state veterinary offices or regional APHIS/REAC offices. Other regulatory agencies in the United States involved in bird trade are the US Department of the Interior, The Convention on International Trade in Endangered Species (CITES) and the US Department of Treasury — Customs Service, which watches for smuggled birds. The Fish and Wildlife Service is charged with restricting imports and exports of many species of birds which may require special permits if listed in CITES. Information about transporting listed species may be obtained through the US Fish and Wildlife Service, PO Box 3507, Arlington, VA 22203-3507; 703-358-2093.

Avian veterinarians should be able to assist clients in purchasing healthy birds by recommending reputable breeders. Clients should be advised that a tame,

domestically raised bird may initially cost more but will be a better-adjusted, healthier pet and require less medical care and behavioral training than a wild-caught, imported, less-expensive bird of the same species. Clients should be wary of "bargain" birds from the flea market, classified advertisements or garage sales. If a bird is diagnosed with exotic Newcastle disease (VVD) virus and definite proof of proper importation cannot be produced, the bird along with any birds that have been in direct contact may be confiscated, tested and euthanized. Many states also require proof of hatching or legal importation before issuing a license to an aviary or breeding facility. The avian veterinarian should record a bird's band number, tattoo number, microchip number, or any pertinent physical information in the medical record. If the band is removed, the client should keep a copy of this record along with the removed band.

#### Products Mentioned in the Text

- a. Kodak DT60 Analyzer, Eastman Kodak, Rochester, NY
- b. VetTest 8008, IDEXX, Portland, ME
- c. Reflotron, Boehringer-Mannheim, Indianapolis, IN
- d. Seralyzer, Miles, Elkhart, IN
- e. Gemstar II Chemistry System, Schiapparelli Biosystems
- f. Analyst, DuPont, Wilmington, DE

#### References and Suggested Reading

1. **Altman RB:** Establishing an avian practice. *Proc Assoc Avian Vet*, 1990, pp 390-393.
2. **Antelyes J:** Tactics vs. strategy in practice. *J Am Vet Med Assoc* 191(12):1542-1544, 1987.
3. **Antelyes J:** Client hopes, client expectations. *J Am Vet Med Assoc* 1997(12):1596-1597, 1990.
4. **Bauk L:** Client compliance in avian medicine. *Proc Assoc Avian Vet*, 1990, pp 491-493.
5. **Bennett PM, et al:** Development of LYNX: A computer application for disease diagnosis and health monitoring in wild mammals, birds and reptiles. *Vet Rec* 128:496-499, 1991.
6. **Cooper JE:** Veterinary work with non-domesticated pets. *I Brit Vet J* 142(5):411-419, 1986.
7. **Elkins AD, Brackenridge S:** Methods of coping with stress and prevention of burnout in veterinary practice. *Comp Cont Ed No Am Ed Small Animal* 14(2):157-161, 1992.
8. **Fudge AM:** Avian practice tips. *Vet Clin No Amer Sm Anim Prac* 21(6):1121-1134, 1991.
9. **Gallerstein GA, Acker H:** "Mixed" avian/small animal practice management: Some of the critical components. *Proc Assoc Avian Vet*, 1991, pp 66-77.
10. **Garbe JAI:** Wildlife law: The international and federal components. *J Zoo & Wildl Med* 21(2):140-154, 1990.
11. **Harrison GJ, Harrison LR:** Management procedures. In Harrison GJ, Harrison LR (eds): *Clinical Avian Medicine and Surgery*. Philadelphia, WB Saunders Co, 1986, pp 85-100.
12. **IME:** Computers in avian practice. *Assoc Avian Vet Today* 2(4):196-201, 1988.
13. **IME:** Practice tips. *J Assoc Avian Vet* 4(3):152-154, 1990.
14. **IME:** Avian practice management part II. *Assoc Avian Vet Today* 1(1):15-16, 1987.
15. **Ingraham AS:** The chemistry of disinfectants and sterilants. *Contemp Topics - AALAS* 31(2):18-23, 1992.
16. **Jenkins J:** Promoting practice loyalty through an enhanced owner/bird bond. *J Assoc Avian Vet* 6(20):1992.
17. **Johnson-Delaney CA (ed):** Avian Emergency Care: A Manual for Emergency Clinics. Seattle, Assoc of NW Avian Vet, 1991.
18. **Kidd R:** Making the most of your clinical pathology laboratory. *Vet Med Jan:12-20*, 1991.
19. **Lawyer DF:** Disinfection of animal environments. In Kirk RW (ed): *Current Veterinary Therapy X*. Philadelphia, WB Saunders Co, 1989, pp 90-95.
20. **Levine BS:** Avian diagnostics: A guide to caring for caged birds. *Vet Med May:469-481*, 1987.
21. **Lyon K:** Sources of information. *Vet Clin No Amer Sm Anim Prac* 21(6):1111-1120, 1991.
22. **Macwhirter P:** Avian practice in Australia. *Proc Assoc Avian Vet*, 1989, pp 46-56.
23. **Marshall R:** The management of diseases in the pet shop. *Proc Assoc Avian Vet*, 1991, pp 205-223.
24. **McDonald SE:** Avian reference list. Introduction to Avian Medicine and Surgery. *Assoc Avian Vet*, 1991, p R2-1.
25. **Merkel E:** Concurrent small animal/exotic practice: Technician's role. *Proc Assoc Avian Vet*, 1989, pp 454-457.
26. **Mitzner B:** In-house laboratory testing for the avian practice. *J Assoc Avian Vet* 6(2):88-90, 1992.
27. **Nye RJ:** How to select avian equipment, supplies and laboratories for the small animal hospital. Introduction to Avian Medicine and Surgery. *Assoc Avian Vet*, 1991, pp R1-R12.
28. **Roskopf WJ, Woerpel RW:** The role and importance of the avian health technician in today's clinical setting. *Proc Assoc Avian Vet*, 1990, pp 489-490.
29. **Stonebreaker B:** Developing an avicultural practice. *J Assoc Avian Vet* 4(1):13-14, 1990.
30. **Wilson L:** Care and handling of clients from phone calls to office calls. *Proc Assoc Avian Vet*, 1989, pp 449-453.
31. **Zimmer JF, et al:** Evaluation of the efficacy of selected commercial disinfectants in inactivating *Giardia muris* cysts. *J Am An Hosp Assoc* 24:379-385, 1988.

**MAKING  
DISTINCTIONS IN  
THE PHYSICAL  
EXAMINATION**

**Greg J. Harrison  
Branson W. Ritchie**

**T**he purpose of the relationship between an avian veterinarian and the client is to ensure a long, comfortable, disease-free life for the companion bird. Clinicians must thoughtfully combine information from the anamnesis, physical examination and minimum database to advise clients on how to prevent medical problems in a companion bird.

In the practice of avian medicine there is a decisive difference between the diagnosis and treatment of obvious problems and the ability to detect, identify and correct subtle abnormalities. By carefully and systematically evaluating the patient and its environment, subtle abnormalities become increasingly obvious. Avian species attempt to hide signs of disease as a survival adaptation. Individuals that appear sick or injured are easy prey for predators and may also be segregated or attacked by the flock. Birds are less capable of successfully hiding signs of disease from clinicians that have become skilled and acute in their observations.

An incomplete understanding of the physical, nutritional, physiologic and psychologic needs of birds frequently leads to long-term, inadequate care. It is these predisposing factors that must be corrected in order to restore and maintain the health of an avian patient. Because of management faults, finding "normal" birds during a physical examination is, unfortunately, rare.

Establishing these predisposing factors requires identifying a common pathogenesis for the abnormalities noted on physical examination. It is when the interconnection between the clinical signs of disease is determined that the true cause of a problem can be clearly defined and corrected. Feather abnormalities and a respiratory disease may have a common etiology that includes a systemic fungal infection, poor nutrition, inadequate exposure to sunlight or frequent exposure to cigarette smoke.

Clients should be instructed to evaluate the movement, body posture, head position, behavior, appetite, attitude, ocular clarity and excrement output of their birds on a daily basis. This will help identify abnormalities before a disease process progresses to an irreversible point. Advanced stages of disease that a client may recognize include drowsiness, increases or decreases in food or water consumption, changes

in the color or consistency of feces, urine or urates, coarse, ruffled or moist feathers, picking or scratching, or changes in body posture, wing position or talking and singing abilities. Clients that are taught to observe a bird's fecal output (not food consumption) can be instructed to seek immediate medical assistance when changes are noted.

To help identify management and disease-related problems early, it is advisable to perform a complete physical examination on a new patient twice in the first year, and annually thereafter. The initial evaluation periods will provide the clinician with an opportunity to identify and correct problems before they can cause irreparable organ damage. A well designed preventive medicine program will improve the quality of a companion bird's life, save the client money and help maintain a positive attitude in the clinical staff.

## Anamnesis

Clinically evaluating an avian patient involves combining information collected from the history, physical examination and minimum database. A thorough history frequently provides obscure clues that may identify risk factors important in diagnosing and resolving a patient's problems. Early identification and correction of subtle abnormalities caused by environmental stresses (eg, exposure to cigarette smoke, kerosene heaters, chemical fumes, disinfectants), management flaws (poor hygiene) or nutritional inadequacies (eg, all-seed diet, excess vitamin supplementation) are clinically more rewarding than attempting to stabilize a chronically compromised patient with an acute, life-threatening metabolic crisis (Figure 8.1).

### Developing the Anamnesis

**When and where was the bird obtained?** Birds obtained from traveling dealers are frequently exposed to infectious diseases and may be illegal imports that have not been through a USDA quarantine system. Many high-quality pet retailers are specializing in domestically raised hand-fed chicks, which generally have fewer medical problems and make much better companions than their wild-caught conspecifics (see Chapter 30).

#### Specific Questions for Developing the Anamnesis


- What is the duration of observed problems?
- Are there other pets?
- What exposure does the bird have to other birds?
- Are other pets ill?
- Are family members ill?
- Has the bird had other medical problems?
- Has the bird received any medications?
- When was the bird first introduced to the home?
- Where was the bird obtained?
- Did the bird come with a health guarantee?
- Where is the bird kept in the home?
- What substrate is used in the enclosure?
- Is the home heater electric or gas?
- What temperature is the home?
- What houseplants does the bird have access to?
- Is the bird frequently exposed to fresh air and sunlight?
- Is the photoperiod natural and regulated, or random and irregular?
- Are exterminators used?
- Is the bird exposed to cigarette smoke?
- What potential aerosols is the bird exposed to (household chemicals, disinfectants, hair sprays)?
- What disinfectants are used in the enclosure and how often?
- Have any changes recently occurred in the home (new enclosure, different diet, painted house, changed carpet, moved to a new location, new pet or strange people in the house, moved bird to a new location in the house)?
- What types of foods are offered?
- What types of foods are consumed?
- What feeding schedule is used?
- Are any dietary supplements used?
- Is the appetite increased or decreased?
- Have the droppings changed in color, frequency, consistency or quantity?
- Has the water intake changed?
- Any coughing, sneezing, diarrhea or vomiting?
- Have noted changes remained the same or progressed?

#### How long has the bird been in the household?

Recently obtained birds (within the last year) are more likely to be suffering from problems associated with infectious disease or stress, while long-term pets are more likely to have problems with malnutrition or chronic systemic diseases.

#### Have any new birds recently been added to the household or aviary?

New birds can invariably be a source for previously unencountered pathogens. A bird obtained from a breeder whose flock is closed to new birds and is constantly being monitored for sub-clinical problems (eg, PBFV virus, polyomavirus and



**FIG 8.1** The quality of the beak, nails, feathers and skin will provide valuable information about the condition of an avian patient. In this Canary-winged Parakeet, the abnormal white-colored feathers, abundance of pin feathers, overgrown nails and hyperkeratotic rhamphotheca were caused by an inadequate diet and a lack of exposure to sunlight.

chlamydia), is less likely to have an infectious disease than a bird obtained from a source that mixes birds from different locations (eg, substandard pet retailers, brokers, bird shows, quarantine stations). The recent addition of birds that are frequent carriers of infectious diseases should also be noted. Contact with free-ranging birds can also expose companion birds to some infectious agents.

**Has there been a change in food or water consumption?** Subtle increases or decreases in food or water consumption can be signs of disease. It is important to distinguish between the food offered to a bird and the food consumed by a bird. An adequate diet may be offered, but an inadequate diet may be consumed. A bird on a seed-based diet (even with supplements) may develop progressive malnutrition that will become increasingly evident over several months to years depending on the bird's age. Young birds are more susceptible to malnutrition and will develop acute signs of disease, while mature birds are more likely to suffer from chronic malnutrition. Many domestically raised neonates are being weaned onto good quality, formulated diets and a variety of nutritional foodstuffs. Unfortunately, many of these birds will be switched by the new owners to a seed-based diet, which induces obvious clinical signs of malnutrition over several years.

**Are other pets or family members ill?** If other pets or family members are ill, the clinician should consider a common etiologic agent (infectious disease or exposure to an environmental toxin). A client should always be advised to seek medical attention if any family members are ill. It should be noted that

companion birds may learn to mimic the sneeze or cough of a family member, which should not be interpreted as an abnormality.

**Is the bird restricted to an indoor environment?** Frequent exposure to fresh air and sunlight is important for a bird's overall health. Medical problems are more common in birds that are restricted to indoor environments. Drafts have no effect on healthy birds that are acclimated to normal temperature fluctuations.

**Is the bird exposed to toxic compounds, particularly aerosols?** Determining if the indoor environment is contaminated with toxins can help with an immediate diagnosis and guide suggested changes to prevent future problems. Birds have an efficient respiratory system, and brief exposures to toxins can be life-threatening. Commonly encountered, but infrequently discussed, toxins that could have a dramatic effect on the health of a bird include cigarette smoke, fumes from disinfectants (eg, Clorox, ammonia, Lysol), furniture polish, floor wax, paint, hair spray, dry cleaning fluid and carpet and furniture cleaners (see Chapter 37).

**Have any medications already been administered?** Discussion of a bird's previous medical problems, and how they were diagnosed and treated, may provide important information to the clinician. With referral cases, all available records should be carefully reviewed. Some breeders and pet retailers recommend the use of over-the-counter (OTC) medications (usually tetracyclines or erythromycin) for the treatment of sick birds. These OTC preparations usually have little or no therapeutic value and further complicate the disease picture by weakening the immune system and encouraging the proliferation of secondary bacterial or fungal pathogens. Knowing which antibiotics have been administered will influence the interpretation of results obtained from cytology, culture and sensitivity.

**Have there been changes in a bird's behavior?** Changes in behavior that should be noted include excessive sleeping, resting in a fluffed condition and a decrease in talking, singing or playing. Scratching and excessive preening may indicate a local or systemic abnormality. Personality changes, including increased aggression, screaming, intolerance of strangers or biting the enclosure or toys also may indicate problems.

**What is the bird's reproductive status?** Seeking seclusion (eg, hiding under furniture, in drawers,

behind book cases, under papers) tearing up paper, a crouched copulatory stance and masturbatory actions with certain family members, toys, mirrors, other animals or inanimate objects are suggestive of breeding behavior. Reproductively active Amazon parrots may fan the wings and lean forward with the iris dilating and contracting, while making a low “purring” type sound. Reproductively active cockatoos, especially Umbrella Cockatoos, may pant rapidly while being stroked. Some birds, especially the larger macaws, may incubate balls or other round objects and will defend stuffed toys as if they were chicks. Single cockatiel hens can lay 20 to 40 eggs a year for several years then gradually reduce, and finally stop egg laying. These birds may continue to go through the behavioral motions of egg laying and develop egg-related peritonitis (eg, depression, anorexia, swollen abdomen) weeks to months after ceasing oviposition.

## Physical Examination

The physical examination can be viewed as a three-part process: observing a bird's response to its environment, examining the bird's environment and systematically examining the patient.

A mental picture of a free-ranging bird (slick, solidly colored feathers; clear, dry skin; bright inquisitive attitude) should serve as a comparative model for evaluating the condition of avian patients (Color 8.1). By carefully performing the same thorough physical examination on each patient, the practitioner can develop an image for the average and a perspective of what should be considered clinically normal. The quest of the physical examination should be to proclaim that a patient is clinically normal, a condition that rarely exists (Color 8.2).

### Evaluating the Bird in its Environment

Birds that are stressed will frequently alter their behavior in an attempt to hide signs of disease. This is particularly true while a patient is in the examination room, and it is a challenge for the clinician to distinguish between stress-related behavior, normal behavior and a disease process. A bird that the client describes as listless at home may appear bright, alert and responsive when subjected to the stress of the

hospital environment. To overcome this problem, the examination room should be free of extraneous noises and interruptions, and a bird should be acclimated to the examination room for five to ten minutes before beginning the evaluation process.

The general appearance, attitude, posture and activity level of the bird should be determined while it remains securely within its enclosure. Birds being observed at a distance are more likely to feel unthreatened and exhibit changes associated with lethargy and depression (Color 8.7). In an aviary setting, birds can best be initially viewed from a distance with the aid of binoculars.

Observational clues that a patient is seriously ill include ruffling of feathers, partially closed eyes, frequent blinking, tucking the head under a wing, labored breathing, sitting on the bottom of the enclosure, a hunched stance, straining to empty the cloaca, cloacal winking and loss of balance (Color 8.15). Birds that are stressed may shiver, causing a rapid movement of the body feathers. A bird that is depressed and lethargic will respond poorly to external stimuli when disturbed and then return to a calm, detached state (Color 8.6).

Abnormalities in body function may include lameness, wing droop, standing on one leg, shifting weight from one leg to another, resting on the sternum or standing on the metatarsus rather than the foot. A bird's wings should be held tightly to the body with the carpi symmetrical. A bird that is hot or excited may hold the wings out from the body, yet still in a symmetrical position. One drooping wing is an indication of an abnormality (eg, fracture, arthritis, tendon or ligament damage, nerve damage, bruising, mass) (see Figure 28.8).

Normal respiratory effort in the bird should not be noticeable, and the mouth should remain closed. Open-mouthed breathing is an indication of severe dyspnea. Resting respiratory rates vary from 6 to over 30 cycles per minute, depending on the size of the bird (Table 8.1). Small birds have higher respiratory rates; large birds have lower respiratory rates. Some avian species (notably Amazon parrots and *Pionus* spp.) may pant when stressed. This normal physiologic response should not be misinterpreted as disease-induced dyspnea.

Respiratory disease is common in birds, and subtle signs are best detected while the bird is in its enclosure. Excessive chest movement, excessive tail motion when breathing (tail-bobbing), open-mouthed

**TABLE 8.1 Normal Heart and Respiratory Rates of Birds (per min)\***

Weight	Heart Rate (Rest)	Heart Rate (Restraint)	Resp. Rate (Rest)	Resp. Rate (Restraint)
25 g	274	400-600	60-70	80-120
100 g	206	500-600	40-52	60-80
200 g	178	300-500	35-50	55-65
300 g	163	250-400	30-45	50-60
400 g	154	200-350	25-30	40-60
500 g	147	160-300	20-30	30-50
1000 g	127	150-350	15-20	25-40
1500 g	117	120-200	20-32	25-30
2000 g	110	110-175	19-28	20-30
5000 g	91	105-160	18-25	20-30
10 kg	79	100-150	17-25	20-30
100 kg	49	90-120	15-20	15-30
150 kg	45	60-80	6-10	15-35

\*The resting or flying heart rate of any sized bird can be estimated with the formulas: Resting HR in beats/sec =  $12 \times (4 \times \text{Wg})^{-0.209}$ . Flying HR beats/sec =  $25 \times (1 \times \text{Wg})^{-0.157}$ . Multiply results of either by 60 for beats per minute. From King AS, McLelland J: Form and Function in Birds Vol. 2. London, Academic Press, 1981 (see Chapter 27).

breathing, neck stretching, yawning, extending the wings away from the body, and forward movement of the head (bobbing) on inspiration or expiration are all indications of respiratory system compromise. Dyspnea associated with the upper respiratory tract or lungs is frequently accompanied by open-mouthed breathing. Lung and lower respiratory tract problems are usually associated with a rhythmic jerking of the tail (tail-bob). Respiratory problems associated with excessive fluid production may cause gurgling sounds that are audible on inspiration and expiration.

Dyspnea induced by protracted respiratory disease is usually associated with other clinical signs including weight loss, depression, ocular or nasal discharge, sneezing or wheezing. Acute dyspnea in an apparently healthy bird usually results from exposure to aerosolized toxins, dislocation and movement of tracheal plaques (from malnutrition or infectious agents) or aspiration of foreign bodies (particularly seed husks or enclosure substrates).

### Gender Determination and Aging

During the physical examination, feather color, patterns and markings can be used in some species to differentiate between various hybrid varieties. Male cockatiels in general have a dark-yellow crown and a dark-orange cheek patch. They may whistle a melody or sing. Females tend to have a light-yellow crown with a blotchy orange cheek patch. They chirp, bite more often and seldom talk or sing melodies. A wild-type immature cockatiel has a gray body, white pri-

mary horizontal bars on the underside of the wings, a light-yellow head and orange cheek patches (Color 8.12). Except in pied and pearl mutations, males over one year of age lose these horizontal bars, while females do not. In piers, some or all of the gray feathers are white. Pearls will have a splotched, repeated pattern of interspaced grey and white feathers. This pearl pattern is retained in the adult female and lost in the adult male. A lutino is characterized by the replacement of gray feathers with white feathers that contain various shades of yellow. Hepatitis, chlamydiosis or heredity should be considered in cockatiels that are dark yellow (Color 8.8). A young pied has stripes in the central tail feathers, which are retained in the mature female but replaced with solid-colored central tail feathers in the mature male. Heavier piers are difficult to sex by feather color.

With continued inbreeding to create color mutations, it has become increasingly difficult to accurately determine gender based on feather color. This is particularly true with albino (colorless with pink eyes) and cinnamon cockatiels. In these birds, endoscopic or genetic testing for gender is required.

Immature male and female wild-type budgerigars are green and appear similar. The male tends to have a "halo" or lighter colored ring around the nares. As the male matures, the cere turns from light pink to blue. Sexually maturing females develop a brown cere. Males tend to be brighter colored, bite less and sing and talk more than females. The color varieties are more difficult to visually sex. For example, with some line-bred budgerigars, as many as 50% of the birds with light blue ceres can be hens. Behavior can indicate gender in some species. For example, male finches tend to sing and perform a mating ritual dance when stimulated by a receptive hen.

Important genetic information can be obtained by determining the phenotype of a bird. For example, a blue budgerigar (or any color other than wild-type green) would clinically be expected to have a substantially reduced life expectancy (six years versus >15 years). Wild-type cockatiels have the potential to live over 20 years, but most color mutations usually die before they are ten years old. Table 8.2 lists some physical changes observed in long-term captive macaws.

### Examining the Bird's Environment

If the bird is transported to the hospital in its regular enclosure (which the client should have been instructed not to clean before the bird's appointment),



**TABLE 8.2** Effects of Aging in Macaws

- Muscle wasting > 40 years old
- Joint stiffness suggestive of arthritis
- Loss of skin tone and elasticity
- Neurologic disease
- Decreased feather production > 40 years old
- Twisting deformities of the carpi > 40 years old
- Pigment spots, polyps, wart-like blemishes, cysts, wrinkling facial skin
- Thinning of the skin on the face and feet > 40 years old
- Cataracts > 35 years

From Clubb SL, Karpinski L: Aging in macaws. *J Assoc Avian Vet* 7(1):31-33, 1993.

the clinician can examine the enclosure and determine what types of foods are offered and which of these foods are actually consumed. Fruits, vegetables and other moist foods can spoil rapidly, promoting the growth of bacteria (particularly *Pseudomonas* spp. and *E. coli*) and fungi. A cuttlebone should be examined for beak marks to determine if it is being consumed by the bird.

Excrement that is allowed to accumulate in the bottom of the enclosure, and perches that are dirty or positioned over the food or water containers are hygienically undesirable (see Chapter 1).

Birds should always have a supply of clean, fresh water with no additives. Vitamins added to the water oxidize quickly (become inactive) and provide an excellent growth media for bacteria and fungi (see Chapter 3).

### Excrement

Examining the color, texture, consistency and volume of the feces, urates and urine will provide information about a bird's appetite, behavioral patterns and gastrointestinal, renal and hepatic functions (Color 8.34 to 8.58). Droppings should be visually evaluated by the client on a daily basis. The amount and character of feces is a more accurate reflection of a bird's condition than the owner's impression of the body weight and food consumed.

The frequency of defecation and the volume of excrement varies with the species of bird. In general, smaller birds with more rapid metabolic rates will defecate more frequently than larger birds with a slower metabolic rate. A normal budgerigar may produce from 25 to 50 stools per day, while a Blue and Gold Macaw may defecate 8 to 15 times a day (Color 8.39). A reduced quantity of excrement can be an indication of decreased food intake, a decreased gastrointestinal transit time or a blockage (Color 8.42).

Dry, scant droppings may indicate dysphagia or food and water deprivation. Birds may have scant droppings for a few days if a change in diet has caused them to consume less food (eg, medicated diets).

The normal excrement should consist of a fecal component, urates and liquid urine (Color 8.34). Normal feces may be green, light- to dark-brown and be slightly loose-to-firm in consistency. Normal urates should be white and the urine should be clear. The physical characteristics of feces can be influenced by the species and age of the bird, the time of day, type of diet consumed, quantity of food and water available, reproductive status, medication administered, renal disease, liver disease and the presence of parasitic, bacterial, chlamydial, fungal or viral pathogens.

It is common for a bird in the exam room to have a stress-induced polyuria or diarrhea. Over-consumption of fruits, vegetables or a recent change in the diet can alter the color and consistency of the feces. Birds that consume heavily pigmented foods (eg, blackberries, blueberries, sweet potatoes, raspberries, beets; some highly colored crackers) can produce oddly colored feces. The reddish-to-black discoloration that is common with the consumption of blackberries and raspberries should not be confused with melena (Color 8.44).

Dark-colored feces (not caused by fruit consumption) is indicative of melena. This is a common finding in budgerigars on an all-seed diet, but may be abnormal considering that the melena stops when birds are placed on a formulated diet. Blood in the excrement can originate from the GI tract, oviduct, kidneys, testicles or cloaca. Frank blood in the excrement may be associated with coagulopathies, liver disease, cloacal pathology, pre- or post-oviposition, malnutrition or enteritis (Color 8.49). Bright-green, loose feces and yellow, green or brown urates may indicate hemolysis or hepatitis and are common with malnutritional, toxic, chlamydial, bacterial or viral hepatitis (Color 8.36). Clay-colored feces are indicative of maldigestion or malabsorption (Color 8.35).

Birds consuming some formulated diets or large quantities of fruits and vegetables will produce a loose voluminous feces and more urine than birds on a principally seed diet. Monkey biscuit and some other formulated diets cause the production of brown feces, while parrots consuming seeds generally have green feces. Neonates fed most standard formulas have soft, semifirmed voluminous feces, as do hens

in the pre- and post-ovulatory period (Color 8.53). Voluminous droppings may also indicate malabsorption (eg, gastrointestinal disease, pancreatitis, peritonitis or parasites), diabetes or renal tumors (Color 8.52). For some birds, especially house-trained birds, a voluminous feces is a normal morning dropping.

Normal feces are smooth, and some high-fiber formulated diets will cause them to cling together in a tight, gelled cylinder. A granular or rough stool can indicate abnormal digestion. The presence of undigested food in the feces is not normal and must be differentiated from food that has fallen into the feces. Excreting poorly digested food can be an indication of maldigestion, malabsorption or hypermotility caused by parasites, pancreatitis, proventriculitis, ventriculitis or intestinal disease (Color 8.57).

Diarrhea is rare in companion birds. Loose, watery feces are normal in lorikeets and birds that consume liquid or nectar diets. The normal feces of Anseriformes also contain a high water content. In psittacine birds, most cases of diarrhea reported by clients are actually polyuria in which the feces are dispersed in an increased volume of urine. Finding bubbles (gas) in the feces is common in birds with true diarrhea (Color 8.51). Diarrhea can occur with various parasitic, fungal, chlamydial, viral and bacterial infections, systemic diseases and following the administration of some medications.

Direct examination of the feces should include a Gram's stain (to detect fungi, bacteria and inflammatory cells), fecal flotation (for helminths), direct wet mount examination for protozoa and determination of pH. The normal pH of the cloaca is 6.5 to 7. A basic pH (>7.5) favors the growth of yeast and Enterobacteriaceae.

### Urine and Urates

The kidneys excrete a pasty white-to-yellow urate (produced in the liver) and a sparse, clear, colorless watery urine that can be separated from the urates for analysis. The stress of being transported to the clinic will cause most birds to be polyuric when they are examined by the attending clinician. The presence of hematuria in any form is abnormal. Blood that is in the urine may originate from the GI tract, oviduct, kidneys, testicles or cloaca (Color 8.48).

Yellow-green urates are indicative of hemolysis or liver disease (Color 8.41). Idiopathic, reddish-brown urates have been described in some hand-fed babies that seem to be otherwise healthy with normal growth patterns (Color 8.36). This phenomenon is

more common in birds that are receiving an animal protein-based diet, and some cases will resolve when a neonate is switched to a plant protein-based formula.

Urine for detailed analysis should be collected from an impervious surface as soon as possible after it is excreted (see Chapter 11). The avian urinalysis should include cytology and determination of the pH, glucose, sediment, color and specific gravity. Glucose should be completely absorbed and is not normally detected in the urine. The presence of ketones is abnormal and may suggest diabetes mellitus. The presence of casts is an indication of renal disease. Uric acid crystals can be dissolved by adding several drops of sodium hydroxide to a urine smear. This will facilitate the identification of casts, bacteria and cellular debris.

Urine may be excreted without urates when birds are nervous, polydipsic or consuming fruits and vegetables with a high-water content. Polyuria may be noted in birds that are egg laying, feeding chicks or holding their droppings overnight. It is also common in hand-fed babies and birds that are excited or housed in hot environments (Color 8.53). Pathologic causes of polyuria include diabetes, renal disease, wasting disease, certain medications (eg, aminoglycosides, steroids, medroxyprogesterone) and exposure to various toxins (Color 8.37).

### Vomiting vs Regurgitation

Detecting foamy, sticky, partially digested food on the walls or floor of the enclosure or attached to the feathers or the bird's head and face is suggestive of regurgitation or vomiting. The distinction between regurgitation and vomiting is not as easily made in birds as in mammals. The expulsion of ingesta from the crop is considered regurgitation. The pH of material regurgitated from the crop is generally neutral to slightly alkaline. The normal pH of the crop is 7 to 7.5. Regurgitation can occur as part of the normal mating activity. If regurgitation is part of courtship activities, the patient will be of normal weight and will have no other clinical signs of disease.

Vomiting is considered the expulsion of ingesta from the proventriculus (see Chapter 19). Vomitus is usually acidic, may be bile-tinged and generally contains partially digested food (Color 8.58). An acute onset of vomiting caused by a pathologic process is often accompanied by depression, severe dehydration and shock.

Regurgitation, and in some cases vomiting, is common in hand-fed babies, if the formula is excessively

thin, if gastrointestinal disease is present, if they are fed excessive amounts of food or if they are being weaned.

### Odors


Varying species of birds, and individuals within the same species, can omit distinct odors that originate from the food consumed, the feces and urine, the uropygial gland oil, the breath, the skin or the feathers.

Normal fresh excrement from companion birds is basically odorless. Birds that consume animal protein (eg, raptors) usually have a distinct odoriferous stool. Foul breath is rare in birds and, when present, indicates an abnormality that might include candidiasis, oral or upper gastrointestinal tract ulcerations, oral or upper GI abscesses or gastroenteritis (Color 8.22). Unpleasant skin and feather odors are usually associated with necrotic tissue secondary to cysts, abscesses or neoplasias. Pasty droppings that adhere to the vent and produce a metallic, offensive odor are frequently noted in cockatoos. These birds generally have abnormally acidic (pH 4 to 6) feces of unknown etiology. Birds consuming high animal fat diets (eg, ribs, chicken marrow bones, fried foods) may have a rancid oil odor that can persist for several weeks after a diet change.

### Gram's Stain

Gram's stains of samples from the feces, cloaca, choanal slit and crop can be used to evaluate a bird's overall health by estimating microbial populations (Figure 8.2). In contrast to cultures, which limit the growth of some organisms, cytologic evaluation of a sample will provide information about the type and relative number of each microbial organism present, including difficult-to-culture anaerobic or fastidious organisms. Fresh feces appear to be the most useful sample to evaluate.

In general, the digestive tract of grain- and fruit-eating Psittaciformes contains a gram-positive bacterial flora with a few yeast (Color 8.59). A normal fecal Gram's stain should contain 100 to 200 bacteria per high-power field with 60 to 80% gram-positive rods and 20 to 40% gram-positive cocci. A few yeast or gram-negative bacteria per high-power field could be considered normal but should alert the clinician to carefully evaluate the patient for subtle abnormalities. The normal microbial flora of birds maintained indoors may be slightly different than the flora of birds residing in a flight outdoors.



**FIG 8.2** If fecal Gram's stain results are abnormal, samples collected directly from the cloaca can be cultured for the presence of abnormal bacteria or yeast. It is best to moisten a swab with sterile transport media or LRS before inserting it into the cloaca to prevent the dry swab from causing excessive tissue damage.

Gram-negative bacteria are common in the oral cavity and in feces of clinically normal carnivorous or insectivorous Passeriformes, raptors, Galliformes and Anseriformes. The feces of canaries and finches normally have a reduced population of bacteria and often show various types of yeast one-fourth to one-half the size of candida.

In most psittacine birds, an absence or decrease in the number of bacteria, the detection of WBCs, a shift from a gram-positive to a gram-negative bacterial population or the presence of a high number of yeast (> 5/HPF) in samples from the choana, cloaca or feces may indicate a primary microbial infection or that immunosuppression with colonization by secondary pathogens has occurred (Table 8.3) (Color 8.61). Occasionally, gram-negative bacteria and yeast can be transiently present in the choana or cloaca of clinically normal birds. Some formulated diets and most breads contain brewer's yeast, which can be passed in the feces and morphologically resembles *Candida* spp. In general, yeast of clinical concern will be budding, while brewer's yeast will not (Color 8.63).

The avian clinician must interpret the results of a fecal Gram's stain with respect to the patient's envi-

**TABLE 8.3** Abnormal Fecal Gram's Stain Findings

- Low bacterial count
- Reduced numbers and percentage of G + cocci
- Reduced numbers and increased percentage of G+ rods
- Increased numbers and percentage of G - rods
- Increased numbers and percentage of budding yeast

## ■ Making Distinctions in the Physical Examination

### Color 8.1

Normal Hyacinth Macaw. Note the normal yellow color of the skin around the eye and lower beak. This coloration should not be misinterpreted as hyperbilirubinemia (courtesy of Apalachee River Aviary).

### Color 8.2

Normal Blue and Gold Macaw exhibiting a defensive behavior (wings extended) in response to being approached. Note the sharp, distinct coloration of the feathers, the bright alert eyes, dry nostrils, smooth black beak and blemish-free facial skin. The nares of Blue and Gold Macaws are clearly visible, while those of other macaws can be covered with feathers.

### Color 8.3

Birds will be at their peak of condition and health when provided a formulated diet supplemented with fresh fruits and vegetables and frequent exposure to fresh air and sunlight. Close observation of this Green-winged Macaw shows black discoloration of the blue remiges on the left wing, frequently seen with nutrient oversupplementation and microhepatia.

### Color 8.4

A resting Major Mitchell's Cockatoo. Normal sleeping behavior must be differentiated from lethargy or depression (Color 8.6). Note that the feathers of this clinically

normal bird are clean, have a reflective quality and are evenly colored.

### Color 8.5

Companion grooming behavior indicative of an effective pair-bond in normal Military Macaws. Note the smooth, evenly colored feathers, bright eyes and clean, dry perinasal area. The blushing noted on the hen's cheek area is common when birds are stressed or excited and should not be misinterpreted as pathology.

### Color 8.6


Birds frequently sleep with their beaks tucked into the shoulder area. A bird that exhibits this behavior in a stressful situation (eg, examination room) would be considered severely depressed. Note the partially closed eyelids in this Yellow-naped Amazon Parrot.

### Color 8.7

Birds should always be observed from a distance to detect any subtle behavioral abnormalities. This Crested Cardinal would start singing and hop from limb to limb when approached; however, when viewed from a distance, the bird appeared depressed, and the feathers were held away from the body ("fluffed up"), suggesting difficulties in maintaining normal body temperature.



8.1



8.3




8.2



8.4



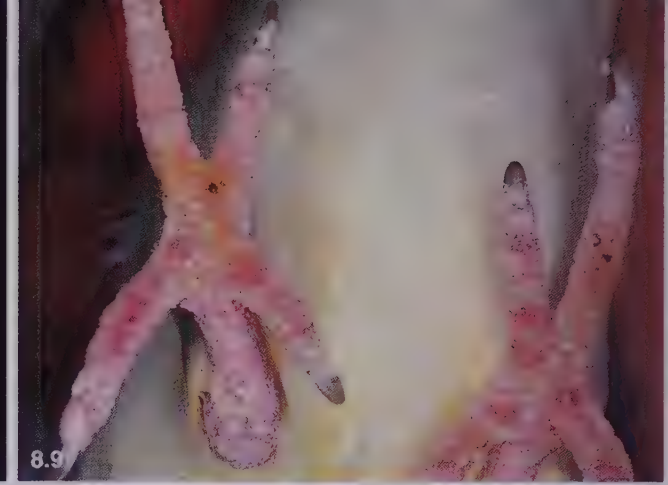

8.5



8.6



8.7



## ■ Making Distinctions in the Physical Examination

### Color 8.8

Yellow discoloration of the feathers in lutino cockatiels is frequently associated with active hepatitis.

### Color 8.9

Loss of the papillae and hyperkeratosis of the plantar surface of the feet are common in malnourished birds. Hypovitaminosis A is frequently implicated. If unresolved, these lesions can become infected (eg, bumblefoot), causing crippling or life-threatening changes.

### Color 8.10

Normal (left) and abnormal Yellow-naped Amazon Parrots. The bird on the right was fed an all-seed diet, was overweight and had elevated liver enzymes. Note the thin, discolored feathers and the rotund nature of the proventer (breast) region in the abnormal bird. This bird's overall health improved when it was changed to a formulated diet supplemented with limited fresh fruits and vegetables and was given frequent exposure to sunlight.

### Color 8.11

Stick-tight flea on the lore region of a cockatiel.

### Color 8.12

Distinct yellow crossbars on the ventral surface of the flight feathers in a female lutino cockatiel.

### Color 8.13

A near comatose Severe Macaw with neuropathic gastric dilatation. Note the glazed, sunken eye (dehydration) and partially closed eyelids. This bird would exhibit intermittent periods of vocalization and wing-flapping, and would then slip back into a comatose state.

### Color 8.14

**a)** Bacterial otitis externa in a Mitred Conure. Note the hyperemia and swelling of the tissues associated with the auditory meatus. **b)** Normal auditory meatus for comparison.

### Color 8.15

Severely depressed Gouldian Finch. Note the yellowish discoloration of the urates (suggestive of liver disease) and the absence of feces. Because of their rapid metabolism, small birds can die within a few hours if they do not consume adequate levels of energy-rich foods.

ronment, diet, general condition and clinical signs. Identifying an organism in a sample does not mean it is associated with a disease process. Different strains of a particular bacteria may appear morphologically similar, but may vary widely in pathogenicity. Distinguishing between pathogenic and non-pathogenic strains of the same genera of bacteria or fungi requires detailed biochemical analysis.

Properly interpreting a Gram's stain requires that the clinician determine if the organism detected is pathologically colonizing a mucosal surface. A clinically normal bird with an abnormal Gram's stain should be observed for changes that could indicate a problem. The management practices associated with the bird should be carefully evaluated to identify problems that could increase a bird's exposure to pathogenic bacteria or that could be weakening the immune system. A shift from an abnormal to a normal Gram's stain over a three- to six-week period is common in birds that are changed from an all-seed to a formulated diet.

An improperly evaluated Gram's stain can result in unnecessary antibiotic therapy that is detrimental to an individual bird or to an aviary as a whole. Damage to the normal flora caused by the indiscriminate use of antibiotics or contact with disinfectants precipitates the colonization of opportunistic pathogens.

### ■ Examination of the Patient

Once a bird's enclosure has been evaluated for clues that may indicate abnormalities and the bird has been carefully observed in its environment, it is time to perform a hands-on physical examination. The initial consideration in performing a physical examination is in handling the patient in a safe and efficient manner. Even the simplest procedure can become life-threatening if improperly performed. A client should be informed that handling a critically ill bird can destabilize the patient to a point where it can no longer compensate.

The examination room used for birds should be secluded, sealable, easily cleaned, contain minimal furniture, have dimmable lights and should not have ceiling fans or uncovered windows. With smaller, easily stressed species (eg, finches, canaries), performing the physical examination in a dimly lighted room will help calm the patient.

Any equipment or supplies that may be needed should be prepared before a bird is removed from its

enclosure. This will expedite the physical examination and decrease restraint-induced stress. The clinician should wear ear protectors to prevent hearing loss when handling large screaming psittacine birds. The use of a magnifying loop, operating microscope or slit lamp will help in discerning subtle changes associated with the skin, feathers, head, cloaca, oral cavity, eye and limbs (Figure 8.3). The ear canal of birds can be examined using a small otoscope cone. An otoscope may also be useful in evaluating the oral cavity, cloacal mucosa and pharyngeal area. The physical examination process should be performed quickly and efficiently. With practice, a thorough examination can be performed on a critically ill patient in less than three minutes.


The physical examination should involve the clinician's use of vision, sound, smell and touch to identify the areas of the body that are unusual. It is a clinical judgement to determine if something is normal for the individual patient yet abnormal for the species as a whole. While a physical examination can be performed using different regional or anatomic approaches, the key to detecting subtle abnormalities is to consistently use the same approach (using a physical examination form may be helpful).

Initial restraint of flighted birds can be accomplished with a net. A small bird can easily be removed from its enclosure by turning out the lights and gently removing the bird from its perch. A paper or cloth towel can be used for removing larger patients from their enclosures. Paper towels are best for handling birds because they can be discarded after use. If cloth towels are used, they should be laundered and autoclaved between each bird to prevent nosocomial infections.

With practice, the most refractory psittacine birds can be easily restrained using a towel. Gloves should never be used to restrain psittacine or passerine birds. Tame birds may associate the shape of the glove with discomfort and may equate the hand with danger. Removing the top or bottom of an enclosure may be easier than attempting to remove the bird through the enclosure door. The towel can be used to position the bird so that it is facing the side of the enclosure in order to have free access to the back of its head. The best time to grab the bird is when it bites the side of the enclosure.

Small birds can be restrained with one hand by placing the bird's head between the second and third fingers (Figure 8.4). Larger birds can be initially





**FIG 8.3** Magnifying loops and high quality lighting will facilitate the detection of subtle abnormalities in avian patients. Ear protectors should always be available in the examination room and treatment area to prevent the hearing loss that can occur from repeated exposure to screaming patients.

removed from the enclosure with a towel or net and then restrained by placing the thumb and index finger on either side of the mandibles. A bird must be able to move the sternum in order to breathe, and excessive force on the chest can result in asphyxiation. The bird should be held upright or parallel to the floor. Holding a sick bird upside down can compromise respiratory effort.

The towel used to initially remove a bird from its enclosure can remain around the bird at a level even with the upper eyelid and just below the nares. This gives the bird something to chew on, as well as reduces its vision to help keep it calm. A large bird can be cradled on its back between the clinician's body and arm. The lower forearm can be used to press the wings gently against the body (Figure 8.5). Using this method of restraint, both hands are free to palpate body surfaces and to manipulate the feet and wings, improving the access of all body surfaces for exami-



**FIG 8.4** Small birds can be restrained with one hand by placing the bird's head between the second and third fingers. The bird can then be gently cradled in the palm of the hand. An individual wing or leg can be easily manipulated for examination.

nation. For some clinicians, a complete physical examination requires that the patient be anesthetized with isoflurane, especially large and aggressive birds.

### The Dermis and its Unique Adaptations


The feather condition of a bird is an excellent indication of its overall health. The feathers and skin should be evenly colored, sleek, clean and dry (Color 8.4). A bird normally has feathered areas (pterylae) and non-feathered areas (apteria) of the body. Normal anatomic areas that may be

featherless in some species include the eye ring, top of the head, mid-proventer and axillary regions. Genetically induced baldness has been described in cockatiels. Some incubating hens will develop a featherless area on the abdomen called a brood patch. Most other areas of baldness should be considered abnormal.

The normal feather brilliance or "sheen" is derived from a combination of physical color, structural reflection of light (structural color), the presence or absence of powder from the powder down feathers (if present) and oil from the preen gland (if present). A bird loses its sheen if abnormalities occur in any of the factors that contribute to the reflectivity of the feathers (Color 8.13). Affected feathers appear dull and dirty (see Chapter 24).

The primary flight feathers have clean, uniformly smooth edges, and the color pattern changes slowly





**FIG 8.5** A large bird can be restrained using a towel to gain access to the head, which is then gently held between the thumb and first finger. The towel can be wrapped around the bird's body to provide additional restraint. The bird can be cradled in a sitting position between the clinician's body and arm, leaving both hands free to palpate body surfaces and to manipulate the feet and wings during examination.

and evenly from one portion of the feather to another. A disparity in any of these lines should be noted. The feather shaft (rachis) is smooth and gradually changes from thin at the tip to thick at the base (calamus). Feathers are usually darker toward the tip and lighter toward the base. The contour feathers that cover the body should blend with each other, giving the bird a smooth, compact appearance (Color 8.10). Feathers should be complete and intact throughout their length and width. Bent, malformed, broken or frayed feather edges are indications of a problem (see Color 24).

Malnutrition in general may cause these kinds of feather problems. Such birds appear sparsely feathered, not because the feathers are reduced in number

but because the feathers that are present are abnormal.

The skin over most of a bird's body is thin, soft, dry and relatively translucent (Figure 8.6). Small portions of discarded feather sheaths are normally found on the skin and should not be confused with dry, flaky skin. Uric acid deposits may be noted under the skin in cases of gout. Examination of subcutaneous tissues can be enhanced by wetting the overlying feathers with warm water or alcohol (Figure 8.7).

Balding, thinning, swelling, peeling or ulcerations of the skin or scales of the feet and legs are indications of abnormalities. The skin and feathers of birds consuming an all-seed diet are rarely normal. Changing a bird from a seed-based to a formulated diet, supplemented with fresh fruits and vegetables, will generally cause a dramatic difference in the skin and feather condition. The improvement in the feather quality will be most noticeable with the first molt following the diet change.

Feathers should be evaluated on a region by region basis. When a bird is relaxed, the feathers lie flat and follow the natural contour of the body. Feathers that are out of place may indicate abnormalities. Body swellings may push feathers away from the body, and feathers from a damaged follicle may twist or grow in an abnormal direction (see Color 24). Localized feather abnormalities should alert the clinician to carefully evaluate certain areas of the body.

Wet, sticky or stained feathers around the nares are indications of rhinitis. Generalized feather abnormalities indicate systemic abnormalities that should be evaluated.

One of the many functions of feathers is to retain body heat. If chilled, a bird increases its insulation capacity by increasing the distance between the feathers and the skin (fluffing up), therefore creating an air space between each feather. Some fluffing can be considered normal in birds that are restricted to an indoor environment. A bird that is diseased may be "fluffed" because it is chilled or because it is consuming insufficient energy to maintain a proper metabolic rate and compensate for normal heat loss. Birds may also fluff their feathers when they are



**FIG 8.6** The skin over most of a bird's body is thin, soft, dry and relatively translucent. The fact that avian skin is translucent allows direct visualization of many subcutaneous structures including vessels, the crop, tendons, ligaments, body musculature, bone and, in small birds, abdominal structures.



**FIG 8.7** Examination of subcutaneous tissues can be enhanced by wetting the overlying feathers with warm water or alcohol. Ethanol should be cautiously applied to open wounds because the systemic uptake of this product can cause intoxication.

content or when they wish to be preened or as a part of the mating ritual. A bird that is fluffing due to illness will show other signs of disease (Color 8.15).

Feather problems should be divided into those that occur before, during or after development. Lesions

occurring before development are caused by damage in the follicle, and the feathers do not emerge properly, if at all. These problems are often characterized by discharges from or enlargement of the feather follicles (see Color 24). Damage that occurs to a feather during development is characterized by an abnormal feather structure or color that is evident as the sheath is removed from the differentiated feather. Dark lines located transversely across several feathers (stress lines) indicate that an adrenocortical surge occurred while the affected feather was developing. Post-developmental feather problems are characterized by an abnormal rachis, barb or barbules but a normal follicle and calamus.

The molting process varies with the individual bird. Some birds (eg, canaries, raptors, pheasants) molt seasonally (typically after breeding season) while other birds molt continuously (budgerigars and cockatoos). The normal molt should be orderly and uneventful with an old feather being forced out by a newly developing feather (see Chapter 24). Birds should lose the feather sheath from the differentiated portion of a feather within days. Retention of the feather sheath is not normal, and may indicate malnutrition, pansystemic disease or an infectious agent. Birds will normally preen the head, neck and facial feathers of a companion.

Damaged pin feathers cut or broken off at the surface may be black and mistaken for mites. These damaged feathers may cause pruritus and excessive preening. Head feathers may appear abnormal in canaries that are malnourished, especially in reproductively active hens. The skin of the neck is frequently hyperkeratotic in these cases (Color 8.24). The powder down feathers of the prolaral region should be examined for the presence of powder formation or feather deformities. Moist lacerations or ulcerations may be noted in the axillary region in some birds with dermatitis (see Color 24).

Birds that are fed a marginal diet, that are not exposed to fresh air and sunlight and that are not allowed to bathe regularly have feathers that appear worn and tattered. The feathers that are replaced may have retained sheaths that give the bird the appearance of having an excessive number of pin feathers. The beak, skin and nails in these birds will frequently contain accumulations of keratinized epithelium (see Figure 8.1). Birds that are provided an inadequate diet may enter a molt cycle when their nutritional requirements are satisfied. Following a

diet change, these birds may go through a period when they seem to scratch and preen excessively.

### Head

The head should be symmetrical with respect to the eyes, periorbital areas, cere, beak and nostrils. The eyes of a normal bird are clear, bright and centered in the socket (see Color 26). The blink response can be evaluated by lightly touching the canthus. Normal eyelid margins should be symmetrical and smooth. Scabs, scars or active pustules on the lid margins may be indicative of poxvirus (particularly in Amazon parrots) (see Color 26).

Periophthalmic swelling, epiphora or conjunctivitis all indicate ocular or sinus abnormalities. Conjunctivitis is most common in cockatiels, lovebirds and Amazon parrots. In cockatiels and lovebirds, bacterial, mycoplasmal, chlamydial or viral conjunctivitis may damage the lids resulting in dry eye (see Color 26). Malnutrition, primary or secondary to giardiasis, may also cause conjunctival damage. A common problem in cockatiels is partial lid paralysis, with ectropion and conjunctivitis (see Chapter 41).

### Cere

The color of the cere varies with the species. An immature budgerigar will have a flesh-colored cere that normally turns dark blue (male) or stays light blue or pink (female) as the bird matures. Some browning of the cere is normal in reproductively active budgerigar hens. An abnormal accumulation of keratinized tissue on the cere (brown hypertrophy of the cere) can occur in some budgerigars with endocrine abnormalities (see Color 24). Estrogen-producing tumors may cause a male budgerigar's cere to change from blue to brown. Hyperkeratotic swelling and hypertrophy of the cere that causes occlusion of the nares may be noted in some Umbrella and Moluccan Cockatoos. A crusty cere and beak may be indicative of *Knemidokoptes* spp. mites (see Color 24).

### Nares

The nares and operculum (keratinized plate inside the nostril) should be smooth, relatively dry, symmetrical and evenly sized and colored. In some species (ducks), the nares are located within the beak, while in other species (Psittaciformes) the nares are at the margin of the beak and edge of the facial skin (Figure 8.8). The feather configuration around the nares varies among species. Cockatoos have dense feathers that completely surround the nares. By comparison, Amazon parrots have sparse bristle-type feathers around the nares. In cockatiels, Amazon parrots and

lories, the nares are round, while in cockatoos the opening forms a slit. Any degree of moisture around the nares should be considered abnormal.

Nasal discharges may be unilateral or bilateral and may appear clinically as dirty, malpositioned or moist feathers around the nares. Mild cases of rhinitis may be accompanied by severe cases of air sacculitis, sinusitis and caseous accumulations in the nares or sinuses. Periorbital swelling usually indicates a sinus infection. Signs of previous respiratory disorders may include grooves in the beak or loss of feathers associated with the nares (see Chapter 22).

The operculum should be well defined in the nasal cavity. The abnormal accumulation of desquamated cells adjacent to the operculum can create a mass that can become secondarily infected with bacteria or fungus, resulting in a unilateral rhinitis accompanied by severe tissue necrosis (see Chapters 22 and 41).


Pathology in the sinus or nasal cavities may alter the normal flow of air, causing the skin over the infraorbital sinus to move in and out as a bird breathes. This abnormality may be subtle and the bird may otherwise appear normal. Mild blockages that are not corrected can progress and cause severe sinusitis and conjunctivitis (cockatiels) or atrophic rhinitis (African Grey Parrots) with structural damage to the rhinal cavity and surrounding bony structures (sunken sinus syndrome in macaws) (see Color 22). In some species, transillumination of the sinus areas may help identify pockets of debris.

The feathers on the head should be smooth and uniform. The ear canals can be evaluated for discharge or the abnormal accumulation of desquamated hyperkeratotic skin by parting the feathers on the side of the head (Figure 8.9). The glistening, translucent ear drum can be visualized and will move slightly with respiration (see Color 13). Ear problems are infrequently seen in birds (Color 8.14). Those that do occur are generally caused by granulomas or neoplasms, and early detection and surgical correction are necessary to insure a favorable prognosis. The ear canal may be hyperemic in birds with sinusitis.

The beak color and shape varies dramatically among species; however, the surface of the beak should be smooth, shiny and uniform regardless of the species. The occlusal surface of the upper and lower beak should meet at midline and be even throughout the margins. The beak of a psittacine bird should grow about 0.25 inches per month, yet maintain a consis-



a



b



c

**FIG 8.8** The location of the nares, and the feather configuration around the nares, will vary among species. **a)** In Amazon parrots, the nares are surrounded by bristle feathers and are located at the edge of the skin margin and the beak. **b)** In some species, like this owl, and in Anseriformes, the nares are located in the beak and may not be surrounded by feathers. **c)** Any degree of discharge from the nares should be considered abnormal. Serous discharges are usually associated with respiratory irritants while mucopurulent discharges are most commonly associated with infectious agents.

tent length. In free-ranging birds, the beak is maintained in good condition through exposure to moisture followed by drying from exposure to sunlight. As the bird eats and chews on woody plants, the dry outer edge of the beak is removed, which maintains its proper shape and length.

Dry, flaky layers on the beak and skin around the cere are abnormal and may signal poor management or systemic disease (Figure 8.10). Birds that frequently bathe, are fed formulated diets and have regular exposure to fresh air and sunlight have fewer beak problems than birds that are fed a seed diet and restricted to an indoor environment. Grooves in the beak originating from the area of the nostril may

indicate a previous or ongoing sinus infection (see Chapter 22). Physical damage (bite wounds) to the epithelial growth centers of the beak can cause similar lesions. Proliferative growths associated with the beak are common with *Knemidokoptes* sp. infections (see Color 24).

### Oral Cavity

Evaluation of the oral cavity can be augmented using a speculum or gauze strips to open the mouth (Figure 8.11). A detailed examination of the oral or pharyngeal mucosa may require isoflurane anesthesia.

The oral cavity should be relatively smooth, glistening and evenly colored (white to black depending on

### ■ Making Distinctions in the Physical Examination

**Color 8.16**

Normal choanal area in a Sun Conure. Note the smooth, even color of the oral mucosa and the well defined choanal papillae (arrows).

**Color 8.17**

White-to-yellow, proliferative, diphtheritic mass on the sublingual mucosa of a pheasant. These lesions can be caused by poxvirus, bacteria, trichomonas, candida or hypovitaminosis A.

**Color 8.18**

Severe, diphtheritic inflammation of the buccal and pharyngeal mucosa in an Umbrella Cockatoo that was DNA probe-positive for PBFV virus. Cytologic evaluation of samples collected from the lesions revealed high numbers of gram-negative bacteria and yeast.

**Color 8.19**

Blunting of the choanal papillae and accumulation of mucopurulent discharge in the palatine area of a conure with hypovitaminosis A and bacterial sinusitis and tracheitis.

**Color 8.20**

**a)** Swollen, edematous, ulcerated masses associated with the buccal and pharyngeal salivary glands secondary to hypovitami-

sis A. The largest mass occluded the glottis and caused asphyxiation. **b)** normal tongue (t), laryngeal mound (l) and trachea (tr).

**Color 8.21**

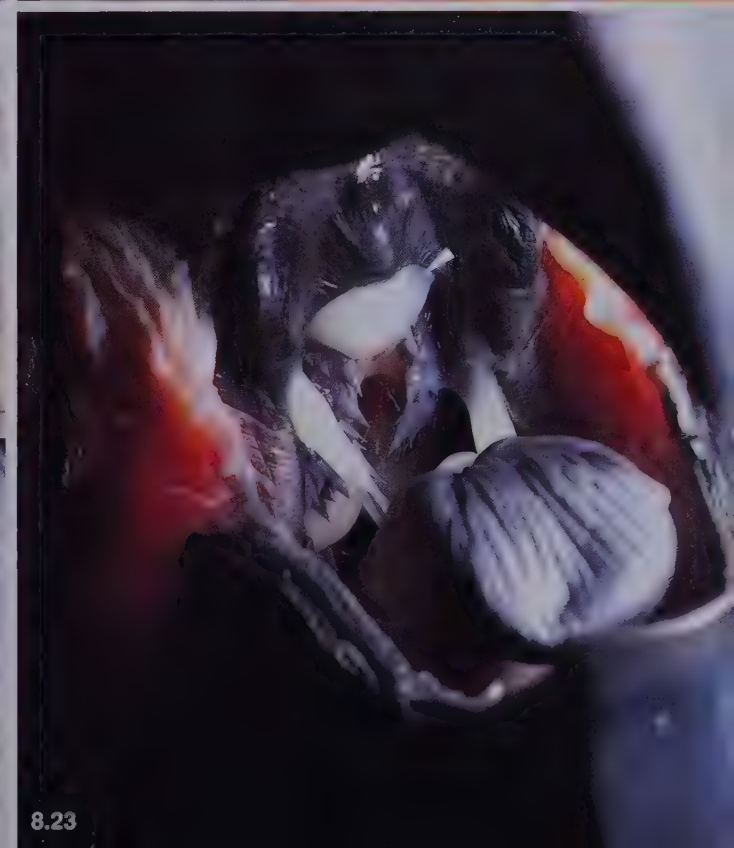
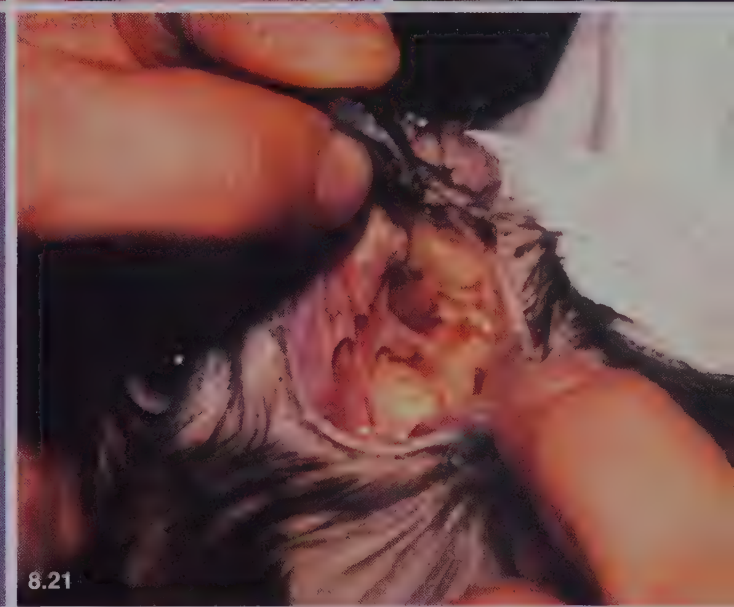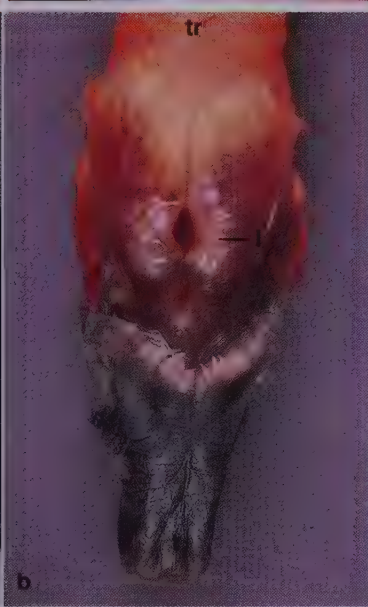
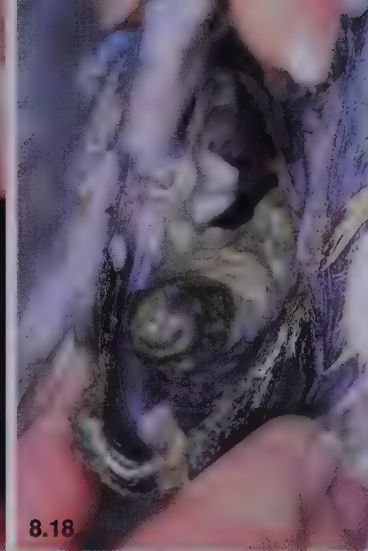
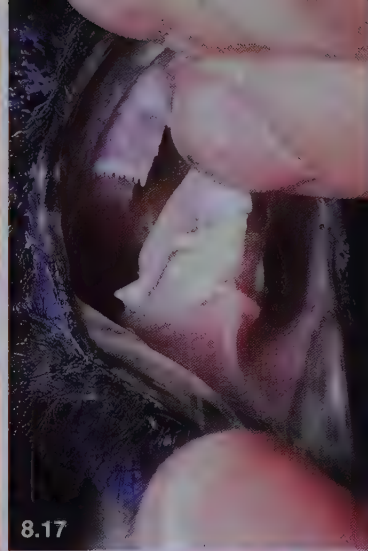

Proliferative, white-to-brown, cheesy masses on the pharyngeal mucosa of a Red-tailed Hawk. Trichomoniasis was diagnosed cytologically.

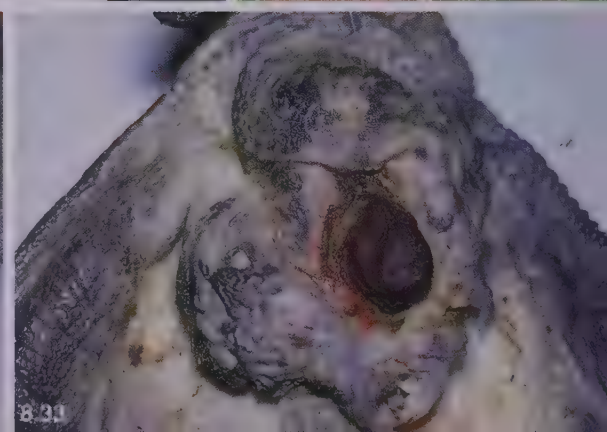
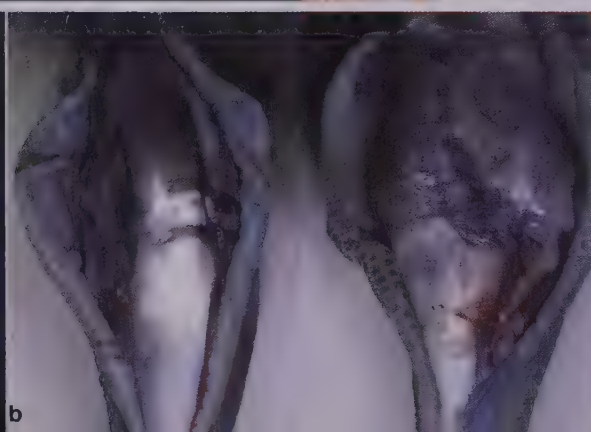
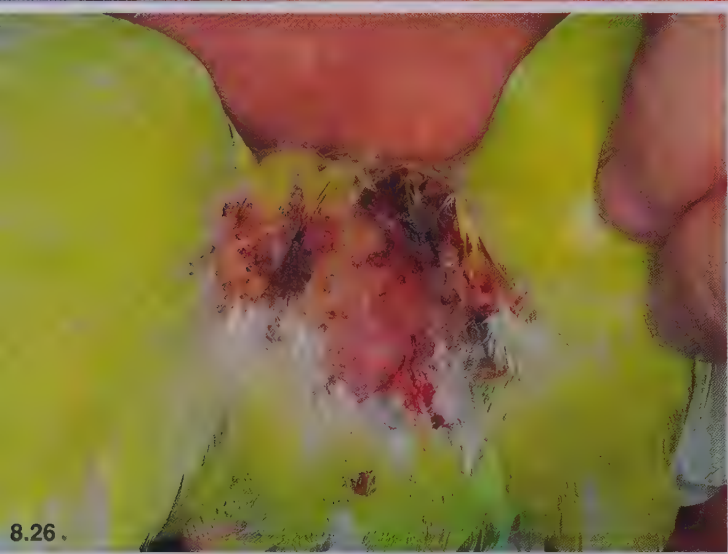
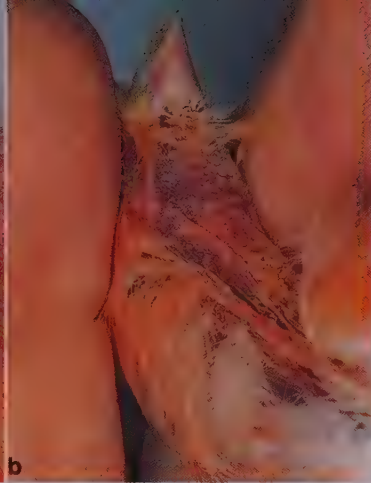

**Color 8.22**

**a)** Ulcerative lesion on the palate of a bird with choanal atresia. In addition to the deformity in the choana, this bird did not have an infundibular cleft and **b)** the lacrimal ducts were not patent (courtesy Cheryl Greenacre).

**Color 8.23**

An adult Green-winged Macaw was presented with a severe upper respiratory tract disease two weeks after being purchased from a traveling bird dealer. In addition to rhinitis, the bird also had diarrhea and mild tremors. A tenacious, mucopurulent discharge was noted in the pharyngeal area bulging from the choanal slit (arrow). The bird did not respond to supportive care. Histology indicated pneumonia, enteritis and lymphocytic perivascular cuffing in the brain.







## Making Distinctions in the Physical Examination

### Color 8.24

**a,b)** Hyperkeratosis and feather loss in a malnourished canary. The bird's feathers, skin and overall health improved when it was changed from an all-seed to a formulated diet.

### Color 8.25

Bruising, ulceration and necrosis of the cranial edge of the sternum secondary to a traumatic injury. Because the bird's wings had been improperly trimmed, the bird landed hard on its sternum on a concrete floor during attempts to fly. The trimmed flight feathers were removed to enable them to regrow. After feather regrowth, surgical debridement of the wound and removal of the necrotic portion of the sternum were necessary to correct the lesion.

### Color 8.26

Chronic ulcerative dermatitis on the back of a lovebird. Note the dry, hyperkeratotic skin at the periphery of the open, bleeding lesions.

### Color 8.27

Severe obesity in a Screech Owl that was fed obese rodents and provided no room for exercise. Note that the keel is not visible, and accumulated fat is bulging into the thoracic inlet area.

### Color 8.28

Tattoo ink is frequently injected into the prepatagium to indicate the gender of a bird following endoscopic evaluation of the gonads. Traditionally, tattoo ink is injected into the right prepatagium of males and the left prepatagium of females.

### Color 8.29

Defect in the comb, wattle and beak secondary to debeaking and a *Trichophyton* sp. (*favus*) infection. A correctly healed bird's beak (left) is shown for comparison (courtesy R. Korbel).

### Color 8.30

Proliferative mass on the head of a canary characteristic of the dry form of poxvirus. Note the ulcerations and scab formation (courtesy of Patricia Macwhirter).

### Color 8.31


A mature Amazon parrot hen was presented with a two-day history of depression and blood-tinged feces. Veterinary assistance was requested when frank hemorrhage was noted in the feces. The cloacal wall was edematous and prolapsed secondary to tenesmus caused by hemorrhagic enteritis.

### Color 8.32

**a)** Caudocranial view of the left pelvic limb of a duckling, demonstrating medial luxation of the Achilles tendon. The trochlear groove (arrow) is visible through the skin. **b)** Normal (left) hock joint and soft tissue damage (right) associated with medial luxation of the Achilles tendon (courtesy of John H. Olsen).

### Color 8.33

Proliferative, ulcerative lesion (bumble-foot) on the plantar foot surface of a swan (courtesy of John H. Olsen).



**FIG 8.9** The feathers on the head should be smooth and uniform. The ear canals can be evaluated for discharge or for abnormal accumulation of desquamated hyperkeratotic skin by parting the feathers on the side of the head.

the species) (see Color 13). Some birds (particularly Passeriformes) may have brightly colored spots in the mouth that play a role in brooding activities. The tongue has a dry sheen while the choanal slit and pharyngeal and laryngeal mucosa are slightly moist (see Color 13). Choanal papillae are well formed in some species (Amazon parrots and macaws) and less distinct or absent in other species (Color 8.16). Excessive moisture in the mouth may indicate inflammation in the oral cavity, choanal slit, sinuses or pharyngeal and laryngeal areas.

Accumulations of debris or food, abnormal coloration, erosions or ulcerations, sticky white mucus or perichoanal, pharyngeal or sublingual swellings are abnormal. White plaques that are easily removed and blunting or swelling of the choanal papillae are common with hypovitaminosis A (Color 8.20). Shallow yellow or white plaques that are attached and difficult to remove are common with pox or bacterial ulcerations (Color 8.17). White or brown cheesy lesions are suggestive of candidiasis or trichomoniasis (Color 8.21). Accumulations of desquamated hyperkeratotic epithelium, recognized clinically as small white bumps on the dorsal surface of the tongue base are common in cockatiels. Birds with these lesions are frequently infected with *Candida* sp.



**FIG 8.10** Layers of dry, flaky hyperkeratotic epidermis on the beak and around the cere are abnormal and may be a sign of malnutrition, lack of exposure to moisture and sunlight or of systemic disease (particularly hepatopathies).

A decreased jaw tone may indicate a systemic weakness. Vitamin E or selenium deficiency and giardia have been suggested as causes of this problem in cockatiels. These birds may not be able to crack seeds and frequently have poor tongue control resulting in food accumulation in the oral cavity.

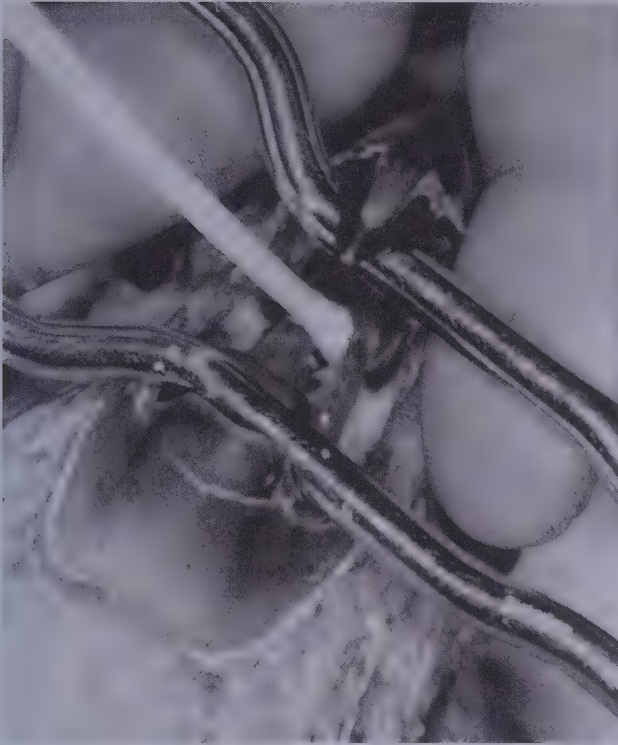
### Respiratory Tract

For examination purposes, it is easiest to divide the respiratory system into the upper respiratory tract (sinuses and trachea), lungs and lower respiratory tract (thoracic and abdominal air sacs). A bird that is in severe respiratory distress may require oxygen before it can tolerate the stress of a physical examination.

The respiratory rate should be determined before and during the hands-on physical examination (see Table 8.1). If the bird is calm and does not struggle during the physical examination, the respiratory rate will generally remain constant. In these birds, the respiratory rate should be increased by gently holding the feet and moving the hand in a downward motion. This will stimulate wing flapping and should increase the respiratory rate. In a normal bird, the respiratory rate should return to its pre-exercise rate within two minutes of ceasing the exercise. A sustained tachypnea can indicate respiratory disease, cardiovascular disease or a mass that is blocking air flow in and out of the caudal air sacs.

### Auscultation

A pediatric stethoscope is ideal for auscultating the avian lungs, heart and air sacs (Figure 8.12). Some sounds can be detected by placing the bird's body



**FIG 8.11** If a speculum is used for the oral examination, it should be firm enough to keep the mouth open but pliable enough not to damage the corneum of the beak. This is particularly true with young birds.

directly to the ear. The heart rate will vary from 45 to 600 beats per minute depending on the species and level of excitement (see Table 8.1).

Hearing a slight rush of air is normal. The sounds associated with inspiration are noted first and are typically louder and shorter in duration than those associated with expiration. The avian lungs move minimally during respiration, and detection of the respiratory clicks that are common with fluid increases in mammalian lungs is rare in birds. Detected cracks, pops, wheezes or whistling sounds are indications of severe respiratory tract abnormalities. Most abnormal respiratory sounds in birds are associated with rhinoliths, infraorbital sinusitis, tracheal stenosis or air sac disease. There may be a decrease in inspiratory sounds if a lung or air sac is consolidated. Sharp clicking sounds are occasionally noted in an apparently healthy bird that is being restrained. These sounds are thought to be caused by a subluxating joint.

#### Body Examination and Palpation

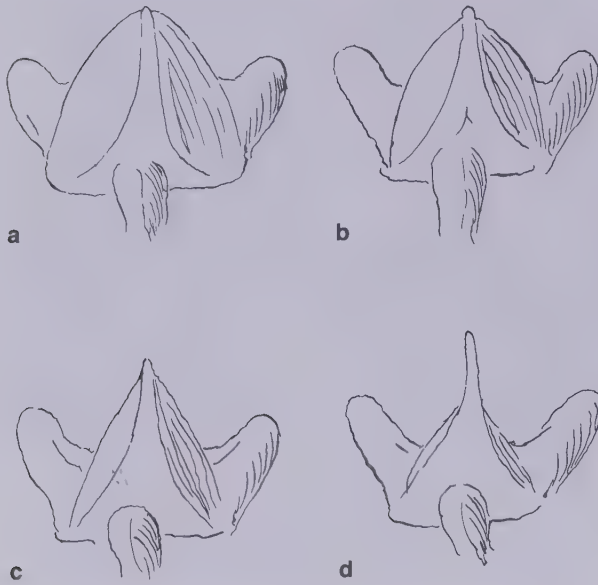
The submandibular and neck areas should be palpated, with particular attention to the esophagus and



**FIG 8.12** A pediatric stethoscope is ideal for auscultating the avian lungs, heart and air sacs. The stethoscope is first placed on the dorsal midline of the back at the level of the scapula, then moved slowly caudally and to the left and right to listen for respiratory sounds in both lungs and the thoracic and abdominal air sacs (courtesy of Cathy Johnson-Delaney).

crop. The esophagus as it extends down the right side of the neck can be palpated for swellings. Large food items (eg, grapes, vegetable chunks) may be swallowed intact and can be palpated as soft fluctuating masses. The crop is normally the largest palpable structure in the thoracic inlet. In Psittaciformes, the majority of the pendulous sac of the crop lies on or to the right of midline (see Anatomy Overlay). If distended with food, the crop can be quite large, and care should be exercised when handling the bird (particularly a neonate) to prevent regurgitation, which may lead to aspiration pneumonia. If empty, the crop and esophagus can be palpated. The crop should feel thin and striated longitudinally (see Colors 13, 19). In adult pigeons, the crop mucosa will be thickened for several weeks after a clutch hatches; this normal physiologic change should not be confused with pathology. Peristalsis of the crop is easy to observe (one to three per minute), particularly in neonates.

The crop and esophagus can be visually examined by wetting the feathers around the thoracic inlet and placing a small, high-powered light (eg, endoscope light) on one side of the crop. Using this transillumination technique, the relative thickness of the crop mucosa and its vascularity can be determined (see Color 19). If empty, expanding the crop with air and holding it in place by digital pressure on the esophagus allows improved transillumination. Thickening or increased vascularization of the crop or esophagus are indications of inflammation.



**FIG 8.13** The patient's general condition can be subjectively evaluated by palpating the pectoral muscles to determine the ratio of muscle mass to sternum. **a**) A normal adult bird should have solid, well formed, rounded pectoral muscles with a slight dip on either side of the sternum. **b,c**) The sternum becomes prominent as a bird's muscles atrophy with weight loss. **d**) A bird that has lost a substantial amount of weight has a reduced muscle mass and prominent sternum.

The patient's general condition can be subjectively evaluated by palpating the pectoral muscles to determine the ratio of muscle mass to sternum (Figure 8.13). If a slight depression is not palpable, the bird is probably overweight. The sternum should be straight, and deviations suggest malnutrition during development or a previous traumatic injury.

A bird's weight in grams should be determined with each visit. A scale that has been fitted with a perch can be used for tame birds (Figure 8.14). Most digital gram scales have a tare feature that allows a bird to be weighed in different containers. The actual weight should be compared to the estimated condition of the bird based on palpating the pectoral musculature. This will provide a clinical perspective of the ideal weight of a particular bird (see Table 30.5). For example, the weight range of Umbrella Cockatoos is 450 to 750 grams. Finding an individual bird that weighs 500 grams but is severely emaciated would indicate that this bird is abnormal even though it falls within a normal weight range. Some hens may have a thirty percent seasonal fluctuation in body weight (usually heaviest in the spring); however, these birds should never be emaciated or have clinical signs of disease.

The feathers over the sternum and abdomen should be moistened with alcohol to visually determine the amount of subcutaneous fat deposits. The abdomen should be slightly concave or flat. A convex bulging of the abdominal wall is indicative of a space-occupying mass (eg, egg, neoplasm, ascites, enlarged organ).


Abdominal organs are difficult to palpate in birds, particularly in small species; however, the ability to palpate unusual structures in the abdomen can provide important information. Normally, the abdomen should be flat, tight and slightly concave in the center. With liver enlargement, ascites, proventricular or ventricular distension or displacement, egg development, egg-related peritonitis or mass formation, the abdomen may appear distended, doughy and convex. The right liver lobe extends farther caudally than the left and can be detected most easily if enlarged (see Color 20). Gentle palpation under the caudal edge of the sternum should not be painful, and if a bird responds to this procedure it could indicate hepatitis. Palpation on a bird with a swollen abdomen should be performed gently. If fluid is present in the peritoneal space and an air sac is ruptured by excessive digital pressure, fluid can rush into the lungs causing asphyxiation. Extra-abdominal wall swellings caused by hernias or lipomas may be visualized and palpated.

In a well muscled, low-body-fat canary or finch the abdominal musculature is almost transparent, and portions of the gastrointestinal tract and liver (especially with hepatomegaly) can be visualized.

### Cloacal Area

A pericloacal accumulation of excrement may indicate enteritis or polyuria or can be associated with cloacal dysfunction (Figure 8.15). If the dried excrement and associated feathers have formed a solid mass that is partially or totally preventing defecation, a bird may produce a voluminous, malodorous stool when the dried excrement is removed. The pericloacal feathers of a bird with chronic biliverdinuria are often stained greenish or greenish-yellow (see Color 20).

Inspection of the cloacal mucosa can be accomplished using a moistened cotton-tipped applicator. The applicator is gently inserted into the cloaca and slowly withdrawn while pushing the tip to one side. As the applicator is withdrawn, the cloacal mucosa will protrude through the vent. Alternatively, the cloaca may be examined by bending the bird's tail over its back



**FIG 8.14** A bird's weight in grams should be determined with each visit. A scale that has been fitted with a perch can be used for tame birds. Small birds can be temporarily disoriented by moving them in several rapid, large circles. This procedure will provide the necessary time to obtain their weight using a digital scale.

and gently pinching the sides of the cloaca to expose the mucosa (Figure 8.16).

The cloacal mucosa should be carefully checked for papillomatous growths. Five percent acetic acid (apple cider vinegar) will cause papillomatous tissue to turn white and can facilitate visualization of subtle lesions. In most species, tissue should not protrude from the cloaca. The cloaca may be distended and partially everted if the bird has a developing egg, cloacal mass (eg, papilloma, fecalith), tenesmus or is constipated. Protruding tissue can be colon, uterus, ureter or cloacal wall (Color 8.31). The cloaca normally everts in reproductively active Vasa Parrots.

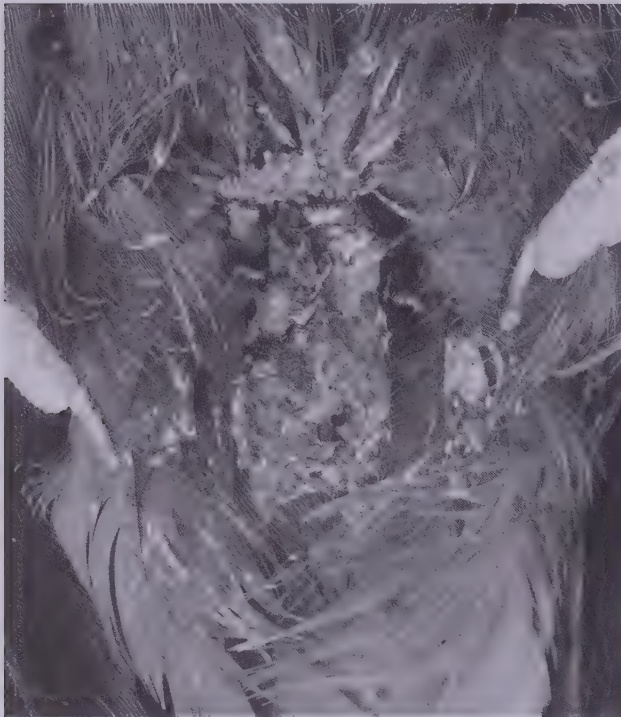The openings of the urinary, gastrointestinal and genital tracts can be examined using an otoscope cone, vaginal speculum, human nasal speculum or endoscope. This procedure induces some level of discomfort and is best performed in an anesthetized bird. In sexually mature hens, the cervix may be observed in the left lateral wall of the urodeum (see Anatomy Overlay).

The uropygial gland, located dorsal to the cloaca at the end of the pygostyle, is well developed in some species (canaries) and absent in other species (Amazon parrots). If present, the gland should be smooth, evenly colored and contain a small amount of yellow, creamy material (see Figure 24.7). A change in the surface structure of the gland, a loss of feathers or a discolored discharge should all be considered abnormal. Infections and neoplasia are the two most common causes of abnormalities. Malnourished birds may have excessively dry, brittle feathers and skin that can spontaneously rupture, particularly in the postventer region (see Figure 24.20).

The internal temperature of a bird can vary from 107 to 112°F and temperatures often elevate rapidly during periods of stress. The temperature of a bird is not routinely determined during the physical examination because the procedure provides little valuable information and danger is associated with forcibly passing a thermometer through the cloacal wall. Tympanic thermometers are being clinically evaluated.

### Wings, Legs and Feet

The bones and some of the musculature of the wing can be directly visualized for signs of bruising, swelling or fractures by wetting the surface of appendages with alcohol. Green discoloration (bruising) of subcutaneous tissues usually represents the breakdown of extravascular hemoglobin. In general, it takes about





**FIG 8.15** The pericloacal area of a normal bird is clean and dry and has minimal feather discoloration. A combination of feces and urates may adhere to the cloacal rim and the surrounding feathers. This pericloacal accumulation of excrement may indicate enteritis or polyuria or can be associated with cloacal dysfunction.

two days after a traumatic event for this green color to appear, providing the clinician with an indication of the chronicity of an injury.

Hemorrhagic, necrotic dystrophic feather shafts are an indication of damage to the developing feather that can be caused by a number of infectious or metabolic problems (see Color 24). Mites may be observed moving on the underside of the wing or the nits may be attached to the feather vanes (see Color 48). Increased translucency, color alterations or structural changes in the flight feathers can be an indication of malnutrition or mismanagement. The ventral surface of the wing and pro lateral region are common locations for feather picking in cockatiels, African Grey Parrots, cockatoos, Grey-cheeked Parakeets and Quaker Parrots (see Color 24). The presence of splintered or damaged feather shafts may indicate that a bird is preening excessively or feather picking (see Chapter 24).

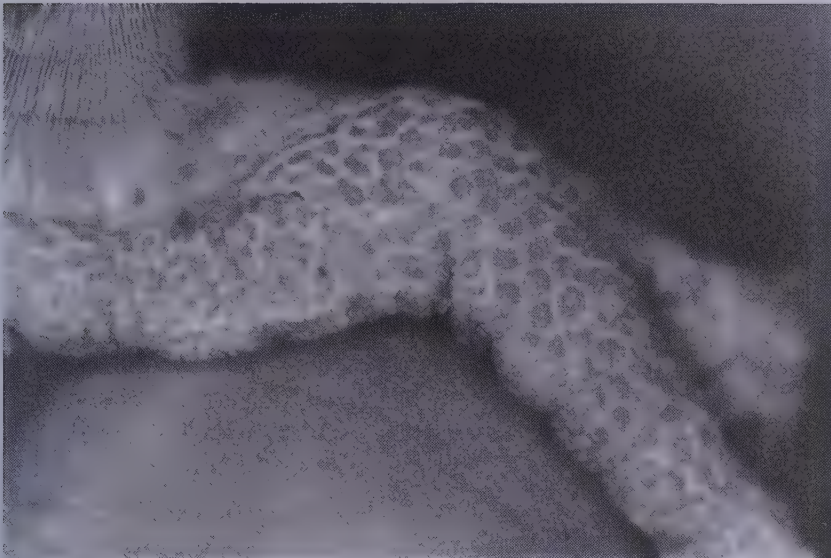
Ulnar vein turgidity and skin consistency on the neck, abdomen and dorsal surface of the digits can be used to evaluate the hydration status of the bird. Flat veins that do not immediately refill when depressed



**FIG 8.16** Inspection of the cloacal mucosa can be accomplished by bending the bird's tail over its back and gently pinching the sides of the cloaca to expose the mucosa. The cloacal mucosa in a normal bird is pink, evenly colored, slightly moist and smooth.

may indicate hypoproteinemia, anemia, dehydration or shock.

The feet and legs should be uniform in texture and color. The feet should have prominent scale patterns on both the dorsal and plantar surfaces (Figure 8.17). Changes that result in smoothing of the plantar foot surface can instigate chronic and severe foot and leg problems (Color 8.9). Common etiologies of foot abnormalities include hypovitaminosis A, a lack of sunlight, contact with nicotine sulfate (from the hands of cigarette smokers) and improper perches (eg, size,

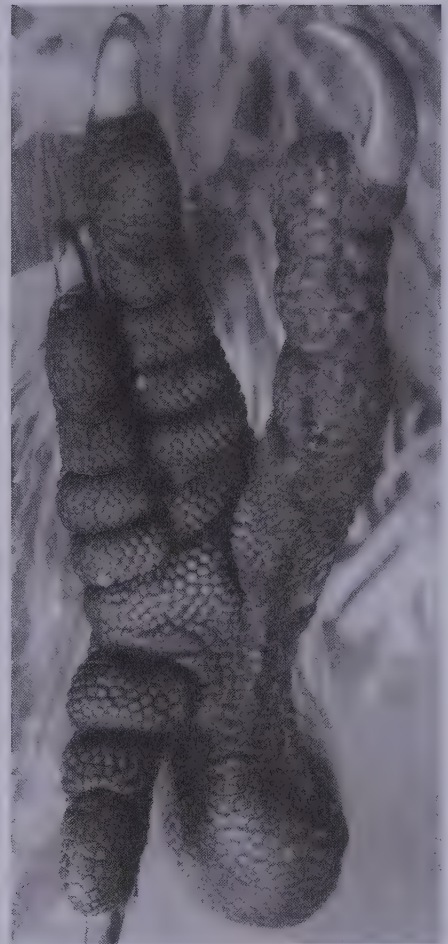

**FIG 8.17** The feet and legs should be uniform in texture and color. The feet should have prominent scale patterns on both the dorsal and plantar surfaces. Flaking, balding, cracking, hemorrhage and peeling of the skin on the feet are all signs of abnormalities.

texture or firmness). Any ulcerative lesion or swelling of the feet should be addressed immediately. Ulcerative lesions can rapidly become infected (bumblefoot) and can be life-threatening if infectious agents invade associated tendon sheaths and bones (Color 8.33). Bacteremia is common in many birds with ulcerative lesions on the feet. The accumulation of exfoliated, dried hyperkeratotic scales is common in malnourished Passeriformes (see Chapter 24). Proliferative lesions on the feet of canaries (tasselfoot) are common with knemidokoptes infections (see Color 24).

The length of a bird's nails should be evaluated and the client should be instructed to carefully monitor the nail growth at home. Overgrown nails are common in birds with hepatopathies and can result in trauma to the fat pads (inducing bumblefoot) or entanglement in enclosures or toys. Hemorrhage in unpigmented nails is an indication of trauma or liver disease.

A weak grip can indicate systemic weakness or specific neuromuscular disease of the feet or legs (see Chapter 28). Leg paresis, ataxia and muscle atrophy may occur in birds with abdominal tumors. This lameness is typically the result of tumors that place pressure on the ischiatic nerve. Unilateral lameness is most common, but bilateral lameness may also occur. Bilateral lameness can also be a direct result of primary neural lesions (eg, aspergillosis, Marek's



disease virus, lymphoid leukosis, spinal injuries, vitamin E or selenium deficiencies and B vitamin deficiencies).

Once the physical exam is completed, the minimum database can be collected. The decision of which test to perform is based on the condition of the patient. For the most accurate results, blood samples for CBC and biochemistries should be drawn when a bird is not stressed. Leaving a bird in a dark clinic overnight so that blood may be drawn the first thing in the morning may be the best solution (Table 8.4).

**TABLE 8.4** Suggested Ideal Examination Database for Medium and Large Psittacines

▪ Physical examination	▪ Radiographs
▪ Body weight	▪ Fecal Gram's stain
▪ CBC	▪ Chlamydia testing
▪ Biochemistries - TP, Glucose, CA, AST, LDH, CPK, UA, Bile Acids	▪ DNA probe testing for PBFD virus, polyomavirus

## ■ Making Distinctions in the Physical Examination

### Color 8.34

Normal excrement from a conure. Note the green fecal component, white urate component and clear, liquid urine component, typical of a bird on a formulated diet with limited fruits and vegetables.

### Color 8.35

Clay-colored, voluminous feces in an Amazon parrot with maldigestion/malabsorption syndrome.

### Color 8.36

Yellow discoloration of the urates is suggestive of hepatitis. The consumption of some yellow-pigmented vegetables and administration of parenteral B vitamins can cause a similar discoloration of the urates. In this case, biliverdinuria was present secondary to Pacheco's disease virus-induced hepatocellular necrosis. The volume of urates and lack of feces are indicative of anorectic disorders.

### Color 8.37

Polyurates and polyuria in a bird with pancreatic or bile-related renal disease.

### Color 8.38

Biliverdinuria and liquid diarrhea in an African Grey Parrot with chlamydiosis.

### Color 8.39

Variation in the color, quantity and consistency of the excrement passed by a normal Amazon parrot in a six-hour period. These illustrate the effects of stress on the nature of the excrement.

### Color 8.40

Variance in the color, form and consistency of excrement from a normal King Pigeon.

### Color 8.41

Biliverdinuria and polyuria in a cockatoo with bacterial septicemia and hepatitis.

### Color 8.42

A five-square-inch area of the bottom of an Amazon parrot's enclosure. The enclosure substrate had been changed 24 hours earlier. The grouping of the excrement indicates that the bird had remained in the same location. A scant quantity of feces is present in the oldest droppings, but the more recent droppings (consisting exclu-

sively of urates) suggest that the bird has been anorectic for at least 24 hours.

### Color 8.43

A mature Yellow-collared Macaw was presented as an emergency for an acute onset of bloody diarrhea. The bird was bright, alert and responsive. The suspected "hemorrhage" was caused by red dyes on the underside of the newsprint "bleeding" through.

### Color 8.44

A cockatiel was presented for emergency evaluation of what the client described as bloody diarrhea. The bird was bright, alert and responsive. The bird had consumed a substantial quantity of fresh blackberries approximately two hours before presentation, and the abnormal color of the excrement was caused by pigments in the blackberries.

### Color 8.45

Frank hemorrhage in an Amazon parrot hen with an ovarian adenocarcinoma, hepatitis and bacterial enteritis.

### Color 8.46

Bluish discoloration of the excrement secondary to blueberry ingestion.

### Color 8.47

Discoloration of the feces and polyuria in a Blue and Gold Macaw that consumed several large slices of sweet potato.

### Color 8.48

A four-year-old Yellow-naped Amazon Parrot was presented for anorexia, depression and straining to defecate. A fecal occult blood test was positive. A Gram's stain of the feces and results of a glucose test and clotting time were normal. Hematology indicated a decreased WBC with a mild left shift. Radiographs indicated metallic densities in the ventriculus, and the bird responded to treatment with CaEDTA.

### Color 8.49

Severe hematochezia in a mynah bird with bacterial enteritis. Abnormal clinicopathologic findings included TP=3.2, PCV=12.

### Color 8.50

A 23-year-old obese Amazon parrot was presented with a one-day history of passing

unclotted blood. Radiographs indicated a soft tissue density that originated near the cranial division of the kidney and extended ventrally into the abdomen. Polyostotic hyperostosis was also evident. The bird did not respond to supportive care. Histopathology indicated severe fatty liver degeneration, bacterial septicemia and ovarian cysts.

### Color 8.51

Air bubbles are frequently present in the feces of birds with diarrhea.

### Color 8.52

"Slug-like" excrement in a caique with pancreatic exocrine insufficiency.

### Color 8.53

Polyuria in a Blue and Gold Macaw chick being fed a standard monkey biscuit-based formula. Polyuria is common in birds fed diets containing a high moisture content.

### Color 8.54

Polyuria and discolored excrement in a bird with mucoid enteritis.

### Color 8.55

Diarrhea, biliverdinuria and polyuria in an Amazon parrot with Pacheco's disease virus-induced hepatitis.

### Color 8.56

Normal excrement in a stressed Umbrella Cockatoo hen. The excrement was one of several with greenish discoloration of the urates caused by bile pigments passing in the urine due to increased heart rate and kidney overload.

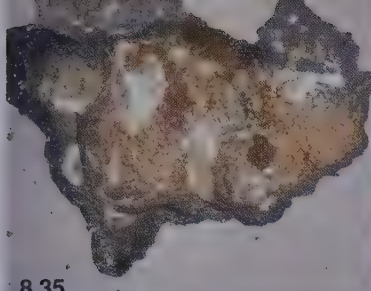
### Color 8.57

Undigested seeds that are a component of the feces (right) must be differentiated from seeds that have fallen onto the feces. This cockatiel had neuropathic gastric dilatation.

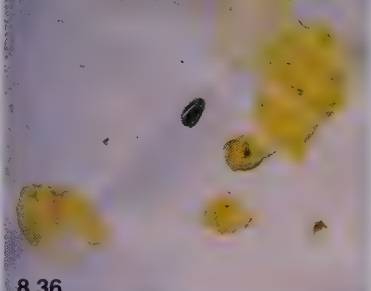
### Color 8.58

Vomitus from a Severe Macaw with neuropathic gastric dilatation. Note the frothy nature of the material and the chunks of undigested seeds. The pH of the material was 2.6, confirming that it had originated from the proventriculus.







8.35



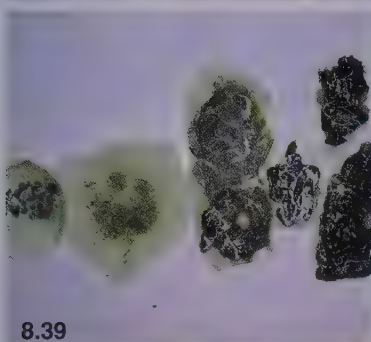
8.36




8.37




8.38




8.39



8.40



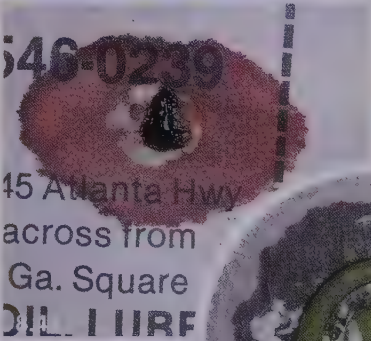
8.41




8.42



8.43



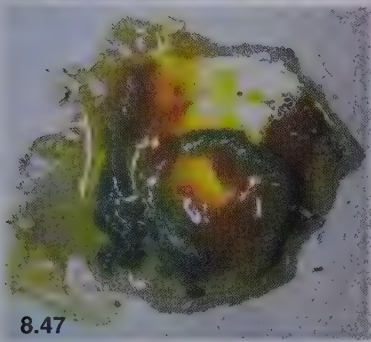
8.44




8.45



8.46




8.47



8.48




8.49



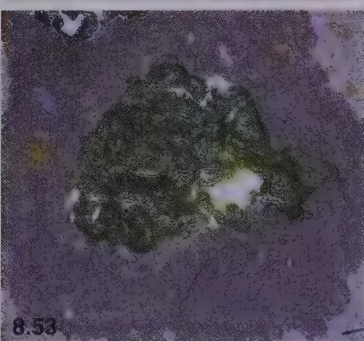
8.50




8.51




8.52



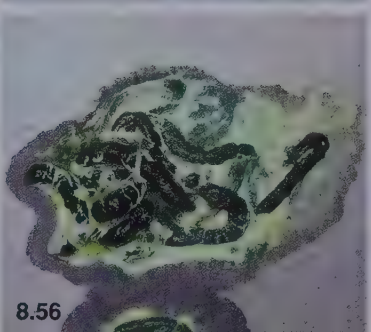
8.53



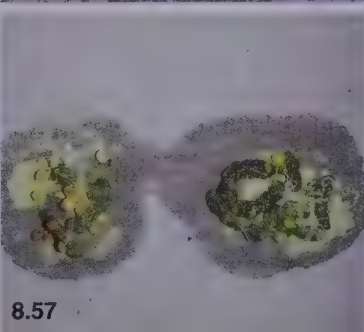
8.54




8.55




8.56



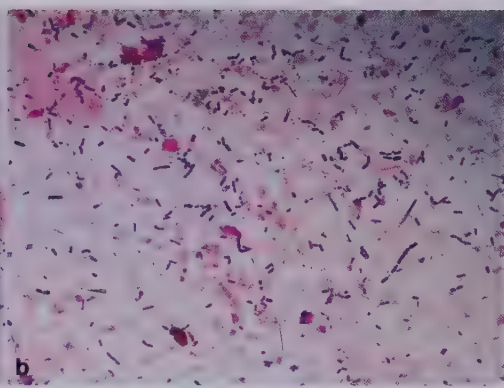8.57



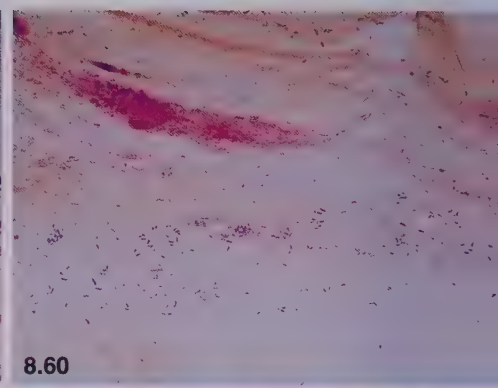
8.58



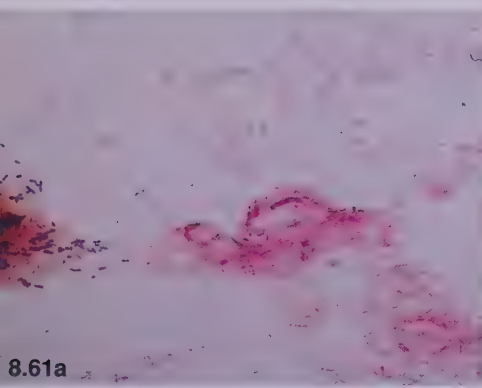
8.59a



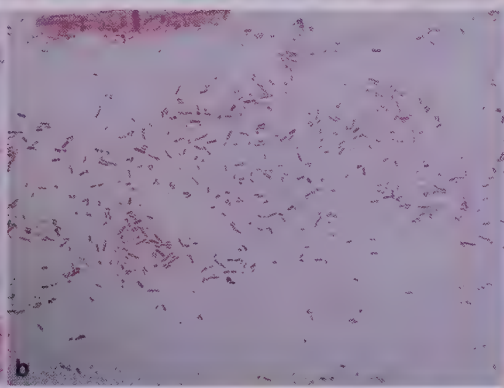
b



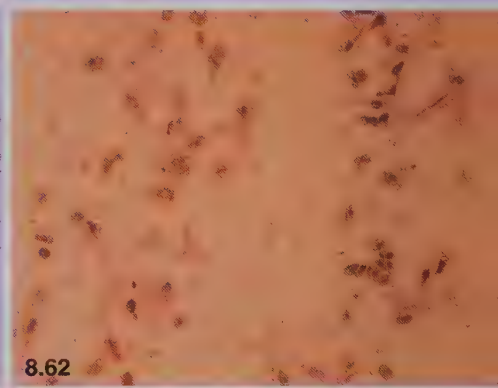
8.60



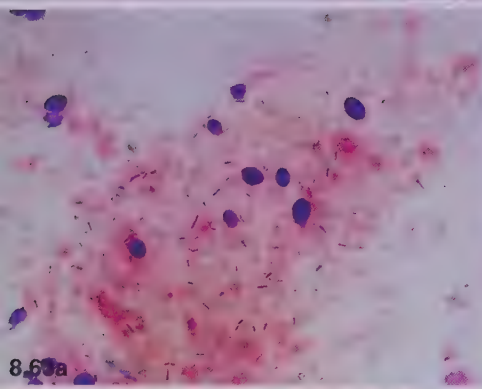
8.61a



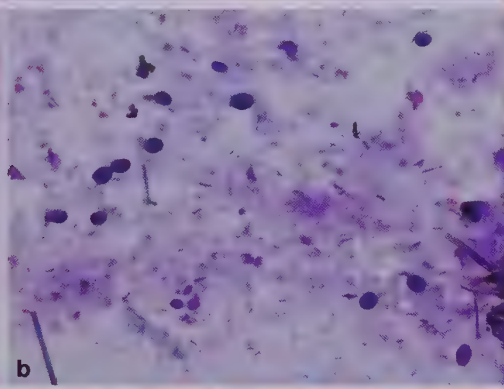
b



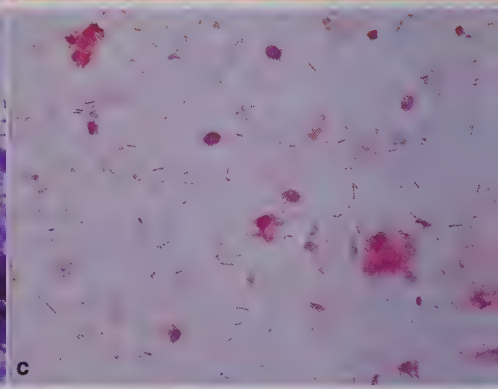
8.62



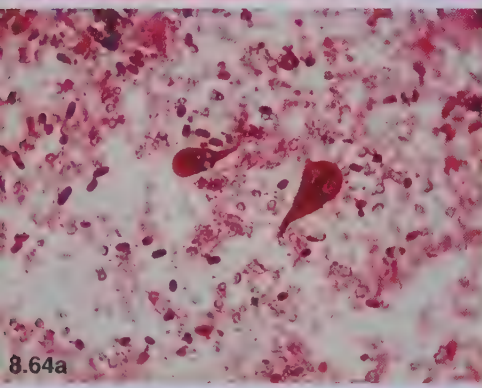
8.63a



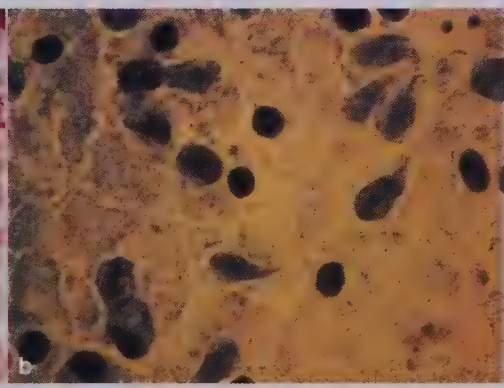
b




c



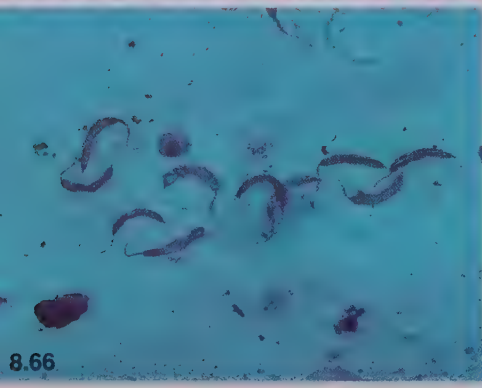8.64a



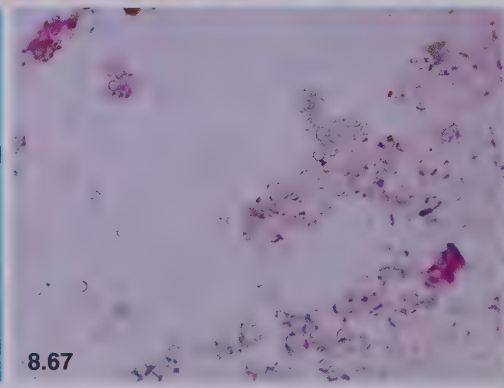
b



8.65



8.66



8.67



8.68

### Making Distinctions in the Physical Examination

#### Color 8.59

Gram's stain of samples collected from the **a)** crop and **b)** feces of a normal Umbrella Cockatoo. Note that the bacterial population consists primarily of gram-positive rods and cocci; no gram-negative bacteria or yeast are present. The red material represents normal undigested dietary components.

#### Color 8.60

Gram-positive bacteria and epithelial cells collected from the choanal slit of a clinically asymptomatic Amazon parrot. Although the choanal slit is normally free of gram-negative bacteria, transitory gram-negative rods in the pharynx are common. A repeat Gram's stain should be performed several days after potential sources of gram-negative bacteria have been removed from the diet.

#### Color 8.61

Gram's stain of the **a)** crop and **b)** feces of an Amazon parrot with depression, vomiting and diarrhea. Note the predominance of gram-negative rods suggestive of a bacterial enteritis. If a Gram's stain is improperly performed, gram-positive rods can appear as though they are gram-negative. To avoid the misinterpretation of an improperly stained sample, it is important to scan the entire slide and make certain that both gram-positive and gram-negative organisms can be identified. A Gram's stain checking system (Gram Q-Chek, Fisher Scientific) is available for quality control of the stains and procedure.

#### Color 8.62

Wright's stain of feces from a budgerigar with severe weight loss. Note the large rod-shaped organisms suggestive of megabacteria. Nucleated RBC's are also present.

#### Color 8.63

**a)** Gram's stain of feces from a clinically normal Blue and Gold Macaw chick. The blue-staining masses are characteristic of yeast. Note that the yeast are not budding. This bird was being fed a diet containing brewer's yeast. These nonpathogenic yeast are frequently passed in the feces and should not be misinterpreted as a fungal enteritis. **b)** Gram's stain of the crop in a Moluccan Cockatoo chick presented for regurgitation and weight loss. Note the budding yeast suggestive of an active *Candida* sp. infection. Detecting an abnormally high number of yeast in the crop or feces is an indication that a bird is immunosuppressed. **c)** Yeast should stain gram-positive. Finding gram-negative staining yeast is an indication that the staining process was improperly performed. Non-viable yeast that have been killed with antifungal therapy will appear as clear halos against the stained background.

#### Color 8.64

**a)** Carbofuschin or **b)** iodine stains can be used to detect *Giardia* sp. trophozoites in the feces (courtesy of Bob Dahlhausen).

#### Color 8.65

Gram-negative bacterial rods (magnified) from a conure with hemorrhagic enteritis.

#### Color 8.66

Sperm from a budgerigar detected during a routine Gram's stain evaluation of the excrement.

#### Color 8.67

Urate crystals are frequently found during microscopic examination of the feces.

#### Color 8.68

Stain precipitates and strands of cotton from a swab will appear as large, amorphous, gram-positive masses.

CHAPTER

# 9

## HEMATOLOGY

Terry W. Campbell

**E**valuation of the avian hemogram involves counting the various blood cells per microliter of blood as well as cytologic evaluation of the cells. The techniques involved in the evaluation of the avian hemogram are easily performed by in-house veterinary laboratory personnel. Because avian blood does not store well (eg, during transport), hematologic results obtained soon after collection are preferred over those performed several hours later.<sup>6,18,34</sup>

Blood volume in birds depends on the species and varies from 5 ml/100g in the Ring-necked Pheasant to 16.3 to 20.3 ml/100g in the racing pigeon. In general, birds are better able to tolerate severe blood loss than mammals, which is due to their greater capacity for extravascular fluid mobilization. However, there is a marked variation among avian species in response to blood loss, which may be a reflection of differences in blood volume or extravascular fluid depots. In healthy Mallard Ducks and racing pigeons, a blood volume equivalent of up to three percent of the body weight can be collected. In Passeriformes, pheasants and Psittaciformes, up to one percent of the body weight can be collected with few ill effects (0.9 ml from a 90 g cockatiel).

Blood can be collected from a variety of sites in avian patients. The choice of a blood collection site is influenced by the species of bird, preference of the collector, physical condition of the patient and volume of blood needed. For best results, venous blood should be collected for hematologic studies. Blood collected from capillaries (eg, blood from clipped nails) often results in abnormal cell distributions and contains cellular artifacts such as macrophages and material not normally found in peripheral blood (Figure 9.1). Blood to be used for hematology should be collected into a collection tube containing EDTA (ethylenediaminetetraacetic acid) as the anticoagulant. Other anticoagulants, such as heparin, interfere with cell staining and create excessive cell clumping, resulting in erroneous cell counts and evaluations (Color 9.3)<sup>6,18,34</sup>

## Processing the Avian Hematologic Sample

### Blood Collection

Jugular venipuncture is a procedure that can be used for collecting blood from most avian species.<sup>6,18,34,38,71</sup> It is the method of choice for small birds that do not have other blood vessels large enough for venipuncture. The right jugular vein is usually chosen over the left for blood collection because in many birds it is the larger of the two. To collect blood from the jugular vein, the bird is properly restrained with the head and neck extended (Figure 9.2). Extending the neck encourages the highly movable jugular vein to fall into the jugular furrow. In many species, there is a featherless tract of skin (apterium) overlying the jugular vein; therefore, lightly wetting the feathers with alcohol in this area will aid in the visualization of the vein. Blood is collected into a syringe, and the size of needle is governed by the size of the vein. Complications of jugular venipuncture include difficulty in proper restraint of the bird or stabilization of the vein and hematoma formation. Improper attention to technique and hemostasis can cause a large hematoma to form during or following jugular venipuncture. However, jugular venipuncture becomes a skill perfected with practice, and complications are infrequent in skilled hands.

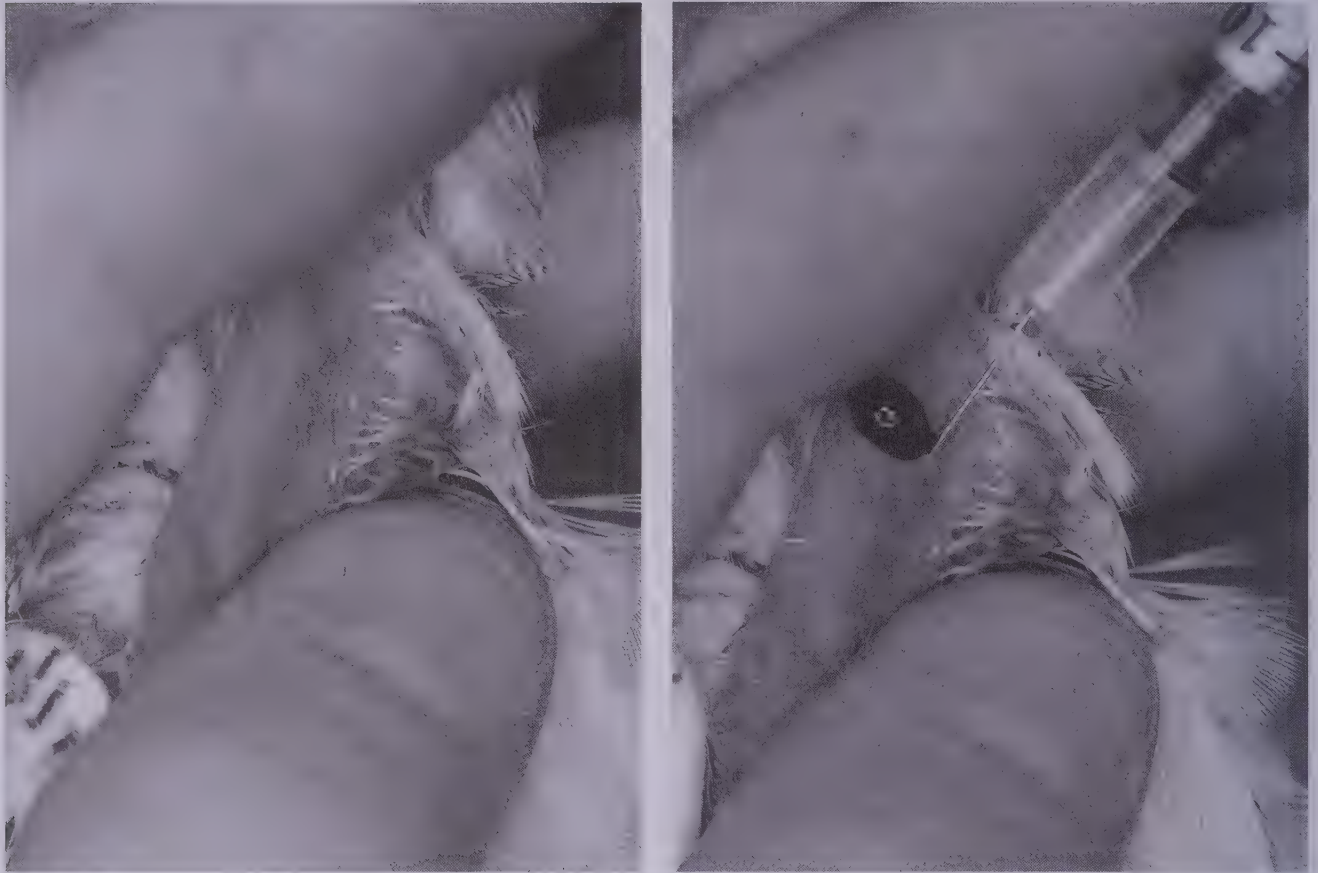
Venipuncture of the cutaneous ulnar or wing vein is a common method for obtaining blood from medium to large birds. A needle is inserted into the vein, which is found crossing the ventral surface of the humero-radioulnar joint (elbow) (Figure 9.3). Blood is either aspirated into a syringe or allowed to drip from the needle hub into a microcollection device. Collecting blood in this manner reduces but does not eliminate hematoma formation. A variety of these devices is available.<sup>a-c</sup> These collecting tubes contain EDTA for hematology studies, are plain (with or without a serum separator) or contain heparin (lithium heparin is the preferred form) for blood chemistry studies. Hematoma formation, which can be severe, is common when the ulnar vein is used for blood collection. A needle with an extension tube, such as a butterfly catheter,<sup>d</sup> aids in stabilization during sample collection to minimize tearing of the vein.



**FIG 9.1** Blood for hematologic evaluation should be collected from a free-flowing venous source. Blood collected from a toenail clip may yield abnormal cell distributions and cellular artifacts.

Venipuncture of the medial metatarsal (caudal tibial) vein, which lies on the medial side of the tibiotarsus at the tibiotarsal-tarsometatarsal joint, is another common method for blood collection in medium to large birds (Figure 9.4).<sup>6,18</sup> The primary advantages of this method over other methods of blood collection is that the surrounding leg muscles protect the medial metatarsal vein from hematoma formation and, in some species, the leg is more easily restrained than the wing.

Blood can be collected from the occipital venous sinus of birds. This technique should be reserved for birds used in research or for blood collection prior to euthanasia,<sup>6,78</sup> because of the potential for injuring the brainstem. When properly executed, however, this method can be safely used for collecting repeated blood samples from birds. The bird must be completely restrained. The head is held firmly in a flexed position in a straight line with the cervical vertebrae. The occipital venous sinus is just below the skin in the space between the base of the skull and the first cervical vertebra. To collect blood from this sinus, an evacuated tube with needle and holder is required. The needle is passed through the skin at a 30 to 40° angle to the cervical vertebrae on the dorsal midline just above the sinus. Following penetration through the skin, the evacuated tube is advanced in the holder, allowing penetration of the tube stopper by the needle within the holder. The needle is advanced slightly downward to penetrate the venous sinus.




**FIG 9.2** The right jugular vein (left) is the preferred site for blood collection in most species of birds. The vessel is easy to visualize and is larger than the left jugular vein. The neck and head are held in extension, and the mid-cervical area is lifted slightly to improve the angle for venipuncture. The vessel is occluded at the thoracic inlet (right) to facilitate distention and blood collection. Note the featherless tract (apterium) overlying the right lateral neck and jugular furrow. The vessel can be entered from either a cranial or caudal direction.

When this occurs, blood will rapidly fill the evacuated tube. Cardiac punctures should be used only for blood collection prior to euthanasia.<sup>1,45,77</sup>

### ■ Laboratory Techniques

After the blood is collected, a blood film is made. The film can be made either from blood containing no anticoagulant (especially if blood parasites are suspected) or blood containing EDTA. EDTA will cause hemolysis of erythrocytes in some birds including Corvidae, currasows, Crowned Cranes, hornbills and Brush Turkeys. Prolonged exposure to EDTA may result in increased disruption of cells in the blood film in some species (Color 9.3). Therefore, when using an anticoagulant, a blood film should be made immediately following blood collection. Heparin should be avoided whenever possible for hematologic studies. Heparinized blood contains artifacts such as clumping of cells (especially leukocytes in counting

chambers) and frequently results in staining artifacts (Color 9.3).<sup>6,34</sup> When preparing a blood film, the standard two-slide wedge technique used in mammalian hematology usually works well with avian blood.<sup>6,12,67</sup> It is advisable to use precleaned, beveled microscope slides to minimize cell damage during preparation of blood films. Peripheral blood films can also be made using a two-coverglass technique. A drop of blood is placed in the center of one coverglass;<sup>16,17</sup> a second coverglass is placed on top of the first, and the two are pulled apart as the blood begins to spread between the two surfaces. A similar technique using a microscope slide and a rectangular coverglass (24 mm x 50 mm) can be used to prepare a film on a microscope slide rather than on coverglasses, making the sample easier to stain.<sup>6,18</sup> Using the two-coverglass or microscope slide-coverglass methods should be considered if the standard two-slide wedge technique creates excessive smudging of the cells. Most veterinarians and technicians accus-



**FIG 9.3** The cutaneous ulnar vein should be considered an inferior site to the right jugular vein for blood collection. The vessel (top) is easy to access on the ventral surface of the wing, but hematoma formation is common. Note that the bevel of the needle is up and the brachial vein is being occluded with the thumb. A small gauge needle (bottom) is used to minimize hematoma formation and is threaded into the vessel to decrease “wobble” and endothelial damage from the needle tip.

tomed to performing the two-slide wedge technique with mammalian blood have little difficulty in using the same technique to prepare proper avian blood films.

A variety of hematologic stains can be used to evaluate the air-dried blood film. Romanowsky stains, such as Wright’s, Giemsa, Wright-Giemsa, Wright-Leishman or May-Grunwald and their combination, are preferred<sup>6,18,34</sup> (see Chapter 10). Wright’s stain

has been the standard in veterinary hematology, and all cell descriptions and illustrations used in this text are based upon that stain. These descriptions also apply to a great extent to the other commonly used quick stains, which essentially are modifications of the classic Wright’s stain procedure.<sup>e,f</sup> The use of an automatic slide stainer<sup>g</sup> simplifies the staining procedure and provides a means for consistency and high quality staining by removing variations that occur with hand-staining procedures.

After making a blood film, the remainder of the blood sample is used to obtain a packed cell volume (PCV), hemoglobin concentration and cell count. The PCV is obtained by centrifuging a microhematocrit tube full of blood at 12,000 G for five minutes. The hemoglobin concentration is measured spectrophotometrically by using the manual or automated cyanmethemoglobin method after centrifugation removal of free red cell nuclei and membrane debris.

The red blood cell (RBC) count is obtained either by automated or manual methods. The automated cell counters<sup>h</sup> provide a quick, reliable method for obtaining a RBC count in birds. The two manual methods that can be used are the erythrocyte Unopette system<sup>i</sup> (standard method in mammalian hematology) or Natt and Herrick’s method. The latter method requires the preparation of a methyl violet 2B diluent.<sup>55</sup> A 1:200 dilution of the blood is made using this solution and a diluting pipette. After mixing, the diluted blood is discharged into a

Neubauer-ruled hemacytometer and the cells are allowed to settle to the surface for five minutes before enumeration. The red blood cells are counted using the four corner squares and one central square of the central large primary square of the hemacytometer. The number of red cells counted is multiplied by 10,000 to obtain the RBC count per microliter of blood. Appropriate secondary squares are counted on each grid and the counts are averaged.



**FIG 9.4** The medial metatarsal vein can be used to collect smaller quantities of blood from medium- to large-sized birds. This vessel is supported by the soft tissues of the leg and in comparison to other blood collection sites, hematoma formation is rare (courtesy of Kathy Quesenberry).

The mean corpuscular values can be calculated using the PCV, hemoglobin and RBC count values. The mean corpuscular volume (MCV) and mean corpuscular hemoglobin concentration (MCHC) are useful in the characterization of the erythrocytes, especially in the evaluation of anemia.

$$\text{MCV} = \frac{\text{PCV} \times 10}{\text{RBC count}}$$

$$\text{MCH (pg)} = \frac{\text{Hemoglobin} \times 10}{\text{RBC}}$$

$$\text{MCHC} = \frac{\text{Hemoglobin} \times 100}{\text{PCV}}$$

A reticulocyte count can be useful in the evaluation of the red cell regenerative response. The erythrocytes are stained with a vital stain, such as new methylene blue stain, and the reticulocytes are identified as red blood cells that contain distinct rings of aggregated reticulum encircling the cell nucleus (Color 9.1).<sup>6,34</sup> Other erythrocytes may contain varying amounts of reticulum, but those with the distinct ring of aggregated reticulum surrounding the cell nucleus appear to be cells that have recently entered the peripheral circulation, and thus reflect the current regenerative response.

The white blood cell (WBC, leukocyte) count of birds is obtained using manual techniques because the presence of nucleated erythrocytes and thrombocytes

interfere with the counting of white blood cells using electronic cell counters. The current methods of choice for obtaining a total leukocyte count in birds are the indirect method using the eosinophil Unopette brand 5877 system or the direct leukocyte count using Natt and Herrick's method.<sup>6,13,18,55</sup> Estimation of leukocyte numbers from a blood film should be reserved for those occasions when a quantitative count is unavailable or when there is suspicion of error in a value obtained from the other methods.

The indirect eosinophil Unopette brand method involves the filling of the 25  $\mu\text{l}$  pipette with blood, mixing the blood with the phloxine B diluent in the vial provided in the system and charging the hemacytometer chamber for cell counting. The blood-phloxine mixture should not be allowed to stand in the Unopette vial for longer than

five minutes or erythrocytes may also be stained. The charged hemacytometer should stand undisturbed for at least five minutes to allow the cells to settle to the surface of the counting grid. It is advisable to keep the charged hemacytometer in a humid chamber to prevent dehydration of the sample if the chamber is going to sit for longer than five minutes. The granulocytes that stain distinctly red (heterophils and eosinophils) are counted in both sides of the hemacytometer (representing 18 large squares). Therefore, a total absolute heterophil and eosinophil count is obtained. A WBC count is obtained by determining a leukocyte differential from the peripheral blood film and using the formulas in Table 9.1.

A total thrombocyte count can be obtained using the Natt and Herrick's method; however, thrombocytes tend to clump, making an accurate count difficult to achieve. A subjective opinion as to the number of thrombocytes present can be made from the peripheral blood film. An average of one to two thrombocytes are present in monolayer oil immersion (100 x) fields in blood films of normal birds. Numbers less than this suggest a thrombocytopenia and those greater suggest a thrombocytosis. An estimate of the thrombocyte count can be made from the peripheral blood film by obtaining the average number of thrombocytes in five monolayer oil immersion fields. This



represents the average number of thrombocytes per 1000 erythrocytes in most species of birds.

A more accurate method would be to count the number of thrombocytes per 1000 erythrocytes in the blood film. The number of thrombocytes per 1000 erythrocytes is multiplied by the erythrocyte count and divided by 1000 to obtain an estimated thrombocyte count per  $\mu\text{l}$  of blood. If the actual erythrocyte count is not known, then 3,500,000 can be used to represent the average number of erythrocytes per  $\mu\text{l}$  of blood in most species of birds having an average PCV of 45%. If the PCV is below 40 or above 50, the estimated thrombocyte count (est T) can be corrected using the following formula:

$$\text{Corrected est T} = \frac{\text{est T} \times \text{observed PCV}}{\text{normal PCV (averages 45\%)}}$$

## Cell Identification

### Erythrocyte Morphology

The normal mature avian erythrocyte is oval with a centrally positioned oval nucleus. The cytoplasm is abundant and stains a uniform orange-pink, resembling the cytoplasm of mammalian erythrocytes (Color 9.1). The nucleus of the mature erythrocyte is condensed and stains dark purple. The nuclear chromatin is uniformly clumped. The red cell nuclei vary with age, becoming more condensed and darker staining as the cells age.

Variations from the typical mature erythrocyte are occasionally seen in the peripheral blood of birds. Avian erythrocytes frequently demonstrate diffuse polychromasia. Polychromatic erythrocytes demonstrate cytoplasmic basophilia and have nuclei that are less condensed compared to mature erythrocytes (Color 9.1). Immature round erythrocytes (eg, rubricytes) may also be found in the peripheral blood of birds. These developmental stages have been described in this chapter with the discussion of the evaluation of hematopoietic tissue. Occasionally, round erythrocytes with oval nuclei may be found, especially in anemic birds. This is suggestive of an asynchronous maturation of the cell nucleus and the cytoplasm, probably owing to accelerated erythropoiesis. Anucleated, oval erythrocytes (erythroplastids) are rare findings in peripheral blood films of birds (Color 9.2). The shape of the red blood cell may appear irregular, or smudging may occur as a result of artifacts created by the preparation of the film. The most common artifact found in peripheral blood films

of birds is the rupturing of cells during preparation of the film (Color 9.3). The majority of these cells appear to be erythrocytes. The free red cell nuclei appear as amorphous, pink-to-purple material on the film. Other abnormal findings include variations in the location of the cell nucleus within the cell and nuclei having indentations, constrictions or protrusions (Color 9.3). Perinuclear rings are usually artifacts of staining (eg, a form of cellular crenation). Cytoplasmic basophilic stippling is also indicative of abnormal erythrocyte morphology. Hypochromasia is indicated by pale-staining cytoplasm, cytoplasmic vacuoles and round, pyknotic nuclei (Color 9.2). Agglutination of erythrocytes in the blood film is a rare, abnormal finding.

**TABLE 9.1 Formulas for Determining WBC counts**

The total heterophil and eosinophil count T(h+e) is obtained by using the formula given for the eosinophil Unopette brand system:

$$T(h+e)/\text{mm}^3 = \frac{\text{cells counted} \times 10 \times 32}{18}$$

The total leukocyte count (TWBC) is obtained using the leukocyte differential and the following formula:

$$\text{TWBC}/\text{mm}^3 = \frac{(T(h+e) / \% \text{ heterophils} + \text{eosinophils}) \times 100}{100}$$

The TWBC can be calculated using the formula:

$$\text{TWBC}/\text{mm}^3 = \frac{\text{number of cells counted} \times 10 \times 32 \times 100}{(\% \text{ heterophils} + \text{eosinophils}) \times 18}$$

This formula can be simplified by using the formula:

$$\text{TWBC}/\text{mm}^3 = \frac{\text{number of cells counted} \times 1.111 \times 16 \times 100}{\% \text{ heterophils} + \text{eosinophils}}$$

or

$$\text{TWBC}/\text{mm}^3 = \frac{\text{number of cells counted} \times 1778}{\% \text{ heterophils} + \text{eosinophils}}$$

The Natt and Herrick's method is a direct method for obtaining a TWBC and utilizes the same dilution and charged hemacytometer used to obtain a RBC count. The dark-staining leukocytes are counted in the nine large squares of the hemacytometer chamber. The TWBC is obtained using the following formula:

$$\text{TWBC count}/\text{mm}^3 = \frac{(\text{total leukocytes in 9 squares}) \times 10 \times 200}{9}$$

or simplified to:

$$\text{TWBC}/\text{mm}^3 = (\text{total leukocytes in 9 squares} + 10\%) \times 200$$

## Hematology

Illustrations for Colors 9.1 to 9.10 are computer-generated reproductions of blood cells originally printed in Lucas AJ, Jamroz C: Atlas of Avian Hematology, USDA Monograph 25, Washington DC, 1961.

### Color 9.1

Normal erythropoiesis (Wright's-Leishman stain unless otherwise noted).

**a)** Rubriblast with prominent nucleolus, finely granular chromatin pattern and dark-blue cytoplasm.

**b)** Prorubricyte with moderately granular chromatin pattern and dark-blue cytoplasm. A nucleolus is not present.

**c-g)** Various stages of developing polychromatophilic erythrocytes. As maturation progresses, the nuclear chromatin pattern condenses, the cytoplasm becomes less basophilic and the nuclear and cell shapes transform from round to elliptical. The presence of these cells in the blood indicates polychromasia or erythrocyte regeneration.

**h,i)** Appearance of polychromatophilic erythrocytes as reticulocytes following new methylene blue staining. Ribosomes are stained and aggregate as particulate material around the nucleus.

**j,k)** Mature erythrocytes contain abundant hemoglobin, which imparts an orange color to the cytoplasm. As erythrocytes continue to mature or age, the cell and nuclear shapes become more elongate, and the chromatin pattern is extremely condensed.

**l)** Early polychromatophilic erythrocyte in mitosis. These cells are observed most commonly in bone marrow smears but are rare in peripheral blood.

### Color 9.2

Common erythrocyte abnormalities in the stained blood smear.

**a-c)** Poikilocytes are misshapen erythrocytes. These cells may assume a variety of shapes including a unipolar-to-bipolar, spindle appearance. Cytoplasmic constrictions also may be present.

**d)** A macrocyte is an enlarged erythrocyte with voluminous cytoplasm and a condensed, displaced nucleus. These cells may be observed with certain forms of anemia.

**e,f)** Microcytes are small erythrocytes with a minimum of cytoplasm. These cells are associated with lack of iron or iron deficiency anemia.

**g)** Anucleated erythrocytes are observed infrequently. These cells also are called erythroplastids.

### Color 9.3

Common erythrocyte artifacts resulting from improper collection or preparation of blood smears.

**a)** Smudge cell resulting from traumatic disruption of a blood cell, usually an erythrocyte.

**b)** Diffuse, non-refractile, cytoplasmic vacuolation suggesting cytoplasmic edema from loss of membrane integrity. These changes often result from cellular damage during blood smear preparation.

**c)** Refractile artifact caused by water or air trapped between the cell membrane and mounting medium or immersion oil. This artifact is commonly mistaken for a hemoparasite.

**d)** Staining artifact seen most commonly in smears from blood collected in heparin and subjected to Romanowsky staining (Wright's or Giemsa staining).

**e)** Intact erythrocyte nucleus following cellular disruption.

### Color 9.4

Normal thrombocytopoiesis.

**a)** Thromboblast containing an indistinct nucleolus, finely granular chromatin pattern and basophilic cytoplasm.

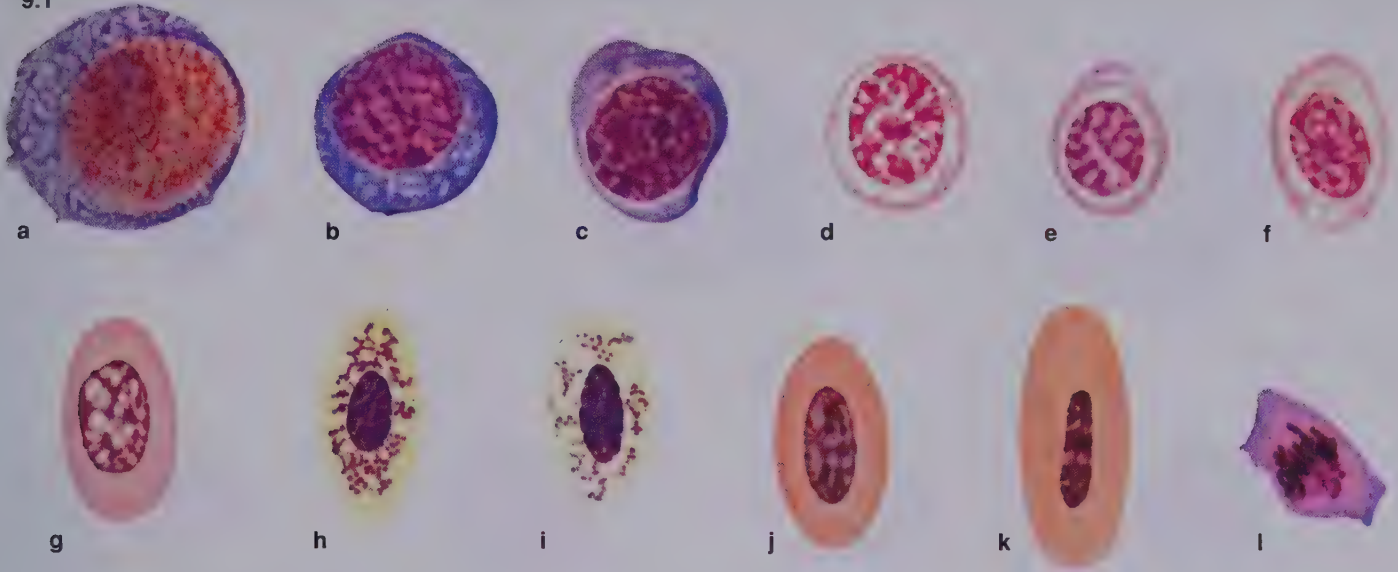
**b,c)** Immature thrombocytes containing round nuclei, a moderately granular chromatin pattern and moderately blue cytoplasm.

**d)** Late immature thrombocyte. As maturation progresses, the cellular and nuclear profiles become more elliptical. Cytoplasmic vacuolation and granules may appear.

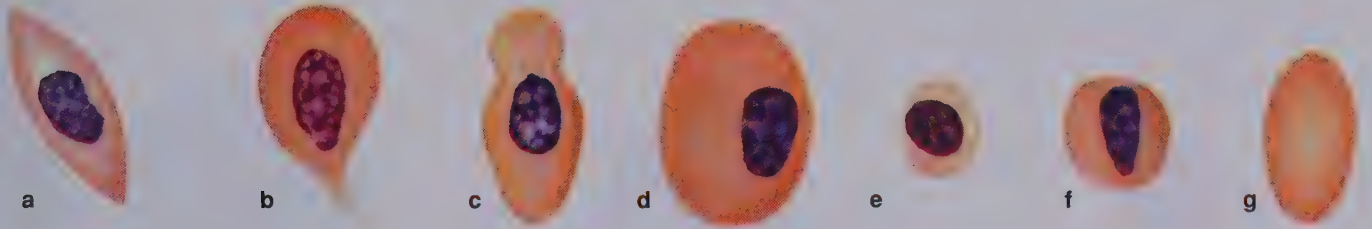
**e-g)** Mature thrombocytes are elliptical with a round-to-oval nucleus, condensed chromatin pattern and light-blue vacuolated cytoplasm. One to three cytoplasmic granules may be present, but granules may vary from absent to abundant.

**h,i)** Shrunken, degenerating thrombocytes with pointed cytoplasmic projections or a condensed nucleus. These cells are observed more frequently in old blood specimens.

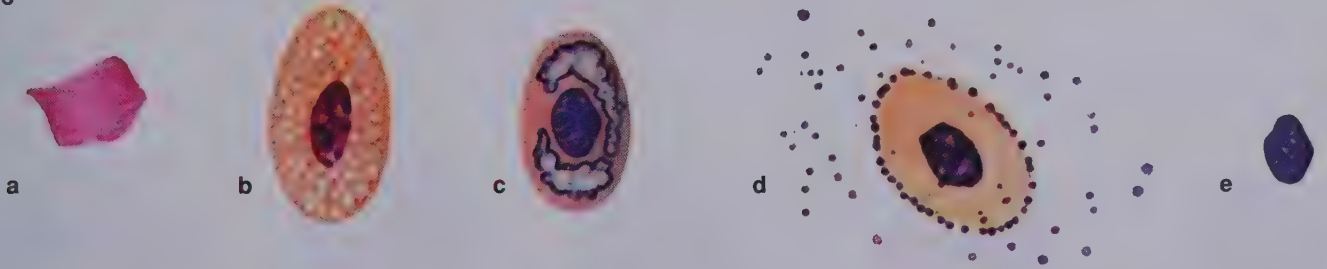
9.1



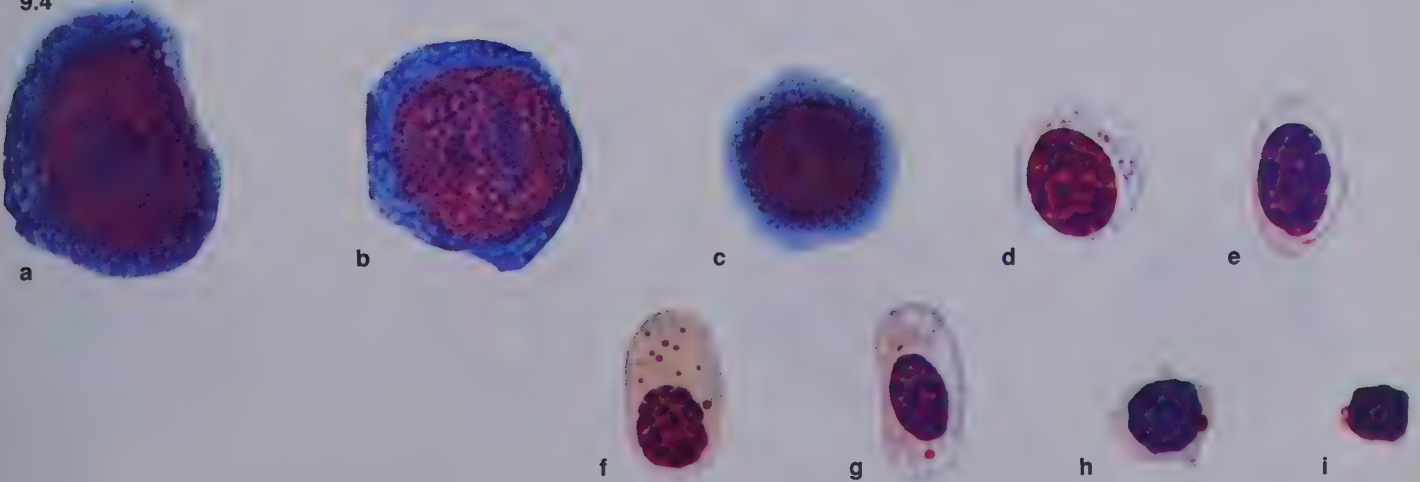
9.2



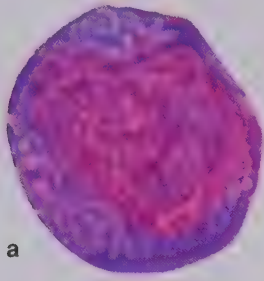
9.3



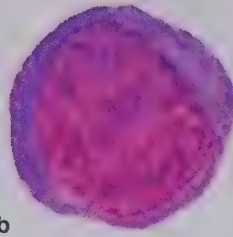
9.4




9.5




a




b



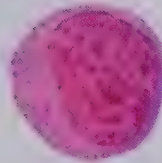
c



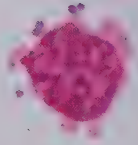
d




e




f



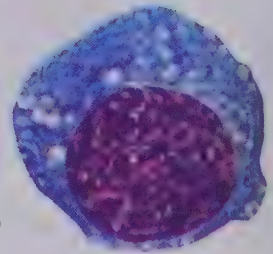
g



h

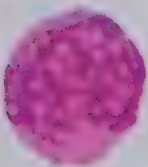


i

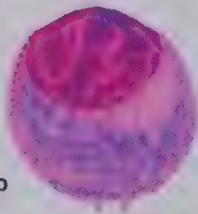


j

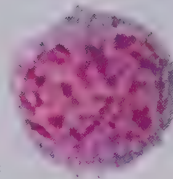
9.6



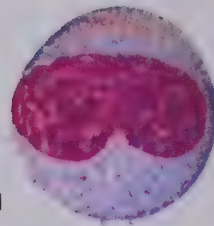
a



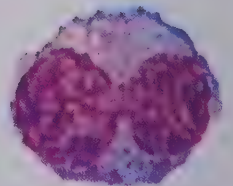
b



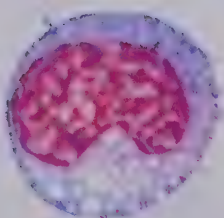
c



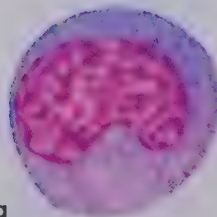
d



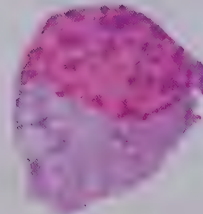
e



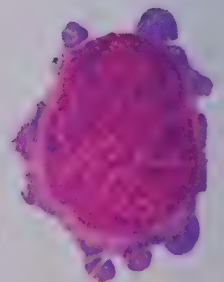
f



g



h



i

## Hematology

### Color 9.5

Normal lymphopoiesis.

**a,b)** Lymphoblasts with a round to slightly irregular nucleus, fine chromatin pattern, multiple nucleoli and basophilic cytoplasm. These cells may be found within the bone marrow in health, but suggest neoplasia when observed within the peripheral blood.

**c)** Small lymphocyte with a scant rim of basophilic cytoplasm. These cells are often confused with thrombocytes by an inexperienced microscopist.

**d)** Typical small lymphocyte with an eccentric nucleus and scant basophilic cytoplasm.

**e)** Small lymphocyte with cytoplasmic azurophilic granules. In mammals, these cells are "killer" lymphocytes.

**f)** Large lymphocytes are observed infrequently in the blood. Usually, monocytes are misidentified as large lymphocytes.

**g,h)** Degenerating lymphocytes with cytoplasmic blebs or broad pseudopodia. These cells are seen most frequently in old blood specimens.

**i)** Plasma cells are the ultimate expression of a B-lymphocyte. These cells are round-to-rectangular with an eccentric nucleus, condensed chromatin pattern, abundant royal-blue cytoplasm and a pale golgi zone. Plasma cells are observed frequently in cytologic preparations, but are rare in blood smears.

**j)** An immunocyte is an antigenically stimulated lymphocyte. These large cells contain a round-to-scalloped nucleus, condensed chromatin pattern and dark-blue cytoplasm. Scattered immunocytes may be observed in the blood smear following antigenic stimulation from immunization or disease.

### Color 9.6

Monocyte development.

**a-c)** Monocytes with oval to slightly indented nuclei, a variable nuclear-to-cytoplasmic ratio and gray cytoplasm. These cells often are misidentified as lymphocytes.

**d,e)** Mature monocytes with an indented to bilobed nucleus, abundant gray cytoplasm and occasional pseudopodia.

**f,g)** Monocytes with cytoplasmic vacuolation or increased dust-like eosinophilic cytoplasmic granules. Cytoplasmic vacuolation usually occurs if the blood specimen is allowed to stand before making blood smears. The eosinophilic granules are lysosomes.

**h,i)** Two degenerating monocytes are present. The first monocyte has nuclear edema and cytoplasmic vacuolation. The second monocyte has broad pseudopodia or cytoplasmic blebs. These cells are observed most frequently within old blood specimens.

### Leukocyte Morphology

The granulocytic leukocytes of birds are heterophils, eosinophils and basophils.<sup>6,18,34,36,44</sup> The heterophil is a round cell with distinct eosinophilic cytoplasmic granules (Color 9.9). These granules are oval to spindle-shaped and often contain a distinct refractile body in the center of the granule. The mature heterophil nucleus is lobed, usually containing fewer lobes than mammalian neutrophils (Color 9.8). The nuclear chromatin contains heavy chromatin clumping. The cytoplasm of normal mature heterophils is colorless and nonvacuolated (Color 9.8).

Avian eosinophils are round granulocytes and contain distinct round-to-oval cytoplasmic granules that lack the central refractile body seen in heterophil granules (Color 9.9). The cytoplasmic granules of eosinophils typically stain brighter or differently from heterophil granules in the same blood film. The intense eosinophilic appearance of eosinophil granules is most likely related to the high concentration of arginine.<sup>19</sup> The cytoplasm of avian eosinophils stains clear blue. The eosinophil nucleus is lobed and generally stains darker than the nuclei of heterophils (Color 9.9). There is variation in the morphologic appearance of the eosinophils of several avian species.<sup>34,41</sup>

The normal basophil is slightly smaller than the heterophil and has a colorless cytoplasm that contains strongly basophilic granules (Color 9.10). These granules often dissolve or coalesce in alcohol-based stains, such as the Romanowsky stains. Avian basophils have round-to-oval, non-lobed nuclei that are often hidden by cytoplasmic granules (Color 9.10).

The mononuclear leukocytes found in the peripheral blood of birds are lymphocytes and monocytes (Color 9.5, 9.6). The mature avian lymphocytes are round cells that frequently "mold" around adjacent cells in the blood film. These cells have high nucleus to cytoplasm (N:C) ratios. The nucleus is usually centrally positioned and round with a scant amount of homogeneous blue cytoplasm appearing as a small band surrounding the nucleus (Color 9.5). Avian lymphocytes often vary in size, and the larger lymphocytes that have pale-staining nuclei may be confused with monocytes. The nuclear chromatin of mature lymphocytes is densely clumped. Occasionally, the cytoplasm of small mature lymphocytes may contain irregular projections.

Monocytes are the largest leukocytes found in the peripheral blood films (Color 9.6). They vary in shape from round to ameboid. Monocytes have an abundant

TABLE 9.2 Characteristics of Blood Cells Using Wright's Stain

<b>Erythrocytes</b>	Dark purple nucleus; orange-pink cytoplasm
<b>Heterophils</b>	Violet, lobed nucleus; colorless cytoplasm, orange-red, rod-shaped granules in most species
<b>Eosinophils</b>	Violet, lobed nucleus; blue cytoplasm; red-orange, round granules in most species
<b>Basophils</b>	Purple, non-lobed nucleus; dark purple cytoplasm granules
<b>Monocytes</b>	Purple nucleus; abundant, finely granular, blue-grey cytoplasm
<b>Lymphocytes</b>	Dark purple, non-lobed nucleus; pale blue, homogeneous cytoplasm
<b>Thrombocytes</b>	Dark purple nucleus; colorless cytoplasm; red granules

amount of cytoplasm compared to lymphocytes. The cytoplasm generally stains darker than the cytoplasm of normal lymphocytes. The cytoplasm of monocytes has a finely granular, blue-gray appearance and often contains vacuoles. Often two distinct cytoplasmic zones can be seen in monocytes: a light-staining area adjacent to the nucleus and a darker staining area on the periphery. The cytoplasm of monocytes may occasionally contain fine, dust-like eosinophilic granules. The nucleus of monocytes generally contains less nuclear chromatin clumping as compared to mature lymphocytes. The shape of the monocyte nucleus is variable, ranging from round to bilobed.

On occasion, abnormal-appearing leukocytes are found in the peripheral blood films of birds (Color 9.5). Immature heterophils are abnormal findings in avian blood films, and their appearance has been described in the evaluation of avian hematopoietic tissue at the end of this chapter. The immature stages most commonly found are heterophil myelocytes and metamyelocytes. In general, immature heterophils have increased cytoplasmic basophilia, non-segmented nuclei and immature cytoplasmic granules compared to mature heterophils (Color 9.5). Usually when immature heterophils are found on a blood film, mature heterophils can also be found.

Mature heterophils appear to show toxic changes in a manner similar to the toxic changes identified in mammalian neutrophils.<sup>6,12,67</sup> Signs of toxicity include increased cytoplasmic basophilia, vacuolation, abnormal granules, degranulation, and degeneration of the nucleus (Color 9.18). The degree of toxicity is reported subjectively on a scale of +1 to +4, where the lower rating reflects slight change and the higher indicates severe change. A +1 toxic heterophil shows increased cytoplasmic basophilia (Color 9.8). An over-

all assessment of the staining of the blood film must be made to assure the hematologist that the film is not overly stained blue, giving the impression that the heterophils have increased basophilia. A +2 toxic heterophil has increased cytoplasmic basophilia, vacuolation and partial degranulation (Color 9.11). A +3 toxicity shows a deeper cytoplasmic basophilia, vacuolation and abnormal granulation (Color 9.8).

Abnormal granulation is indicated by the presence of granules that vary in appearance from the typical rod-shaped eosinophilic granules (eg, large, pale, round eosinophilic granules and small, deeply basophilic granules). A +4 toxic heterophil resembles a +3 toxic heterophil except the cell nucleus has undergone karyorrhexis or karyolysis. The number of toxic heterophils present is an indication of severity and suggestive of duration of an inflammatory response. A slight number (25% or less) of toxic heterophils may be present in the early stages of disorders responsible for their occurrence. As the disorder becomes increasingly severe, the number of toxic heterophils will increase. A marked number (greater than 25%) of toxic heterophils is common in birds showing this heterophil abnormality. It is common for birds with toxic heterophil changes to have all of their heterophils affected on the blood film. Clinically, these birds will be severely compromised.

Cytologic indications for reactivity in lymphocytes include increased cell size, increased cytoplasmic basophilia, the presence of azurophilic cytoplasmic granules and smooth nuclear chromatin (Color 9.12). Blast-transformed lymphocytes have a deeply basophilic cytoplasm and smooth nuclear chromatin (Color 9.5). Blast-transformed lymphocytes may also have nucleoli and distinct Golgi. Occasionally, plasma cells can be found in the peripheral blood of birds. These are relatively large lymphocytes with eccentric, mature-appearing nuclei; abundant, deeply basophilic cytoplasm; and prominent Golgi adjacent to the nucleus. Lymphocytes containing azurophilic granules (large purple cytoplasmic granules) are considered abnormal in birds. Lymphocytes having scalloped cytoplasmic margins are found occasionally in avian blood films; however, large numbers of these cells are considered abnormal.<sup>5,62</sup> Immature lymphocytes in the peripheral blood films are also considered to be abnormal (Color 9.5).

An occasional monocyte having a few cytoplasmic vacuoles is normal, but the presence of large numbers of highly vacuolated monocytes is abnormal.

Cells that contain large granules that fill the cytoplasm are frequently found in blood films of birds. Often these granules fail to stain or may stain blue.<sup>6,34,41</sup> These cells are common in blood films of some species of birds (eg, cockatoos) and suggest either staining artifact or represent variation owing to different cytochemical properties of these cells compared to other avian species. The differential for the type of cell involved includes eosinophils, basophils and rarely, Mott cell variant of plasma cells.

Careful examination of the blood film most often reveals normal staining basophils and no evidence of lymphoid reactivity (which may support the possibility of Mott cells being present), but there are no eosinophils present that stain normally. Based on these characteristics, the majority of these cells have been identified as eosinophils.<sup>6,34,41</sup>

### Thrombocyte Morphology

Birds have nucleated cells (thrombocytes) rather than cytoplasmic fragments as platelets that participate in blood coagulation. Thrombocytes are derived from a distinct line of cells found in hematopoietic tissue. Mature thrombocytes are small oval cells that appear more rounded than the erythrocytes (Color 9.4). The nucleus is pyknotic and the cytoplasm is colorless in mature cells. The cytoplasm may contain one or more red granules and small vacuoles or clear spaces (Color 9.4). Thrombocytes, like mammalian platelets, tend to clump in blood films. Thrombocytes are differentiated from small, mature lymphocytes by having a colorless, nonhomogeneous cytoplasm; small, round, red cytoplasmic granules; and a smaller N:C ratio. Small mature lymphocytes have high N:C ratios with a scant amount of blue, homogeneous cytoplasm (Color 9.5).

Abnormal thrombocyte cytology includes the presence of reactive and immature thrombocytes. Reactive thrombocytes are usually found in aggregates, have a diffusely eosinophilic cytoplasm (suggesting release of chemicals from the granules) and irregular cytoplasmic margins. Reactive thrombocytes tend to be more spindle-shaped than nonreactive thrombocytes (Color 9.4).

Immature stages of thrombocytes are occasionally found in the blood film of birds (Color 9.4). The mid-immature and late-immature thrombocytes are most often seen when immature cells are present.

## Interpretation of the Avian Hemogram

### Interpretation of the Erythron

The normal PCV of birds ranges between 35 and 55 percent. A PCV less than 35 percent is indicative of anemia, and a PCV greater than 55 percent is suggestive of dehydration or polycythemia. An increase in red cell polychromasia is indicative of red blood cell regeneration (Color 9.17). In normal birds, the number of polychromatic erythrocytes (or reticulocytes) found in the peripheral blood film ranges between one and five percent of the erythrocytes. An anemic bird with a five percent or less degree of polychromasia (or reticulocytosis) is responding poorly to the anemia or there has not been enough time for the bird to demonstrate a significant response. An anemic bird showing a ten percent or greater degree of polychromasia is exhibiting a significant regenerative response. The presence of immature erythrocytes (eg, rubricytes) in the peripheral blood along with an increase in polychromasia is indicative of a marked regenerative response.

Some common causes of anemia in birds are discussed in Table 9.3.

Hypochromasia can be associated with certain nutritional deficiencies in birds, especially iron deficiency. Hypochromasia has also been seen in lead toxicosis.<sup>34,42</sup> Lead toxicosis may also create a dichotomous population of erythrocytes in the blood film of a nonanemic bird. In such cases, small senescent, mature erythrocytes with pyknotic nuclei and young erythrocytes (eg, rubricytes) are present in the blood film without the appearance of normal, mature erythrocytes. This condition resembles the inappropriate release of nucleated erythrocytes in the blood of nonanemic dogs suffering from lead poisoning. Basophilic stippling in the cytoplasm of erythrocytes is a rare finding with lead poisoning in birds.<sup>42</sup> Basophilic stippling may be associated with erythrocyte regeneration and hypochromic anemia.

Polycythemia is rarely reported in birds.<sup>74</sup> Increases in the PCV (relative polycythemia) are usually associated with dehydration in birds; however, absolute polycythemia can also occur. The conditions often associated with absolute polycythemia in mammals

TABLE 9.3 Causes of Anemia in Birds<sup>2,10,11,20,24,32,33,39,48,49,61,63,84</sup>

#### Blood-loss Anemia

(Appears regenerative except in the peracute stage)

1. Traumatic injury
2. Parasitism (ticks, *Dermanyssus* mites, coccidia)
3. Primary coagulopathy (rarely reported in birds)
4. Toxicity resulting in a coagulopathy (aflatoxicosis and coumarin poisoning)
5. Organic disease (ulcerated neoplasm, gastrointestinal ulcers, organ rupture)

#### Hemolytic Anemia (Regenerative)

1. Red blood cell parasites (*Plasmodium*, *Aegyptianella* and, rarely, *Haemoproteus* and *Leucocytozoon*)
2. Bacterial septicemia (salmonellosis and spirochetosis)
3. Toxicity (mustards and petroleum products)
4. Immune-mediated (rarely reported in birds)

#### Depression Anemia (Nonregenerative)

1. Chronic diseases (tuberculosis, chlamydiosis, aspergillosis, neoplasia)
2. Hypothyroidism
3. Toxicity (lead poisoning and aflatoxicosis)
4. Nutritional deficiencies (iron and folic acid deficiencies)
5. Leukemia (lymphoid leukemia and erythroblastosis)

are expected to be the causes of this condition in birds as well.

### Interpretation of the Leukogram

There is wide variation in the normal leukograms among birds of the same species. Therefore, values of diagnostic importance must differ greatly from normal reference intervals, which are generally much broader than those obtained from domestic mammals. Preparing normal reference values on healthy individual birds is the best method for evaluating blood parameters of a bird during illness. When these specific values have not been determined, the avian clinician must rely on reference intervals obtained from several birds that are presumed to be healthy. It is best to use values obtained in the laboratory that routinely performs the clinician's avian profiles. Published values obtained from other laboratories can be used as a guide, but may differ from the avian clinician's routine laboratory.

In general, total leukocyte counts greater than 10,000/ $\mu$ l are considered suggestive of leukocytosis in tame, adult psittacine birds. The total leukocyte



count in the blood of normal psittacine birds not accustomed to handling may be high (greater than 10,000/ $\mu$ l) owing to a physiologic leukocytosis. The general causes of a leukocytosis include infection (general or localized), trauma, toxicities, hemorrhage into a body cavity, rapidly growing neoplasms and leukemias. The leukocyte differential aids in the assessment of the leukocytosis. Because a leukocytosis is often caused by inflammation, a heterophilia is usually present.

Although avian heterophils lack the myeloperoxidase and alkaline phosphatase of mammalian neutrophils, studies of their ultrastructure, cytochemistry and function suggest they perform a similar function in the inflammatory response.<sup>14,35,46,52,60</sup> The magnitude of the heterophilia usually indicates the magnitude or severity of the initiating inflammatory process. Although avian heterophils do not produce hydrogen peroxide during phagocytosis, they do contain lysosomal enzymes and have a bactericidal function.<sup>23,50,59,60,75,76</sup> A leukocytosis and heterophilia can be associated with infectious agents (eg, bacteria, fungi, chlamydia and parasites) and noninfectious etiologies (eg, traumatic injury and toxicities). A slight to moderate leukocytosis, heterophilia and lymphopenia can result from either an exogenous or endogenous excess of glucocorticosteroids (stress response).<sup>3,15,31,56,69,83</sup> Species that normally have high numbers of circulating lymphocytes may develop a leukopenia and lymphopenia in the initial stress response, but up to 12 hours later show a leukocytosis and heterophilia.<sup>15</sup> Birds that normally have higher numbers of circulating heterophils than lymphocytes often show a less dramatic change in the leukogram initially. A marked leukocytosis and heterophilia are often associated with chlamydiosis, avian tuberculosis and aspergillosis.

Immature heterophils occur rarely in the peripheral blood of most species of birds. When present, they generally represent an overwhelming peripheral demand for heterophils and a depletion of the mature storage pool in the hematopoietic tissues.<sup>73</sup> The presence of immature heterophils in the peripheral blood usually indicates a severe inflammatory response, especially in association with a leukopenia (degenerative left shift) (Color 9.18). A marked number of immature heterophils may be associated with a granulocytic leukemia, a rare condition in birds.

The presence of toxic heterophils is also uncommon in the peripheral blood of birds. When present, they suggest the presence of a septicemia or toxemia (es-

pecially associated with bacterial toxins affecting the microenvironment of the hematopoietic tissue). The greater the degree of toxicity, the more severe the condition. The presence of a marked number of +4 toxic heterophils indicates a poor prognosis for survival in birds (Color 9.18).

The general causes of leukopenias in birds are depletion of peripheral leukocytes and depression or degeneration of leukopoiesis. Leukopenias associated with heteropenias can be associated with certain viral diseases (eg, Pacheco's disease virus) and overwhelming bacterial infections.<sup>58,64</sup> A leukopenia and heteropenia associated with immature heterophils is suggestive of exhaustion of the mature heterophil storage pool owing to excessive peripheral demand for heterophils. A depression of the hematopoietic tissue is indicated by a leukopenia, heteropenia and few, if any, immature heterophils. A degenerative response is indicated by the presence of a leukopenia, heteropenia, immature heterophils and toxic heterophils. This degenerative response can be differentiated from depletion only by the presence of toxic heterophils or by following the decreasing leukocyte count with serial leukograms. Leukopenias associated with lymphopenias have been reported in early response to corticosteroids in some species of birds.<sup>5,15</sup> A lymphopenia also may be expected with certain viral diseases; however, viral causes have not been well documented in birds.

A lymphocytosis may be expected with antigenic stimulation associated with certain infections. The presence of many reactive lymphocytes is also suggestive of antigenic stimulation. An occasional reactive lymphocyte may be found in the blood film of normal birds. A marked lymphocytosis with or without the presence of immature lymphocytes can occur with lymphocytic leukemia. A marked lymphocytosis, with the majority of cells appearing as small mature lymphocytes with scalloped cytoplasmic margins, is suggestive of lymphoid neoplasia.<sup>5,6,62</sup>

A monocytosis can be found with certain diseases that produce chemotactic agents for monocytes. These conditions include avian chlamydiosis, mycotic and bacterial granulomas and massive tissue necrosis.<sup>32</sup> It should be emphasized that although these disorders can create a peripheral monocytosis, it may not always occur. A monocytosis can also occur in birds on a zinc-deficient diet.<sup>82</sup>

The function of the avian eosinophil is unclear.<sup>54</sup> Although this avian granulocyte was given the name

*eosinophil*, there is evidence that its function may differ from the mammalian eosinophil. Thus, conditions responsible for inducing avian eosinophilias most likely differ from those causing mammalian eosinophilias. Eosinophilias associated with gastrointestinal nematode infections have occasionally been reported; however, it has been difficult to induce this condition experimentally using parasite antigens.<sup>47</sup> Studies suggest that avian eosinophils may participate in delayed (Type IV) hypersensitivity reactions.<sup>51</sup> Idiopathic eosinophilias occur sporadically in birds, and more research is needed to clarify the meaning of this condition.

As with avian eosinophils, the exact function of basophils in birds is unknown. Avian basophils are similar to mammalian basophils in their ability to produce, store and release histamine.<sup>9</sup> Basophils appear to participate in the initial phase of the acute inflammatory response in birds, but this is not always reflected as a basophilia in the leukogram.<sup>8,54</sup> Because basophils appear to play a role in early inflammation and possibly hypersensitivity reactions in birds, a peripheral blood basophilia may suggest the presence of these conditions.

### ■ Interpretation of Thrombocyte Changes

Avian thrombocytes play a primary role in hemostasis in a manner similar to mammalian platelets. They may also have a phagocytic function and participate in removing foreign material from the blood.<sup>19,30</sup> A normal thrombocyte count ranging between 20,000 and 30,000/ $\mu$ l of blood or 10 to 15/1000 erythrocytes can be used as a general reference for most birds.<sup>6,19</sup> Thrombocytopenias are usually indicative of excessive peripheral demand for thrombocytes, although a depression in thrombopoiesis should be considered. Thrombocytopenias are often seen with severe septicemias, where a combination of excessive peripheral demand for thrombocytes and depression of thrombocyte production may occur. A thrombocytosis may reflect a rebound response following hemorrhage or recovery from other conditions associated with excessive utilization of thrombocytes. Often a regenerative response can be detected by the presence of immature thrombocytes in the peripheral blood film.

### ■ Identification of Common Blood Parasites

For a complete review of avian parasites see Chapter 36.

The diagnosis of *Haemoproteus* is made by the detecting characteristic intraerythrocytic gametocytes in peripheral blood films. Only the gametocyte stage of this organism appears in the peripheral blood, whereas schizogony occurs in the tissues (eg, lung, spleen and liver).<sup>70</sup> The mature gametocyte contains yellow-to-brown, refractile pigment granules (Color 9.21). The typical mature gametocyte occupies greater than 50 percent of the red cell cytoplasm, partially encircles the host cell nucleus forming the classic "halter-shape" and causes little displacement of the red cell nucleus. It is rare for more than one mature gametocyte to occur in a cell. Macrogametocytes stain blue with Romanowsky stains and have pigment granules dispersed throughout the cytoplasm of the parasite. The smaller microgametocytes stain pale blue to pink with pigment granules appearing in spherical aggregates. If blood containing *Haemoproteus* organisms is allowed to stand at room temperature for a few hours prior to preparing a blood film, gametes may be released from the cells and found in the extracellular spaces of the blood film. The macrogametocytes appear as spheres that resemble the macrogametocytes within the red cell cytoplasm. The microgametes appear as small spindle-shaped structures. When gametes are found, it should be considered as an artifact of blood film preparation because these structures normally leave the host red cell following ingestion by the intermediate insect host (hippoboscid flies).

*Leucocytozoon* is easily identified from blood films because it grossly distorts the host cell (usually immature erythrocytes) that it parasitizes. Like *Haemoproteus*, only the gametocyte stage of *Leucocytozoon* occurs in the peripheral blood of birds (Color 9.22).<sup>70</sup> The large, round-to-elongated gametocytes cause the host cell to enlarge and appear to have two nuclei: the host cell nucleus pushed to the margin of the cell and the parasite nucleus, a pale-pink nucleus within the parasite. The parasitized cell usually has tapered ends with the remnants of the cell membrane trailing away from the cell. The macrogametocyte stains dark blue with a condensed nucleus and occasional cytoplasmic vacuoles. The microgametocyte stains light blue with a diffuse, pale-pink nucleus. Gametocytes of *Leucocytozoon* lack the refractile pigment granules found in *Haemoproteus*.

The intraerythrocytic gametocytes of *Plasmodium* spp. are often confused with those of *Haemoproteus* spp. because they also contain refractile pigment granules. However, *Plasmodium* gametocytes usually occupy less than 50 percent of the host cell

cytoplasm, and those of some species alter the position of the red cell nucleus (Color 9.26). Two key features that aid in the detection of *Plasmodium* are the presence of schizogony in the peripheral blood and gametocytes or schizonts in blood cells other than erythrocytes.<sup>70</sup> Schizonts appear as round-to-oval intracytoplasmic inclusions that contain dark-staining merozoites. The number of merozoites produced depends upon the species of *Plasmodium*. As with *Haemoproteus*, *Plasmodium* macrogametocytes stain darker than the microgametocytes. Both *Plasmodium* and *Haemoproteus* infections may reveal small, ring-like forms (trophozoites) in the cytoplasm of infected erythrocytes. In rare cases, only these forms may be seen, and it is impossible to identify the parasite involved. In such situations, resampling a week or more later will often reveal the developed forms having the characteristics described for either *Plasmodium* or *Haemoproteus*. Mosquitos (*Culex* and *Aedes* spp.) are the intermediate hosts for *Plasmodium*.

Microfilaria are frequently found in the peripheral blood of a variety of birds.

*Atoplasma* sp. is identified by its characteristic sporozoite within the cytoplasm of mononuclear leukocytes, especially lymphocytes (Color 9.27).<sup>40</sup> The sporozoites appear as pale-staining, round-to-oval intracytoplasmic inclusions that compress the host cell nucleus and create a characteristic crescent shape to the nucleus. This organism can be found in the peripheral blood films or imprints of tissues such as the lung, liver and spleen.

*Aegyptianella* can occur within the cytoplasm in one of three forms: 1) anaplasma-like initial bodies appearing as small (less than one micrometer in diameter), round, basophilic inclusions; 2) intermediate stages resembling *Babesia* and measuring between one and two micrometers in diameter; and 3) large, round-to-elliptical forms measuring between two and four micrometers in length.<sup>70</sup> *Aegyptianella* spp. are considered to be pathogenic to many species of birds (primarily Passeriformes) but may be difficult to detect because the parasitemia stage of the disease is often very short and easily missed.

## Evaluation of the Hematopoietic Tissue

Hematopoiesis occurs primarily in the bone marrow of post-hatch birds; however, hematopoietic activity may also be found in various internal organs (eg, liver and possibly spleen).<sup>4,19</sup> A bone marrow sample should be obtained for cytologic evaluation in avian patients with persistent nonregenerative anemia, thrombocytopenia, panleukopenia and heteropenia. Bone marrow evaluation is also indicated for suspected cases of leukemia or if unexplained abnormal cells are found in the peripheral blood. An evaluation of the hemogram should accompany any bone marrow evaluation to properly assess hematopoiesis.

### Bone Marrow Collection

In general, the proximal tibiotarsus just below the femoral-tibiotarsal joint (knee) is the preferred site for bone marrow collection in most birds.<sup>6,79</sup> After surgical preparation of the skin either on the cranial or medial aspect of the proximal tibiotarsus, a small stab incision through the skin is made using a scalpel blade. A bone marrow aspiration biopsy needle is pushed through the thin cortex and into the marrow space using clockwise-counterclockwise rotational movements. Once the needle has entered the marrow space, the stylet is removed from the needle and a syringe is attached to gently aspirate a small amount of marrow into the needle lumen. Excessive pressure during aspiration should be avoided to prevent peripheral blood contamination of the sample. Following aspiration, the needle is removed from the bone and the syringe is detached from the needle. The syringe is filled with air and reattached to the needle hub. Using the air in the syringe, the marrow within the needle lumen is forced onto a microscope slide. A second slide is placed across the first on top of the marrow sample. As the two slides are pulled horizontally apart, two marrow films are made for cytologic examination.

Marrow can also be obtained from the sternum (keel) of some birds with the biopsy needle inserted into the widest part of the sternal ridge.

Bone marrow biopsy needles commonly used include pediatric Jamshidi bone marrow biopsy-aspiration

## Hematology

### Color 9.7

Early myeloblast with a fine chromatin pattern, nucleolar ring and dark-blue cytoplasm. The myeloblast is the progenitor cell for the heterophil (Color 9.8), eosinophil (Color 9.9) and basophil (Color 9.10).

### Color 9.8

Heterophil development.

**a)** Myeloblast with fine chromatin pattern, nucleolus and light-blue cytoplasm.

**b)** Promyelocyte with oval nucleus, pale-blue cytoplasm and round to slightly irregular metachromatic cytoplasmic granules.

**c)** Heterophil myelocyte with an oval nucleus and a mixture of metachromatic granules and scattered round-to-rod-shaped eosinophilic granules.

**d)** Heterophilic metamyelocyte with a slightly indented nucleus.

**e)** Heterophilic band with U-shaped nucleus.

**f,g)** Mature, segmented heterophils with numerous needle-shaped granules. The granules may obscure nuclear detail, making assessment of lobulation difficult.

**h)** Heterophil with mild toxic changes including cellular swelling, partial degranulation and a basophilic cast to the cytoplasm.

**i,j)** Toxic heterophils with progressive granule dissolution leaving the round granule core intact. The cell is slightly swollen and has basophilic cytoplasm. This cell may occasionally be confused with an eosinophil, except for retention of a few needle-shaped granules. Stain-induced heterophil degranulation is not associated with cytoplasmic basophilia.

**k)** Heterophil with non-staining cytoplasmic granules. This may be an artifact resulting from exposure of the blood smear to formalin vapor during transport or mailing.

**l)** Disrupted heterophil showing typical needle-shaped granules. These smudge

cells are ignored during the leukocyte differential count.

**m)** Smudged heterophil with dissolution of the outer granule matrix leaving intact round central cores. Granule dissolution may cause an eosinophil-like appearance; however, smudge cells are ignored during the leukocyte differential count.

### Color 9.9

Eosinophil development.

**a)** Late myeloblast with condensing chromatin pattern and light-blue cytoplasm.

**b)** Eosinophilic myelocyte with an oval nucleus and scattered, variably sized, round, secondary granules.

**c)** Eosinophilic myelocyte with a slightly indented nucleus and round, red-orange granules.

**d)** Eosinophilic band with U-shaped nucleus and round, red-orange granules.

**e)** Segmented eosinophil with a lobulated nucleus and abundant secondary (specific) granules.

**f)** Disrupted or smudged eosinophil. These cells are ignored during the leukocyte differential count.

### Color 9.10

Basophil development.

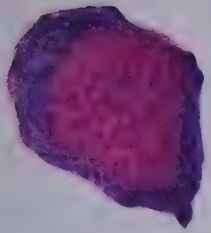
**a,b)** Basophilic myelocytes with round nuclei and round, variably sized, metachromatic granules.

**c,d)** Basophils with round, intensely stained, metachromatic granules. Basophil granules have high affinity for Romanowsky stain, often resulting in poor staining of the cell nucleus. In addition, cytoplasmic granules may obscure nuclear detail.

**e)** Basophil degranulation may occur with disease or as an artifact of blood smear staining.

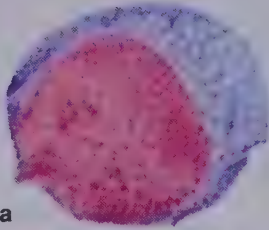
**f)** Disrupted basophil (smudge cell). These cells are ignored during the leukocyte differential count.

9.8

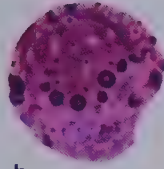


9.7

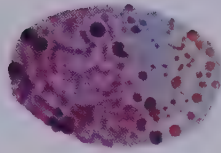
a



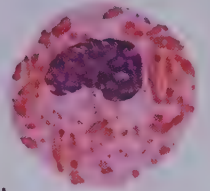
b




c



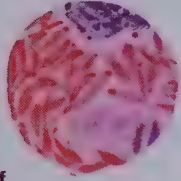
d




e



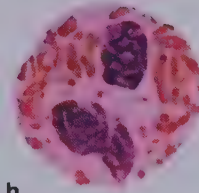
f



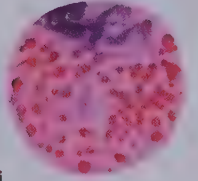
g



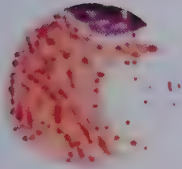
h



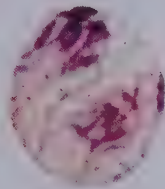
i



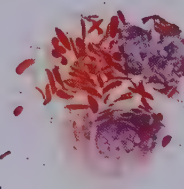
j



k



l

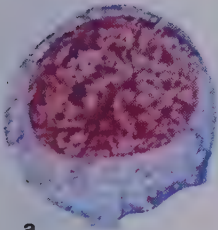


m

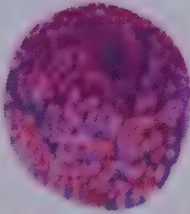


9.9

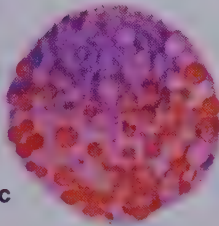
a



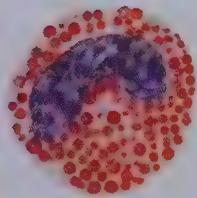
b



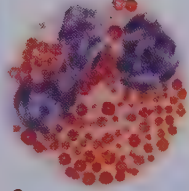
c




d



e

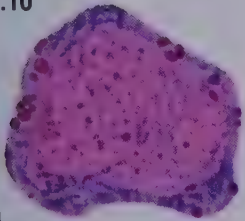


f

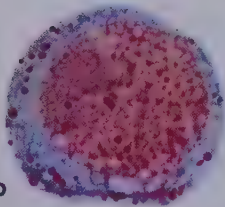


9.10

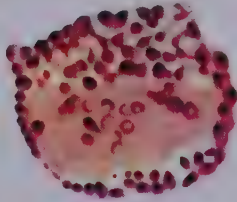
a



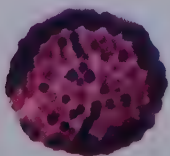
b



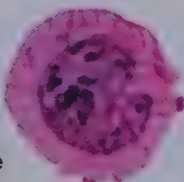
c



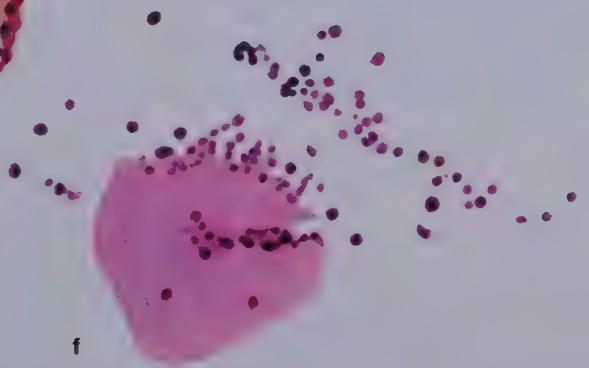
d

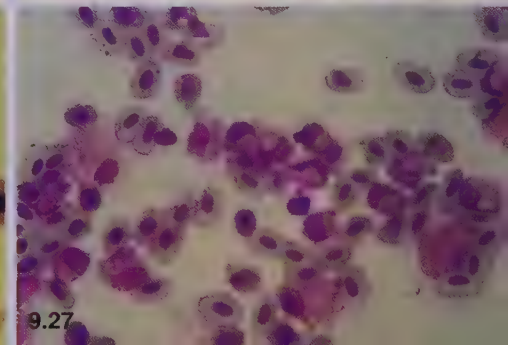
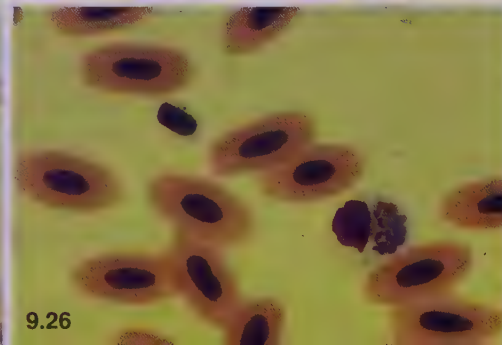
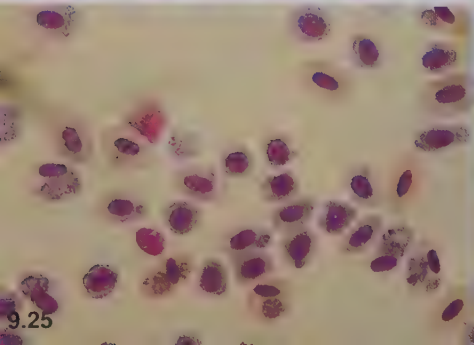
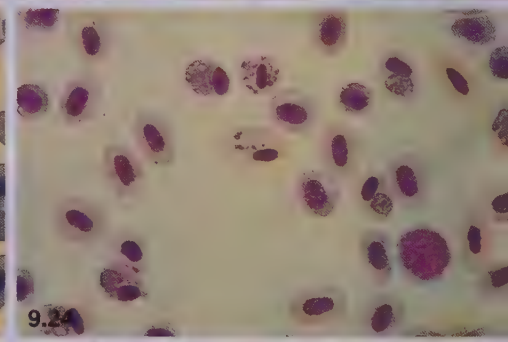
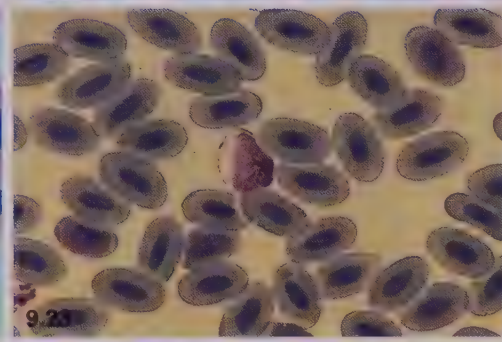
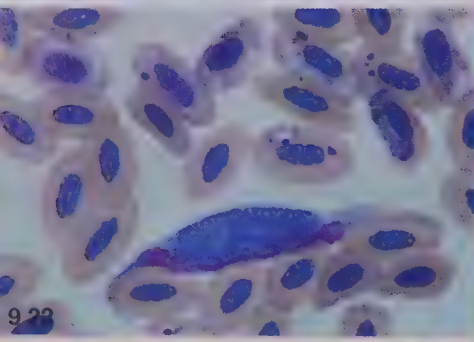
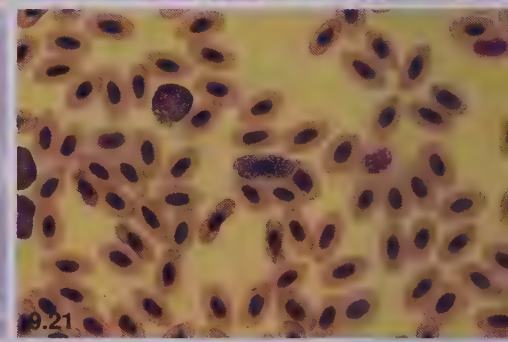
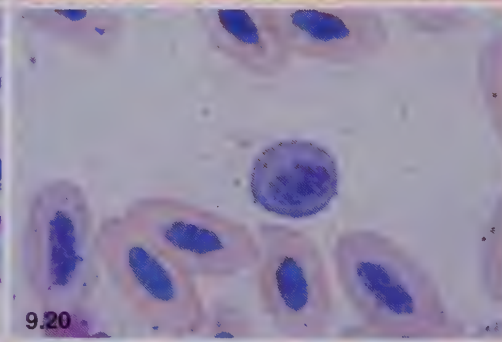
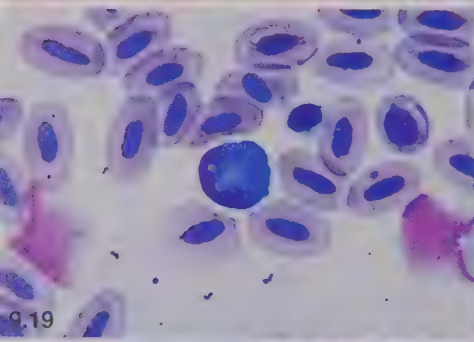
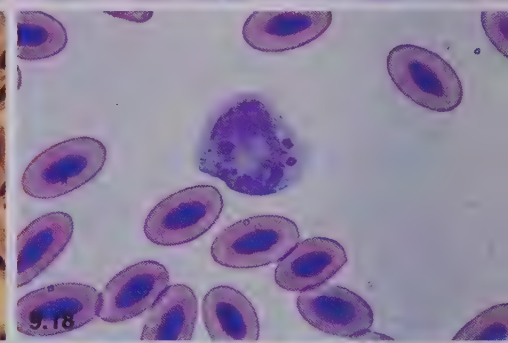

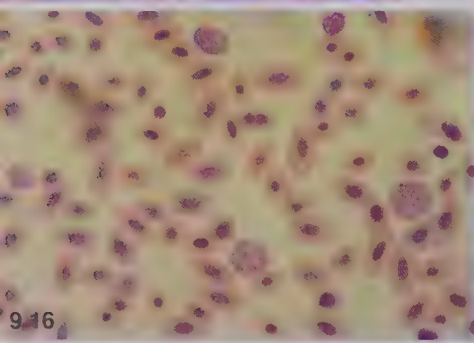
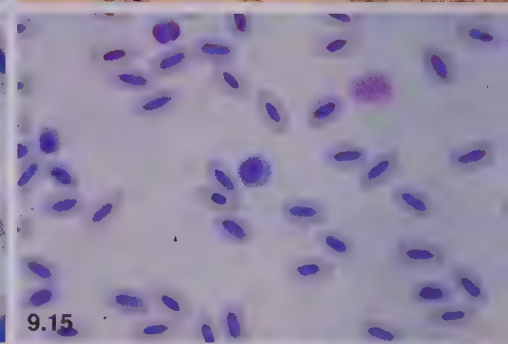
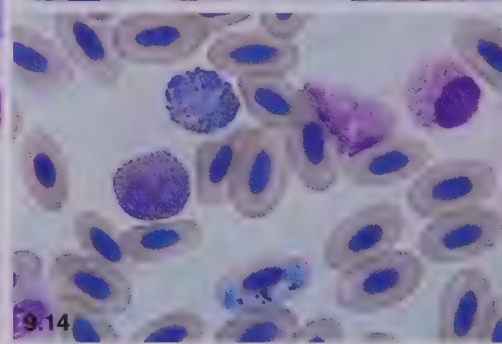
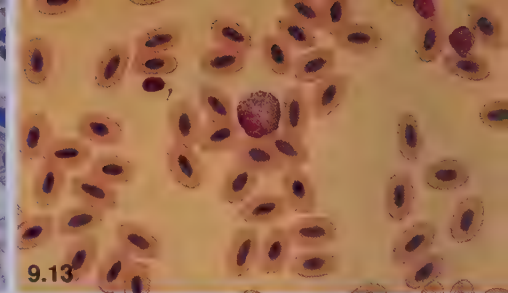
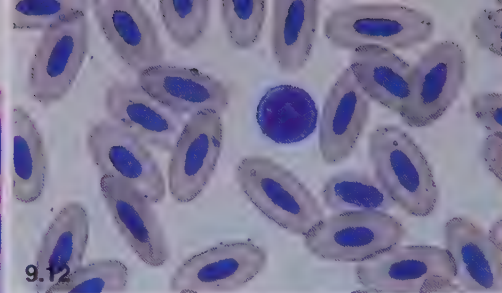
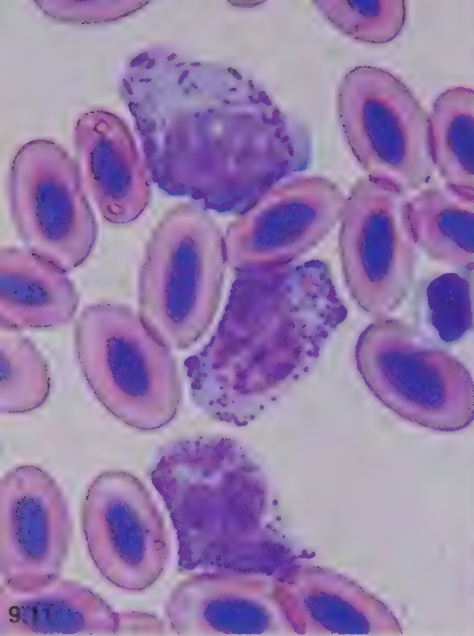


e



f





## Hematology

All photographs on this page were provided courtesy of Terry W. Campbell.

### Color 9.11

An adult female Red-tailed Hawk was presented with clinical signs of lethargy, a marked reduction of the pectoral muscle mass and diarrhea. A diagnosis of salmonellosis was made based upon necropsy and bacterial culture two days later. The hemogram revealed: PCV = 28%, RBC = 1,950,000/mm<sup>3</sup>, WBC = 31,876/mm<sup>3</sup>, heterophils = 28,050/mm<sup>3</sup>, lymphocytes = 1,594/mm<sup>3</sup>, monocytes = 638/mm<sup>3</sup> and eosinophils = 1,594/mm<sup>3</sup>. A toxic heterophil (2+ toxicity) and two eosinophils are shown. Wright's stain.

### Color 9.12

A Blue-fronted Amazon Parrot was presented with multifocal, depigmented, non-raised lesions involving the skin on the feet. Serum chemistries and erythrocyte parameters were within normal limits. The leukogram revealed the following: WBC = 7,543/mm<sup>3</sup>, heterophils = 1,886/mm<sup>3</sup>, lymphocytes = 4,601/mm<sup>3</sup>, monocytes = 830/mm<sup>3</sup> and eosinophils = 226/mm<sup>3</sup>. Typical reactivity of lymphocytes demonstrated by Wright's stain.

### Color 9.13

A critically ill Green-cheeked Amazon Parrot was presented for evaluation. The bird was extremely weak and unable to perch. Severe uveitis was present in both eyes. The bird was housed in a room where varnish was being applied to furniture. Important hematologic findings included: PCV = 40%, total protein = 5.0 gm/dl, WBC = 16,140/mm<sup>3</sup>, heterophils = 13,880/mm<sup>3</sup> (10% of the heterophils were myelocytes and 20% were metamyelocytes), lymphocytes = 807/mm<sup>3</sup>, monocytes = 1,453/mm<sup>3</sup> and thrombocytopenia. A heterophilic myelocyte is demonstrated by Wright's stain.

### Color 9.14

A juvenile Red-tailed Hawk was presented with marked reduction of the pectoral muscle mass. Radiographic evaluation revealed a fracture of the left coracoid bone. The hematologic findings included: PCV = 37%, Hb = 11.5 g/dl, RBC = 2,250,000/mm<sup>3</sup>, 4% polychromasia, total protein = 2.6 g/dl, WBC = 32,932/mm<sup>3</sup>, heterophils = 25,687/mm<sup>3</sup>, lymphocytes = 1,976/mm<sup>3</sup>, monocytes = 988/mm<sup>3</sup>, eosinophils = 3,952/mm<sup>3</sup> and basophils = 392/mm<sup>3</sup>. A heterophil, eosinophil, basophil and *Haemoproteus* ga-

metocyte (0.7% of the erythrocytes contained these gametocytes) are demonstrated by Wright's stain.

### Color 9.15

A Blue and Gold Macaw was examined 93 hours following severe blood loss that resulted from a traumatic injury to the foot. The hemogram revealed: PCV = 21%, RBC = 1,660,000/mm<sup>3</sup>, Hb = 5.8 g/dl, WBC = 19,457/mm<sup>3</sup>, heterophils = 12,255/mm<sup>3</sup>, lymphocytes = 6,615/mm<sup>3</sup>, monocytes = 97/mm<sup>3</sup> and basophils = 389/mm<sup>3</sup>. Twenty-two percent of the erythrocytes exhibited polychromasia, and an occasional immature erythrocyte was noted. Polychromasia and a round, immature erythrocyte (early polychromatic rubricyte) are demonstrated by Wright's stain.

### Color 9.16

The hemogram from a Harris Hawk that died three days later from an acute pneumonia revealed a moderate anemia, leukocytosis, heterophilia and left shift. Marked anisocytosis and polychromasia are illustrated as well as a binucleate erythrocyte (which were frequently seen in the blood film). A heterophil, eosinophil, two lymphocytes, a thrombocyte and an immature erythrocyte (basophilic rubricyte) can also be seen by Wright's stain.

### Color 9.17

A juvenile Bar-headed Goose was presented for weakness and weight loss. Six other geese in the group appeared normal. The hemogram revealed: PCV = 28%, Hb = 9.0 g/dl, RBC = 1,950,000/mm<sup>3</sup>, 11% polychromasia, WBC = 39,556/mm<sup>3</sup>, heterophils = 31,645/mm<sup>3</sup>, lymphocytes = 5,645/mm<sup>3</sup>, monocytes = 1,187/mm<sup>3</sup> and basophils = 791/mm<sup>3</sup>. Blood lead levels were normal. The erythrocyte morphology revealed polychromasia, hypochromasia and stippled basophilia. Wright's stain.

### Color 9.18

A juvenile Red-tailed Hawk was presented with open fractures of the left radius and ulna and poxvirus lesions along the margins of the beak and on the feet. The bird was extremely depressed and died within 24 hours of presentation. The hemogram showed: PCV = 35%, Hb = 11 g/dl, RBC = 3,020,000/mm<sup>3</sup>, WBC = 42,240/mm<sup>3</sup>, monocytes = 3,802/mm<sup>3</sup>, eosinophils = 1,267/mm<sup>3</sup> and basophils = 422/mm<sup>3</sup>. The majority of the heterophils appeared extremely toxic (4+). Wright's stain.

### Color 9.19

An adult African Grey Parrot was presented with a history of an intermittent seizure disorder and was successfully treated for hypocalcemia. The hemogram revealed: PCV = 49%, RBC = 2,940,000/mm<sup>3</sup>, WBC = 15,740/mm<sup>3</sup>, heterophils = 6,453/mm<sup>3</sup>, lymphocytes = 8,814/mm<sup>3</sup>, monocytes = 315/mm<sup>3</sup> and eosinophils = 157/mm<sup>3</sup>. Eosinophils with large, blue cytoplasmic granules are demonstrated by Wright's stain.

### Color 9.20

An adult Red-tailed Hawk was presented with multiple gunshot wounds and open fractures involving the right radius and ulna. The hemogram revealed: PCV = 16%, Hb = 5.3 g/dl, RBC = 1,300,000/mm<sup>3</sup>, WBC = 15,740/mm<sup>3</sup>, heterophils = 6,453/mm<sup>3</sup>, lymphocytes = 8,814/mm<sup>3</sup> and monocytes = 472/mm<sup>3</sup>. The reticulocyte count was 20% and there were many immature erythrocytes present. A mid-polychromatic rubricyte is demonstrated by Wright's stain.

### Color 9.21.

*Haemoproteus* sp. gametocytes in a blood film stained with Wright's stain from a Great Horned Owl.

### Color 9.22

*Haemoproteus* and *Leukocytozoon* spp. gametocytes in a blood film stained with Wright's stain from a Great Horned Owl.

### Color 9.23

*Haemoproteus* sp. microgametes in a blood film stained with Wright's stain from a Screech Owl.

### Color 9.24

*Plasmodium* sp. gametocytes and schizonts in the cytoplasm of erythrocytes from a Skua stained with Wright's stain.

### Color 9.25

*Plasmodium* sp. gametocytes in the cytoplasm of erythrocytes and extracellular space in a Wright's-stained blood film from a Skua.

### Color 9.26

*Plasmodium* sp. gametocyte in the cytoplasm of a thrombocyte in a Wright's-stained blood film from a Mississippi Kite.

### Color 9.27

Numerous intracytoplasmic *Atoxoplasma* sp. inclusions within lymphocytes from a lung imprint of a Siskin.

needles and disposable Jamshidi Illinois-Sternal/Iliac aspiration needles. Disposable spinal needles can be used to sample small birds because they contain a stylet to facilitate passage of the needle through the cortex without occlusion of the needle lumen with bone.

### Erythropoiesis

The terminology describing the different stages of erythrocytic development varies in the literature.<sup>6,19,34,44</sup> In general, there are six recognizable stages involved in red cell development. The earliest recognizable stage is the rubriblast (proerythroblast) (Color 9.1). This cell has large, prominent nucleoli or nucleolar rings. The round nucleus is centrally positioned within the cell. The coarsely granular chromatin is atypical for most blast-type cells. The abundant cytoplasm stains deeply basophilic and contains fine, clear spaces (mitochondrial spaces). Rubriblasts have high N:C ratios, typical of immature cells.

The second stage in erythrocyte development is the prorubricyte (basophilic erythroblast). This cell resembles the rubriblast, but the nucleoli are either absent or indistinct, and the cytoplasm lacks the mitochondrial spaces of the rubriblast (Color 9.1).

The next three stages are the rubricyte stages. These are round-to-slightly oval cells that are smaller than rubriblasts and prorubricytes. Rubricytes are divided into three groups based upon their appearance in the cytologic sample. In order of increasing maturation they are the basophilic rubricyte (early polychromatic erythroblast), early polychromatic rubricyte (late polychromatic erythroblast) and late polychromatic rubricyte (orthochromic erythroblast). The basophilic rubricyte has a high N:C ratio, homogeneous basophilic cytoplasm and round nucleus with distinct chromatin clumping.

The early polychromatic rubricyte appears smaller than the basophilic rubricyte and is the first stage of red cell development in which hemoglobinization of the cytoplasm can be detected with Wright's stain. The hemoglobin gives the cytoplasm a gray, slightly eosinophilic appearance. The nucleus appears smaller with increased density, and the cytoplasm is more abundant when compared to the previous stage of development. The late polychromatic rubricyte is a round-to-slightly oval cell with an eosinophilic gray-to-weakly eosinophilic cytoplasm (Color 9.1). This cell appears to have increased cytoplasmic volume when compared to the previous stage, and the nu-

cleus may appear oval with irregularly clumped chromatin. The penultimate stage of erythrocyte development is the polychromatic erythrocyte, which resembles the oval, mature erythrocyte except for the cytoplasmic basophilia and nuclear chromatin that appear less condensed than the pyknotic nucleus of the mature cell (Color 9.1).

### Granulopoiesis

Avian granulopoiesis appears to follow developmental stages similar to those described for mammalian granulocytes.<sup>6,34,44</sup> These stages are the myeloblast (granuloblast), progranulocyte (promyelocyte), myelocyte, metamyelocyte and mature granulocyte.

Myeloblasts are large, round cells with a narrow rim of cytoplasm that appears less basophilic than that of rubriblasts.<sup>44</sup> In general, the nucleus is round with a delicate reticular chromatin pattern and distinct nucleoli. No cytoplasmic granules are present. The myeloblast stage is common to all the granulocytes (Color 9.7).

The next stage toward maturation is the progranulocyte. These are large cells with cytoplasmic granules and light blue cytoplasm. The granules are variable in appearance. An attempt has been made to differentiate progranulocytes into their respective granulocytic cell lines based upon the appearance of the cytoplasmic granules.<sup>44</sup> Heterophil progranulocytes contain orange spheres (primary granules) or rings and dark magenta granules or rings. The ring forms are thought to be characteristic of the heterophil cell line. Eosinophil progranulocytes lack the dark magenta granules and rings and contain only brightly staining orange spheres (primary granules). Basophil progranulocytes have magenta granules that appear smaller than those of heterophil progranulocytes and have fewer ring forms. The nucleus of progranulocytes is typically eccentric in its cellular position, has a delicate reticular chromatin pattern and often has indistinct margins.

The myelocytes are smaller than the progranulocytes and contain the specific granules (secondary granules) for each cell line. Heterophil myelocytes are round cells with light blue cytoplasm containing primary granules, magenta granules and rings and the definitive rod-shaped heterophil granules. The definitive granules occupy less than 50 percent of the cytoplasmic volume. Eosinophil myelocytes contain primary and secondary granules. The specific or secondary granules occupy less than 50 percent of the



cytoplasmic volume. The basophil myelocyte has magenta granules and mature basophil granules (secondary granules) that occupy less than 50 percent of the cytoplasmic volume. The nucleus of myelocytes is round and has coarsely granular chromatin.

Metamyelocytes resemble myelocytes, except the cell nucleus is slightly indented and may have distinct chromatin clumping. Heterophil metamyelocytes have definitive, rod-shaped granules that occupy greater than 50 percent of the cytoplasmic volume. The primary granules and magenta spheres and rings may be present, but fewer in number than the previous stage. The definitive granules of the eosinophil and basophil series also occupy greater than 50 percent of the cytoplasmic volume in their respective metamyelocyte stages. The basophil myelocyte nucleus remains round.

The granulocytic cell series will occasionally reveal a band cell stage similar to that described in mammalian granulocytes. However, the cell nucleus is often hidden by the cytoplasmic granules (especially in heterophils), making it difficult to differentiate the band cell from mature cells. Mature avian basophil nuclei do not segment.

### Thrombocytopoiesis

The developmental stages involved in thrombopoiesis are the thromboplast, early-immature thrombocyte, mid-immature thrombocyte, late-immature thrombocyte and mature thrombocyte (Color 9.4).<sup>6,44</sup> As the cell develops toward maturity, the cell size decreases, the N:C ratio decreases, the nucleus becomes increasingly pyknotic and cytoplasm becomes less basophilic.

Thromboplasts are large, round-to-ameboid-shaped cells with a narrow rim of deeply basophilic cytoplasm surrounding the round nucleus. The nuclear chromatin often appears punctate, making nucleoli difficult to detect. The cytoplasm may contain small clear spaces.

The early-immature thrombocyte is smaller than the thromboplast. It has a round-to-oval nucleus and smaller N:C ratio than the previous cell. The cytoplasm is basophilic with small, clear spaces or vacuoles. The nuclear chromatin is irregularly clumped and nucleoli are absent. The mid-immature thrombocyte appears slightly elongated or irregular with a pale blue, vacuolated cytoplasm. Specific red cytoplasmic granules may be seen at this stage. The

nucleus usually has marked chromatin clumping. The late-immature thrombocyte is an oval cell that has the appearance of the elongate, mature thrombocyte, except the cytoplasm is a pale blue and the nuclear chromatin is less condensed.

### Lymphopoiesis

Lymphocyte development may be seen occasionally when evaluating hematopoietic tissue (Color 9.5). Three distinctive stages can be identified for lymphocyte development: lymphoblasts, prolymphocytes and mature lymphocytes. Lymphoblasts are large, round lymphocytes with high N:C ratios. The nucleus has smooth chromatin, in comparison to the mature cell, and contains distinct nucleoli. The cytoplasm of lymphoblasts stains deeply basophilic.

Prolymphocytes resemble lymphoblasts but are slightly smaller, lack nucleoli and have a less basophilic cytoplasm. In normal lymphoid tissue, lymphoblasts and prolymphocytes represent less than ten percent of the lymphoid cells. Thus, the majority of the cells should be mature lymphocytes with the heavy nuclear chromatin clumping, high N:C ratio and scant amount of blue, homogeneous cytoplasm.

### Other Bone Marrow Cells

Other cells frequently encountered in bone marrow samples include osteoclasts, osteoblasts, monocytes, plasma cells and mitotic figures. Osteoclasts are large, multinucleated cells that are ameboid in shape. The abundant cytoplasm is weakly basophilic and often contains vacuoles and small red granules of various shapes. The nuclei are round-to-oval and usually contain distinct nucleoli. Osteoblasts are large cells that vary in shape. The oval-to-round nucleus is eccentrically positioned in the cell. The abundant, foamy, basophilic cytoplasm contains a prominent clear space (Golgi) that is located a distance from the nucleus.

#### Products Mentioned in the Text

- a. Microtainer - Becton Dickinson, Rutherford, NJ
- b. Samplette, Monoject, Sherwood Medical, St. Louis, MO
- c. Capiject, Terumo, Elkton, MD
- d. Abbott Hospitals Inc, North Chicago, IL
- e. Diff Quik, American Scientific Products, McGraw Park, IL
- f. Hemacolor, Miles Laboratories Inc, Elkhart, IN
- g. Hema-Tek, Ames Division of Miles Laboratories Inc, Elkhart, IN
- h. Coulter Counter, Coulter Electronics, Inc
- i. Unopette System, Becton-Dickinson, Rutherford, NJ
- j. Kormed Corp., Minneapolis, MN

## References and Suggested Reading

1. **Andrews FX:** Simplified heart puncture in poultry diagnosis. *J Am Vet Med Assoc* 16:38-39, 1950.
2. **Assoku R, Pehale W, Buxton A:** An immunological basis for the anemia of acute *Salmonella gallinarum* infection of chickens. *Clin Exp Immunol* 7:865-874, 1970.
3. **Bhattacharyya TK, Sarkar AK:** Avian leucocytic responses induced by stress and corticoid inhibitors. *Ind J Exp Biol* 6:26-28, 1968.
4. **Campbell F:** Fine structure of the bone marrow of the chicken and pigeon. *J Morph* 123:405-40, 1967.
5. **Campbell TW:** Lymphoid leukosis in an Amazon parrot: A case report. *Proc Assoc Avian Vet*, 1984, pp 229-234.
6. **Campbell TW:** Avian Hematology and Cytology. Ames, Iowa State University Press, 1988.
7. **Campbell TW, Dein FJ:** Avian hematology: The basics. *Vet Clin North Am* 14(2):223-248, 1984.
8. **Carlson HC, Hacking MA:** Distribution of mast cells in chicken, turkey, pheasant, and quail and their differentiation from basophils. *Avian Dis* 16:574-577, 1972.
9. **Chad N, Eyre P:** Immunological release of histamine and SRS in domestic fowl. *Can J Comp Med* 42:519-24, 1978.
10. **Christie G:** Hematological and biochemical findings in an anemia induced by daily bleeding of ten-week-old cockerels. *Br Vet J* 134:358-365, 1978.
11. **Christie G:** Hematological and biochemical findings in an experimentally produced hemolytic anemia in eight-week-old brown leghorn cockerels. *Br Vet J* 135:279-285, 1979.
12. **Coles EH:** Veterinary Clinical Pathology 4th ed. Philadelphia, WB Saunders Co, 1986, pp 53-54.
13. **Costello RT:** A Unopette for eosinophil counts. *Am J Clin Path* 54:249, 1970.
14. **Daimon T, Caxton-Martins A:** Electron microscopic and enzyme cytochemical studies on granules of mature chicken granular leukocytes. *J Anat* 123:553-562, 1977.
15. **Davidson TF, Flack IH:** Changes in the peripheral blood leukocyte populations following an injection of corticotropin in the immature chicken. *Res Vet Sci* 30:79-82, 1981.
16. **Davidson I, Henry JB:** Todd-Sanford Clinical Diagnosis by Laboratory Methods 15th ed. Philadelphia, WB Saunders, 1974.
17. **Dein FJ:** Laboratory Manual of Avian Hematology. Association of Avian Veterinarians, East Northport, 1984.
18. **Dein FJ:** Hematology. In Harrison GJ, Harrison LR (eds): Clinical Avian Medicine and Surgery. Philadelphia, WB Saunders Co, 1986, pp 174-191.
19. **Dieterlen-Lievre F:** Birds. In Rawley AF, Ratcliffe NA (eds): Vertebrate Blood Cells. Cambridge, Cambridge University Press, 1988, pp 257-336.
20. **Djojagung AM, Falkow B, Kovach AGB:** The mechanisms behind the rapid blood volume restoration after hemorrhage in birds. *Acta Physiol Scand* 74:114-122, 1968.
21. **Dorreshtine GM, van de Hage MN, Zwart P:** Diseases of passerines, especially canaries and finches. *Proc Assoc Avian Vet*, 1985, pp 53-70.
22. **Dresser SS:** Schizogony and gametogony of *Leucocytozoon simondi* and associated reactions in the avian host. *J of Protozool* 14:224-254, 1967.
23. **Ericsson JLE, Nair MK:** Electron microscopic demonstration of acid phosphatase activity in the developing and mature heterophils of the chicken. *Histochemie* 37:97-105, 1973.
24. **Ernst RA, Ringer RK:** The effect of DDT, Zectran, and Zytron on the packed cell volume, total erythrocyte count, and mean corpuscular volume of Japanese quail. *Poultry Sci* 47:639-643, 1968.
25. **Fite RW:** Diagnosis and control of Leucocytozoonosis in captive waterfowl. *Proc Assoc Avian Vet*, 1984, pp 193-198.
26. **Flammer K:** Clinical aspects of atoxoplasmosis in canaries. *Proc 1st Intl Conf Zool & Avian Med*, 1987, pp 33-35.
27. **Fry DM, Addiego L:** Hemolytic anemia complicates the clearing of oiled seabirds. *Wildlife Journal* 10:3-6, 1987.
28. **Galvin CE:** Approach to the anemic patient. *Calif Vet* 2:12, 1978.
29. **Gaskin JM:** Psittacine viral diseases: A perspective. *J Zoo Wildlife Med* 20:249-264, 1989.
30. **Grechi R, Saliba AM, Mariano M:** Morphological changes, surface receptors and phagocytic potential of fowl mononuclear phagocytes and thrombocytes *in vivo* and *in vitro*. *J Path* 130:23-31, 1980.
31. **Gross WB, Siegel HS:** Evaluation of the heterophil/lymphocyte ratio as a measure of stress in chickens. *Avian Dis* 27:972-979, 1983.
32. **Hawkey CM, et al:** Normal and clinical haematology of captive cranes (Gruiformes). *Avian Pathol* 12:73-84, 1983.
33. **Hawkey CM, et al:** Haematological findings in healthy and sick African grey parrots (*Psittacus erithacus*). *Vet Rec* 111:580-582, 1983.
34. **Hawkey CM, Dennett TB:** Color Atlas of Comparative Veterinary Hematology. London, Wolfe Medical Publications, Ltd, 1989.
35. **Hodges RD:** The Histology of the Fowl. London, Academic Press, 1974.
36. **Hodges RD:** Normal avian (poultry) haematology. In Archer RK, Jeffcott LB (eds): Comparative Clinical Haematology. London, Blackwell Scientific Publications, 1977, pp 483-517.
37. **Jacobson ER, et al:** Epornitic of papova-like virus-associated disease in a psittacine nursery. *J Am Vet Med Assoc* 185:1337-1341, 1984.
38. **Law GRJ:** Blood samples from the jugular vein of turkeys. *Poult Sci* 39:1450-1452, 1960.
39. **Leighton FP, et al:** Heinz body hemolytic anemia from ingestion of crude oil: Primary toxic effect in marine birds. *Science* 220:871-873, 1983.
40. **Levine ND:** The genus *Atoxoplasma* (Protozoa, Apicomplexa). *J Parasitol* 68:719-723, 1982.
41. **Lind PJ, et al:** Morphology of the eosinophil in raptors. *J Assoc Avian Vet* 4:33-38, 1990.
42. **Lloyd M:** Heavy metal ingestion: Medical management and gastroscopic foreign body removal. *J Assoc Avian Vet* 6:25-29, 1992.
43. **Lothrop C, et al:** Miscellaneous diseases. In Harrison GJ, Harrison LR (eds): Clinical Avian Medicine and Surgery. Philadelphia, WB Saunders Co, 1986, pp 525-536.
44. **Lucas AJ, Jamroz C:** Atlas of Avian Hematology. USDA Monograph 25, Washington DC, 1961.
45. **Mac Arthur FN:** An improved method of obtaining blood from the chicken heart. *Poult Sci* 23:542-544, 1944.
46. **MacRae EK, Powell RE:** Cytochemical reaction for cationic proteins as a marker of primary granules during development in chick heterophils. *Histochemistry* 60:295-308, 1979.
47. **Maxwell MH:** Attempted induction of an avian eosinophilia using various agents. *Res Vet Sci* 29:293-297, 1980.
48. **Maxwell MH:** The production of a "Heinz body" anaemia in the domestic fowl after oral ingestion of dimethyl disulphide: A haematological and ultrastructural study. *Res Vet Sci* 30:233-238, 1981.
49. **Maxwell MH:** The effect of dietary rapeseed meal on the hematology and thrombocyte ultrastructure of the adult fowl. *Avian Pathol* 11:427-440, 1982.
50. **Maxwell MH:** Histochemical identification of tissue eosinophils in the inflammatory response of the fowl *Gallus domesticus*. *Res Vet Sci* 37:7-11, 1984.
51. **Maxwell MH, Burns RB:** Experimental stimulation of eosinophil stimulation and of eosinophil production in the domestic fowl. *Res Vet Sci* 41:114-123, 1986.
52. **Maxwell MH, Trejo F:** The ultrastructure of white blood cells and thrombocytes of the domestic fowl. *Br Vet J* 126:583-592, 1970.
53. **Miller RE, et al:** *Leucocytozoon simondi* infection in European and American eiders. *J Am Vet Med Assoc* 183:1241-1244, 1983.
54. **Montali RJ:** Comparative pathology of inflammation in the higher vertebrates (reptiles, birds, and mammals). *J Comp Path* 99:1-26, 1988.
55. **Natt MP, Herrick CA:** A new blood diluent for counting erythrocytes and leukocytes of the chicken. *Poult Sci* 31:735-738, 1952.
56. **Newcomer WS:** Factors which influence acidophilia induced by stresses in the chicken. *Am J Physiol* 194:251-254, 1958.
57. **Newell SM, McMillan MC, Moore FM:** Diagnosis and treatment of lymphocytic leukemia and malignant lymphoma in a Pekin duck (*Anas platyrhynchos domesticus*). *J Assoc Avian Vet* 5:83-86, 1991.
58. **Olson C:** Avian hematology. In Bester HE, Swarte LH (eds): Diseases of Poultry 5th ed. Ames, Iowa State University Press, 1965, pp 100-119.
59. **Osculati F:** Fine structural localization of acid phosphatase and arylsulfatase in the chick heterophil leukocytes. *Zeitschrift furr Zell Forschung und Mikroskopische Anatomie* 109:398-406, 1970.
60. **Penniall R, Spitznagel JK:** Chicken neutrophils: Oxidative metabolism in phagocytic cells devoid of myeloperoxidase. *Proc Natl Acad Sci* 72:5012-5015, 1975.
61. **Ploucha JM, Scott JB, Ringer RK:** Vascular and hematologic effects of hemorrhage in the chicken. *Am J Physiol* 240:H9-H17, 1981.
62. **Purchas GH, Burmester BD:** Leukosis/sarcoma group. In Hofstad MS, et al (eds): Diseases of Poultry. Ames, Iowa State University Press, 1978, pp 418-468.
63. **Rigdon RH, et al:** Anemia produced by chloramphenicol in the duck. *AMA Arch Pathol* 58:85-93, 1952.
64. **Roskopf WJ, et al:** Chronic endocrine disorder associated with inclusion body hepatitis in a sulfur-crested cockatoo. *J Am Vet Med Assoc* 179:1273-1276, 1981.
65. **Roskopf WJ, Woerpel RW:** Erythremic myelosis in conures: The "hemorrhagic conure syndrome." A preliminary report. *Proc Assoc Avian Vet*, 1984, pp 213-228.
66. **Ritchie BW, et al:** Avian polyomavirus: An overview. *J Assoc Avian Vet* 5:147-153, 1991.
67. **Schalm OW, Jain NC, Carroll EJ:** Veterinary Hematology 3rd ed. Philadelphia, Lea and Febiger, 1975, p 21.
68. **Siccardi FJ, Rutherford HO, Derieux WT:** Pathology and prevention of *Leucocytozoon smithi* infection of turkeys. *J Am Vet Med Assoc* 158:1902-1902, 1971.
69. **Siegel HS:** Blood cells and chemistry of young chickens during daily ACTH and cortisol administration. *Poult Sci* 47:1811, 1968.
70. **Soulsby EJL:** Helminths, Arthropods, and Protozoa of Domesticated Animals 7th ed. Philadelphia, Lea and Febiger, 1982.
71. **Stevens RWC, Ridgway GJ:** A technique for bleeding chickens from the jugular vein. *Poult Sci* 1966, 45:204-205.
72. **Sturkie PD:** Blood: Physical characteristics, formed elements, hemoglobin, and coagulation. In Sturkie PD (ed): Avian Physiology. New York, Springer-Verlag, 1976, pp 53-75.
73. **Tangredi BP:** Heterophilia and left shift with fatal diseases in four psittacine birds. *J Zoo An Med* 12:13-16, 1981.
74. **Taylor M:** Polycythemia in the blue and gold macaw: A case report of three cases. *Proc 1st Intl Conf Zool & Avian Med*, 1987, pp 95-104.
75. **Topp RC, Carlson HC:** Studies on avian heterophils, II: Histochemistry. *Avian Dis* 16:369-373, 1972.
76. **Topp RC, Carlson HC:** Studies on avian heterophils, III: Phagocytic properties. *Avian Dis* 16:374-380, 1972.
77. **Utter JM, Lefebvre EA, Greenlaw JJ:** A technique for sampling blood from small passerines. *Auk* 88:169-171, 1970.
78. **Villaume A:** A new technique for taking blood samples from ducks and geese. *Avian Pathol* 12:389-391, 1983.
79. **VanDerHeyden N:** Bone marrow aspiration technique in birds. *Proc Assoc Avian Vet*, 1986, pp 53-60.
80. **Wainright PO, et al:** Identification of viruses from Amazon parrots with a hemorrhagic syndrome and a chronic respiratory disease. *1st Intl Conf Zool & Avian Med*, 1987, pp 15-19.
81. **White J:** Protocol for the rehabilitation of oil-affected waterbirds. *Proc Assoc Avian Vet*, 1990, pp 153-163.
82. **Wight PAL, et al:** Monocytosis in experimental zinc deficiency of domestic birds. *Avian Pathol* 9:61-66, 1980.
83. **Wolford JH, Ringer RK:** Adrenal weight, adrenal ascorbic acid, adrenal cholesterol, and differential leukocyte counts as physiological indicators of "stressor" agents in laying hens. *Poult Dis* 23:366-385, 1978.
84. **Yuassa N, et al:** Isolation and some characteristics of an agent inducing anemia in chicks. *Avian Dis* 23:366-385, 1978.

**C**ytology is designed to be a rapid, inexpensive “in-house” diagnostic procedure, and the use of cytodiagnosis should be easily within the realm of any veterinary clinician. The basic cytodiagnosis of inflammation, tissue hyperplasia, malignant neoplasia and normal cellularity are easily differentiated from each other (see Figures 10.10, 10.11). One who is well versed in mammalian cytodiagnosis should have little trouble in the interpretation of avian samples. The goal is to achieve a quick presumptive or definitive diagnosis during the patient’s initial visit to the veterinary clinic in an effort to provide an immediate and specific treatment plan. Cytology can then be used to monitor the success of therapy by evaluating changes in microbial and cell populations within or on the host. Cytology should be considered as a part of the minimum database in birds with discharges, masses or swellings. Cytologic evaluation of tissue imprints and fluids collected during a postmortem examination can be used to develop a presumptive diagnosis that can guide disease management decisions within the flock until a definitive diagnosis is provided by culture, DNA probe or histopathology. Cytological samples are of greatest value if they are collected fresh and immediately processed for evaluation. To obtain a cytologic sample and send it to an outside laboratory defeats the purpose and usefulness of cytology. By cytologically examining antemortem and postmortem samples, the clinician can compare the information that is derived from cytology, radiographs, CBC, serum chemistries and histopathology. This will serve to improve understanding of the pathogenesis and cellular effects of a disease process.

CHAPTER

---

10

CYTOLOGY

■  
Terry W. Campbell

## Sample Collection

A variety of sample collection methods can be used to obtain samples for cytologic examination.<sup>4</sup> The method of choice depends upon the location and nature of the material being sampled. Cytologic sample collection methods can be divided into two broad categories: aspiration and contact smears.

### Sample Collection by Aspiration

Fine-needle aspiration biopsy is a simple, inexpensive procedure for obtaining material for cytologic examination (Figure 10.1). Using an alcohol swab, the skin overlying the biopsy site is cleansed and allowed to dry. Excessive application of alcohol should be avoided. A hypodermic needle (eg, 22 ga, one-inch needle) attached to a syringe (12 ml or larger) is inserted into the tissue to be sampled. A full vacuum is applied to the syringe using the syringe

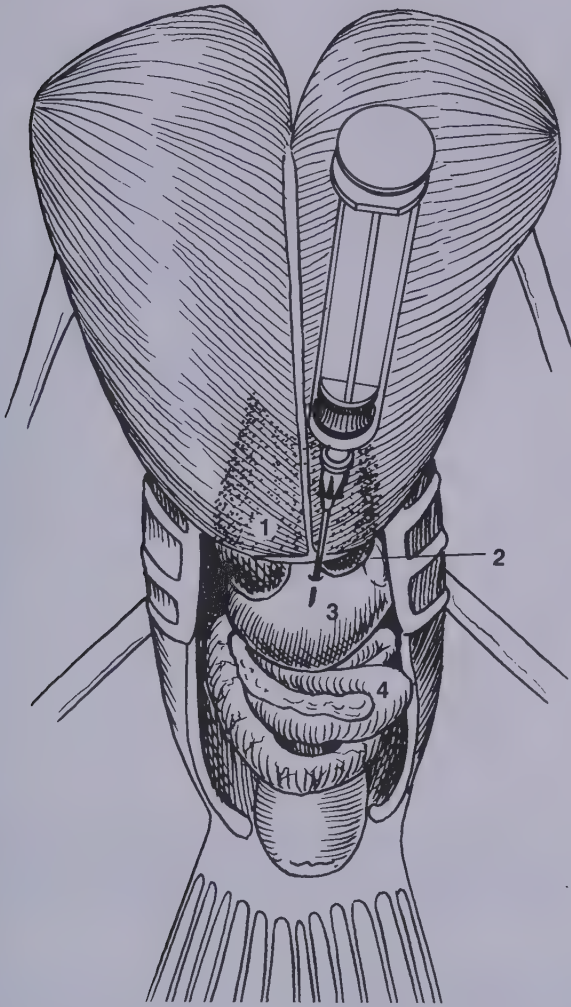


**FIG 10.1** A mature pigeon hen was presented for lameness, an unwillingness to fly and depression. The hen had been incubating eggs, and it was uncertain how long she had been clinically symptomatic. Several joints were swollen and firm. The elbow and ankle joints were severely affected. The masses in areas where the skin was thin appeared grossly as small, white-to-yellow nodules. Cytologic examination of a fine-needle aspirate from the mass revealed numerous crystalline structures suggestive of urate crystals. Articular gout is common in birds that become dehydrated or that have primary or secondary renal disease.

plunger. The needle is moved at different angles in the tissue without releasing the vacuum. It is important to release the vacuum before withdrawing the needle from the tissue, because the aim of the procedure is to obtain a small amount of sample in the lumen of the needle only, not in the syringe itself. Once the needle has been withdrawn from the tissue, it is detached from the syringe and the syringe is filled with air. The needle is reattached to the syringe, and with the point of the needle lying against the slide surface, the air within the syringe is used to force the sample onto a glass microscope slide. A second glass microscope slide placed on top of the first allows the sample to spread between the two glass surfaces when the slides are pulled horizontally apart. Two specimens for cytologic examination are thus created. This technique is often referred to as the “squash preparation technique” because the sample is compressed between the two slide surfaces.

Abdominocentesis is an aspiration biopsy procedure used to collect cytologic samples from birds with abdominal fluid accumulation. The abdominal space is small in normal birds and contains little fluid. Because the abdominal air sacs occupy a large portion of the abdomen, it is difficult to enter the peritoneal cavity of normal birds. However, as peritoneal fluids accumulate, the air sacs are compressed laterally, increasing the size of the peritoneal cavity and making it easier to sample. Abdominocentesis begins with a surgical preparation of the site along the ventral midline just distal to the point of the keel. The needle (21 to 25 ga, one-inch) is attached to a syringe and is directed through the body wall at the midline, pointing toward the right side of the abdomen to avoid the ventriculus, which lies to the left of the midline (Figure 10.2). The abdominal fluid is aspirated into the syringe and prepared for cytologic examination, either by making a direct smear as one would prepare a blood film or by using a concentration method.

The goal of abdominocentesis is to collect fluid from the abdominal cavity for diagnostic purposes. If the abdomen is distended with a soft-shelled egg, ovarian cyst, dislocated bowel loops or an abdominal mass, the fluid may not be collected during abdominocentesis. The material that is collected (eg, gut contents, egg yolk, cells from a mass) should be evaluated with respect to its potential source. Interestingly, some avian species (macaws) will produce *small* quantities of fluid in response to egg-related peritonitis, while others (cockatiels) will produce voluminous fluids.




**FIG 10.2** For abdominocentesis, the needle is attached to a syringe and is directed through the body wall at the midline, pointing toward the right side of the abdomen. 1) Caudal edge of sternum 2) liver 3) ventriculus and 4) intestines.

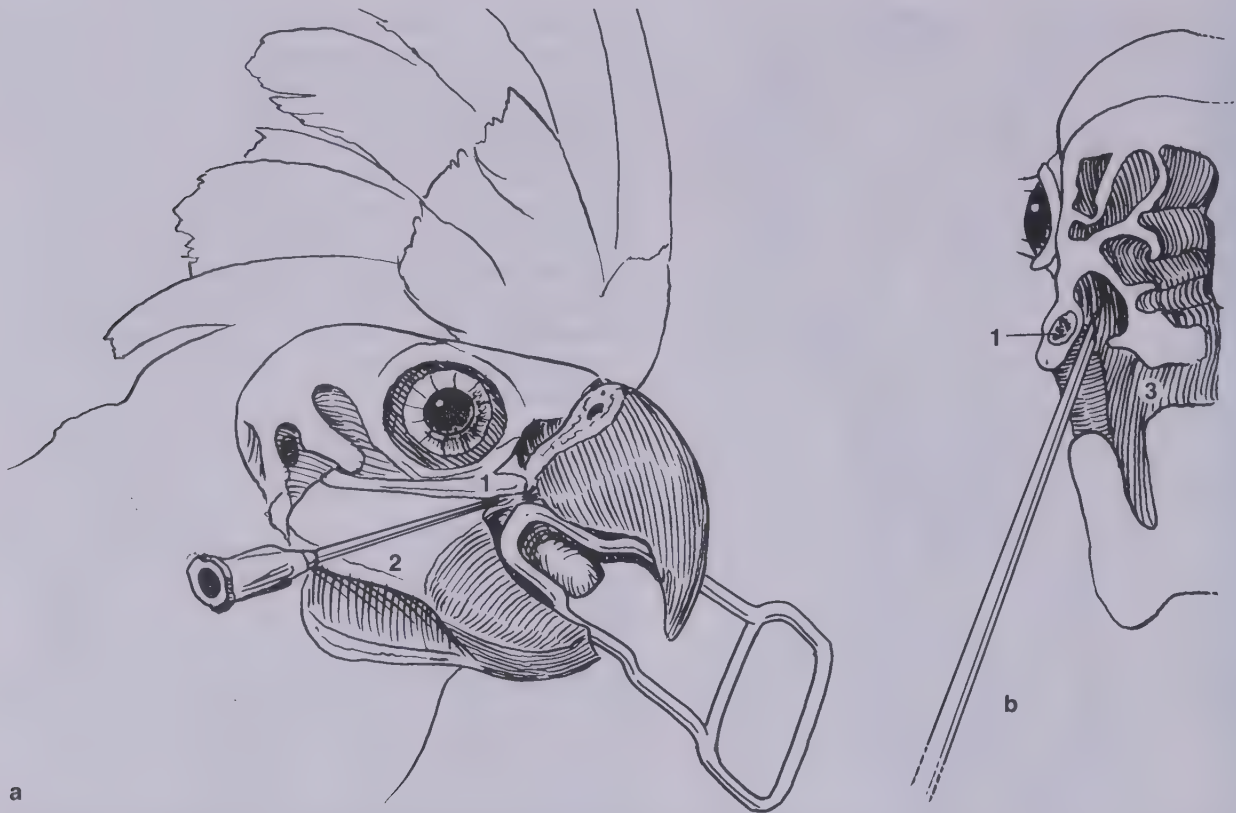
Fluid samples having low cellularity require a concentration procedure for easier examination of the cells. A variety of techniques can be used to concentrate cells on microscope slides. A simple method is to marginate the cells on a smear made by the conventional wedge technique used for making blood films. A drop of the fluid sample is placed on a microscope slide and spread slowly using a spreader slide. Just prior to reaching the end of the smear, the spreader slide is quickly backed slightly into the advancing smear, just before lifting it from the surface of the slide containing the smear. This should produce a slide with the margined cells concentrated at the end of the film.

Cells can be concentrated by centrifugation in a manner similar to that used in mammalian urinalysis procedures. The fluid is placed in a plastic test tube and centrifuged at 600 G (gravity) for ten minutes. Unlike urine sediments, cytologic sediments from poorly cellular fluids do not have a visible button or pellet at the bottom of a spun tube. Therefore, the concentrated cells are usually obtained by aspirating the fluid at the bottom of the tube into a pipette or syringe. The sample is then placed onto a microscope slide and a smear is made in the manner described for concentrating cells in a smear. Special cytocentrifuge equipment<sup>a</sup> is available for concentrating cells on microscope slides while absorbing the fluid onto filter paper. This equipment is expensive and not practical for the average veterinary laboratory.

Because centrifugation distorts the appearance of the cells, a cell concentration method that utilizes gravity provides a concentrated sample with normal appearing cells. A simple, inexpensive sedimentation device can be made for use in the veterinary laboratory. This device consists of a base to support the slide and a clamping mechanism to hold the fluid column onto the microscope slide (Figure 10.3). The column that holds the fluid is made from a one millimeter tuberculin syringe barrel with the tip removed. The base of the syringe barrel allows for the syringe to be held in place by a clamp (usually made of wood). A piece of filter paper (eg, Whatman #2) is cut to the dimensions of the microscope slide and a standard 2 mm paper hole punch is used to create a hole in the center of the filter paper. The filter paper is placed on top of the slide, and the base of the tuberculin syringe barrel is placed on top of the filter paper with the opening of the syringe superimposed over the hole in



**FIG 10.3** Centrifugation can distort the appearance of cells that are intended for cytologic evaluation. A simple device that uses gravity to concentrate cells provides cytologic samples of better quality than centrifugation (courtesy of Terry Campbell).



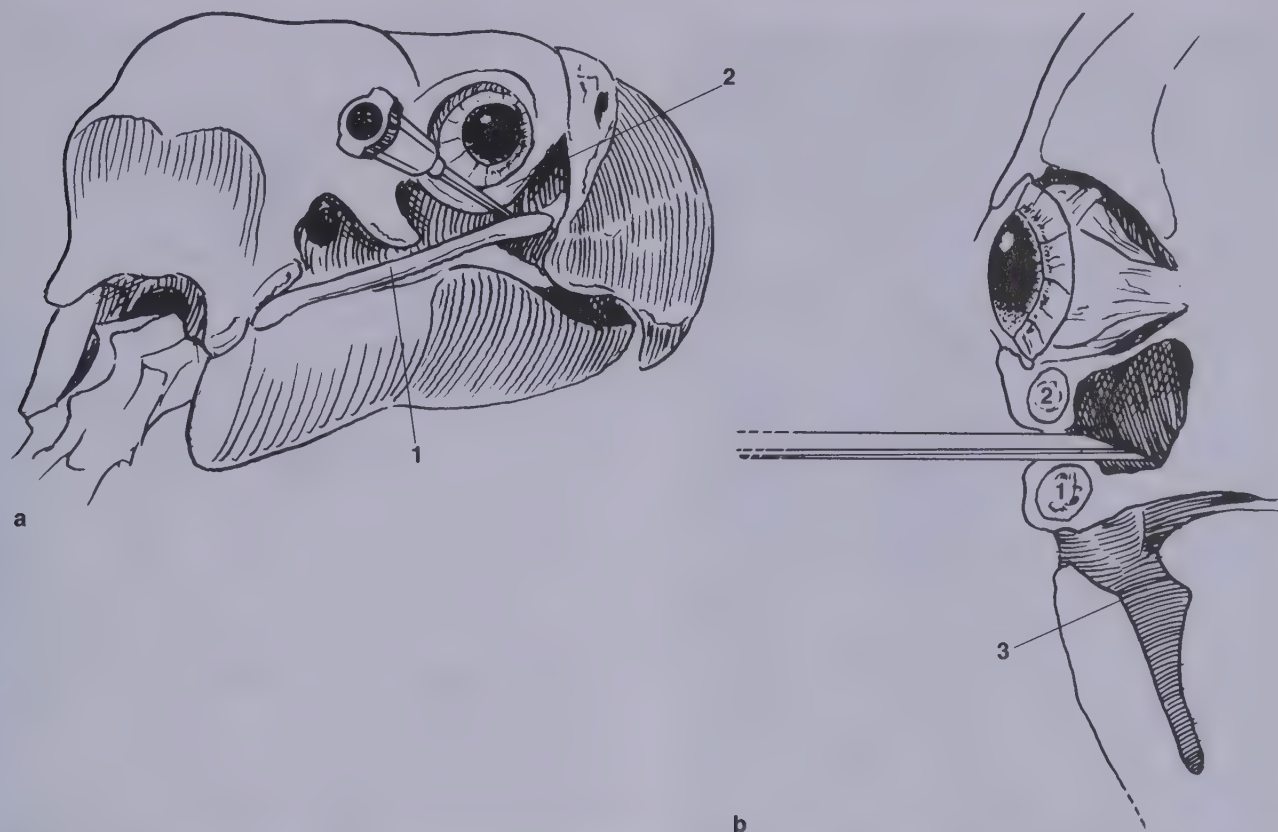
**FIG 10.4** Aspiration of the infraorbital diverticulum of the infraorbital sinus in psittacine birds can be performed by **a**) passing a needle through the fleshy skin at the commissure of the mouth and directing it toward a point midway between the eye and external nares, **b**) keeping parallel with the side of the head and passing under the zygomatic arch. 1) Zygomatic arch 2) mandible 3) oral cavity.

the filter paper. The clamp is used to secure the column to the slide. A small amount of fluid (eg, 0.2 to 0.5 ml) is placed into the syringe column. When allowed to stand undisturbed, the fluid is drawn by gravity and absorbed into the filter paper. The cells in the fluid fall onto the surface of the slide where they adhere. Once the fluid has drained from the column, the apparatus is disassembled and the slide is allowed to air dry. After staining, the cells can be found concentrated in the two millimeter circle created by the filter paper and column.

Cytologic evaluation of the ingluvies (crop) can be performed from samples obtained by aspiration. This is indicated in birds showing clinical signs of regurgitation, vomiting, delayed emptying of the crop or other crop disorders. A crop aspirate is obtained by inserting a sterile plastic, metal or rubber feeding tube through the mouth and esophagus into the ingluvies (see Figure 15.6). The tube should pass freely and not be forced into the crop. Passage of the tube is facilitated by extending the head and neck to straighten the esophagus. The crop content is gently

aspirated into the tube using a syringe attached to the free end. Excessive vacuum should be avoided to prevent damage to the crop mucosa. In cases where material cannot be aspirated for examination, a wash sample can be obtained by infusing a small amount of sterile isotonic saline into the crop and aspirating the fluid back into the tube and syringe.

Aspiration of the infraorbital sinus of birds suffering from sinusitis can provide diagnostic material for culture and cytologic examination. One technique of sinus aspiration in psittacine birds samples the large sinus between the eye and the external nares (Figure 10.4). With the head and body properly restrained, a needle (eg, 22 ga one-inch) is passed through the fleshy skin at the commissure of the mouth. The needle is directed toward a point midway between the eye and external nares, keeping parallel with the side of the head. The needle passes under the zygomatic bone, which lies between the lower corner of the rhinotheca (upper beak) and the ear. Often the passage of the needle is improved by keeping the bird's mouth open with an oral speculum. Once the



**FIG 10.5** The infraorbital diverticulum immediately beneath the eye can be approached by passing a needle **a**) over the zygomatic arch, with **b**) the needle directed rostrally. This procedure requires some practice and complete restraint to prevent damage to the globe. 1) Zygomatic arch 2) suborbital arch of prefrontal and temporal bone 3) oral cavity.

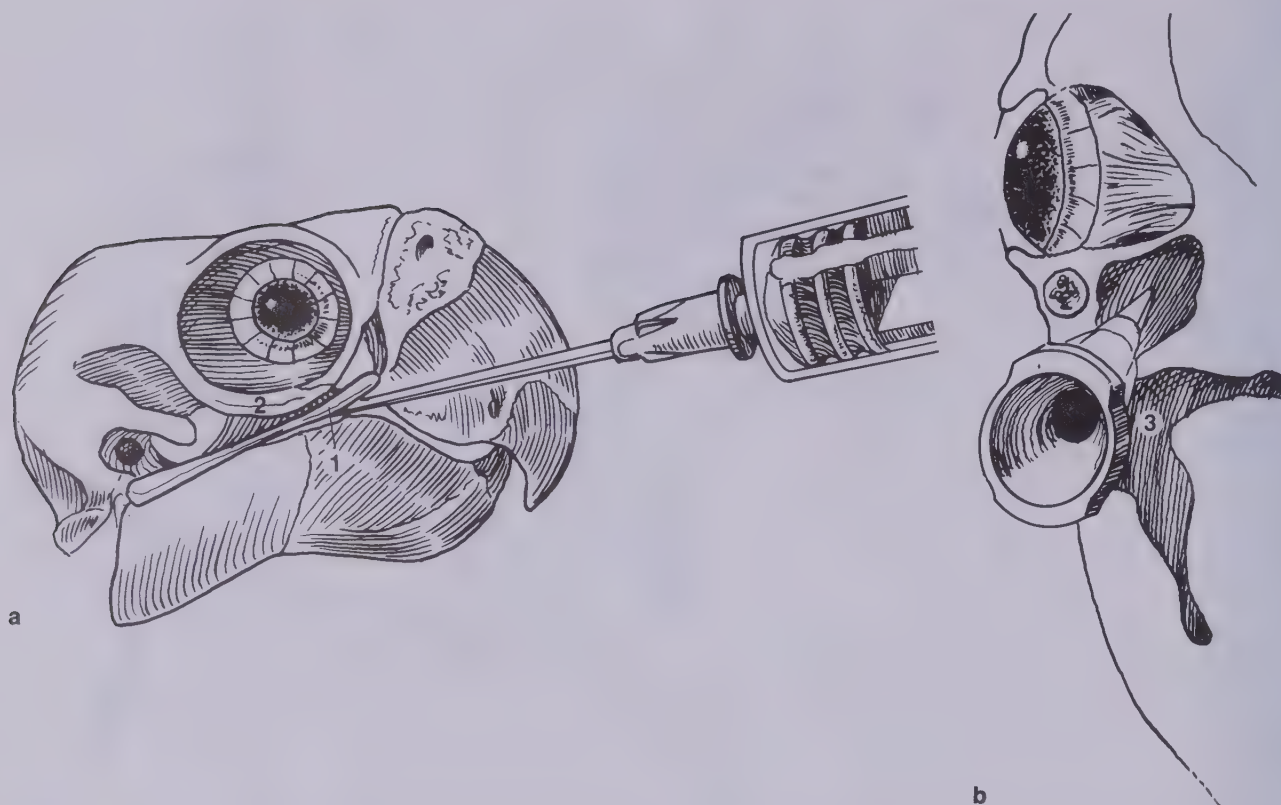
needle has entered the sinus, the sinus contents can be aspirated. A caudally misdirected needle could result in penetration of the ocular orbit; however, more commonly, a misdirected needle results in penetration of the surrounding muscles, causing peripheral blood contamination of the sample. It is important to note that in some species (eg, some passerine birds), the sinuses may not communicate with each other as they do in psittacine birds. Therefore, a bilateral sinusitis may require bilateral aspirations. (*Ed note: If a routine sinus flush does not produce an adequate sample, the anesthetized bird may be held with the head parallel to the floor and the affected sinus down. The sinus is flushed from underneath with the needle directed up; see Chapter 22.*)

A second site of sinus aspiration is the small sinus immediately below the eye. This sinus usually yields a smaller sample volume than the previously described sinus. This sinus can be entered directly by inserting the aspiration needle at a perpendicular angle through the skin just below the eye (Figure 10.5). It can also be approached from a rostral direc-

tion by entering through the commissure of the mouth, directing the needle under the zygomatic bone and ending in the sinus cavity below the eye (Figure 10.6).

Collection of synovial fluid by arthrocentesis is another example of sample collection by aspiration. After the skin over the joint has been prepared as for surgery, a needle (22 ga or smaller) attached to a syringe is used to aspirate a small amount of fluid by direct penetration of the joint space. The cytologic sample is prepared by making direct smears using the "squash preparation technique."

Wash samples are aspiration techniques in which a small amount of sterile isotonic saline is infused into an area and immediately re-aspirated in an effort to collect a cytologic sample from locations that may be difficult to sample or that provide a poorly cellular field. Tracheal washes are commonly performed in birds suspected of having respiratory disease of the trachea, syrinx and bronchi. Depending on the patient, this procedure can be performed with or with-



**FIG 10.6** Aspiration of the suborbital diverticulum of the infraorbital sinus can be accomplished by **a**) entering through the commissure of the mouth, directing the needle under the zygomatic bone and **b**) ending in the sinus cavity below the eye. 1) Zygomatic arch 2) suborbital arch 3) oral cavity.

out general anesthesia. A soft, smooth-tipped, sterile plastic or rubber tube or catheter small enough to pass through the trachea is inserted through the open glottis taking care not to contaminate the tip in the oral cavity. The tube is passed to the level of the thoracic inlet near the syringe. An oral speculum should be used in birds (eg, large psittacine birds) capable of biting off the tube. The animal is held parallel to the floor, and sterile saline (0.5 to 2 ml/kg body weight) is quickly infused into the trachea and immediately re-aspirated to complete the wash sample. Similar wash techniques can be used to collect cytologic samples from the air sacs, ingluvies and infraorbital sinus.

### ■ Contact Smears

Cytologic samples can also be obtained by direct contact between the tissue being sampled and the microscope slide. Often referred to as contact smears, these samples are used to evaluate postmortem tissues or antemortem tissue biopsies. Imprints of solid tissues should be made from freshly cut surfaces that

have been blotted with a clean paper towel to remove the excess fluid and blood. It is best to lay the slide against the tissue surface using the weight of the slide to make the imprint. If the tissue is brought to the slide, too much force is used and the resulting specimen is too thick for evaluation.

Contact smears made from tissues that exfoliate poorly (eg, connective tissue) may require traumatic exfoliation to improve the cellularity. One method of improving cellular exfoliation is to scrape the tissue to be sampled with a scalpel blade and to make the contact smear from either the scraped surface or the material remaining on the scalpel blade. Using a drop of oil on the scalpel blade may improve the ability to detect mites but will interfere with staining for cytologic evaluation. Imprints should be made from biopsy of internal organs (eg, liver, spleen and kidney) using the impression technique.

Scrapings are commonly performed to collect cells from the palpebral conjunctiva, cornea, oral cavity or tissues that normally yield poorly cellular samples. A metal or plastic spatula is used to gently scrape these



tissues, and the exfoliated cells are transferred to a microscope slide.

Cytologic samples can also be obtained using a sterile swab.<sup>b</sup> Once the sample has been collected, the swab is gently rolled across the surface of a clean microscope slide, using light pressure in order to avoid cell damage. The swab should be rolled in one direction only and not rolled back and forth across the smear to prevent the creation of an excessively thick smear. Cytologic samples of internal tissues can be obtained using endoscopic equipment. Samples can be obtained either from the tip of the endoscope or by using brushes or biopsy forceps. The sample is applied directly to a microscope slide.

## Evaluation of the Cytologic Sample

Tables 10.1 to 10.3 describe the use of stains most commonly available for cytology.

### Classification of Cells and Cellular Responses

The cells observed in the cytologic sample can be classified as either hemic, epithelial, mesenchymal or nervous tissue cells.<sup>13</sup> Hemic cells are those cells found in the blood and the hematopoietic tissues (see Chapter 9). It is extremely important to recognize

TABLE 10.2 Results of Cytologic Staining

	STAIN USE	RESULTS
<b>Acid-fast stain</b>	Mycobacterium . . . . .	red
	Other bacteria . . . . .	blue
	Leukocytes . . . . .	blue
	Cellular debris . . . . .	blue
<b>Giemsa stain</b>	Cell nuclei . . . . .	reddish purple
	Chlamydial elementary bodies . . . . .	purple
	initial bodies . . . . .	blue
	Mycoplasma . . . . .	pink or purple
<b>Gram's stain</b>	Gram-positive bacteria . . . . .	violet
	Gram-negative bacteria . . . . .	red
	Eukaryotic cells (except yeast) . . . . .	red
	Yeast . . . . .	deep violet
<b>Modified Gimenez stain</b>	Chlamydial elementary bodies . . . . .	red
	initial bodies . . . . .	blue
	Heterophil granules . . . . .	red
	Eosinophil granules . . . . .	red
	Mycoplasma . . . . .	like chlamydia
<b>New methylene blue stain</b>	Granulocytes . . . . .	purple nuclei, pale blue cytoplasm
	Erythrocytes . . . . .	purple nuclei, distinct cytoplasmic border, cytoplasm greenish blue
	Heterophil granules . . . . .	not stained
	Eosinophil granules . . . . .	not stained
	Fibrin . . . . .	not stained
<b>Stamp stain</b>	Chlamydia, rickettsia . . . . .	bright red
	Cocci tissue, other organisms . . . . .	green
<b>Sudan III stain</b>	Fat globules . . . . .	red-orange
	Cell nuclei . . . . .	blue
	Cell cytoplasm . . . . .	green
<b>Wright's stain</b>	Blood cells(see hematology)	

TABLE 10.1 Cytologic Stains Commonly Used in Avian Practice

- 1. Romanowsky stains (Wright's and Wright-Giemsa)**  
These stains are commonly used for peripheral blood films and routine cytology. They require air-dried smears. Commercially prepared quick stains are available to simplify the staining procedure. These stains can be used to prepare a permanently stained slide.
- 2. New Methylene Blue stain**  
This is a routine cytologic stain used as a wet preparation on dried smears. It does not provide a permanent stain. It is useful in the demonstration of fibrin, lipid droplets, fungal hyphae and other structures that stain poorly with alcohol-based stains.
- 3. Acid-fast stain**  
This specific stain is used to demonstrate acid-fast positive organisms, such as *Mycobacterium* sp. Acid-fast positive organisms stain red, whereas other bacteria stain blue. This stain is not used to evaluate cells.
- 4. Gram's stain**  
This is a microbiologic stain used primarily for the classification of bacteria grown on culture media. Gram-positive organisms stain deep violet, whereas gram-negative organisms stain red. Because of the nature of material on most cytologic preparations, it is difficult to

achieve uniformity of staining on the smear. This stain is not used to evaluate cells.

- 5. Macchiavello's stain**  
This stain is used to identify chlamydia and mycoplasma inclusions. Chlamydia elementary bodies (0.2 - 0.3 μ) stain red, whereas the initial bodies (0.9-1.0 μ) stain blue. Mycoplasma colonies resemble chlamydia. Other particles in some smears may stain red and make the interpretation of the smear difficult. This stain is not used to evaluate cells.
- 6. Gimenez stain**  
This stain is used to identify chlamydia inclusions which stain red against a blue-green cellular background. There is less interference with non-chlamydia particles staining red with this stain as compared to Macchiavello's stain. This stain is not used to evaluate cells.
- 7. Stamp stain**  
This stain is used to detect chlamydia and rickettsia, which appear as small, bright red, "cocci" intracytoplasmic inclusions.
- 8. Giemsa stain**  
This stain is used to identify chlamydia and mycoplasma.

hemic cells because these cells can be either important features of the cellular response or common contaminants of the cytologic sample.

Epithelial cells typically exfoliate easily and are found in clusters or sheets.<sup>13</sup> Epithelial cells vary in shape depending upon their origin. They can be oval, cuboidal, columnar or polygonal (eg, squamous epithelial cells). Epithelial cells typically have an abundant cytoplasm, small round-to-oval nuclei and distinct cytoplasmic margins. Cells from secretory epithelium may contain cytoplasmic granules or vacuoles.

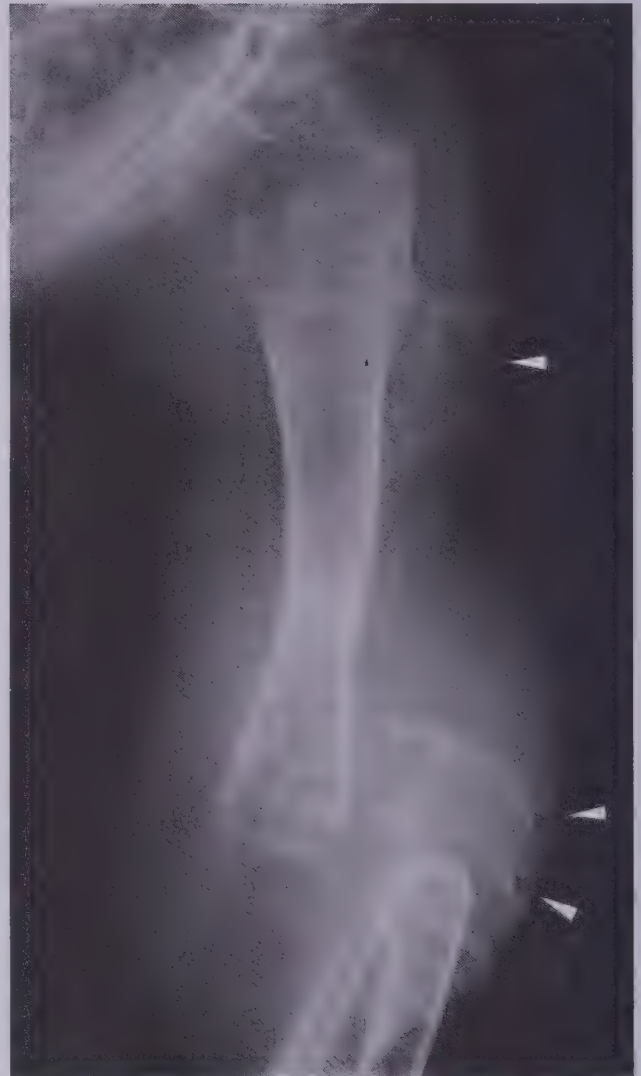Mesenchymal cells tend to exfoliate poorly and normally occur as single cells. These cells vary in shape and usually have indistinct cytoplasmic margins. The fibroblast is the most frequently encountered cell of this group. Fibroblasts are typically spindle-shaped with small nuclei that usually follow the shape of the cell. The cytoplasm has indistinct margins. Fibroblasts usually exfoliate as single cells rather than in sheets or clusters.

Nervous tissue cells are rare in cytologic specimens.<sup>13</sup> They may be seen as deeply basophilic, stellate cells with cytoplasmic projections.

During the cytologic examination, an assessment of the cells is made by identifying the majority of the cell types, the morphology of the cells and character of the noncellular background. The goal of cytology is to identify the cellular message and classify the cell response into one of the basic cytodiagnostic groups. These groups include inflammation, tissue hyperplasia or benign neoplasia, malignant neoplasia and normal cellularity.<sup>14</sup>

### ■ Inflammation

A cytodiagnosis of inflammation is made when an increased number of inflammatory cells is detected in the cytologic sample. The inflammatory cells of birds are heterophils, lymphocytes, plasma cells and macrophages (Figure 10.7). Peripheral blood heterophils and lymphocytes have been described in the hematology chapter. It should be emphasized that heterophils found in tissues and fluids other than peripheral blood may not appear the same as those found in hemic tissue. Heterophils found in inflammatory lesions often degranulate and may resemble mammalian neutrophils. Depending upon the microenvironment, they may appear degenerate. Plasma cells are large, oval lymphocytes with an



**FIG 10.7** Cytology is an effective technique for differentiating between masses caused by infectious agents and those caused by neoplasia. In this goose, several fine-needle aspirates from a soft tissue mass associated with a humeral fracture revealed numerous degenerating heterophils and macrophages containing phagocytized bacteria suggestive of osteomyelitis. There were no pleomorphic cells, abnormal nuclei or mitotic figures suggestive of a neoplasm. Because neoplastic cells were not demonstrated, the client chose surgical removal of the humerus, which was uneventful. The presence of feather follicles (arrows) visible on the displaced antebrachium should not be confused with intralesional gas production.

abundant, deeply basophilic cytoplasm; an eccentric, mature nucleus; and a prominent perinuclear halo (Golgi). Macrophages are large cells with an abundant cytoplasm that may contain small granules, vacuoles or foreign material. Macrophages and their nuclei vary in shape and can coalesce into multinucleated giant cells.

Eosinophils may be included in the list of inflammatory cells; however, eosinophilic inflammation is either extremely rare in birds or difficult to detect based on routine cytologic methods. Heterophils and eosinophils may be difficult to differentiate in cytologic samples using the standard Romanowsky stains. Eosinophils of domestic fowl stain peroxidase-positive and heterophils stain peroxidase-negative with the benzidine or p-phenylenediamine methods.<sup>9,11</sup> A suspected eosinophilic inflammatory response may be confirmed by peroxidase staining; however, one must keep in mind that cytochemical staining may vary among avian species. Avian eosinophils may not behave in the same manner as mammalian eosinophils.<sup>2,7,8,10</sup> Because these cells were given the same name, there is an implied similar function, but the function of avian eosinophils is currently unknown.<sup>11</sup>

The inflammatory response is classified as either heterophilic, mixed-cell or macrophagic inflammation based upon the types of inflammatory cells present.

Heterophilic inflammation is represented by a predominance of heterophils (greater than 70 percent of the inflammatory cells) in the cellular response. Heterophilic inflammation indicates an acute inflammatory response in birds.<sup>11</sup> It is important to examine the heterophils closely for signs of degeneration or phagocytized material.

Degenerate heterophils indicate a toxic microenvironment, usually caused by microbial toxins. Degenerative changes in heterophils include increased cytoplasmic basophilia, vacuolation, degranulation and nuclear karyolysis. If bacterial phagocytosis can be demonstrated, the cytodagnosis of septic heterophilic inflammation can be made. If only extracellular bacteria are found, it cannot be determined that there is a bacterial etiology since the extracellular bacteria may represent either normal flora (depending upon the location of the inflammation) or contaminants of the sample.

Because macrophages migrate quickly (within a few hours of onset) into inflammatory lesions, mixed-cell inflammation is the most commonly found inflammatory response in birds.<sup>11</sup> Mixed-cell inflammation is represented by the presence of heterophils and mononuclear leukocytes (eg, macrophages, plasma cells and lymphocytes). Heterophils represent at least 50 percent of the inflammatory cells in mixed-cell inflammatory responses. Mixed-cell inflammation usu-

ally represents an established, active inflammation. The heterophils in this type of inflammation are usually nondegenerate, suggesting a microenvironment free of microbial toxins even though there may be a bacterial etiology.

Macrophagic inflammation is indicated by the predominance of macrophages (greater than 50 percent) in the inflammatory response. This type of inflammation does not necessarily imply chronicity, but may be suggestive of a number of etiologies (eg, intracellular pathogens). Macrophagic inflammation is common to certain avian diseases. These include avian tuberculosis, chlamydiosis, foreign body reaction, mycotic infections and cutaneous xanthomatosis. Multinucleated giant cell formation is often associated with macrophagic inflammation. Giant cells can appear within hours of the onset of some inflammatory responses and, unlike in mammals, their presence does not imply chronic inflammation.<sup>1,5,12</sup>

### ■ Tissue Hyperplasia or Benign Neoplasia

Tissue hyperplasia resulting from cellular injury or chronic stimulation is difficult to differentiate from benign neoplasia based upon cytology. Cells from hyperplastic tissue appear mature and do not exhibit much pleomorphism. They may appear immature by exhibiting increased cytoplasmic basophilia owing to the increased RNA activity within the cell.<sup>14</sup> Proliferating cells may also exhibit an increase in mitotic figures; however, the nuclear features do not show immaturity. Examples of tissue hyperplasia, frequently seen in birds, include the fibrous and epithelial cell proliferation adjacent to chronic inflammatory lesions, thyroid hyperplasia (especially in budgerigars) and squamous hyperplasia secondary to hypovitaminosis A. A common benign neoplasm of birds is the lipoma, especially in budgerigars (see Color 25).

### ■ Malignant Neoplasia

Cells obtained from malignant neoplasms show varying degrees of pleomorphism. The severity of the malignancy increases with the greater degree of pleomorphism. The appearance of the cell nucleus can provide important clues to the detection of a malignant neoplasm.<sup>14</sup> Increased nuclear size, which is reflected by an increased nucleus to cytoplasm (N:C) ratio, is suggestive of an abnormal cell. Nuclear anisocytosis (variation in size) and pleomorphism (variable nuclear shapes) are features of malignant cells. Multinucleation can also be a feature of malignancy.

The nuclear chromatin may also be abnormal in malignant cells. Coarse, hyperchromatic chromatin is suggestive of neoplasia. Other nuclear features of malignant cells include abnormal nucleoli (very large or multiple, such as greater than five), irregular nuclear margins, abnormal or increased mitotic figures and abnormal lobation, especially in cells that normally do not have lobed nuclei.

Cytoplasmic features of malignant cells include increased basophilia, abnormal vacuolation or inclusions, decreased volume, variation in cell margins and variability in the staining.<sup>14</sup> Abnormal cytoplasmic inclusions may include satellite nuclei (small nuclear fragments) and phagocytized cells.

Once a decision has been made for the cytodiagnosis of malignant neoplasia, an attempt to classify the neoplasm should be made. The four basic classifications of malignant neoplasms based upon cytologic features include carcinomas, sarcomas, discrete-cell neoplasia and poorly differentiated neoplasia.<sup>14</sup> Carcinomas are malignancies of the epithelial cells; therefore, the abnormal cells in the sample have features of epithelial cells. Adenocarcinomas are frequently seen in birds, especially ovarian adenocarcinomas. Cytologic evidence of adenocarcinomas includes epithelial cells that tend to form giant cells, have cytoplasmic secretory vacuoles and tend to occur in aggregates (eg, balls, rosettes or loose groupings). Sarcomas are malignancies of mesenchymal cells and therefore tend to exfoliate cells poorly. Fibrosarcomas are the most frequently encountered sarcomas of birds (see Color 25). Cells from fibrosarcomas are abnormal-appearing fibroblasts, which are spindle-shaped cells that typically exfoliate as single cells. Abnormal fibroblasts show increased cellular size and N:C ratios, nuclear and cellular pleomorphism and exfoliation when compared with normal fibrous tissue. Other mesenchymal cell neoplasms such as chondromas, chondrosarcomas and osteogenic sarcomas may produce a heavy eosinophilic background material (chondroid or osteoid) that can be seen on the microscope sample.

A common discrete or round cell neoplasm of birds is lymphoid neoplasia (see Color 25). The abnormal lymphocytes found in this type of neoplasm exfoliate extremely well. Cellular features of malignant lymphocytic tissue include a marked increase in the number of lymphoblasts, nuclear and cellular pleomorphism, increase in cytoplasmic basophilia and mitotic figures, and abnormal or multiple nucleoli.

Poorly differentiated neoplasms produce cells having features of malignant neoplasia; however, the cells are difficult to classify as carcinomas or sarcomas. In such cases, a cytodiagnosis of a poorly differentiated neoplasm is made.

Circumstantial evidence for a malignant neoplasm without the demonstration of abnormal cells is seen in older birds (eg, female budgerigars) with a spontaneous hemoperitoneum and no history of trauma. This is suggestive of an ulcerated neoplasm leading to abdominal hemorrhage. Ovarian adenocarcinomas of budgerigars and cockatiels often present in this manner. Evidence for malignancy may also be obtained by the demonstration of ectopic cells in unusual anatomic areas. An example of this would be the presence of a large number of cells other than hepatocytes and hemic cells in a cytologic sample of the liver. This is suggestive of a metastatic lesion, even if the cells do not have features of malignant neoplasia.

#### ■ Mixed Cellular Response

Occasionally, a mixed-cellular response may be seen, especially in areas of ulcerated neoplasms. A cytologic sample obtained from an ulcerated neoplasm may reveal features of malignant neoplasia as well as inflammation or hemorrhagic effusion.

## Cytology of Commonly Sampled Fluids and Tissues

#### ■ Abdominal Fluids

Birds presented with abdominal distention may have an abnormal accumulation of fluid within the peritoneal cavity that may be detected by palpation or radiology. Cytologic evaluation of this fluid is often the main technique for establishing a presumptive or definitive diagnosis.

Abdominal effusions can be classified based upon cellularity, types of cells present, protein content, specific gravity and gross appearance. Abdominal fluids are classified as transudates, modified transudates, exudates, hemorrhage and malignant effusion.<sup>14</sup> Transudates are odorless, transparent fluids characterized by a low cellularity (total cell counts

usually less than 1000 /mm<sup>3</sup>), a specific gravity less than 1.020 and a total protein less than 3.0 g/dl. Transudates are typically colorless or have a straw color resembling diluted serum. Transudative effusions do not clot. These poorly cellular fluids contain primarily macrophages and occasional mesothelial cells. Transudates occur as a result of oncotic pressure changes or other circulatory disturbances. The same causes for abdominal transudative effusions in mammals most likely occur in birds. These include hepatic cirrhosis, cardiac insufficiency and hypoproteinemia.

Modified transudates resemble transudative effusions; however, they have an increased cellularity (total cell counts usually less than 5000 /mm<sup>3</sup> but greater than 1000 /mm<sup>3</sup>). The mononuclear leukocytes predominate in this type of effusion with occasional mesothelial cells and rare heterophils. The mesothelial cells usually appear reactive. Reactive mesothelial cells tend to be round or oval with increased cytoplasmic basophilia (Color 10.1). The cell margins often have a scalloped or villus-like appearance. The nuclei have coarse chromatin and prominent nucleoli. Multinucleation, cytoplasmic vacuolation and mitotic activity are often associated with reactive mesothelial cells. Proliferation of mesothelial cells results in the exfoliation of mesothelial cell aggregates that appear as cellular sheets, balls or rosettes (Color 10.2). Care should be taken not to mistake these cells for malignant neoplasia. Modified transudates result from hydrostatic pressure changes or irritation of long-standing transudative effusions. Transudative and modified transudative effusions are commonly found in the abdominal cavity of mynah birds suffering from hemochromatosis.

Exudative effusions are characterized by high cellularity (total cell counts usually greater than 5000 /mm<sup>3</sup>), a specific gravity greater than 1.020 and a protein content greater than 3.0 g/dl. The majority of the cells found in exudative effusions are inflammatory cells (Color 10.3). Acute exudative effusions demonstrate primarily a heterophilic inflammatory response; however, macrophages quickly move into the fluid, creating a mixed-cell inflammatory response within a few hours of onset. Lymphocytes and plasma cells are often seen in long-standing exudative effusions. Exudative effusions vary in color and turbidity. They are frequently viscous, have a foul odor and tend to clot. Abdominal lesions often associated with exudative effusions include septic peritonitis, egg-related peritonitis and abdominal malignancies.

Hemorrhagic effusions are identified by the presence of erythrocytic phagocytosis in the fluid sample (Color 10.4). Without demonstration of erythrocytic phagocytosis, one cannot differentiate hemorrhage from peripheral blood contamination of the sample. If thrombocytes are present, the sample was most likely contaminated with peripheral blood during the sampling procedure. Thrombocytes disappear rapidly in hemorrhagic effusions. Proof of erythrocytic phagocytosis is made by the detection of macrophages that have phagocytized erythrocytes (suggestive of recent hemorrhage), or that contain iron pigment or hemosiderin crystals resulting from erythrocyte degradation (implying a duration greater than 48 hours). Iron pigment appears as gray to blue-black pigment in the cytoplasm of macrophages using Wright's stain. Hemosiderin appears as diamond-shaped, golden crystals within the macrophage cytoplasm.

Malignant effusions have features of either exudative or hemorrhagic effusions, but contain cells compatible with malignant neoplasia (Color 10.5, 10.6). Abdominal effusions caused by neoplasms are the result of blockage of blood or lymphatic vessels. Cystadenocarcinomas of the ovary of older female birds are a common cause of malignant effusions. These effusions can resemble hemorrhagic or exudative effusions that contain epithelial cells with features of malignant neoplasia. These cells often form cellular aggregates of balls or rosettes and have cytoplasmic secretory vacuolation.

Urate peritonitis is a rare effusion that can occur in the abdomen of birds when urinary fluids leak into the abdominal cavity. The cytology of the acute lesion is poorly cellular but contains a marked number of sodium and potassium urate crystals. These crystals are the same ones found in the urate portion of the bird's droppings. Urate crystals are spherical (2 to 8 mm) and have a spoke-wheel appearance. They are also birefringent under polarized light. The milky appearance of this type of abdominal effusion resembles that of the urate portion of avian droppings. If the bird survives this condition long enough, inflammatory cells will migrate into the fluid.

### ■ Cytology of the Alimentary Tract

The oral cavity, esophagus, ingluvies (crop) and cloaca are often sampled for cytologic examination. Lesions in the oral cavity may have different etiologies but similar gross appearance. Therefore, sampling of oral lesions for cytologic examination is a quick and simple procedure for differentiation of these etiolo-

gies. The differential diagnoses for common oral lesions include septic stomatitis, candidiasis, trichomoniasis and squamous cell hyperplasia. The normal cytology of the oral cavity shows occasional squamous epithelial cells, varying amounts of background debris and extracellular bacteria represented by a variety of morphologic types (Color 10.7). Bacteria associated with the surface of squamous epithelial cells are considered part of the normal flora. *Alysiella filiformis*, a gram-negative bacteria common to the upper alimentary tract of birds, occurs as small coccobacilli in pairs forming ribbon-like chains, and is often associated with squamous epithelial cells (Color 10.8).<sup>6</sup>

Smears made from a bacterial abscess reveal either a heterophilic or mixed-cell inflammation with bacterial phagocytosis (Color 10.9, 10.10). Heterophils may appear degenerate if bacterial toxins are present. Squamous epithelial cells are usually present. An increase in the amount of background debris and bacteria is also common.

Cytologic evidence for candidiasis is the presence of numerous narrowly based budding yeast (Color 10.11). *Candida* yeast are typically oval and often stain deeply basophilic with the Romanowsky stains. Occasionally they stain poorly, however, and may appear as "ghosts" in the cytologic specimen. *Candida* sp. can be a normal inhabitant of the upper alimentary tract of birds and may average as few as one per high power field (40x). The cytodagnosis of candidiasis is made when the yeast increase in numbers. Because these organisms can be part of the normal flora of the upper alimentary tract of birds, low numbers of the yeast do not usually elicit an inflammatory response. However, an inflammatory response often occurs when the infection has involved the mucosa indicating the condition has become more serious. The presence of hyphae formation also indicates a potential lethal infection and suggests a systemic involvement by the yeast (Color 10.12).

Trichomoniasis is best diagnosed by observing the movement of the piriform flagellate protozoa in a wet mount preparation. However, it is important to recognize these organisms in a stained cytologic sample if wet mount preparations are not part of the cytologic routine or trichomoniasis is not suspected. Trichomonads appear as basophilic, piriform cells with flagella on Wright's stained smears (Color 10.13, 10.14). These cells vary in staining intensity from poorly stained to deeply basophilic. The cell nucleus usually stains more eosinophilic than most cell nu-

clei. An eosinophilic axostyle can often be seen as a straight line running from the nucleus to the opposite pole of the cell. Eosinophilic flagella at the nuclear end and an undulating membrane on one side of the cell are usually present. Because trichomonas protozoa are not considered part of the normal flora and fauna of the alimentary tract of birds, an inflammatory response is usually found associated with trichomoniasis lesions. Much debris and extracellular bacteria are usually present. The gross appearance of trichomoniasis can vary from ulcerations to the accumulation of large amounts of necrotic debris, depending on the host (species)-parasite relationship.

The gross appearance of lesions caused by squamous hyperplasia and metaplasia from hypovitaminosis A can resemble lesions caused by bacteria, yeast and protozoa; however, the cytology has a very different appearance. Normally, squamous epithelial cells exfoliate as single cells or small groups following gentle scraping of the oral cavity. However, lesions resulting from squamous cell hyperplasia produce smears containing large numbers of cornified squamous epithelial cells that exfoliate in large sheets or aggregates. In the early stages of this condition, there is little background debris. Therefore, the cytology resembles that of the vaginal cytology of a dog in estrus. It is equally important in the diagnosis of squamous cell hyperplasia to note what is not present in the cytologic specimen. One does not see inflammatory cells (at least in acute lesions), yeast or protozoa. Squamous hyperplasia often occurs in the tissue surrounding the choanal slit in the roof of the mouth. As this lesion becomes increasingly chronic, secondary bacterial infections often occur, creating a septic inflammatory response associated with the squamous cell hyperplasia on the cytologic sample.

Cytologic evaluation of the esophagus and ingluvies (crop) is indicated in birds with clinical signs of regurgitation, vomiting, delayed crop emptying or other suspected esophageal and crop disorders. The normal cytology reveals occasional squamous epithelial cells and a variable amount of background debris and extracellular bacteria (represented by a variety of morphologic types). A rare yeast is accepted as normal. It should be emphasized that some foods (eg, monkey biscuits) fed to birds may contain yeast as a source of supplemental B vitamins. In these birds, there may be a high number of nonbudding yeast in a cytologic sample (see Color 8). In addition, the crop will have a normal pH and no other cytologic abnormalities. A sample of the food can be stained to confirm the source of the nonbudding yeast.

The same lesions and cytodiaognoses described for the oral cavity also apply to the normal cytologies of the esophagus and crop. Another cytologic indication of a disorder involving the esophagus and crop is the presence of many bacteria represented by one morphologic type (as compared to the normal variety of types), even though there is no apparent inflammatory response (Color 10.15). This condition is typical of a peracute ingluvitis, and the disorder is often referred to as “sour crop.” It is indicative of a peracute bacterial infection, and an inflammatory response has either not been established or the response has been overwhelmed and the degenerate heterophils cannot be recognized in the background debris. The pH is often greater than 7, whereas normal crop pH is 6.5 to 7. *Capillaria* ova may be detected in cytologic samples from the esophagus or crop of some birds with capillariasis. These ova are double operculated and may not stain (see Chapter 36).

Examination of the cloacal cytology is indicated whenever a disorder of the lower intestinal tract, reproductive tract, urinary tract or cloaca is suspected. The normal cytology of the cloaca reveals a few epithelial cells (noncornified squamous or columnar), extracellular bacteria (variety of morphologic types), background debris and urate crystals. Abnormal findings would include the presence of inflammatory cells, large numbers of yeast and a uniform population of bacteria. Because the cloaca is a common opening to the intestinal tract, urinary tract and reproductive tract, cells found in cloacal samples may have originated from any of these systems or the cloacal tissue. Therefore, if inflammatory cells are found, for example, one cannot determine which system is involved based upon cytologic findings alone.

The use of a speculum and a swab or tube may allow collection of cytologic samples at the cloacal opening of the intestinal tract, urinary tract or reproductive tract. Uterine samples may be obtained through the cervix, especially in hens that have recently laid eggs. Abnormal post-parturient hens (usually showing uterine inflammation) may require flushing of the uterus with lactated Ringer's solution until the inflammatory cells disappear from the wash fluid. Cytology of the lower intestinal tract is usually poorly cellular with occasional epithelial cells, background debris and a variety of extracellular bacteria. Special stains may be required for the detection of pathogens, such as *Mycobacterium* and *Giardia* spp (see Table 10.1).

The normal fluid excreted from the urinary tract of birds is a poorly cellular, cream-colored, thick, mucoid semisolid (see Color 8). The cytology reveals a marked amount of sodium and potassium urate crystals. Abnormal urinary fluid is watery and may contain cellular elements such as inflammatory cells and cellular casts.

### ■ Cytology of the Respiratory Tract

The normal cytology of the nasal and infraorbital sinuses of birds reveals occasional noncornified squamous epithelial cells and low numbers of extracellular bacteria with little background debris. The normal cytology of tracheal wash samples consists of a few ciliated respiratory epithelial cells and goblet cells (Color 10.16, 10.17). An occasional squamous epithelial cell may be found. These cells may represent cellular contamination from the oral cavity if the end of the tube is not passed directly into the glottis or they may originate from the syrinx, which contains bistratified squamous epithelium in some birds. Ciliated respiratory epithelial cells are columnar or prismatic in shape and have an eccentric nucleus at the small pole of the cell. Eosinophilic cilia are located at the opposite, larger pole of the cell. Goblet cells are columnar cells with eccentric nuclei. They lack cilia but contain eosinophilic cytoplasmic granules and vacuoles.

Cytologic evidence for periorbital sinusitis is provided by the presence of inflammatory cells in the aspirate. Lesions with a bacterial etiology are indicated by a septic, heterophilic or mixed-cell inflammation. Mycotic lesions often reveal either a mixed-cell or macrophagic inflammation with the presence of fungal elements, such as yeast, hyphae or spores. Sinus infections associated with chlamydia often reveal a mixed-cell or macrophagic inflammation (Color 10.18). Chlamydial inclusions appear as small, blue-to-purple spherules, often in dense clusters, within the cytoplasm of macrophages when stained with Wright's stain. Chlamydial stains, such as Gimenez or Macchiavello's stains, may be used to aid in the detection of chlamydia (see Color 10.33). The chlamydial inclusions appear red, and the host cells appear blue-green with Gimenez stain. The chlamydial elementary bodies stain red, and the larger initial bodies stain blue with Macchiavello's stain (see Color 10.34).

A septic tracheobronchitis is identified from a tracheal wash sample by the presence of inflammatory cells showing bacterial phagocytosis. An endoscope is

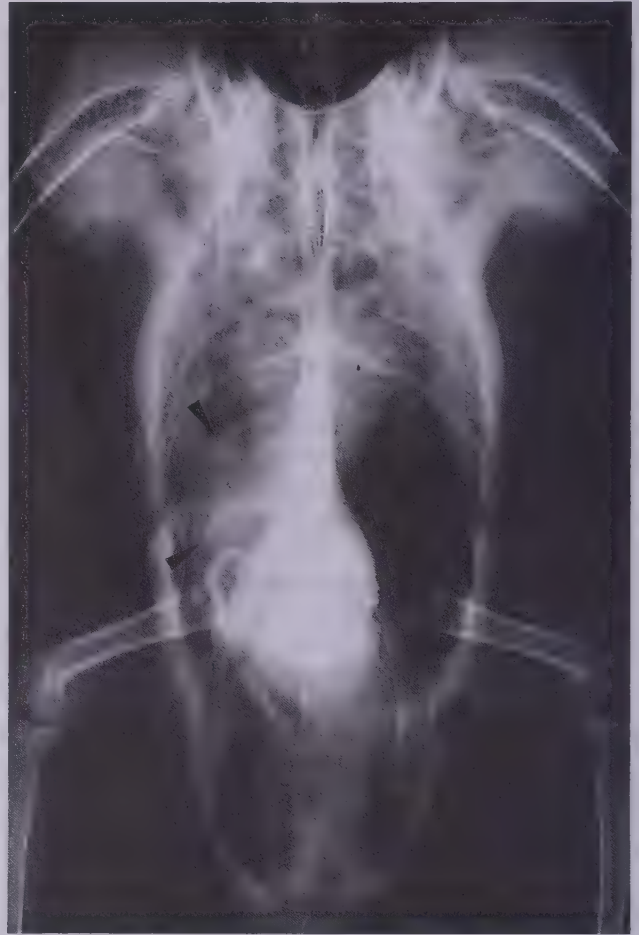excellent for collecting cytologic samples from the trachea of psittacine birds the size of an Amazon parrot or larger. In severe cases, the ciliated respiratory epithelial cells appear degenerate. Degenerate respiratory epithelial cells show loss of cilia, cytoplasmic vacuolation and karyolysis. Degeneration and fragmentation of the ciliated respiratory epithelial cells in association with a macrophagic and lymphocytic inflammation are suggestive of a viral etiology. Inflammation of the trachea and bronchi usually results in an increase in goblet cells and mucin formation, which causes an increased thickness to the noncellular background.

Mycotic lesions involving the trachea, syrinx and bronchi may reveal fungal elements on the tracheal wash samples. Aspergillosis is a common fungal pathogen of the avian respiratory tract. Aspergillosis is characterized by thick, septate hyphae that branch at 45° angles (Color 10.19, 10.20). Occasionally conidiophores can be seen. Other fungal lesions, such as phycomycosis, may reveal nonseptate, branching hyphae (Figure 10.8). Mycotic lesions usually reveal a mixed-cell or macrophagic inflammation. Aspiration of foreign material also results in a macrophagic inflammation. A mixed-cell inflammation generally occurs when secondary bacterial pathogens become involved.

The cytologic evaluation of the lower respiratory tract (lungs and air sacs) is made from either biopsy samples, endoscopy impressions or imprints from necropsy specimens. Imprints of avian lung tissue have an alveolar-like appearance microscopically. The walls of these alveolar-like structures may reveal abnormal cytologic findings of inflammatory cells and etiologic agents such as yeast or fungi (Color 10.19, 10.20). Lung tissue is highly vascularized and imprints usually contain a marked number of erythrocytes.

Normal air sac samples are poorly cellular with the presence of a few noncornified epithelial cells. Bacterial infections show the typical septic inflammatory patterns. Chlamydial and mycotic lesions demonstrate mixed-cell or macrophagic inflammation with the presence of chlamydial inclusions or fungal elements, respectively.

Neoplastic lesions of the respiratory tract of birds are rare; however, they can occur. Cytologic evidence for malignant neoplasia is the presence of cells showing features of malignant cells. A secondary inflammatory response is often associated with malignant lesions.



**FIG 10.8** A mature Blue and Gold Macaw hen was presented for progressive dyspnea and weight loss of two weeks' duration. Radiographs indicated a diffuse soft tissue density in the right caudal thoracic air sac (arrows). Endoscopy indicated a white thickening of the air sac. Impression smears of endoscopically guided biopsies revealed branching fungal hyphae characteristic of aspergillosis. Abnormal clinical pathology findings were limited to marked leukocytosis (WBC=35,000). An agar gel diffusion test was considered positive for *Aspergillus* sp. antibodies.

### ■ Cytology of the Skin

Bacterial infections involving the skin are usually associated with a heterophilic or mixed-cell inflammation. Cytology of skin samples typically contains squamous epithelial cells, debris and extracellular bacteria. Therefore, bacterial phagocytosis must be demonstrated to detect a septic inflammatory lesion.

Foreign bodies typically create a macrophagic inflammatory response with multinucleated giant cell formation. If a secondary bacterial infection has been established, lesions caused by foreign bodies may show a mixed-cell inflammatory response.



Cutaneous xanthomatosis is a unique condition of birds caused by an excessive accumulation of lipids in the skin (see Color 25). A macrophagic inflammatory response with multinucleated giant cells and cholesterol crystals is observed on the cytologic specimen (Color 10.21, 10.22). Cholesterol crystals appear as angular, translucent crystals that vary in size and shape. They often appear stacked upon each other. Skin affected with xanthomatosis is thickened, yellow and friable. It is often found in areas where previous hemorrhage (eg, feather cysts and skin trauma) or pressure from underlying tumors (eg, lipomas) has occurred (see Color 25).

Subcutaneous lipomas produce a cytologic specimen that appears “greasy” on the unstained slide. The cytology reveals numerous lipocytes, which vary in size (Color 10.23). Avian lipocytes often have large cytoplasmic vacuoles in association with clusters of small vacuoles. The vacuoles tend to be round. The cell nucleus appears pyknotic and pushed to one edge of the cell, often appearing as if pushed beyond the cell margin. The background material in slides from lipomas resembles the cytoplasm of the lipocytes and contains numerous fat droplets. These clear, round, fat droplets usually partially dissolve in the alcohol-based stains (eg, Wright’s stain) but are easily seen in the water-soluble stains such as new methylene blue. Special fat stains such as Sudan IV can be used to demonstrate the fat droplets.

The cytology of feather cysts varies, depending upon the chronicity of the lesion (see Color 24). Early stages of feather cyst development reveal a marked number of red blood cells in the sample. Often erythrophagocytosis can be found. As the lesion becomes more chronic and caseous exudation develops, the cytology resembles that of mixed-cell inflammation with a marked amount of background debris and occasional multinucleated giant cell formation. Feather fragments may also be found.

Cutaneous and subcutaneous malignant neoplasms are rare in birds, but can be detected on cytologic examination. Lymphoid neoplasia produces a highly cellular sample of immature lymphocytes (Color 10.24). These lymphoblasts and prolymphocytes are large, round cells that exfoliate as single cells. They have large nuclei with fine chromatin and multiple or large prominent nucleoli. The cytoplasm stains basophilic. Bizarre-appearing lymphocytes and mitotic figures may also be present. The background of lymphoid tissue, such as lymphoid neoplasms, typically contains small, irregular, blue cytoplasmic frag-

ments. Finding these fragments may be helpful in the cytologic identification of lymphoid tissue.

Cutaneous melanomas have also been found in birds. Poorly differentiated melanomas reveal mesenchymal cells that contain few cytoplasmic melanin granules. The gross appearance of the involved skin shows dark pigmentation. The malignant cells usually exfoliate as single cells, and the background may contain melanin granules from ruptured cells. The round melanin granules vary from black to dark brown to golden in color.

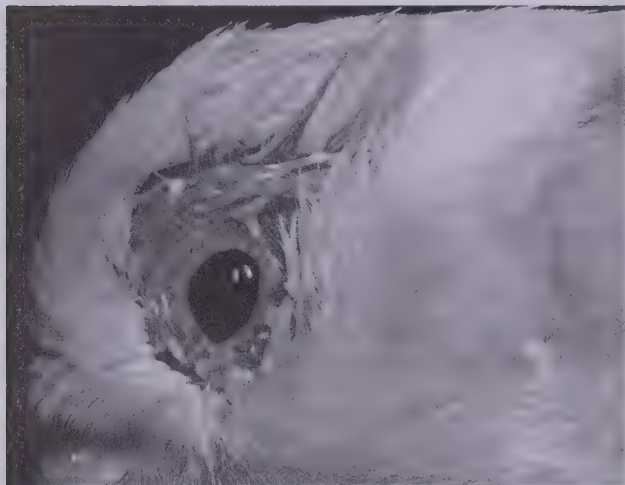
Avian poxvirus lesions reveal clusters of squamous epithelial cells that contain large cytoplasmic vacuoles (Color 10.25). The large cytoplasmic vacuoles found in the affected squamous cell push the cell nucleus to the cell margin. These vacuoles represent the ballooning degeneration of the squamous epithelium typical of pox lesions. These cytoplasmic vacuoles often contain small, pale eosinophilic inclusions with oil immersion examination of Wright’s stained smears. A secondary septic inflammatory response is often associated with ulcerated pox lesions.

### ■ Cytology of the Cornea and Conjunctiva

Normal conjunctival scrapings provide poorly cellular samples with little background material. The cells normally found are epithelial cells that may contain intracytoplasmic pigment granules. The normal cytology of the cornea is also poorly cellular and consists of occasional noncornified squamous epithelial cells. Inflammatory lesions involving the cornea and conjunctiva reveal inflammatory cells and increased numbers of exfoliated epithelial cells. The epithelial cells often demonstrate degenerative changes, such as cytoplasmic vacuolation, karyolysis or karyorrhexis. Chronic inflammatory lesions may show an increase in the number of epithelial cells that contain pigment granules. Chronic lesions may also reveal the presence of cornified squamous epithelial cells that are not normally found in the conjunctiva or cornea (Figure 10.9).

### ■ Cytology of Synovial Fluid

The amount of fluid in synovial joints of most birds is normally too small for sampling; however, an abnormal accumulation of joint fluid may provide enough sample for evaluation. Normal synovial fluid is poorly cellular. The cells are mononuclear cells, representing either synovial lining cells or mononuclear leukocytes. The background of normal synovial fluid



**FIG 10.9** An adult canary was presented with bilateral epiphora and mild conjunctivitis. Cytologic evaluation of conjunctiva scrapings may have been helpful in determining an etiology for this bird's problems. This bird responded to treatment with tylosin (courtesy of Michael Murray).

cytology consists of a heavy, granular, eosinophilic substance representing the mucin in the fluid.

An increase in the inflammatory cells and change in the color, clarity, and viscosity of the fluid is indicative of inflammatory joint lesions (see Figure 12.77). There may be a decrease in the granular eosinophilic background material, suggesting a decrease in mucin content. Erosion of the articular cartilage may result in the presence of multinucleated osteoclasts in the synovial fluid. Spindle-shaped fibroblasts suggest erosion into the fibrous layer of the articular capsule. Septic joint lesions may demonstrate bacterial phagocytosis by leukocytes (primarily heterophils). An increase in the number of inflammatory cells, especially heterophils, is also seen with traumatic arthritis. The presence of erythrocytes and erythrophagocytosis is supportive of a cytodagnosis of hemarthrosis.

Articular gout produces a cream-to-yellow-colored deposit in affected joints (see Color 21). The cytology of this material reveals numerous, needle-shaped crystals (monosodium urate) (Color 10.26). These crystals are birefringent under polarized light. They occasionally stain eosinophilic with Wright's stain. Inflammatory cells are often present and the mucin content is often reduced, as reflected in the reduction in the amount of eosinophilic granular background.

## ■ Cytology of Internal Organs

The liver, kidney and spleen are occasionally sampled by biopsy to achieve an antemortem diagnosis in birds. Cytologic evaluation should also be performed whenever lesions involving these organs are found on postmortem examinations.

Birds typically do not have lymph nodes as found in mammals. Avian lymphoid tissue appears as lymphoid aggregates in the walls of the intestines, internal organs (especially the spleen and liver) and skin. The cloacal bursa of young birds is a sac-like lymphoid nodule found in the dorsal wall of the proctodeum of the cloaca (see Figure 5.6). The cytology of normal lymphoid tissue shows a predominance of small mature lymphocytes (greater than 90 percent of the lymphoid cells) (Color 10.27). The larger prolymphocytes, lymphoblasts and plasma cells normally occur in low numbers. Reactive lymphoid tissue demonstrates an increase in the number of immature lymphocytes (prolymphocytes and lymphoblast) and plasma cells (Color 10.28). Reactivity of the lymphoid tissue is suggestive of antigenic stimulation of the immune system. Lymphoid hyperplasia causes an increase in the lymphoid tissue mass; however, the cytology appears normal with the exception of a slight increase in the number of prolymphocytes. Lymphoid neoplasia produces a marked increase in the number of immature lymphocytes, especially lymphoblasts, in the cytologic specimen. The neoplastic cells may show varying degrees of cellular features of malignant neoplasia. There is usually an increase in the number of mitotic figures in samples obtained from lymphoid neoplasia.

Cytologic samples of the liver are usually highly cellular with a predominance of hepatocytes, erythrocytes and free nuclei. Depending upon the location of sampling, there may be numerous lymphocytes present. Hepatocytes are large epithelial cells that occur in sheets or clusters or as single cells. Normal hepatic cytology reveals uniform-appearing hepatocytes. These cells have an abundant, basophilic, finely granular cytoplasm and a round-to-oval, slightly eccentric nucleus. Binucleation is occasionally seen. Hepatocytes are easily ruptured during slide preparation; therefore, the background of hepatic tissue resembles that of the hepatocyte cytoplasm, and many free nuclei are commonly seen. Normal hematopoiesis is occasionally found because the liver is a common location for ectopic hematopoiesis. Also, macrophages containing iron pigment (hemosiderin) are occasionally seen.

Inflammatory lesions of the liver reveal numerous mature heterophils and an increase in the number of macrophages and plasma cells (Color 10.29). It is important not to confuse normal ectopic granulopoiesis with heterophilic inflammation. If developing stages of the heterophils can be found, the cytology is representative of granulocytopenia (see Chapter 9). If the heterophils are mature cells, however, then the cytology indicates inflammation. The hepatocytes may demonstrate degenerative changes in the presence of hepatic inflammation.

Avian tuberculosis produces a macrophagic inflammatory response in the liver (see Color 20). The cytology reveals numerous macrophages and multinucleated giant cells. When stained with Romanowsky stain, the background of the smear contains numerous large bacterial rods that do not stain. Likewise, macrophages may contain numerous bacterial rods that do not stain (Color 10.30). Because mycobacterium have a waxy cell wall, they do not stain with routine cytology stains. Therefore, an acid-fast stain is required to demonstrate the tubercle bacilli, which stain red (Color 10.31). However, the presence of a macrophagic inflammation with multinucleated giant cells and "ghost-like" bacterial rods provides a presumptive diagnosis for tuberculosis.

Avian chlamydiosis often results in a mixed-cell or macrophagic inflammation in the liver with a marked increase in the number of plasma cells (Color 10.28). Small, blue-to-purple, intracytoplasmic inclusions suggestive of chlamydial elementary and initial bodies may be seen in macrophages (Color 10.32). Confirmation of chlamydial inclusions is aided by special stains (eg, Gimenez or Macchiavello's).

Hepatic lipidosis produces cytologic specimens that appear "greasy" on gross examination. The stained smears reveal enlarged hepatocytes that contain round, cytoplasmic vacuoles (Color 10.35). The background material also contains these round vacuoles suggestive of lipid material.

Primary neoplasm of the liver reveals hepatocytes showing features of malignant neoplasia. Affected cells are usually pleomorphic with deep, cytoplasmic basophilia and immature-appearing nuclei (eg, smooth nuclear chromatin and multiple or large prominent nucleoli). Ectopic cells that show features of malignant neoplasia may also be found and are indicative of a metastatic lesion in the liver.

Occasionally, parasites may be found on hepatic imprints (Color 10.36). Those commonly seen are schizogony of *Haemoproteus* and *Leukocytozoon*, sporozoites of *Atoxoplasma* and microfilaria.

Normally, cytology of the spleen shows a marked number of erythrocytes and lymphocytes, reflecting the cytology of a lymphoid tissue. Macrophages are also present and occasionally contain iron pigment from erythrophagocytosis of senescent red cells. Excessive splenic iron pigment is seen in birds with hemolytic anemia owing to increased red cell degradation by the spleen (Color 10.37). Chlamydial infections often cause a marked increase in the number of splenic plasma cells. Macrophages often demonstrate intracytoplasmic chlamydial inclusions. Developmental stages of blood parasites may also be found in splenic samples (see Color 9). Systemic bacterial or fungal infections may result in an increase in the number of inflammatory cells, especially mature heterophils, in the spleen. Often, the etiologic agent can be found either within the leukocytes or in the non-cellular background.

The normal kidney produces a highly cellular sample that contains numerous epithelial cells with an abundant, slightly basophilic cytoplasm and slightly eccentric, round-to-oval nuclei. Numerous erythrocytes and free cell nuclei are usually present. Urate crystals are also common. Abnormal cytology includes an increase in the number of inflammatory cells or the presence of cells having features of neoplasia. Epithelial cells from renal adenomas show increased cytoplasmic basophilia, slight pleomorphism and occasional mitotic figures. Renal adenocarcinomas produce epithelial cells having features of malignant neoplasia. Nephroblastomas (embryonal nephroma) produce poorly differentiated epithelial and mesenchymal cells. The cuboidal epithelial cells are associated with spindle-shaped cells of the fibrous stroma, and the background may contain a heavy, eosinophilic substance. This background material is suggestive of a cellular attempt to produce a matrix (eg, chondroid or osteoid).

---

#### Products Mentioned in the Text

- a. Cytospin, Shandon Southern Instruments, Sewickley, PA
- b. Calgiswab, Inolex, Glenwood, IL

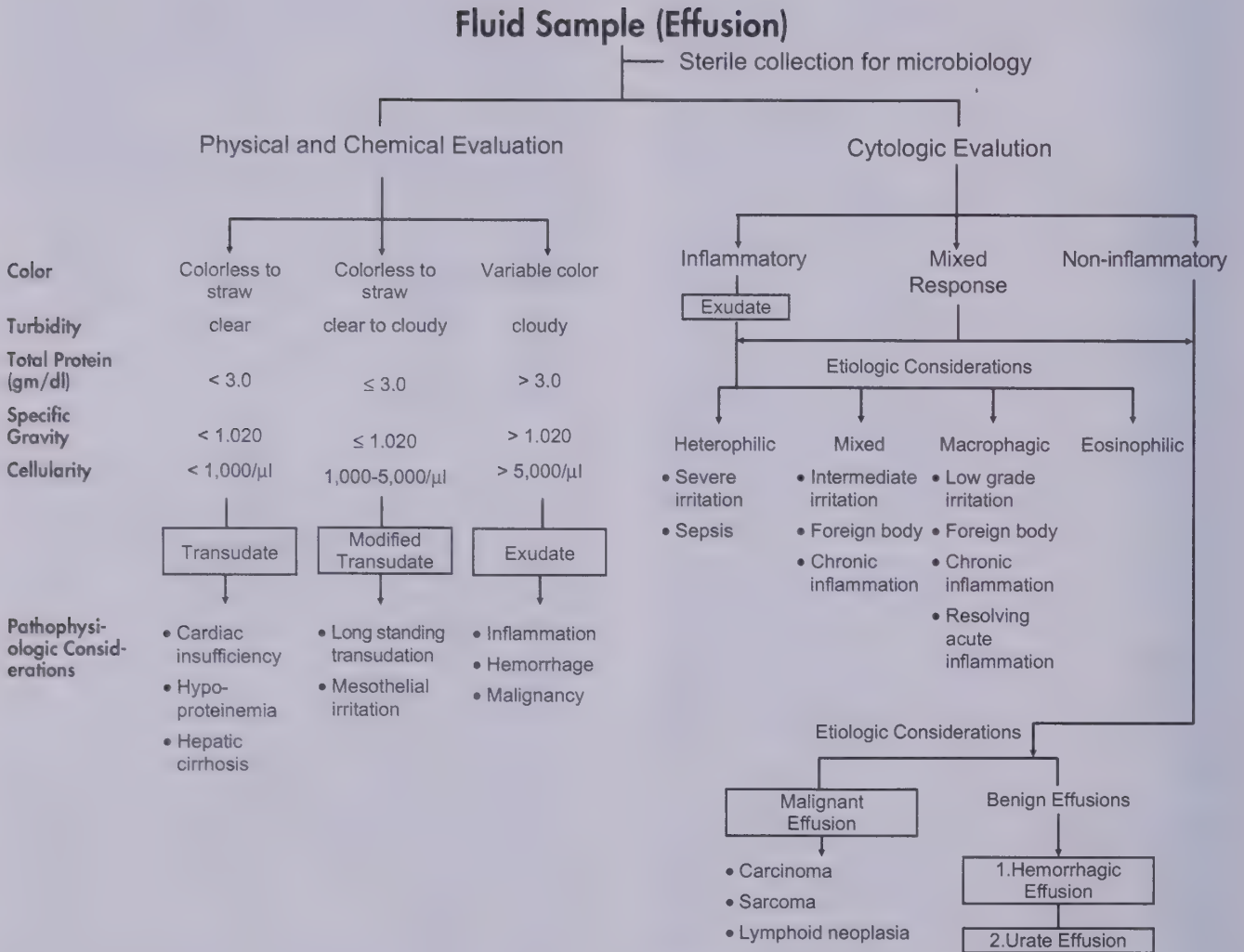


FIG 10.10 Flow chart for characterization of fluids

### Solid Sample

Sterile collection for microbiology

Air-dried Smear

Wet Mount

Microscopic examination for protozoa or motile organisms

Dry

Greasy

(suggests high lipid content)

New Methylene Blue Stain  
Fat Stains (ie, Sudan III)

Romanowsky type Stain (ie, Wright's stain)

Examination with Low Magnification (10x, 20x)

1. Note cellularity (poor, moderate, highly cellular)
2. Identify cellular groupings (cellular aggregates)
3. Look for cellular areas for examination at higher magnification
4. Assess overall staining
5. Identify large etiologic agents (ie, yeast and fungal elements)

Examination with High Magnification (40x, 100x)

1. Examine cell populations and cell structures
2. Begin to categorize the overall cellular response
3. Identify any etiologic agent present
4. Evaluate the noncellular background for thickness, staining characteristics, foreign material, bacteria, lipid droplets and crystals

Inflammatory

Mixed Response

Non-inflammatory

Heterophilic  
(> 70% Heterophils)

Mixed  
(50-70% Heterophils)

Macrophagic  
(> 50% Mononuclear leukocytes)

Normal

Hyperplasia/  
Benign Neoplasia

Malignant  
Neoplasia

Degenerate Heterophils

- Suggestive of potential toxins
- Evaluate for infectious agent

Nondegenerate Heterophils

- Infectious etiology
- Non-infectious etiology

- Resolving phase of heterophilic inflammation
- Etiology did not cause heterophilic inflammation
- Pyogranulomatous inflammation (etiologies include mycotic infections, chronic bacterial infections, chlamydiosis and foreign body reactions)

- Epithelial cells
- Mesenchymal cells
- Hemic cells

- Epithelial cells (Squamous cell hyperplasia)
- Mesenchymal cells (ie, lipoma)
- Plasma cell hyperplasia

- Carcinoma
- Sarcoma
- Discrete cell neoplasia (Lymphoid neoplasia)

- Resolving phase of heterophilic or mixed cell inflammation
- Granulomatous inflammation (etiologies include mycotic infections, chlamydiosis and foreign body reactions)

Gram's stain  
culture

FIG 10.11 Cytologic evaluation of tissue samples

## Cytology

Unless indicated otherwise, cytology photographs are provided courtesy of Terry W. Campbell.

### Color 10.1

An adult mynah bird was presented with a marked dyspnea at rest and abdominal enlargement. Abdominal palpation suggested fluid within the abdomen. An abdominocentesis was performed. The fluid was pale yellow and slightly cloudy. The specific gravity was 1.025. Fluid was prepared by a cytospin preparation and the smear was stained with Diff-Quik stain. Cytology was compatible with a modified transudate. Illustrated are a reactive mesothelial cell and erythrocytes.

### Color 10.2

Shown are a cluster of reactive mesothelial cells, macrophages, erythrocytes and one heterophil from the mynah bird described in Color 10.1.

### Color 10.3

An adult female budgerigar was presented with fluid distension of the abdomen. An abdominocentesis was performed, and a direct smear was made of the fluid and stained with Diff-Quik stain. The fluid appeared thick, red, slightly greasy and contained flocculent material. The photograph demonstrates numerous foaming macrophages, erythrocytes and blue amorphous material in the non-cellular background. A mixed cell or macrophagic inflammation associated with amorphous material is often seen with egg-related peritonitis.

### Color 10.4

A six-year-old, 37 g female budgerigar was presented with a complaint of abdominal enlargement and dyspnea. There was no history of egg laying. An abdominocentesis was performed, the fluid was prepared with a cytospin preparation and the smear was stained with Diff-Quik stain. The fluid sample was pale orange and slightly cloudy. The specific gravity was 1.032. The macrophage shown demonstrates erythrophagocytosis, indicative of a hemoperitoneum.

### Color 10.5

A second area of the preparation from the budgerigar in Color 10.4 shows numerous erythrocytes and a large epithelial cell with basophilic cytoplasm, a large nucleus with smooth chromatin and a large nucleolus. Note the numerous epithelial cells with features of malignant neoplasia. Necropsy revealed an ovarian cystadenocarcinoma.

### Color 10.6

A ten-year-old female cockatiel was presented with a complaint of a large abdomen and dyspnea. The physical examination indicated ascites. An abdominocentesis was performed and a direct smear of the fluid was made and stained with Diff-Quik stain. The fluid was dark yellow and cloudy. The specific gravity was 1.036. Shown is a highly cellular sample with aggregates of pleomorphic cells with abundant vacuolated or basophilic cytoplasm. Necropsy revealed an ovarian cystadenocarcinoma.

### Color 10.7

An adult female African Grey Parrot weighing 480 g was presented for a pre-purchase examination. A small area of depigmentation was found in the oral cavity adjacent to the choanal slit. A scraping of the depigmented area was made. The smear was stained with Diff-Quik stain. The smear was characterized by low cellularity with an occasional squamous epithelial cell and a variety of extracellular bacteria. The large, ribbon-like bacteria associated with the squamous cells is *Alysiella filiformis*. These cytologic findings are considered normal for the oral cavity.

### Color 10.8

A hand-raised crow was presented with a two-day history of anorexia. The physical examination revealed caseous material in the oral cavity. A scraping of the material in the oral cavity was made, and the smear was stained with Wright's stain. Numerous nondegenerate heterophils are seen, indicating a heterophilic inflammation.

### Color 10.9

An adult Red-tailed Hawk was presented with a healed, malaligned fracture of the right radius and ulna. Examination of the oral cavity revealed multiple, raised, white foci just caudal to the choanal slit. A scraping of the lesion was made, and the smear was stained with Wright's stain. The smear shows a marked number of extracellular bacteria and degenerate heterophils, suggesting a severe septic inflammation.

### Color 10.10

A hand-fed, three-week-old, 68 g cockatiel was presented with delayed emptying of the ingluvies during the past 36 hours. An aspirate of the ingluvies was stained with Diff-Quik stain. Cytology revealed numerous, narrowly based, budding yeast and a marked amount of background debris indicative of candidiasis.

### Color 10.11

A three-week-old Eclectus Parrot was presented with weight loss and delayed emptying of the crop. A crop aspirate was taken and a smear was stained with Wright's stain. Narrowly based budding yeast and hyphae formation are seen, indicative of severe candidiasis.

### Color 10.12

A 723 g adult Barred Owl was presented in an emaciated, weak condition. Physical examination revealed multiple ulcerations in the oral cavity. A scraping of the oral lesions was made, and the smear was stained with Diff-Quik stain. The smear shows numerous pale and dark-staining piriform flagellate protozoa with eosinophilic nuclei and flagella (arrow). There is a moderate amount of background debris, free nuclei and bacteria. A few erythrocytes are present. The cytology is indicative of trichomoniasis.

### Color 10.13

An adult male budgerigar was presented with chronic regurgitation and weight loss. The bird was thin, and regurgitated mate-

rial was present on the feathers of the head and face. A crop aspirate was performed, and the dried smear was stained with Wright's stain. A typical oil immersion field shows numerous piriform flagellate protozoa with eosinophilic nuclei, flagella, undulating membrane and axostyle (arrow). Leukocytes are also present. The cytology indicates severe trichomoniasis.

### Color 10.14

A six-week-old Military Macaw chick was presented with a history of inadequate growth. A routine blood profile revealed no abnormalities. A crop aspirate was performed and a typical oil immersion field of this cytologic preparation is shown. The sample was poorly cellular and contained a slight to moderate amount of background debris. Bacteria represented by a variety of morphologic types were seen in the background. The cytology is considered normal for the ingluvies.

### Color 10.15

A four-week-old, hand-raised cockatiel was presented with frequent regurgitation of a fluid with a fermented odor. A crop aspirate was performed for cytologic examination and a smear was stained with Wright's stain. The smear demonstrates a typical oil immersion field showing a uniform population of bacterial rods and yeasts beginning to form hyphae. No inflammatory cells are seen. A cytodagnosis of peracute septic ingluvitis and candidiasis was made, and the bird was successfully treated with antibiotics and a systemic antifungal medication.

### Color 10.16

Ciliated respiratory epithelial cells (arrow) in a lung imprint stained with Wright's stain from an African Grey Parrot.

### Color 10.17

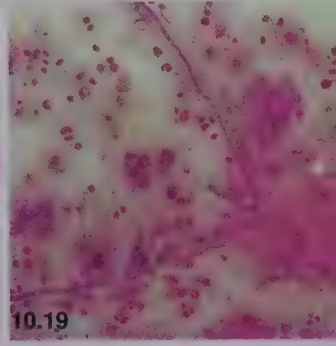
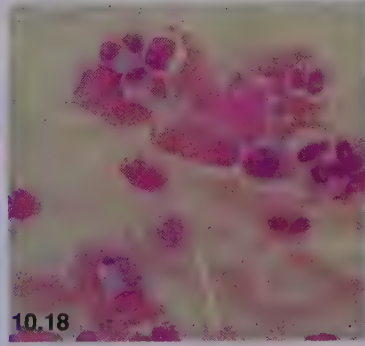
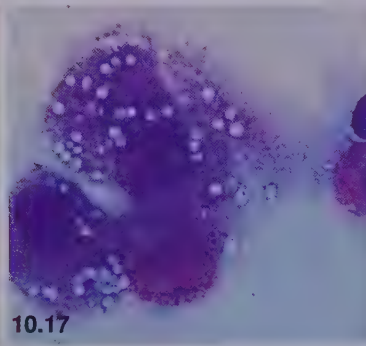
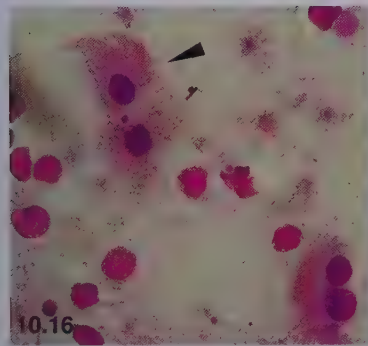
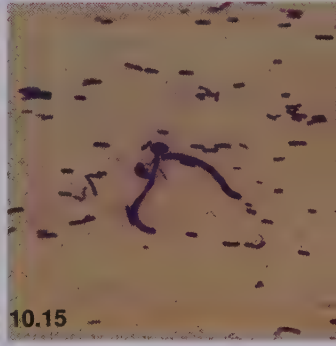
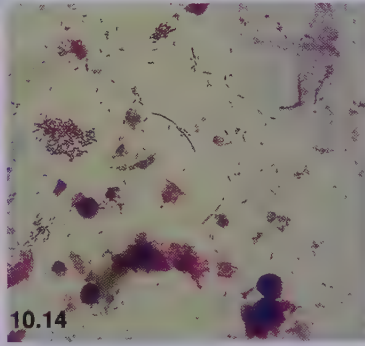
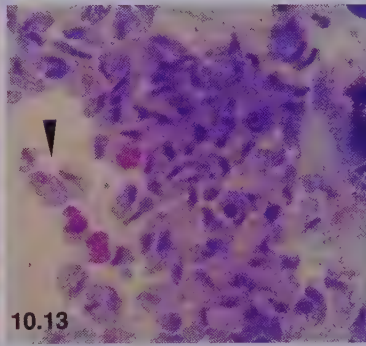
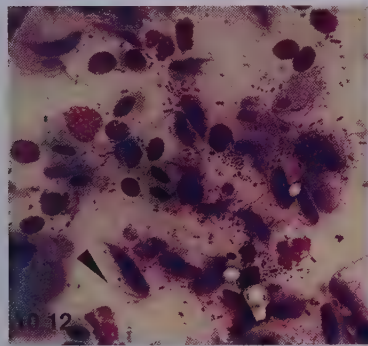

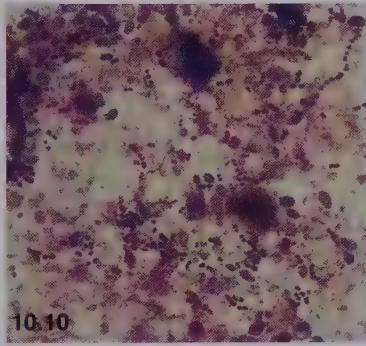
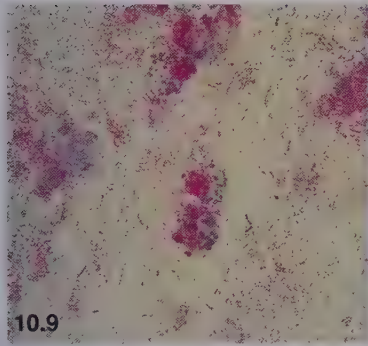
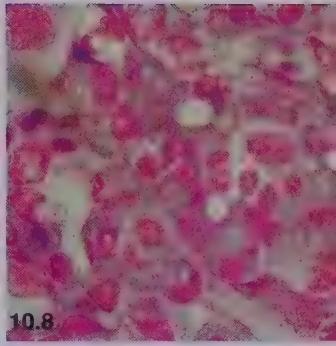

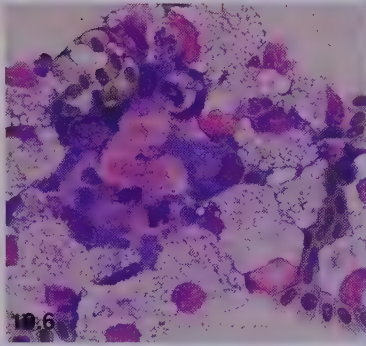
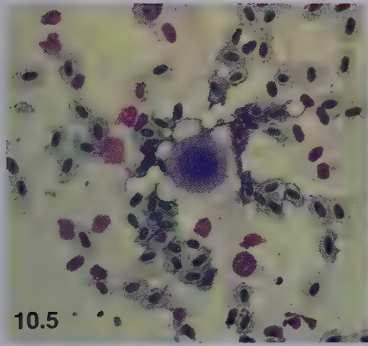
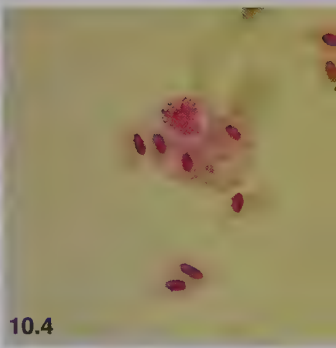
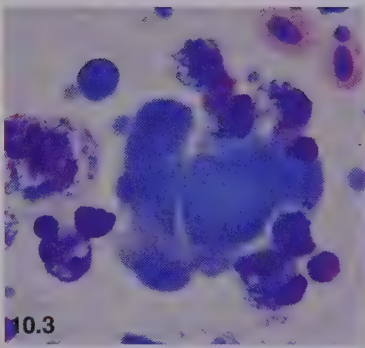
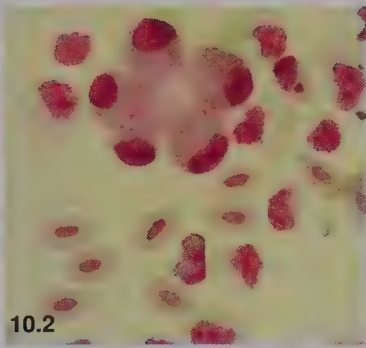
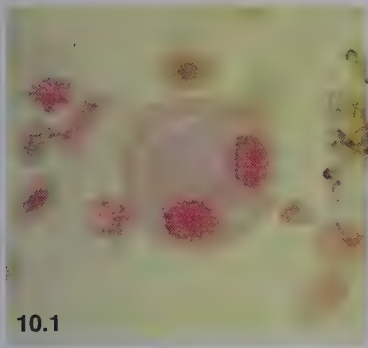
Goblet cells in a tracheal wash sample stained with Diff-Quik stain from a Night Hawk.

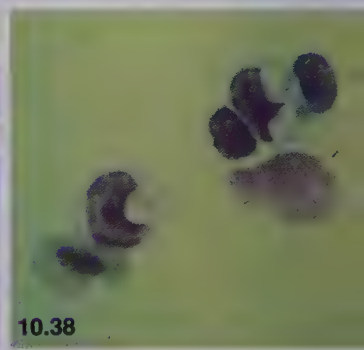
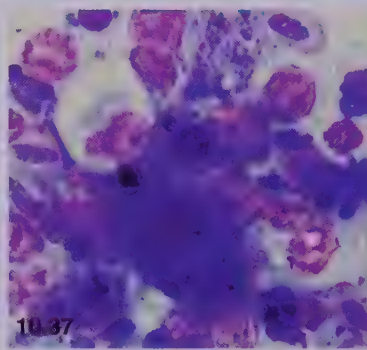
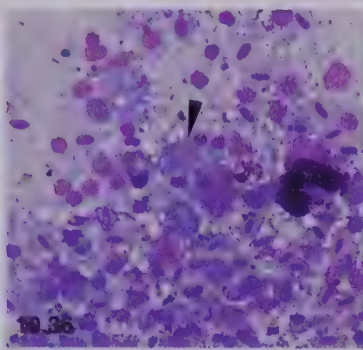
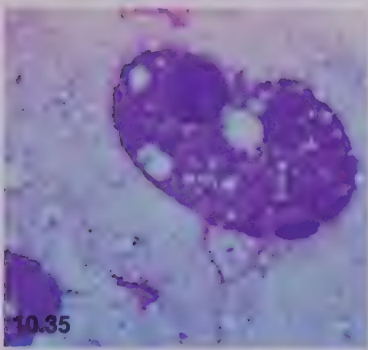
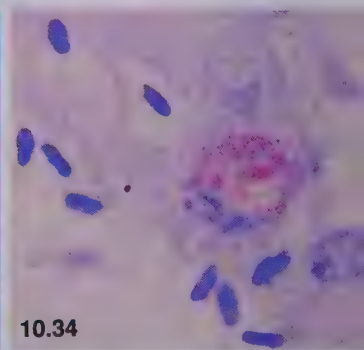

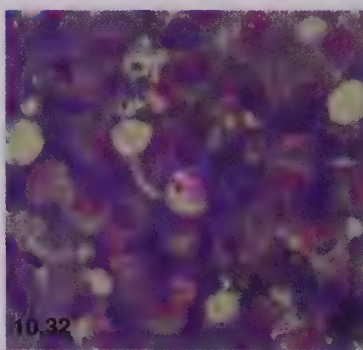
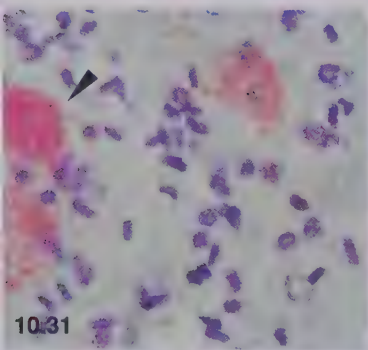
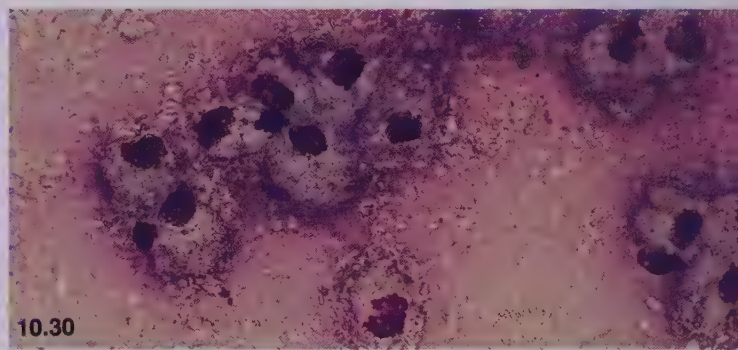
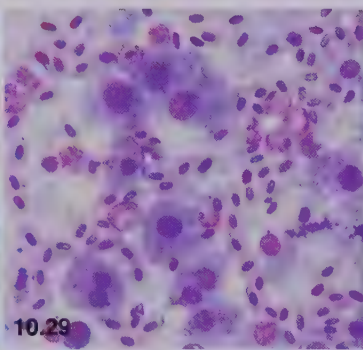
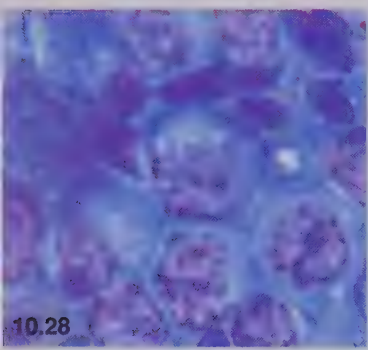
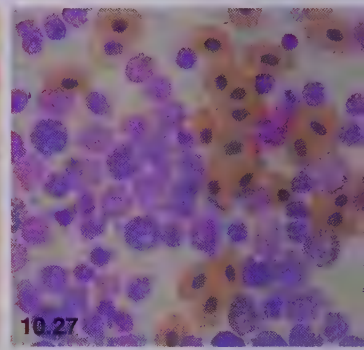
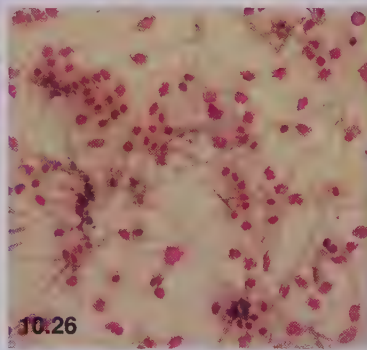
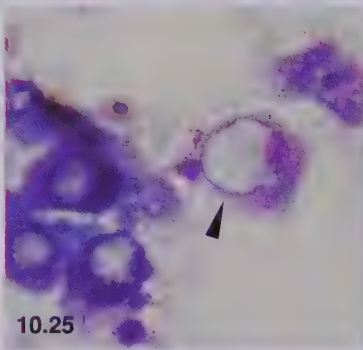
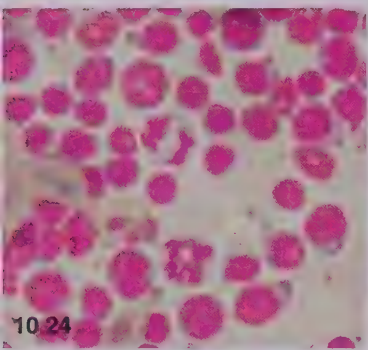
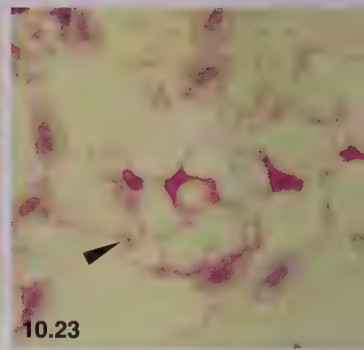
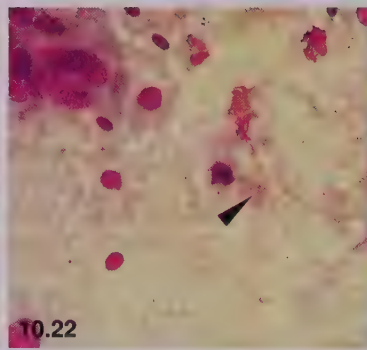
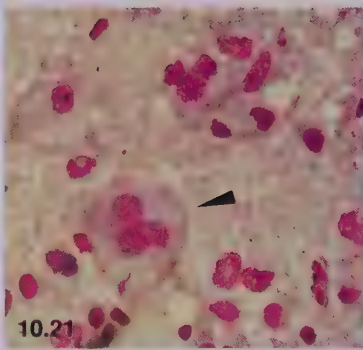
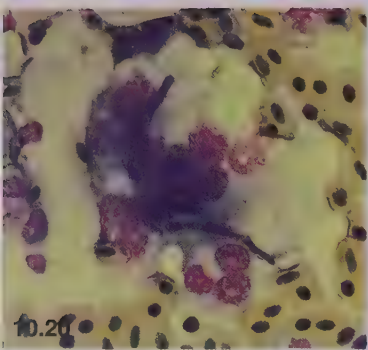
### Color 10.18

An adult, 28 g, male Scarlet-chested Parakeet was presented with a history of sinus infection. A sinus aspirate was performed and the smear was stained with Diff-Quik stain. Shown is a mixed cell inflammation with degenerate heterophils. The heavy eosinophilic background suggests high protein content, most likely representing inflammatory proteins associated with a sinusitis. Although no etiologic agent can be seen, a bacterial or chlamydial etiology is suspected.

### Color 10.19

A Blue-fronted Amazon Parrot was found dead. The only pathology noted on gross necropsy was a tan discoloration on the caudolateral margin of the left lung representing one-fourth of the lung mass. An imprint of the lesion was made, and the smear was stained with Wright's stain. High dry magnification was used to demonstrate a mixed cell inflammation and septate branching hyphae. A cytodagnosis of aspergillosis was made.







### Color 10.20

An adult, 1320 g African Grey Parrot on an all-seed diet was presented because it no longer growled, a typical behavior when approached. A tracheal wash sample was collected, and a smear was prepared by a cytospin preparation and stained with Diff-Quik stain. A highly cellular sample containing numerous erythrocytes is illustrated. There are multinucleated giant cells and septate fungal hyphae, indicative of a mycotic infection involving the respiratory tract.

### Color 10.21

An adult, 1342 g Green-winged Macaw was presented with a complaint of feather loss on the distal end of the right wing. A feather cyst had been removed from this area three months earlier. Physical examination revealed thickened, yellow, friable skin on the dorsal aspect of the right metacarpus. A contact smear of the excisional biopsy of the abnormal skin was obtained and stained with Diff-Quik stain. Multinucleated giant cells and macrophages (arrow) on a heavy granular background are demonstrated.

### Color 10.22

Multinucleated giant cells and cholesterol crystals (arrow) from the bird described in Color 10.21. These findings are compatible with xanthomatosis, which typically reveals a macrophagic inflammation with multinucleated giant cell formation.

### Color 10.23

The physical examination of a 30 g, adult, male budgerigar (fed an all-seed diet) revealed a large, firm, subcutaneous mass overlying the keel. A fine-needle aspiration biopsy of the mass was made, and a smear was stained with Diff-Quik stain. Typical avian lipocytes (arrow) are shown. The cytology is compatible with a lipoma.

### Color 10.24

A 23-year-old, 320 g Spectacled Amazon Parrot was presented with a marked swelling around the right eye and feather loss on the head. A fine-needle aspiration biopsy of the mass on the head was performed, and the smear was stained with Diff-Quik stain. The highly cellular sample shown contains numerous lymphocytes. The majority of the lymphocytes are large, immature and frequently show mytotic activity. These findings are indicative of lymphoid neoplasia.

### Color 10.25

An adult, 112 g Ring Dove was presented in a morbid condition and died soon after the physical examination. The bird was housed in an outdoor aviary, and was presented for marked depression and multiple, raised, irregular cutaneous lesions on the head, legs and feet. A fine-needle aspiration biopsy of a raised lesion near the right eye was made, and the smear was stained with Diff-Quik stain. Shown are epithelial cells with large cytoplasmic vacuoles (arrow) typical of avian poxvirus lesions.

### Color 10.26

An adult, 160 g Nanday Conure was presented with a swollen left tibiotarsal and

tarsometatarsal joint and left leg lameness. Arthrocentesis of the affected joint was performed and the smear was stained with Diff-Quik stain. The sample contains numerous free nuclei, possibly from ruptured erythrocytes, and needle-like crystals. The cytology is compatible with articular gout.

### Color 10.27

An imprint of a normal spleen from a King Penguin that was euthanized because of a severe skeletal deformity. Note the predominance of small-to-medium, mature lymphocytes, one lymphoblast and two plasma cells.

### Color 10.28

A splenic imprint from the Yellow-naped Amazon Parrot described in Color 10.32-10.34 shows a marked increase in plasma cells, indicative of reactive lymphoid tissue.

### Color 10.29

A four-year-old male budgerigar was presented for bilateral leg paralysis. Whole body radiographs revealed a large mass in the area of the kidneys, and a presumptive diagnosis of renal neoplasia was made. At the owner's request, the bird was euthanized. Necropsy revealed a large, locally invasive mass that appeared to involve both kidneys. A histologic diagnosis of nephroblastoma was made. Necropsy also revealed a slight discoloration of the liver, which appeared pale. The imprint of the liver shown here reveals normal-appearing hepatocytes and erythrocytes. There is also an increased number of mature heterophils present, suggesting a mild heterophilic inflammation and hepatitis. Histology confirmed the hepatitis; however, no etiology could be determined.

### Color 10.30

An adult, female, 370 g Blue-fronted Amazon Parrot was presented for necropsy. The bird had shown no previous signs of illness. Necropsy revealed multiple, raised lesions throughout the liver parenchyma. The lesions were varied in size and tended to be round. No other gross lesions were seen. A contact smear of the liver was made, and the smear was stained with Diff-Quik stain. Shown is a typical oil immersion field demonstrating numerous macrophages and bacterial rods in the background that did not stain.

### Color 10.31

Acid-fast-positive reaction (arrow) of the bacteria in the Blue-fronted Amazon Parrot described in Color 10.30, supportive of a diagnosis of avian tuberculosis.

### Color 10.32

An adult, 270 g Yellow-naped Amazon Parrot was presented in critical condition with a history of anorexia, weight loss, frequent regurgitation and loose droppings with green urates. Whole body radiographs revealed hepatomegaly and splenomegaly. The blood profile indicated marked leukocytosis, toxic heterophilia and marked elevations in serum AST. The bird died within one hour of presentation. Necropsy revealed a marked reduction of the pectoral

muscle mass, sinusitis, cloudy air sacs, hepatomegaly and splenomegaly. An imprint of the enlarged spleen was made, and the smear was stained with Diff-Quik stain. A marked number of plasma cells was noted in the splenic imprint (see Color 10.28). Also shown is a macrophage that contains small, intracytoplasmic inclusions suggestive of chlamydia.

### Color 10.33

Chlamydial inclusions stained with Gimenez stain.

### Color 10.34

Chlamydial inclusions stained with Macchiavello's stain.

### Color 10.35

An obese, five-year-old, 125 g female cockatiel was presented for marked lethargy and dyspnea. Whole body radiographs revealed hepatomegaly. The blood profile revealed a lipemic serum sample with a normal CBC and chemistry profile. A biopsy of the liver was performed and the smear was stained with Diff-Quik stain. Shown is the typical appearance of the hepatocyte, which was enlarged and contained numerous vacuoles. The background contained round, fat droplets. The cytology is compatible with hepatic lipidosis.

### Color 10.36

A severely debilitated, adult, male American Kestrel was presented with an open fracture of the right proximal humerus. The peripheral blood smear revealed a marked number of *Haemoproteus* gametocytes. The bird died 24 hours after presentation and an imprint of the spleen was made and stained with Diff-Quik stain. Round *Haemoproteus* schizonts (arrow) were found throughout the splenic imprint as shown here. There is also a large amount of dark-blue iron pigment present.

### Color 10.37

An adult African Grey Parrot housed in a pet store was presented with a history of lethargy and anorexia. A blood profile revealed a moderate degenerative anemia (PCV=21%). The bird died within six hours of presentation. Gross necropsy revealed a slightly enlarged spleen. A splenic imprint was made and stained with Diff-Quik stain. Illustrated is a typical oil immersion field of the splenic imprint showing a marked amount of dark-blue iron pigment. The large amount of iron pigment was also seen histologically. This finding is suggestive of a hemolytic anemia; however, the etiology could not be found.

### Color 10.38

Impression smear from the spleen of a mynah bird. Wright's stain was used to demonstrate *Atoxoplasma* sp. in macrophages. Note that the organism is causing indentation of the nucleus of the infected macrophages (courtesy of Carol Partington).

TABLE 10.3 Staining Procedures

**Acid-Fast Stain**

1. Air-dry then gently heat fix
2. Cover with carbol fuchsin
3. Steam over water bath (3 to 5 min.)
4. Rinse with tap water
5. Decolorize with acid alcohol until most red color is removed
6. Rinse twice in tap water
7. Cover with methylene blue stain (1 min.)
8. Gently rinse with tap water (air dry)

**Gram's Stain**

1. Air dry and gently heat fix slide
2. Cover with crystal violet (1 min.)
3. Gently rinse in tap water
4. Cover with Gram's iodine (1 min.)
5. Gently rinse in tap water
6. Decolorize with 95% ethyl alcohol (15 to 30 sec.)
7. Gently rinse in tap water
8. Cover with safranin (1 min.)
9. Gently rinse in tap water (air dry)

**Macchiavello's Stain**

1. Air dry then heat fix
2. Cover with basic fuchsin (5 min.)
3. Quickly rinse in tap water
4. Dip in citric acid one to ten times (1 to 3 sec.)
5. Rinse in tap water
6. Cover with methylene blue (20 to 30 sec.)
7. Rinse in tap water (air dry)

**Modified Gimenez Stain**

1. Air dry then heat fix
2. Cover with carbol fuchsin (1 to 2 min.)
3. Rinse in tap water
4. Cover with malachite green (6 to 9 sec.)
5. Rinse in tap water
6. Recover with malachite green (6 to 9 sec.)
7. Rinse with tap water (air dry)

**Sudan III Stain**

1. Apply stain to wet or dry smear
2. Apply coverslip

**New Methylene Blue Stain**

1. Completely air dry or use as a wet mount
2. Apply small drop of stain
3. Add coverslip

**Stamp Stain**

1. Air dry smear then heat fix
2. Cover for 10 min. with carbolated fuchsin as used for Gram's stain diluted 1:4 with water
3. Rinse with tap water
4. Differentiate in 0.5% H<sub>2</sub>SO<sub>4</sub> until the preparation looks gray; time according to thickness of the smear
5. Counterstain with 5% malachite green or methylene blue (15 sec.)
6. Rinse with tap water (air dry)

**Wright's Stain**

1. Air dry slide
2. Flood with Wright's stain (stand 1 to 3 min.)
3. Add equal amount of Wright's buffer
4. Gently mix by blowing until a metallic green sheen is formed
5. Allow to stand twice as long as step two (2 to 6 min.)
6. Rinse with tap water (air dry)

**Diff-Quik Stain**

1. Air dry slide
2. Dip in fixative five times (1 sec. each)
3. Dip in solution one to five times (1 sec. each)
4. Dip in solution two to five times (1 sec. each)
5. Rinse in distilled water (air dry)

**Giemsa Stain**

1. Air dry slide
2. Fix in methyl or ethyl alcohol (2 to 7 min.)
3. Air dry
4. Immerse in Giemsa stain (15 to 40 min.)
5. Rinse in tap water (air dry)

**References and Suggested Reading**

1. **Awandhiya RP, Vegad JL, Kolte GN:** A microscopic study of increased vascular permeability and leukocyte emigration in the chicken wing web. *Res Vet Sci* 31:231-235, 1981.
2. **Awandhiya RP, Vegad JL, Kolte GN:** Eosinophilic leukocytic response in dinitrochlorobenzene skin hypersensitivity reaction in the chicken. *Avian Pathol* 11:187-194, 1982.
3. **Banks WJ:** *Histology and Comparative Organology: A Text Atlas.* Baltimore, Williams and Wilkins, 1974.
4. **Campbell TW:** *Avian Hematology and Cytology.* Ames, Iowa State University Press, 1988.
5. **Jortner BS, Adams WR:** Turpentine-induced inflammation in the chicken: A light and electronmicroscopy study with emphasis on the macrophage, epithelioid cell, and multinucleated giant cell reaction. *Avian Dis* 15:533-550, 1971.
6. **Kaiser GE, Starzyk MJ:** Ultrastructure and cell division of an oral bacterium resembling *Alysiella filiformis*. *Can J Microbiol* 19:325-327, 1972.
7. **Maxwell MH, Siller WG, Mackenzie GM:** Eosinophilia associated with facial oedema in fowls. *Vet Record* 105:232-233, 1979.
8. **Maxwell MH:** Attempted induction of an avian eosinophilia using various agents. *Res Vet Sci* 29:293-297, 1980.
9. **Maxwell MH:** Histochemical identification of tissue eosinophils in the inflammatory response of the fowl *Galus domesticus*. *Res Vet Sci* 37:7-11, 1984.
10. **Maxwell MH, Burns RB:** Experimental stimulation of eosinophil stimulation and of eosinophil production in the domestic fowl. *Res Vet Sci* 41:114-123, 1986.
11. **Montali RJ:** Comparative pathology of inflammation in the higher vertebrates (reptiles, birds, and mammals). *J Comp Path* 99(1):1-26, 1988.
12. **Olah I, McCorkle F, Glick V:** Lectin-induced giant cell formation in the chicken wattle. *Poult Sci* 59:2142-2157, 1980.
13. **Perman V, Alsaker RD, Riis RC:** Cytology of the Dog and Cat. South Bend, American Animal Hospital Association, 1979, pp 4-5.
14. **Rebar AH:** *Handbook of Veterinary Cytology.* Saint Louis, Ralston Purina Co, 1979, pp 15-50.

**M**anaging abnormalities in birds requires an understanding of how disease processes change the biochemical functions of the body. Because the clinical signs of illness in birds are frequently subtle, clinical chemistries are necessary to evaluate cellular changes. Properly evaluating a biochemical profile requires knowledge of the diagnostic sensitivities and specificities of tests, correct intervals for a specific test in a given species and a list of diseases that can induce the observed changes.

Adding clinical pathology data to the anamnesis and physical examination findings is important for diagnosing most organopathies. There is a need for further documentation of the clinical and pathologic changes induced by specific diseases of all avian organ systems. Many functional disorders can be diagnosed in birds for which an exact pathomorphologic or pathophysiologic explanation has yet to be reported. Many disease reports based on postmortem findings frequently lack clinicopathologic data that would be of value to the clinician.

With many diseases, a clinician will be able to demonstrate disruption of functional integrity of an organ by means of associated clinicopathologic changes. Supportive therapy, aimed at reestablishing homeostasis, is often lifesaving and enables the body to restore normal organ function. Sometimes a cause for the organ dysfunction can be found for which a specific treatment can be given. Only when distinct diseases can be diagnosed clinically will it be possible to rationally evaluate the effects of a specific therapy.

CHAPTER

---

# 11

**BIOCHEMISTRIES**

---

**Manfred Hochleithner**

## Laboratory Considerations

Nearly all routine hematologic and biochemical investigations can be performed with blood placed in lithium heparin, the anticoagulant of choice when dealing with most avian blood samples. The ability to use one single sample for numerous different tests limits unnecessary blood wastage, which can be an important consideration when dealing with small birds. The amount of blood needed to perform a specific diagnostic test depends on the equipment and technical capacity of the laboratory. When dealing with small birds, the use of micromethods is a necessity.

A blood smear should be made immediately after the blood is collected. A hematocrit-capillary tube is filled and the amount of blood needed for a total white cell count is collected in a diluting pipette. Immediately thereafter, the sample is centrifuged to separate the plasma. Any delay in separation may cause artificial changes of several plasma chemical variables. For example, if whole pigeon or chicken blood is stored at room temperature, a rapid decline (10% in 10 minutes, 30% in 30 minutes, up to 65% in two hours) in plasma potassium concentration occurs due to a shift of potassium ions from the plasma into the red blood cells.<sup>47</sup>

Many reference values for avian blood chemistries are based on values determined using serum instead of plasma, or plasma from blood samples that were not centrifuged immediately. When serum is prepared for blood chemistry, it is inevitable that the blood has to stand for a certain period to allow coagulation, which can cause changes in the sample. Some authors believe that plasma is superior to serum for blood chemistry in birds.<sup>47</sup>

### Analytic Goals

Clinical laboratory data is used by the veterinarian to answer specific questions about a patient's metabolic state. The analytic sensitivity of the test, precision with which the test is performed and the way the sample is handled during collection and processing will affect the validity of the test.

The questions that laboratory results can answer generally fall into one of five categories:

1. Is an unapparent disease present? (screening)
2. Is a particular disease process occurring? (pathophysiology)
3. Is a tentative diagnosis correct? (confirmation)
4. What is the severity of a disease process? (prognosis)
5. Has therapy favorably altered the disease process? (monitoring)

Any disease should be considered an evolving process and not a fixed condition. Diagnostic considerations include the cause (etiology), the destructive and reparative processes involved (pathogenesis), the abnormalities observed (diagnostic criteria) and the probable outcome (prognosis). With the complexity of these considerations, rarely does a single test provide a definitive understanding of the clinically apparent disease process, not to mention any subclinical changes that occur at a cellular level.

### Accuracy and Precision

The two most important concepts for evaluating the analytic performance and thus the validity of any test are: 1) analytic accuracy, which is the agreement between the best estimate of a quantity and its "true" value; and 2) analytic precision, which is the agreement between replicates. Different results from the same sample may be produced by different analyzers. Likewise, repeat analysis of the same sample by the same analyzer may provide different results. This is true for all laboratory equipment including inexpensive dry chemistry units and high quality computerized analyzers.

Other considerations in interpreting test results include analytic sensitivity (the ability of an analytic method to detect small quantities of the measured component) and analytic specificity (the ability of an analytic method to determine solely the component it is designed to measure).<sup>7,39,41,68</sup>

Human clinical pathology laboratories have found that day-to-day variabilities in an individual patient make it difficult to accurately predict certain biochemical levels. For example, calcium is measured with an average precision of 2.0%, but the day-to-day variation in humans and mammals is around 0.9%. This means that normal analytic variations in the test can be interpreted as abnormal. Creatinine kinase, on the other hand, is usually measured with a

precision of 9.0%, which is much better than its day-to-day variation, at least in humans, of 13.0%.

In birds, some blood chemistry variables may show a circadian rhythm (ie, plasma corticosterone) or a circannual rhythm (ie, plasma thyroxine).<sup>38a,49a</sup> Because of these inherent problems in determining specific serum chemistry values it is important to have a basic knowledge of the technical and statistical methods used in establishing the value of these tests. Developing this working knowledge is further complicated in avian medicine due to a lack of knowledge concerning the day-to-day variations that occur in different biochemical parameters in different avian species.

To be of optimum use, clinical chemistry data must be evaluated based on the values in healthy individuals, the precision of quantitative measurements and the clinical chemistry changes characteristically expected in various pathologic states.

## Reference Values – Reference Intervals

Values for any set population of living organisms will have a range that have high, median and low values. For this reason, “normal” is a state of the individual and is not a term that can be easily extrapolated from any given individual as a comparison to others. *The terminus technicus* is to compare the values of an individual to the reference intervals established to define normal limits for a healthy population.<sup>24,65</sup>

Reference ranges established for a population of animals are statistically reduced to reference intervals to allow discrimination between health and disease. Reference intervals of plasma chemical variables are highly dependent on the materials and methods used in the determination, and can vary among different laboratories. At best, reference intervals can be defined for a set population of birds on a given diet, maintained in a given geographic location at a given time of year.

In mammalian medicine, reference intervals are of statistical significance because of the substantial studies that have been performed to evaluate the biochemical changes that occur in various states of

disease. Until reference intervals are established for birds free from subclinical infections (particularly viral diseases) and maintained on adequate diets for long periods, it will be impossible to define precise reference intervals on a population basis. Many normal values published in the literature have been collected by diagnostic laboratories, which generally receive samples from abnormal birds.

In addition to varying among populations, reference intervals may also vary among laboratories because of variation in test methods. A laboratory must be able to provide a reference interval established in that laboratory for the species and variables concerned, or the results from the laboratory will be of little value.

In interpreting clinicopathologic data, it should be noted that:

1. There are subtle changes that exist between health and disease. The concept of normality rarely exists.
2. Not all values from healthy individuals will fall within a normal reference interval (usually encompasses 95% of healthy individuals).
3. Some values from abnormal individuals will fall within the reference interval.

Reference intervals are established statistically to produce a 95% confidence interval. Because many biological data do not have a Gaussian distribution, it is often incorrect to define the reference range as the mean plus or minus two standard deviations. In most cases non-parametric statistics must be used to establish reference intervals for clinicopathologic tests because the data are not normally distributed.

If data is normally distributed, 5% of the healthy population with values that are higher or lower than the defined 95% intervals are considered abnormal. With this test evaluation system, it is accepted that there are 2.5% (one out of 40) of the normal population that fall above or below the normal range even though they are clinically healthy.

Further, reference values established for a species may not be normal for an individual. The individual may regularly have a test value that is in the lower part of the normal range. If such a bird developed pathology, the test parameter could stay within the normal range for the species, even though it is elevated for the individual. Consequently, reference values established for an individual bird are more sen-

sitive in detecting subtle abnormalities than comparing test results to reference intervals for a population. These idiosyncrasies in interpreting data confirm the importance of using laboratory tests as only one part of the patient evaluation process (in conjunction with physical examination, clinical changes, radiography) and not as diagnostic panacea.

### Units of Measurement, SI Units

To be meaningful, a measurement must be expressed with both a number and a unit. The unit identifies the dimension (eg, mass, volume, concentration) of a measured property. The number indicates how many units are contained within a given sample size. Traditionally, measurements in clinical laboratories are expressed in metric units.

An International System of Units, the so-called SI Unit System (Système International d'Unités) was adopted in the 1970's to standardize measurements.

Standardization created a change in the numerical values of many frequently used tests. The mol, for example, indicates the amount of a substance in terms of molecules. The concentration of all substances is now expressed in terms of liters. For biochemical substances, the molar concentration per liter, which is expressed in sub-multiples (millimoles per liter - mmol/l or micromoles per liter -  $\mu\text{mol/l}$ ) is the preferred standard of measurement.

The advantages of an accepted, worldwide standardized system are obvious. Unfortunately, the standardized system is not always used to report data. Many refereed journals continue to use the conventional rather than SI units. All publications before 1975 used the conventional units, and even in countries that are committed to SI units there are laboratory instruments still in use that produce results in conventional units. Most enzyme activities are still expressed in terms of international units per liter (IU/l or U/l) because the SI unit, the catal, has not been widely adopted. It is often necessary to convert values expressed in conventional units to SI units. Conversion tables are provided in the Appendix.

## Types of Testing

### Enzymology

Each cell within an organ has a specific function and contains enzymes designed to perform those functions. In some situations, enzymes are unique to specific cells within an organ, and in other cases, enzymes are found in numerous cells from various organs. When the integrity of a cell is disrupted, enzymes escape into the surrounding fluid compartment, where their activities can be measured as an index of cellular integrity.

An enzyme that is released into the serum/plasma must be easy to assay in order to be of diagnostic value. In addition, the assay must be economically feasible and indicate pathologic changes in a specific organ, or a defined small group of organs. The enzyme must also be stable in the serum/plasma for a sufficient time to permit its detection.

It is important to realize that cells must be damaged before they release enzymes into the serum/plasma. Therefore, enzymatic-based tests are a measure of cell damage, and not necessarily a measure of organ function. Anoxia causes the cell membrane to lose its integrity so that soluble enzymes from the cytosol can leak into the serum/plasma.

With liver disease, it is common to have normal histology with marked biochemical changes. This loss of integrity may be observed histologically as a swelling of the cell. Anoxic red blood cells, for example, leak cytosolic LDH into serum/plasma, causing an increase of LDH activity in a sample. Combining the values obtained for several enzymatic assays will increase the diagnostic value of the biochemical evaluation of a patient.

Enzyme activities in tissue or serum/plasma are usually in such low concentrations that it is not practical to quantitate the enzyme directly. Therefore, enzymes are measured indirectly based on their *in vitro* activity under controlled or specific conditions at which their activity is proportional to enzyme concentration. There are a multitude of methods used by different laboratories for detecting enzyme activities, and the reference intervals will vary among these laboratories despite all results being expressed in U/l. Test

values will vary depending on the substrate, buffer and incubation temperature used by the laboratory.

### Metabolites

Metabolites can be measured to provide information about the functional capacity of the organs that are involved in a particular metabolic pathway. Tests are usually designed to provide measurements of end-point metabolites. Commonly measured metabolites include: plasma ammonia, enzymes, bile acids, bilirubin, calcium, cholesterol, creatinine, glucose, inorganic phosphate, iron, total protein, urea, uric acid and triglycerides.

### Electrolytes

Electrolytes may be positively charged (cations) or negatively charged (anions). Balances of these electrolytes are essential for all living matter, and commonly measured electrolytes include potassium, chloride and sodium. Trace elements including magnesium may also be determined. The major electrolytes occur primarily as free ions. The trace elements exist primarily in combination with proteins.

### Hormones

It has been suggested that hormone concentrations may be good indicators of disease in humans or mammals, but their analytic accuracy and precision are difficult to evaluate in birds.<sup>50,62,37</sup> Hormones are usually detected using a radio-immunoassay (RIA) or an ELISA, both of which require an antigen/antibody reaction. Nonspecific cross-reactions that occur when tests designed for mammalian hormones are used for bird plasma can lead to questionable results.

### Assay Methods

Historically, wet chemistry systems have been used for evaluation of blood parameters. Wet chemistry means that liquid reagents act with a certain volume of sample under strictly defined constant conditions (eg, temperature, pH, time) and produce a change of color that is proportional to the concentration of substances or the activity of enzymes. As the indicator dye changes color, the reaction is read spectrophotometrically. Because the reagents can be prepared in the laboratory, the cost for frequently used tests is inexpensive on a per test basis. The minimum sample size often depends on whether reagents are added by hand (older systems that may require 100 to 200

μl/parameter) or automatically (Autoanalyzer Two only requires 20 μl/parameter).

With dry chemistry systems,<sup>30,35,42</sup> test reagents are dried in layers and are dissolved by the fluid in a sample. Incubation steps, reaction time and factors for calculation of the results are all contained within the reagent strip or slide. The technician need only apply the sample and wait for the result. Like a wet chemistry test, the reaction causes a change in color that is measured photometrically by light reflectance. Specific strips or slides are needed for each test, and these are available only from the manufacturer. When compared to wet chemistry tests, dry chemistry assays are more expensive.

## Indices

Biochemical tests that can be used to evaluate avian patients will be discussed in alphabetical order within three specific groups: enzymes (see Table 11.2), metabolites (see Table 11.3) and electrolytes.

The discussion of each test will include:

- **Sample:** Recommendations for the best sample to collect for testing are listed in Table 11.1. Specific concerns with respect to sample handling are discussed with all indices.
- **Method:** An overview of the common assay techniques designed to show why results will vary between different laboratories.
- **Physiology:** The physiologic role of the parameter in the bird.
- **Diagnostic Value:** The validity of a parameter in suggesting or confirming the presence of disease.
- **Physiologic Influence:** The influence of physiologic conditions on a test assay.
- **Pathologic Changes:** The effect that pathologic changes have on test values with reference to special literature.

Reference intervals for different avian species using various testing methods are provided in the Appendix.

TABLE 11.1 Recommended Samples for Biochemical Tests<sup>41</sup>

Tissue Enzymes	Sample
ALT	Hemolysis-free plasma or serum
AP	Heparinized plasma or serum
AST	Heparinized plasma or serum
CPK	Serum is preferred. Citrate and fluoride inhibit CK activity.
GGT	EDTA plasma or serum (see text)
GLDH	Heparinized plasma or serum
LDH	Hemolysis-free plasma or serum
Metabolites	Sample
Plasma Ammonia	EDTA (see text)
Amylase	Heparinized plasma or serum
Bile Acids	Heparinized plasma or serum
Bilirubin	Heparinized plasma or serum
Calcium	Heparinized plasma or serum (see text)
Cholesterol	Heparinized plasma or serum
Creatinine	Heparinized plasma or serum
Glucose	Heparinized plasma or serum (see text)
Iron	Heparinized plasma or serum
TIBC	Heparinized plasma or serum
Lipase	Heparinized plasma or serum
TP	Heparinized plasma or serum
Triglycerides	Heparinized plasma or EDTA plasma
Urea	Heparinized plasma or serum
Uric Acid	Heparinized plasma or serum
Electrolytes	Sample
Chloride	Heparinized plasma or serum
Potassium	Heparinized plasma or serum
Sodium	Heparinized plasma or serum

## Enzymes

### Alanine Aminotransferase ALT (GPT)

- Method:** It is not possible to monitor transaminase (ALT and aspartate aminotransferase AST) reactions directly; however, continuous monitoring assays can be performed by coupling the transaminase reactions to specific dehydrogenase reactions. Because of the value of AST and ALT activities in diagnosing disease, standardization of reference methods for these two enzymes have been given priority by national and international groups. These groups have chosen a coupled-reaction with malate or lactate dehydrogenase as the indicator enzymes. These methods differ with respect to substrate concentration, nature of buffer and assay temperature.<sup>68</sup>
- Physiology:** Alanine aminotransferase and AST belong to a group of enzymes that catalyze interconversion of amino acids and oxoacids by the transfer of amino groups. While there are numerous enzymes

TABLE 11.2 Causes of Tissue Enzyme Increased Activities<sup>41</sup>

Enzyme	Activity	Causes of Increases
ALT	Present in most tissues 1.6 times higher in RBCs than plasma	Cell damage (nonspecific)
AST	Liver, heart, skeletal muscle, brain, kidney	Mainly liver or muscle disease Vitamin E/Se deficiencies
AP	Mainly duodenum and kidney Low activity in liver	Increased cellular activity (not damage) Higher in juveniles Egg-laying
CK	Skeletal muscle, heart muscle, brain	Mainly muscle damage IM injections Neuropathies Vitamin E/Se deficiencies Lead toxicity
GGT	Biliary and renal tubular epithelium	Hepatocellular damage Some renal diseases
GLDH	Mitochondrial enzyme found in most tissues Liver, kidney, brain	Hepatocellular necrosis
LDH	Skeletal muscle, cardiac muscle, liver, bone, kidney, RBCs	Hemolysis Hepatic necrosis Muscle damage

involved in the conversion cascade, AST and ALT are the two enzymes of greatest clinical importance.

- Diagnostic Value:** Alanine aminotransferase activity occurs in many different tissues. Specific diagnostic value of these enzymes in birds is poor. In many cases, patients with severe liver damage have had normal ALT activities, reflecting a low level of enzyme activity in liver cells from certain species. Alanine aminotransferase activities often increase due to damage in many different tissues. In some avian species, normal ALT activities are below the sensitivity of many analyzers.<sup>35,36</sup>
- Pathologic Changes:** Elevated activities are difficult to interpret, and this enzyme has limited usefulness in birds because it can be increased by pathologic changes in almost all tissues. Activity in erythrocytes is 1.6 times higher than in plasma, and hemolysis will cause elevated activities.<sup>50</sup>
- Physiologic Influence:** Age-dependent elevation (increased activity with aging) of enzyme activity has been described in birds.<sup>25</sup> In raptors, seasonal variation in ALT activities has been reported. These changes were independent of reproductive activity.<sup>22</sup>

### Alkaline Phosphatase - AP

- Method:** Numerous methods of determining AP activity are currently used. The variety of methods in



use make it difficult to compare AP activities between laboratories or reference literature.

- **Physiology:** Alkaline phosphatase operates at an alkaline pH and is possibly involved in energy transfer for exchange of ions across the cell membrane. Alkaline phosphatase activity has been found to occur predominantly in the duodenum and kidney. Low AP activities were reported in the liver with no activity in other organs of pigeons.<sup>50,51</sup> Similar findings have been described in chickens<sup>8</sup> and turkeys.<sup>9</sup> Most enzyme assays are used to document damage to cells resulting in enzyme release. In contrast, plasma AP activity is induced by increased cellular activity (increased synthesis) rather than cell damage.
- **Diagnostic Value:** Alkaline phosphatase activities may be elevated due to irritation of the cells in different tissues. Increased activities have no specific importance.
- **Physiologic Influence:** Juvenile birds have significantly higher AP activities from bone growth and development than adults.<sup>15,16,17,32</sup> In hens, activities are elevated prior to egg laying.<sup>28</sup> Seasonal variations in activities have been described.<sup>4</sup>
- **Pathologic Changes:** Elevations are most common with liver disease even though the level of activity in this organ is low. Hyperparathyroidism-induced stimulation of osteoplastic activity may also cause increased AP activity. Enteritis has been described as a cause of higher AP activities but activity of this isoenzyme is labile and difficult to measure.<sup>36</sup> Aflatoxin B<sub>1</sub> intoxication with massive liver destruction in pigeons, cockatiels, Red-tailed Hawks and Great Horned Owls was not found to significantly increase AP activity.<sup>13</sup> Low AP activities have been linked to dietary zinc deficiencies.

#### Aspartate Aminotransferase - AST (GOT)

- **Method:** See ALT.
- **Physiology:** See ALT.
- **Diagnostic Value:** High AST activity has been described in liver, skeletal muscle, heart, brain and kidney cells. The distribution of AST in avian tissues varies among the species.<sup>43,25,50</sup> Elevated activities are usually indicative of liver or muscle damage. Aspartate aminotransferase activity provides the best information when combined with other more specific tests.<sup>49,36</sup> Creatinine kinase activity can be used to exclude muscle damage as a cause of increased AST activity.

- **Physiologic Influence:** Aspartate aminotransferase values are age-dependent to varying degrees among different species.<sup>25,15,16,17</sup> The cause of this age-dependent increase in activity has not been defined. Gender differences have not been described.<sup>4,32</sup>
- **Pathologic Changes:** In general, AST activities in birds greater than 230 U/l are considered abnormal. Abnormal activities have been linked to vitamin E, selenium or methionine deficiencies,<sup>25</sup> liver damage (particularly psittacosis or Pacheco's disease virus),<sup>23,61,63</sup> pesticide and carbon tetrachloride intoxication<sup>43</sup> and muscle damage. Intramuscular injections of irritating substances may cause elevation of CK with no increases in AST activity. In other patients, both the CK and AST activities will increase post-injection.

#### Creatinine Kinase - CK (CPK)

- **Method:** Numerous colorimetric, fluorimetric and coupled enzyme assays have been developed to detect CK activity.<sup>68</sup>
- **Physiology:** Creatinine kinase functions in skeletal muscle, heart muscle and brain tissue. In muscle, this enzyme makes ATP available for contraction by the phosphorylation of ADP from creatinine phosphate. There are three isoenzymatic forms of CK that can be separated by electrophoresis. In mammals, quantization of isoenzymes can be used to determine the tissue source of the enzyme.<sup>39,68</sup> There have been no reported attempts to separate tissue-specific creatinine kinases in birds.
- **Diagnostic Value:** Elevations in activities are mostly seen because of muscle cell damage. This enzyme has value in distinguishing muscle from liver cell damage. However, the clinician should consider that muscle and liver cell damage can occur simultaneously from the same or different pathologic processes.
- **Physiologic Influence:** In mammals, CK activity is subject to a number of physiologic variations (eg, muscle mass of an individual, gender, age, physical activity).<sup>39,68</sup> Physiologic changes of CK activity in birds have not been described. Neither gender<sup>32</sup> nor age<sup>15,16,17</sup> has been shown to significantly affect CK activity.
- **Pathologic Changes:** Increase in CK activity has been linked to muscle cell necrosis, convulsions, intramuscular injections (depending on the volume and degree of irritation), vitamin E and selenium defi-

ciencies, neuropathies, lead toxicity and occasionally chlamydiosis.<sup>36,43</sup>

#### Gamma Glutamyl Transferase - GGT

- **Sample:** EDTA plasma or serum can be used to determine GGT activity. Heparin will interfere with the test reactants causing turbidity; citrate, oxalate and fluoride may artificially depress activity.<sup>68</sup>
- **Method:** Reagent kits for GGT determination use different substrates that have different sensitivities. Results are totally dependent on the assay used.<sup>68</sup>
- **Physiology:** Peptidases constitute a broad group of enzymes of varied specificity, and some individual enzymes catalyze the transfer of amino acids from one peptide to another amino acid or peptide. Gamma glutamyl transferase cleaves the gamma-glutamyl group from peptides and moves them to an appropriate acceptor. This is primarily a brush border enzyme with greatest activity in the biliary and renal tubular epithelium. Serum activity is from biliary origin.
- **Diagnostic Value:** Little is known about the significance of plasma GGT activity for the diagnosis of hepatobiliary disease in birds. One investigator reported measurable activities in the kidney and brain of pigeons, and the kidney and duodenum of budgerigars.<sup>50</sup> Another investigator<sup>13</sup> concluded that GGT is not a sensitive test for the detection of liver disease in different avian species. Enzyme activity in normal birds typically falls below the sensitivity range of most analyzers.
- **Pathologic Changes:** Elevations in GGT activity have been described in association with liver disease, but not on a regular basis.<sup>36</sup> The highest levels of activity have been reported in the kidneys. However, elevations do not always occur with renal disease, probably because the enzyme is excreted in the urine.

#### Glutamate Dehydrogenase - GLDH

- **Method:** Methods for the determination of GLDH can be based upon both forward and reverse reactions, and results are dependent on the temperature of the reaction.<sup>68</sup>
- **Physiology:** Glutamate dehydrogenase is a mitochondrial enzyme found in numerous tissues.
- **Diagnostic Value:** Significant amounts of this enzyme have been found in the liver, kidney and brain of chickens, ducks, turkeys and racing pigeons.<sup>50,51</sup> In budgerigars, the highest enzyme activity has been reported in the kidney.<sup>50</sup> Significant elevations have

been observed in birds with liver disease, but few reference intervals are available for avian species.<sup>36</sup>

- **Physiologic Influence:** Glutamate dehydrogenase is present in normal serum only in trace amounts. No physiologic variations have been described for this enzyme.
- **Pathologic Changes:** Activity in plasma or serum is increased in all conditions in which hepatocellular damage is present. As an exclusive mitochondrial isoenzyme, GLDH is released from cells that are necrotic or markedly injured. Therefore, activities are lower in inflammatory processes that do not result in cellular necrosis.
- **Reference Intervals:** Hyacinth Macaw - 0 to 1 U/l (method, temperature not described)<sup>54</sup>; Psittacines - < 2 U/l (German Society of Clinical Chemistry, 25°C).<sup>36</sup>

#### Lactate Dehydrogenase - LDH

- **Sample:** Heparinized plasma or serum are satisfactory if hemolysis is not present. Serum must be separated from the clot immediately to prevent LDH contamination of the sample caused by damaged erythrocytes. Plasma containing other anticoagulants, especially oxalate, should not be used.
- **Method:** Numerous LDH assays have been introduced over the last 25 years. Procedures use the forward (lactate to pyruvate) or the reverse (pyruvate to lactate) reactions in almost equal numbers. Methods using the forward reaction are more expensive and less precise, but have fewer problems with substrate inhibition of the test.
- **Physiology:** Lactate dehydrogenase functions in glycolysis. Erythrocytes contain high activities of LDH, and *in vitro* hemolysis will result in falsely elevated values. There are five LDH isoenzymes, each of which occurs in a wide variety of tissues, in particular skeletal muscle, cardiac muscle, liver, kidney, bone and red blood cells. Electrophoretic separation of the isoenzymes can help establish the source of increased activity, but is seldom used in veterinary laboratories.
- **Diagnostic Value:** Although this enzyme is not specific for any organ, elevations are most common with hepatic disease in psittacines. Lactate dehydrogenase activities are thought to rise and fall more quickly than AST activities in birds with liver disease.<sup>61</sup> These differences may provide information on the chronicity of liver disease.

- **Physiologic Influence:** Seasonal variations<sup>43</sup> and gender differences<sup>32</sup> in LDH activities have been described. The highest physiologic activities have been reported in canary finches.<sup>64</sup>
- **Pathologic Changes:** Elevated enzyme activity can be observed due to liver and muscle damage.

## Nutrients and Metabolites

### Plasma Ammonia

- **Sample:** EDTA is the anticoagulant of choice. Lithium heparin can be contaminated with ammonium heparin, which will lead to falsely elevated values. Samples must be analyzed immediately because ammonia is released through the catabolism of various substances (eg, urea).<sup>11</sup> Ammonia levels in serum are significantly but variably higher than corresponding plasma values.<sup>68</sup>
- **Method:** There are several techniques for the determination of ammonia. In private practice, the dry chemistry method used by the Kodak Ektachem System can be used. This assay measures creatinine and ammonia in two different steps.
- **Physiology:** Blood ammonia is principally absorbed from the intestines, although some is derived from protein catabolism, particularly in the skeletal muscles. Normally, ammonia absorbed from the bowel is converted into uric acid and urea in the liver, and blood concentrations of ammonia are maintained at a low level.
- **Diagnostic Value:** Little data is available on the use of ammonia concentrations as a diagnostic test in birds.
- **Pathologic Changes:** High blood ammonia concentrations may indicate reduced liver function or ammonia poisoning. Ammonia toxicity usually occurs from buildup of ammonia gases in poultry houses and has rarely been reported in companion birds. Atmospheric ammonia can contaminate a blood sample that is left open in room air.
- **Reference Values:** Budgerigar - 7-141  $\mu\text{mol/l}$  (Kodak Ektachem, 25°C).<sup>32</sup>

### Amylase

- **Method:** Some 20 methods have been described for assaying amylase activity. These tests are based on nine different principles, and various substrates and reference intervals are dependent on the detection method used. With dry chemistry units, the amylase

TABLE 11.3 Causes of Increases in Metabolic Tests<sup>41</sup>

Metabolite	Comments	Causes of Increases
Ammonia	Absorbed from intestines Released through catabolism	Old sample Decreased liver function Ammonia poisoning
Amylase	Derived from pancreas, liver, small intestine	Pancreatitis Enteritis
Bile acids	Indicator of liver function and enterohepatic circulation	Reduced liver function
Bilirubin	Major bile pigment	Hepatic necrosis
Calcium		Hyperproteinemia (dehydration) Ovulating hens Osteolytic bone Hypervitaminosis D
Cholesterol	Precursor of steroid hormone Precursor of bile acids Component of cell membranes	Lipemia (high fat diet) Fatty liver degeneration Males > females Liver disease Hypothyroidism Bile duct obstruction Starvation
Creatinine	Derived from catabolism of creatine	Low sensitivity Severe renal disease Decreased filtration rate Egg-related peritonitis Septicemia Nephrotoxic drugs Renal neoplasias
Glucose	Energy source	May be higher in neonates Variation in age, time of day, stress Diabetes
Phosphorus	Diagnostic value poor	Renal disease Secondary hyperparathyroidism Hypoparathyroidism Hemolysis
Iron	Unknown	Pre-ovulatory period
TIBC		Iron deficiency
Lipase	Produced in pancreas	Possibly with pancreatitis
TP		Advancing age Pre-ovulatory period Immune stimulation Dehydration Chronic infections
Triglycerides		Egg-related peritonitis Hyperadrenocorticism? Exercise
Urea		Low urine flow Dehydration Bilateral ureteral obstruction
Uric acid	Synthesized mainly by the liver Excreted by the renal tubules	Postprandial Renal disease Ovulation Decreased glomerular filtration Tissue damage Starvation Hepatocellular disease

activity of approximately 30% of avian samples will exceed the upper range limit of the test. Samples that exceed the test limit must be diluted and reanalyzed.

- **Physiology:** Amylase occurs in plasma as a number of isoenzymes that are principally derived from the pancreas, liver and small intestine. In birds, the isoenzymes have not been separated, making it impossible to determine which specific tissues are responsible for increased plasma amylase activity.
- **Diagnostic Value:** Little information is available on amylase activity in birds. In some cases it has been found to be useful in the diagnosis of neuropathic gastric dilatation.<sup>36</sup>
- **Pathologic Changes:** Increased enzymatic activity can be seen with acute pancreatitis. In these cases enzyme activity may exceed three times the upper limit of the reference interval. Activities less than twice the upper limit of the reference interval are sometimes seen in macaws with severe enteritis in the absence of pancreatic lesions. In most cases of neuropathic gastric dilatation, amylase activity is normal or only slightly elevated.<sup>36</sup>
- **Reference Values:** Budgerigars (187-582 U/1); African Grey Parrots (211-519 U/1); Amazon parrots (106-524 U/1); macaws (276-594 U/1) (Kodak Ektachem, Amylopectin, 25°C).<sup>33</sup>

### Bile Acids

- **Method:** Several assays have been used to quantify either total or individual bile acids. The most frequently used assays are gas liquid chromatography, high performance liquid chromatography, enzymatic assays and immunoassays (RIA, ELISA). Among these, RIA and enzymatic methods are mainly used by commercial laboratories. RIA-derived values are not comparable to those detected using other methods. Nonspecific cross reactions occur when human anti-bile acid antibodies are used to detect bile acids in bird plasma; therefore, enzymatic methods seem to be the assay of choice for use in birds.
- **Physiology:** The liver synthesizes the primary bile acids (cholic acid and chenodeoxycholic acid). It then excretes these acids as sodium salts into the bile. With the ingestion of food, bile is carried via the bile duct into the small intestine where the bile acids act principally as emulsifying agents in fat digestion and absorption. Most bile acids that enter the gastrointestinal tract are reabsorbed in the distal small and large intestines where they return, via the portal circulation, to the liver. They are then extracted from

the blood and recycled. Only a small percentage of the total pool of bile acids is lost in the feces each day. A small quantity of the total bile acids reabsorbed from the gastrointestinal tract is not removed from the blood by the liver and reaches the general circulation. It is this fraction of unextracted bile acids that is measured. The quantity of bile acids in the plasma normally increases following the ingestion of food.

- **Diagnostic Value:** If liver function is impaired, bile acids are not properly reabsorbed from the blood, and consequently the proportion of excreted bile acids reaching the peripheral circulation increases. Circulating bile acids can therefore be used as a sensitive indicator of liver function, and of the integrity of the circulation through the liver, biliary tract and intestines. It has been suggested that chronic liver disease that results in cirrhosis may decrease the production of bile acids with a subsequent decrease in the plasma. This may be particularly true in a postprandial sample. Further investigations are needed to determine if decreased bile acid concentrations are a reasonable indicator of a loss of functional liver mass. Low bile acid concentrations are common in birds with microhepatia (as detected radiographically), poor feather formation and an overgrown, malformed beak.
- **Physiologic Influence:** A significant postprandial increase of bile acids has been documented in racing pigeons and the Mallard Duck. Healthy birds with a gall bladder may not have significantly different postprandial bile acid concentrations when compared to species that do not have a gall bladder.<sup>55</sup>
- **Pathologic Changes:** Elevations in bile acids have been shown to correlate with liver disease in pigeons,<sup>55</sup> chickens<sup>10</sup> and African Grey Parrots.<sup>50</sup> With further research, bile acid assays may prove to be one of the best tests for liver function in birds.<sup>38</sup> Bile acids are stable in plasma for prolonged periods, allowing shipment of specimens to distant laboratories for analysis.
- **Reference Intervals:** African Grey Parrots (18-71); Amazon parrots (19-144); cockatoos (23-70); macaws (25-71).

### Bilirubin

- **Method:** Most methods for measuring bilirubin are based on the diazo reaction, in which diazotized sulfanilic acid reacts with bilirubin to produce two azodipyrroles. These products are reddish purple at neutral pH, and blue at low or high pH.

- **Physiology:** In chickens, the major bile pigment is biliverdin. The enzyme biliverdin reductase is absent, and biliverdin is not converted into bilirubin.<sup>44,45</sup>
- **Diagnostic Value:** Low concentrations of bilirubin were detected in the sera of healthy ducks. Concentrations increased following infection with duck hepatitis virus.<sup>1</sup> The diagnostic value of bilirubin appears to vary among species. It has no value in chickens that cannot form bilirubin, but may be of value in other species.
- **Pathologic Changes:** Bilirubin cannot normally be detected in plasma of normal psittacines. With severe hepatic disease (eg, chlamydiosis or Pacheco's disease virus) bilirubin concentrations up to 44.5  $\mu\text{mol/l}$  have been reported. A slight yellow coloration (icterus) could be seen in the facial skin of two macaws with bilirubin concentrations exceeding 40  $\mu\text{mol/l}$ .
- **Diagnostic Value:** Total calcium should always be interpreted along with albumin concentrations. Hypoalbuminemia will reduce the quantity of bound calcium and result in a decreased total calcium concentration without reducing biologically active calcium (ionized fraction).<sup>31,36,53</sup> The hyperproteinemia that occurs with dehydration may result in an increased total calcium concentration.
- **Physiologic Influence:** Ovulating hens have significantly higher calcium levels than non-reproductively active females. Female budgerigars were found to have significantly higher calcium concentrations than males. Young birds generally have lower calcium concentrations than adults.<sup>32,27</sup>
- **Pathologic Changes:** Decreased calcium concentrations are common in seizing African Grey Parrots. This hypocalcemia syndrome has been described as a unique form of hypoparathyroidism in which calcium is not properly released from bone.<sup>31,33,36</sup> Glucocorticoid therapy will decrease total calcium concentrations. Increased calcium concentrations have been reported with dietary excesses of Vitamin D, osteolytic bone tumors and dehydration. Even in cases of severe dietary calcium deficiency, parahormone will normally mobilize bone to maintain calcium blood concentrations within physiologic limits.

### Calcium

- **Sample:** Heparinized plasma or serum can be used. Some calcium-binding anticoagulants, like EDTA, citrate and oxalate (fluoride oxalate is used for determining glucose levels in mammals) will cause falsely low values. For the determination of ionized calcium levels, whole blood, heparinized plasma or serum can be used, but the pH of the specimen must be the same as that of the patient's blood at the time of sampling. This is most readily achieved by collecting and processing the specimen quickly and anaerobically.
- **Method:** Total calcium concentrations include the sum of biologically active ionized calcium, protein bound calcium (which is bound mainly to albumin) and calcium chelated with anions, like phosphate or citrate. Bound calcium is biologically inactive and can be decreased (thus decreasing the measurement of total calcium) without causing any clinical effects. Of the many methods described to measure total calcium, atomic adsorption spectrophotometry and spectrophotometry of calcium-dye complexes are most often used. Ionized calcium levels have been shown to be clinically valuable; however, this is not a commonly available assay.
- **Physiology:** As a major constituent of bone, calcium plays a vital role in the structure of the body. It also has important physiologic functions involving the transmission of nerve impulses, the permeability and excitability of all membranes, the activation of enzyme systems (eg, blood clotting), calcification of egg shells and contraction of the uterus during oviposition.
- **Method:** Cholesterol consists of both free cholesterol and cholesterol esters, which are measured together as total cholesterol. Either enzymatic or chemical methods can be used for quantification. Enzymatic procedures have virtually replaced chemical methods in the clinical laboratory. The initial reaction steps are common to all enzymatic procedures. These include the hydrolysis of cholesterol esters to form free cholesterol, which is measured after a subsequent oxidation step utilizing  $\text{O}_2$  to produce  $\text{H}_2\text{O}_2$ .
- **Physiology:** Cholesterol is a major lipid that is a precursor of all the steroid hormones and bile acids as well as a component of the plasma membrane of cells. It is obtained from the animal protein sources in the diet as well as being synthesized by the liver.
- **Diagnostic Value:** Elevated and decreased cholesterol concentrations may occur from a number of physiologic influences and different diseases; however, the diagnostic value of this test in birds appears to be poor. Very high cholesterol concentrations usually accompany lipemia, especially in Amazon parrots, macaws and Rose-breasted Cockatoos with fatty liver degeneration.

### Cholesterol

- **Physiologic Influence:** Cholesterol concentrations will vary with a bird's diet. Carnivorous birds have higher concentrations, whereas fruit- or grain-eating birds have lower concentrations.<sup>43</sup> Male budgerigars were found to have significantly higher cholesterol concentrations than females.<sup>32</sup>
- **Pathologic Changes:** Elevations can occur because of hypothyroidism, liver disease, bile duct obstruction, starvation or high fat diets.<sup>2,25,73,36</sup> High cholesterol concentrations have been reported in budgerigars with xanthomatosis.<sup>36</sup> Decreased cholesterol levels have been associated with some cases of liver disease, aflatoxicosis,<sup>73</sup> reduced fat in the diet, *Escherichia coli* endotoxemia and spirochetosis.<sup>25</sup>

### Creatinine

- **Method:** Most currently used assays are based on the Jaffe reaction.<sup>68</sup> This reaction occurs between creatinine and the picrate ion formed in an alkaline medium.
- **Physiology:** Blood creatinine is derived mainly from the catabolism of creatine found in muscle tissue. Phosphocreatine is used to store energy in muscle, and its catabolism to creatinine occurs at a steady rate. Excretion of creatinine is solely via the kidneys. It is freely filtered and reabsorbed in the tubules.<sup>25</sup> In birds, creatine is excreted in urine before it has been converted to creatinine.<sup>6</sup> The urinary excretion of creatine may be one reason that creatinine levels do not provide an accurate assessment of avian renal function.
- **Diagnostic Value:** There is a slim margin between the physiologic and pathologic levels of creatinine. For many analyzers, physiologic values are below the detectable range. This test parameter is very insensitive and is a relatively poor diagnostic test in birds.
- **Physiologic Influence:** Normally, creatinine production is relatively constant and is minimally affected by catabolism of dietary or tissue proteins. Theoretically, the pool of creatine from which creatinine is liberated depends on the total muscle mass. However, in all avian species that have been investigated, the reference interval for creatinine has been between 0.1-0.4 mg/dl, with no significant differences between species.
- **Pathologic Changes:** Severe kidney damage can lead to increased creatinine levels, especially if the filtration rate is decreased. Elevations have also been described in connection with egg-related peritonitis, septicemia (eg, chlamydiosis), renal trauma and nephrotoxic drugs.<sup>43</sup>

### Glucose

- **Sample:** Heparinized plasma or serum can be used. For reliable glucose determination in avian blood, it is not necessary to prevent glycolysis as long as the blood is not stored for more than two hours.<sup>57</sup> This is contrary to the situation in mammals in which sodium fluoride is often used to ensure accurate glucose determinations. This is because avian erythrocytes consume very little, if any, glucose, and depend primarily on fatty acid metabolism for energy.
- **Method:** Glucose levels may be determined using enzymatic (eg, hexokinase) or colorimetric (eg, toluidine) techniques. There is a reasonable agreement in the values among the most commonly used methods.<sup>68</sup> Simple colorimetric tests in the form of a dip stick have been used with some success in birds. Lipemia or hemolysis of the sample can interfere with photometric methods of measurement, giving falsely elevated values.<sup>11</sup> This is less likely to occur with kinetic assays that evaluate a change in optical density over time and are therefore self-blanking.
- **Physiology:** Glucose is continuously required as an energy source by all the body cells and must be maintained at adequate levels in plasma. Glucose levels are maintained principally through the conversion of liver glycogen, with some being derived from non-carbohydrate sources (hepatic gluconeogenesis). In periods of starvation, glucose is increasingly derived from the breakdown of fats and proteins, primarily from muscle tissue, through gluconeogenesis in the liver and the kidneys. All plasma glucose is filtered from the blood through the renal glomeruli and then totally reabsorbed in the tubules.

Interestingly, 73 hours of starvation in pigeons induces hyperglycemia rather than starvation hypoglycemia.<sup>57</sup> This finding has important consequences for avian anesthesia and gastrointestinal surgery, as presurgical fasting varying from four hours (emptying of the crop) to 24 hours (emptying of the entire gastrointestinal tract) can be advantageous. Prolonged fasting is not recommended in birds that weigh less than 100 grams.

- **Diagnostic Value:** Glucose is often a part of a laboratory panel<sup>25,43,73</sup> even though pathologic changes in birds are seldom detected.<sup>36</sup> Glucose should be evaluated in convulsing birds or those with glucosuria.

- **Physiologic Influence:** Plasma glucose levels are higher in juvenile than adult budgerigars.<sup>32</sup> Variations also occur due to time of day and amount of environmental stress.<sup>43</sup> Plasma glucose concentrations in fasted birds are subject to a circadian rhythm. A rise in plasma glucose concentration starts during the scotophase, reaching peak values early during the photophase. Subsequently, a gradual increase can be observed with the lowest values at the end of the photophase. Afternoon plasma glucose concentrations in birds that are fed early during the photophase are significantly higher when compared to fasted birds.<sup>57</sup>
- **Pathologic Changes:** Increases in plasma glucose levels are due to increased glucose production or release. For example, increases occur after meals, with excitement or stress or because of decreased glucose usage (diabetes mellitus).<sup>2,25,50,73</sup> Diabetes mellitus has been confirmed in budgerigars, cockatiels, Amazon parrots, Scarlet Macaws, Umbrella Cockatoos and a Toco Toucan.<sup>43</sup> Transient elevations in glucose have been reported in cockatiels with egg-related peritonitis.<sup>63</sup> Decreases in plasma glucose levels can be due to hepatic dysfunction (eg, Pacheco's disease virus), impaired glucose production or its excessive utilization (eg, septicemia, neoplasia, aspergillosis).<sup>61,63</sup> In young birds of prey, hypoglycemia can cause convulsions.<sup>36</sup> Starvation of up to four days' duration will not cause hypoglycemia in all birds, but in some (particularly raptor neonates), hypoglycemia can occur after a few days of anorexia.<sup>50</sup> Glucose concentrations can be artificially decreased during storage if the blood sample is contaminated with bacteria.<sup>34</sup>

### Phosphorus

- **Sample:** Heparinized plasma or serum is suitable. Anticoagulants such as citrate, oxalate or EDTA should not be used because they interfere with the formation of the phosphomolybdate complex. Hemolysis must be avoided, because the phosphate concentration of erythrocytes is higher than that of plasma, and hemoglobin interferes with the colorimetric detection reaction used to determine phosphorus levels.
- **Method:** Most assays for inorganic phosphate rely on the formation of a complex of phosphate ion with a molybdate compound.<sup>20</sup>
- **Physiology:** Inorganic phosphorus is derived from the diet. It is a major constituent of bone and a vital cellular component, playing important roles in the storage, release and transfer of energy and in acid-base metabolism.
- **Diagnostic Value:** Changes in inorganic phosphorus concentration can occur with several diseases, but not on a consistent basis. The diagnostic value is poor.
- **Physiologic Influence:** Diets that consist mostly of seeds may lead to increased phosphorus levels. Juvenile budgerigars were found to have higher concentrations than adults.<sup>32</sup> No changes in inorganic phosphorus levels were noted in laying hens.<sup>43</sup>
- **Pathologic Changes:** Increased plasma inorganic phosphate levels can be seen in some cases of severe kidney damage<sup>2,36,73</sup> due to vitamin D hypervitaminosis,<sup>2</sup> nutritional secondary hyperparathyroidism<sup>43,73</sup> and hypoparathyroidism.<sup>31,33</sup> False elevations will occur if samples are hemolyzed. Occasionally, decreased plasma inorganic phosphate levels may occur from hypovitaminosis D (calcium level also decreased), malabsorption because of phosphate binding agents in the diet (calcium normal) and long-term glucocorticoid therapy.

### Iron

- **Sample:** Heparinized plasma or serum can be used. Plasma specimens collected with EDTA, oxalate or citrate are unsatisfactory, because they bind iron. Markedly hemolyzed specimens are nondiagnostic because free hemoglobin will increase the total serum iron levels.
- **Method:** For iron level assays, reduced Fe (II) is complexed with a chromogen. This complex has a high light absorbance that is proportional to the iron concentration.<sup>68</sup> Most assays require a large sample size (200  $\mu$ l).
- **Physiology:** Iron is an essential constituent of the heme portion of hemoglobin. As the hemoglobin in aged erythrocytes is broken down, iron is recycled and fresh hemoglobin is synthesized. Iron is transported in the plasma attached to a  $\beta$ -1-globulin known as transferrin.
- **Diagnostic Value:** The value of determining iron in different avian species has not been thoroughly investigated. A recent report shows a failure to correlate serum iron levels with liver biopsy and subsequent toxicologic analysis for iron.<sup>75</sup>
- **Physiologic Influence:** Prior to egg laying, iron levels will increase two to three times normal in some species.<sup>25</sup> Raptors maintained in captivity have significantly lower values than their free-ranging counterparts.<sup>36</sup> Captive toucans have approximately three

times higher reference values of iron than psittacine birds (see Chapter 47).<sup>74</sup>

- **Pathologic Changes:** Severe and chronic loss of blood will increase iron values. Iron deficiency anemia has been described in raptors.<sup>40</sup> Changes in plasma iron levels in mynah birds and toucans with iron storage disease are described in Chapter 47.

#### Total Iron-Binding Capacity (TIBC)

- **Method:** An excess amount of ferric ammonium citrate is added to serum to saturate the transferrin iron-binding sites. The unbound Fe (III) is removed and the iron content of the supernatant is assayed as described for iron.<sup>68</sup>
- **Physiology:** Normally, only one-third of the iron-binding sites of transferrin are occupied by Fe (III), creating a reserve of iron-binding sites. The total iron-binding capacity (TIBC) is a measurement of the maximum concentration of iron that serum proteins, principally transferrin, can bind. A urine iron-binding capacity (UIBC) test is also available.<sup>75</sup>
- **Diagnostic Value:** Abnormalities in TIBC occur with some disorders of iron metabolism. Very little data from birds is available. This parameter appears to have little importance in diagnosing hemochromatosis, but insufficient research has been performed.<sup>74,75</sup>
- **Pathologic Changes:** TIBC may be increased with iron deficiency and decreased in chronic inflammatory disorders.

#### Lipase

- **Method:** There are various methods for determination of lipase activity, and the reference ranges depend on the method used.
- **Physiology:** Lipase measured in plasma or serum is produced in the pancreas. This enzyme functions in the digestion of fat in the diet.
- **Diagnostic Value:** Lipase and amylase activities were high in a caique with clinical signs of pancreatic exocrine insufficiency when compared to the activities of these enzymes in the mate (Ritchie BW, unpublished). Hemolysis inhibits enzyme activity.
- **Pathologic Changes:** Although no reference values are currently available, birds do exhibit high lipase activity in severe cases of acute pancreatitis. For diagnostic purposes, a blood sample from a representative of the same species should be included for comparison.

#### Total Protein (TP)

- **Sample:** When only small amounts of blood can be collected, it may be advantageous to use plasma instead of serum to determine the TP concentration. In pigeons, the concentration of TP in plasma is about 1.5 g/l higher than in serum, because the former contains fibrinogen.<sup>58a</sup>
- **Method:** Total protein levels may be determined using a chemical method or a refractometer. The chemical method of choice is the biuret method, which measures the TP in fluids colorimetrically using the formation of a blue peptide (copper complex in alkaline solution). This method is extremely accurate for the protein levels typically found in plasma or serum (1 to 10 g/dl), but is not precise enough to determine the low concentrations of proteins that are found normally in other body fluids. Both wet and dry chemistry methods use this technique, but the results vary with the instrument used.

Most commercial laboratories use a human standard when determining TP and albumin concentrations, and various studies have shown that there are significant differences between TP concentrations when different standards are used (eg, human, bovine, pigeon, chicken). Because it is impossible to have a species-specific standard for all species presented to the avian practitioner and because there is a high correlation between the results obtained with the various standards, it seems wise to establish reference values for the various species using the human standard.<sup>53</sup>

The refractometer is widely used by veterinarians to measure change in the refractive index of a solution, which is caused mainly by the proteins in solution and is proportional to the concentration of total solids or protein. Most refractometers are temperature-compensated and already calibrated in scales expressing TP concentration (g/dl) and specific gravity of urine.

Information on the reliability of the refractometric method to determine TP concentrations in avian blood is conflicting. One study indicated that temperature compensated refractometers provide reliable results when compared to non-temperature-compensated devices.<sup>3</sup> In another study, temperature-compensated and non-compensated refractometers yielded higher values than the biuret method, with the temperature-compensated instrument being consistently higher in readings than the non-temperature-compensated refractometer. In juvenile



Eclectus Parrots,<sup>15</sup> macaws<sup>16</sup> and cockatoos,<sup>17</sup> proteins measured by refractometer were consistently higher than those measured by the biuret method.

Due to its dependence on the transmission of light, it is important that a refractometer be used only for clear, non-turbid and non-lipemic fluids. A moderate degree of hemolysis or icterus should not alter the values.<sup>39</sup> In mammals, hyperglycemia (> 700 mg/dl) affects the accuracy of a refractometer for determining TP.<sup>68</sup> At protein concentrations < 3.5g/dl, refractometric results are likely to be inaccurate.<sup>68</sup> Hemolysis causes the release of hemoglobin and intracellular proteins that will increase the refractometry reading. Because of the higher glucose and lower TP concentrations in birds, correlation of results from the refractometer and the biuret methods may not be possible in some species.<sup>3,15-17,47,48,51,52,53,72</sup> Refractometry should be considered a rapid method for determining an estimate of the body fluid protein. Ideally, total protein concentrations have the most value when considered with the results of plasma protein electrophoresis.

- **Physiology:** Most plasma proteins, with the exception of immunoglobulins and protein hormones, are synthesized in the liver. They form the basis of organ and tissue structure, operate as catalysts (enzymes) in biochemical reactions, are regulators (hormones) and are transport and carrier compounds for most of the constituents of plasma. The biological activity of proteins for these various functions is dependent upon their primary and secondary structure.

In female birds, a considerable increase in plasma TP concentration occurs just prior to egg laying, which can be attributed to an estrogen-induced increase in globulins. The proteins are the yolk precursors (vitellogenin and lipoproteins), which are synthesized in the liver and transported via the plasma to the ovary where they are incorporated in the oocyte.

- **Diagnostic Value:** Total protein is often used as an indicator for the health status of a patient. Determination of plasma protein concentrations may be of value in diagnosing gastrointestinal, hepatic or renal diseases. Furthermore, plasma proteins will be abnormal in infectious diseases that cause a stimulation of the immune system. Although determination of plasma proteins seldom leads to a specific diagnosis (eg, in the case of monoclonal gammopathies), it will help the clinician to evaluate the severity and progression of a disease.<sup>49</sup> Changes in protein concentration can occur passively due to dehydration (hyper-

proteinemia) or over-hydration (hypoproteinemia) or actively due to dysproteinemias.

- **Physiologic Influence:** Changes in TP must be interpreted with respect to physiologic influences dissociated with disease. Age and stage of development will influence the concentration of TP in birds. Advancing age has been associated with increases in TP in several species.<sup>15-17,25</sup> Hormones can have either an anabolic or catabolic effect on TP. In general, hormonal effects on TP are minimal. However, testosterone, estrogen and growth hormone were found to increase TP in chickens; thyroxine decreased concentrations.<sup>39</sup> The effects that diet has on the total protein concentrations are subtle and difficult to detect or interpret. Temperature stress (hypothermia or hyperthermia) is associated with nitrogen loss, increased adrenal activity and increased protein turnover, resulting in a decrease in TP. Similar findings are observed following crushing injuries, bone fractures and extensive surgery.<sup>39</sup>
- **Pathologic Changes (Dysproteinemia):** Hypoproteinemia can reflect reduced synthesis caused by chronic hepatopathies, malabsorption caused by chronic enteropathies (enteritis, tumors, parasitism), increased loss caused by proteinuria due to renal disease, blood loss and malignant tumors (rarely seen in birds) or starvation and malnutrition. Hyperproteinemia may be induced by chronic infectious diseases that stimulate production synthesis of gamma globulin. It also has been seen with chronic lymphoproliferative disease that resembles leukosis in chickens<sup>43</sup> and myelosis in budgerigars.<sup>36</sup> As mentioned previously, dehydration should always be ruled out as a cause of hyperproteinemia.

### Electrophoresis

- **Sample:** Serum is most commonly used for protein electrophoresis in mammals, so fibrinogen is not included in the sample. Hemolysis will affect electrophoresis results, and heparinized plasma is often used to prevent this problem.<sup>50,54,72</sup>
- **Method:** Electrophoresis is used to separate different types of plasma proteins, making it possible to determine their relative proportion in a particular sample. At a neutral or alkaline pH, serum or plasma, supported on a specific matrix, is placed in an electrical field, causing the different protein fractions to migrate at varying speeds toward the anode based on their relative charge. Following staining, these fractions appear as bands of varying intensity, which can be scanned by a densitometer to produce an electro-

phoretic tracing. The length and height of each peak within the pattern indicates the relative amount of a particular protein or group of proteins. This can be translated into percentage readings and, by combining this information with the TP concentration, absolute values for the concentration of each protein, or protein group, can be calculated.

- **Physiology:** Most frequently used electrophoresis methods identify five main protein fractions in birds: albumin,  $\alpha$ 1-,  $\alpha$ 2-,  $\beta$ - and  $\gamma$ -globulins.<sup>66</sup> A pre-albumin fraction has been described in pigeons and some parrot species.<sup>15,16,17,50,54</sup> The  $\alpha$ -globulins are acute phase proteins that typically increase with acute inflammation;  $\beta$ -globulins are composed of complement, hemopexin, ferritin, fibrinogen and lipoproteins.<sup>39</sup> Some immunoglobulins, including IgM and IgA, also migrate in the  $\beta$ -globulin range. The  $\beta$ -globulins are also acute phase proteins. The  $\gamma$ -globulin fraction is mainly composed of immunoglobulins (IgA, IgM, IgE and IgG).<sup>66</sup>
- **Diagnostic Value:** In healthy birds the albumin fraction is the largest protein fraction. An inflammatory process will cause a rise in TP because of increased concentrations of  $\alpha$ ,  $\beta$  or  $\gamma$  globulin fractions. Often albumin concentrations are decreased in these situations. The combined effect of these changes is a decrease in the albumin/globulin (A/G) ratio. Often the TP concentration is within the reference range, while the A/G ratio is decreased. Therefore, the A/G ratio is of greater clinical importance than the TP concentration. Examples of diseases with a decrease in the A/G ratio are egg-related peritonitis, and chronic infectious diseases such as aspergillosis, psittacosis and tuberculosis.

Serum or plasma protein electrophoresis can be used to monitor response to treatment. When the bird responds favorably, an increase in the albumin concentration and a decrease in the globulin concentration can be observed, which leads to normalization of the A/G ratio. In birds with liver failure, extremely low plasma protein concentrations can occur in combination with a decreased A/G ratio. Gastrointestinal and renal diseases can also lead to severe hypoproteinemia. These changes are caused by a loss of albumin. Elevated TP concentrations with a normal A/G ratio can be expected in dehydrated birds.

- **Physiologic Influence:** Physiologic factors that may change the protein concentration and therefore affect protein electrophoresis results include gender, age,

dietary protein, temperature stress, state of hydration, hemorrhage and inflammation.<sup>66</sup>

- **Pathologic Changes:** Decreases in albumin concentration can occur from decreased synthesis due to chronic liver disease or chronic inflammation, increased albumin loss due to renal disease, parasitism or over-hydration.<sup>72</sup> A decrease in albumin causes edema because of a decrease in oncotic pressure. Increases are seen because of dehydration.

Increases in  $\alpha$ - and  $\beta$ -globulins may be caused by acute nephritis, severe active hepatitis, systemic mycotic diseases ( $\gamma$ -) and the nephrotic syndrome.<sup>72</sup> Increases in  $\gamma$ -globulins occur with acute or chronic inflammation, infection, chronic hepatitis and immune mediated disorders.<sup>72</sup>

### Triglycerides

- **Sample:** Serum and lipemic specimens should be warmed to 37°C and vigorously mixed prior to analysis.
- **Method:** Usually, triglycerides are enzymatically detected by breaking down the triglycerides and measuring the glycerol that is liberated.
- **Physiology:** Triglycerides are the major storage form of lipids, and are a major energy source. Each molecule of triglyceride consists of three fatty acid molecules attached to a molecule of glycerol. They are synthesized in the intestinal mucosa and liver from the components of fat digestion and absorption.
- **Diagnostic Value:** Triglyceride values have been insufficiently evaluated in birds. Several factors can influence the blood concentration and increases may not be of clinical importance.
- **Physiologic Influence:** Triglyceride levels may vary based on climate, hormone influence, diet and gender. Increases may occur during starvation, particularly in obese birds. Estrogen injections have been shown to elevate triglyceride concentrations in some species.<sup>25</sup>
- **Pathologic Changes:** Egg-related peritonitis has been associated with high concentrations of triglycerides.<sup>73</sup> High concentrations (2000-5000 mg/dl) were reported in Amazon parrots showing signs of hyperadrenocorticism. Because triglyceride values are determined based on enzymatically released glycerol, these values may be falsely elevated after exercise or following any event that causes increased levels of blood glycerol (eg, catching birds in an aviary).

### Urea

- **Method:** Both indirect methods (based on preliminary hydrolysis of urea with urease) and direct methods (based on variations in the thiazide reaction) are used for urea determination. This reaction involves the condensation of diacetyl with urea to form the chromogen diazine.<sup>68</sup>
- **Physiology:** In the liver, protein breakdown to amino acids releases urea, which is excreted by glomerular filtration in the kidney. Tubular reabsorption can occur and is dependent on the state of hydration. In dehydrated birds, nearly all of the filtered urea is reabsorbed. If properly hydrated, almost all of the filtered urea is excreted.
- **Diagnostic Value:** Urea is present in very small amounts in avian plasma, and determining urea levels has generally been considered of little value. However, recent investigations have shown good correlation between increased plasma urea concentrations and renal disease in pigeons.<sup>50</sup> In other avian species, urea may have little value in detecting renal disease but can be used as a sensitive indicator of dehydration.
- **Physiologic Influence:** Physiologic conditions are known to change urea concentrations in mammals, but similar effects have not been documented in birds.
- **Pathologic Changes:** High urea plasma levels can occur in all conditions that cause low urine flow, such as dehydration or bilateral ureteral obstruction.<sup>50</sup>

### Uric Acid

- **Method:** Both wet and dry chemistry systems use oxidation of urates by uricase as a detection method. Most uricase methods are extremely specific and only a few structural analogues to uric acid will interfere with the test. In general, the concentrations of these analogues are low in biological fluids.<sup>68</sup>
- **Physiology:** In birds, uric acid is the major product of the catabolism of nitrogen. Synthesis occurs mainly in the liver<sup>50</sup> and in the renal tubules.<sup>14</sup> Approximately 90% of blood uric acid is eliminated by secretion into the lumen of the tubules. Only 50% of the healthy avian kidney is actually used for excreting protein waste, providing a large functional reserve.<sup>25</sup>
- **Diagnostic Value:** The evaluation of uric acid concentrations in plasma or serum is widely used in birds for the detection of renal disease. Species differences in the ability of the avian kidney to compensate for damage before uric acid levels are elevated reduces

the diagnostic value for this test. However, if reference intervals are available, hyperuricemia is a good indicator of renal disease. Normal uric acid concentrations do not guarantee that the kidneys are healthy.

- **Physiologic Influence:** Age and diet may influence the concentration of blood uric acid in birds. Juvenile birds have lower concentrations than adults.<sup>15,16,17,32</sup> Hyperuricemia has been documented during ovulatory activity.<sup>43</sup> Grain-eating birds have approximately 50% lower uric acid concentrations than do carnivorous birds.<sup>25</sup> Uric acid levels are higher shortly after food consumption. Gender differences have not been reported.<sup>5</sup>
- **Pathologic Changes:** Hyperuricemia can be expected if the glomerular filtration is decreased more than 70 to 80%. Decreased filtration may occur from hypovitaminosis A-induced damage to renal epithelial cells, dehydration, intoxications or from some bacterial and viral (Newcastle disease) infections.<sup>2,5,21,25,36,73</sup> Uric acid levels may also be increased from the release of nucleic acids caused by severe tissue damage or starvation. If a toenail clip is used for blood collection and urates from the droppings contaminate the sample, the uric acid levels may be falsely elevated.<sup>21,43</sup>

If the blood uric acid concentration exceeds its solubility it will be deposited in different locations in the body. High plasma or serum concentrations of uric acid are a prognostic indicator that gout may occur. Use of nephrotoxic drugs may also lead to hyperuricemia. Hypervitaminosis D<sub>3</sub>-induced renal damage is frequently associated with gout and extremely high uric acid levels. This problem is particularly common in macaws. This has been described for aminoglycosides (gentamicin),<sup>2,25,43</sup> and allopurinol in Red-tailed Hawks.<sup>56</sup> Interestingly, in most species, allopurinol is effective in treating, not inducing gout.

Hypouricemia is much less common in birds than hyperuricemia. Severe hepatocellular disease with reduced synthesis of uric acid has been suggested as one etiology.

## Electrolytes

### Chloride

- **Method:** Different methods are in use, but ion-selective electrode methods are most common.

- **Physiology:** Chloride is the major extracellular anion. Sodium and chloride together represent the majority of the osmotically active constituents of plasma.
- **Diagnostic Value:** Elevations in chloride concentrations rarely are detected.
- **Physiologic Influence:** In budgerigars, no gender or other physiologic variables have been observed.<sup>32</sup>
- **Pathologic Changes:** Hyperchloridemia can occur with dehydration.<sup>25,36</sup> The role of chloride in maintaining acid-base balance has not been sufficiently evaluated in birds.

### Potassium

- **Sample:** Either heparinized plasma or serum is appropriate for detecting potassium. If ion-selective electrode methods are used, whole blood is also an effective sample. Differences in the electrolyte concentrations in serum and plasma must be considered when interpreting results. Potassium levels are usually higher in serum due to the release of potassium from thrombocytes damaged in the coagulation process. Hemolysis will elevate the plasma concentration of potassium (500 to 700%).<sup>39</sup> Potassium concentrations were found to rapidly decline in pigeon and chicken plasma allowed to sit for two hours.<sup>46</sup> For accurate results, plasma should be separated within minutes of collection. Hyperproteinemia and hyperlipemia will result in falsely low potassium levels caused by a decreased aqueous fraction of the total plasma volume.
- **Method:** Potassium may be determined by atomic adsorption spectrophotometry, flame emission spectrophotometry or electrochemically with a sodium ion-selective electrode. The last two systems are most commonly used.<sup>30,68</sup>
- **Physiology:** Only two percent of the body's potassium is in the extracellular fluid. The other 98% is kept within the cells by "potassium pumps" in the cell membranes.
- **Diagnostic Value:** Alternatives in potassium homeostasis have serious consequences. Decreased extracellular potassium is characterized by muscle weakness, paralysis and cardiac effects. Many potassium abnormalities are the result of hemolytic samples.
- **Physiologic Influence:** High amounts of potassium in the diet can elevate plasma concentrations.
- **Pathologic Changes:** Hyperkalemia can be caused by severe tissue damage, reduced potassium excretion by diseased kidneys,<sup>25,73</sup> adrenal disease<sup>73</sup> or because of redistribution of potassium from the intracellular to the extracellular fluid (acidosis).<sup>25</sup> Dehydration<sup>25,73</sup> and hemolytic anemia<sup>25</sup> can also cause hyperkalemia.

Hypokalemia may be caused by decreased potassium intake, increased potassium loss due to chronic diarrhea or diuretic therapy (seldom used in birds)<sup>73</sup> and the shift of potassium from the extracellular to the intracellular fluid (alkalosis).<sup>25</sup>

### Sodium

- **Sample:** Either heparinized plasma or serum is appropriate for sodium assays. With ion-selective electrodes, whole blood may be used. Electrolyte concentrations are different between serum and plasma. Hyperlipemia and hyperproteinemia will cause falsely low potassium levels by a mechanism similar to that described for potassium.
- **Method:** Sodium may be determined by atomic adsorption spectrophotometry, flame emission spectrophotometry or electrochemically with a sodium ion-selective electrode. The last two systems are most commonly used.<sup>30,68</sup>
- **Physiology:** Sodium is present mainly in the extracellular fluid and is primarily responsible for determining the volume of the extracellular fluid and its osmotic pressure. Intracellular sodium levels are kept low by a relatively impermeable cell membrane and a sodium pump which removes sodium from the cell. The amount of sodium in the body is regulated by the kidney. In addition, many avian species have a specialized nasal gland (salt or supraorbital gland) that is able to secrete large quantities of sodium in response to osmotic changes, thus allowing these birds to drink salt water. When sea birds are kept in fresh water for a period of time the gland shrinks so that when returned to salt water the birds can no longer tolerate high sodium levels. This mechanism of decreasing sodium concentration in the serum and urine of birds is mediated by a pituitary-adrenal response.<sup>66</sup>
- **Diagnostic Value:** Abnormal sodium levels that are not caused by technical failures are rarely seen in birds. If they do occur, they are good indicators of a pathologic situation. Salt poisoning, mainly from high salt foods, may occur more frequently in companion birds than is documented.

- **Physiologic Influence:** Sodium plasma levels are maintained within narrow limits, despite wide fluctuations in dietary intake.
- **Pathologic Changes:** Hyponatremia can occur from increased sodium intake (peanuts, crackers), excessive water loss or decreased water intake.

Hyponatremia may be due to increased sodium loss as in kidney disease<sup>73</sup> or severe diarrhea.<sup>25,73</sup> It may also be caused by over-hydration as in psychogenic polydipsia or after intravenous fluid therapy with sodium-free or low sodium solutions. The relative over-hydration, which follows a reduction in renal perfusion possibly because of decreased colloid osmotic pressure, may also cause hyponatremia.

#### Total Carbon Dioxide Content (Bicarbonate)

- **Method:** Heparinized plasma or serum can be used. Bicarbonate levels are determined by mixing the sample with a strong acid and measuring the carbon dioxide (CO<sub>2</sub>) release. Most of the carbon dioxide produced is derived from bicarbonate, but a small amount is generated from dissolved carbonic and carbamino acids.
- **Physiology:** Alterations of bicarbonate and CO<sub>2</sub> dissolved in plasma are characteristic of acid-base balance. For clinical purposes, the total CO<sub>2</sub> content is the same as the bicarbonate content.<sup>11</sup>
- **Diagnostic Value:** Bicarbonate levels are useful for establishing whether or not acidosis or alkalosis is present and, if so, how severe it is.
- **Pathologic Changes:** Increases are mainly due to metabolic alkalosis and decreases due to metabolic acidosis. Reference intervals for most avian species are not available.
- **Reference Values for Adult Budgerigars:** 21 to 26 mmol/l.<sup>32</sup>

#### Blood Gases - pCO<sub>2</sub>, pO<sub>2</sub> and pH

- **Sample:** Venous heparinized blood is the most likely specimen that will be collected for blood gas analysis. Determination should be performed as quickly as possible (in house).<sup>68</sup> When measuring blood gases and acid-base status in birds, it is necessary to collect blood samples in pre-cooled syringes and store the samples on ice to stop the metabolism of the erythrocytes. The nucleated avian erythrocytes possess virtually all the enzymes typical of metabolically active cells and consume oxygen seven to ten times faster than mammalian erythrocytes. Even during analy-

sis, which occurs at 37°C, the values are being influenced by temperature.

- **Method:** An expensive blood gas instrument is necessary.
- **Diagnostic Value:** Clinical significance in companion birds has not been thoroughly investigated.
- **Pathologic Changes:** Acidemia (decrease in blood or plasma pH) has been reported in some birds with renal disease.
- **Reference Values for Budgerigars:**<sup>32</sup> pH (7.334 to 7.489); pCO<sub>2</sub> (30.6 to 43.2 mm Hg) (see Chapter 39).

#### Other Tests

##### Delta-Aminolevulinic Acid Dehydratase

- **Method:** Plasma or serum can be used to measure delta-aminolevulinic acid dehydratase colorimetrically.
- **Diagnostic Value:** Delta-aminolevulinic acid dehydratase can be used to detect lead intoxication, and decreased plasma activity is pathologic.
- **Pathologic Changes:** The activity can decrease depending on the dosage of lead and the species up to 50% of the normal value.<sup>18,19,25</sup> Central nervous system changes have been reported if plasma activity is below 86 U/l (see Chapter 37).

##### Acid Phosphatase

This enzyme consists of a number of isoenzymes in a variety of organs. The activity is much lower than that of alkaline phosphatase. Ovulation has been shown to increase acid phosphatase activities.<sup>25</sup>

##### Copper

- **Method:** Atomic adsorption spectrophotometry after direct dilution is the method of choice for determining serum copper.<sup>68</sup>
- **Physiology:** Copper is a component of several major enzymes and plays a vital role in hemapoiesis. It is involved in the absorption and the transfer of iron and hemoglobin synthesis. In the plasma it is mainly bound to ceruloplasmin.
- **Diagnostic Value:** Elevation occurs with copper intoxication. In postmortem specimens, copper concentration in the liver provides the best diagnostic sample.<sup>25</sup>
- **Physiologic Influence:** Copper levels are generally higher in female mammals under the influence of

estrogens. In birds, the effect of estrogens on copper levels has not been investigated.

- **Pathologic Changes:** Copper intoxications will increase the serum level.

#### Plasma Dye Clearance Test

In many animal species, the hepatic uptake and excretion of different organic dyes injected intravenously has been used for diagnosis of liver disease. Indocyanine green has been successfully used to detect liver disease in three raptor species.<sup>70</sup> The dye was non-irritating if accidentally injected perivascularly and clearance occurred.

In contrast, Bromsulphalein must be injected with care, because perivascular injection causes severe pain. In chickens, the clearance is markedly influenced by age and gender.<sup>6,58</sup> The clinical value of these two tests has been insufficiently studied in birds.

### ■ Urinalysis

Urinalysis is indicated if renal disease is suspected. Polyuria is a common clinical presentation in companion birds.<sup>71</sup> It may be caused by excitement, in which the content of the cloaca is shed before the water is reabsorbed; by the intake of large amounts of fluids (fruits, vegetables); by renal disease, neoplasia, diabetes, sepsis, toxins, adrenal disorders or gout; after administration of some medications; and with impending egg laying. In all of these cases, it is relatively easy to separate the urine from the feces via aspirating the liquid deposited on a water-resistant surface. Transient polyuria can be induced by administering water by crop tube. This will usually result in urine production within 30 minutes after administration.<sup>73</sup> In pigeons, urine for analysis has been collected directly from the cloaca using a cannula.<sup>26</sup> Urine samples can be collected from individual ureters of anesthetized parrots using a speculum.

#### Volume, Color and Consistency<sup>73,25</sup>

Urine evaluation should include a measurement of volume, a record of appearance (color, consistency) and determination of specific gravity. Normal companion birds produce a small quantity of urine, and if it can easily be collected it is generally abnormal (stress or disease). The urine is usually clear in most companion bird species, but in other birds, such as ratites and Anseriformes, it is normally opaque, cloudy or slightly flocculent.

Many factors can influence the color of avian urine. It can change with the ingestion of water-soluble vitamins (especially Vitamin B), the amount of uric acid and feces mixed with the urine, the specific gravity and certain diseases (see Color 8). Macaws often have very dark yellow urine, which is not normal.

The white crystalline portion of the urine in birds is seldom evaluated except for color. Birds that are in a negative nitrogen balance (severe cachexia, catabolic disease) usually have an increased quantity of urates.

- **Pathologic Changes:** Lead intoxication in some species may result in chocolate milk-colored urine and urates. This hemoglobinuria is common and normal for some nervous birds. Severe liver disease, like that induced by chlamydia or Pacheco's disease virus, can increase the secretion of biliverdin, which results in yellow-green or mustard-colored urine and urates. Because many other severe clinical diseases cause this color to be present, it is not pathognomonic.

#### Specific Gravity

- **Normal:** The specific gravity varies with the state of hydration and with the individual bird. In the polyuric bird, values from 1.005 to 1.020 are considered normal. A refractometer can be used for this determination. Water deprivation should be used to evaluate the kidney's ability to concentrate low levels, often due to psychogenic polydipsia.
- **Pathologic Changes:** Increased loss of water without an increased loss of solute will create a low specific gravity. This situation can be caused by intravenous fluid therapy, hyperthyroidism, liver disease, pituitary neoplasia, progesterone or glucocorticoid therapy. Any disease that causes polyuria and polydipsia can cause a low specific gravity. A reduced ability to concentrate or dilute the glomerular filtrate will lead to an increased specific gravity and severe renal pathology.

#### Specific Evaluation

Substances filtered by the normal kidney generally have a molecular weight of less than 68,000 (eg, water, uric acid, urea, glucose, electrolytes). Two substances that are on the border of this molecular weight cutoff are hemoglobin and albumin. Most other physiologic proteins have higher molecular weights. Most substances that are filtered by the kidneys are critical to normal bodily functions and are completely reabsorbed (eg, amino acids, glucose, vitamins). The excretion or retention of other substances are regulated according to the body's needs.

Urinary pH and the concentration of some chemical constituents in the urine can be measured using commercial test strips designed for use with human urine. It should be noted that the sensitivity of these tests has been adjusted to detect what would be regarded as abnormal levels of certain substances in human urine. These sensitivities are not necessarily applicable to birds and the fact that a "higher" reading is obtained on an area of the test strip does not necessarily imply an abnormality. For example, alkaline urine can produce falsely elevated protein levels. The color of the urine sample may also affect the results of some test parameters.

- **Normal pH:** Most pet birds have a pH between 6.0 to 8.0, which is largely related to the diet. Birds fed large amounts of protein (carnivores) have an acidic urine, while grain-eating birds have more alkaline urine.
- **Pathologic Changes:** Companion birds with urine pH lower than 5.0 are considered acidotic.<sup>73</sup> Increased protein catabolism will cause a lower pH. Bacterial metabolism tends to cause an alkaline pH. Companion birds with papillomatosis and other disorders that typically cause tenesmus may have acidic urine. Presumably this is caused by excretion of fluids from the upper intestinal tract.<sup>8</sup> It has been suggested that the cloacal mucosa of a normal companion bird is neutral to slightly alkaline when measured with litmus paper (Harrison GJ, unpublished).

#### Urinary Protein

- **Normal:** Trace amounts of protein can be detected in the urine of 90% of birds tested.<sup>73</sup>
- **Pathologic Changes:** Many renal disorders will result in a mild to moderate proteinuria. Non-renal sources of proteinuria include hematuria, hemoglobinuria and hyperproteinemia, which are usually caused by an increase in the production of immunoglobulins. Inaccurate protein levels will be detected if the urine is alkaline or if the strip is soaked in urine (instead of briefly dipped), which leaches out the citrate buffer.

#### Glucose

- **Normal:** Avian urine normally contains no glucose. In healthy pigeons, reference values between 0 and 3.2 mmol/l were established by the hexokinase reaction.<sup>50</sup> Trace glucose readings may be detected in normal avian urine by using dip sticks.<sup>73</sup>
- **Pathologic Changes:** The threshold for glucosuria to occur varies with the species.<sup>73</sup> Glucosuria will

occur in most birds when the blood glucose level exceeds 600 mg/dl. In diabetes mellitus, birds may have blood glucose concentrations above 800 mg/dl.

#### Ketones

Ketones should be absent from the urine of birds. Any significant shift in energy production from carbohydrates to fats results in the increased oxidation of fatty acids and the production of intermediate metabolites that accumulate faster than they can be oxidized by the tissues. Catabolic processes such as severe hepatitis in combination with low blood glucose concentrations and diabetes mellitus can cause ketonuria.

#### Bilirubin

Bilirubin is not normally present in birds. Biliverdin is the major bile pigment, but will not react with the bilirubin portion of a mammalian urine dip stick.

#### Urinary Urobilinogen

Normal readings are 0.0 to 0.1 in healthy birds. Pathologic changes would be expected in cases of intravascular hemolysis and severe liver disease, but are seldom reported. Falsely high levels of urobilinogen in urine can be due to drugs which appear red in acid urine (eg, Vitamin B<sub>12</sub>) or if sulphonamides are present.

#### Blood

Commercial strip tests are available that can distinguish hematuria (ie, an abnormally large number of intact RBCs in the urine) and hemoglobinuria (ie, hemoglobin that is free within the urine and not contained within cells). With hematuria, individual erythrocytes lyse on the test area, giving individual spots of color. If there is free pigment, the color change is uniform throughout.

Normal readings are negative or trace. Blood in the urine may originate from the cloaca or from the urinary, reproductive or gastrointestinal tracts. Hemoglobinuria can be due to intravascular lysis of RBCs (rare) or lysis of RBCs present in the urine.

#### Urinary Nitrite

This test is included on many commercial test strips and is used to screen for bacteriuria. It is an unreliable test for avian urine.

#### Urinary Sediment

Examination of the urinary sediment is a valuable part of urinalysis but one that is often omitted. A fresh or refrigerated sample is required. With time,

there is increasing alkalinity causing progressive lysis of blood cells and casts. Usually centrifugation is used to concentrate the sediment to approximately ten percent of its original urinary volume.

### White and Red Blood Cells

The number of RBCs and WBCs in the sediment is reported as the number per high power field (HPF). Normal urine contains 0 to 3 RBCs/HPF and 0 to 3 WBCs/HPF.<sup>73</sup> More than 6 white or red blood cells per HPF is a cause for concern. All cells noted within the urine sediment may have origins within the cloaca or the urinary, reproductive or gastrointestinal tracts.

### Epithelial Cells

Normal urine contains no epithelial cells. The presence of any epithelial cells (eg, renal tubular cells) should be considered abnormal.<sup>73</sup>

### Casts

Casts are cylindrical structures molded into the shape of the renal tubules. Normally no casts are seen in avian urine. Casts are frequently noted in

cases of renal disease. Granular casts are most common. Cellular casts (which incorporate cells like RBCs, WBCs or tubular epithelial cells) and hyaline casts (consisting of mucoprotein gel) may also be seen.

### Bacteria

In mammals, it is believed that bacteria in excess of  $3 \times 10^4$ /ml of urine must be present before they are detectable in urinary sediment.<sup>68</sup> Gram-positive cocci and rods may be noted in the avian urinary sediment if the sample has been contaminated with fecal material.

- **Pathologic Changes:** Reports of bacteria that are "too numerous to count" or numerous cocci and rods in reasonably clean urine samples should be viewed with suspicion.<sup>73</sup> Avian urine is sterile leaving the kidneys, and Gram's stains or cultures comparing stool and urine flora may be helpful in documenting bacteria that originate from the urinary tract. Bacteria may multiply en route to the laboratory, which will lead to high counts in the sample.

## References and Suggested Reading

1. **Ahmed AAS et al:** Effects of experimental duck virus hepatitis infection on some biochemical constituents and enzymes in serum of white Peking ducklings. *Avian Dis* 19:305-309, 1974.
2. **Amund WB:** Avian clinical hematology and blood chemistry. In *Fowler ME: Zoo and Wild Animal Medicine*. Philadelphia, WB Saunders, 1986, pp 272-274.
3. **Andreassen CB, et al:** Determination of chicken and turkey plasma and serum protein concentrations by refractometry and the buret method. *Avian Dis* 33:93-96, 1989.
4. **Baron HW:** Die Aktivitätsmessung einiger Enzyme im Blutplasma bzw. -Serum verschiedener Vogelspezies. (Measurement of different enzyme activities in plasma/serum of different bird species.) *Vet Diss München*, 1980.
5. **Baumann CR:** Harnsäurebestimmung im Blutplasma verschiedener Vogelarten. (Measurement of uric acid in different bird species.) *Vet Diss München*, 1980.
6. **Bell DJ, Freeman BM:** Physiology and Biochemistry of the Domestic Fowl. New York, Academic Press, 1971.
7. **Bermes EW, Young DS:** Laboratory principles and instrumentation. General laboratory techniques and procedures. In *Tietz NW (ed): Textbook of Clinical Chemistry*. Philadelphia, WB Saunders Co, 1986, pp 3-45.
8. **Bogin E, Israeli B:** Enzyme profile of heart and skeletal muscle, liver and lung of roosters and geese. *Zbl Vet Med A* 23:152-157, 1976.
9. **Bogin E, et al:** Serum enzyme profile of turkey tissue and serum. *Zbl Vet. Med A* 23:858-862, 1976.
10. **Bromidge ES, et al:** Elevated bile acids in the plasma of laying hens fed rapeseed meal. *Res Vet Sci* 39:378-382, 1985.
11. **Bush BM:** Interpretation of Laboratory Results for Small Animal Clinicians. London, Blackwell Scientific Publications, 1991.
12. **Calle PP, Stewart CA:** Hematologic and serum chemistry values of captive hyacinth macaws (*Anodorhynchus hyacinthinus*). *J Zoo An Med* 18(2-3):98-99, 1987.
13. **Campbell TW:** Selected blood biochemical tests used to detect the presence of hepatic disease in birds. *Proc Assoc Avian Vet*, 1986, pp 43-51.
14. **Chou ST:** Relative importance of liver and kidney synthesis of uric acid in chickens. *Can J Physiol Pharm* 50:936-939, 1972.
15. **Clubb SL, et al:** Hematologic and serum biochemical reference intervals in juvenile eclectus parrots (*Eclectus roratus*). *J Assoc Avian Vet* 4(4):218-225, 1990. 16. **Clubb SL, et al:** Hematologic and serum biochemical reference intervals in juvenile cockatoos. *J Assoc Avian Vet* 5(1):16-26, 1991.
17. **Clubb SL, et al:** Hematologic and serum biochemical reference intervals in juvenile macaws (*Ara* sp). *J Assoc Avian Vet* 5(3):154-162, 1991.
18. **Dieter MP, Wiemeyer SN:** Six different plasma enzymes in bald eagles (*Haliaeetus leucocephalus*) and their usefulness in pathological diagnosis. *Comp Biochem Physiol* 61C:153-155, 1978.
19. **Dieter MP, Fiendley MZ:** Delta-amino-levalulinic acid dehydratase enzyme activity in blood and liver of lead dosed ducks. *Envir Rev* 19:127-129, 1979.
20. **Fiske CH, Subbarow Y:** The colorimetric determination of phosphorus. *J Biol Chem* 66:375-400, 1925.
21. **Flammer K:** Basic laboratory diagnostic techniques in avian practice. *Proc Assoc Avian Vet*, 1985, pp 283-293.
22. **Gerlach C:** Differentialblutbild und Plasmenzymuntersuchungen bei Greifvögeln im Verlauf eines Jahres (Differential blood count and plasma enzymes in birds of prey during one year: May 1977-May 1978). *Prakt Tierärz* 60(8):673-680, 1979.
23. **Goodwin JS, Jacobson ER, Gaskin JM:** Effects of Pacheco's parrots disease virus on hematologic and blood chemistry values of quater parrots (*Myopittacia monachus*). *J Zoo Animal Med* 13(3):127-132, 1982.
24. **Gräsbeck R:** Terminology and biological aspects of reference values. In *Benson ES, Rubin M (eds): Logic and Economics of Clinical Laboratory Use*. New York, Elsevier, 1978, pp 77-90.
25. **Gylstorf I, Grimm F:** Vogelkrankheiten. Stuttgart, Eugen Ulmer, 1987, pp 133-146.
26. **Halsema WB, et al:** Collection and analysis of urine in racing pigeons (*Columba livia domestica*). In *Lumeyt JT: A Contribution to Clinical Investigative Methods for Birds, with Special Reference to the Racing Pigeon (Columba livia domestica)*. PhD Thesis, University of Utrecht, 1987.
27. **Hannon SJ:** Plasma calcium as an indicator of reproductive condition in female Blue Grouse. *Can J Zool* 57:463-465, 1979.
28. **Harrison GJ, et al:** Clinical comparison of anesthetics in domestic pigeons and cockatiels. *Proc Assoc Avian Vet*, 1985, pp 7-22.
29. **Hernandez M:** Blood chemistry in raptors. *Proc European Assoc Avian Vet*, Vienna, 1991, pp 411-419.
30. **Hochleithner M, Schwendenwein I:** Evaluation of two dry chemistry systems in pet bird medicine. *Assoc Avian Vet Today* 2(1):18-23, 1988.
31. **Hochleithner M:** Convulsions in African grey parrots (*Psittacus erythacus*) in connection with hypocalcaemia. Five selected cases. *Proc Europ Symp Avian Med & Surg*, 1989, pp 44-52.
32. **Hochleithner M:** Blutchemische Untersuchungen beim adulten und juvenilen Wellensittich (*Melopsittacus undulatus*). (Blood chemistry in adult and juvenile budgerigars). *Inaug Diss Wien*, 1989.
33. **Hochleithner M:** Reference values for selected psittacine species using a dry chemistry system. *J Assoc Avian Vet* 3(4):207-209, 1989.
34. **Hochleithner M:** Verwertbarkeit von Vogelvollblut- und Plasmaproben nach unterschiedlicher Lagerung zur Bestimmung blutchemischer Parameter. (On the serviceability of avian blood and plasma samples for the determination of various blood-chemical parameters following different forms of storage). *Verh der VII Tagung über Vogelkrankheiten*, München, 1990, pp 25-33.
35. **Hochleithner M:** Einsatzmöglichkeit des Reflotron beim Ziervogel. (Use of Reflotron® in pet birds). *Tagungsbericht WSAVA Kongreß*, Wien, pp: 585-587, 1991.
36. **Hochleithner M:** Möglichkeiten der chemischen Blutuntersuchung beim Wild- und Ziervogel. (Possible approaches to hematochemical investigation in wild and pet birds). *Verhandlungsbericht des 33. Internationalen Symposiums über die Erkrankungen der Zoo- und Wildtiere*, pp: 153-160, 1991.
37. **Hochleithner M, Novotny P:** Cortisol and Corticosteron Plasmaspiegel bei verschiedenen Psittaciformes. (Cortisol and corticosteron plasmalevels in different psittacine birds). *Verh der VII Tagung über Vogelkrankheiten*, München 2. in print.
38. **Hoefler HL, Moroff S:** The use of bile acids in the diagnosis of hepatobiliary disease in the parrot. *Proc Assoc Avian Vet*, 1991, pp 118-119.
- 38a. **Joseph MM, Meier AH:** Daily rhythms of plasma corticosterone in the common pigeon *Columba livia*. *Gen & Comp Endocrin* 20:326-330, 1973.



39. **Kaneko JJ:** Clinical Biochemistry of Domestic Animals. San Diego, Academic Press, 1989.
40. **Kösters J, Meisters B:** Hematokrit und Hemoglobinwerte von verschiedenen Falken und Eulen. (PCV and hemoglobin of different birds of prey). *Prakt Tierarzt* 63(5):444-448, 1982.
41. **Kraft W, Dürr UM:** Kompendium der klinischen Laboratoriumsdiagnostik bei Hund, Katze, Pferd. (Clinical laboratory diagnosis in dogs, cats and horses). Stuttgart, M & H Schaper, 1981.
42. **Kürner D, Grimm F:** Bestimmung von Blutparametern mittels Reflotron®. (Blutchemistry using the Reflotron®). *Tierärztl Prax* 17:101-103, 1989.
43. **Lewandowski AH, Campbell TW, Harrison GJ:** Clinical chemistries. In Harrison G, Harrison L (eds): *Clinical Avian Medicine and Surgery*. Philadelphia, WB Saunders, 1986.
44. **Lin GL, Himes JA, Cornelius CE:** Bilirubin and biliverdin excretion by the chicken. *Am J Physiol* 226:881-885, 1974.
45. **Lind GW, Gronwall RR, Cornelius CE:** Bile pigments in the chicken. *Res Vet Sci* 8:280-282, 1967.
46. **Lumeij JT:** The influence of blood sample treatment on plasma potassium concentration in avian blood. *Avian Pathol* 14:257-260, 1985.
47. **Lumeij TJ, de Bruijne JJ:** Blood chemistry reference values in racing pigeons. *Avian Pathol* 14:401-408, 1985.
48. **Lumeij TJ, de Bruijne JJ:** Evaluation of refractometric methods for determination of total protein of plasma and serum. *Avian Pathol* 14:441-444, 1985.
49. **Lumeij JT, Westerhof I:** Blood chemistry for the diagnosis of hepatobiliary disease in birds. *Vet Quarterly* 9:255-261, 1987.
- 49a. **Lumeij JT, Westerhof I:** Clinical evaluation of thyroid function in racing pigeons (*Columba livia domestica*). *Avian Pathol* 17:63-70, 1988.
50. **Lumeij TJ:** A Contribution to Clinical Investigative Methods for Birds, with Special Reference to the Racing Pigeon (*Columba livia domestica*). Utrecht, Proefschrift, 1987.
51. **Lumeij JT:** Avian clinical pathology: Some experimental findings of importance to the practitioner. *Proc Assoc Avian Vet*, 1988, pp 79-86.
52. **Lumeij JT, de Bruijne JJ, Kwant MM:** Comparison of different methods of measuring protein and albumin in pigeon sera. *Avian Pathol* 19:225-261, 1990.
53. **Lumeij JT:** Relation of plasma calcium to total protein and albumin in african grey (*Psittacus Erythacus*) and amazon (*Amazona* spp.) parrots. *Avian Pathol* 19:661-667, 1990.
54. **Lumeij JT, Overduin LM:** Plasma chemistry reference values in psittaciformes. *Avian Pathol* 19:235-244, 1990.
55. **Lumeij JT:** Fasting and postprandial bile acid concentrations in racing pigeons (*Columbia livia domestica*) and mallards (*Anas platyrhynchos*). *J Assoc Avian Vet* 5(4):197-200, 1991.
56. **Lumeij JT, Redig PT:** Hyperuricemia and visceral gout induced by allopurinol in red-tailed hawks (*Buteo jamaicensis*). *Verh.ber.VII Tagung über Vogelkrankheiten, München, 1992* pp 265-269.
57. **Lumeij JT:** The influence of blood sample treatment, feeding and starvation on plasma glucose concentrations in racing pigeons. In Lumeij JT: *A Contribution to Clinical Investigative Methods for Birds with Special Reference to the Racing Pigeon*. PhD thesis, Utrecht University, 1987, pp 26-30.
58. **JO, Smith AH:** BSP clearance and fatty infiltration of the liver in domestic fowl. *Physiologist* 10:264, 1967.
- 58a. **Mclean B, Lumeij JT:** Evaluation of different refractometric methods for determination of total protein in pigeon blood. In preparation.
59. **Overduin LM, et al:** Diagnosis of liver disease in the African Grey Parrot. *Proc 2nd Eur Symp Avian Med Surg, Utrecht, 1989*, pp 39-43.
60. **Raphael BL:** Hematology and blood chemistries of macaws. *Proc Am Assoc of Zoo Vet*, 1981, pp 97-98.
61. **Roskopf WR, et al:** Pacheco's disease and aspergillosis in a parrot. *Mod Vet Pract* 63:300-301, 1982.
62. **Roskopf WR, et al:** Normal thyroid values for common pet birds. *Vet Med & Small Anim Clin* 77(3):409-412, 1982.
63. **Roskopf WJ, Woerpel RW:** Clinical experience with avian laboratory diagnostics. *Vet Clin No Am* 14:2, 1984.
- 63a. **Schultz DJ, Rich BG:** Gastrointestinal diseases. In Burr EW (ed): *Companion Bird Medicine*. Ames, Iowa State University Press, 1987, pp 80-86.
64. **Schöpf A, Vasicek L:** Blood chemistry in canary finches (*Serinus canaria*). *Proc Conf Europ Comm Assoc Avian Vet, Vienna, 1991*, pp 437-439.
65. **Solberg HE:** Establishment and use of reference values. In Tietz NW(ed): *Textbook of clinical chemistry*, Philadelphia, WB Saunders Co, pp 356-386, 1986.
66. **Sturkie PD:** Avian Physiology 2nd ed. Auflage, Ithaca, New York. S 624-625, 1982.
67. **Tell LA, Cifino SB:** Hematologic and serum chemistry reference intervals for Cuban Amazon Parrots (*Amazona leucocephala leucocephala*). *J Zoo & Wildlife Med* 23(1):65-71, 1992.
68. **Tietz NW:** *Textbook of Clinical Chemistry*. Philadelphia, WB Saunders Co, 1986.
69. **Torres-Medina A, Rhodes MB, Mussman HC:** Chicken serum proteins: A comparison of electrophoretic techniques and localisation of transferrin. *Poult Sci* 50:1115-1121, 1971.
70. **Olsen GH, Holmes RA:** Indocyanine green as an indicator of liver function in raptors. *Assoc Avian Vet Newsletter* 7:60-61, 1986.
71. **Phalen DN:** The avian urinary system: Form, function, diseases. *Proc Assoc Avian Vet*, 1990, pp 44-57.
72. **Quesenberry K, Moroff S:** Plasma electrophoresis in psittacine birds. *Proc Assoc Avian Vet*, 1991, pp 112-117.
73. **Woerpel WR, Roskopf W:** Clinical experiences with avian laboratory diagnostics. *Vet Clin No Amer* 14(2):249-266, 1984.
74. **Worell A:** Serum iron levels in Rhamphastids. *Proc Assoc Avian Vet*, pp 120-130, 1991.
75. **Worrell A:** Further investigations in Rhamphastids concerning hemochromatosis. *Proc Assoc Avian Vet*, 1993, pp 98-107.

CHAPTER

# 12

## IMAGING TECHNIQUES

■  
Marjorie C. McMillan

**W**ith advancing technology, diagnostic imaging techniques available for avian patients now include ultrasound, fluoroscopy, computer tomography (CT) and nuclear scintigraphy; however, routine radiography remains the most frequently performed imaging modality in birds and frequently is diagnostic without the need for more sophisticated procedures. Information obtained from radiographs will frequently complement results from other testing methods, providing for a more thorough evaluation of a disease process.

Both risk and benefit to the patient should be considered when radiography is used as a screening procedure in an apparently normal companion bird. In general, radiography should be performed only when indicated by historical information, physical examination findings and laboratory data. Indiscriminate radiographic studies create an unnecessary risk to the patient and technical staff.

Radiographic findings should always be correlated with surgical, endoscopic or necropsy findings. These comparisons will refine a clinician's ability to detect subtle radiographic changes, and improve diagnostic capabilities and therapeutic results.

## Technical Considerations

The size (mainly thickness), composition (air, soft tissue and bone) and ability to arrest motion are the primary factors that influence radiographic technique. Although the skeleton is easy to visualize, specific soft tissue structures within the coelomic cavity may be difficult to differentiate, especially in smaller birds. Interpretation of the radiographs may be complicated by the blending of soft tissue structures caused by the compact viscera, rudimentary mesenteric attachments and minimal fat. Even in obese birds, contrast of the coelomic cavity is minimally improved, suggesting that, radiographically, the opacity of avian fat is similar to that of soft tissue. In the absence of pathology, the air sacs provide negative contrast throughout the thorax and abdomen that can help in differentiating structures.

Multiple factors influence the quality of a radiographic image. In radiographing the avian patient, the goal is to produce a properly positioned, detailed study with a long scale of contrast, minimal motion and the least exposure of the patient and technical personnel to radiation. In general, the image quality is controlled by:

- the production of the image—influenced by radiographic equipment, technical settings (kVp, mA and time), focal-film distance, part-film distance, focal spot size and collimation;
- the recording of the image—influenced by the type of film, cassette and screen combination; and
- the development of the image—influenced by the darkroom environment and type of processing equipment.

Attention to quality in all aspects of obtaining a radiograph will result in consistent, high quality radiographs with reduced repeat rates, increased efficiency, less patient stress, reduced radiation exposure and economic savings. A quality control program that encompasses all the factors contributing to the radiographic image is beyond the scope of this chapter and appropriate references should be reviewed.<sup>3,5,25</sup>

Radiographic detail depends on sharpness of the image and radiographic contrast. Sharpness, the ability to define an edge, is compromised by motion, uneven film-screen contact and a large focal spot. Radio-

graphic contrast is controlled by subject contrast, scatter, and film contrast and fog. Detail is improved by using a small focal spot, the shortest possible exposure time (usually 0.015 seconds), adequate focus-film distance (40 inches), a collimated beam, single emulsion film and a rare earth, high-detail screen. The contact between the radiographic cassette and the patient should be even, and the area of interest should be as close as possible to the film.

There is increasing discussion of the use of mammography machines for imaging avian patients. While these machines do produce excellent quality images with extremely refined detail, the clinician should be aware that imaging requires exposure to high levels of radiation in comparison to standard radiographs. In general, mammography machines can be considered to deliver low-dose radiation therapy (levels of radiation that cause tissue destruction), and the long-term effect of exposing the body of a bird to this level of radiation is undetermined.


### Radiographic Technique

The specific technical factors needed to obtain a high quality radiograph will vary with the type of radiographic equipment, film-screen combinations and various settings used for specific purposes. A technique chart for the various species can be developed.<sup>28</sup> As a general rule, the clinician should choose the lowest kV, a high mA and a short exposure time.<sup>7</sup> Usually, non-bucky techniques applicable for radiography of cats provide reasonable radiographic settings for medium to large psittacine birds.<sup>5</sup>

In circumstances where single emulsion, rare earth, high-detail systems are used, kVp ranging from 60 to 75 at five mAs (300mA, 1/60th of a second) usually provides an appropriate scale of contrast and eliminates motion. In small Passeriformes, such as canaries and finches, reducing the focal-film distance by one-fourth (to 30 inches) and decreasing the mAs by one-half may improve the radiographic image. Decreasing the focal-film distance can result in loss of detail due to magnification; however, with small patients, a shorter focal-film distance does not seem to compromise the radiographic image.

Although the single-emulsion film and single screen, rare earth systems result in greater detail, they do require increased exposure when compared to double emulsion film-cassette combinations. Low-absorption cassette fronts may provide comparable detailed studies with less radiation exposure.<sup>29</sup>

It is important to radiation safety to maintain an adequate distance from the source of radiation by using techniques that do not require personnel to restrain the patient during a radiographic study. If hospital personnel must be present during an exposure, they should wear a lead apron, lead gloves, thyroid shield, protective glasses and a film badge. No portion of a person's body should be in the primary beam, even if covered by lead. With practice, restraining methods can be developed so only the patient is exposed to radiation.



**FIG 12.0** A plexiglass restraint board can be used for positioning anesthetized or unanesthetized birds for radiographs. An anesthetized bird is shown in the proper position for a VD radiograph.

### Restraint and Positioning

Poor positioning is the most frequently encountered factor that compromises a radiographic study and hampers interpretation of subtle lesions. Some birds can be adequately restrained for routine views with mechanical plexiglass devices and positioning aids such as sandbags, foam blocks, lead gloves, velcro, pipe cleaners and plastic and paper tape.<sup>10,18</sup> Other patients will require isoflurane anesthesia to obtain the most diagnostic radiographs; however, it should be noted that anesthesia or chemical restraint for radiographic examination will decrease normal gastrointestinal motility and as such is generally contraindicated in studies to evaluate the function of this organ system. Anesthesia should be considered mandatory when radiographing strong, powerful birds or patients that are fractious, highly stressed, experiencing significant respiratory distress or those that have an injury that may be exacerbated by struggling. If anesthesia is required, appropriate evaluation of the patient prior to anesthesia is indicated (see Chapter 39). With experience, a complete set of diagnostic, high quality radiographs can be obtained in an anesthetized bird in less than five minutes.

If heavy metal intoxication is suspected in a critically ill bird, a quick radiographic screening for metal densities can be obtained by placing the bird in a bag and taking a DV radiograph. A horizontal beam radiograph can also be taken through the bag to provide a lateral view. This technique is useful only to demonstrate radiographically detectable metal particles (Harrison GJ, unpublished).

The most frequently performed radiographic studies in companion birds are ventrodorsal (VD) and left-to-right lateral (LeRtL) whole body projections. To use a plexiglass restraint board, the neck of the bird just below the angle of the mandible is secured in the stock-like, contoured portion of a restrainer while the body is still wrapped in a towel. For the VD view, the head is restrained and the wings are extended 90 degrees from the body and secured with sandbags, velcro straps or tape. The wings should be restrained close to the body to prevent iatrogenic fractures. The legs are pulled caudally and parallel to the body and secured at the tarsometatarsus with tape or velcro straps (Figure 12.0).

For the LeRtL view, the wing and leg restraints are loosened while the head and body are rotated into right lateral recumbency. The dependent wing is extended 90 degrees to the body and secured. A foam block or other soft material is placed between the wings, and the left wing is extended and restrained slightly caudally to the right. Placing a block of foam between the wings helps to prevent overextension and potential injury. Both legs are extended caudally with slight tension and secured individually at the tarsometatarsus. The dependent leg is positioned slightly cranially. Securing the legs individually helps to reduce rotation of the body, which is common if the legs are fastened together. The beam should be collimated to the patient size to reduce scatter, and radiopaque right or left markers should be appropriately positioned.

In a symmetrically positioned VD view, the spine and sternum will be superimposed, and the scapulae, acetabula and femurs will be parallel (Figure 12.1).

In LeRtL projection, the ribs, coracoid, acetabula and kidneys will be superimposed, if the positioning is accurate (Figure 12.3).

While in the VD position, collimation may be used to obtain radiographs of the pelvis, craniocaudal projection of the legs and mediolateral view of the wings (Figure 12.9, 12.10). The orthogonal view of the wing in the caudocranial projection requires horizontal beam radiography. In the lateral position, views of the pelvis, spine and legs can be achieved (Figure 12.11, 12.12).

Radiography of the skull requires general anesthesia to ensure accurate positioning and to minimize motion. Complete evaluation of the skull requires LeRtL, RtLeL, VD, dorsoventral (DV) and rostrocaudal (RCd, frontal sinus) views (Figure 12.5 to 12.8). In evaluating skull trauma, left and right 75° ventrodorsal oblique views are recommended.<sup>7</sup>

## Radiographic Interpretation

If radiographic films are manually processed, an initial assessment of positioning and technique can be made during a “wet” reading; however, final interpretation should be reserved until the film is completely dry. The environment in which interpretation occurs is important. A dimly lighted area with minimal disturbance and an evenly illuminated viewing box at eye level improves viewing conditions. Personal preference determines whether an organ-by-organ approach or concentric circle system is used to evaluate the radiograph. Whichever method is chosen, it is important that the entire radiograph is studied, and that the observer does not just focus on the lesion. Minifying and magnifying lenses may improve interpretation by enhancing detail or magnifying structures, especially in smaller avian patients. It is advantageous to use a standardized form when recording radiographic findings.

### Neonatal Radiography

Stress should be minimized when radiographing neonatal birds. The surface of the cassette should be warmed with a towel to avoid placing a young bird on a cold surface. Paper tape should be used for restraint to avoid damage to the numerous blood feath-

ers. In some circumstances, proper positioning may be sacrificed in the best interest of the patient. Pressure must not be placed on a full crop to prevent regurgitation and subsequent aspiration.

The abdomen of neonates appears pendulous because the gastrointestinal tract is dilated, fluid-filled and blends with the other soft tissue organs (see Figure 30.7). This results in a homogenous appearance to the coelomic cavity. The air sacs are relatively indistinguishable. The skeleton is incompletely mineralized and will have a reduced density, and fractures may be difficult to detect (Figure 12.76).

## Musculoskeletal System

### Radiographic Anatomy

The cranium of birds contains numerous connections to the sinuses, which are reflected radiographically. The osseous scleral ring is clearly visible radiographically, while the interorbital septum that lies between the eyes is barely visible (Figures 12.5, 12.6).

The articulation between the clavicle and sternum in birds is membranous rather than bony. The distal ends of the clavicle are fused, forming the furcula (wishbone) (Figures 12.1 to 12.4). The coracoid articulates with the cranial portion of the sternum and the shoulder joint. Only the radial and ulnar carpal bones are present. The distal carpal bones are fused with each other and with the proximal ends of the metacarpal bones. This area is referred to as the carpometacarpus. The digits are traditionally numbered I (alular), II (major) and III (minor). Developed feathers are hollow, and the rachis will have an air density center. Developing feathers contain blood to the level of the pulp cavity and will appear as soft tissue densities (Figure 12.9).

The spine is separated into cervical, thoracic, synsacral (fused thoracic, lumbar, sacral and caudal), free-caudal and fused caudal (pygostyle) sections. The number of cervical vertebrae varies with the species (budgerigars = 11, Amazon parrots = 12). In Galliformes, the last cervical vertebra is fused to the first three thoracic vertebrae. The number of thoracic vertebrae varies from three to ten depending on the species.

Ribs are present on the cervical and thoracic vertebrae. The cervical ribs have short, ventrally oriented spines that are fused to the cervical vertebrae. The thoracic ribs are complete (number varies with the species) and are divided into two portions; the dorsal

portion articulates with the vertebra and the ventral portion articulates with the sternum (Figure 12.1). It should be noted that not all ribs have a sternal portion. The sternal rib is equivalent to the mammalian costal cartilage. Uncinate processes that anchor the caudal edge of several vertebral ribs to the cranial edge of the subsequent rib may be present on some ribs (see Anatomy Overlay).

There are 10 to 23 synsacral vertebrae and 5 to 8 free caudal vertebrae. The ilium and ischium are fused and are also fused to the synsacrum. The pubic bones are long, thin and unfused (except in ratites), presumably as an adaptation for egg laying (Figure 12.1).

No separate tarsal bones occur. The proximal tarsal bones are fused with the tibia; this structure is termed the tibiotarsus. The digital tarsal bones are fused with the metatarsal bones resulting in a tarsometatarsus. In parrots, each digit has one more phalange than the number of the digit. For example, digit III is composed of four phalanges (Figures 12.11, 12.12).

Various portions of the skeletal system may be perfused by air sacs in some avian species. The cervical vertebrae may be perfused by the cervical air sac; the thoracic vertebrae, ribs and humerus may be perfused by the interclavicular air sac; and the synsacrum and femur may be perfused by the abdominal air sacs (see Anatomy Overlay).

Avian long bones are characterized by thin cortices. The ossification of long bones is different in birds than in mammals, which should not be misinterpreted as pathology (see Chapter 42).

### Radiographic Evidence of Skeletal Disorders

Categorizing abnormalities aids in reducing the differential diagnoses and allows some judgement as to the aggressiveness and chronicity of a lesion.<sup>15,24</sup>

The species and age of a bird influence the type of musculoskeletal pathology that will be encountered. In companion birds, bone changes associated with metabolic bone disease and pathologic fractures are more common than traumatic injury or infection. Congenital bone abnormalities are uncommon; however, developmental changes associated with poor husbandry and improper nutrition occur frequently. Hypovitaminosis D<sub>3</sub> and calcium and phosphorus imbalances result in changes in the size, shape and length of bones that are characterized by generalized osteopenia and folding fractures secondary to osteomalacia (see Figure 31.10).

Valgus deformity of the tibiotarsi (bow leg), kyphosis, scoliosis, lordosis and sternal compression may occur secondary to osteomalacia (see Figure 33.8). If the spinal or sternal abnormalities are severe, compromise of the thoracic cavity may occur that causes displacement of the heart and respiratory distress. "Splay leg" may be complicated by osteomalacia as well as contracture of tendons and muscles, causing clenching of the feet and rotation at the stifle joint. Hypervitaminosis D<sub>3</sub> can cause diffuse metastatic mineralization within soft tissues, particularly the kidneys (see Figure 21.3).<sup>7</sup>

Skeletal trauma may result in fractures, sprain injuries and concussions (see Chapter 16). Luxations are infrequent and usually involve the digits, stifle or coxofemoral joint, and often occur due to dangling from leg bands, inappropriate toys and unsafe enclosures (Figure 12.78). The important considerations in the radiographic evaluation of fractures include location, articular involvement, bone density, periosteal reaction, soft tissue involvement and whether the fracture is simple or comminuted and open or closed (see Chapter 42).

In companion birds, head trauma most often results in concussion and soft tissue injury. In birds, fractures of the cranium are infrequently discussed, possibly because of the necessity of taking multiple radiographic views to delineate between normally superimposed structures of the head and fracture lines. Detection of non-displaced fractures generally requires a CT scan. Fractures of the jugal arch, pterygoid bone and displacement of the quadrate bone have been reported (Figure 12.37).<sup>18</sup> Penetrating skull injuries occur in big bird-little bird encounters and cat attacks.

Fractures of the cervical spine are infrequent, but may be incorrectly diagnosed due to the normal sigmoid curve in this region. Accurate radiographs of the cervical spine require extension of the head and

### CLINICAL APPLICATIONS

A general approach to interpretation of skeletal disorders includes the evaluation of:

- Change in bone density (osteopenia or osteosclerosis)
- Distribution of lesions (diffuse, monostotic or polyostotic)
- Architecture of the bone (cortical changes, disruption in continuity, size and shape, trabecular pattern)
- Periosteal change (smooth or coarse, lamellar or irregular)
- Margination (sharp, well-defined or poorly defined)
- Soft tissue changes

neck without rotation of the skull or body. When vertebral fractures occur, they are often located in the caudal thoracic region or the synsacrum.<sup>7</sup>

Diaphyseal fractures of the extremities are the most common traumatic injury. Acute fractures are characterized by sharp, well-defined margins, absence of periosteal response and concurrent soft tissue swelling (see Figure 16.15). Chronic fractures are characterized by rounding, flaring and indistinct fracture ends, periosteal change and minimal soft tissue involvement or atrophy. Fracture repair depends on the bone involved, location, type of fracture and chronicity. Avian fractures heal in a manner similar to that described for mammals, except the endosteal component is more pronounced.<sup>2</sup> Healing is usually complete within three to eight weeks. Lack of visualization of the fracture lines and smooth, well-defined callus bridging all cortices indicate complete healing (see Figure 42.2).

Osteolysis is the predominant radiographic change with infectious or neoplastic processes, and differentiation between these etiologies will require biopsy (see Figure 25.8). Osteomyelitis and septic arthritis may occur secondary to open fractures, penetrating wounds, iatrogenic contamination, hematogenous sources, extension from air sac disease or pododermatitis. Acute infection may show bone destruction with minimal periosteal reaction. Periosteal change is usually present with chronic infections (see Figure 33.7).

Fungal osteomyelitis may cause pronounced periosteal reaction or increased medullary opacity due to granuloma formation. *Mycobacterium* spp. may also cause medullary granulomas as well as septic arthritis and bone lysis. Infection is most common in the extremities, and vertebral osteomyelitis is rare. Osteomyelitis in the calvarium is usually due to extension from chronic rhinitis, sinusitis or periorbital lesions, and aspergillosis and mycobacteriosis may be involved. When infection occurs in association with fractures, there is often delayed union, and chronicity is characterized by regions of sclerosis and lysis. Fragments of increased density suggest compromised vascular supply and potential sequestra formation.

With acute septic arthritis, joint effusion due to synovitis may be the only radiographic change, and arthrocentesis is necessary for diagnosis (Figure 12.77). Bacteria, mycoplasma, mycobacteria and parasites may be causative agents. As an infection progresses,

destruction of articular cartilage results in loss of joint space, and osteolysis and periosteal changes may occur in the epiphysis and metaphysis. Distal joints are most commonly affected, especially when the infection is secondary to septic pododermatitis. Occasionally, luxation of the affected joint may occur. Effusion and diminished joint space may occur also with degenerative joint disease, but they are usually accompanied by chronic changes such as periarticular lipping, sclerosis of subchondral bone and osteophytes (see Figure 42.11).

Primary bone neoplasia such as osteosarcoma is uncommon but has been reported in the proximal humerus, maxilla and wing tips. Bone neoplasia is frequently characterized by osteolysis with minimal periosteal change; however, osteoblastic tumors with marked periosteal reaction do occur. Most tumors involving bone occur secondary to soft tissue neoplasia (see Figure 25.2). These tumors are frequently associated with soft tissue swelling, bone destruction and pathologic fractures, and biopsies are necessary to differentiate between tumors and osteomyelitis. Metastatic bone lesions are rare.

Normal pre-ovulatory hens will have an increased medullary bone density (polyostotic hyperostosis). Prolonged, abnormally elevated estrogen levels cause a diffuse, increased medullary bone density.<sup>14</sup> The bones have a “marble” or mottled appearance, depending on whether bone deposition is uniform or patchy (Figure 12.65). Discrete, nodular regions of bone resembling osteomas occasionally occur on the ribs, vertebrae or pubic bones. Polyostotic hyperostosis has also been reported in hens with oviductal tumors and in cocks with sertoli cell tumors.<sup>21,23</sup>

Hypertrophic osteopathy is rare, but has been reported in association with pericardial effusion.<sup>4</sup> Radiographic lesions were characterized by extensive, fine, brush-like periosteal reaction involving most of the long bones. In other species, hypertrophic osteopathy is associated with pulmonary disease and neoplasia involving the lungs, bladder or liver.

## ■ Cardiovascular System

### Radiographic Anatomy

In general, the base of the heart is angled craniodorsally and lies at the second rib. The apex is directed in a caudoventral direction and lies between the fifth and sixth ribs (varies with species) (Figure 12.1 to 12.4, 12.15, 12.16). The size and shape of the cardiac

silhouette will vary with the phase of respiration, cardiac cycle and species.

In mammals, various formulas for measuring the cardiac size from radiographs have proved inaccurate, and currently echocardiography is the most reliable method for assessing cardiac size and function. In the VD view of a normal Amazon parrot, the cardiac silhouette as measured across the heart base at the level of the atria is about 50% of the width of the coelomic cavity measured at the fifth thoracic vertebra (Figure 12.1). The lateral margins of a normal heart and liver in psittacine birds create an hourglass shape (Figure 12.1). In macaws, there is normally a ventrally directed kink between the heart and liver in the lateral view (Figure 12.35).

### Radiographic Evidence of Cardiac Disease

Primary cardiac disease is rare, although congenital defects are occasionally detected on postmortem examination. Congenital and viral diseases should be considered in juvenile birds with cardiac murmurs, exercise intolerance and cardiomegaly. The latter is usually accompanied by other systemic changes. Secondary cardiac disease is more common. Pericardial effusion is recognized radiographically as a symmetrical, globoid enlargement of the cardiac silhouette and may occur in birds with chlamydiosis, polyomavirus, tuberculosis and neoplasia (Figure 12.63).

With cardiomegaly, heart enlargement is usually asymmetrical. Cardiomegaly may be caused by cardiomyopathy secondary to poxvirus (reported in macaws<sup>12</sup>), myxomatous valvular degeneration, endocarditis (particularly secondary to pododermatitis), hemochromatosis, chronic anemia and compression from extrinsic masses (see Chapter 27). Elongation of the heart shadow, loss of the caudal and cranial waists, loss of indentation at the junction between the heart and liver lobes and an increase in transatrial dimensions indicate an increase in cardiac size.

Microcardia is associated with hypovolemia due to acute volume loss or endotoxic shock (see Figure 21.2). There is retraction of the heart from between the liver lobes, a more angular appearance to the cardiac shape and decreased transatrial size. Whatever the etiology, microcardia suggests a critical state, and appropriate volume replacement should be instituted immediately.

Atherosclerosis with mineralization will result in prominence of the great vessels and may cause an increased density of the caudal lung field. Although seen most often in older birds on high-fat diets, se-

TABLE 12.1 Radiographic Lesions of the Respiratory System

Differential Diagnosis	Radiographic Interpretation
Parabronchial infiltrates	Blotchy pulmonary pattern
Caseous exudate, hemorrhages or edema	Non-distinguishable parabronchi
Tumor, fungal granuloma or abscess	Abnormal pulmonary pattern (anatomy)
Air sac disease	Fixed full inspiration, barrel shape to cranial body cavity
Bacterial and fungal infection, hypovitaminosis A	Consolidating air sacculitis
Trauma, infraorbital sinus infection	Subcutaneous emphysema
Abscess or granuloma	Pulmonary masses

vere vascular changes may occur in young birds. Acute myocardial infarcts, syncope and seizures (perhaps due to hypoxemia) have been described in birds with atherosclerosis in the absence of radiographic lesions.

## Respiratory System

### Radiographic Anatomy

The radiographic changes associated with respiratory disease are often subtle, and high quality radiographs are necessary to detect these lesions (Table 12.1). The trachea in toucans and mynah birds deviates ventrally at the level of the thoracic inlet (see Figure 47.3). Radiographically, the normal syrinx is difficult to visualize but lies between the second and third thoracic vertebrae in most birds (Figure 12.3). The heart covers much of the lung field in the VD view and only the caudal edge of the lungs can be visualized (Figure 12.35). In normal birds, the borders of the air sacs cannot be distinguished.

Lung parenchyma appears as a honeycombed structure with the majority of the air densities representing an end-on view of parabronchi (Figure 12.35). The bronchioles can be visualized as transverse, indistinct, linear structures on the ventrodorsal radiograph. Air bronchograms and atelectasis, which occur in mammals with pulmonary disease, do not occur in birds because of their unique lung anatomy (a network of inter-connecting tubules with the lungs adhered to the thoracic wall).<sup>12</sup> Bacterial or fungal infections are the most common cause of pathologic abnormalities involving the respiratory tract. Chronic nasal discharge, periorbital swelling and soft tissue masses are indications for radiographs of the nasal cavity and infraorbital sinus.



### Radiographic Evidence of Respiratory Disorders

Hypovitaminosis A may cause an accumulation of caseous exudate that appears as a soft tissue opacity within the sinus without bone destruction. Soft tissue swelling with osteolysis of the calvarium is often associated with osteomyelitis due to aspergillosis or mycobacteriosis. Air-filled swellings from distention of the cervicocephalic air sacs may be caused by infection, granulomas or idiopathic obstruction and should be differentiated from subcutaneous emphysema, which is more diffuse.<sup>27</sup>

Changes in tracheal diameter may be caused by intrinsic or extrinsic masses, stricture or stenosis. Intraluminal soft tissue masses or undulating soft tissue plaques may be caused by bacteria, hypovitaminosis A, parasites, fungi, foreign body or neoplasm. A solitary mass in the syrinx may cause severe obstructive, open-mouthed dyspnea with no obvious radiographic changes. Superimposition of the great vessels, ribs and soft tissue over the syrinx compromises interpretation. A subtle increase in soft tissue in this region or fluid accumulation in the distal trachea suggests obstruction. Although contrast tracheography may help delineate some masses, tracheoscopy is less stressful to the patient and more definitive (Figure 12.47).

Soft tissue surrounding the distal trachea is usually apparent. Tracheal strictures secondary to trauma from fight-induced injuries or cuffed endotracheal tubes occasionally occur. Tracheal stenosis and deformity of the tracheal rings are uncommon. Peritracheal masses may occur in the thoracic inlet due to thyroid enlargement secondary to goiter or neoplasm (Figure 12.45). Thyroid masses are usually well defined with smooth margins. *Aspergillus* sp. granuloma encasement of the syrinx often causes a hoarseness in vocalization and slow, progressive respiratory distress (Figure 12.46).

With pulmonary disease, the normal honeycombed pulmonary parenchyma may be enhanced by parabronchial infiltration causing prominent ring shadows obliterated by filling of the parabronchial lumen with fluid or caseous exudate or replaced by neoplastic or granulomatous infiltrates (see Table 12.1). Pneumonia often causes a prominent parabronchial pattern in the hilum and mid-portion of the lungs (Figure 12.47). As pneumonia progresses, the air-filled parabronchial lumen is replaced with caseous exudate, causing a blotchy mottled appearance to the lungs. This change is common at the caudal aspects of the lungs and is best detected on VD radiographs.

Pulmonary edema and hemorrhage have a more diffuse appearance (Figure 12.50). Discrete, well defined masses are usually abscesses, granulomas or tumors (Figure 12.49).

The size of the air sacs will vary between inspiration (increased) and expiration (decreased). Additionally, the lung architecture will be more apparent on inspiration. Air sac disease may cause a barrel-shaped appearance to the thorax (Figure 12.51). Consolidated or thickened air sacs are not as compliant as normal air sacs, causing the inspired air to be deposited in a relatively fixed cavity.

Radiographic changes indicative of inflamed air sacs include diffuse thickening, nodular infiltration or consolidation. Fine lines across the air sacs with mild increased opacity indicate thickening and are best detected on the lateral radiograph (Figure 12.52). The loss of visualization of abdominal viscera, blending of the air sacs, blending of the interfaces between air and soft tissue and a hazy heterogeneous appearance to the air sacs are suggestive of consolidation (Figures 12.53, 12.54). Hyperinflation of the air sacs in combination with a radiolucent appearance suggest air trapping due to obstructed flow or abnormal compliance.

Subcutaneous emphysema may result from traumatic rupture of an air sac or as a complication of endoscopy (see Chapter 22). Fractures of the coracoid or ribs may penetrate the air sacs, causing emphysema.

## Coelomic Cavity and Gastrointestinal System

### Radiographic Anatomy

The crop is present in the right lateral thoracic inlet area on the VD view. It may extend to varying degrees across the midline depending on the presence of ingesta and the species of bird (Figure 12.71, 12.74). The thoracic portion of the esophagus can usually be differentiated on the VD and lateral radiographs. The cervical portion of the esophagus cannot be distinguished without contrast media.

The proventriculus lies dorsal to the liver on the lateral view (Figure 12.35). The left lateral border of the proventriculus may be difficult to distinguish from the left lateral edge of the liver on the VD view. If the liver is of normal size, the proventriculus shadow will lie slightly lateral to the liver on the VD view. If the ventriculus contains radiodense material, it can generally be viewed on both the VD and lateral

radiographs in its normal location, caudal and ventral to the proventriculus.

The position of the intestinal tract is widely variable but it generally occupies the caudal, dorsal abdominal cavity (Figure 12.72). The cloaca may or may not be visualized, depending on its contents. The summation between the liver and proventriculus on the VD view should not be misinterpreted as pathology (Figure 12.35). The duodenal loops lie to the right of the ventriculus in the VD view (Figure 12.72).

### Spleen

If detectable on the VD radiograph, the spleen will be noted as a slightly oblong, rounded structure to the right of midline between the proventriculus and ventriculus. On the lateral view, the spleen, if visible, overlaps the caudal end of the proventriculus and may be slightly dorsal to it (Figure 12.35). Suggested normal spleen sizes include: budgerigar = 1 mm, African Grey Parrot or Amazon parrot = 6 mm, Umbrella Cockatoo = 8 mm. The spleen of a pigeon is elongated or bean-shaped. In many other species it is spherical. Splenomegaly may be caused by infectious, neoplastic or metabolic diseases (Figure 12.62), (Table 12.2).

### Liver

The liver does not normally extend beyond the sternum on the lateral radiograph (Figure 12.35). In psittacine birds, the liver should not extend laterally past a line drawn from the coracoid to the acetabulum. The size of the hepatic silhouette can best be determined by making measurements of a VD radiograph taken on inspiration. The distance is measured in millimeters from the mid-sternum to the lateral-most aspect of the ribs at the base of the heart. This measurement is referred to as the sternal/rib distance (SR). This distance is divided by one-half and should be equal to the width of the right liver as measured at the base of the heart. The size of the right liver is determined by measuring from the mid-sternum to the edge of the liver at the base of the heart. If the actual measurement of the liver is greater than its anticipated size as determined by the SR value, then the liver is considered enlarged. If the actual measurement of the right liver is less than its anticipated size as determined by the SR value, then the liver is considered to be reduced in size (Harrison GJ, unpublished).

The liver in macaws and cockatoos frequently appears to be reduced in size (Figure 12.58). The importance of this finding remains undetermined; how-

TABLE 12.2 Differential Diagnosis for Hepatomegaly, Splenomegaly and Nephromegaly

Hepatomegaly	Etiologies
Infectious	Chlamydial, viral (eg, Pacheco's disease virus, reovirus, polyomavirus), bacterial, mycobacterial and fungal
Neoplastic	Primary (biliary adenocarcinoma, hepatocellular carcinoma, fibrosarcoma, hemangiosarcoma, hepatoma and lymphoma) and Metastatic (adenocarcinoma, fibrosarcoma and melanoma)
Parasitic	Toxoplasmosis (mynahs), <i>Sarcocystis</i> sp., flukes (cockatoos) and <i>Plasmodium</i> sp.
Metabolic	Lipidosis, fatty degeneration, hemochromatosis (mynahs and toucans) and gout
Splenomegaly	Etiologies
Infectious	Chlamydial, viral, bacterial and mycobacterial
Neoplastic	Lymphoma, hemangiosarcoma, fibrosarcoma and leiomyosarcoma
Metabolic	Lipidosis and hemochromatosis
Nephromegaly	Etiologies
Infectious	Bacterial, chlamydial
Neoplastic	Adenocarcinoma, embryonal nephroma
Metabolic	Dehydration, lipidosis, gout
Cystic	Occluded ureters, congenital
Toxic	Heavy metals

(modified from McMillan<sup>13</sup>)

ever, many birds with microhepatia are being fed seed diets that may or may not be supplemented with fruits and vegetables. Many affected birds have abnormally low populations of gram-negative bacteria, low bile acids levels and elevated LDH, AST and GGT activities. The CPK may be normal or elevated (Harrison GJ, unpublished). The pesticide residues that are present in most commercially available foods may play a role in the high incidence of hepatopathies in companion birds and should be addressed in birds with microhepatia. In obese pigeons, the liver will appear enlarged, which will resolve when the birds are fasted.

The liver is frequently involved in systemic disease, and hepatomegaly is a common radiographic finding. Symmetrical enlargement of the liver lobes is most common and is usually associated with infectious and metabolic processes (Table 12.2). Neoplasms and granulomatous diseases can cause asymmetrical enlargement of the liver.

Radiographic changes associated with liver enlargement are loss of hourglass waist in the VD view, rounding of liver lobe margins, compression of abdominal air sacs, extension of the liver lobes beyond the scapula/coracoid line, cranial displacement of the

heart, dorsal elevation of the proventriculus and caudodorsal displacement of the ventriculus (Figure 12.1, 12.60).<sup>13</sup> A dilated, fluid-filled proventriculus may appear radiographically similar to hepatomegaly, and a careful assessment of the VD view can be used to differentiate between these lesions.

### Pancreas

Radiographic changes involving the pancreas are rare, although diminished contrast in the right cranial abdomen due to sanguineous exudate from acute necrotizing pancreatitis has been reported. Pancreatic masses are uncommon; however, space-occupying lesions in the right cranioventral abdomen may involve the pancreas, and large pancreatic cysts do occur.

### Gastrointestinal Tract

The specific areas of the gastrointestinal tract are best visualized through barium contrast examination. The presence of gas, change in position and abnormal distention suggest a disease process. Altered gastrointestinal motility causing uniform or segmental dilatation can be due to functional or mechanical ileus.

Birds do not normally have gas in the intestinal tract, and any gas should be considered abnormal. Aerophagia can occur secondary to severe respiratory disease or is frequently seen as an artifact of gas anesthesia (Figure 12.68). Distended, fluid-filled bowel loops should be considered abnormal except in mynah birds and toucans.

Inflammation, infection, foreign bodies, parasites, intussusception, stricture, granuloma and neoplasia may cause intraluminal obstruction and segmental increases in the diameter of the gastrointestinal tract lumen secondary to excess gas and fluid accumulation. Extraluminal masses such as neoplasm, abscesses, eggs and cysts may compress the gastrointestinal tract and cause changes similar to intraluminal obstruction.

Uniform distention of the gastrointestinal tract is most commonly associated with functional ileus due to viral or bacterial infections, toxicity (eg, heavy metals), septicemia, hypoxemia, peritonitis or anesthesia. Distention of the ingluvies, proventriculus or ventriculus may be due to a localized process or obstruction within the intestines. A barium contrast study is indicated for complete evaluation of the intestinal tract.

The cloaca may be distended from a retained soft-shelled egg, papilloma, cloacolith, neoplasm or idiopathic atonic dilatation (Figure 12.70). Atonic distension of the cloaca may occur with spinal trauma and infiltrative neoplasms involving the sacral nerves.

Abdominal masses usually cause a change in the location of the gastrointestinal tract. Hepatomegaly usually causes dorsal displacement of the proventriculus and caudodorsal displacement of the ventriculus. Splenic, testicular, ovarian and renal masses compress the gastrointestinal tract ventrally and either cranially or caudally (Figure 12.67). Adhesions due to inflammatory or septic peritonitis from ruptured eggs or perforation can also result in displacement of the gastrointestinal tract.

Abdominal effusion is associated with liver disease, neoplasia, metabolic disorders, sepsis, inflammation and cardiac failure. Fluid results in a homogeneous appearance to the intestinal peritoneal cavity (IPC) and obscures visualization of specific organs (Figure 12.67). Consolidating air sacculitis can appear radiographically similar to fluid in the IPC in the lateral view, but differentiation is possible in the VD radiograph. If a pathologic process is occurring within the air sacs, specific organs within the intestinal peritoneal cavity will be definable in the VD view. If the fluid is within the IPC, there will still be a homogeneous appearance to the region of the viscera, and the air sacs will be compressed (Figure 12.67). Fluid accumulation in the IPC may compress the liver ventrally and displace the proventriculus and ventriculus cranially.

### Urogenital System

The anatomy and physiology of the avian kidneys prevent the radiopacity that is characteristic of mammalian kidneys. The kidneys are attached to the synsacrum, are flattened dorsoventrally and have smoothly rounded cranial and caudal divisions (Figure 12.35).

The kidneys are best visualized in the lateral view. Because the renal silhouettes are superimposed, lateral oblique views may be necessary to distinguish each kidney. The cranial division of the kidney protrudes from the pelvic brim, and the caudal division may also be visualized on the lateral view. The kidneys are generally not visible on the VD view, although the rostral edge of the cranial division can occasionally be seen. If the kidneys are enlarged or

increased in opacity, they may be more readily visualized in the VD position. The length of a normal African Grey Parrot kidney is about 3 cm on the lateral view. In the Umbrella Cockatoo, the suggested normal kidney size is 3 cm x 0.7 cm. The kidneys are normally surrounded by air, and loss of the air shadow indicates renal enlargement, dorsal displacement of abdominal organs or the presence of abdominal fat or fluid (Figure 12.56).

Bilateral symmetrical nephromegaly results in a diminished abdominal air sac space surrounding the kidneys and occurs with infection, metabolic disease, dehydration, post-renal obstruction and lymphoreticular neoplasia. Dehydration may also be associated with increased renal density (see Figure 21.2). A localized enlargement with irregular borders is most commonly associated with a neoplasm, although abscesses may appear radiographically similar (Figure 12.57).

Most renal tumors are locally invasive and usually do not metastasize. A solitary mass with smooth, well defined margins is suggestive of a cyst; however, biopsy is the only definitive way to differentiate cysts, neoplasms and abscesses. Intravenous excretory urography is necessary to confirm renal disease when severe nephromegaly obliterates the air space and creates a positive silhouette sign with other viscera.

Masses involving the spleen, oviduct, testicles, ovary and intestines may occupy space in the caudodorsal abdomen and mimic renal lesions (Figure 12.62). The testes of a reproductively active male are easily distinguishable and should not be misinterpreted as renal enlargement.

Testicular abnormalities causing radiographic signs are uncommon. Occasionally tumors cause testicular enlargement, and functional sertoli cell tumors may cause polyostotic hyperostosis. Orchitis is most easily diagnosed through laparoscopy, and radiographically cannot be distinguished from physiologic hypertrophy.

In a hen, an active ovary resembling a bunch of grapes may be apparent cranial to the kidneys, and an increased soft tissue opacity in the caudodorsal abdomen just ventral to the kidneys represents the oviduct (Figure 12.64). The most common radiographically detectable abnormalities involving the female genital tract are retained eggs, cystic oviduct and egg-related peritonitis.

Mineralized eggs are easily visualized and often located in the terminal oviduct. Multiple eggs may be

present, and eggs may be free in the coelomic cavity due to reverse peristalsis or oviductal rupture. Soft-shelled eggs are difficult to differentiate from other abdominal masses, and ultrasound may aid in the diagnosis (Figure 12.66).

Hyperestrogen syndrome is common in budgerigars and is characterized by an enlarged, distended oviduct, medullary hyperostosis, diminished abdominal detail, visceral displacement, abnormal attempts at egg formation and abdominal hernia (Figure 12.65).<sup>14</sup> Egg-related peritonitis can be difficult to discern from other causes of abdominal effusion. Cessation of egg laying, weight loss and abdominal distention in a hen with a history of chronic egg laying are suggestive of egg-related peritonitis. Abdominocentesis and ultrasound can be used to differentiate between causes of abdominal fluid (Figure 12.67).

## Contrast Procedures

Administration of contrast agents can be used to enhance visualization of intraluminal abnormalities involving the gastrointestinal tract, respiratory system, cardiovascular system and subarachnoid space, and provides a qualitative assessment of function. Contrast agents used in mammals are considered safe in birds, although limited studies have been performed to assess specific contrast media reactions.<sup>6,14</sup>

The presence of concurrent disease and a patient's age, size and state of hydration should all be considered prior to initiating a contrast study. Severely debilitated and seriously ill birds should be stabilized and any fluid and electrolyte imbalances corrected prior to the study. Contrast studies are often stressful because of the number of radiographs required, and sedation is contraindicated in studies involving the gastrointestinal tract because of its effect on gastrointestinal motility. If anesthesia is used, it will slow the passage of contrast media, which should not be misinterpreted as a pathologically induced decrease in transient time.

### Gastrointestinal Positive and Double Contrast Procedures

Gastrointestinal studies are the most frequently performed contrast procedures in birds. They are useful in delineating the position, structure and function of the gastrointestinal tract and associated organs.

Indications for barium follow-through examination are acute or chronic vomiting or diarrhea that is nonresponsive to treatment, abnormal survey radiographic findings suggestive of an obstructive pattern, unexplained organ displacement, loss of abdominal detail suggesting perforation, hemorrhagic diarrhea, history of ingestion of foreign material and chronic unexplained weight loss.<sup>11</sup> Dehydrated birds should be rehydrated before administration of contrast media to prevent the material from forming concretions within the gastrointestinal tract.

Gastrointestinal motility may be altered by pathological conditions, stress and medications. Any drugs that may alter motility such as tranquilizers, anesthetics and anticholinergics should be discontinued for twenty-four hours prior to the gastrointestinal contrast study. The age, size, diet and condition of the patient will all affect gastrointestinal transient time. Faster transient times occur in small birds on soft diets. Passage is slowed in large seed-eating birds, obese birds, in neonates on soft diets and in anesthetized birds.

Obtaining survey radiographs prior to beginning a procedure will ensure proper technique as well as provide a method of re-evaluating any changes in the radiographic pattern that may influence the study. The best contrast study can be performed when the gastrointestinal tract is empty. Excess fluid in the ingluvies should be removed with a gavage tube prior to the administration of contrast media. The presence of ingesta or fluid interferes with the quality of the study and may obscure lesions. Usually, a four-hour fast is adequate for emptying of the gastrointestinal tract without placing undue stress on smaller avian species. The gastrointestinal tract may be empty at the time of presentation in birds that are regurgitating.

Commercial barium sulfate suspensions provide the best studies. Chemical grade barium is difficult to mix properly and may flocculate. If perforation of the gastrointestinal tract is suspected, an organic iodine is recommended; however, these preparations are hypertonic and can cause dehydration, especially in small patients. Additionally, organic iodines are hy-

droscopic and are rapidly absorbed from the gastrointestinal tract. Dilution of the contrast medium with intraluminal fluid may compromise the study and interfere with defining the region of perforation. These agents do not coat the mucosa like barium does and are not recommended for routine gastrointestinal examinations.

In juvenile birds, barium should be warmed prior to administration. This is not necessary with adult birds. To administer barium, the head and neck are extended and a soft, flexible feeding tube is passed into the crop (see Figure 15.6). Small species do not require a speculum for passage of the tube; however, larger species need the beak held open either with a speculum or gauze. Measuring the distance from the beak to the crop and marking the tube helps ensure that the tube is within the crop and not accidentally passed into the tracheal lumen. The tube should be palpated within the crop prior to the administration of contrast material.

The dose of barium sulfate varies depending on the species and presence or absence of a crop, and ranges from 0.025-0.05 ml/g body weight, with the lower dose range used in larger species. Lesions in the mucosa are best identified by using a higher dose, and a lower dose can be used if the intention is to simply identify borders of the gastrointestinal tract.

The contrast media should be administered slowly until the crop is comfortably distended. Placing a finger over the distal portion of the cervical esophagus may help prevent reflux of barium sulfate while it is being administered. Placing excessive pressure on the full crop may induce regurgitation. Slow removal of the tube may also help reduce reflux. If any regurgitation occurs, the administration of contrast media should cease in order to reduce the risk of

#### CLINICAL APPLICATIONS

Radiographic abnormalities that may be defined by gastrointestinal contrast studies include:

- Change in location, size or shape of abdominal organs
- Differentiation between the gastrointestinal tract and other organs
- Altered motility (increased or decreased)
- Increased or decreased luminal diameter
- Mucosal irregularities
- Filling defects
- Changes in wall thickness
- Extravasation of contrast media
- Dilution of contrast with mucus or fluid

pulmonary aspiration (see Chapter 22). Barium has been used for bronchography in non-avian species because it is less irritating than other contrast agents.<sup>25</sup> It is the volume of barium inhaled into the respiratory tract and not the agent itself that may cause problems.

Radiographic sequence may vary depending on the species and condition under investigation; however, in general, radiographs should be taken immediately after administration of contrast media and at 0.5-, 1-, 2-, 4-, 8- and 24-hour intervals (Table 12.3). The temporal sequence may vary if a lesion is identified during the study.

If the crop is the only area of concern, a double contrast ingluviography may be performed in association with a barium follow-through study or as a separate procedure. Double contrast studies allow enhanced visualization of the crop wall for irregularities such as thickening, mucosal defects, masses and the detection of foreign bodies that may be obscured by a single-phase contrast study. The total volume of contrast to be administered (0.025 ml/g) is determined. Half of the total volume is given as air and the rest as barium. The air should be administered first to prevent air bubbles from forming within the contrast media. Although double contrast cloacography can also be performed, direct visualization with endoscopic equipment or an otoscope is preferable (Figure 12.70).

### Contrast Study Findings

Delayed transit time may be caused by functional or mechanical ileus. Mechanical ileus, depending on the level of obstruction and degree of luminal compromise, usually causes segmental dilation of the gastrointestinal tract. Functional ileus usually causes a uniform distention of the gastrointestinal tract (see

Figure 32.22). Mechanical obstruction occurs with intraluminal or extraluminal masses, foreign body ingestion, helminthiasis and stricture. Intraluminal masses such as neoplasm, abscess, granuloma, intussusception and papilloma will cause filling defects within the contrast column (see Figure 25.15). Mucosal irregularity and ulceration may aid in differentiating neoplasia from more benign processes, but fungal disease and neoplasia can be difficult to distinguish radiographically, and biopsy is the only definitive method to differentiate these diseases. Extraluminal masses involving the thyroid gland, spleen, gonads, oviduct or kidney may compress the lumen of the gastrointestinal tract and cause altered motility or obstruction.

Functional ileus occurs most frequently with neuropathic gastric dilatation and most often involves the proventriculus and ventriculus, although portions of the intestines may also be involved (see Figure 32.24).<sup>11</sup> Neurotoxins such as lead, inflammatory processes involving the coelomic cavity, severe enteritis and anesthetics may cause functional ileus.

Displacement of the gastrointestinal tract may occur with organomegaly, accumulations of fluid in the intestinal peritoneal cavity, adhesions or hernia. Hepatomegaly causes dorsal elevation of the proventriculus and caudal movement of the ventriculus. Splenic, gonadal and renal lesions may displace the intestines ventrally. Masses originating from the cranial division of the left kidney may push the ventriculus cranially. Adhesions associated with egg-related peritonitis may result in abnormal positioning of portions of the gastrointestinal tract, with a fixed appearance and changes in luminal diameter. Hernias, usually in hens, cause caudoventral displacement of the gastrointestinal tract.

A change in luminal diameter and wall thickness most often occurs with obstruction or functional ileus. Fungal diseases and neoplasia can cause narrowing of the lumen due to mural infiltration. Inflammatory changes can also increase wall thickness and influence motility (see Figure 36.29). Mucosal defects are most pronounced with aggressive diseases such as neoplasia or fungal infections. Spiculation of the contrast column due to a hyperemic mucosa, stringing out of barium from mixing with mucus, diminished bowel distensibility and increased transit times occur with inflammation (see Figure 19.12).

TABLE 12.3 Barium Sulfate Transit Times\*

	Stomach	Small Intestines	Large Intestines	Cloaca
African Grey Parrot	10-30	30-60	60-120	120-130
Budgerigar	5-30	30-60	60-120	120-240
Racing pigeon	5-10	10-30	30-120	120-240
Indian Hill mynah	5	10-15	15-30	30-90
Hawk	5-15	15-30	30-90	90-360
Amazon parrot	10-60	60-120	120-150	150-240
Canary	5	10-15	15-30	30-90
Pheasant	10-45	45-120	120-150	150-240

\*Time in minutes for barium sulfate administered by crop gavage to reach and fill various portions of the GI tract.

Extravasation of contrast media occurs most often with foreign body perforation, although metal feeding tubes or inflexible catheters can result in iatrogenic perforation of the gastrointestinal tract if improperly used. Mural erosion in association with neoplasm, abscess or granuloma are less frequent causes of perforation (see Figure 25.14). If a perforation is suspected, an organic iodine contrast agent is recommended to prevent contamination of the coelomic cavity with barium.

Repeatability of a lesion on multiple views is important when attempting to identify intraluminal masses. Gas bubbles and ingesta can create artifacts that mimic mucosal defects and can lead to an incorrect diagnosis. Tailoring the study to the individual patient and obtaining additional views during the study will aid in accurate interpretation.

### ■ Intravenous Excretory Urography

In birds, the absence of a urethra, bladder, renal pelvis or division between the medulla and cortex, as well as the glomerular filtration rate, tubular resorption and the renal portal system make contrast urography of limited value. The primary indication for intravenous excretory urography is in defining mass lesions associated with the urinary tract or delineating the size and shape of the kidneys if they cannot be adequately visualized on routine radiographs (Figure 12.55).<sup>14</sup> Excretory urography may also have some application for diagnosing functional disorders. Excretory urography should not be attempted in patients with dehydration or debilitation or if renal function is severely compromised.

Sodium diatrizoate (680 mg of iodine/kg), iothalamate sodium (800 mg of iodine/kg) or meglumine diatrizoate (800 mg of iodine/kg) have been used for urography in birds with no observable adverse effects.<sup>6,14</sup> These organic iodines should be warmed prior to administration through the ulnar, jugular or medial metatarsal veins. Radiographs are taken immediately after contrast administration and at one-, two-, five-, ten- and twenty-minute intervals using the same technique developed for the survey radiograph.

Most diagnostic information is obtained within the first five minutes of the study (Figure 12.55). The aorta, heart and pulmonary artery will be visualized within ten seconds; kidneys and ureters in 30 to 60 seconds; and cloaca in three to five minutes after administering the contrast media (Figure 12.55).<sup>7</sup> In the nephrographic phases of the study, there is an

immediate, uniform opacification of the kidneys highlighting their size, shape and contour. In the normal kidney, the three divisions are readily discernible. There is no pyelographic phase.

Mass lesions such as renal tumors and cysts cause changes in the size, shape and contour of the kidneys and are distinguishable from gonadal lesions because of the contrast enhancement. Tumors are usually solitary mass lesions with irregular margins and are best visualized in the lateral view. Cysts tend to have smooth, well defined borders. Biopsy is necessary to definitively differentiate between tumors and cysts. Abnormalities of the ureters are rare, but they may be compressed in birds with egg binding and cloacal or abdominal masses.<sup>1</sup> Occasionally, cloacal lesions may be outlined during urography.

Radiographic changes in the excretory urogram are most striking when the renal disease is unilateral because the unaffected kidney is usually hypertrophied. In contrast, obstruction of a ureter may increase the radiodensity of the ipsilateral kidney by delaying the washout from the kidney. If urine containing contrast medium is discharged into a pool of urine containing no contrast media, the opacification will be delayed and reduced. Because a large pool of urine may be retained in a hydroureter and with hydronephrosis, late films should be taken when no contrast media is noted on early radiographs.

If one kidney appears to be non-functioning, it is important to consider the urinary protein concentration; cytologic features of sediment and the size of the contralateral kidney. In acute renal failure, the excretory function is rapidly and severely, but often reversibly, compromised. If the contralateral kidney is hypertrophied, the absence of function on the opposite side is probably chronic in nature (urolithiasis) and may even indicate agenesis of that kidney (see Figure 21.4).

### ■ Positive Contrast Rhinosinography

Contrast studies of the nasal cavity and sinuses may aid in evaluation of the upper respiratory tract; however, CT has replaced these procedures in other species (Figure 12.38 to 12.40). A 15 to 20% organic iodine agent can be injected into the sinus, and the same views recommended under skull radiography are taken for evaluation. Reactions to the contrast agent include edema and periorbital swelling. At the end of the procedure, the media can be flushed out of the sinuses with sterile saline to decrease the amount

of local irritation. Space-occupying masses such as neoplasms, abscesses or granulomas may cause an obstruction to the flow of contrast media (Figures 12.42, 12.43). In normal psittacine birds, there should be communication between the infraorbital sinus, nasal cavity, opposite sinus, periorbital region and tympanic region (Figures 12.40, 12.41).<sup>12</sup> In some Passeriformes, the sinuses do not communicate (Figure 12.41).

### Positive Contrast Tracheography and Bronchography

Contrast studies of the lower respiratory tract should be considered high risk because patients requiring these procedures are usually experiencing serious respiratory compromise. Tracheoscopy is preferable in patients of sufficient size (300 g). Focal lesions in the terminal trachea or at the tracheobronchial bifurcation that are difficult to visualize on survey radiographs may be defined by contrast tracheography (Figure 12.47).<sup>12</sup>

Patients should be stabilized with oxygen therapy and a tube placed in an abdominal sac to provide oxygen and anesthesia. Birds should be anesthetized for these studies. Contrast media is administered via a tube placed in the trachea. Small aliquots (approximately 0.1 ml) of a non-ionic agent or propylidone should be given at a time, and radiographs taken to determine tracheal filling. A minimal amount of contrast media will be needed if fluoroscopy can be used to identify a foreign body.

### Non-selective Angiography

Cardiac disease requiring definition by contrast studies is rare. Diseases such as cardiomyopathy, some congenital shunts and valvular disease may be defined by angiography in some larger birds; however, ultrasonography is being utilized with greater frequency in other species. Non-selective angiography has been used for defining the normal cardiac silhouette and major vessels. The same agents used for urography can be injected as a single, rapid, intravenous bolus in the jugular or ulnar veins to enhance visualization of the heart and great vessels. A rapid film changer, cinefluoroscopy or videotaping is necessary to record the image.

### Myelography

Assessment of back trauma or congenital defects may require myelography. Patients must be anesthetized

for this procedure. The bird is placed in lateral recumbency and a 25 ga needle or smaller is carefully inserted into the subarachnoid space. Cerebral spinal fluid will flow into the needle, and several drops can be collected for cytology. A non-ionic contrast media (0.25 ml/kg) is slowly injected into the cerebellar medullary cistern. Routine radiographs of the spine are taken.

## Alternative Imaging

### Fluoroscopy

A fluoroscope can be connected via an image intensifier to a video camera that can be used to make real-time recordings of organ movement. In birds, fluoroscopy is the best way to monitor the motility of the gastrointestinal tract. Patients can be placed in a darkened box to perform fluoroscopy. This technique may be particularly useful for detecting hernias, neoplasms, proventricular dilatation, hypermotility, ileus and gastric ulceration. In a normal parrot given a bolus of barium sulfate by crop tube, the barium will fill the proventriculus and ventriculus in five to ten minutes. The barium will reach the intestines in 15 minutes. These findings suggest that unrestrained (reduced stress) birds have a faster gastrointestinal motility time than is routinely reported using standard radiographic techniques.<sup>22</sup>

### Ultrasound

Ultrasonography is an imaging technique that makes use of high frequency sound waves transmitted by a transducer that is in contact with the skin. The waves are transmitted through the tissues in the abdomen and the echoes are recorded by the receiving transducer unit. The resistance to sound waves depends on the molecular structure of the tissue that is being penetrated. If the sound waves encounter bone, most of the waves are absorbed and not reflected. If the sound waves are transmitted through air, most are reflected and not absorbed. In both of these cases, organs that lie behind these structures will not be detected.

Ultrasound studies in birds are somewhat limited by patient size and conformation and the presence of air sacs; however, in larger avian patients with abdomi-



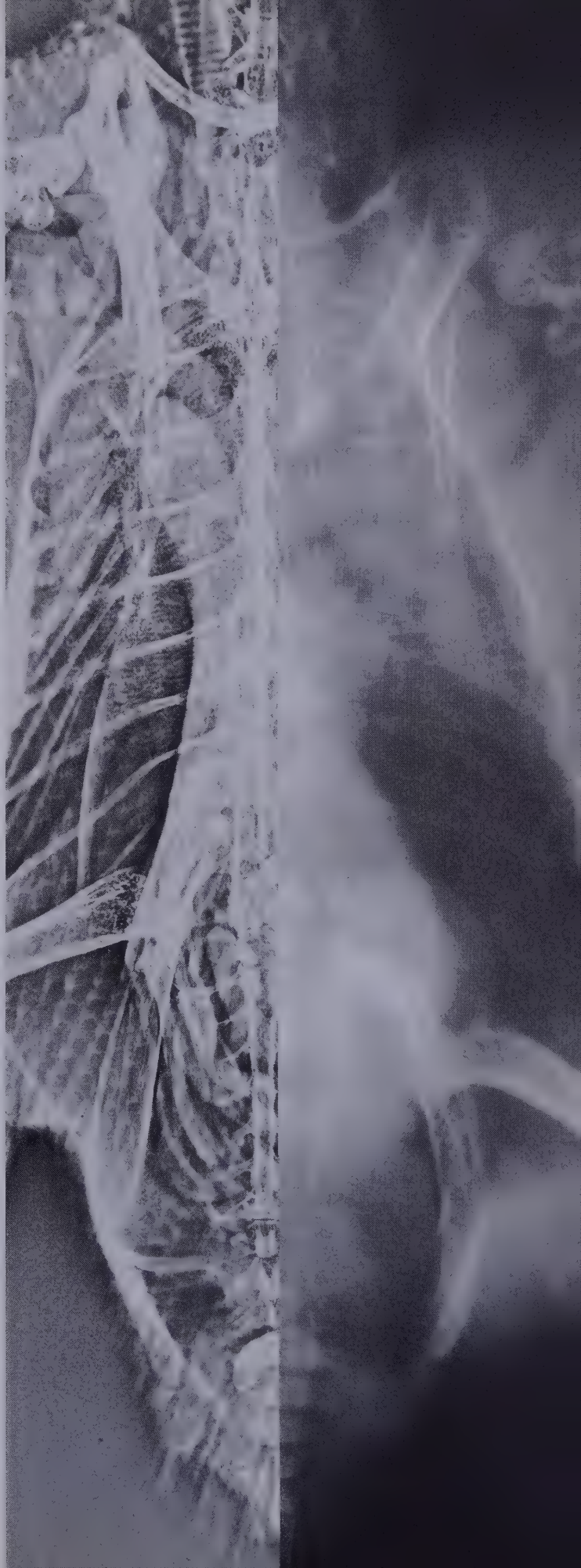
## Radiographic Anatomy and Abnormalities

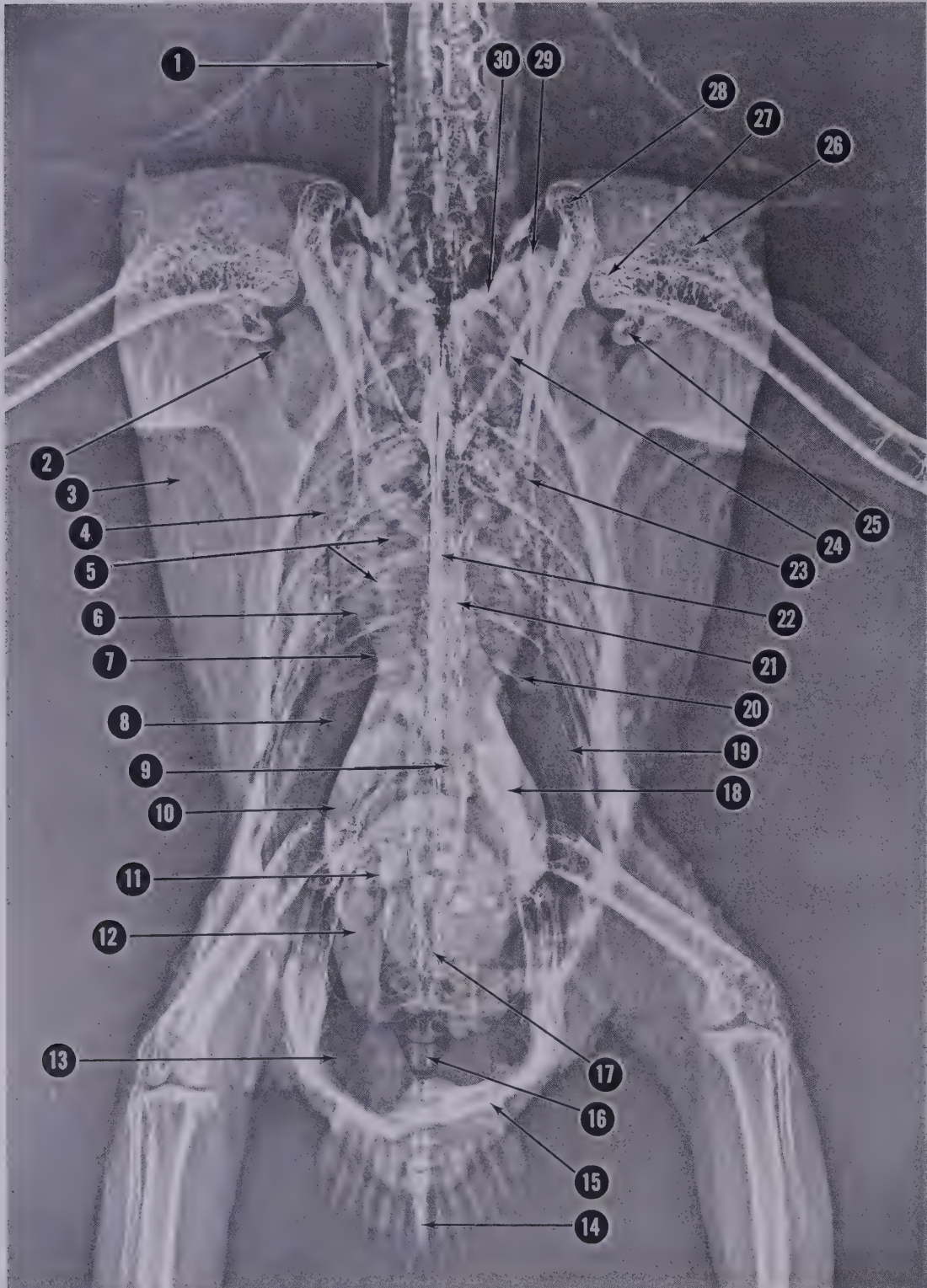
---

---

**R**adiography is an extremely valuable diagnostic tool in avian patients. Every avian clinician should be comfortable with radiographic techniques and interpretation of radiographic findings. One of the challenges of identifying subtle changes in radiographs of birds is the wide species variability in normal anatomic structures. Radiographs and xeroradiographs of the Orange-winged Amazon Parrot, cockatiel, Bobwhite Quail and Mallard Duck are provided to assist the clinician in developing a more complete understanding of the unique anatomic structures encountered in varying genera of birds. These radiographs were provided by Bonnie J. Smith and Stephen A. Smith and are reprinted with permission from *Veterinary Radiology* 31:114-124, 1990; 32:87-95, 1991; 31:226-234, 1990; 32:127-134, 1991.

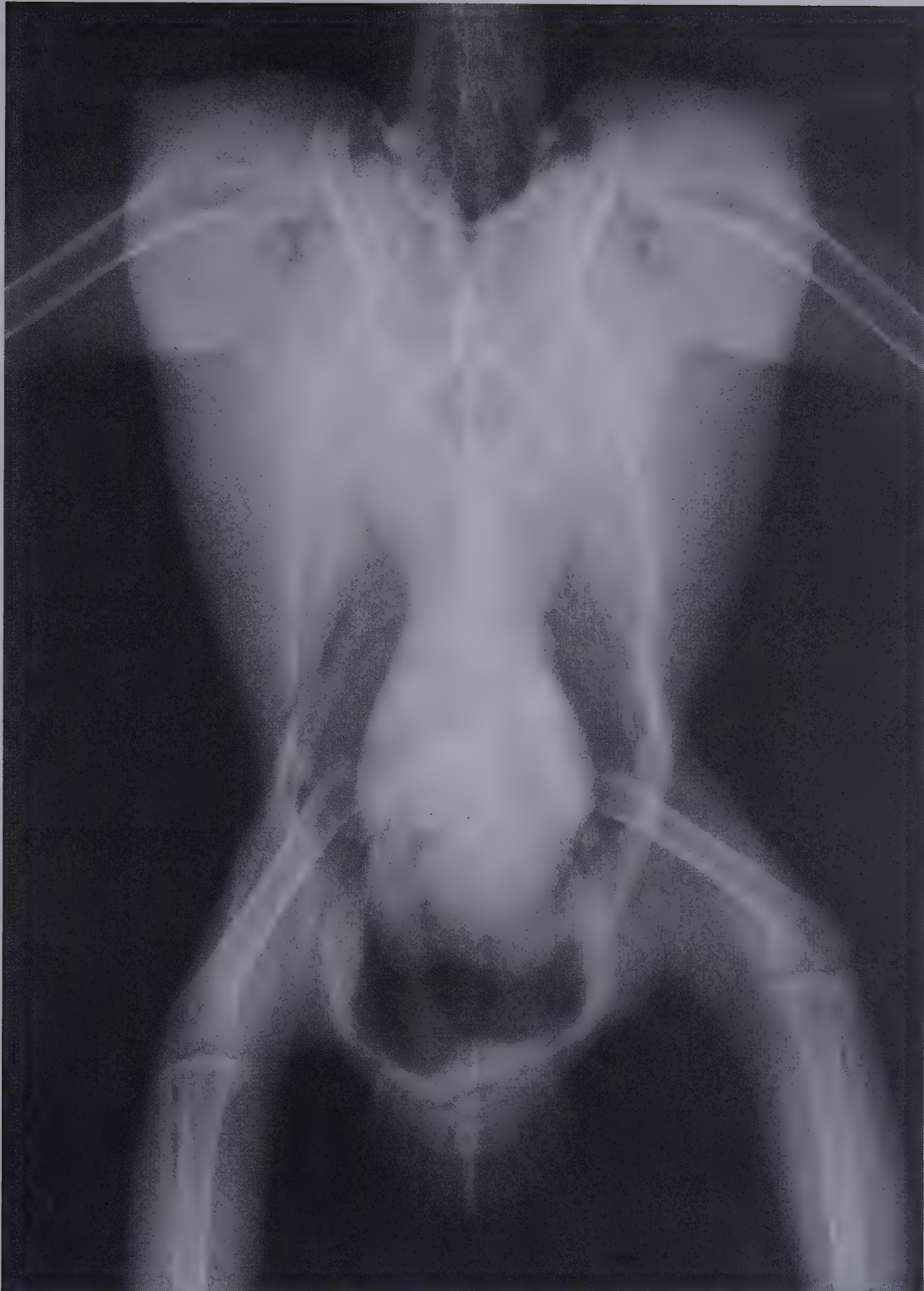Following the initial radiographs that address normal radiographic anatomy are case presentations demonstrating characteristic radiographic changes associated with pathology in various organ systems. The reader is encouraged to compare the radiographic findings in these cases with the normal radiographs and xeroradiographs presented in the first section. Additionally, radiographs detailing changes associated with specific organ systems can be found in respective sections throughout the book.



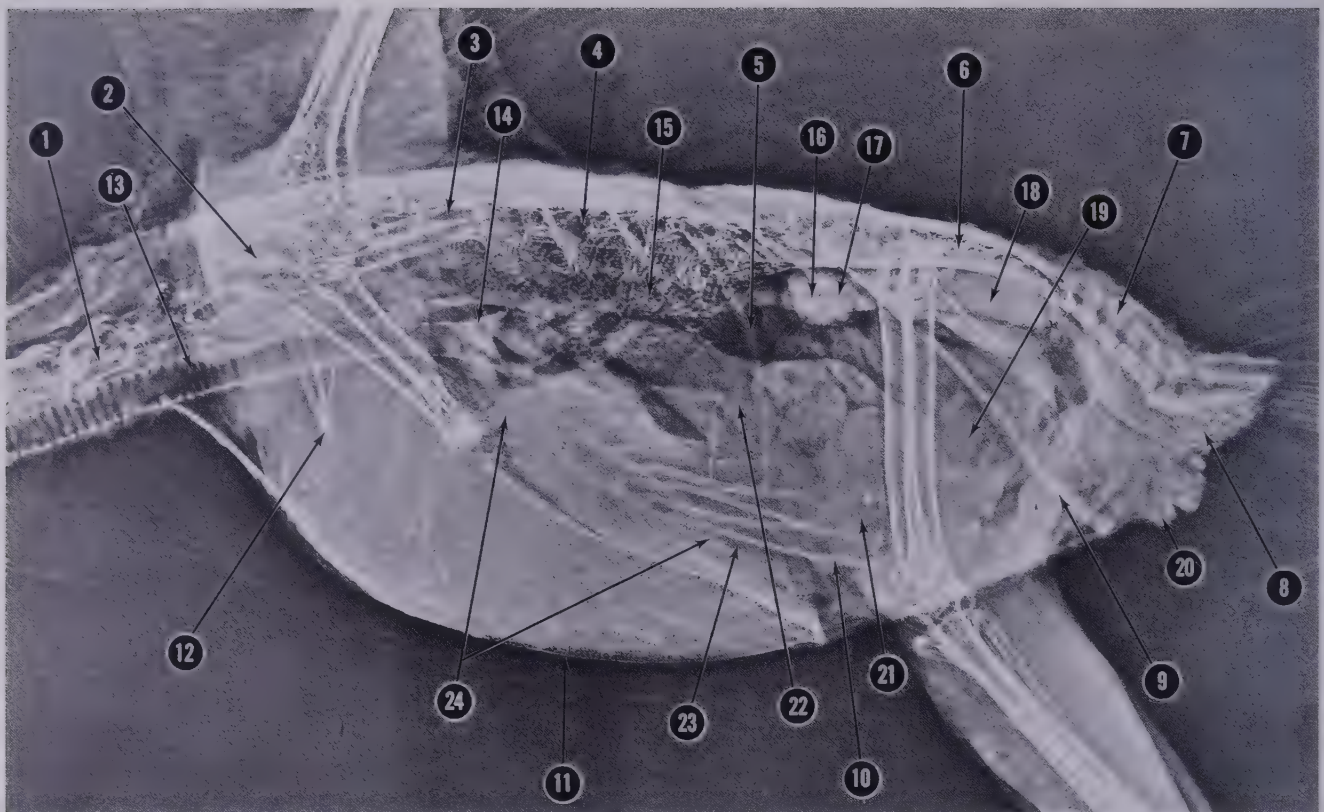


- |                       |  |                                     |  |                                  |
|-----------------------|--|-------------------------------------|--|----------------------------------|
| 1) trachea            | 7) normal hourglass constriction ("waist") of heart-liver shadow | 12) intestines                      | 20) vertebral rib                        | 25) ventral tubercle of humerus  |
| 2) clavicular air sac | 8) area of overlap of caudal thoracic and abdominal air sacs     | 13) abdominal air sacs              | 21) notarium                             | 26) dorsal tubercle of humerus   |
| 3) pectoral muscle    | 9) area of spleen  | 14) pygostyle                       | 22) sternum, ventral extremity of carina | 27) head of humerus              |
| 4) lung               | 10) liver  | 15) pubis                           | 23) caudal extremity of scapula          | 28) should extremity of coracoid |
| 5) great vessels      | 11) ventriculus with grit  | 16) free caudal vertebra            | 24) medial border of coracoid            | 29) head of scapula              |
| 6) heart              |  | 17) synsacrum                       |  | 30) clavicle                     |
|                       |  | 18) periacetabular portion of ilium |  |                                  |
|                       |  | 19) sternal rib                     |  |                                  |

**FIG 12.1** Ventrodorsal xeroradiograph of a normal Orange-winged Amazon Parrot (courtesy of Bonnie J. Smith and Stephen A. Smith).

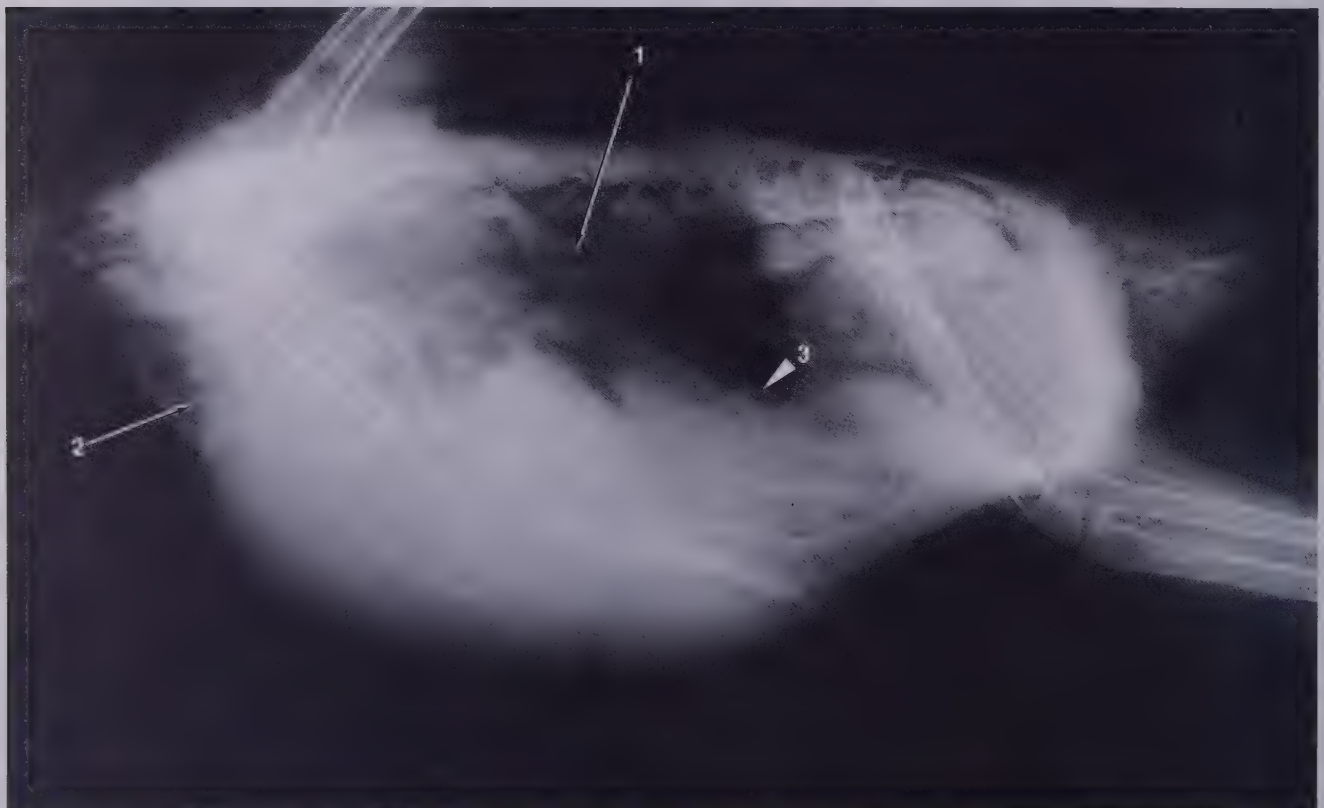


**FIG 12.2** Ventrals dorsal radiograph of a normal Orange-winged Amazon Parrot (courtesy of Bonnie J. Smith and Stephen A. Smith).

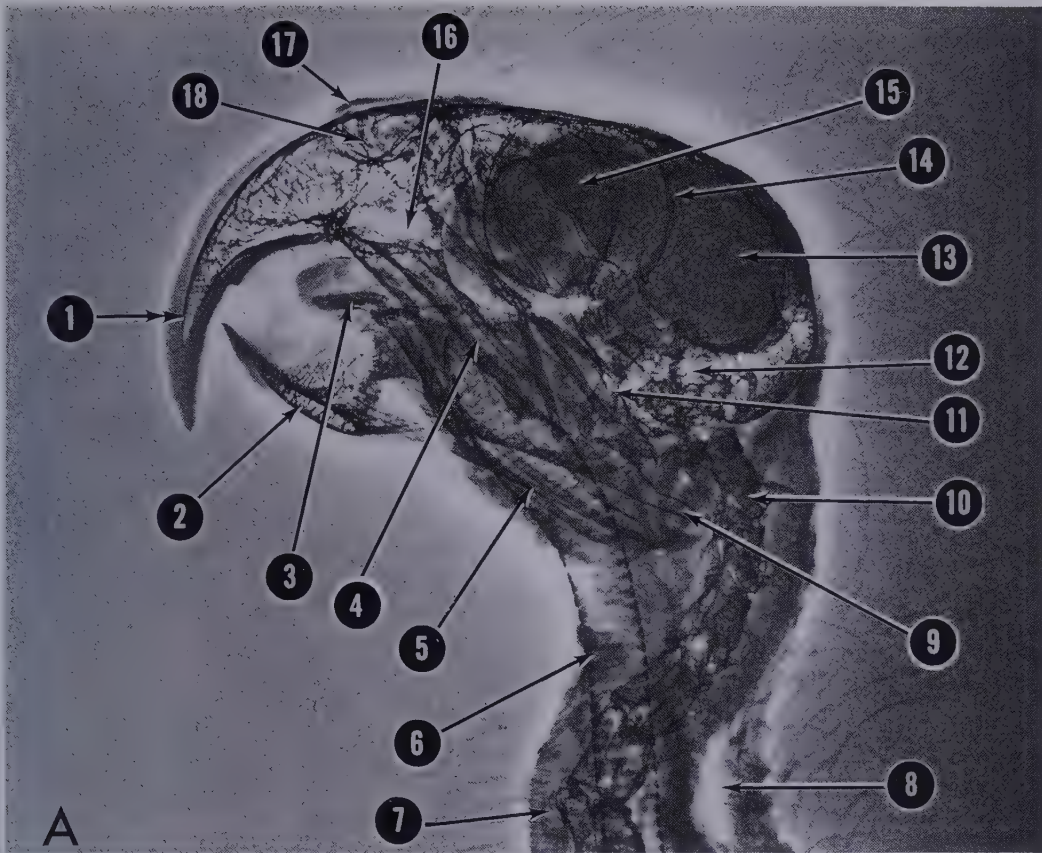


1) cervical vertebra    6) synsacrum    10) sternal rib    13) trachea    16) area of gonad    19) intestines    24) heart (apex and base)  
 2) coracoid    7) free caudal vertebrae    11) kell of sternum    14) syrinx    17) kidney (cranial division)    20) vent    21) ventriculus  
 3) scapula    12) clavicles (at point of fusion into furcula)    15) lung (note characteristic "stipled" appearance)    18) kidney (caudal division)    22) proventriculus    23) liver  
 4) area of notarium    8) pygostyle    9) pubis

**FIG 12.3** Lateral xeroradiograph of a normal Orange-winged Amazon Parrot (courtesy of Bonnie J. Smith and Stephen A. Smith).

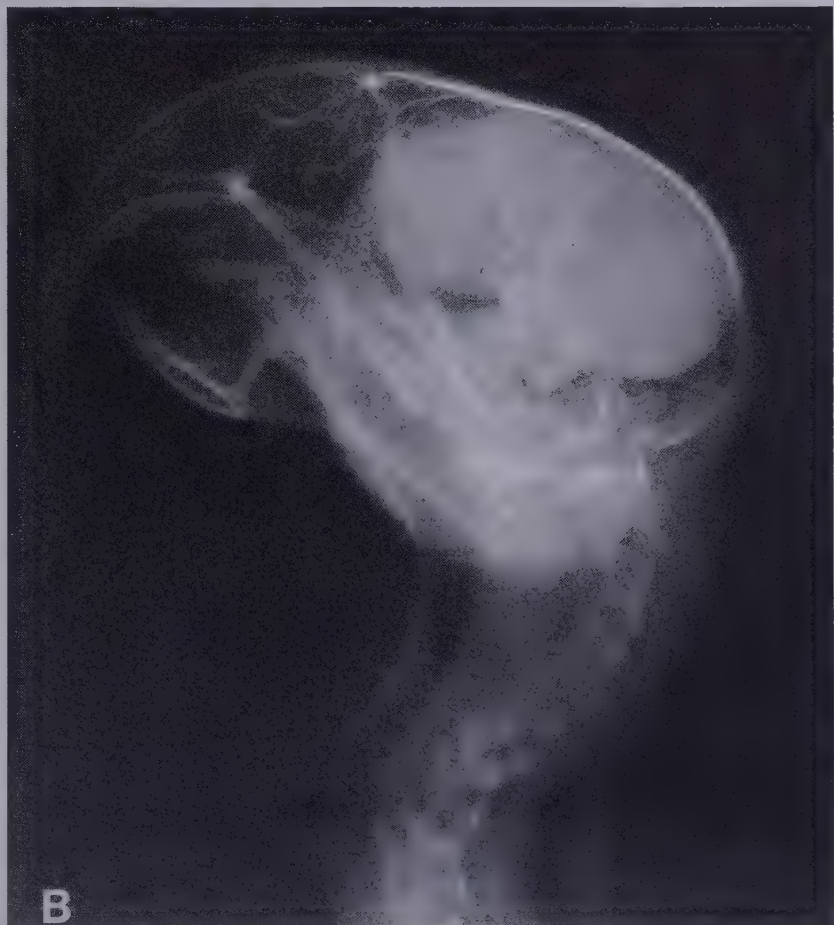

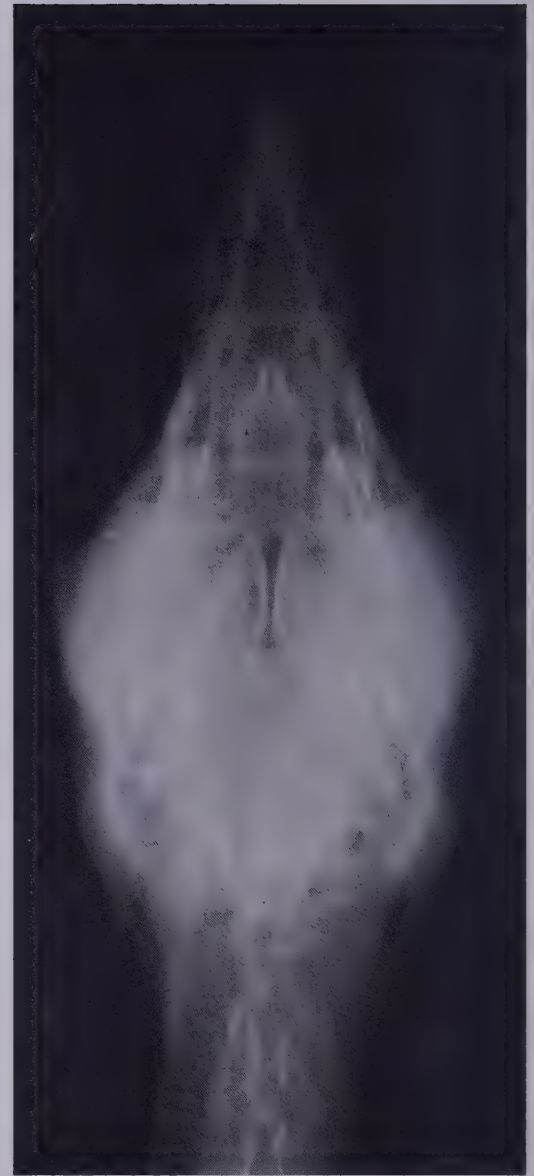
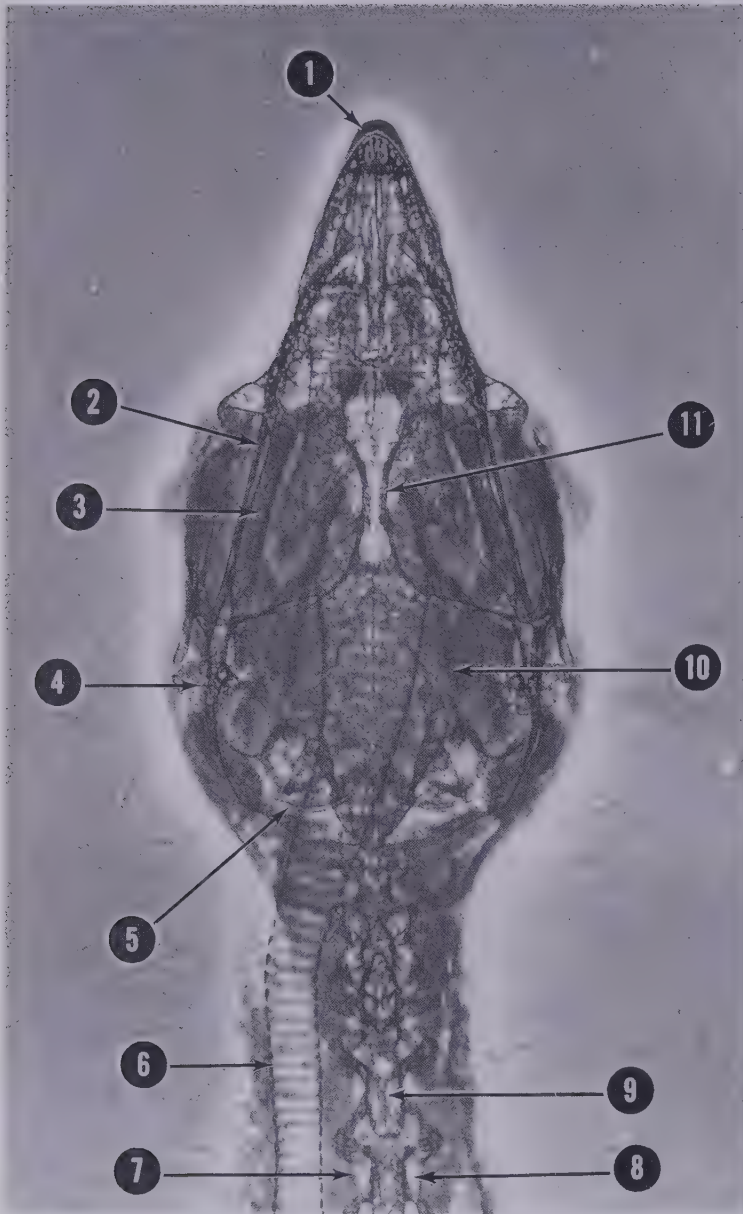
**FIG 12.4** Lateral radiograph of a normal Orange-winged Amazon Parrot. 1) mesobronchus en route to abdominal air sac 2) crop containing ingesta 3) spleen (courtesy of Bonnie J. Smith and Stephen A. Smith).



**FIG 12.5** Lateral xeroradiograph and radiograph of the head of a normal Orange-winged Amazon Parrot (courtesy of Bonnie J. Smith and Stephen A. Smith).

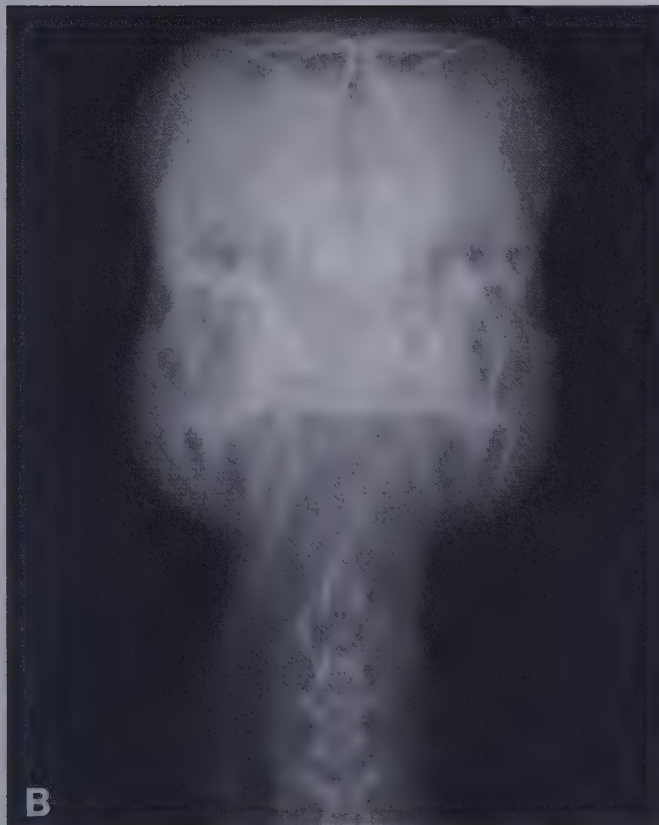
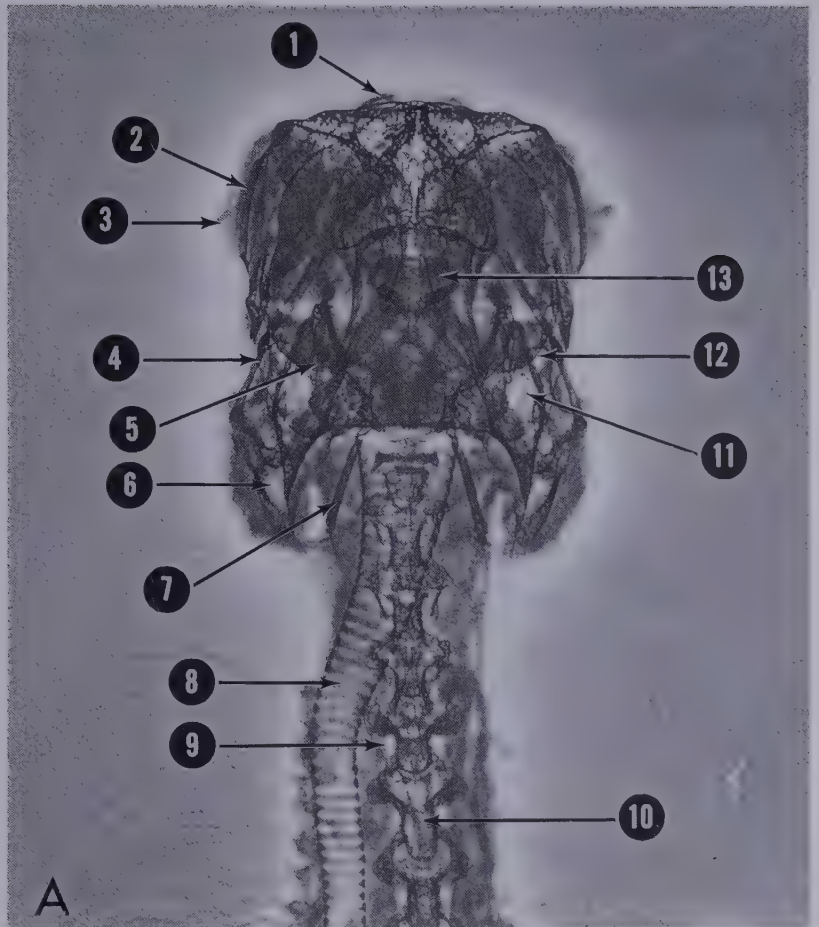
- 1) rhinotheca (superficial portion of arrow) covering premaxilla (lower portion of arrow)
- 2) mandibular symphysis
- 3) entoglossal bone of hypobranchial apparatus (hyoid) within the tongue
- 4) jugal arch (zygomatic arch)
- 5) ceratobranchial bone of hyoid
- 6) trachea
- 7) cervical rib
- 8) cervicocephalic air sac
- 9) retroarticular process of mandible
- 10) cervical vertebra
- 11) quadrate bone
- 12) tympanic area
- 13) cranial cavity
- 14) caudal edge of orbit
- 15) scleral ossicle
- 16) rostral part of infraorbital sinus
- 17) cere
- 18) nasal aperture





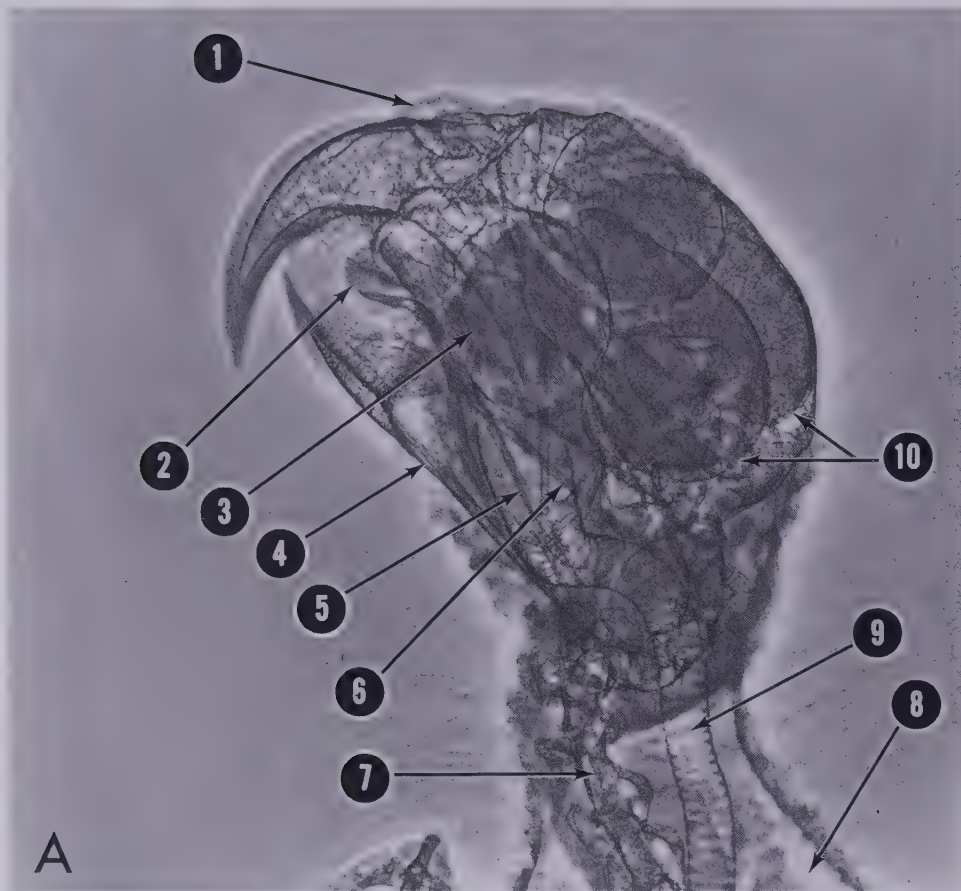
- |                                   |   |                            |  |
|-----------------------------------|---|----------------------------|--|
| 1) rhinotheca covering premaxilla | 4) area of quadratomandibular joint<br>(analogous to temporomandibular joint) | 6) trachea                 | 9) cervical vertebra                       |
| 2) jugal arch (zygomatic arch)    | 5) caudal edge of cranium   | 7) cervical rib            | 10) ceratobranchial bone (hyoid apparatus) |
| 3) mandible                       |   | 8) cervicocephalic air sac | 11) medial border of the left orbit        |

**FIG 12.6** Ventrals xeroradiograph and radiograph of the head of a normal Orange-winged Amazon Parrot (courtesy of Bonnie J. Smith and Stephen A. Smith).



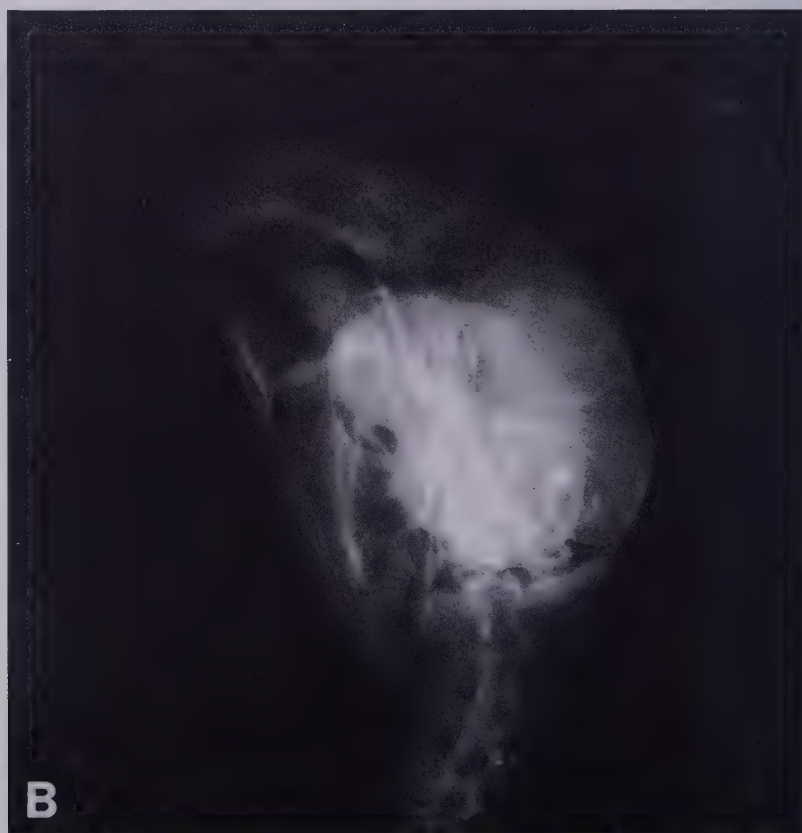**FIG 12.7** Rostrocaudal xeroradiograph and radiograph of the head of a normal Orange-winged Amazon Parrot (courtesy of Bonnie J. Smith and Stephen A. Smith).

- 1) cere
- 2) scleral ossicle
- 3) eyelid
- 4) jugal arch (zygomatic arch)
- 5) tympanic area
- 6) mandible
- 7) ceratobranchial bone of hyoid
- 8) trachea
- 9) cervicocephalic air sac
- 10) cervical vertebra
- 11) infraorbital sinus
- 12) edge of cranium
- 13) tongue (note paired entoglossum of hyoid)

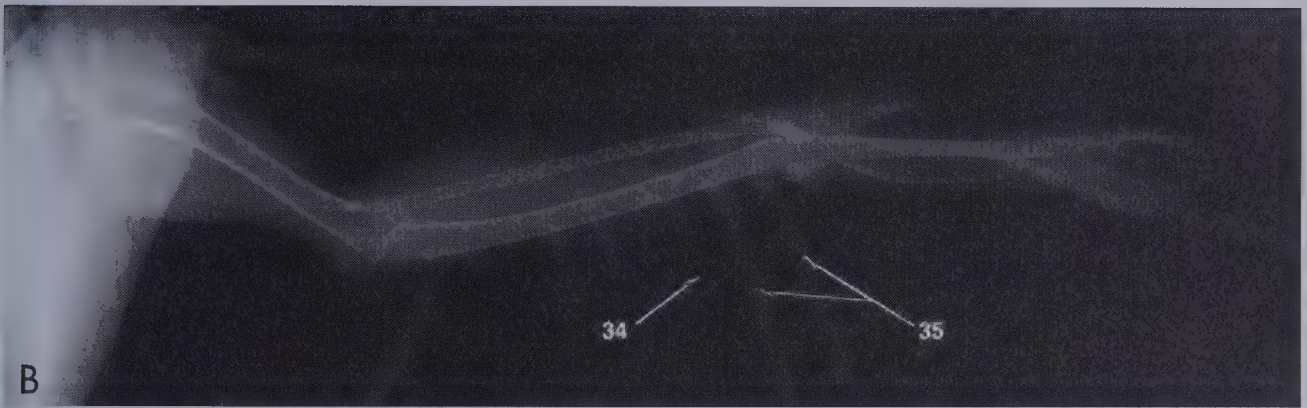
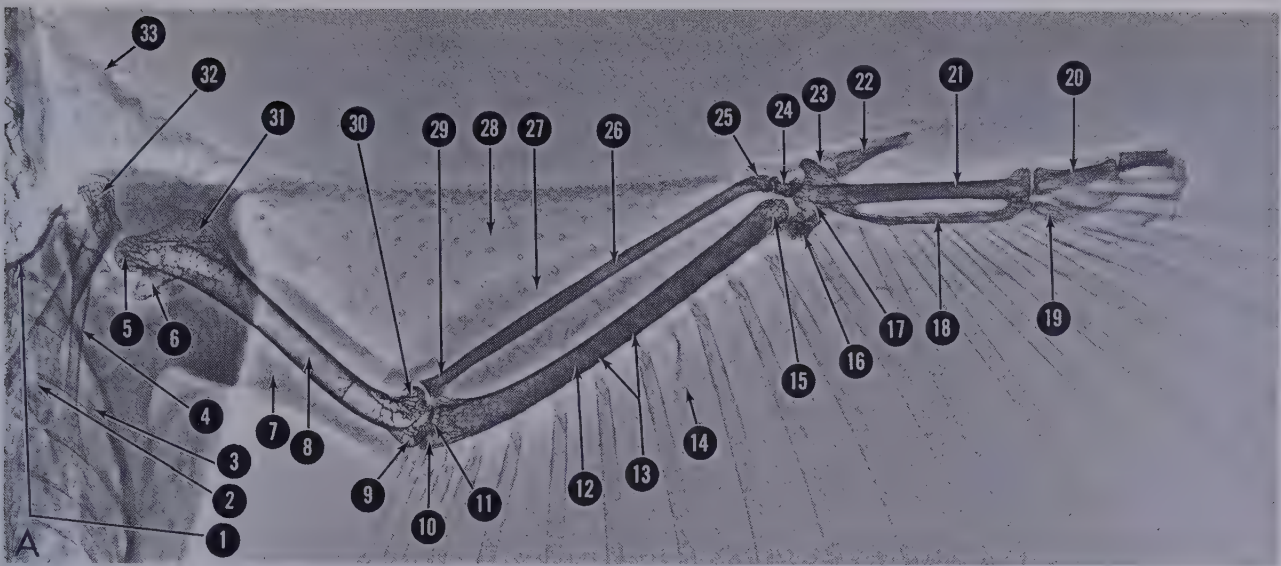


**FIG 12.8** Oblique xeroradiograph and radiograph of the head of a normal Orange-winged Amazon Parrot (courtesy of Bonnie J. Smith and Stephen A. Smith).

- 1) cere
- 2) tongue containing entoglossum of hyoid
- 3) scleral ossicle
- 4) ramus of mandible
- 5) ceratobranchial bone of hyoid
- 6) jugal arch (zygomatic arch)
- 7) cervical vertebra
- 8) cervicocephalic air sac
- 9) trachea
- 10) edge of cranium

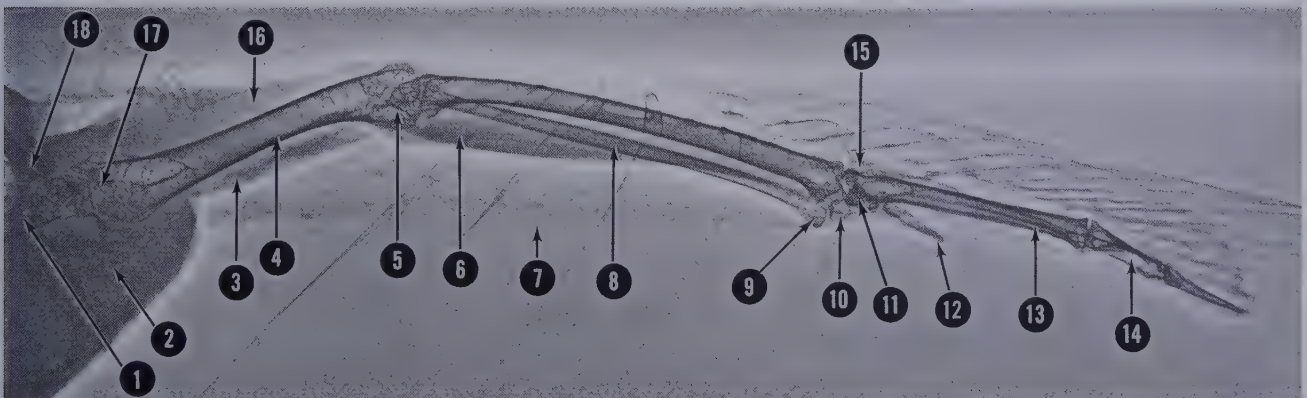






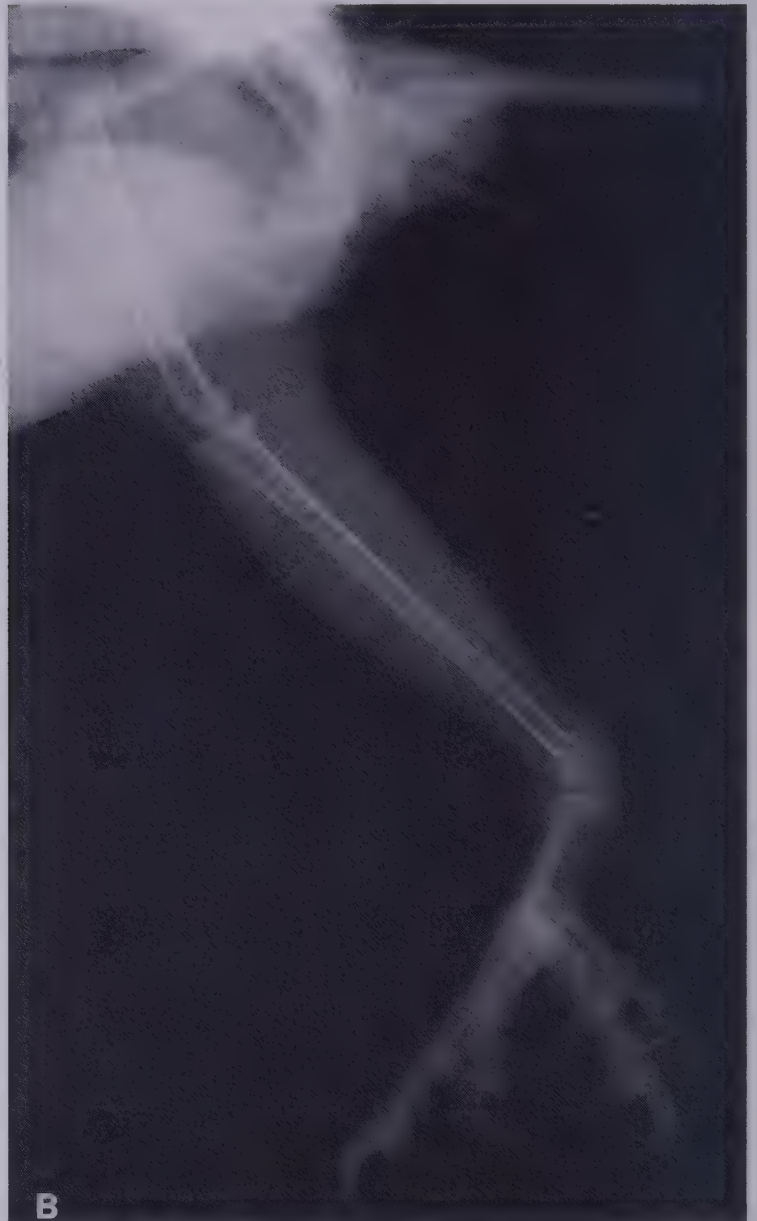
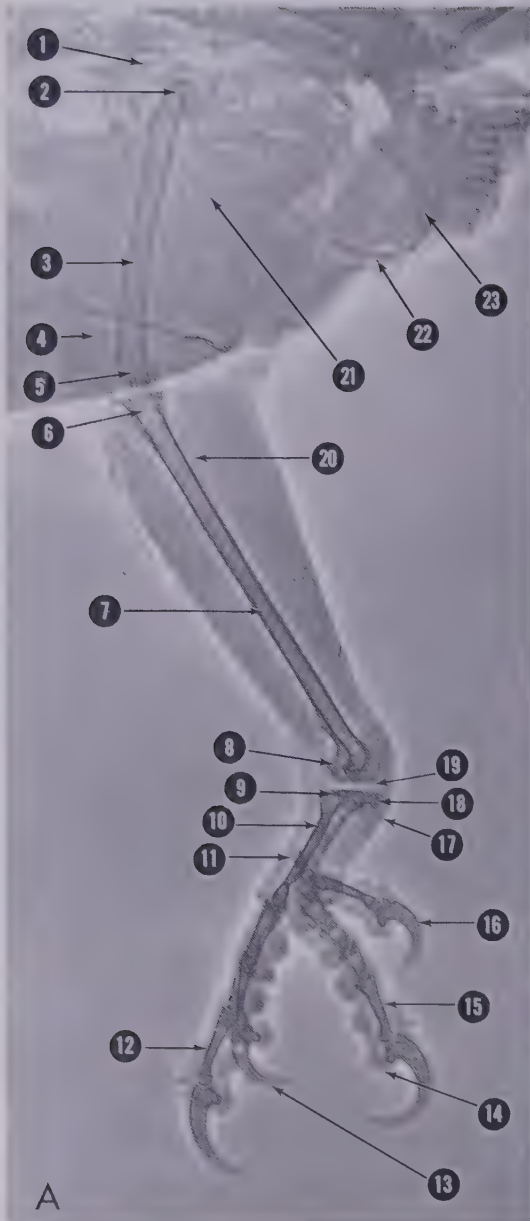
- |                                  |   |   |   |
|----------------------------------|---|---|---|
| 1) clavicle                      | 12) ulna  | 20) major digit (digit II, composed of two phalanges) | 28) propatagium (note feather follicles)                |
| 2) sternal extremity of coracoid | 13) attachment of secondary flight feathers to periosteum of ulna | 21) major metacarpal bone (MC III)                    | 29) head of radius                                      |
| 3) rib                           | 14) post-patagial membrane  | 22) alular digit (digit I)                            | 30) dorsal condyle of humerus                           |
| 4) scapula                       | 15) condyles of ulna  | 23) alular metacarpal bone (MC I)                     | 31) minor tubercle of humerus                           |
| 5) head of humerus               | 16) ulnar carpal bones  | 24) radial carpal bone                                | 32) should extremity of coracoid                        |
| 6) ventral tubercle of humerus   | 17) intercarpal joint   | 25) distal extremity of radius                        | 33) cervical patagium                                   |
| 7) extensor muscles of elbow     | 18) minor metacarpal bone (MC III)                                | 26) radius  |   |
| 8) humerus                       | 19) minor digit (digit III) composed of one phalanx               | 27) extensor muscles of carpus and digit              |   |
| 9) ventral condyle of humerus    |   |   |   |
| 10) olecranon                    |   |   |   |
| 11) cotyles of ulna              |   |   |   |
|                                  |   |   | 34) mature feather with radiolucent core                |
|                                  |   |   | 35) immature feather with vascular core (blood feather) |

**FIG 12.9** Ventrodorsal xeroradiograph and radiograph of the wing of a normal Orange-winged Amazon Parrot (courtesy of Bonnie J. Smith and Stephen A. Smith).



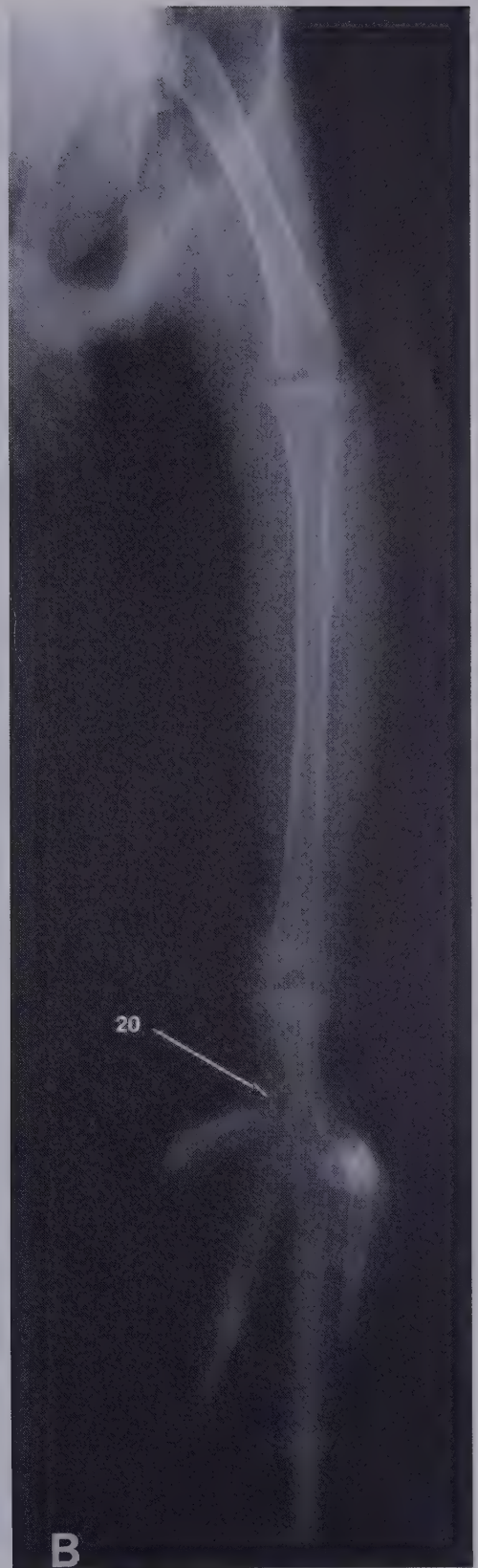
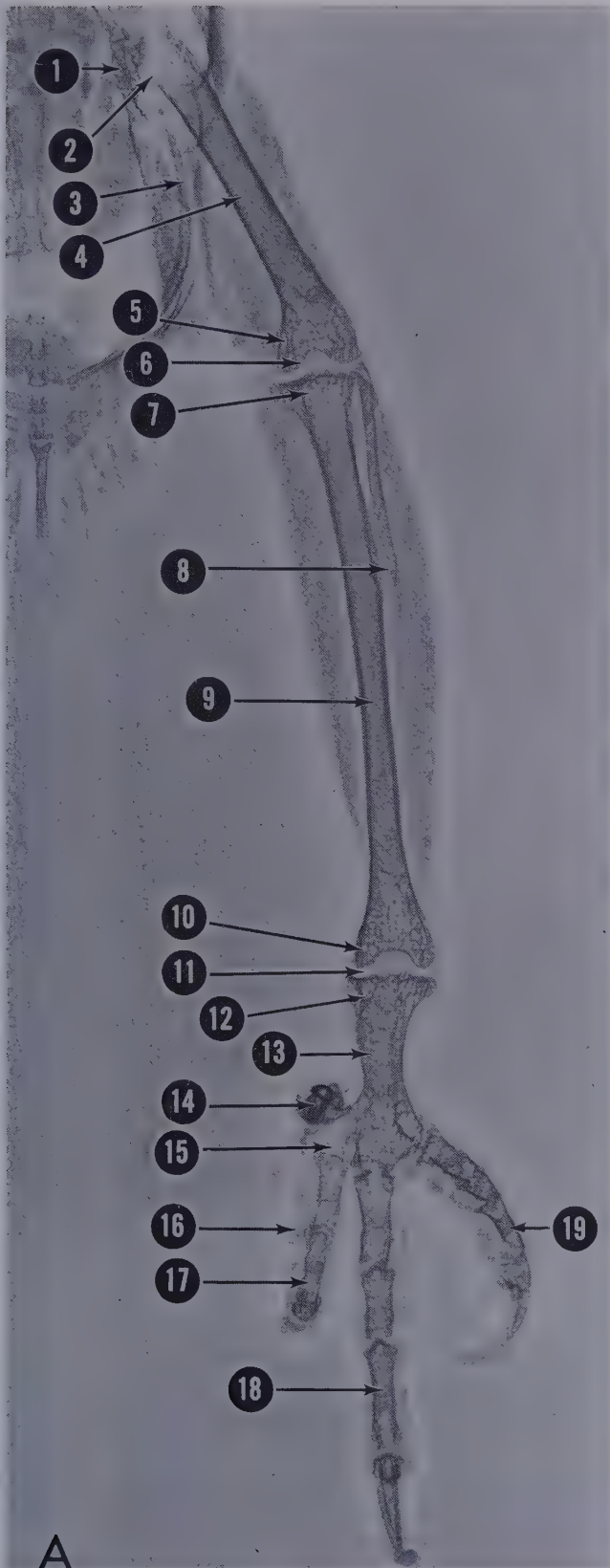
- |  |  |   |  |
|--|--|---|--|
| 1) coracoid  | 6) extensor muscles of carpus and digits | 11) area of carpometacarpus                                     | 14) major and minor digits (superimposed digit III and II) |
| 2) pectoral muscle   | 7) propatagium                           | 12) alular digit (digit I)                                      | 15) intercarpal joint                                      |
| 3) flexor muscles to elbow   | 8) radius                                | 13) major and minor metacarpals (superimposed MC III and MC II) | 16) extensor muscles of elbow                              |
| 4) humerus   | 9) distal extremity of radius            |   | 17) shoulder joint   |
| 5) elbow joint, superimposition of radial head, olecranon and distal humerus | 10) radial carpal bone                   |   | 18) head of scapula  |

**FIG 12.10** Craniocaudal xeroradiograph of a wing of a normal Orange-winged Amazon Parrot. The wing has been slightly rotated to separate the image, of the radius, ulna and alular digit (courtesy of Bonnie J. Smith and Stephen A. Smith).



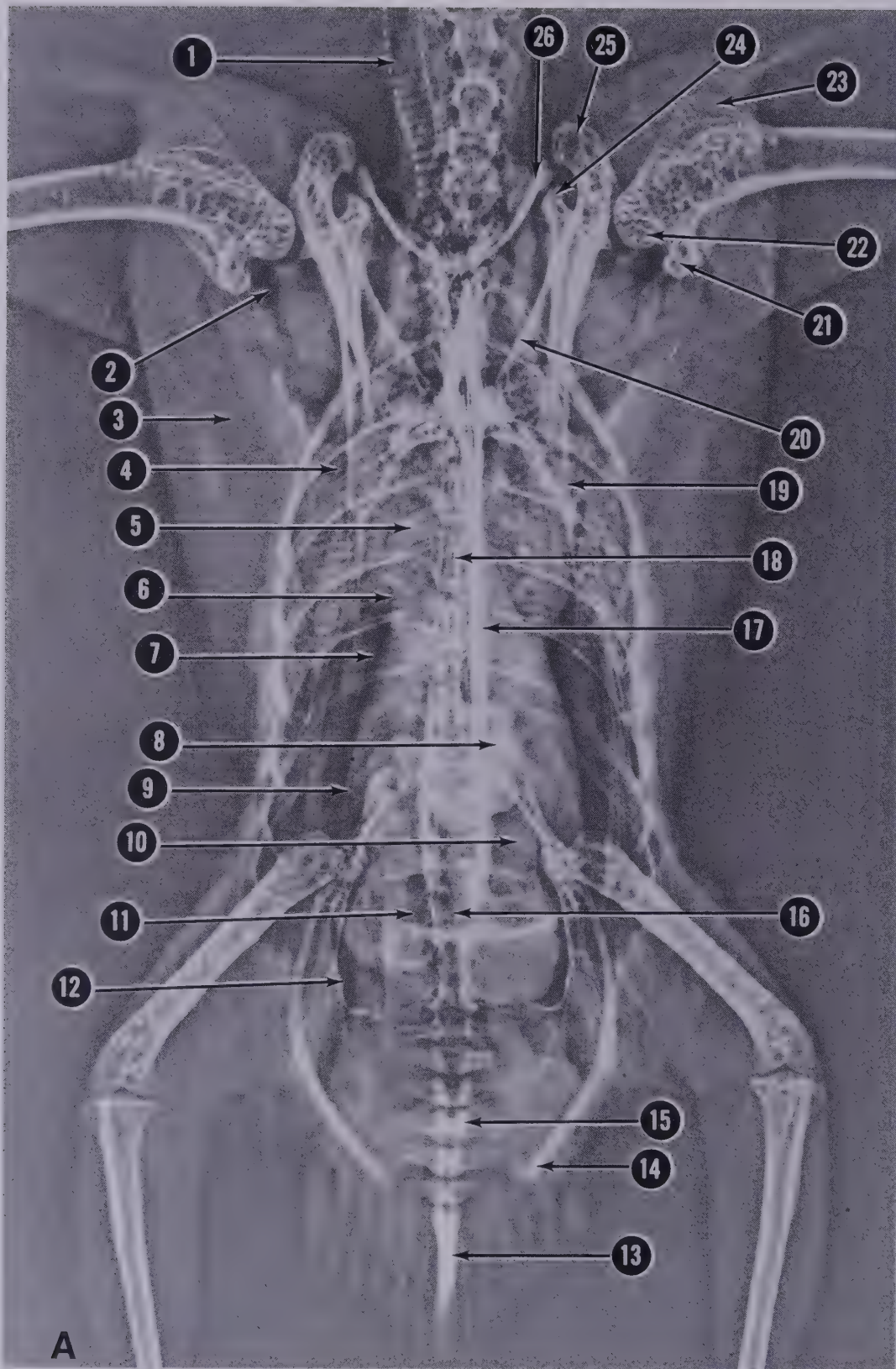
- |   |  |  |                       |
|---|--|--|-----------------------|
| 1) ilium  | 8) condyles of tibiotarsus                 | 14) digital pad  | 19) intertarsal joint |
| 2) greater trochanter of femur superimposed over femoral head | 9) cotyles of tarsometatarsus              | 15) digit IV (consists of five phalanges)  | 20) fibula            |
| 3) femur  | 10) tarsometatarsus                        | 16) digit I (consists of two phalanges)  | 21) sternal rib       |
| 4) patella  | 11) metatarsal I                           | 17) podotheca (note abrupt change in skin from delicate and feathered to thick and scaled) | 22) pubis             |
| 5) femoral condyles   | 12) digit III (consists of four phalanges) | 18) calcaneus  | 23) ischium           |
| 6) proximal extremity of tibiotarsus                          | 13) digit II (consists of three phalanges) |  |                       |
| 7) body of tibiotarsus  |  |  |                       |

**FIG 12.11** Lateral xeroradiograph and radiograph of the pelvic limb of a normal Orange-winged Amazon Parrot (courtesy of Bonnie J. Smith and Stephen A. Smith).



- |                                    |  |                                |                              |                                |
|------------------------------------|--|--------------------------------|------------------------------|--------------------------------|
| 1) neck of femur                   | 5) medial femoral condyle              | 9) tibiotalarsus               | 13) tarsometatarsus          | 17) digit II                   |
| 2) head of femur within acetabulum | 6) intercondylar sulcus                | 10) condyles of tibiotalarsus  | 14) digit I                  | 18) digit III (four phalanges) |
| 3) pubis                           | 7) proximal extremity of tibiotalarsus | 11) intertarsal joint          | 15) tarsometatarsal trochlea | 19) digit IV                   |
| 4) femur                           | 8) fibula                              | 12) cotyles of tarsometatarsus | 16) digital pad              | 20) metatarsal I               |

**FIG 12.12** Craniocaudal xeroradiograph and radiograph of the pelvic limb in a normal Orange-winged Amazon Parrot (courtesy of Bonnie J. Smith and Stephen A. Smith).

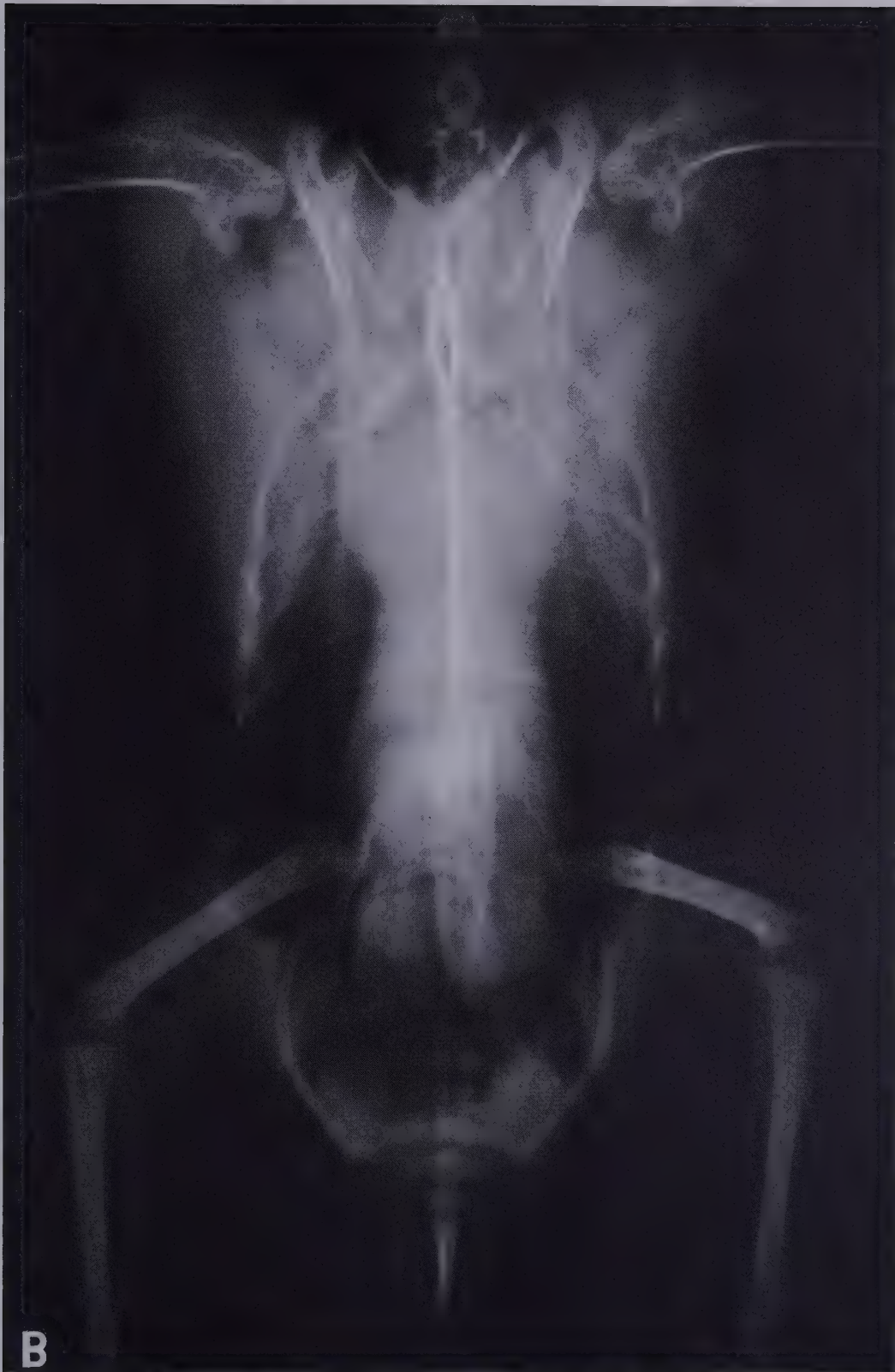

- 1) trachea
- 2) clavicular air sac
- 3) pectoral muscle
- 4) lung
- 5) heart
- 6) normal hour-glass constriction ("waist") of the heart-liver shadow

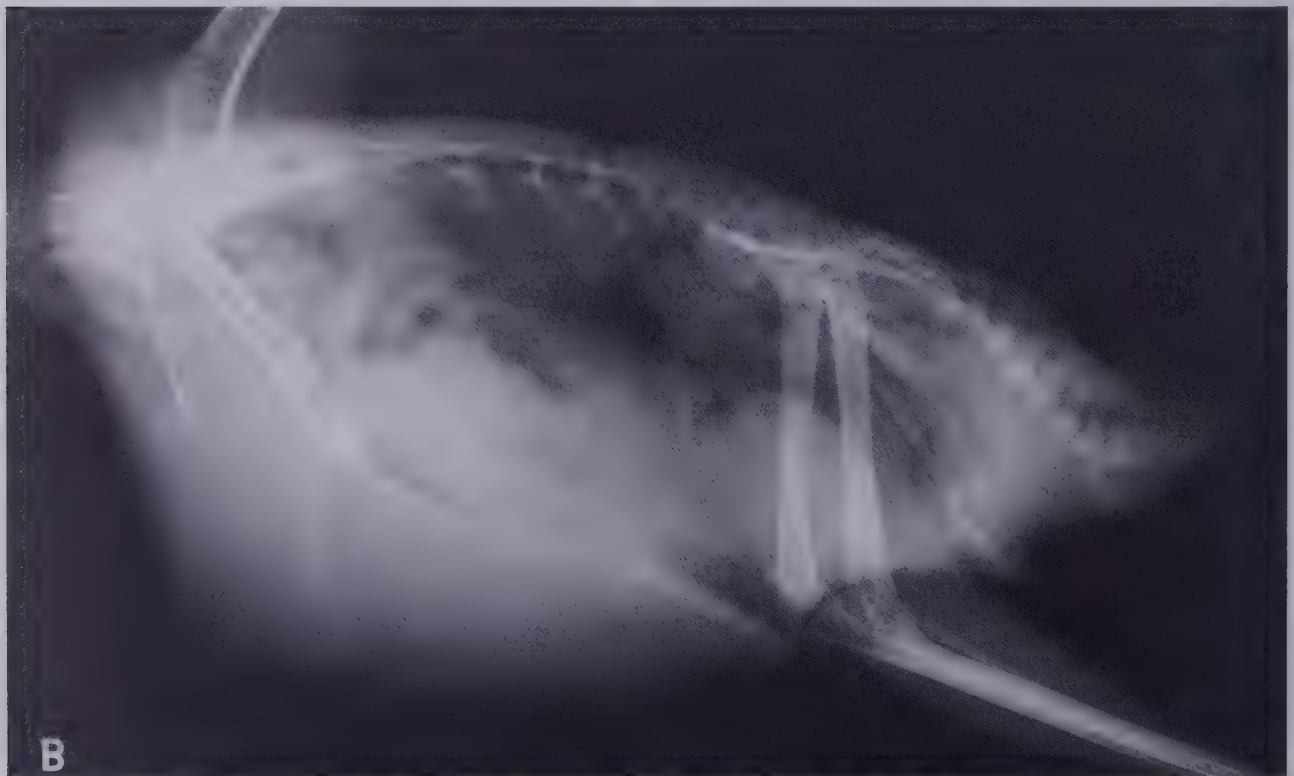

- 7) area of overlap of caudal thoracic and abdominal air sacs
- 8) spleen
- 9) liver
- 10) ventriculus
- 11) intestines
- 12) abdominal air sac
- 13) pygostyle

- 14) pubis
- 15) free caudal vertebra
- 16) synsacrum
- 17) sternum, ventral extremity of carina
- 18) notarium
- 19) caudal extremity of scapula
- 20) medial border of coracoid

- 21) ventral tubercle of humerus
- 22) head of humerus
- 23) dorsal tubercle of humerus
- 24) head of scapula
- 25) shoulder extremity of coracoid
- 26) clavicle

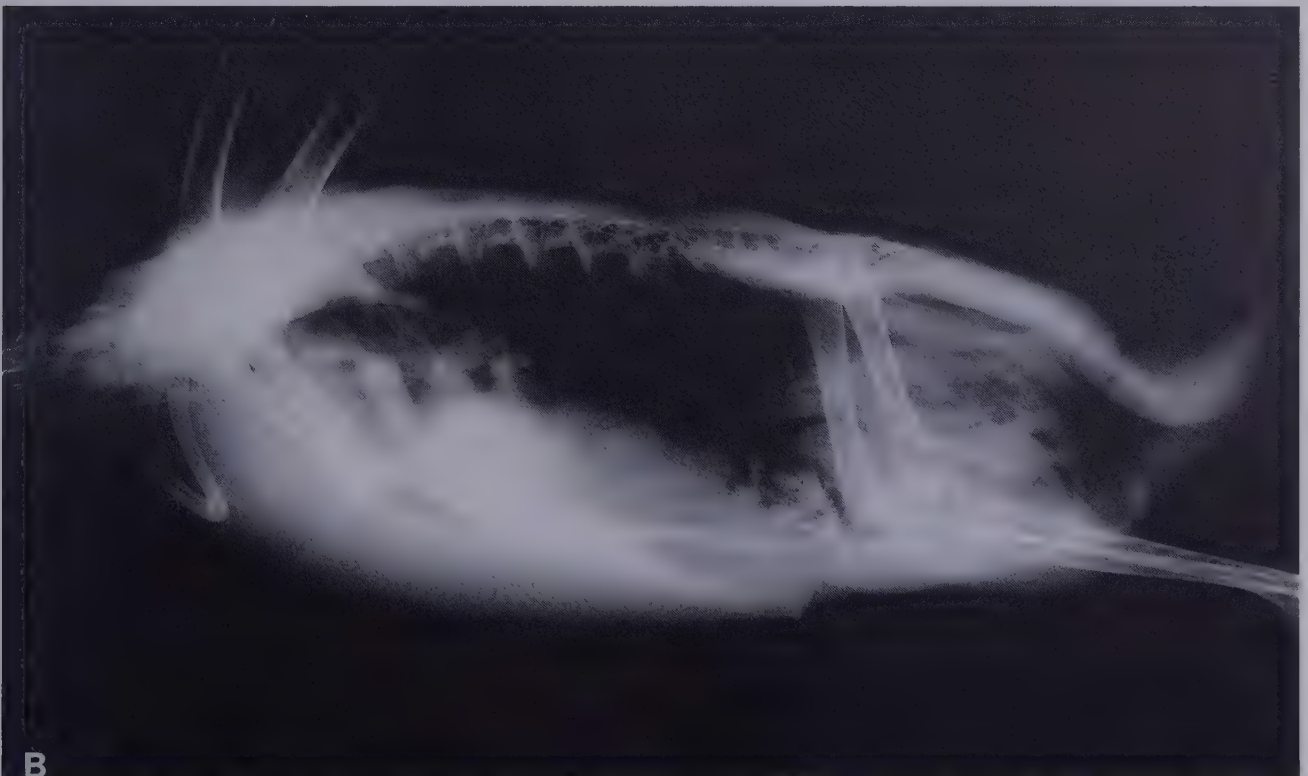
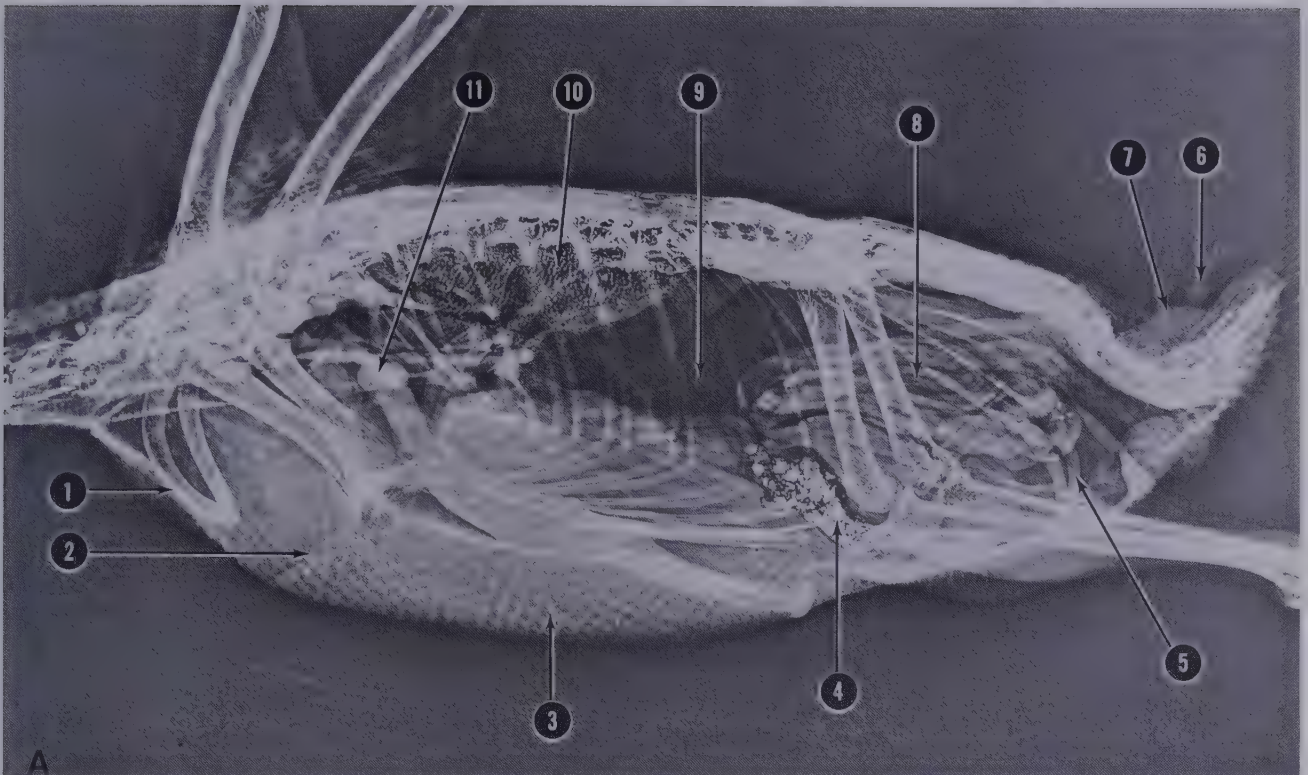


**FIG 12.13** Ventrodorsal xeroradiograph (facing page) and radiograph of a normal cockatiel (courtesy of Bonnie J. Smith and Stephen A. Smith).



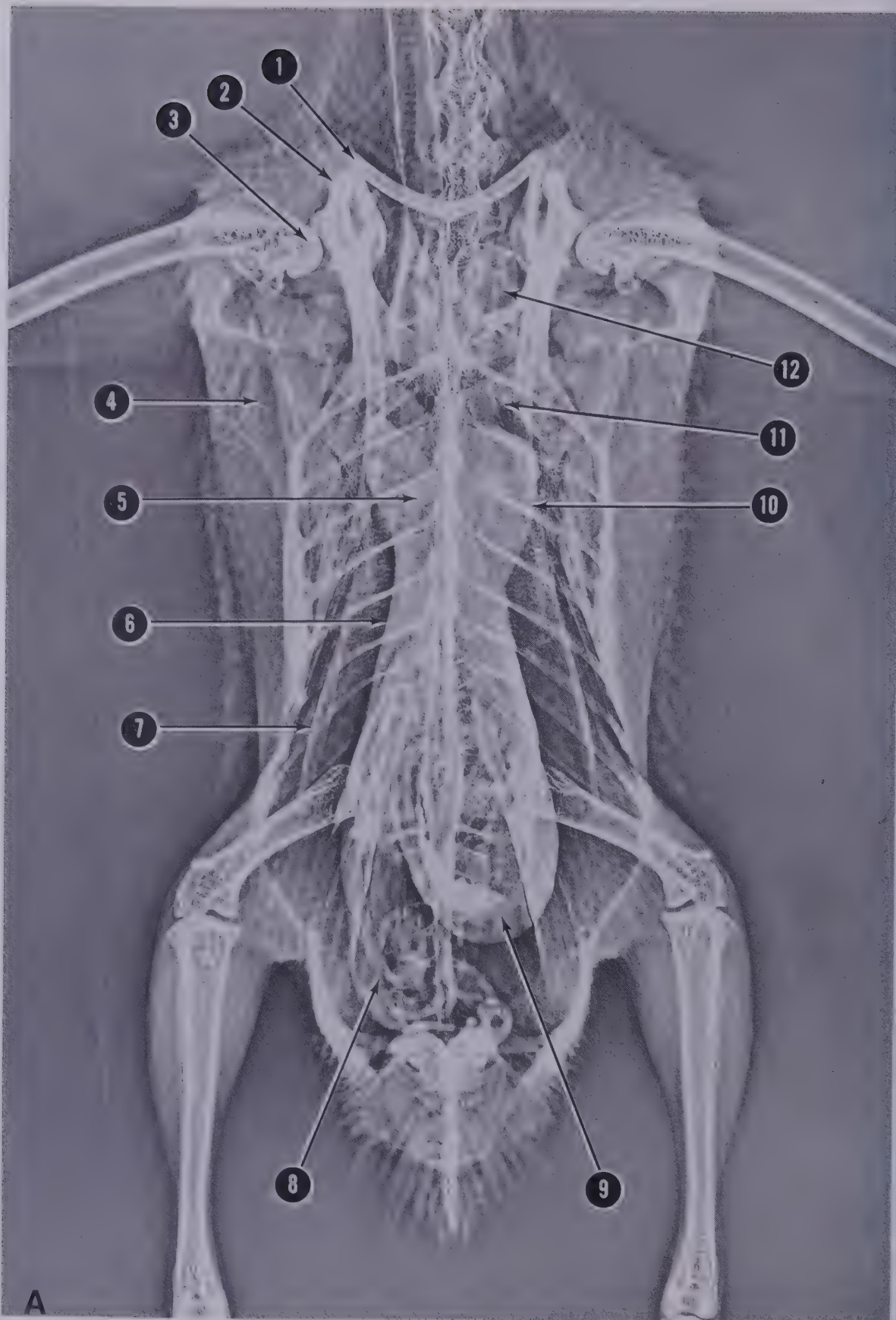- |                      |                         |                     |                                |                    |
|----------------------|-------------------------|---------------------|--------------------------------|--------------------|
| 1) cervical vertebra | 6) synsacrum            | 11) keel of sternum | 16) area of gonad              | 20) intestines     |
| 2) coracoid          | 7) free caudal vertebra | 12) clavicle        | 17) cranial division of kidney | 21) ventriculus    |
| 3) scapula           | 8) pygostyle            | 13) trachea         | 18) caudal division of kidney  | 22) proventriculus |
| 4) area of notarium  | 9) pubis                | 14) area of syrinx  | 19) vent                       | 23) liver          |
| 5) vertebral rib     | 10) sternal rib         | 15) lung            |                                | 24) heart          |

FIG 12.14 Lateral xeroradiograph and radiograph of a normal cockatiel (courtesy of Bonnie J. Smith and Stephen A. Smith).



- |   |                                      |  |
|---|--------------------------------------|--|
| 1) clavicle   | 4) ventriculus containing grit       | 9) abdominal air sac                                     |
| 2) cranial margin of keel of sternum<br>(note absence of concave curvature) | 5) pubis                             | 10) lung   |
| 3) feather follicles (note prominence<br>characteristic of Anseriformes)    | 6) papilla of uropygial gland        | 11) area of syrinx (note absence of bulla in<br>the hen) |
|   | 7) uropygial gland (note large size) |  |
|   | 8) intestines                        |  |

**FIG 12.15** Lateral xeroradiograph and radiograph of a normal Mallard Duck (courtesy of Bonnie J. Smith and Stephen A. Smith).

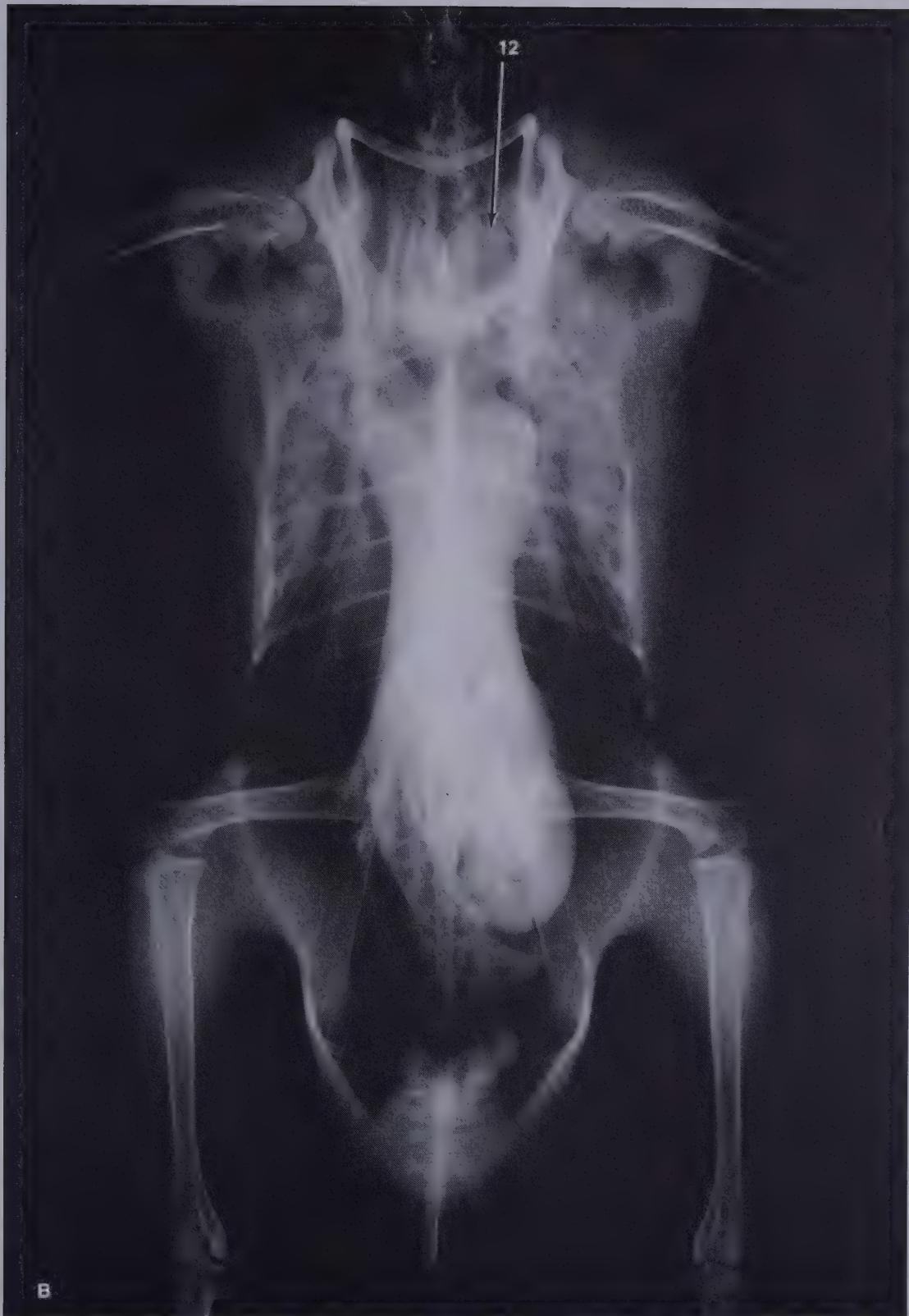

1) clavicle  
 2) shoulder extremity of coracoid base  
 3) head of humerus  
 4) feather follicle

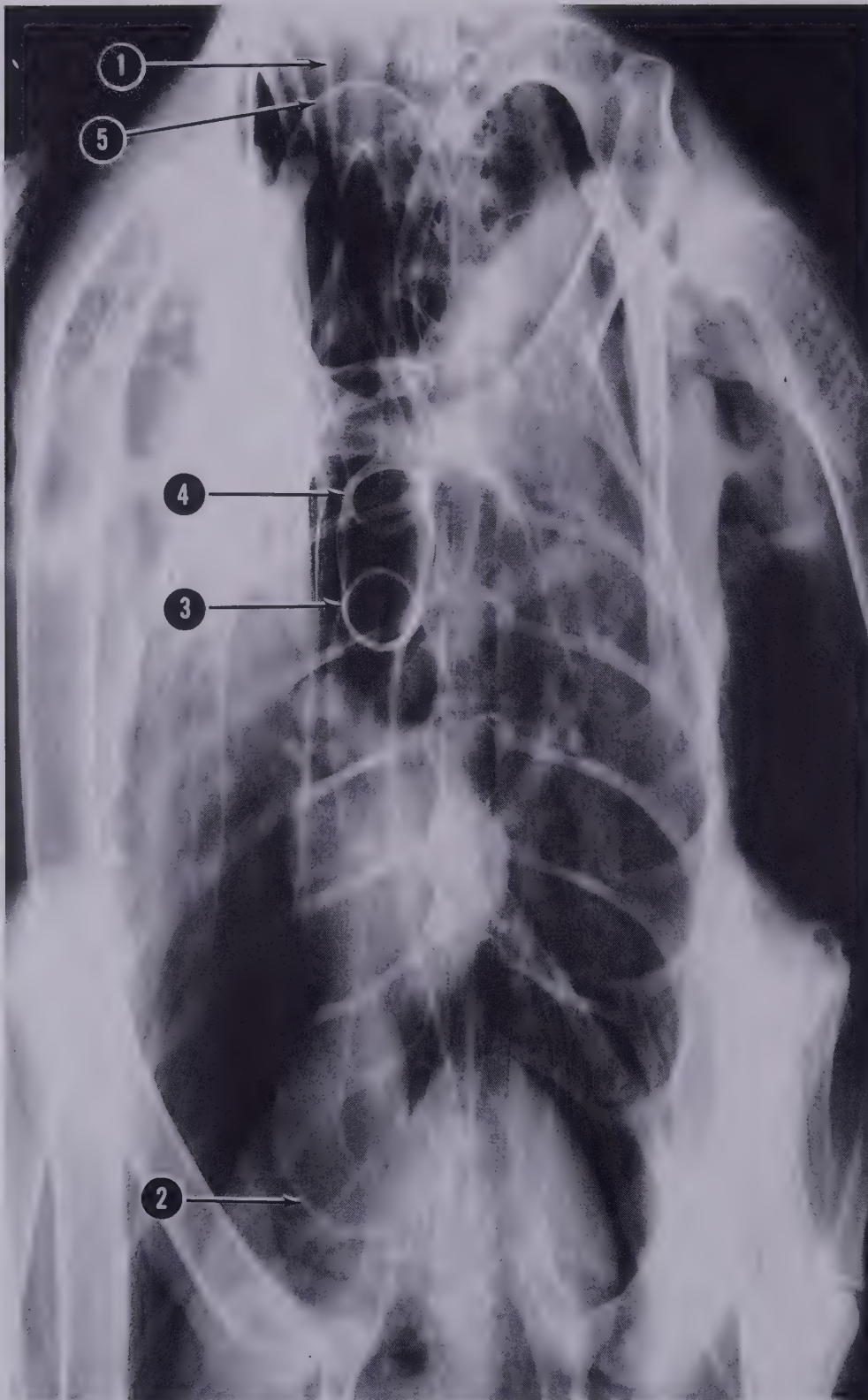
5) heart  
 6) liver  
 7) lateral caudal process of sternum  
 8) intestines

9) ventriculus containing grit  
 10) caudal extremity of scapula  
 11) left brachiocephalic trunk  
 12) cavity of syringeal bulla

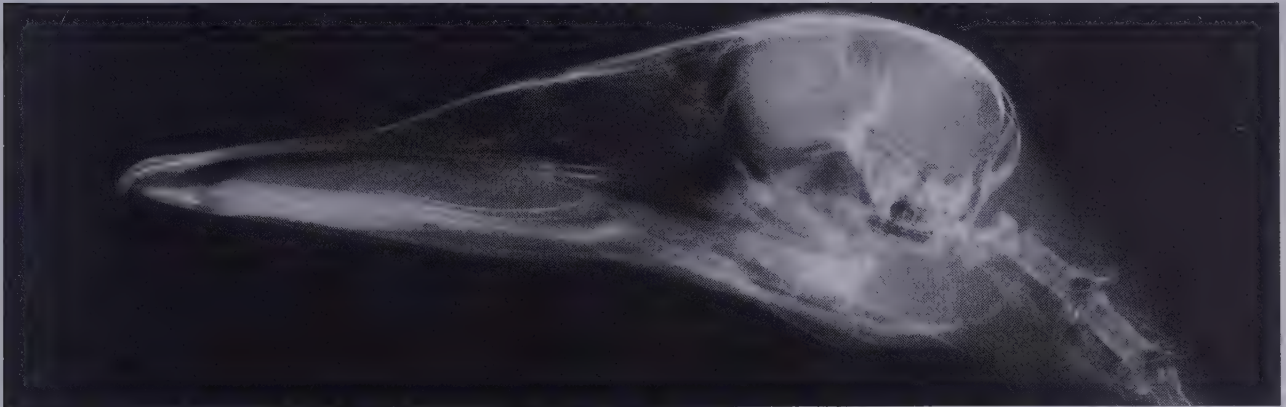
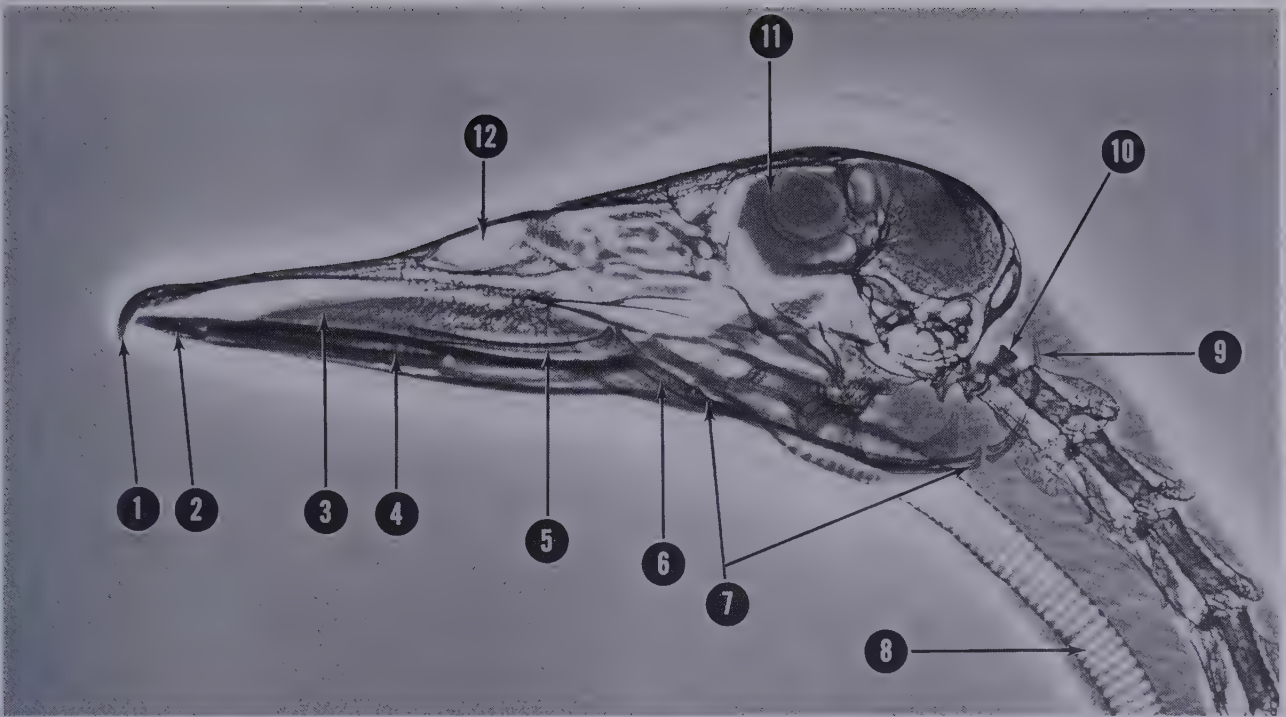




**FIG 12.16** Ventrrodorsal xeroradiograph (facing page) and radiograph of a normal male Mallard Duck (courtesy of Bonnie J. Smith and Stephen A. Smith).

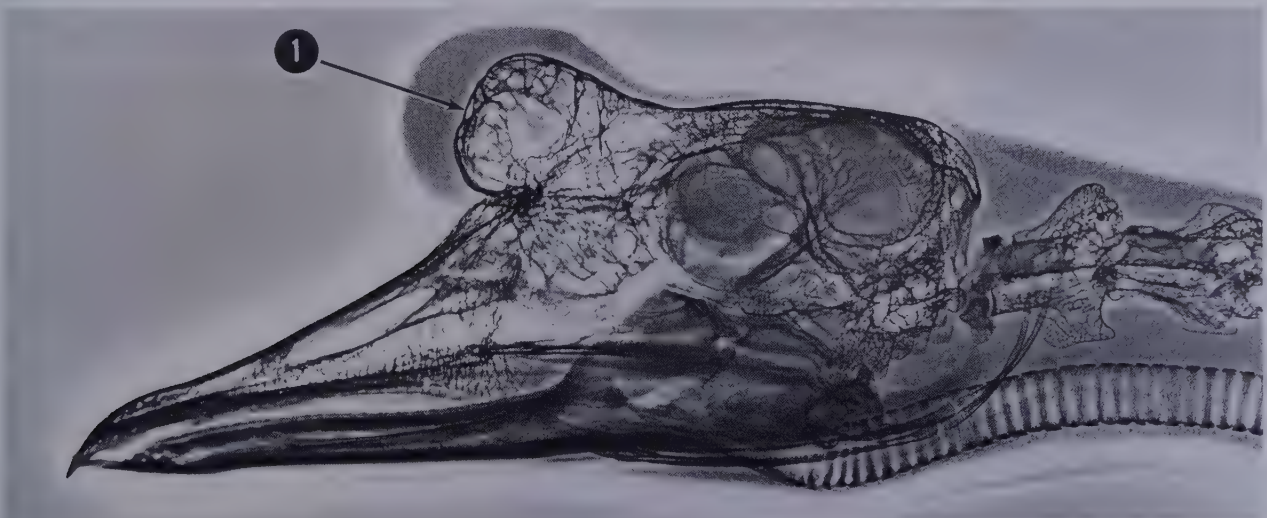


**FIG 12.17** Ventrals radiograph of a clinically normal Trumpeter Swan. In this species, the trachea is lengthened and is permanently curved within an excavation in the sternum. The 1) trachea enters the thoracic inlet, 2) courses caudally within the sternal excavation and re-curves cranially near the caudal end of the sternum. 3,4) A small loop is formed within the sternal excavation, which is visible as an end-on tubular view, and the trachea then courses 5) cranially to the thoracic inlet, where it re-curves and enters the syrinx (courtesy of Bonnie J. Smith and Stephen A. Smith).

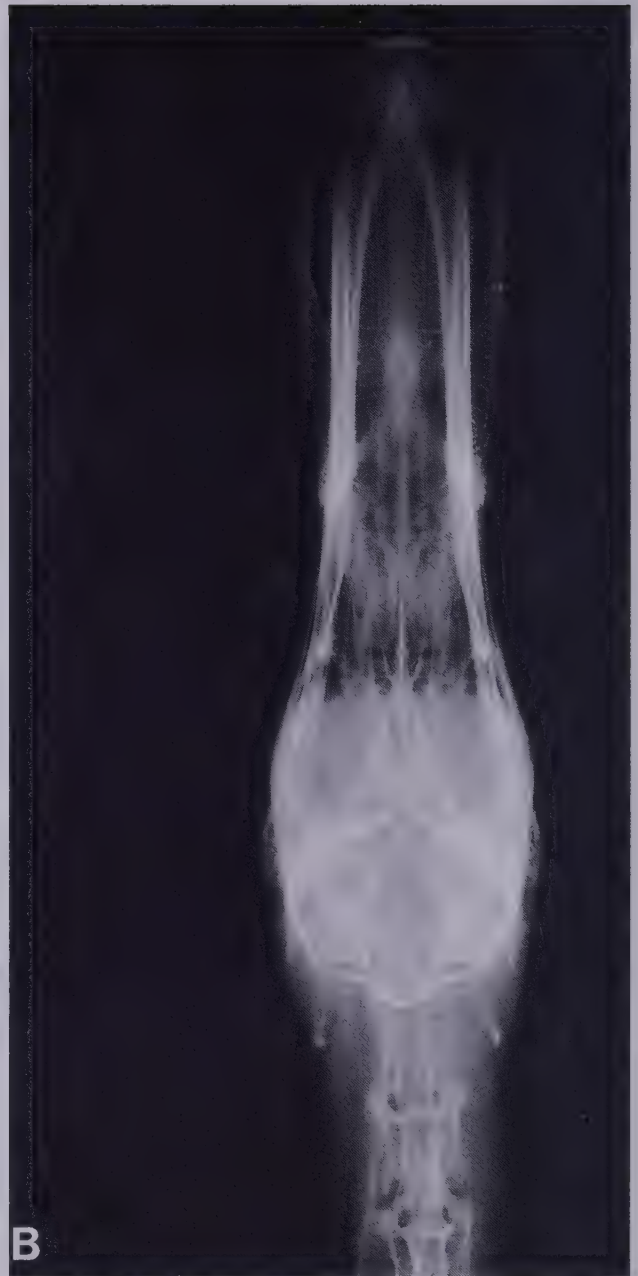
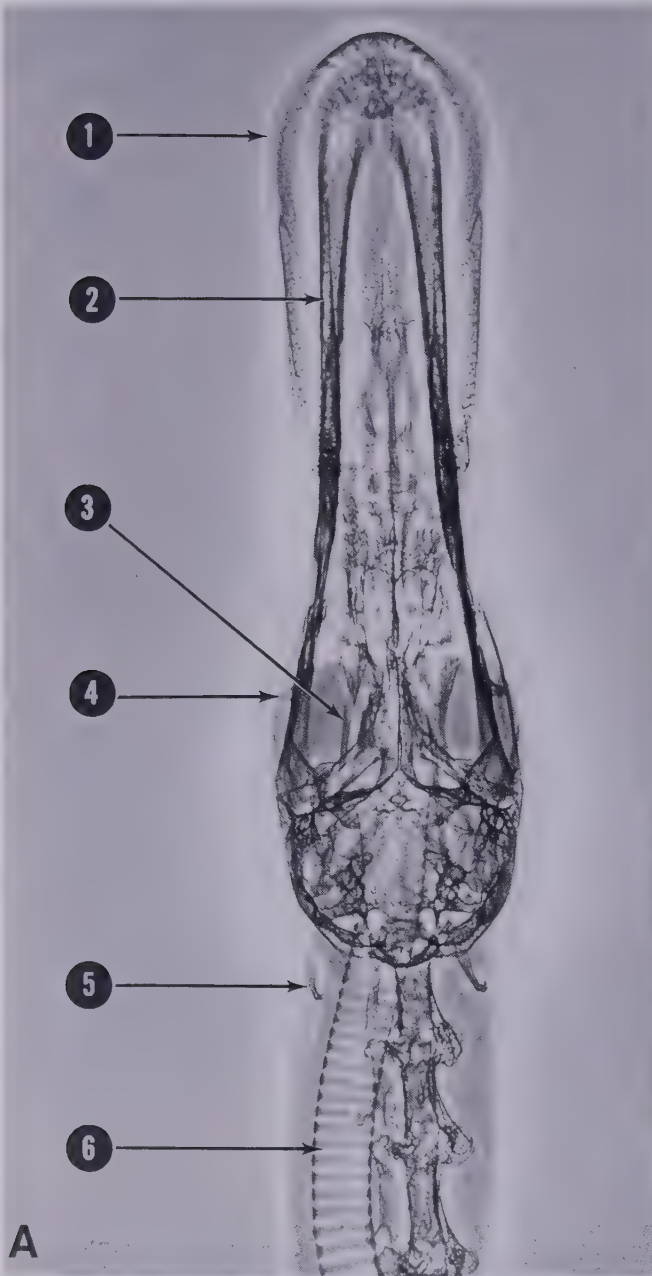


- |                         |  |   |                    |
|-------------------------|--|---|--------------------|
| 1) nail                 | 5) entoglossum of hyoid apparatus (note large size to support well developed tongue) | 8) trachea                              | 11) scleral ring   |
| 2) mandibular symphysis | 6) rostral basibranchial bone of hyoid apparatus                                     | 9) epibranchial bone of hyoid apparatus | 12) nasal aperture |
| 3) tongue               | 7) ceratobranchial bone of hyoid apparatus   | 10) atlas                               |                    |
| 4) lamellae of bill     |  |   |                    |

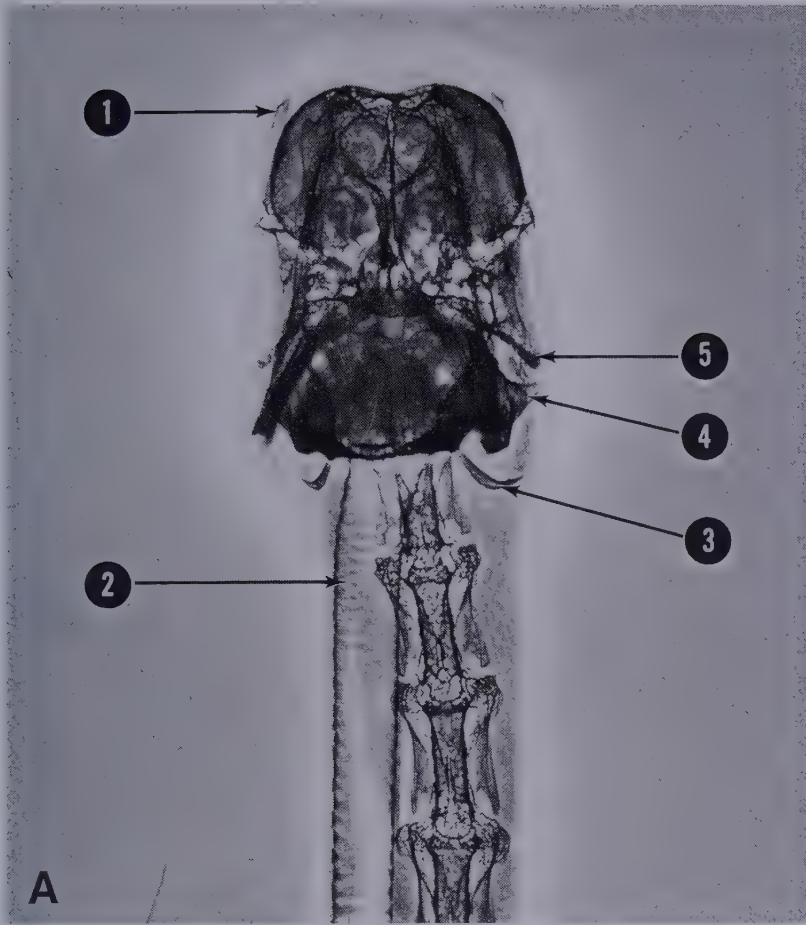
**FIG 12.18** Lateral xeroradiograph and radiograph of the head of a normal Mallard Duck (courtesy of Bonnie J. Smith and Stephen A. Smith).



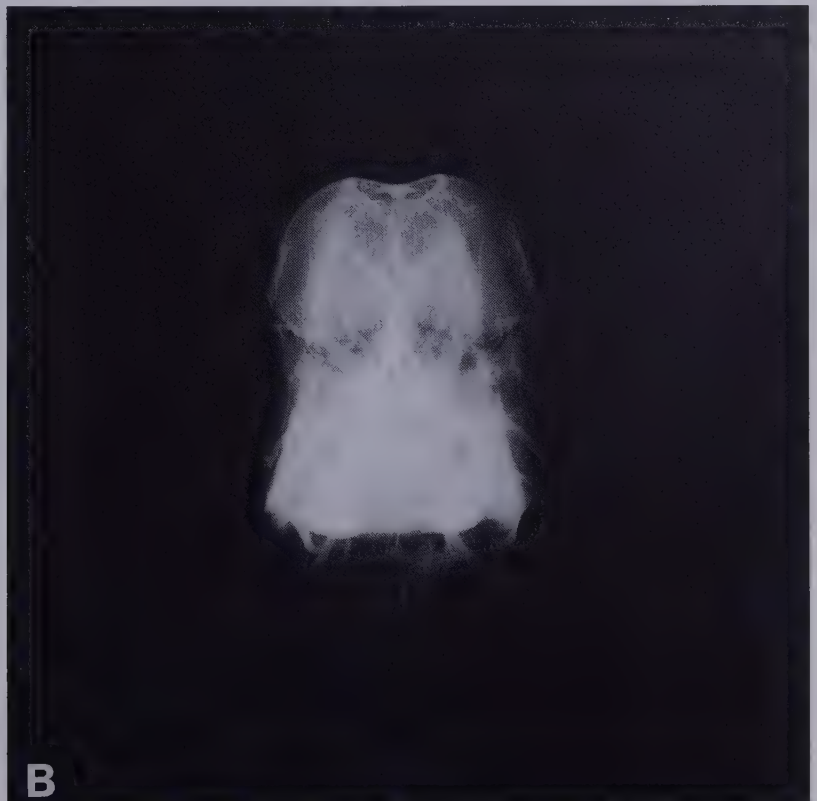
**FIG 12.19** Lateral xeroradiograph of the head of a Chinese Goose demonstrating the 1) frontal knob. Note the bony core of this structure and its well-developed soft tissue covering (courtesy of Bonnie J. Smith and Stephen A. Smith).

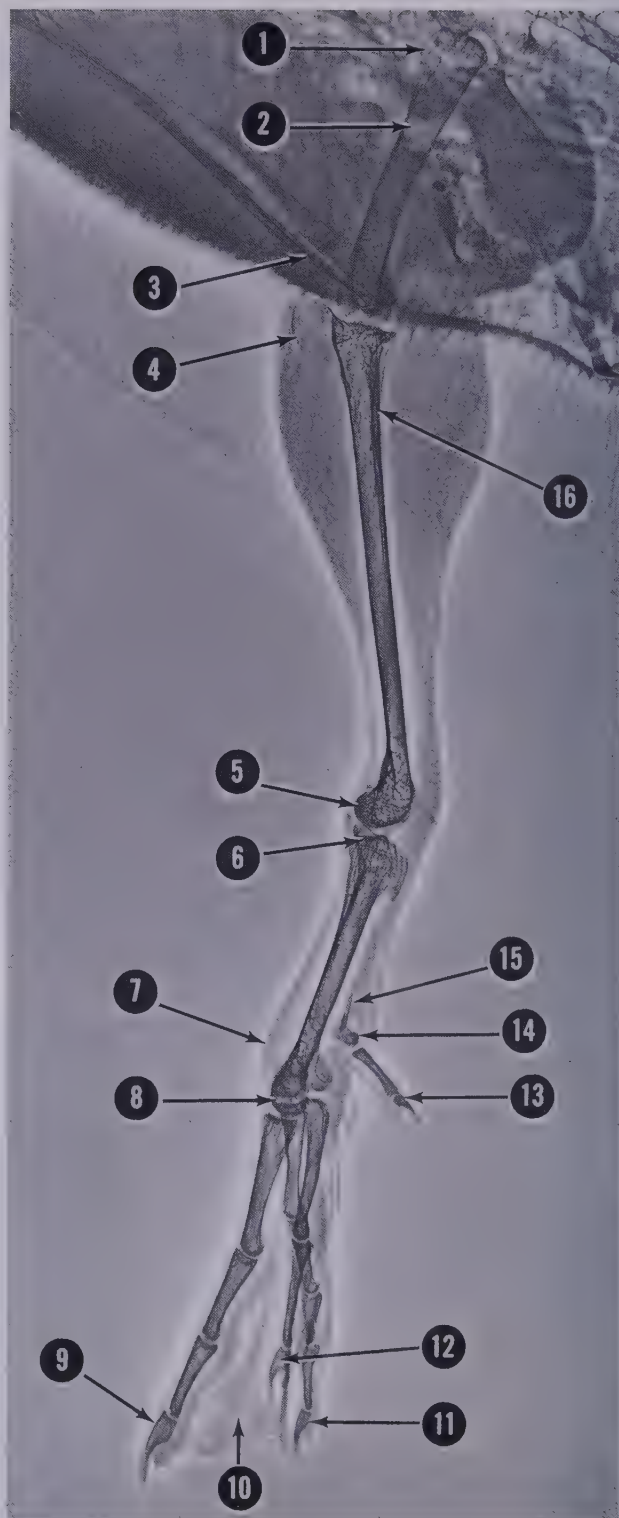
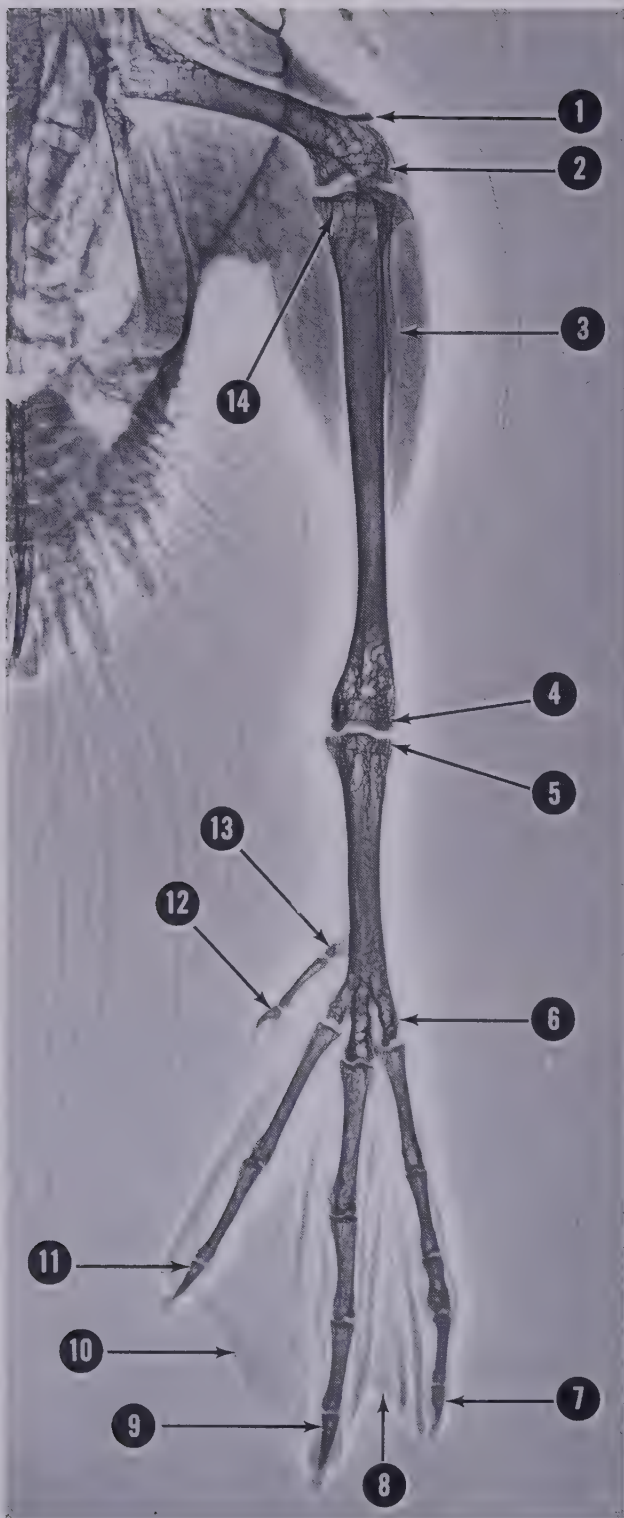


**FIG 12.20** Ventrordorsal xeroradiograph and radiograph of the head of a normal Mallard Duck. 1) upper bill covering premaxilla 2) mandible 3) ceratobranchial bone of hyoid apparatus 4) scleral ring 5) epibranchial bone of hyoid apparatus 6) trachea (courtesy of Bonnie J. Smith and Stephen A. Smith).



**FIG 12.21** Rostrocaudal view of xeroradiograph and radiograph of the head of a normal Mallard Duck. 1) scleral ring 2) trachea 3) ceratobranchial bone of hyoid apparatus 4) mandible 5) jugal arch (zygomatic arch) (courtesy of Bonnie J. Smith and Stephen A. Smith).

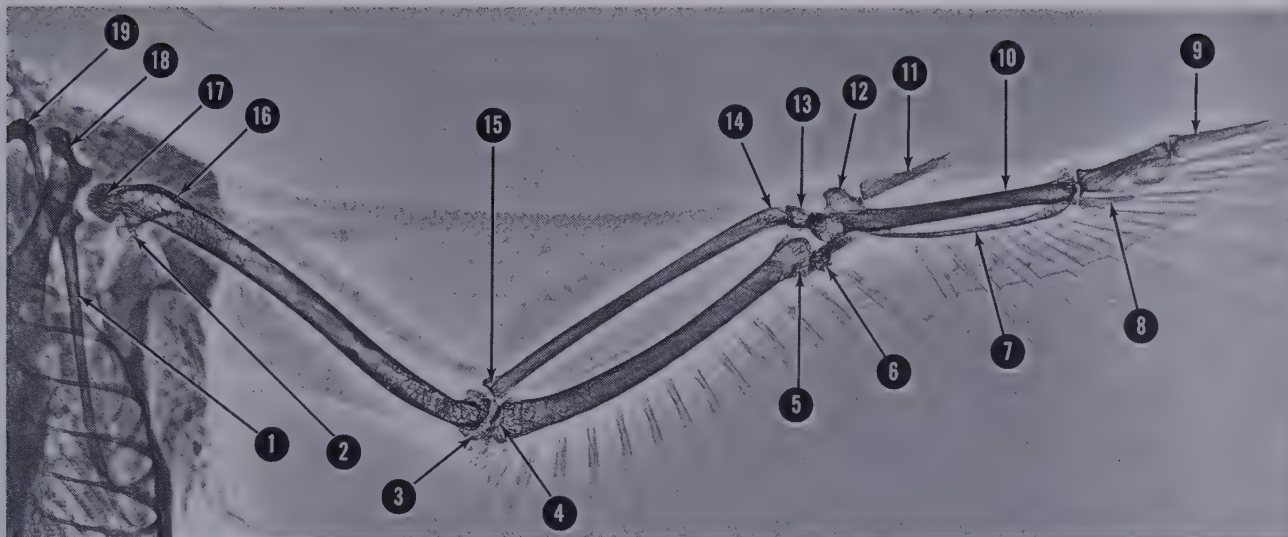




- 1) patella
- 2) condyles of femur
- 3) fibula
- 4) condyle of tibiotarsus
- 5) cotyle of tarsometatarsus
- 6) tarsometatarsal trochlea for digit IV
- 7) distal phalanx of digit IV
- 8) lateral interdigital web
- 9) distal phalanx of digit III
- 10) intermediate interdigital web
- 11) distal phalanx of digit II
- 12) distal phalanx of digit I
- 13) metatarsal bone I
- 14) proximal tibiotarsus

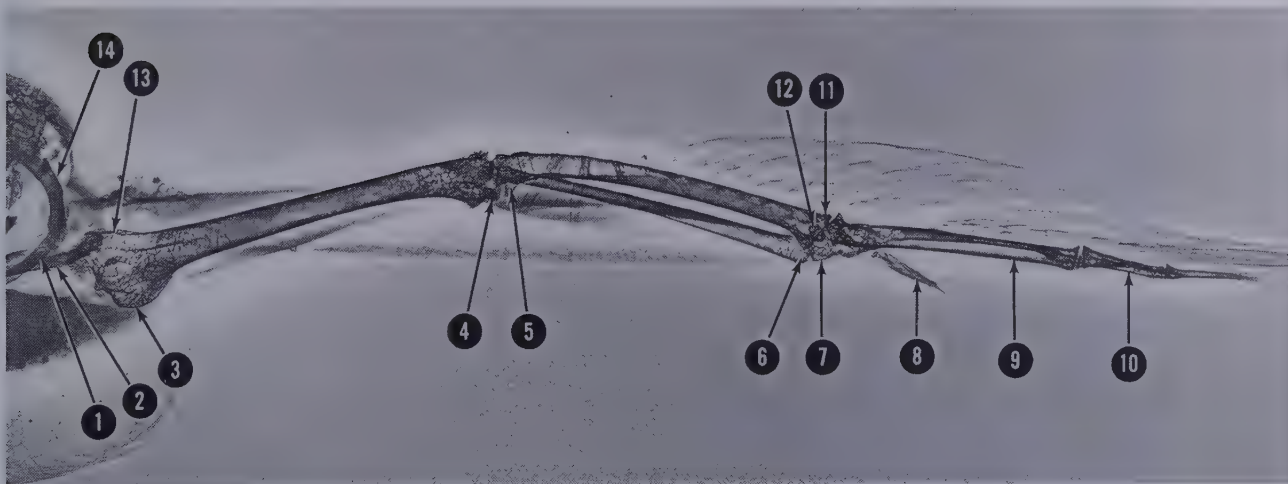
- 1) greater trochanter of femur
- 2) femur
- 3) patella, superimposed over keel
- 4) cnemial crest of tibiotarsus
- 5) condyles of tibiotarsus
- 6) cotyles of tarsometatarsus
- 7) podotheca (unfeathered skin covering pes)
- 8) trochlea of tarsometatarsus
- 9) distal (fourth phalanx) of digit III (note horny nail covering bony core)
- 10) interdigital web
- 11) distal (fifth) phalanx of digit IV
- 12) distal (third) phalanx of digit II
- 13) distal (second) phalanx of digit I
- 14) metatarsal bone I
- 15) ossification within digital tendon
- 16) fibula, superimposed with body of tibiotarsus

**FIG 12.22** Craniocaudal xeroradiograph (left) and mediolateral xeroradiograph (right) of the pelvic limb of a normal Mallard Duck (courtesy of Bonnie J. Smith and Stephen A. Smith).



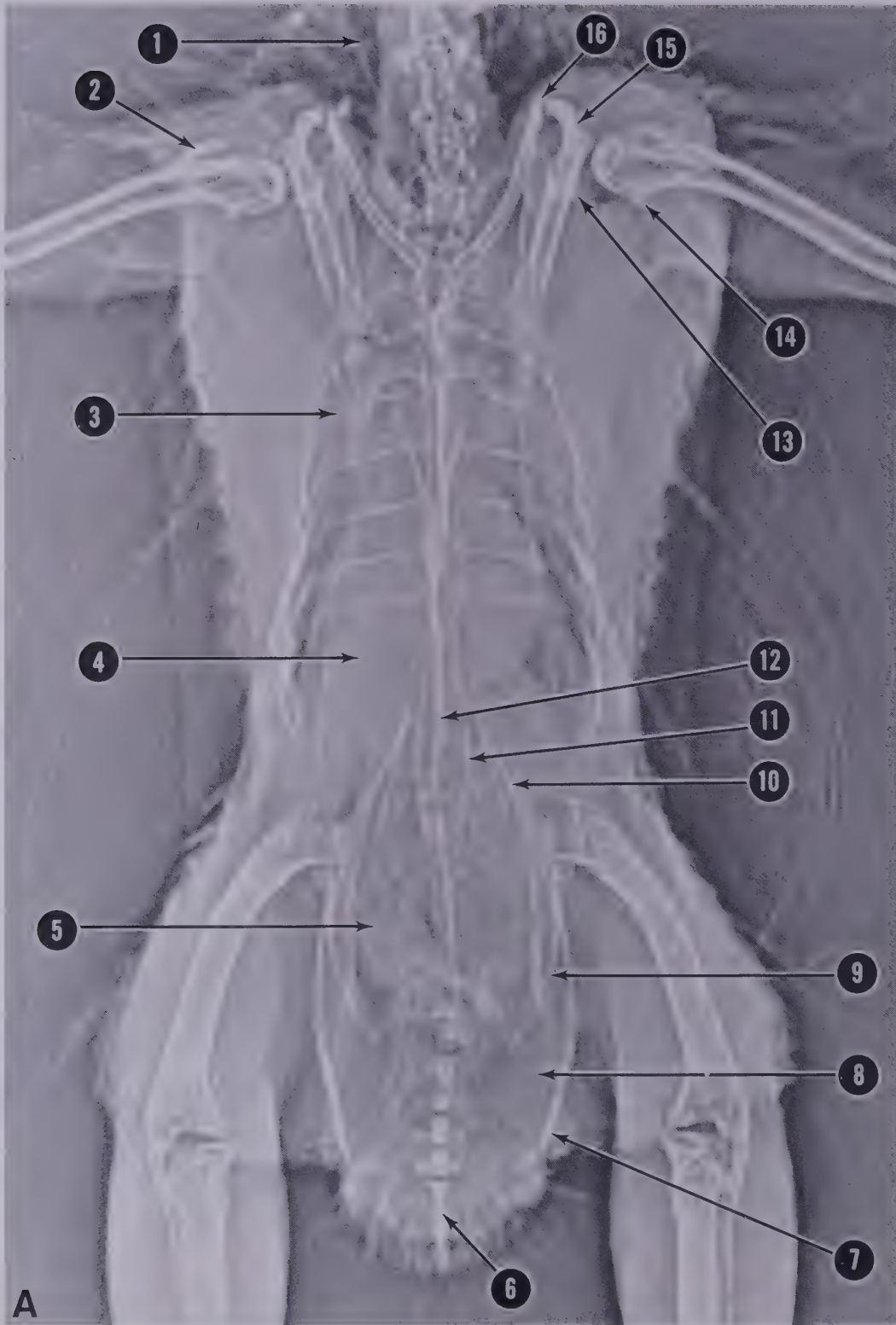- |                                |  |   |  |
|--------------------------------|--|---|--|
| 1) body of scapula             | 7) minor metacarpal bone                     | 12) extensor of alular meta-<br>carpal bone | 17) head of humerus                      |
| 2) ventral tubercle of humerus | 8) minor digit (consisting of one phalanx)   | 13) radial carpal bone                      | 18) should extremity of<br>coracoid bone |
| 3) condyles of humerus         | 9) major digit (consisting of two phalanges) | 14) distal extremity of radius              | 19) clavicle                             |
| 4) olecranon of ulna           | 10) major metacarpal bone                    | 15) head of radius                          |  |
| 5) condyles of ulna            | 11) alular digit                             | 16) pectoral crest of humerus               |  |
| 6) ulnar carpal bones          |  |   |  |

**FIG 12.23** Ventrodorsal xeroradiograph of the wing of a normal Mallard Duck (courtesy of Bonnie J. Smith and Stephen A. Smith).



- |  |   |  |
|--|---|--|
| 1) clavicle                              | 7) radial carpal bone                               | 11) distal extremity of ulna                                       |
| 2) coracoid bone                         | 8) alular digit                                     | 12) ulnar carpal bone superimposed over other<br>carpal structures |
| 3) pectoral crest of humerus             | 9) superimposed major and minor metacarpal<br>bones | 13) humerus  |
| 4) condyles of humerus                   | 10) superimposed major and minor digits             | 14) scapula  |
| 5) superimposed proximal radius and ulna |   |  |
| 6) distal extremity of radius            |   |  |

**FIG 12.24** Craniocaudal xeroradiograph of the wing of a normal Mallard Duck (courtesy of Bonnie J. Smith and Stephen A. Smith).

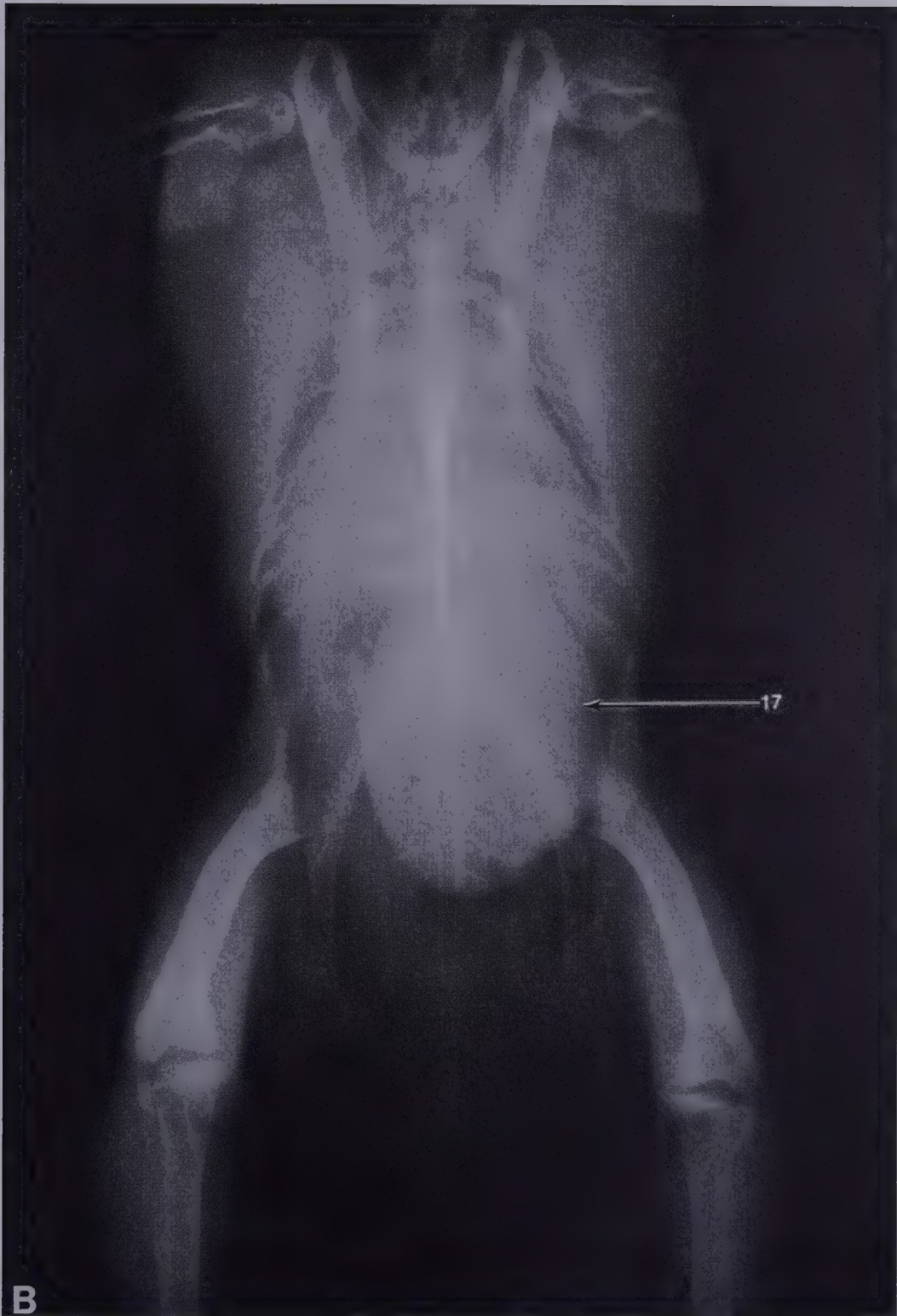

- 1) trachea
- 2) feather shaft (rachis)
- 3) vertebral rib)
- 4) liver
- 5) intestines
- 6) pygostyle

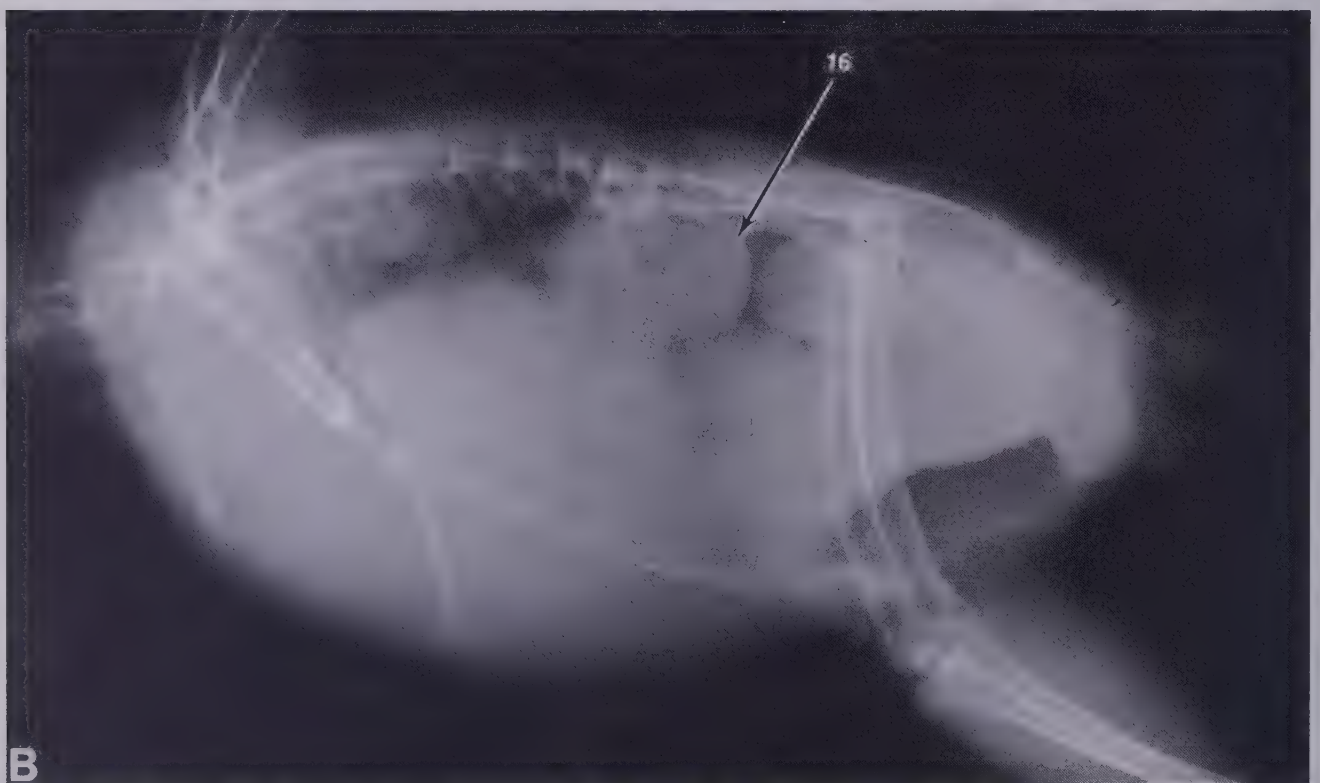
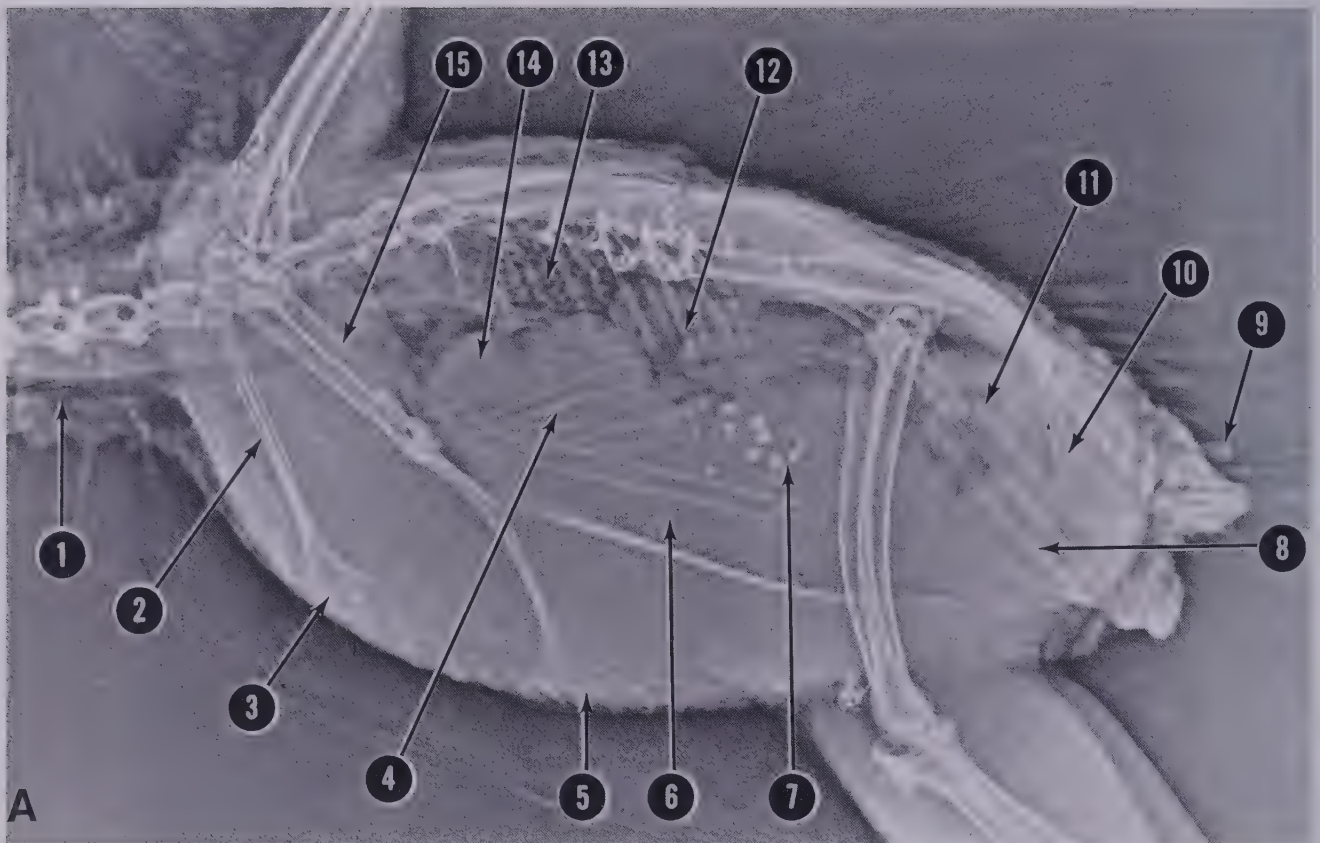
- 7) pubis
- 8) terminal process of ischium
- 9) postacetabular portion of ilium
- 10) preacetabular portion of ilium
- 11) synsacrum
- 12) ventral extremity of carina (keel)

- 13) head of scapula
- 14) ventral tubercle of humerus
- 15) shoulder extremity of coracoid
- 16) shoulder extremity of oviduct
- 17) egg within magnum of oviduct



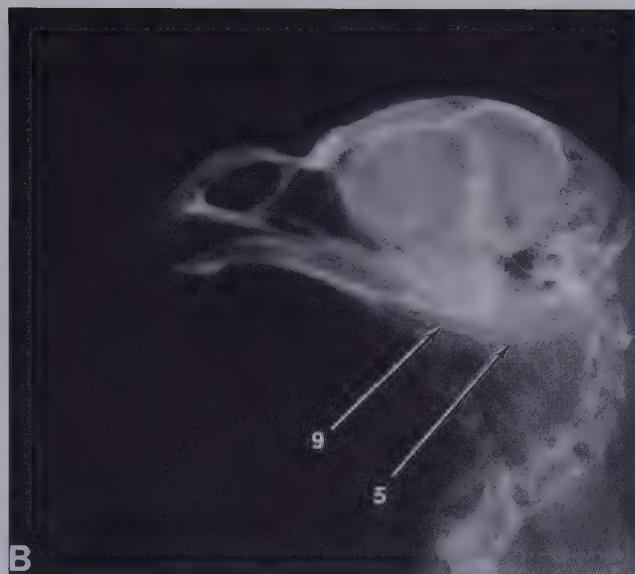
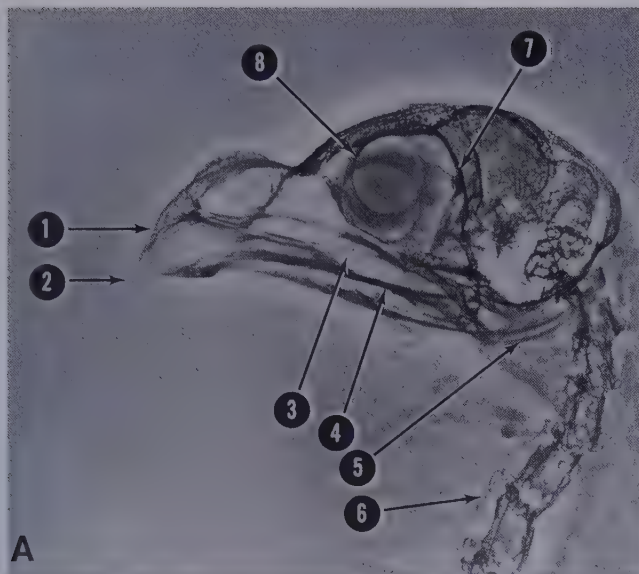


**FIG 12.25** Ventrodorsal xeroradiograph (facing page) and radiograph of a normal female Bobwhite Quail (courtesy of Bonnie J. Smith and Stephen A. Smith).

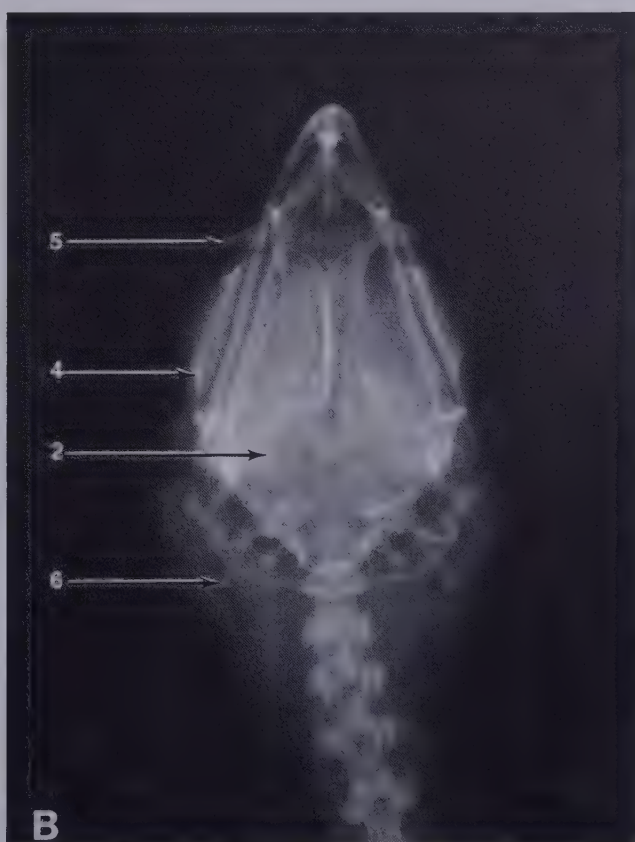
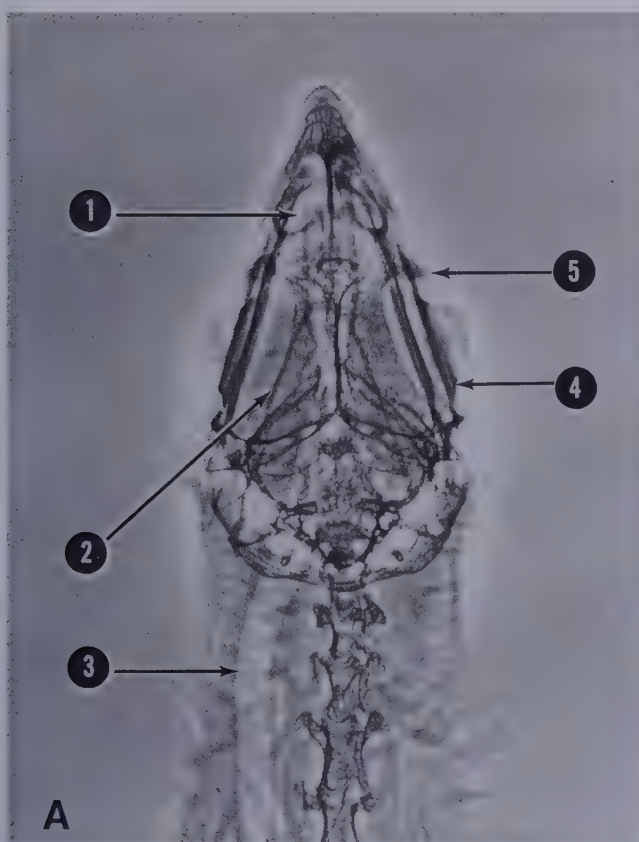
- |   |                                |                                 |                   |                       |
|---|--------------------------------|---------------------------------|-------------------|-----------------------|
| 1) trachea  | 4) sternal rib                 | 8) pubis                        | 12) vertebral rib | 15) coracoid          |
| 2) clavicle   | 5) carina (keel)               | 9) papilla of uropygial gland   | 13) lung          | 16) follicle on ovary |
| 3) clavicle at point of fusion into furcula (note hooked shape) | 6) area of liver               | 10) terminal process of ischium | 14) heart         |                       |
|   | 7) ventriculus containing grit | 11) intestines                  |                   |                       |

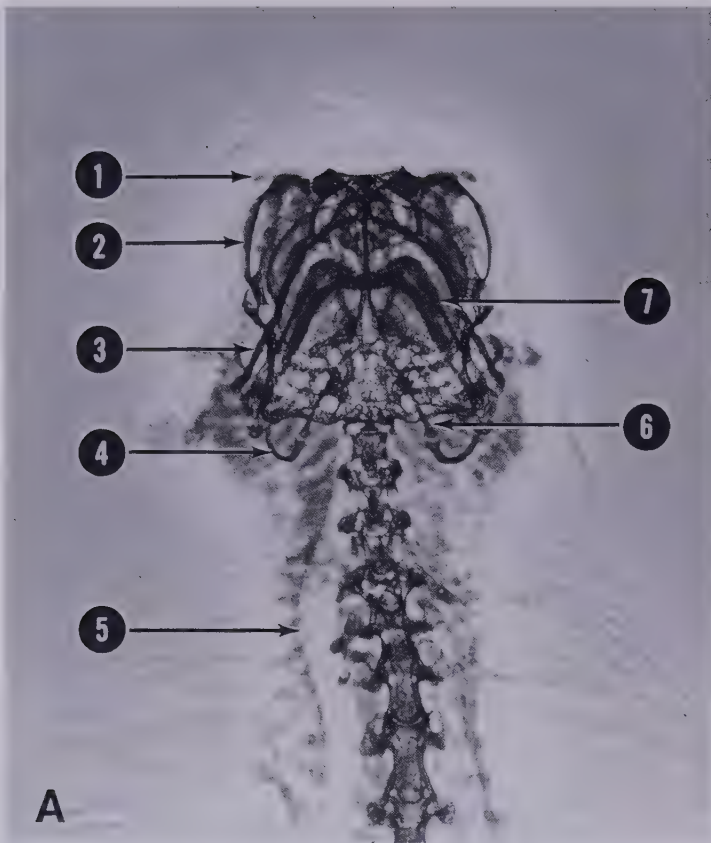
**FIG 12.26** Lateral xeroradiograph and radiograph of a normal female Bobwhite Quail. Note the short, heavy muscled, rotund body and compact viscera. Differentiation between the heart and the liver is difficult (courtesy of Bonnie J. Smith and Stephen A. Smith).



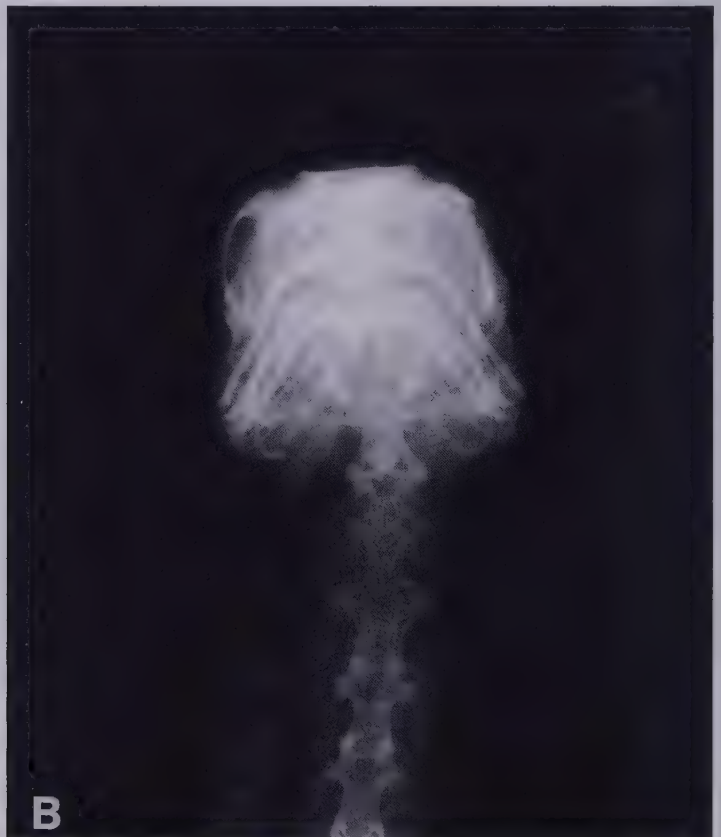**FIG 12.27** Lateral xeroradiograph and radiograph of the head of a normal Bobwhite Quail. 1) premaxilla 2) rhinotheca covering premaxilla 3) jugal arch (zygomatic arch) 4) mandible 5) ceratobranchial bone of hyoid apparatus 6) cervical rib on cervical vertebra 7) caudal edge of orbit 8) scleral ring 9) rostral basibranchial bone of hyoid apparatus (courtesy of Bonnie J. Smith and Stephen A. Smith).

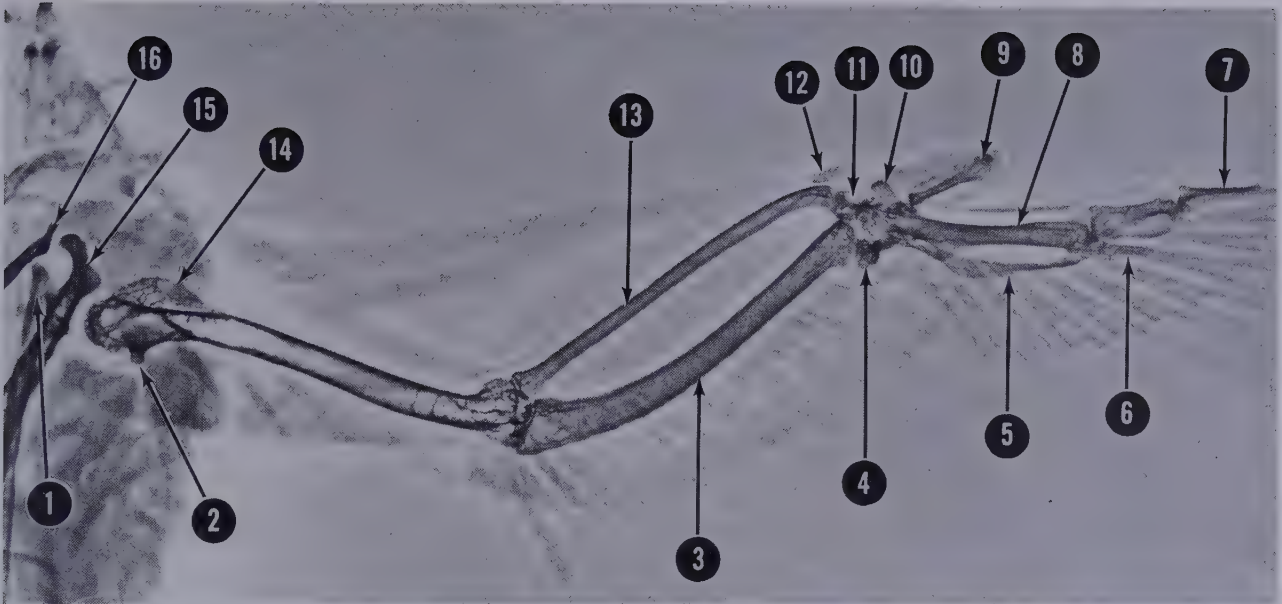


**FIG 12.28** Ventrals xeroradiograph and radiograph of the head of a normal Bobwhite Quail. 1) nares 2) ceratobranchial bone of hyoid apparatus 3) trachea 4) scleral ring 5) lacrimal bone 6) epibranchial bone of hyoid apparatus (courtesy of Bonnie J. Smith and Stephen A. Smith).



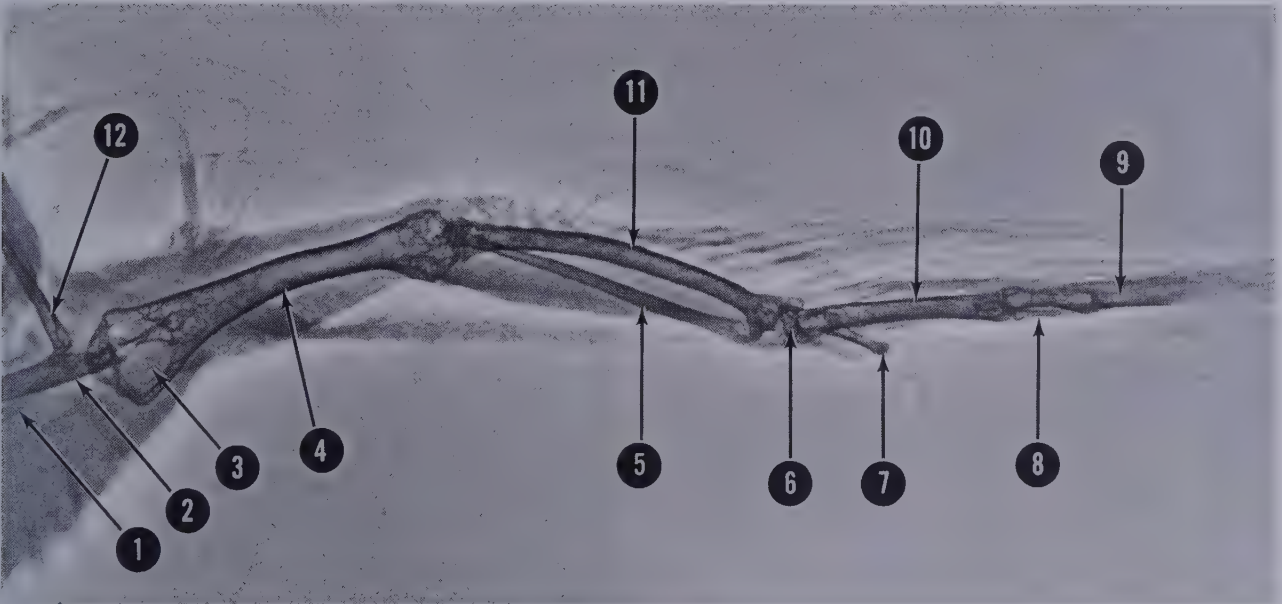
**FIG 12.29** Rostrocaudal xeroradiograph and radiograph of the head of a normal Bobwhite Quail. 1) lacrimal bone 2) scleral ring 3) jugal arch (zygomatic arch) 4) epibranchial bone of hyoid apparatus 5) trachea 6) ceratobranchial bone of hyoid apparatus 7) mandible (courtesy of Bonnie J. Smith and Stephen A. Smith).





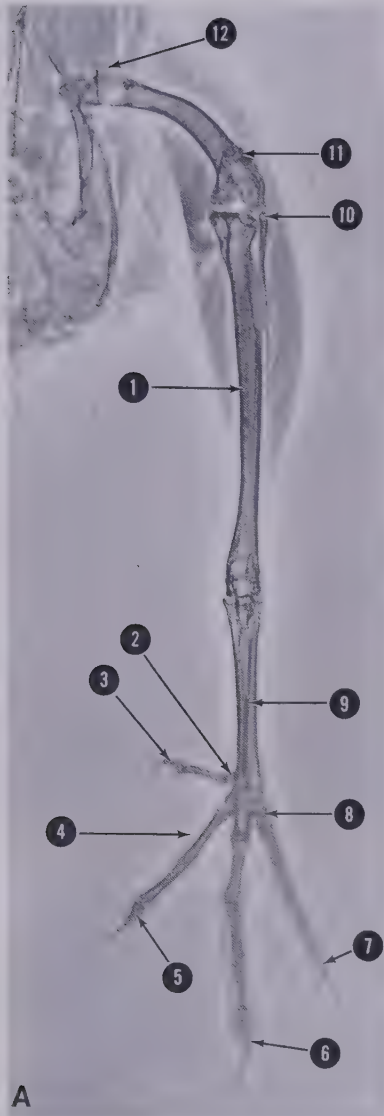
- |                                |  |   |   |
|--------------------------------|--|---|---|
| 1) head of scapula             | 6) minor digit (consisting of one phalanx)   | 10) extensor process of alular meta carpal bone     | 13) radius                              |
| 2) ventral tubercle of humerus | 7) major digit (consisting of two phalanges) | 11) radial carpal bone                              | 14) pectoral crest of humerus           |
| 3) ulna                        | 8) major metacarpal bone                     | 12) sesamoid bone in tendon of tensor propatagialis | 15) shoulder extremity of coracoid bone |
| 4) ulnar carpal bone           | 9) alular digit                              |   | 16) shoulder extremity of clavicle      |
| 5) minor metacarpal bone       |  |   |   |

**FIG 12.30** Ventrodorsal xeroradiograph of the wing of a normal Bobwhite Quail (courtesy of Bonnie J. Smith and Stephen A. Smith).

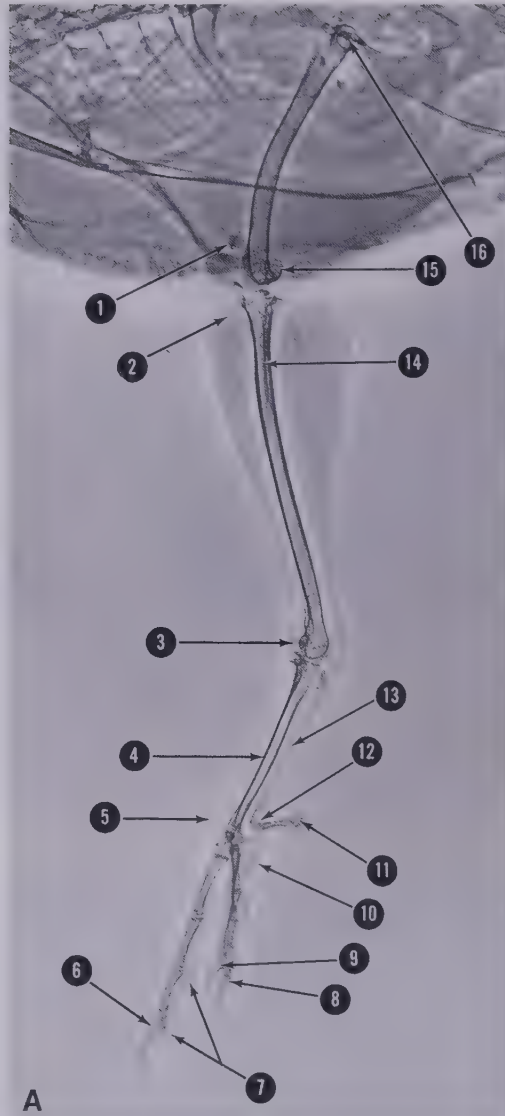


- |  |   |   |
|--|---|---|
| 1) clavicle  | 5) radius                                     | 9) distal phalanx of major digit                  |
| 2) shoulder extremity of coracoid bone                                 | 6) superimposed radial and ulnar carpal bones | 10) superimposed major and minor metacarpal bones |
| 3) pneumatic foramen of humerus (point of entry of clavicular air sac) | 7) alular digit                               | 11) ulna  |
| 4) humerus   | 8) minor digit                                | 12) scapula                                       |

**FIG 12.31** Craniocaudal xeroradiograph of the wing of a normal Bobwhite Quail (courtesy of Bonnie J. Smith and Stephen A. Smith).



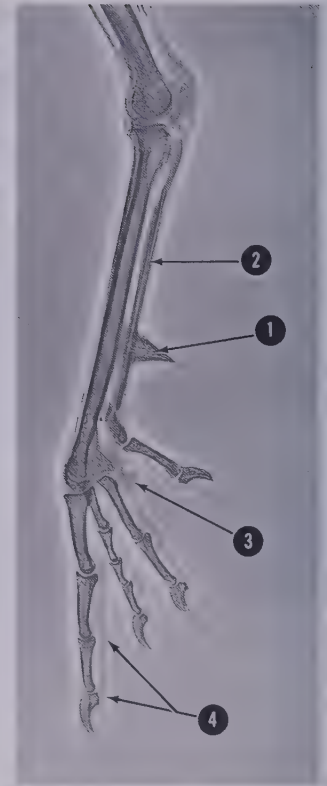
- 1) tibiotarsus
- 2) metatarsal bone I
- 3) distal phalanx of digit I
- 4) podotheca
- 5) distal phalanx of digit II
- 6) distal phalanx of digit III
- 7) distal phalanx of digit IV
- 8) tarsometatarsal trochlea for digit IV
- 9) tarsometatarsus
- 10) fibula
- 11) patella
- 12) greater trochanter of femur



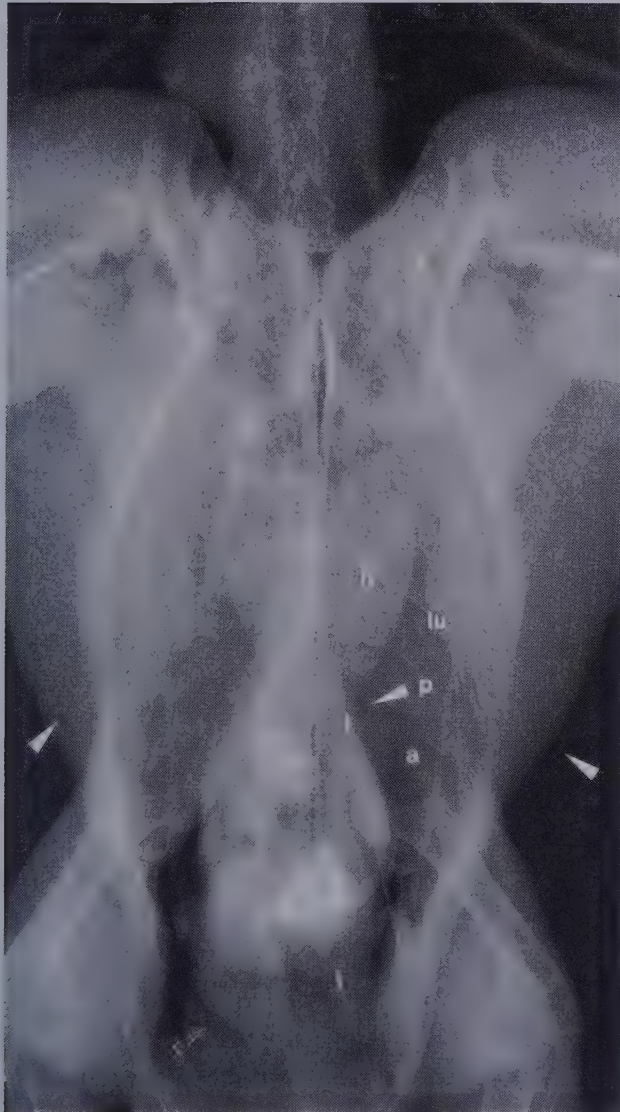
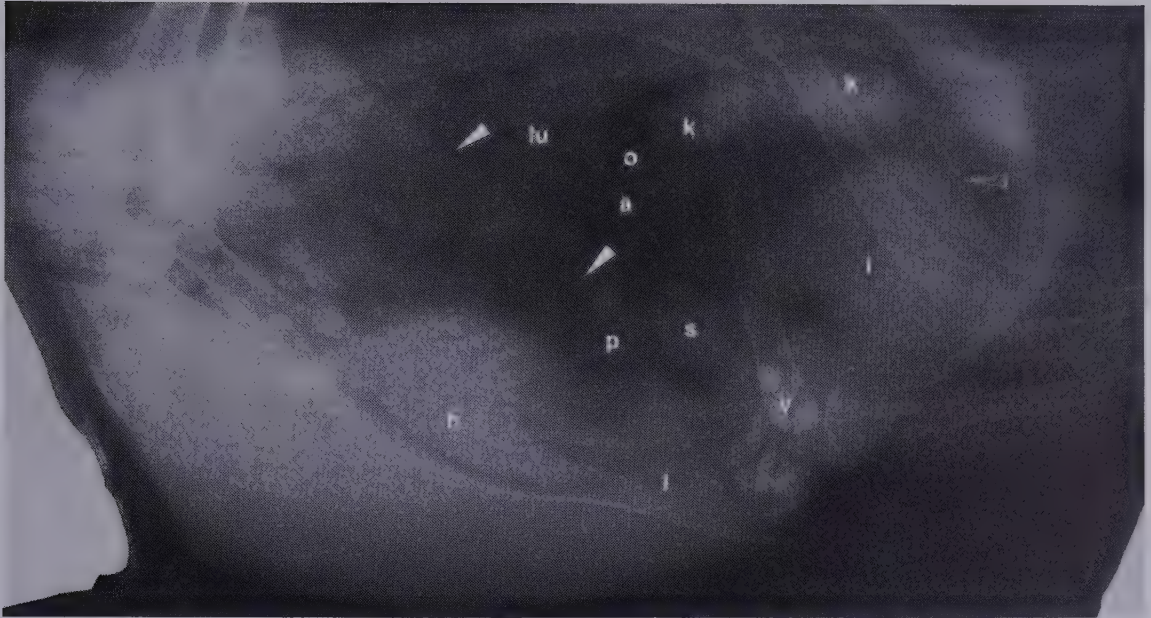
- 1) patella
- 2) cnemial crest of tibiotarsus
- 3) condyles of tibiotarsus
- 4) tarsometatarsus
- 5) podotheca
- 6) distal (fourth) phalanx of digit III (note horny nail covering bony core)
- 7) digital pads
- 8) distal (fifth) phalanx of digit IV
- 9) distal (third) phalanx of digit II
- 10) metatarsal pad
- 11) distal (second) phalanx of digit I
- 12) metatarsal bone I
- 13) mineralized tendons of digital flexor muscles
- 14) fibula, superimposed on body of tibiotarsus
- 15) condyles of femur
- 16) head of femur within acetabulum

**FIG 12.32** Craniocaudal xeroradiograph of the pelvic limb of a normal Bobwhite Quail (courtesy of Bonnie J. Smith and Stephen A. Smith).

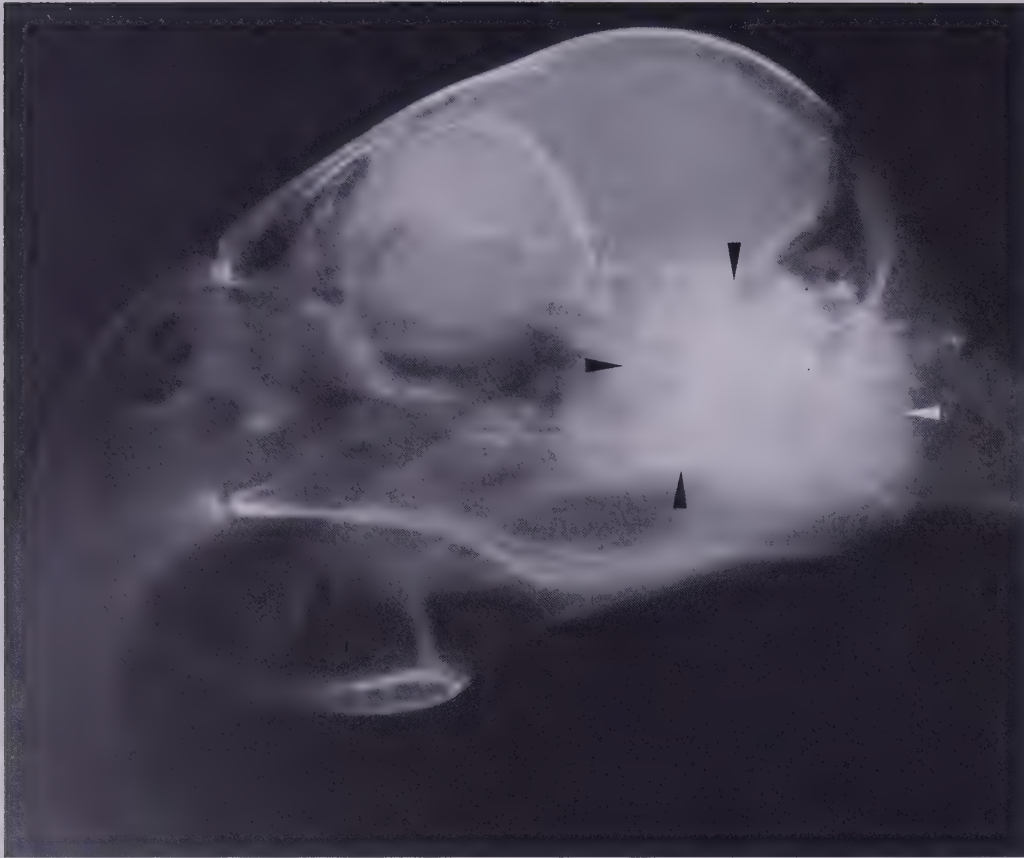**FIG 12.33** Mediolateral xeroradiograph of the pelvic limb of a normal Bobwhite Quail (courtesy of Bonnie J. Smith and Stephen A. Smith).



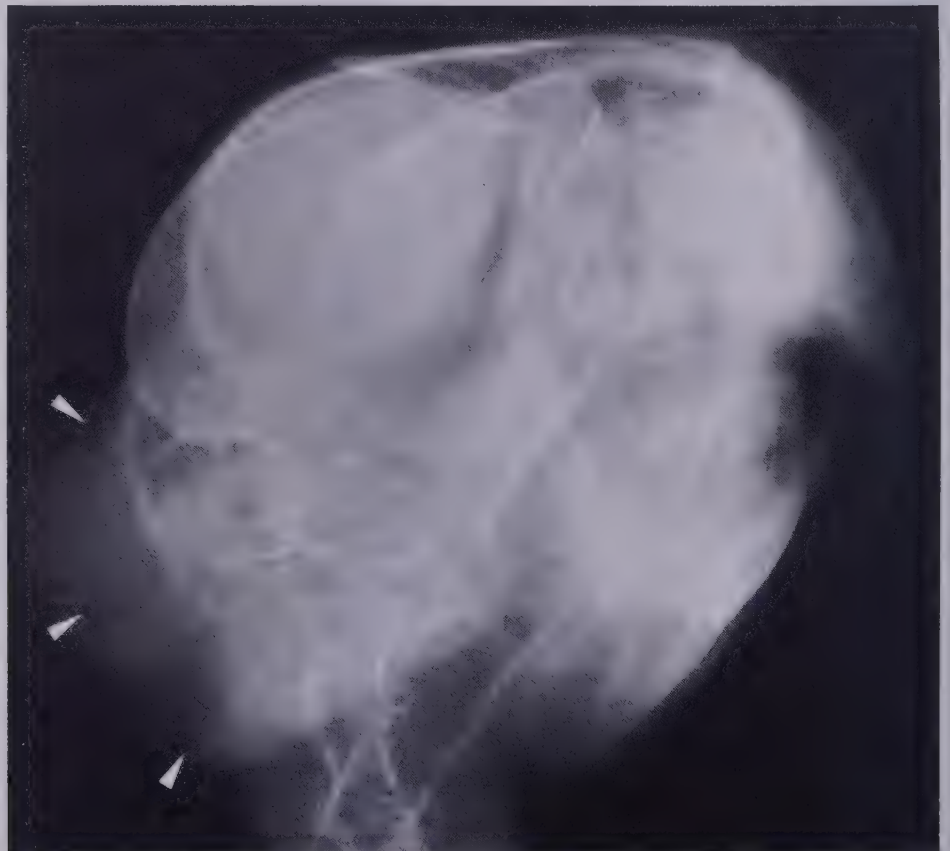
**FIG 12.34** Mediolateral xeroradiograph of the pes of a peafowl. 1) the calcial process is the osseous core of the metatarsal spur or calcar. Note the horny sheath covering the process. 2) Note also the mineralization of the digital flexor tendons as well as the 3) well-developed metatarsal and 4) digital pads in this ground-dwelling bird (courtesy of Bonnie J. Smith and Stephen A. Smith).



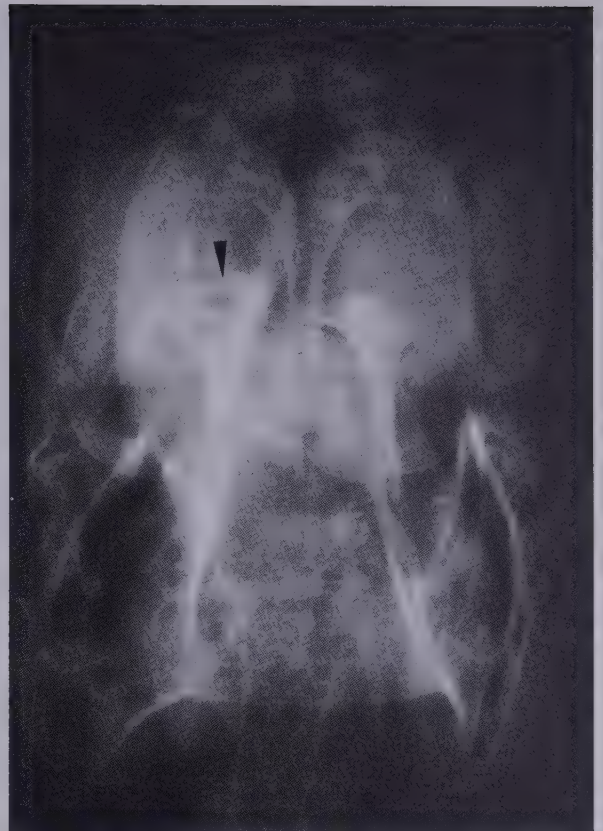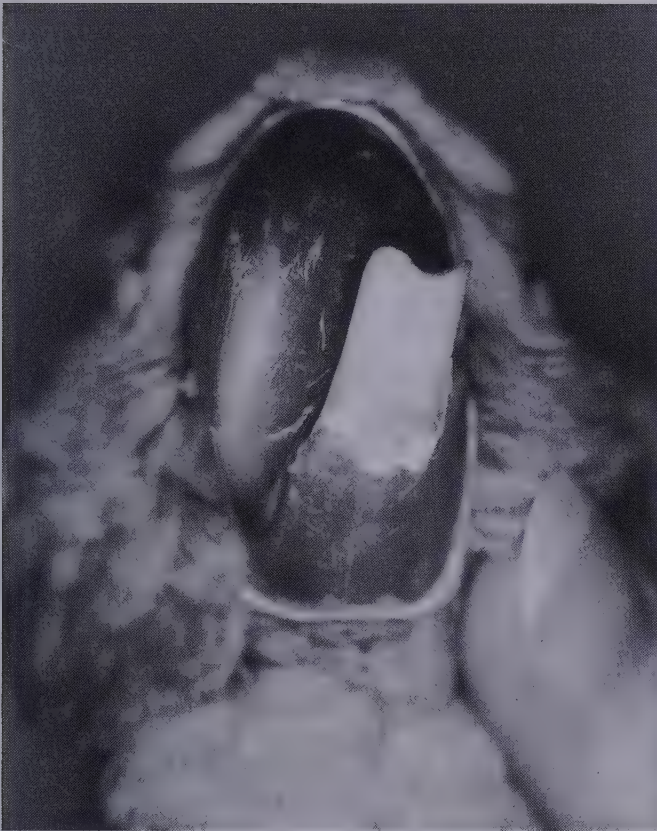**FIG 12.35** Low contrast radiographs of a Hyacinth Macaw demonstrating soft tissue structures: heart (h), spleen (s), liver (l), lung (lu), kidneys (k), proventriculus (p), ventriculus (v), ovary (o), intestines (i), contiguous area of the caudal thoracic and abdominal air sacs (a), body musculature (arrow) and right abdominal air sac (open arrow) (courtesy of Marjorie McMillan).



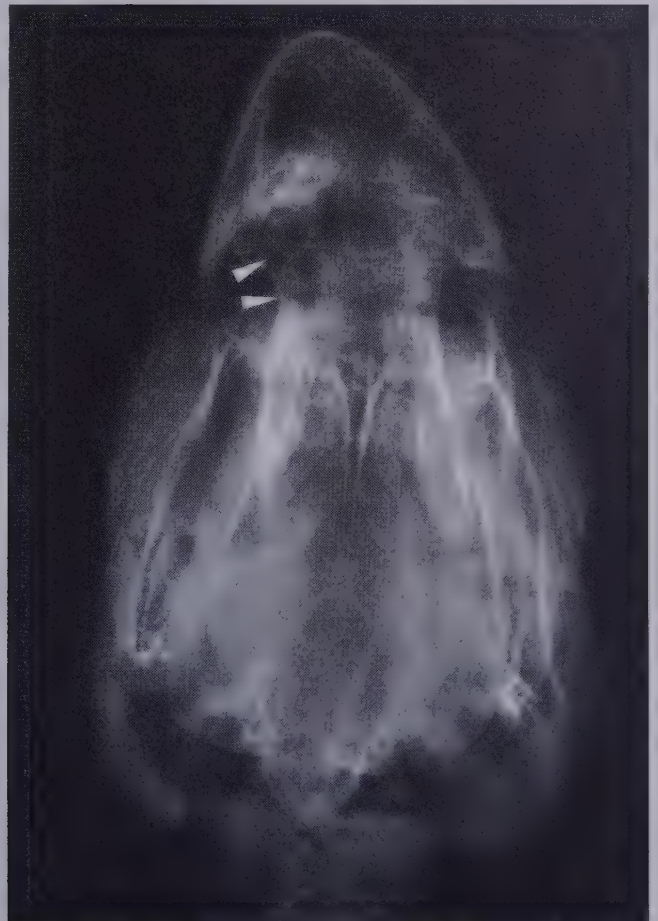
**FIG 12.36** A six-year-old Amazon parrot was presented with firm bilateral swelling surrounding the auditory meatus (arrows). The masses were solid and attached. Surgical biopsy of the mass indicated chronic fibrosing cellulitis. The mass is easily visualized on an oblique view of the head (arrows). The tympanic area can also be visualized (open arrows). The masses resolved when the bird was changed from an all-seed to a formulated diet.

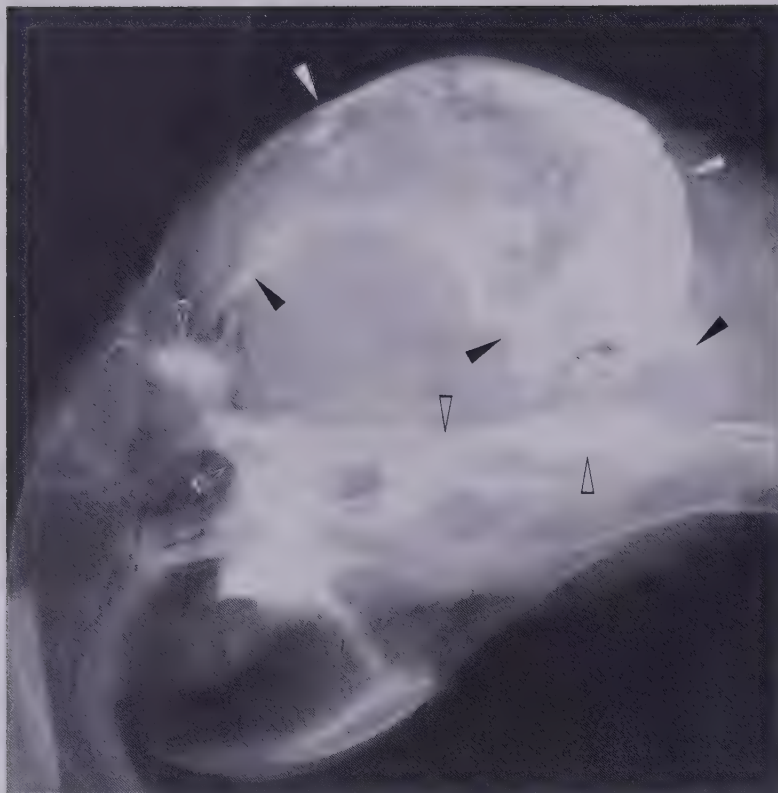




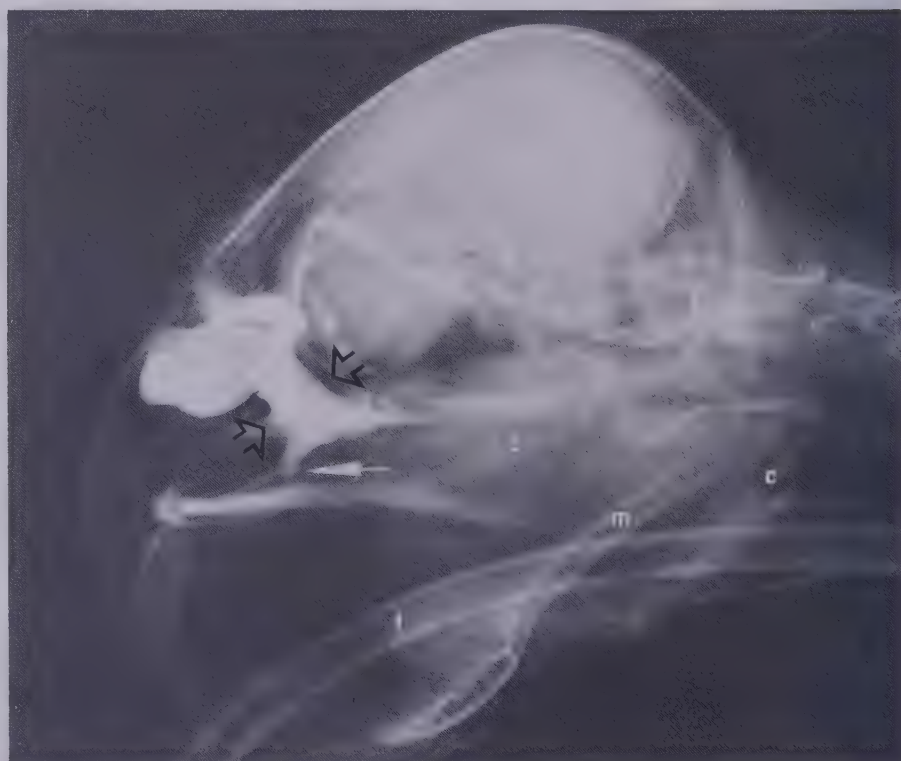

**FIG 12.37** Alexandrian Parakeet with lateral deviation of the maxillae. The deformity had been present since hatching. The parents of this bird produced a defective neonate every four to six chicks, suggesting that the problem was genetic in origin. Rostrocaudal radiograph showing dorsal displacement of the right palatine bone (arrow). Ventrodorsal radiograph showing lysis of the right palatine bone (arrows).

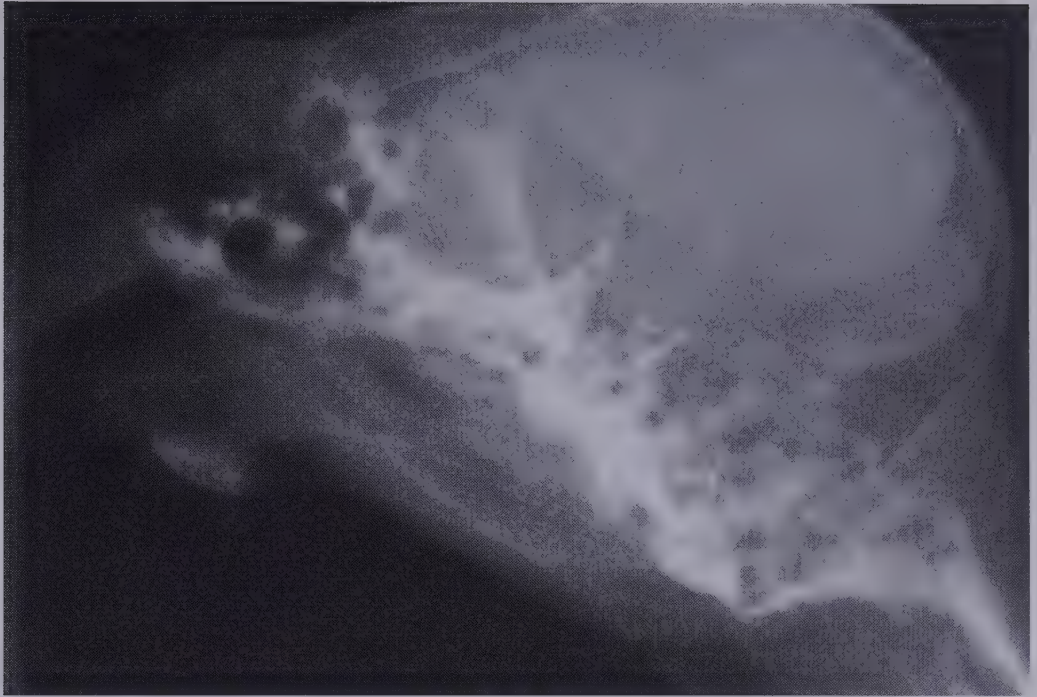




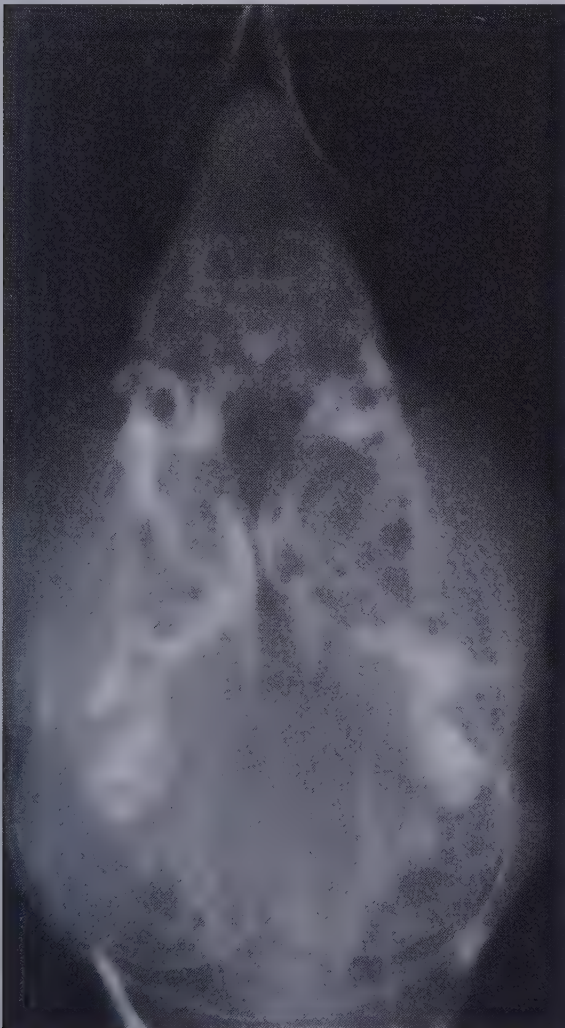
**FIG 12.38** Lateral positive contrast air sacculography demonstrating the extent of the cephalic air sac in a mature Blue-fronted Amazon Parrot. The cephalic portion (arrows) of the cervicocephalic air sac connects to the caudal aspect of the infraorbital sinus (open arrows) (courtesy of Marjorie McMillan).

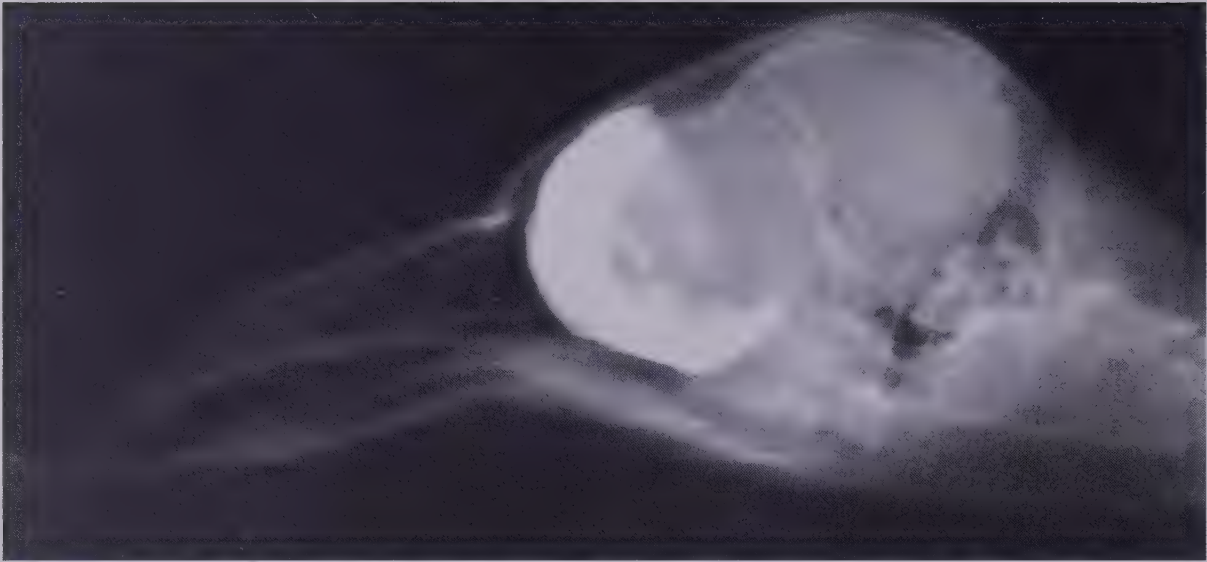


**FIG 12.39** Lateral view of a rhinogram performed on a normal Bare-eyed Cockatoo showing the flow of contrast medium from the nasal cavity (open arrows) through the choanae at the level of the palate and into the nasopharynx and oral cavity (arrow). Other structures include the mandible (m), zygomatic arch (z), ceratobranchial bone of hyoid (c) and tracheal tube (t) (courtesy of Elizabeth Watson).

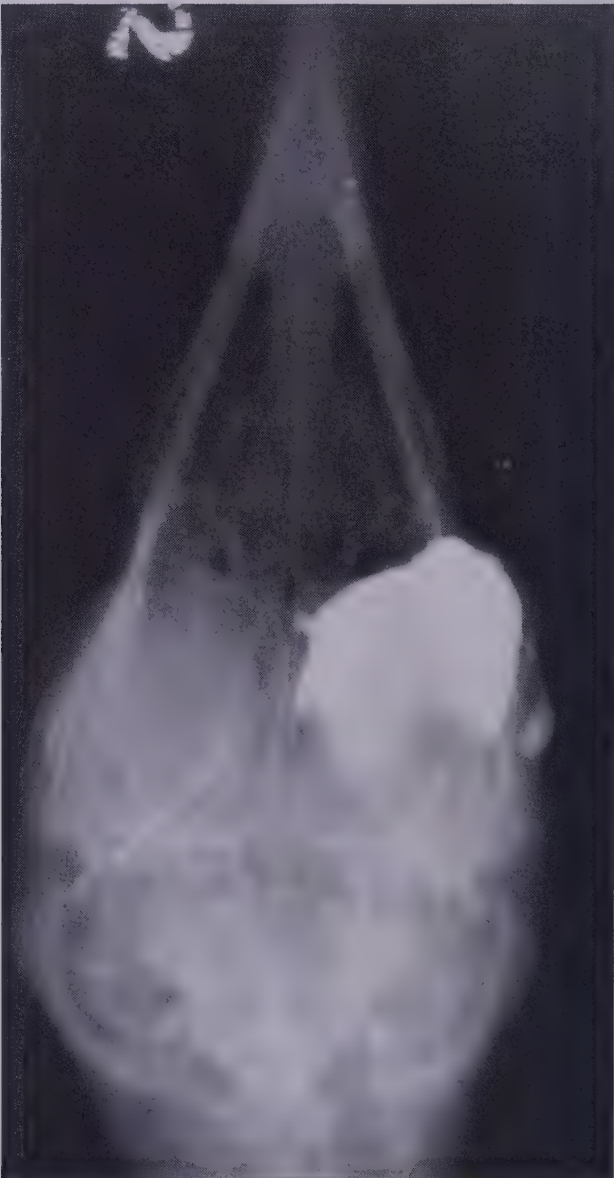


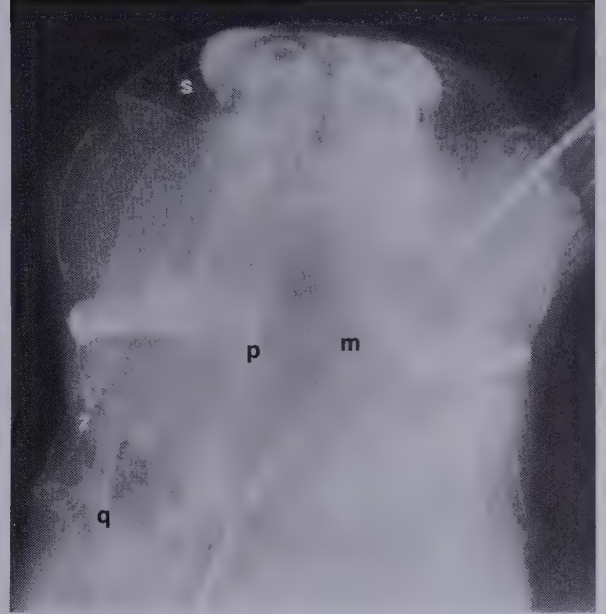
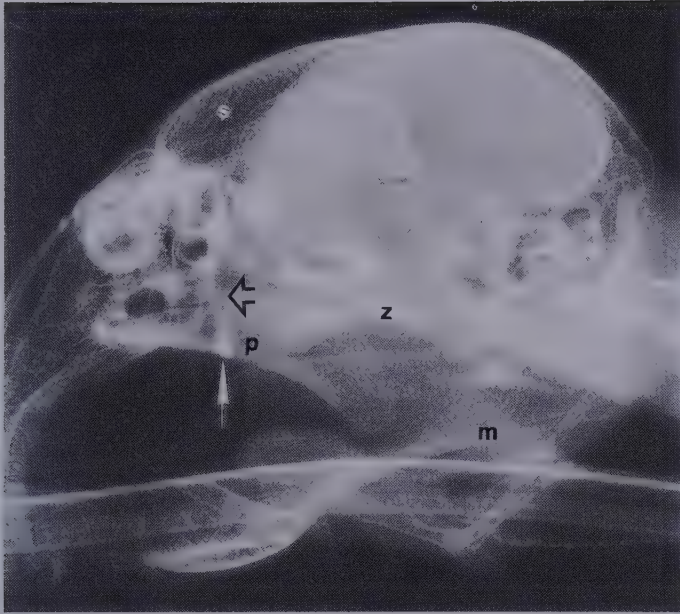
**FIG 12.40** Positive contrast sinography in an adult cockatiel showing drainage and interconnections of the infraorbital sinuses (courtesy of Marjorie McMillan).



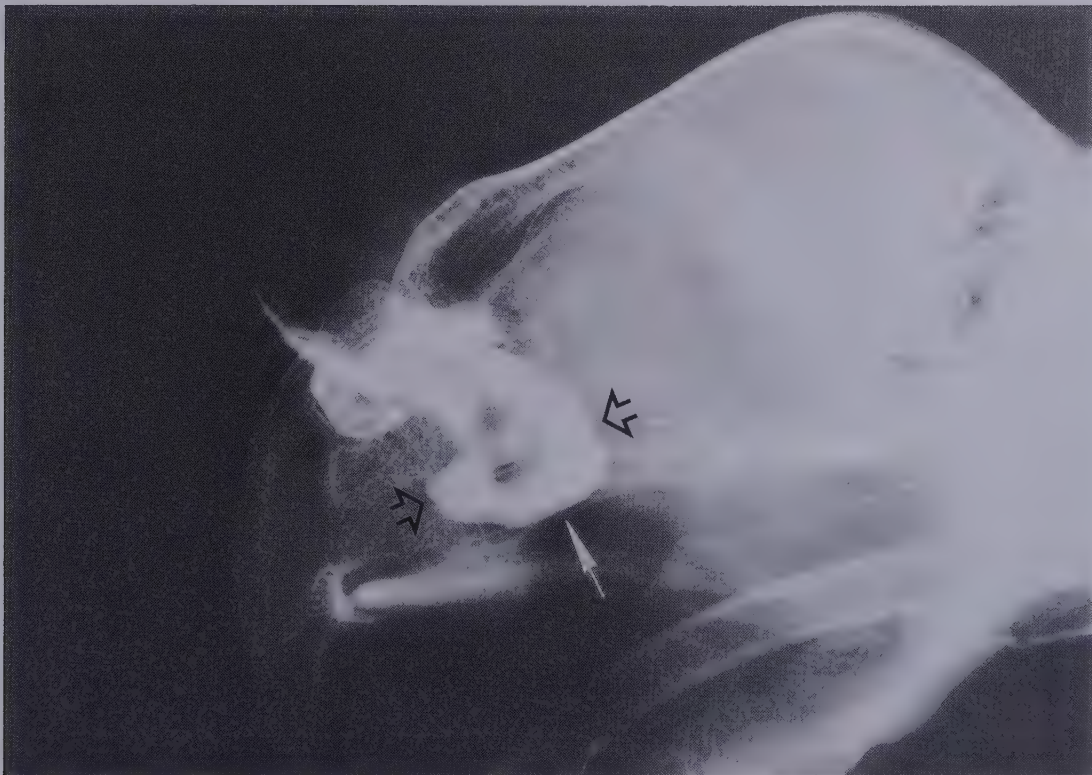

**FIG 12.41** Positive contrast sinography in a mynah bird showing minimal drainage of contrast medium in comparison to Psittaciformes. Additionally, there is not communication between the infraorbital sinuses, and contrast medium injected into the right infraorbital sinus remains localized (courtesy of Marjorie McMillan).

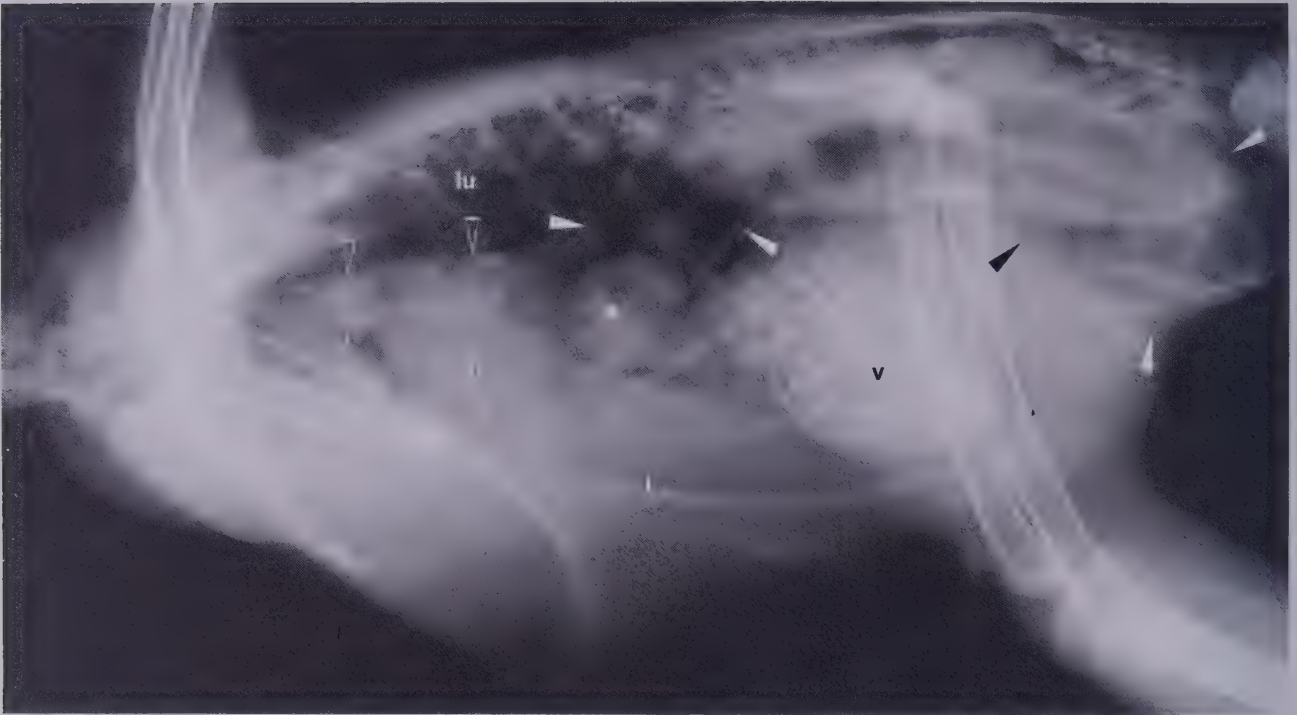




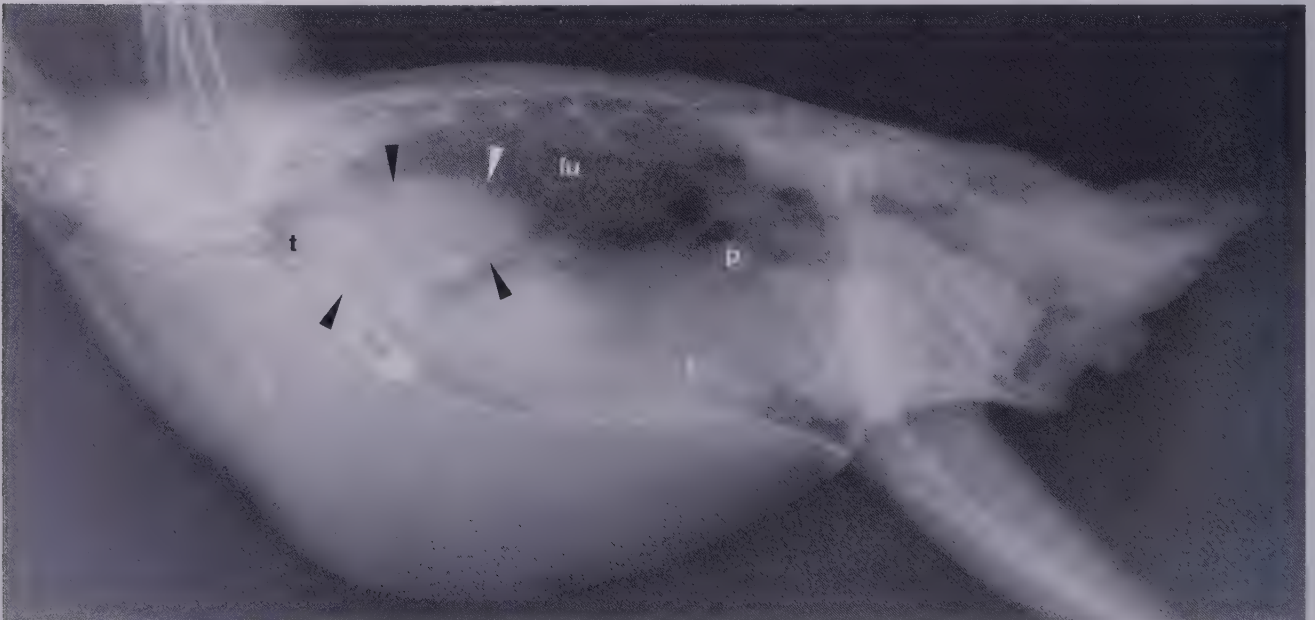
**FIG 12.42** A four-month-old African Grey Parrot was presented with a life-long history of persistent serous to mucopurulent nasal discharge. Antibiotic therapy would change the discharge from mucopurulent to serous but would not resolve the problem. On physical examination, it was noted that fluid introduced into the nostrils would not exit through the oral cavity. Lateral view of rhinogram indicating that contrast medium moved ventrally through the nasal cavity (open arrow) and stopped abruptly at the level of the palate (closed arrow). Endoscopy indicated a persistent membrane covering the choana. Rostrocaudal radiograph following infusion of contrast medium into the right nostril showing communication between the infraorbital sinuses. Note that the contrast medium does not properly pass into the oral cavity in this bird. Other structures of interest include the palatine bone (p), zygomatic arch (z), mandible (m), quadrate (q) and the periorbital diverticulum of the infraorbital sinus (s) (courtesy of Elizabeth Watson).





**FIG 12.43** A four-year-old Umbrella Cockatoo was presented with a long history of bilateral oculonasal discharge. Fluid flushed into the nostrils failed to enter the oropharynx. A lateral rhinogram indicated that contrast medium moved through the nasal cavity (open arrows) and stopped abruptly at the level of the palatine (closed arrows) (courtesy of Elizabeth Watson).



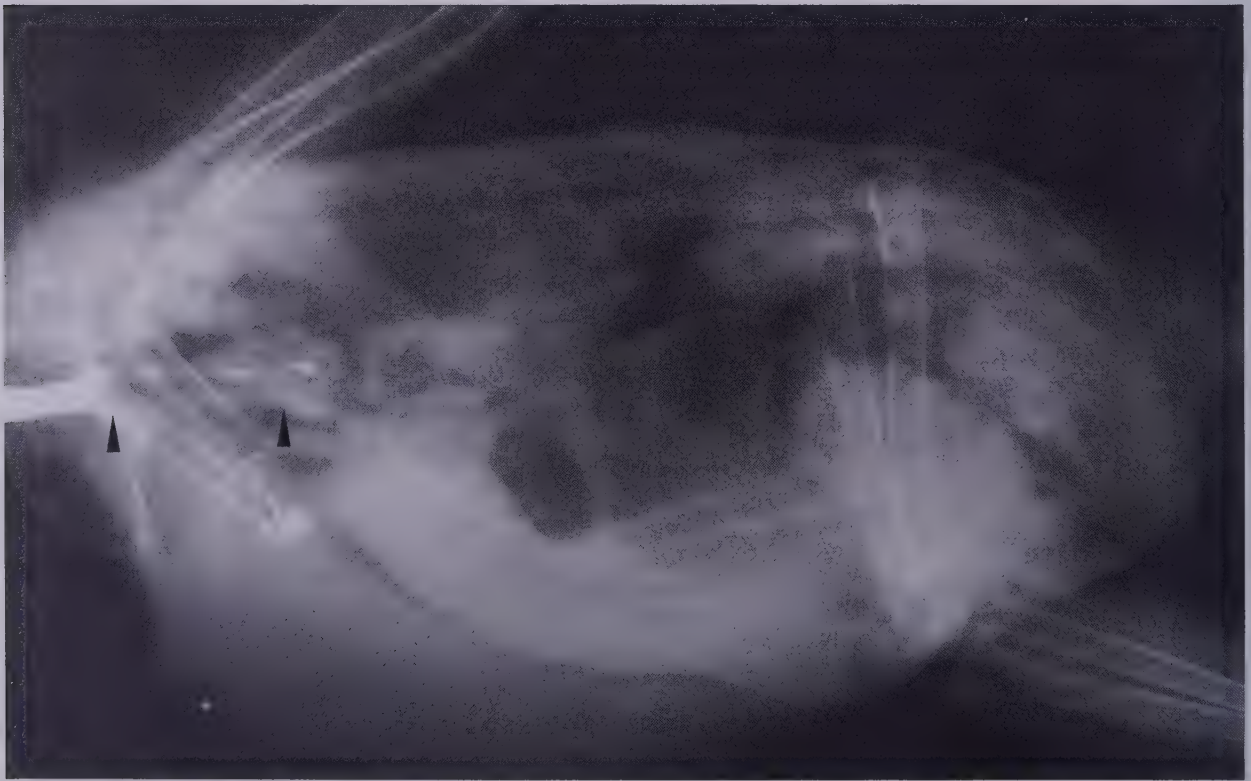
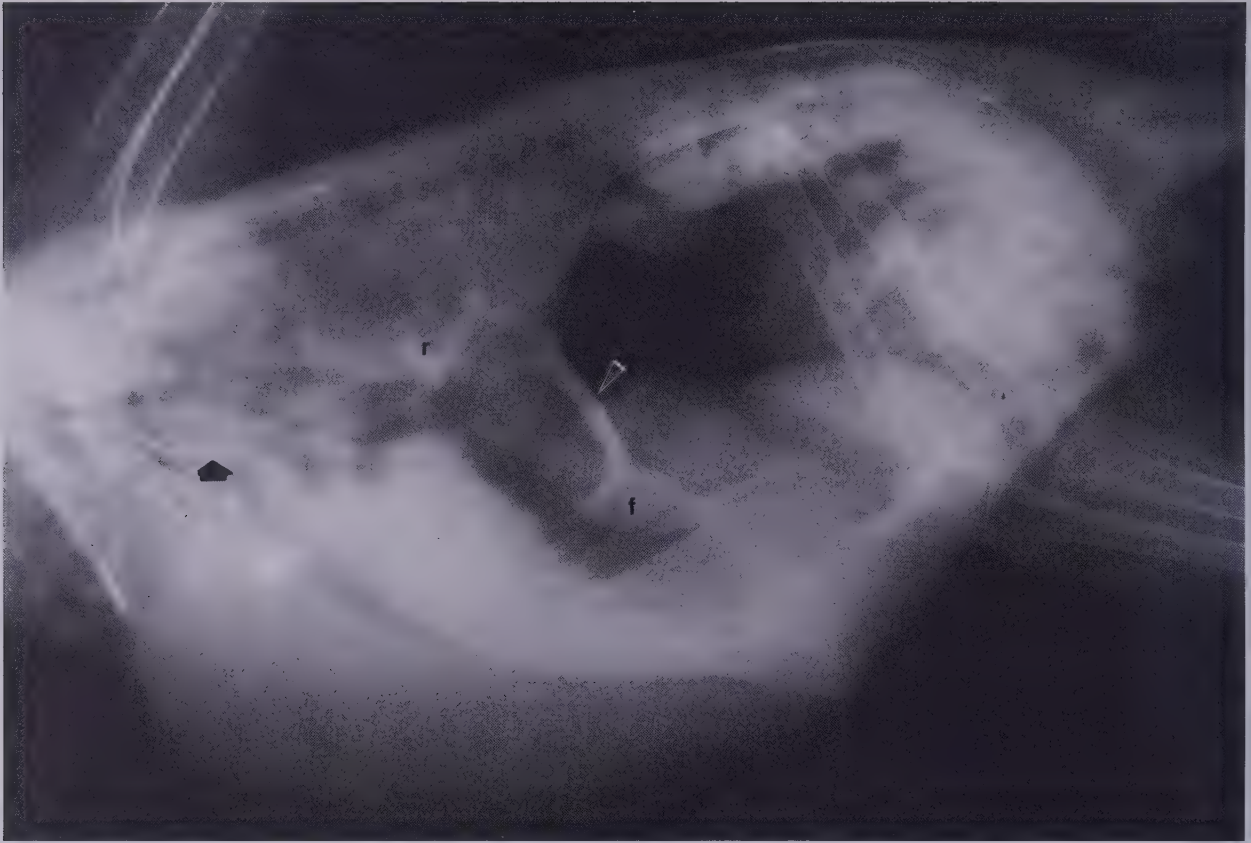
**FIG 12.44** An adult male Satyr Tragopan Pheasant was presented with an acute onset of dyspnea and depression. Abnormal clinicopathologic findings include PCV=23, SGOT=490, LDH=671. Radiographs indicate gaseous distension of the gastrointestinal tract (arrows) causing cranial displacement of other abdominal organs. Increased densities were noted in the syringeal area (open arrows), and the spleen (s) was enlarged. The bird did not respond to supportive care. Necropsy findings included pericarditis and granulomatous pneumonia and tracheitis. Heart (h), liver (l), lung (lu), ventriculus containing grit (v).



**FIG 12.45** A two-year-old male cockatiel was presented for evaluation of a voice change and progressive dyspnea. A lateral radiograph showed a large, lobular, soft-tissue mass surrounding the distal trachea (arrows) that extended into the lung (lu) and displaced the trachea (t) ventrally. The liver (l) is also enlarged and is displacing the gas-filled proventriculus (p) dorsally. The histologic diagnosis was thyroid adenocarcinoma (courtesy of Marjorie McMillan).

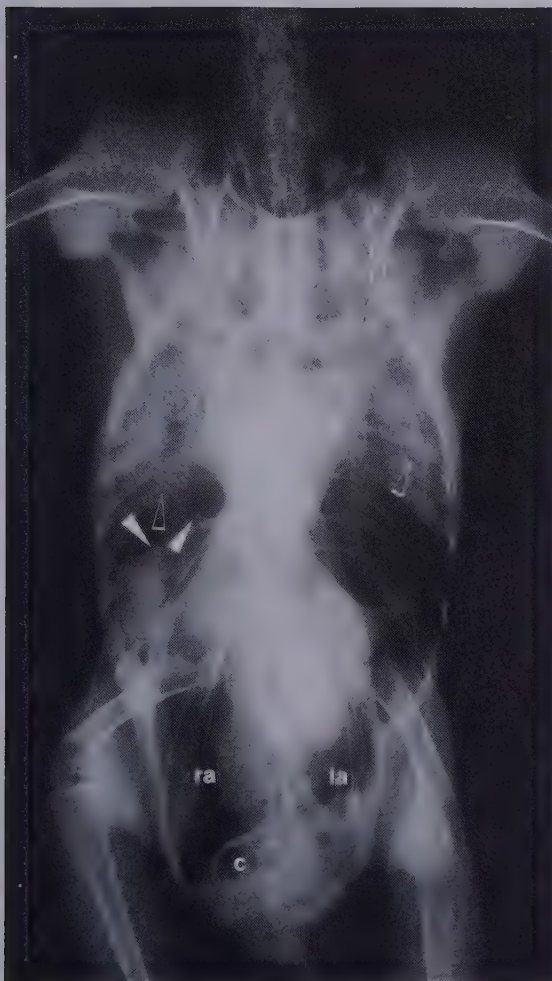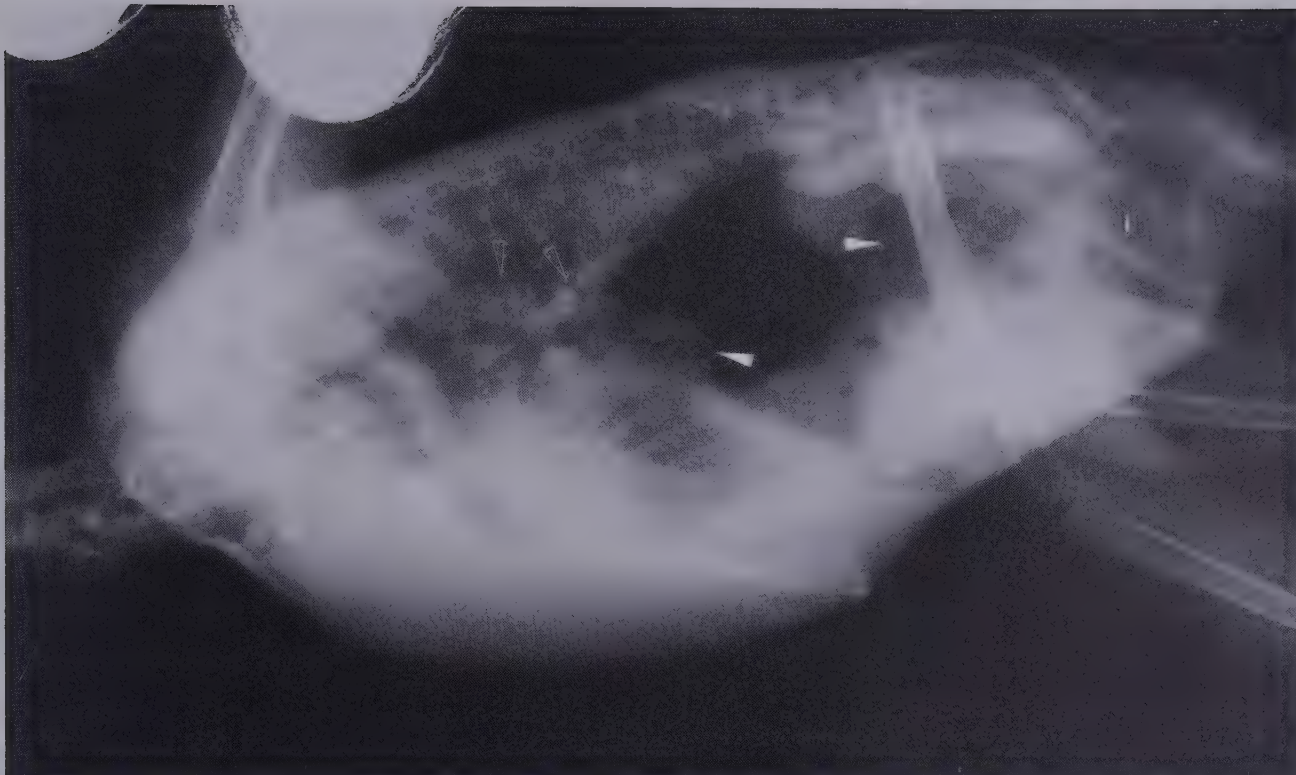


**FIG 12.46** A Red-lore Amazon Parrot was presented with coughing and a voice change. Initial radiographs showed a large, soft-tissue mass (arrows) ventral to the trachea and syrinx. Radiograph taken 11 months after treatment with antifungal agents demonstrates resolution of the mass (courtesy of Marjorie McMillan).




**FIG 12.47** **a)** Lateral radiograph of a mature Blue-fronted Amazon with dyspnea. Abnormal findings included increased parabronchial densities (ring shadows-r), hyperinflation of the air sacs and thickening of the contiguous wall of the cranial and caudal thoracic air sacs (open arrow). The ventral separation of the contiguous wall of these air sacs forms a distinguishable fork (f) with the cranial thoracic air sac coursing cranially and the caudal thoracic air sac coursing caudoventrally. An increased soft tissue density in the trachea suggests a mass (arrow). **b)** Positive contrast study of the trachea using an oil-based contrast medium. The medium is passing dorsally across an intratracheal mass (arrows) (courtesy of Marjorie McMillan).

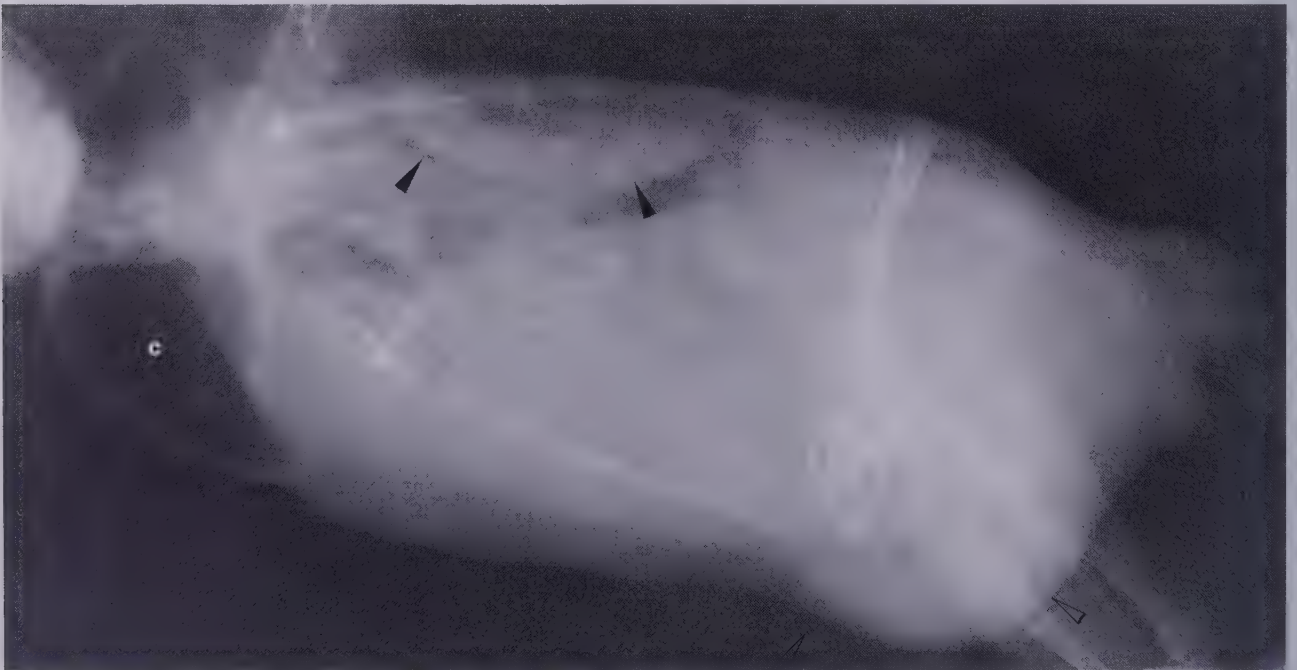




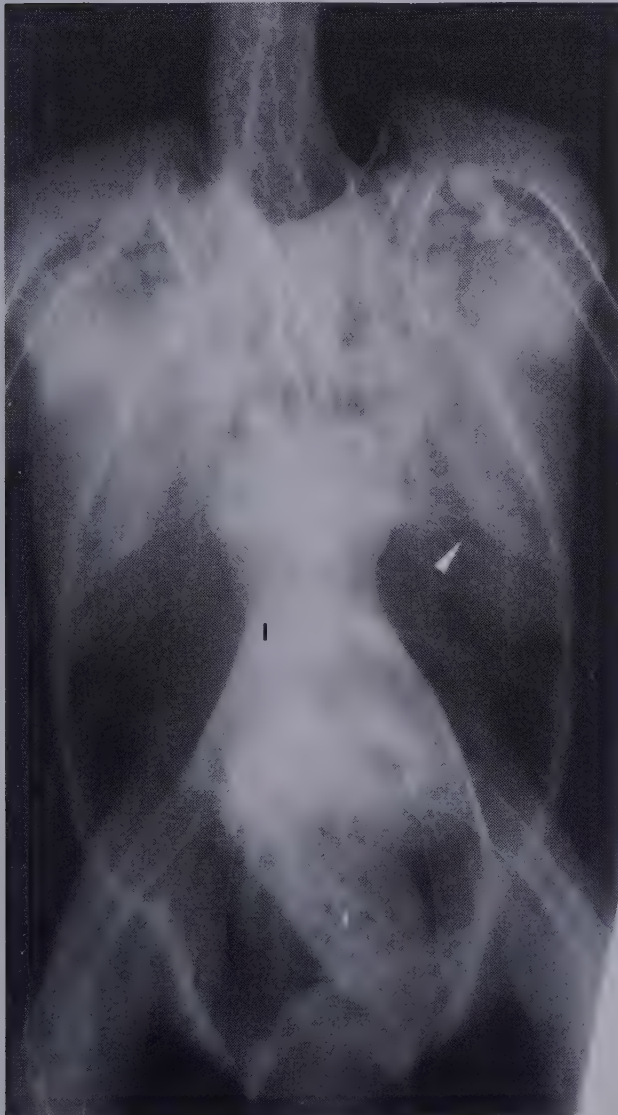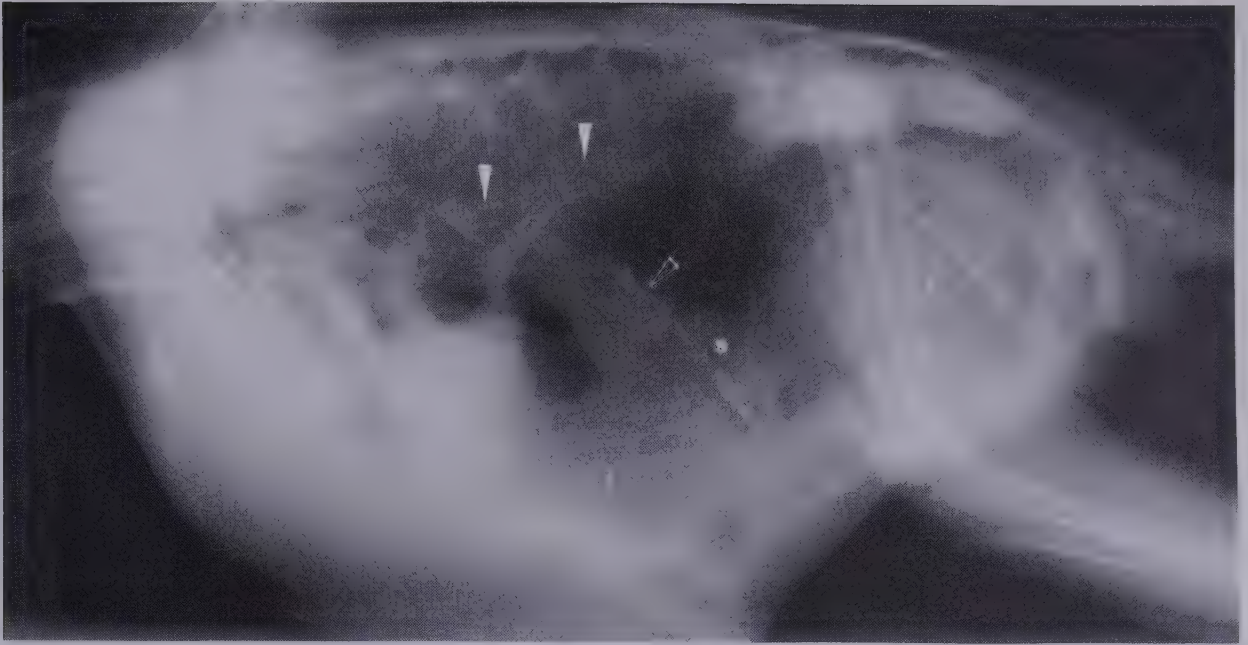
**FIG 12.48** An adult Blue-crowned Amazon Parrot was presented with nasal discharge and dyspnea. The increased parabronchial densities (open arrows) in the mid and caudal portions of the lung are suggestive of pneumonia. Several thickened air sac walls are visible (arrows). The intestines (i) are filled with gas secondary to aerophagia caused by severe dyspnea. The right abdominal (ra) and left abdominal (la) air sac areas are clearly visible. The cloacal wall (c) is also evident.



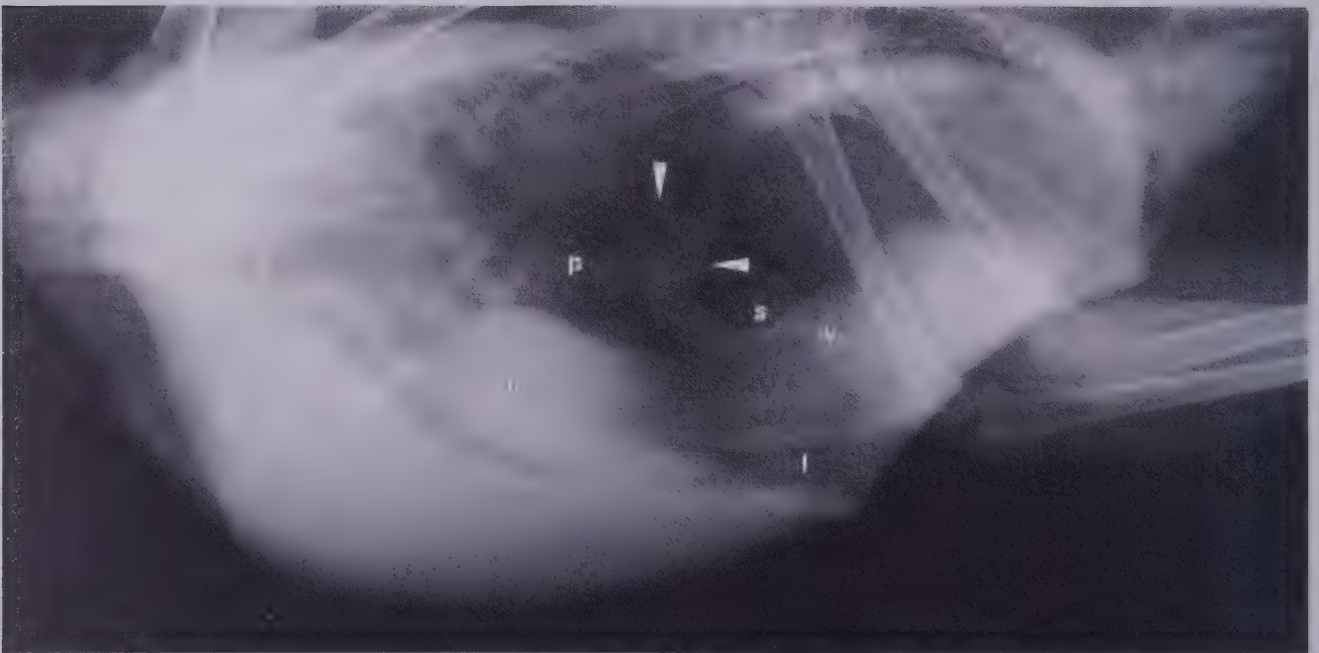

**FIG 12.49** A four-year-old lovebird with a round cell carcinoma of the wing and secondary metastasis to the lung (arrows) (courtesy of Marjorie McMillan).



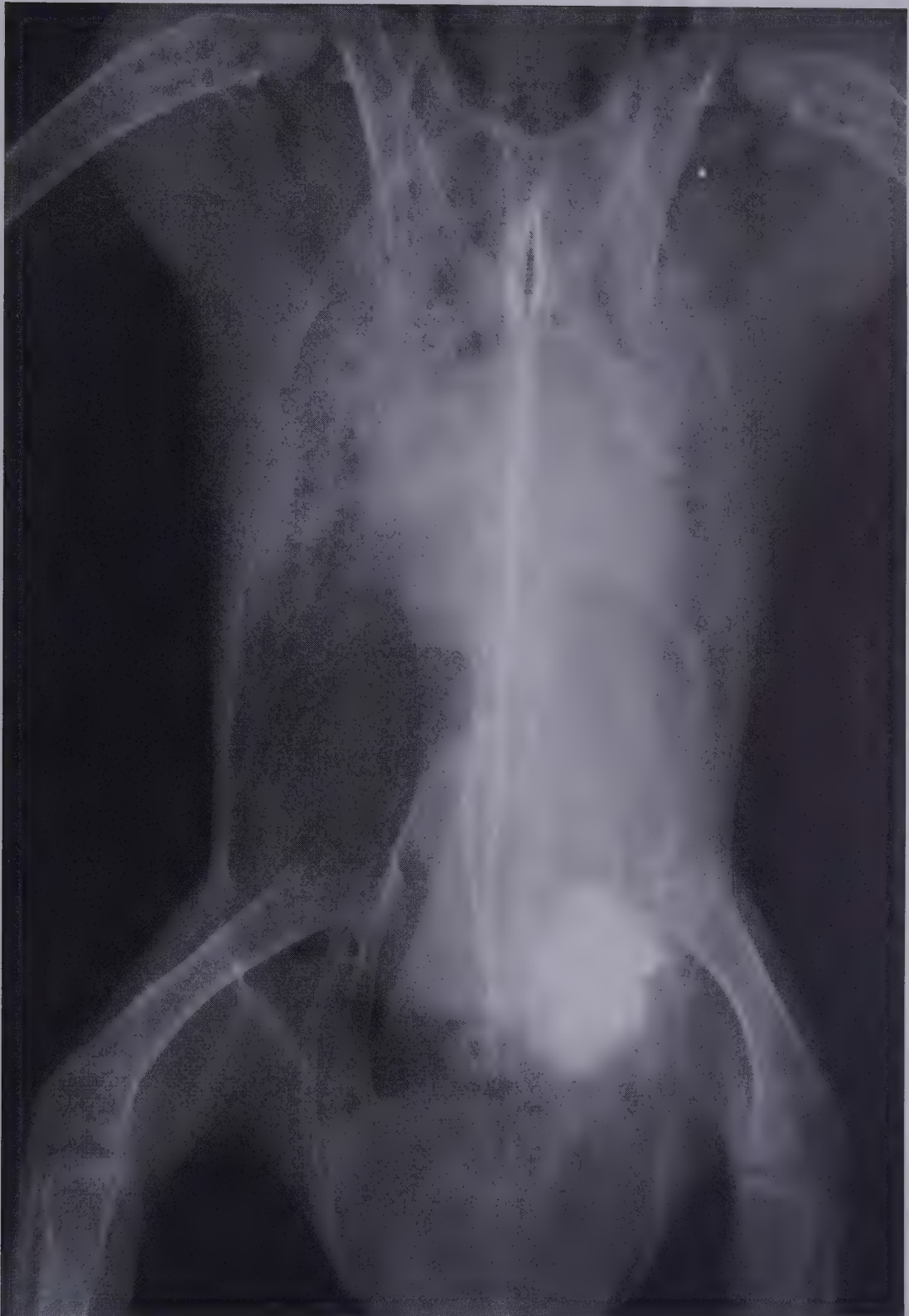**FIG 12.50** A five-year-old male budgerigar was presented for lethargy and dyspnea. Lateral radiographs indicate an air-filled crop (c) secondary to aerophagia. There is a uniform increase in the parabronchial pattern (arrows) and obliteration of the abdominal air sac space due to bulging of the abdominal wall (open arrow). The homogenous appearance of the abdomen is due to a combination of effusion and a mass. The pulmonary pattern is consistent with edema, which responded to diuretic therapy (courtesy of Marjorie McMillan).



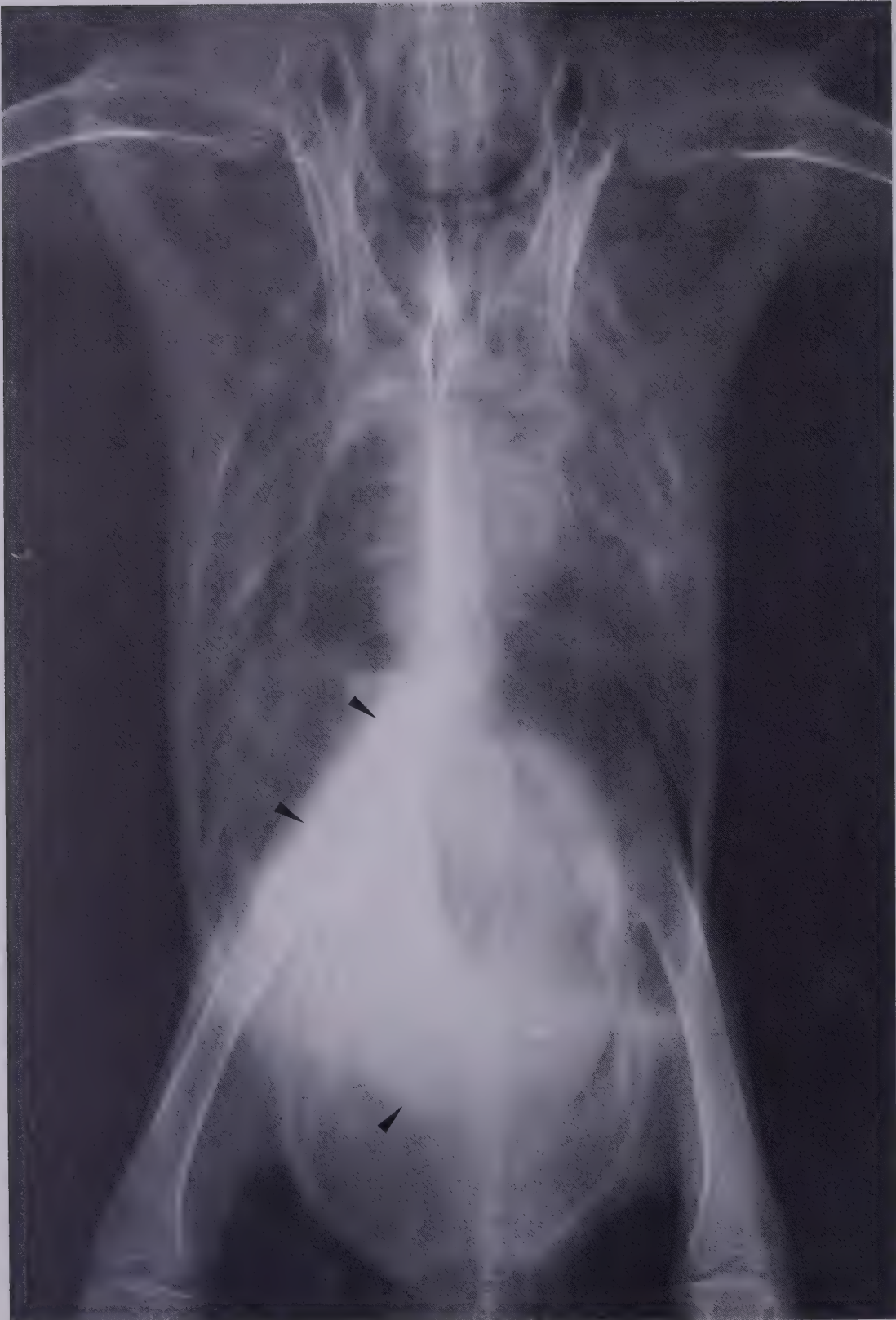
**FIG 12.51** A four-month-old Double Yellow-headed Amazon Parrot was presented with a bilateral, purulent nasal discharge and dyspnea. Radiographs indicated parabronchial ring shadows (arrow) consistent with pneumonia. Hyperinflation of the thoracic and abdominal air sacs and thickening of the air sac membranes are characteristic of air sacculitis (open arrows). Note the barrel shape of the body in the VD radiograph indicative of dyspnea. Cultures from the trachea were positive for *Klebsiella* sp., and the bird responded to antibiotics. Liver (l), intestines (i) and spleen (s).



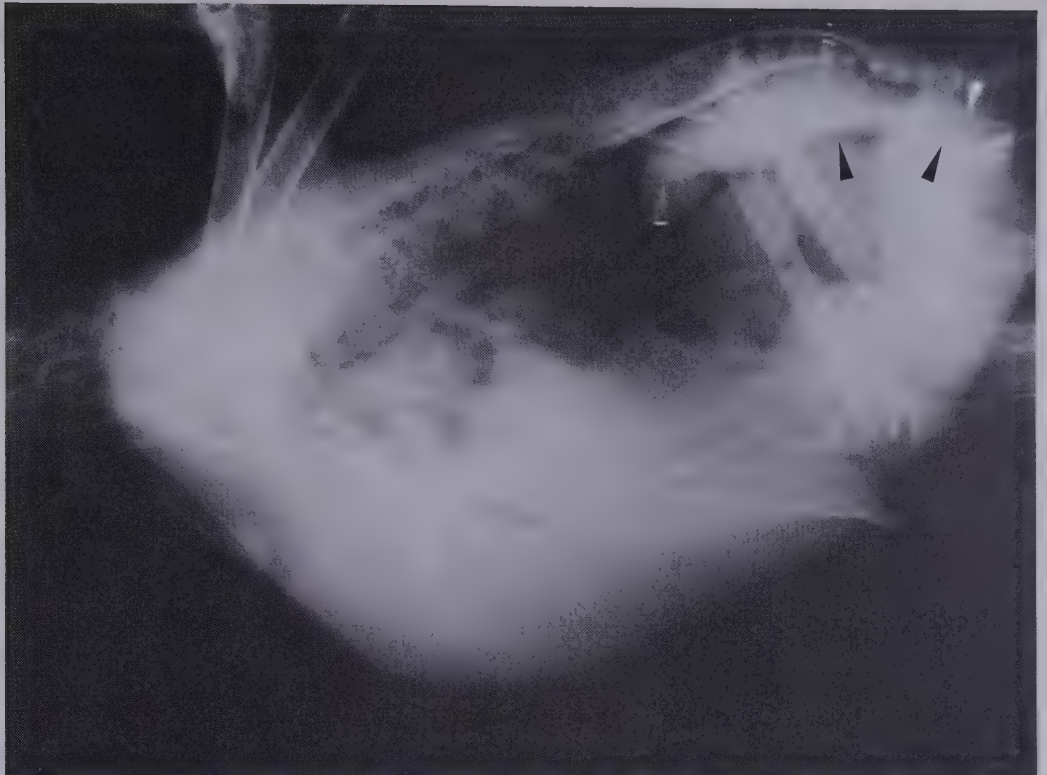
**FIG 12.52** A ten-year-old Green-winged Macaw was presented with exercise intolerance. Initial radiographs (top) indicated thickening or edema of the air sacs. Radiographs one month after the initiation of antibiotic therapy indicate a decrease in the soft tissue opacity of the air sacs. However, the presence of residual thickening (arrows) would warrant continuation of therapy. Spleen (s), proventriculus (p), ventriculus (v), heart (h), liver (l) (courtesy of Marjorie McMillan).



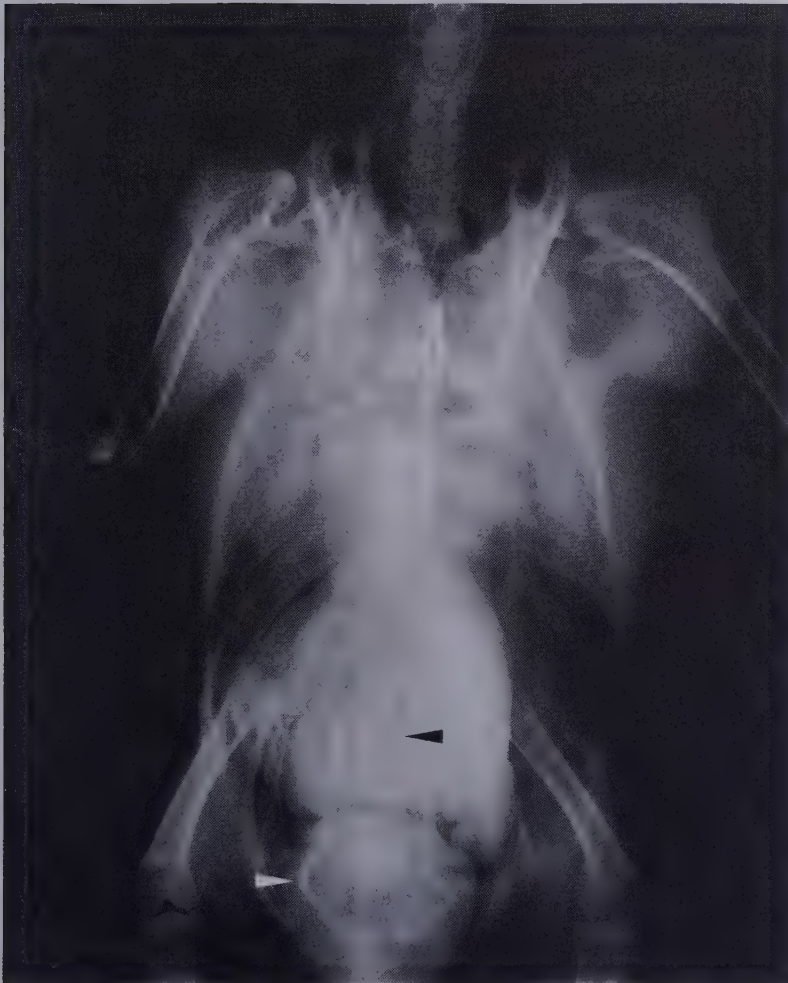**FIG 12.53** An African Grey Parrot with a soft tissue opacity in the left cranial and caudal thoracic air sacs (courtesy of Marjorie McMillan).

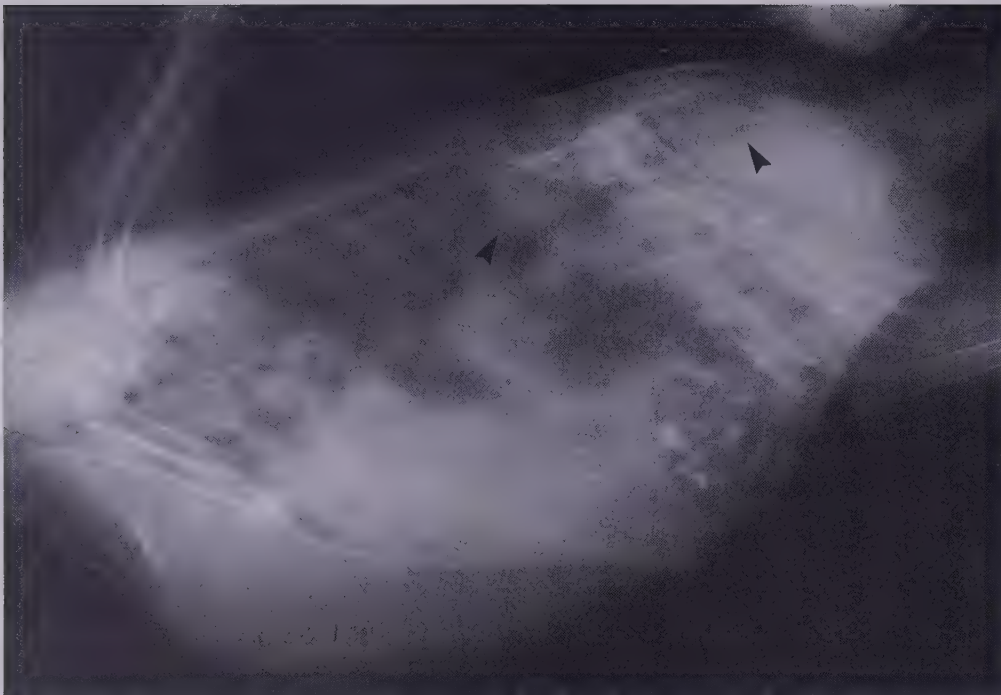


**FIG 12.54** A Blue-fronted Amazon Parrot with a soft tissue plaque in the right abdominal air sac (arrows) (courtesy of Marjorie McMillan).

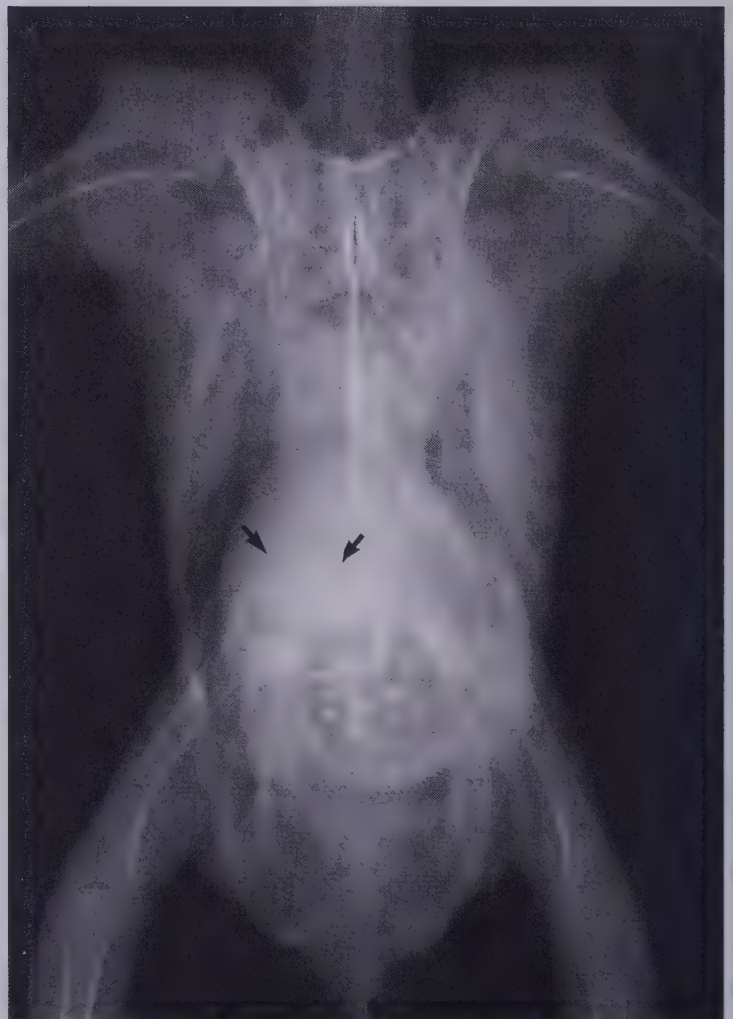

**FIG 12.55** Excretory urogram in an African Grey Parrot. The radiographs were taken 30 seconds after the injection of contrast medium. The kidneys (open arrows) and ureters (arrows) are opacified. Note the rim of air that is normally present dorsal to the kidneys (courtesy of ME Krautwald).

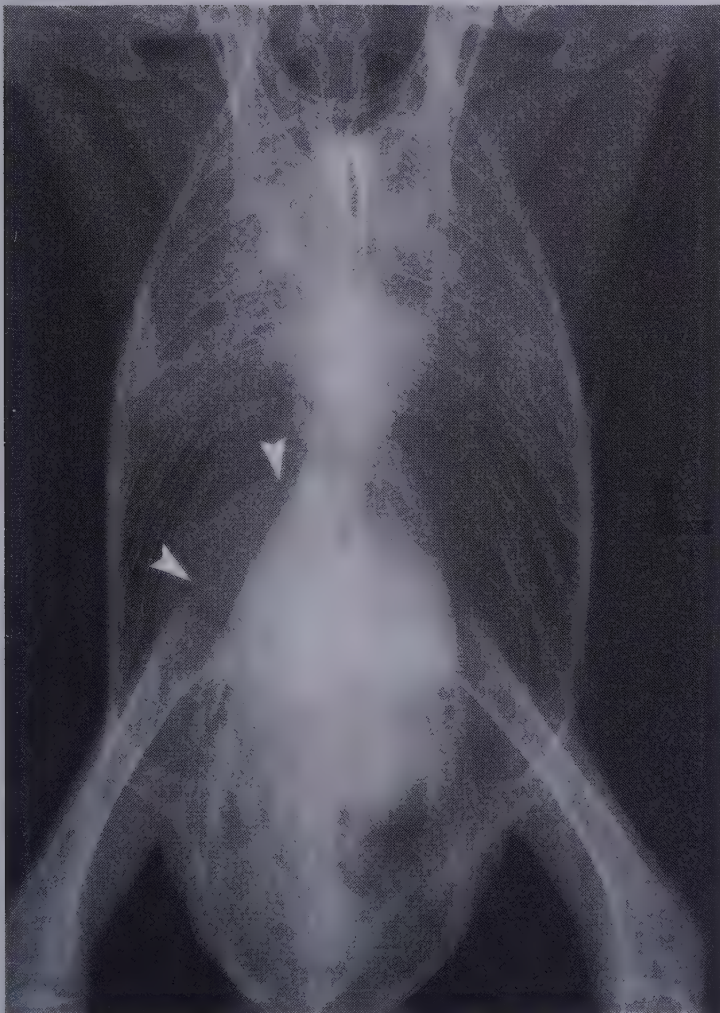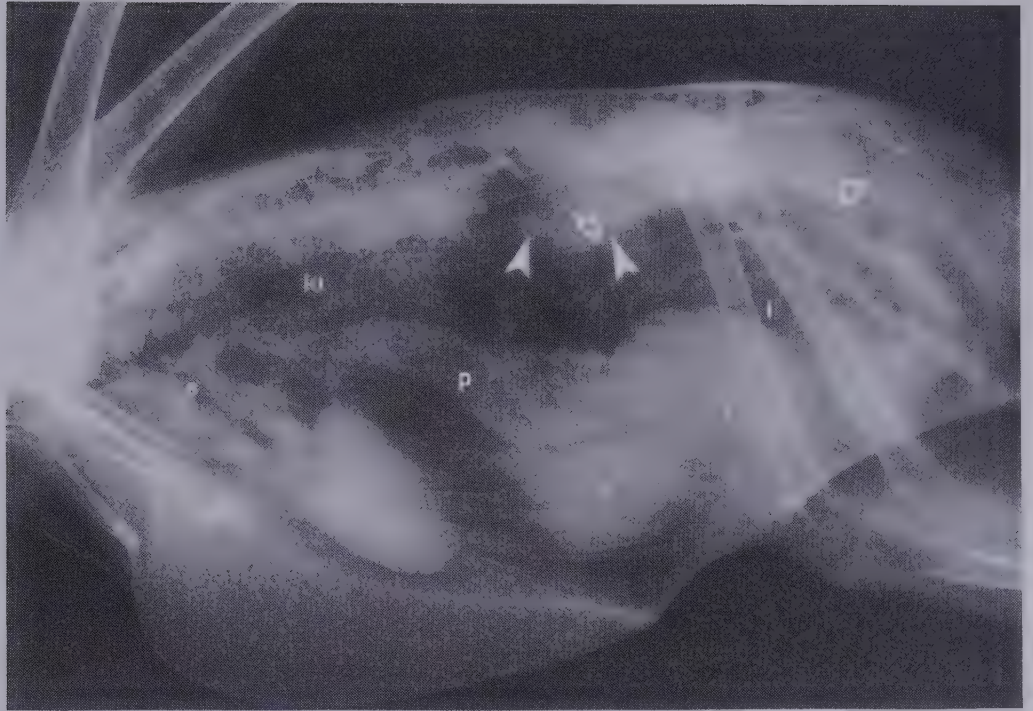




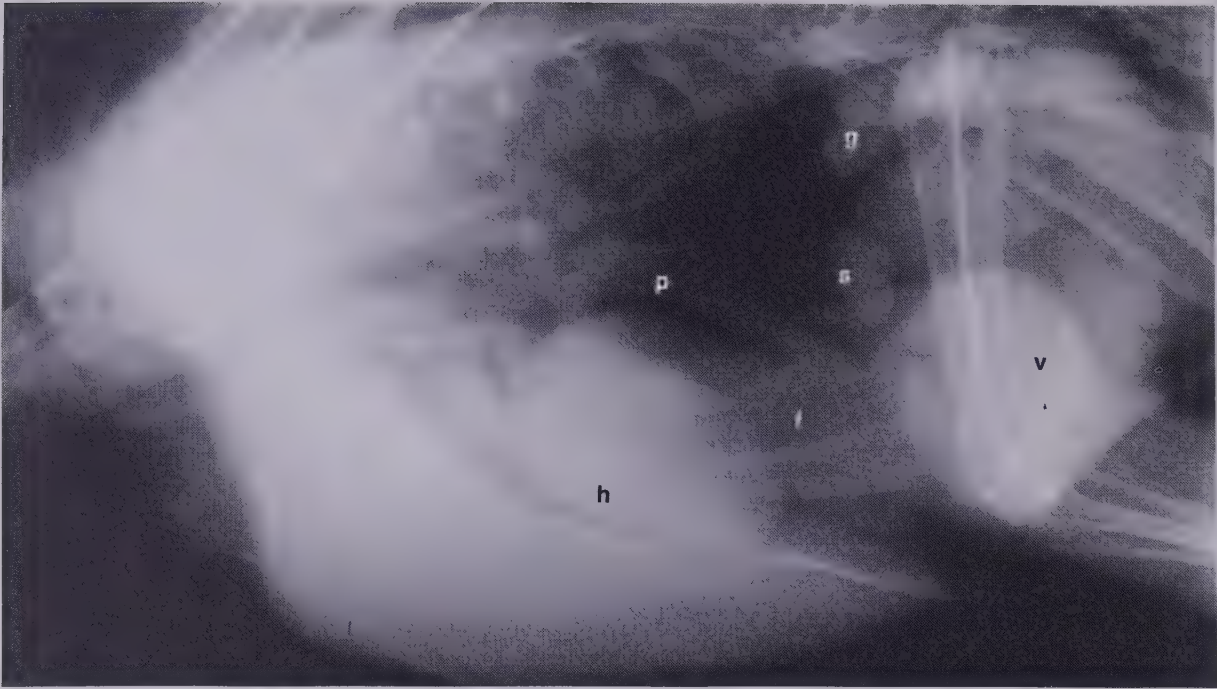
**FIG 12.56** A Blue-crowned Amazon Parrot with nephromegaly (arrows). The diminished serosal detail in the coelomic cavity was caused by hemorrhage from the diseased kidney. The pathologic diagnosis was glomerulonephropathy, infarction and arteritis (courtesy of Marjorie McMillan).



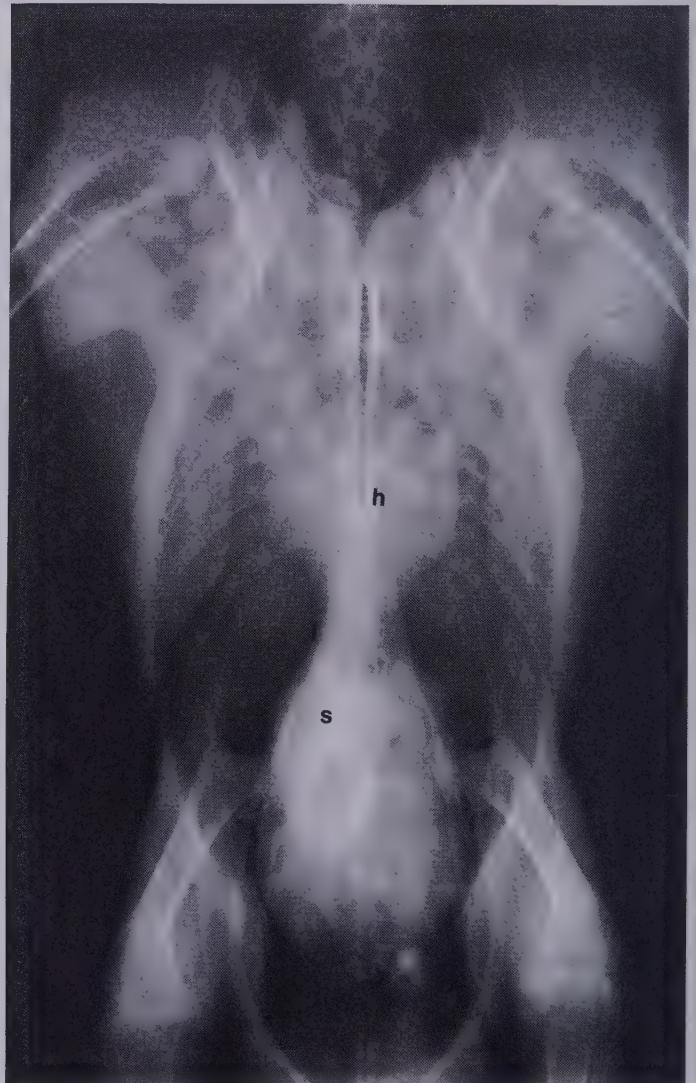

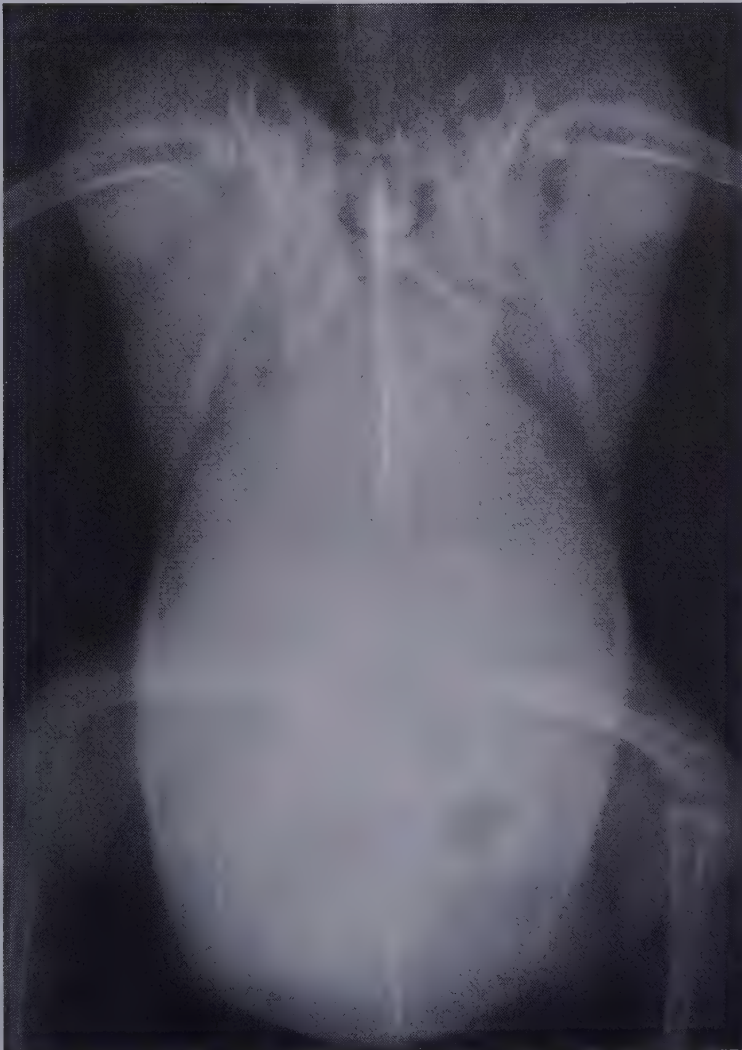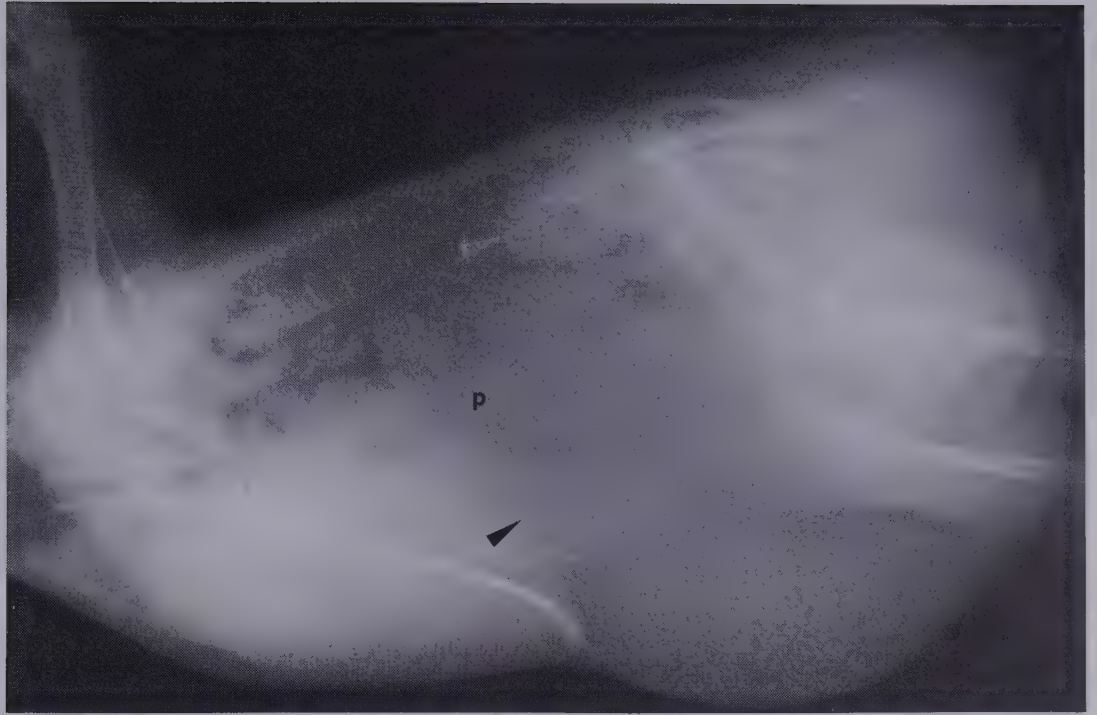


**FIG 12.57** Sulphur-crested Cockatoo with nephromegaly (open arrows) and a perirenal granuloma (arrow) caused by aspergillosis. The severe air sac distension is causing the liver (l) to appear reduced in size. Other structures that are easy to identify include the heart (h), syrinx (s), lung (lu), proventriculus (p), ventriculus (v) and intestines (i) (courtesy of Marjorie McMillan).

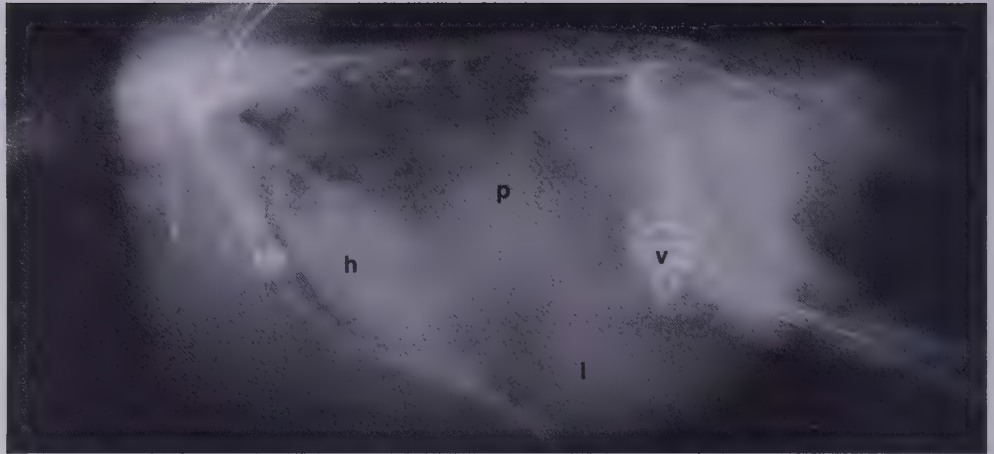


**FIG 12.58** A two-year-old Blue and Gold Macaw was presented with anorexia and mild dyspnea. Increased lung sounds were noted by auscultation. Radiographs indicated microhepatia and splenomegaly. It is common for the liver to be smaller than expected in macaws and some larger cockatoos. The importance of a small liver in these birds has not been determined. Heart (h), liver (l), spleen (s), syrinx (s), proventriculus (p), ventriculus (v), gonad (g).






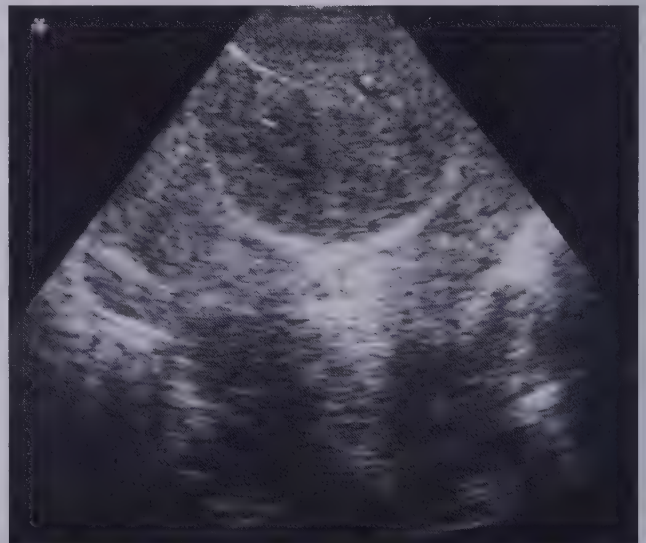
**FIG 12.59** An eight-week-old Sulphur-crested Cockatoo with nephromegaly (open arrow) and massive hepatomegaly (arrow) caused by lipidosi. Note that the normal air sac triangle above the proventriculus is obliterated and the proventriculus (partially gas-filled) is being displaced cranially (courtesy of Marjorie McMillan).




**FIG 12.60** An adult male cockatiel was presented with weakness, a distended abdomen and harsh, moist respiratory sounds. Radiographs indicated massive hepatomegaly (l) with cranial displacement of the heart (h), dorsal displacement of the proventriculus (p) and caudodorsal displacement of the ventriculus (v). A mild diffuse parabrachial pattern secondary to edema was also present. Histopathology indicated severe, chronic active hepatitis and cirrhosis (courtesy of Marjorie McMillan).

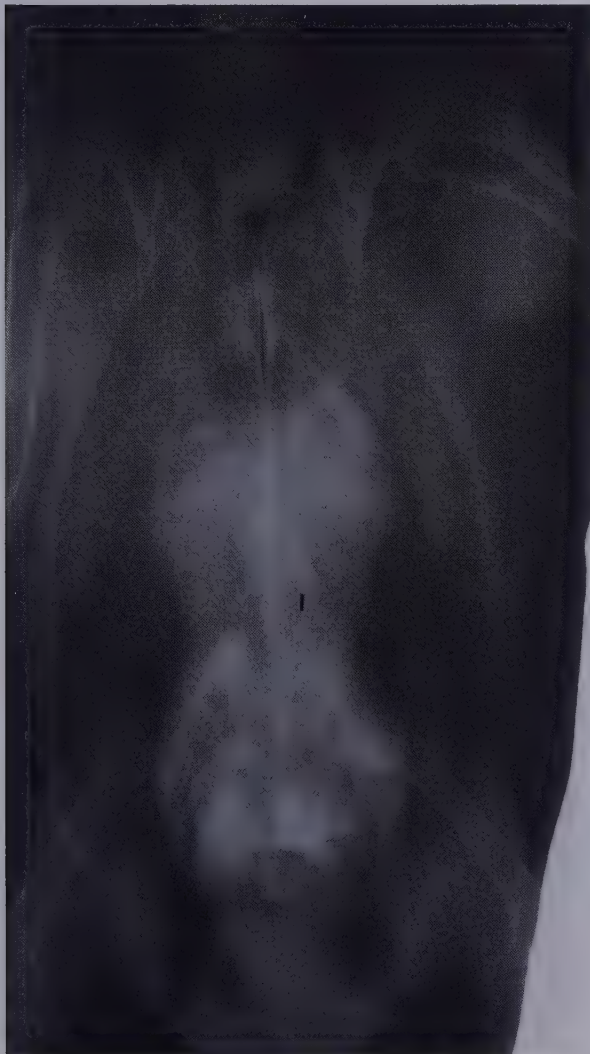

**FIG 12.61** A ten-week-old Blue-fronted Amazon Parrot with a palpable abdominal mass was presented for anorexia and lethargy. Abnormal clinicopathologic findings included WBC=20,000 (4% bands), AST=12,420, LDH=8,000. Radiographs indicated hepatomegaly (l) with dorsal displacement of the proventriculus (p). Ultrasound confirmed the liver enlargement. *Chlamydia* sp. was detected in the bird's excrement using an antigen capture ELISA, and the bird responded to therapy with doxycycline.

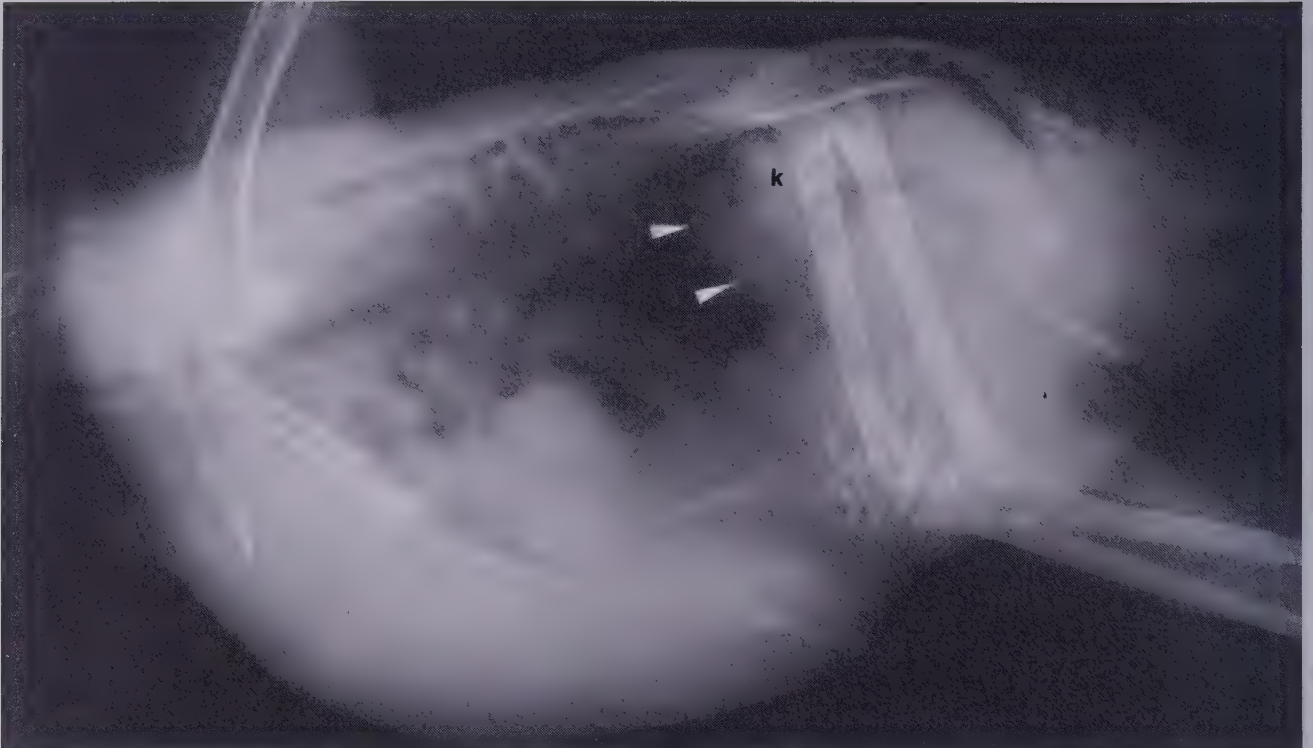




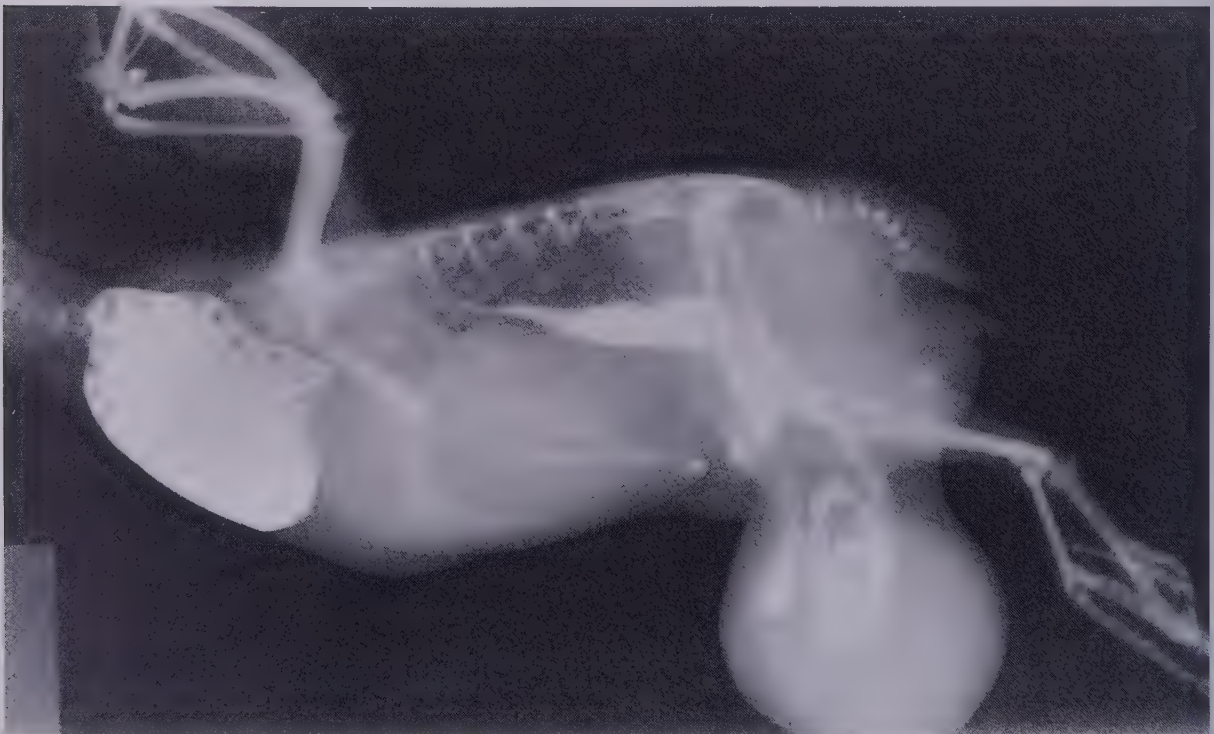
**FIG 12.62** A two-year-old Blue and Gold Macaw was presented with lethargy, anorexia and abdominal distension. Radiographs indicated a massive splenomegaly (arrow) and nephromegaly (curved arrow) caused by *Chlamydia* sp. The enlarged spleen is displacing the proventriculus (p) and ventriculus (v) ventrally and the liver (l) cranially (courtesy of Marjorie McMillan, reprinted with permission of Comp Cont Ed 8:1986).



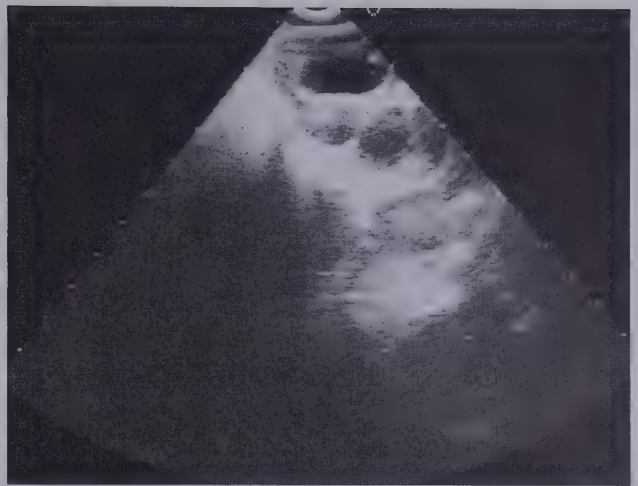
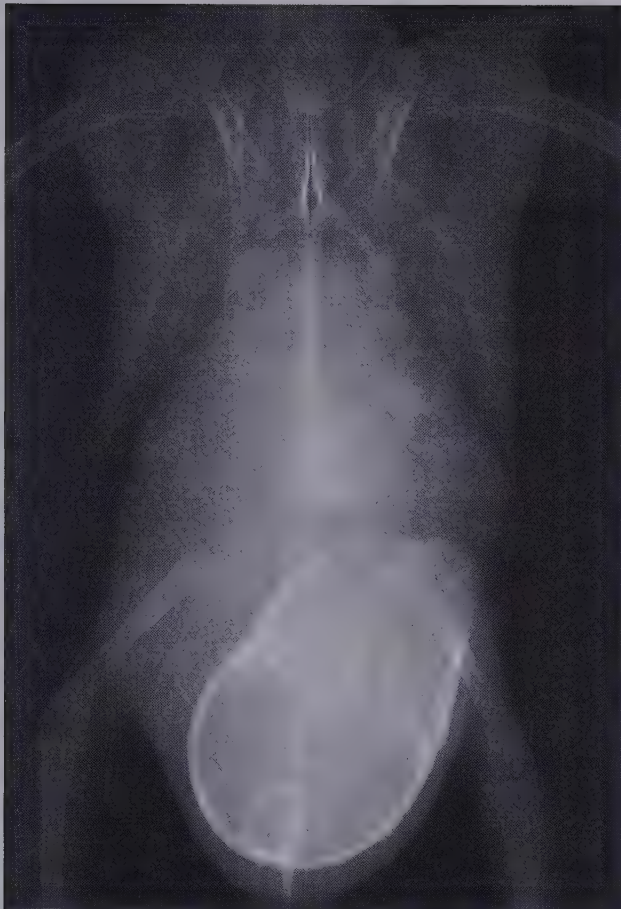**FIG 12.63** A Blue-fronted Amazon Parrot was presented with lethargy and exercise intolerance, intermittent episodes of panting and syncope. VD radiographs indicated a biatrial enlargement and a decrease in the cardiohepatic waist caused by cardiomegaly. Liver (l) (courtesy of Marjorie McMillan).



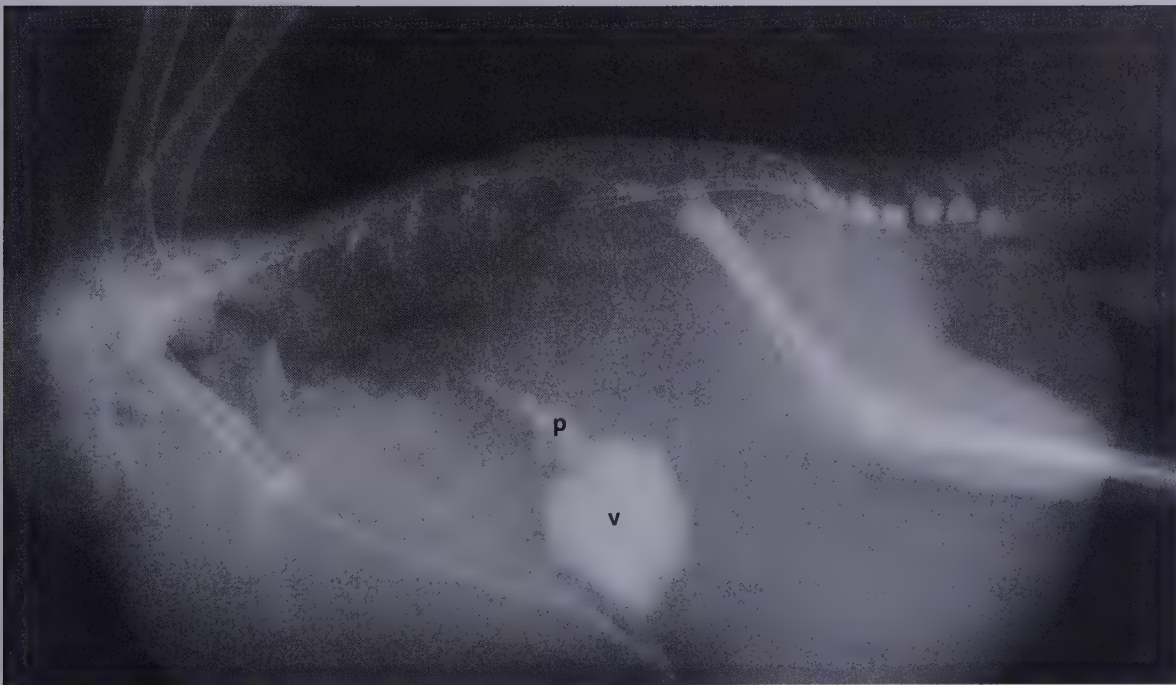
**FIG 12.64** Lateral radiograph of a Double Yellow-headed Amazon Parrot with an active ovary (arrows). Note the “grape-like” cluster of follicles cranioventral to the kidneys (k) (courtesy of Marjorie McMillan).



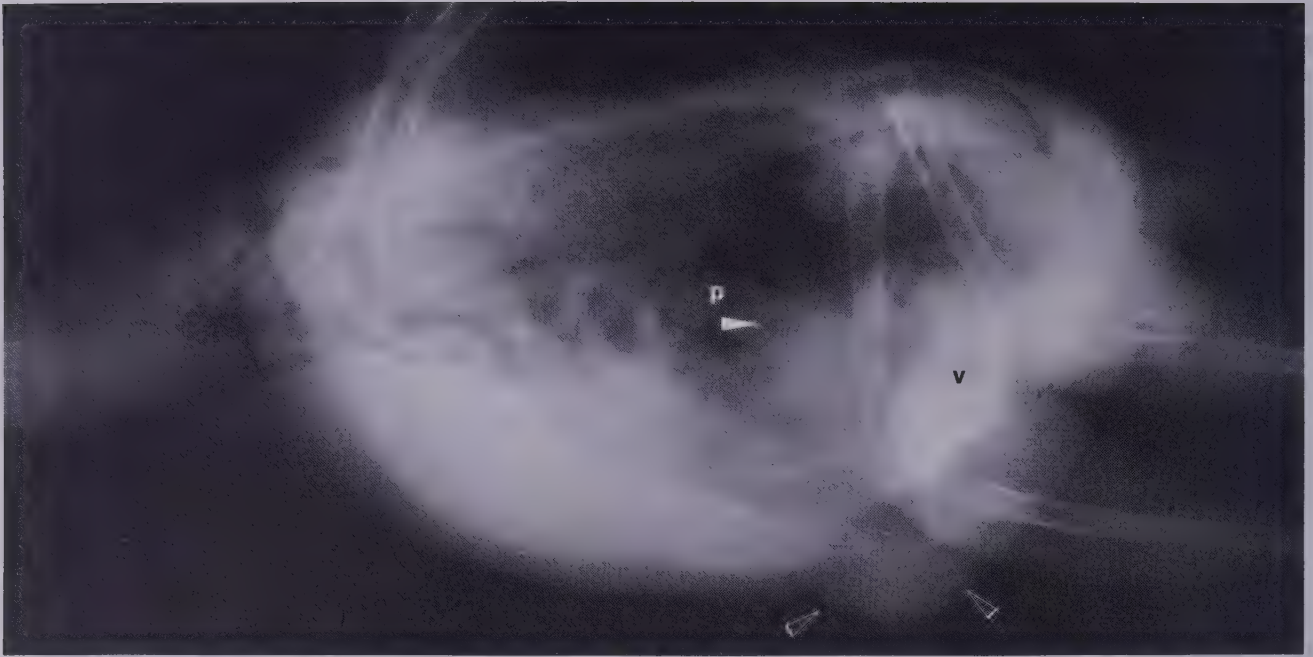
**FIG 12.65** A female budgerigar was presented for evaluation of a ventral abdominal mass. A barium contrast study indicated that the mass was herniated intestines. Note also the increased density of the skeleton (polyostotic hyperostosis). Herniation and polyostotic hyperostosis are characteristic of hyperestrogenism (courtesy of Marjorie McMillan).



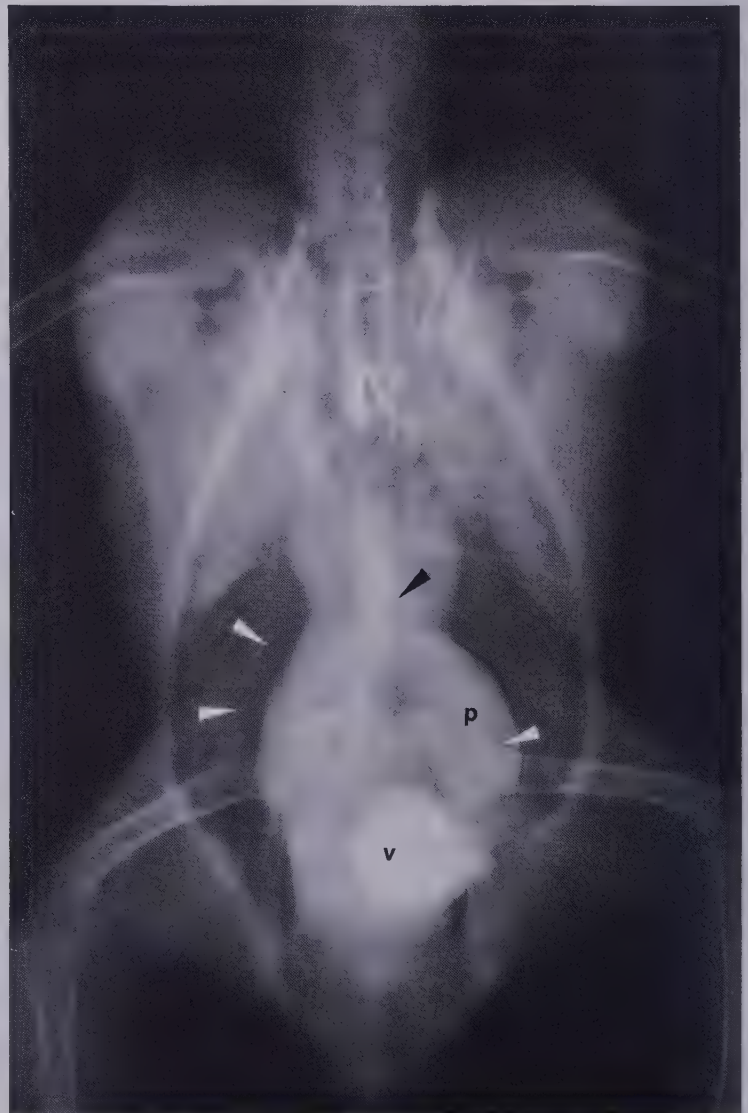**FIG 12.66** Radiographs of an egg-bound cockatiel suggest the presence of one large abnormally shaped egg and one smaller incompletely formed egg. Ultrasound indicated the presence of four eggs (courtesy of Marjorie McMillan).



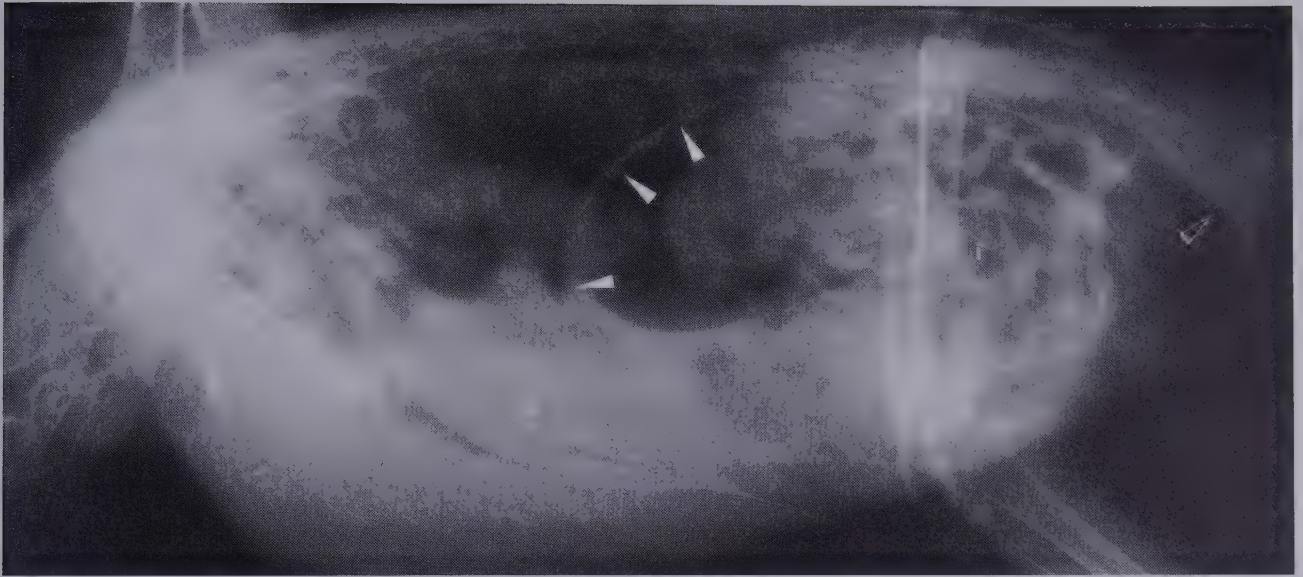
**FIG 12.67** A mature cockatiel hen was presented for dyspnea and a swollen abdomen. Radiographs indicated a fluid-filled abdomen with cranial displacement of the ventriculus (v) and proventriculus (p), both of which are impacted with grit. Abdominocentesis was consistent with an exudative effusion, and the diagnosis was egg-related peritonitis. The cranial displacement of the abdominal viscera indicates that the fluid is present in the intestinal peritoneal cavity (courtesy of Marjorie McMillan).



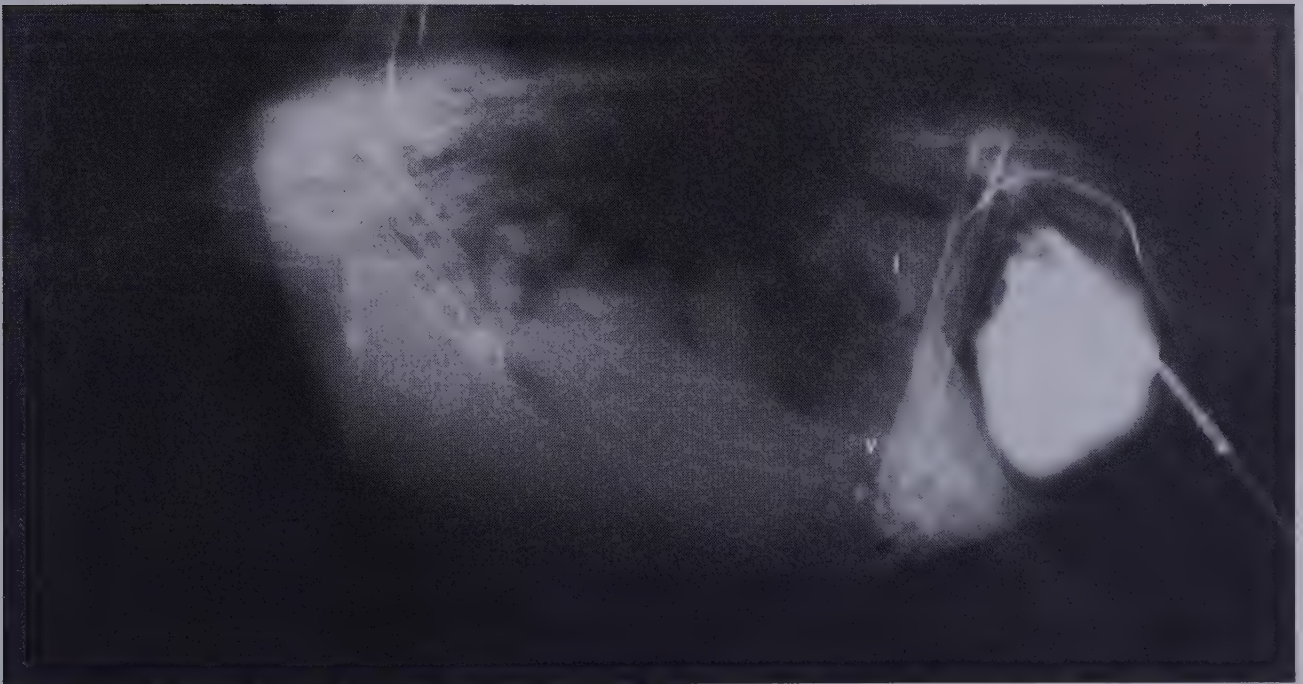
**FIG 12.68** A 35-year-old Yellow-headed Amazon Parrot was presented with a firm ventral midline mass. Radiographs indicated rounding of the liver lobes and hepatomegaly (arrows). The mass was visible as a soft tissue opacity at the caudal edge of the sternum (open arrows). An exploratory laparotomy revealed a herniated liver. Proventriculus (p), ventriculus (v) (courtesy of Marjorie McMillan).



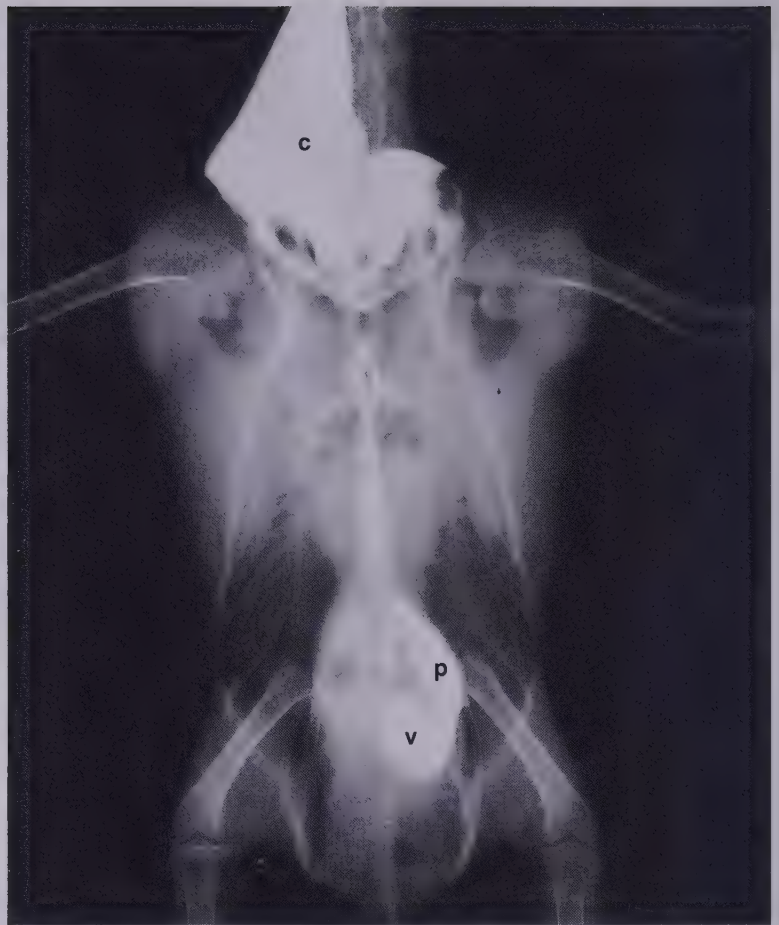




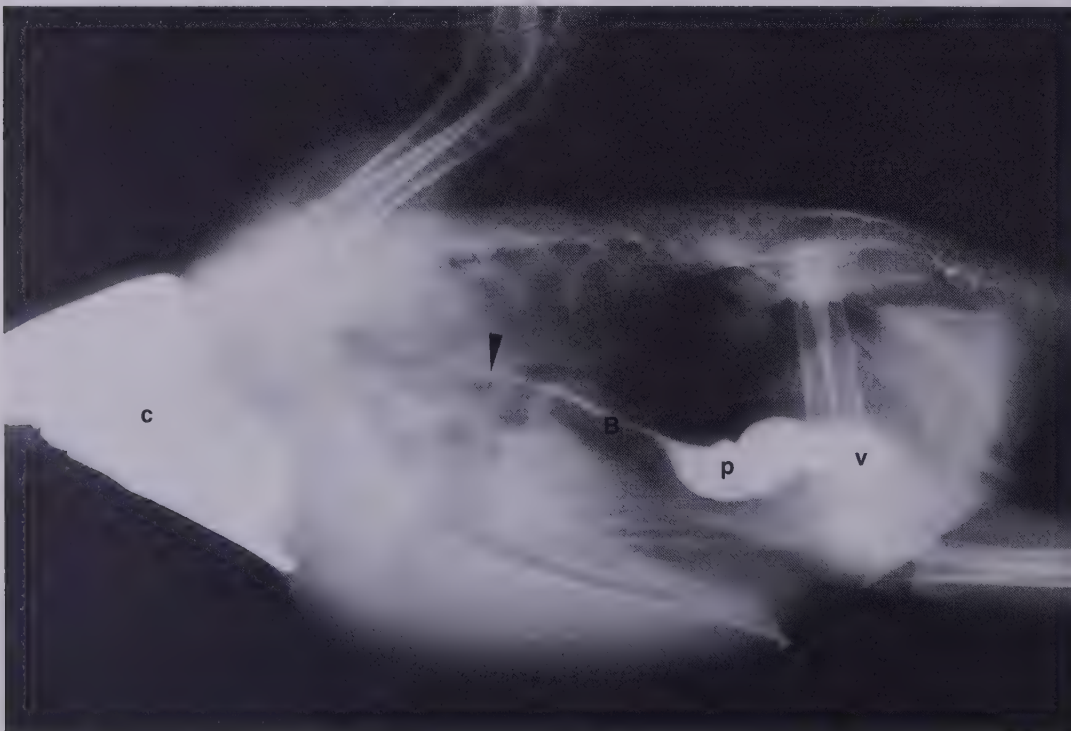
**FIG 12.69** A Blue and Gold Macaw was presented with severe dyspnea including a tail bob. The bird was sneezing and had both ocular and nasal discharges. The only abnormal clinicopathologic finding was WBC=18,000. Radiographic changes included gaseous distension of the intestines (i), thickening of the contiguous membrane of the caudal thoracic and abdominal air sac (open arrow). The client was a heavy smoker, and the lesions resolved over a three-month period when the client quit smoking and the bird received daily exposure to fresh air and sunlight.

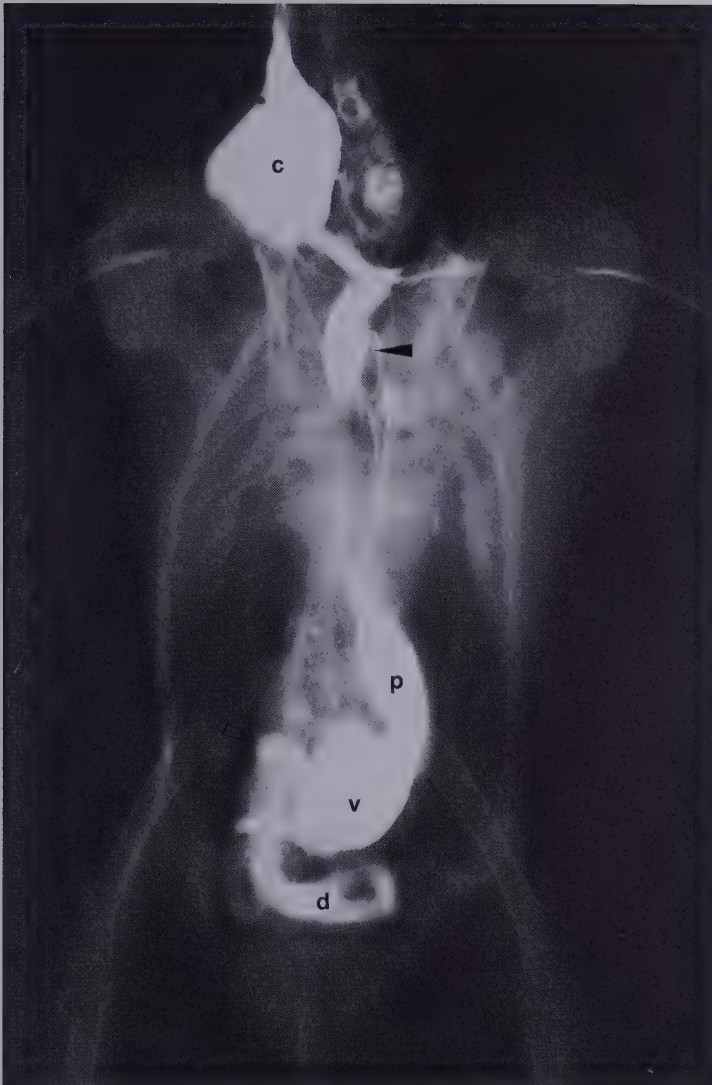

**FIG 12.70** Contrast medium was injected into the gaseously distended cloaca of an Amazon parrot with severe dyspnea. Note the cranial displacement of the intestines (i) and ventriculus (v).

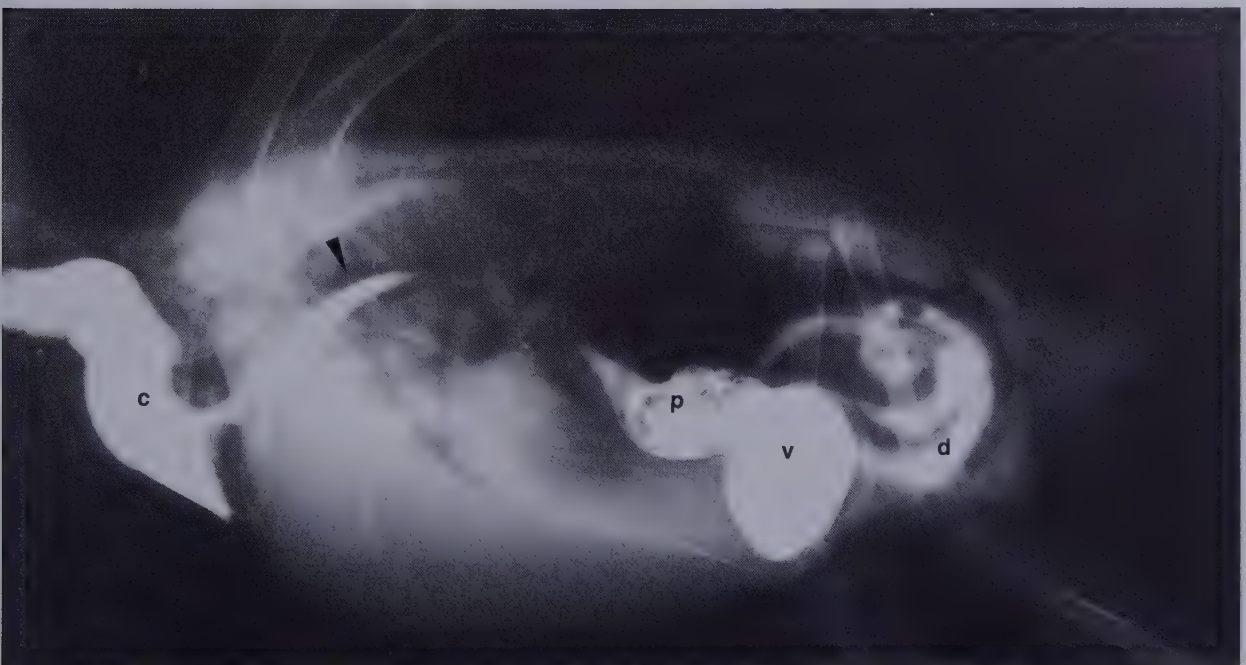


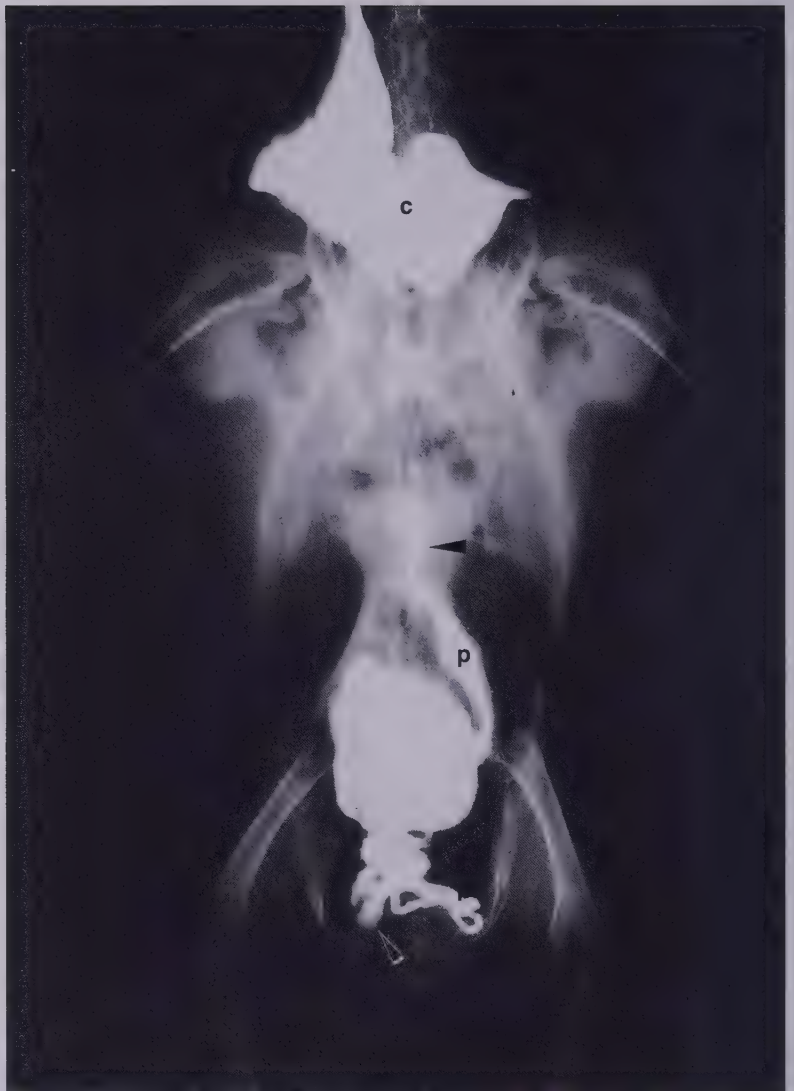**FIG 12.71** Radiographs of an adult African Grey Parrot ten minutes after administering barium sulfate. Crop (c), thoracic esophagus (arrow), proventriculus (p), ventriculus (v) (courtesy of ME Krautwald).






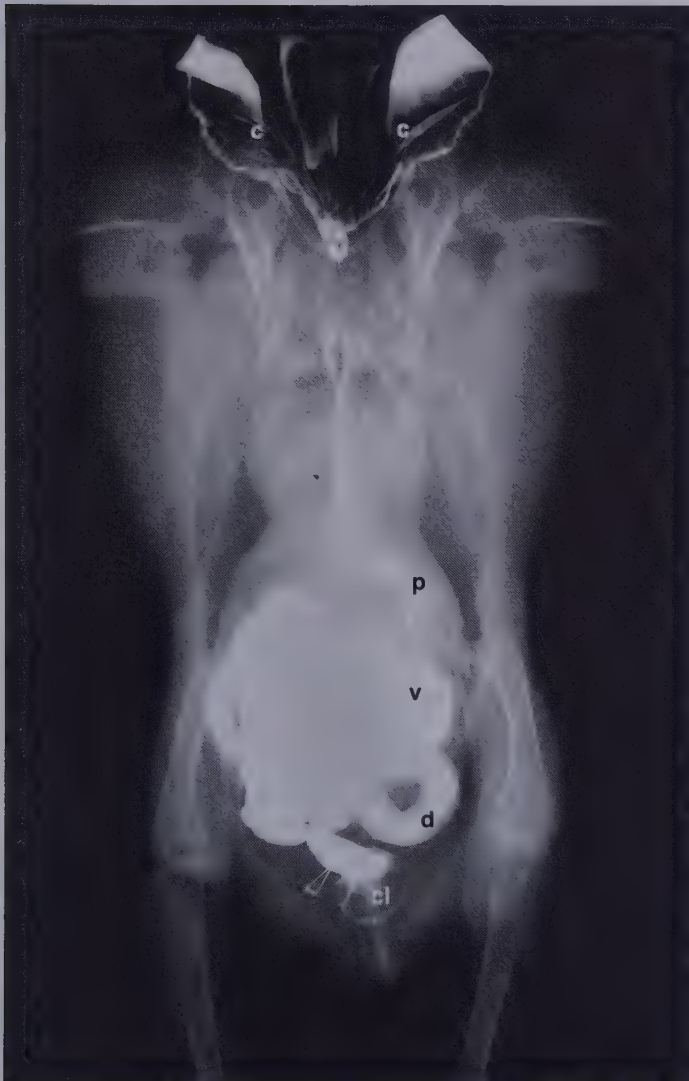
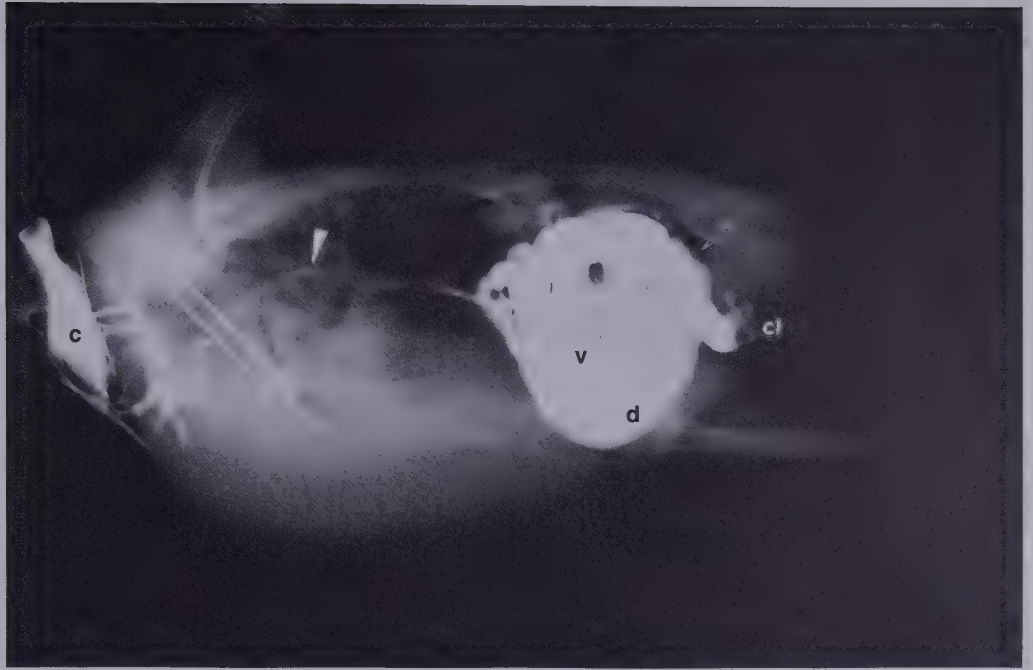
**FIG 12.72** An Amazon parrot 20 minutes after barium sulfate administration. Crop (c), thoracic esophagus (arrow), proventriculus with filling defects (p), ventriculus (v), duodenum (d), ilium and jejunum (open arrow).



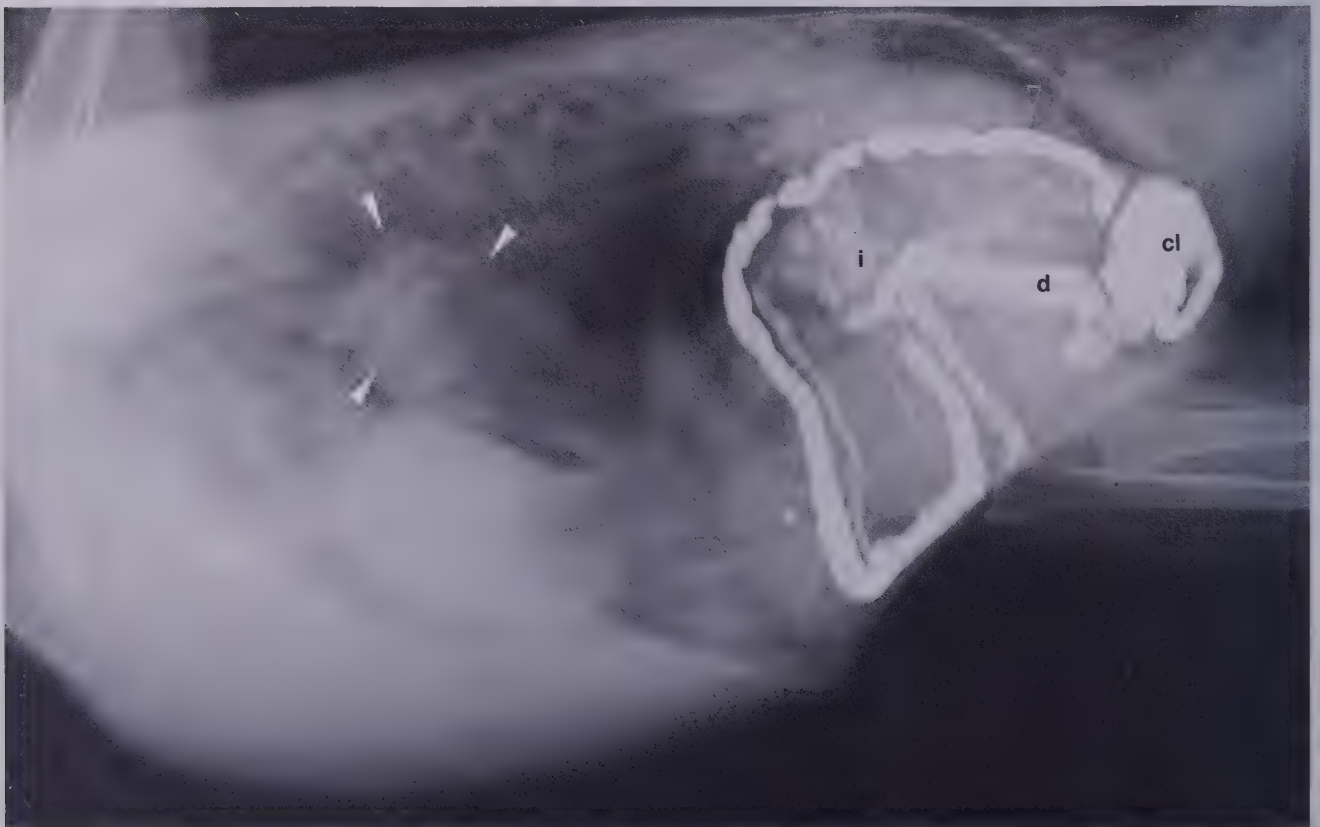
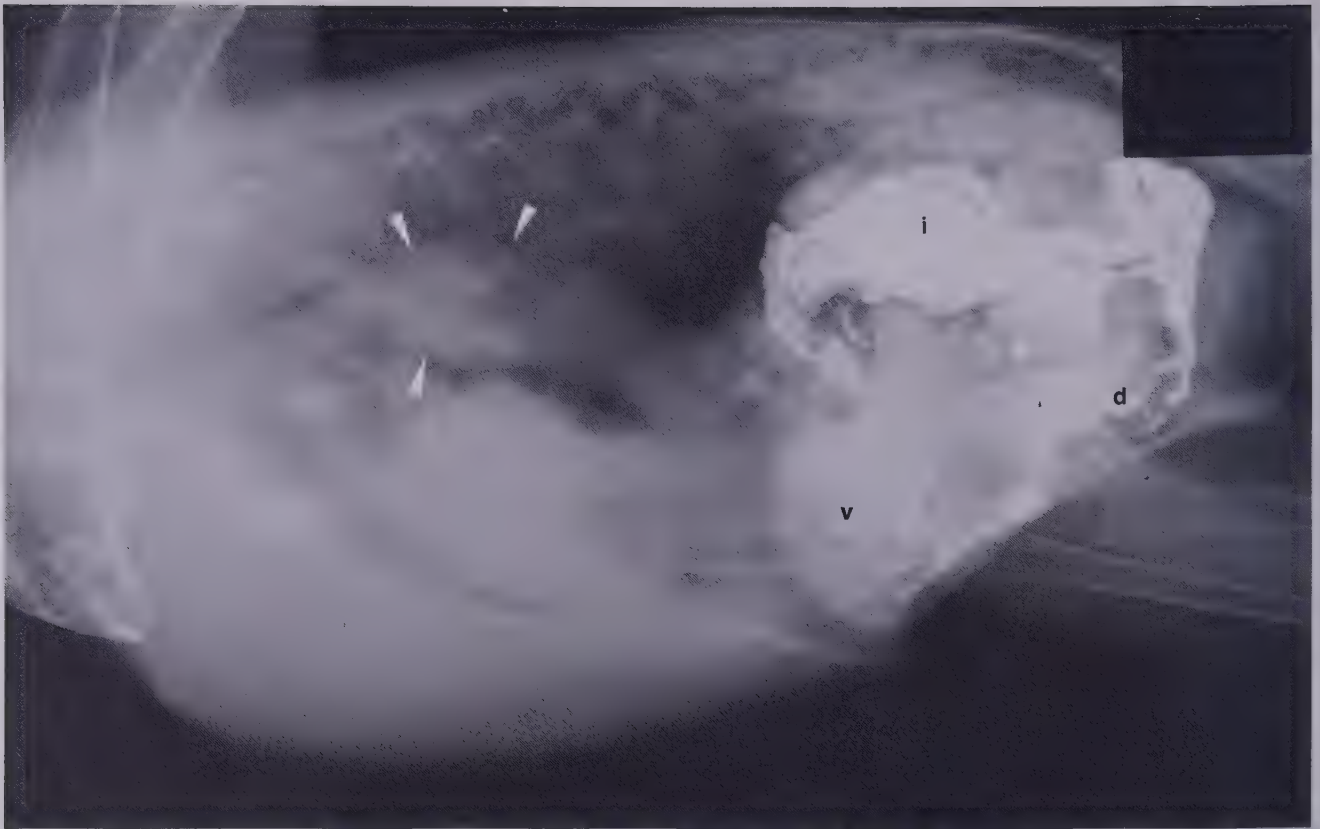


**FIG 12.73** Radiographs of an adult African Grey Parrot 60 minutes after administering barium sulfate. Crop (c), thoracic esophagus (arrow), proventriculus (p), ventriculus (v), duodenum (d), intestines (i), colon (open arrow) (courtesy of ME Krautwald).

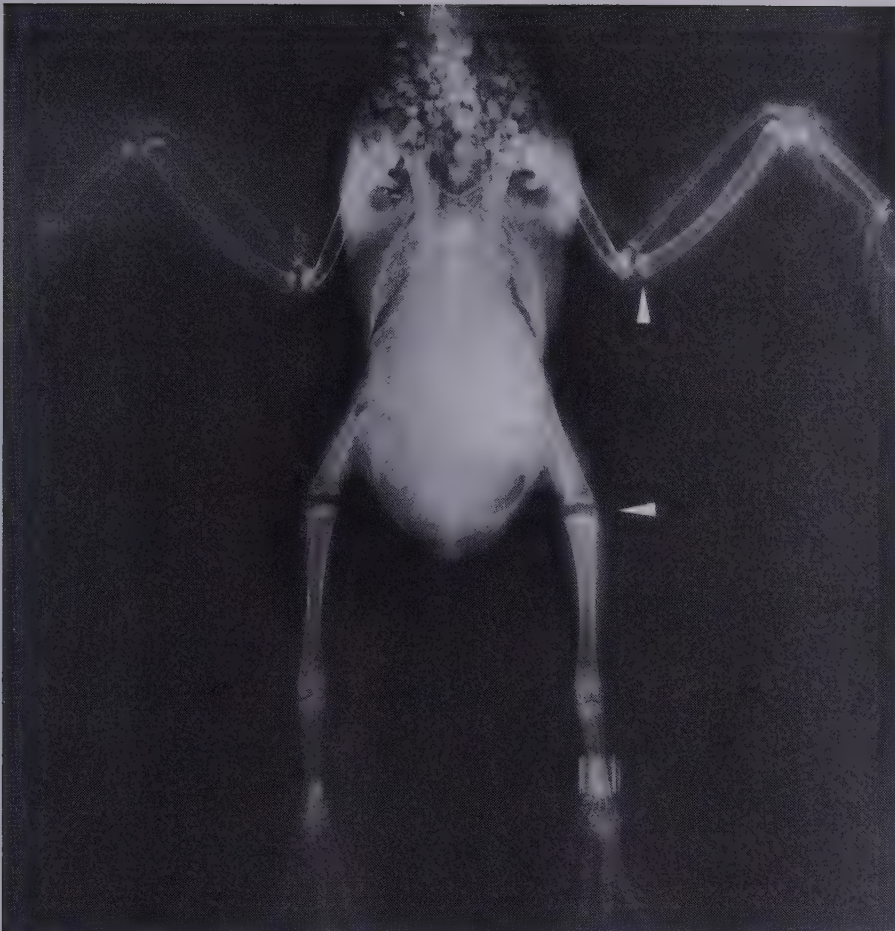



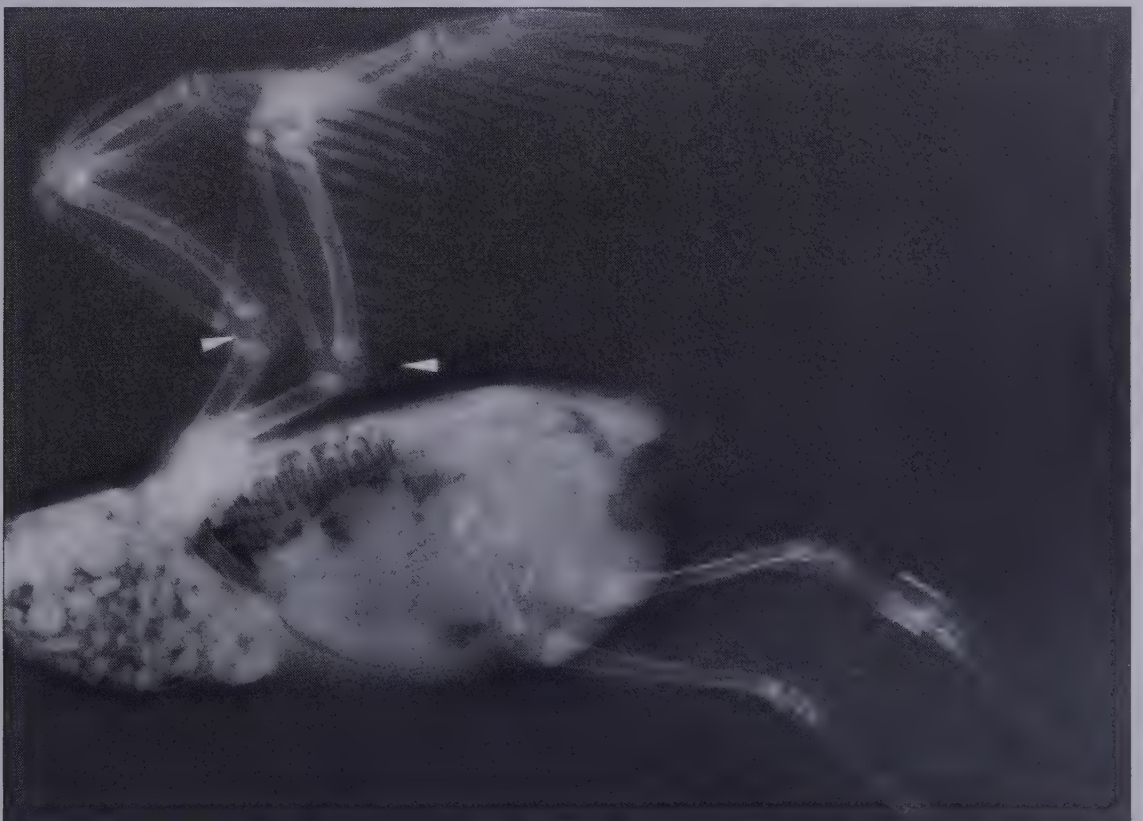
**FIG 12.74** Radiographs of an adult pigeon 20 minutes after administration of barium. Note the crop (c) is composed of two lateral compartments. Thoracic esophagus (arrow), proventriculus (p), duodenum (d), colon (open arrow), cloaca (cl) (courtesy of ME Krautwald).

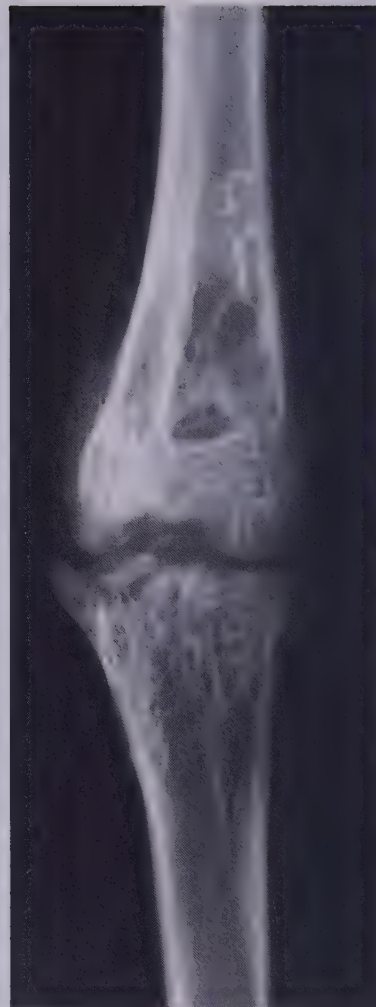
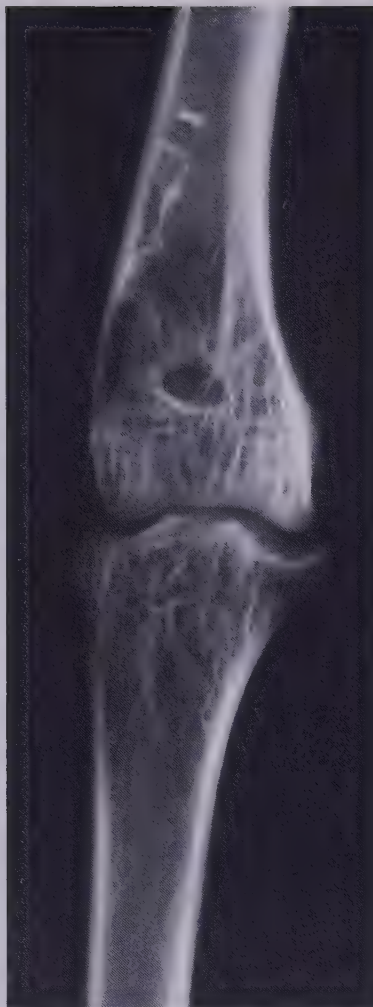

**FIG 12.75** An adult Amazon parrot was presented with a history of dyspnea and weight loss. A mass (arrows) was identified in the dorsocranial thorax. Barium contrast radiography indicated that the mass was associated with the thoracic esophagus. Radiograph **a**) was taken 45 minutes and radiograph **b**) was taken 2 hours after barium administration. Contrast medium can be seen in the ventriculus (v), ascending and descending colon (d), jejunum and ileum (i), colon (open arrow) and cloaca (c).

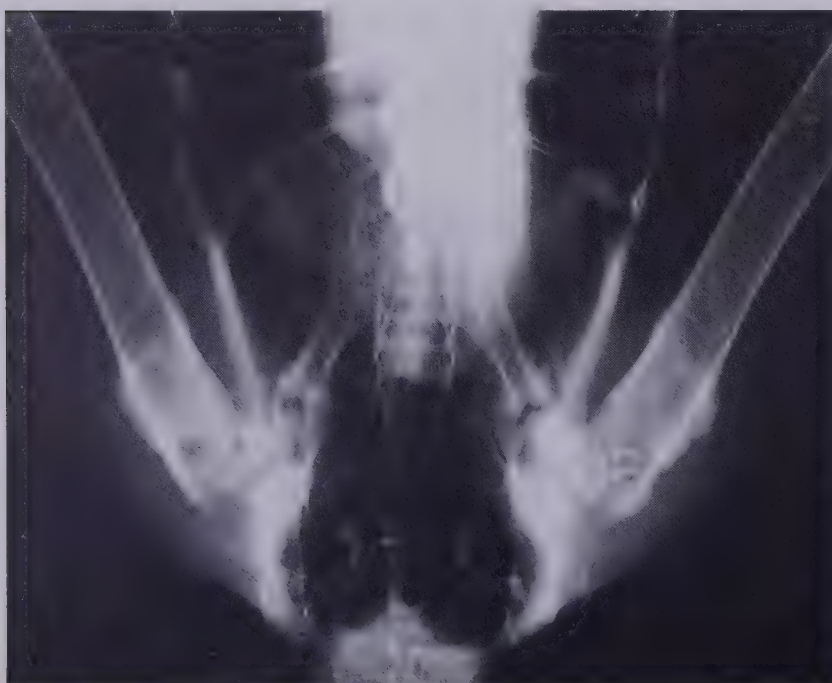

**FIG 12.76** Two-week-old pigeon. The gastrointestinal tract of neonates stays distended with food, making the delineation of abdominal structures difficult. Note the large joint spaces characteristic of developing bones in birds (arrows) (courtesy of ME Krautwald).





**FIG 12.77** An adult swan was presented with intermittent lameness. The tibiotarsal joint was hot, firm and swollen. Radiographs indicated joint enlargement, subchondral bone lysis and erosion of the intercondylar space. These lesions were suggestive of septic arthritis. Radiograph of the normal leg (left) for comparison.



**FIG 12.78** A fledgling Golden Eagle was presented with an inability to stand and a decreased range of motion in both pelvic limbs. The bird had been equipped with a radiotransmitter and released from a hack tower several weeks before presentation. The bird was not being monitored and was found hanging upside down from a tree limb with the transmitter entangling the legs. Radiographs indicated necrosis of both femoral heads. EMGs indicated denervation of both pelvic limbs. The bird was euthanated.



*Continued from page 260*

nal effusion or organomegaly, ultrasound may be used to characterize lesions (Figure 12.66).<sup>14,19,20</sup> Most studies can be performed without anesthesia. Patients may be held or secured with a plexiglass restraining device. Many birds that are minimally restrained in an upright position are extremely tolerant of the procedure. Feathers may be parted or removed, and a water-soluble, acoustic coupling gel is used to improve the transducer contact with the skin.

A 7.5 MHz end-fire mechanical sector scanner or phased array scanner is best in most birds, but 5.0 MHz and 10 MHz transducers may also be used. Higher frequency scanners provide less tissue penetration but finer resolution and are most useful in smaller species. Linear array transducers can also be used, but because of their shape, they do not conform well to the patient's body.

If the patient is in dorsal recumbency, the transducer is placed just caudal to the sternum and the beam is angled cranially. The liver has a uniform, slightly granular, echogenic pattern and is easily recognized (Figure 12.61). The right and left hepatic veins can be identified as anechoic channels on the dorsomedial aspect of the liver. A uniform, hyperechoic, hepatic parenchyma has been described in birds with fatty liver degeneration and hepatic lymphoma.<sup>16</sup> Discrete hyperechoic masses throughout the liver may represent granulomas, abscesses or neoplasms.

Hepatomegaly should be suspected if the liver can be detected caudal to the sternum. Ultrasound is of little value in detecting acute or chronic hepatitis, and it is difficult to differentiate between cirrhosis and necrosis. Granulomas and neoplasms typically appear as focal hyperechoic walls with an echoic center. Hematomas and subcapsular bleeding will appear hypoechoic.

The liver may be used as a window to visualize the cardiac silhouette. Pericardial effusion and enlargement of cardiac chambers and valvular abnormalities can be detected in larger species. Pulmonary masses such as large granulomas have been defined using ultrasonography. A lateral approach can be used for visualization of the spleen, which is normally hyper-echoic in comparison to the liver and is difficult to define unless enlarged.<sup>16</sup>

Ultrasonographic visualization of the kidneys and gonads is not possible due to the presence of the air

sacs, although large ovarian follicles can occasionally be defined. Ultrasound can be used to differentiate between soft-shelled eggs and egg-related peritonitis. Poorly mineralized eggs are often oval with a hyperechoic rim surrounding a hypoechoic content. With egg-related peritonitis, there is a heterogeneous hyperechoic appearance to the coelomic cavity (Figure 12.66). Effusion due to other processes is often anechoic or hypoechoic.

The presence of ingesta or gas will obscure portions of the gastrointestinal tract. Differentiation of the proventriculus, ventriculus and cloaca can be enhanced by administering water.

Ultrasound-guided biopsy can be used to collect diagnostic samples from the liver. The patient must be sedated or anesthetized. A variety of needles may be used for the biopsy. In larger species a 22 ga Westcott needle is used to obtain specimens for cytology, histology and culture. Spinal needles and 25 ga hypodermic needles may be used, but may be difficult to localize with the ultrasound beam and often yield only enough material for cytology.

### ■ Nuclear Scintigraphy

The potential value of nuclear medicine studies in avian patients remains unexplored. The usefulness of musculoskeletal scintigraphy in other species is well recognized.<sup>9</sup> Three-phase bone scans allow evaluation of the blood supply, soft tissue component and skeleton and are especially useful in occult lesions or abnormalities that are undetectable on survey radiographs. Unexplained abnormalities of the extremities, especially following trauma, would be most suitable for bone scintigraphy. Evaluation of the extent of osteomyelitis, joint disease, vascular compromise, impaired fracture healing and less commonly, bone neoplasia, is enhanced by nuclear medicine studies.

Technetium-99m (<sup>99m</sup>Tc) is the isotope most frequently used because of its short half-life (six hours) and ideal energy range (140KeV). For bone scanning, the radiopharmaceutical most commonly used is <sup>99m</sup>Tc methylene diphosphonate (MDP). A whole body scan of most birds is easily obtained because the entire patient can rest on the head of the gamma camera.

Patients must be kept motionless, so sedation or anesthesia is necessary. One millicurie of radioisotope is administered intravenously, and dynamic images are obtained immediately for the vascular

phase, and within the first 15 minutes for the soft tissue phase. Delayed static images are taken within three to four hours for the bone phase.

### Computed Tomography

Computed tomography (CT) is superior to other modalities except magnetic resonance imaging for evaluation of head trauma and abnormalities involving the brain and spinal cord; however, the lack of availability and high cost often prevent the use of

computed tomography in birds. Patients must be anesthetized to prevent any motion during the scan. Technical factors are inadequately studied in birds; however, slice section thickness ranging from 2 mm to 5 mm non-overlapping with varying window settings have been described for body scans.<sup>8,17</sup> The value of CT in avian diagnostic radiology remains relatively uninvestigated, but characterization of lesions with CT should prove as valuable as in other species.

### References and Suggested Reading

1. **Blackmore DK, Cooper JE:** Diseases of the reproductive system. In Petrak ML (ed): *Diseases of Cage and Aviary Birds* 2nd ed. Philadelphia, Lea and Febiger, 1982, pp 458-467.
2. **Bush M, et al:** The healing of avian fractures: A histologic xeroradiographic study. *J Am Anim Hosp Assoc* 12(6):768-773, 1976.
3. **Curry TS, et al:** Christensen's Physics of Diagnostic Radiology. Philadelphia, Lea and Febiger, 1990.
4. **Evans S:** Avian Radiography. In Thrall DE (ed): *Textbook of Veterinary Diagnostic Radiology*. Philadelphia, WB Saunders, Co, 1986.
5. **Hendee WR, et al:** Radiologic Physics, Equipment and Quality Control. Chicago, Mosby Yearbook Medical Publishers Inc, 1977.
6. **Krautwald ME:** Radiographic examination of the urinary tract in birds with organic iodinated contrast media. *Proc Assoc Avian Vet*, 1987, pp 177-193.
7. **Krautwald ME, et al:** Atlas of Radiographic Anatomy and Diagnosis of Cage Birds. Berlin, Paul Parey, 1992.
8. **Krautwald ME:** Radiology of the respiratory tract and use of computed tomography in psittacines. *Proc Assoc Avian Vet*, 1992, pp 366-373.
9. **Lamb CR:** Bone scintigraphy in small animals. *J Am Vet Med Assoc* 191(12):1616-1621, 1987.
10. **McMillan MC:** Avian radiology. In Petrak, ML (ed): *Diseases of Cage and Aviary Birds* 2nd ed. Philadelphia, Lea and Febiger, 1982, pp 329-360.
11. **McMillan MC:** Avian gastrointestinal radiology. *Comp Cont Educ Pract Vet* 5(4):55-60, 1983.
12. **McMillan MC:** Radiology of avian respiratory diseases. *Comp Contin Educ Pract Vet* 8(8):551-558, 1986.
13. **McMillan MC:** Radiographic diagnosis of avian abdominal disorders. *Comp Cont Educ Pract Vet* 8(9):616-632, 1986.
14. **McMillan MC:** Imaging of avian urogenital disorders. *J Assoc Avian Vet* 2(2):74-82, 1988.
15. **Morgan JP:** Systematic radiographic interpretation of skeletal diseases in small animals. *Vet Clin No Am* 4(4):611-626, 1974.
16. **Newell SM, et al:** Diagnosis and treatment of lymphocytic leukemia and malignant lymphoma in a pekin duck. *J Assoc Avian Vet* 5(2):83-86, 1991.
17. **Oross SE, Toal RL:** Tomographic anatomy of the golden eagle (*Aquila chrysaetos*). *J Zoo and Wildl Med* 23(1):39-46, 1992.
18. **Paul-Murphy JR, et al:** Psittacine skull radiography. *Vet Rad* 31(3):125-131, 1990.
19. **Peterson ME, et al:** Ultrasonic imaging in diagnosis of an abdominal mass in a pigeon. *Mod Vet Pract*, pp 825-826, 1983.
20. **Riedel U:** Ultrasonography in birds. *Proc First Conf Europ Assoc Avian Vet*, 1991, pp 190-198.
21. **Schlumberger HJ:** Polyostotic hyperostosis in the female parakeet. *Am J Pathol* 35(1):1-23, 1959.
22. **Storm J, Greenwood AG:** Fluoroscopic investigation of the avian gastrointestinal tract. *Proc Europ Conf Avian Med Surg*, 1993, pp 170-177.
23. **Stauber E, et al:** Polyostotic hyperostosis associated with oviductal tumor in a cockatiel. *J Am Vet Med Assoc* 196(6):939-940, 1990.
24. **Squire LF, et al:** Exercises in Diagnostic Radiology Volume 3 Bone. Philadelphia, WB Saunders Co, 1972.
25. **Ticer JW:** *Veterinary Practice*. Philadelphia, WB Saunders Co, 1984.
26. **Walker M, Goble D:** Barium sulfate bronchography in horses. *Vet Rad* 21(2):85-90, 1980.
27. **Walsh MT, Moys MC:** Clinical manifestations of cervicoccephalic air sacs of psittacines. *Comp Cont Educ Pract Vet* 6(9):783-792, 1984.
28. **Watters JW:** Development of a technique chart for the veterinarian. *Comp Cont Educ Pract Vet* 11(7):568-571, 1980.
29. **Wortman JA:** Film/screen combinations for fine detail radiography. *Vet Med Report* 3(1):80-86, 1991.
30. **Rübel GA, et al:** Atlas of Diagnostic Radiology of Exotic Pets. Philadelphia, W.B. Saunders Co., 1991.

**T**he development of a rigid rod-lens system and the perfection of fiberoptic cables in the late 1950's and early 1960's heralded the modern age of endoscopy in human medicine. A unique lens design<sup>9</sup> allowed for improved light transmission in small diameter telescopes. Over the next decade, various rigid endoscopes were introduced into human gynecology, orthopedics and otolaryngology. By the middle 1970's veterinarians were employing these endoscopes in animal species, and the concept of rigid endoscopy was introduced to avian practitioners.<sup>2,27</sup>

A growing interest in aviculture, particularly of psittacine birds, must also be credited with stimulating the field of avian endoscopy. Endoscopic determination of gender (surgical sexing)<sup>22</sup> has become an integral part of the captive management of many avian species. Birds are ideal subjects for endoscopic examination due to the unique design of their respiratory system, which provides extensive pneumatization of the coelom. A variety of diagnostic uses for endoscopy in birds has previously been described;<sup>2,8,19,21</sup> however, the greater benefits of this technology have hardly been explored. New developments in equipment and techniques are certain to increase the value of endoscopy to avian veterinarians.

CHAPTER

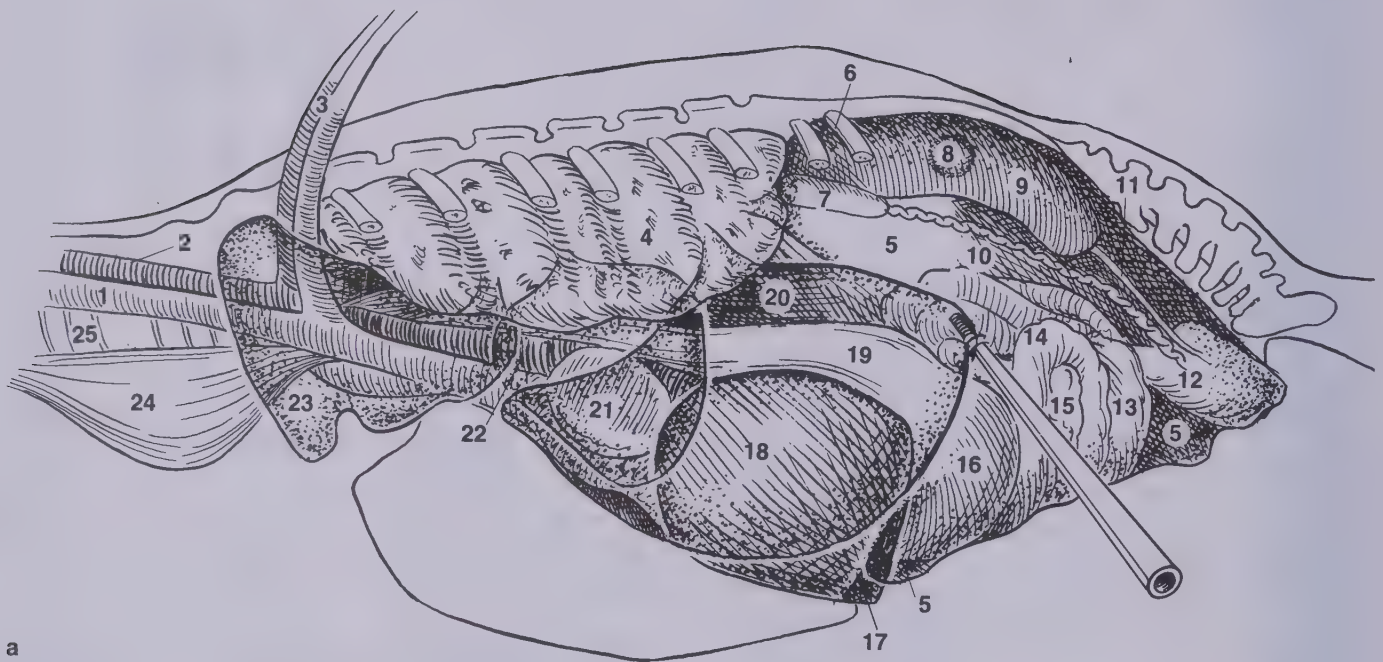
---

# 13

## ENDOSCOPIC EXAMINATION AND BIOPSY TECHNIQUES

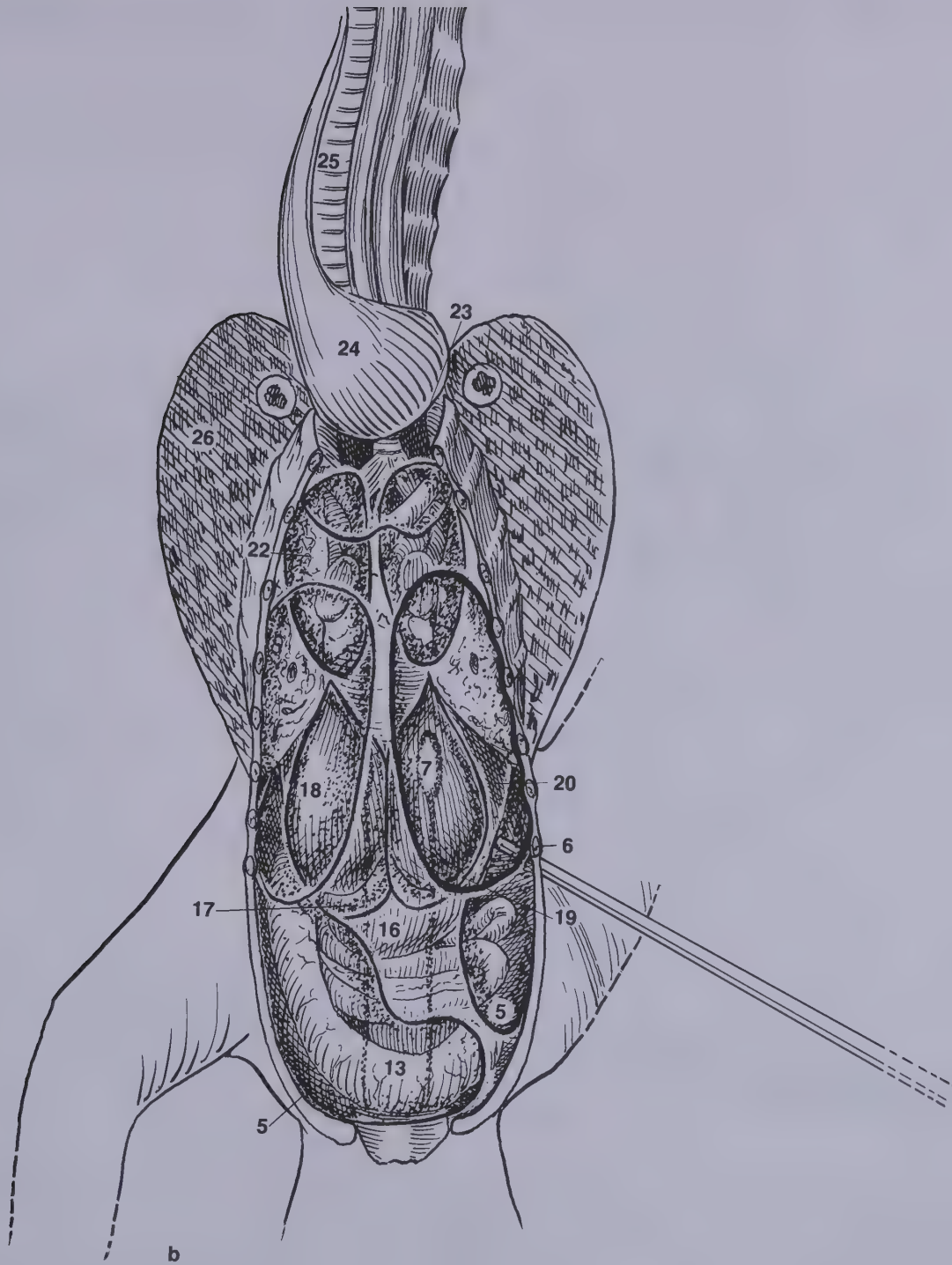
---

**Michael Taylor**



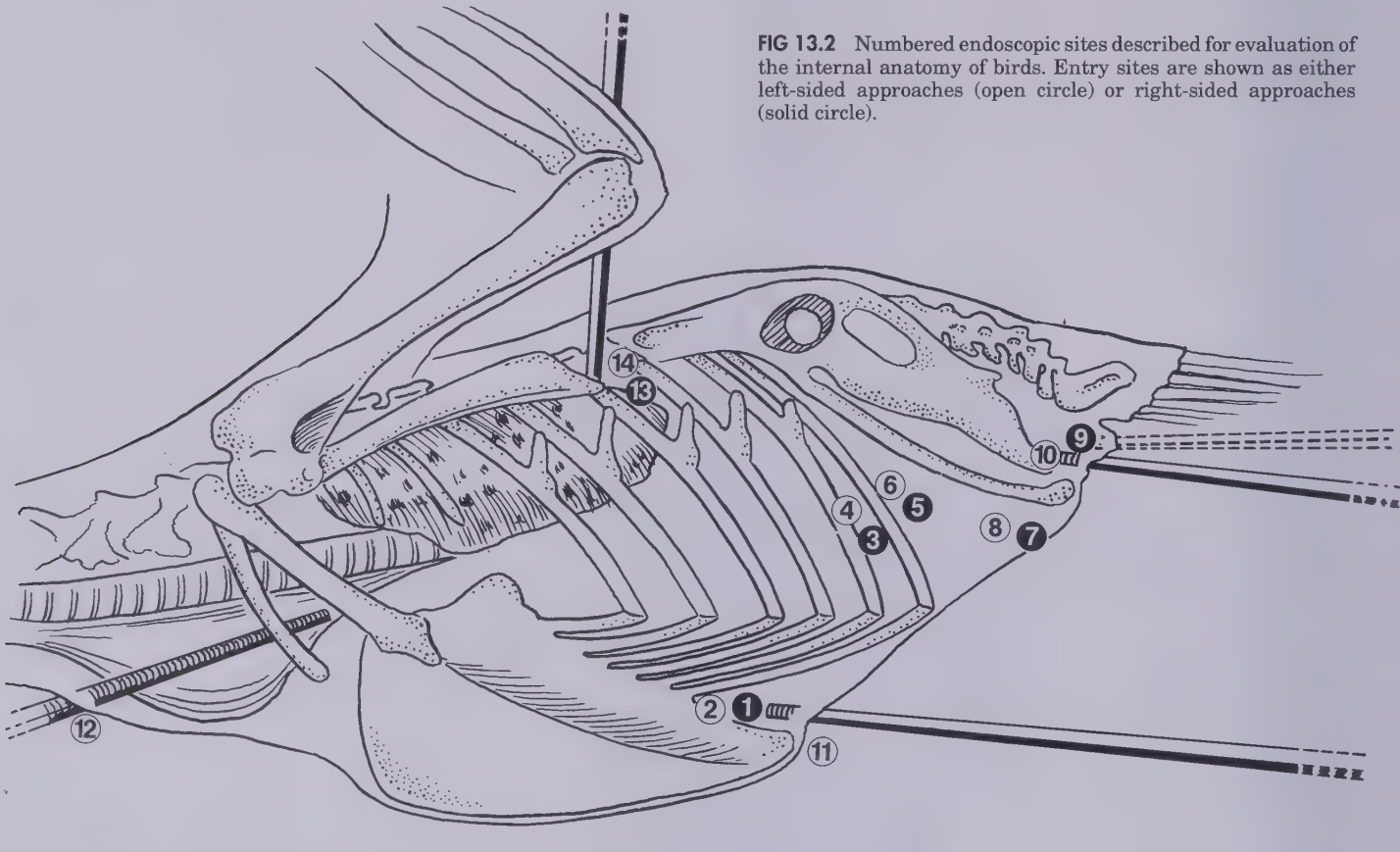
- |                                    |                  |                                       |                              |
|------------------------------------|------------------|---------------------------------------|------------------------------|
| 1) internal carotid artery         | 8) oscoxae       | 15) pancreas                          | 22) cranial thoracic air sac |
| 2) jugular vein                    | 9) kidney        | 16) ventriculus                       | 23) clavicular air sac       |
| 3) subclavian vessels              | 10) vas deferens | 17) ventral hepatic peritoneal cavity | 24) crop                     |
| 4) lung                            | 11) ureter       | 18) liver                             | 25) trachea                  |
| 5) abdominal air sac               | 12) cloaca       | 19) proventriculus                    | 26) pectoral muscle          |
| 6) eighth rib                      | 13) colon        | 20) caudal thoracic air sac           |                              |
| 7) gonad (in this case a testicle) | 14) duodenum     | 21) heart                             |                              |

**FIG 13.1** a) An artist's impression of the lateral view of a bird showing anatomic structures of importance when endoscope is in position 6 (see Figure 13.2).

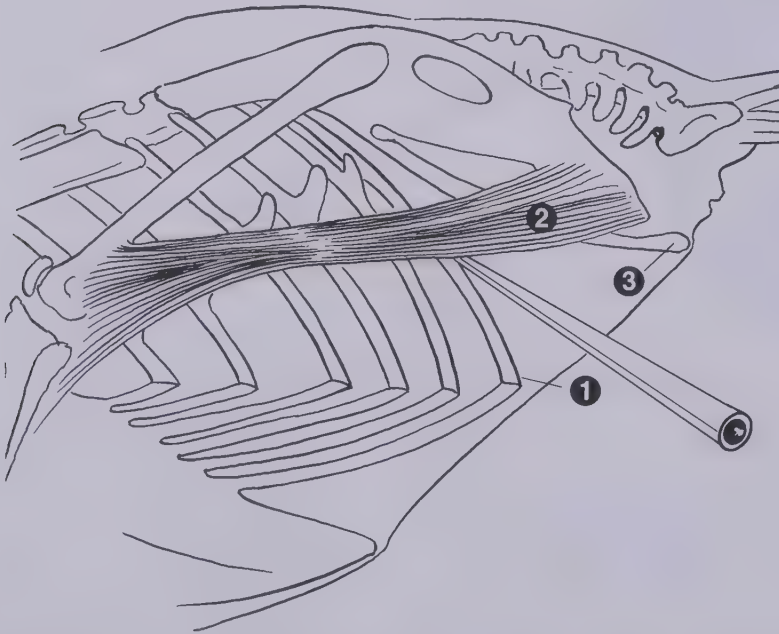


- |                                    |                  |                                       |                              |
|------------------------------------|------------------|---------------------------------------|------------------------------|
| 1) internal carotid artery         | 8) oscoxae       | 15) pancreas                          | 22) cranial thoracic air sac |
| 2) jugular vein                    | 9) kidney        | 16) ventriculus                       | 23) clavicular air sac       |
| 3) subclavian vessels              | 10) vas deferens | 17) ventral hepatic peritoneal cavity | 24) crop                     |
| 4) lung                            | 11) ureter       | 18) liver                             | 25) trachea                  |
| 5) abdominal air sac               | 12) cloaca       | 19) proventriculus                    | 26) pectoral muscle          |
| 6) eighth rib                      | 13) colon        | 20) caudal thoracic air sac           |                              |
| 7) gonad (in this case a testicle) | 14) duodenum     | 21) heart                             |                              |

**b)** An artist's impression of the VD view of a bird showing anatomic structures of importance when performing endoscopy from various entry sites: When the scope is introduced through entry site 6 (see Figure 13.2), it enters the caudal thoracic air sac. On the VD view it may appear as though the scope goes through the abdominal air sac as well. The abdominal air sac actually forms a backwards C positioned dorsal and ventral to the caudal thoracic air sac (see Anatomy Overlay). In some species, the right and left abdominal air sacs may be more symmetrical than shown.

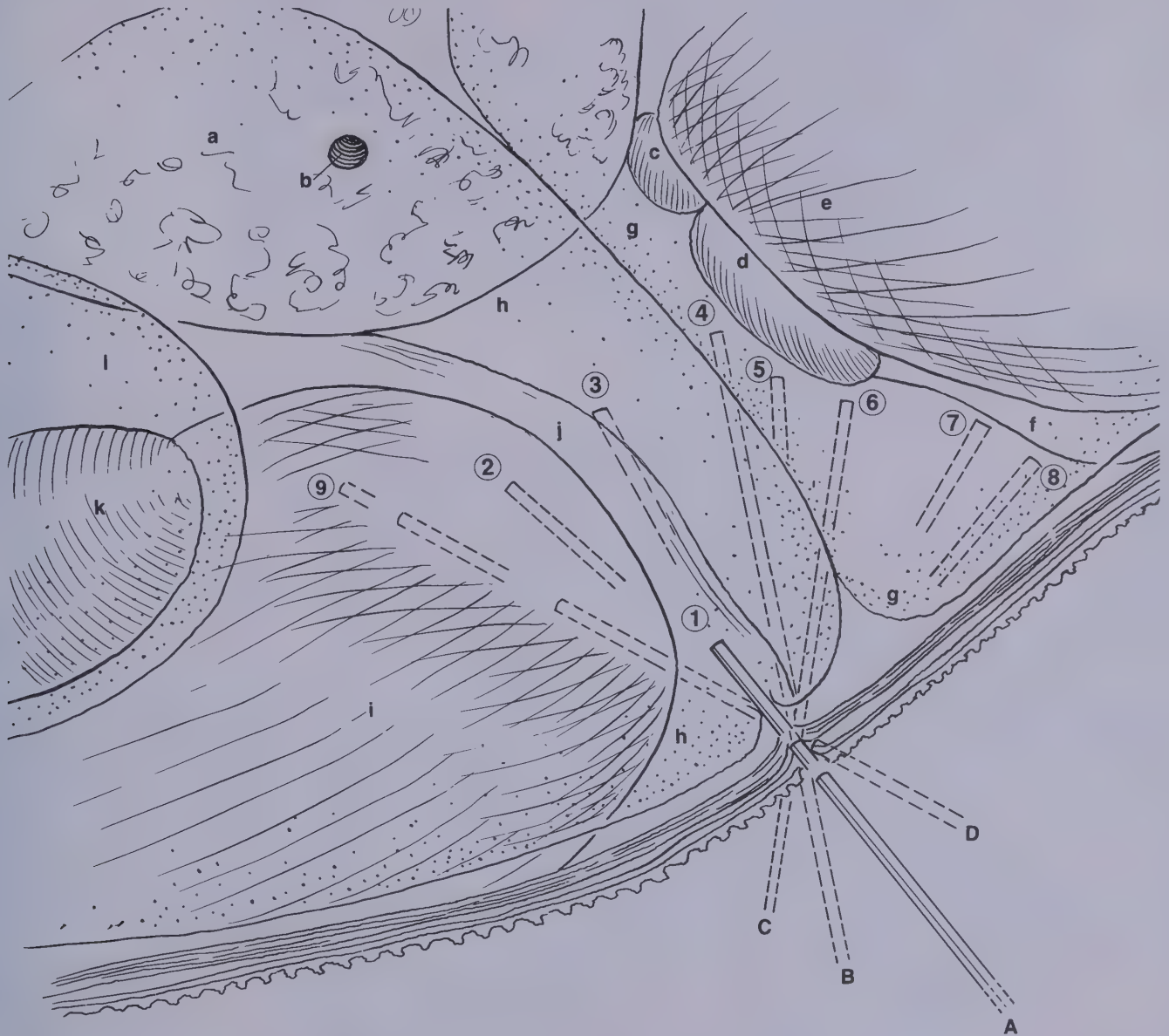


**FIG 13.2** Numbered endoscopic sites described for evaluation of the internal anatomy of birds. Entry sites are shown as either left-sided approaches (open circle) or right-sided approaches (solid circle).



**FIG 13.3** Left flank approach for endoscopic evaluation of the bird. The leg is pulled cranially and the entry site is at the junction of the caudal edge of the 1) eighth rib and the 2) flexor cruris medialis muscle. 3) The pubic bone serves as an additional landmark. This approach is listed as entry site 6 in Figure 13.2.

Endoscopic laparotomy can be performed from either the right or left side of a bird, and 14 different approaches have been described. These approaches are depicted in Figure 13.2. Site 4, located between the seventh and eighth ribs, is frequently used for endoscopic evaluation of the gonads; however, an entrance point through the left flank (site 6, Figure 13.3) just ventral to the flexor cruris medialis muscle and caudal ventral to its interjection with the vertebral portion of the eighth rib and the pubic bone is a site that provides better visualization of many abdominal structures.



**FIG 13.4** An artist's rendition of the anatomic features that are visible when the endoscope is placed in different directions and at different depths from entry site 6 (Figure 13.2). By matching the angle and depth of the endoscope, the endoscopist can develop an insight into the relative position of organs as viewed from entry site 6. The views are divided into four angles (A,B,C,D) and depths (1 through 9). Each color endoscopic picture has a corresponding angle and position marker to help the endoscopist envision the anatomic relationship of the endoscopic view. Thus, if the scope is oriented to B-4, the gonad, adrenal gland and kidney would be in view. Structures that will be used for orientation in the various endoscopic pictures include: a) lung b) ostium of the cranial thoracic air sac c) adrenal gland d) gonad e) kidney f) ureter, oviduct, vas deferens area g) abdominal air sac h) caudal thoracic air sac i) liver j) proventriculus k) heart and l) cranial thoracic air sac.

## ■ Endoscopic Examination and Biopsy Techniques

Understanding the relationship of structures is critical to effective endoscopy. This approach to endoscopic anatomy will guide the clinician through the evaluation of thoracoabdominal structures that can be viewed from various entrance points to the abdominal cavity. (All color photographs in this section © 1994 by Michael Taylor.)

### Color 13.1

The left abdominal wall has been removed from an Amazon parrot. Note the tiered effect of the cranial thoracic (open arrows), caudal thoracic (arrows) and abdominal air sacs (a). The intestinal peritoneal cavity (IPC) has been infused with red dye. Other prominent organs include the lung (lu), heart (h), liver (li) and proventriculus (p).

### Color 13.2

A bird is placed in right lateral recumbency with the leg extended cranially to show the insertion point to entry site 6 (see Figure 13.2). Dotted lines mark the caudal edge of the eighth rib (r), the flexor cruris medialis muscle (m) and the pubic bone (p). The entrance site is at the junction of the eighth rib and the flexor cruris medialis muscle.

### Color 13.3

Endophotograph of entry site 6 to show the eighth rib (r), ventral border of the flexor cruris medialis muscle (m) and the penetration point in the lateral abdominal wall.

### Color 13.4

(Position A-1 see Figure 13.4) Immediately after entering the abdominal cavity of an Amazon parrot, the caudal thoracic air sac can be visualized. The air sac should be transparent with minimal vascularity. The proventriculus (p) is ventral to the endoscope. The medial wall of the caudal thoracic air sac (a) becomes contiguous with the lateral wall of the abdominal air sac.

### Color 13.5

(Position A-2 see Figure 13.4) Normal caudal thoracic air sac of an Amazon parrot. In this view, a clear, unobstructed view of the ostium (o) of the caudal thoracic air sac indicates that the tip of the endoscope is within this air space. Also visible are the dorsal edge of the left liver (li), lung (lu), proventriculus (p) and the confluent wall of cranial thoracic and caudal thoracic air sac (open arrow). The proventricular arteries are clearly visible (arrow).

### Color 13.6

(Position A-3 see Figure 13.4) Normal organs and air sacs in an Amazon parrot. Ostium (o), lung (lu), proventriculus (p), liver (li), confluent wall of cranial and caudal thoracic air sacs (open arrow) and confluent wall of caudal thoracic and abdominal air sacs (arrow).

### Color 13.7

(Position B-4 see Figure 13.4) Mature melanistic left testicle (t) of a Goffin's Cockatoo. Also visible are the left adrenal gland (a), ilium (i), cranial pole of the left kidney (k), left common iliac vein (arrow) and aorta (open arrow).

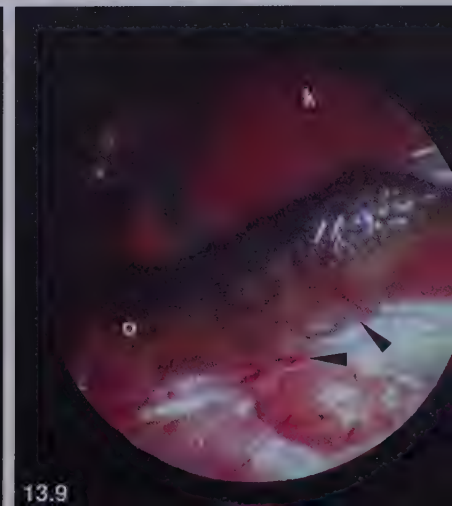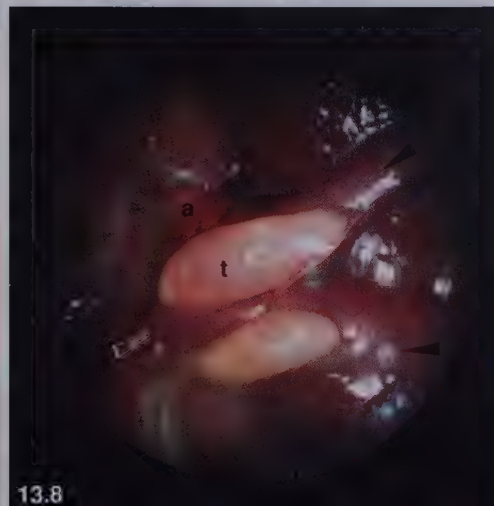
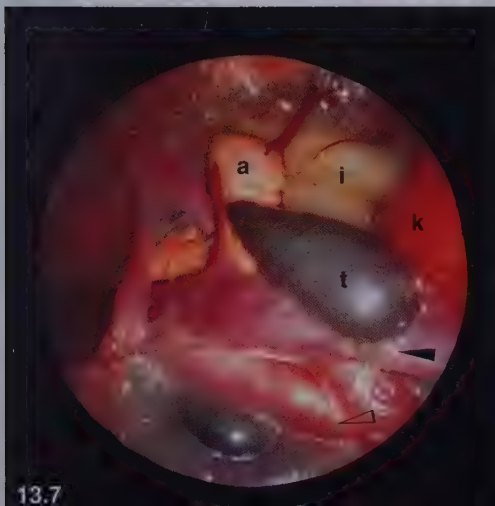
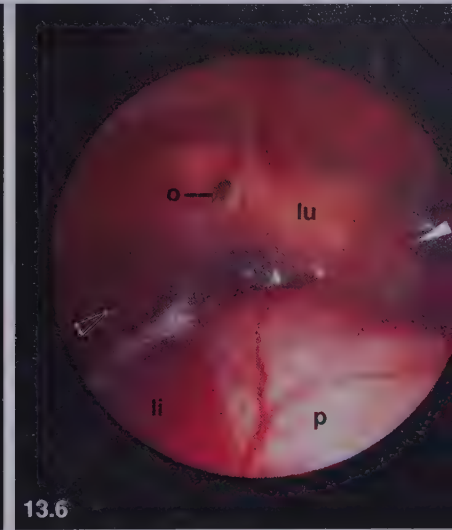
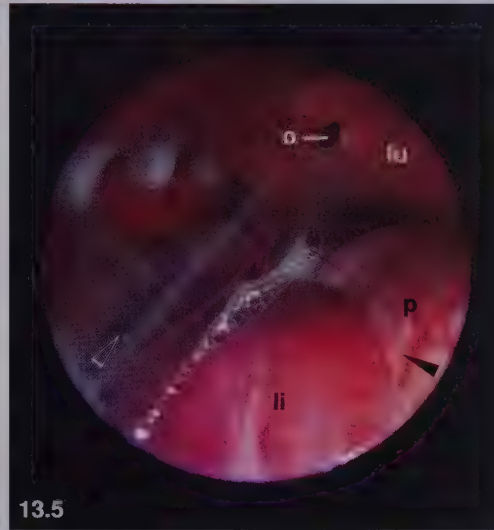
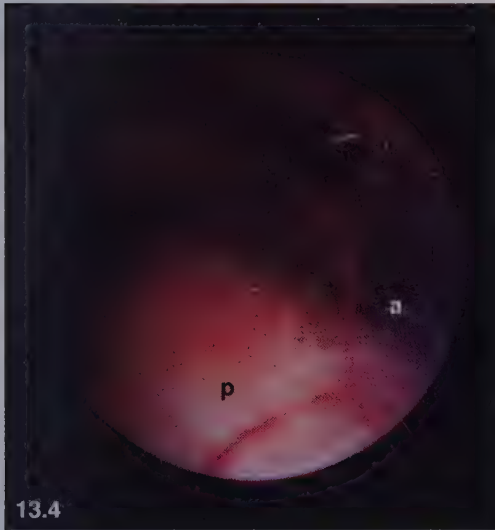
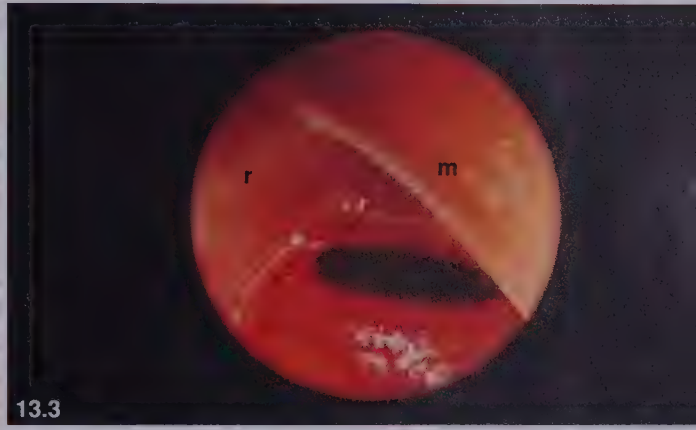
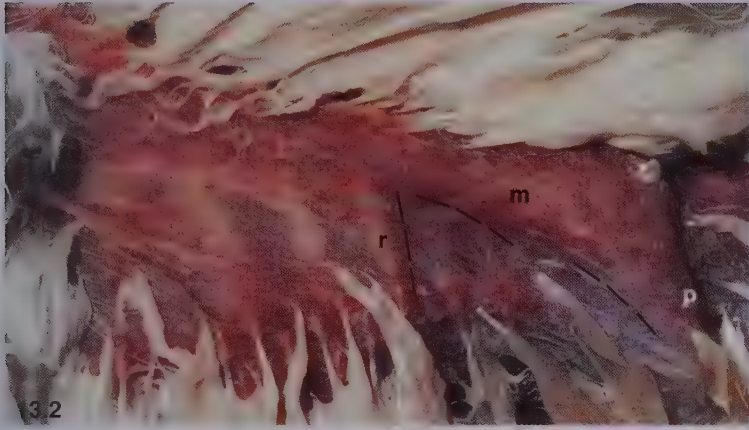
### Color 13.8

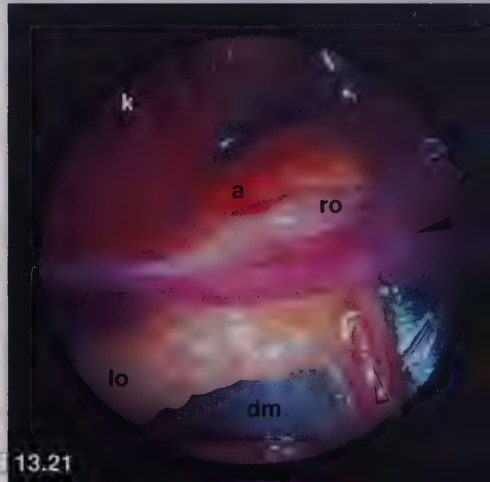
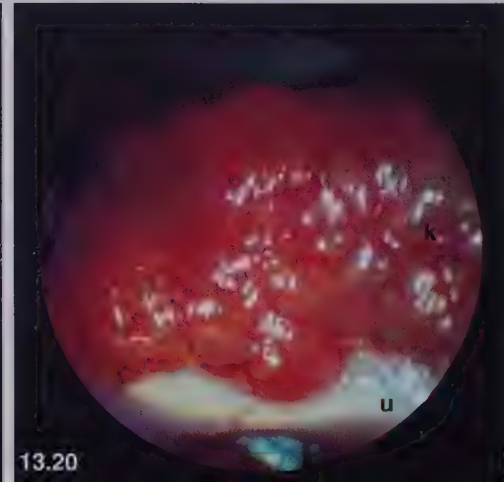
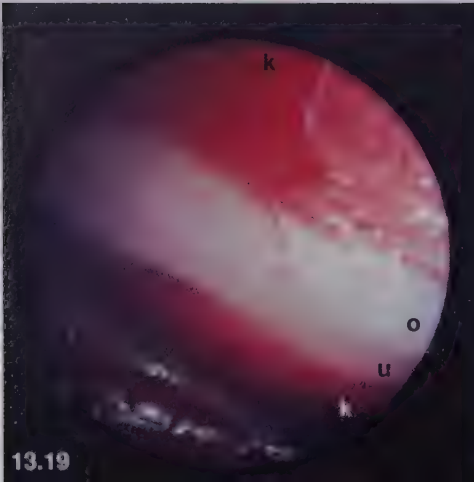
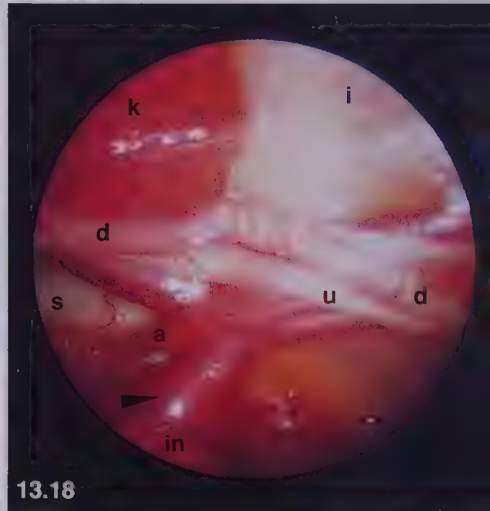
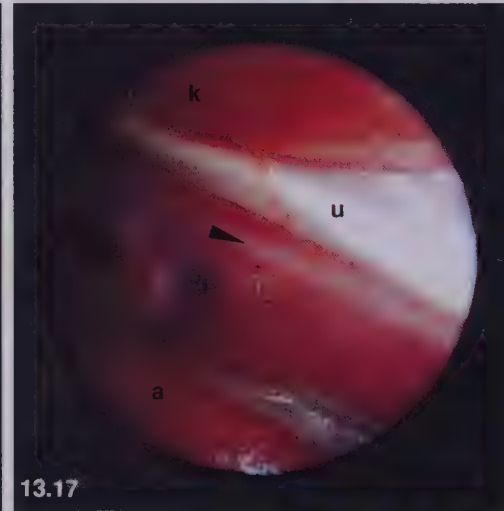
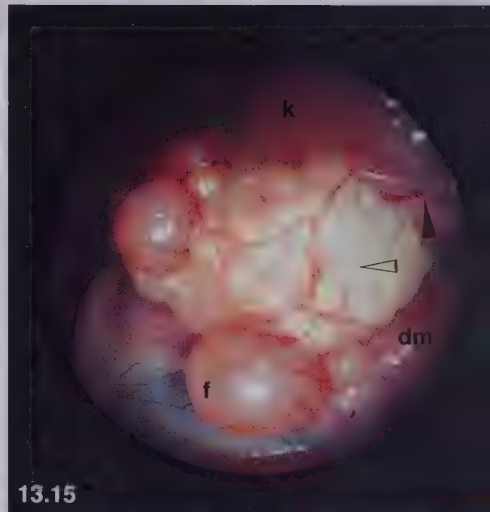
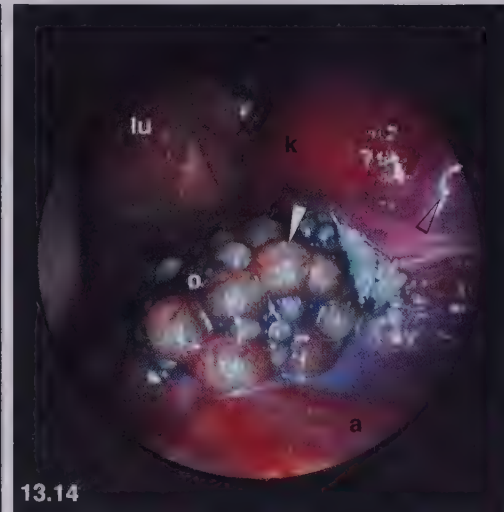
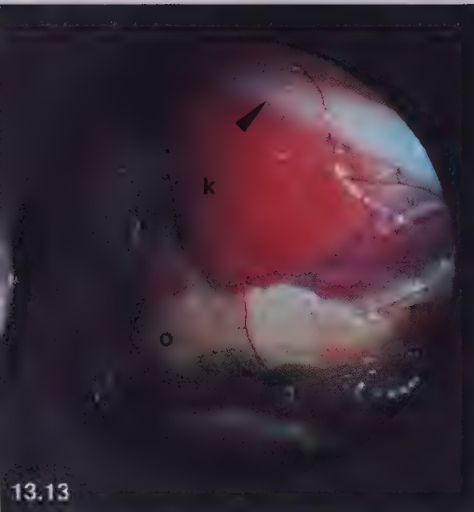
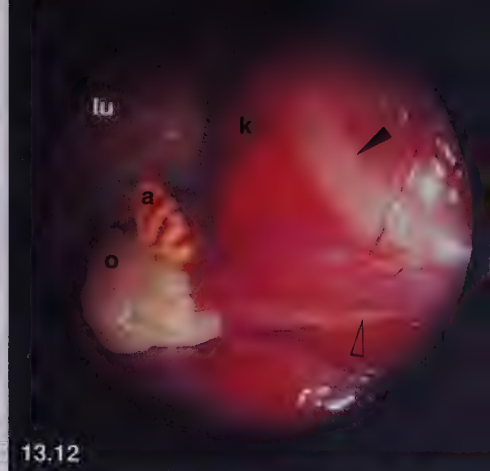
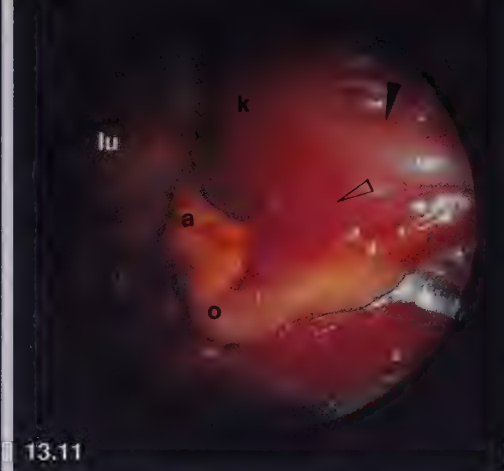
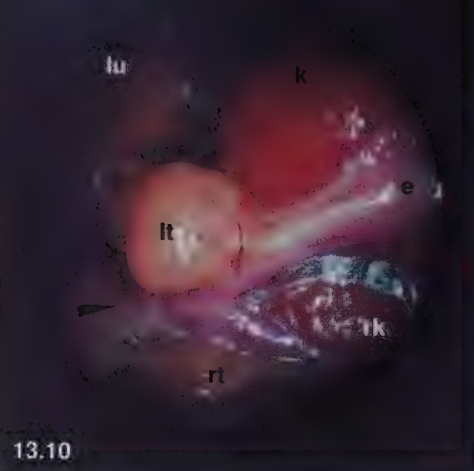
(Position B-4 see Figure 13.4) Normal immature testicle (t) of a Quaker Parakeet. Also visible are the left adrenal gland (a), right and left common iliac veins (arrows) and the caudal vena cava (open arrow).

### Color 13.9

(Position B-4 see Figure 13.4) Endoscopic view of the kidney (k) and immature melanistic ovary (o) of a six-month-old Blue and Gold Macaw. Note the sulci and gyri. Vessels are seen through the abdominal air sac in the peritoneal membrane overlying the gonads (arrows).







## Endoscopic Examination and Biopsy Techniques

### Color 13.10

(Position B-4 see Figure 13.4) Unpigmented, mature testicle (lt) in an Amazon parrot. Also noted are the lung (lu), cranial pole of the left kidney (k), epididymis (e), right testicle (rt), caudal vena cava (arrow) and right kidney (rk).

### Color 13.11

(Position B-4 see Figure 13.4) Normal immature ovary (o) in a 14-week-old Amazon parrot. Also visible are the left adrenal gland (a), cranial pole of the left kidney (k), lung (lu), dorsal ligament of the oviduct (arrow) and common iliac vein (open arrow).

### Color 13.12

(Position B-4 see Figure 13.4) Developing ovary (o), cranial pole of the left kidney (k), lung (lu), adrenal gland (a), dorsal ligament of the oviduct (arrow) and oviduct (open arrow). The vessels coursing across the oviduct, kidney and ovary are present in the abdominal air sac.

### Color 13.13

(Position B-5 see Figure 13.4) Normal ovary in a 14-week-old Blue and Gold Macaw. The nondescript, fatty-appearing ovary (o) is difficult to identify, but the dorsal ligament of the oviduct (arrow) coursing across the kidney (k) confirms that this is a female. The vessels coursing across the kidney and ovary are in the peritoneal membrane and are seen through the abdominal air sac.

### Color 13.14

(Position B-4 see Figure 13.4) Normal ovary of a mature cockatoo. The ovary (o) is melanistic and the developing follicles are translucent (arrow). The cranial pole of the left kidney (k), lung (lu), left common iliac vein (open arrow) and aorta (a) are also visible.

### Color 13.15

(Position B-4 see Figure 13.4) Mature ovary of an Amazon parrot. Note the developing follicles (f) and the characteristic yellowish ("cooked egg") appearance of the involuted ovary, indicating previous ovulation sites (open arrow). The cranial pole of the left

kidney (k) and dorsal mesentery (dm) overlying the right kidney are also noted. The cranial oviductal artery (arrow) is easily visualized. The vessels seen crossing the ovary are those that are present in the peritoneal membrane and are visible through the abdominal air sac.

### Color 13.16

(Position C-6 see Figure 13.4) Normal epididymis (e) of an Indian Hill Mynah. Also visible are the kidney (k), caudal pole of the testicle (t) and a loop of intestines (i).

### Color 13.17

(Position C-7 see Figure 13.4) Ductus deferens (arrow) of an immature macaw. Note that the ductus deferens is smaller than the ureter (u). The kidney (k) and aorta (a) are also visible.

### Color 13.18

(Position C-8 see Figure 13.4) Ductus deferens (d) of a mature Amazon parrot. Also visible are the ureter (u), kidney (k), renal portal vein (arrow), synsacrum (s), ischium (i), aorta (a) and a loop of intestines (in).

### Color 13.19

(Position C-7 see Figure 13.4) Oviduct (o) in a juvenile macaw. The ureter (u), kidney (k), and vessels in the abdominal air sac are also visible.

### Color 13.20

Endoscopic appearance of chronic nephrosis and tubular dilation in a toucan. The abnormal kidney (k) and ureter (u) are clearly visible.

### Color 13.21

(Insertion point 5 see Figure 13.2) A right abdominal (as opposed to the normal left abdominal) approach has been used to demonstrate the regression of the right ovary (ro) as the left ovary (lo) matures in an Orange-winged Amazon Parrot. Also visible are the cranial pole of the right kidney (k), the right adrenal gland (a), the caudal vena cava (arrow), the cranial mesenteric artery (open arrow) and the dorsal mesentery (dm).

## Equipment

### Rigid Endoscope

- **Diameter Size:** Fine-diameter, rod-lens endoscopes are the most suitable for avian work because of their small size, excellent optical resolution and superior light transmission capabilities. For diagnostic purposes, a 1.9 mm is the smallest diameter endoscope available with high quality optics. This endoscope is excellent for patients weighing less than 100 grams or in small anatomic sites (eg, sinus, trachea, oviduct). The major disadvantages of these very small endoscopes are their fragility, relatively small field of view and transmission of less light, which limit usefulness in larger body cavities. Because the 2.7 mm endoscope provides good light transmission capabilities with an adequate image size at a diameter that may be used in a wide range of birds, it is a good choice as the sole or principal endoscope in an avian practice<sup>a</sup> (Table 13.1).

The 2.7 mm endoscope has been used in patients weighing from 55 grams to 4.0 kilograms. Intermediate-sized telescopes (eg, 2.2 mm) are available and may be preferred by some clinicians. Endoscopes (4.0 or 5.0 mm) can be employed in larger patients or when documentation demands. The advantages of the larger optics are greater light transmission and a bigger image circle. Most modern 4.0 or 5.0 mm endoscopes also incorporate new distal lens designs that provide a wider field of view; these are currently unavailable in telescopes less than 4.0 mm diameter. The author has used a 4.0 mm endoscope with wide-angle optics in birds as diverse as Golden Eagles, Crowned Cranes and Marabou Storks.

- **Length:** For general avian endoscopy, a length of the endoscope in the range of 170 to 190 mm is recommended. Shorter working lengths may give a more comfortable feel in use but often lack the reach desired for use in the trachea, esophagus or larger body cavities. An excessively long scope is more prone to bending or breaking.
- **Angle of View:** The final consideration when selecting an endoscope for avian diagnostics is the angle of view of the distal lens element. A 0° lens offset affords straight ahead viewing with a natural orientation. A 30° offset angles the field of view obliquely in the direction of the offset (Figure 13.5). This allows for improved viewing in confined areas, especially when the telescope is rotated. The bevelled distal lens element necessary to achieve this viewing angle enables easier and less traumatic passage through air sac and

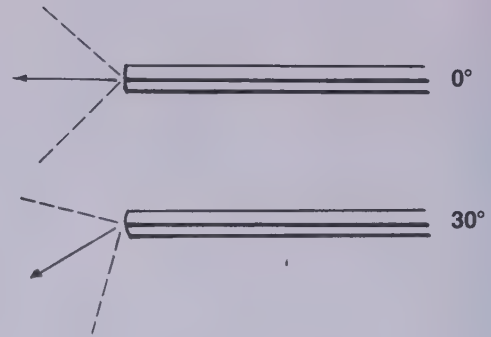


FIG 13.5 Endoscope lens with a 30° offset allows for improved vision in confined spaces.

peritoneal walls. For these reasons endoscopes with a 30° offset are recommended for general diagnostic purposes. Specialized telescopes (eg, 70°, 90°, 130° angles) are not useful for general avian applications.

In the late 1970's, a laparoscopic technique was devised using a veterinary otoscope as the optical device.<sup>12</sup> Although this instrument had the advantage of relatively low cost, it soon became clear that it could not be compared to a rod-lens endoscope in either optical quality or size of the incision necessary

TABLE 13.1 Instrumentation for Avian Endoscopy

#### A. Diagnostic Examination

- 2.7 mm 30° view endoscope
- Glass fiber light cable
- Diagnostic light source (150 W)

#### B. Minimum Diagnostic Working Set for Examination and Biopsy

- Elements listed in "A" as well as:
- Diagnostic sheath for 2.7 mm endoscope incorporating a single 5 Fr instrument channel
- 5 Fr double spoon flexible biopsy forceps (oval jaws)
- 5 Fr flexible grasping forceps

#### C. Expanded Capabilities

- Elements listed in "A" and "B" as well as:
- Diagnostic sheath incorporating a single 7 Fr instrument channel (for larger birds)
- 7 Fr double spoon flexible biopsy forceps (oval jaws)
- 5 Fr double spoon flexible biopsy forceps (round jaws)
- 3 Fr flexible grasping forceps
- 150 W Xenon high intensity light source
- Endovideo camera

#### D. Other Optics

- 1.9 mm endoscope, many different lengths are available
- 2.2 mm endoscope
- 4.0 mm endoscope, 0° to 30° viewing, excellent for photo-documentation or use in larger birds

to perform laparoscopy. In the 1980's a tubular endoscope that attached to a handle-mount battery pack was introduced to the veterinary market as a less-expensive alternative to rod-lens endoscopes.<sup>b</sup> While this device had the advantages of lower cost, a focusing ocular and a length similar to a rod-lens endoscope, it had the disadvantages of poorer resolution, reduced light transmission and a limited field of view. The cost of a rod-lens endoscope system may be up to five times greater than less expensive instruments; however, the high optical quality, light transmission and field of view provide better long-term value when considered over the life of the endoscope. Before purchasing any endoscopic system the veterinarian is well advised to become familiar with the optical qualities of all systems under consideration. An endoscope must allow the clinician to examine tissues with accuracy and to recognize pathology or it is of no value. High quality optical systems are required to enable the clinician to achieve reliable, reproducible results. With appropriate care, modern rigid endoscopes should have a working life of five to ten years.

Veterinarians who see so few cases that they cannot justify the purchase of the appropriate equipment should refer endoscopy services to more experienced practitioners. Over the past decade, rod-lens endoscopes have become the standard for use in avian endoscopy.<sup>2,8,21,23,27</sup> The interests of clients and patients are best served by the use of quality optical equipment.

### Flexible Endoscopes

Conventional flexible endoscopes are based entirely on fiberoptic systems for both illumination and imaging. Unlike modern rigid endoscopes, which employ solid rod-lenses, flexible endoscopes use many coherent, flexible, glass fiber bundles to transmit the image.<sup>10</sup> Rigid telescopes, particularly those with a small diameter, offer far better image resolution, illumination and quality than is technically possible to achieve with a flexible system. However, flexible endoscopes do provide a controllable distal tip, which allows manipulation that is not possible with a rigid rod-lens endoscope. They are most useful in examining tubular organs that are sinuous or folded. A 10 mm flexible colonoscope was found to be effective in removing lead shot from the proventriculus of Trumpeter Swans.<sup>3</sup> Fine-diameter, flexible endoscopes may have limited usefulness in smaller birds (eg, less than 800 g body weight) when compared to newer rigid systems.


The major disadvantage of a small-sized, flexible endoscope is that one cannot control the tip direction unless the instrument is located in a confined area such as the gastrointestinal tract. In an open area (such as the air sac), the scope cannot be manipulated or used to penetrate beyond the air sac walls without a probe. A specialty avian practice may have a small diameter flexible endoscope available to perform indicated procedures. Large flexible scopes with an operating channel for placement of grasping and biopsy instrumentation can be used in ratites.

### Instrument Care

Flexible and rigid endoscopes are expensive, precision, optical instruments that will give excellent long-term performance if properly maintained. Rigid telescopes, especially those of small diameter, are fragile and must be carefully handled during transport and cleaning to avoid damage to the rod-lens elements. Torsional stresses upon the long axis of the endoscope must be avoided. This is most important when a fine-diameter telescope is being used without a protective sheath, as is frequently the case for diagnostic purposes. It is particularly important that the operator be sensitive to the amount of force being applied to the telescope during a procedure. Rigid endoscopes should always be picked up by the ocular (eyepiece) rather than the distal tip. One should lay the instrument flat to avoid bending the optical tip and fracturing the optic bundles. It is wise to clean the instrument immediately after a procedure is finished. A nonabrasive cleanser may be used to remove fat and debris. In many cases, simply washing the telescope in distilled water is all that is needed. A quality lens paper is used to clean the lens surfaces. An alcohol flush chemically dries the endoscope before it is placed in a padded storage container that

### CLINICAL APPLICATIONS

- Rigid endoscopes should always be picked up by the ocular (eyepiece) rather than the distal tip.
- For office or field sterilization, sensitive endoscopic equipment may be soaked in a two percent solution of glutaraldehyde (of a type approved by the manufacturer of the equipment).
- Moderate to marked obesity leading to the intra-abdominal deposition of fat is the most frequent cause of difficulty in endoscopic visualization.
- Familiarity with anatomy, use of gentle tissue handling techniques and careful movements of the endoscope will reduce the risk of iatrogenic trauma.



**FIG 13.6** A sleeve should be placed over the endoscope for protection during movement or sterilization.

meets the manufacturer's recommendations. A simple but effective plastic endoscope sleeve is available to cover the shaft of the telescope for protection during transport and disinfection procedures (Figure 13.6).

Flexible endoscopes should also be handled with care. They should not be coiled tightly or have objects of any weight placed on the shaft, or the glass fiber bundles will be damaged. Instrument channels should be flushed thoroughly with warm soapy water to remove debris after use. Most manufacturers recommend that flexible endoscopes be stored suspended from the ocular end with the flexible shaft allowed to hang vertically. Detailed instructions for endoscope care are provided by most manufacturers. Technical staff should be properly trained in the handling and cleaning of these sensitive instruments before receiving the responsibility for their care.

### **Sterilization**

Most endoscopic procedures require properly sterilized equipment. Even in the examination of noncritical areas such as the oral cavity or ear canal, it is prudent to remember that many animals (particularly carnivores) may harbor pathogenic organisms that can be physically transferred to another patient (particularly birds) if instrumentation is not disinfected between examinations. Due to the sensitivity of the rod-lens systems, sterilization by autoclaving is seldom recommended by the manufacturer. Expansion and contraction caused by the marked temperature extremes of steam autoclaving will damage or severely shorten the life of most telescopes. Some types of recently produced rigid endoscopes are steam autoclavable, although this process may also decrease their working life.

Two options provide safe yet consistently reliable sterilization for sensitive telescopes and light cables. Ethylene oxide gas is an extremely effective sterilant, but exposed materials must be aerated for a minimum of eight to twelve hours before use. Ethylene oxide is a human health hazard and must be used under carefully controlled conditions.

The most practical and safe alternative for the avian practitioner for office or field sterilization of sensitive endoscopic equipment is soaking in a two percent solution of glutaraldehyde (of a type approved by the manufacturer of your equipment).<sup>c</sup> The solution must be used according to the supplier's directions for soaking telescopes, hand instruments and light cables. The practitioner should be aware of the activated life of the product (usually 14 to 28 days) and change solutions accordingly. Stacking or layering instruments in the soak tray should be avoided so that the solution can properly reach all surfaces. Circulating the solution using a syringe is useful to ensure that all surfaces have been contacted. Minimum recommended soaking times in properly prepared glutaraldehyde solutions typically range from 15 to 20 minutes. Although greater germicidal effect is achieved the longer the equipment is soaked, many manufacturers caution against soaking for longer than two hours, as damage to glass fibers may occur.

After the soaking cycle has been completed, the equipment must be thoroughly rinsed in sterile water to prevent tissue-damaging glutaraldehyde from contacting the patient. Glutaraldehyde is extremely irritating to most tissues and may cause local irritation, tissue death, delayed healing and peritoneal reaction. Rinsing the equipment in a sterile container of sterile water for three to five minutes is most effective. The instruments are drained, immersed in a second container of sterile water for three to five minutes and wiped dry. A final alcohol wash may be used to chemically dry the equipment.

Other types of disinfectant solutions such as quaternary ammonium compounds, chlorhexidine and povidone iodine are not acceptable alternatives to two per cent glutaraldehyde solutions for soaking endoscopic equipment. With the number of resistant viruses and bacteria seen in many avian species, it is important for the endoscopist to ensure that only effective, approved products are used, or the result may be the unnecessary spread of disease.

## Clinical Applications of Endoscopy

### Pre-endoscopy Considerations

#### Indications

Endoscopic examination is indicated whenever the visual inspection of an organ or site may yield additional diagnostic information. Diagnostic endoscopy is usually preceded by less-invasive examinations such as a complete blood count, biochemistries or radiology. The patient's history, findings of the physical examination and the results of laboratory and radiologic studies may not be conclusive or may suggest endoscopic followup for additional diagnostic information (Table 13.2).

**TABLE 13.2 Common Indications for Endoscopic Examination**

- Loss or change in character of voice
- Acute or chronic dyspnea
- Acute or chronic sneezing
- Ingluvitis, crop burns or trauma
- Abnormal radiographic findings (plain or contrast); eg, lung, gastrointestinal tract, air sacs, organomegaly, granuloma
- Abnormal biochemical studies; eg, kidney (uricemia) or liver (elevated bile acids or liver enzyme activities)
- Persistent leukocytosis (nonresponsive to treatment)
- Acute or chronic systemic disease
- Reproductive system (suspected infertility)
- Polyuria, polydipsia
- Follow-up examination to check on lesion resolution ("second look")

▪ **Diagnostic Uses:** The endoscope and its light cable may be used to aid the physical examination.<sup>8</sup> The light cable may be used singly to offer additional illumination, to transilluminate a structure such as the trachea, sinus or crop, to augment examination of the oral cavity or for back lighting of overexposed radiographs. Fine-diameter endoscopes can be used in a variety of external sites where the properties of magnification, illumination and small optic diameter enhance diagnostic visualization. Many structures of the eye, ear canal, nares, oral cavity and upper respiratory tract may be examined without anesthesia. More thorough, noninvasive examinations of other body orifices are best completed under general anesthesia. The high quality optics of modern endoscopes allow visualization and inspection of tissues under magnification and are particularly useful in confined


areas. Fine-diameter endoscopes introduced through a small incision, often referred to as laparoscopy,<sup>2</sup> permit excellent visualization of the coelomic cavities and air sacs, while creating minimal trauma.

Endoscopy has been compared to performing a necropsy on a live bird.<sup>21</sup> The endoscopist must become familiar with the normal and pathologic appearance of the tissues to be examined. Lesions should be described accurately regarding the location, color, size, shape and consistency. Photo or video documentation can be a tremendous aid in this process. In one study, the ability to review video recordings of examinations was believed to be an essential tool in understanding certain anatomic relationships in juvenile macaws.<sup>29</sup>

Improved instrumentation enhances the routine collection of specimens of suspect or abnormal-appearing tissue and debris for histologic, cytologic and microbiologic examination. Previous techniques for biopsy and specimen collection have relied on the manipulation of secondary instrumentation (eg, rigid biopsy forceps or cannulas for micro-swabs) separate from but in coordination with the endoscope. These techniques are awkward and can lead to iatrogenic trauma.<sup>18,19,20</sup> A new diagnostic endoscopy system for birds has recently been developed that greatly simplifies sample collection.<sup>11,31</sup> The system incorporates a 2.7 mm, 30° view endoscope with a single instrument port in a special sheath (Figure 13.7). Various flexible instruments may be introduced into the sheath, passed alongside the endoscope and guided to a specific site with great ease (Figure 13.8). Iatrogenic tissue trauma is markedly reduced because the instruments are directed to the visual field through the integral sheath, avoiding the blind manipulation required to place a second, rigid instrument.

▪ **Surgery:** Harrison<sup>8</sup> first suggested the use of the endoscope as an operating telescope in open avian surgery to enhance visualization of small structures.

Endoscopic surgery is currently one of the fastest growing areas in the human surgical specialties. Special hand instruments have been developed to enable tissue manipulation, suture and clip placement and radiosurgical techniques using the endoscope. The advantage of this type of surgery in humans has decreased patient trauma and hospitalization. The technology offers great promise if it can be adapted for avian surgery. In addition to decreased trauma, the magnification and illumination provided by a quality endoscopic system enable more precise techniques in small avian patients. Surgical procedures



**FIG 13.7** A specialized 2.7 mm endoscope that fits into a sleeve is ideal for most avian endoscopic procedures. The sleeve has been designed to accommodate the introduction of biopsy forceps and other flexible instruments to facilitate the collection of diagnostic samples (courtesy of Karl Storz Veterinary Endoscopy–America).

are under development for endoscope-guided hysterectomy, ulcer repair and egg removal.

#### ▪ **Identification of Gender of Monomorphic Birds:**

The use of endoscopy to identify the gender of monomorphic birds was the earliest widespread application of this technology in avian medicine; it has been the major force supporting the development and introduction of improved diagnostic capabilities utilizing endoscopy.

#### **Contraindications**

The general contraindications for endoscopy are those that would apply to general avian surgery and anesthesia. Moderate-to-marked obesity leading to the intra-abdominal deposition of fat is the most frequent cause of difficulty in endoscopic visualization. Large peritoneal fat reserves may make the examination of parts of the coelom impossible. In some cases, an improved diet is recommended for the patient (with reexamination in six to eight weeks).


The presence of ascites may cause difficulties if the peritoneum of the ventral hepatic peritoneal cavity (VHPC) or intestinal peritoneal cavity (IPC) is breached while entering the air sac. Fluid could drain from the peritoneal cavity into the air sac and from there into the lung, leading to aspiration and death. This is most likely to happen in a lateral approach to the caudal thoracic air sac. If ascites is suspected and an endoscopic examination of the liver is necessary, the ventral approach to the VHPC should be used.

Fluid from the VHPC will drain from the incision site and can be safely suctioned without the concern for air sac involvement.

Left coelomic examinations should not be performed in the hen near the time of ovulation, as the ova greatly enlarges in size, virtually obliterating the abdominal air sac. The oviduct also increases in size and tortuosity, filling the left portion of the IPC. Use of the post-pubic approach to the abdominal air sac risks damage to the oviduct or an egg nearing oviposition. A left lateral coelomic approach is rendered less useful by the presence of large, developing ova that makes visualization difficult. Attempting passage into the abdominal air sac from the caudal thoracic air sac may be difficult and potentially

risks damage to the ova.

Inexperience of the operator remains one of the most common causes of endoscopic complications.<sup>8,21</sup> Veterinarians considering the addition of endoscopic services to their avian practice are well advised to seek out appropriate continuing education and to become thoroughly familiar with normal avian anatomy. Experienced colleagues may be contacted for advice on practical equipment needs before purchasing new equipment. Necropsy specimens can be used to study endoscopic principles and are particularly useful in learning to identify tissue changes. Lectures and laboratories are available on endoscopic techniques.



**FIG 13.8** Biopsy forceps passing through a specially designed sheath for a 2.7 mm endoscope (courtesy of Karl Storz Veterinary Endoscopy–America).



### Complications

As part of the informed consent process, the client must be made aware of potential complications of the endoscopic process. Anesthesia-related incidents are described in Chapter 39. Organ trauma is one of the most serious intraoperative endoscopic complications. The proventriculus may be punctured using a trocar and cannula or similar entry device from a lateral approach. Failure to identify and repair this injury can result in a fatal peritonitis. Laceration of a blood vessel or organ such as the liver or spleen is possible and may lead to serious or fatal hemorrhage. Liver or kidney contusions can be caused by the endoscope tip during excessively vigorous manipulation. These are infrequently the cause of serious clinical problems.

Familiarity with anatomy, use of gentle tissue handling techniques and careful movements of the endoscope will reduce the risk of iatrogenic trauma.

Subcutaneous emphysema is a potential (if rare) postoperative complication. Air may leak through the body wall at the point of the air sac entry and collect under the skin. Usually, the body wall opening will seal without incident, but occasionally the skin incision must be reopened and the body wall puncture sutured. This is most common when a large endoscope or sheath has been used. Endoscopic punctures may be routinely closed with a fine-diameter, absorbable, monofilament suture.

Air sac and peritoneal granulomas can occur by using instrumentation that has been improperly sterilized or in situations where poor technique or inadequate skin preparation has allowed contamination of the endoscope tip. The peritoneum of most birds seems to be quite forgiving of small insults. Many granulomas may not be appreciated clinically. The author and editors have never experienced a case of generalized sepsis related to endoscopic manipulation, although this may be possible in cases where the wall of an existing granuloma is damaged or where ineffective sterilization practices have been used. Cold disinfectant solutions such as chlorhexidine<sup>2</sup> are not appropriate, as some organisms such as *Pseudomonas aeruginosa* will survive this treatment. No comprehensive studies have examined the endoscopy and biopsy sites days to weeks following the procedure. However, preliminary work indicates that there was no local infection in patients where a two percent glutaraldehyde solution was used for instrument preparation and appropriate sterile technique was employed. The inability to perform proper steriliza-

tion of a single endoscope makes surgical sexing clinics obsolete. Transmission of viral infections (particularly Pacheco's disease virus and polyomavirus), resulting in the loss of numerous birds has been linked to "sexing clinics." The mixing of birds from multiple sources (particularly when an invasive procedure is performed) should be discouraged. It is possible, however, to safely perform endoscopy on several birds from a single client by utilizing two endoscopes, with one being sterilized while the other is in use.

### Patient Preparation

Patients should be fasted a minimum of three hours. In some cases the length of the fast is extended, especially if the endoscopic examination will involve the gastrointestinal tract. Species that consume large boluses of whole foods (eg, raptors) may require fasting for 24 to 36 hours. Failure to do this may make examination of many portions of the coelom impossible due to distension of the proventriculus.

Surgical sites are prepared as for any avian surgery. Particular attention should be paid to the skin surface. The endoscope can transmit surface debris into the body cavity if the entry site is not properly prepared. Small, sterile, transparent, wound dressings<sup>d</sup> make excellent drapes for endoscopic procedures. They are available in a variety of sizes and are lightly adhesive so they stay in place without clamps; their transparency improves anesthetic monitoring in small patients.

- **Anesthesia:** Appropriate anesthesia is an essential part of good endoscopic practice. It is seldom possible to perform an endoscopic examination in the physically restrained bird without the risk of organ contusion or other trauma. Consistency in positioning of the patient is mandatory for anatomic orientation. Maintaining position is neither possible nor humane using physical restraint only. Clinical anesthesia has been thoroughly reviewed in Chapter 39. The anesthetic agent of choice for most endoscopic procedures remains isoflurane.<sup>e</sup>

### Sites of Application

#### Air Sacs, Lungs

Birds are excellent subjects for endoscopic examination because the unique system of air sacs allows visualization of coelomic structures without artificial insufflation. Air sacs invaginate the thoracoabdomen of birds to facilitate examination of or access to specific organs. There are marked similarities in the

morphology of caudal air sacs among selected Passeriformes, Psittaciformes, Columbiformes, Gruiformes, Strigiformes and Falconiformes. In chickens, there are three paired air sacs (cranial thoracic, caudal thoracic, abdominal) and two single, median air sacs (cervical, clavicular).<sup>17</sup>

There is one published examination of air sac morphology in a psittacine bird (budgerigar).<sup>4</sup> The budgerigar has paired, unfused cervical air sacs but was otherwise similar to the chicken. The caudal thoracic air sacs of the pigeon extend farther caudally than in most Psittaciformes. In some diving birds, the caudal thoracic air sacs are much larger than in other species. This is assumed to be an adaptation to increased air requirements while diving underwater.

For endoscopic purposes, it is preferable to consider the cranial and caudal thoracic and the abdominal air sac pairs together. In the parrot, the cranial thoracic air sacs are the smallest of the group and are located ventral and cranial to the caudal thoracic air sacs (Color 13.1). They are best accessed from the ventrolateral thoracic wall using the approach first described by Bush,<sup>2</sup> who suggested an entry site caudal to the last sternal rib in the area of the lateral notch (a "V"-shaped depression palpable between the sternum and the last rib).

The patient is placed in lateral recumbency with the wings extended dorsally. The wings may be taped to a restraint surface or they may be affixed with a short loop of non-adhesive, self-adhering tape<sup>f</sup> passed between the primary feathers and around the carpus. The landmarks are located and a small skin incision is made. The musculature of the body wall is bluntly separated and the endoscope is inserted in a craniodorsal direction. From this approach the pericardial sac and heart can be seen as well as the lobe of the liver and the caudal, ventromedial surface of the lung (Color 13.23).

The traditional left lateral surgical approach takes advantage of the air sac anatomy to approach the gonads by either directly entering the abdominal air sac or by entering the caudal thoracic air sac first and then passing into the abdominal air sac through a small incision (see Figure 13.2). This approach is similar to the early laparotomy techniques of field ornithologists.<sup>1,26</sup>

The patient is placed in true lateral recumbency with the wings extended dorsally. The upper leg is extended and held caudally. The point of insertion is located by palpating the triangle cranial to the mus-

cle mass of the femur, ventral to the synsacrum and caudal to the last rib.<sup>8,19,23</sup> The body wall may be penetrated by a trocar and cannula or by blunt separation. In Psittaciformes, this entry site has been demonstrated to occur between the seventh and eighth ribs (not the behind the last rib). With this approach, the tip of the endoscope enters the mid to caudal portion of the caudal thoracic air sac in most birds.

As an alternative approach to the caudal thoracic air sac, the bird is restrained in lateral recumbency except that the leg is extended cranially.<sup>15</sup> The site of entry is the same as previously described in the upper part of the triangle formed by the proximal femur, the last rib and the cranial edge of the pubis.

A similar approach to the caudal thoracic air sacs that is based upon precise landmarks has been developed (see Figure 13.3).<sup>29,30,31</sup> The animal is positioned as described. The entry site is located by finding the point where the semimembranosus muscle (*M. flexor cruris medialis*) crosses the last rib (Color 13.2). The ventral fascia of the semimembranosus muscle is bluntly separated from the underlying body wall and the muscle is reflected dorsally. A blunt entry is made just caudal to the last rib, beneath the reflected semimembranosus muscle. Except in individuals with moderately to markedly increased fat reserves, the landmarks are located easily. The procedure is reproducible in members from a wide variety of orders including Psittaciformes, Passeriformes, Columbiformes, Gruiformes, Falconiformes and Strigiformes. A major advantage in placing the leg forward is that the lateral body wall can be more easily approached without the interference of the femoral musculature. This becomes particularly important in birds with heavily muscled upper thighs (eg, many Psittaciformes).

With either of these approaches the endoscope enters the caudal thoracic air sac at or near its caudal border. Color 13.4 was photographed from the left entry point of this caudal approach looking cranially. Visible from eleven to one o'clock is the caudal surface of the lung with its large ostium. From the two to three o'clock position is the transparent membrane formed by the confluent walls of the caudal thoracic air sac and the abdominal air sac. Passing through this wall would place the endoscope within the abdominal air sac. At four to six o'clock is the ventrolateral border of the proventriculus. The lateral edge of the left lobe of the liver may be seen at the seven to eight o'clock position. From nine to ten o'clock is

another transparent membrane. This one is composed of the walls of the confluent caudal thoracic air sac and cranial thoracic air sacs. Passing through this membrane would place the tip of the endoscope in the cranial thoracic air sac.

The abdominal air sacs of most birds are the largest air sacs. They extend from the caudal surface of the lung to the craniolateral borders of the cloaca. Entry into the abdominal air sacs may be gained through one of the previously described caudal thoracic air sac approaches or by direct access through the caudal body wall. Lumeij<sup>14</sup> was the first to describe a post-pubic approach to the caudal portion of the abdominal air sac. The entry point is situated dorsal to the pubic bone and caudal to the ischium (see Figure 13.2). The endoscope generally first enters the most caudal portion of the intestinal peritoneal cavity and must be penetrated through this thin membrane to enter the abdominal air sac. The endoscope can then be moved cranially up the length of the abdominal air sac. From the left approach a large number of structures may be examined including the kidney, adrenal, gonad and associated structures, spleen, proventriculus, ventriculus and intestine (Color 13.26). The abdominal air sac may also be approached from a flank position. The entry site is located directly ventral to the acetabulum and just dorsal to the ventral border of the flexor cruris medialis muscle.

### Reproductive Organs

In most avian species, only the left ovary and oviduct develop.<sup>14,16</sup> The development of the right ovary is normally arrested in a testis-like stage and can frequently be visualized near the right adrenal gland, along the caudal vena cava (Color 13.8). For this reason, endoscopy to examine gonadal structures is performed through the left side of the abdomen.

The testicle of the adult male bird is ellipsoidal to bean-shaped. In most species it is creamy white although it may be more or less pigmented (gray to black) in others (eg, cockatoos, mynahs, toucans) (Color 13.7). Under the seasonal influence of hormones, the mass of the testicle may increase from 10 up to 500 times.<sup>14</sup> The pattern of surface vessels increases and becomes more prominent. The epididymis enlarges, and the ductus deferens becomes very tortuous in preparation for storage and transportation of the spermatozoa (Color 13.16).

In contrast, the ovary of the mature female has the appearance of tapioca pudding with many small follicles visible during the nonbreeding season. Under

appropriate hormonal stimulation, a hierarchy of follicles develops and matures giving the ovary the appearance of a cluster of grapes (Color 13.15). A follicle enlarges as it matures; simultaneously, the oviduct increases in size and becomes tortuous and folded in preparation to accept the ovum. A large ovum can be mistaken for a testicle, especially in an obese bird where other structures are difficult to see or where the surgeon fails to check related anatomic reference points.

The differences in the morphology of adult gonads are relatively distinct. In juvenile birds, gonadal tissue is less obvious and differentiation is more difficult. It is possible to endoscopically identify the correct gender of most species of birds at a young age if good optical equipment is used and a careful examination of the gonads and associated structures is performed.

In one study of juvenile macaws,<sup>29</sup> differentiation of the sexes was uniformly possible as young as six weeks of age when gonadal and oviductal or ductus deferens morphology were considered together. Testicles were tubular to ellipsoidal with distinct, rounded cranial and caudal poles. A paired right testicle could usually be seen through the dorsal mesentery (Color 13.10). The ductus deferens was a thin, white tubular structure, usually only one-third the diameter of the ureter (Color 13.17).

The juvenile ovary was comma-shaped, dorsoventrally flattened and closely applied to the adrenal and cranial pole of the kidney. The surface texture of the ovary was dependent on the age of the bird. Very young ovaries had a faintly granular surface with fine sulci (Color 13.13). As the birds aged, the sulci deepened, giving the ovary a furrowed, brain-like appearance (Color 13.12). With the maturation of the primary oocytes, the ovary began to take on a distinctly granular texture with a more three-dimensional shape, and the sulci disappeared (Color 13.14). The oviduct was pale white with a thicker, more substantial appearance than the vas deferens. The oviduct was generally two to four times the thickness of the ureter and on close inspection, fine, longitudinal, spiral bands were visible (Color 13.19). These may have represented the developing spiral folds of the mature oviductal mucosa. The most interesting finding of this study was the presence of the supporting ligament of the infundibulum, which was clearly visible crossing the cranial division of the kidney. This structure is part of the dorsal ligament of the oviduct and is absent in juvenile males (Color 13.11).

From this approach, it may be difficult or impossible to view the right side in mature birds. Examination of the right abdominal air sac (AAS) would be required to confirm the presence of abnormalities related to the remnant ovary or the right testicle such as ovotestes or hermaphroditism. While these conditions are uncommon, their presence may need to be ruled out in cases of infertility.

Caution should be exercised in estimating age, reproductive history or reproductive potential based upon a single endoscopic examination. During the non-breeding times of the year, the adult gonads return to a quiescent state similar to those of the late adolescent bird. Several male Hyacinth Macaws in their teens had very small testicles, yet went on to breed within months of evaluation. A mature African Grey Parrot showed no evidence of follicular development at examination but ovulated 24 days later.

During the endoscopic examination for gender determination, the endoscopist is able to evaluate the air sacs, liver, lung, spleen, kidney, adrenal gland, proventriculus, ventriculus and the visual portions of the intestines. A systematic examination that may suggest a subclinical health problem can provide data of value to the aviculturist. This information is not available using cytogenetic or molecular biological techniques of gender determination.

### Ear Canal

The external auditory meatus is hidden by specialized covert feathers that lack barbules. There is no pinna. The opening is usually rounded but can vary in diameter from small (2.0 to 15.0 mm in passerine and psittacine birds) to very large (up to 6.0 cm in owls). The ear canal is straight and short. The tympanum can usually be visualized clearly (Color 13.41). A 1.9 mm telescope is often needed to explore the deeper aspects of the canal. Unlike the dog and cat, birds infrequently suffer from otitis externa.

### Oropharynx

The oral cavity is easily approached in most avian species. The bill may be held open manually or with a speculum. In species with strong mandibular musculature (such as Psittaciformes) it is recommended that the patient be anesthetized for most oral examinations. If manual restraint is used, extra care must be taken to prevent damage to the equipment.

The avian tongue may exhibit a number of adaptations for food prehension and manipulation. In many species it is a flat, triangular-shaped organ with a

relatively smooth epithelium. Psittaciformes have large, fleshy tongues ideally suited to food manipulation. They are the only order with intrinsic lingual muscles<sup>17</sup> that allow a great variety of movement and flexibility. In many species, including parrots (Color 13.34), there are a group of mucus-secreting salivary glands at the base of the tongue. Inspissation of keratinized debris due to squamous metaplasia will be seen in birds suffering from hypovitaminosis A (Color 13.33).

Salivary glands are most prominent in species that eat primarily a dry diet (cereal grains) and may be absent in those that eat a moist, lubricated diet (fish). In the parrot, salivary glands are found along the roof and the floor of the mouth and on the tongue. The oropharynx is lined with stratified squamous epithelium and may be keratinized in areas of wear. In some species, the epithelium may be heavily pigmented. It normally has a smooth, unblemished surface except in areas where spike-like sensory papillae are present (Color 13.34). The mucosa should be examined for adherent exudate, debris or ulcers, as may be seen in certain protozoal (eg, *Trichomonas* sp.), fungal (eg, *Candida albicans*) or viral (eg, poxvirus) diseases.

The choanal slit is visible as a median "V"-shaped cleft in the palate. There is species variation in the width of the choanal borders. In pigeons and most raptors, the choana is slit-shaped (Color 13.35). In the parrot the borders are more widely spaced, forming a distinctive "V" shape. The borders of the choanal slit are lined with sensory papillae. By entering the choanal slit with the scope and moving craniodorsally, the nasal septum and conchae can be examined (Color 13.37). Just caudal to and on the midline of the choana is the small slit-like infundibular cleft. This is the common opening of the right and left pharyngotympanic tubes<sup>17</sup> also referred to as the eustachian tubes (Color 13.35).

The laryngeal mound is visualized at the base of the tongue on the midline of the caudal floor of the oropharynx. The paired, fleshy laryngeal prominences open and close to form the conspicuous glottis. There is no epiglottis (Color 13.31).

### Trachea

The trachea may be entered at the larynx by passing through the glottis of an anesthetized patient. The avian larynx does not contain vocal cords. Tracheal rings of the bird are usually calcified and are completely circular. The tracheal mucosa consists of

smooth, stratified squamous epithelium. The syrinx is the site of sound production and is located where the trachea bifurcates into the primary bronchi. The syringeal membrane may be the site of opportunistic bacterial and fungal infection (aspergillosis).<sup>25</sup> Tracheoscopy to the level of the syrinx is possible in medium-to-large birds using a 180 mm long, 2.7 mm endoscope. Smaller patients (larger than cockatiels) may be examined with a 1.9 mm endoscope. Visualization can be improved by extending the neck. In patients with acute to subacute dyspnea, tracheoscopy should be considered to rule out foreign objects or inflammatory debris.

In seed-eating birds, hulls or whole seeds may be aspirated into the larynx or syrinx. In carnivorous birds, small pieces of bone, tendon or cartilage may become lodged in the glottis. These may be removed using endoscopically guided grasping forceps. Tracheitis may be caused by bacterial or viral agents. Culture of the endoscope tip immediately after removal from the patient may be helpful in determining an etiologic agent.

### Esophagus and Ingluvies

The esophagus is easily entered by passing the endoscope caudally into the pharynx and over the laryngeal mound. The surface of the esophagus is comprised of longitudinal folds that vary depending upon the dietary habits of the species (see Color 19). For example, the number and size of folds and the degree of distensibility are less in insectivores and seed eaters than in carnivores like hawks and owls (Color 13.38).

It is a common misconception that all birds have an ingluvies. Galliformes, Psittaciformes, Columbiformes and some Passeriformes have a true crop. The ingluvies can be examined with either a flexible or rigid endoscope after passing the instrument through the cervical portion of the esophagus. Insufflating the crop with air will help with visualization. To do this, a small-diameter, flexible feeding tube,<sup>g</sup> which has been attached to a 35 or 60 cc syringe, can be passed into the crop (Color 13.39). Alternately, the insufflation channel on a 4 mm or greater diameter flexible endoscope, or the instrument channel on the Storz rigid avian sheath<sup>a</sup> can be used to distend the ingluvies with air. Some pressure will need to be maintained around the proximal cervical esophagus to retain the infused air within the crop. Patients undergoing elective ingluviology should be fasted for several hours before the procedure to reduce the effects of retained food materials upon visualization.

With this technique the crop mucosa can be thoroughly examined and small foreign objects can be removed with grasping forceps. The grasping forceps can be endoscopically guided using either a flexible endoscope with an instrument channel or the rigid sheath with channel.

### Proventriculus, Ventriculus

The proventriculus and the ventriculus may be examined using either flexible or rigid equipment. In a 250 to 600 g parrot it can be a difficult chore to guide a small-diameter, flexible endoscope down the cervical esophagus, across the crop and into the thoracic esophagus, although this equipment can be used successfully in larger parrots and in moderately large avian species that lack a crop (eg, raptors and Anseriformes). A pediatric bronchoscope is required in smaller patients. The smallest practical flexible endoscopes with an instrument channel are pediatric bronchoscopes at 4.0 mm and 5.0 mm diameter. Human flexible colonoscopes (10.0 mm) have been shown to be useful in very large species such as swans and cranes.<sup>3</sup> Once the endoscope is positioned in the thoracic esophagus, the pathway becomes a relatively straight one continuing into the proventriculus (Color 13.40) and the ventriculus.

Preliminary studies using a midline ingluviotomy to enter the thoracic esophagus using the Storz 2.7 mm rigid endoscope and instrumented sheath have been performed.<sup>a</sup> Birds were anesthetized, intubated and placed in dorsal recumbency.

Care was taken to avoid the passage of proventricular contents into the trachea or choana by inserting an absorptive gauze tampon into the cranial cervical esophagus and ensuring that the endotracheal tube was secure. Whenever possible, patients were fasted for five to six hours in order to empty the proventriculus. In cases where fasting was not possible (eg, acute foreign body ingestion), the proventriculus was flushed with sterile saline and ingesta was forced out of the thoracic esophagus and into the crop, from which it was suctioned. Placing the patient with its head down facilitated this procedure. A small skin incision was made over the middorsal portion of the crop. The crop wall was incised. The entrance to the thoracic esophagus was located on the ventral midline border of the crop, and the telescope and sheath were introduced.

The sheath and endoscope were inserted into the thoracic esophagus. A 3-5 Fr rubber catheter connected to a syringe containing saline was inserted

into the instrument channel for use in flushing debris from the visual field. Grasping forceps<sup>1</sup> (3 Fr or 5 Fr) can be inserted into the channel to manipulate and remove foreign objects. The crop incision was closed using standard techniques.

### Ventral Hepatic Peritoneal Cavities

The liver of the bird is encapsulated within two paired peritoneal cavities: the ventral and dorsal hepatic peritoneal cavities. The paired ventral hepatic peritoneal cavities (VHPC) are the largest and of greatest clinical significance. The right and left VHPC are separated by the ventral mesentery. The right lobe of the liver is larger in most birds (Colors 13.22, 13.28).

To gain access to the liver, one or both of these ventral cavities must be entered. The liver can be visualized from the cranial and caudal thoracic air sacs (Colors 13.5, 13.24) and indeed seems tantalizingly close in most birds. In reality, the liver is covered by a layer of peritoneum that is contiguous with the overlying air sac. To access the liver, the ventral hepatic peritoneal cavity (VHPC) must be entered either laterally from the caudal thoracic air sac or by a direct, ventral midline approach. The ventral approach<sup>16</sup> is best for examining and sampling both lobes of the liver. A skin incision is made on the midline just caudal to the border of the sternum. The linea alba is incised and the caudal border of the VHPC is bluntly penetrated. A substantial fat pad may be present overlying the outer surface of the caudal border of the VHPC. Under conditions of health, the liver should not protrude past the caudal border of the sternum.

The VHPC may also be entered from the caudal thoracic air sac. This may be most convenient when a lateral approach has been used for a general diagnostic examination and liver lesions have been noted. An opening can be made in the confluent walls of the caudal thoracic air sac and the VHPC by using endoscopically guided forceps to pick up and tear a small hole in the membranes. The lateral border of the liver can then be grasped through this VHPC access (Colors 13.29, 13.42). This approach is contraindicated in patients with ascites because fluid will drain into the air sac and may be aspirated (Color 13.30).

### Intercostal Approach to Lungs

An intercostal approach to the lung for biopsy has been recently described in the pigeon.<sup>11</sup> Entry was recommended through the dorsolateral portion of the third or fourth intercostal space where pulmonary tissue is the thickest in cross section. The third inter-

costal space is located by counting cranially from the last rib. The space is palpated just ventral to the scapula and a small skin incision is made. The intercostal muscles are bluntly separated to the level of the pleura. Care must be taken during dissection through the intercostal muscle to avoid deep penetration, which can traumatize the surface of the lung. The resulting hemorrhage may make visualization difficult and lead to sample artifact.

An instrumented sheath and rigid endoscope are inserted into the incision and maneuvered carefully between the ribs so that the surface of the lung can be visualized. The rounded edges of the sheath aid in atraumatically positioning the instrument. A 5 Fr flexible forceps is advanced into the lung parenchyma, the jaws closed rapidly and removed. Post-biopsy hemorrhage may vary from mild to moderate but is usually controlled by pressure. Intercostal muscle and skin are closed routinely with simple interrupted sutures.

While it is not essential to utilize an endoscope to biopsy the lung from this site, it was found that the sheath and endoscope combination greatly aided the collection of quality pulmonary biopsies with less risk of trauma to the patient.<sup>11</sup> Rigid cup biopsy forceps can be manipulated unaided through a similar intercostal incision, but trauma to the surface of the lung may be greater due to the short working distance and lack of magnification.

### Intestinal Peritoneal Cavity

The intestinal peritoneal cavity (IPC) is the largest of the peritoneal cavities. It is a single, midline potential space that extends from the level of the kidneys caudal to the vent. It is somewhat subdivided by the several mesenteries formed by reflections of the peritoneum that suspend the proventriculus, intestines, gonads and supporting structures.<sup>16,24</sup> The gonads are actually suspended within the IPC and are not located within the abdominal air sac. The confusion in this positioning is understandable because the gonads are clearly visible from the abdominal air sac even though they are covered by the air sac wall and the confluent peritoneum (Color 13.12, 13.13). One method to demonstrate the relationship between the IPC and the abdominal air sac is to insert an endoscope into the IPC, optically guiding it toward the left gonad and then viewing this arrangement from the abdominal air sac via a second endoscope (Color 13.25). The thin but substantial air sac/peritoneal wall can be seen clearly covering the endoscope.

The intimate relationship between the abdominal air sac and the IPC is of greatest clinical significance in the female bird. The dorsal mesentery, the dorsal parietal peritoneum and the peritoneum covering the left abdominal air sac fuse to form a serous pocket surrounding the ovary.<sup>24</sup> This “ovarian pocket” is believed to help guide ova to the infundibulum.<sup>6</sup> It has been suggested<sup>5</sup> that extensive damage to both the right and left abdominal air sacs in female birds will lead to infertility and that trauma should be limited to only one of the abdominal air sacs. This suggestion ignores the presence of the IPC and simplifies the role of the abdominal air sacs. Under routine endoscopic examination from a lateral approach only the lateral wall of the abdominal air sac is penetrated. The confluent medial wall of the abdominal air sac and the IPC would not be penetrated under these circumstances. Thus, the ovarian pocket would not be disrupted. A hysterectomy (salpingohysterectomy) performed from a lateral approach will disrupt the left IPC membrane.

### Cloaca

The cloaca is a unique, three-chambered structure that receives the terminal portions of the colon, ureters and reproductive tract. Endoscopic examination of the three parts of the cloaca is complicated by the presence of feces and urates. Flushing the proctodeum with saline and then insufflating the structure while closing the vent lips around the telescope will enhance viewing. Uroliths,<sup>18</sup> papillomatous inflammation and true prolapse have been documented with endoscopy. Bacterial and fungal cloacitis may also occur.

### Distal Oviduct (Uterus)

Endoscopic examination of the distal oviduct (uterus) is possible in reproductively active birds and may be a useful procedure for the sampling and diagnosis of oviductal disease.

## Biopsy Techniques

### Patient Considerations

#### Indications

Open (surgical) and percutaneous techniques for biopsy of the liver have been described in avian medicine. Other internal organs have occasionally been

biopsied using open techniques. The ability to obtain precise target biopsies of specific organs is a natural extension of endoscopic examination and offers a far less traumatic method for obtaining diagnostic specimens. Carefully selected biopsies of affected organs may be critical in establishing a diagnosis and allow more precise therapeutic decisions. Table 13.3 describes approaches and techniques for specific organ biopsies.

Indications for biopsy may include abnormal radiographic findings or biochemical parameters, chronic respiratory disease, polyuria and polydipsia (see Table 13.2). The endoscopist should be prepared to collect biopsies during routine examinations. It is not uncommon to find unexpected lesions in patients presented for gender determination. Specimens from obvious lesions are easily collected from the border zone where abnormal meets normal tissue. If the patient's history, physical examination or biochemical findings suggest renal or hepatic abnormalities, biopsy of the kidney or liver is indicated. Tissues will frequently appear grossly normal even though there are significant histologic lesions present.<sup>20</sup>

The decision to biopsy the liver or kidney (Color 13.43) is frequently made too late in the disease process to be truly helpful to the patient and client. Sampling the end stage liver is seldom illuminating beyond confirming a poor prognosis that should be otherwise clinically evident. Many birds with early cases of hepatic disease demonstrate few clinical signs. Recent advances in avian clinical biochemistry procedures, particularly the measurement of bile acids, promise to improve the clinician's ability to detect liver disease at an early stage. Bile acids determination is a sensitive and specific indicator of liver damage (see Chapters 11, 20). Histologic changes are seen in the livers of patients with persistent increases in the bile acids of two times or greater the normal reference intervals. A liver biopsy is recommended in cases where the bile acids measurement remains elevated following the completion of therapy for a systemic disease (eg, chlamydiosis) or where continued elevation of two weeks or more is confirmed.

Renal disease can also be challenging to recognize and diagnose in its early stages (Color 13.47, 13.48). Elevations in uric acid levels may not occur until a relatively large number of renal tubules have been damaged. Polyuria is frequently noted. Kidney biopsy is recommended when uric acid levels are consistently above reference values or show evidence of

TABLE 13.3 Specific Organ Biopsies: Approaches and Techniques

Organ	Approach	Technique
Liver	Best accessed from the VHPC but may also be approached through the left and right caudal thoracic air sac (caudal TAS).	In generalized diseases of the liver, samples can be most easily obtained from the hepatic border using a 5 or 7 Fr instrument. In focal disease (eg, granulomas, neoplasia), the lesion should be specifically targeted taking care not to open the jaws of the forceps too wide when pushing into the liver. This will reduce crush artifact. Larger, rigid forceps can be used but are not usually necessary.
Kidney	Through the caudal TAS into the cranial portion of the abdominal air sac (AAS) or via the AAS approach. May also be approached directly through the IPC, although this potential space would need to be insufflated. The caudal TAS approaches are most suitable for reaching the cranial and middle divisions of the kidney. Entry into the AAS is an excellent way to reach the caudal division of the kidney.	Depending upon the size of the patient, 3, 5 or 7 Fr forceps can be used. Cup-shaped forceps can be used to control depth of penetration. In some smaller birds, the 5 Fr round cup forceps <sup>1</sup> may be more appropriate than those with a standard elliptical shape.
Air Sac	In most species, the caudal TAS is the one most frequently involved in air sac pathology. Lesions may be more prominent on one side than another or may involve the cranial TAS more extensively. Radiographs may be most helpful in selecting the preferred entry site.	Cup biopsy forceps may be used to grasp a small piece of air sac from the border of an air sac puncture site (eg, the caudal TAS/AAS entry site) or to harvest focal lesions directly from the surface of the air sac. Exudate may also be collected with the forceps for microbiology.
Lung	Two approaches to the avian lung were recently described. <sup>11</sup> An endoscopically-guided biopsy of the caudal surface of the lung can be collected from the caudal TAS using the Storz system. It is also possible to access the costal surface of the lung through an intercostal approach. The Storz system may be used to enter the intercostal space and visualize the lung, or a rigid forceps may be guided by the surgeon unaided.	5, 7 and 9 Fr forceps have been used to collect pulmonary biopsies. The degree of localized pulmonary hemorrhage is directly related to the size of the biopsy forceps used and the depth of penetration.
Spleen	The spleen is approached from the left AAS. The AAS may be entered through the caudal TAS or from the caudal approach. The spleen is located on the right side of the proventriculus near the junction with the ventriculus.	A 5 Fr elliptical cup is satisfactory for most patients.
Ventriculus	The greater curvature of the ventriculus, particularly the caudoventral surface, is best approached from the caudal TAS through the left paralumbar fossa.	A 7 or 9 Fr elliptical forceps is recommended. A minimum of two biopsies is collected from the caudoventral surface near a blood vessel to ensure the harvesting of nerve as well as serosa and muscularis.
Testes	The right or left testicle can be reached from its respective AAS or from the IPC.	A smaller forceps is less traumatic (eg, 5 Fr round) although testicular biopsy utilizing a 9 Fr elliptical cup instrument has been reported. <sup>8</sup>

an increasing trend or where polydipsia and polyuria persist without clinical explanation.

Air sac and pulmonary biopsies are indicated when clinical examination, radiographic studies or auscultation reveal persistent, nonresponsive respiratory disease. Dyspnea upon exertion is common in parrots with chronic respiratory disease but is not diagnostic because other thoracoabdominal pathology (eg, hepatomegaly, abdominal tumors) may also generate this clinical sign. Generalized pulmonary disease is best assayed with these techniques although specific types of focal lesions may also be sampled (Color 13.49).

Biopsies of the spleen are indicated in persistent systemic diseases where an etiologic diagnosis is lacking, in cases of unexplained splenomegaly and in granulomatous inflammation of the spleen.

Samples of the ventricular serosa and muscularis that include nerve tissue can be valuable in the definitive antemortem diagnosis of neuropathic gastric dilatation (NGD). A minimum of two specimens is obtained from the caudoventral surface of the ventriculus. A site near a branching blood vessel is chosen in an attempt to harvest nervous tissue. The thick ventricular muscularis prevents perforation of the viscus. These sites heal well, as only a portion of the serosa and outer muscularis is required. Ventricular biopsies are preferred for the diagnosis of NGD over proventricular biopsies because the serosa of the ventriculus can be harvested much more safely with less risk of perforation due to the thicker muscularis. The ventriculus is believed to be the most important site for NGD involvement due to its role in the motility of the gastrointestinal system. Biopsy of the proventriculus is contraindicated due to its thin



wall and the difficulty in preventing perforation with gastric spillage and peritonitis. Some researchers are investigating the possibility of identifying histopathologic lesions of NGD in biopsies of the crop.

Small, precise biopsies of the testicle may be useful in the documentation of reproductive failure due to dysfunction of the testes. Local and systemic infections may cause testicular lesions, although these have been poorly documented.

### Contraindications

The specific contraindications for biopsy relate to blood clotting. Biopsy collection should be delayed in any avian patient that shows evidence of abnormalities of the hemostatic system. This usually becomes evident at the time of blood collection. Most birds should show clot formation in one to two minutes. Deficiency of vitamin K is the most common coagulation disorder, for which vitamin K<sub>1</sub>h is administered pre-surgically (see Chapter 18). The blood film should be examined for the presence of adequate thrombocyte numbers.

A biopsy cup shape and diameter appropriate to the size of the patient and organ to be biopsied must be chosen. Forceps too large for the purpose may cause excessive organ trauma and hemorrhage.

Biopsy cups generally come in only two shapes: round or elliptical. The round shape does not penetrate as deeply into tissue as the same diameter elliptical cup and this may be indicated for use with certain organs such as the kidney or testes.

Inexperience with the instrumentation and approaches to the organ is a potential cause of biopsy complications.

### Instrumentation

Table 13.4 lists selected sources of endoscopic and biopsy equipment.

A percutaneous technique to biopsy the avian liver using a 19 ga modified Jamshidi or Menghini needle has been described.<sup>18</sup> The larger, right lobe of the liver was approached through the sternal notch with the needle directed posteriorly to avoid puncture of the heart. The technique is relatively rapid to perform, but it is a blind procedure. The liver cannot be inspected nor can focal lesions be sampled. The proventriculus, heart and bile duct are at risk for organ trauma. Optically guided biopsies of the liver are superior.<sup>20</sup> A rigid cup biopsy forceps originally de-

**TABLE 13.4** Manufacturers of Endoscopic Equipment

Karl Storz Veterinary Endoscopy-America, Inc.  
175 B Cremona Drive  
Goleta, California 93117  
USA

Richard Wolf Medical Instruments Corp.  
7046 Lyndon Avenue  
Rosemont, Illinois 60018  
USA

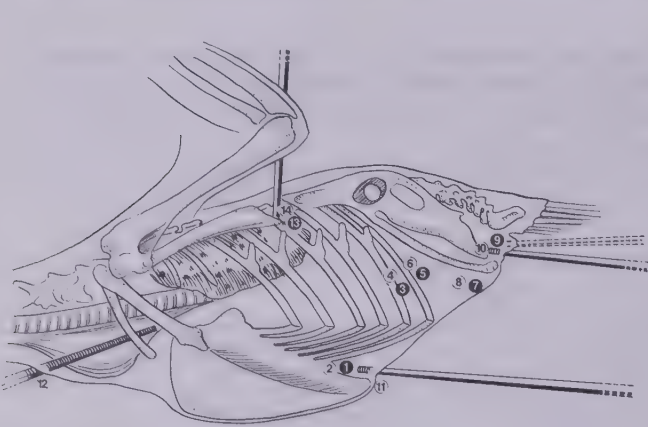
Olympus Corporation  
4 Nevada Drive  
Lake Success, New York 11042-1179  
USA

Orlux Engineering and Instrumentation Ltd.  
18 Strathearn Avenue, Unit 17 B  
Brampton, Ontario L6T 4X9  
CANADA

signed for otolaryngology<sup>i</sup> can be guided along the shaft of the endoscope to the visual field. Biopsies of the liver, kidney, spleen, air sacs, lung and testes can be obtained under direct observation. The 8150.00 forceps has a 3.0 mm (9 Fr) diameter cup and takes a relatively large, elliptical sample. This instrument should not be used in birds under 200 g. This forceps in combination with a 2.2 or 2.7 mm telescope has been the most widely utilized and accepted method for collecting optically guided biopsies in the avian patient. The forceps is "walked" into position along the shaft of the endoscope until it can be visualized.

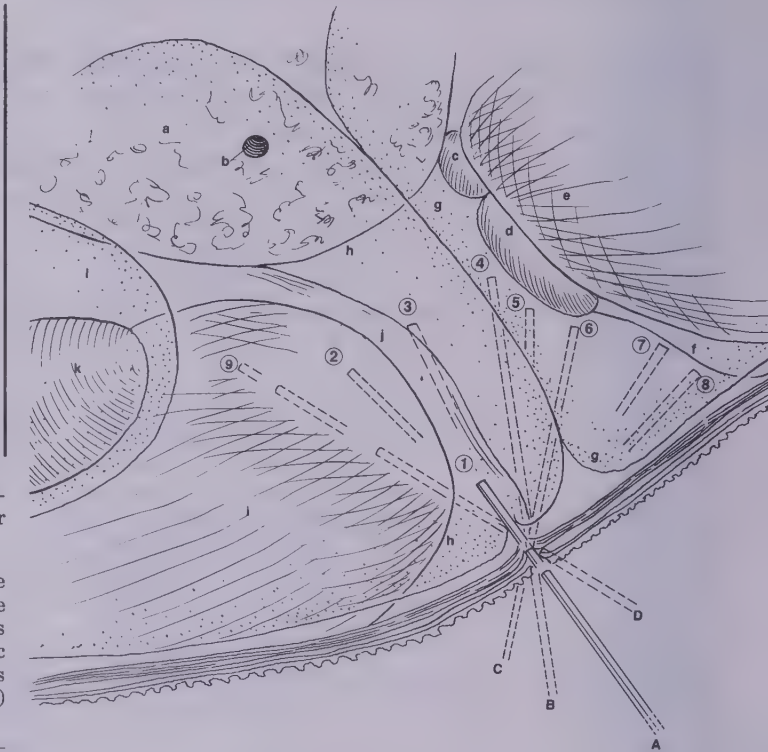
In an effort to improve the usefulness of endoscopically guided biopsies, a new endoscope and sheath set has been developed<sup>a</sup> in cooperation with Karl Storz Endoscopy. An instrument channel permits the use of implements up to 5 Fr (1.7 mm) diameter. Flexible forceps for biopsy and grasping as well as aspiration and infusion cannulas can be placed into the port of the channel and guided easily to the tip of the sheath and into the viewing field of the endoscope. This single puncture system simplifies the manipulation of instrumentation for the endoscopist and helps prevent additional patient trauma.

The system is appropriate for patients weighing approximately 150 g to 2000 g. In larger birds or at certain sites (eg, the ventriculus), a heavier biopsy forceps (eg, 7 Fr) is frequently required. This necessitates a larger sheath. The advantage of a systematic approach to endoscopic equipment employing one manufacturer is that a modular design can be



**FIG 13.2** (repeated) Numbered endoscopic sites described for evaluation of the internal anatomy of birds. Entry sites are shown as either left-sided approaches (open) or right-sided approaches (solid).

**FIG 13.4** (repeated) The endoscopist can develop an insight into the relative position of organs as viewed from entry site 6. The views are divided into four angles (A,B,C,D) and depths (1 through 9). Structures used for orientation include: a) lung b) ostium of the cranial thoracic air sac c) adrenal gland d) gonad e) kidney f) ureter, oviduct, vas deferens area g) abdominal air sac h) caudal thoracic air sac i) liver j) proventriculus k) heart and l) cranial thoracic air sac.



## Endoscopic Examination and Biopsy Techniques

### Color 13.22

Gross view from the end of the sternum in a cockatoo placed in dorsal recumbency. The sternum (s) has been elevated to accentuate the division of the cavities visible from endoscope insertion point 11 (Figure 13.2). The confluent wall of the right cranial thoracic air sac and right ventral hepatic peritoneal cavity (1), ventral mesentery (2) and confluent wall of the left cranial thoracic air sac and right ventral hepatic peritoneal cavity (3) are clearly visible. The right liver lobe (rl) and left liver lobes (ll) are also visible. The right ventral hepatic peritoneal cavity is marked by arrows; the left ventral hepatic peritoneal cavity is marked with open arrows.

### Color 13.23

(Insertion point 2 see Figure 13.2) View inside the left cranial thoracic air sac of an Amazon parrot. For reference purposes, insertion point 2 would provide a similar view to position D-9 if entering through site 6 as shown in Figure 13.4. Easily identifiable structures include ribs (r), proventriculus (p), medial intercostal muscle (m), heart (h), attachment of pericardial sac (arrow), lung (lu), ostium of cranial thoracic air sac (open arrow) and liver (li).

### Color 13.24

(Insertion Point 2 see Figure 13.2) The endoscope is in the cranial thoracic air sac, and the contiguous wall between the cranial and caudal thoracic air sacs is visible caudally (a). In this entry site, the heart (h) will be observed beating cranially. Other structures that can be visualized include ribs (r), lung (lu), liver (l), medial intercostal

muscle (m) and the ostium for the cranial thoracic air sac (arrow).

### Color 13.25

(Insertion point 10 see Figure 13.2) An endoscope placed in the left abdominal air sac was used to take a picture of a second endoscope guided into the intestinal peritoneal cavity. Note the membrane (arrow) covering the tip of the endoscope with the intestinal (in) tract under the membrane. Other visible structures include the lung (lu), cranial pole of the left kidney (k), transverse abdominal muscle (m), ilium (i) and proventriculus (p).

### Color 13.26

(Insertion point 10 see Figure 13.2) This Amazon parrot had been endoscoped from insertion point 6 and the iatrogenic tear that was made in the contiguous wall of the caudal thoracic and abdominal air sac is clearly visible (arrow). Equipment used for endoscopy must be sterile to prevent air sac infections or peritonitis. The air sacs were originally clear and now are considered cloudy, and there is an increase in vascularization. When viewed from insertion point 8, a granuloma is evident in the air sac (g). Other structures that are visible include lung (lu), ilium (i), cranial pole of the left kidney (k), loop of intestines (in), proventriculus (p), external iliac vein (open arrow).

### Color 13.27

(Insertion point 10 see Figure 13.2) A rent is visible in the contiguous wall of the caudal thoracic and abdominal air sac (arrow) showing the path of the endoscope when inserted at point 6 for gender determina-

tion. Other visible structures include lung (lu), external iliac vein (open arrow), cranial division of the left kidney (k1), middle division of the left kidney (k2), (i) ilium, loops of intestines (in) and proventriculus (p). This represents how a site should appear if the original entry was performed under aseptic conditions. Compare this to Color 13.26.

### Color 13.28

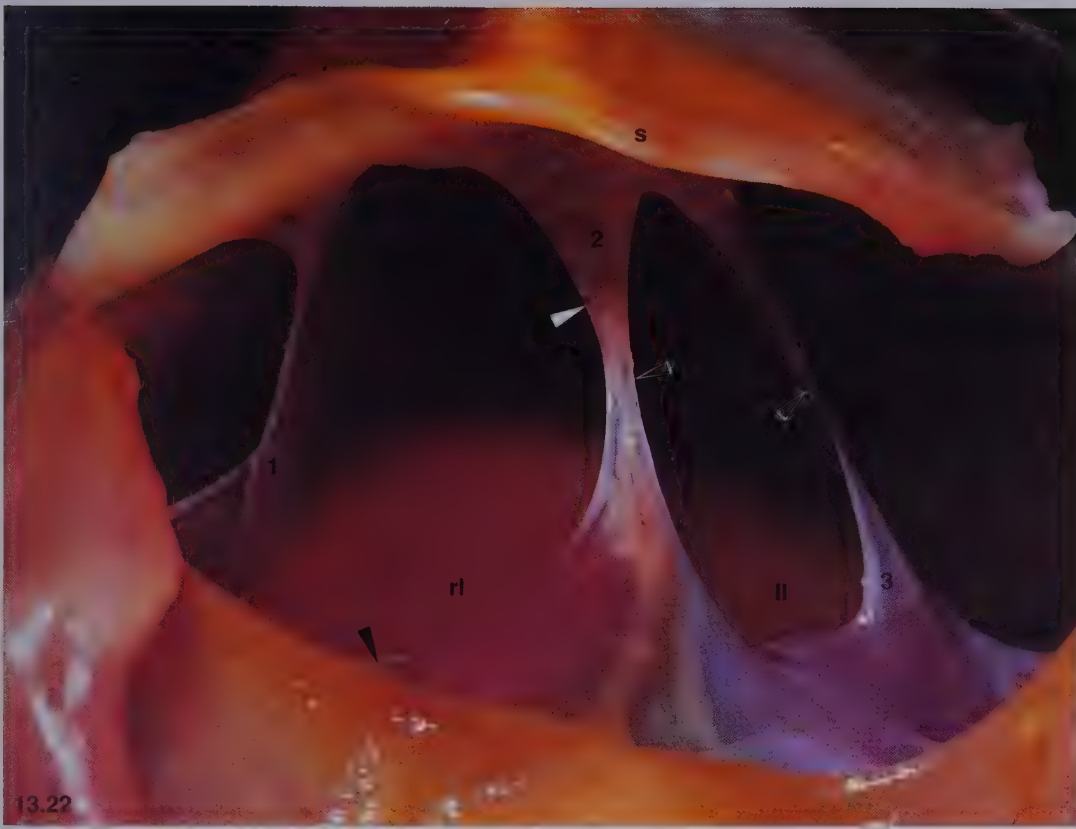
(Insertion point 11 see Figure 13.2) The normal endoscopic anatomy of the ventral hepatic peritoneal cavity of a pigeon. This view provides clear visualization of the size, shape and texture of the liver. This position can be used to obtain endoscopically guided biopsies of the liver. Note that the right lobe of the liver (rl) extends further caudally than the left lobe of the liver (ll). Other structures that can be visualized include the sternum (s), deep pectoral muscle (m), proventriculus (p) and heart (h).

### Color 13.29

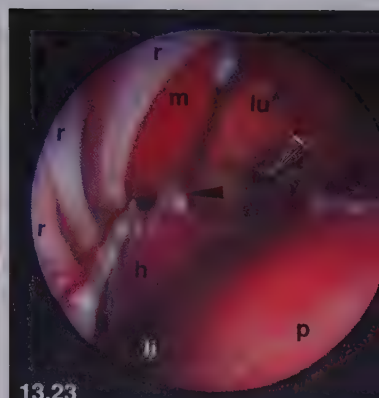
A small tear (arrow) has been created in the caudal thoracic air sac to enter the underlying left ventral hepatic peritoneal cavity of a normal pigeon. Liver (li), proventriculus (p), lung (lu), ostium of caudal thoracic air sac (o), contiguous wall of the caudal thoracic and abdominal air sac (a), contiguous wall of the cranial and caudal thoracic air sac (open arrows).

### Color 13.30

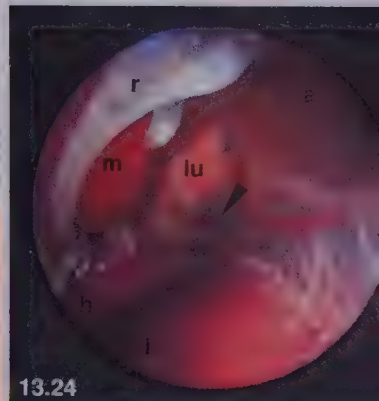
Left, ventral, hepatic peritoneal cavity distended with air (arrows) following biopsy of the liver. Other visible structures include the lung (lu) and proventriculus (p).



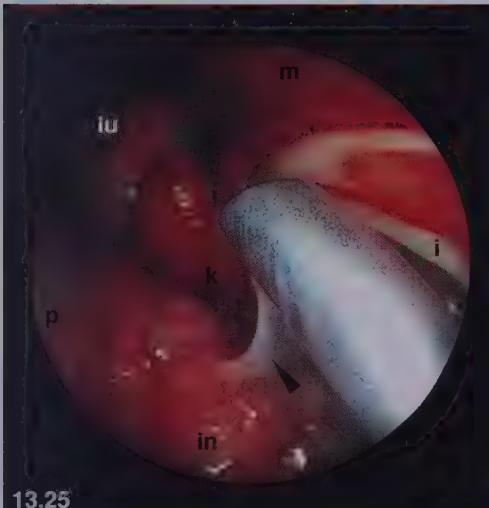
13.22



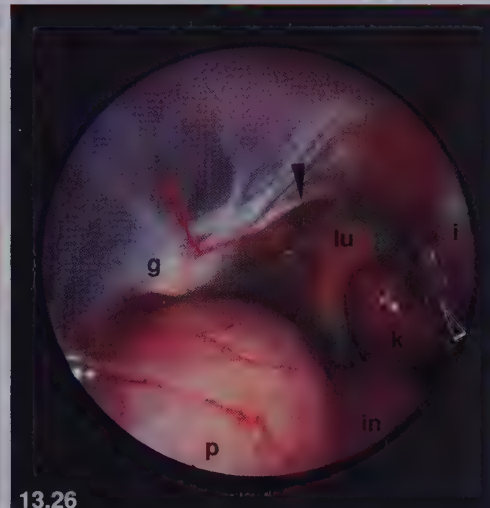
13.23



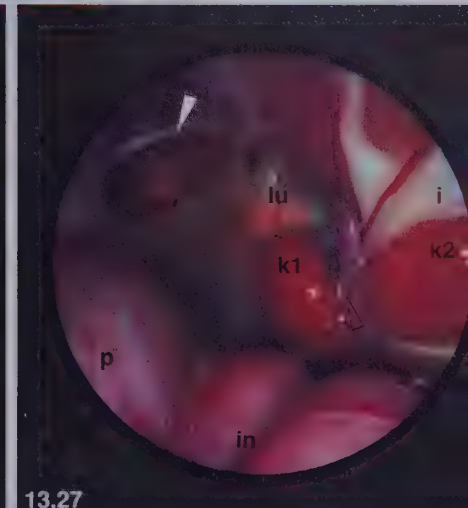
13.24



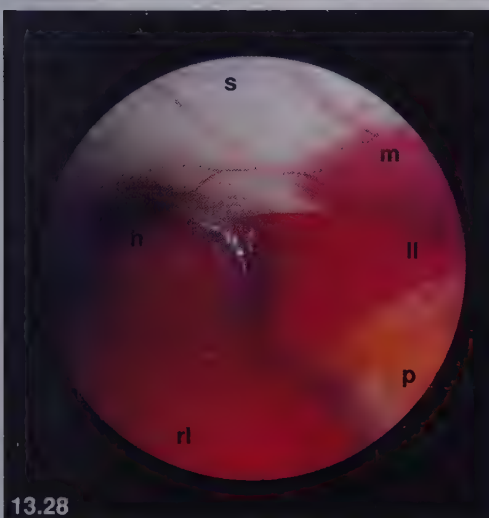
13.25



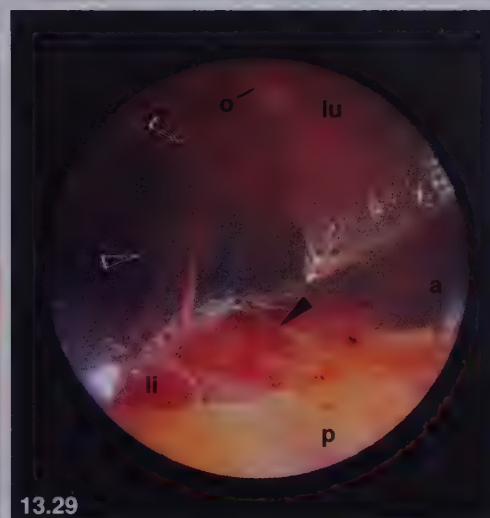13.26



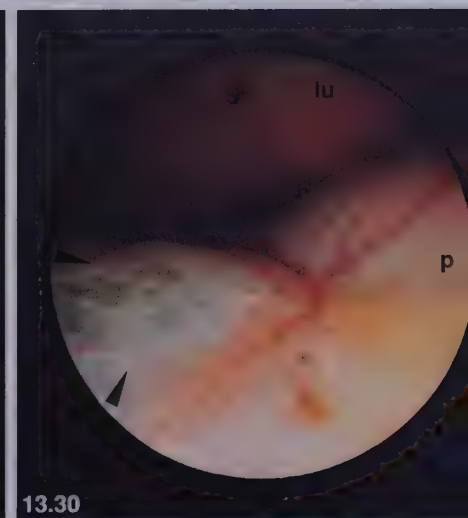
13.27



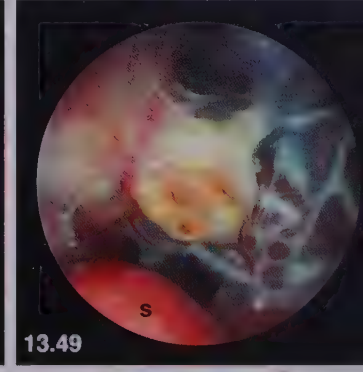
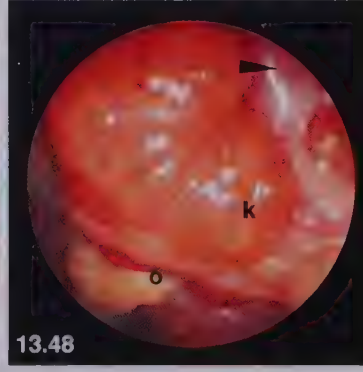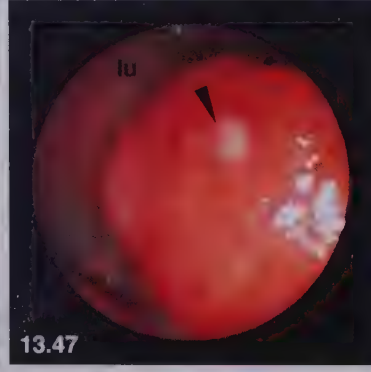
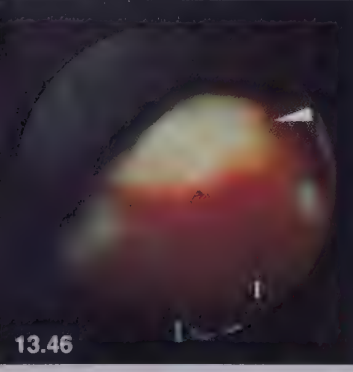
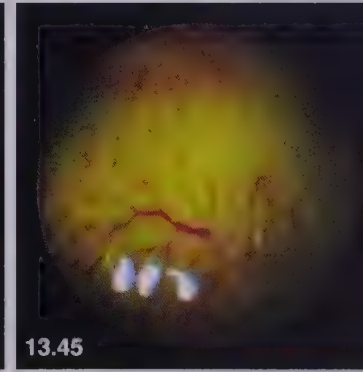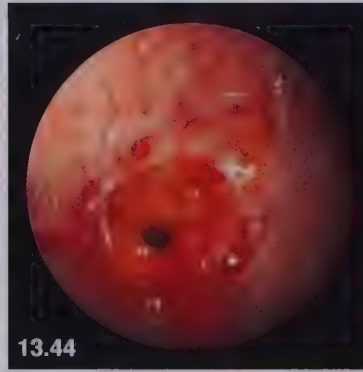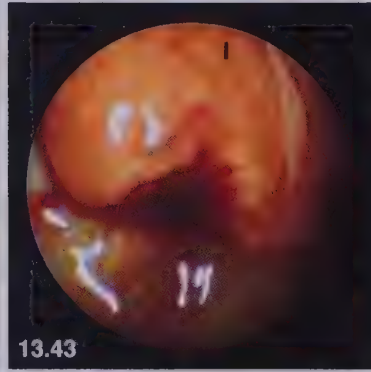
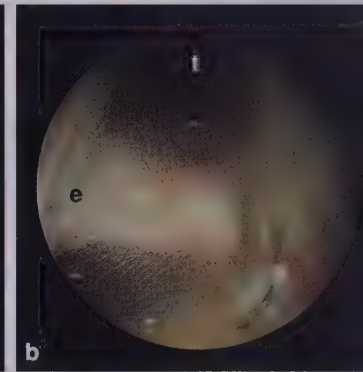
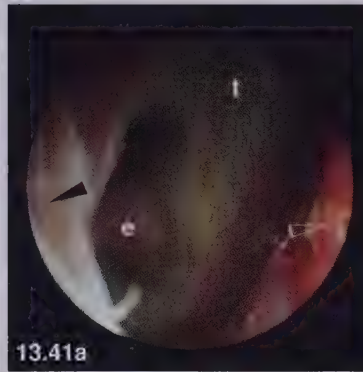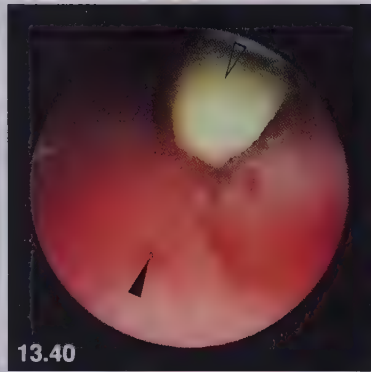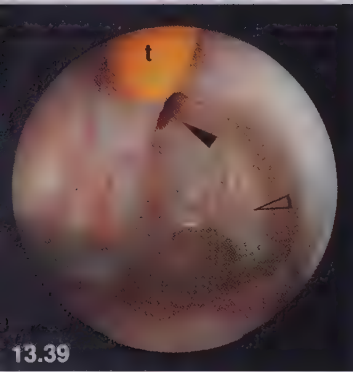
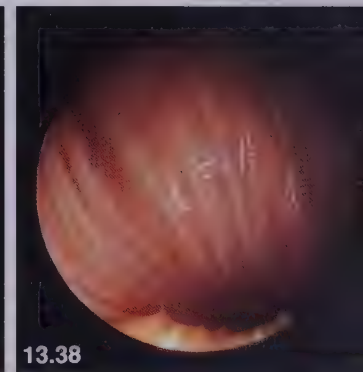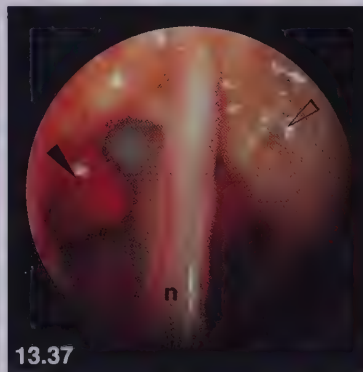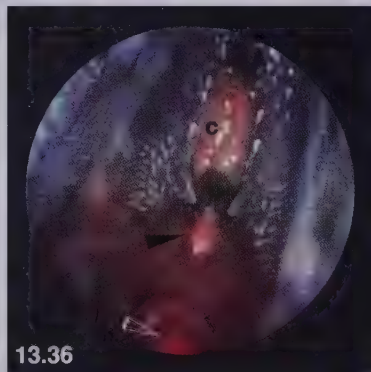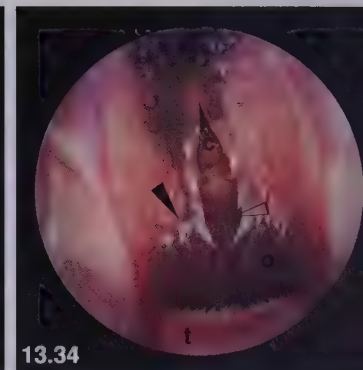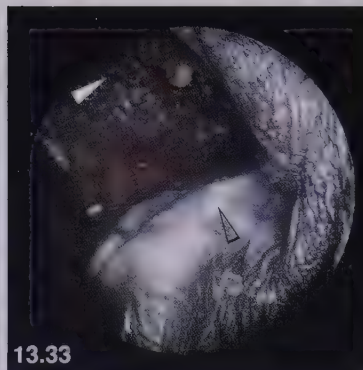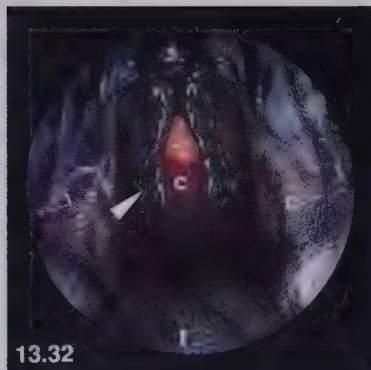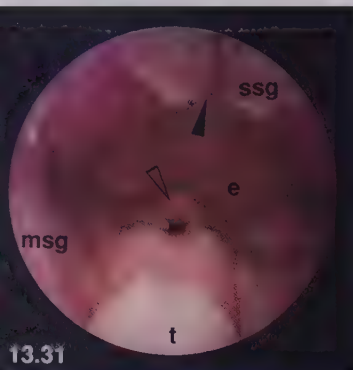13.28



13.29



13.30



## Endoscopic Examination and Biopsy Techniques

### Color 13.31

An endoscope has been placed in the oral cavity of a Great Horned Owl showing the infundibular cleft (arrow), sphenopterygoid salivary glands (ssg), longitudinal folds of the esophagus (e), laryngeal mound (open arrow), tongue (t) and mandibular salivary glands (msg).

### Color 13.32

An endoscope has been placed in the oral cavity of a normal African Grey Parrot. Note the dark pigmentation and uniform coloration and texture of the oral mucosa. Well formed papillae (arrow) are noted on either side of the choanal slit (c). Also visible are the lateral commissures of the mouth (open arrows) and the tongue (t).

### Color 13.33

Lateral view of the oral cavity in a Yellow-crowned Amazon Parrot with hypovitaminosis A. Abscessation (open arrow) at the base of the tongue (t), and blunting and abscessation of the choanal papillae (arrow) are characteristic. Hyperkeratosis of the tongue and oral mucosa are also noted.

### Color 13.34

An endoscope has been placed in the oral cavity of a normal Amazon parrot. Note the smooth texture of the tissues in the oral mucosa. All secretions are serous in nature. The choanal (arrow) and lingual papillae are sharp and well defined. Other structures that can be visualized include the tongue (t), oropharynx (o), infundibular cleft (open arrow) and choana (c).

### Color 13.35

Endoscopic view of the palate in a Great Horned Owl. The cranial choanal slit (arrow) and sphenopterygoid salivary glands (ssg) are visible. Note that the choanal slit does not contain papillae, but that papillae are present on the caudal edge of the sphenopterygoid salivary glands.

### Color 13.36

Caudal view of the choanal area in an African Grey Parrot. The visible structures in-

clude the choanal slit (c), infundibular cleft (arrow) and endotracheal tube placed in the trachea (open arrow). Note that the structure of the choanal papillae is different in an African Grey Parrot than in an Amazon parrot (see Color 13.34).

### Color 13.37

Endoscopic view of the cranial margin of the choanal slit in a Moluccan Cockatoo. The nasal septum (n), left middle nasal concha (arrow) and nasal mucous membranes (open arrow) are visible.

### Color 13.38

Normal esophagus of a Great Horned Owl showing longitudinal folds.

### Color 13.39

Normal crop of a cockatoo. A red rubber feeding catheter (t) has been introduced into the crop and is just ventral to the opening from the crop into the thoracic esophagus (arrow). Normal, clear, bubbly mucus is seen covering the crop mucosa. Wrinkling of the crop mucosa (open arrow) is occurring in response to a peristaltic wave. Note the smooth, thin texture and even color of the crop mucosa.

### Color 13.40

An endoscope has been passed into the fluid-filled proventriculus of a pigeon. Note the openings of the proventricular glands (arrow) and a pelleted food particle (open arrow).

### Color 13.41

**a)** An endoscope has been inserted into the external ear canal of a Great Horned Owl to show the tympanic membrane (t), extracolumellar cartilage (e), cranial wall of the ear canal (arrow) and caudal wall of the ear canal (open arrow). **b)** Closer view of extracolumellar cartilage.

### Color 13.42

Biopsy forceps are being used to take a sample from the caudal edge of the left liver lobe (l). The confluent wall of the caudal thoracic air sac and left ventral hepatic

peritoneal cavity membrane are clearly visible (arrow).

### Color 13.43

Post-biopsy view of the left liver lobe (l) in a pionus parrot with avian mycobacteriosis.

### Color 13.44

Insertion 6. Post-biopsy photograph of the lung as viewed from within the left caudal thoracic air sac.

### Color 13.45

Liver of an Amazon parrot showing severe biliverdin accumulation secondary to chlamydiosis.

### Color 13.46

Endoscopic view of the liver (l) prior to biopsy of several white-to-yellow proliferative masses (arrow). Histopathology indicated bile duct carcinoma in an Amazon parrot. This bird had a history of cloacal papillomatosis.

### Color 13.47

(Position B-4 see Figure 13.4) Endoscopic view of the cranial pole of the left kidney in an Amazon parrot showing several white, proliferative masses (arrow). Biopsy indicated lymphosarcoma. Other visible structures include the lung (lu).

### Color 13.48

(Insertion point 6, position B-4 see Figure 13.4) Endoscopic appearance of chronic glomerulonephritis in an Amazon parrot. The cranial pole of the left kidney (k), common iliac vein (arrow) and ovary (o) are clearly visible.

### Color 13.49

Granuloma in the abdominal air sac of a pionus parrot. The substantial vascularity of the adjacent air sacs suggests a chronic reaction. The fact that the air sac tissue at the periphery of the mass is normal suggests that the infection has been contained. The spleen (s) is enlarged and pale.

used. Thus the 2.7 mm endoscope in the standard Storz avian set can be inserted into other sheaths such as the modified 26156 H, which permits the introduction and use of the larger 7 Fr biopsy forceps.

### Preparation of Small Biopsies

The biopsies obtained with the types of forceps previously mentioned are small and must be handled with care so that they are not lost or damaged. Various techniques have been recommended in the past to enable the histotechnologist to locate and properly imbed small specimens for processing. Wrapping tiny pieces of tissue in filter paper or a very fine cloth before immersion in the fixative is one method. Or the specimens can be placed into a small stoppered blood collection container without anticoagulant.<sup>k</sup> This system is simple and effective, allowing the technician to clearly visualize the sample(s). No more than two to three specimens should be placed in each clearly labelled container. Small tissue samples require far less time to fix than larger samples (likely less than two hours in formalin). Specifically buffered, ten per cent formalin designed for tissue fixation must be used. Failure to do so will lead to precipitates and artifacts. If biopsies cannot be processed immediately, the specimens can be stored in a solution of 97% methyl alcohol after fixation in order to ensure sample quality. The laboratory should be contacted for specific recommendations.

### Consulting Pathologists

The value of the clinical biopsy is directly related to the quality of the sample, the history provided and the experience of the pathologist. Reading small surgical biopsies from exotic avian species is a relatively specialized area of pathology. Best results are likely to be obtained by working with a consultant pathologist who has a real interest and expertise in this field. Timely reporting of results is essential to enable the clinician to make optimal use of the biopsy information.

#### Products Mentioned in the Text

- a. Avian Endoscopy Diagnostic Set, 2.7 mm, Karl Storz Veterinary Endoscopy, Goleta, CA, 64108 BS, 2.7 mm, 30 Telescope, 67065 C Sheath, 67161 Z Biopsy Forceps.
- b. Focuscope, MDS Inc, Clearwater, FL
- c. Glutorex, 3M Medical Products, St. Paul, MN.
- d. Tegaderm 1626 and 9505, 3M Medical-Surgical Division, St. Paul, MN, OpSite 4963C, Smith and Nephew Inc., Lachine, QC
- e. AErrane, Anaquest, Madison, WI; Isoflo, Solvay Animal Health, Mendota Heights, MN
- f. Vetwrap, 3M Corp, St. Paul, MN
- g. Sovereign, Sherwood Medical, St. Louis, MO
- h. AquaMephyton, MSD, Rahway, NJ
- i. Forceps 8150.00, Richard Wolf Medical, Rosemont, IL
- j. Storz # 27071 T, Karl Storz Veterinary Endoscopy, Goleta, CA
- k. Vacutainer red top three ml. tube #6381, Becton Dickinson, Rutherford, NJ

### References and Suggested Reading

1. **Bailey RE:** Surgery for sexing and observing gonad condition in birds. *Auk* 70:497-499, 1953.
2. **Bush M:** Laparoscopy in birds and reptiles. In Harrison RM, Wildt DE (eds): *Animal Laparoscopy*. Baltimore, Williams and Wilkins, 1980, pp 183-197.
3. **Degernes LA, et al:** Lead poisoning in trumpeter swans. *Proc Assoc Avian Vet*, 1989, pp 144-155.
4. **Evans HE:** Anatomy of the budgerigar. In Petrak ML (ed): *Diseases of Cage and Aviary Birds* 2nd ed. Philadelphia, Lea and Febiger, 1982, pp 111-187.
5. **Frankenhuis MT, Kappert HJ:** Infertility due to surgery on body cavity in female birds: Cause and prevention. XXII Inter Symp Erkr Zoo-Arnheim, Akademie-Verlag, Berlin, 1980, pp 237-239.
6. **Goodchild WM:** Differentiation of the body cavities and air sacs of *Gallus domesticus* postmortem and their location *in vivo*. *Br Poult Sci* 11:209-215, 1970.
7. **Harrison GJ:** Endoscopic examination of avian gonadal tissue. *Vet Med Small Anim Clin* 73:479-484, 1978.
8. **Harrison GJ:** Endoscopy. In Harrison GJ, Harrison LR (eds): *Clinical Avian Medicine and Surgery*. Philadelphia, WB Saunders Co, 1986, pp 224-244.
9. **Hopkins HH:** Optical principles of the endoscope. In Berci G (ed): *Endoscopy*. New York, Appleton Century Crofts, 1976, pp 3-27.
10. **Hulka JF:** *Textbook of Laparoscopy*. Orlando, Grune and Stratton, 1985, p 11.
11. **Hunter DB, Taylor M:** Lung biopsy as a diagnostic technique in avian medicine. *Proc Assoc Avian Vet*, 1992, pp 207-211.
12. **Ingram KA:** Laparotomy technique for sex determination of psittacine birds. *J Am Vet Med Assoc* 173(9):1244-1246, 1978.
13. **Ingram KA:** Ooscopic technique for sexing birds. In Kirk RW (ed): *Current Veterinary Therapy VII*. Philadelphia, WB Saunders Co, 1980, pp 656-658.
14. **Johnson AL:** Reproduction in the female and male. In Sturkie PD (ed): *Avian Physiology* 4th ed. New York, Springer Verlag, 1986, p 404.
15. **Jones DM, et al:** Sex determination of monomorphic birds by fiberoptic endoscopy. *Vet Rec* 115:596-598, 1984.
16. **King AS, McLelland J:** Female reproductive system. In *Birds: Their Structure and Function*. London, Ballière Tindall, 1984, pp 145-165.
17. **King AS, McLelland J:** Respiratory system. In *Birds: Their Structure and Function*. London, Ballière Tindall, 1984, pp 110-144.
18. **Kollias GV:** Liver biopsy techniques in avian clinical practice. *Vet Clin North Am* 14(2):287-298, 1984.
19. **Kollias GV:** Avian endoscopy. In Jacobson ER, Kollias GV (eds): *Contemporary Issues in Small Animal Medicine, Exotic Animals*. New York, Churchill Livingstone, 1988, pp 75-104.
20. **Kollias GV, Harrison GJ:** Biopsy techniques. In Harrison GJ, Harrison LR (eds): *Clinical Avian Medicine and Surgery*. Philadelphia, WB Saunders Co, 1986, pp 245-249.
21. **Lumeij JT:** Endoscopy. A Contribution to Clinical Investigative Methods for Birds with Special Reference to the Racing Pigeon (*Columbia livia domestica*). Utrecht, PhD Thesis, 1987, p 151-166.
22. **McDonald SE:** Surgical sexing of birds by laparoscopy. *Calif Vet* 5:16-22, 1982.
23. **McDonald SE:** Endoscopic examination. In Burr EW (ed): *Companion Bird Medicine*. Ames, Iowa State University Press, 1987, pp 166-174.
24. **McLelland J, King AS:** The gross anatomy of the peritoneal and coelomic cavities of *Gallus domesticus*. *Anat Anaz Bd* 127:480-490, 1970.
25. **Redig PT:** Aspergillosis. In Kirk RW (ed): *Current Veterinary Therapy VIII*. Philadelphia, WB Saunders Co, 1983, pp 611-613.
26. **Risser AC:** A technique for performing laparotomy on small birds. *Condor* 73:376-379, 1971.
27. **Satterfield W:** Diagnostic laparoscopy in birds. In Kirk RW (ed): *Current Veterinary Therapy VII*. Philadelphia, WB Saunders Co, 1980, pp 659-661.
28. **Satterfield W:** Early diagnosis of avian tuberculosis by laparoscopy and liver biopsy. In Cooper JE, Greenwood AG (eds): *Recent Advances in the Study of Raptor Diseases*. Keighley, Chiron Publications, 1981, pp 105-106.
29. **Taylor M:** A morphologic approach to the endoscopic determination of sex in juvenile macaws. *J Assoc Avian Vet* 3(4):199-201, 1989.
30. **Taylor M:** Endoscopy. *Proc Assoc Avian Vet*, Phoenix, 1990, pp 319-323.
31. **Taylor M:** Endoscopy. *Laboratory Manual. Assoc Avian Vet*, 1992, pp 1-10.

**N**ecropsy examination of deceased patients should be an integral part of avian clinical medicine. Necropsy examination often is performed to determine the cause of an unexpected death. However, a thorough and systematic postmortem examination also may be used to confirm a clinical diagnosis, identify the etiology of a disease process, explain apparent unresponsiveness to treatment or reveal unrecognized disease processes. Integration of necropsy findings with clinical signs and laboratory data ultimately will enhance the clinician's understanding of disease processes and sharpen clinical diagnostic skills. In addition, necropsy will confirm radiographic interpretations and reinforce applied anatomy, which enhances surgical skills.

Necropsy examination is a relatively straightforward procedure that should follow a written protocol, thereby minimizing the possibility of overlooking important lesions. This chapter emphasizes the necropsy of psittacine and passerine birds; anatomic variations of other avian species such as ratites may be found by consulting appropriate chapters in this textbook and published articles in the veterinary literature.<sup>3</sup>

Maximum necropsy information can be obtained only by following a systematic approach and using ancillary support services as needed to establish a definitive diagnosis. Ancillary support services include histopathology, clinical pathology, microbiology, parasitology and toxicology.

---

CHAPTER

**14**

**NECROPSY  
EXAMINATION**

---

**Kenneth S. Latimer  
Pauline M. Rakich**

# NECROPSY RECORD

Date: \_\_\_\_\_ Postmortem interval: \_\_\_\_\_ Case number: \_\_\_\_\_

Owner: \_\_\_\_\_ Doctor: \_\_\_\_\_

Bird's name: \_\_\_\_\_ Identification: \_\_\_\_\_

Species: \_\_\_\_\_ Gender: \_\_\_\_\_ Age: \_\_\_\_\_ Weight: \_\_\_\_\_

Preservation of body: \_\_\_\_\_ Exposure to other birds: \_\_\_\_\_ Other bird deaths: \_\_\_\_\_

Clinical signs prior to death: \_\_\_\_\_

1. Body condition		18. Adrenal	
2. Oral cavity		19. Esophagus	
3. Integument		20. Crop	
4. Eyes		21. Proventriculus	
5. Ears		22. Intestine	
6. Nares		23. Cloaca	
7. Infraorbital sinus		24. Pancreas	
8. Air sacs		25. Genital	
9. Lungs		26. Subcutaneous	
10. Trachea		27. Musculoskeletal	
11. Pleura		28. Liver	
12. Peritoneum		29. Spleen	
13. Circulatory		30. Heart	
14. Kidney		31. Thymus	
15. Ureter		32. Bursa	
16. Thyroid		33. Bone marrow	
17. Pituitary		34. Nervous system	

Describe abnormalities \_\_\_\_\_

\_\_\_\_\_

\_\_\_\_\_

\_\_\_\_\_

\_\_\_\_\_

\_\_\_\_\_

\_\_\_\_\_

\_\_\_\_\_

\_\_\_\_\_

\_\_\_\_\_

\_\_\_\_\_

Disposal arrangements: \_\_\_\_\_

\_\_\_\_\_

*NGL = no gross lesions, ABN = abnormal, NE = not examined*

## ANCILLARY DIAGNOSTICS

	Laboratory name	Samples submitted	Shipment method
<input type="checkbox"/> Histopathology			
<input type="checkbox"/> Toxicology			
<input type="checkbox"/> Cytology			
<input type="checkbox"/> Parasitology			
<input type="checkbox"/> Microbiology			
<input type="checkbox"/> Virology			
<input type="checkbox"/> Other			



## Preparing for the Necropsy

Several excellent sources of information, in addition to this textbook, are available to help the clinician verify questionable anatomic structures, identify gross lesions and form a differential diagnosis.<sup>6,12,14-17,22</sup> The clinician should recognize certain limitations of the gross necropsy procedure. While recognition and interpretation of gross lesions may allow construction of a differential diagnosis as to the cause of death, few gross lesions are pathognomonic. Therefore, various ancillary services usually are required to determine the cause of death. Furthermore, communication of clinical, laboratory and necropsy findings to the pathologist will vastly improve interpretation of the tissues and histopathologic evaluation. A close working relationship with a veterinary pathologist who is interested in avian diseases is a definite asset. Lastly, the quality of the final diagnosis is directly proportional to the quality of the specimens submitted and the information provided with them.

### Medical Precautions

When performing avian necropsies, the health and well being of the veterinarian and staff members should be considered. Zoonotic diseases of special concern include chlamydiosis, mycobacteriosis, salmonellosis and campylobacteriosis.<sup>5,7,21,25,26,30</sup> Therefore, appropriate protective measures such as surgical masks, eye protection, gloves and disinfectants are recommended. Wetting the carcass with soapy water or disinfectant solutions decreases the possibility of aerosol exposure to potential pathogens and irritating feathers or dander.<sup>30,33</sup> Ventilation hoods or downdraft necropsy tables provide an ideal environment for pathogen containment during avian necropsies; however, such equipment is seldom available in a private practice setting.

### Equipment and Supplies

The equipment necessary to perform an avian necropsy will depend on body size, which may vary from a few grams for a Bumblebee Hummingbird to sev-

eral hundred kilograms for an ostrich.<sup>30</sup> In the case of a small hummingbird, a dissection tray or board, ophthalmic instruments and a magnifying loupe or dissecting microscope may be helpful. With large ratites, rib shears and a Stryker saw will be required.

The body size of most birds encountered in practice will range from a finch to a duck. An assortment of instruments including scissors, poultry shears, scalpels, rongeurs, thumb forceps and hemostats will aid in tissue incision, dissection and specimen procurement. Such instruments should be dedicated for necropsy use only and be thoroughly cleaned and disinfected (eg, glutaraldehyde, phenol, gas, steam) after each use to maintain good functional integrity and prevent carryover of pathogens that could adversely influence future necropsy results. Furthermore, instruments that are sterilized in chemical disinfectants should be rinsed thoroughly before use to avoid killing pathogens in tissues intended for culture.

Ancillary equipment may include sterile swabs<sup>a</sup> and sealable plastic bags<sup>b</sup> to obtain microbiologic and parasitologic specimens; sterile collection tubes for blood, serum or body cavity fluids; and glass slides, stains and a microscope to examine cytologic and blood smear specimens. A camera, macro lens system, flash unit and copy stand can provide photographic documentation of unusual lesions.

The routine fixative for collection of tissue specimens for histologic examination is neutral-buffered 10% formalin solution. Buffering is important to prevent artifacts in the tissues, which can interfere with microscopic examination. Some formalin solution recipes, such as Carson's fixative, provide excellent tissue preservation for both routine histopathology and electron microscopy (see Table 14.2).<sup>27</sup> For more detailed information on sample procurement, refer to the section entitled "Specimen Collection for Ancillary Testing."

Lastly, a printed necropsy form (Figure 14.1) should be available to record important observations. Indelible marking pens should be used to legibly identify all specimen containers concerning patient identification and origin of the specimen(s).

### Euthanasia

Euthanasia may be preferred to natural death to alleviate patient suffering. Acceptable methods of euthanasia include carbon dioxide or anesthetic gas

◀ **FIG 14.1** Use of a standard necropsy form (opposite) ensures that all organ systems are examined and important findings are documented.

administration, intravenous barbiturate administration (jugular vein or cerebral sinus) or anesthetic gas administration followed by exsanguination.<sup>29</sup> Of these various techniques, carbon dioxide administration is used least frequently because of excessive terminal motor activity. Anesthetic gas administration is beneficial because blood specimens may be obtained prior to death.

The clinician must realize that the method of euthanasia may have a bearing on gross and microscopic changes observed in necropsy tissues. For example, carbon dioxide-induced hypoxia may result in terminal involuntary motor activity with subsequent bruising, often noted at the base of the skull and misinterpreted as head trauma. Intravenous injection of caustic solutions may result in erythrolysis, edema and coagulative tissue changes, especially within the lungs.

### ■ Handling the Carcass Prior to Necropsy

Occasionally, a variable period of time will elapse between the point of death and performance of the necropsy. Examples include the unexpected death of a patient outside of regular clinic hours, delay in obtaining permission for necropsy from the owner or shipment of the carcass to a laboratory for necropsy examination. Unless precautions are taken to minimize autolysis, decomposition of the carcass will limit or preclude the benefits of histopathologic or gross examination of the carcass or various lesions, tissues and organ systems.

Rapid autolysis of avian carcasses is the result of a normally high body temperature (approximately 40°C in adults), body conservation of heat by insulating feathers, and use of incubators, heating pads or heating lamps to increase environmental temperatures of neonates and ill patients. Autolysis may be retarded by soaking the carcass thoroughly in cool soapy water, placing it in a thin plastic bag and storing the body under refrigeration before performing a necropsy or shipping the body to the diagnostic laboratory on ice. When shipping the carcass to a diagnostic laboratory, next-day courier service should be employed to minimize the delay of regular mail service.<sup>6</sup>

A carcass intended for necropsy *should not be frozen*. Placing a carcass directly on ice or dry ice during shipping also may result in freezing of the entire carcass or that portion in contact with the ice. Freezing induces artifactual changes, such as cell lysis and

destruction of tissue architecture, which occur as a result of formation and thawing of ice crystals, and may render the tissue nondiagnostic histologically.

## The Necropsy Examination

The necropsy examination should begin with a thorough review of the signalment, physical findings, medical history and pertinent laboratory data. An organized, standard necropsy technique is essential for a thorough necropsy examination without overlooking important lesions or organ systems. Because many more mistakes are made from lack of observation than lack of knowledge, a written necropsy protocol should be followed.

### ■ External Examination of the Carcass

Carcass identification should be verified by visual inspection based upon signalment (age, species and color) as well as leg band, tattoo or microchip implant data. Leg band numbers and other identifying marks should be recorded on the necropsy form. Palpation of the carcass may reveal fractures; swellings involving subcutaneous air sacs; masses of the skin, subcutis or underlying tissues; or physical deformities. An evaluation of general body condition also should be made, and body weight recorded. A prominent keel may indicate weight loss.

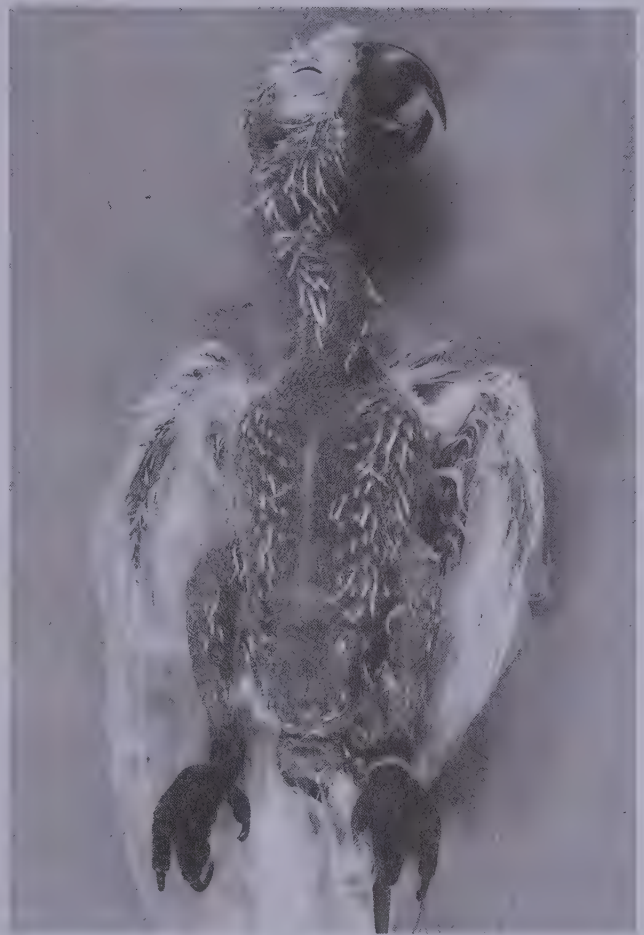The integument including skin, mucocutaneous junctions, plumage, beak and nails should be examined carefully. Avian skin is generally thin and transparent, in contrast to that of mammals (see Color 24). Accumulations of scales and crusts on legs, feet and cere may indicate bacterial, viral, fungal or parasitic infections. Scabs or swellings involving the skin or mucous membranes may indicate neoplasia, bacterial granulomas or viral-induced lesions (see Color 25). Loss, deformity or color alteration of feathers or fracture of blood feathers could be the result of viral, bacterial, fungal or parasitic infection, as well as trauma or nutritional disease.<sup>19</sup> In birds such as cockatoos and African Grey Parrots, the presence or absence of powder on the beak, legs, feet and nails will provide information concerning proper function of powderdown feathers. Mites should be identified microscopically if present.



**FIG 14.2** Following external examination of the carcass, the plumage has been dampened with soapy water to prevent aerosolization of feather debris and potential pathogens.

The beak and nails should be examined for deformities, fissures, fractures or delaminations. Beak pathology could result in difficult prehension of food and subsequent malnutrition. Nail pathology could result in lameness.

All body orifices (eyes, external auditory meatus, nares, oral cavity and vent) should be examined for discharges, masses, foreign bodies, ulcers and plaques. Ocular discharge may be seen with chlamydiosis; bacterial, viral and parasitic infections; or mycoplasmosis. Periocular scabs and masses and oral plaques may be seen in poxvirus infections. Oral plaques alone may be caused by bacterial, viral and parasitic infections as well as by burns, trauma and vitamin A deficiency (see Color 8). Palatine and glosal (tip of the tongue) necrosis may be observed in some birds with psittacine beak and feather disease. Soiling of the vent may indicate enteric disease or



**FIG 14.3** The feathers have been removed from the head, neck, ventral thorax and abdomen and legs; the bird is placed in dorsal recumbency.

cloacal dysfunction. Furthermore, yellow to green discoloration of urates may suggest hepatic or enteric disease (see Color 8). In Amazon parrots, cloacal masses may represent papillomas, which are frequently accompanied by cloacal prolapse. While the external auditory meatus should always be examined, aural pathology is rare, especially in parrots.

At this time, swabs of the choanal slit and vent may be taken for microbiological culture if desired. After cursory external inspection, the feathers may be wetted with soapy water to reduce feather dust and debris (Figure 14.2). The feathers subsequently may be removed to reveal subtle cutaneous pathology such as wounds or hemorrhages. Plucking feathers from the ventral cervical, thoracic and abdominal areas also facilitates further dissection and will avoid obscuring internal lesions (Figure 14.3).

## Necropsy Examination

### Color 14.1

The majority of the viscera have been removed from the carcass. The liver (l), spleen (s), proventriculus (p), ventriculus (v), duodenal loop (d) and pancreas (arrow) are visible.

### Color 14.2

A 25-year-old Scarlet Macaw was presented for egg retention of three days' duration. The egg was surgically removed. The patient became depressed, anorectic and began to regurgitate two weeks postsurgery. Radiographs indicated dilated bowel loops suggestive of an intestinal obstruction. Exploratory laparotomy indicated a fibrous constriction of the ileum. A side-by-side anastomosis was performed, but the bird died postsurgically. Shown are the pancreas (p), inflamed serosal surface of the duodenum (d) and mesenteric hemorrhage (arrow) of the anastomosis.

### Color 14.3

Gastrointestinal obstruction and peritonitis in a pheasant with proliferative typhlitis secondary to a *Heterakis isolonche* infection.

### Color 14.4

Glistening, transparent membranes typical of normal air sacs in an Umbrella Cockatoo; left caudal thoracic air sac (arrow) and left abdominal air sac (open arrow). The heart (h), proventriculus (p), ventriculus (v) and right liver lobe (l) can also be visualized. Note the position of the reflection of the caudal thoracic air sac from the surface of the liver lobe (see Figure 14.18).

### Color 14.5

The pancreas (p) lies between the descending (dd) and ascending (ad) loops of the

duodenum. In some species the pancreas is divided into three lobes: the dorsal lobe (arrow), the ventral lobe (open arrow) and the splenic lobe (see Figure 14.6), which can be identified only from a dorsal view.

### Color 14.6

Distended bile duct (open arrow) in an anorectic cockatoo. Some birds have gall bladders while others do not. In species that do not have gall bladders, bile may accumulate in the right bile duct and appear as though a gall bladder is present. From this dorsal view, the splenic head (arrow) of the pancreas and lateral edge of the liver (l) can also be identified.

### Color 14.7

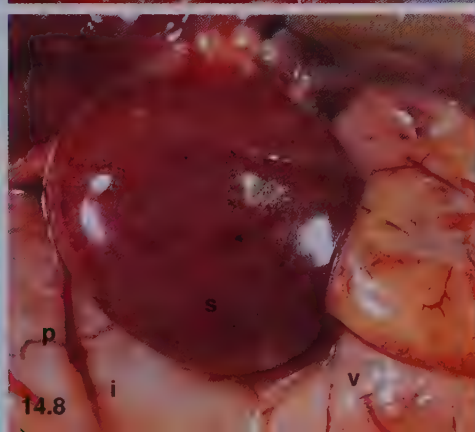
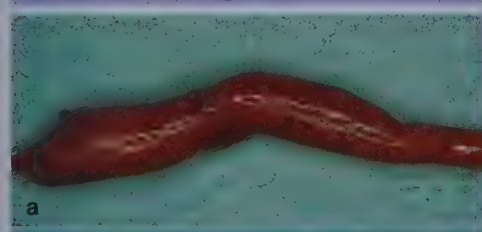
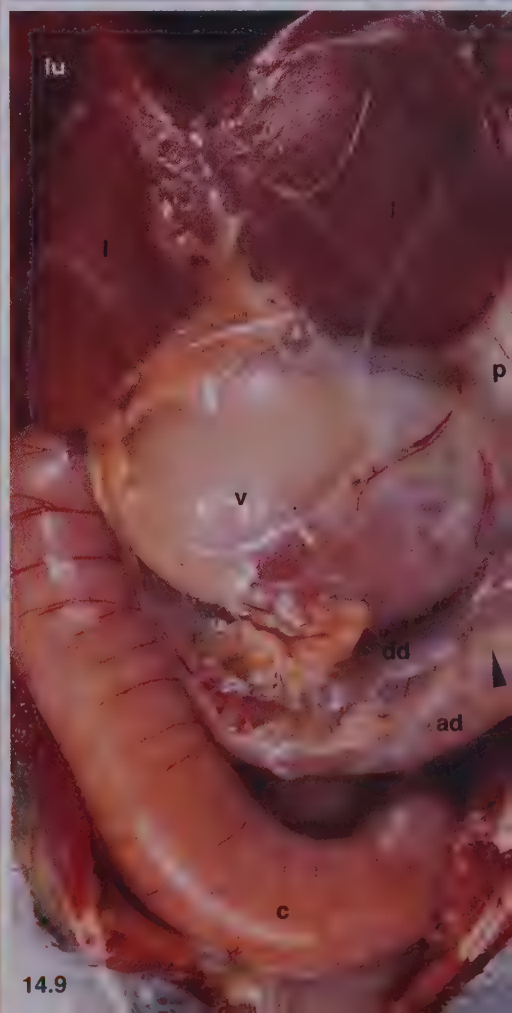
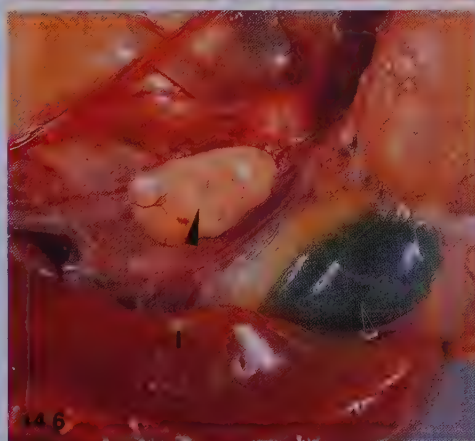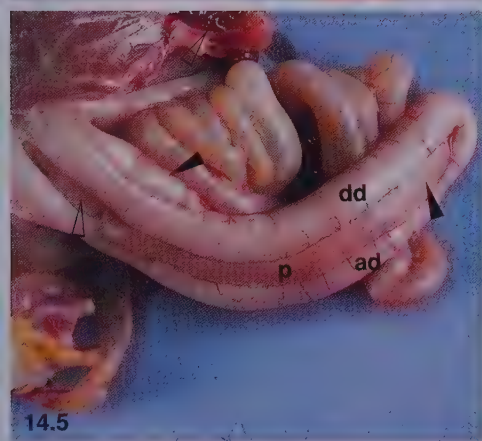
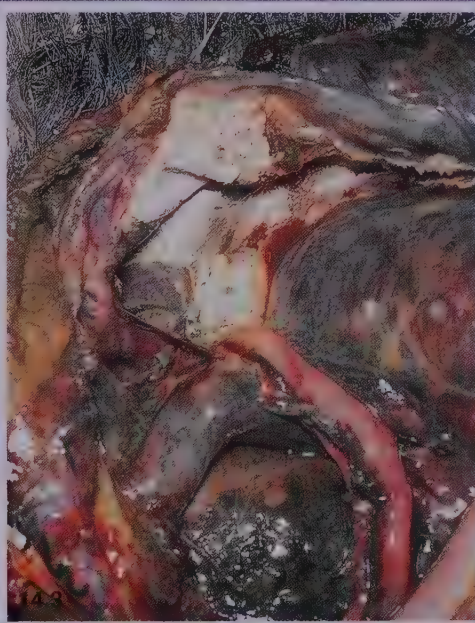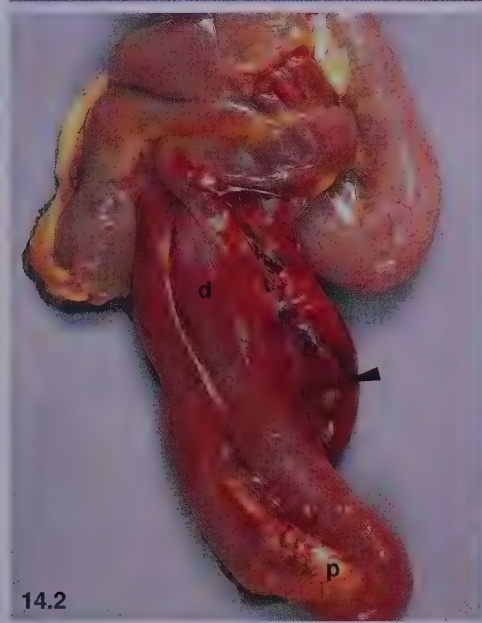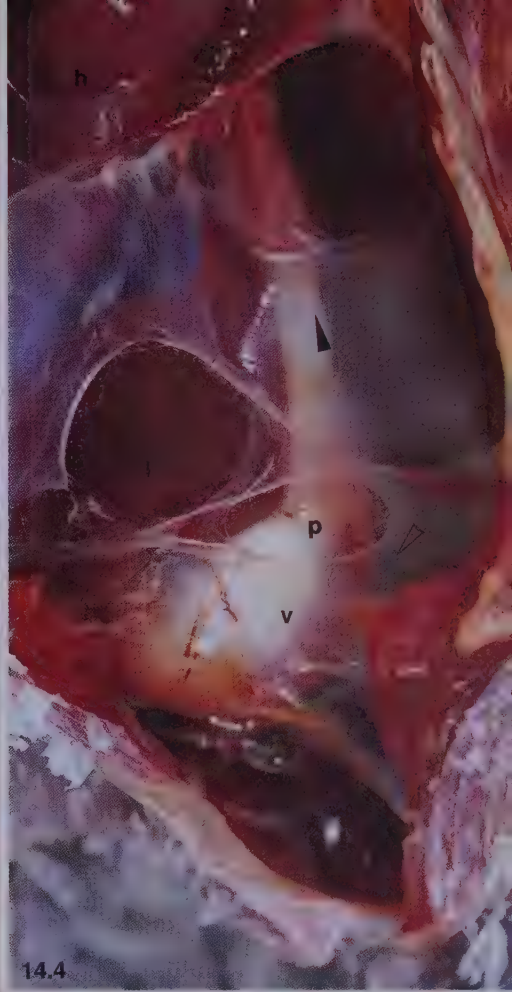
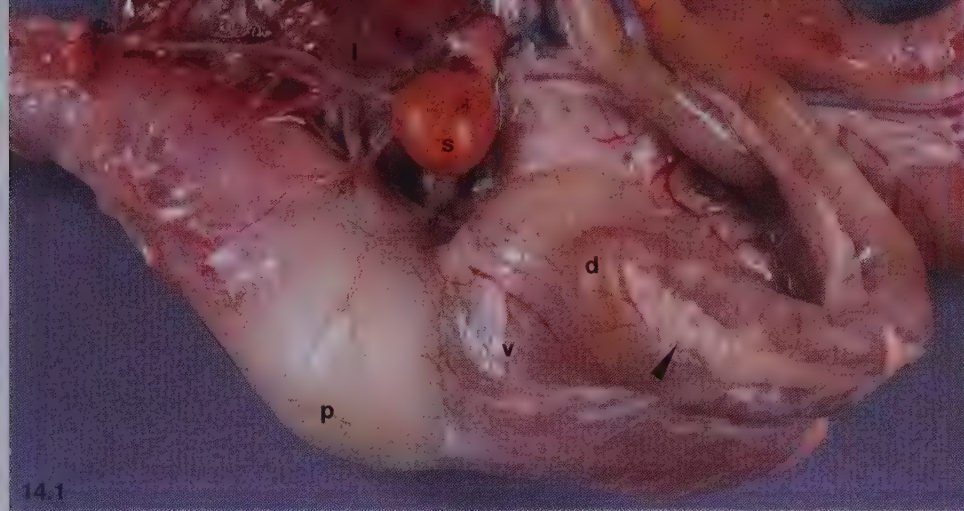
**a)** An enlarged, hemorrhagic spleen caused by *Pasteurella multocida* in a Common Black Bird (courtesy of R. Korbel). **b)** An enlarged spleen with multifocal granulomas caused by *Yersinia tuberculosis* in a toucan (courtesy of R. Korbel).

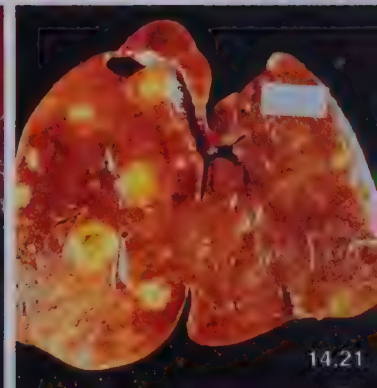
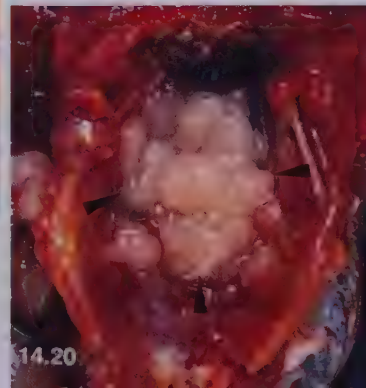
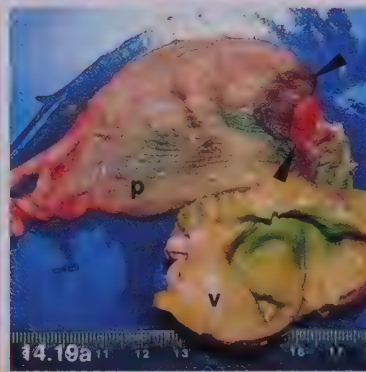
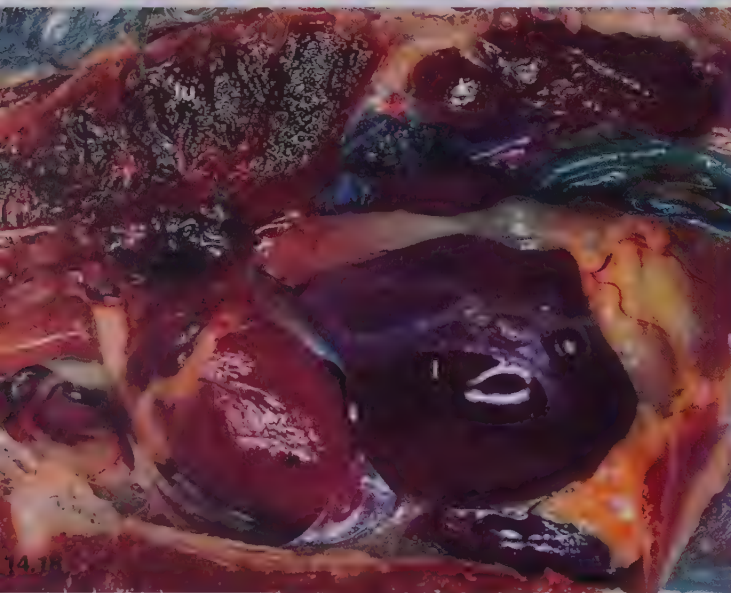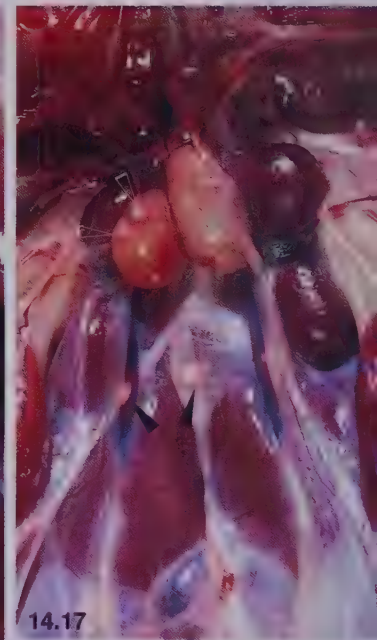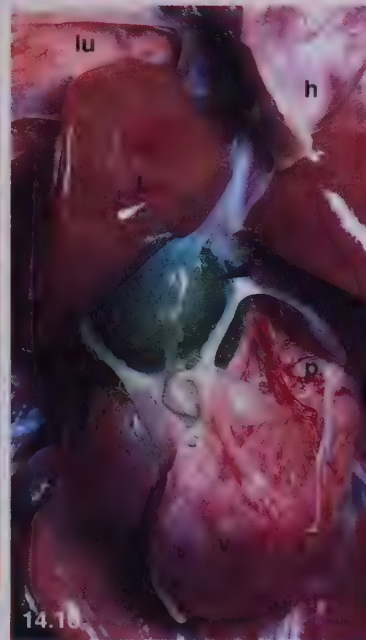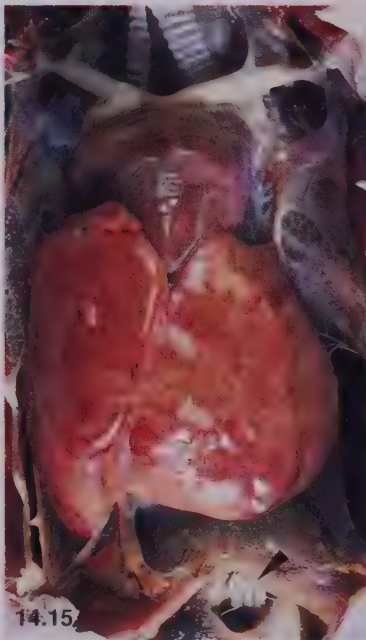
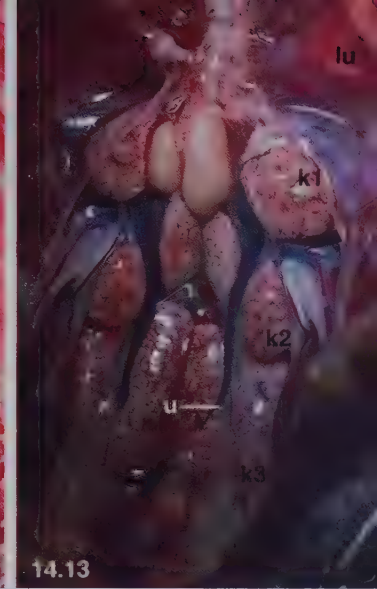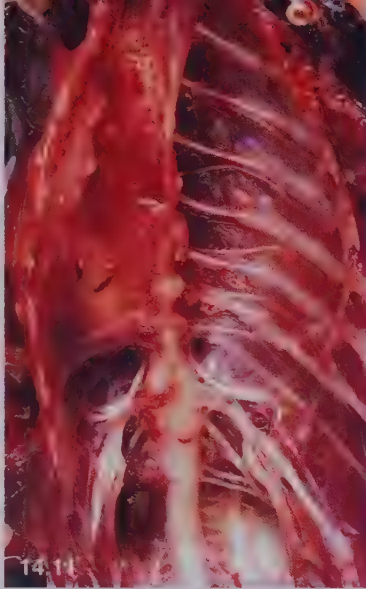
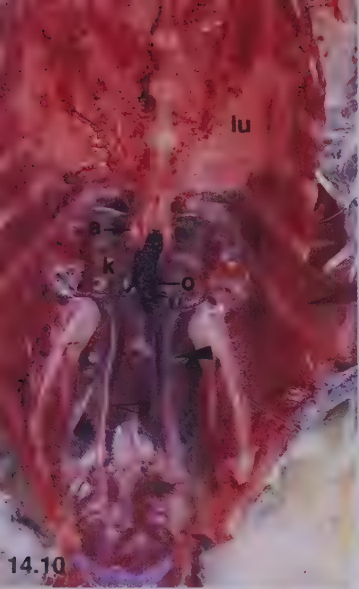### Color 14.8

Splénomegaly is a common finding in many bacterial and viral infections. In this case, the enlarged mottled spleen (s) was from a neonatal Blue and Gold Macaw that died from avian polyomavirus. Proventriculus (p), isthmus (i) and ventriculus (v).

### Color 14.9

The thoracoabdominal viscera can be visualized by removing the sternum. The right lung (lu), both liver lobes (l), proventriculus (p), ventriculus (v), descending duodenum (dd), ascending duodenum (ad), pancreas (arrow) and colon (c) can be visualized from this view. Note the thin hepatic peritoneal membrane attached to the lobes of the liver.





## Necropsy Examination

### Color 14.10

The lungs (lu), kidneys (k), ovary (o) and adrenal glands (a) remain in the carcass following removal of the majority of the viscera. Normal lungs appear deep pink and kidneys appear red-brown. Note the inactive oviduct (arrow) and ureter (open arrow). In health, the kidneys appear dark red-brown and are embedded within the renal fossae. The adrenal glands are small, round, yellow structures at the cranial divisions of the kidneys. The quiescent ovary of this bird is granular and pigmented (melanin pigment) (courtesy of Ken Latimer).

### Color 14.11

The left lung has been removed to demonstrate its normal anatomic position in the dorsal thoracic cavity. The lung is attached to the dorsal body wall and interdigitates with the spinal processes and ribs.

### Color 14.12

Trauma-induced spinal cord hemorrhage (arrow) in a cockatoo. The ventral vertebral structures have been removed for visualization.

### Color 14.13

Pale kidneys in an anemic male Amazon parrot. Cranial division of left kidney (k1), middle division of left kidney (k2), caudal division of left kidney (k3), lung (lu), common iliac vein (arrow), caudal renal vein (open arrow) and ureters (u).

### Color 14.14

Hepatic rupture and hemorrhage (h) in a six-month-old emu with *Clostridium shovii*. Infected birds frequently die of exsanguination secondary to the tears in the liver (l) (courtesy of Brett Hopkins).

### Color 14.15

A Barn Owl was presented with severe depression and weight loss. A palpable mass was present in the lower abdominal cavity. Abdominocentesis indicated the presence of a septic exudate containing numerous gram-negative bacteria. At necropsy, a perforating lesion was noted in the proventriculus (arrow), and the liver was enlarged, pale and mottled. Histopathology indicated a gram-negative septicemia with hepatitis and peritonitis.

### Color 14.16

Cystic dilatation of the right bile duct (arrow) in an anorectic Amazon parrot. The accumulation of bile was detected radiographically as a fluid-filled mass slightly

dorsal to the hepatic shadow. Lung (lu), heart with thickened, opaque pericardium (h), liver (l), proventriculus (p) and ventriculus (v).

### Color 14.17

Congested, swollen kidneys in a male Scarlet Macaw with aspergillosis. Note the plaques (open arrows) on the right testicle. Note the plaques (arrows) and thickening of the dorsal wall of the intestinal peritoneal cavity.

### Color 14.18

A mature Rose-breasted Cockatoo was presented with an acute onset of depression, dyspnea and syncope. The bird did not respond to supportive care. Necropsy findings included dark, congested lungs (lu), an enlarged, congested liver (l) (note the line of reflection of the lateral wall of the caudal thoracic air sac from the liver's surface, see Color 14.4), enlarged, congested kidneys (k) and an enlarged heart (h) with petechiation. Histopathology indicated *Sarcocystis* sp. The bird was housed indoors but the food was kept in an open container and was contaminated with roach feces.

### Color 14.19

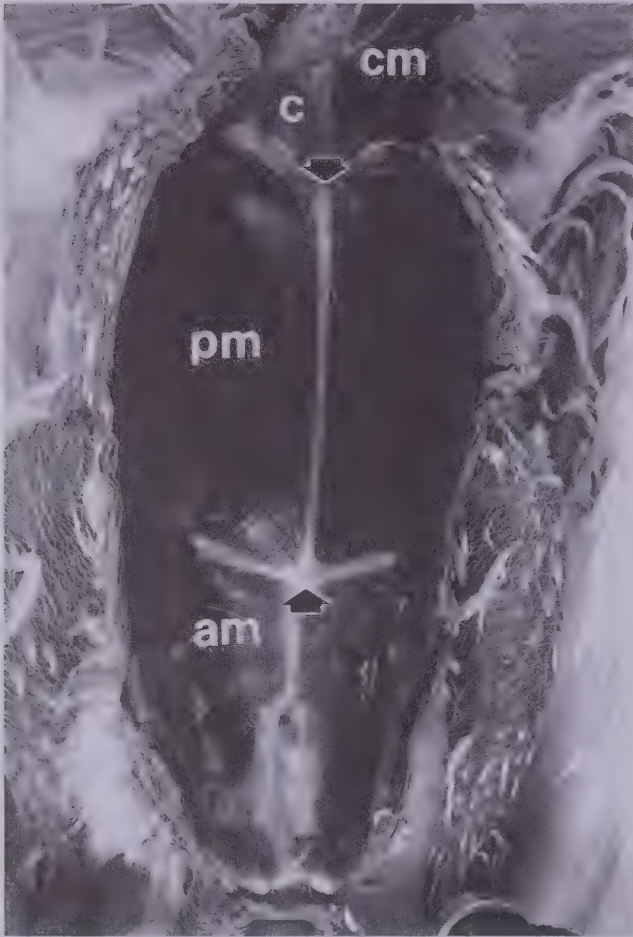
**a)** Proventriculus (p) and ventriculus (v) from a one-month-old ostrich. Note the hemorrhage and ulceration (arrows) at the isthmus, which is common in birds with *Clostridium perfringens* infections. This bacteria secretes an exotoxin that causes generalized vasculitis and is associated with atony of the proventriculus. **b)** Similar *C. perfringens*-induced lesions in the proventriculus of a 23-month-old ostrich (courtesy of Brett Hopkins).

### Color 14.20

A mature cockatiel hen was presented with depression and severe abdominal distention. The bird did not respond to supportive care. At necropsy, multiple masses were identified in association with the pancreas and dorsal body wall. Histopathology indicated a pancreatic adenocarcinoma with carcinomatosis (arrows) of the abdominal cavity (courtesy of Cheryl Greenacre).

### Color 14.21

Diffuse amyloidosis in the liver of an American Merganser. Focal granulomatous lesions characteristic of *Mycobacterium* sp. are also noted. Amyloidosis commonly occurs in waterfowl with chronic inflammatory diseases (courtesy of R. J. Montali).

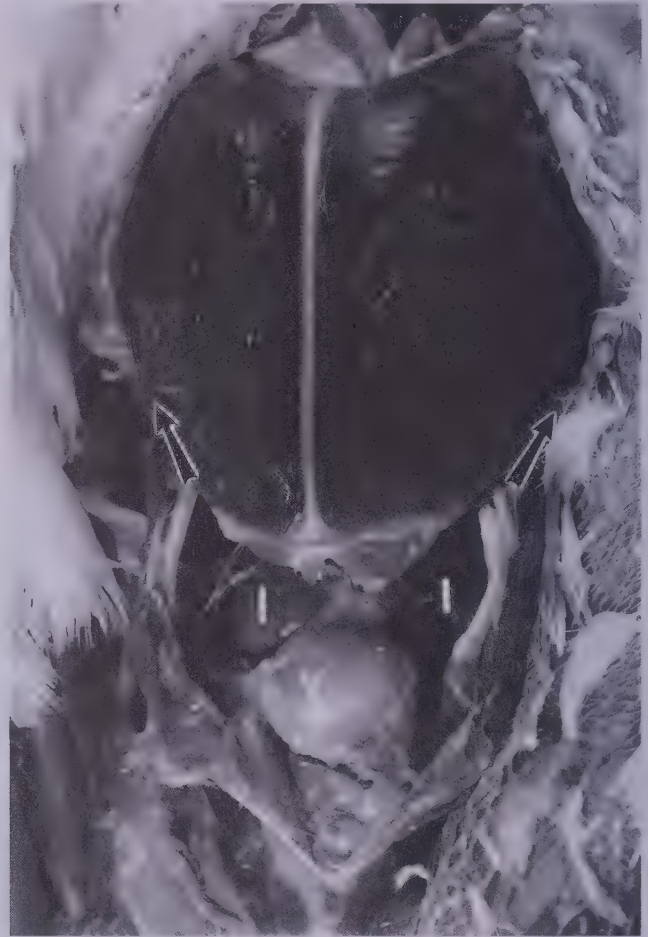


**FIG 14.4** The skin has been incised and reflected. The proximal cervical musculature (cm), crop (c), pectoral musculature (pm) and abdominal musculature (am) have been exposed. The keel of the sternum identifies the ventral midline (arrows).

When external examination of the carcass is complete, survey radiographs may be taken if heavy metal toxicosis is suspected. These radiographs may assist the clinician in localizing metal densities that may be collected for analysis during the necropsy.

### Initial Dissection

The bird is placed in dorsal recumbency for initial dissection (Figure 14.3). With very small birds, the wings and legs may be pinned to a dissecting tray or board to immobilize the carcass. With larger birds such as ducks or geese, the coxofemoral joints may be disarticulated by incising the skin, adductor muscles of the medial thigh and coxofemoral joint capsule. The knees are then forced craniolateral. Using a scalpel and scissors, a ventral midline incision is made from the intermandibular area to the pelvic

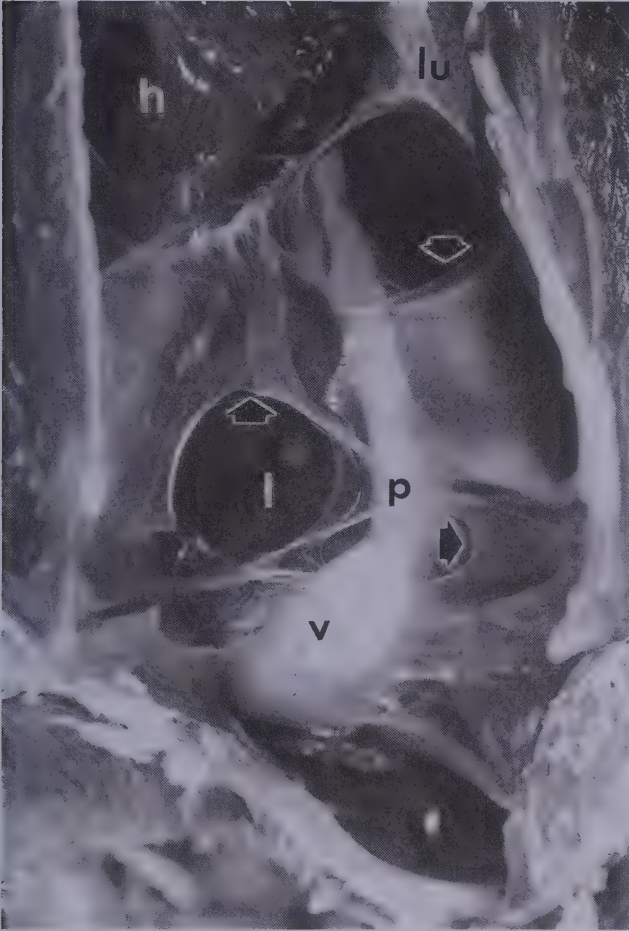


**FIG 14.5** An incision has been made through the abdominal musculature and continued around the left and right margins of the sternal plate (arrows). The posterior portions of the left and right hepatic lobes (l) and ventriculus (v) are observed.

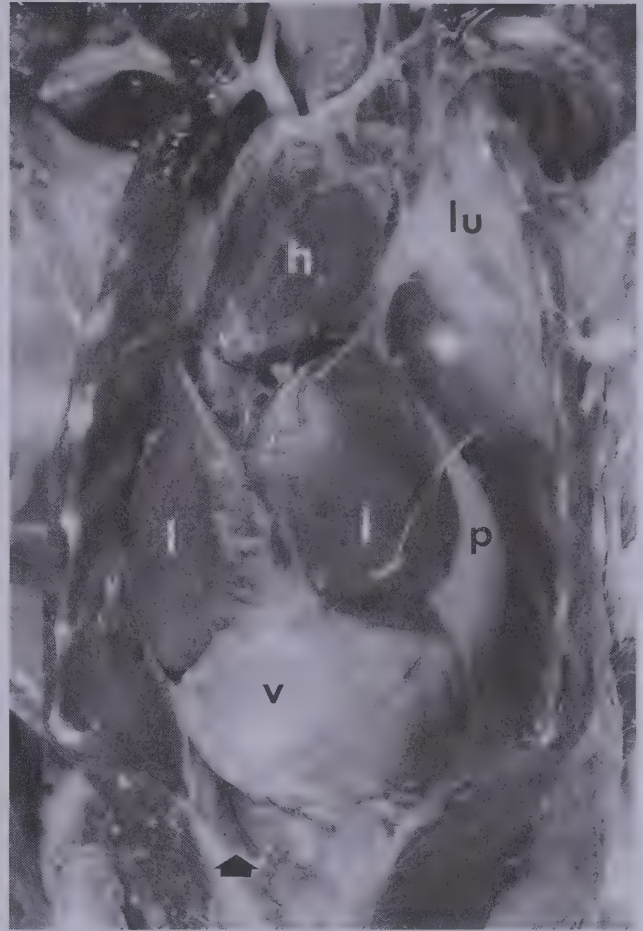
area, encircling the vent. The skin is reflected by blunt dissection to reveal the underlying cervical musculature, trachea, crop, keel and pectoral and abdominal musculature (Figure 14.4).

Normal pectoral musculature of most companion birds is plump and appears red-brown. The musculature should be examined for hemorrhage, penetrating wounds, pallor, pale streaking or loss of total mass. Pallor or pale streaking may represent muscle necrosis, inflammation or neoplasia. Pale streaking of the pectoral musculature may be observed in feral birds with sarcocystosis. Muscle wasting is often a sign of inanition.





**FIG 14.6** Normal air sacs (arrows) appear as glistening, transparent membranes that can be visualized as the sternal plate is lifted. Portions of the heart (h), lung (lu), liver (l), proventriculus (p) and ventriculus (v) also are visualized.



**FIG 14.7** The sternal plate and a portion of the abdominal musculature have been removed to expose the thoracoabdominal viscera for gross examination. The heart (h), lung (lu), right and left hepatic lobes (l), proventriculus (p) and ventriculus (v) are identified. A small segment of the duodenum also is observed (arrow).

### ■ Exposure of the Thoracoabdominal Cavity

An incision is made through the abdominal musculature at the distal tip of the sternum. The incision is continued left and right through the pectoral musculature lateral to the sternum (Figure 14.5), which can be lifted craniodorsal to expose the thoracic and abdominal air sacs (Figure 14.6). Normal air sacs appear as glistening transparent membranes (Color 14.4). If air sacs appear opaque or contain accumulations of fluid or exudate, appropriate specimens should be obtained for microbiological culture or cytology before the field is contaminated (see Color 22). Air sac tissues collected for histopathology should be placed on a small piece of paper before fixation. This will facilitate identification of the tissue for processing and minimize the possibility that these transparent membranes will be discarded inadvertently.

The sternal plate is removed by continuing to incise the thoracic musculature and transecting the ribs, coracoid bones and clavicles using scissors, rongeurs or poultry shears (large pruning shears may be necessary for ratites). The midline incision is extended caudad through the abdominal musculature proximal to the vent; care should be taken to prevent incising the cloaca. The pectoral musculature of the sternal plate may be incised and examined; any abnormal tissue is collected for cytologic imprints and histopathologic evaluation. Abdominal wall musculature is then removed as necessary to expose the viscera within the body cavity (Figure 14.7).


### Examination of Thoracoabdominal Viscera *In Situ*

Several gross observations should be made before the viscera are disturbed. The presence of fluid, exudates or fibrin tags within the thoracoabdominal cavity should be noted (minimal fluid is present in health). Air sac remnants can be examined further for opacity related to bacterial, chlamydial or fungal infection. Aspergillosis is observed commonly in the abdominal air sacs and appears as a velvet-like yellow to green mat (see Color 22). A small amount of fat may be observed normally in the abdomen, around the cloaca and within the coronary groove. Excessive fat may be present in obese companion birds, while serous (gelatinous) atrophy of fat may occur with inanition. The pericardial sac should be relatively transparent and contain little measurable fluid (Color 14.25). A white chalky discoloration may indicate visceral gout from urate deposition (see Color 21). White streaks occasionally are present on the pericardial sac and epicardium following euthanasia by intracardiac injection. Petechial epicardial hemorrhages may represent septicemia or be observed as an agonal event (Color 14.26).

The liver is mahogany brown and bilobed, extending around the left and right margins of the heart. In psittacine birds, the right lobe is larger, occasionally giving an asymmetric appearance (Color 14.9). A swollen, pale-yellow liver may be observed in severe hepatic lipidosis or may represent a normal finding in neonates that are mobilizing egg yolk (see Color 30). Diffuse yellow-orange discoloration of the liver may be observed in severe hemosiderosis, which occurs with some frequency in mynah birds. Multifocal white-to-yellow discoloration of the hepatic parenchyma suggests necrosis secondary to chlamydial, bacterial or viral infection (see Color 20). Large umbilicated lesions in the liver, especially in peafowl, are strongly suggestive of histomoniasis. Pallor of the hepatic parenchyma may be observed in severely anemic birds. The gallbladder should be examined if present (some birds lack a gallbladder), and the patency of the common bile duct should be determined if possible (Color 14.16).

The heart and great vessels are examined next. The epicardium should be examined for petechiation. The heart is roughly triangular with the length slightly exceeding the width. Any alteration in the size or shape (eg, globose shape) of the heart should be noted.

As the great vessels are examined, any changes in the size of the thyroid and parathyroid glands also



**FIG 14.8** The syringeal area is a common location for pathologic lesions of the respiratory tract. This area should be carefully examined and the trachea (t) and synx (s) should be opened under sterile conditions to collect samples for bacterial, fungal or viral isolation in birds with respiratory sounds. Note the reduction in size of the primary bronchi as they leave the synx (arrows). The thoracic esophagus (e) is dorsolateral to the trachea at the level of the synx and then courses from right to left to connect to the proventriculus. (vs) = ventral syringeal and (dt) = dorsal tracheo-bronchial muscles.

should be recorded. These glandular structures are located at the thoracic inlet lateral to the synx and adjacent to the jugular veins and carotid arteries. Normal thyroid glands are small, oval and reddish-brown (Color 14.22). The parathyroid glands are very small and best distinguished microscopically. In dietary-induced secondary hyperparathyroidism, the parathyroid glands will appear as enlarged circular off-white to yellow structures (Color 14.29).

A small portion of the ventriculus may be observed ventral to the liver. Much of the caudal portion of this organ is obscured by the duodenal loop and pancreas. The proventriculus is located beneath the left liver lobe and may not always be visible unless severely dilated (Color 14.9).<sup>4</sup>

Disease-induced alterations in gastrointestinal morphology usually are quite subtle grossly and may be limited to congestion, hemorrhage or gas-filled intestinal loops (this latter change also is observed commonly following a long postmortem interval). Gas-filled intestinal loops and discoloration due to altered intestinal contents or hemorrhage should be noted. On rare occasions, gastrointestinal lesions may be quite striking. Examples include gastrointestinal tract obstruction and impaction in pheasants with proliferative typhlitis secondary to *Heterakis isolonche* infestation, severe nematode or trematode infestations, surgically-induced visceral adhesions, marked proventricular distention in birds with neuropathic gastric dilatation and severe egg-related peritonitis (Color 14.2, 14.3).

In hens, the viscera are reflected on the left side of the dorsal thoracoabdominal cavity to examine the communication of the colon and oviduct with the cloaca. The cloacal bursa may be partially visualized, especially in juvenile birds.

### ■ Removal and Examination of the Viscera

The heart is removed by transecting the great vessels. At this time the thyroid and parathyroid glands also may be collected while they are easily identified.

The epicardial surface should be examined for changes in size, shape and color. The heart of small birds may be transected near the apex and placed whole in formalin solution. In larger birds, the heart may be opened to inspect the valves and chambers; sections of tissue may be taken for formalin fixation.

The tongue and oral mucosa should be inspected for erosions, ulcers, plaques or masses. The tongue is freed by transecting the hyoid apparatus and pharyngeal tissues in the intermandibular region. Gentle traction is applied to remove the tongue, esophagus, crop, trachea and thymus with attached large vessels. The thymus may appear as pale tan to gray lobules of tissue extending along the cervical fascial planes adjacent to the trachea. This organ undergoes involution as sexual maturity is reached. The distal trachea is transected below the syrinx, leaving the lungs for later dissection (Figure 14.8). The esophagus is transected just below the syrinx and lifted upward. The ligamentous attachments, air sacs, blood vessels and ureters (including the oviduct if present) are transected and the vent area is excised with an intact margin of skin. The entire gastrointestinal tract, along with the liver and spleen, is re-

moved from the carcass. The adrenal glands, gonads and kidneys remain in the carcass.

The spleen may be found dorsally in the angle between the ventriculus and proventriculus (Color 14.8). It appears as a variably-sized, round to elongate, red-brown structure. It should be removed and examined. Swelling and tan discoloration suggest inflammation or infection (viral, bacterial, chlamydial or protozoal such as atoxoplasmosis). Cytologic imprints may be made and a small portion removed for microbiological culture; the remainder is fixed in formalin solution.

The liver, gallbladder (if present) and patency of the bile duct connections to the duodenum should be examined. Excess accumulation of bile may cause gross distention of the bile ducts. The liver is removed, and its color, size and texture are examined in more detail. The parenchyma is examined by making several transverse slices through the organ with a sharp knife or scalpel. Lesions are imprinted and appropriate specimens are fixed for histopathologic examination, and fresh tissue is retained for other ancillary tests (microbiologic culture or toxicologic analysis) as necessary.

Lobules of thymic tissue, if present, are preserved for histopathologic examination. The esophagus, crop and trachea should be opened and the luminal surfaces and contents examined. Any abnormalities such as hemorrhage, erosion or ulceration and plaques or masses should be noted and appropriate portions of tissue imprinted, preserved in formalin solution and retained for other analyses (see Color 22). The crop contents should be examined carefully, especially in cases of unexplained death where poisonous plants may have been ingested. Crop contents may be collected for analysis if toxicosis is suspected.

The proventriculus and ventriculus are opened and examined for surface erosions or ulcers and foreign bodies. The morphology of the ventriculus varies

### CLINICAL APPLICATIONS

- Maximum necropsy information can be obtained only by following a systematic approach and using ancillary support services as needed to establish a definitive diagnosis.
- The final diagnosis is directly proportional to the quality of the specimens submitted and the information provided with them.
- A telephone call or fax to the diagnostic laboratory prior to performing the necropsy is a prudent measure to ensure correct specimen collection, preparation and handling.

with the species of bird and its diet. The ventriculus of seed-eating and omnivorous birds has a thick muscular wall, and the mucosa has a koilin lining (thick horny material) that is often bile-stained. In carnivorous and piscivorous birds, the ventriculus may be fusiform, thinner-walled and blend with the proventriculus.<sup>14</sup>

The intestine may be opened in large birds and inspected for luminal hemorrhage, erosions, ulcerations or parasites. Direct visualization of parasites is noted and intact organisms may be preserved in appropriate fixatives for later identification (see Table 14.4). Wet mounts of intestinal contents and mucosal scrapings should be examined microscopically to identify protozoa (giardiasis, cryptosporidiosis), parasite ova or merozoites (coccidiosis). In large birds, various portions of the intestinal tract may be excised and preserved for histopathologic examination. In tiny birds, the intestine may be fixed *in toto* without gross examination, but it should be cut into multiple sections to allow adequate penetration of the formalin fixative. Portions of intestine also may be retained in a sealable plastic bag for microbiologic culture.

The terminal colon and cloaca should be examined externally and internally. Patency of the colon, ureters and oviduct, if present, should be determined. In some species of birds, such as pheasants and peafowl, the ceca should be examined for the presence of inspissated exudates, masses, parasites or other lesions.

The bursa of Fabricius generally may be found associated with the dorsal wall of the cloaca. Grossly, this organ may resemble a large lymph node in young birds (see Figure 5.6). In older individuals, the bursa may have involuted and will be difficult to identify. Histopathologic examination of formalin-fixed cloacal tissue may allow identification of bursal remnants following involution.

In juvenile hens, the reproductive tract will be minimally developed. The ovary will be small and have a slightly granular appearance (see Colors 13, 29). Adult hens that are sexually quiescent or severely stressed may experience atrophy of the reproductive tract, resembling a juvenile hen. In sexually active hens, the oviduct is a prominent, large, off-white, flaccid, vascular, hollow tubular organ with a rugose luminal surface.<sup>17</sup> Egg binding may induce inflammation wherein the distal wall of the oviduct will appear thickened. The oviduct also may be the origin of adenocarcinoma, especially in budgerigars. Hens

that have undergone stress may have the uterus and ovaries reduced in size to that of juveniles due to alterations in hormonal secretions.

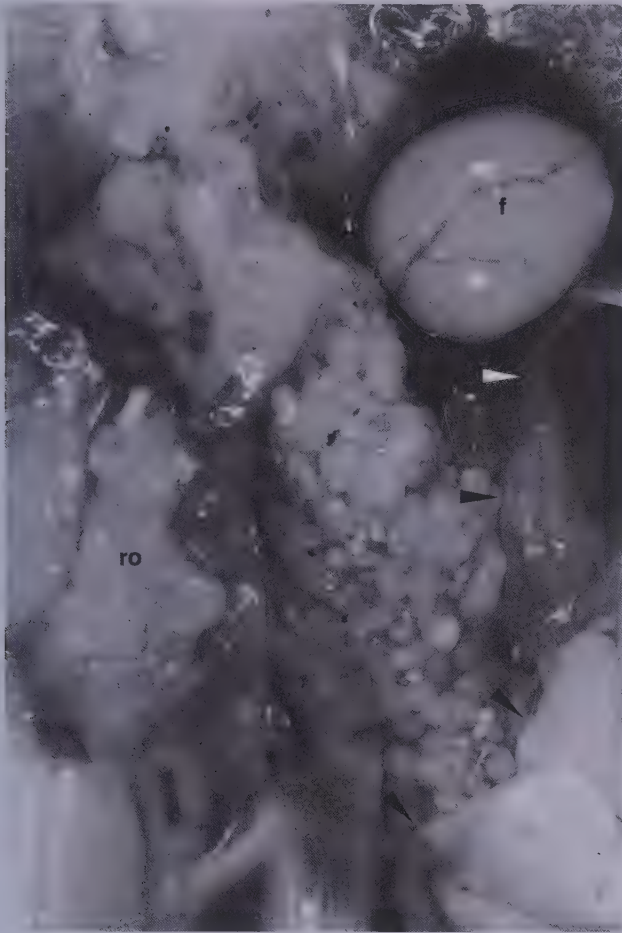
Removal of the majority of the viscera permits inspection of the lungs *in situ*. Normal lungs are deep pink. The lungs should be examined for areas of discoloration or other abnormalities. A dark red, wet appearance of the lungs suggests pulmonary edema and hemorrhage, which may accompany acute pulmonary sarcocystosis, polytetrafluoroethylene (Teflon®) toxicosis, inhalation of noxious gases, carbon monoxide asphyxiation or necrotizing bacterial pneumonia (see Color 22). Fungal pneumonia may present as cavitating nodules, the walls of which have a velvety green lining.

Because avian lungs are attached to the dorsal ribcage, removal requires gentle traction along with blunt and sharp dissection (see Chapter 22). The lung parenchyma should be transected at 0.5 cm intervals (as with the liver) to look for occult lesions such as bronchial exudates, particulate debris and areas of consolidation or cavitation. In small birds, use of a magnifying loupe may facilitate identification of particulate debris in aspiration pneumonia.

Next, the kidneys, gonads and adrenal glands are inspected *in situ* (Color 14.10). These organs are removed as a single unit by careful dissection, especially in regard to removing the kidneys from the renal fossae of the synsacrum (pelvis). The sacral plexus is embedded within the kidney, which makes removal of the kidneys difficult. Normal kidney tissue is dark red-brown. The renal parenchyma is examined for discoloration, pallor, swelling or masses or linear white foci that may indicate renal gout. Removal of the kidneys may be impossible in some small birds; however, this portion of the synsacrum may be removed from the carcass and fixed *in toto*. The tissue subsequently may be decalcified, processed, embedded in paraffin and sectioned *en bloc*.

The testes of male birds are elongate to cylindrical organs near the anterior portion of the kidneys (Color 14.13).<sup>15</sup> Juvenile testes are yellow due to interstitial cell lipid.<sup>17</sup> These organs undergo cyclic atrophy and enlargement in sexually mature individuals and may be quite large in breeding birds.<sup>14</sup> The testes of adult male birds appear large and are commonly white with a vascular surface. Some species of male birds have melanistic testicles.

Only the left ovary normally persists in psittacine hens (Figure 14.9). In some species, such as raptors,



**FIG 14.9** In a normal psittacine hen, only the left ovary and oviduct are present. Occasionally, the right ovary (ro) and oviduct will also be present. Note the large follicle (f) and enlarged left oviduct (arrows) indicative of a reproductively active hen.

the ovaries are frequently bilateral. The juvenile left ovary appears yellow and granular, resembling a piece of fat.<sup>15</sup> Variably-sized, vascular, yellow follicles are present in sexually active hens (see Color 13, 29). The yellow color is imparted by variable quantities of yolk.<sup>17</sup> In some species of female birds, the ovary may be pigmented.

The adrenal glands are identified as small, round, yellow structures to the left and right of the midline at the cranial pole of the kidneys. Adrenal gland enlargement may be observed in chronically stressed birds.

The remainder of the carcass consists of the musculoskeletal, integumentary and nervous systems. Specimens of skin, feather follicles and feathers may be taken for histopathology if they have not already been obtained. Abnormal, newly emerging feathers

and associated follicles provide the best diagnostic specimens. Sections of the uropygial gland may be taken from appropriate species if masses are palpated or observed.

### Examination of Special Organs and Tissues

Examination of the nervous system and associated tissues is governed by the presence or absence of neurologic or ocular disease. Although the brain and ischiatic (sciatic) nerves are routinely obtained for histologic evaluation, the spinal cord, brachial and sacral nerve plexuses and eyes are obtained only if pathology is present.

#### Brain

The brain is relatively accessible and is frequently obtained for routine histopathologic examination (Figure 14.10). The brain may be removed by plucking the feathers from the head, incising the scalp and reflecting it. A sagittal incision is made through the calvarium using a pair of blunt-sharp scissors. Using a forceps or rongeurs, the bony calvarium is removed as necessary to expose the brain.

Before removing the brain from the calvarium, it should be inspected for congestion or hemorrhage. Depending upon the rapidity of death or method of euthanasia, agonal hemorrhage may be observed in birds following severe terminal motor activity. Agonal hemorrhage must be distinguished from ante-mortem head trauma if possible.<sup>6,14</sup> Greenish bruising is more typical of old hemorrhage. The brain may be removed from the calvarium by severing the cranial nerves from rostral to caudal (Figure 14.11). The optic tectum (a bony plate that covers the large optic lobes) may present a problem in removing the brain from psittacine birds. In hatchlings, the calvarium is soft and may be transected through the midline with a scalpel. The halves of the calvarium may be fixed *in toto* or one-half of the calvarium may be retained for culture.

#### Vertebral Column

If neurologic disease involves spinal cord or nerve roots, appropriate sections of the vertebral column or synsacrum may be identified, removed *en bloc* and fixed in formalin solution.<sup>6</sup> The pathologist subsequently can decalcify these tissues and section them with a knife or scalpel to discern subtle gross lesions. These tissue sections can be processed and examined microscopically to evaluate nervous tissue, bone and attached soft tissues.

## ■ Necropsy Examination

### Color 14.22

Normal thyroid glands (arrows) appear as small, oval, red-brown structures adjacent to the carotid arteries. The parathyroid glands are present at the caudal pole of the thyroid gland but are normally minuscule.

### Color 14.23

A greater than 20-year-old Rosella was presented with a history of feather dystrophy and exercise intolerance. The bird was DNA probe-positive for PBFV virus. The bird died shortly after presentation, and at necropsy the great vessels were noted to be hard, irregularly shaped and yellow. The vessels were partially calcified and the histologic diagnosis was atherosclerosis.

### Color 14.24

Normal heart (h), liver (l) and lungs (lu) demonstrating the relationship of these organs in the cranial portion of the thoracic cavity. Note the pericardial sac (arrow) and the left and right hepatic peritoneal membranes (open arrows). The ostium (o) of the caudal thoracic air sac is also clearly visible through the transparent, contiguous wall of the cranial thoracic and caudal thoracic air sacs.

### Color 14.25

A mature Moluccan Cockatoo was presented for an acute onset of lethargy, dyspnea and weakness. The PCV was 12, and a large quantity of blood was noted in the right axillary and neck region. The bird was given a blood transfusion but did not survive. Necropsy indicated a pale heart and liver, and a ruptured brachial artery. The pale heart is shown resting in an increased quantity of clear pericardial fluid.

### Color 14.26

A male duck from a zoological collection was found dead in its enclosure. Necropsy findings indicated multifocal, petechial hemorrhage in the epicardium. *Pseudomonas* sp. was isolated from the heart blood. Multifocal, myocardial, petechial hemorrhage can be an indication of septicemia or can represent agonal hemorrhage. Note the syringeal bulla (arrows) that is an extension of the trachea found in some male ducks.

### Color 14.27

Pericardial effusion (arrow) can occur from several bacterial or viral diseases. In this case, hydropericardium was associated with avian viral serositis in a Blue and Gold Macaw neonate.

### Color 14.28

A wild-caught Ducorps' Cockatoo was presented with abnormal feather development. DNA probe testing of a blood sample confirmed the clinical diagnosis of PBFV. During routine necropsy, filariid worms (arrows) were removed from the right ventricle. The parasites were identified as a new species of filariid worms, *Chandlerella* sp. (courtesy of Ken Latimer).

### Color 14.29

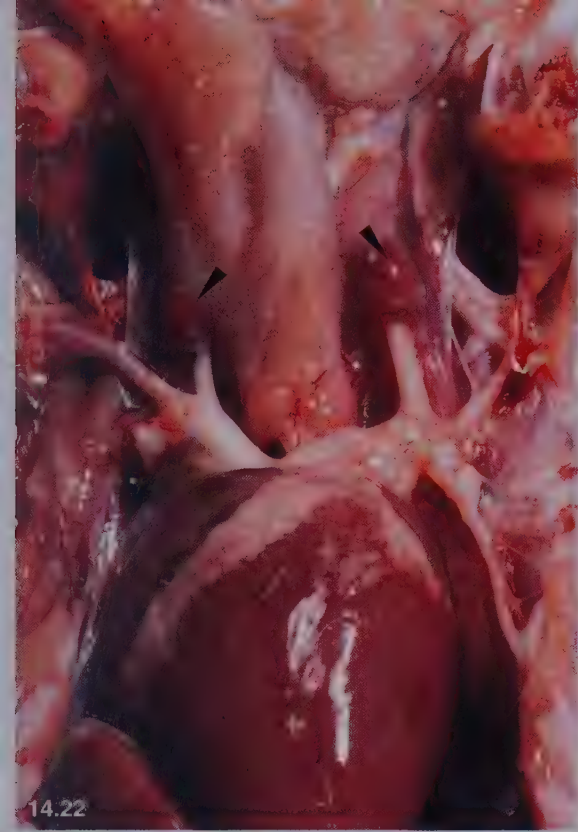A mature, female Amazon parrot with a history of an all-seed diet was presented for evaluation. The hen had been a consistent egg producer for several years. The bird was provided cuttlebone that was seldom consumed. The bird flew into a wall and sustained multiple fractures. Radiographs indicated metabolic bone disease and egg-related peritonitis. Finding enlarged hyperplastic parathyroid glands (pt) suggested nutritional secondary hyperparathyroidism. The normal syringeal muscles (s), trachea (t), thyroid (th) and thoracic esophagus (e) can be visualized. Note how the thoracic esophagus passes dorsally to the syrinx at the level of the heart.

### Color 14.30

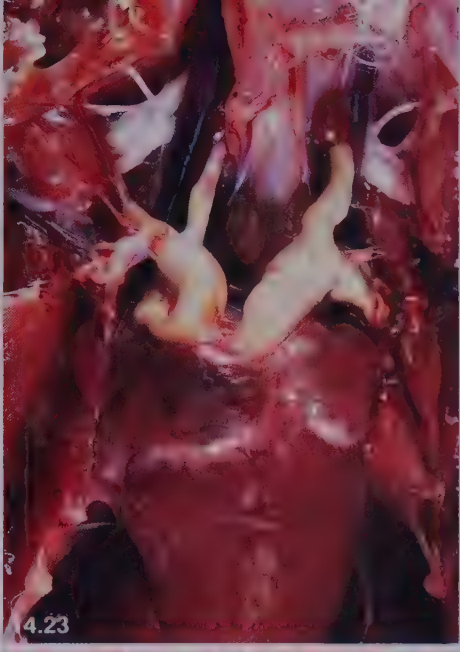Pericarditis can be caused by many bacterial, fungal or viral pathogens. In this Amazon parrot, the pericarditis with plaques was secondary to a gram-negative bacterial septicemia. Note the congestion of the liver.

### Color 14.31

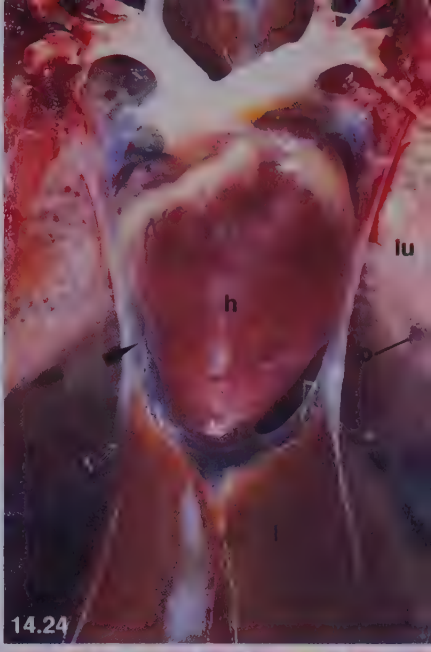
A 32-year-old Green-winged Macaw was presented for progressive weakness of several weeks' duration. The bird was recumbent, depressed and severely dyspneic. The bird died shortly after presentation. Necropsy indicated a pale, mottled heart. Histopathologic changes included atherosclerosis and myocardial fibrosis.



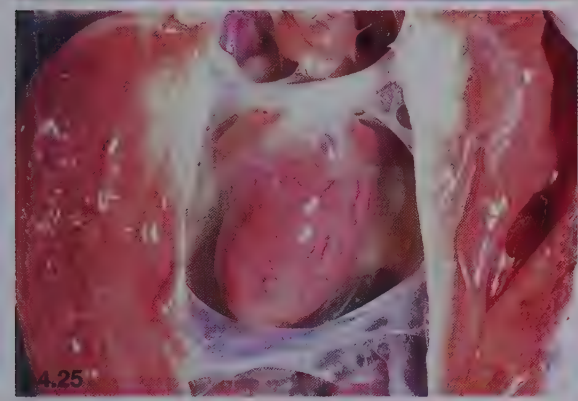
14.22



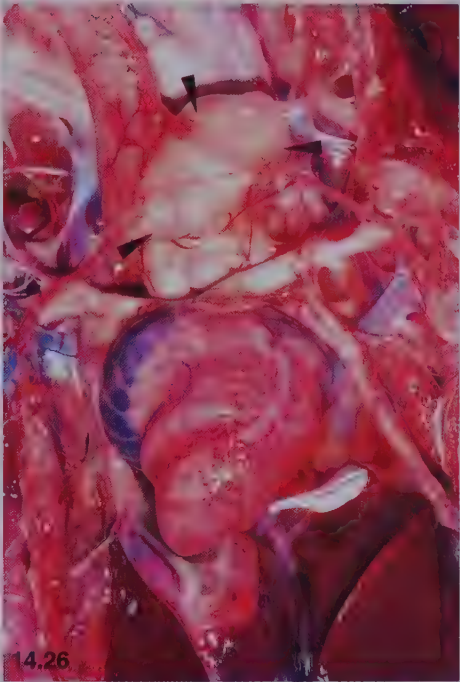14.23



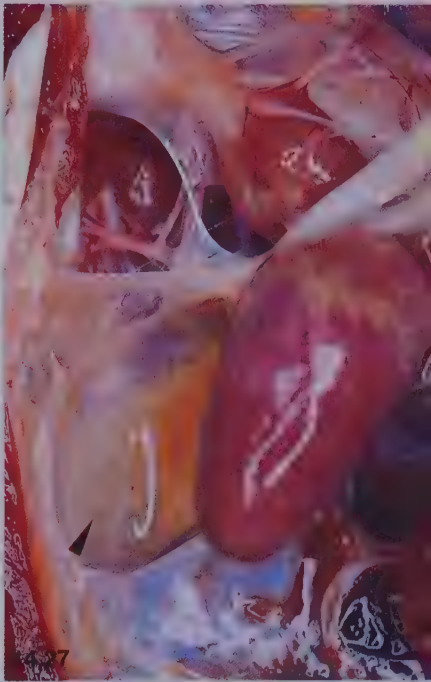14.24



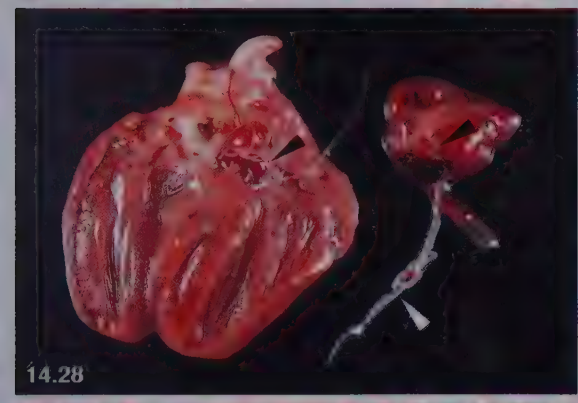
14.25



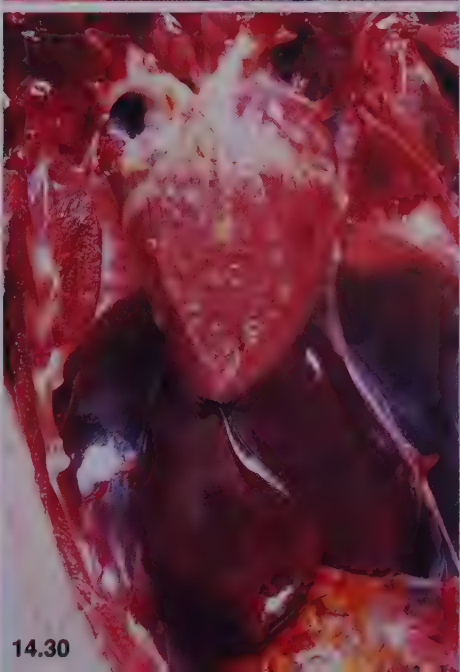14.26



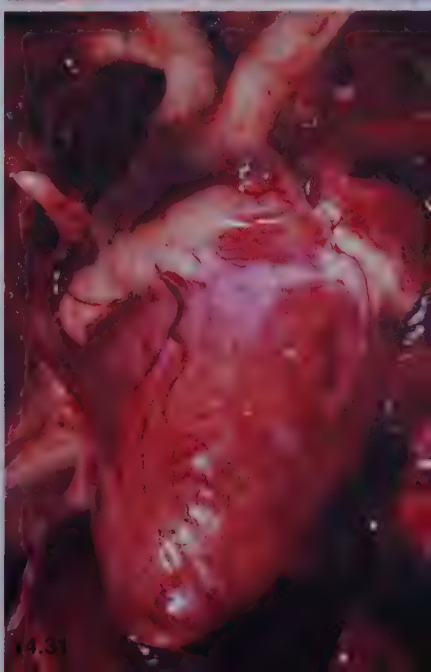14.27



14.28



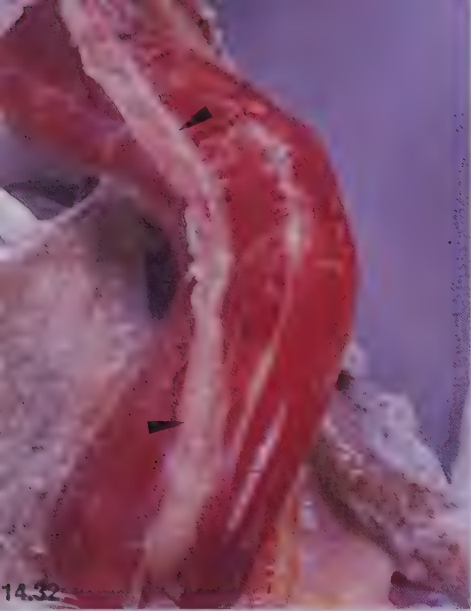14.30



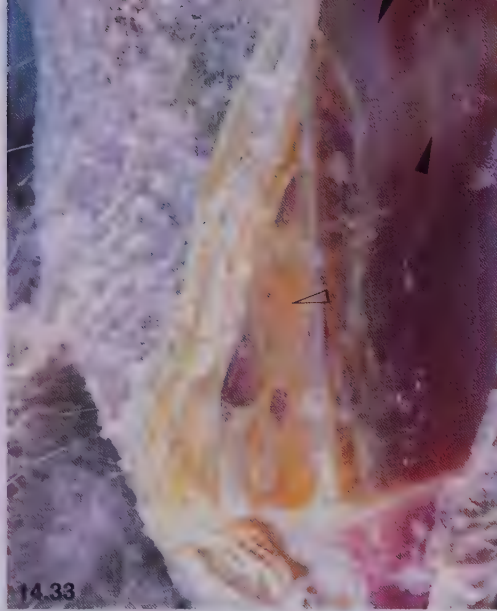14.31



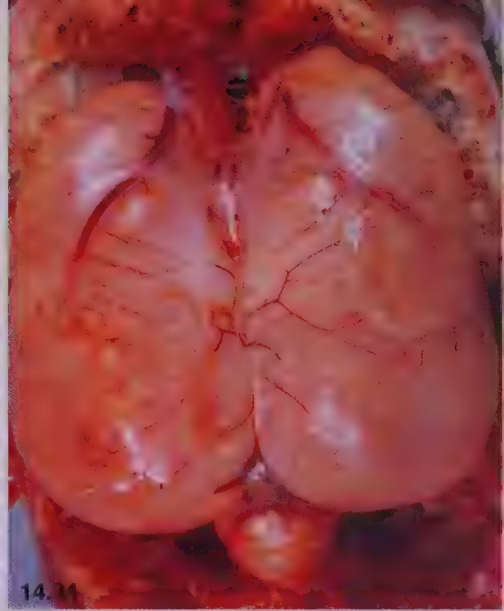14.29



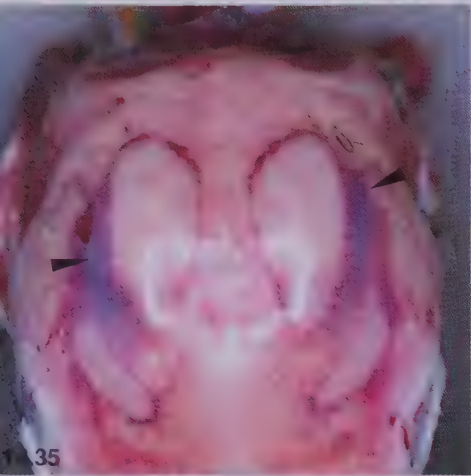
14.32



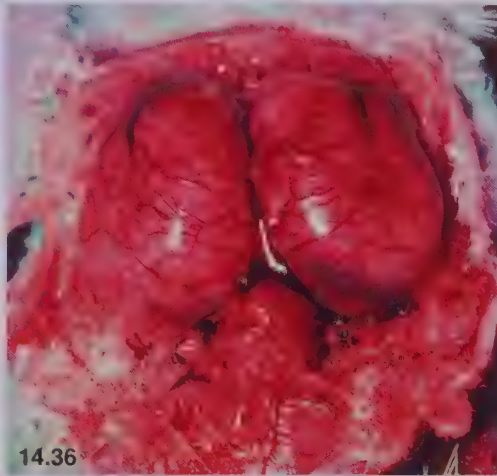14.33



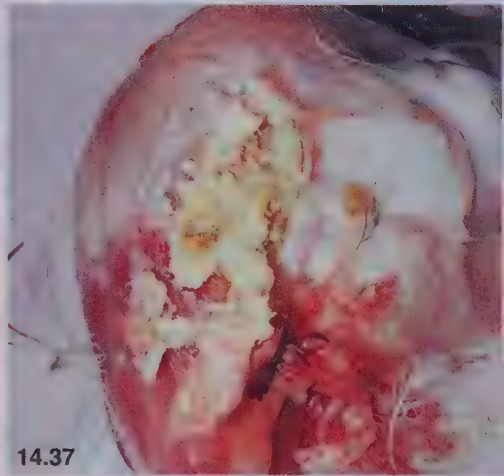
14.34



14.35



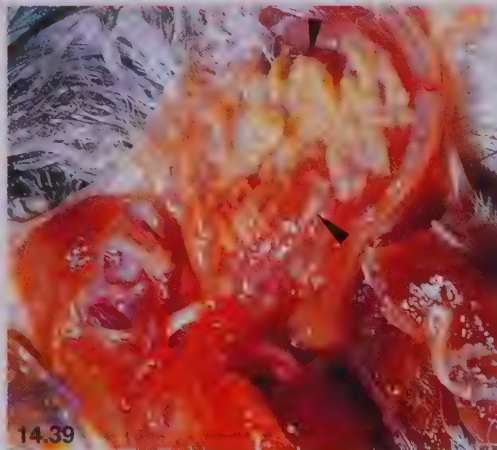14.36



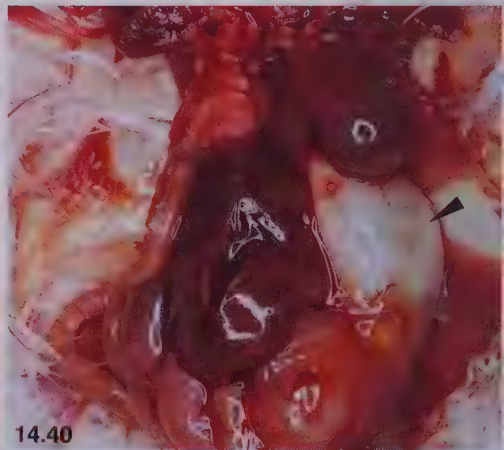14.37



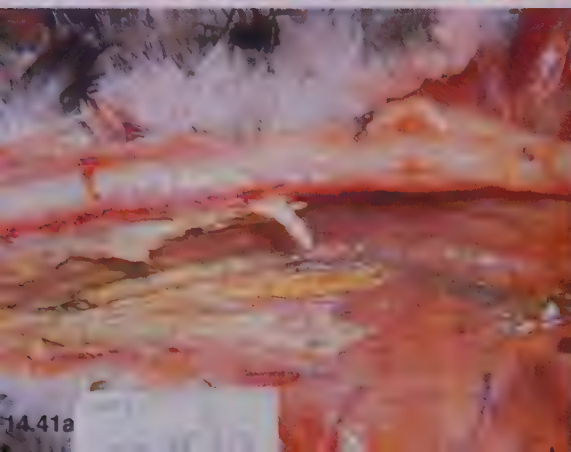
14.38



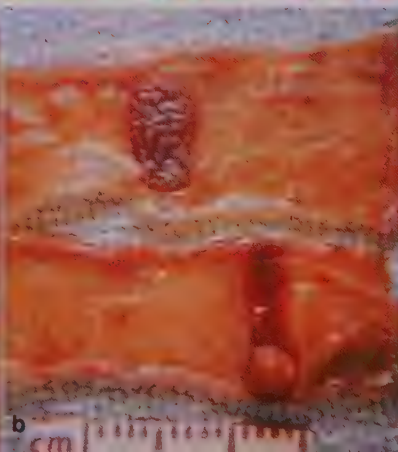14.39



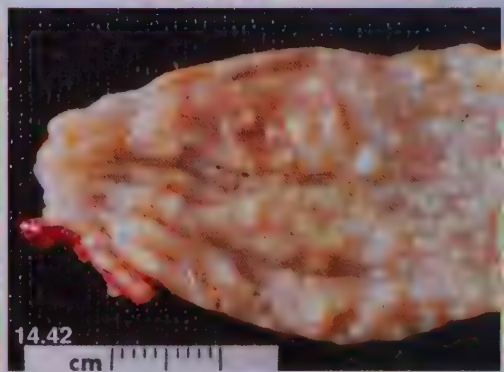14.40



14.41a



14.41b



14.42



## Necropsy Examination

### Color 14.32

Lobules of normal thymic tissue (arrows) within fascial planes adjacent to the cervical musculature in a young cockatoo (courtesy of Ken Latimer).

### Color 14.33

Fibrotic areas of pectoral muscle (arrows) secondary to the injection of enrofloxacin. Note the yellowish discoloration of the subcutaneous tissue (open arrow) associated with the area where the bird had been vaccinated with an oil-emulsion vaccine.

### Color 14.34

Normal brain. The cerebral hemispheres and cerebellum are exposed following removal of the posterior aspect of the cranial vault. Note that the tissues are moist but there is no accumulation of fluid (courtesy of Kenneth Latimer).

### Color 14.35

Subdural hemorrhage (arrows) can be an indication of trauma or can occur as an agonal change.

### Color 14.36

A mature Amazon parrot was presented with a progressive onset of ataxia and severe depression. The WBC was markedly elevated, and the bird did not respond to antibiotics and supportive care. Severe congestion and hemorrhage in the brain were caused by bacterial encephalitis.

### Color 14.37

A ten-year-old Barn Owl was presented for a progressive head tilt and ataxia. Physical examination revealed numerous gram-negative rods in a necrotic discharge from

the right ear canal. Auditory evoke potentials indicated a centralized inflammatory disease. Necropsy indicated an internal and external bacterial ear infection with progression to the brain.

### Color 14.38

*Acuaria skjabini* is a common nematode parasite in finches maintained in aviaries in Australia. The nematode burrows into the koilin layer of the ventriculus, causing hypertrophy (arrows). A normal ventriculus is shown on the right to show the marked hypertrophy in the affected ventriculus (courtesy of Patricia Macwhirter).

### Color 14.39

Proliferative, necrotic lesions (arrows) in the crop of a finch. These “turkish towel”-type lesions can be caused by candidiasis or aspergillosis.

### Color 14.40

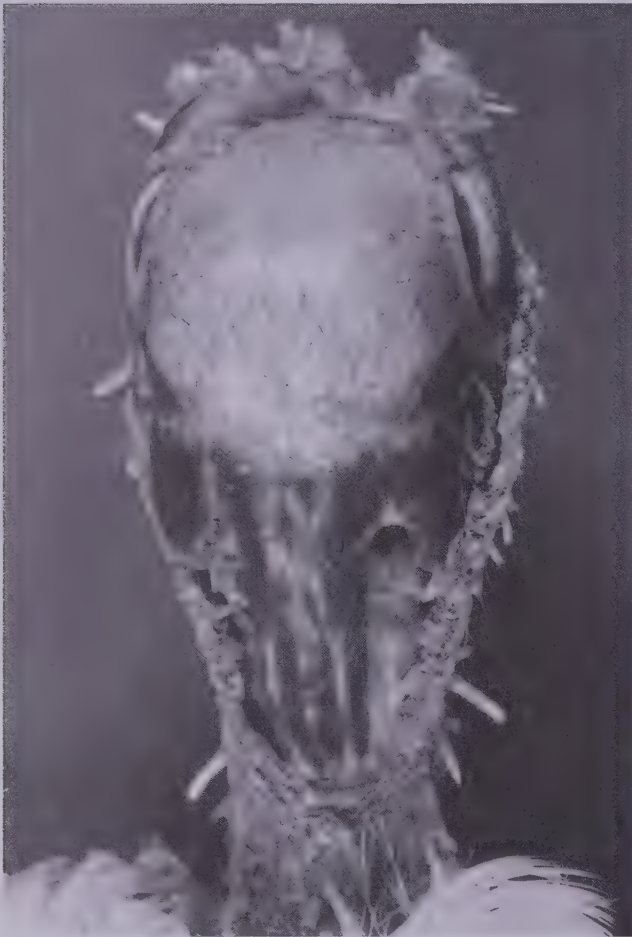Proventricular dilatation (arrow) in a canary infected with megabacteria.

### Color 14.41

**a)** Esophageal necrosis and diphtheritic membranes in a North American Black Duck caused by duck virus enteritis (duck plague) (courtesy of R. J. Montali). **b)** Necrotic, hemorrhagic bands of lymphatic tissues in the small intestines of a duck with duck virus enteritis (courtesy of John H. Olsen).

### Color 14.42

Proventricular nodules in an Anseriforme caused by *Tetrameres* sp. (courtesy of R. J. Montali).



**FIG 14.10** The scalp has been incised and reflected to expose the posterior portion of the skull.

### Brachial Plexus

The brachial plexus lies lateral to the thyroid gland in the vicinity of the subclavian artery (see Anatomy Overlay). Although the plexus commonly is inspected at necropsy, dissection and collection of tissues is limited except in cases of suspected neurologic damage from penetrating wounds, inflammation, neoplasia or trauma resulting in avulsion of the plexus.

### Sacral Plexus

The sacral nerve plexus should be examined carefully in instances where pelvic limb paresis or paralysis has been noted (see Anatomy Overlay). This plexus is best inspected when removing the adrenal glands, gonads and kidneys because it is embedded in the midportion of the kidney just anterior to the ischiatic artery (Figure 14.12). The ischiatic nerve, which innervates the pelvic limb, may be damaged in



**FIG 14.11** A midline incision has been made through the cranial vault using blunt-sharp scissors. The cranium is then peeled away to expose the brain.

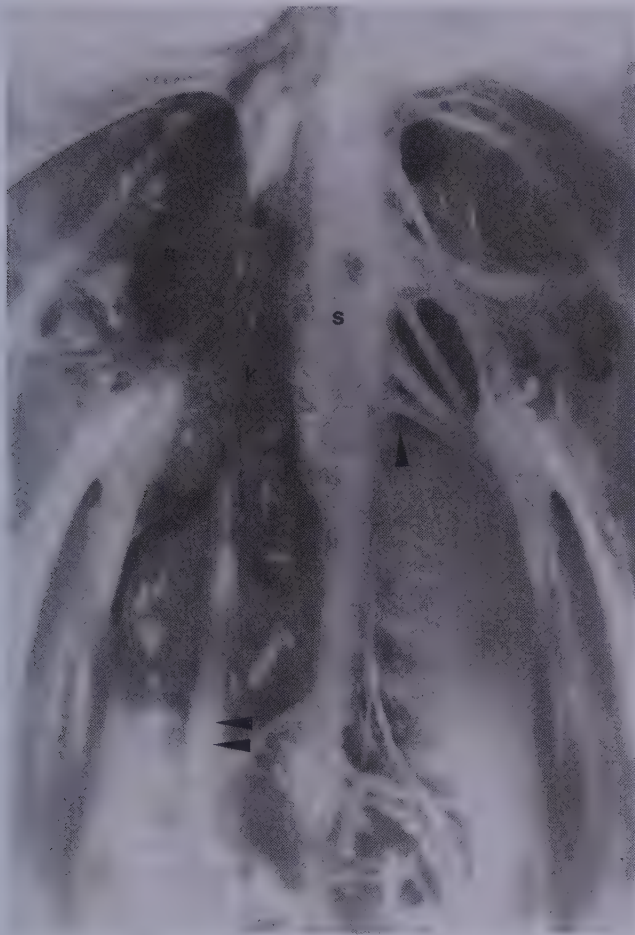
severe nephritis or renal neoplasia where compression or infiltration of the nerve occurs.

### Ischiatic (Sciatic) Nerve

In instances of pelvic limb paresis or paralysis, the ischiatic nerve should be examined grossly and histologically. The ischiatic nerve can be found beneath the medial thigh muscles caudal to the femur (see Anatomy Overlay).

### Removal of the Eyes

If intraocular disease is present, the eye(s) should be removed from the orbit(s) for histologic evaluation. This process is slightly more difficult in birds because of the relatively large size of the eye. The eyeball is removed by sharp and blunt dissection of orbital soft tissues and transection of the optic nerve.



**FIG 14.12** The sacral plexus (arrow) should be carefully examined in all cases involving weakness or ataxia (unilateral or bilateral) of the pelvic limbs. The sacral plexus and lumbosacral spinal column should be submitted for histopathology in these cases as well as those with clinical changes suggestive of neuropathic gastric dilatation. The left kidney has been removed to show the relationship of the kidneys and sacral plexus. The right kidney (k) and ureter (double arrow) are in their normal anatomic locations lateral to the spine (s).

### Other Cranial and Skeletal Tissues

The nares, cere, beak, choanal slit, infraorbital sinus and ears should be examined. Abnormal tissues can be collected for formalin fixation or ancillary testing. Joints of the wings, legs and feet should be opened and examined. Articular surfaces should be off-white, smooth and glistening. If exudates are present, appropriate specimens should be taken for cytologic and microbiologic examination. White, chalky deposits may represent urate deposition. The presence of urate crystals can be confirmed by microscopic examination of cytologic preparations (under polarized light if available). Urate crystals will appear as refractile needles. Appropriate bony lesions may be

collected with a dovetail saw, fixed in formalin, decalcified and processed for histopathologic examination.

### Collection of Bone and Bone Marrow

Detailed examination of portions of the skeletal system may be necessary in instances of fractures, metabolic bone disease, osteomyelitis, arthritis or synovitis and anemia or blood cell dyscrasia. Collection of various skeletal tissues ultimately may be essential for a definitive diagnosis.

In the case of fractures, osteomyelitis and arthritis or synovitis, the tissues of interest may be localized with the assistance of survey radiographs. Blunt and sharp dissection will allow gross observations of these tissues. Callus formation, if present, should be noted and specimens for culture or cytology can be taken after the site is exposed by dissection. Cytology preparations will be useful to characterize inflammatory infiltrates, identify pathogens or identify urate crystals.

Joints can be disarticulated with a scalpel, knife or scissors. The joint capsule, ligaments and tendons can be inspected grossly. Articular surfaces should be examined for erosions of cartilage, eburnation of subchondral bone, tags of fibrin or the presence of exudates or hemorrhage. Rongeurs or a small dovetail saw can be used to excise portions of bone *en bloc* for histopathologic examination.

If the bird is anemic based upon laboratory studies or gross necropsy examination (pale liver and kidneys suggest anemia) or has a blood cell dyscrasia, bone marrow also should be examined. When bone marrow examination is necessary, it should be collected as soon as possible after death since bone marrow cells undergo rapid degeneration. Because many bones of the bird are pneumatized (including those of the thoracic girdle, humerus, sternum, sternal ribs and occasionally femur), the tibiotarsus or vertebral rib(s) should be used for collection. Because the tibiotarsus is larger, more marrow can usually be obtained for both cytology and histopathology. To obtain tibiotarsal marrow, the integument over the tibiotarsus is plucked and the skin is incised and reflected. The underlying musculature is dissected to reveal the shaft of the tibiotarsus. Using rongeurs, a portion of the shaft is excised. The cortex is cracked and small amounts of marrow are teased or gently squeezed from the marrow cavity. Smears or squash preparations of bone marrow are made for cytologic examination. Additional small segments of cortical

bone and marrow are taken for histologic examination. The cortex should be cracked to promote rapid penetration of fixative into the tissues.

### Whole Carcass Submission

In instances where the entire carcass is extremely small, such as embryos, nestlings or very small adult birds, the entire carcass may be submitted for histologic examination. This is best accomplished by opening the thoracoabdominal cavity, gently separating the viscera and fixing the entire carcass in formalin solution.

## Specimen Collection for Ancillary Testing

Ancillary testing often is essential to confirm or establish a definitive diagnosis. Tissue specimens should be collected routinely for histopathologic evaluation; however, additional specimens (eg, swabs for bacterial culture, fresh tissues for bacterial culture and virus isolation, crop contents for toxicologic analysis) are obtained as necessary based upon historical, clinical and necropsy findings. These latter specimens can be submitted along with the formalin-fixed tissues if the need for additional laboratory testing is obvious or they may be held under appropriate conditions for later submission if required. It is better to have taken specimens for ancillary testing and not need them, than to need the specimens and not have taken them. The following information is designed to expedite specimen procurement and handling to maximize the results obtained. A telephone call to the diagnostic laboratory prior to performing the necropsy is a prudent measure to ensure correct specimen collection, preparation and handling.

### Histopathology

Tissue specimens for histopathology should be preserved in neutral-buffered ten percent formalin solution. Buffered formalin is necessary to prevent acid hematin formation, which can obscure microscopic examination. Furthermore, adequate preservation of tissues requires rapid and complete penetration of the fixative. This is best accomplished by procuring

TABLE 14.1 Tissues Routinely Collected for Histopathology

Skin (including feathers, follicles)	Crop	Pancreas
Trachea	Proventriculus	Ovary and oviduct (female)
Lung	Ventriculus	Testis (male)
Air sac	Small intestine	Pectoral muscle
Heart	Large intestine	Bone marrow
Kidneys	Ceca (if present)	Cloacal bursa
Thyroid glands	Cloaca	Thymus
Parathyroid glands	Spleen	Brain
Adrenal glands	Liver	Ischiatic (sciatic) nerve
Esophagus	Gall bladder (if present)	

Selection of additional tissues will depend upon gross lesions observed at necropsy.

thin (four to five mm thick) slices of tissue. Excessively thick (one cm thickness) tissue slices or tissues that float (gas-filled intestine, fatty liver, lung) when immersed in formalin solution often do not fix and become autolytic. Representative tissue specimens from all organ systems should be collected (Table 14.1). When specific lesions are observed at necropsy, the tissue specimen collected should include a small margin of normal tissue adjacent to the lesion.

Specimens should be shipped to the laboratory in leak-proof containers that are well packaged. To decrease shipping weight, tissues that have been fixed in formalin solution for at least 24 hours can be wrapped in a formalin-soaked gauze square that is placed into a sealable plastic bag for shipment. In the authors' experience, a complete set of necropsy tissues provides the best diagnostic material. Because cost is often a consideration when submitting histopathologic specimens to the laboratory, the practitioner should consult a veterinary pathologist concerning the tissues to be submitted in a particular case. The remaining fixed tissues can be held for additional study if needed.

### Hematologic and Cytologic Specimens

Preparation of blood and cytology specimens for microscopic examination is detailed in Chapters 9 and 10.<sup>2</sup> Smears of blood or exudates may be prepared in a routine manner by the wedge technique. Tissue scrapings may be smeared onto a clean glass slide, or squash preparations may be made if particles of tissue are present. Tissue imprints are prepared by blotting the tissue specimen on an absorbent surface (filter paper or paper towel) to remove excess blood and tissue fluid. The tissue specimen is then gently touched to a clean glass slide several times or vice versa. Imprints of liver and spleen can be prepared on a single slide and submitted for special stains (eg,

Macchiavello's or Gimenez staining for chlamydiosis, acid-fast staining for mycobacteriosis or fluorescent antibody staining for chlamydiosis or herpesvirus infection). Intestinal mycobacteriosis also may be diagnosed using cytologic imprints. Swab specimens are properly prepared by gently rolling the swab the length of the glass slide. Three such passes may be made on a single slide from top to bottom. All specimens are air-dried. If they are not stained before examination or submission to the diagnostic laboratory, they should be protected from excessive moisture or formalin fumes, which could cause cellular lysis or interfere with staining, respectively.

### ■ Microbiology

Microbiology includes culture and identification of bacteria, viruses and fungi as well as certain serologic assays to detect the presence of or exposure to these pathogens. Specimens procured for analysis may include culture swabs, fresh tissues, body fluids or exudates, cytologic smears and imprints (eg, fluorescent antibody staining for chlamydia and herpesvirus) and serum. These specimens are perishable and should be shipped to the laboratory without delay. Next-day courier service is recommended.

Fresh tissues submitted for bacterial culture should be at least two cubic centimeters to yield accurate results. At the laboratory the surface of the tissue is seared with a heated spatula to sterilize it, and a loop is inserted through the seared area into the center of the specimen to collect tissue for culture. If the tissue is too small, the entire specimen (including bacteria) is destroyed during the searing step, and a false-negative culture result is obtained. Tissues for routine bacterial culture can be placed in sterile, sealable plastic bags and submitted immediately or frozen if a delay of more than 12 to 24 hours before culturing is expected. If unusual pathogens are suspected, the diagnostic laboratory should be consulted regarding the best means of handling the tissue to optimize culture results.

Specimens for bacterial culture also may be obtained aseptically using swabs. Products such as Culturettes® are preferred because they are self-contained, minimize the possibility of specimen contamination and contain a transport medium that maintains organism viability while preventing saprophytic bacterial overgrowth.

Fresh tissues (especially liver, spleen, kidney, lung and brain) are collected for viral isolation. The selec-

tion of tissues for viral isolation depends in part upon the organ system affected. Tissue specimens may be placed in sealable plastic bags and frozen prior to shipment to the laboratory. If tissues are not sent to the laboratory immediately, they may be stored in the freezer until needed for diagnostic testing. After the definitive diagnosis has been made, remaining tissues can be discarded.

Tissue specimens for fungal culture and identification may be collected, placed in sealable plastic bags and refrigerated or frozen until analyzed. The choice of tissues is variable, depending upon the extent of infection.

### ■ Parasitology

Fecal flotation for detection of parasite ova is performed frequently as a portion of the minimum database to assess a patient's medical status. Additional fecal specimens may be taken for analysis at necropsy, especially in those patients with diarrhea, where protozoal infection is a consideration. Also, intact parasites such as cestodes, trematodes, nematodes or arthropods may be taken for specific identification when encountered in exotic birds or observed in unusual locations. Proper fixation of these parasites is essential for successful identification by a veterinary parasitologist.<sup>20</sup> Preferred fixatives for preservation of fecal material and parasites are detailed in Tables 14.3, 14.4.

Wet mounts of feces or a feces-saline slurry should be examined within minutes of death to detect organisms such as *Giardia* sp., which are identified by their characteristic rolling movement. Following initial examination, a small drop of Lugol's iodine can be added to kill and stain protozoa and their cysts for more detailed examination. These specimens are perishable and generally will not survive shipment to the diagnostic laboratory. Intestinal scrapings or imprints, which may be air-dried, stained and examined in-house or shipped unstained to the laboratory for examination, may be useful to diagnose coccidiosis, atoxoplasmosis and cryptosporidiosis.

### ■ Toxicology

Toxicologic analysis is generally labor-intensive, requires sophisticated analytical equipment and is often expensive. The clinician should have some suspicion of the substance involved before toxicologic analysis is requested, because tissue handling and the specimen(s) required vary with the type of toxic-

cologic analysis performed. A veterinary toxicologist or diagnostic laboratory should be contacted to ensure that the proper samples are collected and submitted for analysis. In addition, a particular laboratory may not perform a desired test or may not be equipped for analysis of small tissue specimens.

The most commonly ingested toxins in companion and aviary bird practice are heavy metals (eg, zinc, lead), aflatoxin-contaminated feeds and various ornamental houseplants. The most commonly inhaled toxins include the fumes of polytetrafluoroethylene produced from over-heated cooking pans or utensils and some varieties of red heat lamps.<sup>1,9,11,13,18,24,28</sup> The following discussion briefly covers sample submission for toxicologic analysis, especially for identification of certain heavy metals and aflatoxins (see Chapter 37).

### Heavy Metals

Heavy metal toxicosis is most frequently associated with ingestion of zinc by companion or aviary birds and lead by foraging waterfowl. Sources of excess zinc include ingestion of particulate material from homemade galvanized wire mesh enclosures and ingestion of pennies thrown into captive bird displays.<sup>9,13,23</sup> United States pennies minted since 1982 are essentially copper-plated zinc wafers. Lead poisoning is usually due to ingestion of lead shot by waterfowl during normal feeding activities.<sup>18</sup> However, lead poisoning in companion birds may result from chewing leaded windows, lead-containing toys or costume jewelry, lead pellets and fishing sinkers.<sup>32</sup> Suspicion of heavy metal toxicosis may be based upon observing metallic foreign bodies in the crop and gizzard on routine survey radiographs or at necropsy.

Heavy metal toxicosis is best detected using graphite furnace atomic absorption spectrophotometry, which requires a small sample volume. Using this technique, quantitation of lead requires submission of 250 µl of blood in heparin or one-half gram each of liver and kidney. Quantitation of zinc requires 250 µl of serum (avoid hemolysis) or one-half gram each of liver and kidney. The above specimens may be submitted refrigerated or frozen. Blood and serum should be submitted in screw-cap plastic containers or stoppered test tubes. Control specimens are helpful in evaluating results because reference values have not been established for most birds. Liver and kidney specimens may be submitted in sealable plastic bags.

### Aflatoxins

Aflatoxins B<sub>1</sub>, B<sub>2</sub>, G<sub>1</sub> and G<sub>2</sub> are metabolites of *Aspergillus flavus*. These substances may form in improperly stored feed and act as potent hepatotoxins. They may be identified in feed or tissue specimens using thin-layer chromatography or high performance liquid chromatography. An ELISA test is available for identification of aflatoxin B<sub>1</sub>. Identification of aflatoxin in foodstuffs requires submission of 50 to 100 g of feed. The feed should be well mixed to prevent sampling errors, and should be derived from the same lot of material fed before the onset of disease. Detection of aflatoxin residues in tissues requires 100 g of fresh or frozen liver. Samples for analysis should be placed in sealable plastic bags. Although not ideal, tissues from several dead birds can be pooled for analysis if necessary.

### Poisonous Plants and Chemicals

Suggestion of plant-induced toxicosis may be based upon the medical history and observation of crop contents. Although large lists of potentially toxic plants have been published, recent publications indicate that development of toxicosis is dependent on the species of bird, portion of plant ingested and season of plant growth.<sup>1,8,28</sup> Diagnosis of plant alkaloids or chemical-induced toxicosis should be pursued on an individual basis. A veterinary toxicologist should be consulted concerning appropriate specimens and handling prior to analysis.

#### Products Mentioned in the Text

- Culturettes, Becton Dickinson, Cockeysville, MD
- Whirl-Paks, Fort Atkinson, WI

TABLE 14.2 Fixative Solutions for Tissue Specimens<sup>27</sup>

- **Neutral-buffered 10% formalin solution:** This solution is used as a common fixative to preserve tissue specimens for histologic examination. Proper fixation requires a ratio of one part tissue to 10-20 parts fixative solution.
 

Concentrated formaldehyde (37%)	100 ml
Distilled water	900 ml
Sodium phosphate monobasic, monohydrate	4.0 g
Sodium phosphate, dibasic, anhydrous	6.5 g
- **Carson's modified Millong's phosphate-buffered formalin:** This solution may be used for routine preservation of tissue specimens for both histopathology and electron microscopy. Proper fixation requires a ratio of one part tissue to 10-20 parts fixative solution.
 

Concentrated formaldehyde (37%)	100 ml
Deionized water	900 ml
Sodium phosphate monobasic	18.6 g
Sodium hydroxide	4.2 g

TABLE 14.3 Fixative Solutions for Fecal Material<sup>20</sup>

The following fixatives are intended for preservation of fecal material for storage or mailing to the diagnostic laboratory. Comments on the usefulness of each fixative solution follow.

- **PVA fixative:** This fixative is recommended because stained preparations of fecal material subsequently can be made for identification of protozoa.
 

PVA, Elvanol 71-24	10.0 g
95% ethanol	62.5 ml
Mercuric chloride, saturated aqueous	125.0 ml
Glacial acetic acid, concentrated	10.0 ml
Glycerin	3.0 ml

Mix all liquid ingredients thoroughly. Add the PVA powder without stirring and allow to soak overnight in a sealed beaker. Heat solution slowly to 75°C, remove from heat and swirl for 30 seconds until a homogeneous, slightly milky solution is observed. Using applicator sticks, mix approximately 1 g feces with 7-9 ml fixative and store in a labeled brown bottle.

- **10% formalin solution:** This fixative is used primarily to preserve ova for identification. Stained smears cannot be made for identification of protozoa.
 

Concentrated formaldehyde (37%)	100 ml
Deionized water or 0.85% saline	900 ml

Best preservation is achieved by mixing 1 part feces with 10-20 parts of hot (60°C) fixative.

- **MIF preservative:** Fecal specimens may be stored indefinitely in MIF solution and ova may be harvested by common concentration techniques. This fixative is useful for large surveys where fecal materials are collected from many animals over a long period of time.

Solution A (store in a brown bottle):

Distilled water	50 ml
Concentrated formaldehyde (37%)	5 ml
Thimerosal (tincture of merthiolate, 1:1,000)	40 ml
Glycerin	1 ml

Solution B (Lugol's solution; good for several weeks in a tightly capped bottle):

Distilled water	100 ml
Potassium iodide crystals	10 g
Iodine crystals (after above crystals dissolve)	5 g

Combine 9.4 ml of solution A with 0.6 ml of solution B just before use in a small vial. Add feces (up to 1 g) and mix thoroughly. If the suspension is allowed to sit undisturbed for 24 hours, 3 well-defined layers will be apparent. The microscopic specimen is collected from the interface and bottom layers using a disposable Pasteur pipette.

TABLE 14.4 Fixative Solutions for Specific Parasites

- **Trematodes and Cestodes:** Platyhelminths may be fixed in 10% neutral-buffered formalin solution or alcohol-formalin-acetic acid mixtures. The parasites should be flattened under a slide and coverslip during fixation. Fixatives are best used hot (60°C) for more rapid penetration.

Alcohol-formalin-acetic acid fixative (Galigher's fixative):

Concentrated formaldehyde (37%)	10 ml
95% ethanol	70 ml
Distilled water	15 ml
Glacial acetic acid, concentrated	5 ml

- **Nematodes:** Living nematodes should be placed in boiling (60-63°C) alcohol glycerin fixative to rapidly kill the parasites and prevent contraction of the specimen. Nematodes can remain in this fixative indefinitely.

Alcohol-glycerin fixative:

95% ethanol	70 ml
Distilled water	25 ml
Glycerin	5 ml

- **Arthropods:** Arthropods can be preserved in 70% ethanol or 70% isopropyl alcohol solutions (formalin is unsatisfactory for arthropod fixation).

## References and Suggested Reading

1. **Arai M, et al:** Evaluation of selected plants for their toxic effects in canaries. *J Am Vet Med Assoc* 200:1329-1331, 1992.
2. **Campbell TW:** Avian Hematology and Cytology. Ames, Iowa State University Press, 1988.
3. **Fowler ME:** Comparative clinical anatomy of ratites. *J Zoo Wildlife Med* 22:204-207, 1991.
4. **Gaskin JM, et al:** Preliminary findings in avian viral serositis: A newly recognized syndrome of psittacine birds. *J Assoc Avian Vet* 5:27-34, 1991.
5. **Grimes JE:** Chlamydiosis in psittacine birds. *J Am Vet Med Assoc* 190:394-397, 1987.
6. **Graham DL:** Necropsy procedures in birds. *Vet Clin N Am Small Anim Pract* 14:173-177, 1984.
7. **Guthertz LS, et al:** *Mycobacterium avium* and *Mycobacterium intracellulare* infections in patients with and without AIDS. *J Inf Dis* 160:1037-1041, 1989.
8. **Hargis AM, et al:** Avocado (*Persea americana*) intoxication in caged birds. *J Am Vet Med Assoc* 194:64-66, 1989.
9. **Howard BR:** Health risks of housing small psittacines in galvanized wire mesh cages. *J Am Vet Med Assoc* 200:1667-1674, 1992.
10. **Keymer IF:** Postmortem examinations of pet birds. *Mod Vet Pract* 42:35-38, 47-51, 1961.
11. **LaBonde J:** Avian toxicology. *Vet Clin N Am Small Anim Pract* 21:1329-1342, 1991.
12. **Latimer KS, et al:** Recognition and interpretation of selected gross necropsy lesions and anatomical variations. *J Assoc Avian Vet* 6:31-33, 1992.
13. **Lloyd M:** Heavy metal ingestion: Medical management and gastroscopic foreign body removal. *J Assoc Avian Vet* 6:25-29, 1992.
14. **Lowensine LI:** Necropsy procedures. In Harrison GJ, Harrison LR (eds): *Clinical Avian Medicine and Surgery*. Philadelphia, WB Saunders Co, 1986, pp 298-309.
15. **McDonald SE:** Anatomical and physiological characteristics of birds and how they differ from mammals. 1991 Manual of Basic Avian Medicine, Association of Avian Veterinarians, Atlanta, GA, 1991, pp 1-18.
16. **McKibben JD, Harrison GJ:** Clinical anatomy with emphasis on the Amazon parrot. In Harrison GJ, Harrison LR (eds): *Clinical Avian Medicine and Surgery*. Philadelphia, WB Saunders Co, 1986, pp 31-66.
17. **McLelland J:** A Color Atlas of Avian Anatomy. Philadelphia, WB Saunders Co, 1991.
18. **Murase T, et al:** Treatment of lead poisoning in wild geese. *J Am Vet Med Assoc* 200:1726-1729, 1992.
19. **Pass DA:** The pathology of the avian integument: A review. *Avian Pathol* 18:1-72, 1988.
20. **Prestwood AK:** Clinical parasitology techniques for veterinarians. University of Georgia, Athens, GA, 1992.
21. **Prince DS, et al:** Infection with *Mycobacterium avium* complex in patients without predisposing conditions. *N Engl J Med* 321:863-868, 1989.
22. **Randall CJ:** Color Atlas of Diseases of the Domestic Fowl & Turkey. Ames, Iowa State University Press, 1985.
23. **Reece RL, et al:** Zinc toxicity (new wire disease) in aviary birds. *Aust Vet J* 63:199, 1986.
24. **Richardson M:** Teflon toxicity from heat lamps. *J Assoc Avian Vet* 5:192, 1991.
25. **Ritchie BW, Dreesen DW:** Avian zoonoses: Proven and potential diseases. Part I. Bacterial and parasitic diseases. *Comp Cont Educ* 10:484-492, 1988.
26. **Ritchie BW, Dreesen DW:** Avian zoonoses: Proven and potential diseases. Part II. Viral, fungal and miscellaneous diseases. *Comp Cont Educ* 10:688-695, 1988.
27. **Sheehan DC, Hrapchak BB:** Theory and Practice of Histotechnology, 2nd ed. St Louis, CV Mosby Co, 1980, pp 45-46.
28. **Shropshire CM, et al:** Evaluation of selected plants for acute toxicosis in budgerigars. *J Am Vet Med Assoc* 200:936-939, 1992.
29. **Smith AW, et al:** 1986 report of the AVMA panel on euthanasia. *J Am Vet Med Assoc* 188:252-268, 1986.
30. **T-W-Fiennes RN:** Diseases of bacterial origin (Techniques of postmortem examination). In Petrak ML (ed): *Diseases of Cage and Aviary Birds* 2nd ed Philadelphia, Lea & Febiger, 1982, pp 498-499.
31. **van Ripper C, van Ripper SG:** A necropsy procedure for sampling disease in wild birds. *Condor* 82:85-98, 1980.
32. **Woerpel RW, Roskopf WJ:** Heavy-metal intoxication in caged birds - part I. *Comp Cont Educ* 4:729-738, 1982.
33. **Zander DV, Mallinson ET:** Principles of disease prevention: Diagnosis and control. In Galnek BW, et al (eds): *Diseases of Poultry*, 9th ed Ames, Iowa State University Press, 1991, pp 27-36.

---

**CHAPTERS**

**15 SUPPORTIVE CARE AND  
EMERGENCY THERAPY**

Katherine E. Quesenberry  
Elizabeth V. Hillyer

**16 TRAUMA MEDICINE**

Laurel A. Degernes

**17 ANTIMICROBIAL THERAPY**

Keven Flammer

**18 FORMULARY**

Branson W. Ritchie  
Greg J. Harrison



---

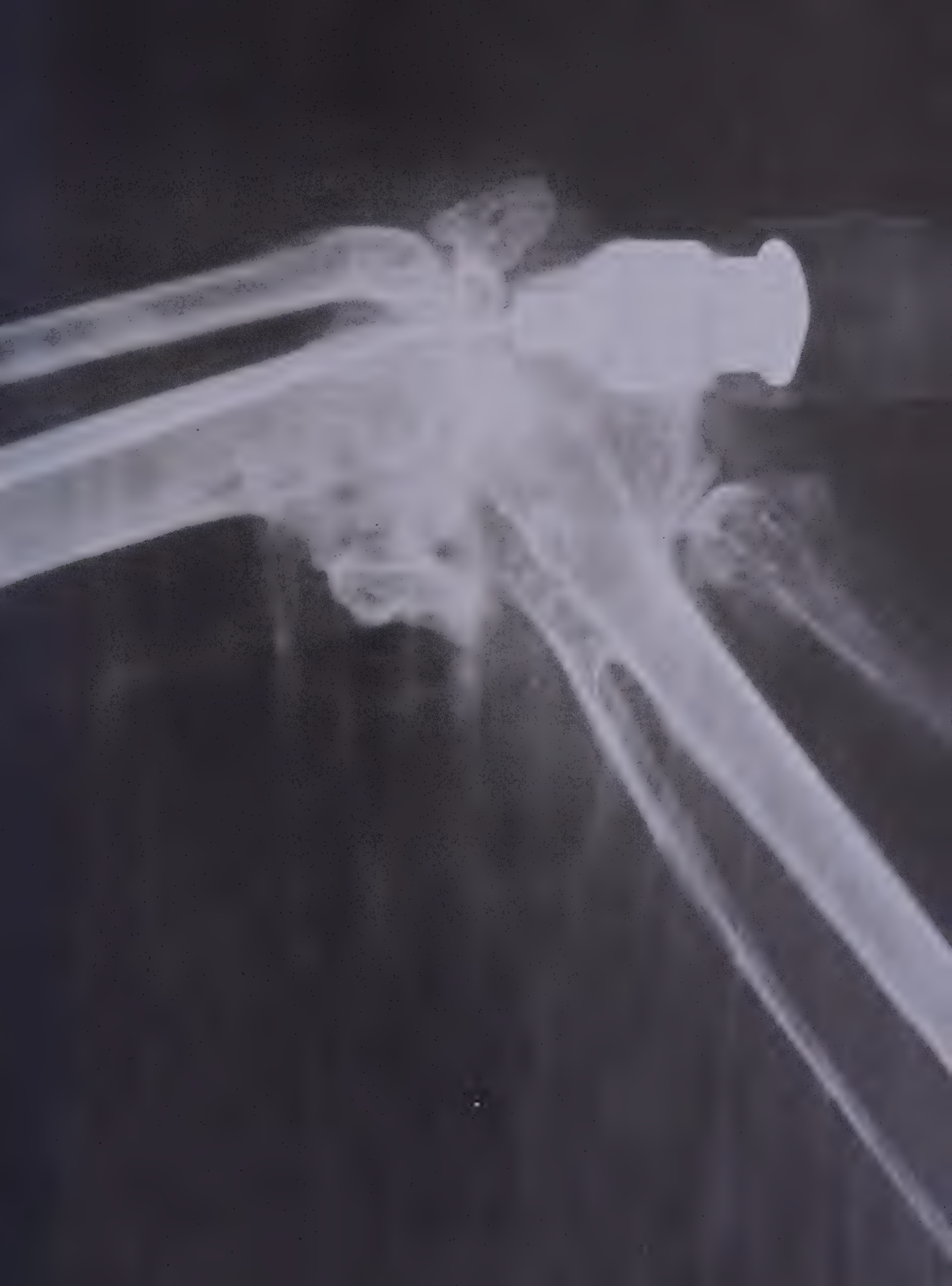---

**SECTION THREE**

**TREATMENT  
REGIMENS**







CHAPTER

# 15

## SUPPORTIVE CARE AND EMERGENCY THERAPY

■  
Katherine E. Quesenberry  
Elizabeth V. Hillyer

**K**nowledge of the principles and techniques of supportive care and emergency medicine is necessary for the successful medical management of avian patients. The basic concepts of emergency and supportive care of small animal medicine apply to birds, but modifications must be made to compensate for their unique anatomy and physiology. Supportive care including fluid therapy, nutritional support, and heat and oxygen supplementation is critical to both emergency and maintenance therapy.

Emergencies of many different types are seen in avian medicine. A common emergency is the extremely debilitated, cachectic, chronically ill bird that is too weak to perch or eat. Because certain syndromes are more common in certain species and at certain ages, the signalment of the bird is helpful in establishing a rule-out list. Recently obtained birds frequently present with acute infectious problems, including chlamydiosis and viral diseases.

Neonates that are being hand-fed commonly suffer from management-related problems (eg, crop burns, nutritional deficiencies) and certain fungal, bacterial and viral diseases such as candidiasis, gram-negative ingluvitis and avian polyomavirus. Birds that are long-term companion animals are more likely to have chronic infectious diseases such as aspergillosis, chronic nutritional diseases or toxicities. Egg binding and egg-related peritonitis frequently occur in companion budgerigars and cockatiels. Aviary birds can have a variety of infectious, metabolic, toxic and nutritional problems. Traumatic emergencies are common in all types of birds.

Critically sick or injured birds are often too weak for an extensive examination when first presented. Birds that are on the bottom of the cage and dyspneic need immediate medical attention with an organized, efficient approach to stabilization therapy. Physical examination, diagnostic tests and treatments should be performed in intermittent steps to decrease restraint periods and reduce stress.

## Emergency Stabilization

Although each bird should be evaluated individually, some basic guidelines for emergency diagnostic testing and treatment can be followed. The bird should be observed carefully in its enclosure before handling, to assess the depth and rate of breathing. Birds with airway obstruction or severe respiratory disease are usually extremely dyspneic. Birds that are septicemic, in shock or weak from chronic disease may also have labored breathing. If respiration is rapid or difficult, the bird should be placed immediately in an oxygen cage. This is usually less stressful than using a face mask, especially if the bird is refractory to restraint. While the bird is allowed to stabilize, a complete history can be obtained from the owner, and a diagnostic and therapeutic plan based on the history, clinical signs and the initial physical findings can be formulated.

If the bird can be weighed without undue stress, an accurate pretreatment weight should be obtained. Otherwise, drug dosages are calculated based on an estimate of the body weight for the species (see Chapter 30). The most important treatments must be given first. If the bird shows any signs of stress during restraint, it may be placed back in oxygen or in a quiet enclosure until it is stable. Alternatively, the bird can be given oxygen by face mask while treatments are administered.

Some veterinarians prefer to use isoflurane anesthesia when treating very weak, dyspneic or fractious birds. For gradual induction in critically ill patients, low isoflurane concentrations (0.25%) are slowly increased to 1.5% or 2.5% over two to five minutes. Once the bird is anesthetized, lower maintenance concentrations (0.75% to 2%) can be used. Birds can be maintained with a face mask or intubated.

The use of anesthesia allows several procedures to be performed within a few minutes, including collection of a blood sample, placement of a catheter or air sac tube and radiographs. For each bird, the risk of anesthesia must be considered and weighed against the risks of stress associated with manual restraint. If anesthesia is chosen for restraint, the episode should be of short duration and the bird must be carefully monitored.

Pretreatment blood samples are valuable if appropriate to obtain. If intravenous fluids are given, a sample can be obtained through a butterfly catheter in the jugular vein immediately before fluid administration. The bird should be evaluated for anemia before blood is withdrawn. If the conjunctiva and mucous membranes appear pale, the packed cell volume (PCV) should be determined by taking a small blood sample from a toenail clip. If the PCV is 15% or less, collecting blood for a full biochemistry analysis or complete blood count can be life-threatening. Collecting a pretreatment blood sample is usually too stressful in extremely dyspneic birds unless anesthesia is used for restraint.

While the bird is resting after the initial treatments, necessary diagnostic samples collected during the restraint period (eg, fecal or crop cultures, chlamydia test, blood work) can be evaluated. Radiographs are usually postponed until the bird is stable. If radiographs are essential for establishing a correct diagnosis and initiating treatment, isoflurane anesthesia can be used to ensure that diagnostic radiographs are safely obtained.

### Fluid Replacement Therapy

#### Fluid Requirements

The daily maintenance fluid requirement for raptors and psittacine birds has been estimated at 50 ml/kg/day (5% of the body weight).<sup>42</sup> This estimate is appropriate clinically for most companion and aviary bird species. However, water consumption may vary from 5 to 30% of body weight per day in many free-ranging species. The amount of water needed is generally inversely related to body size<sup>3</sup> and can also vary according to age, reproductive status, dietary intake and the type of foods consumed (Table 15.1).

TABLE 15.1 Variance in Water Intake

Adult chickens	5.5%	bw/day <sup>15</sup>
Cockatiels	5-8%	bw/day
Growing chickens	18-20%	bw/day
Laying hens	13.6%	bw/day <sup>63</sup>

An estimate of hydration status is based on the clinical signs and history. The turgescence, filling time and luminal volume of the ulnar vein and artery are good indicators of hydration status.<sup>1</sup> A filling time of greater than one to two seconds in the ulnar vein indicates dehydration greater than seven percent. Severely dehydrated birds (ten percent) may have

sunken eyes and tacky mucous membranes. The skin of the eyelids may tent when pinched.

As for mammals, anemia or hypoproteinemia can affect the accuracy of a PCV or total solids in detecting dehydration (Table 15.2).

**TABLE 15.2 Findings with Dehydration**<sup>31,33</sup>

Increased PCV	15 to 30%
Increased total solids	20 to 40%
Increased plasma urea	6.5 to 15.3 x normal

Changes will vary with the degree of dehydration.

Most birds presented as emergencies have a history of inadequate water intake and can be assumed to be at least five percent dehydrated. An estimation of the fluid deficit can be calculated based on body weight:

$$\text{Estimated dehydration (\%)} \times \text{body weight (grams)} = \text{fluid deficit (ml)}^{18}$$

Half of the total fluid deficit is given over the first 12 to 24 hours along with the daily maintenance fluid requirement. The remaining 50% is divided over the following 48 hours with the daily maintenance fluids.

Lactated Ringer's solution (LRS) or a similar balanced isotonic solution warmed to 100.4° to 102.2°F (38° to 39°C) is recommended for fluid replacement and shock therapy. Using warm fluids is particularly important with neonates and with intravenous or intraosseous administration of fluids for hypothermia or shock.<sup>1</sup>

The exact fluid requirements of birds in shock are difficult to determine. In mammals in septic shock, a fluid volume of 0.5 to 1.5 times the estimated blood volume may be needed to correct peripheral vasoconstriction. Thirty minutes after treatment, only 25% of administered isotonic crystalloid fluids remains in the vascular compartment.<sup>21</sup> The remaining 75% redistributes to the interstitial fluid compartment. Consequently, circulatory improvement may be transient, requiring additional fluid therapy to prevent recurrence of hypotension and vasoconstriction.

As illustrated by this example, hemodilution is the primary limitation to crystalloid fluid therapy, making administration of colloids or blood necessary for effective shock therapy. Synthetic colloid solutions (dextran, hetastarch) have not been used to any extent in birds. These solutions contain large molecules that do not cross the endothelium and remain in the intravascular fluid compartment. Colloid solutions draw fluid from the interstitial fluid compartment

into the intravascular space and are more effective blood volume expanders than crystalloids.<sup>1,21</sup> They are particularly useful in restoring circulating blood volume without aggravating hypoproteinemia or causing pulmonary edema in animals with low oncotic pressure and hypoproteinemia.

There is evidence that hemorrhagic shock does not occur in birds.<sup>64</sup> Severe blood loss is tolerated much better in birds than in mammals, especially in flighted birds. This tolerance is the result of an increased rate of absorption of tissue fluids to replace lost blood volume and baroreceptor reflexes, which maintain normal blood pressure. Prostaglandins, which potentiate shock in mammals, have been shown to have no effect in chickens.

### Route of Fluid Therapy

Supplemental fluids can be given orally, subcutaneously, intravenously or by intraosseous cannula (Figure 15.1). Fluids can be given orally for rehydration and maintenance in birds that are mildly dehydrated. Oral rehydration is often used for waterfowl and other large species in which administration of intravenous or subcutaneous fluids is difficult. In pigeons, administration of an oral five percent dextrose solution has been shown to be more effective for rehydration than oral administration of lactated Ringer's solution.<sup>33</sup> This effect may be the result of glucose causing a more rapid uptake of water from the intestinal tract. Gatorade<sup>®</sup> is used by some veterinarians for oral rehydration and fluid maintenance. For effective rehydration, oral fluids need to be readministered within 60 to 90 minutes of the first treatment. Mixing oral fluids with ppsyllium<sup>®</sup> may increase fluid and calcium absorption from the intestinal villi. Oral fluids should not be given to birds that are seizing, laterally recumbent, regurgitating, in shock or have gastrointestinal stasis.


Subcutaneous administration is used primarily for maintenance fluid therapy. The axilla and lateral flank areas are commonly used for injection. The intrascapular area is preferred by some clinicians in young birds that may be difficult to restrain for flank injection. The area around the neck base should be avoided because of the extensive communications of the cervicocephalic air sac system. A small (25 to 27 ga) needle is used to prevent fluids from leaking from the injection site. The total volume of fluids should be given in several sites (5 to 10 ml/kg/site) to prevent disruption of blood flow and subsequent poor absorption.<sup>1</sup> Subcutaneous fluids are less effective than intravenous or intraosseous fluids for shock therapy



**FIG 15.1** Subcutaneous fluids can be administered in the lateral flank, axilla or intrascapular region (shown here) in cases of mild dehydration (five percent) to provide maintenance fluids. The area of the base of the neck should be avoided because of the cervicocephalic air sacs. Subcutaneous fluids are generally ineffective in cases of severe dehydration or shock.

because of peripheral vasoconstriction. Subcutaneous fluids may pool in the ventral abdominal area causing hypoproteinemia, overhydration or poor absorption. If ventral abdominal edema is noted, subcutaneous fluid administration should be decreased or discontinued.

Intravenous fluids are necessary in cases of shock to facilitate rapid rehydration. Intraosseous cannulas or use of the right jugular vein are the best access points to the peripheral circulation. Dyspneic birds and those with distended, fluid-filled crops should be carefully handled to prevent regurgitation and aspiration. Injection of a large fluid volume into the ulnar or metatarsal veins is difficult and frequently results in hematoma formation.



**FIG 15.2** IV fluids and drugs can be slowly administered through a butterfly catheter in the right jugular vein. The biggest disadvantage to this technique is that fluids should not be given faster than 10 ml/kg over a five- to seven-minute period necessitating prolonged restraint for fluid administration (courtesy of Kathy Quisenberry).

A butterfly catheter (25 ga) with 3.5-inch tubing is ideal for fluid administration in medium-sized to large birds (Figure 15.2). A 27 ga needle can be used in small birds. The catheter allows pretreatment blood collection and “slow” administration of fluids, antibiotics or other medications with one venipuncture. Drug dosages and fluids should be prepared before the bird is restrained.

The amount of fluid that can be administered at one time depends on the size of the bird. Injections of ten ml/kg given slowly over five to seven minutes are usually well tolerated.<sup>1</sup> The bolus injections can be repeated every three to four hours for the first twelve hours, every eight hours for the next 48 hours, and then BID.<sup>18</sup>

Intravenous catheters (24 ga in medium to large birds) can be placed in the ulnar or medial metatarsal veins of some birds for continuous fluid administration. For placement in the ulnar vein, the catheter is inserted using sterile technique, secured loosely with elastic tape<sup>24</sup> and fixed in place using a tongue depressor that extends 1.5 inches beyond the catheter end. Both the proximal and distal ends of the tongue depressor are then firmly incorporated in a wing wrap to stabilize the catheter.<sup>5</sup> The risk of hematoma formation is probably greater using the ulnar vein than with the metatarsal vein.

Maintenance of an IV catheter can be difficult. Many birds will chew at the catheter, tape or extension set tubing.



**FIG 15.3** A mature Umbrella Cockatoo was presented with a two-day history of vomiting and profuse diarrhea. The bird was estimated to be ten percent dehydrated (reduced ulnar refill time, tacky mucous membranes, dull sunken eyes). PCV=28 and TP=6.8. An intraosseous catheter was placed in the ulna and the bird was given warm LRS using an infusion pump. The clinical response to rehydration was dramatic. The bird had destroyed a plastic cup the day before clinical signs started. Large pieces of plastic were flushed out of the proventriculus by gastric lavage using warm LRS.

An intraosseous cannula can be used for administration of fluids, blood, antimicrobials, parenteral nutritional supplements, colloids, glucose and drugs used for cardiovascular resuscitation in birds.<sup>36</sup> Administration of hypertonic or alkaline solutions can be painful and should be avoided. The advantages of intraosseous cannulas include the ease of placement and maintenance, cannula stability, tolerance by most birds and reduced patient restraint once the cannula is placed. Continuous fluid administration by intraosseous cannula is less stressful than repeated venipunctures.

It has been shown in pigeons that 50% of the fluids administered in the ulna enters the systemic circulation within 30 seconds.<sup>30</sup> Over a two-hour period, the flow into the systemic circulation was almost equivalent to the administration rate.

Intraosseous cannulas can be placed in any bone with a rich marrow cavity.<sup>36</sup> A cannula may be placed in the distal ulna in medium-sized to large birds that will require several days of therapy (Figure 15.3). The proximal tibia is ideal in birds that will require shorter terms of therapy. Pneumatic bones such as the humerus and femur cannot be used. Isoflurane anesthesia is sometimes necessary for cannula placement in fractious birds. In medium-sized or larger birds, an 18 to 22 ga, 1.5 to 2.5 inch spinal needle<sup>4</sup> can be used as the cannula. In smaller birds, a 25 to 30 ga hypodermic needle is used.

For placement in the ulna, the feathers from the distal carpus are removed and the area is aseptically prepared. Using sterile technique, the needle is introduced into the center of the distal end of the ulna parallel to the median plane of the bone (Figure 15.4).<sup>46</sup> The entry site is ventral to the dorsal condyle of the distal ulna (Figure 15.4). The needle is advanced into the medullary cavity by applying pressure with a slight rotating motion. The needle should advance easily with little resistance once the cortex is penetrated. If resistance is encountered, the needle may have entered the lateral cortex. When seated correctly, a small amount of bone marrow can be aspirated through the cannula. This aspirate can be submitted for bone marrow analysis if desired. The

## CLINICAL APPLICATIONS

### Fluid Therapy Considerations

#### Oral Fluids

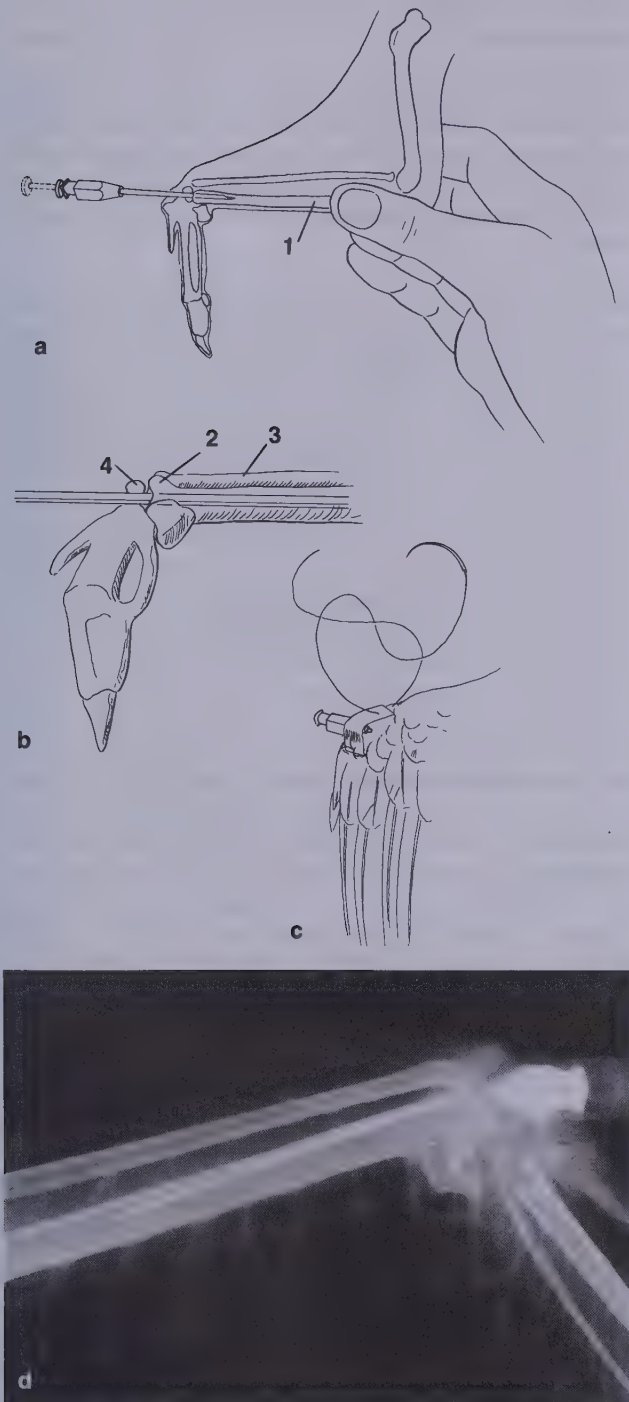
- Only effective with mild dehydration
- 5% dextrose may be better than lactated Ringer's solution
- Contraindicated with GI stasis
- Contraindicated with lateral recumbency
- Contraindicated with seizing and head trauma
- Ineffective for shock

#### Subcutaneous Fluids

- Primarily used for mild dehydration
- Effective for providing maintenance fluids
- Given in axilla or lateral flank
- Divide dose among several sites

#### Intravenous or Intraosseous Fluids

- Rapidly expands circulatory volume
- Rapidly perfuses kidneys
- Indicated in shock
- Indicated with severe dehydration
- Right jugular vein - one time use
- Medial metatarsal vein - one time use
- Tibial intraosseous cannula - one time use



**FIG 15.4** Technique for placing an intraosseous cannula in the distal ulna. If fluid or drug administration will be restricted to a single dose or a short period (eg, surgery), it is easier to place a catheter in the tibia. An intraosseous catheter placed in the ulna is easier to maintain if several days of continuous IV therapy are necessary. **a)** The thumb is placed in the center of the 1) ulna as a guide. **b)** The cannula is inserted slightly ventral to the 2) dorsal condyle of the distal ulna. The 3) radius and 4) radial carpal bone can be used for orientation. **c)** The cannula is sutured in place. **d)** Radiograph of properly inserted cannula.

cannula should be flushed with a small amount of heparinized saline, which should flow without resistance. Initial fluids should be administered slowly to check for subcutaneous swelling, which would indicate improper placement of the cannula. If the cannula is properly placed, fluid can be visualized passing through the ulnar vein. The cannula is secured in place by wrapping a piece of tape around the end and suturing the tape to the skin or by applying a sterile tissue adhesive<sup>b</sup> at the point of insertion (Figure 15.4). A gauze pad with a small amount of antibacterial ointment is placed around the cannula at the insertion site, and a figure-of-eight bandage is used to secure the wing. One to two loops of the extension tube should be incorporated into the bandage to decrease tension on the cannula.

Tibial cannulas are seated in the tibial crest and passed distally, similar to the technique used for obtaining a bone marrow aspirate. A light padded bandage or lateral splint is used to secure the cannula in place (see Figure 17.5).

Fluids are administered through the cannula using an infusion pump, buretrol<sup>c</sup> or Control-a-Flow regulator.<sup>d</sup> Unlike a vein, the marrow cavity cannot expand to accommodate rapid infusions of large fluid volumes. Consequently the rate of infusion into the marrow cavity is limited. The ideal infusion rate to avoid fluid extravasation in birds is unknown. In small mammals, fluids can be given at shock doses (90 ml/kg) at a pressurized flow rate of 2 l/hr.<sup>36</sup> Clinically, infusion rates in birds for shock therapy should probably be much lower. A flow rate of ten ml/kg/hr is suggested for maintenance. Excessively rapid infusion of the fluids may cause signs of discomfort or edema of the soft tissue in the area of the cannula. Fluid extravasation may occur if the infused volume is too large, or if several holes were made in the cortex while attempting to place the cannula.

Intraosseous cannulas are most successful in birds if used during the first 24 to 48 hours for initial rehydration and shock therapy. Cannulas can remain in place for up to 72 hours without complications if placed aseptically and maintained with heparinized flushings every six hours.<sup>36</sup> Clinically, after two to three days of use, many birds exhibit a painful response when fluids are given through an intraosseous cannula. This could result from pain associated with local edema or the extravasation of fluids around the marrow cavity. Some birds will not tolerate the cannula and will bite at the extension tubing or the wrap as their general condition improves.

The use of vascular access devices (VAD) in birds has recently been described.<sup>20</sup> A vascular access device consists of a catheter that is placed within a vessel, and a port that is implanted in the subcutaneous tissue. No portion of the catheter is externally exposed, reducing the incidence of bacterial contamination and infection. A specially designed needle (Huber needle) is used for access to the depot port by skin penetration. Use of a VAD allows repeated blood sampling and drug administration without repeated venipuncture, with minimal stress on the patient. Vascular access ports are used in humans primarily for long-term intravenous chemotherapy and total parenteral nutrition. More recently, vascular access devices have been used in dogs and laboratory animals.<sup>2,37</sup> Potential complications of the vascular access port include thrombosis, sepsis, local infection and drug extravasation.<sup>2</sup>

Vascular access devices have been used experimentally in pigeons and geese and clinically in an auklet.<sup>20</sup> The use of the device in small birds may be limited by the size of the animal and absence of an appreciable subcutaneous space. Other disadvantages of the device in birds include the necessity of surgical placement and removal and the difficulty of venotomy in small avian patients.

The system is usually implanted with the animal under general anesthesia (see Chapter 41). A skin incision is made over the jugular vein. The vein is isolated and occluded cranially for venotomy and insertion of the catheter. The catheter is secured in place in the vein with sutures above and below a retention ring on the catheter. A tunnel is made through the subcutaneous tissue to a site dorsal to the catheter where the port is sutured to the underlying muscle fascia. The extravascular portion of the catheter is left in a short loop to prevent tension during neck movement. The catheter is flushed with heparinized saline at regular intervals to ensure patency.

### Antibiotics

Septicemia and bacteremia should be considered in any bird that is severely depressed. Prophylactic antibiotics are frequently used in birds that are immunocompromised from a noninfectious disease. Antibiotics are not necessary in all emergencies. Birds with simple closed fractures, uncomplicated heavy metal toxicity, hypocalcemia and other noninfectious problems may not require or benefit from the use of antibiotics. However, in many emergency patients the history and clinical signs are vague and inconclu-

sive, and antibiotics may be indicated on a precautionary basis.

Parenteral antibiotics are recommended for the initial treatment of birds that are weak, sick, debilitated or in shock.<sup>45</sup> General peak plasma concentrations following parenteral drug administration vary with the route: IV = seconds; IM = 30 to 60 minutes; oral = 60 to 120 minutes.

Absorption following oral administration may be erratic in birds that are severely dehydrated, have gastrointestinal stasis or are regurgitating. Intravenous administration is recommended if septicemia is a primary concern. Intravenous drugs can be given during the initial fluid bolus or through an indwelling or intraosseous cannula. Intravenous drugs should be given slowly to avoid circulatory shock.

Intramuscular administration of antibiotics is used routinely for maintenance therapy. A small gauge needle (26 to 30 ga) is used to minimize muscle trauma. The pectoral muscles should be used for most injections (see Chapter 17).

The major disadvantage to intramuscular injection is the potential for muscle damage. In a study using hens, eight of thirteen injectable antibiotic preparations caused muscle necrosis, with the most severe damage being induced by tetracyclines and sulfonamides. Muscle damage was a common sequela to IM injections of almost 50 different medications in budgerigars.<sup>13</sup>

Subcutaneous administration of drugs is less traumatic to the muscle and is often used for maintenance therapy. Subcutaneous injections may be preferred in very small or cachectic birds with limited muscle mass and in birds with suspected coagulopathies. Disadvantages of subcutaneous injections include the possibility of leakage from the injection site and poor absorption.

The initial choice of an antibiotic depends on the clinical signs and history of the bird. Birds with suspected gram-negative septicemia should be treated with a bactericidal antibiotic effective against the most common avian pathogens, including *Escherichia coli*, *Enterobacter* spp., *Klebsiella* spp. and *Pseudomonas* spp.<sup>45</sup> Antibiotics commonly used for initial treatment of septicemia include piperacillin, cefotaxime, enrofloxacin, trimethoprim-sulfa, doxycycline and amikacin (see Chapters 17 and 18).



If chlamydiosis is suspected, the bird should be treated with a parenteral doxycycline to rapidly establish therapeutic blood concentrations and stop the shedding of the organism. After initial parenteral therapy (IV doxycycline in the United States,<sup>e</sup> IM doxycycline in the rest of the world<sup>f</sup>), the patient can be switched to oral medication for continued therapy (see Chapter 34).

### Other Drug Therapy

Severe metabolic acidosis is common in mammals that are in shock or that are critically ill. In mammals in hemorrhagic shock, acidosis occurs secondary to inadequate tissue perfusion; however, acidosis has not been shown to occur in chickens following prolonged hemorrhage.<sup>64</sup> Bicarbonate replacement therapy has been recommended in birds if severe metabolic acidosis is suspected, but because it is not usually feasible to measure blood gases in birds, bicarbonate deficit must be estimated.<sup>18</sup> A dose of 1 mEq/kg given IV at 15- to 30-minute intervals to a maximum of 4 mEq has been recommended.<sup>42</sup> In small animals, bicarbonate must be administered slowly IV over 20 minutes or longer.<sup>21</sup> If administered too rapidly or given in excessive amounts, alkalemia, hypercapnia, hypocalcemia, hypernatremia, hyperosmolality, hypokalemia and paradoxical CNS acidosis may occur.<sup>65</sup> The result may be vomiting, hypotension or death.

Stress causes release of catecholamines, which have hyperglycemic effects. Consequently, birds with traumatic wounds or chronic, non-septic diseases may have normal to increased blood glucose concentrations and do not need initial supplemental glucose. Hypoglycemia is most common in sick hand-fed babies, septicemic birds, raptors or extremely cachectic birds in which body stores of glycogen have been depleted. In birds that have been determined to be hypoglycemic, an IV bolus of 50% dextrose at 2 cc/kg body weight can be given with fluids to restore blood glucose concentrations. Glucose can then be added to maintenance fluids in a 2.5% to 10% solution given intravenously or intraosseously. Intramuscular injections of hyperosmotic (75%) dextrose should not be given, because severe muscle irritation and necrosis can result.

Birds that are on poor diets or are chronically ill should receive a parenteral multivitamin on initial hospitalization. Vitamin A and D<sub>3</sub> should be administered with care in patients on formulated diets to prevent toxicities from over-supplementation. Vita-

min B complex is suggested both initially and on a daily basis in anorectic or anemic birds. Iron dextran therapy is also recommended in anemic birds. Vitamin K<sub>1</sub> will improve clotting time and is important in birds with suspected hepatopathies or birds that may require surgery. Vitamin E and selenium should be considered in patients that have neuromuscular disease. Supplementation of calcium and iodine may be indicated in some cases.

Recently an injectable amino acid supplement<sup>h</sup> has been marketed for use in birds. The product has been recommended for use as an immune stimulant and a nutritional supplement in anorectic and compromised birds. Although no scientific studies have been conducted, some veterinarians report improvement in birds after using this product at recommended doses, and no detrimental side effects have been reported.

### Corticosteroids

The use of corticosteroids in the treatment of shock is controversial. Shock is a very complex disease with many complicating factors, making it difficult to compare treatment results in clinical studies. In humans, there are numerous conflicting studies comparing mortality and reversal of shock in corticosteroid- versus non-corticosteroid-treated groups. Experimentally, pharmacologic doses of steroids have anti-shock effects in laboratory animals. These include improved microcirculation, organelle and cell membrane stabilization, improved cellular metabolism and gluconeogenesis and decreased production of endogenous toxins.<sup>21</sup> Hydrocortisone, prednisolone, methylprednisolone and dexamethasone are recommended in the treatment of hypovolemic and septic shock. There is no definitive evidence of one drug being superior to another.

Complications of steroid use include immunosuppression, adrenal suppression, delayed wound healing and gastrointestinal ulceration and bleeding. Except for immunosuppression, which may occur with one dose of dexamethasone, other negative side effects are primarily associated with chronic therapy using high dosages.

Prednisolone or dexamethasone are used routinely for central nervous system injuries in animals. Methylprednisolone sodium succinate (MPSS) has been shown to improve recovery in humans and cats with spinal cord injuries.<sup>7,8</sup> Dexamethasone was no better than a placebo in improving neurologic signs.<sup>8</sup> The beneficial effects of MPSS are primarily attributed to

the antioxidant effects in protecting cell membranes from lipid peroxidation. It was also found that improvement was strictly dose-dependent. The optimal dose was 30 mg/kg IV in cats and mice. Lower or higher dosages were ineffective or even promoted further lipid peroxidation. In mice, prednisolone sodium succinate was found to be equally efficacious, but half as potent, as MPSS when given five minutes after concussive head injury. Hydrocortisone was ineffective even at high dosages.

There are few studies detailing corticosteroid use in birds. In Red-tailed Hawks and Barred Owls, both intravenous and intramuscular injections of dexamethasone (3 mg/kg) produced peak plasma concentrations within 15 minutes of injection.<sup>9</sup> Intravenous injections resulted in a higher peak concentration. Serum half-life of dexamethasone varied with the species and was found to be 53.5 minutes in Red-tailed Hawks, 37.5 minutes in Barred Owls and 36 minutes in male broiler chickens.<sup>4</sup> Suppression of plasma corticosterone concentrations lasted for 24 hours in owls and for 18 hours in hawks following single-dose administration. Intramuscular injection of dexamethasone sodium phosphate (4 mg/kg) in Red-tailed Hawks was associated with elevations in AST and ALT. Elevations were 3.2 times normal values within 36 hours of single-dose administration.<sup>26</sup> No elevations in AST or ALT were seen following IV administration.

Corticosteroids are used in birds in the treatment of shock, acute trauma and toxicities. Clinically, birds receiving corticosteroids for head trauma and shock therapy seem to improve; however, clinical improvement may result from supportive care and fluid therapy rather than corticosteroid use.

Secondary fungal and bacterial infections are common in birds receiving steroids for longer than one week.<sup>24</sup> These findings suggest that birds are very susceptible to the immunosuppressive effects of corticosteroids; therefore, corticosteroids should be used in birds on an infrequent, short-term basis.

### Nebulization

Nebulization therapy may be beneficial in birds with bacterial or fungal respiratory infections, particularly those limited to the upper respiratory system (see Chapter 22). Air sacculitis is frequently associated with the accumulation of inflammatory cells and pathogenic organisms. The caudal thoracic and abdominal air sacs are more commonly involved, prob-

ably as a result of the directional air flow within the respiratory system.

The air sac wall consists of a thin layer of simple squamous epithelial cells supported by a small amount of connective tissue. Blood supply is extremely limited, and parenteral and oral antimicrobials that depend on the circulatory system for tissue distribution are ineffective in treatment of air sacculitis.<sup>27</sup> In effect, nebulization provides topical, localized treatment of the internal air sacs and is not dependent on absorption (see Chapter 22). Because of the anatomy of the avian respiratory tract and the lack of physical activity in the sick bird, nebulized drugs probably reach only 20% of the lung tissue and the caudal thoracic and abdominal air sacs.<sup>13</sup>

The particle size of nebulized medications must be less than 3  $\mu\text{m}$  to establish local drug levels in the lungs and air sacs.<sup>13</sup> Particles from 3 to 7  $\mu\text{m}$  generally deposit in the trachea and mucosal surface of the nasal cavity.<sup>13,60</sup> Many inexpensive commercial nebulizers do not produce a particle size small enough for penetration of the lower airways. Ultrasonic nebulizers are most effective in producing small particle size and are recommended for use in birds. The tubing and chamber of the nebulizer should be easy to clean after each use, and should be sterilized between birds to avoid introduction of bacterial or fungal organisms with the nebulized solutions.

In general, most parenteral antibiotics formulated for intravenous use can be used for nebulization. Bactericidal antibiotics appear most successful in nebulization therapy. With air sacculitis caused by an unidentified bacteria, the authors prefer to use cefotaxime (100 mg in saline) or piperacillin (100 mg in saline) for nebulization. The suggested protocol is to nebulize for ten to thirty minutes, two to four times daily for five to seven days.<sup>61</sup> Saline is preferred as the nebulizing fluid. Mucolytic agents should be avoided due to their irritant properties.<sup>65</sup> If amikacin is used, the patient should be carefully monitored for signs of polyuria. The effectiveness of treating mycotic air sacculitis with nebulization is not known.<sup>13</sup> In some cases, medications can be injected directly into the trachea or a diseased air sac.

### Nutritional Support

Nutritional support is mandatory for the successful recovery of an anorectic bird. There are two main routes for providing nutritional support. Enteral feeding uses the digestive tract and is the simplest,

while parenteral feeding bypasses the digestive tract by supplying amino acids, fats and carbohydrates directly into the vascular system. In mammals, enteral feeding has been shown to be comparable to or possibly superior to parenteral feeding.<sup>70</sup> Parenteral nutrition is in its infancy in avian medicine, but may be necessary for birds with gastrointestinal disease.

Enteral nutritional support is generally provided in companion and aviary birds using a tube passed into the crop (Figure 15.5). Necessary equipment includes 10 to 18 ga stainless steel feeding needles with rounded tips, rubber feeding catheters of various diameters, plastic catheter adapters, oral beak specula and regular and catheter-tipped syringes. A “sterile” feeding needle or catheter should be used for each bird to prevent the transmission of pathogenic organisms. Feeding needles and catheters should be

cleaned thoroughly and sterilized after each use. Raptors are usually hand-fed pieces of prey.

Parenteral medications and fluids should be administered before gavage feeding. If given afterwards, there is a risk of regurgitation during restraint for the subsequent treatments. Oral medications can often be administered with the enteral feeding formula.

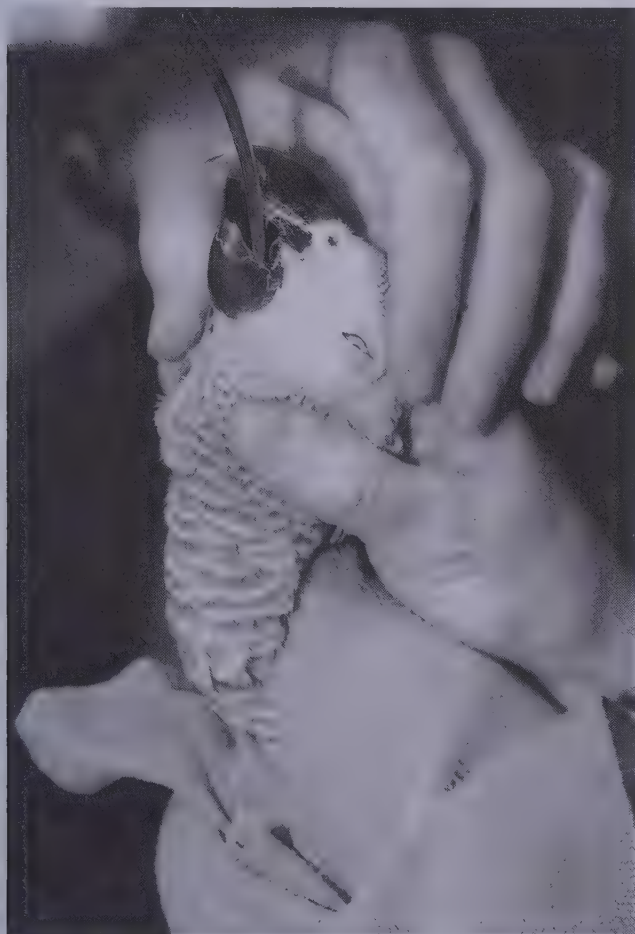The crop should be palpated before each feeding to determine if residual feeding formula remains. Birds with ingluvititis or gastrointestinal stasis frequently have slow crop emptying times. If residual food remains, the crop should be flushed thoroughly with a warm, dilute chlorhexidine solution. The crop may need flushing for several days before motility returns to normal. “Crop bras” are sometimes used to support slow-moving, pendulous crops and will often improve crop emptying (see Chapter 30).

Tube-feeding is facilitated with the help of an assistant, but it can be done in small birds by one person. The handler holds the bird upright with the body wrapped in a paper or cloth towel (Figure 15.6). An oral speculum can be useful in large birds but is not usually necessary in small birds. A speculum must be used with care to prevent damage to the soft tissues at the lateral beak commissures.

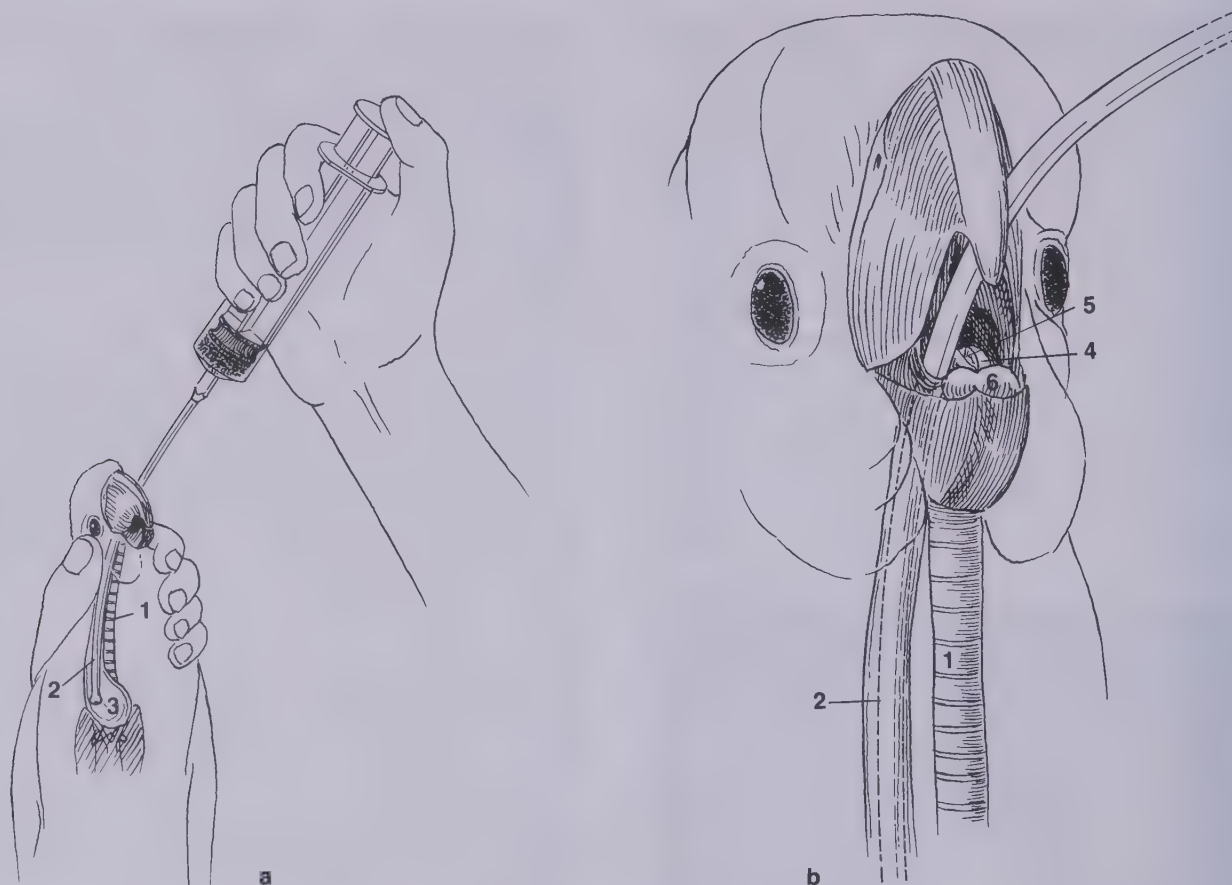
The bird’s neck is straightened vertically with the head grasped around the mandibles. An index finger is placed on top of the head to prevent the bird from throwing its head back. The second person then passes the tube into the left oral commissure (Figure 15.6). If the tube is passed directly from the front, the bird will try to chew at the tube. In medium-sized to large birds, the top beak can be pushed slightly to one side with one hand to open the beak for passage of the tube. Alternatively, the upper beak is inserted in the lower beak, preventing the bird from biting on the tube.<sup>34a</sup>

After entering the oral cavity, the tube is passed down the esophagus on the right side of the neck into the crop. Tube placement can be visualized by moistening the feathers on the right lateral neck region. The crop is palpated to check the position of the end of the tube before injecting the feeding formula. The total volume that can be given depends on the size of the bird (Table 15.3). The neck should be kept in full extension during feeding to discourage regurgitation.

After injection of the food, the tube is carefully removed to prevent reflux. The assistant continues to



**FIG 15.5** Tube-feeding is frequently necessary as part of the supportive care provided to anorectic patients that do not have gastrointestinal tract disorders that would prohibit oral alimentation (eg, crop stasis, ileus). Note that this African Grey Parrot’s head is held upright and the tube is inserted from the left oral commissure (courtesy of Kathy Quesenberry).



**FIG 15.6** a) For tube-feeding or crop aspiration, the bird is held in an upright position with the neck in extension. b) The tube is passed through the left side of the oral cavity and down the esophagus in the right side of the pharyngeal cavity. The tip of the tube should be palpated to ensure that it is in the crop before delivering fluids or feeding formula. 1) trachea 2) esophagus 3) crop 4) laryngeal mound 5) rima glottis and 6) tongue.

hold the bird with the neck in extension until the bird is released into its enclosure. If reflux of formula occurs at any time during the tube-feeding process, the bird should be released immediately to allow it to clear the oral cavity on its own. Attempting to swab the oral cavity or turning the bird upside down will cause undue stress and may increase the possibility of aspiration.

**TABLE 15.3** Suggested Volumes and Frequency for Tube Feeding Anorectic Birds

	Volume	Frequency
Finch	0.1 - 0.3 ml	Six times/day
Parakeet	0.5 - 1.0 ml	QID
Cockatiel	1.0 - 2.5 ml	QID
Conure	2.5 - 5.0 ml	QID
Amazon	5.0 - 8.0 ml	TID
Cockatoo	8.0 - 12.0 ml	BID
Macaw	10.0 - 20.0 ml	BID

Most hospitalized birds are tube-fed two to four times daily according to their clinical condition and caloric needs. Neonates and small birds may need to be fed more frequently (see Chapter 30).

If the crop or upper gastrointestinal system is dysfunctional (eg, crop stasis, crop burns, proventricular dilatation or ventricular impaction), a bird can be provided enteral nutrition by injecting food directly into the proventriculus or lower gastrointestinal tract through an esophageal gastric tube (pharyngostomy tube) or duodenal catheter (see Figure 41.10). The first method involves placing a soft feeding tube into the esophagus at the base of the mandible, through the esophageal opening at the right crop base and into the proventriculus. The tube is sutured in place. Cellulitis should be expected to occur at the interface of the tube and esophagus, but generally resolves when the tube is removed.

A second method for supporting enteral alimentation while bypassing the crop is the placement of a duodenal feeding catheter.<sup>17</sup> A small Foley catheter is surgically placed in the proximal duodenum and exited through the lower abdominal wall. The end of the tube is secured to the dorsum or intrascapular area with tape or sutures (see Chapter 41). An easily absorbed liquid diet is infused into the proximal small intestine.<sup>1,41</sup> The volume of liquid formula that can be infused at one time is small, and frequent feedings (as often as every one to two hours) are necessary to meet caloric requirements. Alternatively, food can be infused at a constant rate using an infusion pump. The authors have used this method in young birds for up to six days without complications. Duodenal tubes are not practical for use in small birds due to the difficulty of the surgical procedure and the need for a duodenal tube with a large enough diameter to allow easy infusion of a liquid feeding formula.

### Total Parenteral Nutrition

Parenteral alimentation involves the intravenous administration of all essential nutrients including amino acids, lipids, carbohydrates, vitamins, electrolytes and minerals. Potential indications for the use of total parenteral nutrition (TPN) in birds include gastrointestinal stasis, regurgitation, some gastrointestinal surgeries, severe head trauma that precludes oral alimentation, malabsorption or maldigestion. In dogs, 50 to 60% of the calories are supplied by a 20% lipid solution, and the remaining calories are supplied by a 50% dextrose solution.<sup>28</sup> Daily protein requirements (1.5-6 gm/kg) are met by using amino acid supplements compounded into the TPN solution.

Difficulties associated with parenteral nutrition in birds include placing and maintaining a catheter, the necessity of multiple intermittent feedings to supply caloric requirements and potential metabolic complications associated with parenteral nutrition<sup>41</sup> (hypophosphatemia, hypo- or hyperkalemia, hyperglycemia and liver function abnormalities). Sepsis or bacteremia can occur from bacterial contamination of the catheter. Continuous infusion is the preferred method for administration of TPN, allowing for rapid dilution of the hypertonic solution, which minimizes irritation to the vascular endothelium.

The intraosseous cannula or a vascular access device can be used for parenteral alimentation.<sup>12</sup> Vascular access devices have been used experimentally for TPN in two geese.<sup>20</sup> The birds received the TPN

formula in four daily infusions of twenty to thirty minutes each using an infusion pump set at 5 ml/min. Both geese showed marked hematologic changes after receiving TPN, including heterophilic leukocytosis; increases in SGPT, AP, cholesterol and CPK; and decreases in glucose, bile acids and triglycerides. One goose died on the second day of TPN. Acute renal ischemia and necrosis were cited as the cause of death. Histopathologic, microbiologic and clinical parameters implicated inflammation and bacteremia secondary to *Staphylococcus aureus* contamination of the VAD. The second goose was maintained on TPN for four days with no clinical abnormalities. Necropsy showed minor changes in the kidneys that were not associated with uric acid elevations.

Total parenteral nutrition administered by VAD was successful when given experimentally in pigeons.<sup>12</sup> The TPN was administered in four daily infusions over a five-day period. Clinical changes were mild including weight loss, regurgitation, transient hyperglycemia, polyuria, glucosuria and tachycardia.

Because the nutritional requirements for avian patients are not known, formulation of TPN diets is primarily extrapolated from mammalian diets and the nutritional requirements of poultry. Enteric liquid diets are estimated to be 90% bioavailable, while TPN solutions are 100% available.

Typically a 10% amino acid solution<sup>i</sup>, a 20% lipid solution<sup>j</sup> and a 50% dextrose solution are used. The amino acid solution provides 100 mg protein/ml, the lipid solution provides 2 kcal/ml, and the dextrose solution, 1.7 kcal/ml. These three solutions can be mixed under clean conditions as a three-in-one TPN solution.<sup>20</sup> A 1000 ml bag of five percent dextrose solution is connected to an IV drip set and aseptically emptied. One day's supply of amino acid solution is injected through the port into the bag. The 50% dextrose solution is then added and mixed by inverting the bag. The lipid solution is added last. It should be added and mixed slowly over a two-minute period. This mixture should be used within 24 hours and should be stored in the refrigerator.<sup>20</sup>

### Nutritional Requirements

Illness and stress cause a hypermetabolic state in animals and humans. Release of catecholamines, glucagon and glucocorticoids increases the rate of gluconeogenesis and glycogenolysis. When the increase in metabolic rate is coupled with a decreased nutritional intake, fat oxidation occurs at a maximum rate, and body proteins are used as an energy

source.<sup>28</sup> Blood glucose concentrations are increased. Intravenous infusion of isotonic glucose has little sparing effect on body proteins, and may actually be detrimental by increasing the release of insulin.<sup>28</sup> The antilipolytic action of insulin may decrease the use of fat stores and increase body protein breakdown.

Protein demand is high during periods of hypermetabolism. Proteins are necessary for tissue repair, white and red blood cell production, maintenance of blood proteins (albumin, fibrinogen, antibodies) and enzyme production. During periods of high demand, the body uses fatty acids preferentially for energy to spare protein. In the management of human patients, more than 40% of the total kilocalories in many enteral diets are derived from fatty acids.

The size, weight, reproductive status and season all affect the daily caloric needs of birds. The basal metabolic rate (BMR) is the minimum amount of energy necessary for daily maintenance. An estimate of the BMR for birds can be made based on metabolic scaling:<sup>58</sup>

$$\text{BMR} = K(W_{\text{KG}})^{0.75}$$

Passerine birds K = 129  
Non-passerine birds K = 78

The K factor is a theoretical constant for kcal used during 24 hours for various species of birds, mammals and reptiles. The maintenance energy requirement (MER) is the BMR plus the additional energy needed for normal physical activity, digestion and absorption. The MER for adult hospitalized animals is approximately 25 percent above the BMR.<sup>28</sup> In passerine birds, MER varies from 1.3 to 7.2 times the BMR, depending on the energy needed for activity and thermoregulation during different times of the year.<sup>72</sup> With growth, stress or disease, animals are in a hypermetabolic state with daily energy needs that surpass maintenance. The amount of increased demand depends on the type of injury or stress and varies from one to three times the daily maintenance requirement (Table 15.4).

**TABLE 15.4 Adjustments to Maintenance for Stress (as multiples of MER)<sup>41</sup>**

Starvation	0.5 - 0.7
Elective Surgery	1.0 - 1.2
Mild Trauma	1.0 - 1.2
Severe Trauma	1.1 - 2.0
Growth	1.5 - 3.0
Sepsis	1.2 - 1.5
Burns	1.2 - 2.0
Head Injuries	1.0 - 2.0

Although not exact, metabolic scaling can be used to estimate the approximate daily caloric needs of birds.

### Enteral Nutritional Formulas

In humans, diets used for enteral nutrition are chosen based on the clinical condition of the patient. For birds, a formula should be used that supplies basic protein, fat and carbohydrates, and is adequate in meeting the energy requirements of the patient.

Commercial enteral nutritional formulas marketed for humans are widely available (Figure 15.7). These diets are usually liquid formulations sold in 250 ml containers. The diets vary in caloric density, protein, fat and carbohydrate content and osmolality (Table 15.5). Formulas vary from meal replacement formulas, which require some digestion, to monomeric diets, which require little or no digestion. Almost all diets are lactose-free and are approximately 95 percent digestible. These diets have been successfully used for routine nutritional support in sick birds via an enteral route. Knowing the exact caloric density per milliliter is convenient for calculating daily maintenance requirements. Formulas range from less than 1.0 to 2.0 kcal/ml. With a calorie-dense formula (2.0 kcal/ml), the total volume of liquid can be given in two to four feedings per day. Maintaining adequate hydration is important in birds when using calorie-dense formulas. Once opened, enteral formulas can be refrigerated for two to three days. For feedings, the formulas can be heated gently, such as in a syringe under hot running water.

### CLINICAL APPLICATIONS

#### Example of Metabolic Scaling to Estimate Approximate Daily Caloric Needs of Birds\*

An Amazon parrot weighing 350 grams is presented for septicemia secondary to bacterial enteritis. Estimating MER as 1.5 times BMR, the daily caloric needs can be estimated as:

- BMR =  $78(0.35^{0.75})$  or 35 kcal/day
- $1.5 \times 35$  kcal/day = 53 kcal/day approximate MER
- $1.2 \times 53$  kcal/day = 63.6 kcal/day increase for sepsis

If the energy content of the feeding formula is known, the daily caloric needs are divided by the calories per ml of formula to calculate the total volume of formula needed daily. For example, using a formula that is 1.5 kcal/ml, the total volume of formula needed per day for the Amazon is:

- $63.6$  kcal/day  $1.5$  kcal/ml = 42.4 ml needed daily

\*See Appendix for instructions on using this formula.



**FIG 15.7** Commercially available enteral nutritional products are superior to homemade formulas because they provide consistent nutritional and caloric content. Feeding needles can be used to deliver these products (courtesy of Kathy Quesenberry).

**TABLE 15.5** Commercial Enteral Products: Nutrients per 100 kcal\* Energy<sup>41</sup>

Product	Protein (g)	Fat (g)	Carbos (g)	kcal/ml
Isocal <sup>k</sup>	3.4	4.4	13.3	1.0
Isocal HCN <sup>k</sup>	3.8	5.1	10.0	2.0
Traumacal <sup>k</sup>	5.5	4.5	9.5	1.5
Pulmocare <sup>l</sup>	4.2	6.1	7.0	1.5
Ensure Plus <sup>l</sup>	3.6	3.5	13.0	1.5

\* kcal = calories

Formula may curdle in the crop of birds with ingluvititis and gastrointestinal stasis, probably because of changes in the pH of the crop. Flushing the crop with warm water while gently massaging the crop will cause the curdled formula to break apart, allowing aspiration and removal. Multiple feedings of small amounts of an isotonic or diluted formula should be given until the crop motility is normal.


Commercial enteral formulas marketed for use in birds are available. These diets are either dry powders or liquids. They are consistent in nutritional content, easy to prepare and use and relatively low in cost. In general, these diets are relatively high in carbohydrate content when compared to human products. Some products are low in calorie content. Powdered products can curdle or sludge in the crop, especially if an inadequate amount of water is used for mixing.

Some veterinarians prefer to blend their own feeding formulas. Combinations of monkey chow, baby cereal, strained baby vegetables, vitamin and mineral supplements and water are used. Plant enzymes are sometimes added to improve digestibility (see Chapter 18). Homemade formulas may work but have the disadvantage when compared to commercial products of varying consistency and nutritional and caloric content. Formulas based on baby cereal are usually high in carbohydrates and low in fat and protein. Many homemade formulas are too high in water content and provide insufficient levels of energy. Following the bird's weight on a daily basis (in grams) is the best evaluation of enteral feeding.

### Oxygen Therapy

An oxygen enclosure is highly recommended as standard equipment in an avian practice (Figure 15.8). There are several commercially available enclosures made specifically for use in birds. Most are designed as incubators with controls for heat and monitors for humidity. Human infant incubators with oxygen input ports can be adapted for use in birds. Oxygen levels within the enclosure can be monitored with an oxygen analyzer. Analyzers<sup>m</sup> are available with accuracy to within two percent. Administration of oxygen by face mask is effective for short-term treatment if an oxygen enclosure is not available, or during restraint while treatments or diagnostic tests are performed. If there is upper airway obstruction, oxygen can be infused through an air sac tube.

The actual benefits of oxygen supplementation in birds are unknown. Birds have a unique and efficient



**FIG 15.8** An oxygen enclosure should be standard equipment in any avian hospital (courtesy of Kathy Quesenberry).

respiratory system and may respond to oxygen supplementation differently than do mammals. Clinically, dyspneic birds appear to stabilize when placed in an oxygen enclosure and maintained at 40 to 50% oxygen concentration. Oxygen therapy is potentially toxic in mammals if given for prolonged periods at high concentrations. Oxygen can be supplemented in small animals at levels up to 100% for less than 12 hours without complications.<sup>65</sup> Canaries and budgerigars given continuous supplemental oxygen at concentrations of 82 to 100% and 68 to 93%, respectively, showed signs of lethargy, anorexia, respiratory distress and death after three to eight days.<sup>62</sup> Pathologic changes in the lungs included pulmonary congestion, histiocytic infiltration into the bronchi and deposition of proteinaceous material. Changes were consistent with those seen in mammals with oxygen toxicity.


Oxygen delivery to the tissues is dependent on adequate perfusion. Birds that are severely anemic or in circulatory shock need adequate volume expansion and red blood cell replacement for improved tissue oxygenation to occur.

#### Air Sac Tube Placement

Placement of an air sac tube is beneficial in birds with tracheal obstructions, or when surgery of the head is necessary. In companion birds the tube is normally placed in the caudal thoracic or abdominal air sac, allowing direct air exchange through the tube into the air sac. Following tube placement, dyspnea stops almost instantaneously in birds with upper airway obstruction. An air sac tube may also improve respiration in birds with air sacculitis, although the improvement in breathing is usually less dramatic (Figure 15.9).

An alternative site for air sac cannulation used in raptors is the interclavicular air sac.<sup>43</sup> In a study with Peking Ducks, there were no changes in heart rate, mean arterial blood pressure, PaO<sub>2</sub> or PaCO<sub>2</sub> when the clavicular air sacs were cannulated (see Chapter 39).<sup>47</sup> There were significant increases in the tidal volume and minute ventilation when compared to control birds. These increases may have resulted from a decrease in effective ventilation or an increase in respiratory dead space.

A shortened endotracheal tube, trimmed rubber feeding tube or plastic tubing from an IV extension set can be used for an air sac tube.<sup>54</sup> The diameter and length of the tube depend on the size of the bird. The tube can be placed in the lateral flank area in the



**FIG 15.9** A Sulphur-crested Cockatoo was presented with an acute onset of severe dyspnea. The bird was in excellent overall condition. The bird was anesthetized with isoflurane and an air sac tube was inserted in the abdominal air sac. The bird began to breathe normally within two to three minutes of inserting the air sac tube. An Ayres T-piece was connected to the air sac tube and the bird was maintained on 1.5% isoflurane delivered into the air sacs. A small plastic ball was identified in the rostral part of the trachea by endoscopy. A needle was passed through the trachea distal to the ball to prevent it from descending further down the trachea. The ball was removed by holding the bird upside down and using suction.

same anatomic location as for lateral laparoscopy, or caudal to the last rib with the femur pulled forward (Figure 15.10). The bird is placed in lateral recumbency, prepped with a surgical scrub and a small incision is made in the skin. Mosquito forceps are used to bluntly penetrate the muscle wall and enter the air sac. The end of the tube is inserted into the air sac between the opened jaws of the mosquito forceps. If the tube is patent, condensation will appear on a glass slide held over the end of the tube. Tape is placed around the tube in a “butterfly” fashion and sutured to the skin, or a fingertrap suture technique is used. If a shortened endotracheal tube is used, the cuff can be slightly inflated just inside the abdominal wall to form a secure seal.

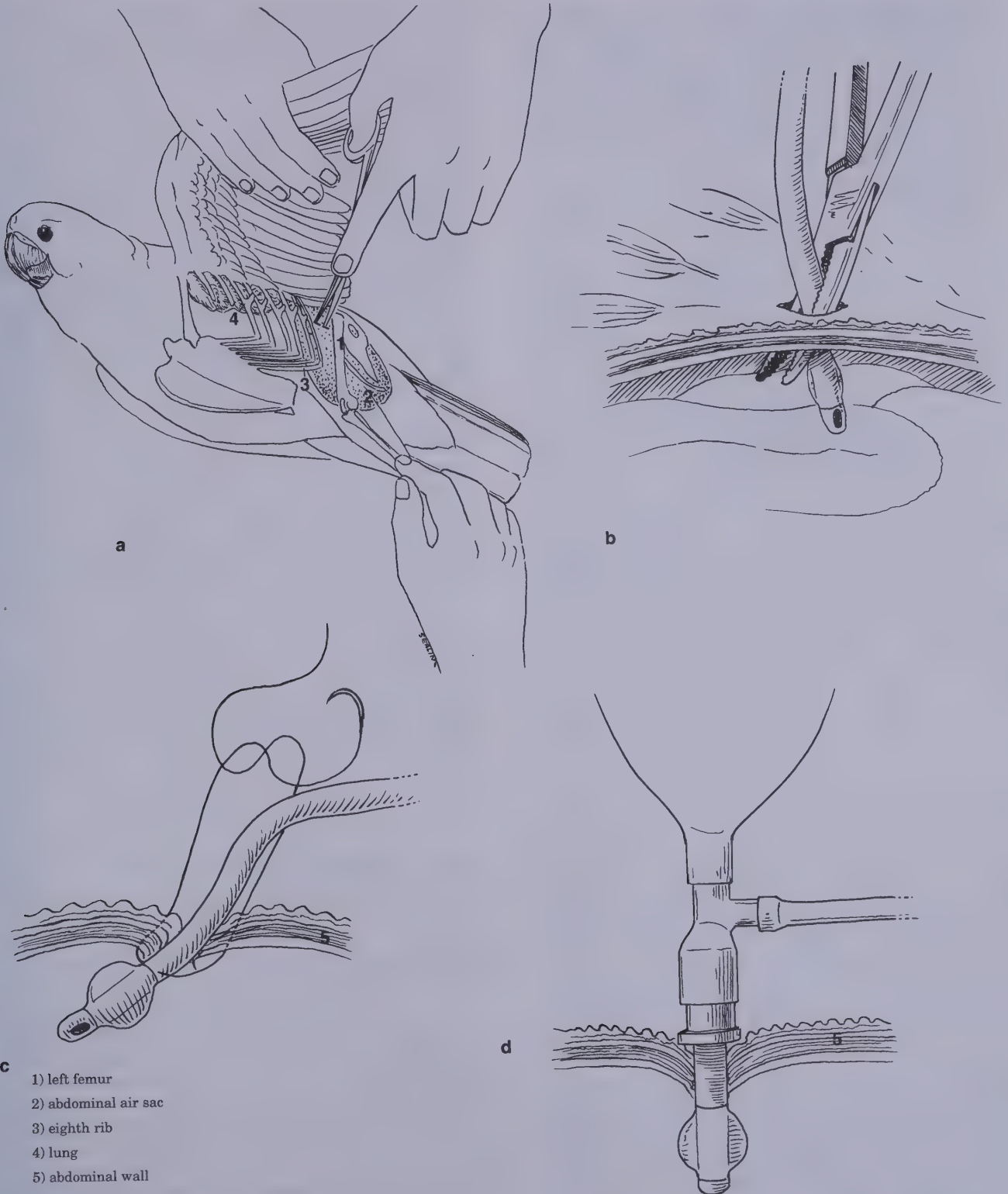
If placed correctly, the bird will immediately begin breathing through the tube. If anesthetized, the bird

#### CLINICAL APPLICATIONS

##### Air sac tubes can be used to:

- Alleviate dyspnea secondary to URD
- Deliver anesthesia for evaluation or surgery of the head or trachea
- Provide an immediate airway following apnea
- Deliver nebulized medications to a specific air sac





**FIG 15.10** Placement of a tube in the abdominal air sac can be used to provide oxygen or isoflurane anesthesia. **a)** The tube is placed by making a small skin incision in the area of the sternal notch. **b)** A pair of hemostats is passed through the body musculature and the air sac tube is inserted between the jaws of the hemostats. **c,d)** A cuffed endotracheal tube can be sutured to the body wall if the tube will remain in place for several days.

will become light unless the end of the tube is occluded or attached to the anesthesia machine. The air sac tube can be left in place for three to five days. The effect of direct exchange of room air into the air sac and the potential for introduction of contaminants and infectious organisms into the cannulated air sac are unknown.

An air sac tube allows many treatment techniques to be performed that would otherwise be impossible in a dyspneic bird. Liquid medications can be instilled directly into the trachea for the treatment of bacterial or fungal tracheitis. The bird can be anesthetized through the tube for surgery or endoscopy of the trachea or head, and the tube can be used for positive pressure ventilation or resuscitation. Birds can be nebulized with the air sac tube in place, possibly increasing the concentration of antimicrobials in the air sacs. If apnea occurs, a needle can be used in place of a tube for providing a rapid source of oxygen.

### Heat

A warm ambient environment is necessary for birds that are debilitated or in shock. Many commercial enclosures and incubators are available with floor or ceiling heating elements, side heating consoles or radiant heat systems. Floor heating elements may occasionally cause hyperthermia when debilitated birds are forced to stand or lie on the enclosure floor or in direct contact with the heating surface. Alternatively, heat can be provided by a hot water bottle or well insulated heating pad (preferably water). Birds receiving supplemental heat from any source other than a commercial incubator should be carefully monitored to prevent burns. Small, heated rooms that hold two to three enclosures allow birds to be treated in a temperature-stable environment, reducing the stress associated with being removed from a warm incubator to a cooler treatment area. It should be noted that none of the commercially available incubators with forced air heating systems can be properly sterilized with any procedure that does not involve the generation of formalin gas.

Enclosures should be equipped with thermometers to monitor ambient temperature. Many commercial enclosures also have humidity sensors. Ambient temperature for adult birds should be 85°F and humidity should be approximately 70%. Unfeathered baby birds less than ten days old need an ambient temperature of 94°F.<sup>25</sup> Older chicks can be maintained at 90°F. Birds in heated enclosures should be monitored

for hyperthermia, which is clinically suggested by panting and holding the wings away from the body.

### Housing

Many sick birds are too weak to perch. These birds should be placed in a smooth-sided enclosure or incubator without perches. Thick paper or non-woven towels can be used on the bottom of the enclosure. Many sick birds will not eat unless food and water are easily accessible. Seeds, fruits and vegetables can be spread around the bird to encourage eating. If the bird is still perching, food and water containers should be placed next to the perches to encourage food consumption. Millet spray is an attractive food item for many smaller species.

Although abrupt diet changes should not be attempted while the bird is sick, offering the bird a balanced diet in addition to any food it is accustomed to eating is appropriate, and may offer therapeutic benefits because of improved nutrient value. Food and water should be removed from the enclosure of birds that are seizing, obtunded or post-anesthetic to decrease the danger of aspiration or drowning.

Birds with leg fractures or paralysis are best maintained in a wire enclosure on thick cage paper or toweling. These birds will grasp the wire siding with their beak to steady themselves. If perches are provided, they should be close to the enclosure floor to prevent injuries.

## Emergency Problems

### Cardiovascular System

#### Bleeding and Anemia

The emergency clinician is often presented with bleeding birds and sick birds that are anemic. Anemia in birds may be caused by blood loss, decreased red blood cell production and increased red blood cell destruction. As in mammals, anemias can be classified as regenerative or non-regenerative.

The most common cause of blood loss in birds is trauma (Figure 15.11). Other causes include gastrointestinal (GI) bleeding, genitourinary bleeding, hemolysis and idiopathic hemorrhage. Hematochezia and melena may occur from enteritis, gastrointesti-


nal ulcers, coagulopathies, liver disease and GI foreign bodies. Cloacal bleeding may be caused by cloacal papillomas, cloacitis, egg laying, or cloacal or uterine prolapse. Heavy metal toxicity can cause hemolysis, which may result in dramatic hemoglobinuria in some birds, especially Amazon parrots. Conures may present for a sudden onset of weakness, ataxia, epistaxis, bloody regurgitation, bleeding from the oral cavity, hematochezia, hemorrhagic conjunctivitis or muscle petechiation.

Anemias resulting from decreased red blood cell production are common in birds, possibly because of the relatively short life-span (28 to 45 days) of the avian erythrocyte.<sup>22</sup> “Depression anemias” are usually caused by chronic infectious, toxic or nutritional disease. A rapidly fatal non-regenerative anemia seen in two- to four-month-old African Grey Parrots is suspected to be of viral etiology. Some birds with this problem have been shown to have polyomavirus or PBFD virus antigens in the bone marrow.

Diagnosis of anemia is based on clinical signs and documentation of a decreased PCV. Weakness is the most common clinical sign. Severely anemic birds may have a dull, almost dazed demeanor. Tachypnea and tachycardia may also be present. On physical examination, pallor of mucous membranes is evident in the oral cavity, palpebral conjunctiva and cloaca.

CBC and reticulocyte count, serum or plasma biochemistry analysis, blood heavy metal concentration and whole body radiographs should be considered in cases of anemia of unknown origin. Further testing might include chlamydia screening and a bone marrow aspirate. If an intraosseous cannula will be necessary for stabilizing the patient, a bone marrow sample can be obtained through the cannula at the time of placement. If the mucous membranes are pale, the PCV should be determined before drawing more blood. If the PCV is below 15%, further blood collection is inadvisable. It should be noted that the volume of serum or plasma relative to the volume of whole blood will be increased due to the anemia; the minimum amount of blood necessary to perform the desired diagnostic tests should be drawn.

If the bird is actively bleeding on presentation, localization of hemorrhage and hemostasis are the first priorities. Developing feathers are called “blood feathers” because of the rich vascular supply within the shaft. When one of these feathers is broken, it may continue to bleed until it is removed from its follicle. For removal, the base of the damaged feather



**FIG 15.11** A mature female Red-tailed Hawk was presented after being found in a forest dragging a steel jaw trap. All of the soft tissues surrounding the metatarsus were destroyed. The metatarsus was black. The bird was euthanized. Steel jaw traps are illegal in many states but are still used by poachers and individuals unconcerned with the inhumane destruction of free-ranging animals.

is identified by parting the surrounding feathers. The base is grasped firmly with hemostats, and the feather is removed from its follicle by gently placing opposing pressure on the structure around the feather base (Figure 15.12). If any bleeding occurs from the dermis, it can be controlled by applying pressure to the area or packing the follicle with surgical gel. Chemical or radiosurgical cautery<sup>o</sup> should not be used inside the feather follicle because the subsequent inflammation and tissue damage can cause abnormal feather regrowth, resulting in the formation of feather cysts.

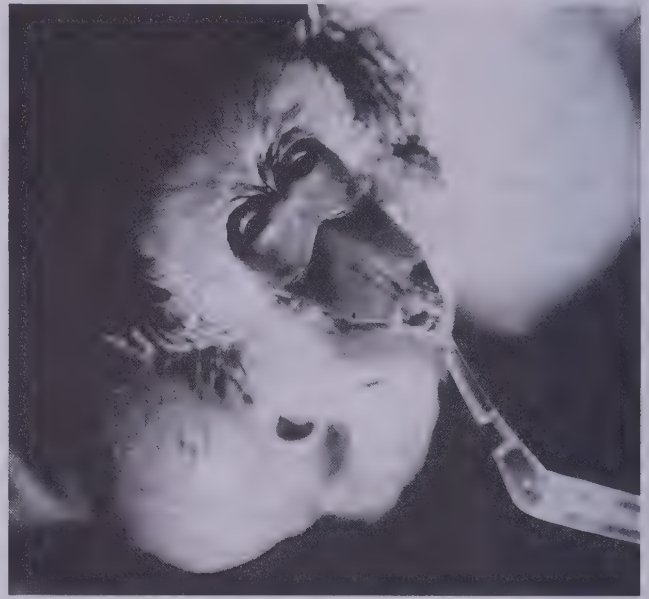For home first aid, the client can be advised to wash any blood away with hydrogen peroxide, apply cornstarch or flour to the bleeding area and place the bird in a dark area until it can be presented to the clinician for evaluation. Bleeding from a nail can be arrested using ferric subsulfate, silver nitrate or bipolar radiosurgery. Application of bar soap or heat from a red-hot item can also serve as first aid measures.



**FIG 15.12** Primary and secondary pin feathers have a substantial blood supply that arises at the base of the feather shaft where it is attached to the periosteum. Damaged pin feathers can result in substantial blood loss. Correctly removing the feather will allow the nutrient artery to collapse and will stop the bleeding. To remove a pin feather, the base of the feather is grasped with a pair of hemostats as close as possible to the skin edge. The skin is supported by applying gentle, opposing force around the feather base.

Persistent bleeding from soft tissue wounds is less common. If such bleeding occurs, it can be controlled by applying pressure to the area or through the use of bipolar radiosurgery. Surgical tissue adhesive<sup>b</sup> is often useful (Figure 15.13). Hemorrhage from oral and tongue lacerations may be difficult to control. Complete evaluation and suturing of these lacerations usually require general anesthesia.

The extent of blood loss can be gauged by the history or by the amount of blood present in the carrier. The capacity of birds to tolerate acute blood loss is often underestimated. In general, flighted birds tolerate blood loss better than mammals and non-flighted birds. Blood volume in birds averages ten percent of body weight. A healthy bird can lose as much as 30% of blood volume (about 3 ml/100 grams of body weight) with minimal clinical problems.<sup>44</sup> Because it



**FIG 15.13** Careful application of tissue adhesives can be used to control bleeding of the beak or nails. Glue applied to the beak must not be allowed to run into the mouth or onto the eyelids.

takes roughly 24 hours following hemorrhage for the PCV to equilibrate, measurement of the PCV two days after the onset of blood loss is most useful as a diagnostic and prognostic indicator.

Nonspecific treatment for blood loss includes volume replacement by subcutaneous or intravenous fluids, and the administration of iron dextran and B vitamins (see Chapter 18). The need for hospitalization and further supportive care depends on physical examination findings. Birds that are weak and in shock will require more aggressive therapy. Birds on an all-seed diet can be assumed to be nutritionally deficient and will benefit from an injection of vitamin K<sub>1</sub>.

In birds with idiopathic hemorrhage, such as in conure bleeding syndrome, injectable vitamin K<sub>1</sub>, vitamin D<sub>3</sub>, calcium and antibiotics are indicated. The etiology of conure bleeding syndrome is unknown, but it is possible that a dietary lack of vitamin K, calcium and other nutrients may alter normal clotting mechanisms.<sup>51,55</sup> If hemoglobinuria is present, treatment should be initiated with calcium disodium edetate (CaEDTA) for possible heavy metal toxicity (see Chapter 37). If clinical signs are being caused by heavy metal toxicity, there will usually be clinical improvement within six hours of initiating CaEDTA therapy.

The benefits of blood transfusions in birds are controversial. In pigeons that lost 70% of blood volume, it

was determined that fluid replacement with LRS was more effective in resolving anemia than iron dextran, homologous blood transfusions or heterologous blood transfusions. All study birds had a normal PCV within six days following acute blood loss. Heterologous transfusions from chickens were not an effective treatment, but the authors concluded that a homologous blood transfusion might be useful in birds with a PCV <20%.<sup>6</sup> A similar controlled study is needed to evaluate blood transfusions in psittacine birds. Until a controlled study is performed, it is probably valid to assume that homologous blood transfusions are preferable to heterologous, and that in most instances, a blood transfusion will not greatly increase the survival rate in acute blood loss. However, in the authors' experience, even heterologous blood transfusions appear to be clinically beneficial to birds suffering from chronic anemia. The goal of the transfusion is to stabilize the patient while diagnostic tests can be used to determine the etiologic agent of the anemia. A transfusion volume of roughly 10 to 20% of calculated blood volume is ideal. A rough cross-match can be performed by mixing red blood cells from the donor with serum from the recipient; the absence of gross agglutination or hemolysis suggests compatibility.

### Shock

The state of shock is difficult to determine in the avian patient. Clinical signs include weakness, pallor and poor perfusion of peripheral vessels. Vascular perfusion can be estimated by occluding the ulnar vein proximally on the medial surface of the wing and evaluating turgescence and filling time.<sup>1</sup> Decreased turgor and a filling time greater than 0.5 seconds are indications of reduced circulatory volume. Septic shock is a possibility in debilitated birds, and is clinically recognized as severe depression, particularly in birds with known exposure to infectious diseases.

Therapy for shock includes administration of fluids to expand the circulating blood volume and rapidly acting corticosteroids. If possible, corticosteroids and fluids should be administered intravenously or intraosseously. Intramuscular corticosteroids and subcutaneous fluids are beneficial but take more time to enter the circulation. In cases of shock, a state of metabolic acidosis may be present, and bicarbonate replacement therapy should be considered. Parenteral bacteriocidal antibiotics are given if bacterial infections are suspected.

### Cardiac Failure

The field of avian cardiology is in its infancy, and cardiac failure is rarely diagnosed antemortem. Suspicious clinical signs include weakness, anorexia, tachypnea, dyspnea, coughing and abdominal distension due to hepatomegaly and ascites. The diagnosis is suggested by finding an arrhythmia or murmur on auscultation, and by radiographic changes including cardiomegaly, hepatomegaly and ascites (Figure 15.14). A single IM dose of furosemide, low-dose subcutaneous fluids and an oxygen-rich environment are indicated. Electrocardiography and ultrasonography are used to confirm cardiac disease and guide the selection of other cardiac medications (see Chapter 27).<sup>35,48</sup>

### Cardiopulmonary Resuscitation (CPR)

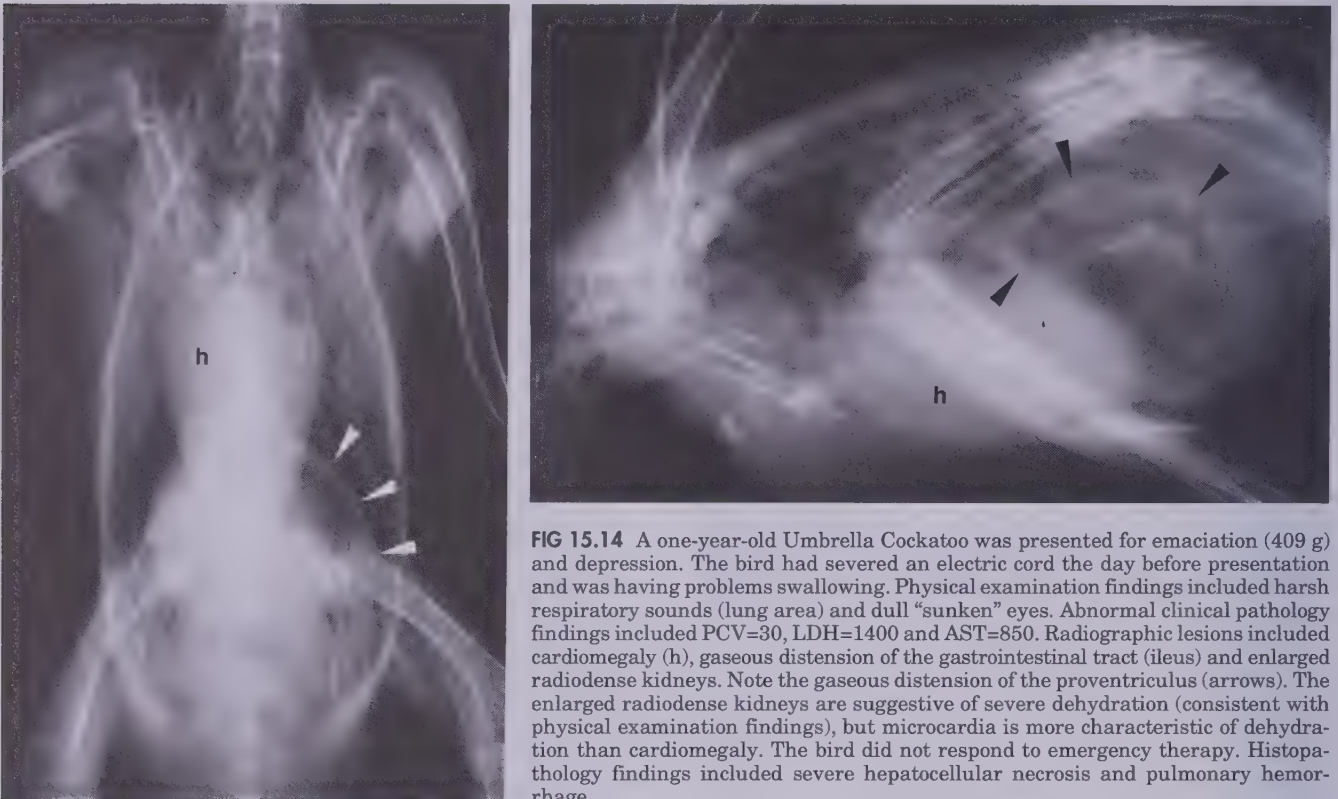
Avian CPR follows the same "ABC's" as mammalian CPR: Airway, Breathing and Circulation. In a bird that has stopped breathing, an airway must be established by placing an endotracheal or air sac tube. To avoid the danger of zoonotic disease, it is preferable to ventilate the bird in this fashion; alternatively, mouth-to-mouth respirations can be given by cupping the mouth over the bird's nares and beak opening. Positive pressure ventilation should occur once every four to five seconds. Once ventilation has been started, the heart beat or peripheral pulse should be determined. If neither is present, the heart should be massaged by firm and rapid compression of the sternum. Epinephrine and doxapram are given as necessary. The intratracheal, intracardiac or intraosseous routes (even spray into the thoracic cavity if open) for emergency drug administration should be considered when peripheral vascular access is not possible.<sup>24</sup>

Cardiopulmonary resuscitation should always be attempted in previously healthy birds that have collapsed; however, CPR is rarely successful in birds that are debilitated from long-standing, chronic disease.

## Gastrointestinal System

### Crop Burns and Injuries

Thermal burns of the crop are seen in hand-fed neonates, particularly psittacine birds. The most common cause is the occurrence of "hot spots" in poorly mixed microwaved formulas. Birds will accept the overheated formula without showing discontent. A few hours after feeding, an erythematous area of skin is evident overlying the crop, generally on the right ventral portion. If the bird has feathers in this area, the burn is often not noted unless the crop and skin



**FIG 15.14** A one-year-old Umbrella Cockatoo was presented for emaciation (409 g) and depression. The bird had severed an electric cord the day before presentation and was having problems swallowing. Physical examination findings included harsh respiratory sounds (lung area) and dull “sunken” eyes. Abnormal clinical pathology findings included PCV=30, LDH=1400 and AST=850. Radiographic lesions included cardiomegaly (h), gaseous distension of the gastrointestinal tract (ileus) and enlarged radiodense kidneys. Note the gaseous distension of the proventriculus (arrows). The enlarged radiodense kidneys are suggestive of severe dehydration (consistent with physical examination findings), but microcardia is more characteristic of dehydration than cardiomegaly. The bird did not respond to emergency therapy. Histopathology findings included severe hepatocellular necrosis and pulmonary hemorrhage.

necrose, leaving a fistula from which formula drains out onto the breast feathers (see Color 30).

The presence of a fistula is alarming to most owners; however, it is a true emergency only if the fistula is so large that all formula drains out of the crop, leaving the bird in danger of dehydration and starvation. The frequency of feedings may have to be increased in the interim in order to replace the formula lost through the fistula. If the burn is discovered soon after it occurs, the crop area should be monitored daily. The use of anti-inflammatories (eg, corticosteroids) represents more of a risk than a benefit in young birds (see Chapter 41).<sup>24</sup> Some periesophageal burns, lacerations and other injuries may not result in fistula formation and are recognized clinically as crop stasis. In some cases, the feeding instrument may have punctured the crop, and the food is deposited between the skin and the crop wall. This is a true emergency because the bird can suddenly become toxic, exhibit massive edema and die.

### Gastrointestinal Stasis

Gastrointestinal stasis is a common problem in pediatric medicine. Multiple factors that may affect GI motility in young birds include infectious disease, poor sanitation, low environmental temperature, low

formula temperature and low humidity. Physical obstructions are usually caused by foreign body ingestion (bedding is a common culprit) or accidental ingestion of a feeding tube. Causes of GI stasis in adult birds include gastroenteritis (leading to ileus), neuro-pathic gastric dilatation, heavy metal toxicity and obstruction (see Chapter 19).

Delayed crop emptying is the most common presenting sign of GI stasis. Regurgitation or vomiting may occur also. Fecal output is reduced. If allowed to persist, the bird becomes dehydrated, loses weight and may become septic. Chronic cases in debilitated birds can be difficult to manage and treat effectively, and the client should be advised that therapy may be lengthy and that the prognosis is poor.

Physical examination begins with an assessment of hydration status and thorough palpation of the crop for the presence of foreign bodies or inspissated food material. Some crop foreign bodies, particularly linear ones, can be removed by carefully manipulating them back up the cranial esophagus and into the oropharynx, where they are visualized and grasped with forceps. Removal of other foreign objects and inspissated food material is most easily accomplished via ingluviotomy (see Figure 41.13). The bird is anes-

thetized with isoflurane and intubated to reduce the danger of aspiration. A small incision is made over the left lateral pendulous crop to ensure that the incision is not damaged should the bird require tube-feeding. The incision is closed in two layers using a 6-0 absorbable suture. Postoperative feedings should be small and frequent, beginning with clear liquids and gradually increasing the strength and amount of formula over the next 24 to 48 hours until a normal feeding schedule has been resumed.

If a crop foreign body cannot be palpated, food and water should be withheld until the crop is empty or the crop can be drained by the clinician. Usually it is difficult to empty the crop via gavage tube because crop contents tend to become thickened when the crop is static. Some clinicians hold the bird upside down and express the crop contents.<sup>50</sup> The authors believe that this technique in unanesthetized patients puts the bird in risk of aspiration, and that even when used in anesthetized patients, a finger should be placed over the choanal slit during the procedure to prevent reflux from entering the nasal passages. Another technique is percutaneous aspiration of the crop using an 18 to 22 ga needle.<sup>24</sup> Flushing the crop with 0.05% chlorhexidine solution is often beneficial. This can be done two to four times daily if the bird can tolerate the handling. After flushing, a small amount of LRS, followed in three hours with dilute formula or Isocal,<sup>k</sup> should be administered by gavage tube.

Radiographs and a barium series are indicated if impaction or extraluminal obstruction is suspected, particularly in adult birds. Before the series is begun, the crop contents should be removed and the anesthetized bird should be held upright until the esophagus can be packed with moist gauze. A finger placed over the cranial esophagus will help prevent reflux from entering the pharyngeal area.

A minimum database should include cytology of the crop contents and fecal wet mounts (see Chapter 10). Samples can be collected by crop lavage or by passing a flexible swab directly into the crop. Culture and sensitivity of the crop contents and feces are indicated if bacterial infection is suspected. An in-house blood glucose determination is important if the bird is weak.

In birds with GI stasis, restoring and maintaining hydration with subcutaneous, intravenous or intraosseous fluids is important, and should be considered prior to performing surgery or other stressful proce-

dures. Parenteral antibiotics and metoclopramide<sup>n</sup> are often indicated (see Chapter 18). Oral medications are mostly ineffective because of slow passage into the intestinal tract. Oral aminoglycosides, however, may be beneficial in cases of bacterial overgrowth because they act locally with minimal absorption or side-effects. Parenteral feeding or placement of a duodenal feeding tube should be considered in critically ill birds (see Chapter 41).

Budgerigars with goiter often present with crop stasis and a history of regurgitation due to pressure of the enlarged thyroid glands on the caudal esophagus. These birds may also have a squeaky voice or an audible click with each respiration; tachypnea and tail-bob may be present. Diagnosis of goiter is based on clinical signs and history of an iodine-deficient diet. These birds should be hospitalized for parenteral fluids, steroids, antibiotics and iodine therapy. In mild cases, crop motility may be restored without the need for emptying and flushing the crop by gavage tube. Occasionally a bird may not respond to standard therapy, and thyroid gland neoplasia should be considered in these cases.

### Regurgitation and Vomiting

The distinction between regurgitation and vomiting in birds is often difficult to make clinically and, for the purposes of this section, the term regurgitation will be used.

Regurgitation to a "mate" (often the owner) or mirror is a normal part of breeding behavior; this is seen most commonly in budgerigars and cockatiels but can occur in any psittacine bird. A clinical history that includes intermittent regurgitation when the bird is being handled or talked to will help differentiate this normal behavior from a pathologic problem. Pathologic regurgitation in birds is caused by primary GI problems, metabolic problems and toxicities that induce nausea. Primary GI problems include infection (bacterial, viral, fungal and parasitic) and both intraluminal and extraluminal obstruction. Metabolic problems include hepatic and renal disease (see Chapter 19). Toxins that may cause vomiting include ingestion of some plants, pesticides and heavy metals such as lead or zinc. Some birds will regurgitate from stress or from motion sickness (such as during a car trip). Iatrogenic regurgitation may occur when the crop is over-distended with gavage formula and during recovery from chemical sedation or anesthesia.

Birds that are regurgitating will make a head-bobbing and neck-stretching type of motion. If the owner

does not observe or recognize this characteristic motion, a sign of regurgitation is finding food caked on the head feathers, giving the bird a spiky, “punk-hairedo” appearance (see Figure 19.7). A bird will often shake its head when regurgitating, depositing the regurgitus about the face and head. The bird should be evaluated for hydration, and the crop and abdomen should be palpated for distension or the presence of a foreign body or a mass. Goiter is the most common pathologic cause of regurgitation in budgerigars over two years of age. Bloody regurgitation may be seen in conure bleeding syndrome.

Initial diagnostic testing should include swabbing or flushing the crop for a wet mount, cytology, Gram's stain and culture. Fecal examination by wet mount and Gram's stain is often informative also. Other diagnostic tests to consider include a CBC, biochemistry profile and blood heavy metal concentration. Whole body radiographs, a routine barium series, or a double contrast study of the upper GI tract may be useful (see Chapter 12).

Initial stabilization of the regurgitating patient involves parenteral fluid therapy, removal of foreign bodies or toxins, specific toxin antidotes and appropriate antimicrobials if bacterial or fungal infections are suspected. Flushing the crop with 0.05% chlorhexidine reduces local bacterial levels in cases of ingluvitis.

#### Severe Diarrhea, Hematochezia and Melena

Diarrhea in birds is clinically recognized by unformed feces, often in association with an increase in the fluid portion of the dropping (see Color 8). Stools may “normally” be loose from stress, excitement, over-consumption of dairy products and ingestion of foods with a high water content (vegetables and fruits). Pathologic diarrhea usually results from bacterial, viral, fungal, chlamydial or parasitic gastroenteritis. The presence of a foreign body in the GI tract can also cause diarrhea. Pancreatic or liver disease and ingestion of some toxins may cause diarrhea. The differential diagnosis list for the emergency patient with diarrhea includes gram-negative enteritis, hepatopathy, chlamydial infection and heavy metal toxicity.

Physical examination of the bird with diarrhea should begin with careful evaluation of the hydration status and gross evaluation of droppings for evidence of blood, mucus, undigested food, plant material or gravel. Melena may be noted with problems of the upper GI tract (enteritis, foreign bodies, parasites,

ulcers). Hematochezia may be present with disease of the colon or cloaca. Cytology or a dip stick for fecal occult blood should always be used to document GI bleeding before aggressive and unnecessary therapy is instigated. The cloacal mucosa can be examined by prolapsing it gently with a well lubricated cotton swab (Figure 15.15). The presence of yellow or green urates suggests involvement of the liver. Brown, pink, red or rust-colored urates are seen most commonly with acute heavy metal toxicity, particularly in Amazon parrots (see Color 8). Birds consuming heavily pigmented fruits (eg, blueberries, blackberries) may have dark feces that mimics melena or hematochezia (see Color 8).

The database for diarrhea includes fecal examination by wet mount, Gram's stain and culture. Cytology for *Giardia* sp., *Trichomonas* sp. or other protozoa should be considered. Other valuable diagnostic tests include a CBC, biochemistry profile, radiographs, blood heavy metal concentration and screening for chlamydia.

Parenteral fluids should be administered to meet maintenance levels and replace estimated fluid volume lost to diarrhea. Debilitated birds may benefit from intravenous or intraosseous fluids and one dose of rapidly acting corticosteroids. Parenteral administration of a bacteriocidal antibiotic with a broad gram-negative spectrum is indicated because bacterial enteritis is common with diarrhea either as a primary cause or as a secondary problem.

#### Cloacal Prolapse

Prolapse of the cloacal mucosa is associated with masses within the cloaca, neurogenic problems or conditions causing tenesmus (eg, enteritis, cloacitis or egg-binding). Idiopathic prolapses are seen also.

A prolapsed cloaca may not be immediately apparent to the owner unless the bird is seen self-traumatizing the area or there is blood on the droppings. The history should include questions about diarrhea, straining or previous egg laying. Abdominal palpation for a mass and checking for prolapse of the ureters or uterus should be a priority during the physical examination. Cloacal tumors, such as adenocarcinomas, tend to be single and discrete. An irregular, “raspberry-like” appearance of the mucosa suggests cloacal papillomatosis (see Color 19).

Diagnostics and treatment are best performed with the bird relaxed under isoflurane anesthesia. Fecal retention is a problem with long-standing prolapses and with neurogenic etiologies (see Color 19). Man-





**FIG 15.15** A mature Amazon parrot was presented with chronic diarrhea. On physical examination, an accumulation of excrement was noted in the pericloacal area and on the tail feathers. The cloacal mucosa was examined using a moistened cotton-tipped applicator. A tentative diagnosis of papillomatosis was made by identifying small, pink nodules on the cloacal mucosa (courtesy of Elizabeth Hillyer).

ual massage of the caudal abdominal and cloacal regions promotes fecal evacuation. Parenteral fluid therapy and treatment for septic shock should be used in these cases.

A complete examination of the cloacal area must be performed. In larger birds, a vaginal speculum and strong light source permit examination deep into the cloacal region. Diagnostic tests to consider include fecal wet mount, Gram's stain, culture and radiographs. If cloacal papillomatosis is suspected, tissue excision with biopsy is necessary to confirm the diagnosis. A prolapsed cloaca caused by papillomas does not require a purse-string suture preoperatively. In fact, purse-string sutures in birds with cloacal papillomas may result in blockage of the cloacal opening and are thus contraindicated. Solitary tumors should be biopsied by excision if possible.

Prolapsed mucosa should be protected from damage and desiccation. The tissues should be flushed with saline and covered with a sterile lubricating jelly or ointment. The need for a retention suture will vary depending on the individual bird and the clinician's preferences. Retention sutures may complicate the prolapse by exacerbating straining and should be avoided if at all possible. If a retention suture is placed, it must not interfere with evacuation of the cloaca.<sup>24</sup> A cloacapexy may be necessary in some birds

that chronically prolapse (see Chapter 41). It is important to treat any possible underlying cause of prolapse such as hypocalcemia or other nutritional or metabolic problems.

### Liver Disease

As in mammals, liver disease is often difficult to diagnose and characterize in birds (see Chapter 20). Clinical signs of hepatitis are often nonspecific, including lethargy, inappetence, polyuria, polydipsia, diarrhea and ascites. Birds with ascites are often tachypneic or dyspneic. The presence of yellow or green urates is an indicator of probable liver disease (see Color 8). On physical examination, an enlarged liver may be palpable or, particularly in passerine birds, may be visible through the skin.

The basic database for suspected hepatitis includes a complete blood count, serum biochemistry profile, bile acids, fecal Gram's stain, fecal culture, cytology of the abdominal fluid, whole body radiographs and chlamydial testing.

While laboratory tests are pending, treatment for suspected liver disease includes basic supportive care, broad-spectrum antibiotics, oral lactulose and at least one dose of parenteral vitamin K<sub>1</sub>. Doxycycline is the drug of choice for chlamydiosis. Metronidazole, cephalosporins and the penicillins are the antibacterials of choice for small mammal hepatic infections. Investigations to determine the best antibiotics for avian hepatitis have not been performed.

### Pancreatic Disease

Primary pancreatitis is seldom diagnosed in birds, but is occasionally found at necropsy.<sup>17a</sup> Bacterial, viral and chlamydial infections of other organs may spread to the pancreas causing secondary problems. Acute pancreatic necrosis in an Umbrella Cockatoo<sup>38</sup> and pancreatic atrophy in a Blue and Gold Macaw<sup>40</sup> have been described. The underlying cause was not found in these two birds; however, it was speculated that obesity and a high-fat diet contributed to disease in the cockatoo.

Clinical signs of pancreatitis may include inappetence, lethargy, weight loss, polyuria, polydipsia, ab-

dominal distension and abdominal pain. Pancreatic exocrine insufficiency results in polyphagia, weight loss and bulky, pale droppings (see Color 8).

A CBC and a biochemical profile that includes amylase and lipase levels are indicated. In cases of acute pancreatitis, a radiograph may demonstrate a hazy or fluid-filled abdomen. Initial treatment should include aggressive parenteral fluid therapy and broad-spectrum antibiotics. One dose of rapidly acting corticosteroid may be beneficial in some birds. Plant enzymes (rather than canine pancreatic enzymes) can be added to the tube-feeding formula to help with digestion (see Chapter 18). Vitamin E and selenium should also be given, and the bird tested for zinc toxicosis.

## Urogenital System

### Egg Binding

Egg binding is most common in hens that are on a poor diet, are first-time egg layers or are prolific layers. Problems are most common and most severe in smaller species such as cockatiels, budgerigars and finches. Egg-laying is metabolically demanding, requiring large expenditures of protein, calcium and fat. Lack of sufficient dietary calcium, protein and trace minerals such as vitamin E and selenium will predispose to egg binding by resulting in soft-shelled eggs and uterine atony. Hypovitaminosis A is often a contributing factor due to alteration of mucosal integrity.

Clinical signs of egg binding include lethargy, inappetence, abdominal straining and remaining fluffed on the bottom of the enclosure. Owners often report "diarrhea." Droppings often tend to be large and wet due to cloacal relaxation associated with egg laying. In some birds there is a lack of droppings due to the egg's interfering with normal defecation. The owner should be questioned about previous egg laying activity and for clues that would suggest nesting behavior (eg, paper-shredding, hiding under papers or in dark places and nest building).

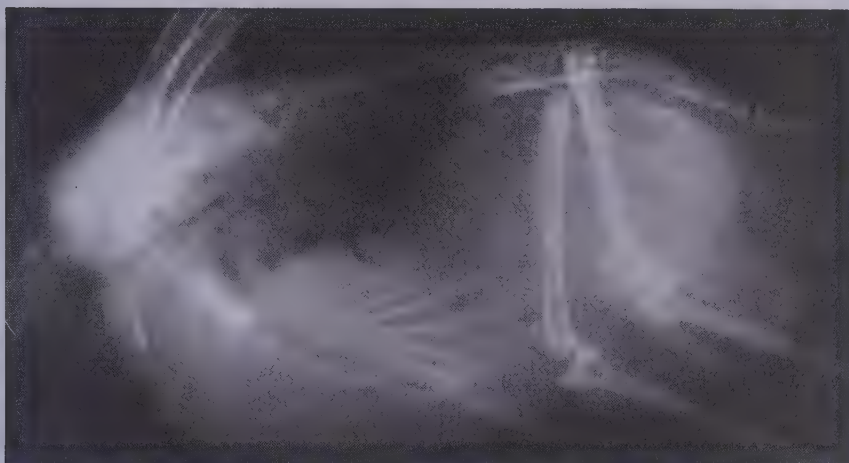
On physical examination, the hen may appear weak and quiet. Tachypnea is common. Unilateral or, less commonly, bilateral leg lameness or paresis occurs if the egg is pressing on the ischiatic nerve as it runs through the pelvic region. In most cases an egg is palpable in the abdomen. If the egg is poorly calcified, it may not be palpable but the abdominal region will be moderately swollen and soft. The cloacal region is often swollen also. Whole body radiographs can be

used to confirm the diagnosis. Medullary bone formation, also termed hyperostosis or osteomyelosclerosis, occurs under the influence of female reproductive hormones and is seen especially in the femur, tibiotarsus, radius and ulna (see Figure 12.65).


Occasionally, the presence of an egg with a non-calcified shell may be difficult to distinguish radiographically from egg-related peritonitis or an abdominal mass. In this case, a repeat radiograph approximately one hour after the administration of barium may aid in localizing internal structures. An alternative is to administer supportive care, calcium, vitamins and antibiotics, and then to repeat the radiograph one to two days later, assuming that an egg would have calcified or passed in that time period. Uterine rupture is possible, and will negate this last assumption (see Chapter 41).

Conservative medical treatment for egg binding is often successful and should always be given a chance to work before more aggressive therapy is instigated. Decisions regarding therapy should be based on the bird's clinical condition, but in most cases, it is best to allow up to 24 hours of medical therapy before initiating more aggressive steps. Even with paresis of a leg, it is best to attempt medical therapy first because the paresis usually resolves once the egg is passed. Small birds such as finches may require earlier intervention.<sup>19</sup> The real emergency associated with a retained egg is that it may place excessive pressure on internal pelvic structures, such as the caudal poles of the kidneys, where ischemic renal necrosis may occur (Figure 15.16). In contrast, some birds are not clinically ill from egg binding. An example is an egg-bound budgerigar that the authors treated medically for six months because the owners refused surgery.

Medical therapy for egg binding includes fluids, lubricating the cloaca, supplemental heat and parenteral calcium, vitamin A and vitamin D<sub>3</sub>. If the bird is anorectic, oral dextrose or a small gavage feeding may be given, and the bird should be placed in a warm, moist environment such as an incubator containing wet towels. (An old-fashioned, sometimes successful, therapy for egg binding is to submerge the caudal portion of the bird in a bowl of warm water for five to ten minutes!) After one or two doses of calcium, an injection of oxytocin may promote egg passage. Prostaglandin may be more effective in facilitating the passage of an egg than oxytocin (see Chapter 29).



**FIG 15.16** An adult Amazon parrot was presented with an acute onset of lethargy and mild dyspnea. Abnormal clinical pathology changes included WBC=22,400, Ca=28.5 and LDH=750. A hard mass, suspected to be an egg, was palpable in the caudal abdomen. Radiographs indicated a calcified egg in the caudal abdomen and hyperostosis. The high Ca level, elevated LDH activity and hyperostosis in the femur are all common with egg laying. This bird delivered a normal egg the day after evaluation.



**FIG 15.17** A cockatiel hen was presented for depression, straining to defecate and rear limb ataxia. A firm mass was palpable in the caudal abdomen and an egg could be visualized through the urodeum using a small otoscope cone. The bird was given five percent dextrose SC, calcium and oxytocin IM and the cloaca was lubricated with a water-soluble jelly. The bird was placed in a warm incubator. One hour later, the bird was re-evaluated and had not improved. The egg was gently pinched into the cloaca, the egg contents were removed with a needle and syringe, and the egg was collapsed. The fragments of the egg were removed with hemostats. The bird was given SC fluids and corticosteroids and placed back in the incubator. The bird had returned to normal and was eating within three hours (courtesy of Kathy Quesenberry).

If the egg has not passed in 24 hours, or if the bird appears to be weakening, two nonsurgical techniques can be considered. The first works best if the egg is low in the abdomen. With the bird under isoflurane anesthesia to achieve full relaxation, the egg may be manually pushed caudally so its tip is visible through the uterine opening into the cloaca (see Chapter 29).

An 18 to 22 ga needle is inserted into the egg, the egg contents are withdrawn, the egg is carefully imploded and the egg shell fragments are withdrawn using a small hemostat (Figure 15.17). Generally, the hen will pass any remaining egg shell fragments within several days.

The second technique is transabdominal aspiration of egg contents using a large gauge needle (see Chapter 29). The egg is manipulated to the ventral body wall and the egg contents are removed with a syringe. The egg is then gently imploded, relieving pressure on pelvic structures. Supportive care and calcium are continued until the bird delivers the egg shell on its own. Some clinicians flush the uterus for several days to prevent feces from contaminating the traumatized uterus. The positive or negative effects of this procedure have not been studied. The disadvantage of this technique is that occasionally a hen does not pass the egg shell fragments, necessitating a hysterectomy.

Surgical removal of the egg via laparotomy is necessary if the uterus is ruptured, if an egg cannot pass due to adhesions or other causes, or if there are multiple eggs (see Chapter 41).

### Uterine Prolapse

Uterine prolapse containing an egg is common, particularly in budgerigars. Occasionally the uterus will prolapse without the egg. Both conditions probably result from constant straining coupled with muscle weakness due to nutritional deficiencies or physical exhaustion.

The bird is anesthetized with isoflurane to allow careful examination of the prolapsed tissue. While the bird is anesthetized, SC or IV fluids, parenteral calcium, vitamins A and D<sub>3</sub> and a broad-spectrum bacteriocidal antibiotic are administered. One dose of a rapidly acting corticosteroid is appropriate if the bird appears to be in shock. The ureters, rectum and cloaca will sometimes prolapse with the uterus. The prolapsed tissue should be flushed with sterile saline and replaced with a lubricated blunt probang, sterile swab or other sterile, blunt instrument (see Color 29).

Oxytocin or prostaglandin (see Chapter 29) applied directly to the uterus will help reduce swelling and

control bleeding. If an egg is in the prolapsed tissue, the open end of the prolapse should be identified and the egg contents aspirated with a needle to gently collapse the egg. The egg is usually tightly adhered to the fine, transparent uterine tissue, which should be liberally moistened with warm sterile saline. A moist, sterile swab will help gently peel the uterine tissue from the egg without tearing. The prolapsed tissue should be flushed again and replaced as described. The need for a retention suture in the cloaca is based on clinical judgment.

The prognosis for recovery depends on the extent of tissue trauma. In the authors' experience, many hens respond well to therapy even if the replaced uterine tissue appears severely desiccated or inflamed. Antibiotic therapy for five to seven days is recommended. Any remaining necrotic areas should be exteriorized and amputated. The necrotic areas are sutured with 4-0 or 5-0 absorbable suture material, being careful to avoid the ureters.<sup>19</sup> Most birds will temporarily cease egg laying after the trauma and illness associated with uterine prolapse. After the bird is stable, a hysterectomy may be necessary to prevent future egg-related problems.

#### **Egg-related Peritonitis**

Egg-related peritonitis is thought to occur because of a failure of the ovum to enter the infundibulum. The peritonitis that occurs is usually sterile, but may be complicated by secondary bacterial infection. The condition is seen most commonly in cockatiels, lovebirds and budgerigars, but can occur in any hen.

The history usually includes a gradual onset of lethargy, weakness, inappetence, tachypnea and dyspnea. Nesting or egg-laying behavior often precedes the onset of illness. Occasionally, a bird will show no clinical signs other than tachypnea or dyspnea related to fluid accumulation in the abdomen. The clinical presentation of egg-related peritonitis varies with the species. Ascites is most common in cockatiels.

On physical examination, the bird is found to have a fluid-filled, distended abdomen. If the bird is dyspneic, it should be placed in an oxygen-rich environment prior to diagnostics and treatment. Abdominocentesis is performed with a 23 or 25 ga butterfly catheter or an appropriately sized needle and syringe (see Chapter 10). Only a sufficient volume of fluid to relieve the dyspnea should be removed. The needle is passed into the abdomen just below the end of the keel. Care should be exercised to prevent laceration

of the liver if hepatomegaly is suspected. Fluid drainage can be attempted from several sites, choosing avascular areas of skin. Fluid may range from yellow to rust-colored and may be clear or cloudy. More than one abdominocentesis may be necessary. Some veterinarians prefer to place a Penrose drain to allow a continuous port for fluid removal.<sup>19</sup>

Fluid analysis and cytology, a CBC and whole body radiographs should be performed. Radiographic changes are characterized by a fluid-filled abdomen with loss of detail. Increased ossification in the long bones suggests that calcium is being stored for impending ovulation. Parenteral fluids, a broad-spectrum antibiotic and an anti-inflammatory dose of corticosteroid should be administered. Although corticosteroids should be used with caution in birds, low-dose corticosteroid therapy for two to five days in conjunction with antibiotics appears to be beneficial in birds with egg-related peritonitis. A course of medroxyprogesterone acetate is a common companion therapy to steroids (see Chapter 29). A laparotomy and abdominal lavage may be necessary in birds with severe or non-responsive egg-related peritonitis (see Chapter 41).

#### **Renal Failure**

Renal failure is uncommonly diagnosed in avian medicine (see Chapter 21). Possible causes include some toxicities, ureteral obstruction and trauma (such as occurs with egg binding) and bacterial, viral, fungal or parasitic infections.

Clinical signs include polyuria, polydipsia, inappetence, depression and dehydration. Uric acid deposits may be visible on joint surfaces. The basic database consists of a CBC, biochemistry analysis, urinalysis, fecal Gram's stain and fecal culture.<sup>52</sup> Radiographs are useful to evaluate the size and density of the renal shadows. Uric acid deposits are radiolucent but renal mineralization will be visible on radiographs.

Emergency treatment consists of subcutaneous or intravenous fluids, antibiotics and a multi vitamin injection. The latter would be contraindicated if hypervitaminosis is suspected (eg, vitamin D toxicosis in macaws).

### **Respiratory System**

#### **Dyspnea**

Dyspnea in birds is characterized by open-mouthed breathing, prominent abdominal excursions and tail-bobbing with respiration. Causes of dyspnea can be

divided into two categories: primary respiratory and extra-respiratory disease. Primary respiratory disease occurs in the trachea, lungs or air sacs and may be caused by viral, bacterial, fungal, parasitic, chlamydial and mycoplasmal infections, inhaled toxins or foreign body aspiration. Extra-respiratory diseases can cause dyspnea by interfering with normal air flow patterns through the respiratory tree or by limiting expansion of the lungs and air sacs. This category includes thyroid enlargement, abdominal masses, abdominal fluid and oral masses such as papillomas. Birds with severe rhinitis, impacted nares, choanal atresia or sinusitis may also show open-mouth breathing and a tail-bob because they cannot breathe through the nares. Anemia may also induce dyspnea (see Chapter 22).

A thorough history should include questions regarding the possibility of exposure to other birds or to air-borne toxins, the possibility of foreign body aspiration and recent evidence of crop stasis or ileus, which may lead to aspiration. Before a dyspneic bird is handled, it should be carefully observed for conjunctivitis, swollen sinuses, nasal discharge and respiratory sounds. Budgerigars with goiter may have a high-pitched voice or a squeak with each respiration. These birds are also prone to crop-emptying problems and may have a dilated crop. Birds with infectious respiratory conditions often have conjunctivitis, swollen sinuses or nasal discharge. Mynah birds and toucans may develop cardiomyopathy or iron-storage hepatopathy, resulting in ascites and dyspnea. Egg binding or egg-related peritonitis should be considered as a cause of dyspnea if the bird has a history of egg laying. The bird should be placed in an oxygen-rich environment while diagnostic and treatment plans are being formulated.

Some birds may benefit from immediate placement of an air sac tube (see Figure 15.10) while diagnostic tests are performed. If a bacterial pneumonia or air sacculitis is likely, antibiotics may be administered by nebulization in order to minimize handling. Alternatively, the bird may be anesthetized with isoflurane to collect diagnostic samples and initiate therapy. Initial diagnostic tests should include radiographs, CBC, biochemistry profile, abdominal fluid analysis (if present) and tracheal wash. Birds with ascites or egg-related peritonitis will often improve once the abdominal fluid is removed. Early in the course of therapy, enough fluid should be withdrawn to relieve dyspnea and provide a diagnostic sample. In theory, sudden withdrawal of too much fluid can cause hypovolemia and shock;<sup>11,19</sup> however,

in practice, the authors have not experienced this problem. A 23 to 25 ga butterfly catheter or fine-gauge needle and syringe are used to aspirate from several sites through areas of avascular skin.

A tracheal wash should be performed just before the bird recovers from anesthesia. A sterile catheter or tube is passed into the tracheal opening. With the bird held parallel to the floor, sterile saline (up to 10ml/kg) is infused into the trachea and immediately aspirated. Cytology and bacterial and fungal culture can be used to evaluate the aspirated material.

General supportive care, including fluid therapy, heat, vitamins and nutritional support, is administered according to the patient's ability to withstand handling. Specific therapy is given according to the differential diagnosis (see Chapter 22).

### Acute Dyspnea

Acute onset of dyspnea in a previously healthy bird is usually due to one of three causes: 1) inhalation of a toxin, 2) plugging of the trachea by dislocation of an infectious plaque from the choana or tracheal bifurcation or 3) inhalation of a foreign body such as seed or bedding material. Inhalation of small seeds by cockatiels is common.

When a blockage of the upper respiratory tract is suspected, an air sac tube will provide immediate relief of dyspnea. The bird can be anesthetized by administering isoflurane through the air sac tube, making it possible to examine the trachea endoscopically. In smaller birds, transillumination of the trachea may be used to identify tracheal foreign bodies. Radiographs often demonstrate the site of obstruction and will also allow for evaluation of the lungs and air sacs. Removal of a tracheal foreign body is accomplished using suction or a biopsy forceps. In some cases it may be necessary to perform a tracheotomy by incising between tracheal rings just distal to the foreign material. The foreign body is retrieved with biopsy forceps or pushed up and out of the trachea using a blunt probang.<sup>19</sup>

### Air Sac Rupture

Rupture of an air sac often results in a balloon-like deformity of the skin (see Figure 22.11). While the clinical appearance is quite alarming to owners, the problem is rarely a true emergency. Rupture of a cervicocephalic air sac in small birds is most common. The rupture is usually acute, but gradual onset is seen also. Most birds are reported to be otherwise normal and the cause of the rupture is not identified.

On physical examination, a soft, air-filled swelling is palpable. The swelling will involve the head and neck region when the cervicocephalic air sacs are involved. A small needle and syringe can be used to aspirate some air and confirm the diagnosis. A medical workup should be considered if the bird is showing clinical signs of illness, particularly those associated with respiratory disease.

Initial treatment for air sac rupture involves making a percutaneous fistula to allow for continued drainage of air. This relieves pressure on the site of rupture to allow for healing. A rapid, simple technique is to use a hand-held ophthalmic cautery<sup>o</sup> to make a one to two centimeter opening in an avascular area of skin over the swelling, causing rapid deflation. Occasionally the swelling may recur when the fistula closes and the technique must be repeated, making a larger fistula. Surgical repair may be necessary in some birds if initial treatment fails (see Chapter 41).

## Neurologic System

### Head Trauma

Companion birds are often presented with head trauma caused from flying into ceiling fans, mirrors, windows and walls. Free-ranging birds may be injured by colliding with buildings, windows or automobiles.

Birds frequently recover from seemingly severe head trauma. Examination should include visual assessment for alertness and neurologic signs, an evaluation for shock, and examination of the cranium, eyes, nares and ears for evidence of fractures, hemorrhage or bruising. If the trauma is recent, treatment consists of IV or IM rapidly acting corticosteroid and placement of the bird in a dark environment maintained at a comfortable (cool) temperature. A warm environment may potentiate intracranial vasodilation. If the bird is in shock, IV fluids are given at one-half to two-thirds of the normal volume to avoid overhydration and cerebral edema. The use of diuretics is controversial in mammals with head trauma,<sup>59</sup> but mannitol or furosemide may be beneficial if the bird does not respond to initial therapy. Short-term monitoring consists of neurologic evaluation and measurement of blood glucose.

Birds may be presented with severe neurologic abnormalities from head trauma that occurred several days earlier. If the trauma occurred over 24 hours previously, an empirical course of antibiotics and short-term corticosteroids can be attempted, but this

is usually ineffective. Neurologic impairment may be permanent if the injury is several days old and no improvement is noted following 48 hours of therapy. Long-term corticosteroid therapy should be avoided in such birds.<sup>24</sup>

### Seizures

Although the study of avian neurology is in its infancy, most seizure disorders in birds can be managed effectively, even if the exact cause is not determined. Avian seizures have not been classified according to the criteria used in mammals; however, several different types of seizure activity are seen clinically. Mild seizures are characterized by a short period of disorientation with ataxia and inability to perch. Generalized seizures are characterized by a loss of consciousness, vocalizing, wing flapping and paddling. Partial seizures are characterized by persistent twitching or motor activity of the head or one of the extremities. They can be continuous and chronic, and frequently go unrecognized by the owner because they are less dramatic than generalized seizures.

Causes of seizures in birds include primary central nervous system (CNS) disease resulting from trauma, hyperthermia, vascular accidents, infection or neoplasia, and metabolic problems such as hypocalcemia, hypoglycemia, hepatoencephalopathy, toxin exposure and fat emboli. Idiopathic epilepsy, a diagnosis of exclusion, has been reported in Peach-faced Lovebirds, Red-lored Amazon Parrots, Double Yellow-headed Amazon Parrots and mynah birds.<sup>53,55,56,68</sup> A syndrome of hypocalcemia causing weakness and seizures occurs in African Grey Parrots.<sup>55</sup> Cockatiels and lovebirds may show neurologic signs with an undiagnosed, fear-induced mild flapping of the wings, or occasionally with chlamydiosis. Egg-laying birds often have severe lipemia and may develop fat emboli with resultant neurologic abnormalities including seizures and paralysis. Hypoglycemic seizures occur most commonly in raptors and neonates of other species.

The history should include questions regarding diet, egg laying and possible toxin exposure. Owners rarely can verify heavy metal exposure although it is common in psittacine birds due to their propensity for chewing on toys and household objects. Even toys manufactured expressly for birds should not be assumed to be safe.<sup>67</sup> If the bird is not actively seizing, a full physical and neurologic examination including a CBC, biochemical analysis and blood metal concentration should constitute the minimum database in most cases (see Chapter 37). Radiographs are

useful to evaluate bone quality and screen for metallic particles in the gastrointestinal tract. If the bird is weak or actively seizing, an in-house blood glucose test should be performed. Abnormal values are less than 50% of the published normal reference interval for the species (see Appendix).<sup>44</sup>

While laboratory results are pending, treatment for birds not actively seizing consists of general supportive care. If the bird is seizing on presentation, the first goal of therapy is to stop the seizure activity with IM or IV diazepam. Intravenous phenobarbital should be underdosed and used with caution in birds.<sup>19</sup> If lead or zinc poisoning is a possibility, treatment with CaEDTA should begin immediately. Hyperthermia should be evaluated and treated, and hypoglycemia should be corrected with IV dextrose. Suspected chlamydiosis or other infectious diseases should be treated accordingly.

Seizure activity associated with hypocalcemia is most common in African Grey Parrots and young birds on a poor diet. The African Grey hypocalcemic syndrome is thought to occur because of a lack of compensatory mechanisms to maintain serum calcium levels.<sup>55</sup> The syndrome may actually represent a deficiency of vitamin D<sub>3</sub>; however marginal dietary calcium levels seem to play a role.<sup>68</sup> These birds can have a serum calcium concentration as low as 2.5 mg/ml. Radiographically, the skeletal mineralization appears normal, indicating an inability to mobilize skeletal calcium. Other species that develop hypocalcemia will show decreased bone density, folding fractures and pathologic fractures. Treatment for hypocalcemia consists of parenteral calcium, vitamin D<sub>3</sub> and supportive care.

### Coma

Coma can result from head trauma, toxin ingestion, hyperthermia, CNS infection or neoplasia, cerebral ischemia due to a vascular accident, or severe metabolic disease such as hepatic encephalopathy or uric acidemia. The history should include questions related to the onset of clinical signs and possible trauma, toxin ingestion or inhalation (carbon monoxide) and exposure to viruses or parasites (eg, *Sarcocystis* spp., *Baylisascaris* sp.).

Ensuring a patient's airway and adequate ventilation are of primary importance. Establishing an airway with a tracheal or air sac tube and placing the bird in an oxygen-rich environment or applying positive-pressure ventilation may be necessary. The bird should be given dextrose IV if an in-house test indi-

cates hypoglycemia. Emergency treatment consists of IV fluids (low dose if cerebral edema is a possibility), parenteral corticosteroids and treatment for hyperthermia as necessary. The use of IV diuretics such as mannitol or furosemide should be considered in birds with head trauma and hyperthermia. Bacteriocidal antibiotics or doxycycline for chlamydiosis may be indicated in some patients. The bird should be placed in a dark, cool environment after treatment to discourage cerebral vasodilation and edema.

The prognosis for recovery depends on the patient's progress during the first two days of therapy. Supportive care should include lubrication of the eyes and frequent turning of the recumbent bird as necessary.

### Paralysis of Acute Onset

Paresis or paralysis of one or both legs is seen more commonly than problems with the wings. Possible causes of leg paresis include soft tissue trauma, fractures, osteoporosis, neural infections or vertebral trauma or neoplasia. Fractured leg bones are usually associated with reversible paresis of the foot and toes. Another cause of unilateral or, less commonly, bilateral leg paresis is pressure on the pelvic portion of the ischiatic nerve caused by egg binding or renal or gonadal tumors (see Color 25). Paresis of a wing is indicated by a wing droop. This is most commonly caused by soft tissue or bony trauma. Occasionally lead or other heavy metal toxicity will cause peripheral neuropathy resulting in wing or leg paresis.

A neurologic examination of affected birds should include assessment of cloacal tone, grasping strength of the feet and ability to move the tail (see Chapter 28). Muscles may undergo atrophy in the affected limb. The feathers should be parted with alcohol in order to examine the skin for evidence of bruising or wounds. This technique is useful for detection of fractures. The skin overlying the skull and spine should also be examined.

In many cases, the cause of the paresis or paralysis is evident on physical examination but radiographs may be useful to detect or assess intra-abdominal masses, metallic densities in the GI tract, coxofemoral luxations, or fractures of the spine, long bones or shoulder girdle. If heavy metal poisoning is a possibility, blood levels of lead or zinc can be determined.

Treatment is tailored to the specific condition. Egg binding and fractures are managed routinely. Paretic toes must be taped in the proper perching position to avoid knuckling and resultant damage to the top of the foot. One to three days of corticosteroid therapy

may be indicated in cases of head or vertebral trauma. In general, birds have a good capacity for return to function after the cause of the paresis or paralysis is resolved. An Amazon parrot with a pelvic plexus avulsion, incurred when its foot was trapped between the cage bars, had no perceptible sensation or function of the leg or foot. Treatment consisted of one dose of rapidly acting corticosteroid and seven days of a broad-spectrum antibiotic. A gradual return of sensation began around one month and the bird was back to normal at three months. It is impossible to predict the possibility of recovery with most avian neurologic injuries.

### Chronic Disease With Acute Presentation

Birds are able to hide subtle signs of disease from owners until illness is advanced. The most common avian emergency presented to avian clinicians is a chronically ill bird that has decompensated to the point where the owner finally becomes aware of the illness. These birds are usually debilitated, dehydrated and cachectic. It is important with these patients to minimize stress (eg, loud noises, bright lights and excess handling). These birds generally require therapy for severe dehydration and cachexia. Emaciated birds are frequently anemic. Some birds begin to eat on their own within a short time after the initiation of therapy. Birds that refuse to eat should receive an easily digestible enteral preparation such as Isocal-HCN.<sup>k</sup>

Occasionally a cachectic bird will be presented that is alert and relatively active with a good appetite. The owner may not be aware of the weight loss and may have brought the bird in for another problem. This is a common presentation in birds with tuberculosis and some neoplasias. Although the bird may appear strong, its body fat and glycogen stores are depleted and it may decompensate as easily as birds that appear weaker. Prognosis for cachectic birds is grave.

## Physical Injury

### Animal Bites

Birds that have been attacked by a mammal or another bird are often presented for emergency evaluation. Bite-induced injuries are typically of the crushing and tearing type, often necessitating surgical repair or debridement of damaged tissue (see Chapter 16). Mammal bites are usually from a pet dog or cat. These are true emergencies and require immediate attention due to the pathogenic oral bacteria that are introduced deep into bite wounds. Cat attacks, in particular, are especially dangerous because many

cats carry *Pasteurella multocida* on the gingival tissue and teeth.

Shock therapy is instituted if necessary. For a carnivore bite, treatment with a bacteriocidal antibiotic should begin immediately. Penicillins are the antibiotics of choice for cat bites because of their efficacy against *P. multocida*. All wounds must be flushed with copious volumes of warm sterile saline or 0.05% chlorhexidine. If they are difficult to find, small amounts of alcohol may be used to part the feathers, keeping in mind that there are usually two wounds, one from either jaw, associated with a bite. Puncture wounds must be left open for drainage, but large gaping lacerations may require partial closure.

### Burns

The most common burns in birds occur on the legs and feet. These result when free-flighted birds land in hot cooking oil, hot water or on a hot surface. Burns to the oral mucosa and tongue may occur when birds bite on electric cords (see Color 24).

The treatment for burns involves basic supportive care, topical therapy and prevention of secondary infection while the wounds are healing. Secondary invaders are typically *Staphylococcus intermedius*, streptococci, coliforms and *Pseudomonas* spp. Systemic antibiotics and corticosteroids should be avoided during initial therapy because their use may predispose the patient to immunosuppression and nosocomial infection.<sup>57</sup>

Diligent topical therapy is the key to burn management. The burned areas should be flushed with copious amounts of cool water or saline. Feathers surrounding the wounds should be removed to allow for aeration. Water-soluble, topical antibacterial creams such as silver sulfadiazine<sup>x</sup> should be used instead of greasy or oily medications. If the wound is not infected (Gram's stain of cleansed wound negative for organisms), a hydroactive dressing<sup>p</sup> is beneficial to prevent water loss and promote granulation tissue (see Chapter 16). Wounds should be flushed twice daily and debrided once a day.

Gram's staining and culture and sensitivity of burned tissue may be indicated to monitor for infection. Systemic antibiotic therapy is initiated based on positive culture results. In humans, early surgical closure of burn wounds is beneficial. Perioperative antibiotic therapy may prevent surgically induced bacteremia or endotoxemia.<sup>57</sup>



### Glue Traps

Free-flighted companion birds can become caught in glue traps intended for rodents. Trapped birds usually struggle, entangling many contour and primary feathers in the glue. Unless the bird can be removed from the trap with relative ease, the client should be instructed to bring the bird to the hospital still attached to the glue device.

Removing a bird from the glue entails gentle restraint of the body while freeing one extremity at a time. Feathers may be cut or gently removed. Shock therapy and supportive care should be given as needed. To prevent ingestion, the glue remaining on the bird must be removed before preening activity is allowed. Ether, acetone and water are ineffective. A commercial automobile protectant<sup>†</sup> is nontoxic and can be rubbed gently on affected feathers to remove the glue. This material can be rinsed away with warm water. These agents should be used with caution because some products contain lead (see Chapter 37).

### Exposure

#### Oil

The avian veterinarian may be called on to treat free-ranging birds caught in an oil spill, companion birds that have flown into household oils, or birds whose owners have applied greasy, over-the-counter medications as topical mite or wound therapies (see Color 24). Large quantities of oil on the feathers disrupt normal thermoregulatory mechanisms and may result in hypothermia and coma (Figure 15.18). Oil-contaminated birds may also suffer from blockage of the nares and conjunctivitis. Systemic toxicity and GI upset may occur if the oil is ingested during preening.

The goals of treating oil-soaked birds are to reverse shock, prevent or treat hypothermia, provide basic supportive care and remove the oil from the feathers, nares and oral cavity. The bird is wrapped in a towel or thermal blanket to conserve body heat, and shock therapy is initiated if needed. The eyes are lubricated and oil is removed from the nares and oral cavity with a swab. Depending on the bird's tolerance for restraint, it may be necessary to alternate rest periods in a dark, heated environment (95°F) with warm baths (100 to 105°F) to remove the oil. A commercial dish-washing detergent<sup>‡</sup> is a safe and effective solvent and is used in decreasing concentrations in sequential baths with thorough warm water rinses in between.<sup>71</sup> When the feathers are clean, the bird is dried with a blow-dryer and placed in a warm environment.



**FIG 15.18** The most life-threatening concern with an oil-contaminated bird is hypothermia. Oil should be removed from the nostrils and oral cavity with cotton-tipped applicators and from the feathers with repeated baths in warm dish-washing detergent (courtesy of J Assoc Avian Vet).

#### Hyperthermia

Panting and holding the wings away from the body indicate hyperthermia in birds. Birds do not have sweat glands and do not dissipate heat efficiently. If allowed to progress, hyperthermia results in ataxia, seizures and coma.

The first goal of emergency therapy is to reduce body temperature by placing the feet and legs in cool water and wetting the feathers down to the skin with water or alcohol. If the bird is severely overheated, cool water can be infused into the cloaca, taking care not to induce hypothermia by overzealous cooling. Flunixin meglumine may be used to reduce hyperthermia rapidly and safely. A bird in shock should be given low doses of IV or SC fluids, and one dose of rapidly acting corticosteroid. Mannitol or furosemide may help control cerebral edema.

#### Frostbite

Frostbite injuries in birds generally occur on the feet and toes, but may also occur around large metal identification bands that are exposed to freezing temperatures. If the injury is recent, the frozen tissues appear pale, dry and avascular, sometimes with a swollen area proximally. If left untreated, the frozen tissue will become necrotic with an erythematous line of demarcation separating it from viable tissue. Ascending infections and gangrene do not appear to be complications of frostbite in birds.

Treatment of a recent frostbite injury involves gradual warming of the extremity by placing the affected tissue in circulating water baths and increasing the water temperature over a 20- to 30-minute period. If

**QUICK REFERENCE FOR EMERGENCY TREATMENT****ANIMAL BITES**

- Parenteral penicillin ASAP
- Clean wounds

**BLOOD LOSS/ANEMIA**

- Stop bleeding
- Volume replacement (IV or IO fluids)
- Iron dextran
- B vitamins
- Vitamin K<sub>1</sub>
- Blood transfusion (PCV <20%)

**BURNS**

- Gently remove feathers
- Clean wounds
- Antimicrobial creams
- Hydroactive dressing if not infected

**CACHEXIA**

- Fluids - IV or IO
- 5% dextrose IV or IO
- Oral or parenteral alimentation

**COMA**

- Ensure patent airway
- Oxygen-rich environment
- Low dose fluids if dehydrated
- Single-dose corticosteroids
- Mannitol or furosemide

**CPR**

- Establish airway - air sac tube
- Ventilate every 4 to 5 secs
- Rapidly press on cranial sternum
- Epinephrine and doxapram IC, IO, IT

**DIARRHEA**

- Fluids (IV, IO)
- Bactericidal antibiotics
- Shock therapy if necessary

**DYSPNEA**

- URD - air sac tube
- Oxygen-rich enclosure
- Removal of some ascitic fluid
- Remove tracheal foreign bodies (suction or surgery)

**EGG BINDING**

- Medical therapy initially:
  - Subcutaneous fluids
  - Lubricate cloaca
  - Prostaglandin
  - Parenteral calcium and oxytocin
- Dextrose
  - oral (50%)
  - SC (5%)
- Vitamins A and D<sub>3</sub>
- Supplemental heat

- If medical therapy fails:
  - Assisted cloacal delivery
  - Percutaneous oocentesis
  - Ventral laparotomy

**FROSTBITE**

- Gradual warming in water bath
- Increase temperature

**HEAD TRAUMA**

- Corticosteroids - IV, IO
- Dark, cool environment
- Minimal fluids - correct shock only

**HYPERTHERMIA**

- Wet with cool water
- Flunixin meglumine
- Mannitol
- Single dose corticosteroids
- Dry and keep at 85°F

**LIVER DISEASE**

- Fluids (IV, IO)
- Lactulose
- Vitamin K<sub>1</sub>
- Doxycycline - if suspect chlamydia
- Parenteral penicillin - if suspect bacteria

**OIL**

- Shock therapy
- Prevent hypothermia
- Bathing in warm detergent

**PANCREATITIS**

- Fluids (IO)
- Bactericidal antibiotics
- Single-dose corticosteroids
- NPO if possible

**PROLAPSED CLOACA**

- Keep tissues moist and clean
- Replace cleansed tissue
- Correct underlying urogenital or GI problem
- Retention suture if necessary

**PROLAPSED UTERUS**

- Clean with sterile saline
- Topical oxytocin or prostaglandin to reduce swelling
- Lubricate with water-soluble gel
- Replace with blunt probang
- Retention suture if necessary

**REGURGITATION**

- Fluids (IV, IO)
- Remove foreign bodies or toxins
- Gastric lavage
- Specific toxin antidotes
- Appropriate antimicrobials

**SEIZURES**

- Diazepam - IV or IM
- Supportive care
- African Grey Parrots - calcium and vitamin D<sub>3</sub>
- Raptors and neonates - glucose if needed

**SHOCK**

- Fluids (IV or IO)
- Corticosteroids (IV or IO)
- Bicarbonate if acidotic
- Bactericidal antibiotics if septic

**SUPPORTIVE CARE**

- Fluids
- Heat
- Vitamin/mineral supplements
- Nutritional support

**TOXINS**

- Treat for shock
- Remove ingested foreign bodies
- Oxygen for inhaled toxins
- Specific antidotes (see Chapter 37)

the tissue becomes necrotic, it can be surgically amputated at a later date (see Chapter 41).

**General Emergency Principles of Toxin Exposure**

Toxicity problems in companion birds are extremely common, with heavy metal poisoning leading the list.<sup>24</sup> Toxins that may enter by the alimentary route include lead, zinc and other heavy metals, various plants, rodenticides and some foods like chocolate (see Chapter 37). Birds are also very sensitive to aerosolized toxins, which include overheated polytetrafluoroethylene (Teflon or other non-stick coatings), tobacco smoke, hair spray, pesticides, paint fumes, naphthalene, ammonia and carbon monoxide. Leaded fumes or dust can cause lead toxicity by inhalation in mammals. Iatrogenic drug toxicities may occur due to species or individual differences in drug metabolism or errors in administration or dosing.

Ingestion of prey animals or contaminated water may expose free-ranging birds to potential toxins, the most common being organophosphates, botulism toxin and lead.<sup>39</sup>

Clinical signs of toxicity vary widely and may include depression, anorexia, diarrhea, regurgitation, dyspnea and neurologic signs including ataxia, seizures, head tilt and peripheral neuropathy. Amazon parrots may have hemoglobinuria with acute lead toxicity. Occasionally a bird will be exposed deliberately or allowed unrestricted access to substances such as chocolate, alcohol or marijuana. Careful and specific questioning is usually necessary to delineate potential toxin exposure.

The first step in treatment of any toxin exposure is to stabilize the patient as necessary with shock and anticonvulsant therapy. If a known toxin was recently ingested, a crop lavage is the quickest method of removal. An ingluvotomy may be necessary to remove solid toxins (see Chapter 41). If more than one-half hour has passed since ingestion, a poison control center should be contacted (see Chapter 37).

Most often, an exposure to a specific toxin cannot be identified. A CBC and biochemistry analysis, blood lead and zinc concentration and radiographs are indicated. Nonspecific treatment for suspected toxicosis includes decreasing further absorption of the toxin from the GI tract, hastening elimination of the toxin and providing supportive care. If heavy metal toxicity is a possibility, treatment with Ca EDTA should be initiated.

**TABLE 15.6 Suggested Equipment for Avian Emergency Practice (items not commonly found in a standard small animal practice)**

- Incubator with temperature control, temperature and humidity sensors, oxygen port
- Nebulizer (ultrasonic)
- Anesthesia machine with isoflurane
- Radiosurgical unit
- Hand-held ophthalmic cautery devices
- 5-0 and 6-0 absorbable and nonabsorbable suture material
- Endotracheal tubes (2.0 and larger)
- Pre-sterilized air sac tubes of different sizes (shortened endotracheal tubes, red rubber tubes, others)
- 18 to 22 ga spinal needles (for use as intraosseous cannulas)
- 24 ga short, indwelling catheters
- 25 ga butterfly catheters with 3.5 inch tubing
- Buretrol or Control-a-Flow extension sets
- Low-dose insulin syringes (for accurate measuring down to 0.01 cc)
- Leg band cutters
- Metal feeding needles
- Various sizes of red rubber tubes (for crop and GI lavage)
- Catheter-tipped syringes
- Catheter-tip adapters
- Enteral feeding formula
- Seeds, millet, other foods for inpatients

If the ingested toxin is still in the GI tract, lavage is performed with saline or activated charcoal. Crop, proventricular and ventricular lavage are best performed with the bird intubated and under isoflurane anesthesia. A tube is passed into the proventriculus per os or a small crop incision is made and a red rubber tube is passed distally. The bird can be held with the head tilted down, and foreign objects and toxins can be retrieved by flushing.<sup>67</sup> The administration of activated charcoal helps to bind toxins and decrease GI absorption.

Saline and osmotic cathartics are used to speed elimination of toxins. Saline cathartics (eg, sodium sulfate [Glauber's salt]) will precipitate heavy metal in the GI tract, decreasing absorption. Psyllium is an osmotic cathartic.<sup>29</sup> For specific toxin therapies see Chapter 37.

#### Products Mentioned in Text

- a. Metamucil, Proctor and Gamble, Cincinnati, OH
- b. Nexaband, Tri-point Medical, Raleigh, NC
- c. Buretrol Add-On Set, Baxter Healthcare Corp, Deerfield, IL
- d. Baxter Healthcare Corp, Deerfield, IL
- e. Vibramycin Hyclate Intravenous, Roerig Division, Pfizer, Inc, New York, NY
- f. Vibravenös, Pfizer, Inc, Zurich; London, Ontario
- g. Boehringer Mannheim Corp, Indianapolis, IN
- h. PEP-E, Phylomed, Plantation, FL
- i. Animosyn II, Abbott laboratories, North Chicago, IL
- j. Liposyn II, Abbott Laboratories, North Chicago, IL
- k. Mead Johnson Nutritionals, Evansville, IN
- l. Ross Laboratories, Columbus, OH
- m. OXA-10 oxygen analyzer, Avtech Systems, San Diego, CA
- n. Reglan, AH Robins, Cherry Hill, NJ
- o. Storz Sure-Temp Surgical Cautery, Storz Instrument Co., St. Louis, MO
- p. DuoDerm hydro-active dressing, Convatec, Squibb, Canada
- q. Armor All Protectant, Armor All Products Corp., Irvine, CA
- r. Dawn dish detergent, Proctor and Gamble, Cincinnati, OH
- s. Lipomul, The Upjohn Company, Kalamazoo, MI
- t. Leadcheck Swabs, Hybrivet Systems, Framingham, MA
- u. Injacom-100, La Roche, Nutley, NJ
- v. Spinal needles, Baxter, Valencia, CA
- w. Gatorade, Gatorade Co., Chicago, IL
- x. Silvadene, Marion Labs Inc., Kansas City, MO

#### References and Suggested Reading

1. **Abou-Madi N, Kollias GV:** Avian fluid therapy. In Kirk RW, Bonagura JD (eds): Current Veterinary Therapy XI. Philadelphia, WB Saunders Co, 1992, pp 1154-1159.
2. **Bagley RS, Flanders JA:** The use of totally implantable vascular access systems. *Comp Cont Pract Vet* 12(1):22-27, 1990.
3. **Bartholomew GA, Cade TJ:** The water economy of land birds. *Auk* 80:504-539, 1963.
4. **Birrenkott GP, Wiggins ME:** Determination of dexamethasone and corticosterone half-lives in male broilers. *Poult Sci* 63:1064-1068, 1984.
5. **Band M: IME:** Intravenous catheter placement. *J Assoc Avian Vet* 6(1):40, 1992.
6. **Bos JH, et al:** Treatment of anemic birds with iron dextran therapy: Homologous and heterologous blood transfusions. *Proc Assoc Avian Vet*, 1990, pp 221-225.
7. **Bracken JM, et al:** A randomized controlled trial of methylprednisolone or naloxone in the treatment of acute spinal cord injury. *New Engl J Med* 58:1405-1411, 1990.
8. **Brown SA, Hall ED:** Role of oxygen-derived free radicals in the pathogenesis of shock and trauma, with focus on central nervous system injuries. *J Am Vet Med Assoc* 200(12):1849-1858, 1992.
9. **Burns RB, Baker B, Birrenkott GP:** Half-life of dexamethasone and its effect on plasma corticosterone in raptors. *Proc Joint Conf Am Assoc Zoo Vet & Am Assoc Wildlife Vet*, 1988, pp 12-13.
10. **Coles BH:** Cloacal prolapse: A recurrent emergency for the practitioner. *Proc Euro Assoc Avian Vet*, 1991, pp 323-331.
11. **Campbell TW:** Cytology of abdominal effusions. In *Avian Hematology and Cytology*. Ames, Iowa State University Press, 1988, pp 41-44.
12. **Degernes LA, et al:** Preliminary report on the use of total parenteral nutrition in birds. *Proc Assoc Avian Vet*, 1992, pp 1-2.
13. **Dorrestein GM:** The pharmacokinetics of avian therapeutics. *Vet Clin No Am Sm Anim Pract* 21(6):1241-1264, 1991.
14. **Duke GE:** Alimentary canal: Anatomy, regulation of feeding and motility. In Sturkie PD (ed): *Avian Physiology*. New York, Springer-Verlag, 1986, pp 289-302.
15. **Dunston WA, Buss EG:** Abnormal water balance in a mutant strain of chickens. *Science* 161:167.
16. **Flammer K:** Psittacine antimicrobial pharmacokinetics: An introduction to enrofloxacin. *Proc Assoc Avian Vet*, 1989, pp 1-2.
17. **Goring RL, et al:** Needle catheter duodenostomy: A technique for duodenal alimentation of birds. *J Am Vet Med Assoc* 189:1017-1019, 1986.
- 17a. **Graham DL, Heyer CW:** Diseases of the exocrine pancreas in pet, exotic and wild birds: A pathologist's perspective. *Proc Assoc Avian Vet*, 1992, pp 190-193.
18. **Harrison GJ:** What to do until a diagnosis is made. In Harrison GJ, Harrison LR (eds): *Clinical Avian Medicine and Surgery*. Philadelphia, WB Saunders Co, 1986, pp 356-361.
19. **Harrison GJ, et al:** Symptomatic therapy and emergency medicine. In Harrison GJ, Harrison LR (eds): *Clinical Avian Medicine and Surgery*. Philadelphia, WB Saunders Co, 1986, pp 362-375.

20. **Harvey-Clark C:** Clinical and research use of implantable vascular access ports in avian species. *Proc Assoc Avian Vet*, 1990, pp 191-209.
21. **Haskins SC:** Management of septic shock. *J Am Vet Med Assoc* 200(12):1915-1924, 1992.
22. **Hoefler H:** Transfusions in exotic species. *Prob Vet Med* 4:625-635, 1992.
23. **In my experience,** roundtable discussion: Clinical therapy. *J Assoc Avian Vet* 5(4):186-191, 1991.
24. **In my experience,** roundtable discussion: Emergency medicine. *J Assoc Avian Vet* 6(1):10-15, 1992.
25. **Joyner KL:** Avicultural emergency medicine. *Proc 60th World Vet Conf*, 1988, pp 390-398.
26. **Kaufman GE, Paul-Murphy JR, Finnegan M:** Preliminary evaluation of the effects of dexamethasone on serum hepatic enzymes, glucose and total protein in red-tailed hawks. *Proc Assoc Avian Vet*, 1988, pp 14-20.
27. **King AS, McLelland J:** Respiratory system. *In* Birds: Their Structure and Function. London, Baillière Tindall, 1984, pp 110-144.
28. **Labato MA:** Nutritional management of the critical care patient. *In* Kirk RW, Bonagura JD (eds): *Current Veterinary Therapy XI*. Philadelphia, WB Saunders Co, 1992, pp 117-124.
29. **LaBonde J:** Avian toxicology. *Vet Clin No Amer Sm An Prac* 21(6):1329-1342, 1991.
30. **Lamberski N, Daniel GB:** Fluid dynamics of intraosseous fluid administration in birds. *J Zoo Wildlife Med* 23(1):47-54, 1992.
31. **Lumeij JT:** Plasma urea, creatinine and uric acid concentrations in response to dehydration in racing pigeons. *Avian Pathol* 16:377-382, 1987.
32. **Lumeij JT, de Bruijne JJ:** Evaluation of the refractometric method for the determination of total protein in avian plasma or serum. *Avian Pathol* 14:441-444, 1985.
33. **Martin HD, Kollias GV:** Evaluation of water deprivation and fluid therapy in pigeons. *J Zoo Wildlife Med* 20(2):173-177, 1989.
34. **Mautino M:** Avian lead intoxication. *Proc Assoc Avian Vet*, 1990, pp 245-247.
- 34a. **McCluggage DM:** Basic techniques in avian medicine. *Proc Mid-Atlantic States Vet Conf*, 1992.
35. **Miller MS:** Avian cardiology. *Proc Assoc Avian Vet*, 1986, pp 87-102.
36. **Otto CM, Crowe DT:** Intraosseous resuscitation techniques and applications. *In* Kirk RW, Bonagura JD (eds): *Current Veterinary Therapy XI*. Philadelphia, WB Saunders Co, 1992, pp 107-112.
37. **Perry-Clark LM, Meunier LD:** Vascular access ports for chronic serial infusion and blood sampling in New Zealand white rabbits. *Lab An Sci* 41(5):495-497, 1991.
38. **Phalen DN:** Acute pancreatic necrosis in an umbrella cockatoo. *Proc Assoc Avian Vet*, 1988, pp 203-205.
39. **Poppenga RH:** Common toxicosis of waterfowl, loons and raptors. *In* Kirk RW, Bonagura JD (eds): *Current Veterinary Therapy XI*. Philadelphia, WB Saunders Co, 1992, pp 183-188.
40. **Quesenberry KE, Liu S:** Pancreatic atrophy in a blue and gold macaw. *J Am Vet Med Assoc* 189(9):1107-1108, 1986.
41. **Quesenberry KE:** Avian nutritional support. *In* Kirk RW, Bonagura JD (eds): *Current Veterinary Therapy XI*. Philadelphia, WB Saunders Co, 1992, pp 1160-1162.
42. **Redig PT:** Fluid therapy and acid base balance in the critically ill avian patient. *Proc Assoc Avian Vet*, 1984, pp 59-73.
43. **Redig PT:** Management of medical emergencies in raptors. *In* Kirk RW, Bonagura JD (eds): *Current Veterinary Therapy XI*. Philadelphia, WB Saunders Co, 1992, pp 1134-1138.
44. **Ritchie BW:** Emergency care of avian patients. *Vet Med Report* 2:230-245, 1990.
45. **Ritchie BW:** Avian therapeutics. *In*: Introduction to Avian Medicine and Surgery. *Assoc Avian Vet*, 1991, pp T2:1-18.
46. **Ritchie BW, et al:** A technique of intraosseous cannulation for intravenous therapy in birds. *Comp Cont Ed Pract Vet* 12(1):55-59, 1990.
47. **Rode JA, Bartholow S, Ludders JW:** Ventilation through an air sac cannula during tracheal obstruction in ducks. *J Assoc Avian Vet* 4(2):98-102, 1990.
48. **Rosenthal KR:** Congestive heart failure due to mitral regurgitation in an Indian Hill mynah bird. *Proc Assoc Avian Vet*, 1992, pp 171-173.
49. **Roskopf WJ:** Iron storage disease in an umbrella cockatoo. *Proc Assoc Avian Vet*, 1992, pp 98-107.
50. **Roskopf WJ, et al:** Pet avian emergency care. *Proc Assoc Avian Vet*, 1991, pp 341-356.
51. **Roskopf WJ, Woerpel RW:** Erythremic myelosis in conures: The hemorrhagic conure syndrome. *Proc Assoc Avian Vet*, 1984, pp 213-229.
52. **Roskopf WJ, Woerpel RW:** Kidney disease in a military macaw, a yellow-naped Amazon parrot and an umbrella cockatoo. *Proc Assoc Avian Vet*, 1988, pp 207-218.
53. **Roskopf WJ, Woerpel RW:** Epilepsy in peach-faced and pied peach-faced lovebirds. *Proc Assoc Avian Vet*, 1988, pp 225-229.
54. **Roskopf WJ, Woerpel RW:** Abdominal air sac breathing tube placement in psittacine birds and raptors, its use as an emergency airway in cases of tracheal obstruction. *Proc Assoc Avian Vet*, 1990, pp 215-217.
55. **Roskopf WJ, Woerpel RW:** Psittacine conditions and syndromes. *Proc Assoc Avian Vet*, 1990, pp 432-459.
56. **Roskopf WJ, Woerpel RW, Lane R:** Epilepsy in red-loreed amazons. *Proc Assoc Avian Vet*, 1985, pp 141-145.
57. **Saxon WD, Kirby R:** Treatment of acute burn injury and smoke inhalation. *In* Kirk RW, Bonagura JD (eds): *Current Veterinary Therapy XI*. Philadelphia, WB Saunders Co, 1992, pp 146-154.
58. **Sedgwick C, Pokras M, Kaufman G:** Metabolic scaling: Using estimated energy costs to extrapolate drug doses between different species and different individuals of diverse body sizes. *Proc Am Assoc Zoo Vet*, 1990, pp 249-254.
59. **Shores A:** Craniocerebral trauma. *In* Kirk RW, Bonagura JD (eds): *Current Veterinary Therapy X*. Philadelphia, WB Saunders Co., 1989, pp 847-853.
60. **Spink RR:** Nebulization therapy in cage-bird medicine. *Vet Med Sm An Clin* 75:791-795, 1980.
61. **Spink RR:** Aerosol therapy. *In* Harrison GJ, Harrison LR (eds): *Clinical Avian Medicine and Surgery*. Philadelphia, WB Saunders Co, 1986, pp 376-379.
62. **Stauber E, et al:** Effects of increased concentration of inspired oxygen. *Proc Euro Assoc Avian Vet*, 1991, pp 105-114.
63. **Sturkie PD:** Avian Physiology. Ithaca, Cornell University Press, 1965.
64. **Sturkie PD:** Body fluids: Blood. *In* Sturkie PD (ed): *Avian Physiology*, New York, Springer-Verlag, 1986, pp 102-121.
65. **Tams TR:** Pneumonia. *In* Kirk RW (ed): *Current Veterinary Therapy X*. Philadelphia, WB Saunders Co, 1989, pp 376-384.
66. **Van Pelt D, Wingfield WE:** Controversial issues in drug treatment during cardiopulmonary resuscitation. *J Am Vet Med Assoc* 200(12):1938-1944, 1992.
67. **Van Sant F:** Zinc toxicosis in a hyacinth macaw. *Proc Assoc Avian Vet*, 1991, pp 255-259.
68. **Walsh MT:** Seizuring in pet birds. *Proc Assoc Avian Vet*, 1985, pp 121-128.
69. **Wells RE, Slocombe RF, Trapp AL:** Acute toxicosis in budgerigars caused by pyrolysis products from heated polytetrafluoroethylene. *Clinical study*. *Am J Vet Res* 43:1238-1242, 1982.
70. **Weeren FR, Muir WW:** Clinical aspects of septic shock and comprehensive approaches to treatment in dogs and cats. *J Am Vet Med Assoc* 200(12):1859-1869, 1992.
71. **White J:** Protocol for the rehabilitation of oil-affected waterbirds. *Proc Assoc Avian Vet*, 1990, pp 153-163.
72. **Whitton GC:** Energy metabolism. *In* Sturkie PD (ed): *Avian Physiology*. New York, Spring-Verlag, 1986, pp 253-268.

**P**roper management of traumatic injuries in birds significantly decreases complications and wound-healing time. Many of the principles and techniques for wound management and bandaging in mammals apply to birds; however, anatomic differences require modifications and adaptations. Treatments and bandaging techniques for soft tissue wounds and nonsurgical fractures in birds will be discussed.

An understanding of wound healing is important in order to devise a treatment plan for optimal results. Wound healing is a complex interaction of host responses to an injury leading to regeneration of connective tissue, vascular supply and epithelium.<sup>1</sup> The three basic phases of wound healing are inflammatory (exudative), collagen and maturation.

**Inflammatory Phase:** The hemodynamic and cellular responses of the acute inflammatory response in birds have been studied in chickens and pigeons<sup>2,6,10,19,22</sup> (see Chapter 40). The response is similar in both mammalian and chicken skin in the first 12 hours. Immediate vasoconstriction to control hemorrhage is followed by vasodilation within 30 minutes.<sup>22</sup> Polymorphonuclear leukocytes and monocytes infiltrate the margins of the injured and necrotic tissue within the first 2 to 6 hours, causing active phagocytosis of necrotic cellular debris and bacteria.<sup>10,22</sup>

By 12 hours post-injury, the ratio of polymorphonuclear to mononuclear cells shifts toward a predominance of mononuclear cells.<sup>22</sup> During the next 36 hours, necrotic leukocytes that were active in phagocytosis accumulate at the periphery of the necrotic tissue and are phagocytized by macrophages and multinucleated giant cells. Fibroblasts appear in the wound during this period and continue to proliferate during the next few days, signaling the end of the first phase of the healing process.

---

CHAPTER

---

# 16

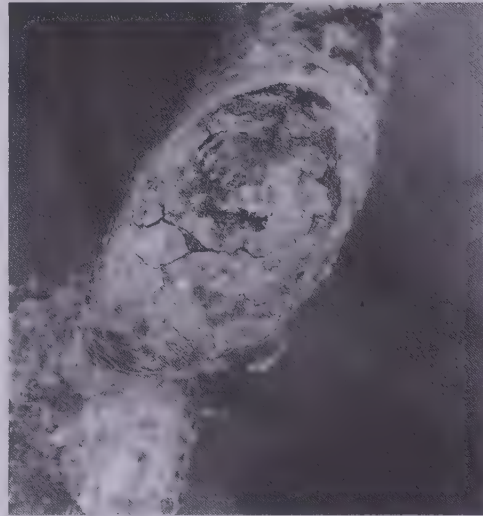
## TRAUMA MEDICINE

---

Laurel A. Degernes

**Collagen Phase:** Beginning the third or fourth day following injury in chickens, fibroblasts synthesize collagen in the form of microfibrils, which aggregate into larger fibers over time.<sup>10</sup> During this phase, which lasts approximately two weeks, capillaries develop from bud-like structures from nearby vessels and penetrate the wound. Wound contraction occurs, and epithelial cells proliferate and migrate across the wound surface.<sup>20,21</sup>

**Maturation Phase:** The final phase of wound healing may take weeks to months, and is marked by remodeling of the collagen bed and a decrease in the number of fibroblasts.<sup>21</sup> The weak, poorly developed collagen is replaced by thicker, stronger collagen fibers, which become oriented relative to the normal tension on the wound margins (see Chapter 40).



**FIG 16.1** A mature female Sulphur-crested Cockatoo was presented for a unilateral non-weight-bearing lameness noted the day before presentation. The bird was reluctantly willing to use the affected limb but when she did, she ambulated on the distal tibiotarsal area with the foot closed and held in extension. A large blue-black wound was located on the caudal tarsometatarsus. Radiographic findings were limited to soft tissue swelling. The wound was thoroughly cleaned with chlorhexidine scrub and flushed with copious quantities of warm lactated Ringer's solution. A Gram's stain of the wound after cleansing revealed a few gram-positive cocci. The wound was placed in a sterile bandage that incorporated a ball bandage to keep the foot open. The bandage was changed every two to three days. By the fourth bandage change, a healthy granulation bed had formed, and a primary skin closure was performed. The bird was returned to the aviary with no further complications.

## Principles of Wound Management

### Impediments to Wound Healing

There are many factors that can impair or prevent normal wound healing.<sup>8</sup> Dehydration, starvation, severe protein deficiency and chronic anemia may have adverse effects on wound healing (Figure 16.1). Necrotic tissue or blood clots may harbor bacteria and physically impede epithelial cell migration. Infection by pathogenic bacteria may significantly delay wound healing. Dirt, debris, dead bone and even suture material<sup>6</sup> may cause host reaction leading to the development of fistulous tracts.

Tissue destruction resulting from desiccation, severe trauma (eg, crushing or projectile injuries) or poor surgical technique will delay healing. Wounds of the distal extremities (reduced vascular supply) and non-immobilized injuries over joints, the axilla and the patagia tend to heal more slowly.

### Initial Assessment

Preliminary assessment of the injured avian patient will determine if immediate life-saving treatments are necessary.<sup>11</sup> A complete history is taken to determine the cause of injury, followed by a thorough physical exam. It is important to avoid overlooking less obvious injuries and unrelated problems. Trau-

matized birds often have multiple injuries and may be further compromised by dehydration, malnutrition and other problems, especially if there has been a delay (hours to days) between injury and presentation. Shock, fluid and nutritional therapy are critical in the early management of traumatized birds. Overzealous wound and fracture treatment before stabilization of the patient may result in the patient's death. Anesthesia may be necessary with fractious birds or in birds with extensive soft tissue or orthopedic injuries. However, if the bird is not stable, partial wound management and bandaging may have to suffice until more thorough treatment can be safely completed.

When assessing a wound, one should note the location, extent and age of the injury. Associated orthopedic injuries and the vascular and nerve supply to the area should also be evaluated (Figure 16.2). It is common to have underlying fractures or luxations associated with soft tissue wounds of the limbs. Wounds can be located by parting or wetting the feathers and viewing the normal translucent avian

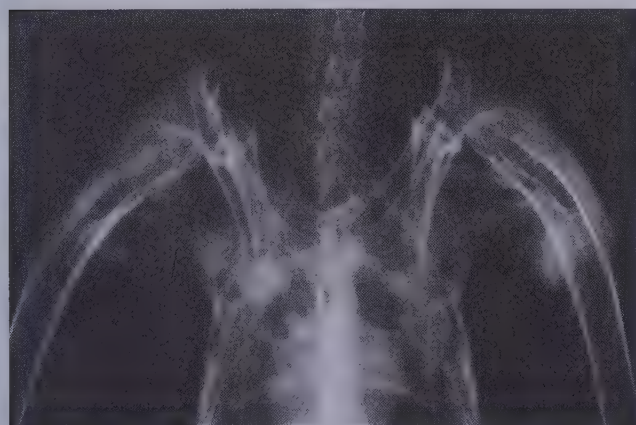
skin. Greenish discoloration of the skin is normal in bruised birds due to accumulation of biliverdin pigment following breakdown of hemoglobin. This discoloration develops two to three days post-injury and may persist for a week or more.

The vascular integrity may be evaluated by palpating the warmth of the limb, checking the capillary refill time of the skin, clipping a toe nail or pricking the skin. Other diagnostic tests used to assess an injured bird include microbiological cultures, hematology, radiology and ophthalmologic examination. Biopsies may be indicated in chronic, non-healing or self-inflicted wounds.

### ■ Surface Preparation and Wound Treatment

The initial goal in treating contaminants or infected wounds is the removal of devitalized tissue, foreign material and bacteria. The feathers surrounding the wound should be gently plucked or trimmed to allow more thorough cleansing and to prevent feather matting during the healing phases. Plucking feathers will allow for earlier regrowth of feathers, but caution should be used to prevent additional trauma to friable skin while plucking.

Wound lavage using a curved tip irrigating syringe will remove foreign material, reduce bacterial numbers and rehydrate soft tissues. Sterile isotonic saline with or without 0.05% chlorhexidine<sup>a</sup> or 0.5-1.0% povidone iodine<sup>b</sup> solution is recommended for wound lavage.<sup>33</sup> Cultures should be obtained after surface



**FIG16.2** An immature Red-tailed Hawk was found beside a highway, unable to fly. A severe wing droop was noted on physical examination. Radiographs indicated a fractured coracoid. The bird was placed in a figure-of-eight bandage. Fracture repair was uneventful, but when the bandage was removed, a severe wing droop was still evident and muscle atrophy had occurred to the wing musculature. EMG findings indicated denervation of all of the muscles in the wing. Necropsy indicated a brachial plexus avulsion.

contaminants have been removed and before any antiseptics have been applied. Hydrogen peroxide has been shown to be ineffective for bacterial infections, but may be effective as a sporicide in cases of suspected clostridial infections, or for initial cleansing of dirty wounds.<sup>3</sup> The volume of solution required will depend upon the severity and location of the wound and the degree of contamination.

Wound debridement following lavage involves removal of as much of the devitalized and necrotic tissue as possible until viable, vascularized tissue is recognized. In complicated or older wounds, the debridement process may have to be repeated over a period of a few days.

Topical medications in certain wounds may be beneficial; however, use of non-water-soluble medications should be avoided due to loss of insulation with soiled feathers. Bacitracin, neomycin and polymyxin are effective against a wide spectrum of bacteria.<sup>33</sup> One percent silver sulfadiazine<sup>c</sup> is effective for thermal burns and other wounds.<sup>27</sup> Topical use of hemorrhoid creams containing live yeast cell derivatives<sup>d</sup> (LYCD) has been shown to stimulate epithelialization and collagen synthesis in human<sup>23</sup> and canine<sup>33</sup> wounds. LYCD has been successfully used in raptors with granulating wounds and pododermatitis (bumble-foot) lesions.<sup>12</sup> A topical medication commonly used for pododermatitis in raptors and other birds is dimethyl sulfoxide (DMSO), used either alone or with a combination of dexamethasone and an antibiotic, such as carbenicillin or piperacillin.<sup>30</sup>

Products that have been shown to retard wound healing in mammals include nitrofurazone, which slows epithelialization,<sup>13</sup> and gentamicin sulfate, which impairs wound contraction.<sup>24</sup> Although similar studies have not been conducted in birds, it is advisable to avoid these products in avian wounds.

After lavage and debridement, the wound should either be sutured, managed by second intention healing or managed as an open wound with delayed closure.<sup>8</sup> Wounds less than eight hours old and not heavily contaminated, or wounds that were surgically created under sterile conditions should be sutured. Older, infected or more complicated wounds should be managed as open wounds and allowed to heal by second intention.

## Bandaging Principles

Properly applied dressings and bandages will provide an optimal environment for epithelialization and wound contraction with the fewest complications.

The functions of bandages<sup>32</sup> are to:

- Apply pressure to reduce dead space, swelling, edema and hemorrhage
- Protect the wound from pathologic microorganisms
- Immobilize the wound and underlying fractures, if present
- Protect the wound from desiccation and additional trauma from abrasions or self-mutilation
- Absorb exudate and help debride the wound surface
- Provide comfort for the patient.

The three layers of a bandage are the primary layer (or dressing that is in contact with the wound), the secondary layer for absorption and the tertiary layer, which serves to hold the other layers in place.

### Primary Layer

The primary layer is the most critical layer for optimal wound healing. This layer should be sterile, remain in place even with patient movement, provide a moist wound environment and assist with the debridement process.<sup>32</sup>

The two basic groups of dressings include adherent and non-adherent dressings. Adherent dressings such as fine mesh or open weave gauze pads are indicated during the initial phase of wound treatment when there is a large amount of necrotic debris that cannot be surgically debrided, or with excessive exudate production. Wet-to-dry bandage techniques involve the application of sterile saline-soaked, warm gauze pads over the wound surface.<sup>8,9</sup> The exudate and necrotic debris will be mechanically removed with daily dressing changes during the first few days of treatment, at which time the type of dressing used can be changed to a non-adherent one. Disadvantages of wet-to-dry bandages may include tissue maceration and bacterial colonization with the moist environment, and disruption of the wound healing surface with each dressing change.<sup>8</sup>

Non-adherent dressings, by definition, do not adhere to the healing wound surface,<sup>25</sup> and include a variety of products. Traditional non-adherent products com-

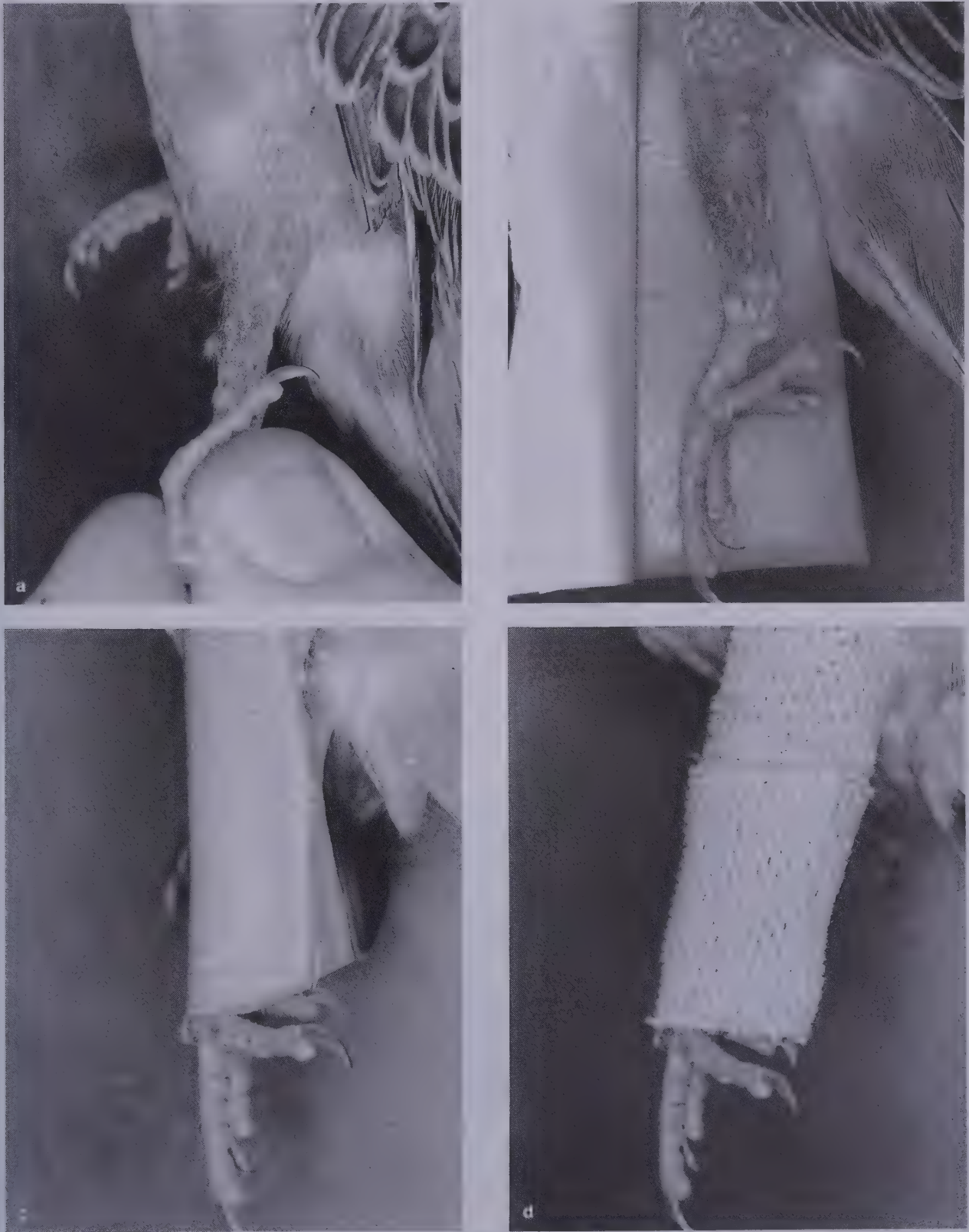
monly used in veterinary wound management include cotton film dressings<sup>e</sup> and petrolatum-impregnated fine mesh gauze pads<sup>f</sup>. Advantages of these products for use in avian medicine include availability and low cost. However, disadvantages include disruption of the healing surface when the dressing is removed after being in place for more than two to three days, soiling of feathers (petrolatum-impregnated products), slippage of dressings under the bandage and difficulty in bandaging certain anatomic locations.<sup>11</sup>

Increased understanding of wound healing processes has resulted in the development of many new synthetic adhesive, non-adherent dressings for use in humans.<sup>4,5,14,15</sup> These new dressings keep the wound surface moist and prevent scab formation, which significantly increases the rate of re-epithelialization, compared to air-exposed and wet-to-dry gauze dressings.<sup>1</sup> Adaptation of these products to avian wound management has resulted in elimination of many of the problems outlined earlier, and significant improvements in the rate and quality of wound healing.<sup>11</sup> The two product groups discussed include hydrocolloid dressings and moisture vapor permeable (MVP) dressings.

Hydrocolloid dressings or hydroactive dressings (HAD)<sup>g,h</sup> are semi-flexible, opaque membranes that are impermeable to moisture vapor and oxygen, and absorb fluid and exudate to develop a moist, gelatinous cover over the wound. These dressings adhere to normal skin and not wounds, but generally require additional bandaging material to be held in place. Hydrocolloid dressings have been used successfully in a variety of avian species,<sup>9,11,12,17</sup> and are most useful for extensive wounds with greater than normal exudate production, wounds that require debridement or for slow healing wounds (Figure 16.3).

Moisture vapor permeable (MVP) dressings<sup>i,j,k</sup> are thin, flexible, transparent polyurethane membranes that are oxygen permeable, impermeable to water and bacteria, allow accumulation of fluid and exudate under the dressing and are adhesive to normal skin but not wounds.<sup>26</sup> The maintenance of a moist, aerobic environment under the dressing promotes leukocyte debridement of the wound surface, prevents desiccation and scab formation and reduces pain associated with desiccation of raw nerve endings.<sup>4</sup> Epithelialization is more rapid when scabs are not present to impede cell migration from the wound margins.<sup>1,4,5</sup>





**FIG 16.3** In birds that weigh less than 150 g, hydrocolloid dressings can be used as a splint material for distal tibiotarsal fractures. This material is superior to tape because it is more rigid. **a)** Note the bruising associated with this distal tibiotarsal fracture. **b,c)** A hydrocolloid dressing is wrapped around the leg incorporating the femur and the tarsometatarsus. **d)** The hydrocolloid dressing is covered with self-adherent bandage materials.

Both MVP and hydrocolloid dressings are indicated for a variety of avian wounds, but MVP dressings are more suited to areas that are impossible to bandage (eg, head wounds) because of the superior adhesive quality and flexibility of the material. The dressings are changed every two to three days initially, or more often if excessive exudate production results in fluid leakage from underneath the dressing. Once a healthy granulation bed is established, dressings can be changed weekly. Wounds treated with these dressings appear to heal more rapidly and with fewer complications compared to conventional non-adherent dressings.<sup>11</sup> Patient acceptance is usually very good, even with psittacine species.

### Secondary Layer

The functions of the secondary bandage layer are to absorb fluids and wound exudate, pad the wound from trauma, and immobilize the wound and underlying fracture during the healing phases.<sup>8</sup> Conforming gauze material<sup>1</sup> or cast padding is most commonly used.

### Tertiary Layer

The tertiary or outer layer serves to hold the other layers of the bandages in place. Most bandages consist of conforming stretch tapes with or without an adhesive. Self-adherent bandages<sup>sm</sup> are excellent for birds because they are light-weight and breathable, are well tolerated by most birds, and the material adheres to itself cohesively without problems associated with tape residues on feathers. In cases where

patient acceptance is poor, white adhesive tape, duct tape, neck braces or Elizabethan collars may be required for bandage protection.

## Specific Traumatic Injuries and Their Management

### Lacerations and Abrasions

Lacerations and abrasions in companion birds are commonly caused by enclosure wires, inappropriate toys, collisions during flight, other birds or household pets (Figure 16.4). Specific management of a laceration is determined by the size, location and age of the wound. In birds with breast or wing tip lacerations that result from frequent falls, additional therapy may include pulling improperly clipped wing feathers to stimulate their replacement.

### Band Injuries

As useful as leg bands are for individual identification, they are not totally innocuous. Open style steel quarantine bands may cause serious problems if the band gap is large enough to allow the bird to get hung up on the cage wire. Resulting injuries may include soft tissue bruising, swelling or lacerations, leg fractures or luxations and occasionally death. Even captive-raised birds with closed bands may get their bands caught on toys, clips or enclosure wire (Figure 16.5). Inappropriately sized bands may cause soft tissue swelling and vascular compromise to the distal leg and toes if young birds outgrow bands that are too small. Some birds on a marginal diet will collect excessive quantities of desquamated skin under a band, resulting in a constrictive injury. Soft tissue swelling of the tarsometatarsus associated with fractures or other injuries may be further complicated by vascular constriction caused by the band. Large psittacines may crimp aluminum bands with their beaks,



**FIG 16.4** A maxilla fracture occurred in this budgerigar when it was bitten by a larger bird. Placement of a wire suture in a mattress pattern was used to oppose the maxilla. Beak injuries of this magnitude should be handled as emergencies. The sooner the damaged area is repaired, the more likely the beak is to heal.

**FIG 16.5** Necrosis of the metatarsal skin in a cockatiel that caught its band in an unsafe toy. If a bird hangs by the leg for prolonged periods, microvascular damage may occur that results in necrosis 10 to 14 days post-injury. In severe cases, amputation of the most proximal joint and application of a hydroactive dressing to the stump is necessary.

causing a tight constriction of the distal limb, making band removal difficult. Abrasions and swelling underneath the band may develop when the leg is bandaged.

Band injuries should be prevented by anticipating potential problems, especially with open bands that have large gaps and with inappropriately sized bands (too small or too large). Prophylactic band removal or crimping to reduce the gap is preferable to treating a band injury (see Chapter 1). Once an injury or associated problem with a band is recognized, extreme caution should be exercised with band removal to avoid additional injury to the bird. The owner should always be warned of potential risks to the bird whenever a band is removed, even when the procedure is elective and not associated with trauma. Complications may include fractures, dislocations and lacerations. If a wound is already present, avascular necrosis may complicate the band removal procedure. Specific treatment options following band removal involve wound debridement and cleansing, surgical closure if indicated and coverage with appropriate dressing and bandaging material as needed.

### ■ Feather, Toenail and Beak Injuries

Significant hemorrhage may occur with broken blood feathers, especially broken flight and tail feathers. Direct digital pressure over the bleeding feather should be applied immediately to prevent excessive blood loss. A first-aid home procedure involves putting flour over the bleeding feather stub. This conservative treatment may be adequate in some cases, but most broken blood feathers require timely removal. The feather should be grasped at the base with a hemostat (needle-nosed pliers can be used on large birds) or fingers and pulled from the follicle while applying counter pressure to the area surrounding the follicle, to prevent tearing the skin (see Figure 15.12).

It is critical to remove the entire feather shaft from the follicle and continue to apply pressure over the follicle until the hemorrhage stops. Products intended for hemorrhage control during nail and beak trims, such as silver nitrate and ferric subsulfate powder<sup>m</sup> should never be used in a feather follicle to stop bleeding, due to the irritation caused by these products and the possible foreign body reaction that may occur (granuloma or feather cyst formation). Radiocautery should also not be used to blindly cauterize the interior of a follicle.

Broken or torn toenails can be managed by trimming the exposed portion with a nail trimmer to make a smooth surface, and packing ferrous subsulfate or silver nitrate into the exposed nail bed pulp cavity. If the keratin sheath of the toe nail has been pulled off to expose the underlying bone, direct pressure should be applied to control hemorrhage. The exposed bone can be protected with liquid bandage products,<sup>o,p</sup> or light bandaging.

Beak injuries occur most often from bites from other psittacines, or from collisions during flight. Cockatoo males often become extremely aggressive toward the females, sometimes inflicting lethal injuries (see Chapter 4). Head trauma is common with mate aggression and may be associated with beak fractures, punctures or avulsion of the maxillary or mandibular beak, in addition to soft tissue trauma. Hemorrhage may be controlled with direct digital pressure or by applying clotting products such as silver nitrate or ferric subsulfate. For specific beak repair see Chapter 42.


### ■ Self-mutilation

Many factors may induce self-mutilation behavior (see Chapters 4 and 24). A thorough diagnostic workup to rule out predisposing factors should be considered. Appropriate antibiotic, antifungal or anthelmintic treatment is combined with soft tissue wound management and protection of the wounds from further trauma. The wounds should be cleansed and debrided, and surrounding feathers carefully plucked or trimmed to prevent them from becoming matted in the wound. Aloe vera preparations may help in soothing the pain and irritation caused by massive self-trauma.

Application of moisture vapor permeable dressings<sup>i</sup> is very effective in promoting rapid wound healing, and is well tolerated by most avian species including psittacines. The use of topical non-water-soluble wound medications is discouraged due to feather soiling, and is not necessary when MVP dressings are used. In severe cases of self-mutilation, an Elizabethan collar or neck brace collar may be indicated to protect the wounds from further trauma (Figure 16.6).

### ■ Burns

The most common thermal burns occur in the crop of neonates fed improperly heated hand-feeding formula (microwaved without proper stirring). Further discussion of medical and surgical management of crop burns is covered in Chapter 30. Accidental burns



**FIG 16.6** A mature Quaker Parakeet was presented with a one-month history of feather picking that progressed to self-mutilation. Note the numerous emerging pin feathers that many bird owners mistakenly identify as mites. The cause of this bird's self-mutilation was undetermined.



**FIG 16.7** An Amazon parrot was presented four days after flying into a pot of hot liquid on the stove. The bird had been treated at home with a topical burn ointment. On presentation, several phalanges were missing, and the foot and leg distal to the mid-metatarsal region were cold, firm and black. Tissue fluids were oozing from the margin of the burned area. Because four days had passed since the initial injury, the only effective therapy was amputation of the necrotic limb. The prognosis for burn wounds is best if they are treated on an emergency basis.

may occur when pet birds come in contact with hot liquids, hot surfaces or electrical wires (Figure 16.7). The feathers provide some measure of insulation; however, the extent of the trauma depends upon the cause and the duration of exposure. Damage may range from singed feathers, ocular irritation or mild erythema of the feet or other exposed skin, to severe destruction of the toes or feet, melted beaks or death (see Color 24). Treatment action to be taken includes immediate cooling and rinsing of the affected areas, followed by supportive care, topical wound management and systemic antibiotic therapy. Topical medications may include DMSO for acute inflammation and silver sulfadiazine<sup>c</sup> cream for antibacterial protection.

Chemical burns secondary to contact with caustic solutions, acids or other irritants may be seen occasionally. The affected areas should be thoroughly washed and the compound neutralized by either sodium bicarbonate solution for acidic compounds, or dilute vinegar for alkaline compounds.<sup>27</sup>

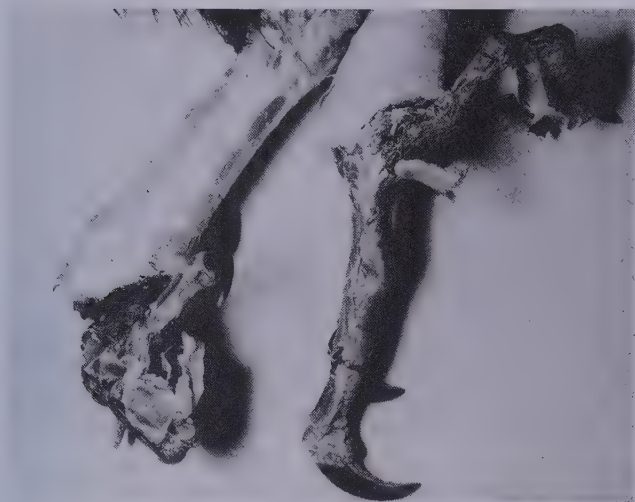### ■ Frostbite

Frostbite injuries are more common in cooler climates, but may occur in warmer regions during unexpected cold snaps when birds are not acclimated or do not have adequate shelter and supplemental heat. Injuries may range from mild redness, swelling and pain of the affected digit(s) or limbs, to gangrenous necrosis and death (Figure 16.8). Treatment requires

supportive care including supplemental heat, fluid therapy, anti-inflammatory agents or topical DMSO, bandaging and treatment of secondary complications (see Chapter 15). Loss of soft tissue viability may be assessed by discoloration of the skin, loss of neuromuscular control, cooler skin temperature, odor, leakage of serosanguinous fluid and disruption of blood flow to distal extremities. The prognosis for saving a frozen digit or foot is extremely guarded, and amputation may be necessary if gangrenous necrosis develops.

### ■ Degenerative Joint Disease

Degenerative joint disease (DJD) is a chronic inflammatory condition involving the joint and surrounding tissues. Bony changes and reduced function in the joint may be secondary to trauma, bacterial infection, malnutrition or neoplasia. Radiographs, microbiologic cultures and biopsies are indicated to determine the cause and severity of the problem. The prognosis for successful treatment and return to normal joint function is extremely guarded, even with long-term antibiotic treatment.



**FIG 16.8** An adult toucanette hen was presented for a bilateral non-weight-bearing lameness. The bird had not been seen for several days and was presumably incubating eggs. Dry gangrene secondary to frostbite was evident in both legs distal to the tarsometatarsal joint. Temperatures the week before presentation were below freezing. The bird was euthanized.

### Bumblefoot

Bumblefoot or pododermatitis is a general term for any inflammatory or degenerative condition of the avian foot and may range from very mild redness or swelling to chronic, deep-seated abscesses and bony changes.<sup>12,16,18,29,30</sup> Considerations for prevention of bumblefoot include proper perches (size, shape and texture), flight pen or cage construction (wall components, substrate, perch arrangements), nutrition, general health of the bird and sanitation of facilities.

#### Classification and Causes of Bumblefoot

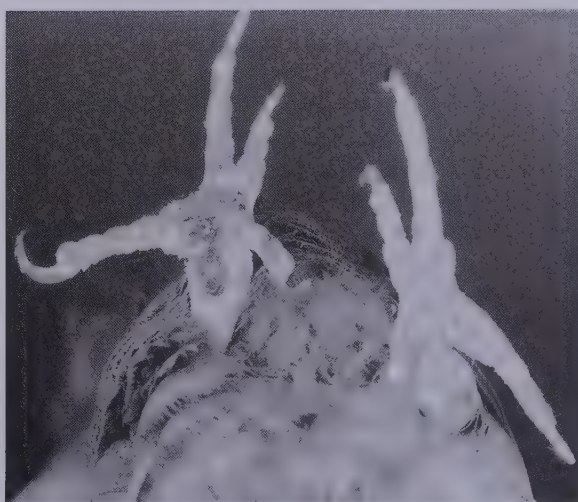
With the common occurrence of bumblefoot in companion and aviary birds, it seems appropriate to classify bumblefoot in a new manner, combining the concepts described by Halliwell<sup>18</sup> with subtle clinical changes that alter the management and prognosis of the disease (Table 16.1). A classification scheme grading from minor early clinical signs progressing to severe lesions is proposed (Harrison GJ, unpublished). The clinical progression of the disease varies based on the species of bird (eg, Psittaciformes, Passeriformes, raptors or Anseriformes) and the factors that contributed to the infection (Figure 16.9).

Grade I to III lesions may not be recognized in raptors that are commonly presented with Grade IV or V lesions. Older budgerigars and cockatiels (five to ten years old) may have a Grade V to VI lesion if precipitating factors are not corrected early. Bony

changes and osteomyelitis may be present. Prognosis for full recovery of Grades I to IV is usually more favorable than Grade V to VI lesions.

Grade I to III lesions are common in Psittaciformes and Passeriformes that are on all-seed or over-supplemented fruit and vegetable diets, overweight, have no exposure to sunlight or are kept on improper perches (covered with sandpaper, too small or too large, no variance in size) (see Color 8). With proper husbandry and nutrition, most cases recover. Substrate perch size, shape and covering material may all influence the bird's weight distribution on the toes and metatarsal pad and the amount of skin wear on the plantar surface.<sup>12,16,18,29</sup> For example, a perch that is too wide and flat may cause excessive weight-bearing on the toe pads, while one that is too small may cause excessive weight-bearing on the metatarsal pads.

Bruising and abrasions on the plantar surface of the feet may develop when raptors persistently bate (jump) from a perch onto a hard surface or hang from the cage wire,<sup>18</sup> or when they are forced to stand on perches or cement. Any soft tissue or orthopedic injury involving one leg or foot may cause excessive weight bearing and secondary bumblefoot on the contralateral foot. Overgrown talons cause improper weight distribution on the plantar surface of the foot (especially in falcons and finches) or self-inflicted puncture wounds of the metatarsal pad.<sup>16</sup> Other traumatic injuries to the foot include bite wounds from prey, punctures from thorns or quills and trap inju-



**FIG 16.9** A 12-year-old cockatiel was presented with a non-weight-bearing lameness. Grade III bumblefoot is common in older inactive birds that are fed inadequate diets. Early lesions (smoothing of the plantar foot surface and hyperemia) are frequently missed, and the birds are not presented until they are lame.

**TABLE 16.1 Clinical Grades of Bumblefoot**

<b>Grade I</b>	Desquamation of small areas of the plantar foot surfaces represented clinically by the appearance of small, shiny pink areas - peeling or flaking of the skin on the legs and feet.
<b>Grade II</b>	Smooth, thinly surfaced, circumscribed areas on the plantar metatarsal pads of one or both feet with the subcutaneous tissue almost visible through the translucent skin. No distinct ulcers are recognized.
<b>Grade III</b>	Ulceration of the plantar metatarsal pads. In some birds a peripheral callus may form.
<b>Grade IV</b>	Necrotic plug of tissue present in ulcer. Most species with ulcers and accumulation of necrotic debris exhibit pain or mild lameness.
<b>Grade V</b>	Swelling and edema (cellulitis) of the tissues surrounding the necrotic debris. The digits or foot may also be edematous. Necrotic debris may start to accumulate in the metatarsal area, suggesting infection of the tendon sheaths. Severe lameness is common. The entire metatarsal pad may be affected. This is generally a chronic lesion.
<b>Grade VI</b>	Necrotic tendons recognized clinically as swelling in the digits and ruptured flexor tendons. Ankelosis and nonfunctioning digits usually present in recovery.
<b>Grade VII</b>	Osteomyelitis.

ries. Pathogenic bacteria introduced at these sites may lead to abscessation, osteomyelitis or joint changes.<sup>31</sup> Other causes of bumblefoot include severe poxvirus lesions with secondary bacterial infections, frostbite injuries and thermal burns.<sup>29,30</sup>

The precise pathogenesis of bumblefoot in various avian species remains undetermined. It is theorized that dry, flaky hyperkeratotic skin on the feet (possibly precipitated by malnutrition, environmental deficiencies and systemic disease) changes the mechanics of weight bearing on the metatarsal pads, leading to reduced circulation, micro-epithelial damage, localized impairment of the immune system and invasion of opportunistic pathogens. A bird's inactivity in an enclosure (inability to fly) may be a major precipitating factor. In one group of raptors, birds that were housed outdoors and were able to exercise did not develop bumblefoot regardless of their perching surface. By comparison, a group of raptors maintained indoors on the same diet developed bumblefoot irrespective of the perching material (Redig PT, unpublished).

### Prevention and Treatment


Prevention of bumblefoot involves constant vigilance for early signs of hyperkeratosis, baldness, flaking of

the skin of feet and legs, redness or swelling and correction of the underlying causes. The walls of an enclosure should be designed with vertical bars or solid barriers to minimize the tendency for hanging from the wire. Selection of proper perch size, shape and cover for a particular species of bird is very important.<sup>29</sup> Perches wrapped with hemp rope or covered with AstroTurf work well for most raptors. Falcons do best on flat shelf or block perches covered with short AstroTurf or cocoa mats. Strict sanitation of the facilities and feet is important to minimize bacterial infections. Feeding some formulated diets and providing fresh water for bathing prevents or reverses early bumblefoot in Psittaciformes (Harrison GJ, unpublished).

The goals of advanced bumblefoot treatment are to reduce inflammation and swelling, ensure an adequate diet, establish drainage if needed, begin antibacterial therapy to eliminate underlying pathogens, manage the wound to promote rapid healing and address dietary deficiencies.<sup>29,31</sup> Surgical excision of the abscess or amputation of a severely traumatized digit may be indicated. Treatment for Grade V to VI lesions must be vigorous, and the prognosis is guarded. Treatment for Grade IV should include drainage, irrigation and closing the wound when the infection has been resolved. The prognosis is fair. Grade I to III lesions generally respond to keeping the foot clean and correcting underlying management or nutritional deficiencies. With Anseriformes, this frequently involves changing the dimension, shape and surface of the enclosure, including the addition of adequate swimming areas.

Conservative treatment options may include changing the diet and padding the perches, applying topical medications and, if needed, bandaging. Many topical products have been used, such as softening agents (udder balm or lanolin-based lotions) for dry, scaly feet; topical dimethylsulfoxide (DMSO) for acute inflammation and swelling;<sup>29</sup> hemorrhoidal ointment with live yeast cell derivative for granulating wounds;<sup>12,23</sup> and liquid bandage products for minor skin cracks or torn talon sheaths.<sup>12</sup>


Moisture vapor permeable dressings or hydrocolloid dressings should be applied topically to enhance wound healing for open, granulating wounds or post-operative incisions.<sup>11</sup> Bandaging of affected Psittaciformes may go on for several months until the bird responds to the new diet. Bandaging options include simple toe bandages, interdigitating bandages and ball bandages (Figures 16.10, 16.11).



**FIG 16.10** Ball bandages can be used to protect the foot while plantar lesions are healing.

In raptors, therapy for Grade IV to V lesions include a DMSO preparation that is made by combining piperacillin (1 g) with dexamethasone (4 mg) and DMSO to make a 10 ml mixture. This is refrigerated and discarded after one week. Resolution of Grade IV to VI lesions is slow, and complete healing may take several months. Initial treatment also includes systemic antibiotics for seven to ten days. The entire foot should be cleaned with surgical scrub and any scabs should be soaked free without applying pressure to the wound. A swab taken from deep within the abscess should be cultured for bacteria and fungus. *E. coli*, staphylococcus and candida are commonly isolated pathogens. The wound should be flushed with copious quantities of one percent povidone iodine solution and allowed to soak for five minutes. The wound should then be flushed with large quantities of sterile saline, the defect packed with a sterile gauze 2 x 2 soaked in povidone iodine solution and a large soft bandage applied. On the second day, the flushing of the wound, gauze pack and bandaging are repeated. Most can be done without anesthesia.

On the third day, swelling may be reduced and much of the exudate gone. Any fibrotic material is removed and the foot is prepared for sterile surgery. A wide exposure of the affected area is made and the abscess wall is dissected out. Any devitalized ligaments or tendons must be removed in their entirety. A tourniquet may be required to control hemorrhage. The wound should be vigorously irrigated with povidone iodine followed by sterile saline. If hemorrhage returns after removing the tourniquet, pressure, epinephrine or selective radiocautery may be used for control, and the wound should be flushed to remove all free blood. The wound is partially sutured shut to



**FIG 16.11** Interdigitating foot bandages are used when a wound needs to be protected or padding is needed for the bottom of the foot, yet it is desirable for the bird to perch.

allow for drainage, packed with a seton soaked in saline and rebandaged with a large soft wrap. If hemorrhage was poorly controlled, the bandage should be changed in four to six hours.

The bandage should be removed daily and the foot scrubbed and flushed with iodine solution and sterile saline until a “dry socket” is obtained (see Color 24). This may take a week or more. Then the bandage can be changed at two- to three-day intervals. Each time the bandage is changed, the wound should be flushed and kept open as long as there is serum seepage. Mechanical debridement of the wound with a sterile swab will prevent premature closure. The wound may be sutured closed when there is no apparent infection or drainage. Appearance of granulating tissue around the edges of the wound indicates healing is occurring, which may take up to two to five weeks. A week after closure, bandaging can be reduced to only a light wrap. After healing is complete, the foot may still be tender for several weeks. Prevention of trauma and maintaining the patient on soft footing are important to prevent recurrence. Waterfowl should be returned to water as soon as possible to prevent other problems. Modifications and compromises to this procedure may be necessary depending on the species involved and the individual situation.

### ■ Nonsurgical Immobilization of Fractures

There are many indications for bandaging avian limbs: nonsurgical immobilization of fractures, soft tissue and joint injuries, and following orthopedic fracture repair. The following bandages and splints have been developed and modified to meet specialized anatomic requirements for avian limb immobi-

lization.<sup>7,28</sup> Specific indications, contraindications and application techniques will be discussed for each type of bandage or splint.

### Bandaging Materials

Bandage materials used in birds should be soft, pliable and not have adhesive materials that can adhere to or damage feathers. Cast padding is an ideal base for slings, bandages and wraps. Self-adherent bandage materials are best for the outer layer. When necessary, wooden splints, aluminum rods or lightweight casting materials can be used to reinforce bandages. Some human orthopedic products have been excellent support materials for use in birds. Orthoplast<sup>®</sup> and Hexcelite<sup>®</sup> are excellent support materials for use in birds. At room temperature, these materials are firm, but when placed in hot water they become malleable and can be manipulated to conform to the shape of a bird's limb.


### Fracture Stabilization

To be effective, an external coaptation device must immobilize the joint above and below a fracture. Once in place, bandages should be carefully monitored for tissue abrasions, slipping, seepage or swelling in the distal part of a limb, all of which would indicate that the bandage needs to be replaced.

### Figure-of-Eight Wing Bandage

The indications for figure-of-eight wing bandages include wing fractures distal to the elbow, luxations of the elbow or carpal joint and soft tissue wounds in these areas that require bandaging and immobilization.<sup>28</sup> There are no rules to dictate which wing fractures can be adequately repaired with external coaptation, which fractures require surgical repair and which are simply not repairable. In general, external coaptation in the form of a figure-of-eight wing bandage can be considered for the following fractures: most closed fractures of the ulna and radius, when the fragments are relatively well-aligned (Figure 16.12); most fractures of the major and minor metacarpals; fractures that are too close to a joint or too comminuted to surgically repair; fractures in birds that may not require full return to flight capability; fractures in small or very young birds; and following most orthopedic surgeries of the wing. It is contraindicated to apply a figure-of-eight wing bandage for a humerus fracture without also immobilizing the shoulder with a wing-body wrap.

Application of a figure-of-eight wing bandage is shown in Figure 16.13. It is important to incorporate the scapular or tertiary covert feathers in the ban-



**FIG16.12** Wing fractures, in which either the radius or ulna remain intact, can be successfully managed with a figure-of-eight bandage.

dage and apply the bandage as high in the axillary region as possible to prevent the bandage from slipping below the elbow. The bandage should not extend more than approximately one-half bandage width beyond the elbow joint and should not be applied too tightly. A bandage that is applied too tightly may cause vascular compromise of the wing distal to the carpal joint and sloughing of flight feathers. If the primary and secondary flight feathers have a criss-crossed appearance following bandaging (instead of lying parallel), the bandage is too tight. The bandage should not be so bulky that it causes balance problems in the patient. It may be advantageous to tape the tips of the primaries to the tail feathers in birds with long primary feathers.

The length of time a wing bandage is left on is determined by the underlying problem. Most fractures require three to five weeks of bandaging, and soft tissue wounds may require a few days to two weeks of immobilization. Complications of prolonged bandaging are joint stiffness, bony changes, disuse muscle atrophy and occasionally sloughed flight feathers.<sup>28</sup> Weekly bandage changes with physical therapy on the wing, proper bandage application and removal of the bandage as soon as possible after healing will minimize these problems.

### Wing-Body Wrap

Fractures or luxations involving the humerus, coracoid, furcula or scapula should be immobilized with a wing-body wrap,<sup>28</sup> as shown in Figure 16.13. Humerus fractures are often immobilized with both figure-of-eight and wing-body wrap bandages, and most of these fractures require orthopedic repair.<sup>7</sup> The legs should be extended to pull the stifle joints away from

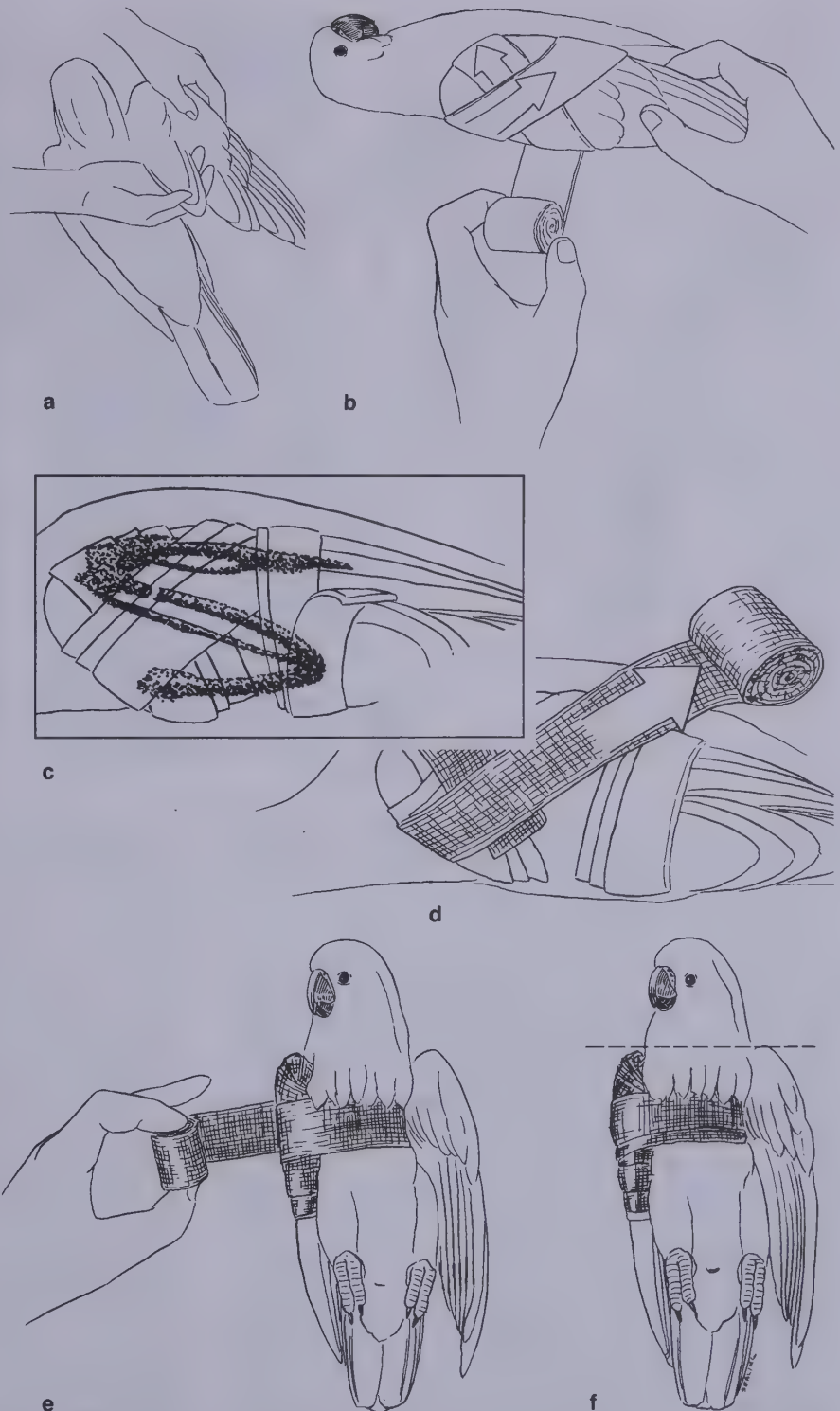


the keel, and the wing should be folded in a normal flexed position and held to the body using a self-adherent bandage<sup>m</sup> or adhesive tape that does not harm feathers (masking tape or Durapore<sup>a</sup> tape). The bandage should be positioned approximately halfway between the top and bottom of the keel to avoid interference with the legs and the vent. It is important to apply the body wrap tight enough to prevent wing motion, but not tight enough to compromise respiration.

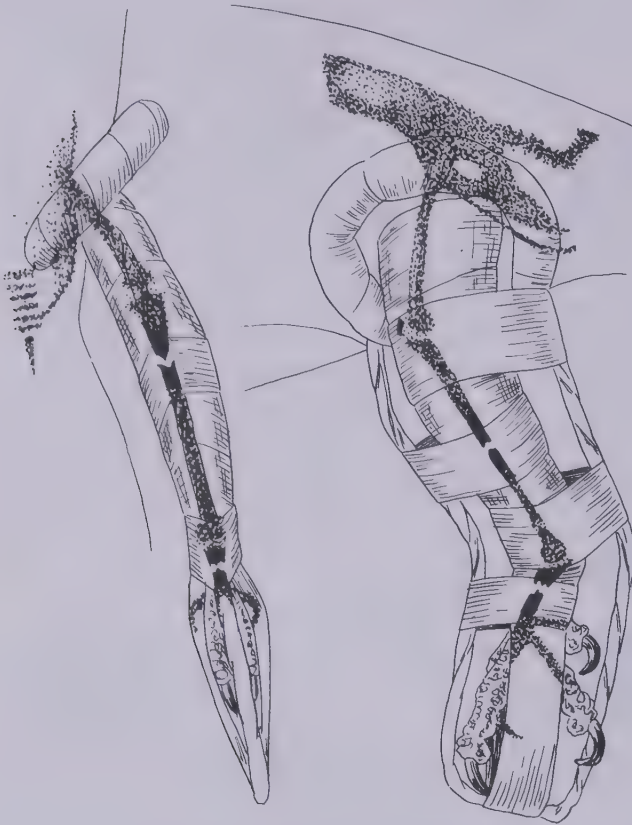
### Schroeder-Thomas Splint

The use of a Schroeder-Thomas splint is limited to fractures of the tarsometatarsus and the distal one-third of the tibiotarsus<sup>26</sup> (Figure 16.14). Indications for these splints include fractures of the tarsometatarsus in psittacine birds in which the bone is too small to apply any form of orthopedic repair, fractures too close to the tibiotarsal-tarsometatarsal (hock) joint or foot, uncomplicated fractures in small birds, and following internal surgical fixation of distal tibiotarsal fractures. Contraindications for Schroeder-Thomas splints include all fractures of the femur and proximal two-thirds of the tibiotarsus, because the extreme flexion at the ileal-femoral joint and the wide inguinal skin web in birds results in the proximal portion of the splint acting as a fulcrum and interfering with immobilization.

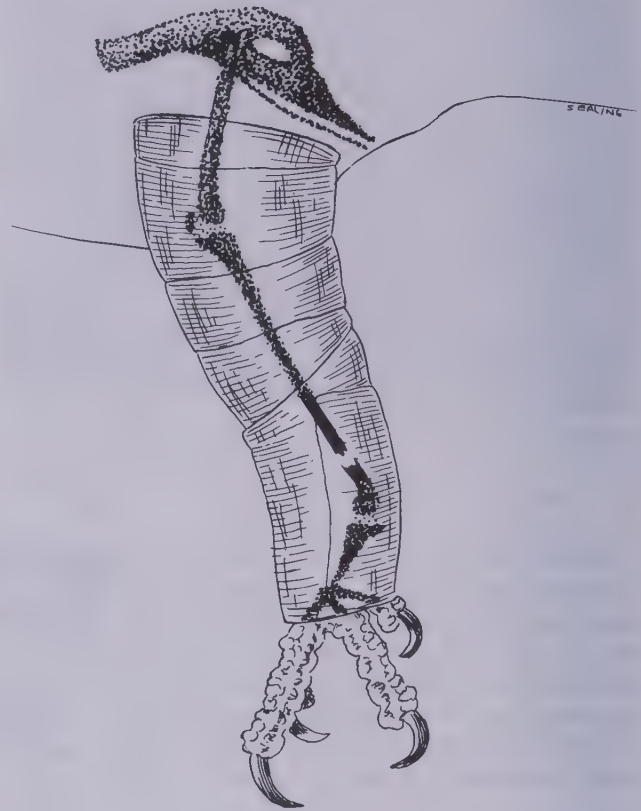The wire or rod material of the splint should be made with two right-angle bends next to the ring at the top so that the splint is parallel to the long axis of the leg (Figure 16.14). The leg should be positioned with some flexion at the hock joint, with the splint angles bent to conform to the angles of the leg. The splint should be slightly longer than the partially



**FIG16.13** a,b,c) Rolled cotton padding is used for the initial layer of a figure-of-eight bandage d,e) followed by the application of a self-adherent bandage material. f) If the bandage is properly applied, the carpus of the injured wing will be positioned neither higher nor lower than the unbandaged carpus. In addition, the primary and secondary feathers will be in a normal anatomic association. If the primary tips are medial to the secondary feathers, the carpus is being excessively flexed and the bandage is too tight.



**FIG 16.14** Craniocaudal and lateral views of a Schroeder-Thomas splint, which can be used to temporarily stabilize fractures of the tarsometatarsus and distal tibiotarsus.



**FIG 16.15** Lateral view of a Robert Jones bandage, which can be used to temporarily stabilize fractures of the distal tibiotarsus and tarsometatarsus.

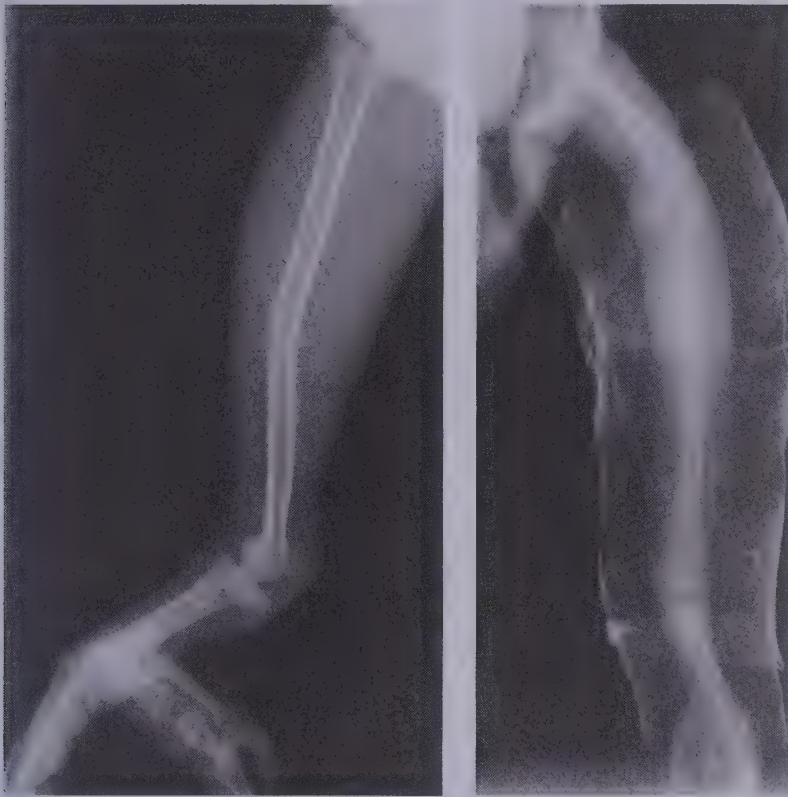flexed leg and extended toes. The leg is lightly bandaged with gauze and tape and is suspended within the splint by alternating strips of tape placed cranially and caudally with the toes extended to the end of the splint. The splinted leg is then covered with bandaging material. Weekly or bimonthly bandage changes with passive physical therapy should be conducted until the fracture heals in four to six weeks. The bird should be provided a low perch so that the splinted leg can hang below or be propped on the perch. With all leg injuries, bumblefoot lesions in the contralateral, weight-bearing foot should be prevented through the use of soft flooring materials, adequate nutrition and, in some cases, ball bandages.

#### Robert Jones Bandage

The Robert Jones bandage (Figure 16.15) should be limited to simple fractures of the distal one-third of the tibiotarsus and tarsometatarsus, injuries involving the hock joint, soft tissue wounds of the tibiotarsus or tarsometatarsus, or following orthopedic repair of the distal two-thirds of the leg. These heavily

padded leg bandages can be used with or without additional splinting material, such as tongue depressors, aluminum splints or orthopedic casting material<sup>15</sup> (Figure 16.16). Fractures involving the tarsometatarsus should be combined with a ball bandage to immobilize the foot. The Robert Jones bandage is contraindicated for leg fractures of the femur, proximal two-thirds of the tibiotarsus and in larger birds (eg, over 500 g) because of inadequate immobilization.

A thick layer of casting material is wrapped from the top of the foot to the most proximal point of the leg. The leg is slightly flexed, conforming gauze material is tightly wrapped around the cast padding, additional splinting material is incorporated into the bandage and tape or self-adherent bandaging material is used to cover the bandage. The toes should be monitored for swelling and discoloration if they are not incorporated within the bandage.



**FIG 16.16** An adult male Amazon parrot was presented for an acute onset of a non-weight-bearing lameness. The bird's wing had been improperly trimmed, and it fell from the top of its enclosure to a concrete floor. Radiographs indicated an oblique fracture of the mid-tibiotarsus. The owner chose a cast repair (right) over the application of an external fixator. In this case, with a calm bird and a minimally displaced fracture, casting was sufficient coaptation to allow bone repair.

### Spica Splint

Spica splints may be used for simple, aligned fractures of the femur in smaller birds, but generally need to be combined with orthopedic fracture repair in larger birds (eg, over 300 g).<sup>7,28</sup> Splint material can be molded from orthopedic casting material<sup>7,8</sup> or padded aluminum finger splints. This splint is a modification of the Robert Jones bandage, except that the padded, molded splint extends from the tibiotarsus proximally and over the bird's pelvis in an inverted U-shape to immobilize the femur against the body of the bird.

### Ball Bandage

Indications for ball bandages (Figures 16.17) include moderate to severe forms of pododermatitis (bumble-foot), toe fractures and other soft tissue injuries involving the toes or feet in perching birds.<sup>12,29</sup>

The toes should be conformed around a stack of gauze sponges, and wrapped snugly with conforming gauze

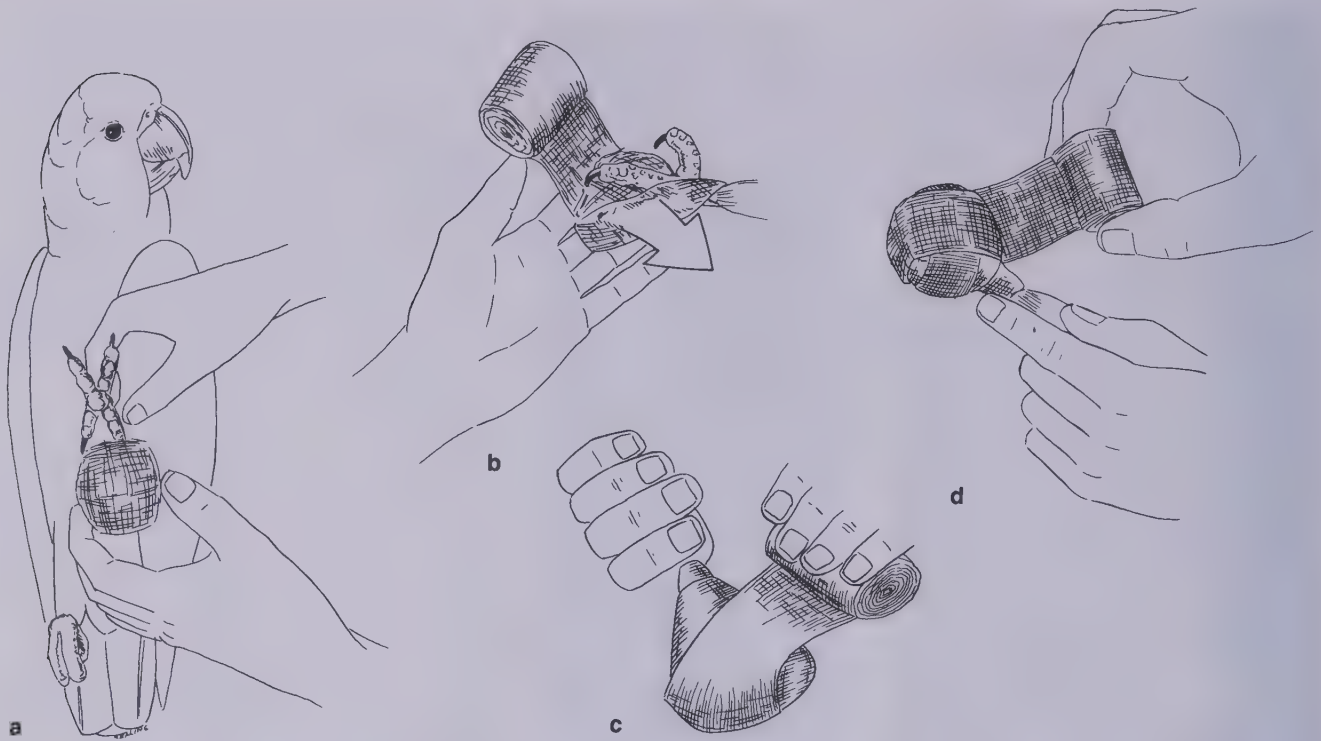
material to form a teardrop-shaped bandage. There should be adequate padding and support around the distal tarsometatarsus to allow the bird to be able to stand upright on the bandaged foot. It is also important to make sure that the bandage is not applied too tightly around the tarsometatarsus at the top of the bandage, which can cause vascular compromise of the foot. Birds with one or both feet in ball bandages should be placed in an enclosure with a padded surface.

### Other Leg and Foot Bandages and Splints

Various tape splints have been devised for immobilizing simple tibiotarsal and tarsometatarsal fractures in small birds.<sup>26</sup> Additional splinting material such as paper clip wire or toothpicks, balsa wood, pipe cleaners or wooden applicator sticks can be used to provide more stabilization. Such support must be properly padded over bony protuberances to avoid pressure ulcers. The joint above and below the fracture should be immobilized.

Toe fractures can be immobilized by taping two toes together, by splinting with a padded tongue depressor or cardboard in a modified "snowshoe" splint using two or more toes, or by using thermoplastic coated casting material<sup>8</sup> to mold a "shoe splint" to fit the entire foot (Figure 16.18). For small birds, hydrocolloid dressings can be used as splint material for tibiotarsal and tarsometatarsal fractures (see Figure 16.3). The hydrocolloid dressing should be covered by another bandage material to prevent chewing, and should be changed on a daily basis if it becomes moist. When the wound is dry, the dressing can be left in place for up to ten days.

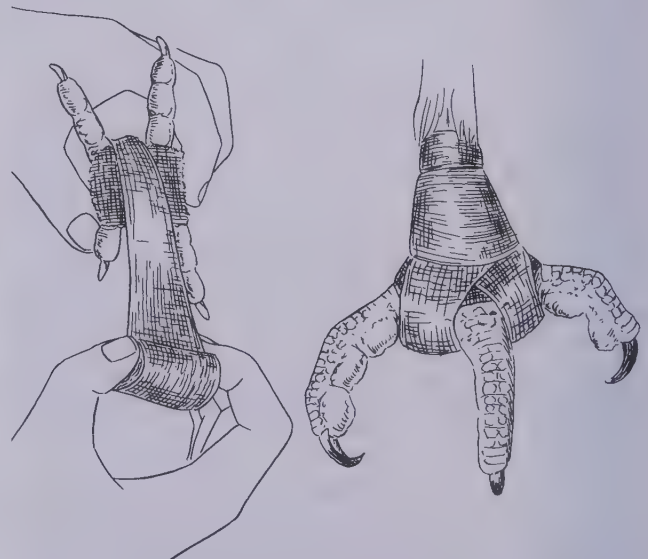
Soft tissue wounds involving the plantar surface of the foot can be effectively bandaged with an interdigitating bandage that leaves the toes exposed for perching (Figure 16.19). It is important to avoid applying the bandage too tightly, or using too much bandaging material between cranial digits. The lightest possible bandage would be used in finches and other small birds to prevent loss of balance.



**FIG 16.17** Ball bandages can be used to protect foot injuries while they heal. A stack of gauze pads or a piece of cardboard cut to fit the bottom of the foot is covered with cotton padding and placed on the plantar surface of the foot. The foot is then wrapped with a layer of rolled cotton padding and covered with a self-adherent bandage material.



**FIG 16.18** A snowshoe splint can be used to provide primary support for phalangeal fractures. The bandage is applied by wrapping the toes and foot in a protective layer of cotton padding. A “snowshoe”-shaped splint is fashioned out of Hexcelite and placed onto the plantar surface of the foot. The splint is held in place with cotton padding covered with a self-adherent bandage material.



**FIG 16.19** An interdigitating bandage is applied by placing gauze on the metatarsal pad and wrapping it in place with cotton padding, which is then covered with a self-adherent bandage.

### Products Mentioned in the Text

- a. Nolvasan, Fort Dodge Labs Inc, Fort Dodge, IA
- b. Betadine, The Purdue Frederick Co, Norwalk, CT
- c. Silvadene, Marion Labs Inc, Kansas City, MO
- d. Preparation H, Whitehall Labs Inc, New York, NY
- e. Telfa Pads, The Kendall Co Hospital Prod, Boston, MA
- f. Nu Gauze Sponges, Johnson & Johnson, New Brunswick, NJ
- g. Dermaheal or DuoDerm, Squibb, Princeton, NJ
- h. Epi-Lock, Virbac, Inc, Lenexa, KS
- i. Tegaderm, 3M Animal Care Products, St. Paul, MN
- j. Op-Site, T.J. Smith and Nephew, Welwyn Garden City, Herts, UK
- k. Bioclusive, Johnson & Johnson Prod, New Brunswick, NJ
- l. Kling, Johnson & Johnson Prod, New Brunswick, NJ
- m. Vetrap, 3M Animal Care Products, St. Paul, MN
- n. Kwik-Stop, Gimborn-Rich Health, Irvine, CA
- o. Collodium Flexible, Humco Lab, Texarkana, TX
- p. NuSkin, Medtech Labs Inc, Jackson, WY
- q. Durapore Tape, 3M Animal Care Products, St. Paul, MN, USA
- r. Orthoplast, Johnson & Johnson Prod, New Brunswick, NJ
- s. Hexcelite, Hexcel Medical Co, Dublin, CA
- t. Elastikon, Johnson & Johnson, Arlington, TX

### References and Suggested Reading

1. **Alvarez OM, Mertz PM, Eaglstein WH:** The effect of occlusive dressings on collagen synthesis and re-epithelialization in superficial wounds. *J Surg Res* 35:142-48, 1983.
2. **Awadhiya RP, Vegad JL, Kolte GN:** Studies on acute inflammation in the chicken using mesentery as a test system. *Res Vet Sci* 29:172-180, 1980.
3. **Baldry MGC:** The bactericidal, fungicidal, and sporicidal properties of hydrogen peroxide and peracetic acid. *J App Bact* 54:417-423, 1983.
4. **Barnett A, et al:** Comparison of synthetic adhesive moisture vapor permeable and fine mesh gauze dressings for split-thickness skin graft donor sites. *Amer J Surg* 145:379-381, 1983.
5. **Barnett A, et al:** Scalp as skin graft donor site: rapid reuse with synthetic adhesive moisture vapor permeable dressings. *J Trauma* 23(2):148-151, 1983.
6. **Bennett RA:** Tissue reaction to five suture materials in pigeons. *Proc Assoc Avian Vet*, 1992, pp 212-218.
7. **Bennett RA, Kuzma AB:** Fracture management in birds. *J Zoo Wildl Med* 25(1):5-38, 1992.
8. **Bojrab MJ:** A handbook on Veterinary Wound Management. Boston, Kendall Co, 1981.
9. **Cambre RC:** Use of DuoDerm hydroactive dressing (Convatec, Squibb) for wound healing in zoo animals. *Proc Am Assoc Zoo Vet*, 1984, pp 27-28.
10. **Carlson HC, Allen JR:** The acute inflammatory reaction in chicken skin: local cellular response. *Avian Dis* 13:817-833, 1969.
11. **Degernes LA, Redig PT:** Soft tissue wound management in avian patients. *Proc Assoc Avian Vet*, 1990, pp 182-90.
12. **Degernes LA, Talbot BJ, Mueller LR:** Prevention and treatment of bumblefoot in raptors. *Wildl Rehab* 9:73-78, 1991.
13. **Eaglstein WH, Mertz PM:** Effect of topical medicaments on the rate of repair of superficial wounds. In Dineen P, Hildick-Smith G (eds): *The Surgical Wound*. Philadelphia, Lea & Febiger, 1981, pp 150-167.
14. **Eaglstein WH, Mertz PM:** Effects of occlusive dressings on wound healing. *Clin Derm* 2:107-111, 1984.
15. **Eaglstein WH, et al:** Optimal use of an occlusive dressing to enhance healing. *Arch Derm* 124:392-395, 1988.
16. **Garcelon D, Bogue GL:** Raptor Care and Rehabilitation. Walnut Creek, Night Owl Press, 1977, pp 60-64.
17. **Gonzales-Tirado C:** The use of Epi-Lock, a semi-occlusive dressing on a deep wound in a blue peacock (*Pavo cristatus*). *Proc 1st Intl Conf Zool Avian Med*, 1987, pp 273-276.
18. **Halliwell WH:** Bumblefoot infections in birds of prey. *J Zoo An Med* 6(4):8-10, 1985.
19. **Jain NK, Vegad JL, Awadhiya RP:** Studies on acute inflammation in the chicken using turpentine-induced pleuroperitonitis as a test system. *Vet Rec* 110:421-22, 1982.
20. **Johnston DE:** Wound healing and reconstructive surgery. *J Am Anim Hosp Assoc Sci Proc* 2:383-398, 1975.
21. **Johnston DE:** The processes in wound healing. *J Am Anim Hosp Assoc* 13:186-196, 1977.
22. **Jortner BS, Adams WR:** Turpentine-induced inflammation in the chicken. A light- and electron-microscope study, with emphasis on the macrophage, epithelioid cell, and multinucleated giant cell reaction. *Avian Dis* 15:533-550, 1971.
23. **Kaplan JZ:** Acceleration of wound healing by a live yeast cell derivative. *Arch Surg* 119:1005-1008, 1984.
24. **Lee AH, et al:** Effects of gentamicin solution and cream on the healing of open wounds. *Am J Vet Res* 45:1487-1492, 1984.
25. **Lee AH, et al:** Effects of non-adherent dressing materials on the healing of open wounds in dogs. *J Am Vet Med Assoc* 190(4):416-422, 1987.
26. **Mertz PM, Marshall DA, Eaglstein WH:** Occlusive wound dressings to prevent bacterial invasion and wound infection. *J Amer Acad Derm* 12(4):662-668, 1985.
27. **Perry RA:** Avian dermatology. In Burr EW: *Companion Bird Medicine*. Ames, Iowa State University Press, 1987, pp 40-50.
28. **Redig PT:** Evaluation and nonsurgical management of fractures. In Harrison GJ, Harrison LR (eds): *Clinical Avian Medicine and Surgery*. Philadelphia, WB Saunders Co, 1986, pp 380-394.
29. **Redig PT:** Medical Management of Birds of Prey. St. Paul, MN, The Raptor Center, University of Minnesota, pp 130-141. **Date?**
30. **Redig PT:** Treatment of bumblefoot and the management of aspergillosis and various other problems commonly seen in raptors. *Proc 1st Intl Conf Zool & Avian Med*, 1987, pp 309-321.
31. **Riddle KE:** Surgical treatment of bumblefoot in raptors. In Cooper JE, Greenwood AG (eds): *Recent Advances in the Study of Raptor Diseases*. London, Chiron Press, 1981, pp 67-73.
32. **Swaim SF, Wilhah D:** The physics, physiology, and chemistry of bandaging open wounds. *Comp Cont Ed* 7(2):146-156, 1985.
33. **Swaim SF, Lee AH:** Topical wound medications: A review. *J Am Vet Med Assoc* 190(12):1588-1593, 1987.

CHAPTER

# 17

## ANTIMICROBIAL THERAPY

■  
Keven Flammer

**M**icrobial diseases are common in companion and aviary birds, and careful drug selection and delivery can greatly influence the outcome of many clinical cases.

In contrast to mammals in which it may be possible to try an empirical treatment regimen, birds are often presented in an advanced state of illness, necessitating immediate and correct diagnosis and treatment. For best results, antimicrobial therapy should be maximized early in the disease process.

Published avian drug doses are often based on clinical experience or data extrapolated from other species. Suggested doses may or may not be optimal, and avian veterinarians should be attentive to the possible toxic effects or lack of efficacy when treating birds with empirically derived doses. Sub-therapeutic dosing can result in treatment failure and encourage the development of microbial resistance. Excessive drug treatment may be toxic and damage the kidneys or liver. In particular, care should be extended when treating rare birds in which the effects of a specific drug have not been investigated.

The goal of antimicrobial therapy is to aid elimination of the infecting organism from the host. Antibiotics play only a partial role in this process, and the host immune system is usually required to resolve an infection. Supportive care is therefore an important component of the overall therapeutic plan. The clinical outcome of using an antimicrobial agent depends upon the intrinsic susceptibility of the agent and microbiological activity of the drug (efficacy), the ability of the drug to reach the site of infection at adequate concentrations (pharmacodynamics), and the ability of the drug to kill the pathogen without harming the host (selective toxicity). Other considerations include the route and frequency of administration, cost and ability of the bird owner to accomplish the treatment regimen. Because birds are often presented in a state of advanced illness and immunosuppression, the best drug should be given via the best route to maximize the chances for treatment success. A general approach to the treatment of microbial diseases is provided in Table 17.1.

## Factors Influencing Selection of an Antibiotic

There are no exact criteria to determine which antibiotic is best for each situation. Some of the important factors influencing the rational selection of an antibiotic are discussed below.

TABLE 17.1 General Approach to Treatment of Bacterial Diseases

1. **Identify** the pathogen and location of infection.
2. **Determine** the antimicrobial susceptibility of the isolate if the susceptibility cannot be predicted.
3. **Select** an antimicrobial drug based on susceptibility, ability to reach the site of infection, available routes of administration, required frequency of administration and minimal toxicity to the host.
4. **Determine** if it is feasible for the bird owner to complete the treatment regimen.
5. **Treat** with appropriate antibiotics.
6. **Maintain** host defenses by reducing stress and maximizing supportive care.
7. **Find** and **eliminate** the source of bacteria.
8. **Decontaminate** the bird's environment.

### Antimicrobial Spectrum

The target organism must be susceptible to the antibiotic at concentrations achievable at the site of infection if treatment is to be effective. Some microbial organisms have predictable susceptibility. For example, all strains of chlamydia are presumed to be susceptible to tetracyclines. If chlamydiosis is diagnosed, it is rational to begin therapy without a susceptibility test. Unfortunately, the most common infectious agents in psittacine birds (gram-negative bacteria, streptococcus and staphylococcus) have unpredictable antimicrobial susceptibilities, and an *in vitro* susceptibility test is required to aid drug selection.

Laboratories can determine the antimicrobial susceptibility of a bacterial isolate by two primary methods: disk diffusion and dilution tests. The Kirby-Bauer disk diffusion susceptibility test is a semi-quantitative method, and the test organism is classified as susceptible, of intermediate susceptibility, or resistant to the drug. It is important to understand that the classification "susceptible" is based on the

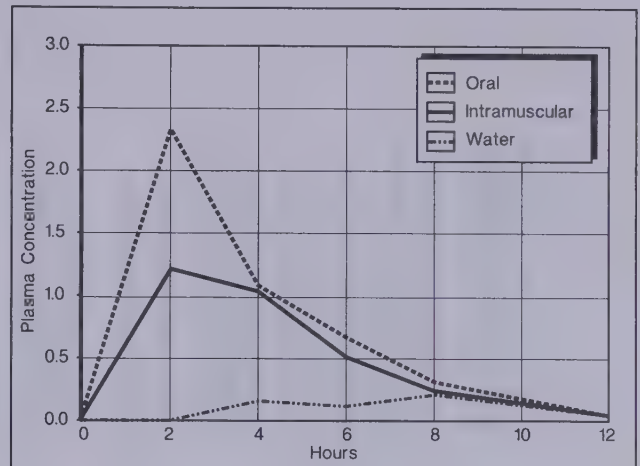


FIG 17.1 Plasma concentrations of enrofloxacin in African Grey Parrots vary with the route of administration. Bacteria must be highly susceptible (MIC <0.05 µg/ml) to be effectively treated with water-based administration.

antibiotic serum concentrations that are achieved by a *standard treatment regimen in humans* (or a test animal if the drug is veterinary-labeled). A pathogen that is classified as susceptible by an *in vitro* test will be susceptible in the bird only if similar concentrations are maintained at the site of infection. As explained below, the achievable drug concentrations are influenced by many factors including dose, frequency and route of administration. Therefore, if a disk diffusion susceptibility test indicates that an organism is resistant, treatment with that drug will not be successful. If the test indicates the organism is susceptible, then treatment *may* be successful if drug concentrations similar to those in humans are achieved in the bird.

Antimicrobial susceptibility tests using dilution methods determine the minimal inhibitory concentration (MIC) of the antibiotic. Since the MIC is quantitative, it allows the clinician to select the drug to which the organism is *most* susceptible and provides a better prediction of treatment success. An example illustrates how disk diffusion and dilution tests differ. When using a disk diffusion test to determine microbial susceptibility to enrofloxacin, all isolates with a zone of inhibition corresponding to an MIC of 2 µg/ml (based on achievable concentrations in dogs) would be reported as susceptible. It would not indicate if the organism was at the low end of susceptibility (0.03 µg/ml) or the high end (2.0 µg/ml). If a dilution susceptibility test were performed, the precise MIC for that organism would be determined. Figure 17.1 illustrates the plasma concentrations

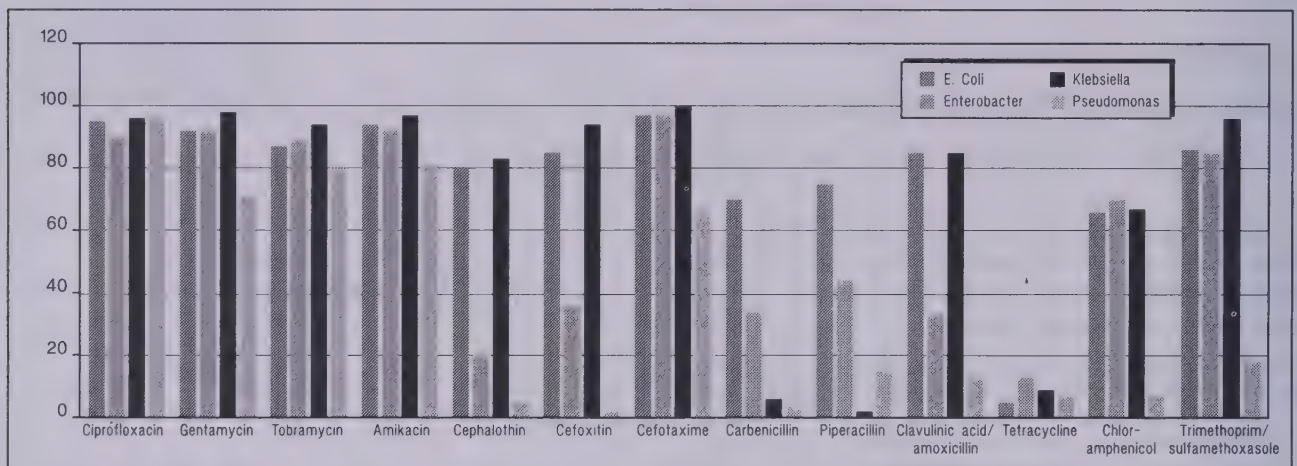


FIG 17.2 Susceptibility of gram-negative bacteria to commonly used antibiotics in one study of psittacine birds.

achieved when enrofloxacin is administered to African Grey Parrots by intramuscular, oral (gavage) or water route. This data shows that isolates with an MIC of 1-2  $\mu\text{g/ml}$  would not be successfully treated by enrofloxacin in African Grey Parrots under any circumstances; oral and IM administration would be effective against isolates with an MIC < 1.0  $\mu\text{g/ml}$ ; and water administration would be effective only against isolates with an MIC < 0.05  $\mu\text{g/ml}$ . The dilution test enables selection of a drug and route of administration that will have a high likelihood of success. Information on the pharmacokinetics of antibiotics in avian species is expanding, making decisions based on MIC data increasingly possible and effective.

In a severely ill patient, or in one that has an infection in an area that is difficult to culture, it may be necessary to start treatment without the benefit of a culture and susceptibility test. In these cases it is helpful to know the common causes of infection and the antimicrobial drugs most likely to be effective. There are many exceptions to the comments made below; however, following these suggestions can result in successful therapy. Figure 17.2 displays the predictive efficacy for using various antimicrobial drugs to treat gram-negative bacteria isolated from psittacine patients at the Veterinary Teaching Hospital, College of Veterinary Medicine, North Carolina State University. Antimicrobial susceptibility patterns vary geographically, so this data may not be applicable to all areas.

The most common causes of primary and secondary microbial infections in psittacine birds are gram-

negative bacteria, chlamydia and yeast. Gram-negative bacteria are frequently resistant to routine antibiotics (eg, ampicillin, tetracycline, chloramphenicol and erythromycin); however, most isolates are susceptible to trimethoprim/sulfa combinations, enrofloxacin, amikacin, and the advanced generation cephalosporins (eg, cefotaxime) and penicillins (eg, piperacillin). Yeast are usually confined to the alimentary tract and can be readily identified by performing a Gram's stain of a fecal smear. Most yeast are susceptible to treatment with nystatin, ketoconazole or fluconazole. Chlamydia are susceptible to treatment with tetracyclines.

#### CLINICAL APPLICATIONS

- Prolonged tetracycline therapy may be catabolic, cause immunosuppression, reduce normal gut flora or render a bird more susceptible to secondary pathogens.
- Nystatin must come in direct contact with yeast to be effective. If nystatin is delivered by gavage tube, infections in the mouth will not be treated.
- Medicated food and water are traditionally favored routes for poultry but seldom achieve therapeutic drug concentrations in companion and aviary birds.
- Birds receiving antibiotics should be monitored for secondary infections with cloacal cultures and fecal Gram's stains.
- Trimethoprim/sulfadiazine is often effective for treating gram-negative infections in nestling birds.
- Critically ill birds should be treated via parenteral routes to establish effective drug concentration quickly.
- On a body weight basis, a 0.05 ml injection in a canary is equivalent to a 40 ml injection in a 25 kg dog.
- Given orally, the IM formulation of enrofloxacin produces therapeutic plasma concentrations.



Less common infectious agents of psittacine birds are gram-positive bacteria (*Staphylococcus aureus* and some *Streptococcus* spp.), mycoplasma, systemic fungi and mycobacteria. Many of the *S. aureus* and streptococcus isolates tested by the author are susceptible to cephalexin or cephalothin. Mycoplasma are presumed to be susceptible to enrofloxacin, tetracyclines and tylosin. Systemic fungal infections are difficult to treat under any circumstances and require multiple drug therapy with amphotericin B and itraconazole, fluconazole or flucytosine. Mycobacteria are extremely difficult to eliminate. *Mycobacterium avium* can cause fatal infections in immunosuppressed humans, and therapeutic management must be considered with caution (see Chapter 33). A summary of the susceptibilities of common avian infectious agents to antimicrobial therapy is given in Table 17.2.

### Pharmacodynamics of the Drug

Antibiotics penetrate tissues differently, so the site of infection will also influence drug selection. Most bacteria remain extracellular while causing infection; however, there are a few notable exceptions (eg, salmonella, mycobacteria and some staphylococci). Treatment of intracellular infections may require drugs that are highly lipophilic and can penetrate cells (eg, chloramphenicol). Polar drugs (eg, the beta lactams and aminoglycosides) are frequently excluded from pharmacologically privileged spaces such as the cerebrospinal fluid (CSF) and ocular fluids.

Conditions at the site of infection are also important. Exudates, abscesses and granulomas create a hostile environment for the action of antibiotics. Perfusion of fibrous tissue is limited, and this may prevent the drug from reaching the site of infection. Changes in pH, oxygen tension, binding by intracellular proteins and slow microbial division may reduce antimicrobial activity. Surgical drainage or removal of an infected mass may be required before antibiotics can be effective.

The pharmacokinetics of the drug are also important. With bacteriostatic drugs, it is desirable to maintain the concentration of drug above the bacterial MIC for at least half of the dosage interval, and preferably throughout the interval, if this is attainable and not toxic. With most bacteriocidal drugs, it is not necessary to maintain the drug above the MIC for the entire dosage interval; however, if concentrations drop below the MIC for too long, the bacteria will

multiply, and a “break-through bacteremia” may occur. Drugs with a short half-life, like the beta lactams, must be given frequently to maintain effective concentrations.

Pharmacokinetic information is invaluable and has become available for specific drugs in some avian species, but it is likely that the use of extrapolated drug treatment regimens to untested species will continue to be a common practice in avian medicine. The extrapolation of pharmacokinetic data to untested species is complicated by the fact that there may be differences in the way that even individuals and closely related species absorb and excrete antimicrobial drugs.<sup>15</sup> For example, the aminoglycosides are excreted unchanged by the kidney, and the pharmacokinetics are similar across species lines. The recommended dose and elimination half-life are similar in cockatiels and macaws despite a 10-fold difference in body weight. The pharmacokinetics of drugs that are metabolized show greater variability.

For some drugs there is good correlation between dose and metabolic rate calculations based on body size. It has been suggested that the techniques of “allometric scaling” be used to extrapolate the doses of these drugs from human and mammalian medicine to birds.<sup>15,55</sup> Although allometric scaling has validity for some compounds, veterinarians should be aware of its limitations. Evaluation of drug excretion and potential metabolic pathways are important, as numerous exceptions to scaling exist — some with potentially toxic results. For example, the elimination half-life of chloramphenicol in budgerigars is twice as long as in macaws, despite a 30-fold difference in body weight. In this instance, scaling a dose from a macaw to a budgerigar would result in toxic doses, while scaling from a budgerigar to a macaw would result in completely ineffective doses. Unexpected differences are also seen with doxycycline. The elimination half-life of orally administered doxycycline in Goffin’s Cockatoos is approximately 20 hours, but in similarly sized Orange-winged Amazon Parrots it is approximately 10 hours.<sup>19</sup> Finally, scaling of a compound with a narrow therapeutic range such as gentamicin could result in potentially lethal dosage recommendations if the drug is scaled from doses from small to large species. Allometric scaling is a useful tool when pharmacokinetic data is not available, but it should be used with caution and the effects of dosing closely monitored. The adverse effects of improper antimicrobial therapy are discussed below in the section on toxicity and side effects.

## Route of Administration


Selecting the route of drug administration in birds requires careful consideration. Available routes include medicated water, medicated food, oral, intramuscular, intravenous, subcutaneous, intraosseous, intratracheal, inhalation and topical. Factors to consider when selecting a route include: 1) The severity of the infection. Critically ill birds should be treated with parenteral medications to establish effective drug concentrations quickly. 2) The number of birds to be treated. Medicated food or water may be the only practical way to treat multiple-bird flocks (Figure 17.3). 3) The availability of appropriate drug formulations. 4) The frequency of administration, resultant stress to the bird and the labor involved in completing the treatment regimen. 5) The ability of the owner to complete the treatment regimen.

As noted previously, the route of delivery greatly influences the drug concentration achieved in the host. For example, Figure 17.1 shows that the concentration of enrofloxacin achieved in African Grey Parrots by offering medicated water is one-tenth of that achieved by oral or parenteral administration. This data must be considered when interpreting antimicrobial susceptibility tests, as the achievable drug concentrations will depend on the route of administration.

The advantages and disadvantages of various routes are discussed below. In general, medicated food and water are traditionally favored routes for poultry but seldom achieve therapeutic drug concentrations in companion and aviary birds. Most serious microbial infections must be treated by the oral or a parenteral route.

### Water-based Drug Administration

- **Advantages:** It is easy, handling of the birds is not required and the birds will self-medicate several times daily. The presence of medication may decrease disease transmission via contaminated drinking water.
- **Disadvantages:** Consumption is erratic and therapeutic serum concentrations are rarely achieved, especially during the night when less water is consumed. Medicated water is often unpalatable, and reduced water consumption not only decreases therapeutic drug concentrations but may also result in decreased water consumption and dehydration. Many antibiotics are not stable or soluble in water.



**FIG 17.3** An adult cockatiel with a three-day history of anorexia was found on the bottom of the enclosure. Depression is a hallmark clinical sign of septicemia. These emergency cases usually require parenteral administration of broad-spectrum antibiotics, parenteral fluid therapy and corticosteroid administration to prevent endotoxic shock due to degenerating gram-negative bacteria.

- **Comments:** At first glance, medicated water would appear to be the ideal way to medicate many avian species. Unfortunately, with a few exceptions, medicated water will not adequately treat most companion and aviary bird diseases. Psittacine birds simply fail to drink enough water to consume adequate doses of most antimicrobial drugs, especially if they are ill. If water is consumed, low drug concentrations are usually sustained in the bird because small amounts of drug are consumed often. Only highly susceptible bacterial infections in a stable patient should be treated in this manner. Water-based drugs should not be used in sick birds where the rapid establishment of therapeutic drug concentrations is required. Water-based medications can be used as an adjunct to direct drug administration or in situations where direct medication is impossible. Water-based drugs are most successful against mild infections of the alimentary tract where the drug may have a local effect in the gut.

There are some specific drugs and therapeutic situations where water-based administration may be successful. Enrofloxacin may successfully treat highly susceptible gram-negative bacteria (MIC <0.05 µg/ml). Sulfachlorpyridazine may be effective against alimentary tract infections caused by highly susceptible strains of *Escherichia coli*. Spectinomycin may be effective against alimentary tract infections caused by highly susceptible strains of *E. coli*. Nitrofurazone may slow the spread of salmonella within a flock. Aminoglycosides (eg, gentamicin, neomycin and amikacin) are not absorbed but may have

a local effect against pathogens in the gut. Tetracyclines may slow the spread and alleviate clinical signs in birds with chlamydiosis but will not consistently clear birds of infection. Tetracyclines degrade rapidly in water. Chlorhexidine may inhibit the spread and severity of candida infections of the alimentary tract.

### Food-based Drug Administration

- **Advantages:** It is easy, the birds will self-medicate several times daily, capture and handling are not required and food consumption is often more consistent than water consumption. It may be possible to medicate nestling birds by adding medication to the food of their parents.
- **Disadvantages:** Food often reduces drug absorption and sick birds consume less food, especially if the medicated ration is unpalatable. As with medicated water, it is difficult to achieve therapeutic concentrations with food-based administration. Psittacine birds are notorious for refusing new foods and may reject even palatable medicated rations if the diet must be changed to provide a food that will carry the drug.
- **Comments:** Powders, ground tablets and oral suspensions can be added to a palatable food vehicle such as cooked mashes, rolled corn, canned and frozen vegetables or fruit mixtures. A cooked mash containing 13% dry oatmeal and 29% each cooked kidney beans, rice, and corn is nutritious and well accepted by many psittacine birds. If a favorite treat food is well accepted and quickly consumed, it may be possible to lace it with the divided daily drug dose and offer it several times daily. If the drug must be added to food consumed on an intermittent basis throughout the day, the total daily dose plus extra (based on wastage and estimated reduced drug availability) should be placed in the amount of food the bird will consume in one day. As with medicated water, the achievable serum drug concentrations are usually much lower than those reached with oral or parenteral administration, so only highly susceptible bacteria should be treated with food-based medications.

Formulated diets containing chlortetracycline are commercially available and can be used to treat chlamydiosis. Chlortetracycline-impregnated millet seed<sup>a</sup> is also available and is readily accepted by budgerigars and finches. These products sustain chlortetracycline blood concentrations of 0.5-1.5 µg/ml when fed with diets containing < 0.7% calcium.

It is also possible to prepare a medicated mash using powdered chlortetracycline.

Research on developing doxycycline-medicated diets illustrates the importance of standardizing the components of a medicated ration. Consumption of the diet determines the amount of drug ingested and is dependent on energy content, palatability and familiarity of the diet. For example, cockatoos receiving ad libitum diets medicated with identical concentrations of doxycycline (0.1%) achieved toxic plasma concentrations (8-10 µg/ml) when fed a medicated corn and soybean mash, adequate concentrations (1-2 µg/ml) when fed a medicated rice, corn, bean, and oatmeal mash, and low concentrations (< 0.5 µg/ml) when fed medicated pellets. The primary difference among these diets is the energy content. Drug concentrations for medicated feed cannot be extrapolated from one diet to another without knowing the energy content and palatability of the diets.

### Oral Medication

- **Advantages:** A precise dose can be administered and, because many drugs are available as oral suspensions in flavored pediatric strengths, dosing is easy. Sick birds frequently require assisted feedings, and these drugs can easily be added to the feeding formula.
- **Disadvantages:** Unless the bird is tame and finds the medication palatable, the bird must be captured and fully restrained to deliver the medication. This is stressful, and some birds will refuse to swallow medications or may aspirate them into the nasal passages. It is often necessary to pass a tube and deliver oral drugs into the crop of recalcitrant birds. Drug selection is restricted since not all drugs are absorbed orally (eg, aminoglycosides, advanced generation penicillins and cephalosporins). Some birds, (eg, macaws) may regurgitate medications delivered per os.
- **Comments:** It is surprisingly difficult to force psittacine birds to accept oral medications. Bird owners may initially be able to administer the drug, but as treatment progresses the bird may become more difficult to medicate. Sometimes the stress of handling exceeds the benefits of the drug itself. Acceptance can be improved if the drug is mixed with a palatable vehicle such as lactulose syrup or fruit juice. Oral suspensions and solutions are appropriate for use in all birds; tablets and pills are probably not appropriate for use in birds with a crop. Capsules that rapidly dissolve can be used in those birds that are "pillable" (eg, pigeons, waterfowl and gallinaceous birds).

### Intramuscular Injection


- **Advantages:** An exact dose can be administered, and absorption is usually rapid. The bird must be captured, but restraint time is minimal.
- **Disadvantages:** Not all antibiotics can be given IM, and injections may be painful and cause muscle necrosis (Figure 17.4). The volume of injected fluid must be carefully monitored in small patients.
- **Comments:** Intramuscular injection is often the quickest and least stressful method of directly administering drugs to companion birds. It is often easier to administer drugs IM than orally, and most bird owners can be taught to perform this procedure. The pectoral muscles provide the optimal injection site. Drugs injected into the muscles of the legs may pass through the renal portal system first, clearing the drug before it can reach the systemic circulation. Injection sites can be rotated to avoid excess trauma in one area. Short, 26 ga x 3/8" intradermal needles or insulin syringes work well.

Intramuscular injection may not be feasible in all birds. Nestling birds of all species have relatively little pectoral muscle mass, and it is easy to pierce the sternum, which is non-ossified at this age. Ratites, even as adults, lack large pectoral muscles. Owners of racing pigeons, raptors and some game birds may refuse to give medications IM in the breast because they fear muscle damage will interfere with flight or normal activity.

The injection volume in relation to body size must also be considered. For example, on a body weight basis, a 0.05 ml injection in a canary is equivalent to a 40 ml injection in a 25 kg dog. Injection volumes in psittacine birds should be small but permit accurate measurement of the medication.

### Subcutaneous Injection

- **Advantages:** An accurate dose and large volumes can be administered. This is a good site for fluid administration if the bird is not volume depleted or severely dehydrated. The best sites are the groin and dorsal cervico-thoracic area.
- **Disadvantages:** Full restraint is required. Birds have very thin skin and fluid will often leak out of the injection site. Irritating drugs may cause skin necrosis and ulceration.
- **Comments:** The subcutaneous route is not ideal but can be used for irritating drugs when muscle necrosis



**FIG 17.4** Muscle necrosis secondary to a single IM injection of ticarcillin. Many of the drugs available for parenteral administration in birds can cause mild to severe muscle necrosis.

or injection trauma is to be avoided. This site is often used by pigeon and game bird breeders.

### Intravenous Injection

- **Advantages:** An exact dose can be given and therapeutic levels are rapidly achieved.
- **Disadvantages:** The bird must be fully restrained; anesthesia may be helpful. Because avian veins are fragile, leakage of drug from the vessel and hematoma formation are common.
- **Comments:** Intravenous injection should be reserved for emergencies and one-time drug administration. Veins may also be needed for blood withdrawal for diagnostic tests. The right jugular, superficial ulnar, basilic vein on the ventral humerus and medial metatarsal veins are most accessible. Intravenous catheters are available but are potentially dangerous to leave in unattended birds. Intravenous fluids can be delivered as a slow bolus at a dose of 10 ml/kg without pulmonary compromise.

### Intraosseous Injection

- **Advantages:** If repeated drug administration is required the intraosseous route may be selected (Figure 17.5). The intraosseous route allows stable access to the intravascular space. A cannula can be inserted and used for repeated fluid or drug administration. If properly bandaged, psittacine birds will usually tolerate cannulas for short periods of time. Intraosseous cannulas are well tolerated in raptors, pigeons, waterfowl and other less temperamental species. The



**FIG 17.5** It may be safe to deliver some drugs designed for IV administration through indwelling intraosseous cannulas. If several days of therapy are necessary, the cannula can be placed in the ulna. For birds that need only a single administration of a drug that must be given slowly (most IV products), a cannula can be placed in the tibia. It has not been determined which of the IV drug preparations can safely be delivered through IO cannulas.

distal ulna and proximal tibia are the best locations for cannulation.

- **Disadvantages:** Only fluids or non-irritating drugs should be delivered via intraosseous cannulas. Sterility is critical, as infection may result in osteomyelitis.

#### Nebulization

- **Advantages:** Nebulized antibiotics are useful for pulmonary, sinus and trachea infections, and are often combined with mucolytic and penetrating agents (eg, DMSO) to break down caseous material and increase antibiotic uptake. Simple humidification of the lungs is also helpful. Therapeutic serum levels are seldom achieved but effective concentrations may be achieved in restricted sites in the upper respiratory tract.
- **Disadvantages:** At rest, there is little or no air exchange in much of the respiratory tract. It has been suggested that only 20% of the respiratory tract would be reached by nebulization.<sup>2</sup> The nebulized particle size should be less than 1-3  $\mu\text{m}$ . Nebulization should usually be combined with systemic therapy.

#### Topical Medications

- **Skin:** Topical medications should be used carefully and sparingly. Oily and toxic compounds should be avoided, as they will mat the feathers and be ingested when the bird preens. A water-soluble formulation should be selected if available. If it is necessary to use

greasy compounds, the site should be bandaged or the bird collared to prevent preening and ingestion. Propylene glycol can be added to some preparations (eg, ivermectin) to allow systemic absorption of cutaneously applied drugs.

- **Eye:** Liquid eye drops retard corneal healing less than ointments but must be given more frequently. Ointments should be applied very sparingly, as excess ointment will cause matting and loss of feathers surrounding the eye. Misting the eye with a water-soluble, topical spray may also be effective. Subconjunctival injections may be considered for delivering repository drugs.
- **Nasal Flushes:** Nasal irrigation can be very helpful for treating upper respiratory infections. Antibiotics can be added to flushing solutions, but in many cases unmedicated saline works as well. Isotonic solutions should be delivered with minimal pressure to avoid damage to inflamed tissues.
- **Infraorbital Sinus Injection:** Sinus injection is useful for flushing and delivering medication into the infraorbital sinus in birds with sinusitis. The injection is made at the level of the commissure of the beak, just ventral to the zygomatic arch, the same site as for cytologic sampling (see Chapter 10). Care must be taken not to penetrate the globe of the eye. If sinusitis has resulted in blockage of the outflow tracts, low volumes of fluid must be slowly injected to prevent exophthalmus. Only non-irritating drugs should be used.
- **Intratracheal** (through the glottis): This is an effective route for delivering amphotericin B to birds suffering from tracheal and pulmonary aspergillosis.

#### Toxicity and Adverse Effects of Antimicrobial Therapy

All antimicrobial drugs have the potential to harm the host. Direct toxic effects and the reduction of normal alimentary tract flora can occur even when antibiotics are used properly, requiring that birds should be monitored during treatment. Treatment failure and the development of resistant strains of bacteria occur most often when drugs are used improperly. Because the interplay between effective treatment, toxicity and adverse side effects is complex, the use of antimicrobials in birds should be pursued with caution, and routine prophylactic treatment of birds without a clear indication of infection is not suggested in any circumstance.

Misuse of antimicrobials can have serious consequences, especially in an avicultural facility or multiple-bird household. Selection of the wrong agent can result in treatment failure and spread of disease-causing organisms by the inappropriately treated bird. Use of low-dose administration (eg, drinking water-based) often generates resistant strains of bacteria that may become established in the aviary. This, coupled with the stress and adverse effects of drug delivery on normal flora, can actually make a disease problem worse rather than better. When prescribing antimicrobials, it is important to explain to the client the necessity of giving the full treatment regimen without skipping doses, even if the bird improves before treatment ends. This is necessary to prevent a recurrence of the infection and generation of resistant strains of bacteria.

#### Direct Toxic Effects

Drug toxicity varies with the compound, dose and physiologic status of the patient. Toxic effects of specific agents are listed in the section below, but some generalities can be made. The beta lactam antibiotics have relatively few direct toxic effects. The aminoglycosides are nephrotoxic at therapeutic doses and should be used with extreme caution in juvenile and dehydrated birds. Sulfa drugs should also be used cautiously in birds that are uricemic, because they are potentially nephrotoxic in dehydrated animals and are metabolized via the same metabolic pathway in the liver as uric acid. The fluoroquinolones cause defects in the articular cartilage of some species of growing animals (eg, dogs, pigeons and horses) but not others (eg, cats). These effects are both species- and dose-dependent. To date, toxic effects have not been proven in psittacine birds treated with recommended doses of fluoroquinolones.

#### Adverse Effects on Normal Alimentary Tract Flora

Most of the antibiotics used in avian practice are broad spectrum and their use will reduce or eliminate normal alimentary tract flora. Normal flora help reduce infection by potentially harmful microorganisms by competing for nutrients and occupying cellular attachment sites. Eliminating normal flora may render the bird more susceptible to colonization by potential pathogens such as yeast, viruses and gram-negative bacteria. Birds receiving antibiotics should be monitored for secondary infections with cloacal cultures and fecal Gram's stains.

Inappropriate antimicrobial therapy may potentiate an infection if the pathogen is resistant but the drug selected eliminates normal flora. This will favor

growth of the pathogen in a competition-free environment (eg, digestive tract, skin, nasal passages). For this reason, drugs and the route of administration should be selected with care, and non-specific prophylactic use of antimicrobials should be avoided. It may also be advisable to culture the cloaca prior to antimicrobial treatment of all birds, even if the alimentary tract is not the primary site of infection. If potential pathogens are isolated, the treatment regimen should include a drug that will be effective for these organisms as well as the primary pathogens; otherwise minor alimentary tract pathogens may proliferate and cause illness if the competition from normal flora is eliminated. Environmental sources of harmful microorganisms should be eliminated during antimicrobial treatment by improving husbandry. Young and immunocompromised birds should be monitored every day during antimicrobial therapy to prevent potential yeast infections.

#### Treatment Failure

Birds are perceived to be masters at hiding their signs of disease and are often in an advanced state of illness by the time they are presented for treatment. It is important to establish a correct diagnosis and implement an effective treatment plan early in the disease process because there is seldom time to simply try a drug and see what happens. If the wrong drug or route of administration is selected, or if the problem is not due to a microbial infection, the bird may die while waiting to determine if prophylactic therapy is successful.

Some pet stores may sell over-the-counter (OTC) antibiotics with label claims that they are beneficial for treating a variety of avian respiratory and gastrointestinal complaints. Most of these products contain tetracycline, erythromycin or a sulfa drug, and are compounded for water administration. These products are *seldom* effective at the doses and routes recommended, and many bird owners waste valuable time attempting treatment with these products before consulting an avian veterinarian. By the time the bird receives appropriate care, it is usually too late. Bird owners should be educated to avoid these useless medications and to use more effective diagnostic and therapeutic methods with their pets.

#### Development of Resistant Strains of Bacteria

Bacteria develop resistance to drugs by two primary methods: transfer of plasmids and chromosomal mutation. These methods may: 1) induce production of an enzyme that degrades the antibiotic; 2) alter membrane permeability and therefore prevent the

antibiotic from penetrating the bacteria; or 3) create an alternate metabolic pathway that bypasses the action of the antibiotics. Plasmids are cytoplasmic bundles of nucleic acid that can be transferred among different species of bacteria, and are therefore the most important mechanism of developing, maintaining and transferring resistance in a bacterial population. Resistance is most common among gram-positive and gram-negative bacteria and less common in anaerobes, chlamydia and yeast.

Sub-therapeutic treatment can encourage the development of resistant bacteria. If low antibiotic concentration is achieved at the site of infection (such as typically occurs with water-based treatment regimens), only the highly susceptible bacteria will be killed. The remaining resistant bacteria will then multiply to use the space and nutrients formerly consumed by the susceptible bacteria. Over time, resistant bacteria may become established in a hospital or aviary. Sub-therapeutic or random non-specific treatment would be considered worse than no treatment at all if resistant bacterial strains are generated at the same time normal alimentary tract flora is reduced.

### Cost

The small size of most avian patients makes it possible to economically use antibiotics that would be too expensive in traditional small animal species. This permits use of a variety of advanced generation antibiotics, especially among the beta lactams. In appropriate situations, these antibiotics are quite effective; however, they should not be used inappropriately, or microbial resistance will occur.

## Antibacterial Therapy

The following sections were written to provide concise, practical information about the pharmacology and use of antimicrobial drugs in birds, primarily psittacines. More exhaustive reviews of drug pharmacology and use in poultry are available in the references (see Chapter 18).<sup>47,51</sup>

## Fluoroquinolones

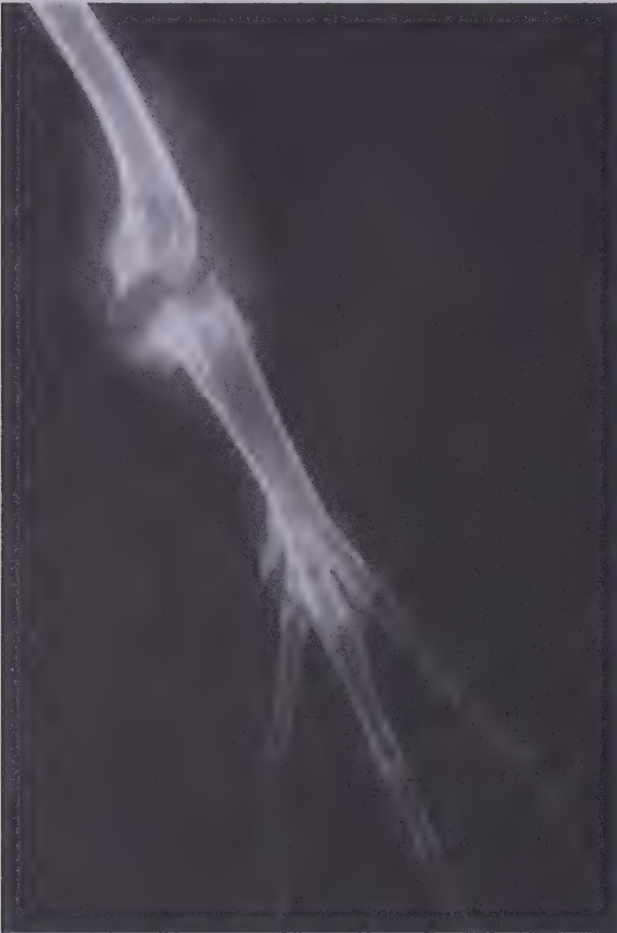### Pharmacology

The fluoroquinolones are a relatively new class of antimicrobial drugs that inhibit bacterial gyrase, the enzyme responsible for coiling DNA within the bacterial nucleus. They are bactericidal, widely distributed to tissues and the extracellular space, and are excreted primarily through renal tubular secretion and glomerular filtration. There is some hepatic metabolism, and enrofloxacin is partially metabolized to ciprofloxacin, an equipotent metabolite. Fluoroquinolones are generally well tolerated, although gastrointestinal upset and anorexia have been occasionally reported, and they may induce seizures in seizure-prone animals. High-dose or prolonged treatment may cause permanent articular defects in growing juveniles of certain species, including dogs, pigeons and horses.<sup>36</sup>

### Use in Companion Avian Medicine

- **Enrofloxacin:** Enrofloxacin is currently the only veterinary-labeled fluoroquinolone. It has excellent activity against mycoplasma, some gram-positive bacteria and most gram-negative bacteria. Resistance of *Pseudomonas* spp. is occasionally seen. Enrofloxacin is highly active against most Enterobacteriaceae recovered from psittacine birds. It reduces clinical signs in birds infected with *Chlamydia psittaci*, but anecdotal comments indicate that enrofloxacin treatment does not routinely clear the carrier state. Currently, only tablets and IM preparations are available in the United States. A water-soluble liquid is available in some countries.

Studies on the single-dose kinetics of enrofloxacin in healthy African Grey Parrots, Blue-fronted and Orange-winged Amazons, and Goffin's Cockatoos indicate that a dose of 7.5-15 mg/kg administered IM or PO BID should maintain effective concentrations in these species.<sup>26,27</sup> Elimination in the African Grey Parrot was more rapid than in the Amazon parrot or cockatoo. For highly susceptible bacterial infections (MIC  $\leq$  0.03  $\mu\text{g/ml}$ ) in the Amazon parrot and cockatoo, SID therapy may be adequate. Intramuscular injection achieves greater peak concentrations (3-5  $\mu\text{g/ml}$  versus 1-1.5  $\mu\text{g/ml}$  with oral administration at 15 mg/kg), but concentrations after two to four hours are similar to those achieved with oral administration of the water-soluble solution. The IM formulation causes irritation at the site of injection, but given orally, the IM formulation induces higher peak plasma concentrations (1.5-2.5  $\mu\text{g/ml}$  at 15 mg/kg) than the water-soluble formulation.



**FIG 17.6** A duck with osteomyelitis of the tibiotarsal/tarsometatarsal area. Surgical debridement and long-term antibiotic therapy are usually required to resolve bone infections.

Mean plasma concentrations of approximately 0.1 µg/ml were maintained in African Grey Parrots fed drinking water medicated at 0.19-0.38 mg/ml. These concentrations might be effective for highly susceptible gram-negative bacteria.<sup>25</sup> Effective clearance of gram-negative bacteria from psittacine birds has been reported using IM (10 mg/kg SID) or water-based administration (100-200 ppm) for ten days.<sup>36</sup> Combination therapy in Senegal Parrots treated with enrofloxacin-medicated drinking water (100 ppm) and ketoconazole (30 mg/kg PO SID) for 10 days produced evidence of renal toxicity.<sup>36</sup> The half-life of enrofloxacin in pigeons was 2.6-4.7 hours with tissue concentrations exceeding those of serum in one hour. Recommended doses are 5 mg/kg, BID IM, PO or SC, or 100-200 ppm (0.1-0.2 mg/ml) in the drinking water for highly susceptible bacteria.<sup>14</sup>

Enrofloxacin and ciprofloxacin have been widely used in psittacine nurseries without reports of side effects. However, the drug should be used with caution in growing birds since toxic effects are species-specific and dose-related, and the drug has not been studied in all species. There have been scattered, anecdotal reports of aggressive, irritable behavior in adult Amazon parrots treated with quinolones.

- **Ciprofloxacin:** Ciprofloxacin is a human-labeled fluoroquinolone with an antibacterial spectrum and pharmacology similar to enrofloxacin. Ciprofloxacin tablets appear to be more water soluble than enrofloxacin. Ciprofloxacin has not been shown to have a therapeutic advantage over enrofloxacin.

#### Comments

The fluoroquinolones, especially enrofloxacin, are among the most effective drugs for treating gram-negative bacterial infections (Figure 17.6). Effective treatment with BID (or in some species, SID) administration is a clear advantage over some other antibiotics. Enrofloxacin can be administered orally but is bitter, and many birds will refuse to accept it. It may be necessary to dilute the drug in a palatable vehicle such as fruit juice or lactulose syrup, or to deliver it via a gavage tube. The major disadvantage to parenteral administration is intramuscular pain and irritation at the site of injection.

#### ■ Penicillins

- **Characteristics:** The penicillins are beta lactam antibiotics. They inhibit the formation of the bacterial cell wall and are bactericidal for growing and dividing organisms. The spectrum and route of administration vary with the generation of the product. Older agents, such as ampicillin and amoxicillin, are effective against many gram-positive and some gram-negative organisms, and are available in oral and injectable formulations. Later-generation penicillins such as ticarcillin and piperacillin have enhanced activity against gram-negative bacteria, including *Pseudomonas* spp., but are primarily available in parenteral formulations.<sup>40</sup>

Penicillins are widely distributed to the extracellular space but poorly penetrate the CSF. Excretion is rapid (half-lives are usually less than 60 minutes) and is accomplished primarily through renal tubular secretion and glomerular filtration. Penicillins are considered relatively nontoxic, although allergic reactions (anaphylaxis) can occur. Procaine penicillin may cause adverse reactions in small patients (eg,



finches, canaries, budgerigars and cockatiels) due to the procaine component. Penicillins have reduced efficacy in the presence of overwhelming numbers of organisms ("inoculum effect"). Penicillins are synergistic when combined with aminoglycosides, and this combination can be used to treat severe infections, especially those caused by *Pseudomonas* spp.. These two agents should not be combined in the same syringe or the aminoglycoside will be inactivated.

#### Use in Companion Avian Medicine

- **Natural Penicillins:** Natural penicillins have a narrow spectrum restricted to *Pasteurella* spp. and some gram-positive organisms with MIC's less than 1 µg/ml. They are rarely used in avian medicine due to the availability of more effective drugs.
- **Ampicillin / Amoxicillin:** Many gram-positive bacteria are susceptible to ampicillin and amoxicillin, but most gram-negative isolates are resistant at concentrations achievable in birds. Oral absorption of ampicillin is highly erratic, so treatment failures are common even when laboratory tests suggest the isolated organisms are susceptible. Tests in chickens and ducks indicate that oral amoxicillin induces double the plasma concentrations of oral ampicillin.<sup>37</sup> Parenteral administration results in much higher and more consistent plasma concentrations. Ampicillin sodium doses of 100 mg/kg IM induced mean peak plasma concentrations of 60 µg/ml that declined to 0.65 µg/ml in four hours in Blue-naped Parrots. Based on this study, and another in Amazon parrots, it was recommended that ampicillin be dosed at 150 mg/kg PO QID.<sup>17</sup> Clark suggested that ampicillin in birds may be eliminated via hepatic and intestinal routes, in addition to renal excretion.<sup>9</sup>
- **Ticarcillin:** The pharmacology of ticarcillin is similar to that of carbenicillin; however, it is often two to four times more active against *Pseudomonas* spp. It is available for parenteral administration only.
- **Piperacillin:** In humans, piperacillin has greater activity against more gram-negative bacteria than other penicillins. It is widely used by avian veterinarians to treat systemic gram-negative bacterial infections. It is available for parenteral administration only. Serum and intestinal concentrations of piperacillin after an IM dose of 100 mg/kg in budgerigars were very high, and doses up to 1000 mg/kg did not induce clinically apparent toxic effects.<sup>32</sup> The half-life of piperacillin in Blue-fronted Amazon Parrots dosed with 100 mg/kg IM was less than 30 minutes, and doses of 75-100 mg/kg IM administered three to

six times daily have been recommended.<sup>23</sup> Higher and more frequent doses should be used in more severe infections.

- **Clavulanic Acid:** Clavulanic acid has no antimicrobial activity of its own, but when combined with a penicillin, it inhibits beta-lactamase, a bacterial enzyme that inactivates many penicillins. Formulations combining clavulanic acid with amoxicillin or ticarcillin are available. Reports of use in birds are rare, but this drug may offer safe, effective activity against gram-negative and gram-positive pathogens.

#### Comments

Early generation penicillins are appropriate for treating infections caused only by highly susceptible pathogens. The advanced generation penicillins have an excellent gram-negative spectrum and are appropriate for treating severe infections caused by these organisms. Penicillins have a very high therapeutic index, an advantage when treating patients with compromised renal or hepatic function. A major disadvantage of using penicillins is the frequency of administration required to maintain effective concentrations.

### Cephalosporins

#### Pharmacology

Like penicillins, the cephalosporins are beta lactam antibiotics; they share similar pharmacology but differ in spectrum.<sup>41</sup> Cephalosporins inhibit the formation of the bacterial cell wall and are bactericidal for growing and dividing organisms. They are widely distributed in the extracellular space, but most products poorly penetrate the cerebrospinal fluid and other pharmacologically privileged spaces. Excretion is primarily through renal tubular secretion and glomerular filtration. Cephalosporins are considered to be relatively nontoxic. They are classified into first, second and third generation products. In general, first generation products are effective against many gram-positive and some gram-negative bacteria, while increasing generations demonstrate enhanced gram-negative activity but reduced activity against gram-positives. Like the penicillins, cephalosporins also suffer from the "inoculum effect," and show reduced activity in the presence of overwhelming numbers of organisms. They are potentially synergistic when combined with aminoglycosides.

#### Use in Companion Avian Medicine

- **First Generation Agents** (eg, cephalexin and cephalothin): The antimicrobial spectrum of first genera-

tion agents includes most gram-positive cocci, some gram-negative bacteria and some anaerobes. Oral cephalexin is readily absorbed after oral administration in quail, ducks, cranes and emus. Doses of 35-50 mg/kg QID for larger birds and BID to TID for smaller birds have been recommended.<sup>42</sup> Cephalothin is available as a parenteral formulation, and, based on single-dose studies, therapeutic concentrations should be maintained with doses of 100 mg/kg IM QID in pigeons, cranes and emus, and BID to TID in quail and ducks. The author has successfully treated psittacine birds with cutaneous infections caused by *S. aureus* using administration of cephalexin at a dose of 100 mg/kg PO TID for 14-21 days.

- **Second generation agents** (eg, cefoxitin and cefotaxime) have increased gram-negative activity and are available primarily in parenteral formulations. There are few reports of their use in birds. Presumably, the pharmacology would be similar to first and third generation products.
- **Third generation agents** (eg, cefotaxime and ceftriaxone) have an expanded gram-negative spectrum (including increased activity against *Pseudomonas* spp.) and variable activity against gram-positive bacteria. Cefotaxime is unusual among cephalosporins because it penetrates the CSF in effective concentrations. Ceftriaxone has an extended half-life in humans (eight hours versus one hour for most other cephalosporins); however, the half-life is the same as other cephalosporins in Amazon parrots.<sup>23</sup> Doses of 75-100 mg/kg IM given three to six times daily should maintain effective plasma concentrations. These agents are mostly available in parenteral formulations; the use of newer drug preparations that can be given orally has not been reported in birds.

#### Comments

Recommendations are similar to the penicillins. First generation products have shown good activity against staphylococcus infections of the alimentary tract and skin of birds. The third generation products have an excellent gram-negative spectrum. Cephalosporins have a high therapeutic index, an advantage when treating patients with compromised renal or hepatic function. A major disadvantage of using cephalosporins is the frequency of administration required to maintain effective plasma concentrations.

## Aminoglycosides

### Pharmacology

The aminoglycoside antibiotics interfere with bacterial protein synthesis and are bactericidal.<sup>42</sup> They are not absorbed from the GI tract and must be administered parenterally. Aminoglycosides are confined to the extracellular space and poorly penetrate the eye and cerebrospinal fluid. Excretion is almost exclusively by glomerular filtration. Aminoglycosides must penetrate the bacterial cell wall to interfere with protein synthesis. This process requires oxygen, so aminoglycosides are not active against anaerobes or at sites with low oxygen tension (eg, large abscesses). Although aminoglycosides are poorly bound to blood proteins, they are extensively bound to intracellular proteins and may be inactivated in proteinaceous environments such as abscesses and exudates.

The aminoglycosides are relatively toxic when compared to other antibiotics. Nephrotoxicity and ototoxicity are relatively common, even in humans where dosage regimens are tailored for individual patients. The nephrotoxicity associated with recommended dosage regimens and short-term treatment is usually reversible once treatment stops. Chronic renal dysfunction occurs when high-dose or prolonged therapy is attempted. Since excretion is dependent on glomerular filtration, aminoglycosides should be used with caution in dehydrated patients. Another side effect, neuromuscular synaptic dysfunction and paralysis, can occur if the drug is given intravenously at a rapid rate.

### Use in Companion Avian Medicine

- **Early Generation Aminoglycosides:** Streptomycin, dihydrostreptomycin, neomycin and kanamycin have limited spectrum and greater toxicity, and are seldom used systemically in birds. Neomycin is used in topical and ocular formulations and can be administered orally to sterilize the gut.
- **Gentamicin:** Gentamicin is effective against many gram-negative and gram-positive bacteria. It is more toxic than amikacin, and signs of nephrotoxicity (eg, polyuria and polydipsia) are often encountered even when birds are treated with low doses. The degree of toxicity varies with individuals and species. For example, toxic reactions were more severe in Rose-breasted Cockatoos than in Scarlet Macaws treated with 5 mg/kg IM BID for seven days (Figure 17.7). The cockatoos remained polyuric for more than 30 days after treatment ended.<sup>24</sup> Based on these studies, gentamicin doses of 2.5-5 mg/kg IM BID should pro-

vide efficacious plasma concentrations and reduce toxicity. Variability in toxicity has also been demonstrated in raptors. Renal toxicity was found in Lanner Falcons treated with 5 mg/kg/day for four days,<sup>18</sup> and doses of 10 mg/kg administered BID for five days in Great Horned Owls produced reactions ranging from no signs to death. Doses similar to those in psittacine birds (2.5 mg/kg IM TID) are recommended for raptors.<sup>4</sup> Previously recommended doses (10 mg/kg IM TID) are excessive and may cause severe toxicity and death.

- **Tobramycin:** The pharmacology of tobramycin in mammals is similar to that of gentamicin, but it has greater activity against *Pseudomonas* spp. and some other gram-negative bacteria. Pharmacology studies in birds are lacking, but it is probably similar to gentamicin. In dogs and humans, tobramycin is considered slightly less toxic than gentamicin but more so than amikacin. The estimated dose for tobramycin is 2.5-5 mg/kg IM BID.

- **Amikacin:** Amikacin has excellent activity against many gram-negative bacteria, including some strains that are resistant to gentamicin and tobramycin. Amikacin is approximately four times less active than gentamicin but is correspondingly less toxic, so higher doses can be used safely. Amikacin causes fewer toxic side effects and is the aminoglycoside of choice for use in birds.

Pharmacokinetic studies have been completed in several psittacine species. Doses of 13 and 20 mg/kg IM in healthy Blue-fronted Amazon Parrots produced peak plasma concentrations of 40 and 75 µg/ml respectively that declined to zero by eight hours.<sup>20</sup> When these doses were administered for seven days, mild signs of toxicity (polyuria) occurred but rapidly resolved when treatment ended. Similar single-dose pharmacology was observed in cockatiels, Goffin's Cockatoos,<sup>20</sup> and Orange-winged Amazon Parrots and in African Grey Parrots.<sup>28</sup> Based on these studies, amikacin doses of 10-15 mg/kg IM administered BID or TID should provide effective plasma concentrations for most susceptible gram-negative bacteria. The higher end of the dosage range should be used with more resistant organisms, sites of infection with poor perfusion or in critically ill patients. In dehydrated birds and those with compromised renal function, the dose should be reduced or a less toxic drug selected.

### Comments

The aminoglycosides are excellent drugs for treating resistant gram-negative bacterial infections in birds. They are active against *Pseudomonas* spp., especially when combined with a third generation cephalosporin (eg, cefotaxime) or late generation penicillin (eg, piperacillin). However, these two agents must not be combined in the same syringe. Aminoglycosides should be avoided or used with care in dehydrated patients. Amikacin is currently the aminoglycoside of choice for avian use because of its broad spectrum and reduced toxicity compared to other aminoglycosides.

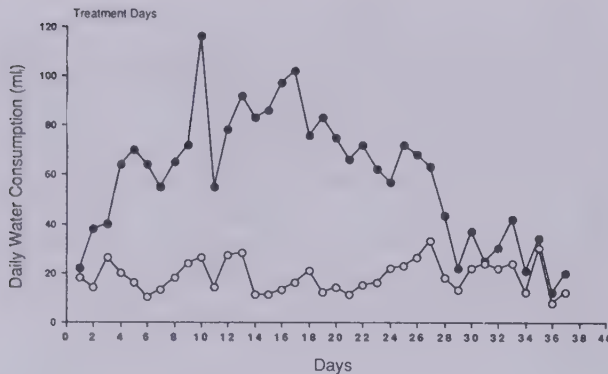
## Tetracyclines

### Pharmacology

Tetracyclines interfere with bacterial protein synthesis and are bacteriostatic.<sup>43</sup> In mammals, they are effective against a broad spectrum of gram-positive and some gram-negative bacteria. It is difficult to achieve concentrations that are effective for treating bacterial infections in companion and aviary birds, and tetracyclines are primarily used to treat chlamydiosis and mycoplasmosis. Tetracyclines are lipid soluble and are widely distributed to tissue. They are mostly available as oral formulations. Injectable formulations are available for some compounds but cause necrosis at the site of injection. Oral absorption is generally good except in the presence of cations such as calcium or magnesium, which chelate tetracyclines. The route of excretion varies with the compound. Oxytetracycline and chlortetracycline are excreted primarily by hepatic metabolism and renal excretion; minocycline is metabolized by the liver and excreted in the bile; and doxycycline is excreted as an inactive conjugate in the feces. Toxicity varies with the compound used, species of animal and duration of treatment. Tetracyclines will chelate calcium in the teeth and bone. GI upset and photosensitization have been reported. Prolonged treatment may have catabolic and immunosuppressive effects, reduce normal gut flora and render the animal more susceptible to opportunistic infections.

### Use in Companion Avian Medicine

- **Chlortetracycline:** Diets containing 1% chlortetracycline are recommended for treating psittacine chlamydiosis in the United States.<sup>12</sup> Diets containing 0.5% chlortetracycline have been shown to be effective in Europe. Powdered chlortetracycline can be added to a cooked mash, or medicated pellets are commercially available. The efficacy of these diets



**FIG 17.7** Adverse effects of gentamicin in Scarlet Macaws and Rose-breasted Cockatoos (Flammer, et al: *Am J Vet Res* 51[3]:406, reprinted with permission).

will vary with the nutritional composition of the ration. Birds will tend to consume less of a diet with a high-energy content (eg, formulated diets) and more if the energy content is reduced (eg, cooked corn mashes). Although medicated diets may be successful in reducing the clinical signs of chlamydiosis, common sequelae to treatment include diet refusal, starvation, treatment failures and secondary microbial infections.<sup>21</sup>

- **Oxytetracycline:** Water-soluble formulations of oxytetracycline are available, but oral absorption is poor. A long-acting injectable formulation<sup>c</sup> is available and may maintain plasma concentrations effective for controlling chlamydiosis in Goffin's Cockatoos for two to three days; however, this drug preparation is irritating and will cause necrosis at the injection site.<sup>22</sup> The single dose kinetics of intramuscular injection has been investigated in pheasants, Great Horned Owls and Amazon parrots.<sup>59</sup> It can be nebulized for treating respiratory infections, but must be dosed every four to six hours.<sup>16</sup>
- **Minocycline:** This drug has an extended half-life in mammals. It has been used experimentally to coat millet seeds and treat chlamydiosis in small psittacine birds.<sup>54</sup>
- **Doxycycline:** Doxycycline has a prolonged half-life and differs from conventional tetracyclines because it is more lipophilic. The half-life varies with the species. At oral doses of 50 mg/kg, the half-life averages ten hours in cockatiels and Amazon parrots and greater than 20 hours in cockatoos and macaws.<sup>19</sup> This is the drug of choice for treating chlamydiosis, and oral dosage recommendations are: 40-50 mg/kg PO BID in cockatiels and Blue-fronted and Orange-winged Amazons; 25 mg/kg PO BID in African Grey

Parrots, Goffin's Cockatoos and Blue and Gold and Green-winged Macaws. In untested species it is impossible to precisely extrapolate dosages; however, 25-30 mg/kg is the recommended starting dose in cockatoos and macaws, and 25-50 mg/kg is recommended in other species.

If regurgitation occurs, the dose should be reduced by 25% or divided and administered BID. Hepatotoxicity, as detected by elevated AST and LDH tests, may occur in macaws. Dosage recommendations for treating chlamydiosis in psittacine birds with injectable doxycycline (Vibravenös formulation only!) is 75-100 mg/kg IM every five to seven days. In macaws, the lower dose and more frequent administration should be administered in the last three weeks of treatment.<sup>29</sup> There have been anecdotal reports of use of pharmacist-compounded injectable doxycycline products; however, kinetic studies are lacking and it is impossible to extrapolate dosage schedules from one formulation to another.

#### Comments

In companion and aviary birds, tetracyclines are primarily used to treat chlamydiosis and, to a lesser extent, mycoplasmosis and pasteurellosis. Dosage regimens are based on attaining sustained blood concentrations of 1 µg/ml — a concentration thought to inhibit chlamydiosis.<sup>1</sup>

### ■ Trimethoprim / Sulfonamide Combinations

#### Pharmacology

A combination of trimethoprim and a sulfonamide is synergistic, as both drugs interfere with microbial folic acid synthesis.<sup>7</sup> This combination has good efficacy against many gram-positive and gram-negative bacterial pathogens, with the exclusion of *Pseudomonas* spp. Use of these drugs in combination has largely replaced use of either component alone for treatment of systemic bacterial infections. This combination is probably bacteriostatic at the doses used in birds. Oral and parenteral formulations are available and readily absorbed. The sulfa drugs are primarily distributed to the extracellular space, while trimethoprim is more lipophilic and has good tissue penetration. Excretion is primarily renal, and the degree of hepatic metabolism varies with the species. A number of side effects, including rashes, photosensitization, arthritis and hepatic disorders, have been reported in mammals but not in birds.

### Use in Companion Avian Medicine

The pharmacology of trimethoprim/sulfonamide combinations has been investigated in poultry,<sup>65</sup> geese<sup>52</sup> and pigeons,<sup>13</sup> but not in psittacine birds. Empirical doses of 16-24 mg/kg trimethoprim/sulfonamide (oral solution) administered BID, and 8 mg/kg IM (40 mg/ml trimethoprim + 200 mg/ml sulfadiazine) BID have been widely used clinically with good success.

Trimethoprim and sulfonamide combinations have few toxic effects, but many birds (especially macaws) suffer GI upset and will regurgitate one to three hours after an oral dose. The incidence of GI upset can be reduced if the drug is added to a small amount of food or if the dose is reduced. Sulfonamides form crystals and damage renal glomeruli in dehydrated birds and those with compromised renal function. The injectable product may cause irritation and necrosis at the site of injection.

Two formulations are available, each combining trimethoprim with a different sulfa drug. There is no clear advantage for either preparation. Trimethoprim/sulfadiazine (veterinary formulation) is available in injectable and oral forms. Trimethoprim/sulfamethoxazole (human formulation) is available in oral suspension.

### Comments

Trimethoprim/sulfadiazine is an excellent broad-spectrum bacteriostatic drug. It is often the drug of choice when using the oral route to deliver antibiotics (eg, treating gram-negative infections in nestling birds).

## Macrolides and Lincosamides


### Pharmacology

The macrolides and lincosamides interfere with bacterial protein synthesis, are bacteriostatic and share similar pharmacology.<sup>6</sup> Their spectrum of action includes gram-positive bacteria, pasteurella, bordetella, some mycoplasma and obligate anaerobic bacteria. Injectable formulations are available but are seldom used in birds due to irritation and necrosis at the site of injection. Oral absorption is good in mammals, but there are few pharmacokinetic studies in birds. All are well distributed to tissues and eliminated primarily by hepatic metabolism. Toxicity is usually limited to gastrointestinal irritation and vomiting.

### Use in Companion Avian Medicine

The primary uses for the macrolides are to treat gram-positive infections in finches, suspected or confirmed mycoplasma in psittacine birds and gram-positive or anaerobic osteomyelitis. These drugs are also active against *Campylobacter* spp. and *Clostridia* spp. Clindamycin is the most active of the listed drugs.

- **Tylosin:** The pharmacokinetics of intramuscularly administered tylosin has been studied in quail, pigeons, cranes and emus.<sup>38</sup> Peak concentrations of 3-5 µg/ml were achieved, and doses of 15-25 mg/kg TID to QID were recommended, with the cranes receiving the lower dose. Unfortunately, tissue necrosis at the site of injection would preclude a multi-day treatment regimen using the IM formulation at this frequency. Effective pulmonary concentrations were achieved with nebulization of 1 gram tylosin in 50 ml dimethyl sulfoxide (DMSO) for one hour.<sup>39</sup> Treatment of conjunctivitis in cockatiels with a tylosin and water spray has been suggested.<sup>33</sup>
- **Erythromycin:** Erythromycin is active against campylobacter and mycoplasma. Dosages have been investigated in pigeons,<sup>44</sup> but it is rarely used in companion and aviary birds. In humans, erythromycin is active against chlamydia, but it is not likely to eliminate this organism in birds at accepted avian dosages. A water-soluble powder has been used to treat mild respiratory infections in psittacine birds at a rate of 500 mg/gallon of water but is of questionable efficacy. A popular over-the-counter product<sup>b</sup> is available for medicating drinking water, but it is doubtful that this product achieves plasma concentrations effective for treating most microbial infections in companion birds.
- **Clindamycin:** Clindamycin is the most active of the macrolides mentioned. It is used to treat anaerobic infections and osteomyelitis caused by susceptible gram-positive pathogens. The author treated osteomyelitis in a macaw with a combination of enrofloxacin and clindamycin for seven months without detectable toxic effects.
- **New Macrolides:** Research on treating *Chlamydia trachomatis* infection in humans has focused on the use of new macrolide (azalide) antibiotics (ie, azithromycin and clarithromycin). These drugs are well tolerated and have a prolonged tissue half-life. Studies in humans have demonstrated that a single dose of either drug is as effective in eliminating *C. trachomatis* infection as a seven-day course of doxycycline. The



**FIG 17.8** Bacterial-induced pruritic dermatitis that was responsive to systemic antibiotic therapy. Many cases of bacterial dermatitis recur when therapy is stopped (photo courtesy of Louise Bauck).

disposition and safety of these drugs in birds remain to be investigated.

- **Lincomycin:** Lincomycin is usually combined with spectinomycin and has been used in finches to treat respiratory and alimentary tract infections caused by gram-positive bacteria and mycoplasma in other species.

## ■ Chloramphenicol

### Pharmacology

Chloramphenicol interferes with bacterial protein synthesis and is bacteriostatic.<sup>58</sup> Its antimicrobial spectrum includes many gram-positive and some gram-negative bacteria. It will inhibit chlamydial growth and alleviate clinical signs in infected birds, but will not routinely clear a bird of infection. Oral and parenteral formulations are available; however, oral absorption is highly erratic. Chloramphenicol is highly lipid-soluble and is widely distributed to most tissues, including the central nervous system. Tissue concentrations often exceed serum levels. The route of excretion varies with different species, but in most cases it is metabolized by the liver.

Potential toxic effects include reversible dose-related bone marrow depression, inhibition of hepatic microsomal enzyme synthesis, inhibition of host protein synthesis resulting in decreased wound healing and decreased immunoglobulin synthesis.<sup>58</sup> In a small percentage of the human population, non-dose-re-

lated, irreversible, aplastic anemia may occur, even with mild cutaneous contact. For this reason, clients are instructed to handle this drug carefully and wear gloves when treating birds.

### Use in Companion Avian Medicine

- **Oral Formulation** (palmitate ester): This formulation is readily accepted by most birds but achieves erratic blood concentrations.<sup>10</sup> It is infrequently used in avian medicine due to the potential toxicity in humans and the availability of more effective oral drugs (eg, trimethoprim/sulfa combinations and enrofloxacin).
- **Injectable Formulations** (succinate, propylene glycol-based): These formulations yield more predictable serum concentrations than the oral preparations. The succinate formulation yields lower serum concentrations, but is less irritating to muscle. There is wide pharmacokinetic variation among species. For example, the elimination half-life in budgerigars was longer than in macaws.<sup>10</sup> Doses of 50 mg/kg IM TID are recommended for most psittacine birds.

### Comments

Use of chloramphenicol has been largely replaced by other antibiotics that are more effective and can be administered less frequently. Chloramphenicol is still useful for treating infections caused by susceptible intracellular bacteria (eg, salmonella) and where penetration into the central nervous system is desired. Chloramphenicol is bacteriostatic and is probably not the drug of choice for initial treatment of severe, life-threatening infections.

## ■ Antifungal Therapy

The most common fungal infections encountered in psittacine birds, raptors and waterfowl are candidiasis (usually confined to the alimentary tract) and aspergillosis (respiratory and cutaneous).<sup>47</sup> Other fungal infections such as cryptococcosis, sporotrichosis, blastomycosis and histoplasmosis are infrequently encountered.

Historically, nystatin, flucytosine and amphotericin B have been widely used in birds. Development of the orally active, broad-spectrum azole antifungals (first

ketoconazole and more recently, fluconazole and itraconazole) may offer similar or greater efficacy, easier administration and lower toxicity. The major drawback to the use of azoles is the lack of pharmacokinetic and toxicologic information to guide dosage selection. However, empirical doses have been established, and use of these drugs is becoming established in avian medicine. As with antibacterial agents, spectrum, ability to reach the site of infection, route of administration and potential toxicity are important considerations when selecting an antifungal agent.

### Nystatin

#### Pharmacology

Nystatin is a polyene antimicrobial that disrupts the fungal cell membrane by substituting for ergosterol.<sup>48</sup> It is effective against most strains of candida and some other yeasts, although clinical evidence suggests resistant yeast strains may occur in some psittacine nurseries.<sup>46</sup> It is not absorbed from the GI tract and is available for oral or topical use only. Nystatin is relatively nontoxic due to the lack of systemic absorption, and is suitable for treating alimentary tract infections caused by candida and other susceptible yeast. It must come in direct contact with the yeast to be effective. Treatment failures may occur if the nystatin is delivered via a tube or syringe to the back of the oral pharynx, bypassing more rostral sites of infection in the mouth.

#### Use in Companion Avian Medicine

Nystatin is a highly useful drug for yeast infections that are confined to the alimentary tract. It has low toxicity and is safe for use in nestling birds. Some birds suffer GI upset and may regurgitate following repeated or large doses. With oral infections, nystatin or a more potent topical drug (eg, amphotericin B cream) can be applied directly to the lesions. If resistance or a non-alimentary tract infection is encountered, a systemically active antifungal should be used.

Nystatin dosage recommendations have been empirically derived but are supported by effective, long-term clinical use. Individual birds can be treated with 300,000 IU/kg orally BID or TID for five to ten days. Nystatin can also be added to hand-feeding formulas for prophylactic treatment in nurseries experiencing chronic yeast problems. If the yeast is highly susceptible to nystatin, food-based administration will be effective. A nystatin feed premix<sup>d</sup> has been used to medicate a mash diet to treat flocks.

### Amphotericin B

#### Pharmacology

Amphotericin B is a polyene antimicrobial drug that disrupts the fungal cell membrane by substituting for ergosterol.<sup>3</sup> It is active against most of the yeast and fungi of medical importance. Resistance by some strains of *Aspergillus* spp. has been reported in man and other animals. Comparison studies in humans have shown that amphotericin B is still one of the most efficacious antifungal drugs, especially for chronic infections and infections in immunocompromised hosts. Clinical data demonstrating improved efficacy when amphotericin B is combined with flucytosine or an azole antifungal are conflicting, but combination therapy is a common practice for treating serious fungal infections in humans. Amphotericin B is not well absorbed after oral administration and is too irritating for intramuscular or subcutaneous injection; thus, it must be delivered intravenously or used topically. It is widely distributed to tissue and extracellular spaces where it is metabolized and slowly excreted in the urine. Amphotericin B is highly nephrotoxic in mammals, although this can be reduced by instituting a step-wise dosing scheme based on renal function calculated from creatinine clearance levels.

#### Use in Companion Avian Medicine

Amphotericin B is one of the drugs of choice for initially treating serious, systemic fungal infections. Major disadvantages are potential toxicity and the need for IV administration. It has been used in combination with flucytosine in raptors and swans with fair results.<sup>48</sup> A new, orally active azole, itraconazole, may offer similar activity or may potentiate the effects of amphotericin B.

Amphotericin B can be nebulized or injected into an affected air sac for respiratory infections. It can also be injected through the glottis or administered trans-tracheally to treat tracheal and syringeal aspergillosis. A topical cream in a plasticized base is available for treatment of topical lesions and oral candidiasis.

The pharmacokinetics of amphotericin B in turkeys and selected raptors indicate that these birds eliminate the drug much more rapidly than mammals.<sup>52</sup> Based on these findings and clinical experience, doses of 1.5 mg/kg IV BID are recommended. Pharmacokinetic data in psittacine birds is lacking. Long-term use in raptors was not associated with nephrotoxicity, so the drug may be safer in avian than mammalian species.<sup>49</sup> However, until more informa-

tion on avian use is available, patients receiving this drug should be monitored for signs of nephrotoxicity (polyuria and uricemia).

## ■ Flucytosine

### Pharmacology

Flucytosine is converted by the liver to 5-fluorouracil, and exerts its antifungal effect by inhibiting DNA synthesis.<sup>34</sup> It is always used in combination with amphotericin B in humans, and this combination is considered useful for treating candida and cryptococcus infections. Resistance develops quickly when the drug is used alone. It is well absorbed orally, shows little protein binding and is widely distributed to tissues that are difficult to penetrate such as the CSF, eye and joints. This drug is excreted almost entirely unmetabolized in the urine, and dosage modifications are necessary in patients with reduced renal function. Dose-related, reversible bone marrow depression is the major toxic change seen in humans, presumably due to the conversion of flucytosine into 5-fluorouracil by GI tract bacteria. Hepatotoxicity and GI toxicity are occasionally reported in mammals.

### Use in Companion Avian Medicine

Flucytosine has been used singly as a prophylactic treatment to prevent aspergillosis in highly susceptible avian species undergoing stress (eg, hospitalization of swans) and in combination with other drugs to treat respiratory aspergillosis. *In vitro* susceptibility of eleven strains of *Aspergillus fumigatus* indicated that flucytosine doses of 20-30 mg/kg QID would maintain inhibitory plasma concentrations.<sup>49</sup> Because reported *in vitro* susceptibility data varies greatly, a combination of flucytosine, amphotericin B and rifampin has been suggested for treating respiratory aspergillosis in raptors.<sup>48</sup> Clinically, doses of 50 mg/kg orally BID for two to four weeks appears to prevent aspergillosis when prophylactically administered to swans (Degernes L, unpublished). Flucytosine has been safe for long-term use (two to four weeks) in raptors and waterfowl.<sup>49</sup> Roskopf, et al. reported successful treatment of esophageal and subcutaneous aspergillosis in a cockatoo using a combination of flucytosine (65 mg/kg orally BID) and ketoconazole (20 mg/kg orally BID) for approximately one month.<sup>53</sup>

Recently available azole compounds may replace flucytosine with drugs that are safer and more effective.

## ■ Ketoconazole

A major breakthrough in antifungal therapy occurred in 1979 with the release of the azole drug ketoconazole, the first orally active, systemic antifungal with a broad spectrum. Further research resulted in release of fluconazole in 1990 and itraconazole in 1992. All three of these drugs are labeled for human use only. Older azole antifungals, miconazole and clotrimazole, are suitable for intravenous and topical use only and are more toxic than more recently available drugs.

The use of the azole antifungals in veterinary medicine has been reviewed.<sup>30</sup> They inhibit synthesis of the primary fungal sterol, ergosterol, which is important in fungal cell membrane integrity. This is accomplished by inhibition of a P<sub>450</sub> enzyme system, and the relative potency of the azoles is determined by their affinity for this P<sub>450</sub> enzyme moiety. Vertebrates also have a P<sub>450</sub> enzyme system, and the selective toxicity of the azoles depends on their relative specificity for binding fungal P<sub>450</sub> enzymes. Potential toxic effects of interfering with vertebrate P<sub>450</sub> enzymes include decreased synthesis of cholesterol, cortisol and reproductive steroid hormones. Ketoconazole has the least affinity and specificity and is therefore considered less active and potentially more toxic than fluconazole and itraconazole; however, it is still a highly useful drug. All three azoles are fungistatic and several days of therapy are needed to achieve steady-state concentrations.

### Pharmacology

Ketoconazole is effective against many of the yeast and fungi of medical importance, but *Aspergillus* spp. are often resistant.<sup>45</sup> It is readily absorbed in an acid environment such as exists in the stomach following a meal. It is widely distributed to tissues but is highly protein-bound and does not significantly penetrate into the cerebrospinal or ocular fluids. It is eliminated via hepatic metabolism, and significant interactions occur with drugs that inhibit or induce hepatic enzyme metabolism (eg, rifampin and barbiturates). Ketoconazole is considered more toxic than either itraconazole or fluconazole. Reports of toxicity are rare in birds, but anorexia, vomiting, jaundice and elevated liver enzymes have been reported in other animals. Long-term use in dogs has resulted in decreased cortisol levels and decreased testosterone synthesis.

Ketoconazole is available in 200 mg tablets. Crushed tablets can be compounded with 0.15% methylcellu-



lose into an oral suspension that is stable for six months if refrigerated. Ketoconazole is water insoluble unless in an acid environment. Medicated water is therefore of questionable benefit except for infections caused by highly susceptible yeast that are limited to the GI tract.

### Use in Companion Avian Medicine

Ketoconazole is currently the most widely used, least expensive, orally available and systemically active antifungal. It is useful for treating resistant yeast infections and yeast infections where systemic drug delivery is required. It is not usually effective against aspergillosis alone, but may have a synergistic effect when combined with other antifungals.

Limited pharmacokinetic studies have been performed in pigeons and cockatoos.<sup>35</sup> Following oral administration at 30 mg/kg, peak concentrations were achieved in 0.5 to 4 hours and the elimination half-life was 2 to 3.8 hours in pigeons and 3.8 hours in Moluccan Cockatoos. No significant toxic reactions were seen in pigeons given 30 mg/kg orally BID for 30 days or Amazon parrots treated with 30 mg/kg BID for 14 days. Because absorption is increased in an acid environment, ketoconazole should be administered with food. It is not necessary to pre-dissolve the drug in acid.

Tracheal aspergillosis in an Amazon parrot was treated using ketoconazole (approximately 25 mg/kg orally BID for 14 days) and intratracheal amphotericin B (50-75 mg/kg SID for seven days).<sup>53</sup>

## Itraconazole

### Pharmacology

Itraconazole is a triazole that was recently licensed for use in humans in the United States.<sup>30</sup> It is similar to ketoconazole but has 5 to 100 times greater potency, better *in vitro* and *in vivo* activity against aspergillus infections and meningeal cryptococcoses, and fewer side effects. It is insoluble in water, highly lipophilic and is well absorbed if taken with a meal. It is highly protein-bound and widely distributed to tissues. Tissue concentrations (especially fat, liver, adrenal cortex and skin) are substantially greater than plasma concentrations, and therapeutic concentrations are maintained longer in tissue than in plasma. The volume of distribution greatly exceeds body water (11-17 l/kg). It is poorly distributed to CSF, ocular fluids and plasma. It is degraded by hepatic metabolism, and the primary route of elimination is via the bile. Elimination half-life in man is

longer than for ketoconazole (17 to 25 hours versus 8 hours), and steady-state concentrations are achieved in approximately six days. Itraconazole is considered safe for long-term treatment in humans at a dose of approximately 4-6 mg/kg/day, and dogs receiving up to 40 mg/kg/day for three months did not show signs of toxicity.<sup>60</sup> Maternal toxicity, embryo toxicity and teratogenicity were absent in mice treated with 10 mg/kg/day, but did occur when the dose was increased to 40 and 160 mg/kg; use in pregnant animals is not recommended.<sup>61</sup>

In man, itraconazole has shown promising results for treating aspergillosis; however, there are conflicting reports when efficacy is compared to other drugs (primarily amphotericin B and flucytosine). Even with prolonged treatment (eg, several months), relapses and treatment failures are common. If reports in the literature are any indication, itraconazole alone or in combination with amphotericin B appears to be the treatment of choice for aspergillosis in humans.

There is limited data on the use of itraconazole in animals. It was as effective as ketoconazole when used for three months in cats with cryptococcosis, but less toxic.<sup>44</sup> Variable success has been seen with itraconazole used to treat superficial dermatophyte infections and systemic blastomycosis.<sup>5</sup> It was unsuccessful as a sole treatment in resolving four cases of canine nasal aspergillosis; better success was achieved in another study when itraconazole was combined with topical enilconazole infusion.<sup>64</sup>

### Use in Companion Avian Medicine

Reports of itraconazole use in birds are limited, but it has been used to treat aspergillus and candida infections in macaws and penguins.<sup>31</sup> A severe *Candida krusei* tracheitis was resolved in a Blue and Gold Macaw that received itraconazole at 10 mg/kg/day for 35 days. Presumed ocular aspergillosis in a King Penguin was successfully resolved after treatment with 8 mg/kg/day for 29 days. Two penguins with candida infections of the uropygial gland were successfully treated with 10 mg/kg/day for 20 days. A Gentoo Penguin with a pulmonary aspergilloma showed marked improvement and reduction in the size of the aspergilloma after receiving itraconazole at 8.3 mg/kg for 30 days and 17 mg/kg for an additional 19 days. However, the bird died from cerebral aspergillosis three weeks after therapy ended. In man, pulmonary aspergillosis is treated for six to nine months, so the treatment failure in this case may have been due to the short duration of therapy.

## Fluconazole

### Pharmacology

Fluconazole is a synthetic bistriazole that became available in the United States in 1990.<sup>30</sup> *In vitro* potencies are up to 100 times greater than ketoconazole. Most yeast and fungi of medical importance are susceptible to fluconazole *in vitro*. *In vivo*, it has excellent activity against yeast and variable activity against aspergillus. In contrast to ketoconazole and itraconazole, fluconazole is highly water soluble and is readily absorbed from the GI tract regardless of acidity or food intake. It is not highly protein-bound and penetrates the CSF, brain tissue, ocular fluids and sputum; the volume of distribution is similar to body water (0.7 l/kg). It is eliminated primarily by the kidney, and the prolonged serum half-life of 4 to 5 hours in rats and mice, 14 hours in dogs, and 22-30 hours in humans is presumably due to tubular reabsorption. The dose should be modified if renal function is impaired. Fluconazole alters the kinetics of drugs that undergo hepatic metabolism, but not to the degree described with ketoconazole. The manufacturer recommends giving a double loading dose during the first 24 hours, because five to seven days are needed to achieve steady-state concentrations in man. Fluconazole is well tolerated in humans, although mild GI, CNS and skin reactions are occasionally reported. Hematologic abnormalities are rare. Doses of 30 mg/kg/day in dogs caused increased hepatic fat and hepatic weight.

Clinical studies in humans are still investigating the efficacy of fluconazole *in vivo*. It has been highly successful for treating tissue candida and coccidiomycosis infection and variably successful for treating pulmonary aspergillosis. It is probably the drug of choice in situations where penetration into the CSF is desirable.

Clinical studies in animals with fluconazole are even more limited. Six of ten dogs with nasal aspergillosis were successfully treated with 2.5-5 mg/kg/day orally for eight weeks.<sup>56</sup> Fluconazole was considered effective treatment in animal models for blastomyces, cryptococcus, candida, coccidioides and histoplasma infection. As with clinical trials in humans, fluconazole was variably effective against aspergillosis.<sup>30</sup>

### Use in Companion Avian Medicine

Juvenile psittacine birds treated with fluconazole were found to be fecal negative for yeast as determined by Gram's stain; clearance of yeast required 48 hours.<sup>2</sup> Based on this limited study, dosage recom-

mendations of 2-5 mg/kg/day were suggested. Transient regurgitation, increased AST and LDH levels were observed in some birds. Further studies are needed to establish the safety and efficacy of fluconazole in birds.

## Enilconazole

### Pharmacology

Enilconazole is an imidazole antifungal agent with a broad spectrum. It is not approved for use in the United States. It is poorly soluble and its use is limited to topical application and inhalation. Inhalation of burned enilconazole has been used to treat aspergillosis in poultry.<sup>50</sup> It has also been infused into the nasal passages and sinuses to treat canine nasal aspergillosis.<sup>57</sup> Reports of use in companion and aviary birds are lacking.

## Summary of Antifungal Treatment

Spectrum, ability to reach the site of infection, route of administration and potential toxicity are important considerations when selecting an antifungal agent. Spectrum is difficult to determine for antifungal drugs because the methods for *in vitro* testing are expensive, are poorly standardized and there is often little correlation between *in vitro* and *in vivo* efficacy. This makes drug selection somewhat empirical, but some generalities can be made. Most candida are susceptible to nystatin, and almost all yeast of medical importance are susceptible to ketoconazole, itraconazole, fluconazole and amphotericin B. In human and animal studies, itraconazole and fluconazole are more active than ketoconazole, with itraconazole showing greater activity against aspergillosis, and fluconazole showing greater activity against yeast infections. A combination of amphotericin B and flucytosine or an azole, or an azole and flucytosine may provide better efficacy than either drug alone.

The ability of the drug to reach the site of infection is also important. Nystatin is not absorbed from the alimentary tract and must come in contact with the yeast. Systemic infections by hyphal fungi (eg, aspergillus) usually cause a granulomatous response that inhibits drug penetration to the site of infection. Ketoconazole and itraconazole are highly protein-bound and develop high tissue concentrations, but are found in low concentrations in the CSF and ocular fluids. In contrast, fluconazole is water-soluble, minimally protein-bound, and able to treat the CNS, eye and sputum. In general, fungal infections require

TABLE 17.2 Susceptibility of Common Avian Infectious Agents to Antimicrobial Therapy

ANTIBACTERIAL	G <sup>-</sup> bacteria	Pseudomonas	G <sup>+</sup> bacteria	Mycoplasma	Chlamydia	Anaerobes
Amikacin	+++++	+++	+++	-	-	-
Ampicillin / Amoxicillin	+	-	+++	-	-	-
Chloramphenicol	+	-	+++	-	+	-
1st generation Cephalosporins	+	-	+++++	-	-	-
3rd generation Cephalosporins	+++++	+++	+	-	-	-
Enrofloxacin	++++	+	+++	+++++	+	-
Gentamicin	+++	+++	+++	-	-	-
Macrolides (Tylosin, Clindamycin)	+	-	++++	+	-	++++
New Macrolides	-	-	++++	+	possible	++++
Tetracycline	+	-	+	++++	+++++	-
Trimethoprim / Sulfa	++++	-	++++	-	-	-

ANTIFUNGAL	Yeast	Aspergillus	Other Fungi
Amphotericin	+++++	++++	+++++
Fluconazole	++++	+++	-
Flucytosine	+++++	+	+++++
Itraconazole	++++	+++++	+++++
Nystatin	++++	-	-

+++++ = most isolates susceptible; ++++ = many isolates susceptible; +++ = some isolates susceptible; ++ = few isolates susceptible; + = almost no isolates susceptible

longer treatment periods than bacterial infections. Sometimes many months of therapy are needed to control aspergillosis.

Finally, the route of administration and potential toxicity are important considerations. All of the antifungal drugs mentioned are delivered orally with the exception of amphotericin B, which must be administered IV. Nystatin is virtually nontoxic. Ketoconazole has greater potential toxicity than either itraconazole or fluconazole, especially if long-duration and high-dose therapy are used. Drug interactions should also be considered. Ketoconazole and fluconazole may significantly alter the hepatic metabolism of drugs such as barbiturates and rifampin.

Nystatin is the drug of choice for uncomplicated yeast infections of the alimentary tract. It is inexpensive and virtually nontoxic. Resistant or severe yeast infections can be treated with ketoconazole or fluconazole. Ketoconazole is less expensive but potentially more toxic; few side effects have been observed when used for fewer than two to three weeks. Systemic yeast infections can be treated with either ketoconazole,

fluconazole or itraconazole, depending on the site of infection.

Drug selection for treatment of aspergillosis infections is more problematic. Cutaneous aspergillosis is probably best treated with fluconazole or itraconazole (ketoconazole might be effective in limited cases). Topical administration of enilconazole or miconazole may also be effective. Severe pulmonary or disseminated aspergillosis carries a poor prognosis for recovery regardless of the treatment program. Amphotericin B is the primary drug of choice for chronic infections and infections in immunocompromised patients because it rapidly develops fungicidal concentrations. Prior to the availability of the new azole antifungals, a combination therapy with amphotericin B, flucytosine and rifampin was recommended. Based on human clinical studies, it is probably more effective to use amphotericin B in combination with itraconazole for initial treatment, and then continue long-term treatment for months with itraconazole alone. Flucytosine also has substantial anti-aspergillus activity and may be preferable if there is CNS involvement. Intratracheal ad-

ministration of amphotericin B is very useful when treating syringeal or tracheal infections. Systemic infections caused by other fungi (eg, mucormycosis and cryptococcosis) can be treated in the same manner as systemic aspergillosis.

Antifungal drug research is currently an active field, spurred by the increasing numbers of opportunistic fungal infections in immunocompromised human HIV patients. New drugs may soon be available.

## References and Suggested Reading

1. **Arnstein P, et al:** Control of psittacosis by group chemotherapy of infected parrots. *Am J Vet Res* 11:2213-2227, 1968.
2. **Bennett JE:** Antifungal agents. In Gilman AG, et al (eds): *The Pharmacological Basis of Therapeutics*. New York, Pergamon Press, 1990, 1165-1181.
3. **Bird JE, et al:** Pharmacokinetics of gentamicin in birds of prey. *Am J Vet Res* 44:1245-1247, 1983.
4. **Brooks DE, et al:** The treatment of canine ocular blastomycosis with systemically administered itraconazole. *Prog Vet Comp Ophthalmol* 4:263-268, 1992.
5. **Burrows GE:** Pharmacology of macrolides, lincosamides, and spectinomycin. *J Am Vet Med Assoc* 176:1072-1077, 1980.
6. **Bushby SRM:** Sulfonamide and trimethoprim combinations. *J Am Vet Med Assoc* 176:1049-1060, 1980.
7. **Campbell TW:** Mycotic diseases. In Harrison GJ, Harrison LR (eds): *Clinical Avian Medicine and Surgery*. Philadelphia, WB Saunders Co, 1986, pp 464-471.
8. **Clark CH:** Pharmacology of antibiotics. In Harrison GJ, Harrison LR (eds): *Clinical Avian Medicine and Surgery*. Philadelphia, WB Saunders Co, 1986, pp 319-326.
9. **Clark CH, et al:** Plasma concentrations of chloramphenicol in birds. *Am J Vet Res* 43:1249-1253, 1982.
10. **Clubb SL:** Therapeutics in avian medicine-flock vs. individual bird treatment regimens. *Vet Clin No Amer Sm Anim Pract* 14:345-361, 1984.
11. **Cooper R:** Psittacosis - An ever-present problem in caged birds. In Kirk RW (ed): *Current Veterinary Therapy VII*. Philadelphia, WB Saunders Co, Philadelphia, 1980, 677-686.
12. **Dorrestein GM, et al:** A preliminary report on pharmacokinetics and pharmacotherapy in racing pigeons (*Columba livia*). *Proc Intl Conf Avian Med, Assoc Avian Vet*, 1984, pp 9-14.
13. **Dorrestein GM:** Update in avian chemotherapy. *Proc Assoc Avian Vet*, 1988, pp 199-122.
14. **Dorrestein GM:** The pharmacokinetics of avian therapeutics. *Vet Clin North Am Sm An Pract* 21(6):1241-1264, 1991.
15. **Dyer DC, van Alstine WG:** Antibiotics aerosolization: tissue and plasma oxytetracycline concentrations in parakeets. *Avian Dis* 31:677-679, 1987.
16. **Enslay PK, Janssen DL:** A preliminary study comparing the pharmacokinetics of ampicillin given orally and intramuscularly to psittacines. *J Zoo Anim Med* 12:42-47, 1981.
17. **Fernandez-Repollet E, et al:** Renal damage in gentamicin-treated lanner falcons. *J Am Vet Med Assoc* 181:1392-1394, 1982.
18. **Flammer K:** Avian chlamydiosis - Observations on diagnostic techniques and use of oral doxycycline for treatment. *Proc 1st Intl Conf Zool & Avian Med*, 1987, pp 149-158.
19. **Flammer K:** Use of amikacin in birds. *Proc 1st Intl Conf Zoo & Avian Med*, 1987, pp 195-198.
20. **Flammer K:** Treatment of chlamydiosis in psittacine birds in the United States. *J Am Vet Med Assoc* 195:1537-1540, 1989.
21. **Flammer K, et al:** Potential use of long-acting oxytetracycline for the treatment of chlamydiosis in Goffin's cockatoos. *Avian Dis* 34:228-234, 1990.
22. **Flammer K:** An update on psittacine antimicrobial pharmacokinetics. *Proc Assoc Avian Vet*, 1990, pp 218-220.
23. **Flammer K, et al:** Adverse effects of gentamicin in scarlet macaws and rose-breasted cockatoos. *Am J Vet Res* 50:404-407, 1990.
24. **Flammer K, et al:** Plasma concentrations of enrofloxacin in African grey parrots treated with medicated water. *Avian Dis* 34:1017-1022, 1990.
25. **Flammer K, Aucoin DP, Whitt DA:** Intramuscular and oral disposition of enrofloxacin in African grey parrots following single and multiple doses. *Vet Pharm Therap* 14:359-366, 1991.
26. **Flammer K, et al:** New advances in avian therapeutics. *Proc Assoc Avian Vet*, 1992, pp 14-18.
27. **Gronwall R, Brown MP, Clubb SA:** Pharmacokinetics of amikacin in African grey parrots. *Am J Vet Res* 50:250-252, 1989.
28. **Gyalsdorff I:** The treatment of chlamydiosis in psittacine birds. *Isr J Vet Med* 43:11-19, 1987.
29. **Heit MC, Riviere:** Antifungal therapy: Ketoconazole and other azole derivatives. *Comp Cont Ed Pract Vet*.
30. **Hines RS, Sharkey P, Friday RB:** Itraconazole treatment of pulmonary, ocular and uropygeal aspergillosis and candidiasis in birds - Data from five clinical cases and controls. *Proc Am Assoc Zoo Vet*, 1990, pp 322-327.
31. **Hochleitner M, Grogopoulos A:** Experiences with piperacillin in psittaciformes. *Proc VI. Tagung uber Vogelkrankheiten - Schwerpunkt Tauber und Wassergefluegen*, DVG, Munich, 1988.
32. **Karpinsky LG:** Ophthalmology. In Harrison GJ, Harrison LR (eds): *Clinical Avian Medicine and Surgery*. Philadelphia, WB Saunders Co, 1986, pp 278-281.
33. **Kauffman CA:** Flucytosine. In Peterson PK, Verhoef J (eds): *Antimicrobial Agents Annual 3*. Elsevier Science Pub, BV, 1988, pp 246-265.
34. **Kollias GV, et al:** The use of ketoconazole in birds: Preliminary pharmacokinetics and clinical applications. *Proc Assoc Avian Vets*, 1986, pp 103-104.
35. **Krautwald ME, et al:** Further experiences with the use of Baytril<sup>®</sup> in pet birds. *Proc Assoc Avian Vet*, 1990, pp 226-236.
36. **Lashev L, Semeralzhev U:** Comparative studies of amoxicillin absorption and distribution in poultry. *Vet Med Nauki*, 22:5-6, 1983.
37. **Locke D, Bush M, Carpenter JW:** Pharmacokinetics and tissue concentrations of tylosin in selected avian species. *Am J Vet Res* 43:1807-1810, 1982.
38. **Locke D, Bush M:** Tylosin aerosol therapy in quail and pigeons. *J Zoo Anim Med* 15:67-72, 1984.
39. **Mandell GL, Sande MA:** Penicillins, cephalosporins, and other beta lactam antibiotics. In Gilman AG, et al (eds): *The Pharmacological Basis of Therapeutics*. New York, Pergamon Press, 1990, pp 1065-1097.
40. **Mandell GL and Sande MA:** Penicillin, cephalosporins, and other beta lactam antibiotics. In Gilman AG, et al (eds): *The Pharmacological Basis of Therapeutics*. New York, Pergamon Press, 1990, pp 1065-1097.
41. **Mandell GL, Sande MA:** Tetracyclines, chloramphenicol, erythromycin, and miscellaneous antibacterial agents. In Gilman AG, et al (eds): *The Pharmacological Basis of Therapeutics*. New York, Pergamon Press, 1990, pp 1117-1145.
42. **Medleau L, Greene CE, Rakich PM:** Evaluation of ketoconazole and itraconazole for treatment of disseminated cryptococcosis in cats. *Am J Vet Res* 51:1454-1458, 1990.
43. **Moriello KA:** Ketoconazole: Clinical pharmacology and therapeutic recommendations. *J Am Vet Med Assoc* 188:303-306, 1988.
44. **Parrott T:** Clinical treatment regimens with fluconazole. *Proc Assoc Avian Vets*, 1991, pp 15-16.
45. **Quesenberry KE:** Avian antimicrobial therapeutics. In Jacobson E, Kollias GV (eds): *Exotic Animals*, 1988, pp 177-207.
46. **Redig PT, et al:** A review of current methods for the diagnosis and treatment of avian aspergillosis. *Proc Assoc Avian Vets*, 1986, 90-92.
47. **Redig PT, Duke CE:** Comparative pharmacokinetics of antifungal drugs in domestic turkeys, red-tailed hawks, broad-winged hawks, and great horned owls. *Avian Dis* 29:649-661, 1988.
48. **Redmann T, Schilder B:** Enileonazole treatment of broiler-chicks with aspergillosis. *Deutsche-Tierarztliche-Wochenschrift* 96:15-17, 1989.
49. **Ritchie BW:** Avian therapeutics. *Proc Assoc Avian Vets*, 1990, 415-431, 1990.
50. **Romvay A, Horvay MS:** On the pharmacokinetics of sulphonamide trimethoprim combination orally in geese. *Acta Vet Acad Sci Hung* 26:173-179, 1976.
51. **Roskopf WJ, et al:** Successful treatment of aspergillosis in two psittacine birds. *Proc Assoc Avian Vets*, pp 119-127, 1986.
52. **Schafer J, et al:** Measurement of itraconazole levels in parakeets. *Avian Dis* 28:295-302, 1984.
53. **Sedgewick CJ, Pokras M, Kaufman G:** Metabolic scaling: Using estimated energy costs to extrapolate drug doses between different species and different individuals of diverse body sizes. *Proc Am Assoc Zoo Vets*, 1990, pp 249-254.
54. **Sharp NJH:** Treatment of canine nasal aspergillosis/penicilliosis with fluconazole (UK 49,858). *J Small Anim Pract* 32:513-516, 1991.
55. **Sharp NJH, Harvey CE, Sullivan M:** Canine nasal aspergillosis and penicilliosis. *Comp Cont Ed Pract Vet* 13:41-49, 1991.
56. **Sisodia CS:** Pharmacotherapeutics of chloramphenicol in veterinary medicine. *J Am Vet Med Assoc* 176:1069-1171, 1980.
57. **Teare JA, et al:** Pharmacokinetics of a long-acting oxytetracycline preparation in ring-necked pheasants, great horned owls, and Amazon parrots. *Am J Vet Res* 46:2639-2643, 1985.
58. **Van Cauteren H, et al:** Itraconazole: Pharmacologic studies in animals and humans. *Rev Infect Dis* 9(S1):43-46.
59. **Van Cauteren H, et al:** The toxicological properties of itraconazole. In Fromtling RA (ed): *Recent Trends in the Discovery, Development, and Evaluation of Antifungal Agents*. Barcelona, JR Prous Publishers, 1987, pp 263-271.
60. **Van DerHeyden N:** Avian tuberculosis: Diagnosis and attempted treatment. *Proc Assoc Avian Vets*, 1986, pp 203-214.
61. **Vanhaeck E, et al:** Pharmacokinetics and bioavailability of erythromycin in pigeons. *J Vet Pharm Ther* 13:356-360, 1990.
62. **Van Oosterhout ICAM, Venker-van Haagen AJ:** Aspergillosis: Report on diagnosis and treatment. *Tijdschrift Voor Diergeneeskunde* 116(S1):37-38.
63. **White G, Williams RB:** Evaluation of a mixture of trimethoprim and sulphaminoxaline for the treatment of bacterial and coccidial diseases of poultry. *Vet Rec* 24:608-610, 1983.

## Products Mentioned in the Text

- a. Keet Life, Hartz Mountain, Harrison, NJ
- b. Ornacin, Mardel Laboratories, Glendale Heights, IL
- c. LA-200, Pfizer Laboratories, New York, NY
- d. Myco 20, Squibb Laboratories, Princeton, NJ
- e. Bactrim, Roche, Nutley, NJ

**T**his chapter provides an overview of the unique characteristics of various drugs used in avian species. All suggested drug uses are for companion (non-food) birds only. Complete reviews of all the drugs discussed in this book are available through a variety of desk references and product information forms provided by the manufacturers. The clinician is referred to these references for a review of the general pharmacology and specific contraindications of any drug discussed. The suggestions of the manufacturer should always be followed. A drug should never be used for which the clinician is not fully aware of the indications, contraindications and potential side effects. Some drugs administered concurrently will potentiate toxicity, and the clinician should review any potential drug interactions before placing a bird on more than one drug at a time.

In this chapter, commonly used drugs and their associated doses are provided in table form for easy reference. The information concerning the use of the drugs listed in the table should be reviewed before administering any therapeutic agent. If a drug is not discussed, either insufficient data is available to warrant its use in birds, or it has been used but has little applicability.

The doses and material presented for each drug have been compiled from numerous reference sources, including the various chapters in this book. Some of the recommended doses are based on pharmacokinetic information, and some are based totally on observation. An asterisk in the formulary table indicates that the suggested dose is based on pharmacologic data obtained in some species of birds other than poultry. Notes on any adverse drug reactions should be forwarded to the *Journal of the Association of Avian Veterinarians* to keep colleagues informed of any problems that occur with commonly used therapeutic agents. Representative manufacturers listed in the formulary are for reference purposes only. Other manufacturers may produce similar products of equal efficacy.

---

CHAPTER

18

FORMULARY

---

Branson W. Ritchie  
Greg J. Harrison

**ACETYLCYSTEINE - Mucomyst (Apothecan)**

Neonates treated with nebulized Mucomyst developed dyspnea, lethargy, edema of the eyelids and tachycardia 20 minutes after therapy.

**ACETYLSALICYLIC ACID - Aspirin (Butler; Vedco)**

Available as tablets (5 or 60 grain) for oral administration. Also available as 1.25 grain orange-flavored chewable tablets. May be effective as an analgesic, antipyretic and anti-inflammatory agent in some avian species. May be indicated to prevent clot formation and embolisms secondary to egg-related peritonitis, granulomatous diseases and shock. Uricosuric at low doses and may be effective in some cases of acute and chronic gout. A five grain tablet can be mixed in 30 ml of diluent and administered at a dose of 0.5 ml/kg, TID (or 1 tablet per pint of drinking water).

**(ACTH) ADRENAL CORTICOTROPIC HORMONE - (Vedco; Phoenix; Butler)**

Available as an injectable solution (40 or 80 units/ml) for IM administration. Used to test stimulation of the adrenal glands in suspected cases of adrenal insufficiency. Glucocorticoid administration may falsely elevate endogenous cortisol levels. Prolonged administration induces adrenal gland hyperplasia.

**ACTIVATED CHARCOAL, KAOLIN - Toxiban (Vet-A-Mix)**

Available as a suspension (104 mg/ml activated charcoal and 62.5 mg/ml kaolin) for oral administration. Can be used to absorb some ingested toxins (many insecticides, pesticides, lead, mercury, inorganic arsenic and chemotherapeutic agents) from the gastrointestinal tract. High therapeutic index. Can be mixed with sodium sulfate in cases of heavy metal ingestion to form lead complexes that are not absorbed. Sodium sulfate can cause osmotic diarrhea and should be used with extreme caution in birds that weigh less than one kg. Can be mixed with hemicellulose to function as a bulk laxative and aid in the passage of ingested toxins.

**ACYCLOVIR - Zovirax (Burroughs Wellcome)**

Available as a soluble powder (50 mg/ml when reconstituted) for IV administration and as a capsule (200 mg), tablet (200 mg) or suspension (40 mg/ml) for oral administration. Has been shown to be effective in decreasing mortality associated with flock outbreaks of Pacheco's disease virus. Appears to be most effective if treatment is initiated in an individual bird before clinical signs occur.

Acyclovir is preferentially absorbed by herpesvirus-infected cells and primarily inhibits herpesvirus DNA polymerase. Acyclovir is effective in preventing herpesvirus replication in only those strains of herpesvirus that code for their own DNA polymerase. Acyclovir also has varying effects on different strains of susceptible herpesviruses. Low level of effect on uninfected host cells results in a high therapeutic index. It has been suggested for treatment of poxvirus, but there is no conclusive evidence to support its efficacy.

The injectable product may cause severe muscle necrosis if administered IM and may cause phlebitis (common) and neurologic signs (rare) when administered IV. Oral administration may cause vomiting. Acyclovir has been shown to interfere with spermatogenesis and is mutagenic when administered at high doses in some mammals.

**ALCOHOL**

An excellent solvent for many drugs as well as a popular skin disinfectant. Bactericidal for most common pathogenic bacteria with variable activity for viruses and fungi. Will cause a dramatic decrease in core body temperature when applied to large areas of the skin as a presurgical dressing. Consumption of alcoholic beverages or absorption of ethanol through open wounds can result in lethargy, incoordination and regurgitation in most avian species.

**ALLOPURINOL - Zylorim (Burroughs Wellcome)**

Available as a tablet (100 or 300 mg) for oral administration. Used for the treatment of gout. Well absorbed from the gastrointestinal tract. Functions to inhibit purine catabolism, which prevents the production of uric acid. A 100 mg tablet can be crushed and dissolved in 10 ml of sterile water. Up to 1 ml of the diluted suspension may be added to 30 ml of drinking water. A fresh solution of drinking water should be provided several times per day. A reduction in serum and urinary uric acid levels should be noted within two to three days of administration.

Birds being treated with allopurinol should be thoroughly hydrated at all times. It has been found to *cause* gout in Red-tailed Hawks, and may cause a skin rash, urticarial lesions or hepatitis. In birds with severe gout, the initial dose should be 25% of the recommended dose, with a gradual increase over several days. Should be used in conjunction with colchicine in severe cases of gout.

**ALOE VERA - George's Aloe Vera (Warren Laboratories)**

Available as a lotion or for topical application on pruritic lesions or as a liquid for oral administration. Solution for treating pruritic skin lesions is made by mixing 0.5 oz of aloe vera oral liquid with 1 tsp of Penetran, 2 drops of Woolite and 1 pint of water.

**AMIKACIN SULFATE - Amiglyde (Aveco); Amikin (Bristol Labs)**

Available as injectable solutions (50 mg/ml and 250 mg/ml) for IM or SC administration. Limited activity against gram-positive organisms. Should be used only in birds when absolutely necessary to treat gram-negative bacteria (*Pseudomonas*, *Klebsiella* spp.) that are resistant to other, less toxic antibiotics. Very effective when used in combination with synthetic penicillins.

Birds should be thoroughly hydrated throughout the treatment period to decrease the possibility of nephrotoxicity. Use in conjunction with furosemide may potentiate renal damage. Toxic effects of aminoglycosides may be potentiated when used in combination with cephalosporins (see Chapter 17).

**AMINOPENTAMIDE HYDROGEN SULFATE - Centrine (Aveco)**

Available as an injectable solution 0.5 mg/ml for SC or IM administration for controlling vomiting.

**AMINOLOID - (Essex; Schering Corporation)**

Has been used to induce molt in raptors. Should induce complete molt within 2 months of administration.

**AMITRIPTYLINE HCL - Elavil (Stuart); Endep (Roche)**

Available as a tablet (10, 25, 50, 75, 100, 150 mg) for oral administration or as an injectable solution (10 mg/ml) for IM administration. Tricyclic antidepressant with a sedative effect that has been suggested for use in some cases of feather picking. Appears to be rarely effective. Should not be used in conjunction with monoamine oxidase inhibitors. May cause depression, arrhythmias, tachycardia, vomiting or muscle rigidity.

**AMMONIUM SOLUTION - Penetran (Trans Dermal Technologies)**

Available as an ointment for topical application. Used as a topical analgesic or antipruritic (see Aloe Vera).

**AMOXICILLIN - Amoxi-drops, Amoxi-Inject (SmithKline)**

Available as a suspension (50 mg/ml, Amoxi-drops) for oral administration or as an injectable solution (250 mg/ml, Amoxi-Inject) for IM administration. Palatable and easy to administer but rarely effective against the bacterial organisms that affect birds. Absorbed from the gut more effectively than ampicillin, resulting in higher blood levels than are achieved with oral ampicillin. Injectable solution stable one year after reconstitution if refrigerated. Oral suspension stable for 14 days if refrigerated (see Chapter 17).

**AMPHOTERICIN B - Fungizone (Squibb)**

Available as an injectable solution (5 mg/ml) for slow (over several hours) IV administration. Functions by binding to sterols in the membrane of fungi, causing alterations in permeability. Rapid administration may cause arrhythmias and death. Can also be given intratracheally. Has been suggested to be effective if administered SC, but efficacy is unknown. Can be nebulized in conjunction with systemic flucytosine or ketoconazole therapy for fungal infections in the upper respiratory tract. Intratracheal or intra-air sac administration does not result in systemic absorption and is effective only against aspergillosis localized to the site of infection. May be effective in treating megabacteria. A lotion or cream (3%) is available that can be used for fungal dermatitis and for oral candidiasis that is resistant to nystatin.

May cause renal damage and bone marrow suppression. May potentiate toxic effects of flucytosine when used in combination. Depression, vomiting and irritation at the injection site are common side effects. Amphotericin B injected into the sinuses of an African Grey Parrot caused a severe granulomatous sinusitis and death. If used in combination with imidazoles may result in fungi that are resistant to amphotericin B. Stable one week after reconstitution if refrigerated. Stable only 24 hours at room temperature. Can be mixed, divided into small aliquots and frozen (see Chapter 17).

**AMPICILLIN - Polyflex (Fort Dodge)**

Available as an injectable suspension (100 mg/ml) for subcutaneous or IM administration. This drug has minimum activity for the common gram-negative bacteria that infect birds. IM administration for treatment of "cat bite" injuries in which pasteurella septicemia is common. Ampicillin administered orally is poorly absorbed and the drug that is absorbed is rapidly excreted by the kidneys. Oral administration is limited to highly sensitive pathogens restricted to the gastrointestinal tract. May be effective in treating salmonella arthritis in gallinaceous birds. May be effective against some L-form bacteria when used in conjunction with erythromycin (see Chapter 17).

**AMPROLIUM - Corid (MSD-Agvet)**

Available as a solution (9.6% - 96 mg/ml) for oral administration. Structurally related to thiamine and competitively inhibits thiamine utilization by some parasites. May be effective against some strains of coccidia. The strains that infect mynahs and toucans appear to be particularly resistant. Resistances may develop following repeated use in an aviary. Not as effective in Galliformes and cranes as monensin. Must be used in conjunction with thorough aviary cleaning to prevent reinfection following treatment.

**ASCORBIC ACID - Vitamin C (Phoenix; Vedco)**

Available as an injectable solution (250 mg/ml) for IM administration. May be beneficial support for avian patients with infectious or debilitating metabolic diseases.

**ATROPINE - (Butler; Vedco; Phoenix)**

Available as an injectable solution (0.5 mg/ml or 15 mg/ml) for IM or SC administration. More concentrated solution used as a treatment for organophosphate poisoning. Used with caution in birds as a preanesthetic. May thicken secretions in the trachea resulting in blockage of the endotracheal tube. Does not cause pupil dilation as occurs in mammals. Inappropriate or excessive use can result in cardiac arrhythmias and gastrointestinal stasis.

**AVIPRO - (Vetark Animal Health)**

Mixture of bacteria, enzymes, electrolytes and vitamins that may be an effective adjunct therapy in debilitated birds.

**AZITHROMYCIN - Zythromax (Pfizer)**

Available as capsules (250 or 500 mg) for oral administration. Used for the treatment of chlamydiosis. Should be administered on an empty stomach. A 250 mg capsule is mixed with 0.25 oz of lactulose and dosed at one drop per gram of body weight BID for 14 days.

**BISMUTH SUBSALICYLATE - Pepto-Bismol (Procter and Gamble)**

Available as a suspension (1.75% subsalicylate) for oral administration. Indicated for gastrointestinal irritation, ulcers or to aid in the removal of some ingested toxins.

**BOTULISM ANTI-TOXIN - (Schering Plough Animal Health; United Vaccine Inc.)**

*Clostridium botulinum* Type C for use in mink. Dose at one-half the mink dose.

**BUTORPHANOL TARTRATE - Stadol (Bristol Labs)**

Available as an injectable solution — Torbutrol (10 mg/ml) IV; or as tablets — Torbugesic (1, 5 or 10 mg) PO. Synthetic opiate that is used for its antitussive effects and to control abdominal pain. May be helpful in suppressing a non-productive cough and for post-surgical pain. May cause vomiting at 10 mg/kg in some species. Should be used with caution in patients with liver disease.

**CALCIUM - (Vedco; Phoenix; Butler)**

Available as a solution (23 mg/ml - Vedco, Phoenix) for oral administration; as an injectable solution (5 mg Ca glycerophosphate and 5 mg Ca lactate/ml - Butler) for IM, SC or IV administration and as a powder for oral administration. Oral administration is recommended for long-term therapy of calcium deficiencies and for supplementation during bone healing, bone development and egg laying. Parenteral administration is recommended for the treatment of hypocalcemia, hypocalcemic tetany, egg binding and soft-shelled eggs. Oral calcium will chelate some tetracycline preparations. Tucans being treated with tetracyclines should receive parenteral calcium supplementation to prevent bone deformities. Supplemental calcium may help prevent hypocalcemia in some African Grey Parrots.

**CALCIUM DISODIUM VERSEDATE - Calcium EDTA (3M Pharm.)**

Available as an injectable solution (200 mg/ml) for IM administration. Used to chelate circulating lead or zinc. Can be used orally to prevent lead or zinc from being absorbed from the gastrointestinal tract. Long-term treatment (over two weeks) can result in unacceptable chelation of normal cations from the blood. May cause renal tubular necrosis and its use should be discontinued if polyuria and polydipsia occur. May cause muscle necrosis when administered IM.

**CAPRILLIC ACID - Kaprycidin A (Ecological Formulas)**

Available as a capsule containing 325 mg of calcium, magnesium and zinc carprylates for oral administration. May be effective as an adjunct therapy with imidazole antifungals for the treatment of aspergillosis.

**CARBARYL - Sevin (Southern Agricultural Insecticides)**

Available as a 5% powder. Used to lightly dust birds for treatment of some ectoparasites. May be added to the nest litter to control mites and ants (one tsp is effective for a small nest box; two tsp may be needed for a larger box). Should be used in conjunction with thoroughly cleaning the box. Should be used only when necessary. May be helpful in reducing ant infestations in the aviary.

**CARNIDAZOLE - Spartrix (Wildlife Laboratories)**

Available as a tablet (10 mg) for oral administration. Single dose treatment for trichomoniasis, hexamitiasis and histomonas in pigeons. High therapeutic index in pigeons. Birds did not develop

any signs of toxicity even when treated with 640 mg/kg (32 times the therapeutic dose).

**CEFOTAXIME - Claforan (Hoescht-Roussel)**

Available as an injectable solution (10 to 300 mg/ml depending on reconstitution) for IM or IV administration. The less concentrated solution should be used for slow IV administration. Broad-spectrum activity for many gram-negative and gram-positive avian pathogens. Penetrates CSF. Reconstituted solution is stable for ten days refrigerated or six months frozen. Cannot be thawed and refrozen (see Chapter 17).

**CEFOXITIN - Mefoxitin (Merck)**

Available as an injectable solution (10 to 400 mg/ml depending on reconstitution) for IM or IV administration. The less concentrated solution should be used for slow IV administration. Reconstituted solution is stable for ten days refrigerated or six months frozen. Cannot be thawed and refrozen (see Chapter 17).

**CEFTRIAXONE - Rocephin (Roche)**

Available as an injectable solution (10 to 250 mg/ml depending on reconstitution) for IM or IV administration. The less concentrated solution should be used for slow IV administration. Reconstituted solution is stable for ten days refrigerated or six months frozen. Cannot be thawed and refrozen (see Chapter 17).

**CEPHALEXIN - Keflex Pediatric Suspension (Dista)**

Available as an oral suspension (25-100 mg/ml). Varied efficacy for many gram-negative bacteria. Frequent dosing makes treatment in all but hand-feeding neonates impractical. Reconstituted suspension stable for 14 days if refrigerated. May be effective in cases of staphylococcus dermatitis where long-term therapy is necessary (see Chapter 17).

**CEPHALOTHIN - Keflin (Lilly)**

Available as an injectable solution (100 mg/ml) for IV or IM (painful) administration. This drug is not absorbed from the gastrointestinal tract (see Chapter 17).

**CEPHRADINE - Veloself (Squibb)**

Available as a suspension (25 or 50 mg/ml) for oral administration. Similar in activity and spectrum to cephalixin.

**CHLORAMPHENICOL - (Parke-Davis; Fort Dodge)**

Available as injectable solution (100 mg/ml, succinate) for IV administration or as a suspension (30 mg/ml - chloramphenicol palmitate) for oral administration. May cause bone marrow suppression in humans, and clients should be warned to avoid skin contact. A dose of 1000 mg/kg may cause death in most avian species. Should be used with extreme caution in patients with renal or liver disease. Rapidly excreted by pigeons, necessitating a dosing frequency that makes therapy impractical.

Chloramphenicol succinate administered IV is excreted rapidly by the liver. May be useful in suppressing bacterial replication in cases of severe bacterial septicemia.

Chloramphenicol palmitate is erratically absorbed from the gastrointestinal tract. This drug should not be used in critical cases of bacterial septicemia. Usually well accepted by hand-feeding birds. May be useful in some cases of enteritis in young birds. If gastrointestinal stasis has occurred, a parenteral antibiotic should be chosen. Suspension or powder from capsules can be used to lace favorite foods or to mix into a mash for flock treatment of some highly susceptible bacteria. Particularly effective in the flock treatment of salmonella. Has been associated with temporary infertility in male pigeons.

Must be used with caution. Chloramphenicol has been associated with contact dermatitis and pernicious anemia in some people (see Chapter 17).

**CHLORHEXIDINE - Nolvasan (Fort Dodge; Bio-Ceutic)**

Available as a disinfectant solution (2% = 20 mg/ml). Off label use for oral or topical administration. Also available as an ointment or cream for topical administration. Commonly used to clean skin wounds and as a surgical scrub. May be used to prevent further cases of candidiasis in a flock while hygiene problems that caused the outbreak are corrected. Is not absorbed from the gut. May be effective in reducing the spread of some enteric viruses. The scented form added to water may prevent birds from drinking and result in death from dehydration, especially finches. Some preparations contain alcohol that may cause local skin irritation.

As a disinfectant, mix six tablespoons (3 oz or 90 ml)/gallon of water. Not effective for pseudomonas or gram-positive cocci. Extremely toxic to aquatic environments (lakes, ponds, streams). Waste products must be carefully handled. May irritate eyes or mucous membranes.

**CHLORINE - Household bleach**

Available as a 10% solution (100 mg/ml) that can be used to disinfect water (8 drops/gallon). May also be used as a disinfectant when mixed 1:10 with water. The longer the chlorine is in contact with an organism the more efficient it is as a disinfectant. Clorox, like most disinfectants, is not effective if organic debris is present.

Exposure to fumes may cause epiphora, coughing, sneezing, rhinorrhea and dyspnea in most avian species, particularly neonates. Should not come in contact with some metals. May react with some basic cleaners. Must always be used with adequate ventilation. Difficult to rinse out of porous materials (eg, wooden perches).

**CHLOROQUINE PHOSPHATE - Aralen Phosphate (Sandoz)**

Available as tablet (500 mg) for oral administration. Rapidly and completely absorbed from the intestinal tract. Used to treat the circulating forms of plasmodium (avian malaria). Must be used in conjunction with primaquine phosphate.

Overdose may be fatal. May cause retinal damage, vomiting, diarrhea or CNS problems.

**CHLORTETRACYCLINE (CTC) - Aureomycin (Cyanamid)**

Available as a feed additive (100 g/lb), tablet (25 mg) or powder (200 mg/teaspoon) for oral administration. Also available in pelleted feeds (Zeigler Brothers, Lafaber Co., Bird Life), in impregnated millet (Keet Life - Hartz) and for oral administration. Soybean meal base and CTC soluble powder may be added to cooked mashes containing rice, beans, chick starter ration and ground monkey biscuit for the flock control of chlamydiosis. Mixture must be made fresh each day. Addition of CTC to water for the flock treatment of chlamydiosis should not be considered effective. Pelleted foods may be useful in controlling chlamydiosis outbreaks in flocks of large psittacine birds. Tetracyclines are known to have immunosuppressive effects in other animals and the indiscriminate or periodic use of CTC in a flock of birds is not recommended. CTC chelates divalent and trivalent cations and interferes with normal bone development in mammals. No evidence to support the theory that annual treatment with CTC-impregnated pellets increases productivity as has been reported in the lay literature. Impregnated millet seeds may be helpful in treating chlamydiosis in flocks of budgerigars and cockatiels. The use of chlortetracycline for the treatment of chlamydiosis should be considered inferior to the use of doxycycline and enrofloxacin (see Chapter 17 and 34).



**CHLORSULON - Curatrem (MSD Agvet)**

Available as a suspension (8.5%, 85 mg/ml) for oral administration. Has been suggested as a treatment for tapeworms and liver flukes. Leads to death of the parasite by inhibiting glycolytic enzymes and incapacitating the parasite's primary source of energy.

**CIMETIDINE - Tagamet (SmithKline Beecham)**

Available as tablets (200, 300, 400, 800 mg) or liquid (60 mg/ml) for oral administration. Also available as an injectable solution (150 mg/ml) for IM or IV administration. Inhibits gastric acid secretion by inhibiting the effects of histamine at the H<sub>2</sub> receptor of the parietal cells. Indicated in cases of gastric ulceration and to decrease gastric acidity if the cloacal pH is low, a common problem with tenesmus and cloacal papillomas. May cause depression, diarrhea, tachycardia and respiratory failure.

**CIPROFLOXACIN - Cipro (Miles)**

See enrofloxacin. Available as a tablet (250, 500 or 750 mg) for oral administration, as an injectable solution (200 or 400 mg/ml) for slow IV administration or as an ophthalmic solution (3 mg/ml). Well absorbed from the gastrointestinal tract. Tablet can be crushed and added to liquid but must be shaken well before administration. May cause irritability in some birds. May cause CNS problems. Has been associated with crystalluria and joint abnormalities in some mammals (see Chapter 17).

**CLAZURIL - Appertex (Janssen)**

Available as a tablet (2.5 mg) for oral administration. Used for coccidiosis in pigeons. Not as effective in Galliformes and cranes as monensin.

**CLINDAMYCIN - Antirobe (Upjohn)**

Available as a suspension (25 mg/ml) or capsule (25, 75, or 150 mg) for oral administration. Primarily indicated in cases of osteomyelitis where long-term therapy is often required. Renal and hepatic function should be monitored during long-term use. Patients should be monitored for secondary yeast infections.

**CLOMIPRAMINE HCL - Anafranil (Baker Cummins)**

Available as a capsule (25, 50, or 75 mg) for oral administration. Tricyclic antidepressant. Used in humans to control compulsive behavior disorders. May be effective in some cases of feather picking and self-mutilation. Initial dose should be low with a gradual increase over a four- to five-day period. Clinical impressions suggest that this drug is rarely effective in controlling mutilation behavior in birds.

Numerous metabolic side effects. Regurgitation and drowsiness may occur in some birds. One cockatoo developed ataxia following administration.

**COLCHICINE - (Merck; Lilly)**

Available as a tablet (contains 0.5 mg colchicine and 0.5 mg probenecid) for oral administration or as an injectable solution (0.5 mg/ml) for IV administration. Both colchicine and probenecid have anti-gout activity. Inhibits release of histamine-containing granules from mast cells. Injectable solution used as an inhibitor of collagen production and may stimulate collagenase activity. May be indicated in some cases of hepatic fibrosis. Will not reverse fibrosis but may be helpful in preventing further damage.

May potentiate gout formation in some cases. Numerous metabolic side effects. Administration should be discontinued if vomiting or diarrhea occur.

**COPPER SULFATE - Caustic Powder (Phoenix; Butler)**

Available as a powder (51%) for topical application. Used for treating cases of ulcerative dermatitis.

**CYANOCOBALAMIN - Vitamin B<sub>12</sub> (Butler)**

Available as an injectable solution (1 or 3 mg/ml) for IM or SC administration. Birds being treated with B<sub>12</sub> may develop pink droppings.

**DEXAMETHASONE - Azium (Schering)**

Available as an injectable solution (2 or 4 mg/ml) for IM or IV administration. Anti-inflammatory that may be useful in debilitated animals. Dexamethasone is 20 times more active as an anti-inflammatory than prednisolone. Higher dose is used for treatment of shock and to reduce the effects of gram-negative endotoxemia that may occur when patients with bacteremia are treated with antibiotics. Higher dose may be immunosuppressive and a lower dose should be used for repeated therapy. Induces rapid glucocorticoid and anti-inflammatory response. May be useful as an adjunct therapy (with iodine) for treating goiter in budgerigars.

Has been associated with congenital deformities when administered to pregnant mammals. May cause increased levels of liver enzymes, polydipsia, polyuria and diarrhea. AST and ALT activities may increase to three times normal values within 36 hours of IM administration. Doses of three drops/gallon of water were found to be immunosuppressive in pigeons.

**DEXTROSE 5 to 50% - (Fort Dodge; Butler)**

Available as an injectable solution ( 5% - 50 mg/ml to 50% - 500 mg/ml) for slow IV administration. Used for the treatment of hypoglycemia. Must be given slowly to prevent circulatory collapse. 50% solution is hypertonic and cannot be given IM. Must be diluted to 5% solution for IM administration.

**DIAZEPAM - Valium (Roche)**

Available as an injectable solution (5 mg/ml) for IM or IV administration or as a solution (1 or 5 mg/ml) for oral administration. Can be used to control some seizures and feather picking (0.6 mg/kg IV, IM) in birds. Birds should be carefully supervised. May become so drowsy that they fall from an enclosure or perch.

**DIETHYLSTILBESTROL DIPHOSPHATE - Stilphostrol (Miles)**

Available as a tablet (50 mg) and as an injectable solution (0.25 mg/ml) for IM or IV. Low therapeutic index. Overdosing may cause anemia.

**DIGOXIN - Cardoxin (Evsco); Lanoxin (Coopers)**

Available as a solution for oral administration: Cardoxin = 15 mg/ml; Lanoxin = 0.05 mg/ml. Limited studies in birds. Suggested dosages based on studies in Quaker Conures, sparrows, parakeets and ducks. A dose of 0.01 mg/kg was found to reduce right ventricular enlargement in chickens. A dose of 0.02 mg/kg daily was considered safe and produced satisfactory plasma levels in parakeets.

Low therapeutic index. A dose of 0.1 mg/kg was found to induce arrhythmias in pigeons. Patients receiving digoxin should have regular ECG evaluations. Toxic reactions include depression, ataxia, vomiting, and diarrhea.

**DIHYDROSTREPTOMYCIN - Azimycin (Schering)**

Intramuscular injection has been associated with paralysis and death in some avian species.

**DIMERCAPROL - BAL (Becton Dickinson)**

Available as an injectable solution (100 mg/ml) for IM (painful) administration. Dimercaprol is a chelating agent that binds heavy metals including lead, gold, arsenic or mercury. Binding is reversible and a decreased activity occurs in an acidic environment. Less toxic than calcium EDTA and can be given orally. More rapid reduction in blood lead levels than occurs with calcium EDTA. Considered the drug of choice for removing lead from the CNS;

however, D-penicillamine is also effective and has a higher therapeutic index. Tachycardia is the most common side effect.

#### **DIMETHYLSULFOXIDE - Domoso (Syntex)**

Available as a liquid or gel (90% - 900 mg/ml) for topical application. Has been suggested as a method of reducing swelling and as a vehicle for carrying some antibiotics into difficult-to-reach sites of infection (joints, cellulitis, bumblefoot). May be helpful in reducing the swelling of prolapsed cloacal tissue prior to surgical correction. May cause local skin irritation. Has been associated with birth defects when used in pregnant mammals. Avoid contact with human skin.

#### **DIMETRIDAZOLE - Emtryl (Jensen Salisbury)**

Available as a soluble powder (182 g/6.42 oz) for oral administration. Used to treat giardiasis, trichomoniasis, histomoniasis, and hexamitiasis. Dimetridazole has activity against some anaerobic bacteria and may be useful in some cases of bumblefoot, ulcerative dermatitis, chronic sinusitis and metritis.

Low therapeutic index. Toxic to Pekin Robins and may be toxic in some other Passeriformes. Breeding birds should be treated only by gavage. If dimetridazole is added to the food or drinking water, a toxic level may be consumed or fed to a mate or nestlings. At a dose of one tsp/gal of drinking water, cockatiels, budgerigars and pigeons have been reported to develop incoordination, acute seizures and death. Extended therapy or excessive dosing may result in toxicity. Acute hepatitis has been reported in cockatiel fledglings. Some affected birds may respond to treatment with B vitamins. Is no longer available in the United States.

#### **DINOPROST TROMETHAMINE - Lutalyse (Upjohn)**

Available as a solution (5 mg/ml) for IM administration. Contains naturally occurring prostaglandin F<sub>2</sub> alpha. Prostaglandins may be effective in some cases of egg retention. This agent would be expected to relax the vagina and increase uterine tone, which may facilitate the passage of an egg. Prostaglandins may prove also to have a therapeutic benefit in removing necrotic debris from the uterus in cases of salpingitis.

#### **DIPHENHYDRAMINE HCl - Benadryl (Parke Davis)**

Available as a capsule (25 or 50 mg) for oral administration or injectable solution (10 or 50 mg/ml) for IM or IV administration. May be effective in calming some feather pickers or excessively anxious birds. Has sedative, antihistamine and anti-depressant activity. Dose may need to be altered based on clinical response. Has atropine-like action and toxic side effects.

#### **DOXAPRAM HCl - (Fort Dodge)**

Available as an injectable solution (20 mg/ml) for IV or SC administration. Has been used in birds as a respiratory stimulant. May be helpful in reversing the respiratory depressant effects of ketamine and xylazine.

#### **DOXEPIN HCl - Sinequan (Roerig)**

Available as capsules (10, 25, 50, 75, 100, or 150 mg) or suspension (10 mg/ml) for oral administration. Tricyclic anti-depressant that may be helpful in some cases of feather picking. May cause severe lethargy.

#### **DOXYCYCLINE - (Pfizer; Henry Schein; Roerig)**

Available as a suspension (5 mg/ml, Vibramycin monohydrate), syrup (10 mg/ml, Vibramycin calcium syrup) or capsules (100 mg, Henry Schein) for oral administration. Also available in the US as an injectable solution (10 mg/ml, Vibramycin hyclate) for IV administration. In Europe and Canada, an injectable solution (20 mg/ml, Vibravenös) is available that can be administered IM. A doxycycline for IM administration produced by a compounding pharmacist has been suggested for use in individual birds.

Doxycycline is the therapeutic agent of choice for the treatment of chlamydiosis. This agent has greater activity, less immunosuppression and fewer side effects with fungal overgrowth than other tetracycline preparations. Calcium and zinc have little effect on the absorption of doxycycline. Iron decreases absorption substantially. Calcium and zinc may reduce the half-life of doxycycline by binding excreted doxycycline and thereby preventing enterohepatic circulation. A bird's feces may turn red when being treated with oral doxycycline.

Vibramycin hyclate IV is the therapeutic agent of choice for treating acute and severe cases of chlamydiosis in the United States. Once a patient is stabilized with IV administration, it can be switched to an oral suspension (monohydrate or syrup). Vibravenös, available in Europe and Canada, administered IM, is the preparation of choice for treating chlamydiosis where available. Vibramycin monohydrate designed for IV administration may cause severe muscle necrosis when administered IM.

Injectable doxycycline should be used within six hours of being reconstituted. The drug may remain stable if refrigerated for 72 hours. Reconstituted IV injectable (hyclate only) solution can be maintained in the freezer. In general, the time-related degeneration of tetracyclines results in the formation of toxic by-products. If vomiting occurs with the higher recommended dose of oral doxycycline, the dose should be split and administered BID. If vomiting continues, the dose should be reduced in 5 mg/kg intervals until vomiting stops. Macaws appear to be particularly sensitive to doxycycline and are the most frequent species to regurgitate following oral administration. Consumption of doxycycline-medicated food caused an increase in AST and LDH activities in Goffin's Cockatoos. Gram's stains of the feces should be monitored for proliferation of candida when any tetracycline is being administered. Doxycycline does persist and may stop oviposition in egg-laying hens. Toucans, particularly young birds, are sensitive to tetracyclines and may develop bone deformities following its use (see Chapter 17).

#### **D-PENICILLAMINE - Cuprimine (Merck); Depen (Wallace)**

Available as capsules (Cuprimine, 125 or 250 mg); or tablets (Depen, 250 mg) for oral administration. Used as a chelating agent. Particularly effective for copper. May also reduce blood and tissue concentrations of lead, zinc and other heavy metals. Low therapeutic index. May cause aplastic anemia, agranulocytosis, vomiting and diarrhea.

#### **D-TUBOCURARINE**

Mydriatic (3 mg/ml strength) (see Chapter 26).

#### **ECHINACEA - (BioBotanica Inc.)**

Available as a solution (a derivative of *Angustifolia purpurea*) for oral administration. Used as an immunostimulant. May speed recovery in some cases of poxvirus and in debilitated birds.

#### **EDTA - TRIS Lysozyme Solution**

Must be prepared from a chemical base. Best obtained from a compounding pharmacist. Materials to prepare the solution are available from Sigma Chemical Co. The solution is made by mixing 3.07 g Trizma HCL, 3.71 g Trizma base, 1.12 g disodium EDTA and 0.045 g lysozyme in 1000 ml of water. Solution can be used intratracheally, intranasally or to lavage wounds. Toxic if administered orally or parenterally. Particularly effective in treating *Pseudomonas* dermatitis and sinusitis. EDTA - TRIS solution can be mixed and frozen. The lysozyme component should be added just before use.

The impermeability of the cell wall of gram-negative bacteria results in some of the antibiotic resistance seen with this group of bacteria. EDTA binds bivalent cations, which are required for

formation of the lipopolysaccharide layer of the cell wall. Lysozyme catalyzes the hydrolysis of peptidoglycans found in the bacterial cell wall. The damaged cell wall is more permeable to antibiotics.

**ENILCONAZOLE - Clinafarm (Sterwin)**

Available as a solution (13.8% - 138 mg/ml) for topical use on hatchery and farm equipment for the control of aspergillosis. Corrosive and may cause irreversible damage to the eyes.

**ENROFLOXACIN - Baytril (Haver/Diamond)**

Available as a tablet (5.7, 22.7 or 68 mg) for oral administration or as an injectable solution (22.7 mg/ml) for IM administration. Baytril is the veterinary-labelled form of a fluoroquinolone class of antibiotics (human product = ciprofloxacin). The injectable solution can be administered orally. IM injection may result in severe muscle necrosis in some species. There is no advantage to using ciprofloxacin in place of enrofloxacin. Inability of bacteria to develop resistance is over-rated. Many gram-negative bacteria, particularly pseudomonas, are resistant to enrofloxacin and ciprofloxacin. Early studies show encouraging results in chlamydia therapy (see Chapter 34). Birds should be monitored for the development of secondary yeast infections.

Enrofloxacin may cause irritability in some birds. Long-term enrofloxacin treatment in pigeons was well tolerated; however, a dose-dependent increase in embryonic mortality was associated with drug administration to breeding pigeons. Hens receiving 800 ppm of enrofloxacin passed the drug in their crop milk, causing decreased weight gains and occasional joint abnormalities in squabs. A Senegal Parrot treated with enrofloxacin and ketoconazole for ten days was found to have renal damage. This drug should be used with caution in young birds. Quinolones have been suggested as a cause of joint problems in young psittacines and pigeons in Europe (see Chapter 17).

**EPINEPHRINE (1:1000) - (Webster; Vedco; Butler; Phoenix)**

Available as an injectable solution. Dilute with 10 parts LRS. This drug should be used with caution in birds. The therapeutic index for this drug is low. Clinical indications are confined to desperate attempts at restoring cardiac function in cases of peracute death from anesthesia.

**ERGONOVINE MALEATE - Ergotrate maleate (Lilly)**

Available as an injectable solution (0.2 mg/ml) for IM administration. Causes firm contractions of the uterus. Used in conjunction with calcium gluconate to induce the passage of an egg from the oviduct. Contraindicated if the egg is adhered to the wall of the oviduct or if a mechanical blockage is preventing egg passage.

**ERYTHROMYCIN - (Sanofi; Lextron)**

Available as an injectable solution (100 or 200 mg/ml) for IM or IV administration or as tablets (250 or 500 mg) or solutions for oral administration. Most gram-negative bacteria that affect psittacines are resistant to this drug. May be effective in cases of sinusitis and air sacculitis caused by mycoplasma. Injectable solution can be used in a nebulizer to treat upper respiratory infections caused by mycoplasma. Injectable solution administered IM can cause severe muscle necrosis (see Chapter 17).

**ETHAMBUTOL HYDROCHLORIDE - Myambutol (Lederle)**

Available as tablets (100 or 400 mg) for oral administration. Used for the treatment of *Mycobacterium* spp. infections, particularly strains that are resistant to isoniazid.

**FENBENDAZOLE - Panacur (Hoechst-Roussel)**

Available as a suspension (10% -100mg/ml) for oral administration. Can be used for ascarids, some microfilaria, flukes and capillaria. Fenbendazole should not be used while active feather development is occurring (may damage developing feathers). Has not been

found to be effective against the gizzard worm that infects finches. May not always be effective against capillaria. May be effective against *Syngamus* spp. The drug has a low therapeutic index in some species of finches. A dose of 10 ml/liter of water has been associated with death three to five days following administration. This dose may cause ataxia, depression and mydriasis in canaries.

**FERRIC SULFATE - Monsel's Solution**

Available as a liquid or powder for topical application. Used for chemical cauterization of minor bleeding caused by damage to beak or nails. Should not be used to stop bleeding associated with soft tissue or damaged pin feathers. Placing a foreign compound into a feather follicle can cause the formation of feather cysts.

**FLUCONAZOLE - Diflucan (Roerig)**

Available as tablets (50, 100 or 200 mg) for oral administration or as an injectable solution (2 mg/ml) for IV administration. *In vitro* activity for aspergillosis, candida and cryptococcus. Passes blood-brain barrier.

May not be compatible with other antifungals. Transient regurgitation may occur in some species, particularly cockatoos and cockatiels. Elevated AST and LDH levels have been reported in some species being treated with fluconazole (see Chapter 17).

**FLUCYTOSINE - 5-fluorocytosine, Ancobon (Roche)**

Available as a capsule (250 and 500 mg) for oral administration. May be indicated for the long-term treatment of aspergillosis infections or for severe candidiasis infections that are resistant to nystatin. Because nystatin is not absorbed from the gut, flucytosine may be used to treat candida infections in other organ systems (particularly respiratory infections).

Flucytosine is toxic to the bone marrow and frequent CBCs should be used to monitor for evidence of bone marrow damage.

**FLUNIXIN-MEGLUMINE - Banamine (Schering)**

Available as an injectable solution (50 mg/ml) for IV or IM administration. Derived from nicotinic acid. Potent cyclo-oxygenase inhibitor that functions as a non-steroidal analgesic, anti-inflammatory and antipyretic agent. May be helpful in some cases of shock and trauma. May also be useful as an antipyretic in cases of hyperthermia. May cause vomiting and diarrhea in some birds.

**FURAZOLIDONE**

Has been associated with congestive heart failure and death in chicks, ducklings and turkey poults.

**FUROSEMIDE - Lasix (Hoescht-Roussel)**

Available as an injectable solution (5% - 50 mg/ml) for IM or IV administration or as a syrup (1% - 10 mg/ml) for oral administration. Used as a diuretic. Furosemide should be considered to have a low therapeutic index in birds. Some avian species (particularly lorries) are extremely sensitive. Overdose may cause severe dehydration and electrolyte abnormalities. Toxic reactions are characterized by neurologic signs and death.

**GENTAMICIN SULFATE - (Butler; Schering)**

Available as an injectable solution (50 mg/ml) that may be used orally, intranasally, topically or for nebulization. Also available as ophthalmic ointment or as otic solution (3 mg/ml) that can be used intranasally or topically. For nebulization, 1 ml of injectable solution is mixed with 10 ml of saline and nebulized for 15 minutes TID.

Experimental data indicate that the doses needed to maintain therapeutic blood levels and the doses that cause nephrotoxicity and ototoxicity vary widely among avian species. A transient polyuria indicative of renal damage is common. The dose that is considered nephrotoxic has not been determined for all birds.

Prolonged use in any bird can cause permanent renal damage. Owls appear to be particularly sensitive to the toxic effects of gentamicin, as are some cockatoo species. A dose of 20 mg/kg IM, subcutaneously or IV can cause collapse, respiratory arrest and death in some avian species, particularly lories. Parenteral administration of amikacin is safer in birds. Gentamicin ophthalmic solution must be used with caution in small birds to prevent overdosing and nephrotoxicity. Gentamicin should be used only in life-threatening infections that have been shown to be resistant to less toxic antibiotics or amikacin.

Gentamicin is not absorbed from the gut and can be given orally to sterilize the gut or to treat severe cases of enteritis in which an infection is localized to the gastrointestinal tract. Oral administration is generally needed only for two to three days. This drug can be nebulized for the treatment of upper respiratory infections (sinuses, trachea, lungs). Topical preparations may impair wound contraction and retard healing. The toxic effects of aminoglycosides may be potentiated when used in combination with cephalosporins or furosemide (see Chapter 17).

#### **GENTIAN VIOLET - GV-11 (Norelco)**

Available as a powder or solution (1.6% - 16 mg/ml) for oral administration. Can be used to treat gastrointestinal candidiasis that is resistant to nystatin. Acts as a drying agent, which may be helpful in treating moist dermatitis. Will stain clothing, feathers and hands.

#### **HALOPERIDOL - Haldol (Henry Schein)**

Available as a solution (2 mg/ml) for oral administration or as an injectable solution (50 or 100 mg/ml) for IM administration. Used in humans to treat compulsive, obsessive behavior. Has a tranquilizing effect in humans with mental confusion. May be effective in some cases of feather picking and self-mutilation in birds. Appears to work best in cockatoos. African Grey Parrots and Quaker Parakeets may be disoriented or neurotic following administration. The IM product may provide two to three weeks of activity. Should be used in conjunction with behavioral modification to correct the inciting cause of the destructive behavior. The dose should be adjusted by increasing or decreasing 0.01 ml every two days. Administration should be discontinued if anorexia, ataxia or vomiting occur. Quaker Parakeets and Umbrella and Moluccan Cockatoos appear to be particularly sensitive to this drug and may respond to much lower doses (0.05 mg/kg, SID).

#### **HALOXON**

Often combined with piperazine for the treatment of capillaria in pigeons. Low therapeutic index in Psittaciformes, Anseriformes and raptors. Antidote for toxicity is atropine.

#### **HEMICELLULOSE - Psyllium; Metamucil (Searle)**

Found as a fiber source in some formulated diets. May be effective in controlling glucosuria, hypocalcemia and hypercholesterolemia. Can be administered as a bulk laxative to aid in the passage of foreign bodies. Large doses may precipitate out in the crop or upper intestinal tract causing an impaction.

#### **HYDROCHLORIC ACID**

A one M/l solution is mixed at a rate of 30 ml/pint of drinking water. May be effective in some cases of enteritis that are not responsive to traditional therapy. Preliminary findings suggest that this treatment may help in some cases of megabacteriosis.

#### **IMMUNOREGULIN - (Immunovet)**

Available as a solution for IV administration. Has been suggested as an immunostimulant in birds, but there is no scientific documentation that it is effective. Anaphylactic reactions and death have been reported in some birds.

#### **IODINE - Lugol's Solution (Butler); Renografin-76 (Solvay)**

Available as a solution (50 mg/ml free iodine and 100 mg/ml potassium iodine). Used in water to prevent goiter in iodine-deficient areas. Will oxidize if exposed to light and must be stored in dark-colored bottle. Concentrated solution is made by mixing two ml of Lugol's solution in 30 ml of water. Working solution is mixed fresh daily by mixing one drop of concentrated solution in 250 ml of drinking water. Organic iodines (diatrizoate sodium, 37% iodine) can be administered IM (122 mg/kg) in budgerigars with goiter.

#### **IPRONIDAZOLE - Ipropan (Roche)**

Available as a solution (100 mg/ml (61 g/2.65 oz) for oral administration. Used to treat trichomoniasis, histomoniasis and giardiasis.

#### **IRON DEXTRAN - (Butler; Lextron; Vedco)**

Available as a solution (100 mg/ml) for IM injection. Indicated in some cases of anemia and hemorrhage. Must be used with caution in toucans and mynah birds that are prone to hemochromatosis.

#### **ISONIAZID - INH (CIBA Pharmaceuticals)**

Available as a tablet (300 mg) Also available as a capsule in combination with rifampin (Rifamate - 300 mg isoniazid and 300 mg rifampin). Destroys actively growing tubercle bacilli. May cause a fatal hepatitis, vomiting, depression and ataxia.

#### **ITRACONAZOLE - Sporanox (Janssen)**

Available as capsules (100 mg) for oral administration. *In vitro* activity for aspergillosis, candida and cryptococcus. Used successfully in Europe for aspergillosis in waterfowl and penguins. This drug is considered to be more effective against aspergillosis and less toxic than other anti-fungals.

Has been associated with anorexia and depression in African Grey Parrots given 8-10 mg/kg BID. Other reports indicate that it is effective against aspergillosis in Psittaciformes with few side effects at a dose of 10 mg/kg BID for months. Has been associated with hepatitis in mammals (see Chapter 17).

#### **IVERMECTIN - Ivomec, Eqvalen (Merck Agvet)**

Supplied as an injectable solution (10 mg/ml) for IM, topical or oral administration. Effective for some nematodes, mites and lice. Most effective therapy for *Knemidokoptes*. Calculated dose can be used topically on affected areas or can be given orally.

May also be effective for *Oxyuris*, some coccidia, some nematodes, gapeworms and sternostomatosis. May not be effective against all coccidia. Toxic in bullfinches and goldfinches when used topically at 0.4 mg/kg. Propylene glycol is used as a carrier in the solution designed for cattle and pig use. This product will precipitate out if diluted with sterile water. The propylene glycol-based product may cause toxic reactions when administered IM, particularly in small birds. Ivermectin diluted in propylene glycol will settle out and the diluted product should be thoroughly mixed before administration. The water-soluble preparation designed for use in horses is easier to work with and appears to be safer. However, deaths in finches and budgerigars have been reported when Eqvalen (the water based formula) was administered IM at the recommended dose.

Ivermectin is environmentally stable and is highly toxic to fish and crustaceans. The drug or its metabolites should not be allowed to contaminate lakes, streams or rivers.

#### **KETOCONAZOLE - Nizoral (Janssen)**

Available as a tablet (200 mg) for oral administration. Used for the treatment of severe candidiasis in which other therapies have been ineffective. This drug is water-soluble and is easiest to dissolve in acid. Tablets can be dissolved in 0.8 ml one M hydrochloric acid and 3.2 ml of water for administration by gavage. The mixture normally turns light pink.

Crushed tablets can also be added to mashes or mixed in orange juice, aloe vera, lactulose or pineapple juice if accepted by the patient. Crushed tablets can be mixed with methyl-cellulose by a compounding pharmacist to produce a stable product that is easy to administer. This drug impairs synthesis of ergosterol, which is a critical component of the fungal cell membrane. May cause hepatocellular necrosis (see Chapter 17).

#### LACTATED RINGER'S SOLUTION (LRS)

Available as an isotonic solution for IV administration. Can also be administered orally if gastrointestinal stasis or vomiting are absent. In cases of mild dehydration (5%), oral administration may be effective. Absorption may be enhanced by mixing with psyllium and sugar. In more severe cases, parenteral administration of fluids is required. Fluid replacement is calculated by: body wt in g X % dehydration = quantity of fluid in ml. The maintenance fluid requirement for birds is considered to be 50 ml/kg/day.

#### LACTOBACILLUS - Probiocin (Pioneer)

Contains *Lactobacillus planatarum*, *Streptococcus faecium*, *L. casei* and *L. acidophilus*. Multi-dose application may be effective in establishing flora that can act to prevent pathogenic gram-negative bacteria from colonizing the gastrointestinal tract. Should be considered as adjunct therapy in any bird that has received antibiotics, has bacterial enteritis or has a reduced population of intestinal microbes as determined by Gram's staining.

#### LACTULOSE - Cephulac (Marion Merrell Dow)

Available as a suspension (667 mg/ml) for oral administration. Acts as an osmotic retardant to the absorption of potential toxins from the gastrointestinal tract. Palatable and usually well tolerated by patients. Can be used as a carrier for many less palatable drugs. Indicated in cases of liver disease to decrease the load of metabolites that must be processed by the liver. May be effective as an appetite stimulant in some birds. May also be effective in establishing a gastrointestinal environment that favors the growth of autochthonous flora. Can be used daily for weeks if needed. The dosage should be reduced if diarrhea occurs.

#### LEVAMISOLE - Levasole (Pitman Moore);

#### Tramisol (American Cyanamid); L-Spartakon (Janssen)

Available as an injectable solution (13.65% - 136.5 mg/ml) for IM, SC, or PO or as tablets (20 mg) in Europe for PO in pigeons. May be effective for intestinal nematodes. Experimental studies in chickens suggest that a dose of 1.25-2.5 mg/kg administered PO or SC increases immune response in immunosuppressed birds. However, there is no work to confirm a positive immunostimulatory effect in other birds. Suggested dosing when used as an immunostimulant is 2 mg/kg IM or SC every 14 days for three doses. May cause swelling at the injection site.

Low therapeutic index. This drug is not recommended for use in debilitated patients. Parenteral administration of 2 to 4 times therapeutic dose may cause vomiting, neurologic problems and death. A dose of 40 mg/kg SC or IM has been associated with ataxia, depression, regurgitation and mydriasis in some cockatoos, budgerigars and mynah birds. Clinical signs are most severe when administered IM. A dose of 25 mg/kg IM has been associated with hepatotoxicity in budgerigars. Death has been reported in pigeons administered 35 mg/kg IM, Peach-faced Lovebirds administered 66 mg/kg IM and White Ibis administered 22 mg/kg IM.

#### LEVOTHYROXINE SODIUM - Thyroxine L (Butler)

Available in tablet form (0.1, 0.2, 0.3, 0.5, or 0.8 mg) or suspension (0.4 mg/ml) for oral administration. Can be mixed with drinking water (mixed fresh daily) to treat goiter and hypothyroidism. A tablet (0.1 mg) is crushed and mixed with 4-12 oz of drinking water. Response to therapy is widely variable. May induce molt. T<sub>4</sub> levels

should be monitored with long-term therapy to maintain proper blood levels and prevent overdose. Should be used with extreme caution except in cases of documented hypothyroidism. Overdose causes an iatrogenic hyperthyroidism (tachycardia, polydipsia, polyuria, vomiting, weight loss, convulsion and death) (see Chapter 23).

#### LINCOMYCIN HCL - Lincocin (Upjohn)

Available as a solution (50 mg/ml) for oral administration or as an injectable solution (100 mg/ml) for IM or IV administration. This drug has poor activity against most gram-negative bacteria but does have good activity for many gram-positive organisms. May be effective in treating chronic respiratory infections caused by mycoplasma. May be useful in cases of chronic dermatitis caused by gram-positive organisms. Has been associated with death in some birds when administered IV. Patients should be monitored for secondary yeast infections.

#### LEUPROLIDE - Lupron (TAP Pharmaceuticals)

Available as lyophilized microspheres (7.5 mg/vial) for IM injection. Has been shown to cause cessation of ovarian activity for up to 14 days in cockatiels. May be used in cases of egg-related peritonitis to stop ovarian function. Reduces levels of testosterone to castration levels. Has been used to stop aggressive male behavior.

#### LORELCO - Probacoll (Merrell Dow)

Available as tablets (250 or 500 mg) for oral administration. Used in mammals to lower blood cholesterol levels. Has been used in birds to control lipemia and suppress the growth of lipomas. In humans, drug administration is discontinued if a patient has a prolonged QT interval.

#### MANNITOL - (Webster; Vedco)

Available as an injectable solution (20 mg/ml or 180 mg/ml) for slow IV administration. Functions as an osmotic diuretic and may be effective in reducing intraocular and intracranial pressure. Used primarily to reduce brain swelling following head trauma.

#### MEBENDAZOLE - Telmintic, Telmin (Pitman Moore)

Available as a soluble powder (Telmintic, 40 mg/g) or suspension (Telmin, 33.3 mg/ml) for oral administration by gavage or by lacing food. Primarily used for capillaria. Has been associated with hepatitis in some mammals and raptors. Death and intestinal obstruction caused by dead nematodes have been reported at all doses in some finches and some psittacine birds. Reported to be toxic in pigeons, cormorants, pelicans and raptors. Commonly mixed in the food of geese and pheasants. A dose of 12 mg/kg may cause death in Columbiformes.

#### MEDROXYPROGESTERONE ACETATE - (Upjohn)

Available as tablets (2.5, 5, or 10 mg, Provera promone) for oral administration or as an injectable suspension (100 mg/ml, Depo-provera) for IM or SC administration. Intramuscular injection may cause muscle necrosis. Can be used to inhibit ovulation and as an antipyretic. Inhibits secretion of pituitary gonadotropin and prevents follicular development and ovulation. In some birds, one dose may be effective in suppressing ovulation for six months. The dose of medroxyprogesterone varies with the size of the bird (150 g [0.05 mg/g]; 150-300 g [0.04 mg/g]; 300-700 g [0.03 mg/g]; 700 g [0.025 mg/g]; Umbrella Cockatoo [0.018 mg/g]).

There are numerous metabolic side effects. A single dose may cause lethargy, obesity, polydipsia, polyuria and fatty liver syndrome in some species. Cockatoos and Quaker Parakeets appear to be very sensitive and require a reduced dose (see Chapter 29).

**METHRIDINE -**

Used to treat capillaria in raptors only. Commonly causes vomiting which helps expel parasites in the pharynx and esophagus. Should not be stored in plastic.

**METHYLPREDNISOLONE ACETATE - Depo-Medrol (Upjohn)**

Available as an injectable solution (20 or 40 mg/ml) for IM administration. Has been associated with birth defects when administered to pregnant mammals.

**METOCLOPRAMIDE HCl - Reglan (Robins)**

Available as tablets (10 mg) or syrup (1 mg/ml) for oral administration. Also available as an injectable solution (5 mg/ml) for IV or IM administration. Thought to sensitize tissues to acetylcholine. In mammals, stimulates gastrointestinal motility without increasing gastric, biliary or pancreatic secretions. Indicated in birds with gastrointestinal motility problems, slow crop-emptying, regurgitation and vomiting that is not associated with blockage of the gastrointestinal tract.

Has been associated with hyperactivity in some birds. Should not be used when gastrointestinal stasis is caused by intraluminal or extraluminal masses that are preventing the movement of ingesta. Also contraindicated in cases of gastrointestinal bleeding or perforation.

**METRONIDAZOLE - Flagyl (Searle)**

Available as tablets (250 or 500 mg) for oral administration or as an injectable solution (5 mg/ml) for slow IV administration. Used for treatment of giardia, hexamita and for anaerobic bacterial infections. Resistant organisms may require two daily injections followed by two more doses in 14 days.

Contraindicated in finches. Injectable solution can be administered IM but may cause necrosis at the site of injection. Needles and IV sets containing aluminum should not be used with some preparations.

**MIBOLERONE - Cheque (UpJohn)**

Available as a solution (100 µg/ml) for oral administration. May be effective in stopping oviposition. The experimental dose is 10 µg/kg.

**MICONAZOLE - Monistat (Janssen)**

Available as an injectable solution (10 mg/ml) for slow IV administration or as an ointment or cream (1 or 2%) for topical administration. Used for the treatment of systemic mycosis, particularly candida and cryptococcus. Must be given slowly to prevent tachycardia, cardiac arrhythmia or death. Ointment can be used for nasal or dermal fungal infections. High therapeutic index in mammals.

**MINERAL OIL**

Administered by gavage as a laxative and to aid in the removal of intraluminal foreign bodies (eg, lead, zinc, plastics). Aspiration pneumonia is common if administered orally.

**MONENSIN SODIUM - Coban (Elanco)**

Available as a feed additive (45 or 60 g/lb) for oral administration. Used to prevent coccidiosis in Galliformes, quail, cranes and pigeons. Has been shown to be safe in cranes at five times the therapeutic dose. Monensin was more effective than clazuril or amprolium for treating coccidiosis in Galliformes and cranes. May be lethal if consumed by mature turkey or guinea fowl.

**MORPHINE**

Sensitivity and response varies with species. In Galliformes, 2.5 - 30 mg/kg produces analgesia.

**NALOXONE - (Pitman; Moore)**

Available as an injectable solution for slow IV administration as a narcotic and tranquilizer antagonist.

**NATAMYCIN - Natacyn (Alcon)**

Available as a 5% solution for ophthalmic use. Used for ocular and periocular fungal infections. Patients receiving this medication should be slowly weaned off the drug by a gradual reduction in dosing.

**NEOMYCIN - Biosol (Upjohn)**

Available as a solution (50 mg/ml) for oral administration. The drug preparation that contains methscopolamine bromide (BiosolIM) can be toxic. Not absorbed from the gastrointestinal tract. Drug preparation used mainly for sterilizing the gut in infections localized to the gastrointestinal tract.

**NEOMYCIN TOPICAL - (Schering)**

Available as an ointment or cream for topical administration. Some preparations may also contain other antibiotics, steroids, trypsin, and chymotrypsin. The preparations containing trypsin and chymotrypsin are particularly useful for debriding and providing antimicrobial activity to necrotic areas of skin.

**NICLOSAMIDE - Nicloside (Miles)**

Available as a tablet (500 mg) for gavage or by lacing food. Primarily used for tapeworms. Causes the expulsion of the parasite, which can be a diagnostic aid in difficult-to-detect infections. The ground tablets are not soluble in water and must be added to a gruel. Has been used in a baked bread type of food for administration to finches in Australia. Tablets can be administered directly to some larger species. All doses have been associated with death in pigeons, geese and some other Anseriformes.

**NITROFURAZONE - Furacin (SmithKline Beecham)**

Available as a soluble powder (9.2% - 92 mg/ml) for oral administration or as a solution or ointment (0.2% - 2 mg/ml) for topical application. May be effective in preventing the spread of *E. coli* and salmonella-induced enteritis on a flock basis. Has been used to treat some strains of coccidia in psittacine birds. The coccidia that infect toucans and mynahs appear to be less susceptible. Topical preparations slow epithelialization and retard wound healing.

Nitrofurazone has a low therapeutic index and should not be mixed in nectar. Overdose may cause neurologic signs or death. If neurologic signs occur, treatment should stop immediately. A dose of 1 tsp/gallon of drinking water may cause screaming, incoordination, vomiting, and death in mynahs, lorikeets and lories. Topical preparations slow epithelialization of damaged tissues. Furacin powder should not be used on wounds that could be open to the pneumatic bones or to the abdomen or thorax. May cause severe granulation formation if it enters the air sacs.

**NITROTHIAZOLE - Enhapin (American Cyanamid)**

All doses administered orally have been associated with death in finches.

**NORTRIPTYLINE HCl - Aventyl HCl (Lilly)**

Available as a tablet (25 mg/ml) or syrup (2 mg/ml) for oral administration. A tricyclic anti-depressant that is used in humans as a mood elevator to treat depression. May be effective in treating some cases of feather picking. If a bird becomes hyperactive, the drug dose should be reduced and if it remains hyperactive, treatment should be stopped. Clinical experience suggests that this drug is rarely effective in cases of feather picking.

**NYSTATIN - Mycostatin (Apothecan); Myco 20 (Squibb)**

Available as a suspension (100,000 units/ml) or as a feed premix (Myco 20) for oral administration. Used for the treatment of sus-

ceptible strains of candida localized to the gastrointestinal tract. Nystatin must come in contact with candida to be effective and is not absorbed from the gastrointestinal tract. Oral lesions must be treated topically and will not resolve if nystatin is administered by gavage. Neonates that are receiving antibiotics should be monitored by Gram's stains for the early detection of candida overgrowth. If candida is found to be proliferating, nystatin therapy should be initiated. Some strains of candida are resistant to nystatin and Gram's stains should be used to monitor therapeutic results.

Nystatin feed premixes contain high levels of calcium and should not be used in conjunction with tetracycline therapy (see Chapter 17).

#### **OXFENBENDAZOLE - Synanthic (Syntex)**

Available as a suspension (90.6 or 225 mg/ml) for oral administration. May be effective for some nematode infections.

#### **OXYTETRACYCLINE - Liquamycin - LA200 (Pfizer)**

Long-acting tetracycline available as an injectable solution (200 mg/ml) for IM or IV administration. It may be effective in treating chlamydiosis, but severe muscle necrosis may occur in some species following IM administration. Secondary yeast infections may be a problem (see Chapter 17).

#### **OXYTOCIN - (Butler; Lextron; Vedco)**

Available as an injectable solution (20 units/ml) for IM, IV or SC administration. Used in conjunction with calcium gluconate for the treatment of uncomplicated uterine stasis. Should not be used if an egg is adhered to the oviduct, if the uterus is ruptured or if passage of an egg is mechanically inhibited.

#### **2-PAM**

Available as an injectable solution for IM injection as an antidote to cholinesterase inhibitor toxicosis as seen in many insecticide toxicities.

#### **PANCREATIC ENZYMES - Viokase V (Fort Dodge); Hi-Vegi-Lip (Freeda Vit, Inc.)**

Available as a powder for oral administration. Contains lipase, protease and amylase. Can be mixed with food or administered by gavage. Primarily indicated in cases of pancreatic insufficiency but may also help in the digestion of food in some cases of weight loss, enteritis or slowed crop-emptying. Viokase has been developed for use in mammals. Hi-Vegi-Lip may be more effective for assisting in the digestion of high-cellulose diets consumed by grain-eating birds. This product is available in 2400 g tablets. One-fourth of a tablet may be mixed with water or hand feeding formula and gavigated in a 250-500 g bird with each meal.

#### **PANCURONIUM BROMIDE - (Astra)**

Synthetic, non-depolarizing, neuro-muscular blocking agent used to dilate the pupil. Dose of 0.06 mg/kg injected into the anterior chamber of the eye of an eagle resulted in tachycardia, dyspnea and depression within 20 minutes.

#### **PARCONAZOLE**

Used as a food additive in Europe to control candida.

#### **PHENOBARBITAL - Donnatal (Robins)**

Available as a tablet (16.2 mg), elixir (3 mg/ml), or solution (4 mg/ml) for oral administration. Has a peripheral anticholinergic, antispasmodic and mild sedative effect. Should not be used in patients with gastrointestinal blockage. May cause depression, vomiting and ataxia.

#### **PHENYLBUTAZONE - Butazolidin (Coopers)**

Available as an injectable solution (200 mg/ml) for IV administration or as a tablet (100 or 400 mg) for oral administration. Non-

steroidal anti-inflammatory anti-pyretic agent. Not for SC or IM administration.

#### **PIPERACILLIN - Pipracil (Lederle)**

Available as an injectable solution (200 mg/ml) for IM or IV administration. Lower end of dose range used when combined with aminoglycoside administration.

Piperacillin is unstable (48 hours when refrigerated) once it is reconstituted. It can be reconstituted, transferred into sterile vials and frozen for one month (see Chapter 17).

#### **PIPERAZINE - (Agrilabs)**

Available as a suspension (17% - 170 mg/ml or 34% - 340 mg/ml) for oral administration. Has been used for ascarids in gallinaceous birds. Has not been shown to be effective in psittacine birds and finches.

#### **POLYMYXIN B**

A dose of 5-10 mg/kg has been associated with weakness, incoordination, vomiting and death in Amazon parrots.

#### **POTASSIUM CHLORIDE**

Available as an injectable solution for slow IV administration in concert with electrolyte analysis and electrocardiography. Can cause arrhythmias.

#### **PRAZQUANTEL - Droncit (Haver/Diamond)**

Available as tablets (23 or 34 mg) for oral administration or as an injectable solution (56.8 mg/ml) for IM, SC or PO. Used for treating tapeworm infections. Can be administered by gavage or by lacing food. May stop the shedding of tapeworm eggs but not eliminate the adults. Discussed as treatment for liver flukes but may not be effective (see chlorsulon).

Injectable form may be toxic in some species, particularly finches. A dose of 100 to 250 mg/kg IM has been associated with depression and death in some species.

#### **PREDNISOLONE SODIUM SUCCINATE - Cort Sol (Butler); Solu-Delta-Cortef (Upjohn)**

Available as a tablet (5 mg) for oral administration or as an injectable solution (10 or 50 mg/ml) for IM or IV administration. For oral administration, mix one (5 mg) tablet in 2.5 ml of water (makes a solution of 2 mg/ml). Dose is 6 mg/kg BID. Can be mixed with lactulose for oral administration. Used as an anti-inflammatory in cases of shock and trauma. Long-term therapy should be avoided. Also effective in reducing the effects of endotoxins released from the destruction of gram-negative bacteria.

#### **PRIMAQUINE PHOSPHATE**

See chloroquine phosphate. Used in combination with chloroquine for the treatment of avian malaria (*Plasmodium* sp.).

#### **PROCAINE PENICILLIN G AND PENICILLIN BENZATHINE - Ambi-pen (Butler); Benza-pen (SmithKline Beecham)**

Available as an injectable solution (150,000 units penicillin G procaine and 150,000 units penicillin benzathine) for IM or SC administration. Maintains therapeutic blood levels up to 48 hours in some species. Most effective in gallinaceous species and Anseriformes that are difficult to catch for more frequent drug administration. Should not be used in small birds because of a high incidence of procaine overdose and death in these species. A dose of 1 mg/kg has been associated with paralysis and death in some species.

#### **PROPRANOLOL - Inderol (Wyeth-Ayerst)**

Available as a tablet (10, 20, 40, 60, 80 mg) for oral administration or as an injectable (1 mg/ml) for slow IV administration. Beta adrenergic receptor blocker that has antihypertensive and antiar-

rhythmic effects. Used in cases of tachycardia. May cause depression, vomiting, heart failure or bradycardia, and patients should be carefully monitored during administration.

#### **PYRANTEL PAMOATE - Strongid T (Pfizer)**

Available as an oral suspension (4.5 mg/ml). High therapeutic index. Effective for many intestinal nematodes.

#### **PYRETHRINS**

Used topically for the treatment of external parasites that are resistant to carbaryl. Therapy for lice is the primary indication for use. Lice frequently inhabit the axillary regions, and the wings should be extended during treatment to ensure that pyrethrin is properly applied to the axillary regions.

#### **PYRIMETHAMINE - Daraprim (Burroughs Wellcome)**

Available as a tablet (25 mg) for oral administration. To facilitate administration, tablets can be mixed in 21 ml of water and 4 ml of KY jelly, creating a suspension containing 1 mg/ml. Used to treat plasmodium, toxoplasma and sarcocystis. The drug is a folic acid antagonist and its effects are potentiated by the administration of sulfonamides.

#### **QUINACRINE HCL- Atabrine (Sanofi; Winthrop)**

Available in a tablet (100 mg) that can be crushed and administered by gavage. Effective for the treatment of *Haemoproteus*; however, this parasite is not currently considered to be pathogenic, and treatment is not recommended. Low therapeutic index. Dose of 50-150 mg/kg (five times the recommended dose) causes hepatotoxicity in cockatoos.

#### **RAFOXANIDE**

For treatment of cestodes in Falconiformes. May be effective against some trematodes. Dose is 40 mg/kg orally.

#### **RIFAMPIN - Rifadin (Marion Merrell Dow)**

Available as a capsule (150 or 300 mg) for oral administration. Also available in combination with isoniazid (Rifamate). Inhibits DNA-dependent RNA polymerase activity. Interferes with bacterial but not mammalian RNA polymerase. Destroys growing tubercle bacilli. May cause a fatal hepatitis, CNS signs, depression or vomiting.

#### **SODIUM SULFATE - GoLYTELY (Braintree Laboratories)**

Osmotic cathartic that can be used to evacuate the gastrointestinal tract. Used in heavy metal poisoning to prevent absorption from the gastrointestinal tract by forming insoluble complexes. Should not be used in cases with impaired gastrointestinal function. Contraindicated with dehydration.

#### **SPECTINOMYCIN - Spectam (Sanofi; Syntex)**

Available as an injectable solution (50 or 100 mg/ml - Spectam) for IM administration or as a water-soluble solution (50 mg/ml) for oral administration. Used with some success for the flock (Galliformes) treatment of enteritis caused by gram-negative bacteria.

#### **STA SOLUTION**

Salicylic acid (3 g), tannic acid (3 g) qs in ethyl alcohol to 100 ml. Used as a topical treatment for moist and fungal dermatitis.

#### **STANOZOLOL - Winstrol V (Upjohn)**

Available as a tablet (2 mg) for oral administration or an injectable solution (50 mg/ml) for IM administration. For oral administration, a 2 mg tablet is crushed in 4 oz of water. Anabolic steroid used to increase weight gain and improve recovery from debilitating disease. Should be used with caution in birds with hepatic or renal disease. The effects of administration to gravid hens is unknown. A controlled substance in some states.

#### **STREPTOMYCIN SULFATE**

Used frequently in Columbiformes and Galliformes. Low therapeutic index. Appears to be highly toxic in most species of companion birds.

#### **SUCRALFATE - Carafate (Marion Merrell Dow)**

Available as a tablet (1 g) for oral administration. Can be mixed in 10 ml of water for administration. Disaccharide that reacts with stomach acids to form a complex that binds to the proteins associated with an ulcer, producing a protective layer that protects the ulcerated mucosa from gastric acids and microbial pathogens. Indicated in cases of gastrointestinal bleeding.

#### **SULFACHLORPYRIDAZINE - Vetsulid (Solvay)**

Available as an oral suspension (5% - 50 mg/ml) for oral administration or as an injectable solution (215 mg/ml) for IV administration. Used for treatment of *E. coli*-induced enteritis in Galliformes. Can cause hypersensitivity reaction resulting in a hemorrhagic syndrome. Repeated use of sulfonamides can induce hypersensitization and toxicity (hemorrhagic crisis).

#### **TESTOSTERONE CYPIONATE - (Henry Schein; Upjohn)**

Available as a tablet (10 mg or 25 mg, Methyltestosterone) for oral administration or as an injectable solution (200 mg/ml, Depo-testosterone) for IM administration. Incorrectly used to increase male reproductive activity and for some cases of feather loss. May be useful in some cases of reproductive-associated feather picking and chronic egg-laying. Prolonged use is not advised. Contraindicated in cases of renal or liver disease. For water administration, 100 mg is added to one oz. of water. Five drops of the stock solution is added to one oz of drinking water and is mixed fresh daily.

#### **TETRACYCLINE**

Available as a soluble powder, capsules (250 mg), suspension or solution (100 mg/ml) for oral administration. Also available as an eye ointment that is particularly effective in many cases of idiopathic conjunctivitis in cockatiels. Ineffective for many of the avian pathogens frequently found in pet birds. Immunosuppressive in many animal species. Potentiates secondary fungal infections. Few therapeutic uses in birds. Toucans, particularly young birds, are sensitive to tetracyclines and may develop bone deformities following its use. See Chapter 34 for chlamydia indications.

#### **THIABENDAZOLE - Equizole (MSD AgVet)**

Available as a suspension (4 mg/30 ml) for oral administration. Used for the treatment of ascarids and *Syngamus trachea*. May be toxic in ostriches, diving ducks and cranes.

#### **THIAMINE - Vitamin B<sub>1</sub> (Butler; Phoenix; Vedco)**

Available as an injectable solution (200 or 500 mg/ml) for IM administration. Also available as a powder to be added to the feed of birds consuming fish that contain thiaminase.

#### **TICARCILLIN - Ticar (SmithKline Beecham)**

Available as an injectable solution (30 to 400 mg/ml depending on reconstitution) for IM or IV administration. Lower concentration is used for IV injection. Good activity against many *Pseudomonas* spp. Wide therapeutic index. Good synergistic effect with aminoglycosides for use in difficult-to-treat gram-negative bacteria. Can be reconstituted and held in refrigerator for 72 hours or mixed into individual doses and frozen. IM infection in conjunction with tobramycin was associated with hepatotoxicity in a Rose-breasted Cockatoo (see Chapter 17).

#### **TOBRAMYCIN - Nebcin (Lilly)**

Available as an injectable solution (40 mg/ml) for IM administration. Low therapeutic index. Reserved for use in life-threatening infections caused by pseudomonas that are resistant to combina-



tion therapy with other aminoglycosides and synthetic penicillins (see Chapter 17).

**TRIMETHOPRIM/SULFADIAZINE - Bactrim (Roche); Tribissen (Coopers)**

Available as a suspension (8 mg trimethoprim and 40 mg sulfamethoxazole/ml, Bactrim) for oral administration or as an injectable solution (Tribissen 48%; 80 mg trimethoprim and 400 mg sulfadiazine/ml) for IV administration or (Tribissen 24%; 40 mg trimethoprim and 200 mg sulfadiazine/ml) for IM or SC administration.

Oral suspension is one of the drugs of choice for treating gastrointestinal and respiratory infections in hand-feeding babies that do not have gastrointestinal stasis. May be effective in treating some cases of coccidiosis, particularly in toucans and mynahs.

Regurgitation, facial flushing and GI stasis have been noted in some birds (particularly macaws). Should not be used in patients with liver disease or bone marrow suppression (see Chapter 17).

**TSH - Dermathycin (Jen-Sal Laboratories)**

Used for thyroid stimulation testing.

**TYLOSIN - (Butler; Elanco)**

Available as an injectable solution (50 mg/ml or 200 mg/ml Tylan 200) for IM injection. Also available as a soluble powder (Elanco) for oral administration. Soluble powder can be mixed with sterile water (mixed 1:10) and used as an eye spray. Tylosin 200 mg/ml injectable solution can be mixed with DMSO (1 ml tylosin/50 ml DMSO) and used for nebulization. May be effective in the initial therapy of upper respiratory infections, particularly when nebulized. May be useful as an eye spray for the frequent treatment of conjunctivitis (particularly if mycoplasma is suspected). Tissue concentrations of tylosin may last for three hours following an hour of nebulization in quail and pigeons. High therapeutic index (see Chapter 17).

**VERCURONIUM BROMIDE**

Available as an injectable solution. Used topically to induce mydriasis. Suggested dose in raptors is 4 mg/ml every 5 min x 3 (see Chapter 26).

**VITAMINS, MULTIPLE - Injacom (Hoffman LaRoche)**

A mixture of vitamins A, D, and E, in an aqueous emulsion for IM or SC injection. Indicated in the treatment of Vitamin A and D<sub>3</sub> deficiencies, bone healing, egg binding and other reproductive or debilitating diseases. Should be used with caution in species that appear to have problems with Vitamin D<sub>3</sub> and calcium metabolism including macaws and African Grey Parrots. Must be used with caution in birds on formulated (heavily fortified) diets.

**VITAMINS, MULTIPLE - Injacom + B (Hoffman LaRoche)**

A mixture of vitamins A, D<sub>3</sub>, E, and B available in an aqueous emulsion for IM or SC injection. Indicated in the treatment of Vitamin A and D<sub>3</sub> deficiencies, bone healing, egg binding and other reproductive or debilitating diseases. Should be used with caution in species that appear to have problems with Vitamin D<sub>3</sub> and calcium metabolism including macaws and African Grey Parrots. Must be used with caution in birds on formulated (heavily fortified) diets.

**VITAMIN B COMPLEX - (Butler; Lextron; Vedco)**

Available in injectable solution for IM administration. Indicated for cases of neuromuscular disease, debilitating illness of the liver, kidney and gastrointestinal tract, and anemia. Overdosing may cause an anaphylactic reaction.

**VITAMIN E AND SELENIUM - Seletoc (Schering)**

Available as an injectable solution (1 mg Se and 50 mg vit E/ml) for IM or SC administration. Used in cases of neuromuscular disease. May be helpful in some cockatiels with jaw, eyelid and tongue paralysis. Can be given before or shortly after stressful event (capture) to reduce the chances of capture myopathy in long-legged birds. Selenium can cause toxicity if administered in high doses.

**VITAMIN K<sub>1</sub> - (Butler; Phoenix; Vet-A-Mix; Vedco)**

Available as injectable solution (10 mg/ml) for IM or SC administration or as tablets (25 mg) for oral administration. May be effective in cases of severe and pathologic hemorrhage. Can also be used to offset the effects of drugs that cause hemorrhage (eg, sulfas, amprolium).

**YEAST CELL DERIVATIVES - Preparation H (Whitehall Laboratories)**

Stimulate epithelialization. Used to treat wounds that are not healing. Can be used in the eye.

**TABLE 18.1 Conversions and Formulas for Drug Dose Calculations**

---

$\text{mg/g} \times \text{wt}$ divided by $\text{mg/ml} = \text{dose in ml}$
$(\text{wt in g}/1000) \times (\text{mg/kg})$ divided by $\text{mg/ml} = \text{dose in ml}$
1 ppm (dry weight) = 1 mg/kg
1 ppm (liquid) = 100 µg/dl
1 oz (dry) = 28.35 g
1 oz (liquid) = 29.5 ml
1 lb = 454 g
1% = 10 mg/ml
16 oz = 480 ml = 1 pint
1 cup = 8 oz = 237 ml
1 TBS = 15 ml
1 tsp = 5 cc
1 oz = 30 ml
1 ml = 1 cc

---

TABLE 18.2 Therapeutic Agents

DRUG	SPECIES	ROUTE	DOSAGE
Acetylsalicylic acid	Most	Oral	1 tablet in 250 mls of water; see formulary
ACTH	Pigeon	IM	50-125 µg
Activated charcoal	Most	Oral	2-8 g/kg as needed
Acyclovir	Most	Oral	80 mg/kg TID, up to 240 mg/kg of food
Allopurinol	Budgerigar	Oral (water)	See formulary
Aloe vera	Most	Topical	0.5 ounce/pint of water, use as spray
Amikacin*	Most	IV, IM, SC	10-15 mg/kg BID or TID
Aminopentamide Hydrogen Sulfate	Most	IM, SC	0.05 mg/kg q 12 hrs - 5 doses maximum
Aminolid	Raptors	IM	0.25-0.75 mg/kg, repeat 10-14 days
Amitriptyline HCl	Psittaciformes	Oral	1-2 mg/kg SID to BID
Ammonium solution	Most	Topical	See formulary
Amoxicillin	Most Pigeons Pigeons	Oral IM Oral	150-175 mg/kg SID or BID 150 mg/kg every 4 hrs 150 mg/kg QID
Amphotericin B	Raptors, Psittaciformes Raptors, Psittaciformes Raptors, Psittaciformes Most	IV Intratracheal Nebulize Topical	1.5 mg/kg BID to TID 1 mg/kg BID to TID 1 mg/ml saline (15 min BID) BID
Ampicillin*	Pigeons Pigeons Psittaciformes Psittaciformes Galliformes	IM Oral Oral IM Oral (drinking water)	150 mg/kg every 2 hrs 150 mg/kg QID 100-200 mg/kg TID to QID 100 mg/kg every 4 hrs 250 mg/8 ounces of water
Amprolium	Most	Water	2-4 ml/gallon for 5 days
Ascorbic acid (vitamin C)	Most	IM	20-40 mg/kg, daily to weekly
Atropine	Most	IM, SC	0.01-0.02 mg/kg as needed; see formulary
Avipro	Psittaciformes	Oral	4 g/200 mls of water
Azithromycin	Most	Oral	See formulary
Butorphanol tartrate	Psittaciformes	IV, oral	See formulary; 3-4 mg/kg
Calcium gluconate	Most Most Most Most	Water IM, SC IV Feed	1 ml/30 mls of water to effect 5-10 mg/kg, BID as needed 50-100 mg/kg, slowly to effect 1/8 tsp/kg feed, as needed
Calcium disodium versenate (CaEDTA)	Most	IM	20-40 mg/kg BID-TID
Caprillic acid	Most	Oral	1/4 capsule/300 g
Carbaryl	Most	Topical	See formulary
Carnidazole	Pigeons	Oral	Adults 200 mg/kg once Newly weaned 100 mg/kg once
Cefotaxime*	Most	IM, IV	75-100 mg/kg TID, QID; see text
Cefoxitin*	Most	IM, IV	See formulary
Ceftriaxone	Most	IM, IV	75-100 mg/kg TID, QID or every 4 hrs; see formulary
Cephalexin*	Most Pigeons, Cranes, Emus	Oral Oral	35-50 mg/kg QID to every 4 hrs 100 mg/kg QID to every 4 hrs
Cephalothin*	Most	IM, IV	100 mg/kg QID
Cephradine	Most	Oral	See cephalixin
Chloramphenicol*	Pigeons  Most Psittaciformes Galliformes	Oral (with grit) Oral (without grit) IM IV, IM Oral	95 mg/kg QID 30 mg/kg QID 80 mg/kg BID or TID 50 mg/kg TID or QID 50 mg/kg TID or QID
Chlorhexidine	Most Most Finches	Oral Topical Oral	10-30 ml/gallon 0.5% as wound lavage Very sensitive, toxic, may not drink
Chlorine	Most	Oral, topical	See formulary

## CHAPTER 18 FORMULARY

DRUG	SPECIES	ROUTE	DOSAGE
Chloroquine phosphate	Penguin	Oral	10 mg/kg once, then 5 mg/kg at 6, 18, 24 hrs
Chlortetracycline	Psittaciformes	Oral	See formulary and Chapter 34
Chlorsulon	Psittaciformes	Oral	20 mg/kg, 3 times, two weeks apart
Cimetidine	Psittaciformes	Oral	300 mg/5cc
Ciprofloxacin	Most (see enrofloxacin)	Oral	20-40 mg/kg BID
Clazuril	Pigeons	Oral	1 tablet/pigeon
Clindamycin*	Pigeons	Oral	100 mg/kg SID
Clomipramine HCl	Psittaciformes	Oral	0.5-1 mg/kg SID or BID
Colchicine	Psittaciformes	Oral	0.04 mg/kg/day, BID
Copper Sulfate	Most	Topical	As needed
Cyanocobalamin (vitamin B <sub>12</sub> )	Most	IM	250-500 µg/kg once/week
Dexamethasone	Most Raptors	IM, IV IM, IV	2 mg/kg SID or BID 1 mg/kg
Dextrose - 50%	Most	IV	50-100 mg/kg, slowly
Diazepam	Most Psittaciformes	IM, IV Oral	0.5-1 mg/kg BID, TID 2.5-4 mg/kg as needed
Diethylstilbestrol	Most	IM Oral	0.1-0.3 ml/kg 1 drop/30 mls of water
Digoxin	Conures, parakeets	Oral	0.02-0.05 mg/kg SID
Dimercaprol (BAL)	Most	Oral	25-35 mg/kg BID 5 days per week for 3-5 weeks
Dimethylsulfoxide	Most	Topical	1 ml/kg, BID as needed for swelling
Dimetridazole	Budgerigars  Most Lories, mynahs	Oral (gavage)  Oral (drinking water) Oral (drinking water)	Stock solution: 1 tsp/pint of water Dose: 0.5 ml/30 g repeat at 12 and 24 hrs 1 tsp/gallon 0.5 tsp/gallon
Dinoprost tromethamine	Most	Intracloacal, IM	0.02-0.1 mg/kg once
Diphenhydramine HCl	Psittaciformes	Oral	0.5 tsp/8 ozs water or 2-4 mg/kg BID
Doxapram	Most	IM, IV	5-10 mg/kg once
Doxepin HCl	Psittaciformes	Oral	0.5-1 mg/kg BID
Doxycycline*	Pigeons Pigeons  Pigeons  Cockatiels, Amazons, African Greys, cockatoos Macaws Other Psittaciformes	IM Oral (with grit)  Oral (without grit)  Oral Oral IM (Vibravenös) IV	10 mg/kg QID 7.5 mg/kg QID 25 mg/kg BID 150 mg/kg SID 3 mg/kg QID 7.5 mg/kg BID 25 mg/kg SID 40-50 mg/kg SID or BID 25 mg/kg SID or BID 75-100 mg/kg every 5-7 days 25-50 mg/kg; see formulary
D-penicillamine	Most	Oral	52 mg/kg BID
D-tubocurarine	Raptors	Ophthalmic	Every 5 min x 3
Echinacea	Psittaciformes	Oral Water	2.5 drops/kg 5 drops/cup of drinking water
EDTA-TRIS	Most	See formulary	See formulary
Enilconazole	See formulary		
Enrofloxacin*	Greys, Amazons Cockatoos Pigeons Psittaciformes	IM, Oral IM, Oral, SC Oral Oral (food)	7.5-15 mg/kg SID to BID 5 mg/kg BID 15 mg/kg BID 250-1000 ppm; see Chapter 34
Epinephrine	Most	IV, IO, IT, IC	0.1 mg/kg
Ergonovine maleate	Most	IM	0.06 mg/kg, once
Erythromycin	Most Most Psittaciformes	Oral (Powder) Nebulize injectable Oral (Suspension)	500 mg/gallon of drinking water 1 ml/10 ml saline 15 min TID 10-20 mg/kg BID
Ethambutol	Most	Oral	15 mg/kg BID

table continued on next page

DRUG	SPECIES	ROUTE	DOSAGE
Fenbendazole	Anseriformes Most	Oral Oral	5-15 mg/kg daily for 5 days For ascarids 20-50 mg/kg - repeat 10 days For flukes 20-50 mg/kg SID for 3 days For capillaria 20-50 mg/kg SID for 5 days
Ferric subsulfate	Most	Topical	As needed for hemorrhage
Fluconazole	Most	Oral	2-5 mg/kg SID, 7 days
Flucytosine	Most Raptors Psittaciformes, mynahs	Oral (gavage) Oral (gavage) Oral (feed)	20-50 mg/kg BID for 21 days 20-30 mg/kg QID 50-250 mg/kg of feed
Flunixin-meglumine	Most	IM	1-10 mg/kg
Furosemide	Most (see text)	IM, SC	0.15-2 mg/kg, SID-BID
Gentamicin*	Most	Ophthalmic solution intra-nasally	Several drops/nostril TID
Gentian Violet	Psittaciformes	Oral (feed), topical	0.5-1.0 g/kg of feed
Haloperidol	Psittaciformes	IM Oral	1-2 mg/kg every 2-3 weeks 0.2 mg/kg BID for birds < 1 kg 0.15 mg/kg BID for birds > 1 kg; see formulary
Haloxon	Pigeons	See formulary	See formulary
Immunoregulin	Most	See formulary	See formulary
Iodine	Budgerigars	Water, IM	See formulary
Iprnidazole	Most Psittaciformes	Water Oral	500 mg/gallon for 7-21 days 0.25 tsp/gallon
Iron dextran	Most	IM	10 mg/kg, repeat in 7-10 days if needed
Isoniazid	Most	Oral	15 mg/kg BID
Itraconazole	Penguins, waterfowl Psittaciformes	Oral	5-10 mg/kg BID
Ivermectin	Most	IM, oral, topical	200 µg/kg, repeat 10-14 days
Ketoconazole*	Most Most Most	Oral (gavage) Oral (water) Oral (feed)	20-30 mg/kg BID for 21 days 200 mg/l 10-20 mg/kg
Lactated Ringer's solution	All	IV	See formulary
Lactobacillus	Psittaciformes	Oral	1 pinch/day/bird 1 tsp/ quart of hand-feeding formula
Lactulose	Most	Oral	0.3 ml/kg
Levamisole	Anseriformes Australian parakeets Most Most	Oral (gavage) Oral (gavage) Oral (drinking water) IM, SC	20-50 mg/kg 15 mg/kg, repeat 10 days 5-15 ml/gallon, 1 to 3 days 5 mg/kg, repeat 10-14 days
Levothyroxine	Most	Oral	20 mg/kg SID to BID; see formulary
Lincomycin	Budgerigar Amazon parrots Raptors Most	Oral Oral Oral Water	1 drop BID 75 mg/kg BID 100 mg/kg SID 1/8 - 1/4 tsp/pint of water
Leuprolide	Psittaciformes	IM	See formulary
Lorelco	Psittaciformes	Oral	0.25 tsp/day for 2-4 months
Mannitol	Most	IV	0.5 mg/kg slowly SID
Mebendazole	Anseriformes Raptors, Psittaciformes	Oral Oral	5-15 mg/kg daily for 2 days 25 mg/kg BID for 5 days
Medroxyprogesterone acetate	Pigeons Most	Oral (feed) IM, SC	0.1% of ration, continuous 5-25 mg/kg, every 4 to 6 weeks; see formulary
Methylprednisolone acetate	Most	IM	0.5-1 mg/kg
Metoclopramide	Most	IM, IV, oral	0.5 mg/kg
Metronidazole	Psittaciformes	Oral IM	10-30 mg/kg, BID for 10 days 10 mg/kg SID for 2 days
Miconazole	Psittaciformes	IV, topical	20 mg/kg TID
Mineral oil	Most	Oral	6-10 ml/kg, repeated as needed

## CHAPTER 18 FORMULARY

DRUG	SPECIES	ROUTE	DOSAGE
Monensin	Galliformes, cranes	Oral (feed)	90 g/ton of feed
Morphine	Galliformes	IM, SC	2.5-3 mg/kg
Naloxone	Most	IV	2 mg 14-21 hours
Natamycin	Most	Ophthalmic	1 drop QID; after 14-21 days, taper off
Neomycin	Most	Water	1-8 drops/oz water; 5 g/gallon
Neomycin ointment	All	Topical	BID to QID as needed
Niclosamide	Most Finches, see text	Gavage Gavage	50 mg/kg, repeat 10-14 days 500 mg/kg, weekly for 4 weeks
Nitrofurazone	Most Psittaciformes Lories, Lorikeets, Passeriformes	Water Water	1 tsp/gallon of water 0.5 tsp/gallon water
Nortriptyline HCl	Psittaciformes	Oral	1 ml/4 oz drinking water
Nystatin	Most Most	Oral (gavage) Oral (feed)	1 ml/300 g BID to TID, 7 days
Oxytetracycline*	Pheasants Owls Psittaciformes Cockatoos	IM IM IM IM, SC	43 mg/kg, every 24 hrs 16 mg/kg, every 24 hrs 58 mg/kg, every 24 hrs 50-100 mg/kg, every 2-3 days
Oxytocin	Most	IM	0.01-0.1 ml, once
2-PAM	Most	IM	10-30 mg/kg SID
Pancreatic enzymes	Most	Oral (feed)	1/8 tsp/kg; see formulary
Phenobarbital	Most	Oral	1-5 mg/kg BID
Phenylbutazone	Psittaciformes Raptors	Oral	3.5-7 mg/kg BID to TID 20 mg/kg TID
Piperacillin*	Most Amazon parrots	IM, IV IM	100-200 mg/kg TID to QID 75-100 mg/kg QID to every 4 hrs
Piperazine	Galliformes Anseriformes	Oral	100-500 mg/kg; repeat 10-14 days 45-200 mg/kg
Potassium chloride	Most	IV	0.1-0.3 mg/kg
Praziquantel	Most	Oral IM	10-20 mg/kg; repeat 10-14 days 9 mg/kg (flukes: SID for 3 days then oral for 11 days; tapeworms: once, then repeat in 10 days)
Prednisolone	Most	IM or IV	0.5-1 mg/kg once (anti-inflammatory) 2-4 mg/kg (immunosuppressive)
Primaquine	Penguins	Oral	0.03 mg/kg, SID for 3 days
Procaine penicillin G	Galliformes	IM	100 mg/kg SID every 2 days
Propranolol	Most	IM IV	0.2 mg/kg 0.04 mg/kg slowly
Pyrantel pamoate	Most	Oral	4.5 mg/kg, repeat 10-14 days
Pyrethrins	Most	Topical	See formulary
Pyrimethamine	Most	Oral	0.5 mg/kg BID
Quinacrine	Psittaciformes	Oral	5-10 mg/kg, SID for 7 days
Rifampin	Most	Oral	10-20 mg/kg BID
Sodium bicarbonate	Most	IV	1-4 mEq/kg slowly over 15-30 minutes - do not exceed 4 mEq/kg
Sodium sulfate	Large birds	Oral	2 g/kg, slurry for 2 days; see Chapter 37
STA solution	Most	Topical	As needed
Stanozolol	Most	IM	25 to 50 mg/kg, 1 to 2 times weekly
Streptomycin	Most larger birds	IM	10-30 mg/kg BID or TID
Sucralfate	Psittaciformes	Oral	25 mg/kg TID
Sulfachlorpyridazine	Most	Water	0.25 - 1 tsp/gallon
Testosterone	Most	IM	8 mg/kg, weekly as needed
Tetracycline	Most	Water Oral	0.25 - 1 tsp/gallon 200-250 mg/kg BID

table continued on next page

DRUG	SPECIES	ROUTE	DOSAGE
Thiabendazole	Most	Oral	For ascarids; 250-500 mg/kg, repeat 10-14 days For <i>Syngamus</i> ; 100 mg/kg, SID for 7 to 10 days
Thiamine	Raptors, penguins, cranes	Oral	1-2 mg/kg, daily
Ticarcillin	Most	IM, IV	150-200 mg/kg TID or QID
Tobramycin	Pheasants, cranes, Psittaciformes	IM	2.5-5 mg/kg BID
Trimethoprim and Sulfamethoxazole*	Psittaciformes Toucans, mynahs Psittaciformes	Oral Oral (for coccidia) IM	16-24 mg/kg BID or TID 25 mg/kg SID 8 mg/kg BID
TSH	Psittaciformes	IM	1-2 IU/kg; see Chapter 23
Tylosin*	Most Quail, pigeons, emus Cranes Most Cockatiels, Psittaciformes Most	IM IM IM Water Eye spray Nebulization	10-40 mg/kg TID or QID 15-25 mg/kg TID or QID 15 mg/kg TID or QID 2 tsp/gallon BID or TID (see formulary) One hour BID (see formulary)
Vitamin A, D <sub>3</sub> , E (Injacom 100)	Most	IM	0.1-0.2 ml/300 g, weekly as needed
Vitamin B complex	Most	IM	1-3 mg thiamine/kg, weekly
Vitamin B complex (Methiscal)	Most	Oral	1-2 g/kg food, daily
Vitamin E/Selenium (Seletoc)	Most	IM	0.05 to 0.1 mg/kg, every 14 days
Vitamin K <sub>1</sub>	Most	IM	0.2-2.5 mg/kg, as needed
Yeast cell derivatives	Most	Topical	See formulary

\* Pharmacological data are available to support doses in avian species other than poultry.

Although the authors and editors have made every effort to ensure the accuracy of the information presented herein (particularly drug doses), it is the responsibility of the clinician to critically evaluate the contents, to stay informed of pharmacokinetic information and to observe recommendations provided in the manufacturer's insert.

#### Brand Names and Nonproprietary Names (brand names in italics)

<b>Acetylcysteine</b> - <i>Mucomyst</i>	<i>Bactrim</i> - Trimethoprim/Sulfadiazine	<b>Chlortetracycline</b> - <i>CTC</i>
<b>Acetylsalicylic acid</b> - <i>Aspirin</i>	<i>BAL</i> - Dimercaprol	<b>Cimetidine</b> - <i>Tagamet</i>
<b>ACTH</b> - Adrenal Corticotrophic Hormone	<i>Banamine</i> - Flunixin Meglumine	<b>Clindamycin</b> - <i>Antirobe</i>
<b>Activated charcoal/kaolin</b> - <i>Toxiban</i>	<i>Baytril</i> - Enrofloxacin	<b>Cipro</b> - <b>Ciprofloxacin</b>
<b>Acyclovir</b> - <i>Zovirax</i>	<i>Benadryl</i> - Diphenhydramine HCl	<b>Ciprofloxacin</b> - <i>Cipro</i>
Adrenal Corticotrophic Hormone - ACTH	<b>Bismuth subsulicylate</b> - <i>Pepto-Bismol</i>	<b>Claforan</b> - <b>Cefotaxime</b>
<b>Allopurinol</b> - <i>Zyloprim</i>	<i>Biosol</i> - Neomycin	<b>Clazuril</b> - <i>Appertex</i>
<b>Ambi pen</b> - Procaine Pen. G and Pen. Benzathine	<i>Butazolidin</i> - Phenylbutazone	<b>Clinafam</b> - <b>Enilconazole</b>
<b>Amiglyde</b> - Amikacin Sulfate	<b>Butorphanol Tartrate</b> - <i>Torbutrol</i> , <i>Torbugesic</i>	<b>Clomipramine HCl</b> - <i>Anafranil</i>
<b>Amikacin Sulfate</b> - <i>Amiglyde</i>	<b>Calcium EDTA</b> - Calcium Disodium Versenate	<b>Coban</b> - <b>Monensin Sodium</b>
<b>Amitriptyline HCl</b> - <i>Elavil</i>	<b>Calcium Disodium Versenate</b> - Calcium EDTA	<b>Copper Sulfate</b> - <i>Caustic Powder</i>
<b>Ammonium Solution</b> - <i>Penetran</i>	<b>Caprillic Acid</b> - <i>Kaprycidin A</i>	<b>Corid</b> - <b>Amprolium</b>
<b>Amoxi-drops</b> - Amoxicillin	<i>Carafate</i> - <b>Sucralfate</b>	<b>CTC</b> - <b>Chlortetracycline</b>
<b>Amoxi-Inject</b> - Amoxicillin	<b>Carbaryl</b> - <i>Sevin</i>	<b>Cuprimine</b> - <b>D-Penicillamine</b>
<b>Amoxicillin</b> - <i>Amoxi-drops</i> , <i>Amoxi-Inject</i>	<b>Cardindazole</b> - <i>Spartix</i>	<i>Curatrem</i> - <b>Chlorsulon</b>
<b>Amphotericin B</b> - <i>Fungizone</i>	<i>Cardoxin</i> - <b>Digoxin</b>	<b>Cyanocobalamin</b> - <i>Vitamin B<sub>12</sub></i>
<b>Ampicillin</b> - <i>Polyflex</i>	<i>Cart Sol</i> - <b>Prednisolone Sodium Succinate</b>	<b>D-Penicillamine</b> - <i>Cuprimine</i>
<b>Amprolium</b> - <i>Corid</i>	<b>Caustic Powder</b> - <b>Copper Sulfate</b>	<b>Daraprim</b> - <b>Pyrimethamine</b>
<b>Anafranil</b> - <b>Clomipramine HCl</b>	<b>Cefotaxime</b> - <i>Claforan</i>	<b>Depo-Medrol</b> - <b>Methylprednisolone Acetate</b>
<b>Ancobon</b> - <b>Flucytosine</b>	<b>Cefoxitin</b> - <i>Mefoxitin</i>	<b>Demathycin</b> - <b>TSH</b>
<b>Antirobe</b> - <b>Clindamycin</b>	<b>Ceftriaxone</b> - <i>Rocephin</i>	<b>Dexamethasone</b> - <i>Azium</i>
<b>Appertex</b> - <b>Clazuril</b>	<b>Cephalexin</b> - <i>Keflex Pediatric Suspension</i>	<b>Diazepam</b> - <i>Valium</i>
<b>Aralen Phosphate</b> - <b>Chloroquine Phosphate</b>	<b>Cephalothin</b> - <i>Keflin</i>	<b>Diethylstilbestrol Diphosphate</b> - <i>Stilphostrol</i>
<b>Ascorbic Acid</b> - <i>Vitamin C</i>	<b>Cephrandine</b> - <i>Veloself</i>	<b>Diffucan</b> - <b>Fluconazole</b>
<b>Aspirin</b> - <b>Acetylsalicylic acid</b>	<b>Cephulac</b> - <b>Lactulose</b>	<b>Digoxin</b> - <i>Cardoxin</i> , <i>Lanoxin</i>
<b>Atabrine</b> - <b>Quinacrine HCl</b>	<b>Cheque</b> - <b>Mibolerone</b>	<b>Dihydrostreptomycin</b> - <i>Azimycin</i>
<b>Aventyl HCl</b> - <b>Nortriptyline HCl</b>	<b>Chlorhexidine</b> - <i>Nolvasan</i>	<b>Dimercaprol</b> - <i>BAL</i>
<b>Azimycin</b> - <b>Dihydrostreptomycin</b>	<b>Chlorine</b> - <i>Household Bleach</i>	<b>Dimethylsulfoxide</b> - <i>Domoso</i>
<b>Azithromycin</b> - <b>Zythromax</b>	<b>Chloroquine Phosphate</b> - <i>Aralen Phosphate</i>	<b>Dimetridazole</b> - <i>Emtryl</i>
<b>Azium</b> - <b>Dexamethasone</b>	<b>Chlorsulon</b> - <i>Curatrem</i>	<b>Dinoprost Tromethamine</b> - <i>Lutalyse</i>

## CHAPTER 18 FORMULARY

- Diphenhydramine HCl** - *Benadryl*  
*Domoso* - Dimethylsulfoxide  
*Donnatal* - Phenobarbital  
*Dopram* - Doxapram HCl  
**Doxapram HCl** - *Dopram*  
**Doxepin HCl** - *Sinequan*  
*Droncit* - Praziquantel  
**Echinacea** - *Echinacea angustifolia*  
*Echinacea angustifolia* - *Echinacea*  
**EDTA** - TRIS  
*Elavil* - Amitriptyline HCl  
*Emtryl* - Dimetridazole  
*Enhaptin* - Nitrothiazole  
**Enilconazole** - *Clinafam*  
**Enrofloxacin** - *Baytril*  
**Enzymes** - see pancreatic enzymes  
*Eqizole* - Thiabendazole  
*Eqvalen* - Ivermectin  
**Ergonovine Maleate** - *Ergotrate maleate*  
*Ergotrate maleate* - *Ergonovine Maleate*  
**Ethambutol** - *Myambutol*  
**Fenbendazole** - *Panacur*  
**Ferric Sulfate** - *Monsel's Solution*  
*Flagyl* - Metronidazole  
**Fluconazole** - *Diflucan*  
**Flucytosine** - *Ancobon*  
**Flunixin** - *Banamine*  
*Fungizone* - Amphotericin B  
*Furacin* - Nitrofurazone  
**Furosemide** - *Lasix*  
**Gentian Violet** - *GV-11*  
*GoLYTELY* - Sodium Sulfate  
*GV-11* - *Gentian Violet*  
*Halodol* - Haloperidol  
**Haloperidol** - *Halodol*  
**Hemicellulose** - *Psyllium*  
*Hi-Vegi-Lip* - Pancreatic Enzymes  
*Inderol* - Propranolol  
*Injacom + B* - Vitamins, Multiple  
**Iodine** - *Lugol's Solution*, *Renografin 76*  
**Ipronidazole** - *Ipropan*  
*Ipropan* - Ipronidazole  
**Itraconazole** - *Sporanox*  
**Ivermectin** - *Eqvalen*  
*Kaprycidin A* - Caprillic Acid  
*Kefflex Pediatric Suspension* - Cephalexin  
*Keflin* - Cephalothin  
**Ketoconazole** - *Nizoral*  
*L-Spartakon* - Levamisole  
**Lactobacillus** - *Probiocin*  
**Lactulose** - *Cephulac*  
*Lanoxin* - Digoxin  
*Lasix* - Furosemide  
*Leuprolide* - *Lupron*
- Levamisole** - *Levasole*, *Tramisol*, *L-Spartakon*  
*Levasole* - Levamisole  
**Levothyroxine Sodium** - *Thyroxine L*  
*Lincocin* - Lincomycin HCl  
**Lincomycin HCl** - *Lincocin*  
*Liquamycin LA200* - Oxytetracycline  
**Lorelco** - *Probacoll*  
*Lugol's Solution* - Iodine  
*Lupron* - Leuprolide  
*Lutalyse* - Dinoprost Tromethamine  
**Mebendazole** - *Telmintic*, *Telmin*  
*Mefoxitin* - Cefoxitin  
**Meglumine** - *Banamine*  
**Methylprednisolone Acetate** - *Depo-Medrol*  
**Metoclopramide HCl** - *Reglan*  
**Metronidazole** - *Flagyl*  
**Mibolerone** - *Cheque*  
**Miconazole** - *Monistat*  
**Monensin Sodium** - *Coban*  
*Monistat* - Miconazole  
*Monsel's Solution* - Ferric Sulfate  
*Mucomyst* - Acetylcysteine  
*Myambutol* - Ethambutol  
*Mycostatin* - Nystatin  
*Natacyn* - Natamycin  
**Natamycin** - *Natacyn*  
**Nebicin-Tobramycin**  
**Neomycin** - *Biosol*  
**Niclosamide** - *Nicloside*  
*Nicloside* - *Nidosamide*  
**Nitrofurazone** - *Furacin*  
**Nitrothiazole** - *Enhaptin*  
*Nizoral* - Ketoconazole  
*Nolvasan* - Chlorhexidine  
**Nortriptyline HCl** - *Aventyl HCl*  
**Nystatin** - *Mycostatin*  
**Oxfenbendazole** - *Synanthic*  
**Oxytetracycline** - *Liquamycin LA200*  
*Panacur* - Fenbendazole  
**Pancreatic Enzymes** - *Hi-Vegi-Lip*, *Viokase V*  
*Penetran* - Ammonium Solution  
*Pepto-Bismol* - Bismuth subsalicylate  
**Phenobarbital** - *Donnatal*  
**Phenylbutazone** - *Butazolidin*  
**Piperacillin** - *Pipracil*  
*Pipracil* - Piperacillin  
*Polyflex* - Ampicillin  
**Praziquantel** - *Droncit*  
**Prednisolone Sodium Succinate** - *Cart Sol*  
*Preparation H* - Yeast Cell Derivatives  
*Probacoll* - Lorelco  
*Probiocin* - Lactobacillus  
**Procaine Penicillin G and Penicillin Benzathine** - *Ambi pen*
- Propranolol** - *Inderol*  
*Psyllium* - Hemicellulose  
**Pyrantel Pamoate** - *Strongid T*  
**Pyrimethamine** - *Daraprim*  
**Quinacrine HCl** - *Atabrine*  
*Reglan* - Metoclopramide HCl  
*Renografin 76* - Iodine  
*Rifadin* - Rifampin  
*Rifampin* - *Rifadin*  
*Rocephin* - Ceftriaxone  
*Seletoc* - Vitamin E and Selenium  
*Sevin* - Carbaryl  
*Sinequan* - Doxepin HCl  
**Sodium Sulfate** - *GoLYTELY*  
*Spartix* - Cardindazole  
*Spectam* - Spectinomycin  
**Spectinomycin** - *Spectam*  
*Sporanox* - Itraconazole  
**Stanozolol** - *Winstrol V*  
*Stilphostrol* - Diethylstilbestrol Diphosphate  
*Strongid T* - Pyrantel Pamoate  
*Sucralfate* - *Carafate*  
**Sulfachlorpyridazine** - *Vestisulid*  
*Synanthic* - Oxfenbendazole  
*Tagamet* - Cimetidine  
*Telmin* - Mebendazole  
*Telmintic* - Mebendazole  
**Thiabendazole** - *Eqizole*  
**Thiamine** - *Vitamin B<sub>1</sub>*  
*Thyroxine L* - *Levothyroxine Sodium*  
*Ticar* - Ticarcillin  
*Ticarcillin* - *Ticar*  
**Tobramycin** - *Nebicin*  
*Torbutrol* - Butorphanol tartrate  
*Torbugesic* - Butorphanol tartrate  
*Toxiban* - Activated charcoal/kaolin  
*Tramisol* - Levamisole  
**Trimethoprim/Sulfadiazine** - *Bactrim*  
**TRIS** - EDTA  
**TSH** - *Dermathycin*  
*Valium* - Diazepam  
*Veloself* - Cephrandine  
*Vestisulid* - Sulfachlorpyridazine  
*Viokase V* - Pancreatic Enzymes  
*Vitamin B<sub>12</sub>* - Cyanocobalamin  
**Vitamin E and Selenium** - *Seletoc*  
**Vitamin C-Ascorbic Acid**  
**Vitamin B<sub>1</sub>** - *Thiamine*  
**Vitamins, Multiple** - *Injacom + B*  
*Winstrol V* - Stanozolol  
**Yeast Cell Derivatives** - *Preparation H*  
*Zovirax* - Acyclovir  
*Zyloprim* - Allopurinol  
**Zythromax** - Azithromycin

DRUG DOSING CHART

		Drug Concentration mg/ml or mg/unit												
		0.1	0.4	0.5	0.8	1.0	2.0	4.0	5.0	10.0	15.0	20.0	23.0	25.0
Drug Dose (mg/kg)	0.1			0.0002										
	0.2			0.0004		0.0002				0.00002				
	0.25					0.00025								
	0.5					0.0005			0.0001	0.00005				0.0002
	1.0						0.0005	0.00025	0.0002	0.0001	0.000066	0.00005		0.0004
	1.5								0.0003	0.00015				
	2.0					0.002	0.001	0.0005	0.0004	0.0002	0.00013	0.0001		
	3.0								0.00075	0.0006	0.0003			
	4.0	0.04	0.01	0.008	0.005	0.004	0.002	0.001	0.0008	0.0004	0.00027	0.00015		
	5.0								0.001			0.00025	0.00022	0.0002
	6.0								0.0012					
	8.0	0.08	0.02	0.016	0.01		0.004	0.002	0.0016	0.0008	0.00053		0.00035	
	10.0								0.002	0.001		0.0005	0.0004	
	15.0									0.0015	0.001		<b>0.00065</b>	0.0006
	20.0	0.2	0.05	0.04	0.025		0.01	0.005	0.004	0.002	0.00133	0.001		
	25.0								0.005	0.0025				0.001
	30.0								0.006	0.003		0.0015		
	35.0									0.0035				
	40.0								0.008	0.004		0.002		
	50.0								0.01	0.005		0.0025	0.0022	0.002
60.0														
75.0								0.015	0.0075		0.00375		0.003	
80.0														
100.0								0.02	0.01		0.005	0.0044	0.004	
150.0								0.03	0.015		0.0075		0.006	
175.0														
200.0									0.02		0.01		0.008	

The quantity of drug to administer for agents listed in Table 18.1 can be quickly and easily calculated by knowing the bird's weight in grams, the drug concentration and the drug dose. A bird's weight in grams is multiplied by the factor that corresponds to a drug's concentration and its respective dose. For example, the dose for enrofloxacin administered orally is 15 mg/kg. This drug is available in an injectable solution (23 mg/ml) that can be administered orally. The factor that corresponds to 23 mg/ml and 15 mg/kg is 0.00065. The drug dose for a 100 gram bird would be 0.00065 X 100 = 0.065 mls. The drug dose for a 600 gram bird would be 0.00065 X 600 = 0.39 mls.



## DRUG DOSING CHART

		Drug Concentration (mg/ml or mg/unit)										
		30.0	40.0	50.0	75.0	85.0	100.0	104.0	150.0	200.0	250.0	400.0
Drug Dose (mg/kg)	0.1											
	0.2											
	0.25											
	0.5			0.00001								
	1.0		0.000025	0.00002	0.000013		0.00001		0.000007	0.000005		
	1.5											
	2.0		0.00005	0.00004			0.00002	0.000019		0.00001		
	3.0											
	4.0							0.000038	0.000026			
	5.0	0.00017	0.00012	0.0001			0.00005			0.000025		
	6.0							0.000058				
	8.0			0.00016				0.000077	0.000053	0.00004		
	10.0		0.00025	0.0002	0.00013		0.0001			0.00005	0.00004	
	15.0	0.0005	0.00037	0.0003			0.00015		0.0001	0.000075	0.00006	
	20.0					0.00023		0.0002		0.0001	0.00008	0.00005
	25.0	0.00083	0.00063	0.0005	0.00033		0.00025		0.00017	0.00013	0.0001	0.00006
	30.0	0.001					0.0003			0.00015	0.00012	
	35.0					0.00035						
	40.0			0.0008			0.0004			0.0002	0.00016	0.0001
	50.0	0.0016	0.0013	0.001	0.00067		0.0005		0.00033	0.00025	0.0002	0.00013
60.0									0.0003			
75.0			0.0015	0.001		0.00075		0.0005	0.00038	0.0003		
80.0	0.0026	0.002	0.0016			0.0008						
100.0		0.0025	0.002	0.00133		0.001		0.00067	0.0005	0.0004	0.00025	
150.0	0.005	0.0375	0.003	0.002		0.0015		0.001	0.00075	0.0006	0.00037	
175.0			0.0035							0.0007	0.00044	
200.0	0.0067	0.005	0.004	0.0027		0.002		0.0013	0.001	0.0008	0.0005	

**TABLE 18.3 Distributors of Drugs Discussed in the Formulary**

<b>Agri Laboratories Inc.</b> 6221 North K Highway P.O. Box 3101 St. Joseph, MO 64505 Phone 816-233-9533 Order 800-542-8916	<b>Elanco Products Co.</b> Lilly Corporate Center Indianapolis, IN 46285 317-276-3000	<b>Merck Sharp &amp; Dohme</b> Division of Merck & Co., Inc. West Point, PA 19486 215-661-5000	<b>Sterwin Laboratories</b> P.O. Box 537 Millsboro, DE 19966-0537 Phone 302-934-0537 Order 800-633-0462
<b>A. H. Robins Co.</b> P.O. Box 26609 Richmond, VA 23261-6609 Phone 804-257-2000 Emergency 215-688-4400	<b>Eli Lilly</b> (see Dista)	<b>Miles Inc. Pharmaceutical Division</b> 400 Morgan Lane West Haven, CT 06516 Phone 800-468-0894 203-937-2000	<b>Stuart Pharmaceuticals</b> Wilmington, DE 19897 302-886-2231
<b>American Cyanamid Co.</b> One Cyanamid Plaza Wayne, NJ 07470 609-799-0400	<b>Elkin-Sinn Inc.</b> 2 Esterbrook Lane Cherry Hill, NJ 08003-4099 215-688-4400	<b>MSD-Agvet</b> P.O. Box 2000, WBF475 Rahway, NJ 07065-0912 201-855-3800	<b>Syntex Animal Health</b> 4800 Westown Parkway Building 3, Suite 200 West Des Moines, IA 50265 Phone 515-224-2400 Order 800-247-2210
<b>Apothecon</b> (see E. R. Squibb and Sons Inc.)	<b>E. R. Squibb and Sons Inc.</b> P.O. Box 4000 Princeton, NY 08543-4000 Phone 609-921-4000 Service 800-321-1335	<b>Parke Davis</b> 201 Tabor Road Morris Plain, NJ 07950 Phone 201-540-2000 Info 800-223-0432	<b>Tap Pharmaceuticals</b> 2355 Waukegan Road Deerfield, IL 60015 708-317-5700
<b>Astra Pharmaceutical Products</b> 50 Otis Street Westboro, MA 01581-4428 508-366-1100	<b>EVSCO Pharmaceuticals</b> P.O. Box 209 Buena, NJ 08310 609-691-2577	<b>Pfizer Labs Division</b> (see Roerig)	<b>3M Pharmaceuticals</b> (see Roerig)
<b>Baker Cummins Pharmaceuticals</b> 8800 NW 36th Street Miami, FL 33178-2404 800-347-4474	<b>Fort Dodge Laboratories</b> P.O. Box 518 Fort Dodge, IA 50501 515-955-4600	<b>Phoenix Pharmaceuticals Inc.</b> 3336 Pear Street P.O. Box 7, Fairleigh Station St. Joseph, MO 64506-0007 816-364-5777	<b>Trans Dermal Technologies</b> 1368 North Killian Drive Lake Park, FL 33403
<b>Becton Dickinson Microbiology Systems</b> P.O. Box 243 Cockeysville, MD 21030 800-638-8663	<b>Freeda Vitamins, Inc.</b> 36 East 41 Street New York, NY, 10017 800-777-3737	<b>Pioneer</b> 4601 Westown Parkway, STE 120 West Des Moines, IA 50265 800-247-5782	<b>United Vaccine, Inc.</b> 7819 Airport Road Middleton, WI 53562 608-836-8788
<b>Bio-Botanica, Inc.</b> 75 Commerce Drive Hanppauge, NY 11788 516-231-5522	<b>G. D. Searle Co.</b> Box 5110 Chicago, IL 60680 800-323-1603	<b>Pitman-Moore Inc.</b> 421 East Hawley Street Mundelein, IL 60060 Phone 708-949-3300 Order 800-525-9480	<b>Upjohn Company</b> 7000 Portage Road Kalamazoo, MI 49001 Phone 616-329-8244 616-385-6736
<b>Bio-Ceutic</b> 2621 North Belt Highway St. Joseph, MO 64506 Phone 816-233-2804 Order 800-325-9167	<b>Haver/Diamond Scientific</b> 12707 West 63rd Street P.O. Box 390 Shawnee, KS 66201	<b>Roerig Division</b> Pfizer Incorporated 235 East 42nd Street New York, NY 10017 Phone 212-573-2187 Service 800-533-4535	<b>Vedco Inc</b> Route 6, Box 35A St. Joseph, MO 64504 816-238-8840
<b>Burroughs Wellcome Co.</b> 3030 Cornwallis Road Research Triangle Park, NC 27709 Phone 800-722-9292 Emergency 800-443-6763	<b>Hoechst-Roussel Pharmaceuticals</b> Route 202-206 P.O. Box 2500 Somerville, NJ 00876-1258 Phone 800-445-4474 Service 800-451-4455	<b>Sandoz Pharmaceuticals Co.</b> Route 10 East Hanover, NJ 07936 201-503-7500	<b>Vet-A-Mix Animal Health</b> 604 West Thomas Avenue Shenandoah, IA 51601 Phone 712-246-4000 Order 800-831-0004
<b>Butler Company</b> 5000 Bradenton Avenue Publin, OH 43017-0753 614-761-9095	<b>Immunovet Inc.</b> 5910-G Breckenridge Pkwy. Tampa, FL 33610 813-621-9447	<b>Sanofi Animal Health</b> 7101 College Blvd Overland Park, KS 66210 Phone 913-451-3434 Order 800-255-6144	<b>Wallace Laboratories</b> Post Office Box 1001 Cranbury, NJ 08512 609-655-6000
<b>CIBA Pharmaceuticals</b> Div. of CIBA-GEIGY 581 Main Street Woodbridge, NJ 07095	<b>Janssen Pharmaceutical Inc.</b> 40 Klingsbridge Road Piscataway, NJ 08855-3998 Phone 201-524-9591 800-253-3682	<b>Schering-Plough Animal Health</b> P.O. Box 529 Kenilworth, NJ 07033 Phone 201-298-4000 Order 800-648-2118	<b>Warren Laboratories, Inc.</b> 12603 Executive Drive Stafford, TX 77477 713-240-2563
<b>Coopers Animal Health</b> 421 East Hawley Street Mundelein, IL 60060 Phone 708-949-3300 Order 800-525-9480	<b>Lannett Co.</b> 9000 State Road Philadelphia, PA 19136 215-333-9000	<b>SmithKline Beecham Animal Health</b> Whiteland Business Park 812 Springdale Drive Exton, PA 19341 215-363-3100	<b>Westwood-Squibb Pharmaceuticals</b> 100 Forest Avenue Buffalo, NY 14213 716-887-3400
<b>Dista</b> Division of Eli Lilly Lilly Research Laboratories Lilly Corporate Center Indianapolis, IN 46285 317-276-3714	<b>Lederle Laboratories</b> Pearl River, NY 10965 914-735-2815	<b>SmithKline Beecham Pharmaceuticals</b> One Franklin Plaza P.O. Box 7929 Philadelphia, PA 19101 215-751-4000	<b>Wildlife Laboratories</b> 1401 Duff Dr., Suite 600 Ft. Collins, CO 80524 303-484-6267
<b>Ecological Formulations</b> 106113 Shary Circle Concord, CA 94518 510-827-2636	<b>Lextron Inc</b> 630 "O" Street P.O. Box BB Greeley, CO 80632 303-353-2600	<b>Solvay Animal Health</b> 1201 Northland Drive Mendota Heights, MN 55120-1139 800-247-1830	<b>Wyeth-Ayerst Laboratories</b> Post Office Box 8299 Philadelphia, PA 19101 215-688-4400



## CHAPTERS

### 19 GASTROENTEROLOGY

J.T. Lumeij

### 20 HEPATOLOGY

J.T. Lumeij

### 21 NEPHROLOGY

J.T. Lumeij

### 22 PNEUMONOLOGY

Thomas N. Tully, Jr.  
Greg J. Harrison

### 23 ENDOCRINOLOGY

J.T. Lumeij

### 24 DERMATOLOGY

John E. Cooper  
Greg J. Harrison

### 25 ONCOLOGY

Kenneth S. Latimer

### 26 OPHTHALMOLOGY

David Williams

### 27 CARDIOLOGY

J.T. Lumeij  
Branson W. Ritchie

### 28 NEUROLOGY

R. Avery Bennett

### 29 THERIOGENOLOGY

Kim L. Joyner

### 30 NEONATOLOGY

Keven Flammer  
Susan L. Clubb

IV

## SECTION FOUR

# INTERNAL MEDICINE

IV



CHAPTER

# 19

## GASTRO- ENTEROLOGY

J. T. Lumeij

**D**iseases of the alimentary tract occur frequently in birds. Nonspecific clinical signs of gastrointestinal diseases may include anorexia, dysphagia, regurgitation, vomiting, constipation, diarrhea and tenesmus. With polyuria, the feces are normal and are surrounded by a large volume of clear fluid, while with diarrhea the feces are abnormal (see Color 8). The composition and quality of food and ingestion of bedding material, poisonous plants or chemicals may influence gastrointestinal signs. Weight loss and generalized weakness are characteristic of chronic diseases.

Fecal evaluation, hematology, blood chemistry, radiology and esophago-ingluvio-(gastro)scopy or laparoscopy are considered indispensable diagnostic tools in avian gastroenterology. Diseases that may affect the gastrointestinal system are listed in Table 19.1.

Cytologic examination of a fresh ingluvial aspirate is best for detecting flagellates (*Trichomonas* spp.). Examination of freshly voided feces is essential to detect *Histomonas meleagridis*, *Hexamita* spp., *Giardia intestinalis*, *Cochlosoma* sp. and *Chilomastix gallinarum*. Direct microscopic examination of feces may reveal helminthic ova and protozoal oocysts. Flotation and sedimentation techniques are best for detecting the low number of eggs or oocysts that occur in an early parasitic infection (see Chapter 36). Parasites infecting the liver, kidney, uterus and pancreas can deposit ova or oocysts that can be detected in the feces. Parasite ova originating from the respiratory tract may be coughed up, swallowed and found in the excrement.<sup>28,78</sup>

TABLE 19.1 Differential Diagnosis of Clinical Signs Associated with the Gastrointestinal Tract

**Regurgitation or Vomiting in Adults**

- Iatrogenic - apomorphine, levamisole, trimethoprim/sulfadiazine (macaws), ketoconazole, doxycycline suspension (particularly macaws and Amazons)
- Fear and excitement (vultures, pelicans, penguins)
- Courtship behavior (male psittacines)
- Crop milk feeding in pigeons
- Physiological cast formation - (raptors)
- Goiter (particularly budgerigars)
- Callus formation after coracoid fracture
- Neuropathic gastric dilatation (NGD)
- Food allergies
- Motion sickness
- Viral diseases - looping ill virus, Pacheco's disease virus, pigeon herpesvirus, avian polyomavirus, avian viral serositis (togavirus), poxvirus (diphtheritic form)
- Bacterial diseases - megabacterial infection, most Enterobacteriaceae, Pasteurella, Serratia
- Mycotic diseases - candidiasis, aspergillosis
- Helminths (oropharynx/esophagus) - capillariasis, ser-ratospicilliasis
- Protozoal disease - trichomoniasis of upper digestive tract, Plasmodium (penguins, gyrfalcon)
- Poisoning - alcohol, arsenic, copper, lead, organochlorine (lindane), organophosphate, carbamate, organomercurial, rotenone, phosphorus, polytetrafluoroethylene (Teflon), sodium chloride, thallium, zinc
- Plants - Yew (*Taxus baccata*), Philodendron spp., Rhododendron spp. (azalea), Solanaceae (green berries and roots)
- Obstructed alimentary tract - stricture, foreign body, neoplasia, intussusception, volvulus, hernia, stenosis, parasites, impaction, paralytic ileus
- Organopathy - renal disease, hepatopathy, pancreatitis, peritonitis, egg binding, electrolyte disturbances

**Regurgitation in Neonatal Psittacines (Sour Crop)**

- Overgrowth of bacteria or yeast (improper food storage)
- Overheated formula
- Underheated formula
- Crop burns
- Foreign body ingestion (eg, substrates)
- Improper formula consistency
- Over-stretching the crop
- Aerophagia
- Fear and excitement
- Infectious agents
  - Avian polyomavirus
  - Avian viral serositis
  - Candida spp.
  - Gas-producing bacteria

**Diarrhea<sup>28,78</sup>**

- Use of antibiotics
- Dietary changes
- Bowel obstruction
- Toxins
- Obstruction
- Foreign bodies
- Organopathy - hepatopathy, renal disease, pancreatitis
- Viral diseases - Newcastle disease virus, paramyxovirus type 3, influenza, adenovirus, astrovirus, calicivirus, coronavirus, enterovirus, Pacheco's disease virus, pigeon herpesvirus, duck virus enteritis, herpesvirus (Ciconiidae), herpesvirus (gruiformes), Marek's disease virus, orthoreovirus, parvovirus, reovirus, rotavirus, togavirus-like agent, retrovirus (leukosis/sarcoma group)
- Bacterial diseases - borreliosis, spirochaetosis, most Enterobacteriaceae, Campylobacter spp., Streptococcus spp., Erysipelothrix rhusiopathiae, Listeria monocytogenes, megabacteria, Clostridium spp., Mycobacterium avium, Yersinia pseudotuberculosis, Aeromonas hydrophila, Pasteurella multocida, Pasteurella anatipestifer (new duck disease)
- Chlamydia
- Mycoplasma
- Candida albicans
- Protozoa - Histomonas meleagridis, Hexamita spp., Giardia spp., Cochlosoma sp., Chilomastix gallinarum, coccidiosis
- Helminths - nematodes, trematodes, cestodes

**Hematochezia**

- Cloacal papillomas
- Egg laying
- Ulcers
- Hepatitis
- Infectious enteritis - bacterial, viral, parasitic
- Aflatoxicosis
- Coagulopathies
- Heavy metal intoxication
- Foreign bodies
- Cloacal neoplasias

**Passing Undigested Food**

- Gastric foreign body
- Gastrointestinal dysfunction
- Neuropathic gastric dilatation
- Enteritis - bacterial, viral, parasitic
- Pancreatitis
- Use of antibiotics
- Food allergies
- Hepatitis

**Tenesmus**

- Egg-laying problems (binding)
- Abdominal mass
- Goose venereal disease
- Cloacal pathology
- Prolapse
- Papilloma
- Stricture
- Cloacolith
- Cloacitis
- Intestinal obstruction (eg, constipation)
- Uterine prolapse
- Rectal prolapse
- Enteritis - diarrhea
- Bacteria
- Parasites
- Fungi
- Viruses
- Toxins
- Decreased bacteria (eg, indiscriminate antibiotic use)

Bacteriologic cultures of the gastrointestinal tract must be interpreted with respect to the normal flora.<sup>78</sup> Gram-positive microorganisms including lactobacilli, staphylococci, streptococci and *Bacillus* spp. are common in the oropharynx of healthy psittacine birds. *Mycoplasma* spp. and *Aspergillus* spp. are sometimes encountered.<sup>168,176</sup> Enterobacteriaceae are normally not found in the feces of Psittaciformes and Passeriformes, where gram-positive organisms, especially *Corynebacterium* sp. and *Bacillus* sp., predominate.<sup>17</sup> The isolation of a large number of Enterobacteriaceae in pure culture from Psittaciformes or Passeriformes is suggestive of a primary or secondary infection. *E. coli* and other Enterobacteriaceae are normal inhabitants of the gastrointestinal tract in Galliformes, Columbiformes, Falconiformes, Strigiformes and Corvidae.<sup>140</sup>

Routine bacteriologic examination of the feces may fail to reveal some important microbes that can cause diarrhea, including mycobacteria, campylobacter and chlamydia. A technique for identifying mycobacteria is described in Table 19.2. Detection of campylobacter can be augmented by the use of Hemacolor; the bacteria appear S-shaped or in gull-wing form. Chlamydia is best detected using an antigen capture system.<sup>21,102</sup>

**TABLE 19.2** Detection of Acid-fast Bacteria in Feces<sup>78</sup>

- Combine 4 grams of feces and 12 ml of 15% sputofluol (Merck)
- Gently mix for 30 minutes
- Centrifuge for 5 minutes 10,000 rpm
- Make smear of sediment
- Stain with Ziehl-Neelsen

## The Beak

### Anatomy and Physiology

The avian beak is a continuously growing, dynamic structure composed of bone, vascular layers, keratin, dermis, joints and a germinative layer. In psittacine birds, the upper and lower jaws are connected to the skull via a kinetic joint. The keratinized sheath covering the upper and lower beaks is called rhamphotheca and can be divided into the rhinotheca (maxillary keratin) and the gnathotheca (mandibular keratin).

The median dorsal border of the rhinotheca is called the culmen, and the median ventral border of the gnathotheca is called the gonys. The cutting edges of the rhamphotheca are called the tomia. The rhinotheca is perforated by the paired nostrils. Aviculturists classify caged birds into hardbills (eg, most psittacine birds) and softbills (eg, mynahs, starlings).

In ducks and parrots, the tip of the bill contains well developed mechanoreceptor nerve endings. The beak is used for prehension, for the physical preparation of food, and in some species such as parrots, for locomotion.<sup>130</sup>


The rate of keratin replacement is strongly dependent on the use of the beak. In large parrots, the complete rhinotheca is replaced in about six months, while in toucans the rhinotheca grows approximately 0.5 cm over a two-year period. The rate of growth of the gnathotheca is about two to three times faster than that of the rhinotheca.<sup>38</sup> Shedding and replacement of the rhinotheca has been described in capercaillie (annually)<sup>4</sup> and Suriname finches.

### Beak Diseases

A variety of congenital and acquired defects, including scissor beak and mandibular prognathism, can interfere with normal beak function. In gallinaceous birds, a deformed upper mandible has been associated with embryonic deficiencies of folic acid, biotin or pantothenic acid. Crusty, scab-like lesions in the corners of the mouth are considered a definite sign of biotin or pantothenic acid deficiency in these birds.<sup>5</sup> Examples of acquired lesions that can lead to malformations or necrosis of the beak include punctures, lacerations, splits and avulsions. Traumatic fractures, especially of the mandible, occur frequently in psittacine birds that get caught in hooks suspended from the ceiling of their enclosures or as a result of fighting.

Any bacterial, mycotic, viral or parasitic pathogen that damages the germinative layers of the beak can cause developmental abnormalities.<sup>108</sup> Examples include *Candida albicans*, psittacine beak and feather disease virus, *Knemidokoptes* spp. in Psittaciformes or *Oxyspirura* spp. in cranes. Rhinothecal overgrowth in psittacines, especially budgerigars, has been associated with liver disease (Figure 19.1).<sup>133</sup> The rhinotheca may overgrow in hardbills maintained in an indoor environment and provided soft foods. "Rubber bill," caused by insufficient mineralization of the upper beak, has been described with





**FIG 19.1** A two-year-old budgerigar, maintained on an all-seed diet in a strictly indoor environment, was presented for a beak trim. The bird was obese and was passing bile-tinged urates. This clinical presentation is suggestive of a hepatopathy.



**FIG 19.2** An eight-year-old Umbrella Cockatoo was presented with a nine-month history of progressive sneezing and nasal discharge. The feathers around the beak were moist from a serous nasal discharge. The rhinotheca had a deep groove that extended from the nostril to the rostral commissure of the upper beak (arrows). The extent of this defect suggests that the germinative layer of the rhinotheca had been involved in a disease process for over six months. This bird belonged to a heavy smoker. A mixed population of gram-positive and gram-negative bacteria were cultured from a sinus aspirate. The bird responded to nasal flushing, systemic antibiotics, frequent exposure to fresh air and sunlight and being removed from a smoke-filled environment.

vitamin D and calcium deficiencies. Necrotic lesions at the commissure of the beak have been described with trichotecene mycotoxicosis, avian poxvirus and trichomoniasis (cockatiels).<sup>137</sup>

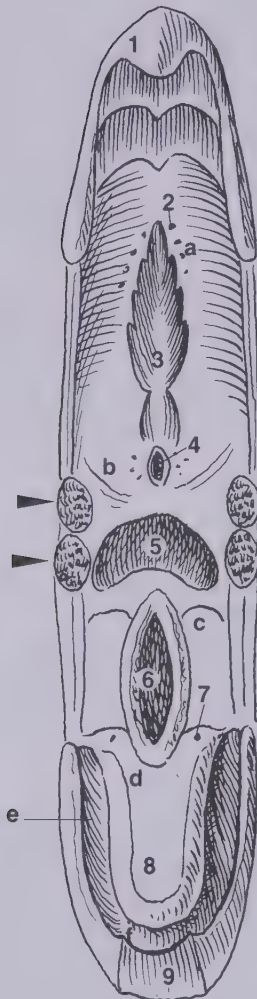
Beak deformation consisting of loss of normal epithelium on the surface of the beak, upturning of the tomia and shortening of the upper beak have been reported secondary to photosensitization in ducks following ingestion of seeds from *Ammi visnaga*, *A. majus* and the plant or seeds from *Cynopterus watsonii* and *C. longipes*.<sup>152</sup> Photosensitization has been suspected in many cases of vesicular dermatitis, but the precise etiologic agents are frequently undetermined.

Chronic rhinitis may lead to permanent defects in the adjoining germinative layer of the rhinotheca (Figure 19.2). Dysphagia, which may be recognized clinically as an accumulation of food under the tongue, can be an indication of rhamphothecal dysfunction.

## The Oropharynx and Salivary Glands

### Anatomy and Physiology<sup>49,101</sup>

Birds lack an oropharyngeal isthmus, and the oral and pharyngeal cavities are combined to form an oropharynx. The walls of the oropharynx contain numerous mucus-secreting salivary glands (Figure 19.3). The palate contains a median fissure called the choana, which connects the sinuses to the glottis. Just caudal to the choana is the infundibular cleft, which is the common opening of the auditory tubes. Tongue anatomy varies widely among avian species. Parrots have intrinsic muscles in the tongue, while other birds have only extrinsic tongue muscles. Swallowing involves a rapid rostrocaudal movement of the tongue and the larynx, assisted by sticky saliva and caudally directed papilla on the tongue, laryngeal mound and palate. During swallowing, the choana, infundibular cleft and glottis are closed. The salivary glands secrete mucus and, in some species, amylase. During the breeding season, the salivary gland of swifts temporarily enlarges to produce an adhesive liquid used in nest construction. The nests of some of the cave swiftlets of Southeast Asia are made entirely of this edible secretion (birds' nest soup). The Grey Jay produces large quantities of mucus that are formed into boluses and stored on the sides of trees as a winter food supply. The mucosa of the oral cavity



**FIG 19.3** Anatomy of the oral cavity of an Umbrella Cockatoo. The depressor mandibulae muscles (arrows) have been transected bilaterally to allow the jaws to be opened, revealing the 1) upper beak, 2) openings of the seromucous glands, 3) choana, 4) rima infundibuli, 5) esophagus, 6) rima glottis, 7) salivary orifice, 8) tongue, 9) lower beak. Abscesses occur in multiple locations including a) perichoanal, b) pharyngeal, c) periglottal, d) lingual, e) lateral-ventral lingual and f) sublingual tissues.

in some passerine chicks is brightly colored, with distinctive markings that disappear when the chick is weaned. These markings appear to stimulate the parents to feed the chick.

### ■ Oropharyngeal Diseases

Table 19.3 lists common upper gastrointestinal tract diseases, the typical anatomic sites affected, the types of lesions induced and the common species affected.

### Poxvirus

Poxvirus may cause proliferative caseous lesions (diphtheritic form) in the mouth and esophagus in a variety of avian species. Diagnosis can be achieved by identifying elementary bodies (Bollinger bodies) in impression smears prepared from lesions and stained with Wright's stain or by the Gimenez method. Trichomoniasis lesions may have a similar gross appearance.

### Pigeon Herpesvirus Infection (Smadel's Disease)

Pigeon herpesvirus (PHV) infection has been associated with pharyngeal and esophageal diphtheritic membranes, which are attached to the underlying tissues. Lesions are most severe when secondarily infected with *Trichomonas* spp.<sup>105</sup> Other clinical signs include dyspnea, mucopurulent rhinitis and conjunctivitis. Histologic identification of basophilic and eosinophilic intranuclear inclusion bodies is suggestive.

### Granulomas

Granulomas caused by *Mycobacterium* spp. or other bacterial or fungal agents frequently occur in the oral cavity. A diagnosis can be made by staining suspected material with the Gram's or Ziehl-Neelsen methods (see Table 19.2).<sup>50,71,202</sup> Surgical removal in conjunction with appropriate antimicrobial agents is usually effective in resolving non-mycobacterial-induced granulomas. A case of malignant fibrohistiosarcoma located on the tip of the tongue in a seven-year-old Brown-throated Conure was successfully removed by radiosurgery.

### Nematodes

Various *Capillaria* spp. may infect the mucosa of the tongue, pharynx, esophagus and ingluvies of Falconiformes, Psittaciformes, Galliformes, Passeriformes and Anseriformes.<sup>78,91,174</sup> Characteristic lesions include hemorrhagic inflammation in the commissure of the beak and diphtheritic membranes in the pharynx and tongue. Parasites can be found embedded in inflammatory material. Typical bipolar eggs may be found in esophageal smears or ingluvial washings. In Strigiformes, *Synhimanthus (Dispharynx) falconis* has been reported in the oropharynx.<sup>109</sup>

Spirurid infections have been reported in diurnal and nocturnal birds of prey. Lesions containing the adult nematodes can be found in the mouth, esophagus and crop. The embryonated eggs are thick-walled. Ascarides belonging to the genus *Contracaecum* have been found in fish-eating birds, and severe infections of the oral cavity have been documented in young Pelecanidae. In birds of prey, *Seratospiculum amacu-*

TABLE 19.3 Upper Gastrointestinal Tract Diseases<sup>22, 24, 51, 76, 191, 220, 221</sup>

Organism	Location	Lesion Type	Species Susceptibility
<i>Candida</i> spp.	Oral cavity Esophagus	Ulcerative, necrotic, diphtheritic	Most species, particularly neonates, immunosuppressed animals
Duck enteritis virus	Oral cavity Sublingual salivary glands	Ulcerative	Ducks
Herpesvirus	Oropharynx, Esophagus Proventriculus	Diphtheritic	Owls
Lice ( <i>Piagetiella peralis</i> )	Oral cavity	Stomatitis	Penguins
Leeches ( <i>Theromyzon</i> spp.)	Nasal cavity, Conjunctiva Oropharynx	Hyperemia at attachment site	Anseriformes
<i>Mycobacterium</i> spp.	Tongue, Frenulum Hard palate	Granulomas	Psittaciformes, Falconiformes Galliformes
Neoplasias	All locations	Masses, ulcerative	Most species
Papillomas	Oropharynx, Esophagus Proventriculus	Masses	Psittaciformes
Pigeon herpesvirus	Pharynx, Esophagus	Diphtheritic	Pigeons
Poxvirus	Mouth Esophagus	Diphtheritic	Galliformes, Psittaciformes, Passeriformes, Raptors, Columbiformes
Trematodes ( <i>Cathaemasia</i> spp. <i>Clinostomum</i> spp.)	Oral cavity	Stomatitis	Ciconiiformes
Trichomoniasis	Oral cavity, Esophagus Crop	Ulcerative Proliferative	Falconiformes, Psittaciformes, Columbiformes, Passeriformes

*latum* can cause lesions that resemble those of oral trichomoniasis.<sup>212</sup> The adult worms are found in the air sacs. Eggs may be found in the oral mucus or feces.

### Hypovitaminosis A

In psittacine birds, a typical clinical sign of hypovitaminosis A is metaplasia of the submandibular or lingual salivary glands and clubbing of the choanal papillae (see Color 8). Affected birds are usually fed all-seed diets with a large percentage of sunflower seeds. Treatment should include parenteral vitamin A and the use of a formulated diet. Keratogenic cysts in the lingual salivary glands should be differentiated from lingual abscesses by biopsy.

Lesions associated with hypovitaminosis A in gallinaeous birds first appear in the pharynx and are largely confined to the mucous glands and their ducts. The epithelium is replaced by a stratified squamous epithelium that occludes the ducts of the mucous glands, causing accumulations of secretions and necrotic debris. Small, white, hyperkeratotic le-

sions (up to 2 mm in diameter) may be seen in the nasal passages, mouth, esophagus, pharynx and crop.

Some authors suggest that hypovitaminosis A is unlikely in pigeons because these birds efficiently metabolize this vitamin.<sup>155,223</sup> Other authors suggest hypovitaminosis A frequently occurs in pigeons but it is seldom recognized because the histologic lesions are limited to inflammation of the mucous glands.<sup>194</sup> As the condition progresses, the duct systems fill with masses of degenerate lymphoid and inflammatory cells, amorphous debris and mucus.

### Sialoliths in Pigeons

Mucosal lesions that appear similar to those caused by hypovitaminosis A have been described on the palate of pigeons and are referred to as sialoliths (see Color 13).<sup>223</sup> Sialoliths consisting of a proteinaceous substrate mixed with cellular debris are clinically recognized in approximately one percent of pigeons. The etiology of sialoliths remains unknown. However, based on their histologic, histochemical, chemi-

cal and physical characteristics, they are not thought to be caused by hypovitaminosis A.<sup>223</sup> An association with pigeon herpesvirus infection has been suggested and seems plausible.<sup>110,206,223</sup>

### Foreign Bodies

Clinical signs of foreign bodies in the upper GI tract can include respiratory distress, head shaking, scratching the head with the feet, dysphagia or anorexia. A thorough oropharyngeal examination and radiographs may reveal the foreign body.

A string looped around the base of the tongue and passing down the esophagus has been associated with dysphagia and respiratory distress in gallinaceous birds.<sup>71,151</sup> The string tightens and cuts further into the tongue with each swallowing movement, causing edema of the glottis. Ring-shaped foreign bodies (eg, tracheal rings of prey eaten by raptors) can become lodged around the tongue, causing avascular necrosis. Wooden, plastic or metal splinters

(originating from toys or enclosures) may lodge in the mouth or esophagus of psittacine birds (Figure 19.4). Waterfowl frequently ingest baited fishhooks, which can be lodged anywhere in the upper or lower digestive tract. Fish bones may lodge in the pharynx or proximal part of the esophagus causing dysphagia. Plant hairs that lodge in the oral or esophageal mucosa can cause granulomas.

### Stomatitis

Stomatitis in birds has been associated with the consumption of hot foods, ingestion of oil and ingestion of caustic substances.<sup>51</sup> Birds that chew on silver nitrate sticks may have extensive chemical burns of the oropharynx and crop.<sup>131</sup> Use of bipolar radiosurgery is superior to silver nitrate sticks for controlling hemorrhage of the beak and nails. Stomatitis may occur secondary to food accumulations caused by beak deformities (eg, Pbfd) (Figure 19.5). Beak necrosis has been described in pigeons and gallinaceous



**FIG 19.4** A mature Umbrella Cockatoo was presented for evaluation of palatine beak necrosis. The bird's feathers were in poor condition, and the bird appeared to be hungry but would eat reluctantly. The referring veterinarian had diagnosed Pbfd based on the combination of beak necrosis and feather abnormalities. On physical examination, the defect in the palatine area of the beak appeared to contain a foreign body. Magnification indicated that the bird had a large wood splinter lodged in the occlusal surface of the upper beak. The splinter was removed and the wound was debrided and flushed. The bird's appetite improved within several days of presentation, and it began to preen normally within a week. The bird was DNA probe-negative for Pbfd virus and polyomavirus.



**FIG 19.5** Palatine beak necrosis may occur in some birds with Pbfd virus. Once a defect in the oral mucosa occurs, food may accumulate in the damaged tissues and create a nidus for secondary bacterial and fungal pathogens. In this Umbrella Cockatoo, the rhinotheca was completely necrotic and separated from the underlying bone. The bird had relatively minor feather pathology. This bird was euthanized.

birds fed a finely ground, high-gluten food. The gradual accumulation of fine particles of food along the inner edge of the lower beak leads to secondary infection and necrosis of the beak. Feeding pelleted rations prevents the problem. The tongue of turkey poult fed a finely ground mash may be curled backward by an accumulation of food on the floor of the mouth.<sup>151</sup>

Many trichotecenes, notably T<sub>2</sub> toxin, can cause caustic injury to the alimentary mucosa. Yellow erosive and exudative plaques with underlying ulcers located near the salivary duct openings on the palate, tongue and buccal floor are characteristic lesions. Thick crusts of exudate may accumulate along the anterior margin of the beak. Anorexia is probably caused by the painful lesions in the beak.<sup>87,219</sup>

*Spirillum pulli* may cause stomatitis in chickens.<sup>127</sup> The organism can be demonstrated cytologically in fresh scrapings from diphtheritic lesions or salivary glands. Experimental transmission occurs by inoculation of tissue suspensions and by direct contact. Moist, slick mucosal membranes have been described in pheasants with Newcastle disease virus and in chronic cholera.

### Lacerations of the Tongue

Lacerations of the tongue have been encountered in psittacine birds and may be due to mate-induced trauma, automutilation during the excitement phase of post-anesthetic recovery or gnawing on sharp objects. The tongue is highly vascular and bleeds profusely if damaged. Anesthesia, magnification and radiocautery are usually necessary to control bleeding and repair the laceration.

### Glossitis Gelatinosa Circumscripta

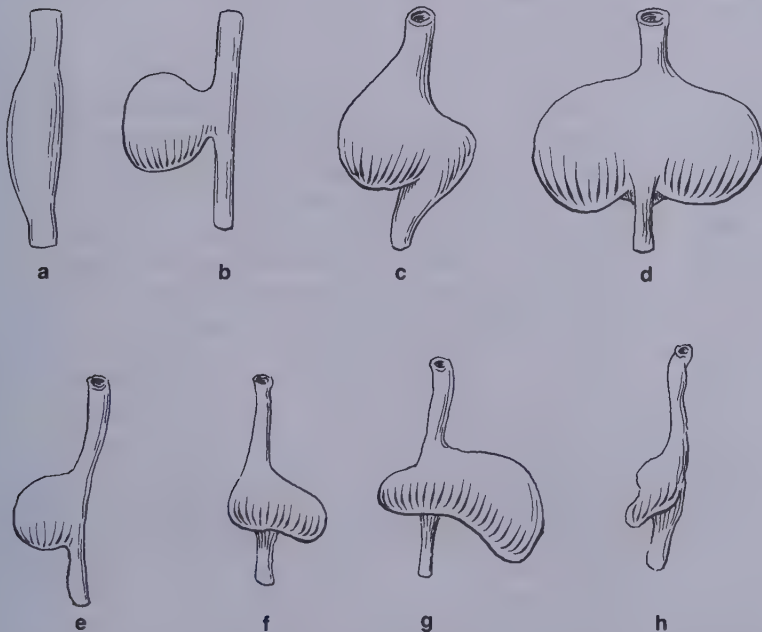
A gelatinous mass may be found on the dorsal aspect of the tongue in five- to twelve-week-old ducklings and goslings. The precise etiology is undetermined, but a multi-deficient diet has been suggested.<sup>103</sup>

## The Esophagus and Crop

### Anatomy and Physiology<sup>31,49,101</sup>

The esophagus lies immediately under the skin and to the right of the trachea (see Color 13).<sup>16</sup> The internal surface of the esophagus is longitudinally folded, increasing its distensibility and allowing carnivorous and piscivorous birds to consume large food items. From a clinical perspective, the anatomy of the avian esophagus allows for easy introduction of instruments or endoscopes for foreign body removal from the esophagus, crop and proventriculus. In most birds, the esophagus is divided by the crop or ingluvies (some birds do not have a crop) into a cervical and a thoracic component.

In Galliformes and Falconiformes, the crop forms a ventral enlargement of the esophagus at the thoracic inlet. In Psittaciformes, the crop is stretched transversely across the neck. In canaries and ducks, the crop is absent, but there is a spindle-shaped swelling of the esophagus at the thoracic inlet. In pigeons, the ventral diverticulum of the esophagus that forms the crop is divided into two large lateral sacs. The esophagus is lined with partly kera-



**FIG 19.6** The shape of the crop varies dramatically depending on the species and the amount and shape of the ingesta. Some crop shapes include **a)** Great Cormorant, **b)** peafowl, **c)** budgerigar and **d)** domestic pigeon. **e-h)** Various shapes noted in a cockatoo. Modified in part from King and McLelland.<sup>101</sup>

tinized, stratified squamous epithelium. Mucous glands are located in the lamina propria, and are numerous in the thoracic esophagus. The structure of the crop resembles that of the esophagus, except that the mucous glands are restricted to an area adjacent to the esophagus. The function of the crop is to store food when the ventriculus is full (Figure 19.6). When the ventriculus is empty, food can bypass the crop and move directly into the proventriculus. The entire length of the esophagus can be used to store food in species that do not have a crop (eg, penguins and gulls). The esophagus and crop produce mucus, which softens and moisturizes the food in preparation for mechanical and chemical digestion lower in the gastrointestinal tract. Initial stages of carbohydrate digestion (mediated by salivary amylase) may occur in the crop of some species. The highly developed crop of the Hoatzin is unusual in having a large cervical component and two thoracic components. In this species, the ventriculus is small, and the muscular crop is the main site for the mechanical dissociation of food.

Adult pigeons of both genders produce a secretion called crop milk that is regurgitated and fed to the squabs during the first week after hatching. Other food items gradually replace the crop milk as the babies mature. Prolactin controls the production of crop milk, which consists of desquamated cells of the proliferated stratified squamous epithelium of the crop. Crop milk physically resembles mammalian milk and contains a high concentration of fat (6.9-12.7%) and protein (13.3-18.6%), but lacks carbohydrates and calcium. The crop of Psittaciformes and finches may also produce some secretions that are regurgitated and fed to neonates. The male Emperor Penguin feeds its chicks a fluid produced by desquamation of the esophageal epithelial cells, while the merocrine esophageal glands of both genders of Greater Flamingos produce a red nutritive juice that is regurgitated and fed to the young.

The crop of some birds may be involved in courtship behavior. Regurgitation is a common courtship behavior in some psittacine birds, particularly budgerigars, cockatiels and macaws. Males of some avian species (eg, pigeon, Great Bustard, ostrich, Sage Grouse) have inflatable esophageal diverticula that act as resonating chambers or display devices.

### Investigative Methods

Clinical signs of esophageal or ingluvial disorders may include dysphagia, anorexia, retching, regurgi-



**FIG 19.7** A two-year-old male budgerigar was presented with a three-week history of regurgitation. The bird was in overall good condition and would regurgitate when handled by either of the female members of the family. The bird would flick its head when it regurgitated, causing vomitus to land on the head feathers giving them a stiff, displaced appearance. Rhinorrhoea can cause similarly appearing feather changes. The regurgitation in this bird was linked to courtship behavior.

tation or vomiting. In budgerigars, vomiting may be accompanied by a rapid flick of the beak, which frequently deposits vomitus on top of the bird's head (Figure 19.7).<sup>8</sup> A history of recent drug administration, assisted feeding, poor hygiene or access to toxic compounds may suggest an etiology for esophageal problems.

The skin and feathers overlying the crop should be examined for abnormalities. Wetting of the feathers will help in visualizing lacerations, discolorations or necrosis of the crop. Hypermotility or hypomotility may occur with crop disorders.<sup>96</sup> In domestic fowl, peristaltic waves occur in the cervical esophagus at intervals of 15 seconds and in the thoracic esophagus, at intervals of about one minute. A psittacine crop that is partially filled with food should average one or two contractions per minute.

The esophagus and crop are thin-walled structures that are difficult to palpate unless abnormally thickened (Color 19.6). The crop can be palpated when it is full of food, fluid, air or abnormal masses. An enlarged crop with a dough-like consistency that fails to empty is suggestive of a crop impaction (Color 19.17). Occasionally, large deposits of fat, and in some cases lipomas, can occur near the crop and should not be misdiagnosed as a full or impacted crop. The use of improperly designed feeding cannulas to provide supportive nutrition to birds can result

in esophageal lacerations, with food being deposited into the subcutaneous, periesophageal tissues (see Color 30.8). Discolored necrotic areas, swelling and edema are common clinical findings.

For diagnostic purposes, an esophageal or ingluvial aspirate can be obtained by inserting a catheter and washing the mucosa with sterile isotonic saline solution. Luer-lock syringes should always be used when tube-feeding or collecting samples from psittacine birds to prevent them from swallowing the tube. Immediate microscopic examination of a wet mount slide is best for diagnosing trichomoniasis. Material aspirated from the crop should be centrifuged, and microscopic examination of the sediment may reveal nematode eggs or *Candida* spp. (Color 30.15). Airdried smears can be stained with Diff-Quik, Gram's stain, Wright's stain, Hemacolor or other stains for specific cytologic examination (see Chapter 10).

A fecal flotation and crop aspirate should be performed to detect parasite ova that might indicate an esophageal or ingluvial nematode or trematode infection. Flotation is more likely to detect low concentrations of eggs than a direct smear. Endoscopy is useful for examining the gastrointestinal mucosa and for removing some foreign bodies (Color 19.1).

## Diseases of the Esophagus and Crop

### Trichomoniasis

*Trichomonas gallinae* infections commonly occur in pigeons and raptors, and may also occur in Passeriformes (particularly canaries and Zebra Finches)<sup>115</sup> and Psittaciformes (particularly budgerigars and cockatiels).<sup>8,61,137</sup> In pigeons, the proliferative necrotic lesions caused by trichomoniasis are called "canker," while in falcons the disease is called "frounce." Trichomoniasis lesions appear similar to those caused by poxvirus; however, in cockatiels, poxvirus infections are uncommon.<sup>137</sup> Table 19.4 compares the clinical presentation of trichomoniasis in budgerigars and pigeons.

TABLE 19.4 Differences in Clinical Presentation of Trichomoniasis in Budgerigars and Pigeons

	Budgerigars	Pigeons
Anatomic Location	Esophagus, crop	Mouth, cloaca, umbilicus, liver, generalized
Lesions	Proliferative	Diphtheritic
Age	Mainly adults	Squabs

Samples for detecting *T. gallinae* can best be collected by introducing a slightly moistened cotton-tipped applicator into the esophagus, and moving it up and down several times against the mucosal lining. The cotton tip is then compressed between the thumb and index finger to produce one drop of fluid, which is placed on a slide for direct examination. A clinical diagnosis in Psittaciformes can be difficult because of low parasite numbers in the early stages of the disease<sup>137</sup> and the intracellular location of the parasite.<sup>8</sup>

Trichomoniasis can cause inflammation of the upper intestinal tract and mouth resulting in dysphagia or vomiting, and may be an underdiagnosed cause of ingluvitis in budgerigars. Historically, idiopathic vomiting, diarrhea and death with yellow caseous plaques and papilliform projections in the esophagus and crop have been defined in many budgerigars. These lesions resemble those caused by trichomoniasis.<sup>3,154</sup> Trichomoniasis was documented in 70% of a group of budgerigars with clinical signs of vomiting and diarrhea.<sup>8</sup> There was no gender predisposition, but the majority of cases occurred in birds from one to three years of age. The cervical part of the esophagus was most frequently affected, but many birds also had crop involvement. Histologic examination revealed that the increased thickness of the crop and esophagus was the result of an increase in depth of the mucosa. The intracellular occurrence of trichomoniasis has not been reported in other avian genera, and this unique feature of infection in budgerigars may contribute to the underdiagnosis of trichomoniasis as a cause of morbidity and mortality in Psittaciformes.

Trichomoniasis-induced ingluvitis and stomatitis have been reported in a cockatiel and budgerigar flock, respectively.<sup>138,162</sup> Trichomoniasis was considered the cause for 80% morbidity and 72% mortality in a flock of 60 cockatiels exhibiting regurgitation, diarrhea and depression.<sup>222</sup> A large caseous mass in the distal trachea caused by *Trichomonas* sp. was reported in a ten-week-old Blue-fronted Amazon parrot.<sup>61</sup>

Trichomoniasis was diagnosed in neonatal cockatiels, Lilac-crowned Amazon Parrots, Mexican Red-headed Amazon Parrots, Sun Conures and Blue-crowned Conures that were fed from a single food source with three syringes. Clinical signs included necrotic dermatitis at the commissure of the beak, depression, crop stasis and white caseous plaques on the tongue and pharynx. Histopathology was negative in all cases. The diagnosis was made by identifying tricho-

## Gastroenterology

### Color 19.1

A >20-year-old Amazon parrot was presented with a six-month history of intermittent dyspnea that had become progressively worse. Survey radiographs indicated a soft tissue mass in the area of the caudal thoracic esophagus. Laparoscopy indicated a diffuse air sacculitis (that was not detected on radiographs), and the soft tissue mass was determined to be a dilated portion of the esophagus. Endoscopy of the trachea revealed thick mucus from which *Klebsiella* spp. and *Pseudomonas* spp. were recovered. The bird responded to systemic antibiotics but would relapse with the cessation of antibiotic therapy. Endoscopy of the esophagus revealed a large mass in the esophagus. Histologically, the surface of the mass contained hyperplastic mucus-producing cells. The etiology of the mass remains undetermined.

### Color 19.2

An eight-year-old Sulphur-crested Cockatoo was presented with a five-week history of vomiting and progressive weight loss. Contrast radiographs indicated a mucosal filling defect in the proventriculus. Gastroscopy with a 3.5 mm flexible endoscope was performed. **a)** The opening from the crop into the thoracic esophagus is clearly visible. **b)** The opening from the proventriculus to the ventriculus is visible. Note the koilin layer (dark green areas), which can partially extend into the proventriculus. **c)** Bile-stained koilin layer of the ventriculus. **d)** Ulcers on the proventricular mucosa. Note barium sulfate is still adherent to some of the sites of ulceration. The bird did not respond to supportive therapy. Histopathology indicated marked myocardial degeneration and necrosis of undetermined etiology.

### Color 19.3

A mature Scarlet Macaw was presented for intermittent regurgitation and weight loss. The bird was maintained in an outdoor environment and was frequently exposed

(every hour) to an automatic pesticide fogger. The bird had been in this environment off and on for several years. Abnormal clinical pathology findings included WBC=22,000, AST=750 and LDH=800. Radiographs indicated a rough appearance to the dorsal serosal surface of the proventriculus, suggestive of inflammation. The client chose to treat the bird at home with only antibiotics. The bird died several days after presentation. At necropsy, a large perforating ulcer was present in the proventriculus.

### Color 19.4

Hemorrhagic, necrotizing, gram-negative bacterial colitis in an Umbrella Cockatoo with a chronic PBF virus.

### Color 19.5

Several different nematodes can cause nodular-type lesions and mucosal hypertrophy in the proventriculus and ventriculus. In this case, proventricular hypertrophy was caused by *Dyspharynx* sp. in a crane that died following a period of weight loss, depression and anemia (courtesy of Robert E. Schmidt).

### Color 19.6

A cockatoo with PBF virus was found dead in its enclosure. The bird was in excellent overall condition and was of normal weight. Necropsy findings included hyperemia of the intestinal tract with distended vessels. Histopathology indicated a gram-negative bacterial enteritis and septicemia.

### Color 19.7

A mature Yellow-collared Macaw hen died following a period of unseasonably low temperatures well below freezing. The bird had exhibited several days of depression before death. At necropsy, the cloaca and lower intestinal tract were filled with blood-tinged, poorly digested food. Histopathology indicated severe necrosis of the villi and crypt cells with a minimum inflammatory response. An etiologic agent was not identified.





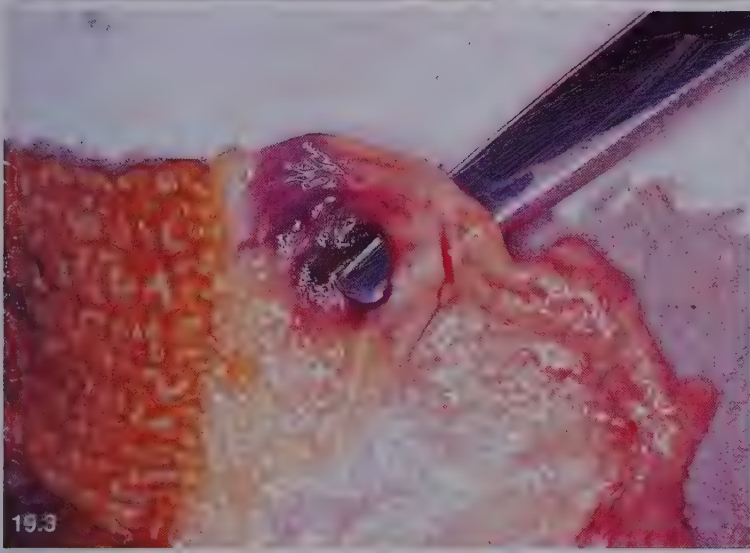19.1



19.2



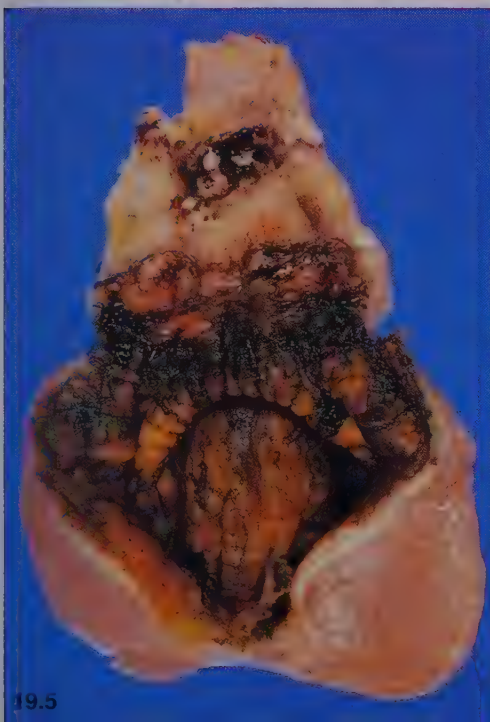19.2



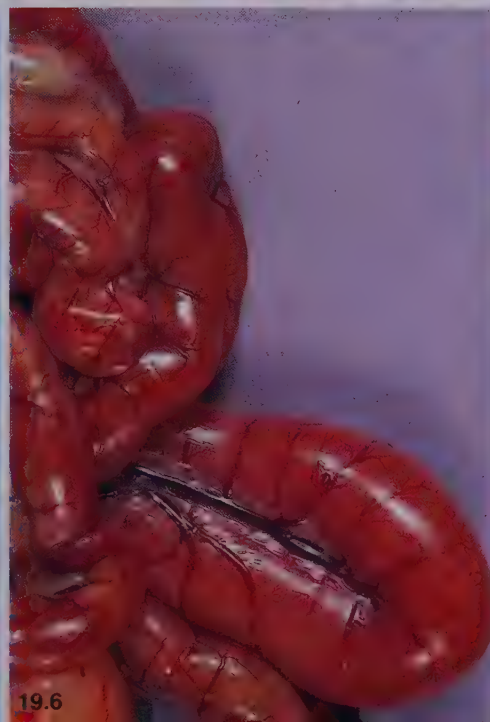19.3



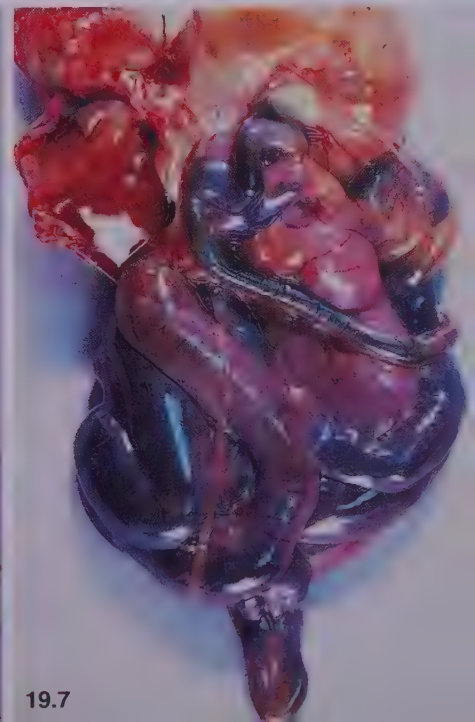19.4




19.5



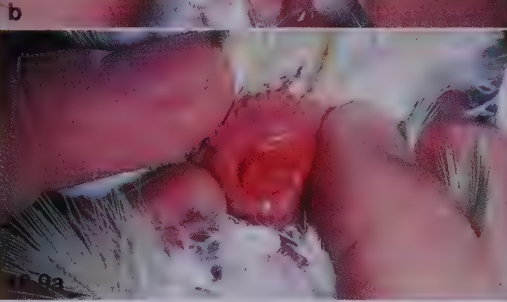
19.6



19.7



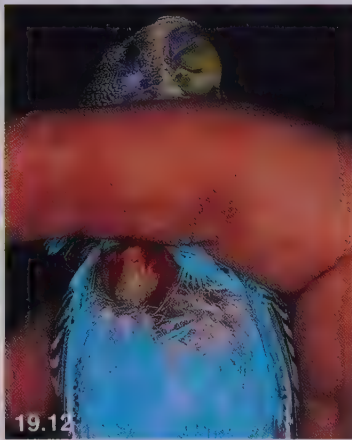
19.8



19.10



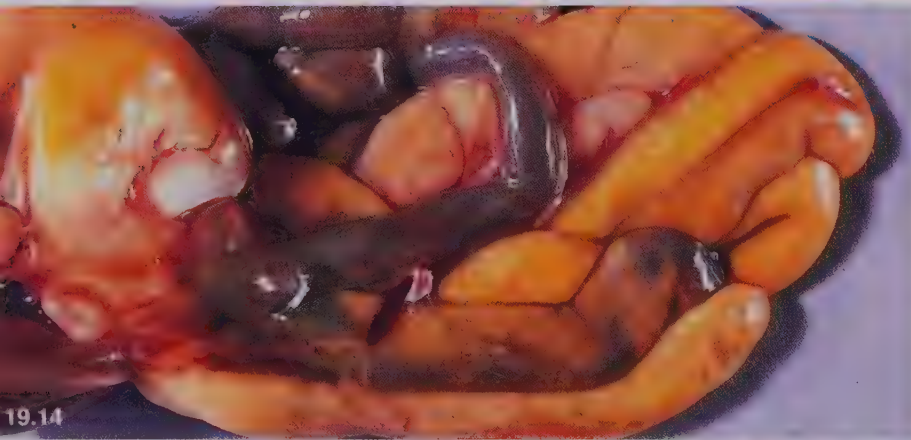
19.11



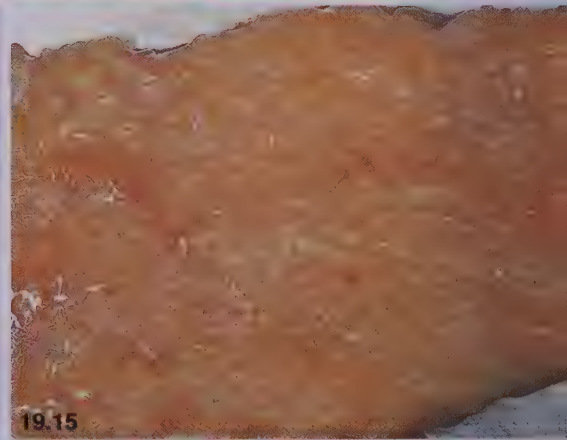19.12



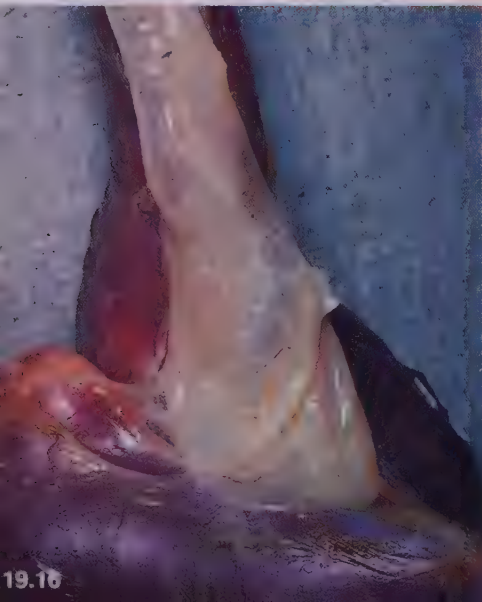19.13



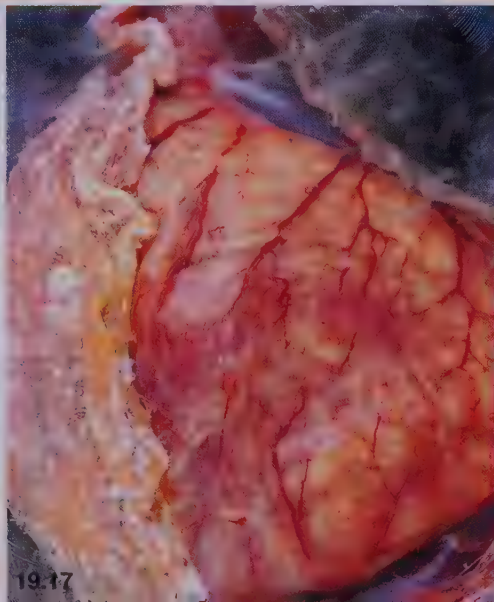19.14



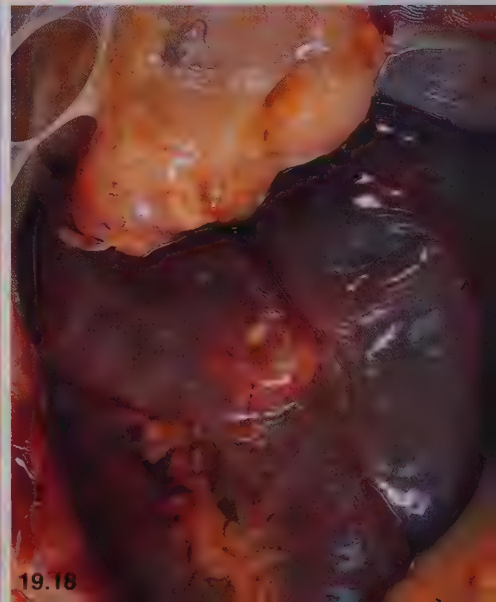
19.15



19.16



19.17



19.18

## Gastroenterology

### Color 19.8

The pericloacal area of birds is normally dry and the feathers are of normal color. Accumulations of excrement or bile-stained feathers are indications of enteritis or cloacal dysfunction. In this case, a mature cockatiel had biliverdinuria from hepatopathy and enteritis associated with giardiasis.

### Color 19.9

**a)** A cloacal papilloma appears as multiple, pink-to-red masses on the cloacal mucosa. Large lesions may protrude from the cloaca and be misidentified as a cloacal prolapse. Five percent acetic acid will cause papillomatous tissue to appear white while normal mucosa will stay pink. Stage cauterization with silver nitrate may be the easiest and most efficacious way to remove papillomatous tissue. Large masses should be removed with repeated treatments several weeks apart to prevent excessive damage to the cloacal mucosa. **b)** The silver nitrate stick is placed in direct contact with the papillomatous tissue and moved gently over the lesion. When the tissue turns grey, the silver nitrate is inactivated by flushing with water. The undiluted silver nitrate must not be allowed to run inside the cloaca, or nonspecific chemical burns will occur.

### Color 19.10

A mature pigeon was presented for depression and anorexia of two days' duration. The feathers around the vent and lower abdomen were covered with excrement and fly larvae. The contaminated feathers were removed. The cloaca was impacted with dry, firm feces and urates. The feces were removed from the cloaca with forceps, and the cloaca was flushed with dilute chlorhexidine solution. A Gram's stain of the rostral cloacal wall revealed a moderate number of short, gram-negative bacteria. The bird responded to parenteral enrofloxacin.

### Color 19.11

A female Amazon parrot was presented three days after egg laying when she was found on the bottom of the enclosure. The bird was depressed and emaciated. A cloacal prolapse had occurred, and the mucosa had multifocal, dry, necrotic areas. The necrotic tissues were cleansed with a dilute chlorhexidine solution and surgically removed. The cloaca was placed back in the abdomen and was held in place with a cloacopexy. The bird was placed on oral enrofloxacin, and the cloaca was flushed BID with dilute chlorhexidine solution followed by the installation of Preparation H. The bird responded to the therapy. The prolapse was considered to have occurred following the passage of an unusually large egg.

### Color 19.12

A mature male budgerigar was presented with a three-week history of intermittent regurgitation. Several masses (inglu-

violiths) were palpated and were removed surgically from the crop.

### Color 19.13

A mature budgerigar was presented for a swelling in the thoracic inlet area. The crop was severely distended with food, and the bird had an audible click on inspiration. Goiter was the presumptive diagnosis and the bird responded to iodine therapy (courtesy of Elizabeth Hillyer).

### Color 19.14

A >25-year-old rosella died acutely. The gastrointestinal tract was dilated and contained poorly digested ingesta. The bird died from severe atherosclerosis.

### Color 19.15

Typical "turkish towel" appearance of the crop in a bird with a severe *Candida* spp. ingluvitis. Compare to Color 19.16 in which the crop is transparent.

### Color 19.16

In Psittaciformes, the normal crop and esophagus are thin, milk-colored, partially transparent membranes with a few distinguishable, small blood vessels. Note that the trachea can be seen through the crop.

### Color 19.17

A 15-week-old Hyacinth Macaw was presented for necropsy following a brief period of depression. The client had noticed that the bird's crop had not emptied over a twelve-hour period. The bird was being fed a commercial hand-feeding formula supplemented with a liquid vitamin and mineral supplement. At necropsy, the crop was hyperemic and distended with food, and the vessels were congested. The kidneys were calcified. Macaws appear particularly sensitive to hypervitaminosis D<sub>3</sub>. This bird's diet was estimated to have four to six times the necessary level of vitamin D<sub>3</sub>.

### Color 19.18

A 23-year-old Scarlet Macaw hen was presented two weeks after the referring veterinarian had surgically removed an impacted egg from the distal uterus. The bird was severely depressed and emaciated, and the abdomen was distended. Radiographs indicated gaseous distention of the intestinal tract. Abnormal clinical pathology findings included WBC=45,000 (toxic heterophils), PCV=25, TP=2.2 and AST=900. Fluid collected by abdominocentesis was characteristic of an exudate (SpGr=1.025, Protein=4.5 g/dl and numerous heterophils). An exploratory laparotomy was performed, a section of strangulated colon was removed and a side-to-side anastomosis was performed. The bird did not recover from the surgery. Note the congested, distended bowel loops and the presence of granulation tissue on the abdominal wall.

monas in impression smears of the lungs of a bird that died one hour before examination.<sup>137</sup>

In another case, six Yellow-naped Amazon Parrot babies were affected. Clinical signs included whitish gray plaques on the tongue, choana and pharynx. Wet mount examination of scrapings from these lesions, crop lavage and transtracheal wash were negative. Postmortem examination of one of the Amazon parrots revealed a caseous plaque partially occluding the syrinx and lungs and filled with a yellowish, clear exudate containing abundant trichomonads that were demonstrated by a wet mount impression smear.<sup>137</sup> These cases suggest that trichomoniasis is a severely underdiagnosed cause of upper gastrointestinal disease in psittacine birds. Histopathologic examination is of limited diagnostic value because the causative organisms float away from the tissue in formalin.<sup>137</sup> Nitroimidazole drugs like metronidazole, ronidazole, dimetridazole and carnidazole are usually effective in treating trichomoniasis; however, nitroimidazole-resistant strains of trichomoniasis occur in The Netherlands because of the improper use of these drugs by pigeon fanciers.<sup>56</sup>

#### Nematode and Trematode Infections

Many nematodes including *Capillaria* spp., *Echinura uncinata*, *Gongylonema ingluvicola* and *Dispharynx nasuata* can invade the esophageal or crop mucosa. The thorny-headed worm (*Oncicola canis*) has been reported in turkeys.<sup>78,174</sup>

#### Ingluvial/Esophageal Stasis and Dilatation

The suggestive causes of crop stasis include heavy metal toxicity, crop impaction, callus formation after a coracoid fracture, thyroid enlargement, atonic crop, sour crop, overstretching of the crop, esophagitis (candidiasis, trichomoniasis, capillariasis, serratospiciliasis), ingluvioliths and esophageal stenosis (Color 19.13). If the fluid in the crop remains stagnant, it will decay and have a foul odor (often referred to as sour crop). Regurgitation of proventricular fluid may be a contributing factor. Feeding a liquid formula to granivorous birds can induce crop stasis, possibly as a result of a lack of mechanical stimulation.

In turkeys, there is thought to be a hereditary predisposition to developing a pendulous crop after increased liquid intake during the first wave of seasonal hot weather. The majority of affected birds do not recover, but continue to have pendulous crops. It has been shown that feeding cerelose as a substitute for starch increases the incidence of pendulous crop

in gallinaceous birds. Affected birds had large quantities of the gas-producing yeast *Saccharomyces telulustris*. Large quantities of gas may have initiated the crop dilatation.<sup>151</sup>

#### Crop Impaction

Crop impaction is occasionally seen in Galliformes and Anseriformes that have sudden access to an abundant supply of lush grasses and sprouted grains.<sup>79,122</sup> Dried oatmeal and soybeans swell when they absorb water and can impact the crop. This is a major cause of mortality in free-ranging Canada Geese.<sup>80,92</sup> About 2000 Canada Geese died from impaction of the cervical esophagus accompanied by necrosis and ulceration of the esophageal mucosa following the ingestion of fox tail grass (*Setaria lutescens*). Lead poisoning, acute fowl cholera and ventricular worm infections can cause similar clinical signs.<sup>122</sup> Crop impactions can occur in birds provided ad libitum grit. Food substances that are difficult to digest, such as raw potatoes, beets, apple skins, sausage skins and large pieces of animal tissues, may also cause crop impaction. In captive raptors, ingluvial impaction may occur when roughage is suddenly added to a low roughage diet, or when the moisture content of the diet is inadequate. Crop impaction may be complicated by secondary *Clostridium perfringens* infection in the European Kestrel.<sup>91</sup>

Impacted material in the crop can be softened by the administration of warm water followed by massaging the crop. However, an ingluviotomy will generally be the method of choice for removing impacted material. Foreign bodies may be removed endoscopically. Expressing the ingluvial contents through the mouth by turning the bird upside down is a dangerous procedure that may lead to irritation of the nasal mucosa, sinusitis or aspiration pneumonia. Packing the choana with cotton and intubating with an endotracheal tube will help eliminate this problem.

#### Ingluvioliths

Ingluvioliths have occasionally been reported in birds (Figure 19.8).<sup>3,10,12</sup> Urate (excreta) calculi with seed husk centers were described in the crops of several budgerigars.<sup>12</sup> It was speculated that the calculi originated from the ingestion of excreta and seed husks in birds provided no food. Other ingluvioliths have been found to contain potassium phosphate, oxalate and cystine, and were not considered to have occurred secondary to urate ingestion (Color 19.12).<sup>3</sup>

### Foreign Bodies

Unweaned psittacine neonates (especially macaws and Eclectus Parrots) frequently ingest foreign bodies.<sup>11</sup> Any ingested foreign body, including rubber or metal feeding tubes, should be removed immediately from the ingluvies before it has an opportunity to align with the thoracic esophagus and pass into the (pro)ventriculus. The type of foreign body is dependent on the species (Figure 19.9). Fishing hooks are common in waterfowl. Perforating or obstructing bones are encountered in raptors.

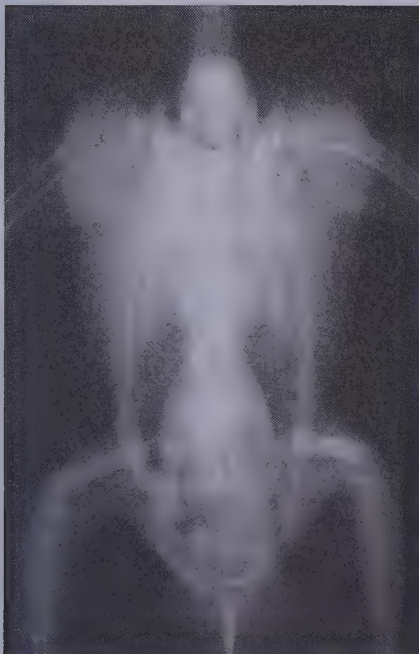
### Crop and Esophageal Lacerations and Fistula

Penetration of the pharynx or esophagus by feeding cannulas, or esophageal-ingluvial burns caused by


ingestion of overheated feeding formulas or caustic materials can result in deposition of food subcutaneously and lead to extensive foreign body reactions. In birds of prey, sharp bones from prey animals may cause an esophageal or ingluvial fistula.<sup>20,153</sup> Traumatic lacerations of the chest including the ingluvies are often seen in racing pigeons. The most likely cause for these lacerations is a collision with antenna wires. Bite wounds from mates or cats and dogs may also cause crop lacerations. A bird with a crop fistula may be presented with weight loss despite a ravenous appetite. The feathers surrounding the fistula are usually matted with dried food. Subcutaneous pockets of food should be surgically drained and frequently flushed. A feeding tube can be passed from the esophagus directly into the proventriculus to allow enteral feeding while the esophagus and crop heal (see Chapters 15, 16 and 41).<sup>81</sup>

### Esophageal Stricture

A ten-year-old Hyacinth Macaw developed a stricture in the thoracic esophagus after ingesting several large pieces of hard plastic. The most obvious clinical sign was regurgitation of mucus. A barium study revealed a filling defect in the caudal esophagus. Endoscopic examination through an ingluvial incision revealed an annular ring of exudate and hyperplastic tissue. The stricture was resolved by periodic mechanical dilation.<sup>203</sup> Esophageal strictures may also occur secondary to burns. A cockatoo with severe self-mutilation syndrome damaged the periesophagus



**FIG 19.8** An ingluviolith is evident in these radiographs of a cockatiel (courtesy of Jean Paré).



**FIG 19.9** An adult female Umbrella Cockatoo was presented with an acute onset of lethargy and regurgitation. Several small solid masses could be palpated in the crop. The bird was producing small amounts of excrement and had tenesmus. The bird was maintained in an earthen-floored flight enclosure and was fed wild bird seeds. Abnormal clinical pathology findings were limited to hypokalemia and mild anemia (PCV=34%). Radiographs indicated several metallic densities in the crop. In addition, an excessive number of mineral densities (small rocks, grit) were present in the ventriculus and intestinal tract. The metallic densities (pieces of wire) were removed using an endoscope and forceps. The ventriculus was flushed with copious amounts of warmed LRS, which resulted in the removal of about 20 to 30 small rocks. The bird was given corn oil by crop tube three times a day for three days, and rocks were noted in the stool on the day after the first corn oil treatment. The bird's diet was corrected and no further problems were noted.

phageal skin to such a degree that the esophagus was occluded and the bird died from asphyxiation.

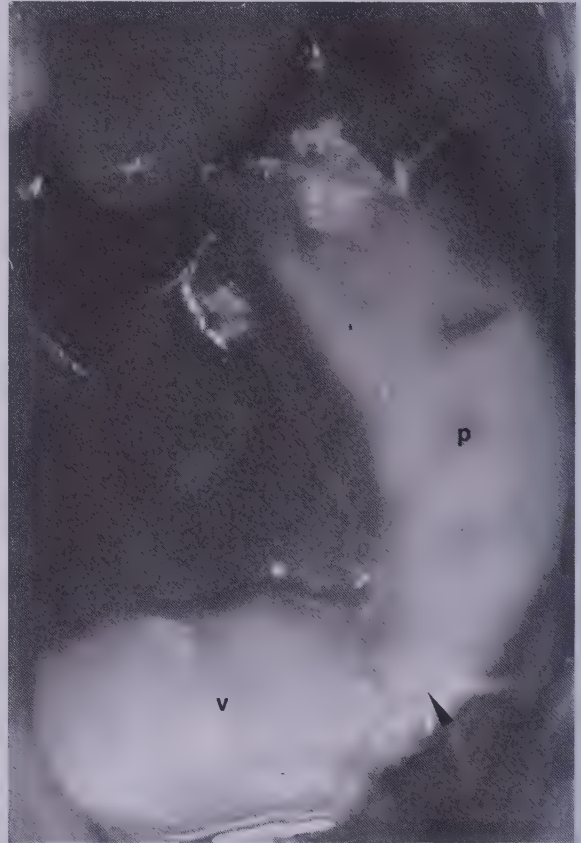## The Proventriculus and Ventriculus

### Anatomy and Physiology<sup>55,101</sup>

The avian stomach consists of a cranial glandular part (proventriculus) and a caudal muscular part (ventriculus). The proventriculus in birds is situated in the left dorsal and left ventral regions of the thoraco-abdominal cavity, and is covered ventrally by the fat-laden posthepatic septum (see Color 14). The pyloric part of the ventriculus joins the duodenum and is located on the right side of the midline. In granivorous, insectivorous and herbivorous birds, the muscular wall of the ventriculus is highly developed and is clearly distinct from the proventriculus. The two organs are divided by an intermediate zone, or isthmus, which can be seen grossly as a constrictive band (Figure 19.10). The ventriculus can be palpated in granivorous birds on the left ventral side of the abdomen just caudal to the sternum.

The proventriculus has two types of glandular epithelial cells. Mucus-producing, columnar epithelial cells line the proventricular mucosa and the lumina of the ducts from the proventricular glands. These cells contain numerous periodic acid Schiff (PAS)-positive mucin granules. The multilobular glands of the proventriculus are lined by oxynticopeptic cells. These cells have ultrastructural features similar to both the parietal (acid-secreting) and the peptic (enzyme-secreting) cells of the mammalian stomach, and secrete both pepsinogen and hydrochloric acid. The ducts from these glands empty from numerous papillae that can be found in the proventricular wall. These oxynticopeptic cells possess a very eosinophilic and somewhat granular cytoplasm and do not contain PAS-positive mucin granules.

The wall of the ventriculus is composed of smooth muscle arranged into four semi-autonomous masses. The caudodorsal and cranioventral thick muscles and the craniodorsal and caudoventral thin muscles attach to the right and left tendinous centers in the lateral walls of the ventriculus. The asymmetric arrangement of the muscles enables rotary and crush-



**FIG 19.10** The isthmus (arrow) is distinguished as a constrictive band separating the proventriculus (p) from the ventriculus (v). The proventriculus can be seen laying dorsal to the caudal thoracic air sac. This bird died from myocardial degeneration.

ing movements during ventricular contractions. The thin muscles form the cranial and caudal blind sacs. The caudal blind sac is a good point for gastrotomy incision in granivorous birds because incisions in the thick muscles heal poorly. The inner surface of the ventriculus of granivorous birds is lined by a carbohydrate-protein complex (koilin layer or cuticle). This koilin layer is composed of vertical rods secreted by the mucosal glands of the lamina propria and a horizontal matrix, which is a secretion of the surface epithelium that hardens after spreading around the rods. Desquamated cells of the surface epithelium are trapped within the horizontal matrix. Hydrochloric acid from the proventriculus causes precipitation of the protein complex to form a tough, water-resistant lining. The brown, green or yellow color of the koilin is caused by regurgitation of bile through the pylorus.

The intermediate zone that divides the proventriculus and ventriculus has histologic characteristics

similar to both organs. Compound glands are absent, and the internal surface is relatively smooth. The columnar epithelium lining the proventriculus gradually changes into ventricular glands. There is a mixture of proventricular-like mucoid secretions and ventricular-like glandular secretions. Most gastric neoplasms in birds occur in the intermediate zone, and use of PAS stains appears useful in determining the types of epithelial cells that have been transformed.<sup>113,161</sup>

The ventriculus is the site of gastric proteolysis, and in many species also of mechanical digestion. In carnivorous and piscivorous birds, the proventriculus is more adapted for storage than for physical digestion. In these species, the ventriculus is thin-walled and sac-like, and the ventriculus and proventriculus are difficult to differentiate grossly. The koilin layer is relatively thin and softer than in granivorous birds. The muscularis is relatively thin. In raptorial species (eg, owls), the ventriculus is involved in the formation and regurgitation of pellets or “castings,” which are composed of undigestible fur, feathers or bones. Intermediate forms of proventricular and ventricular differentiation are found in many avian species including frugivorous (fruit-eating) and testacivorous (shellfish-eating) birds.

In certain frugivorous pigeons, the koilin layer is composed of rows of hard, pointed, conical projections that facilitate crushing firm fruits such as nutmeg. In some species (magpie and starling), massive shedding and excretion of the koilin layer occur periodically. Male hornbills may regurgitate the koilin layer as a seed-filled sac that is fed to the nesting female.

The proventriculus in an ostrich is a large, thin-walled structure. In contrast to other birds, the oxynticopeptic cells are restricted to a patch on the greater curvature. The distal extremity of the ostrich proventriculus passes dorsal to the ventriculus and empties on the caudal aspect of this organ. The ostrich ventriculus is a thick-walled muscular organ. The isthmus between the proventriculus and ventriculus is large, which makes it easy to remove foreign bodies from the ventriculus through a proventricular incision. In emus and nandus, the proventriculus is large and spindle-shaped, and the ventriculus is slightly larger and more lightly muscled than that of the ostrich.

## Proventricular and Ventricular Diseases

Most diseases of the proventriculus or ventriculus produce similar clinical signs and make differentiation difficult. For example, an enlarged proventriculus may be found in many of the diseases in Table 19.1. The following is a discussion of some of the diseases that affect the proventriculus and ventriculus.

### Megabacterial Proventriculitis

“Going light” syndrome in budgerigars, a disease characterized by emaciation, weakness, high morbidity and low mortality, has been described in canaries and budgerigars. Vomiting of slimy material is seen in advanced stages of the disease.<sup>64,177,197,201</sup> Postmortem findings include proventriculitis and proventricular dilatation. Histologically, gram-positive, PAS-positive, acidophilic (with Giemsa), rod-shaped bacteria can be identified, especially in the area between the proventriculus and ventriculus. The organisms have been characterized as large bacteria (not fungi), hence the name “megabacteria” (see Figure 33.13).

A diagnosis can be made by cytologic demonstration of the organisms in a proventricular washing. The pH of the proventriculus is markedly elevated in affected birds. The pH of the proventriculus from normal canaries was found to range from 0.7 to 2.4 compared to severely infected canaries in which the pH was 7.0 to 7.3. In birds with moderate numbers of megabacteria, the pH of the proventriculus ranged from 1.0 to 2.0.<sup>201</sup> The most important differential diagnosis is trichomoniasis.

### Proventricular and Ventricular Nematodes

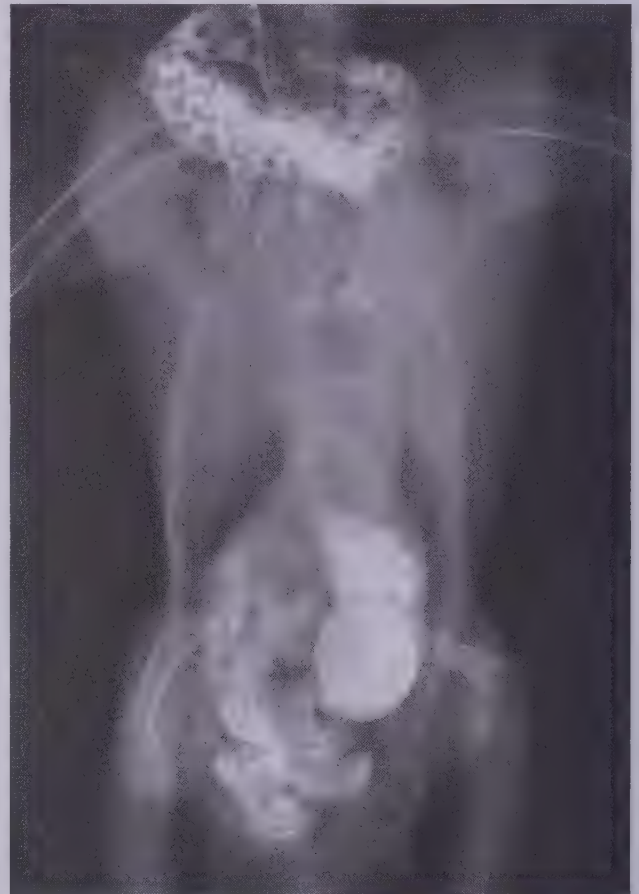
Many nematode species have been reported to occur in the proventriculus (*Echinura uncinata*, *Gongylonema ingluvicola*, *Cyrnea* spp., *Dyspharynx nasuta* and *Tetrameres* spp.). *Amidostomum* spp., *Cheilospirura spinosa* and *Epomidiostomum uncinatum* are found under the horny layer of the ventriculus (Color 19.5).<sup>60,174,179</sup> Lesions vary considerably depending on the host and the parasite, and may be quite extensive (see Chapter 36). Clinical signs may be absent or include emaciation, anemia and mortality. Diagnosis can often be made by detecting parasite eggs using a fecal flotation technique. Treatment can be attempted with levamisole (20 mg/kg orally, or 10 mg/kg parenterally) or ivermectin (200 µg/kg parenterally). It should be stressed that experience with ivermectin in many avian species is absent. Acute death has been reported after the use of ivermectin in some mammalian and reptilian species.

### Neuropathic Gastric Dilatation and Encephalomyelitis of Psittacines

Neuropathic gastric dilatation (NGD)<sup>123</sup> has been given many names since it was first recognized as a clinical entity in 1971 (Table 19.5).

The descriptive term myenteric ganglioneuritis and encephalomyelitis of Psittaciformes best defines the following histologic lesions that can be observed in affected animals: lymphocytic and monocytic infiltration of intrinsic and extrinsic splanchnic nerves of the muscularis tunics of the alimentary tract; in some cases, leiomyositis in organs innervated by affected nerves and non-suppurative encephalitis, myelitis and radiculoneuritis have been described.<sup>68</sup> Many psittacine species can be affected, including macaws, cockatoos, conures, African Grey Parrots, Senegal Parrots, Amazon parrots, Eclectus Parrots, Thick-billed Parrots and cockatiels.<sup>68</sup>

Clinical signs are related to (pro)ventricular and sometimes neurologic dysfunction, and may include anorexia, regurgitation, undigested seeds in the feces and weight loss. The occurrence of neurologic signs is variable. In advanced cases, proventricular dilatation can be visualized on abdominal radiographs, with or without contrast media (Figure 19.11). In the clinical patient, a tentative diagnosis of NGD can be made based on clinical signs and radiographic findings. It should be stressed that other diseases can mimic NGD and should be ruled out before a definitive diagnosis is considered (Table 19.6).<sup>69,90,197</sup> NGD



**FIG 19.11** A three-year-old female cockatiel was presented with a two-week history of passing undigested seeds. Survey radiographs suggested a dilated proventriculus. Barium contrast study indicated a slowed gastric emptying time (VD and lateral radiographs eight hours after the administration of barium by crop tube). Note the numerous filling defects (ingesta and undigested seeds) in the crop, proventriculus and intestines. The client chose to have the bird euthanized. Histopathology confirmed a diagnosis of neuropathic gastric dilatation.

**TABLE 19.5** Synonyms for Neuropathic Gastric Dilatation\*

- Psittacine proventricular dilatation syndrome (PPDS)
- Macaw wasting syndrome
- Myenteric ganglioneuritis
- Psittacine encephalomyelitis
- Proventricular dilatation of psittacines
- Proventricular dilatation and wasting syndrome
- Myenteric ganglioneuritis and encephalomyelitis of psittacines
- Wasting/proventricular dilatation disease (WPDD)
- Proventricular dilatation disease
- Proventricular dilatation syndrome
- Macaw fading syndrome

\* References 37,45,68,89,94,121,123,157,167,172,195,221



**TABLE 19.6 Differential Diagnosis of Neuropathic Gastric Dilatation**

- Heavy metal poisoning
- Fungal infection of ventriculus or koilin mycosis
- Nematode infection of the (pro)ventriculus
- Megabacteria infection of the proventriculus
- Gastric impaction
- Pyloric obstruction by a foreign body
- Ventriculus perforation by a foreign body
- Myoventricular dysgenesis
- Proventricular foreign body
- Koilin dysgenesis
- Myoventricular calcinosis
- Intestinal papillomatosis
- Proventricular and ventricular neoplasia
- Vitamin E and selenium deficiencies

can be confirmed by histologic identification of characteristic lesions in the splanchnic nerves from a ventricular biopsy (Figure 19.12). However, a negative result derived from a small biopsy of the ventricular wall does not rule out NGD.<sup>68</sup>

Although the etiology is presently unclear, a viral etiology has been suggested because of epidemiologic histories of affected aviaries and the demonstration of intranuclear and intracytoplasmic inclusion bodies in affected tissue of some birds.<sup>26,63,84,123</sup> Paramyxovirus-like inclusions have been described by some researchers<sup>123</sup> but could not be identified by others.<sup>68</sup> The “avian viral serositis” virus produces experimental lesions that are similar to those described with NGD (see Color 33).

Affected animals invariably die after a more or less protracted course of the disease. Controlled studies to document the effects of treatment on the prognosis of NGD have not been reported. General therapy including supportive care, a liquid diet, vitamin supplementation and treatment of secondary diseases has been recommended. It has been suggested that birds can survive on a liquid diet,<sup>78</sup> but no case reports could be found that document long-term survival of birds confirmed by ventricular biopsy to have NGD. Treatment of NGD should be considered with caution, given that the disease may be caused by an infectious agent.

It has been suggested that a virus may induce an autoimmune reaction that would be responsible for the lesions observed in NGD.<sup>67</sup> The inciting virus would no longer be present when the disease became clinically obvious or was diagnosed at necropsy. If this scenario is true, then administration of an anti-

inflammatory dose of corticosteroids might be indicated.<sup>161</sup>

### Ganglioneuritis and Encephalitis in Geese

Proventricular impaction with non-suppurative encephalomyelitis and ganglioneuritis morphologically similar to NGD in psittacine birds has been reported in two Canada Geese.<sup>43</sup>

### Proventriculitis in Chickens

Proventricular enlargement and infiltration of the proventricular interglandular tissue with mononuclear cells has been described<sup>106</sup> as part of the infectious runting and stunting syndrome in broiler chickens.

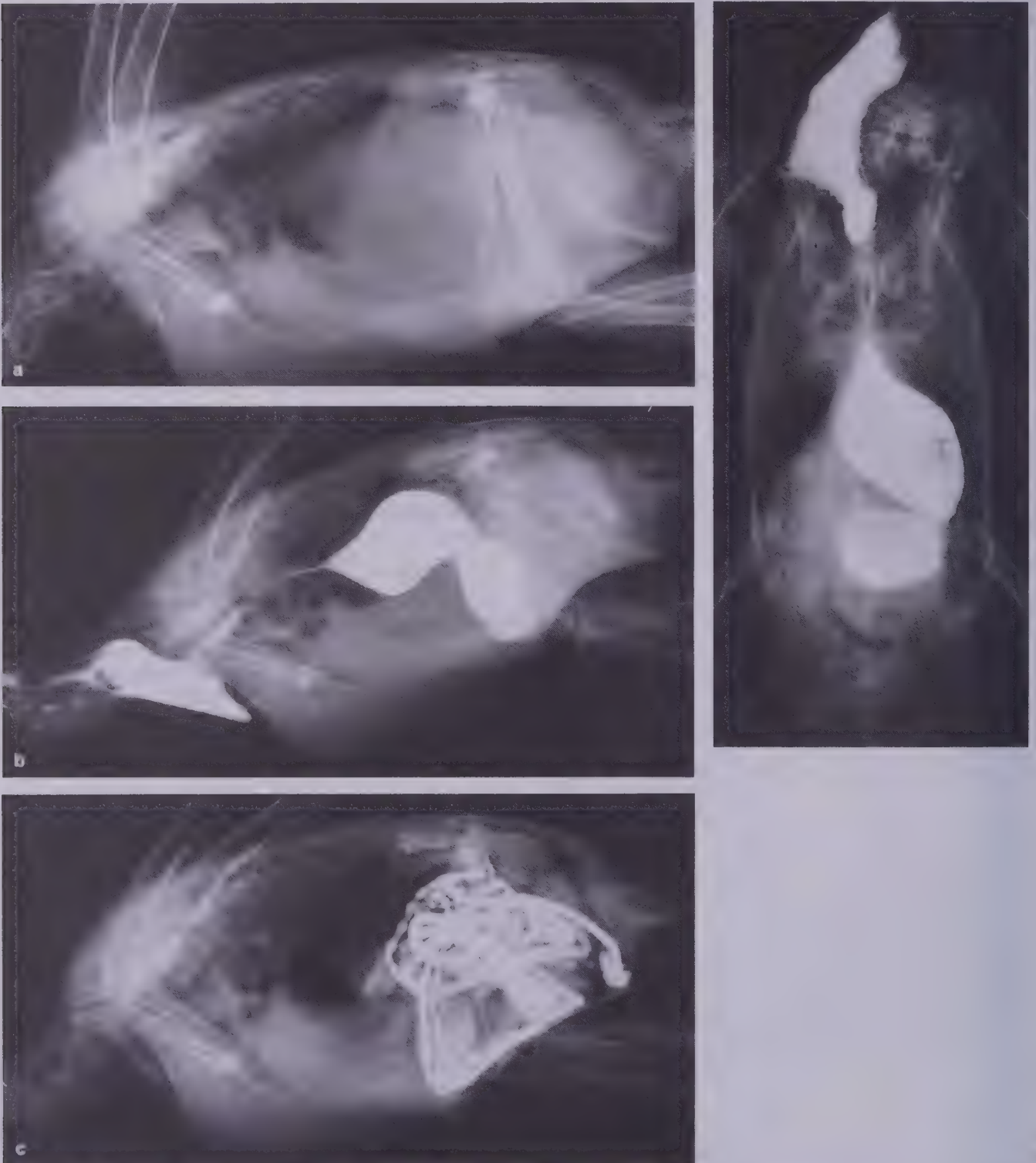### Gastric Impaction and Gastric Foreign Bodies

Gastric impaction is common in psittacine babies that consume bedding material such as crushed walnut shell, ground corncob, shredded paper pulp, styrofoam packing, kitty litter and excess grit. These bedding materials should not be used with neonates.<sup>35,39</sup>

Ventricular impaction secondary to litter ingestion has been reported to cause high mortality during the first three weeks of life in turkey poults. Affected animals were emaciated and had empty intestinal tracts, distended impacted ventriculi and foreign bodies in the first part of the duodenum.<sup>170</sup>

Gastric obstruction caused by phytobezoars or detachment of the koilin layer of the ventriculus has been reported in chickens, a goose, ducks and a pigeon.<sup>51</sup> Gastric rupture may occur secondary to an impaction. In raptors, ventricular impaction caused by a hard mass of fur can also occur. Gastric impaction is more common in captive raptors fed early during the day in hot weather. Those fed late in the day are less likely to retain their casting.<sup>66</sup>

In ostriches, (pro)ventricular impaction is a serious management problem.<sup>209</sup> The condition occurs usually two to three weeks after moving the birds to a new environment containing a novel substrate or food. Most affected birds are under six months of age, but the condition can also occur in adults. Clinically the birds are sluggish and produce small, firm fecal balls. Some affected birds may be lame. Cloacal prolapse may occur in young birds several days to four weeks old. Early diagnosis through abdominal palpation and radiographs followed by immediate surgical correction are imperative for successful resolution.<sup>88,187</sup> A 17-inch string of beads could be palpated



**FIG 19.12** A one-year-old male Eclectus Parrot was presented for severe emaciation, depression, diarrhea and a distended abdomen. The bird had a ravenous appetite. Abnormal clinical pathology findings included AST=1637, LDH=4049 and WBC=3000. **a)** Survey radiographs indicated a severely dilated proventriculus and hepatomegaly. The bird was fasted for eight hours and a barium contrast study was performed. **b)** Ventrodorsal and lateral radiographs were taken two hours post-barium administration and **c)** lateral radiograph represents eight hours post-barium administration. The proventriculus was markedly reduced in size following fasting. Contrast studies indicated a delayed gastric-emptying time, hepatomegaly (causing the proventriculus to be displaced dorsally) and retention of barium in the proventriculus, suggestive of mucosal inflammation. The bird responded to treatment with broad-spectrum antibiotics and lactulose. It should be stressed that the survey radiographs were suggestive of NGD; however, a dilated proventriculus and slowed gastric-emptying time are not pathognomonic for NGD. A biopsy is necessary to confirm a diagnosis.

in the crop of an Amazon parrot. Barium contrast radiographs were used to confirm that the string of beads passed into the small intestines. The string was extracted through the mouth using sponge forceps.<sup>213</sup>


Although poorly documented in birds, emetics might be useful to remove foreign bodies that would not damage the gastrointestinal mucosa during the regurgitation process. Apomorphine induced emesis in 55% of treated birds<sup>36</sup> and in another study, a 0.5% solution of tartar emetic was effective.<sup>114</sup>

### Metallic Foreign Bodies: Traumatic Gastritis, Heavy Metal Poisoning

Ingestion of metallic foreign bodies is relatively common in Galliformes, Anseriformes, Columbiformes, Gruiformes, Pelecaniformes, Psittaciformes and ratites.<sup>51,71,205,209,210</sup>

In captive Psittaciformes and free-ranging Anseriformes, ingestion of lead is extremely common. Paralysis of the intestinal tract from nerve damage may occur secondary to lead poisoning. In Anseriformes, this is clinically recognized as esophageal and proventricular dilatation. In the other orders, ingestion of ferrous metal objects, such as nails, wire, hairpins and needles, account for the majority of cases. This is particularly common in gallinaceous birds.<sup>151</sup> In one case, each affected bird had a piece of one-inch wire penetrating the ventriculus (see Figure 45.2). It was discovered that the owner used a wire brush to clean the water container.

Ingestion of ferrous objects may cause perforation of the ventriculus (majority of cases) or proventriculus, leading to an acute, generalized, purulent peritonitis or to a local peritonitis with abscess formation on the serosal surface of the (pro)ventriculus or duodenum. The powerful contractions of the ventriculus muscles in the domestic fowl can result in a pressure of 100-200 mmHg, which can easily force sharp objects through the tough muscular wall. Occasionally, penetration of a large (hepatic) artery or vein can result in fatal hemorrhage. In some rare cases, the ferrous foreign body will be resorbed by the inflammatory reaction without permanent deleterious effects. Cases have been documented in which a foreign body



**FIG 19.13** A mature African Grey Parrot was presented for evaluation of depression and anorexia several days after destroying a panel of chicken wire placed over a screened-in-porch. Radiographs indicated that the ventriculus was full of metallic densities. Because the wire was composed of a ferrous metal, **a**) the foreign bodies were removed by repeatedly inserting a red rubber feeding catheter equipped with several neodymium-ferro-borium alloy magnets (arrows). **b**) The metal removed from the bird is firmly attached to the magnet contained within the tube.

was exteriorized by penetration through the body wall.<sup>51,205</sup>

Foreign body penetration of the ventricular wall causes a decrease in ventricular contraction and an insufficient digestion of food, which may be recognized clinically by the passage of undigested seeds in the feces. In the racing pigeon, passing undigested seed is considered pathognomonic for a traumatic gastritis. In chronic cases, anorexia, weight loss and a palpable abscess on the left side of the abdominal wall may be noted.<sup>205</sup> Radiology is the method of choice to confirm a tentative diagnosis.

Noninvasive treatments for removal of gastric metal foreign bodies should be attempted before (pro)ventriculotomy. Ferrous metals may be removed from the (pro)ventriculus using a powerful magnet of neodymium-ferro-borium alloy (The Magnet Store 1-800-222-7846) attached to a small-diameter polyvinyl catheter with a removable steel guide wire (Figure 19.13).<sup>120</sup> The size of the polyvinyl probe and magnetic disk can be varied according to the size of the animal. A probe with a length of two meters, a diameter of 18 mm and an attached cylinder magnet of 17 x 70 mm (derived from a bovine cage magnet) has been used to remove thirteen large staples from the ventriculus of an ostrich. Fluoroscopy or endoscopy can be used to guide grasping forceps in the

removal of gastric foreign bodies.<sup>117,119</sup> Most cases of lead and zinc ingestion can be managed medically and do not require surgery.

### Myoventricular Dysgenesis

Proventricular dilatation secondary to ventricular abnormalities caused by feeding finely ground food low in fiber is commonly observed as an incidental finding in chickens. The enlarged proventriculus has a distended thin wall and is full of food. The ventriculus in affected birds is poorly developed, and there is no sharp demarcation between the proventriculus and ventriculus.<sup>169</sup> The postmortem findings are similar to those with pyloric obstruction or gastroesophageal paralysis (ie, dilatation of the food-filled ventriculus, proventriculus, esophagus and crop). In the latter condition, the ventricular muscles are of normal thickness.

### Vitamin E and Selenium Deficiencies

Vitamin E and selenium deficiencies may cause degenerative lesions in the smooth muscle of the ventriculus of domestic and free-ranging Anseriformes.<sup>135,178,219</sup>

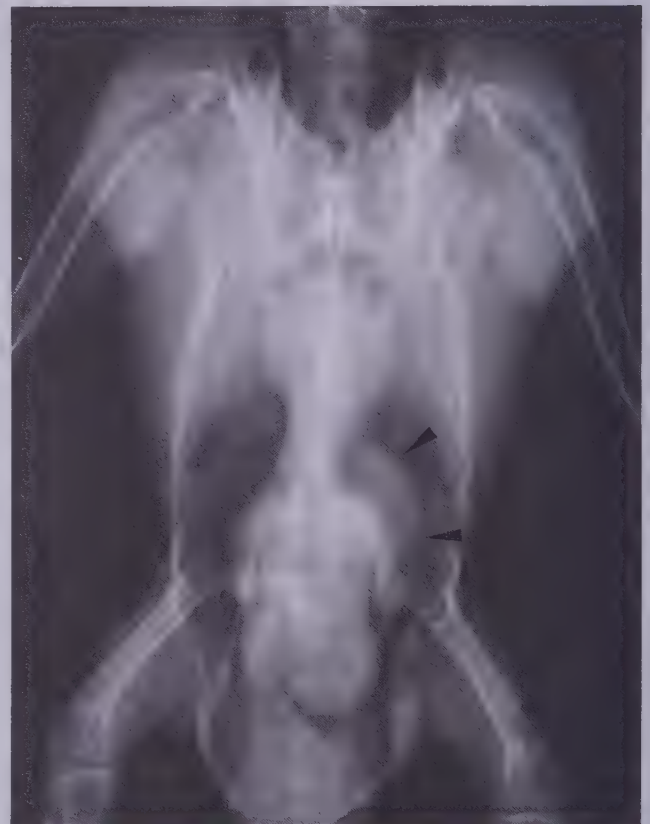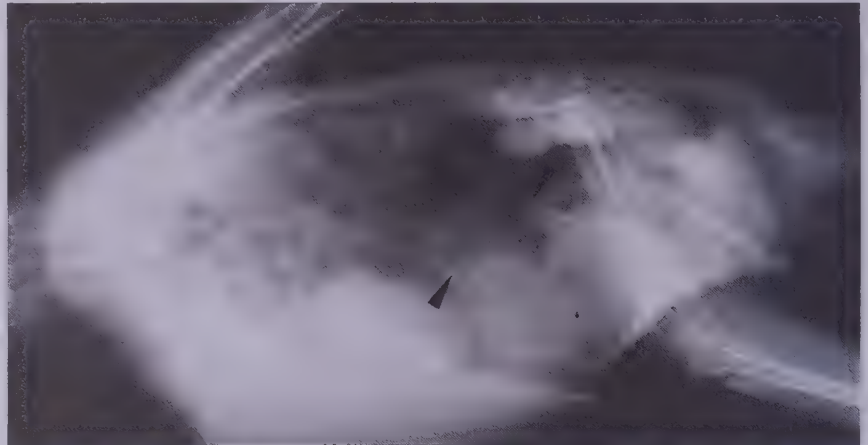
### Gastric Ulceration, Ventriculus Erosion, Gastritis, Koilin Dysgenesis

Idiopathic proventricular ulcers do occur in psittacine birds. Many affected animals are "high strung" or in what could be called stressful environments (Figure 19.14); (Color 19.3).

High dietary levels of certain types of fish meal or finely ground, low-fiber diets can cause erosions and ulcers in the koilin layer of gallinaceous birds.<sup>71,144</sup> Infectious and parasitic agents may damage the ventricular wall causing dysfunction. Penetration of foreign bodies may cause localized lesions. Zoalene (DOT) toxicosis may cause gastric erosion.<sup>71</sup> Ventriculus erosion with a heavy infiltration of heterophils has been reported with zinc poisoning.<sup>46,48,216</sup>

### Copper Poisoning

Excessive dietary copper leads to roughening and thickening of the koilin layer. The marked thickening and folding may have a wart-like appearance. Hemorrhages may be seen under the koilin layer.<sup>53,216</sup>



**FIG 19.14** An eight-year-old Sulphur-crested Cockatoo was presented with a five-week history of vomiting and progressive weight loss. Survey radiographs indicated gaseous distention of the proventriculus (arrows). Contrast radiographs indicated mucosal filling defects in the proventriculus. Gastroscopy with a 3.5 mm flexible endoscope indicated numerous proventricular ulcers (Color 19.2). The bird did not respond to supportive therapy. Histopathology indicated marked myocardial degeneration and necrosis of undetermined etiology.

**Neoplasias**<sup>2,68,74,113,161</sup>

The clinical effects of (pro)ventricular neoplasia may vary, depending on the size of the tumor and the presence or absence of active bleeding from the ulcerated tumor. Clinical signs may include weight loss, vomiting, passing of whole seeds in the feces, regenerative anemia, hypoproteinemia and melena. Although hypoproteinemia may occur, the albumin/globulin ratio is not affected, which together with the anemia and melena is strongly indicative of gastrointestinal blood loss (Table 19.7). Death usually ensues when massive gastric bleeding occurs following erosion of a major vessel. Contrast radiography using both positive and negative contrast may be helpful in outlining the (pro)ventricular neoplasm.<sup>196</sup> Endoscopic-guided biopsy may be used to confirm a tentative diagnosis.

Tumors are frequently located at the isthmus on the boundary between the proventriculus and ventriculus. Gross lesions in the (pro)ventriculus may be subtle, and histologic examination is needed to differentiate tumors from other causes of ulceration or hypertrophy. The use of specific staining methods (Alcian blue and periodic acid Schiff) facilitates differentiation between tumors of proventricular and ventricular origin.<sup>113,161</sup>

Presently, no reports of successful treatment of (pro)ventricular tumors have been published, but it has been suggested that early diagnosis and surgical excision are feasible.<sup>161</sup>

**TABLE 19.7 Documented Cases of Gastrointestinal Neoplasias in Psittaciformes (P), Galliformes (G) and Other (O).**

	Adenoma/ Adenocarcinoma <sup>57</sup>	Basal Cell Carcinoma	Fibroma/ Fibrosarcoma	Hemangiosarcoma	Histiocytic Sarcoma <sup>86, 71</sup>	Islet Cell Carcinoma	Leiomyoma/ Leiomyosarcoma <sup>156</sup>	Lymphangioma	Myxoma/ Myxosarcoma	Papillomas <sup>71, 129, 69, 112, 200, 145</sup>	Sarcoma	Spindle Cell Carcinoma <sup>71</sup>	Squamous Cell Carcinoma <sup>71, 74, 196, 34, 180</sup>
Rhamphotheca	P	P	P								P	P	
Oropharynx			P		G,P					P	G	G	G,P
Esophagus	G				G					G,P			G,P,O
Crop	G						P			G,P			
Proventriculus	G,P,O			G						P		G	
Ventriculus	G,P,O		G	G	G		G			P	G		
Intestines	G,P		G,P	G			G,P	G	G			G	
Rectum	O		G										
Cloaca	G,P,O		P							P	P		
Pancreas	G					G					G		

Squamous cell carcinomas are the most common tumor in the oral cavity of Galliformes. Oropharyngeal tumors may be painful, ulcerative and infiltrative but rarely metastasize. Clinical signs may include dysphagia, regurgitation, vomiting, diarrhea, tenesmus and cloacal prolapse. A definitive diagnosis can be made by biopsy. Prognosis depends on the location of the tumor, the degree of tissue infiltration and the occurrence of metastasis. Many connective tissue tumors in gallinaceous birds may be caused by the leucosis sarcoma group of viral infections.<sup>149</sup> There is a high incidence of pharyngeal and esophageal squamous cell carcinoma in humans and chickens in northern China suggesting a common etiology.<sup>34, 180</sup> The incidence of gastric neoplasia seems higher in psittacine birds compared to other species. Intestinal tumors must be differentiated from metastatic oviductal or ovarian tumors by demonstrating that no primary tumors of these organs exist and that the tumor originates from intestinal mucosal epithelium or glands, rather than growing inward from the serosal surface.<sup>29</sup> Obstruction of the pancreatic ducts can occur with pancreatic neoplasias. Islet cell carcinomas can cause diabetes mellitus.<sup>74, 196</sup>

## The Small and Large Intestines

### Anatomy and Physiology<sup>101</sup>

In the majority of avian species, the duodenum is a narrow, U-shaped organ that originates from the pylorus on the right side of the ventriculus. The pale pink or yellow lobulated pancreas is located between the proximal descending and distal ascending duodenal loops (see Color 14). In some species (eg, White-tailed Sea Eagle and Jackass Penguin), secondary folds are present in the duodenum. In the Black Stork, the duodenum is twisted, while in other species (eg, Northern Fulmar and Gannet), the duodenum consists of more than one loop. The bile and pancreatic ducts often open near each other at the distal end of the duodenum. There are one, two (ducks and geese) or three (domestic fowl) pancreatic ducts and two bile ducts. When a gallbladder is present, this organ drains the right liver lobe via the right hepatocystic duct and empties into the duodenum via the cysticoenteric duct. In species where a gallbladder is absent (most pigeons, many parrots and the ostrich), the right liver lobe drains directly into the duodenum via the right hepatoenteric duct. In gallinaceous birds, the common hepatoenteric duct drains bile from both liver lobes to the duodenum. The jejunum and ileum are arranged in a number of loops, and are suspended by a long, distal mesentery on the right side of the abdominal cavity.

The vitelline diverticulum (Meckel's diverticulum), which is the remnant of the yolk duct, is located opposite the distal end of the cranial mesenteric artery. The duct of the yolk sac opens into the small intestine on a small papilla. The yolk provides nourishment, minerals, fat-soluble vitamins and maternal immunoglobulins to the embryonic bird and to the chick during the first few days of life. Just before hatching, the yolk sac is internalized and the umbilicus is closed. Precocial birds have a yolk sac that ranges from 10 to 25% of body weight at hatching, while in altricial species these values range from 5 to 10% of body weight.<sup>99</sup> Precocial birds must learn to eat during the first few days of life, while altricial birds are fed by their parents. In altricial species, resorption of the yolk is faster than in precocial species and takes about four days.

In gallinaceous birds, the yolk sac should not persist beyond six to nine days and should not be larger than pea-size between six to eight days of age.<sup>71</sup> In the ostrich, yolk sac absorption may require eight or more days. In the emu and cassowary, a yolk sac can be palpated for at least one week, but it should be reduced in size. It should be noted that at hatching, the liver of some birds is a bright yellow color due to absorption of pigments from the yolk sac (see Color 30). The liver gradually changes to the mahogany color of the adult between eight and fourteen days of age in gallinaceous birds.<sup>130</sup> In the adult chicken, the vitelline diverticulum has been found to contribute to extramedullary myelopoiesis, and it has been suggested to have a lymphoepithelial function.<sup>130</sup>

The large intestine usually consists of paired ceca and a short, straight rectum. The ceca arise at the ileorectal junction. The anatomy of the ceca varies among species. In Galliformes, the ceca are large and curve in a caudodorsal direction. Tetraonids (eg, capercaillies (grouses that eat branches and twigs of trees) have the largest ceca of any species because of their high cellulose diet.<sup>4</sup> The ostrich has a large sacculated cecum while other ratites have only vestigial ceca. Passeriformes, Columbiformes and some Psittaciformes also have vestigial ceca. Budgerigars have no ceca. Vestigial ceca usually contain large amounts of lymphoid tissue. In Galliformes, the lymphoid cecal tissue is located in the proximal part of each cecum and is called the cecal tonsil. Large ceca are involved in the bacterial fermentation of cellulose, and are also important in water reabsorption from ureteral urine. The type of food consumed by a bird influences intestinal length. Red Grouse fed a pelleted ration have a cecal length 50% shorter than those of free-ranging birds.<sup>136</sup> This is extremely important when one considers the problems with digestion that could occur if captive-raised birds were released into the wild.

The rectum lies in the dorsal part of the abdominal cavity and is a continuation of the ileum. It is usually a short, straight organ, but in some species, including the rhea, the rectum is looped or folded. In the emu, the rectum is adapted to preserve water. The high resorptive capacity may be related to increased folding of the mucosal surface, which increases the surface area by a factor of five. The emu has a limited renal concentrating ability with a maximal urine:plasma osmotic ratio of only 1.4:1.5.<sup>182</sup>


## Intestinal Diseases

### Enteritis

Many infectious agents can cause enteritis. Table 19.1 lists some infectious causes of diarrhea. Infectious stunting syndrome (ISS) in chickens (probably of viral etiology) is associated with an enteritis and inflammation of the pancreatic ducts. Most affected birds recover completely after a period of diarrhea. However, some birds develop exocrine pancreatic deficiency secondary to blockage of the pancreatic ducts (Colors 19.4 and 19.6).<sup>93</sup>

### Ileus

Ileus (intestinal obstruction) can be defined as a condition wherein the passage of intestinal contents is arrested or severely impaired. The cause of intestinal obstruction may be physical or it may be due to impaired motor function (paralytic ileus) (Color 19.18). Physical causes may be located within the lumen, in the intestinal wall or outside the intestine. Occlusion of the intestinal lumen may be caused by foreign bodies, enteroliths or parasites. Intestinal wall lesions that have been reported to cause stenosis



**FIG 19.15** A twelve-week-old Blue and Gold Macaw chick was presented for anorexia, depression and regurgitation of three days' duration. The abdomen was severely distended and doughy. Heart sounds were muffled dorsally, and severe dyspnea occurred following minimal exercise. A modified transudate was collected by abdominocentesis. Abnormal clinical pathology findings included: WBC=4500, AST=800 and LDH=1200. Radiographs indicated gaseous distention of the bowel. The bird did not respond to supportive care. At necropsy, the abdomen was filled with yellow fluid, and the bowel loops were distended with gas and were blue-black in coloration. Histologic findings were suggestive of avian viral serositis. The bird's sibling died following a similar clinical disease.

in birds include tumors, granulomas and strictures (eg, cicatrization tissue induced by foreign bodies). Extraluminal compression may occur from intussusception, volvulus mesenterialis, volvulus nodosus, incarcerated hernia mesenterialis, pseudoligaments and adhesions due to tumors or peritonitis. Vascular causes of ileus include embolism and thrombosis of a splanchnic artery or vein with infarction of a bowel segment.

Neurogenic causes (paralytic ileus) include lead poisoning, peritonitis, neuropathic gastric dilatation and enteritis (Figure 19.15).

Once the intestine is obstructed it dilates, and fluid is collected in the intestinal lumen and lost from the circulation. Clinical signs depend on the site and severity of the obstruction. The birds become rapidly dehydrated and are severely depressed. In many conditions ischemic necrosis of the intestinal wall occurs, leading to increased permeability and protein loss into the intestinal lumen. Resorption of intestinal contents, including endotoxins released from gram-negative bacteria, can cause shock. Usually complete intestinal obstruction in birds caused by intussusception or volvulus is fatal within 24 to 48 hours. A more protracted course is common with other causes of intestinal obstruction. Vomiting is usually present in complete mechanical obstruction, although this sign may be absent when the obstruction is in the caudal part of the intestinal tract. The passage of feces is diminished or absent. Diarrhea may be present with partial obstruction. Emaciation is seen when the obstruction occurs gradually from a progressive disease.

Plain radiographs may show the extent and location of the gas-filled intestinal loops. A barium enema or upper GI contrast study may be used to determine the exact location of the obstruction. The use of double contrast techniques facilitates visualization of lesions in the intestinal wall. Early diagnosis and rapid surgical correction may successfully resolve many intestinal obstructions. Birds should be stabilized with fluids and antibiotics before surgery.

### Intussusception

Intussusception of the distal part of the small intestine is occasionally reported in young gallinaceous birds secondary to enteritis or spasmodic antiperistalsis caused by a nematode infection or coccidiosis. The affected part of the intestine rapidly becomes necrotic, inducing adhesions with neighboring tissues. Death usually occurs from peritonitis and toxemia.<sup>93</sup>

In 19 cases of intestinal intussusception in gallinaceous birds and ducks, 15 cases involved the small intestine, three cases involved the ceca and one case involved the rectum. The middle and distal parts of the small intestine were usually involved. The beginning of the intussusception was usually located about 30 cm proximal to the ileocecal junction in chickens and 10-20 cm proximal in ducks. In one bird the distal end of the small intestine was invaginated into the rectum, while in another bird, 5 cm of the small intestine was prolapsed through the cloaca. In one case of cecal intussusception, the cecum passed through the rectum, and the black-red color of the apex could be seen in the cloaca. In the other cases of cecal invagination, part of the cecum was invaginated into itself. Invagination leads to partial obstruction with accumulation of fluid and gas proximal to the affected site. Rectal intussusception, which can lead to rectal prolapse, has been reported in gallinaceous birds and has been noted in Psittaciformes.<sup>51</sup>

#### **Volvulus Mesenterialis**

Volvulus mesenterialis can be defined as the twisting of a portion of the intestine around its mesenteric attachment. Volvulus mesenterialis jejuni has been reported in chickens, ducks and pigeons.<sup>51</sup> The presence of stalked tumorous egg follicles with associated adhesions and stalked mesenteric cysts are common predisposing factors. In one case (pigeon), a heavy ascarid infection was present. In the other cases, enteritis was present, which may have predisposed the birds to mesenteric torsion. In one case, a fecalith caused obstruction and torsion of the rectum just proximal to the junction with the cloaca. The entire rectum was filled with fecal material and gas. In the ostrich, torsion of the large bowel has also been reported.<sup>209</sup> It is speculated that an abrupt change in feed may be a predisposing factor.

#### **Volvulus Nodosus**

Volvulus nodosus can be defined as twisting of an intestinal loop around itself. Volvulus nodosus is usually seen in conjunction with a volvulus mesenterialis jejuni but may occur independently. Predisposing factors include adhesions and antiperistaltic movements induced by intestinal ulcerations, heavy ascarid infestations, accumulation of sand, foreign bodies and tumors.

Occlusion of the bowel can occur if intestinal loops herniate through tears in the mesentery or through the abdominal wall.<sup>51</sup> Abdominal herniation is particularly common in egg-laying hens, and may be

associated with trauma, abdominal masses, egg binding, tenesmus or endocrine abnormalities.

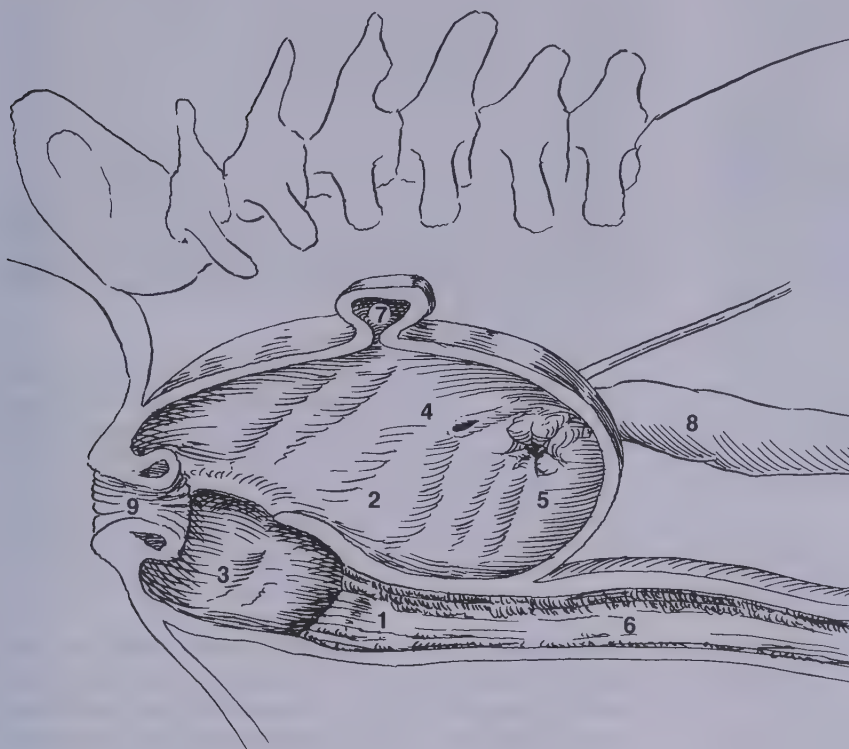
Other reported causes of intestinal obstruction include a stone lodged near the boundary between the duodenum and jejunum, sloughed koilin layer in a pigeon obstructing the distal part of the rectum where it joins the cloaca, and phytobezoars lodged in the distal part of the ileum or distal part of the rectum. Acute death was caused by rupture of an intestinal diverticulum in two of these cases and intestinal hemorrhage in one case. Other affected birds died eight to ten days after developing clinical signs, probably due to shock and absorption of intestinal toxins.<sup>51</sup> Sarcoma of the small intestine, an abscess or a cyst in the distal part of the rectum, diphtheritic enteritis with obstruction in the distal part of the small intestine and a stenosis caused by circular cicatrization tissue in the small intestine or rectum have also been reported as causes of intestinal obstruction.

Persistently feeding voluminous feedstuffs of poor nutritional value caused intestinal impaction in a group of Galliformes, Anseriformes and Columbiformes. In some cases, the entire gastrointestinal tract was involved. In others, the small intestine, rectum or cecum was the major site of impaction. Obstruction of the small intestine, which may progress to rupture, may be caused by ascarids or cestodes in Galliformes, Anseriformes, Falconiformes, Psittaciformes or Passeriformes (see Figure 36.30).<sup>91,93,154</sup> Esophageal and intestinal perforations in turkeys occurred following the ingestion of grasshoppers.<sup>215</sup> Intestinal perforation by fir cones and glass have been reported in Tetraonidae.<sup>4</sup>

#### **Coligranuloma: Hjarre's Disease**

A coliform-induced granulomatous disease (Hjarre's disease) has been reported in captive<sup>75</sup> and free-ranging Galliformes. Clinical signs are not specific and include emaciation and diarrhea. Large lesions may cause intestinal obstruction. Granulomas may also occur in the liver, ceca (which may be very large), duodenum and mesentery. The lesions should be differentiated from leukotic neoplasms and tuberculosis.





**FIG 19.16** The cloaca is composed of the 1) coprodeum, 2) urodeum and 3) proctodeum. The 4) openings of the ureter and 5) vagina can be seen in the urodeum. Other structures associated with the cloaca include the 6) rectum, 7) cloacal bursa, 8) oviduct and 9) vent.

## The Cloaca

### Anatomy and Physiology

The cloaca consists of three compartments: the coprodeum, which is directly continuous with the rectum; the urodeum, which contains the openings of the ureters and genital ducts; and the proctodeum, which opens to the outside through the lips of the vent.<sup>130</sup> The coprodeum is separated from the urodeum by the coprourodeal fold, while the urodeum and proctodeum are separated by the uroproctodeal fold (Figure 19.16). A striated sphincter muscle controls the action of the vent. In the cock, the phallus, if present, lies on the crest of the ventral lip of the vent. It consists of a median phallic body flanked on either side by a lateral phallic body and lymphatic folds. Tumescence of the phallus is due to

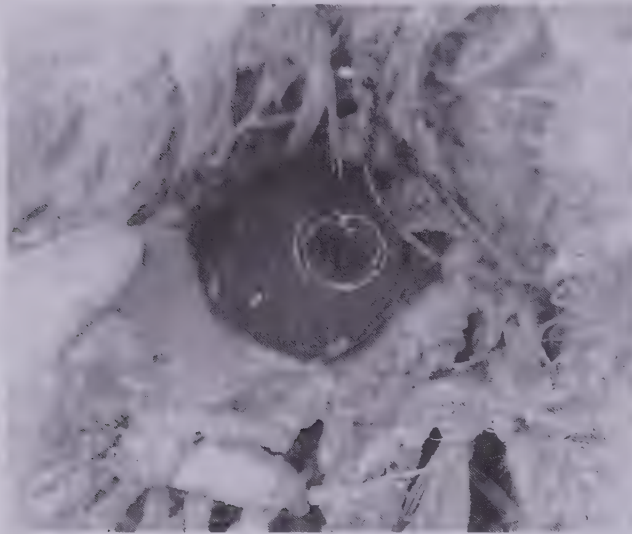lymph, which flows from the paracloacal vascular bodies that lie in the ventrolateral walls of the urodeum. In the detumescent state, the phallus is directed toward the interior of the cloaca. This type of phallus is called non-intromittent, because it does not enter the cloaca of the female but is merely applied to the protruded oviduct of the female. In adult male ducks and ratites, a distinct phallus is present that is inserted into the female cloaca during coitus. The male Vasa Parrot also has a large copulatory organ that swells considerably during the breeding season. This physiologic phenomenon in the Vasa Parrot should not be confused with cloacal pathology.

The cloacal bursa (bursa of Fabricius) is a dorsomedian pear-shaped diverticulum of the cloacal wall (see Figure 5.6). In chickens, it reaches its maximum size at six weeks when it measures 3 x 2 x 1 cm and weighs about 4 grams. It then begins to regress at about 8 to 12 weeks of age, and by 20 months it weighs only 0.5 g. In the adult, a nodular remnant of the bursa can be identified. In ratites, the neck of the bursa has a wide lumen, which does not occur in other avian species. In these birds, the proctodeum and cloacal bursa form one single cavity. The unusually wide entrance to the bursa is often incorrectly identified as a urinary bladder. The bursa is the site of differentiation of B-lymphocytes, which play an important role in the humoral defense system of the body (see Chapter 5).

During defecation, the coprourodeal fold protrudes through the vent to prevent fecal contamination of the urodeum and proctodeum. Similarly, the uroproctodeal fold protrudes through the vent during egg laying. Urine deposited in the urodeum moves retrograde into the rectum (and ceca, if present), where reabsorption of water takes place. Often birds will have watery excreta when they are excited, because they defecate before water reabsorption is complete.

### Clinical Examination

Clinical signs indicative of cloacal disorders may include flatulence, tenesmus, soiled pericloacal area,



**FIG 19.17** A two-year-old Umbrella Cockatoo was presented with a four-day history of tenesmus. The bird was fed a seed-based diet and was constantly demanding affection from its owner. Physical examination findings included the accumulation of excrement around the vent and protrusion of a smooth, glistening, pink cloaca. The bird had a moderate number (15%) of gram-negative bacteria in the feces and was placed on injectable enrofloxacin and medroxyprogesterone acetate. The mucosa of the cloaca was coated with apple cider vinegar to check for papillomas. None were detected. The bird responded to the antibiotic and hormone therapy as well as to a change in diet to a formulated product and behavior modification. The tenesmus stopped, and there were no further problems with cloacal prolapsing.


protruding tissue from the cloaca and foul-smelling feces. Examination of the cloaca should start with the feathers and skin around the vent. Normally these structures should be clean, and there should be no signs of inflammation (Color 19.8). An abnormal acidic smell can be a sign of cloacitis, which is often associated with cloacal papillomatosis.

## Cloacal Diseases

### Cloacal Prolapse

A prolapse involving the cloaca may contain intestines, oviduct and one or both ureters. The appearance of smooth, glistening, pink tissue is an indication that the cloaca has prolapsed, which may be caused by sphincter problems, chronic irritation of the rectum or tenesmus. A cloacal prolapse may cause severe constipation and toxemia (Color 19.10). In gallinaceous birds, cannibalism by cage mates may result in cloacal rupture and evisceration of the affected individual.

Acute cloacal prolapse associated with egg laying generally responds to manual reduction, followed by



**FIG 19.18** A four-year-old male Amazon parrot was presented with a history of straining to defecate and emitting a foul odor. A large pericloacal mass was palpable on physical examination. The mass was ulcerated, hyperemic, moist and associated with a yellowish-green discharge. Cytologic evaluation of samples collected from within the mass revealed gram-negative rods, degranulating heterophils and macrophages containing bacteria. Radiographs showed an extensive pericloacal mass that was causing cloacal distention (arrows) and cranial displacement of the intestines. The mass was surgically debrided, and the bird was successfully treated with piperacillin.

application of two simple transverse stay sutures perpendicular to the vent. Postoperative straining can be prevented by applying xylocaine gel in the cloaca BID. The cause of the straining or increased abdominal pressure should be corrected to prevent further prolapsing.

In cockatoos, chronic cloacal prolapse may be associated with sexual behavior in the presence of the owner, or can be caused by idiopathic straining (Figure 19.17). A combination of ventral cloacopexy<sup>173</sup> and cloacal mucosal “reefing” has been used to correct chronic cloacal prolapse (see Chapter 41).

### Cloacitis

A sporadically occurring, chronic inflammatory process of the cloaca with a very offensive odor, commonly known as “vent gleet,” may occur in laying hens and occasionally in males. A yellow diphtheritic membrane may form on the mucosal surface, and urates and inflammatory exudate contaminate the skin and feathers around the vent. The cause is unknown. Treatment consists of cleaning the area and applying a local antibiotic ointment.<sup>93</sup>

A similar condition has been reported in ducks. Scarring, which reduces the elasticity and diameter of the cloaca and may prevent egg laying and, in extreme cases, defecation, is a complication of cloacitis (Figure 19.18).<sup>71,93</sup>

### *Neisseria*, *Mycoplasma* spp. and *Candida albicans*

Bacteria (especially *Neisseria* and *Mycoplasma* spp.), and *Candida albicans* have been associated with a venereal disease affecting ganders.<sup>9,14,188</sup> It seems likely that the cloacitis observed in drakes has a similar etiology, but an association has not been confirmed.

Cloacal infections may occasionally be observed in other species and may result from trauma, surgery or infectious diseases. Uroliths or fecaliths may form during the process. Cloacitis is often seen in psittacine birds suffering from cloacal papillomatosis.

### Phallus Prolapse and Venereal Disease in Anseriformes


The phallus may not retract into the cloaca in some sexually mature drakes. The problem is usually associated with an extensive infection in the erectile tissue at the base of the phallus. It has been suggested that the etiology of this condition is traumatic, because the incidence is higher under conditions where the drakes have to mate with the females out of the water.<sup>71</sup> Drakes with females that have cloacitis may have a phallus infection, suggesting that an infectious agent can play a role in phallus prolapse.

### Cloacal Stricture

Infections, surgical manipulation of the cloaca (particularly for removal of papillomas) and trauma may cause stricture of the vent, requiring surgical recreation of an opening and appropriate aftercare to prevent a recurrence.<sup>173</sup>

### Cloacal Impaction

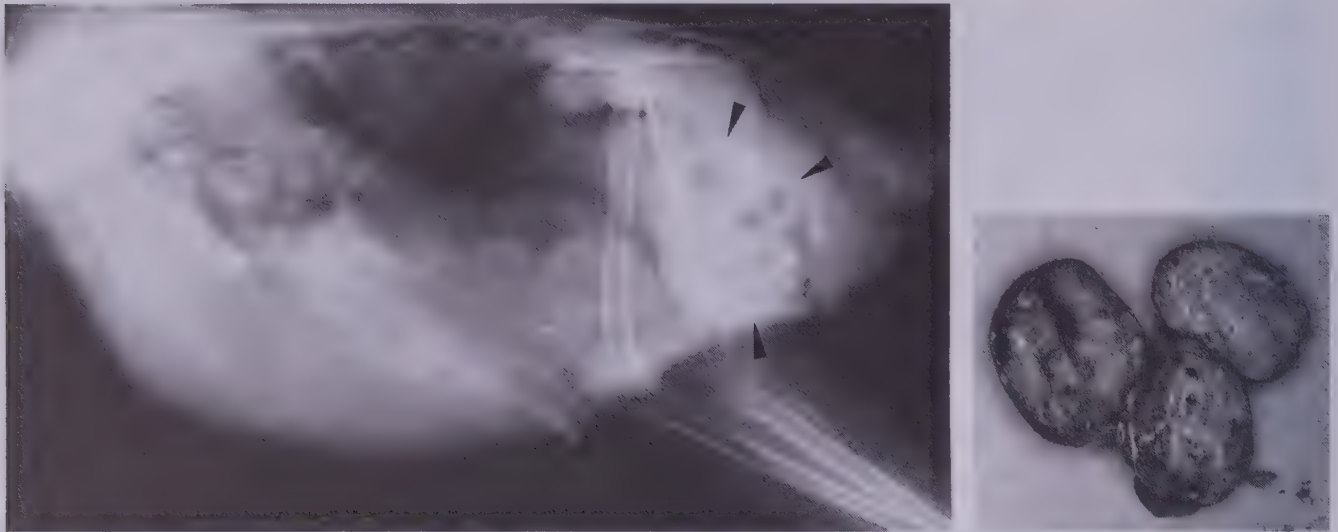
Cloacal impaction may occur from foreign bodies (eg, potato chunks in Galliformes), fecaliths, concretions of urates and retained necrotic eggs (Figure 19.19). Uroliths can vary from six to eight millimeter-thick concretions on the cloacal wall to solid masses the size of a chicken egg. In any case of cloacal impaction, passing excrement is difficult or impossible and can cause congestion of the ureters and dilatation of the intestines as far proximal as the duodenum. Renal failure and visceral gout may occur if the ureters are blocked.<sup>51</sup>



**FIG 19.19** A mature Amazon parrot was presented with a two-day history of depression, anorexia and straining to defecate. The abdomen was distended. When a cotton swab was inserted into the cloaca, excrement would “squirt” out. When the swab was removed, no excrement would be released. Several uroliths that were functioning as a valve were identified at the opening of the cloaca. When the uroliths were removed, the bird was able to defecate normally.

Cloacoliths composed of urates have been observed in numerous psittacine birds, particularly macaws and Amazon parrots.<sup>173</sup> The etiology is unknown. Treatment consists of segmenting and removing the concretions. Cloacal impaction may also occur secondary to cloacal infections and cloacal stricture (Figure 19.20).

Cloacal papillomatosis is a well known disease in psittacine birds and is recognized clinically as a glistening red or pink cauliflower- or strawberry-like mass rising from the cloacal orifice (Color 19.9).<sup>42,67,86,112,173,190,196,200</sup> Early lesions are characterized by a rough-appearing mucosa at the mucocutaneous junction of the cloaca. Other presenting signs may include tenesmus, melena, foul-smelling feces, flatulence, pasting of the vent and cloacoliths. The abnormal odor is likely to be caused by bacterial proliferation in the crypts caused by the papillomas. The incidence of disease is higher in New World parrots, but Old World parrots may also be affected.<sup>69</sup> The condition is frequently misdiagnosed as a cloacal prolapse. Applying an acetic acid solution (apple cider vinegar) to cloacal epithelium will change the color of papillomatous tissue to white. A definitive diagnosis can be made after histopathologic examination of a biopsy. Cloacal papillomas are often associated with similar lesions in the oropharynx, choana, esophagus, crop, proventriculus, ventriculus and occasionally mucosa of the eye and nose.<sup>67</sup> The etiology is presently unknown. There seems to be a high correlation between neoplasia of bile ducts and pancreatic ducts and papillomatosis in psittacine birds.<sup>41,69,86,159</sup>



**FIG 19.20** A ten-year-old Blue-fronted Amazon Parrot was presented with depression, failure to defecate and a distended abdomen. The referring veterinarian had placed a purse-string type suture to correct what was diagnosed as a cloacal prolapse three days before presentation. The abdomen was distended and tight. Unproductive tenesmus was noted by a constant “winking” of the cloaca. The purse-string suture was removed and the bird released a large quantity of excrement; however, the tenesmus continued. Survey radiographs revealed several elongated mineralized masses in the cloacal area (arrows). Three large uroliths were removed from the cloaca with forceps. The cloacal mucosa was hyperemic and ulcerated. A large cloacal papilloma was evident in the left lateral wall of the cloaca. The papilloma was cauterized by specific application of silver nitrate, and the cloaca was flushed with a dilute povidone-iodine solution. Removal of the papilloma required two further treatments. Papillomas that protrude from the cloaca must not be confused with a cloacal prolapse, as initially occurred in this case.

Various techniques have been used to treat cloacal papillomas, including cryosurgery, chemical cauterization, radiosurgery and autogenous vaccination,<sup>173</sup> but the reported spontaneous remissions and intermittent nature of the disease<sup>67,69,129,200</sup> makes evaluation of the various treatments difficult. The introduction of birds with papillomas to a breeding facility should be prevented by performing a thorough physical examination at the beginning and end of the quarantine period. Of 41 papillomatous lesions, growth was benign in 40, but one single case was diagnosed as carcinoma *in situ*.<sup>190</sup> Other tumors should be considered in the differential diagnosis.<sup>13,58,15,163</sup> Papillomas are most easily removed from the cloaca with careful, staged cauterization with a silver nitrate stick. The silver nitrate must come in contact only with the tissue intended to be removed to prevent severe burns of normal cloacal mucosa (Color 19.9).

## The Pancreas

### Anatomy and Physiology

The pancreas is situated on the left ventral side of the abdominal cavity between the descending and ascending loops of the duodenum. There are three lobes: dorsal, ventral and splenic. The dorsal and ventral lobes are usually connected (except in the Mallard and pigeon). The splenic lobe extends cranially from the dorsal or ventral lobe. There are one, two or three pancreatic ducts, which usually drain the pancreatic secretions into the ascending part of the duodenum. The exocrine pancreatic enzymes that are present in the duodenum include amylase, lipase, trypsin and chymotrypsin, which facilitate degradation of carbohydrates, fats and proteins, respectively. Trypsin and chymotrypsin are secreted as inactive precursors, and they become active only when they enter the duodenum. The activator is the locally produced enzyme, enterokinase, which changes trypsinogen to trypsin. This prevents the pancreas from being digested by its own enzymes.<sup>49</sup>

### Diagnostic Considerations

The pancreas has both endocrine and exocrine functions. The former are discussed in Chapter 23. Many postmortem lesions have been reported in avian pancreata.<sup>70</sup> There are two major clinical manifestations of pancreatic disease. If no pancreatic enzymes are available in the duodenum, maldigestion and passing of feces with excessive amylum and fat will occur. Affected animals may have voluminous, pale or tan, greasy feces (see Color 8). Fat in the feces can be demonstrated by Sudan staining. Interpretation of microscopic examination of feces for undigested food such as fat, starch grains and muscle fibers is complicated by variation in diets and by changes due to intestinal causes of malabsorption. Measurement of fecal proteolytic activity can be performed in several ways. The X-ray film gelatin digestion test is an unreliable assay of fecal proteolytic activity.<sup>217</sup> A test for fecal proteolytic and amylase activity is probably more reliable for use in birds.<sup>214</sup>

### Pancreatic Diseases

#### Acute Pancreatic Necrosis/Acute Pancreatitis

The pathogenesis of acute pancreatitis involves the activation of pancreatic enzymes in and around the pancreas and in the bloodstream, resulting in coagulation necrosis of the pancreas, and necrosis and hemorrhage of peripancreatic and peritoneal adipose tissue (see Color 14). Affected birds may be in shock, and radiographs may show loss of abdominal detail due to peritonitis and fluid accumulation in the peritoneal cavity. Dilatation of the small intestine may be visible due to an accompanying ileus. Increased plasma amylase activity (secondary to destruction of exocrine pancreatic cells) has been reported in chronic active pancreatitis in birds. Elevated plasma amylase may also occur with occlusion of the main pancreatic duct,<sup>164</sup> and might be a component of the infectious stunting syndrome in chickens.<sup>181</sup> Lipemia may be present. A diagnosis of pancreatitis can be confirmed by endoscopy or exploratory laparotomy.

Obesity seems to be a predisposing factor of pancreatitis in birds. Treatment should include withholding food and oral medication for 72 hours, correction of fluid and electrolyte balance and prophylactic use of antibiotics. Dietary fat intake should be restricted to decrease the secretory load of the pancreas.<sup>70,158</sup>

#### Chronic Pancreatic Fibrosis/Chronic Pancreatitis/Pancreatic Exocrine Insufficiency

A decrease in pancreatic glandular tissue or fibrosis may occur as the result of a chronic inflammatory process and cause clinical changes suggestive of pancreatic exocrine insufficiency (PEI).<sup>70,160</sup> Further studies on the relation between pancreatic disease and plasma amylase and plasma lipase activities in birds are needed to facilitate clinical diagnosis; however, birds with a malabsorption syndrome and high amylase and lipase levels may respond to therapy with pancreatic enzymes, suggesting PEI. Frequently, the cause of PEI is undetermined. Pancreatic fibrosis was reported in two psittacine birds with chronic chlamydiosis.<sup>70</sup>

High dietary levels of zinc may cause dilation of acinar lumina and degenerative changes in acinar cells including depletion of zymogen bodies, cytoplasmic vacuolization, the presence of hyaline bodies and other electron-dense debris, necrosis of individual acinar cells and fibrosis.<sup>46,48,98,204,216</sup> Excess levels of zinc also interfere with exocrine pancreatic function.<sup>118</sup>

Pancreatic atrophy and fibrosis accompanied by impaired fat digestion have been reported in chickens on a selenium-deficient diet.<sup>192,193</sup> It has been shown that addition of 0.1 ppm selenium to the diet could reverse the clinical signs and cause complete pancreatic acinar regeneration.<sup>72</sup>

#### Infectious Stunting Syndrome (ISS)

Infectious stunting syndrome (ISS)<sup>93,1709</sup> has many synonyms including runtting and leg weakness,<sup>104</sup> runtting syndrome,<sup>147</sup> infectious stunting,<sup>19,171</sup> pale bird syndrome,<sup>65,116,142</sup> malabsorption syndrome,<sup>142</sup> brittle bone disease,<sup>199</sup> diarrhea and stunting,<sup>93</sup> runtting and stunting syndrome,<sup>165</sup> and stunting and runtting syndrome.<sup>125</sup> Clinical signs include growth retardation, steatorrhea, polyphagia, coprophagia, soft bones, swollen tibial epiphyses, rachitic ribs and abnormal feather development. The latter is possibly related to decreased circulating concentrations of thyroxine (see Chapter 23).<sup>93,170</sup>

Although the etiology of this disease is not known, a virus is likely to be the etiologic agent,<sup>170</sup> but mycotoxins, other toxins, *Campylobacter* spp. and spirochetes may also be involved.<sup>93,189</sup> Chickens, turkeys and guineafowl have all been documented with this disease. Most birds develop enteritis and inflammation of the pancreatic ducts and recover completely after a prolonged period of diarrhea.<sup>93</sup>

Pancreatic lesions are thought to be incited by inflammatory reactions in the pancreatic ducts, which may result in complete blockage of the pancreatic ducts in a small proportion of affected birds. Blockage leads to vacuolization and shrinkage of exocrine cells and atrophy of the acini. As the disease progresses, much of the exocrine tissue is obliterated by fibroplasia. The changes are similar to those induced after experimental ligation of the pancreatic ducts.<sup>124,126</sup> The resulting exocrine pancreatic insufficiency leads to maldigestion,<sup>173</sup> steatorrhea and inappropriate absorption of fat-soluble vitamins. The skeletal changes are likely to be related to reduced absorption of vitamin D and calcium, the latter being bound to the excessive amounts of fat and excreted in the feces.<sup>93</sup>

#### Paramyxovirus Infections in Psittaciformes and Passeriformes

Paramyxovirus type III is a common infection in *Neophema* spp. and *Platyserca* spp., and is also encountered in some passerine birds, especially Estrildidae.<sup>184,198</sup> Torticollis, other neurologic signs, cachexia and death are common. Some infected birds develop a yellow-to-white chalky stool that contains large amounts of starch. In almost all cases, a pancreatitis can be detected. Histologically, the lesions can vary from a few lymphoid follicles to massive infiltration with lymphocytes and plasma cells. In some cases, this is clinically manifested as pancreatic exocrine insufficiency.

Campylobacter infections in Estrildidae cause similar discoloration of the feces. Histologically, atrophy of the microvilli of the small intestine, which may cause a malabsorption syndrome, can be found.<sup>47</sup>

#### Pancreatic Tumors

A high correlation between neoplasia of bile ducts and pancreatic ducts and internal papillomatous diseases in psittacine birds has been suggested.<sup>41,69,86,159</sup>

## The Pleuro-peritoneum

### Anatomy and Physiology<sup>101,130</sup>

The coelomic cavity in birds is subdivided by peritoneal, pleural and pericardial reflections into eight different cavities, excluding the eight cavities that are formed by the air sacs. Birds do not have a

diaphragm. They have two pleural cavities and five peritoneal cavities (Table 19.8). Clinically, these cavities dictate the location and spread of pathologic processes within the coelomic cavity and are important when considering surgical approaches to the abdominal organs (see Color 13, Anatomy Overlay).

TABLE 19.8 Reference Guide to the Coelomic Cavities in Birds

- Right pleural cavity (RPC)
- Left pleural cavity (LPC)
- Pericardial cavity (PC)
- Left ventral hepatic peritoneal cavity (LVHPC)
- Right ventral hepatic peritoneal cavity (RVHPC)
- Left dorsal hepatic peritoneal cavity (LDHPC)
- Right dorsal hepatic peritoneal cavity (RDHPC)
- Intestinal peritoneal cavity (IPC)

As in mammals, both the parietal and the visceral pleura are reflected over the lungs, but in birds a large surface of the parietal pleura is joined to the visceral pleura by fibrous strands. The degree of obliteration of the pleural space depends on the species. In some birds, including the domestic fowl, extensive areas of pleural cavity persist in the adult (in the chicken, dorsolateral). In these areas the lungs can collapse inward when the pleural cavity is opened. Some fluid can accumulate in these areas under certain disease conditions.

The pericardium in birds is essentially similar to that in mammals. Because the lungs are situated dorsally and there is no diaphragm, the heart is not enclosed by the lungs. The liver lies on both sides of the heart, and the parietal pericardium becomes continuous with the peritoneum. During embryonic development, the pleural cavity becomes separated from the peritoneal cavity by the pulmonary fold, which is a double-layered sheet formed by the parietal pleura (dorsal) and the parietal peritoneum (ventral). The cranial and caudal thoracic air sacs develop as dilatations from the bronchi and penetrate into this double-layered sheet, splitting the dorsal from the ventral layer. The dorsal layer becomes fused with the adjacent wall of the thoracic air sac, becomes tough and tendinous and acquires fascicles of striated muscle along its lateral edge that attach to the ribs (costoseptal muscle). This is called the horizontal septum, saccopleural membrane or pulmonary aponeurosis. The ventral layer becomes fused with the ventral walls of the thoracic air sacs and is called the oblique septum, which occurs bilaterally. Unlike the

horizontal septum, the oblique septae or saccoperitoneal membranes remain thin and look like air sac walls.

The partitions in the peritoneal cavity proper are formed by five sheets of peritoneum which, apart from the mesentery, do not occur in mammals.

The combined dorsal and ventral mesentery form a continuous midline vertical sheet from the dorsal to the ventral body wall as far caudally as the ventriculus. Caudal to this level, only a dorsal mesentery is present supporting the intestines. Cranially, the mesentery is continuous with the pericardium.

The posthepatic septum is composed of a left and a right double-layered sheet. It extends caudal to the liver from the last thoracic vertebra in a ventrocaudal direction to the caudal wall of the peritoneum. The posthepatic septum has connections with the visceral peritoneum enclosing the liver.

The ventriculus is enclosed between the two layers of the left sheet of the posthepatic septum. The principal peritoneal fat depot is located between the two peritoneal layers of the posthepatic septum. The lateral layers of the right and left sheet form the medial wall of the right and left hepatic peritoneal cavities. Because the right and left sheets are fused cranially and unite in the midline ventrally, the liver is separated from the rest of the viscera by this posthepatic septum. The posthepatic septum (together with the mesentery) divides the peritoneum into three principal cavities: the intestinal peritoneal cavity dorsomedially, and two lateral hepatic cavities that enclose the liver. The left and right hepatic cavities are further subdivided by the left and right hepatic ligaments, which run horizontally and are continuous with other peritoneal sheets (medially with the mesentery, cranially with the parietal peritoneum, caudally with the posthepatic septum and laterally with the oblique septum), thus forming the LDHPC, LVHPC, RDHPC and RVHPC, respectively. The LVHPC and RVHPC are large, elongated cavities extending from the left and right liver lobe, respectively, to the caudal body wall. The LDHPC and RDHPC are much smaller and are in contact with the craniodorsal aspects of the left and right liver lobes. The IPC is enclosed between the left and right hepatic cavities and extends from the liver to the vent. The intestines and gonads are suspended by mesenteries within the IPC. Each peritoneal cavity is blind and has no connections, except for one that exists between the IPC and the LDHPC. The peritoneum

plays an important role in the defense system of the body by closing perforations, containing infection and providing blood supply. The peritoneum heals rapidly after damage. Peritoneal injuries normally heal without the formation of adhesions, but in the presence of infection, ischemia or foreign bodies, fibrous adhesions may occur. The peritoneal surface allows the passive diffusion of water and solutes of low molecular weight between the peritoneal cavities and the subperitoneal vasculature. Larger molecules and particulate matter enter the bloodstream via the lymphatics. Healthy birds have a thin film of fluid in the peritoneum, which facilitates organ movement. The presence of free fluid in the peritoneal cavities is considered pathologic.

From the anatomic relationships outlined above, it is clear that diseases associated with the female genital tract (ovarian adenocarcinoma with implant metastasis on the peritoneum, egg-related peritonitis) are often confined to the IPC and LDHPC. Peritonitis from gastric perforation may be restricted to the LVHPC. Rupture of the liver can lead to accumulation of blood in one of the hepatic peritoneal cavities. Accumulation of transudate is most often seen in the LVHPC and the RVHPC and the PC, although the dorsal hepatic and peritoneal cavities may sometimes be involved. It is even possible to see some fluid accumulate in the RPC and LPC.

### Ascites

Ascites is defined as the accumulation of serous fluid within one or more of the peritoneal cavities and may be caused by peritoneal and extraperitoneal diseases. Accumulation of fluid in one or more peritoneal cavity can result in abdominal distention. Large amounts of ascitic fluid may compress the pulmonary air sac system, causing dyspnea. During physical examination, abdominal distention can be recognized by the increased distance from carina to pubic bones. A bird with ascites should be handled carefully to prevent rupture of the air sacs, which can lead to immediate asphyxiation. Clinical signs may or may not occur with abdominal fluid accumulations. In liver disease, yellow or green feces may be seen. In neoplastic or liver disease, palpable masses may be present in the abdomen (Figure 19.21).

In ascites associated with liver disease (including hepatic congestion due to cardiac disease), increased portal venous hydrostatic pressure and decreased portal venous colloid osmotic pressure are important factors. Increased subperitoneal capillary permeabil-



**FIG 19.21** A mature caique was presented with a two-week history of progressive dyspnea and abdominal swelling. Note the distal protrusion of the abdomen. Fluid collected by abdominocentesis was yellow and was characterized as a transudate (SpGr=1.012, Protein=1.8 mg/dl, few cells). The liver was swollen and the blood was lipemic. An exploratory surgery was performed, at which time a soft-shelled egg was removed from the uterus. Soft-shelled eggs are most often related to a primary etiology of malnutrition, which results in the fatty liver, lipemia and dystocia leading to possible egg-related peritonitis.

ity, decreased peritoneal lymphatic drainage and leakage from disrupted abdominal viscera (bile, urine) may cause non-liver-related ascites. Sometimes the definition of ascites is restricted to non-inflammatory transudate,<sup>44</sup> but the distinction between transudate and exudate is not always clear under clinical conditions. Conditions where an inflammatory exudate is present can be defined as peritonitis.

Although it has been suggested that chylous ascites (ascites due to the presence of lipoproteins and chylomicrons in the peritoneal cavity) can occur in birds,<sup>44</sup> current information on avian physiology sug-

gests that the absorption of fat from the intestine in birds is different from what occurs in mammals. The lymphatic system is not as well developed in birds as in mammals. The lymphatic vessels are small, the largest being hardly more than 1 mm in diameter, and the thoracic duct is only 1.5 mm across.<sup>148</sup> Because there is no functional intestinal lymphatic system in birds, absorbed lipids enter the portal system as large, very low-density lipoproteins. These lipoproteins have been defined as “portomicrons” in contrast to “chylomicrons” (the fat-rich particles that are absorbed by mammals).<sup>16</sup> Chylous peritonitis, which occurs in mammals secondary to rupture of the lymphatic vessels or lymphatic congestion, is therefore theoretically not possible in birds.

Blockage of lymph drainage can be an important factor in the development of ascites in birds. For example, implantation of oviduct carcinoma on the intestinal peritoneal cavity rapidly induces ascites from portal hypertension secondary to pulmonary hypertension. Right ventricular failure with valvular insufficiency results in increased pressure in the vena cava where the lymph ducts connect to the circulatory system.<sup>93</sup>

Pseudochylous ascites is the condition whereby turbid or milky abdominal fluid is seen. This may be caused by cellular debris and is associated with abdominal malignancies and infections.<sup>57</sup> A goose with a severe fatty degeneration of the liver accompanied by extreme hepatomegaly and hyperlipemia developed severe dyspnea secondary to pseudochylous ascites of unknown origin. A milky-appearing ascitic fluid was demonstrated in the ventral hepatic peritoneal space by laparotomy. Removal of 0.5 liter of ascitic fluid and diuretic therapy decreased the dyspnea. The concentration of total triglycerides in the ascitic fluid was 55 mmol/l, while total triglycerides in the plasma was 77 mmol/l. The ascitic fluid:plasma triglyceride ratio in this bird was opposite to what would be expected in chylous ascites, although the physical characteristics of the fluid were highly suggestive for this condition.

Edema may occur in organs and tissues in conjunction with ascites caused by hypoalbuminemia. It may be recognized clinically as edema of subcutaneous tissues of the abdomen or pitting edema on the feet (ducks with amyloidosis).



### Diagnostic Methods

Radiographically, ascites is characterized by a diffuse, ground-glass haziness in the abdomen, and specific organs are often impossible to delineate. Administration of furosemide for several days or abdominocentesis will increase the diagnostic value of the radiographs. The cardiohepatic silhouette may appear widened, and the air sacs may appear narrowed laterally on the ventrodorsal view. Occasionally, ileus or enlargement of the heart, liver, spleen or other abdominal organs may be detected, providing information with respect to the primary disorder. Ultrasonography is a noninvasive technique that is valuable in the differential diagnosis of abdominal enlargement and ascites (see Chapter 12).<sup>27,100</sup>

Abdominocentesis provides diagnostic information in birds with ascites (see Chapter 10).<sup>33</sup> Peritoneal lavage is possible, but extreme caution should be practiced to prevent iatrogenic puncture of the pulmonary air sac system and asphyxiation of the bird. Abdominocentesis should be performed when one is certain that free fluid is present to prevent inadvertent organ puncture. Transudate is characterized by a clear to pale-yellow color, a low specific gravity (<1.020), low protein (1 g/dl) and a low cellularity. Exudate is characterized by a high specific gravity (>1.020), a high protein content (3 g/dl) and possible presence of many inflammatory and mesothelial cells. Exudates may clot during sampling and may require an anticoagulant for proper cytologic examination. Septic exudates contain intracellular bacteria. Identifying a wide variety of bacteria suggests perforation of the gastrointestinal tract or the abdominal wall.

### Clinical Biochemistry and Hematology

Laboratory investigations in birds with ascites should include plasma chemistries for hepatic and renal disease (AST, CPK, LDH, bile acids, protein electrophoresis, uric acid, urea). Renal protein loss should be evaluated by a quantitative determination of protein in the urine. Additionally, a PCV and total WBC and differential are indicated. When peritonitis is present, a marked leucocytosis can be observed, with the predominant cell type being heterophilic leukocytes. Juvenile heterophils (band cells) are normally not present in the peripheral blood and indicate severe inflammation. Granulomatous diseases and avian tuberculosis are often associated with monocytosis.

In neoplastic disease, exfoliated neoplastic cells may be encountered. Hemorrhagic effusions may have the

appearance of peripheral blood and have leukocyte and erythrocyte numbers comparable to peripheral blood. Chronic hemorrhagic effusions may show signs of erythrophagocytosis. Urine in the abdominal cavity can be recognized by the presence of spherical urate crystals.

In mammals, LDH and the ascites serum protein and LDH ratios are helpful in differentiating between exudates and transudates.<sup>15</sup> The ascitic fluid amylase:plasma amylase ratio is useful for the diagnosis of pancreatic ascites. Ascitic fluid with a milky appearance and a triglyceride:plasma triglyceride ratio <1 is suggestive of pseudochyloous ascites because chyloous ascites does not occur in birds.

### Differential Diagnosis<sup>44,62,71,89,97,112,170</sup>

Abdominal enlargement due to ascites should be differentiated from other causes of abdominal enlargement such as obesity, neoplasia, herniation, egg-related peritonitis, granuloma, gravid uterus, gastrointestinal dilatation, hepatomegaly, splenomegaly and renomegaly. A cystic right oviduct can also pose a diagnostic challenge to the clinician because these fluid-filled cysts may reach a size up to 10 cm in diameter and may compress the abdominal viscera, mimicking ascites.

Chronic liver disease can cause ascites through intrahepatic portal hypertension due to hepatic fibrosis (aflatoxicosis, coal tar poisoning, plant toxins from *Crotalaria* spp. or rapeseed, bacterial or viral cholangiohepatitis). The accompanying hypoalbuminemia contributes to ascites formation. Blood chemistries, bile acids, low plasma albumin and liver biopsies are useful diagnostic techniques. Ascites from chronic liver disease is common in Anseriformes with amyloidosis and in mynahs, toucans and birds of paradise with iron storage disease.

Ascites may occur as part of generalized edema secondary to hypoalbuminemia caused by chronic liver disease, nephrotic syndrome and protein-losing enteropathy.

Neoplasias, particularly abdominal carcinomas (especially ovarian adenocarcinoma with implants on intestinal peritoneal cavity), may block lymph drainage, causing ascites with a high-protein content that contains neoplastic cells.

Congestive heart failure (right ventricular failure; RVF) is a common cause of ascites in gallinaceous birds and ducklings that are raised at high altitudes

and forced to grow at a rapid rate. Low environmental temperature and high-sodium diets have been associated with RVF and ascites in chickens and turkeys. Furazolidone causes cardiomyopathy in turkeys, ducks and chickens. *Fusarium moniliforme* var. *subglutans* produces the mycotoxin moniliformin that induces myocardial degeneration with associated hydropericardium and ascites in chicks, ducklings and turkey poults. RVF and ascites may also be associated with ricketts. Congenital ventricular septal defect can cause a left to right shunting of blood and result in RVF and ascites. Numerous drugs have been shown to cause cardiovascular malformations in chick embryos.

Exposure to chlorinated biphenyls, dioxin (toxic fat syndrome), creosol and coal tar products can damage the endothelial lining of blood vessels, causing hydropericardium and ascites.

Viral infections such as Marek's disease tumors may occur in the heart, and viruses of the leukosis-sarcoma group can cause various tumors associated with ascites (hemangioma and hemangiosarcoma of mesentery, erythroblastosis, mesotheliomas). Other viruses including avian polyomavirus and avian viral serositis can cause myocarditis and pericarditis leading to RVF and ascites.

Bacterial endocarditis and myocarditis may result in cardiac insufficiency (RVF) and ascites. *Staphylococcus*, *Streptococcus* and *Erysipelothrix* spp. have been associated with endocarditis, while bacterial myocarditis may occur in listeriosis, pullorum disease, fowl typhoid and other bacterial infections. *E. coli* peritonitis may be associated with ascending infections from the female genital tract.

*Mycobacterium* spp. infections can cause blockage of lymph drainage in some cases. Acid-fast (Ziehl-Neelsen) staining organisms may be noted in ascitic fluid. Peritonitis can occur from foreign bodies penetrating the intestinal tract and secondary to infections in the lungs, air sacs, pericardium, female reproductive organs and gastrointestinal tract. *E. coli*, staphylococci and streptococci can often be isolated in serofibrinous peritonitis in females as a result of ascending infections from the uterus. Aspergillosis air sacculitis can also involve the peritoneum.

Penetrating or nonpenetrating trauma to the abdomen can cause urate ascites, bile ascites, pancreatic ascites and hemoperitoneum (rupture of liver, spleen or kidney). Enlargement of an organ or other space-

occupying masses can block lymph drainage, resulting in ascites.

Cystic right oviduct occurs if the right Muellerian duct does not regress normally. The oviduct remnant is attached to the cloaca by a narrow stalk. Ultrasonography can differentiate between free fluid and fluid encapsulated within a cyst (see Chapter 12).

Therapy for ascites should be aimed at the primary disorder. Therapeutic removal of ascitic fluid is indicated only if ascites is accompanied by a life-threatening dyspnea. If hypoproteinemia is present, abdominocentesis will remove protein from a bird that may have compromised liver or kidney function. Diuretic therapy (furosemide) can be administered to effect. Low-sodium diets may be helpful.

Accumulation of fat in the peritoneal cavity can cause dyspnea through compression of the thoracic and abdominal air sacs. Obesity is an important differential diagnosis in birds with dyspnea and abdominal enlargement. It is commonly seen in parrots, cockatoos and pigeons on high-energy diets with restricted exercise, but many other species can be affected.

Ventral abdominal hernias are common in budgerigars and racing pigeons (particularly hens). A causal relationship with hyperestrogenism, which causes weakening of the abdominal muscles, has been suggested. The hernia may contain fat, loops of bowel or other abdominal organs. Incarceration of the intestinal tract is a rare but possible complication. A diagnosis can be made by physical examination and radiology. Treatment involves surgical closure of the abdominal hernia. Removal of excess fat that is primarily located between the sheets of the posthepatic septum facilitates the procedure. A perineal hernia containing a persistent right oviduct was observed by the author in a budgerigar.

The most common causes of peritonitis in birds are foreign bodies (from alimentary tract or through abdominal wall) and egg-related peritonitis. The latter condition can be the result of oviduct or ovarian dysfunction. Conditions such as false layer, internal layer, impaction of oviduct and torsion of egg yolk followed by infarction should be considered. Abdominocentesis is indicated to collect samples for further examination (cytology, culture).

## References and Suggested Reading

- Andersen WI, et al: Proventricular hemangiosarcoma identified in a broiler at slaughter. *Avian Dis* 32:148-150, 1988.
- Appleby EC, Keymer IF: More tumors in captive wild animals: A second brief report. International Symposium on Diseases in Zoo Animals, Helsinki, 1971, pp 241-244.
- Arnall L, Keymer IF: Bird Diseases. London, Ballière-Tindall, 1975.
- Aschenbrenner H: Rauhfußhühner [Tetraonidae]. In Gabrisch K, Zwart P (eds): Krankheiten der Wildtiere [Diseases of Wild Animals]. Hannover, Schlutersche, 1987, pp 319-364.
- Austic RF, Scott ML: Nutritional diseases. In Calnek B, et al (eds): Diseases of Poultry. Ames, Iowa State University Press, 1991, pp 45-71.
- Baker JR: A proventricular adenoma in a Brazilian teal (*Amazonetta brasiliensis*). *Vet Rec* 107:63-64, 1980.
- Baker JR: Going light in budgerigars. *A-Z Nachrichten* 32:402-405, 1975.
- Baker JR: Trichomoniasis, a major cause of vomiting in budgerigars. *Vet Rec* 118:447-448, 1986.
- Barnes HJ: Miscellaneous bacterial diseases. In Calnek BW, et al (eds): Diseases of Poultry 9th ed. London, Wolfe Publishing Co, 1991, pp 289-293.
- Batwell R: Crop lithiasis in a budgerigar. *Austral Vet J* 54:452-453, 1978.
- Bauk L: Vomiting in the young macaw. *Proc Assoc Avian Vet*, New Orleans, 1992, pp 126-128.
- Beach JE, Wilkinson JS, Harvey DG: Calculus in the crop of a budgerigar *Melospittacus undulatus*. *Vet Rec* 72:473, 1960.
- Beach JE: Diseases of budgerigars and other cage birds. A survey of post-mortem findings. *J Sm Anim Prac* 7:10-15, 63-68, 134-140, 1962.
- Beemer AM, Kuttin ES, Katz Z: Epidemic venereal disease due to *Candida albicans* in geese in Israel. *Avian Dis* 17:639-649, 1973.
- Bender MD: Diseases of the peritoneum. In Wingarden JB, Smith LH (eds): *Textbook of Medicine* 18th ed, vol 1. Philadelphia, WB Saunders Co, 1988, pp 790-795.
- Bensadoun A, Rothfeld A: The form of absorption of lipids in the chicken *Gallus domesticus*. *Proc Soc Exp Biol Med* 141:814, 1972.
- Birlbauer R: Laktobazillen bei Wellensittichen [*Lactobacillus* spp. in budgerigars]. *Vet Med Diss*, München, 1980.
- Blackmore DK: The clinical approach to tumours in cage birds. The pathology and incidence of neoplasia in cage birds. *J Sm Anim Prac* 7:217-223, 1966.
- Bracewell CD, Wyeth P: Infectious stunting of chickens. *Vet Rec* 109:64, 1981.
- Brooks NG: Crop wall necrosis in a sparrow hawk. *Vet Rec* 111:513, 1982.
- Brown PA, Newman JA: Diagnosis of avian chlamydiosis: Questions, answers, questions. *Proc Assoc Avian Vet*, New Orleans, 1992, pp 42-47.
- Burgess EC, Ossa J, Yuill TM: Duck plague: A carrier state in waterfowl. *Avian Dis* 23:940-949, 1979.
- Burtscher H, Loupal G, Hamied MAA: Glandular stomach carcinoma in *Rhyticeros undulatus* and a great white egret (*Casmerodius albus*). *Verhandlungsbericht über die Erkrankungen der Zootiere*, 1983, pp 169-175.
- Burtscher M, Sibalín M: Herpesvirus strigis: Host spectrum and distribution in infected owls. *J Wildl Dis* 11:164-169, 1975.
- Bush M, Kennedy S: Ventriculostomy for removal of foreign bodies in Sarus cranes. *J Am Vet Med Assoc* 173:9, 1978.
- Busche R, Frese K, Weingarten M: Zur Pathologie des Macaw Wasting Syndroms [The pathology of macaw wasting syndrome]. *Verh Ber 27 Symposium Erkrankungen d Zootiere*, St. Vincent/Toronto, 1985, pp 317-324.
- Enders F, Krautwald M, Dühr D: Sonographic evaluation of liver disease in birds. *Proc European Conf on Avian Med & Surg*, 1993 pp 155-163.
- Calnek BW, Witter RL: Marek's disease. In Calnek BW, et al (eds): Diseases of Poultry. Ames, Iowa State University Press, 1991, pp 342-385.
- Campbell JG: Tumours of the fowl. London, William Heinemann Medical Books Ltd, 1969, pp 134-138.
- Campbell JG, Appleby EC: Tumours in young chickens bred for rapid growth (broiler chickens). A study of 351 cases. *J Pathol Bacter* 92:77-90, 1966.
- Campbell TW: Disorders of the avian crop. *Comp Cont Educ Pract Vet* 5:813-821, 1983.
- Campbell TW: Neoplasia. In Harrison GJ, Harrison LR (eds): Clinical Avian Medicine and Surgery. Philadelphia, WB Saunders Co, 1986, pp 600-608.
- Campbell TW: Cytology of abdominal effusions. In Avian Hematology and Cytology. Ames, Iowa State University Press, 1988, pp 41-44.
- Cancer Institute, Chinese Academy Medical Sciences: The epidemiology of esophageal cancer in North China and preliminary results in the investigation of its etiological factors. *Acta Zool Sinica* 19:309-312, 1973.
- Cannon C: Proventricular and ventricular obstruction with bedding materials. *J Assoc Avian Vet* 6:16,40, 1992.
- Chaney SG, Kare MR: Emesis in birds. *J Am Vet Med Assoc* 149:938-943, 1966.
- Clark FD: Proventricular dilatation syndrome in large psittacine birds. *Avian Dis* 28:813-815, 1984.
- Cliphsham R: Surgical beak restoration and correction. *Proc Assoc Avian Vet*, Seattle, 1989, pp 164-176.
- Cliphsham R: Pediatric management and medicine. *J Assoc Avian Vet* 3(1):10-13, 1989.
- Cliphsham R: Noninfectious diseases of psittacine birds. *Sem Avian & Exotic Pet Med* 1(1):22-33, 1992.
- Coleman CW: Bile duct carcinoma and cloacal prolapse. *J Assoc Avian Vet* 5:87-89, 1991.
- Cribb PH: Cloacal papilloma in an Amazon parrot. *Proc Assoc Avian Vet*, Toronto, 1984, pp 35-37.
- Daoust PY, Julian RJ, Yason CV, Arisob H: Proventricular impaction associated with nonsuppurative encephalomyelitis and ganglioneuritis in two Canada Geese. *J Wildl Dis* 27:513-517, 1991.
- Degernes LA: A clinical approach to ascites in pet birds. *Proc Assoc Avian Vet*, Chicago, 1991, pp 131-136.
- Degernes LA, Flammer K: Proventricular dilatation syndrome in a green-winged macaw. *Proc Assoc Avian Vet*, Chicago, 1991, pp 45-49.
- Dewar WA, et al: Toxic effects of high concentrations of zinc oxide in the diet of the chick and laying hen. *Brit Poultry Sci* 24:397-404, 1983.
- Dorrestein GM, Kummerfeld N: Singvögel (Songbirds). In Gabrisch K, Zwart P (eds): Krankheiten der Heimtiere (Diseases of Exotic Pets). Hannover, Schlutersche, 1984, pp 97-144.
- Droual R, Meleyer CU, Goley FD: Zinc toxicosis due to ingestion of a penny in a gray-headed chachalaca (*Ortalis cinericeps*). *Avian Dis* 35:1007-1011, 1991.
- Duke GE: Alimentary canal: Secretive and digestive, Special digestive functions, and Absorption. In Sturkie PD (ed): *Avian Physiology* 4th ed. New York, Springer Verlag, 1986, pp 289-302.
- Eber A: Tuberkulose der Stubenvögel (Papageien, Singvögel) [Tuberculosis in pet birds (parrots, songbirds)]. In Stang V, Wirth D: Tierheilkunde und Tierzucht. Eine Enzyklopädie der praktischen Nutztierkunde, Band 10, Trächtigkeit-Zygotie. Berlin, Urban & Schwarzenberg, 1932, p 226.
- Eber A, Pallaske-Eber R: Die durch Obduktion feststellbaren Geflügelkrankheiten [Poultry diseases diagnosed postmortally]. Hannover, M & H Schaper, 1934.
- Feldman WH, Olson C: Neoplastic diseases of the chicken. In Biester HE, Schwartz LH (eds): Diseases of Poultry, 5th ed. Ames, Iowa State University Press, 1965, pp 863-924.
- Fisher C, et al: The effect of copper sulphate on performance and the structure of the ventriculus in broilers. *Brit Poultry Sci* 14:55-68, 1973.
- Flammer K: Pediatric medicine. In Harrison GJ, Harrison LR (eds): Clinical Avian Medicine and Surgery. Philadelphia, WB Saunders Co, 1986, pp 634-650.
- Fowler ME: Comparative clinical anatomy of ratites. *J Zoo & Wildl Med* 22:204-227, 1991.
- Franssen FJ, Lumeij JT: *In vitro* nitroimidazole resistance of *Trichomonas gallinae* and successful therapy with an increased dosage of ronidazole in racing pigeons (*Columba livia domestica*). *J Vet Pharm & Therap* 15:409-415, 1992.
- Fredrickson TN, Helmboldt CF: Tumors of unknown etiology. In Calnek BW, et al (eds): Diseases of Poultry. Ames, Iowa State University Press, 1991, pp 459-470.
- Frost C: Experiences with pet budgerigars. *Vet Rec* 73:621-626, 1991.
- Gabrisch K, Zwart P (eds): Krankheiten der Heimtiere [Diseases of Exotic Pets]. Hannover, Schlutersche, 1984.
- Gabrisch K, Zwart P (eds): Krankheiten der Wildtiere [Diseases of Wild Animals]. Hannover: Schlutersche, 1987.
- Garner MM, Sturtevant FC: Trichomoniasis in a blue-fronted Amazon parrot. *J Assoc Avian Vet* 6:17-20, 1992.
- Gaskin JM, Homer BL, Eskelund KE: Preliminary findings in avian viral serostitis: A newly recognized syndrome of psittacine birds. *J Assoc Avian Vet* 5:27-34, 1991.
- Gerlach H: Update on the Macaw wasting syndrome. *Proc Assoc Avian Vet*, Miami, 1986, p 21.
- Gerlach H: Going light in budgerigars. *Proc Assoc Avian Vet*, Miami, 1986, pp 247-250.
- Goodwin MA, et al: Quantitation of intestinal D-xylose absorption in normal broilers and in broilers with pale bird syndrome. *Avian Dis* 29:630-639, 1985.
- Graham DL: Structure function, and disorders of the avian alimentary tract. (An outline from stem to stern). *Proc Assoc Avian Vet*, 1986, Miami, pp 307-316.
- Graham DL: Internal papillomatous disease. *Proc Assoc Avian Vet*, Houston, 1988, p 31.
- Graham DL: 'Wasting/proventricular dilatation disease' A pathologist's view. *Proc Assoc Avian Vet*, Chicago, 1991, pp 43-44.
- Graham DL: Internal papillomatous disease: A pathologist's view. *Proc Assoc Avian Vet*, Chicago, 1991, pp 141-143.
- Graham DL: Diseases of the exocrine pancreas in pet, exotic, and wild birds: a pathologist's perspective. *Proc Assoc Avian Vet*, New Orleans, 1992, pp 190-193.
- Gratz E, Köhler H: Spezielle Pathologie und Therapie der Geflügelkrankheiten [Pathology and Therapy of Poultry Diseases]. Stuttgart: Ferdinand Enke Verlag, 1968.
- Gries CI, Scott ML: Pathology of selenium deficiency in the chick. *J Nutri* 102:1287-1296, 1972.
- Griffiths GL, Williams W: Runting in broilers associated with temporary maldigestion. *Vet Rec* 116:160-161, 1985.
- Griner LA: Pathology of Zoo Animals. San Diego, Zoological Society of San Diego, 1983, pp 215-228.
- Gross WB: Colibacillosis. In Calnek BW, et al (eds): Diseases of Poultry, 1991, pp 138-144.
- Grünberg W, Kutzer E: Die Pathologie verschiedener Trematodeninfektionen bei Störchen (*C. ciconia* und *C. nigra*) [Pathology of various trematode infections in storks]. *Zentralbl Veterinärmed B11:712-727*, 1964.
- Guerin M: Tumeurs spontanées de la poule, Tumeurs d'organes thoraco-abdominaux [Spontaneous tumors in poultry, tumors of the thoraco-abdominal cavity]. In Tumeurs spontanées des animaux de laboratoire. Paris, Legrand, 1954, pp 153-180.
- Gylstorff I, Grimm F: Vogelkrankheiten [Avian Diseases]. Stuttgart, Ulmer Verlag, 1987.
- Hansen HA, McNeil CW, Priebe MD: Mortality of Canada geese with impacted gullets in eastern Washington, 1949-1954. *J Wildl Manag* 21:96, 1957.
- Hanson HC, Smith RH: Canada geese of the Mississippi flyway with special reference to an Illinois flock. *Bull Ill Nat Hist Surv* 25:67, 1950.
- Harrison GJ: Initial treatment of severe crop wounds. *J Assoc Avian Vet* 5:126, 1991.
- Harry EG: The effect on embryonic and chick mortality of yolk contamination with bacteria from the hen. *Vet Rec* 69:1433-1440, 1957.
- Harry EG: The survival of *E. coli* in the dust of poultry houses. *Vet Rec* 76:466-470, 1964.
- Heldestab A, et al: Pathologie einer endemie-artig verlaufenden Neuritis im Magen-Darm-Bereich bei Grasspazieren [Pathology of an enzootic neuritis of the gastro-intestinal system in psittacines]. *Verh Ber 27 Symposium Erkrankungen der Zootiere*, St. Vincent/Toronto, 1985, pp 317-324.
- Helmboldt CF, Fredrickson TN: Tumors of unknown etiology. In Hofstad MS, et al (eds): Diseases of Poultry 7th ed. Ames, Iowa State University Press, 1978, pp 479-480.
- Hillyer EV, Moroff S, Hoefler H, et al: Bile duct carcinoma in two out of ten Amazon parrots with cloacal papillomas. *J Assoc Avian Vet* 5:91-94, 1991.
- Hoerr FJ: Mycotoxicoses. In Calnek BW, et al (eds): Diseases of Poultry 9th ed. London, Wolfe Publishing Ltd, 1991, pp 884-915.
- Honnas CM, Jensen J, Cornick JL, et al: Proventriculotomy to relieve foreign body impaction in ostriches. *J Am Vet Med Assoc* 199:461-465, 1991.
- Hughes PE: The pathology of myenteric ganglioneuritis, psittacine encephalomyelitis, proventricular dilatation of psittacines, and macaw wasting syndrome. *Proc 33rd West Poultry Dis Conf*, Davis, 1984, pp 85-87.
- Ingram IA: Proventricular foreign body mimicking proventricular dilatation in an umbrella cockatoo. *Proc Assoc Avian Vet*, Phoenix, 1990, pp 314-315.
- Isenbügel E, Rübél A: Greifvögel [Raptors]. In Gabrisch K, Zwart P: Krankheiten der Wildtiere [Diseases of Wild Animals]. Hannover, Schlutersche, 1987, pp 191-252.

92. **Jarvis RL:** Soybean impaction in Canada geese. *Wildl Soc Bull* 4:175, 1976.
93. **Jordan FTW:** Poultry Diseases. London, Ballière-Tindall, 1990.
94. **Joyner KL, Kock N, Styles D:** Encephalitis, proventricular and ventricular myositis, and myenteric ganglionneuritis in an umbrella cockatoo. *Avian Dis* 33:379-381, 1989.
95. **Joyner KL:** Psittacine pediatric support. *J Assoc Avian Vet* 3(1):8, 1989.
96. **Joyner KL:** Psittacine pediatric diagnostics. *Sem Avian & Exotic Pet Med* 1(1):11-21, 1992.
97. **Julian RJ, Summers J, Wilson JB:** Right ventricular failure, and ascites in broiler chicks caused by phosphorus-deficient diets. *Avian Dis* 30:453-459, 1986.
98. **Kazacos EA, Van Vleet JF:** Sequential ultrastructural changes of the pancreas in zinc toxicosis in ducklings. *Am J Pathol* 134:581-595, 1989.
99. **Kenny D, Cambre RC:** Indications and technique for the surgical removal of the avian yolk sac. *J Zoo Wildl Med* 23:55-61, 1992.
100. **Krautwald-Junghans ME, Riedel U, Neumann W:** Diagnostic use of ultrasonography in birds. *Proc Assoc Avian Vet, Chicago, 1991*, pp 269-276.
101. **King AS, McLelland J:** Birds. Their Structure and Function. London, Ballière-Tindall, 1984, pp 84-109.
102. **Kingston RS:** Evaluation of the Kodak SureCell™ Chlamydia test kit in companion birds. *J Assoc Avian Vet* 6:155-157, 1992.
103. **Kösters J, Jacoby JR:** Enten und Gänse [Ducks and Geese]. In: *Gabrichsch K, Zwart P: Krankheiten der Heimtiere (Diseases of Exotic Pets)*. Hannover, Schlutersche, 1987, pp 363-399.
104. **Kouwenhoven B, Davelaar FG, Van Walsum J:** Infectious proventriculitis causing runting in broilers. *Avian Pathol* 7:183-187, 1978.
105. **Kouwenhoven B, et al:** Enkele gevallen van herpesvirus infectie bij duiven in Nederland [Some cases of pigeon herpes virus infection in the Netherlands]. *Studiedag duivenziekten en therapie*. Amerongen, Nederlandse Vereniging voor Dierenartsen voor Duiven, 1985, pp 21-29.
106. **Kouwenhoven B, Vertommen MH, Goren E:** Runting in broilers. In: *McFerrer JB, McNulty MS (eds): Acute Virus Infections of Poultry*. Dordrecht, Netherlands, Martinus Nijhoff, 1986, pp 165-178.
107. **Kummerfeld N:** Gastrotomie (Muskelmagen) bei Hühner und Entenvögeln [Ventriculotomy in galliforme and anseriforme birds]. *Tagungsbericht II. Tagung Krankheiten der Vögel der DVG in München, 1981*, pp 75-78.
108. **Kummerfeld N, et al:** Parasitärbedingte Schnabelkrankungen bei Paradiesenkranichen (*Anthropoides paradisea*). [Parasitic rhamphotecal diseases in cranes]. *Verh Ber 25 Symp d Krankheiten d Zootiere*, Wien, 1983, pp 155-159.
109. **Kutzer E, et al:** Zum *Synthanthus* (Dispharynx) falconis-Befall bei Eulenvögeln [*Synthanthus falconis* infection in owls]. *Zool Garten NF* 52:263-270, 1982.
110. **Lahaye J:** Maladies des pigeons et des poules, des oiseaux de basse-cour et de volière [Diseases of pigeons, chickens, ornamental and aviary birds]. Anatomie, hygiène, alimentation. 2ème Edition. Remouchamps, Imprimerie Steinmetz-Haenen, 1928.
111. **Lafimer KS, et al:** Zinc-induced hemolytic anemia caused by ingestion of pennies by a pup. *J Am Vet Med Assoc* 195:77-80, 1989.
112. **Leach MW:** A survey of neoplasia in pet birds. *Sem Avian & Exotic Pet Med* 1:52-64, 1992.
113. **Leach MW, Paul-Murphy J, Lowenstein U:** Three cases of gastric neoplasia in psittacines. *Avian Dis* 33:204-210, 1989.
114. **Lederer RJ, Crane R:** The effects of emetics on wild birds. *No Am Bird Bander* 3:3-5, 1978.
115. **Lemahieu P, DeHondt G:** Trichomonosis bij kanaries. *Vlaams Diergeneeskundig Tijdschrift*, 46:442-443, 1977.
116. **Lilburn MS, Edwards Jr HM, Jensen LS:** Impaired nutrient utilization associated with pale bird syndrome in broiler chicks. *Poult Sci* 61:608-609, 1982.
117. **Lloyd M:** Heavy metal ingestion: Medical management and gastroscopic foreign body removal. *J Assoc Avian Vet* 6:25-29, 1992.
118. **Lü J, Combs GF:** Effect of excess dietary zinc on pancreatic exocrine function in the chick. *J Nutri* 118:681-689, 1988.
119. **Lumiej JT, et al:** An unusual case of lead poisoning in a honey-buzzard (*Pernis apivorus*). *Vet Quart* 7:165-168, 1985.
120. **Lumiej JT, Goojies P, Wolvick WThC:** A new instrument for removing gastric foreign bodies in birds. *Proc Europ Assoc Avian Vet, Utrecht, 1993*, pp 91-98.
121. **Lutz ME, Wilson RB:** Proventricular dilatation syndrome in an umbrella cockatoo. *J Am Vet Med Assoc* 198:1962-1964, 1991.
122. **MacNeil AC, Barnard T:** Necropsy results in free flying and captive Anatidae in British Columbia. *Can Vet J* 19:17, 1978.
123. **Mannl A, Gerlach H, Leipold R:** Neuropathic gastric dilatation in psittaciformes. *Avian Dis* 31:214-221, 1987.
124. **Marland MF:** Histopathology of the chick pancreas following pancreatic duct ligation. *Vet Rec* 118:526-530, 1986.
125. **Marland MF:** Advances in stunting and runting syndrome research. In: *Pandy R (ed): Progress in Veterinary Microbiology and Immunology Vol 5, Nononcogenic Avian Viruses*. 1989, pp 101-133.
126. **Marland MF, Farmer H:** Pancreatic duct obstruction in a stunting syndrome of broiler chickens. *Vet Rec* 118:531-534, 1986.
127. **Mathey WJ:** A diphtheroid stomatitis in chickens apparently due to a spirillum pulli, species nova. *Am J Vet Res* 17:742-746, 1956.
128. **McCluggage D:** Proventriculotomy: A study of select cases. *Proc Assoc Avian Vet, New Orleans, 1992*, pp 195-200.
129. **McDonald SE:** Clinical experiences with cloacal papillomas. *Proc Assoc Avian Vet, Houston, 1988*, pp 27-30.
130. **McLelland J:** A Colour Atlas of Avian Anatomy. London, Wolfe Publishing Ltd, 1990.
131. **McMillan MC:** Avian gastrointestinal radiography. *Comp Cont Educ Pract Vet* 4:273-294, 1983.
132. **Meerdink GL, Reed RE, Perry D, Warfield TK:** Zinc poisoning from the ingestion of pennies. *Proc Am Assoc Vet Lab Diag*, 1986, pp 141-150.
133. **Minsky L, Petrak ML:** Diseases of the digestive system. In: *Petrak ML (ed): Diseases of Cage and Aviary Birds*. Philadelphia, Lea and Febiger, 1982, pp 432-448.
134. **Mladenov Z:** Comparative pathology of avian leukosis. In: *Yohn DS, Lapin BA, Blakeslee JR (eds): Advances in Comparative Leukemia Research*. Amsterdam, Elsevier/North Holland Biomedical Press, 1980, pp 131-132.
135. **Moran Jr ET, Carlson HC, Peiri JR:** Vitamin E-selenium deficiency in the duck aggravated by the use of high moisture corn and molding prior to preservation. *Avian Dis* 18:536, 1974.
136. **Moss R:** Effects of captivity on gut length in red grouse. *J Wildl Mgt* 36:99-105, 1972.
137. **Murphy J:** Psittacine trichomoniasis. *Proc Assoc Avian Vet, New Orleans, 1992*, pp 21-24.
138. **Murtaugh RJ, Jacobs RM:** Trichomoniasis of the crop in a cockatiel. *J Am Vet Med Assoc* 185:441-442, 1984.
139. **Murtaugh RJ, Ringle DJ, Petrak ML:** Squamous cell carcinoma of the esophagus in an Amazon parrot. *J Am Vet Med Assoc* 188:872-873, 1986.
140. **Needham JB:** Bacterial flora of birds of prey. In: *Cooper JE, Greenwood AG (eds): Recent Advances in the Study of Raptor Diseases*. Keighly (UK), Chiron Publications, 1980, pp 3-10.
141. **Neumann U, Kummerfeld N:** Neoplasms in budgerigars (*Melospittacus undulatus*): Clinical, pathomorphological, and serological findings with special consideration of kidney tumors. *Avian Pathol* 12:353-362, 1983.
142. **Odor EM, Page RK, Fletcher OJ, Villegas P:** Pale bird syndrome: Clinical picture and etiology. *J Am Vet Med Assoc* 179:273, 1981.
143. **Ogden L, Edwards WC, Nail NA:** Zinc intoxication in a dog from the ingestion of copper clad zinc pennies. *Vet & Human Tox* 30:577-578, 1988.
144. **Okazaki T, et al:** Gizzerosine, a new toxic substance in fish meal, causes severe gizzard erosion in chickens. *Agric Biol Chem* 47:29-49, 1983.
145. **Olson C, Bullis KL:** A survey of spontaneous neoplastic diseases in chickens. *Mass Agric Exper Sta Bull* 391, 1942.
146. **Page RK, Fletcher OJ, Rowland GN, Gaudry D, Villegas P:** Malabsorption syndrome in broiler chickens. *Avian Dis* 26:618-624, 1982.
147. **Pass DA, Robertson MD, Wilcox CE:** Runting syndrome in broiler chickens in Australia. *Vet Rec* 110:386-387, 1982.
148. **Payne LN, Powell PC:** The lymphoid system. In: *Freeman BM (ed): Physiology and Biochemistry of the Domestic Fowl*. London, Academic Press, 1984, pp 277-321.
149. **Payne LN, Purchase HG:** Leukosis/sarcoma group. In: *Calnek BW, et al (eds): Diseases of Poultry*. Ames, Iowa State University Press, 1991, pp 386-439.
150. **Peclander H:** Bemerkenswerte Toedersachen bei Vögeln im Alpenzoo Innsbruck [Remarkable causes of death in birds at the Alpenzoo Innsbruck]. *Verhandlungsberichte XVIII Intern Symp Erkrank Zootiere*, 1976, pp 117-120.
151. **Peckham MC:** Vices and miscellaneous diseases. In: *Hofstad MS, et al (eds): Diseases of Poultry 7th ed*. Ames, Iowa State University Press, 1978, pp 847-893.
152. **Peckham MC:** Vices and miscellaneous diseases and conditions. In: *Hofstad MS, et al (eds): Diseases of Poultry 8th ed*. Ames, Iowa State University Press, 1984, pp 741-782.
153. **Pepper WJ:** Crop wall necrosis. *Vet Rec* 111:591, 1982.
154. **Persson L, Borg K, Falt H:** On the occurrence of endoparasites in eider ducks in Sweden. *swed. Wildl Viltrevy* 9:1, 1974.
155. **Petrak ML (ed):** Diseases of Cage and Aviary Birds. Philadelphia, Lea & Febiger, 1982.
156. **Petrak ML, Gilmore GE:** Neoplasms. In: *Petrak ML (ed): Diseases of Cage and Aviary Birds 2nd ed*. Philadelphia, Lea and Febiger, 1982, pp 606-637.
157. **Phalen DN:** An outbreak of psittacine proventricular dilatation syndrome (PPDS) in a private collection of birds and an atypical form of PPDS in a nanday conure. *Proc Assoc Avian Vet, Miami, 1986*, pp 27-34.
158. **Phalen DN:** Acute pancreatic necrosis in an umbrella cockatoo. *Proc Assoc Avian Vet, Houston, 1988*, pp 203-205.
159. **Potter K, et al:** Cholangiocarcinoma in a yellow-faced Amazon parrot (*Amazona xanths*). *Avian Dis* 27:556-558, 1983.
160. **Quisenberry KE, Liu SK:** Pancreatic atrophy in a blue and gold macaw. *J Am Vet Med Assoc* 189:1107-1108, 1986.
161. **Rae MA, Merryman M, Linner M:** Gastric neoplasia in caged birds. *Proc Assoc Avian Vet, New Orleans, 1992*, pp 180-189.
162. **Ramsay EC, Drew ML, Johnson B:** Trichomoniasis in a flock of budgerigars. *Proc Assoc Avian Vet, Phoenix, 1990*, pp 309-311.
163. **Ratcliffe HL:** Incidence and nature of tumors in captive wild mammals and birds. *Am J Cancer* 17:116-135, 1933.
164. **Read AE:** The pancreas. In: *Scott RB (ed): Price's Textbook of the Practice of Medicine 7th ed*. Oxford, Oxford University Press, 1978, pp 585-589.
165. **Reece RL, et al:** Field, clinical, and pathological observations of a runting and stunting syndrome in broilers. *Vet Rec* 115:483-484, 1984.
166. **Reece RL, Dickson DB, Burrows PJ:** Zinc toxicity (new wire diseases) in aviary birds. *Austral Vet J* 63:199, 1986.
167. **Rich GA:** Classic and atypical cases of proventricular dilatation disease. *Proc Assoc Avian Vet, New Orleans, 1992*, pp 119-125.
168. **Richter T:** Untersuchungen über die Zusammensetzung der Nasenflora bei Greifvögeln [Investigations into the nasal flora of birds of prey]. *Vet Med Diss München*, 1981.
169. **Riddell C:** The influence of fiber in the diet on dilatation (hypertrophy) of the proventriculus in chickens. *Avian Dis* 20:442-445, 1976.
170. **Riddell C:** Developmental, metabolic and miscellaneous disorders. In: *Calnek BW, et al (eds): Diseases of Poultry*. Ames, Iowa State University Press, 1991, pp 827-862.
171. **Riddell C, Derow D:** Infectious stunting and pancreatic fibrosis in broiler chickens in Saskatchewan. *Avian Dis* 29:107-115, 1985.
172. **Ridgeway RA, Gallenstein GA:** Proventricular dilatation in psittacines. *Proc Assoc Avian Vet, San Diego, 1983*, pp 228-233.
173. **Roskopf WJ, Woerpel RW:** Cloacal conditions in pet birds with a cloacopy update. *Proc Assoc Avian Vet, Seattle, 1989*, pp 156-163.
174. **Ruff MD:** Nematodes and acantocephalans. In: *Calnek BW, et al (eds): Diseases of Poultry*. Ames, Iowa State University Press, 1991, pp 731-763.
175. **Ryan CP, Walder EJ, Howard EB:** Diabetes mellitus and islet cell carcinoma in a parakeet. *J Am Anim Hosp Assoc* 18:139-142, 1992.
176. **Saiforster R:** Untersuchungen über die Nasenflora bei einigen Gesunden Psittaciformes-Arten [Investigations into the normal nasal flora of some psittacine species]. *Vet Med Diss München*, 1979.
- 176b. **Schmidt RE, Dustin LR, Slevin RW:** Proventricular adenocarcinoma in a budgerigar (*Melospittacus undulatus*) and a grey-cheeked parakeet (*Brotogeres pyrropterus*). *Assoc Avian Vet Today* 2:13-14, 1988.
177. **Schweighardt H, Pechan P, Lauermann E:** Leichtverdem, Hinfälligkeit und Erbrechen als Ausdruck einer spezifischen pilzbedingten Drüsenagenzierung bei Wellensittichen und Kanarienvögeln [Emaciation and vomiting as signs of a specific fungal proventriculitis in budgerigars and canaries]. *Kleintierpraxis* 9:439-442, 1984.
178. **Scott ML, Olson G, Krook L, Brown WR:** Selenium responsive myopathies of myocardium and smooth muscle in the young pout. *J Nutri* 91:573-583, 1967.
179. **Shanhikumar SR:** Helminthology. In: *Burr EW (ed): Companion Bird Medicine*. Ames, Iowa State University Press, 1987, pp 135-146.
180. **She RP:** Epidemiology and pathology of oropharyngo-esophageal carci-

- noma in chickens from different areas in Zongxian county, Hubei province. *Acta Vet Zootech Sinica* 18:195-200, 1987.
181. **Sinclair AJ, et al:** Pancreatic degeneration in broilers with runting and stunting syndrome. *Vet Rec* 115:485-488, 1984.
  182. **Skadhauge E, Maloney SK, Dawson TJ:** Osmotic adaptation of the emu (*Dromaius novaehollandiae*). *J Comp Physiol B* 161:173-178, 1991.
  183. **Smadel JE, Jackson EP, Harman JW:** A new virus disease of pigeons. *J Exper Med* 81:385-387, 1945.
  184. **Smit T, Rondhuis RR:** Studies on a virus isolated from the brain of a parakeet (*Neophema* sp.). *Avian Pathol* 5:21-30, 1976.
  185. **Stam JWE:** Een onderzoek naar de vitamine A behoefte bij de duif [Investigations into vitamin A requirements in the pigeon]. Thesis Utrecht University, 1965.
  186. **Steinberg H:** Leiomyosarcoma in the jejunum of a budgerigar. *Avian Dis* 32:166-168, 1988.
  187. **Stewart J:** A simple proventriculotomy technique for the ostrich. *J Assoc Avian Vet* 5:139-141, 1991.
  188. **Stipkovits L, Varga Z, Czifra G, Dobos-Kovacs M:** Occurrence of mycoplasmas in geese affected with inflammation of the cloaca and phallus. *Avian Pathol* 15:289-299, 1986.
  189. **Stuart BP, Cole RJ, Waller EF, Vesonder RF:** Proventricular hyperplasia (malabsorption syndrome) in broilers: Involvement of mycotoxins and other dietary factors. *J Am Vet Med Assoc* 179:273, 1981.
  190. **Sundberg JP, et al:** Cloacal papillomas in psittacines. *Am J Vet Res* 47:928-932, 1986.
  191. **Szidal L:** Die Parasitenfauna des weissen Störches und ihre Beziehungen zu Fragen der Ökologie, Phylogenie und der Urheimat der Störche [Parasites of the white stork in relation to ecology, phylogeny, and the country of origin]. *Zeitschrift für Parasitenkunde* 11:563-592, 1940.
  192. **Thompson JN, Scott ML:** Role of selenium in the nutrition of the chick. *J Nutri* 97:335-342, 1969.
  193. **Thompson JN, Scott ML:** Impaired lipid and vitamin E absorption related to atrophy of the pancreas in selenium-deficient chicks. *J Nutri* 100:797-809, 1970.
  194. **Tudor DC:** Vitamin A deficiency in pigeons. *Vet Med/Sm An Clin*, January: 88-89, 1982.
  195. **Turner R:** Macaw fading or wasting syndrome. Proc 33rd Western Poultry Disease Conference, Davis, 1984, pp 87-88.
  196. **Turrel JM, McMillan MC, Paul-Murphy J:** Diagnosis and treatment of tumors of companion birds. *Assoc Avian Vet (AAV) Today* 1(4):159-165, 1987.
  197. **Uytendaele E, Ducatelle R:** Megabacterium proventriculitis, a disease of cage birds. *Vlaams Diergeneeskundig Tijdschrift* 59:147-150, 1990.
  198. **Van der Hage M, Dorrestein GM, Zwart P:** Paramyxovirusinfecties bij Psittaciformes en Passeriformes [Paramyxovirus infections in Psittaciformes and Passeriformes]. Proc EuroP Symp Bird Dis, Beerse, Belgium, 1987, pp 85-88.
  199. **Van der Heide L, Lüticken D, Horzinek M:** Isolation of avian reovirus as a possible etiologic agent of osteoporosis ("brittle bone disease"; "femoral head necrosis") in broiler chickens. *Avian Dis* 25:847-856, 1981.
  200. **Van Der Heyden N:** Psittacine papillomas. Proc Assoc Avian Vet, Houston, 1988, pp 23-25.
  201. **Van Herck H, et al:** A bacterial proventriculitis in canaries (*Serinus canaria*). *Avian Pathol* 13:361-372, 1984.
  202. **Van Nie GJ, et al:** [Tuberculosis in raptorial birds. Clinical cases and differential diagnosis]. *Tijdschrift Diergeneeskunde* 107:563-572, 1982.
  203. **Van Sant, F:** Resolution of an esophageal stricture in a hyacinth macaw. Proc Assoc Avian Vet, New Orleans, 1992, pp 177-179.
  204. **Van Vleet JF, Boon GD, Ferrans VJ:** Induction of lesions of selenium-vitamin E deficiency in ducklings fed silver, copper, cobalt, tellurium, cadmium, or zinc: Protection by selenium or vitamin E supplements. *Am J Vet Res* 42:1206-1217, 1981.
  205. **Van Vloten JGC:** [Traumatic gastritis in pigeons]. *Tijdschrift voor Diergeneeskunde* 89:687-694, 1964.
  206. **Vindevogel H:** La coryza infectieux du pigeon [Infectious coryza in pigeons]. Thesis, Bruxelles University, 1981.
  207. **Vindevogel H, Duchatel JP:** Miscellaneous herpesvirus infections. In Calnek BW, et al (eds): *Diseases of Poultry*. Ames, Iowa State University Press, 1991, pp 665-669.
  208. **Vogel K, et al:** Die Taube. Taubenkrankheiten [Pigeon Diseases]. Hengersberg. Schober Verlags GmbH, 1983, pp 75-81, 211-222.
  209. **Wade JR:** Ratite pediatric medicine and surgery. Proc Assoc Avian Vet, New Orleans, 1992, pp 340-353.
  210. **Wallach JD, Boever WJ:** Diseases of Exotic Animals. Philadelphia, WB Saunders Co, 1983.
  211. **Walsh MT:** Radiology. In Harrison GJ, Harrison LR (eds): *Clinical Avian Medicine and Surgery*. Philadelphia, WB Saunders Co, 1986, pp 201-233.
  212. **Ward FP:** A clinical evaluation of parasites of birds of prey. *J Zoo Anim Med* 6:3-8, 1975.
  213. **Wells S:** Alimentary foreign body in an Amazon parrot. *Mod Vet Prac*, pp 385-386, 1984.
  214. **Westermarck E, Sandholm M:** Fecal hydrolase activity as determined by radial enzyme diffusion: A new method for detecting pancreatic dysfunction in the dog. *Research in Vet Sci* 28:341, 1980.
  215. **Wickware AB:** Grasshoppers as a potential danger in turkeys. *Can J Comp Med Vet Sci*, 9:80-81, 1945.
  216. **Wight PAL, Dewar WA, Saunderson CL:** Zinc toxicity in the fowl: Ultrastructural pathology and relationship to selenium, lead and copper. *Avian Pathol* 15:23-38, 1986.
  217. **Williams DA:** Exocrine pancreatic insufficiency. In Kirk RW (ed): *Current Veterinary Therapy X*. Philadelphia, WB Saunders Co, pp 927-932, 1989.
  218. **Williams RB, Daines LL:** The relationship of infectious omphalitis of poults and impetigo staphylogenes in man. *J Am Vet Med Assoc* 101:26-28, 1942.
  219. **Wobeser GA:** Diseases of Wild Waterfowl. New York, Plenum Press, 1981, pp 123-124, 178-179, 248-293.
  220. **Wobeser GA, Johnson GR:** Stomatitis in a juvenile white pelican due to *Piagetia peralis* (Mallophaga: Menoponidae). *J Wildl Dis* 10:135, 1974.
  221. **Woerpel RW, Rosskopf WJ, Hughes E:** Proventricular dilatation and wasting syndrome: myenteric ganglioneuritis and encephalomyelitis of psittacines: An update. Proc Assoc Avian Vet, Toronto, 1984 pp 25-28.
  222. **Woods LW, Chin RP, Barr BC:** Esophageal trichomoniasis in cockatiels. Proc West Poult Dis Conf, 1987.
  223. **Zwart P, Van der Sluis J, Stam JWE:** Sialolithen (Weisse Punkte) im Munddach bei Tauben [Sialoliths (white spots) on the palate in pigeons]. Proceedings III Tagung über Vogelkrankheiten - Schwerpunkt Taube. München, 1983, pp 39-45.

CHAPTER

---

# 20

## HEPATOLOGY

---

J. T. Lumeij

**T**he avian liver is bilobed and relatively large in comparison to the size of the bird. The left hepatic duct connects to the duodenum. The right hepatic duct connects to the gall bladder in those species that have this organ (gallinaceous birds, ducks, geese). If the gall bladder is absent (pigeons, parrots, ostriches), the right hepatic duct drains directly into the duodenum. If this duct dilates, it may appear as though a gall bladder is present (see Color 14). Birds have no mesenteric lymph nodes, and patients with chronic enteritis may also have periportal hepatitis. The liver in a normal Psittaciforme rests ventrally against the sternum, wraps cranially around the base of the heart and wraps dorsally along the lateral margins of the proventriculus (see Anatomy Overlay). The size of the liver varies among species. In Galliformes, the liver lobes are of similar size while in Psittaciformes, the right lobe is generally larger. Bile acids secreted by the liver function to emulsify fats and activate pancreatic lipase and amylase, all of which aid in digestion. The liver also metabolizes fats, proteins and carbohydrates and detoxifies metabolites and ingested toxins.

## Diagnostic Considerations<sup>22</sup>

Physical findings associated with liver disease are often nonspecific, and are generally not sufficiently diagnostic to establish a clinical diagnosis. A green coloration of the urine and urate fractions in the excreta is a strong indication of liver disease (Color 20.4). Dyspnea is a common finding in birds with hepatomegaly or ascites. Occasionally, an enlarged liver can be palpated and in the smaller Passeriformes, an enlarged liver may be visible through the transparent abdominal wall. Abnormal coloration of the liver is also sometimes visible, particularly in small species and neonates. Polydipsia and vomiting are sometimes associated with liver disease. Pruritus occurs commonly in icteric humans and is thought to be caused by the deposition of irritant bile salts in the skin. Clinical signs suggestive of pruritus and feather picking have been reported in birds with liver disease. Other integumentary disorders that are loosely discussed in association with liver disease include pigment changes of feathers (Color 20.2), abnormal molting and softening, flaking and overgrowth of beak and nails (Figure 20.1).

Because liver diseases may be associated with many physical findings and may even be asymptomatic, fecal examination, hematologic examination (PCV,



**FIG 20.1** Liver disease should always be considered in the differential diagnosis list for birds with beaks and nails that consistently overgrow.

WBC and differentiation, buffy coat for parasites), total protein, plasma protein electrophoresis (A:G ratio), AST, LDH, bile acids and a total body radiograph are considered the ideal database for evaluating a sick bird. The history should involve questions concerning contact with birds outside the premises, which might indicate exposure to infectious diseases that cause hepatitis like Pacheco's disease virus or chlamydia.

### Clinical Pathology

#### Bile Pigments

Green-colored urates are suggestive of liver disease.<sup>5,20,38</sup> This discoloration is the result of increased excretion of biliverdin (biliverdinuria), which is the most important bile pigment in birds. Icterus or jaundice, which is caused by a hyperbilirubinemia, is seen very infrequently in birds. In chickens, if both bile ducts are ligated, the concentration of plasma bile pigments rises immediately but stabilizes after two weeks at about 85  $\mu\text{mol/l}$ . This is a much lower concentration than is found in mammals with total biliary obstruction. In sera of healthy ducks, low levels of bilirubin may be detected, and significantly elevated levels have been reported after experimental infection with duck hepatitis virus; however, the observed levels of about 17  $\mu\text{mol/l}$  were well below the serum concentration of 34-51  $\mu\text{mol/l}$ , which is considered the level above which jaundice becomes apparent in man. The infrequent occurrence of icterus in birds may also be explained by the fact that the enzyme biliverdin reductase, which converts biliverdin to bilirubin, is absent in the bird species that have been tested.<sup>18,19,39</sup> It has been suggested that in birds, some biliverdin may be converted to bilirubin by bacteria or nonspecific reducing enzymes.<sup>17</sup>

Avian plasma may be colored yellow because of the presence of carotenoids, and this normal color should not be misinterpreted as icteric plasma. Some avian species, such as Hyacinth Macaws, have a normal yellow coloration of the skin that could be misinterpreted as icterus (see Color 8). A few hours after birds have received an intramuscular multivitamin injection, the urate fraction can be yellow-brown in color, which should not be confused with liver-induced changes in the urates (see Color 8).

#### Clinical Enzymology

The application of clinical enzymology in human and veterinary medicine is a common method for estab-

lishing a diagnosis in certain disease conditions. Increases in plasma enzyme activities are usually related to leakage of enzymes from damaged cells, but sometimes there may be increased production in affected tissues. The increased concentration of a particular enzyme in plasma depends on factors such as the activity of enzyme in the cells, the rate of leakage and the rate of clearance of the enzyme from the plasma. Rational interpretation of elevated plasma activity of intracellular enzymes due to cellular damage can be performed only if the enzyme profiles of the various organs of the species under investigation and the elimination half-lives of these enzymes are known. The most reliable way to investigate the specificity and sensitivity of various plasma enzymes for detecting liver disease is to establish reference intervals in healthy individuals, and to monitor plasma enzyme changes after selective experimental liver damage. These data are compared to changes associated with diseases of other organs.

Enzyme profiles of the various organs have been investigated in chickens, Mallard ducks, turkeys, racing pigeons, budgerigars and African Grey Parrots.

The elimination half-life of an enzyme can be calculated from the exponential decline in activity during recovery from acute tissue damage. Alternately, it can be determined by measuring the decline in activity after intravenous administration of purified enzymes. After intravenous injection, most enzymes follow a biphasic exponential decline. The rapid primary phase is related to distribution of enzymes by diffusion from plasma into other extracellular body fluids, and the slower secondary phase is related to the actual clearance of enzyme from the body fluids. During the secondary phase, a constant fraction of the enzyme present is eliminated per unit of time, making the decline linear on a logarithmic scale (first order kinetics). The time required for 50 percent completion of the latter process is defined as the elimination half-life ( $t_{1/2\beta}$ ).

Plasma enzyme profiles have been studied in a number of avian species following experimentally induced or spontaneously occurring liver disease. Unfortunately, there is a large interspecies variation in data and the type of liver disease. Additionally, the presence of concomitant injury to other organs that could alter the results of enzyme activity measurements may occur. The results of experimental studies of liver-specific enzymes in racing pigeons are listed in Table 20.1.<sup>22,27,28</sup> Information on enzyme activity in

other tissues may be found in Chapter 11 and in the Appendix.

Glutamate dehydrogenase (GLDH) is the most liver-specific enzyme in the racing pigeon. Since GLDH is localized within the mitochondria of the liver cells, elevated plasma GLDH activities are seen only after severe liver cell damage (necrosis). Liver cell degeneration without necrosis will not cause elevated GLDH activities. In the budgerigar, GLDH activity in liver tissue is relatively low when compared to man and most other birds tested, including cockerel, duck, turkey and pigeon.<sup>31</sup> However, increased GLDH activities were observed in Amazon parrots with extensive liver necrosis due to Pacheco's disease virus, suggesting that this enzyme may be useful for the detection of liver necrosis in at least some psittacine species.

Aspartate aminotransferase (AST, formerly GOT) is the most sensitive indicator of liver disease in the pigeon. This variable, however, is not specific because elevated AST activities can also be seen with muscle damage.

Despite relatively low alanine aminotransferase (ALT, formerly GPT) activities in liver tissue of racing pigeons, this enzyme is useful for detecting liver cell damage because the elimination half-life in plasma is relatively long.

Lactate dehydrogenase (LDH) disappears rapidly from plasma, making it a poor indicator of liver damage, despite relatively high concentrations of this enzyme in liver tissue. Neither ALT nor LDH is specific for the liver because these enzymes, like AST, also occur in muscle.

Gamma glutamyl transferase ( $\tau$ -GT), has been found to be a specific indicator of liver disease in the racing pigeon. The fact that no activity of this enzyme can be found in supernatants of liver tissue homogenates may be due to the synthesis of  $\tau$ -GT during cholestatic liver disease, as has been reported in mammals. This enzyme is not as sensitive as AST.

Alkaline phosphatase (AP) and creatine kinase (CK) are never elevated after liver cell damage, while activities of these enzymes in liver tissue are negligible.

It should be emphasized that elevated activities of "liver enzymes" in plasma may indicate recent damage to liver cells and does not give information on liver function.



Intramuscular injections given within one to five days before collection of a blood sample may cause an elevation of some plasma enzyme activities due to damage of muscle tissue. This can lead to an erroneous diagnosis of liver disease.

**TABLE 20.1 Plasma Chemical Variables in Liver and Muscle Disease Based on Experimental Studies in Pigeons.<sup>22</sup>**

Variable	Liver Disease		Muscle Disease	
	Specificity	Sensitivity	Specificity	Sensitivity
Bile acids	+++	+++	—	—
γ-GT	+++	+	—	—
AST	—	+++	—	+++
ALT	—	+	—	+++
AP	—	—	—	—
GLDH	+++	+*	—	—
CK	—	—	+++	+++
LDH	—	+	—	+

— low, + some, ++ moderate, +++ high  
\*Only with liver and kidney cell necrosis.

### Bile Salts

Plasma bile acids and bile salts are formed in the liver from cholesterol. It is likely that there is a continuous secretion of bile into the intestine in birds, with or without a gall bladder. A slight increase in secretions would be expected postprandially due to the intrahepatic effects of intestinal hormones like secretin, avian vasoactive intestinal peptide (VIP) and cholecystokinin (CCK). These hormones are released after the consumption of food.

The exact site responsible for increased bile secretion and the regulatory mechanisms involved are presently unknown.<sup>24</sup> Bile acids secreted by the liver enter the small intestines, are absorbed in the lower small intestines, enter the portal vein and are extracted from the blood by the liver. Enterohepatic recirculation accounts for over 90% of the secreted bile acids being reabsorbed in the jejunum and ileum.<sup>9</sup> Plasma bile acid concentrations (PBAC), including their salts and corresponding glycine and taurine conjugates, are a reflection of the clearing capacity for bile acids by the liver. All liver functions (extraction, conjugation and excretion) are involved in this process, and determination of plasma bile acid concentration provides information on the combined effectiveness of these functions.

Due to the development of specific and sensitive enzymatic assays for bile acids, bile salts and their corresponding glycine and taurine conjugates, there

has been substantial progress with respect to the use of PBAC for the diagnosis of hepatobiliary disease. Circulatory levels of bile acids increase if the liver is damaged and cannot extract bile from the portal vein or if the enterohepatic cycle is blocked and blood from the portal vein does not reach the liver. PBAC should be considered a sensitive and specific variable for testing liver function in birds as it is in mammals.<sup>3,12,23,36</sup> Reference intervals for PBAC have been established for the racing pigeon and the most common psittacine species found in captivity (see Appendix). Experimental studies<sup>22</sup> indicate that PBAC is the single most useful, available test for determining liver dysfunction in the racing pigeon. In experimentally induced liver disease, five- to ten-fold increases of PBAC over the upper limit of the reference interval are common.

Food consumption significantly increased PBAC in granivorous birds with a gall bladder (Mallard Duck) and granivorous birds without a gall bladder (racing pigeon).<sup>24</sup> The same effect was seen in carnivorous birds.<sup>30</sup> Although up to a 4.5-fold postprandial increase of PBAC was seen in individual birds, the concentrations were never elevated more than 1.65-fold over the upper limit of the reference range. In hepatobiliary disease, five- to ten-fold increases over the upper limit of the reference range were common.<sup>27</sup> Although postprandial increase might complicate interpretation of PBAC, differentiation between postprandial elevations and elevations due to hepatobiliary disease is possible. Experimental findings suggest that values >70 μmol/l in fasted racing pigeons and most psittacine species, and values >100 μmol/l postprandially should be considered elevated, and therefore suggestive for hepatobiliary disease. In Amazon parrots, PBAC values >145 μmol/l are considered elevated.<sup>24,28,29</sup>

### Hepatic Encephalopathy

A tentative diagnosis of hepatic encephalopathy is often made when neurologic signs are seen in birds with documented liver disease; however, this syndrome has not been well documented in avian species. In man and other mammals, hepatic encephalopathy and hepatic coma are mostly seen in portosystemic shunting as a result of a portocaval anastomosis. It is not a disease in itself but a medical condition characterized by neurologic symptoms caused by intoxication of the brain byproducts of protein digestion, which enter the portal circulation and are not detoxified in the liver. It is believed that degradation products from protein catabolism act as false neurotransmitters. For this reason, protein-rich

## Hepatology

### Color 20.1

A mature Blue and Gold Macaw was presented with a history of developing necrotic lesions in the beak. The bird was severely obese (1300 g) and had thick, white serum. The bird's cholesterol level was 1700 mg/dl. A biopsy of the liver indicated severe fatty degeneration. The obesity and lipemia were controlled by switching the bird to a formulated diet supplemented with fresh fruits and vegetables. The formulated portion of the diet was offered on a limited basis and the bird's exercise was increased. The beak lesion was theorized to have occurred secondary to a vascular accident that caused an area of ischemic necrosis.

### Color 20.2

The occurrence of black discolored feathers in Amazon parrots and macaws is frequently discussed as a clinical change indicative of hepatitis. While a connection between the appearance of black feathers and hepatitis has not been confirmed, clinical experience suggests that hepatitis should be included in the differential diagnosis list.

### Color 20.3

An obese Amazon parrot was presented for exercise intolerance (dyspnea) and intermittent depression. The bird weighed 700 g and had difficulty ambulating because of fat in the inguinal and abdominal regions. The bird's blood was yellow; a normal Amazon parrot's blood is provided for comparison. The bird's cholesterol level was 2300 mg/dl. Most other blood parameters were considered non-diagnostic because of the lipemia. Radiographs indicated severe hepatomegaly. Histopathology of a liver biopsy confirmed fatty liver degeneration.

### Color 20.4

Yellow-to-green urates are suggestive of biliverdinuria and are most commonly associated with hepatitis.

### Color 20.5

Normal liver of an adult Umbrella Cockatoo hen with PBFV virus. Note the reddish-brown color, smooth consistency of the surface and sharp defined margins of the normal liver lobes. In Psittaciformes, the right liver (rl) lobe is slightly larger than the left liver (ll) lobe. The lung (lu) can be seen lying under the transparent, contiguous wall of the cranial and caudal thoracic air sacs (open arrow). The transparent ventral hepatic peritoneal membrane can also be seen (arrows). Other organs that should be noted include the heart (h), proventriculus (p) and ventriculus (v).

### Color 20.6

A breeding toucanette was found dead in its enclosure. The abdomen was severely distended. Characteristics of fluid collected by abdominocentesis at necropsy were consistent with a transudate. The enlarged liver was orange and rough in appearance. Histopathology was suggestive of hemochromatosis, and the disease was confirmed using a Prussian blue stain to demonstrate iron-laden hepatocytes.

### Color 20.7

Swollen, pale-yellow liver from an Amazon parrot with severe hepatic lipidosis. Neonates that are mobilizing egg yolk will have a similarly appearing liver for the first two to three weeks of life. Note that the heart is also pale and rotund.

### Color 20.8

A Blue and Gold Macaw chick was presented for evaluation. The bird was in a comatose state and was the sixth baby from a psittacine nursery to die acutely. The bird had subcutaneous hemorrhages, hepatomegaly and swollen, hemorrhagic kidneys, all suggestive of avian polyomavirus. A polyomavirus infection was suspected by identifying basophilic intranuclear inclusion bodies in the liver, spleen, kidneys and heart, and was confirmed by DNA probe detection of viral nucleic acid on a swab taken of the cut surface of the liver and

spleen. Note the petechial to ecchymotic hemorrhages in the liver and heart.

### Color 20.9

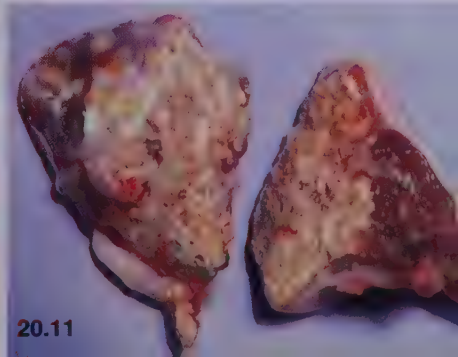
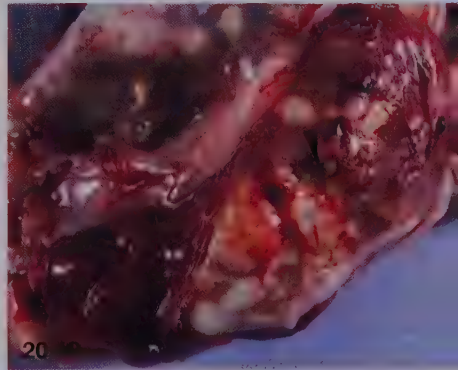
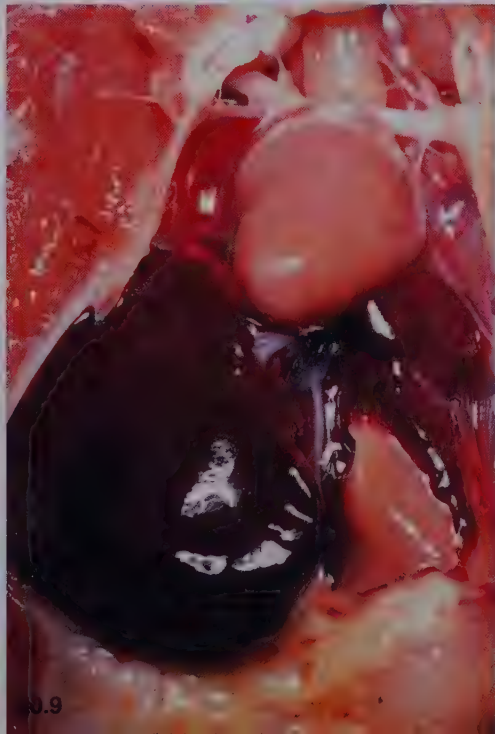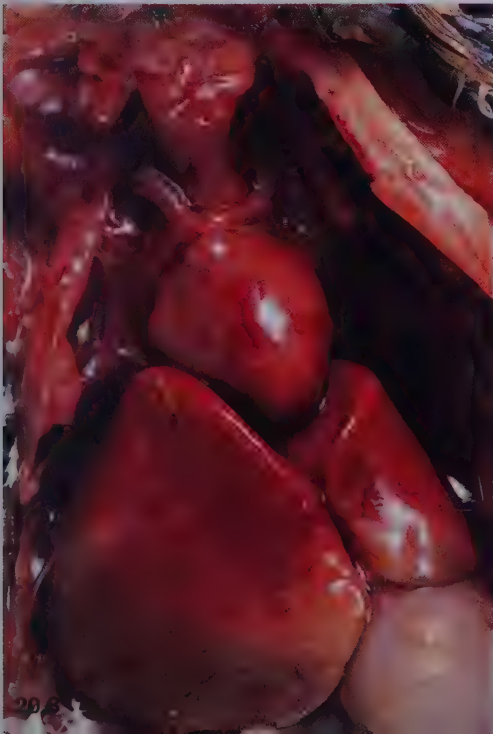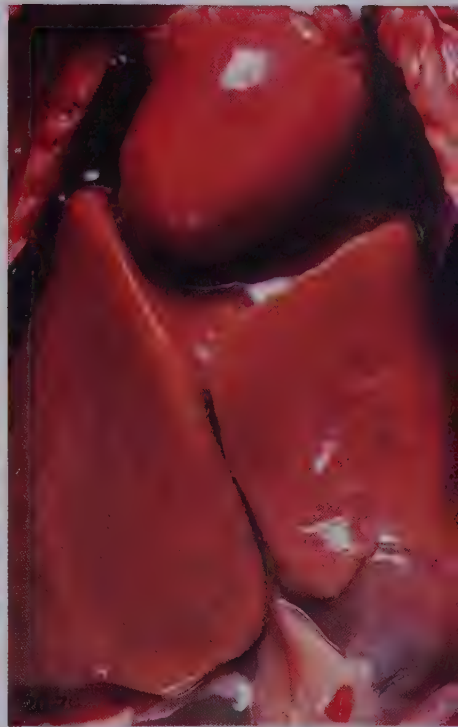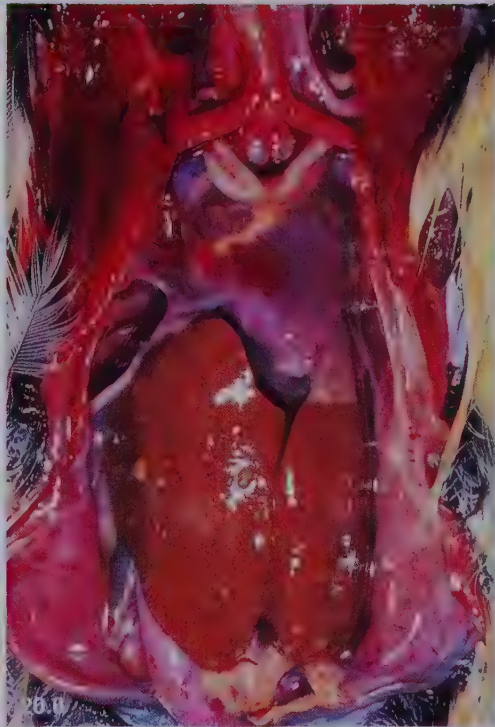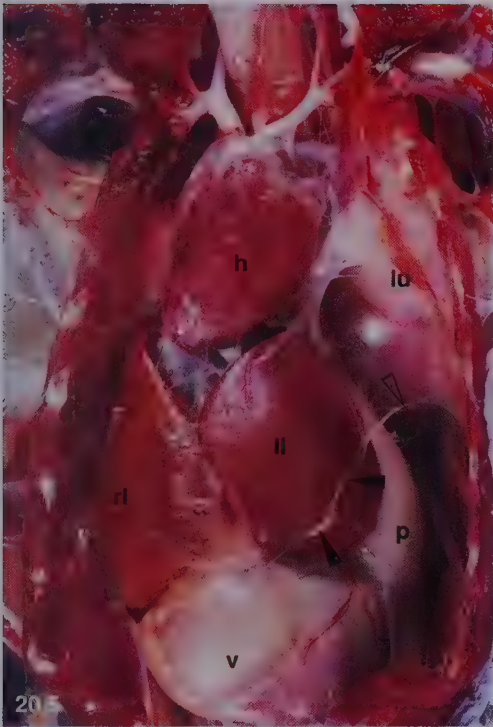



An Amazon parrot with severe dyspnea was found on the bottom of its enclosure. The bird died while en route to the emergency clinic. At necropsy, the bird's muscle tissue was extremely pale. Exsanguination had occurred secondary to a tear in the liver capsule. Note the pale heart and left liver below the blood clot.

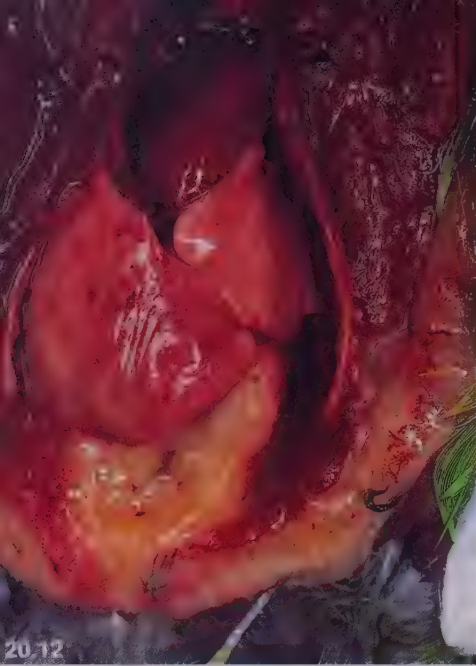### Color 20.10

A Blue and Gold Macaw that was being treated for aspergillosis air sacculitis was presented with an acute onset of anorexia, depression and abdominal swelling. Radiographs indicated a soft tissue density filling most of the abdominal cavity. Abdominocentesis was unproductive. An exploratory laparotomy was performed. When the abdominal cavity was opened, unclotted blood flowed from the incision with each breath. The bleeding originated from a tear in the right lateral liver lobe (arrow). The hemorrhage was controlled with pressure. Both liver lobes had multiple, raised, white lesions that were suspected to be fungal granulomas. The client elected euthanasia. At necropsy, the liver was firm and had multiple, granulomatous-like lesions. Similar lesions were noted in the lungs, and the right caudal thoracic air sac was thickened and necrotic. Histopathology confirmed *Aspergillus* sp. in the lung and air sac. The liver lesions were characterized by massive hepatocellular necrosis and biliary hyperplasia. These lesions are suggestive of aflatoxicosis. Interestingly, the LDH=397, AST=141 and bile acids=1.9, determined two weeks before surgery, did not reflect the severity of the liver damage.

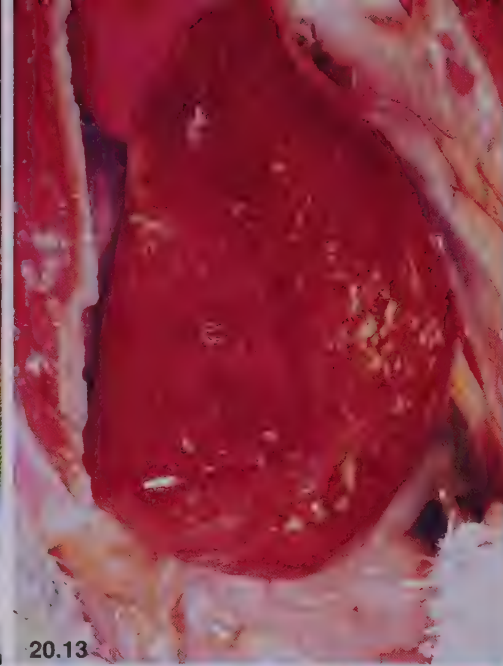### Color 20.11

Cut surface of the liver from the Blue and Gold Macaw in Color 20.10. Note the substantial involvement of the liver and the scarcity of normal-appearing liver tissue.

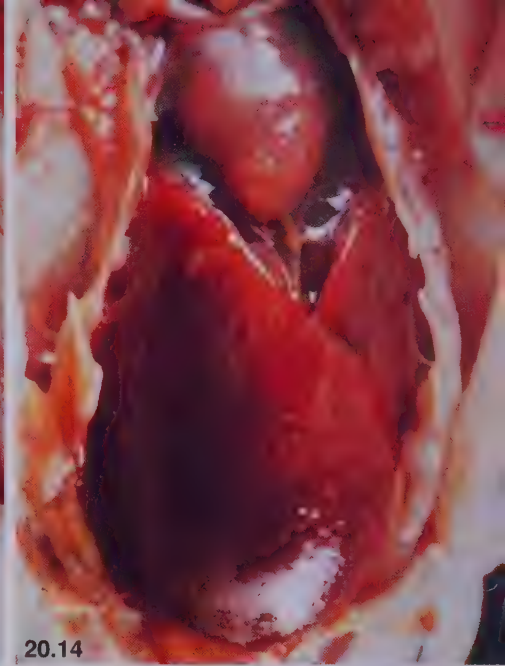



20.12



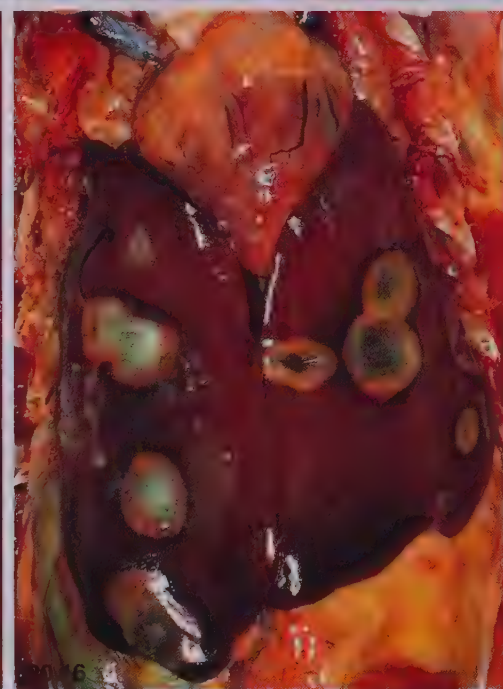20.13



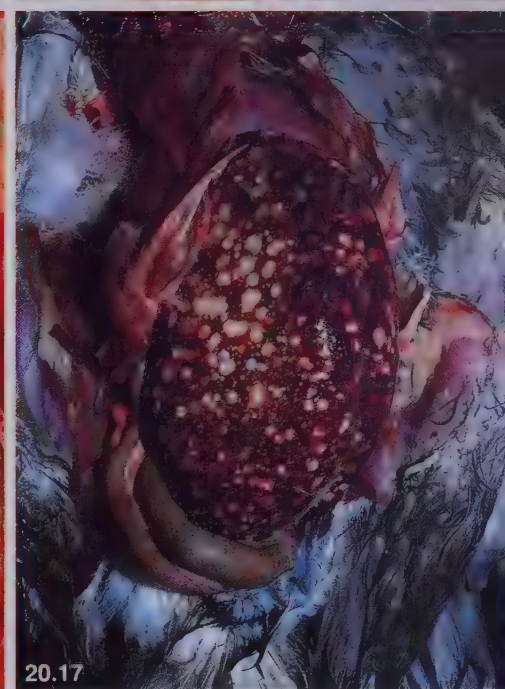20.14



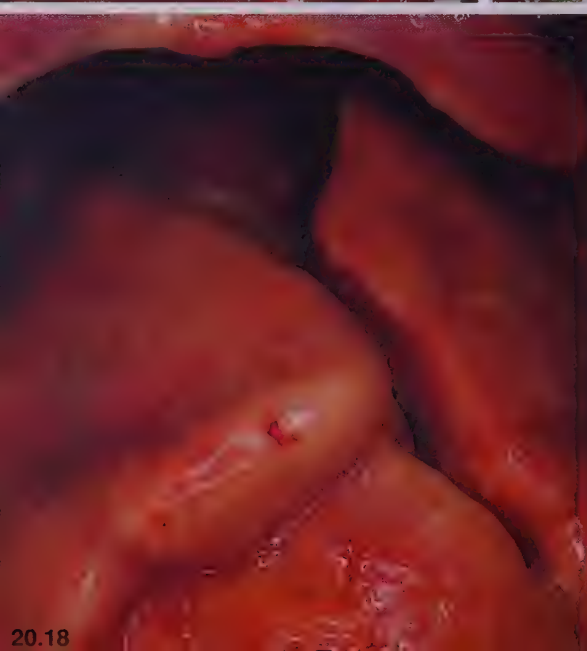
20.15



20.16



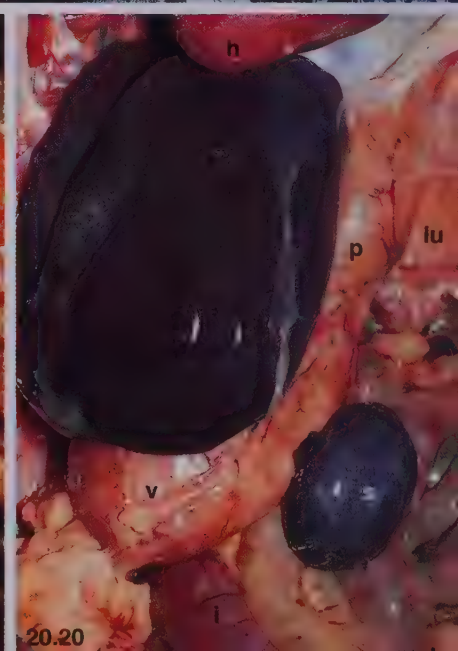20.17



20.18



20.19



20.20

## Hepatology

### Color 20.12

Severe fatty liver degeneration and bacterial hepatitis in a 23-year-old Amazon parrot hen with ovarian cysts.

### Color 20.13

Multifocal, white-to-yellow discoloration of the liver is characteristic of hepatocellular necrosis. The lesions in this African Grey Parrot were caused by *Chlamydia* sp. Bacterial and viral infections can cause similarly appearing lesions.

### Color 20.14

Hepatomegaly and multifocal, white-to-yellow foci in the liver and heart of a mynah bird that died from atoxoplasmosis (courtesy of Carol Partington).

### Color 20.15

Iron storage hepatopathy in a mynah bird. Small brown-black foci were clearly visible throughout the liver parenchyma. The lesions can be more clearly visualized using a magnifying glass (courtesy of Robert E. Schmidt).

### Color 20.16

*Histomonas meleagridis* (blackhead) lesions in the liver of a gallinaceous bird. Multiple round foci with central depressions extending into the liver parenchyma are considered pathognomonic (courtesy of R. Korbel).

### Color 20.17

Mycobacteriosis hepatitis in a Sandhill Crane. *Mycobacterium* spp. infections frequently affect the liver and gastrointestinal tract in birds. Unlike in mammals, infec-

tions rarely occur in the lungs. Mycobacteriosis should be considered in any bird with granulomatous hepatitis. A quick diagnosis can be achieved by acid-fast staining of an impression smear of the cut surface of the liver (courtesy of Robert E. Schmidt).

### Color 20.18

An Amazon parrot was presented with anorexia, dyspnea, depression and weight loss of three days' duration. Radiographs indicated severe hepatomegaly. Abnormal clinicopathologic findings included WBC=25,000, LDH=700, AST=600 and bile acids=150. A fecal antigen test for *Chlamydia* sp. was positive. Doxycycline therapy was initiated, but the bird did not respond and died the following day. Necropsy indicated a severely enlarged, firm, irregular yellow liver. The histopathologic diagnosis was lymphosarcoma. Chlamydia was not detected in any tissues, suggesting that the fecal antigen test result was a false positive.

### Color 20.19

Multiple, disseminated granulomas in the liver of a gallinaceous bird. These lesions were caused by *Mycobacterium tuberculosis* (courtesy of R. Korbel).

### Color 20.20

*Plasmodium* sp. infection in a Peregrine Falcon. The liver (l) and spleen (s) are both enlarged, but the characteristic change is the black discoloration of both organs. Other easily distinguishable organs include the lung (lu), proventriculus (p), ventriculus (v), heart (h) and intestines (i) (courtesy of Robert E. Schmidt).

diets in patients with liver disease frequently trigger neurologic symptoms.

Fasting plasma ammonia levels and plasma ammonia levels 30 minutes after oral loading with  $\text{NH}_4\text{Cl}$  (100 mg/kg in a gelatine capsule) have been used in dogs to establish the ability of the liver to convert ammonia into urea. Fasting plasma ammonia concentrations in healthy psittacines have shown values ranging from 36 to 274  $\mu\text{mol/l}$ , which are well above the fasting concentrations described in dogs. Furthermore, some avian species will normally show up to an eight-fold increase of plasma ammonia concentration on oral ammonia tolerance test (ATT) using the canine protocol, and therefore an abnormal ATT is not diagnostic for portosystemic shunting in these species.<sup>26</sup> Further work is needed to properly diagnose and document the occurrence of hepatic encephalopathy in birds.

#### Avian Hemochromatosis

Limited work has been done on the clinical pathology associated with avian hemochromatosis. The iron status of an individual bird is determined by measuring three main areas of iron: storage iron, transport iron and erythrocyte iron. Storage iron can be semiquantitated by histologic examination of liver biopsies for stainable iron. In humans with hemochromatosis, urinary iron excretion in the six hours following injection of an iron chelating agent, desferrioxamine or diethylenetriamine pentacetic acid (DTPA) is significantly higher compared to normal individuals. Serum concentration of the iron storage protein ferritin is directly related to the available storage iron in the body and is clinically the most useful method for assessing iron stores.<sup>14</sup>

Transport iron in man is determined by measuring serum iron concentration and the total iron binding capacity (TIBC). The latter estimation is performed by determining the amount of iron required to saturate fully the iron-binding protein present in the serum sample. Reference values for serum or plasma iron concentration and TIBC in man are 10-34  $\mu\text{mol/l}$  and 45-72  $\mu\text{mol/l}$ , respectively.<sup>37</sup> In pigeons these values are 11-33  $\mu\text{mol/l}$  and 30-45  $\mu\text{mol/l}$ , respectively.<sup>25</sup> In Ramphastidae, total serum iron concentrations should be below 63  $\mu\text{mol/l}$ , while TIBC should fall below 100  $\mu\text{mol/l}$ .<sup>42</sup> Total serum iron in a mynah bird with confirmed hemochromatosis exceeded 360  $\mu\text{mol/l}$ , while control birds had values that were about 36  $\mu\text{mol/l}$ .<sup>32</sup> (See update on need for biopsy in Chapter 47.)

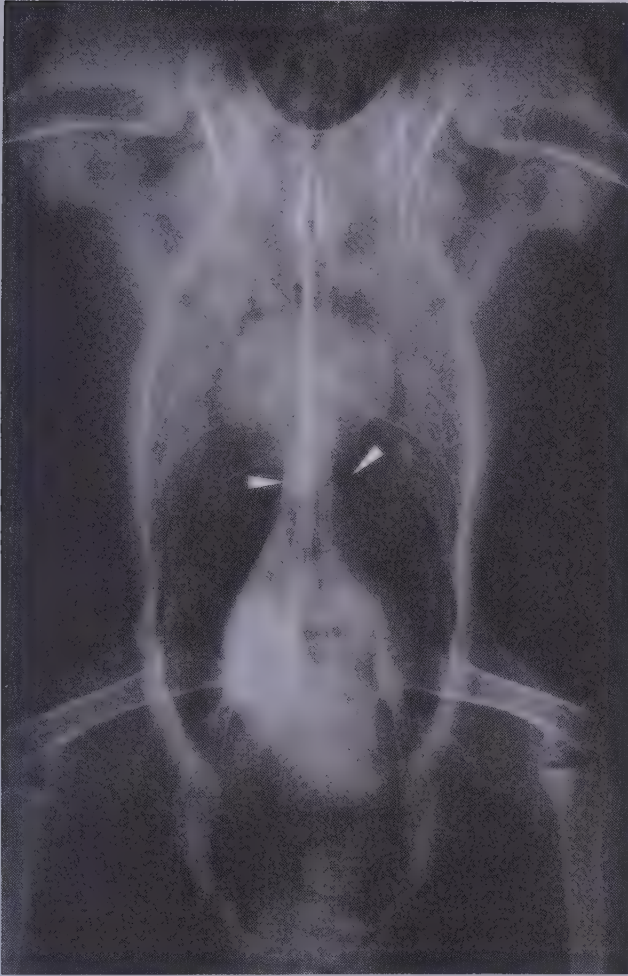Erythrocyte iron can be evaluated by determining the red blood cell morphology and the various red cell parameters, such as PCV, hemoglobin concentration, mean corpuscular volume, mean corpuscular hemoglobin and mean corpuscular hemoglobin concentration. Low erythrocyte iron will be reflected by abnormalities in these parameters. Treatments of patients with hemochromatosis using repeated phlebotomies require frequent evaluation of red cell parameters to detect excessive iron depletion.

#### Plasma Chemistry and Liver Disease

To facilitate interpretation of plasma chemistry, it is advisable to include specific and sensitive indicators of both liver and muscle disease in the plasma chemistry panel (eg, GLDH, AST, CPK, bile acids). It should be stressed that elevated plasma enzyme activities are a sign of recent cell damage and not necessarily of impaired organ function. Most enzymes are not specific for one particular organ. Furthermore, in chronic conditions, extensive damage occurring in the past may have led to major dysfunction of an organ while enzyme activities may have returned to normal. This is a common finding in birds with liver fibrosis (normal AST, but elevated bile acids and extremely low protein and albumin) (Figure 20.2). When periodic blood chemistry is performed in a bird with liver disease, fluctuation of plasma enzymes and bile acids are often noted. Enzymes may be elevated while bile acids are not, and vice versa. Occasionally both variables may be found to be within established reference intervals. Repeated plasma chemistries are recommended when evaluating liver disease to prevent misinterpretation of results.

#### Radiology

Both hepatomegaly and ascites due to liver disease may be diagnosed radiographically. Hepatomegaly and microhepatia are common findings in birds (see Chapter 12). It is important to differentiate between hepatomegaly and cardio-hepatomegaly, because the latter indicates the presence of cardiac failure and secondary congestion of the liver. Caudal displacement of the ventriculus on a lateral radiograph is often caused by enlargement of the liver or associated structures (eg, bile duct or gallbladder in those species that possess one). Loss of the hourglass appearance between the heart and the liver on a ventrodorsal radiograph and widening of the liver beyond a line between the scapula and the acetabulum indicate hepatomegaly. Caudodorsal displacement of the ventriculus is also possible with hepatomegaly. As-

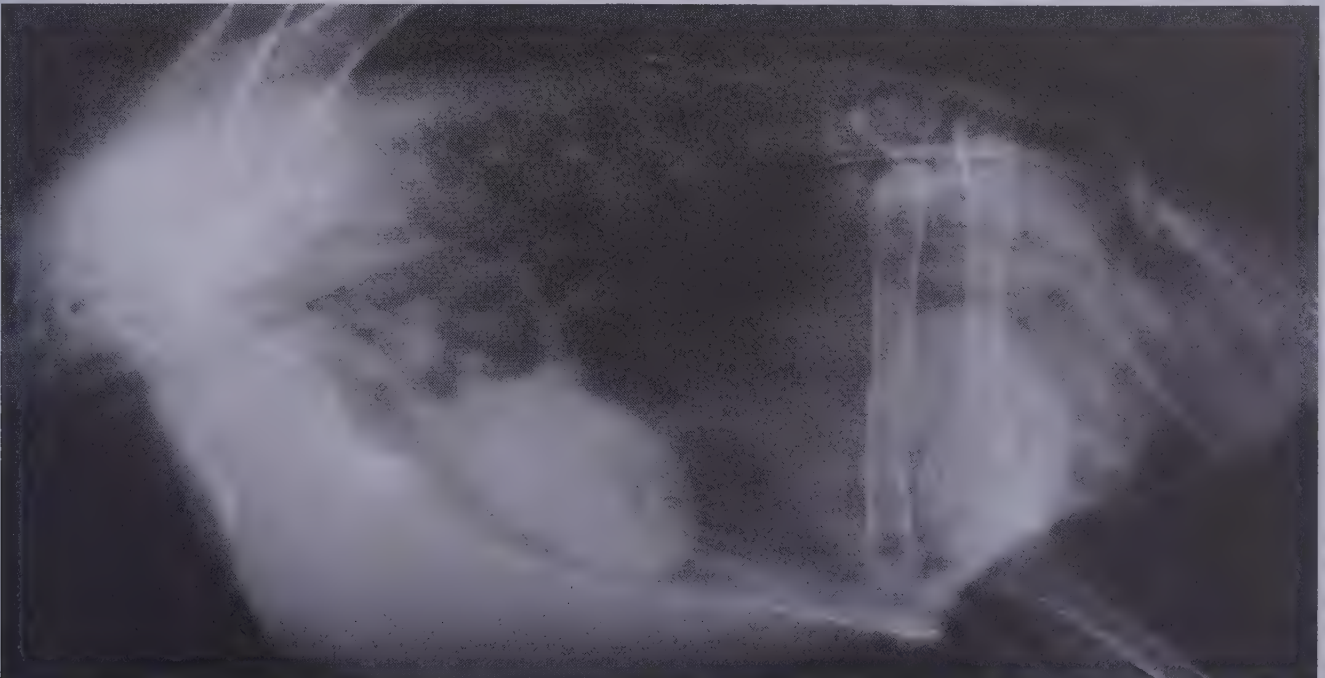


cites and peritonitis may complicate radiographic interpretation and obscure hepatic enlargement by overshadowing the liver. Repeat radiography of the abdomen after removal of peritoneal effusion fluid by paracentesis or diuretic treatment may be needed to visualize an enlarged liver and heart.

### ■ Liver Biopsy

In order for the clinician to establish a definitive diagnosis of liver disease, it is essential to take biopsies for histologic examination. Indications for liver biopsy include biochemical and radiographic changes suggestive of liver disease. Laparoscopic examination and biopsy of the liver through a midline ventral approach just caudal to the sternum is the method of choice to confirm a diagnosis of liver disease (see Chapter 13).<sup>8,16,22</sup> Alternatively, the liver can be exposed through a ventral laparotomy incision and a small wedge of liver tissue can be excised with small surgical scissors. The possibility of severe, life-threatening hemorrhage secondary to liver congestion should be considered prior to biopsy in cases

**FIG 20.2** A one-year-old Scarlet Macaw was presented with blood-tinged feces two days after destroying a plastic bowl. Radiographs indicated severe microhepatia (arrows). Abnormal clinicopathologic findings included WBC=18,500, TP=3.1 and bile acids=130. AST=50 and LDH=130 were both normal. High bile acid levels with normal AST and LDH activities suggest liver dysfunction in the absence of ongoing cellular injury. Histopathologic evaluation of a liver biopsy indicated severe hepatic fibrosis of unknown etiology.



showing radiographic signs of congestive heart failure or electrocardiographic abnormalities indicative of cardiac disease. A liver biopsy site will usually clot without complication, but caution should be exercised when performing biopsies in birds that have prolonged bleeding times after blood collection. Routine tests to determine the efficiency of the avian clotting mechanism are presently not available. In birds with ascites, it is important to perform a biopsy by entering just caudal to the carina to avoid damaging the air sacs and asphyxiating the bird with its own ascitic fluid.<sup>4</sup> Liver biopsies should be examined histologically and cultured for bacteria. Acid-fast staining is of importance for the detection of mycobacteria.

## Liver Diseases

Liver disease occurs frequently in companion birds. Clinical and clinicopathologic signs may indicate liver disease that can be confirmed by histologic examination of a liver biopsy. The following liver diseases discussed below have been documented in gallinaceous, companion or aviary birds.<sup>1,2,6,7,10,13,15,33,34,40</sup> This review is based on known etiologies of avian liver disease, but it should be stressed that an etiologic diagnosis for many hepatopathies cannot be determined.

### Infectious Diseases

#### Bacteria

Many bacterial species can cause hepatitis in birds (Color 20.12). A diagnosis can be made by culturing the organisms from a biopsy specimen. If bacteremia occurs, the same organisms can be isolated by blood culture. Elevated white blood cell counts and monocytosis are common with hepatitis caused by *Mycobacterium avium*. Bacteria that have been associated with hepatitis in birds include: *Borrelia*, *Escherichia coli*, *Salmonella typhimurium*, *Yersinia pseudotuberculosis*, *Acinetobacter*, *Serratia marcescens*, *Staphylococcus*, *Campylobacter*, *Corynebacterium*, *Streptococcus zooepidemicus*, *Pseudomonas*, *Citrobacter*, *Pasteurella haemolytica*, *P. multocida*, *Mycobacterium avium*, *M. bovis*, *M. tuberculosis* (Colors 20.17 and 20.19). In gallinaceous birds, bacterial cholecystitis has been reported. *Eubacterium tortuosum* has

been associated with hepatic granulomas and ulceration of the lower intestines in turkeys.

#### Chlamydiosis

*Chlamydia psittaci* is an extremely common cause of hepatitis in psittacine birds (Color 20.13). Hepatosplenomegaly on radiographs of a bird that has been in recent contact with infected birds is a characteristic clinical presentation (Figure 20.3). A tentative diagnosis can be made by using an ELISA-type antigen capture test for the detection of chlamydial organisms in a fecal swab. Liver biopsies can be screened for chlamydiosis with a Stamp, Giemsa or Macchiavello's stain, or by fluorescent antibody IFA or ELISA.

#### Viruses

Many viruses that infect birds can cause hepatitis alone or in combination with other systemic changes. Elevated plasma GLDH activity has been shown to occur with Pacheco's disease virus infections and should alert the practitioner to extensive liver necrosis. Other herpesviruses are known in other avian species. Pacheco's disease virus, adenovirus, polyomavirus, reovirus, coronavirus and avian serositis virus have all been associated with hepatitis in companion birds (Color 20.8).

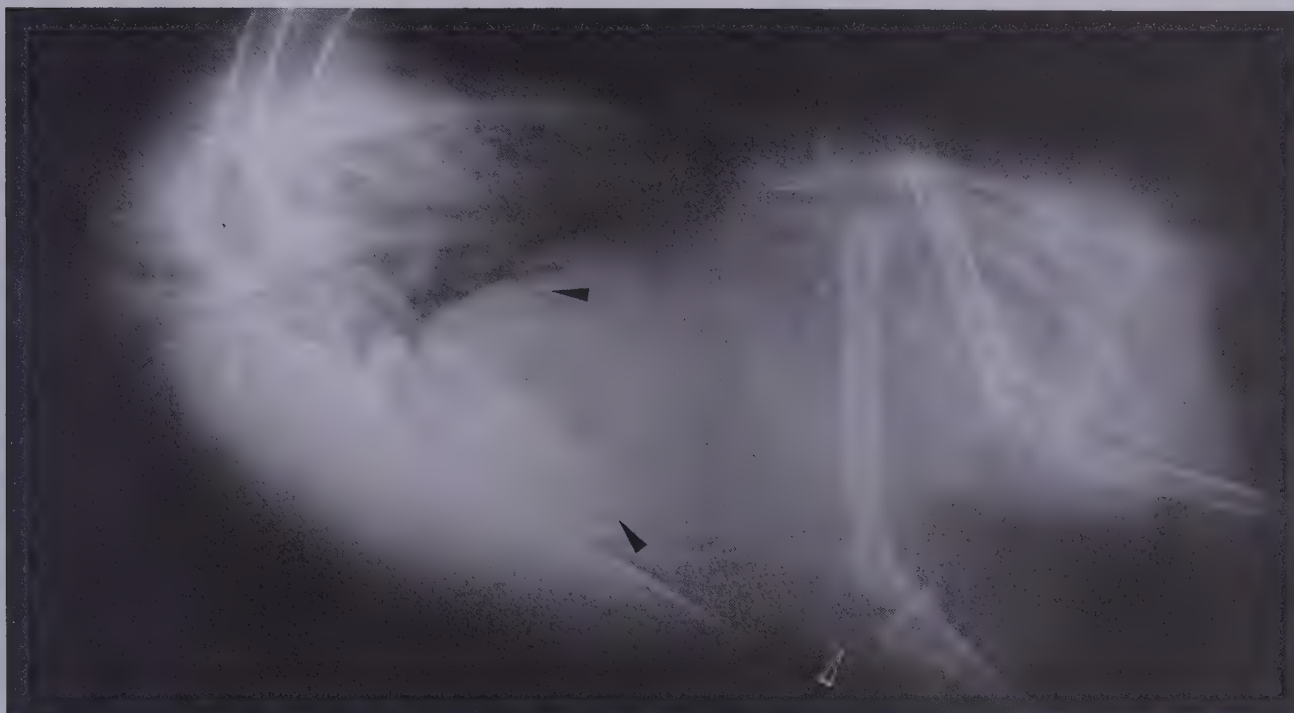
Duck virus hepatitis is a highly fatal, rapidly spreading viral disease of young ducklings that can be caused by either of one of the three known duck hepatitis viruses: DHV types 1 (worldwide distribution, classified as a picornavirus), 2 (only in England, classified as astrovirus), or 3 (only in USA, classified as picornavirus, unrelated to type 1). The sudden onset, rapid spread and acute course of this disease, in combination with hemorrhagic lesions in livers of ducklings up to three weeks of age, are practically pathognomonic.

Turkey viral hepatitis is a highly contagious, often subclinical disease of turkeys that produces lesions only in the liver and pancreas (hence the suggested name hepatopancreatitis). The presence of stress factors is considered to be essential for manifestation of the disease. Mortality is usually very low and does not occur over six weeks of age.

#### Helminths

Trematode infections have been reported in the liver and bile ducts of cockatoos (*Platysomum proxillicensis*), penguins (*Renicola* sp.), cormorants (*Amphimerus elongatus*), ducks and turkeys. A diagnosis can be made by examination of the feces for trematode eggs.





**FIG 20.3** A young Double Yellow-headed Amazon Parrot was presented with lethargy, dyspnea and lime-green excrement. Radiographs indicated massive hepatomegaly causing cranial displacement of the heart (arrows), abdominal swelling (open arrow) and compression of the abdominal air sacs. The bird was positive for chlamydiosis by serology and responded to doxycycline therapy (courtesy of Marjorie McMillan).

It should be noted that in birds, trematode eggs in the feces do not always originate from parasites in the liver. In pigeons and ducks, trematodes can also be found in the alimentary tract (*Echinoparyphium* and *Echinostoma* spp.) or the kidney (*Tamerlania bragai* in the pigeon). In various avian species (including chickens, Passeriformes and Anseriformes), trematodes can be found in the oviduct (*Prosthogonimus ovatus*). Pancreatic trematodes have also been reported in birds.

#### Protozoa

A variety of protozoa can cause hepatopathies. *Trichomonas gallinae*-induced hepatic necrosis has been reported in Columbiformes, Falconiformes and Passeriformes.

*Histomonas meleagridis* is a common cause of hepatitis in captive Galliformes (Color 20.16). Sulfur-colored feces in turkeys, bloody cecal discharge in chickens, leucocytosis with heterophilia, a decreased albumin/globulin ratio and elevated liver enzymes are all suggestive of histomoniasis.

*Leucocytozoon simondi* is a well known cause of mortality in ducks and geese; however, the infection can also occur in other species. Hepatosplenomegaly is

common, and parasites can often be detected in a peripheral blood smear.

Atoxoplasma (*Lancesterella* sp.) and toxoplasma infections are common in Passeriformes, but the latter also occurs in Psittaciformes (Color 20.14). An enlarged liver can often be seen through the transparent abdominal wall in Passeriformes with atoxoplasmosis. Sporozoites may be seen in small lymphocytes in a peripheral blood smear.

Microsporidian infections have been associated with hepatitis in lovebirds.

#### ■ Noninfectious Diseases

##### Metabolic Disorders

In zoological collections, Psittaciformes show a high prevalence of fatty infiltration of the liver (Color 20.7). Hepatic steatosis, hepatic lipidosis and fatty degeneration have all been used to describe the condition. It has been well established that an unbalanced diet (biotin, choline and methionine deficiencies) or excessive consumption of high-energy diets with restricted exercise may lead to fatty degeneration. It should be stressed that many companion

psittacine birds are fed high-energy, multi-nutrient-deficient, all-seed diets that predispose them to fatty liver degeneration.


Fatty liver hemorrhagic syndrome in laying hens has been associated with high-energy diets fed to birds with restricted exercise. The dramatic estrogen-induced increase in liver lipogenesis to supply the developing ova has been suggested as the etiology of this condition. Reticulolysis and fibrosis of hepatic parenchyma is sometimes associated with a fatty liver. Reticulolysis is associated with rupture of intrahepatic portal veins and liver hemorrhage. Affected chickens have greatly elevated serum calcium and cholesterol concentrations. The condition can be artificially induced with estrogen injections.

Fatty liver and kidney syndrome of young broilers or layer pullets is associated with diets with a marginal biotin content. Extensive fatty infiltration occurs in the heart, liver and kidney without inflammatory or degenerative changes. There is a failure of hepatic gluconeogenesis which may lead to an acute hypoglycemia in biotin-deficient, otherwise healthy birds, if normal food intake is interrupted for a short time.

### Iron Storage Disease

Hemosiderosis has been defined as an accumulation of an increased amount of hemosiderin in tissues without alteration of tissue morphology, while hemochromatosis is associated with pathologic lesions in hemosiderin-containing tissues (Color 20.6).<sup>21</sup> Hemosiderin is an iron-containing pigment derived from hemoglobin. The abnormal storage of iron is most frequently seen in the liver, but other organs may be involved. It has been suggested that excessive iron in the diet may be the cause of iron storage disease but this hypothesis has not been confirmed.

Hemochromatosis is most frequently described in Rampastidae (see Chapter 47), Sturnidae (birds of paradise), mynahs and quetzals, but has also been reported in Psittaciformes. Rampastidae are generally clinically normal prior to death, but occasionally affected birds are listless 24 hours prior to dying. Cardiac disease has been reported in mynahs due to iron storage in the myocardium. Electrocardiographic changes are possible due to cardiomegaly. In mynahs, generalized weakness, dyspnea and ascites are common. Radiography may reveal (cardio)hepatomegaly and ascites, and blood chemistry may indicate a liver function disorder (Figure 20.4). A specific diagnosis can be made by histologic examination of a



**FIG 20.4** A four-year-old mynah bird fed predominately a seed-based diet was presented for severe dyspnea, lethargy and abdominal swelling. Radiographs indicated a diffuse soft tissue opacity in the abdomen suggestive of hepatomegaly and ascites. The heart was displaced cranially (arrows). Fluid collected by abdominocentesis was characterized as a transudate (low cellularity, SpGr=1.012 and TP=2 gm/dl). These findings are typical for iron storage disease.

liver biopsy after specific staining for iron (see Chapter 10). Total serum or plasma iron and TIBC may not be helpful in evaluating the iron status of the animal.

### Circulatory Disorders

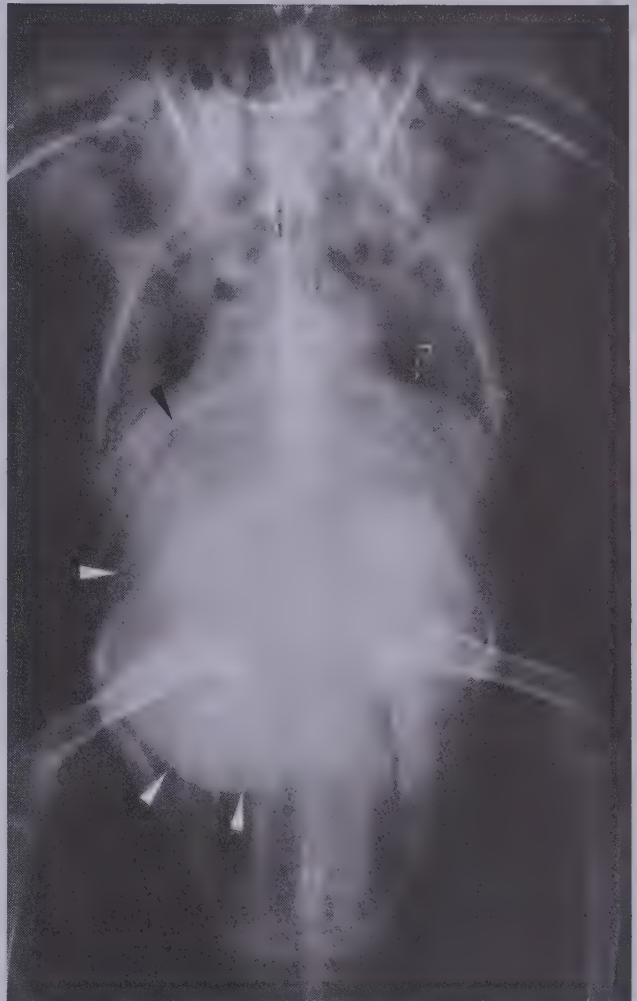
Portal hypertension can occur as the result of right atrioventricular valvular insufficiency. Portal hypertension may cause hepatic congestion. In the acute stage, the liver is swollen; as the disease progresses, the organ may be fibrotic and have a shrunken appearance. When liver enlargement is caused by congestion, a liver biopsy may result in fatal hemorrhage. The use of an artificial substrate (eg, Gelfoam) at the biopsy site to facilitate clotting may help control bleeding.

Anemic infarctions of the liver, especially of the caudal margins, can be seen as a result of bacterial endocarditis. Streptococci or staphylococci are often involved, but other bacteria like *Erysipelothrix rhusiopathiae* (formerly *E. insidiosa*) and *Pasteurella* spp. have also been associated with these lesions.

### Hepatotoxins

Many plants are known to be hepatotoxic in some birds including: rapeseed (*Brassica napus*), ragwort (*Senecio jacobea*), castor bean (*Ricinus communis*),

**FIG 20.5** A mature Blue and Gold Macaw with a history of aspergillosis air sacculitis that was being treated with systemic antifungals became depressed and anorectic (see Color 20.10). Radiographs indicated a diffuse soft tissue opacity throughout the abdomen (arrows). Gas is seen in the dorsally displaced proventriculus (open arrows).



hemlock (*Conium maculatum*), oleander (*Nerium oleander*), *Oxalis* spp., *Grantia* spp., *Crotalaria* spp., *Daubentonia* seed and cotton seed (*Gossypium* spp.). Interestingly, canaries are routinely fed rapeseed and do not appear to be affected by its toxins.

The following substances are hepatotoxic: arsenic, phosphorus, carbon tetrachloride, toxins from certain blue-green algae, halothane, methoxyflurane and mycotoxins (especially aflatoxin from *Aspergillus flavus*, *A. parasiticus* and *Penicillium puberulum*) (Figure 20.5). Degeneration and necrosis of hepatocytes are typical with aflatoxicosis. Bile duct proliferation and fibrosis leaving only islands of hepatocytes are common in chronic cases (Colors 20.10 and 20.11).

Fatty degeneration and the feeding of feeds contaminated with mycotoxins causing aflatoxin hepatitis are likely to be involved in the high incidence of liver disease in birds. Peanuts and Brazil nuts are notorious sources of aflatoxins, but many other seed mixtures can be contaminated. Chemical analysis of food for aflatoxin is possible (see Chapter 37).

### Neoplasia

Liver tumors can be classed as primary and multicentric (metastatic) (see Chapter 25). Examples of the former are hepatoma, hepatocellular carcinoma, cholangioma, cholangiocarcinoma, lipoma, fibroma, fibrosarcoma, hemangioma, and hemangiosarcoma. Examples of metastatic tumors are leukosis/lymphosarcoma, rhabdomyosarcoma, renal carcinoma, and pancreatic carcinoma (Color 20.18).

It has been suggested that there is an association between cholangiocarcinoma and the presence of cloacal papillomatosis in Amazon parrots (see Chapter 19). Likewise, it has been suggested that hemochromatosis in mynah birds and aflatoxicosis in ducks are associated with hepatomas.

### Amyloidosis

Amyloidosis is commonly seen in Anseriformes, gulls and shorebirds. It is caused by deposition of amyloid A (a waxy, translucent substance) in various organs, including liver and kidney (see Chapter 21). Amyloid A is a degradation product of an acute phase, reactant protein. Amyloidosis is often seen in birds with chronic infections (bumblefoot, tuberculosis and aspergillosis). Severe hypoalbuminemia caused by glomerular and hepatic damage can cause ascites and peripheral edema of the feet and legs.

### Traumatic Rupture

Rupture of the liver is most likely to occur secondary to liver diseases, such as fatty degeneration, amyloidosis, mycobacteriosis and neoplasia, but can also occur as a result of trauma (Color 20.9). The reticulolysis that is associated with some liver diseases makes the liver more sensitive to traumatic insult. When the bleeding is limited or confined to a subcapsular hematoma, survival is possible. Birds can also survive liver hemorrhage confined to one of the hepatic peritoneal cavities. This is based on clinical cases and the documentation of blood clots in these cavities during laparotomies.

In the acute phase, bleeding birds may show signs of shock. Radiographically, liver enlargement is indistinguishable from perihepatic hematoma (Color 20.10). A diagnosis is usually made during endoscopy or exploratory laparotomy. Ultrasonography is a useful diagnostic tool in these cases.

## Treatment of Liver Disorders

Generalities about treating avian liver disease can be extracted from known etiologies. The single most important treatment seems to be the administration of a well balanced diet free of hepatotoxins. Moldy foods and seed-based diets, particularly those containing peanuts (unless certified mycotoxin-free), should be avoided. The use of lactulose, hemicellulose and supportive care including IV fluids and assisted feeding are indicated in many cases of hepatitis. Special attention should be given to known causes of fatty degeneration or fatty infiltration of the liver (biotin, choline and methionine deficiencies or excessive consumption of high-energy diets in birds with restricted exercise). A multivitamin injection is indicated when malnutrition is suspected. In birds with hemochromatosis, the iron content of the diet should be drastically reduced (<100 ppm), although high iron content of the diet may not be the only cause of excessive iron storage in the body.

The treatment of choice for hemochromatosis in man is to remove excess iron from the body by phlebotomy (one percent of body weight once a week for six months, then twice a month for two years). Frequent

monitoring of hemoglobin and serum iron level is essential.<sup>35</sup> A few birds with hemochromatosis have responded to phlebotomy therapy (see Chapter 47).<sup>32,41</sup>

When a microbiologic cause of liver disease can be diagnosed, a specific treatment against the causative organism is possible. Doxycycline is the treatment of choice for chlamydiosis (see Chapter 34). Pacheco's disease virus infections can be treated with acyclovir. Liver flukes may be susceptible to praziquantel.

Outbreaks of duck hepatitis virus can be controlled by IM injection of DHV antiserum into each duckling at the time the first deaths are noted.

Ascitic fluid should not be removed from birds with liver disease. Removal of this fluid will further deplete body stores of protein in a bird with an already compromised liver function. The author's preference

for treating ascites is to use a potent diuretic, such as furosemide, to effect, and to take only a small amount of ascitic fluid for diagnostic purposes.

Corticosteroids are occasionally used for the treatment of hepatopathies in man (eg, viral hepatitis, chronic active hepatitis) and may result in a dramatic clinical improvement. Limited experience with prednisolone in cases of chronic active hepatitis of unknown etiology in African Grey Parrots suggests that this drug may also be beneficial for treating some avian liver disorders. The use of corticosteroids in mycotoxicosis may limit the formation of fibrosis; however, corticosteroids may exacerbate an underlying infection and may be contraindicated in cases of infectious hepatitis. Colchicine has been used to prevent the progression of hepatic fibrosis in a conure.<sup>11</sup>

## References and Suggested Reading

- Burr EW: Companion Bird Medicine. Ames, Iowa State University Press, 1987.
- Calnek BW, et al: Diseases of Poultry 9th ed. Ames, Iowa State University Press, 1991.
- De Bruijne JJ, Rothuizen J: The value of serum bile acid and GLDH in the screening for canine liver function disorders. In Blackmore DJ, et al (eds): Animal Clinical Biochemistry, The Future. Cambridge, Cambridge University Press, 1988, pp 175-180.
- Degernes LA: A clinical approach to ascites in pet birds. Proc Assoc Avian Vet, Chicago, 1991, pp 131-136.
- Galvin C: Laboratory diagnostic aids in pet bird practice. Proc 47th Am Anim Hosp Assoc, 1980, pp 41-52.
- Gould J: Liver disease in psittacines. Proc Assoc Avian Vet, Seattle, 1989, pp 125-129.
- Gratz E, Köhler H: Spezielle Pathologie und Therapie der Geflügelkrankheiten [Pathology and Therapy of Poultry Diseases]. Stuttgart, Ferdinand Enke Verlag, 1968.
- Harrison GJ: A clinical comparison of anesthetics in domestic pigeons and cockatiels. Proc Assoc Avian Vet, Boulder, 1985, pp 7-22.
- Hill KJ: Physiology of the digestive tract. In Freeman BM (ed): Physiology and Biochemistry of the Domestic Fowl Vol 4. London, Academic Press, 1983, pp 31-49.
- Hillyer EV: Cholangiocarcinoma in association with cloacal papilloma in two Amazon parrots. Proc Europ Assoc Avian Vet, 1991, pp 332.
- Hoefler H: Hepatic fibrosis and colchicine therapy. J Assoc Avian Vet 5:193, 1991.
- Hoffmann WE, et al: Alterations in selected serum biochemical constituents in equids after induced hepatic disease. Am J Vet Res 48:1343-1347, 1987.
- Howerth EW, et al: Fatal toxoplasmosis in a red lory (*Eos bornia*). Avian Dis 35:642-646, 1991.
- Jacobs A: Iron metabolism, deficiency and overload. In Scott RB (ed): Price's Textbook of the Practice of Medicine. Oxford, Oxford University Press, 1978, pp 1118-1129.
- Jordan FTW: Poultry Diseases 3rd ed. London, Ballière Tindall, 1990.
- Kollias GV: Liver biopsy techniques in avian clinical practice. Vet Clin No Am 14(2):287-298, 1984.
- Lewandowski AH, Campbell TW, Harrison GJ: Clinical chemistries. In Harrison GJ, Harrison LR (eds): Clinical Avian Medicine and Surgery. Philadelphia, WB Saunders Co, 1986, pp 192-200.
- Lin GL, Himes JA, Cornelius CE: Bilirubin and biliverdin excretion by the chicken. Am J Phys 226:881-885, 1974.
- Lind GW, Gronwall RR, Cornelius CE: Bile pigments in the chicken. Res Vet Sci 8:280-282, 1967.
- Lothrop C, et al: Miscellaneous diseases. In Harrison GJ, Harrison LR (eds): Clinical Avian Medicine and Surgery. Philadelphia, WB Saunders Co, 1986, pp 525-536.
- Lowenshine L: Nutritional disorders of birds. In Fowler ME (ed): Zoo and Wildlife Animal Medicine 2nd ed. Philadelphia, WB Saunders Co, 1986, pp 204-205.
- Lumeij JT: Diagnosis of hepatobiliary disease. In Lumeij JT: A Contribution to Clinical Investigative Methods for Birds, with Special Reference to the Racing Pigeon, *Columba livia domestica*. PhD Thesis, Utrecht University, 1987, pp 35-77.
- Lumeij JT: Enzyme profiles and biochemical changes due to liver disease in the racing pigeon. In Blackmore DJ, et al (eds): Animal Clinical Biochemistry, The Future. Cambridge, Cambridge University Press, 1988, pp 161-174.
- Lumeij JT: Fasting and postprandial plasma bile acid concentrations in racing pigeons (*Columba livia domestica*) and mallards (*Anas platyrhynchos*). J Assoc Avian Vet 5:197-200, 1991.
- Lumeij JT, DeBruijne JJ: Blood chemistry reference values in racing pigeons (*Columba livia domestica*). Avian Pathol 14:401-408, 1985.
- Lumeij JT, Peccati C: Suspected hepatoencephalopathy in an African grey parrot. Proc Europ Assoc Avian Vet, Utrecht, 1993, pp 558-566.
- Lumeij JT, et al: Enzyme activities in tissues and elimination half-lives of homologous muscle and liver enzymes in the racing pigeon (*Columba livia domestica*). Avian Pathol 17:851-864, 1988.
- Lumeij JT, et al: Changes in plasma chemistry after drug-induced liver disease or muscle necrosis in racing pigeons (*Columba livia domestica*). Avian Pathol 17:865-874, 1988.
- Lumeij JT, Overduin L: Plasma chemistry reference values in psittaciformes. Avian Pathol 19:235-244, 1990.
- Lumeij JT, Remple JD: Plasma bile acid concentrations in response to feeding in peregrine falcons (*F. peregrinus*). Avian Dis 36:1060-1062, 1992.
- Lumeij JT, Wolfswinkel J: Tissue enzyme profiles of the budgerigar (*Melopsittacus undulatus*). In Lumeij JT: A Contribution to Clinical Investigative Methods for Birds, with Special Reference to the Racing Pigeon, *Columba livia domestica*. PhD Thesis, Utrecht University, 1987, pp 71-77.
- Morris PJ, Avgeris SE, Baumgarner RE: Hemochromatosis in a greater Indian hill mynah (*Gracula religiosa*). J Assoc Avian Vet 3: 87-92, 1989.
- Pleumeekers J: Leveraandoeningen bij vogels [Liver diseases in birds]. Student thesis. Faculty of Veterinary Medicine and Sciences, Utrecht University # 83-06. 20 pages, 120 references.
- Quessenberry KE, et al: Hepatic trematodiasis in five cockatoos. J Am Vet Med Assoc 189:1103, 1986.
- Read AE: The liver. In Scott RB (ed): Price's Textbook of the Practice of Medicine 12th ed. Oxford, Oxford University Press, 1978, pp 557-580.
- Rutgers HC, et al: Serum bile acid analysis in dogs with experimentally induced cholestatic jaundice. Am J Vet Res 49:317-320, 1988.
- Scott RB (ed): Price's Textbook of the Practice of Medicine. Oxford, Oxford University Press, 1978, p 1458.
- Steiner CV, Davis RB: Caged Bird Medicine: Selected Topics. Ames, Iowa State University Press, 1981.
- Tenhunen R: The green color of avian bile. Biochemical explanation. Scand J Clin Lab Invest 16 suppl 27:9, 1971.
- Wadsworth PF, Jones DM, Pugsley SL: Fatty liver in birds at the Zoological Society of London. Avian Pathol 13:231-239, 1984.
- Worell A: Phlebotomy for treatment of hemochromatosis in two sulfur-breasted toucans. Proc Assoc Avian Vet, Chicago, 1991, pp 9-14.
- Worell A: Serum iron levels in Ramphastids. Proc Assoc Avian Vet, Chicago, 1991, pp 120-130.
- Worell A: Further investigation in Ramphastids concerning hemochromatosis. Proc Assoc Avian Vet, Nashville, 1993, pp 98-107.

**C**onfirming a diagnosis of renal disease in birds is often difficult because clinical signs are generally nonspecific and are frequently complicated by secondary changes caused by renal dysfunction. Lethargy, with a diminished appetite leading to emaciation, is typical of renal disease. Birds may appear unable to fly, while in reality they are too weak to fly. A distended abdomen with or without ascites may be seen with renal tumors. In over 50% of renal neoplasms, the tumor can be palpated (Color 21.11).<sup>2</sup> Renal masses and ascites may prevent normal air flow and cause dyspnea because of compression on the abdominal and caudal thoracic air sacs (Color 21.4). Urinary output may vary from anuria to polyuria. In oliguric patients, the possibility of acute nephrotoxic renal failure should be considered, and the client should be carefully questioned concerning the administration of nephrotoxic drugs (eg, allopurinol, aminoglycosides, polypeptide antibiotics and sulfonamides) or exposure to sodium chloride (eg, saline as drinking water, sea sand for bedding material, heavily salted foods) or other nephrotoxic substances (eg, heavy metals, ethylene glycol, carbon tetrachloride).

Clinical findings can be quite suggestive of renal disease. During the physical examination, signs of dehydration or shock may suggest a diagnosis of prerenal renal failure. Dehydrated birds have a reduced skin elasticity and dry mucous membranes. Subcutaneous urate tophi or urate accumulations in joints are signs of articular gout (Color 21.2), a clinical sequela to hyperuricemia, which in birds is caused by a renal disorder. Unilateral or bilateral paresis of the legs is often the first clinical sign of renal neoplasm in psittacine birds (particularly budgerigars). Neurologic signs are seen in about one-third of renal neoplasms, but may also be caused by other space-occupying lesions in the ipsilateral kidney (eg, iatrogenic hematoma, renal aspergillosis) (Color 21.2). Neurologic changes are secondary to compression or inflammation of branches of the lumbosacral plexus, which pass through the kidneys (Color 21.1). Constipation may also occur if the renal mass compresses the large intestine. In large birds, a lubricated, gloved finger can be inserted and moved dorsally in the cloaca in order to palpate the caudal division of the kidney. Any swelling, asymmetry or tenderness may be an indication of renal disease.<sup>4</sup>

Clinicopathologic changes in the blood and urine depend on location and severity of the renal lesions (eg, glomerulopathies may lead to severe protein loss and hypoalbuminemia, while tubular lesions may lead to hyperuricemia or polydipsia).

## Anatomy and Physiology of the Kidney

The paired kidneys are located dorsally in a depression of the pelvis. Each kidney is made up of three divisions that are frequently referred to as lobes (cranial, middle and caudal). The divisions are composed of lobules with a large cortical mass and a small medullary mass. It is difficult to demarcate between the cortical and medullary portions of the lobules. The cortex is composed of both reptilian-type nephrons that do not contain loops of Henle and mammalian-type nephrons that do contain loops of Henle. The reptile-type nephrons are most numerous, and birds are less efficient in the excretion of electrolytes than mammals. The cortical-type nephrons are uricotelic and the medullary-type produce urine. The former are located on the surface of the kidney, and the latter are located in a deeper orientation. The nephrons' collecting ducts and ureters are contiguous. The kidneys of birds are larger by weight than in mammals. There are three pairs of renal arteries. The anterior branch arises from the aorta, and the middle and posterior branches arise from the sciatic artery or external iliac artery. The anterior branch supplies the cranial division of the kidney, and the middle and posterior branches supply the middle and caudal divisions of the kidney.

Birds have a renal portal system in which the renal portal vein functions like an artery by carrying blood to the tubules. Flow of blood into the kidneys from the renal portal system is controlled by valves. These valves are bilateral and are located at the junction of the external iliac vein and the renal vein. Studies suggest that acetylcholine causes the valves to close and epinephrine causes them to open. If agents excreted by the renal tubules are injected into the legs, they are excreted by the tubules on the injection side of the body before entering the general circulation.

Glucose is completely filterable and is normally absorbed by the kidney. Glucosuria indicates that renal absorption is damaged or that excessively high levels of glucose are being presented to the kidneys. The avian kidney has a reduced capacity to secrete creatinine in comparison to uric acid.

Renal output varies with the water intake and stress levels of the bird, but is generally considered to be 100 to 200 ml/kg/day. By comparison, dehydrated birds may have a renal output of 25 ml/kg/day. There is a physiologic polyuria that occurs a few hours before egg laying.

Some urine water that is excreted into the cloaca is passed by antiperistaltic movement of the cloaca into the colon where absorption of the liquid occurs. In dehydrated birds, 15% of urine water may be reabsorbed from the colon. The amount of water absorbed by the colon is decreased with polyuria or with a stress-induced defecation creating a moist-appearing excrement.

### Pathophysiology

#### Etiology of Gout

Uric acid (UA) is produced in the liver and is the major end product of deamination of amino acids in birds. It constitutes approximately 60 to 80% of the total excreted nitrogen in avian urine. Uricotelism permits excretion or storage of nitrogen waste in a small volume of water. Uric acid is relatively non-toxic when compared to urea or ammonia. This method of handling nitrogenous waste is essential for embryo development within an egg. Uricotelism may also be viewed as an adaptation for water conservation.


Uric acid is synthesized in the liver. Ninety percent of its excretion is via tubular secretion from reptilian-type nephrons and therefore largely independent of urine flow rate. The clearance of uric acid surpasses the glomerular filtration rate by a factor of eight to sixteen and is occasionally even higher. The rate of secretion is largely independent of the state of hydration because UA excretion is independent of tubular water reabsorption. Very high concentrations of uric acid can be found in ureteral urine in dehydrated birds. Renal function disorders can eventually lead to elevated uric acid concentrations. However, non-protein nitrogen substances in plasma, such as uric acid, creatinine and urea will be elevated only when renal function is below 30% of its original capacity.

Hyperuricemia is defined as any plasma uric acid concentration higher than the calculated limit of solubility of sodium urate in plasma and is an indication of nephrosis or impaired renal dysfunction. An ordinary aqueous solution at 37°C, with a sodium concentration equal to that of normal human plasma is saturated when the urate concentration reaches 383 to 407  $\mu\text{mol/l}$ . It is generally accepted that the upper limit of solubility of urate in human plasma, is 420  $\mu\text{mol/l}$ .<sup>3</sup> Urate solubility increases with higher sodium concentrations and higher temperatures. When the higher body temperature of birds (up to 43°C) is taken into account, the theoretical limit of solubility would be about 600  $\mu\text{mol/l}$ . Because avian species have a higher plasma sodium concentration than humans (136-145 mmol/l), the theoretical limit of urate solubility is even higher. Hyperuricemia can result in urate precipitation in joints (articular gout) (Colors 21.18 and 21.12) and in visceral organs or other extra-visceral sites (visceral gout) (Color 21.7). The exact mechanism of deposition or the predilection for gout to occur in certain sites is unknown. Gout should not be regarded as a disease entity, but as a clinical sign of any severe renal dysfunction that causes a chronic, moderate hyperuricemia.

When birds are provided with dietary protein in excess of their requirements, the surplus protein is catabolized and the nitrogen released is converted to uric acid. The total amount of uric acid formed may surpass the clearing capacity of this substance from the body, and hyperuricemia and articular gout may result. The use of high-protein poultry pellets as the bulk food in psittacine aviaries may result in an increased incidence of gout (See Chapter 3).

▪ **Articular and Visceral Gout** There is no consensus on the different etiologies of articular and visceral gout in birds. The following hypothesis seems to explain all known facts.

A plasma uric acid concentration that is slightly above the solubility of sodium urate will lead to uric acid precipitation in the body. Predilection sites are those areas where the solubility of sodium urate, for whatever reason, is lower than in other areas (Figure 21.1). The joints and synovial sheaths may be predilection sites because of a lower temperature than the rest of the body. Once uric acid deposits have occurred in a specific area, these deposits will grow with time, forming tophi (accumulations of uric acid) (Color 21.8).



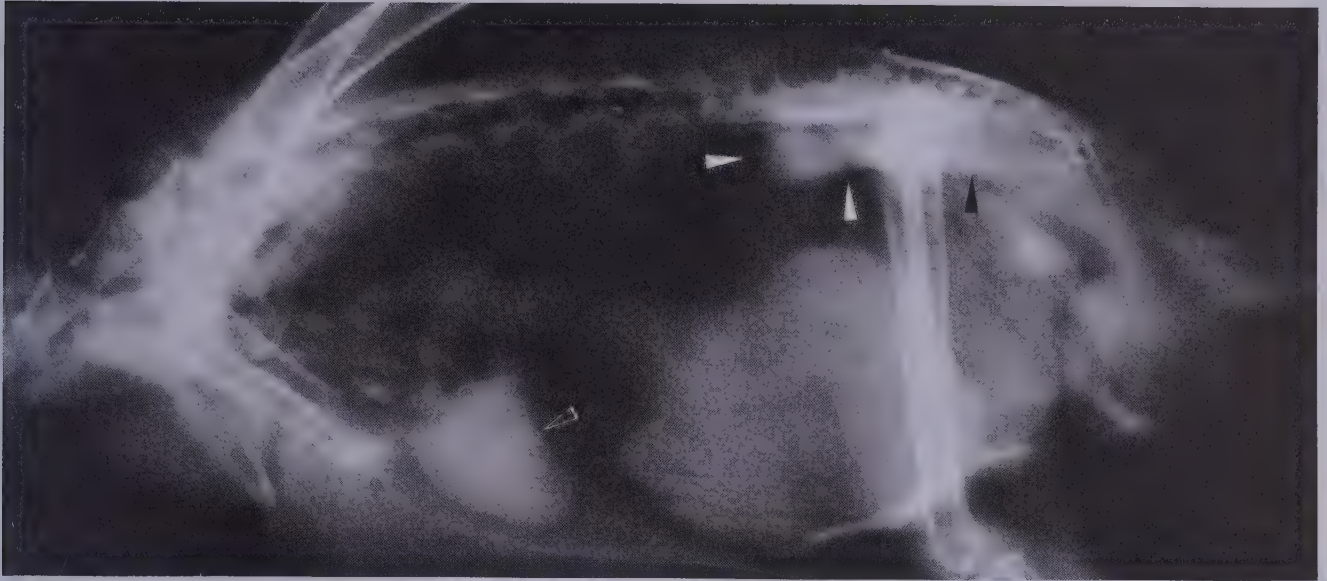
**FIG 21.1** A six-year-old male budgerigar was presented for lameness of several days' duration. Multiple, firm, raised nodules (tophi) were noted at several periarticular locations. The severe articular gout was considered unresolvable and the bird was euthanized. Histopathology revealed severe nephritis.

If, for whatever reason, uric acid crystals precipitate in the tubules or collecting ducts of the kidney (eg, severe dehydration of long duration, hypovitaminosis A) or the ureters, an acute obstructive uropathy (postrenal obstruction) will occur (Color 21.3). These birds develop anuria or gross oliguria, and tubular secretion of uric acid is severely compromised or stops. This results in a rapid and severe elevation of plasma uric acid concentration with precipitation of urates on many visceral surfaces, including those predilection sites for articular gout. Visceral gout will rapidly lead to death of the affected animal. This hypothesis is supported by the fact that inflammation and tophi formation are rare with visceral gout, because the condition has a rapidly fatal course. There is simply no time for an inflammatory reaction or tophi to develop. The kidney tubules, collecting ducts and ureters may contain uric acid deposits.

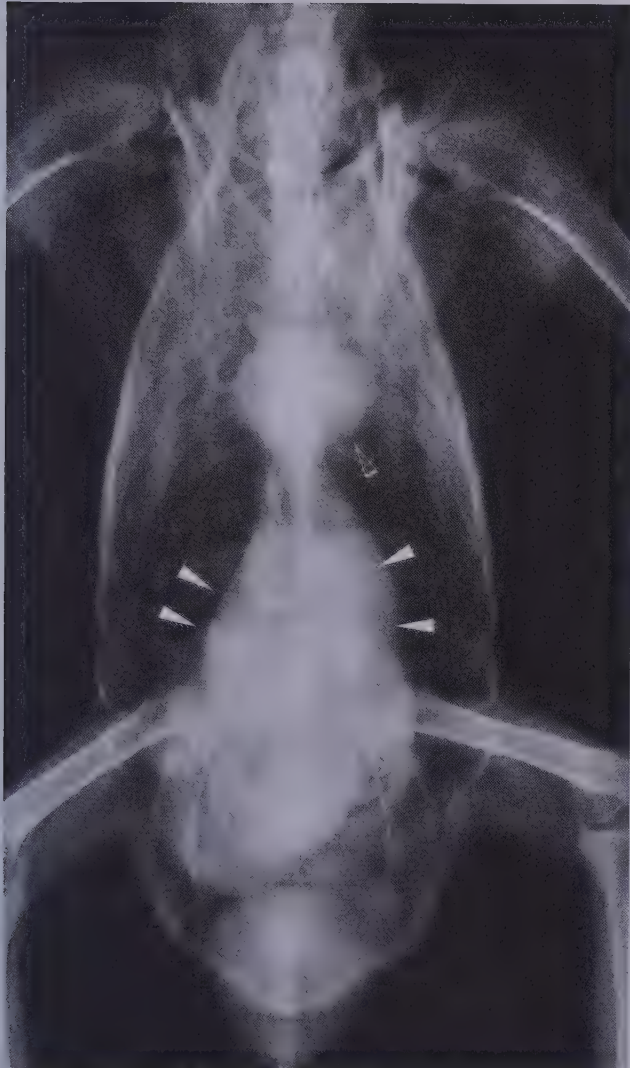
Acute, renal tubular failure, which would lead to acute abolishment of uric acid secretion, would result in a similar course of events. In this situation, visceral gout could develop without uric acid deposits forming in the tubules, collecting ducts and ureters.

The acute mortality seen in birds with visceral gout is probably not due to the effects of hyperuricemia, because uric acid is generally a nontoxic, insoluble substance. It is likely that these birds die from cardiac arrest caused by hyperkalemia, although this hypothesis needs confirmation.





**FIG 21.2** An adult male Umbrella Cockatoo was presented with severe depression, emaciation (470 g) and putrid, watery diarrhea. Abnormal clinical pathologic findings included WBC=46,000, PCV=34%, TP=7.5 and LDH=500. Radiographic lesions included a microcardia (open arrow) and radiodense kidneys (arrows), both of which are indicative of dehydration and hypovolemia. Necropsy findings included small irregular kidneys with multiple granulomas and granulomatous tubulointerstitial nephritis.



### Acute and Chronic Renal Failure

Renal dysfunction may result from any progressive destructive condition affecting both kidneys (chronic renal failure), but can also occur in conditions wherein the function of the kidneys is rapidly and severely, but often reversibly, compromised (acute renal failure) (Figure 21.2). In the latter condition, oliguria usually occurs, while in the former situation, polyuria is normally seen. Dehydration and shock (prerenal renal failure), urolithiasis (postrenal renal failure) and urinary tract infections and the administration of nephrotoxic drugs can all cause changes that mimic irreversible chronic renal failure. Appropriate and timely treatment of the former conditions can often prevent further damage and in some cases result in improved function. Extrarenal factors such as infection, gastrointestinal hemorrhage and hypovolemia can disturb an otherwise stable, well compensated, asymptomatic patient with chronic renal disease and precipitate a life-threatening, acute clinical change.

### Prerenal Azotemia

Prerenal azotemia can be defined as the clinical condition associated with reduced renal arterial pressure or perfusion leading to oliguria and retention of

nitrogenous urinary waste products in the blood. It is often seen during shock or severe dehydration. In clinical textbooks, it is commonly stated that dehydrated birds have elevated plasma uric acid concentrations. In recent experimental studies, elevated plasma uric acid concentrations were not observed in racing pigeons that were deprived of water for four days, while plasma urea concentration showed a significant 6.5- to 15.3-fold increase above reference values. Urea is normally present in low concentration in avian plasma and determination of this has traditionally been considered of little value in evaluating renal function in birds; however, plasma urea appears to be the single most useful variable for early detection of prerenal causes of renal failure (dehydration).<sup>21</sup>

These observations can be explained by the fact that urea is excreted in the kidneys by glomerular filtration, while tubular reabsorption is dependent on tubular urine flow, which in turn depends on the state of hydration. In a hydrated bird, almost all of the filtered urea is excreted. When a bird is dehydrated, nearly all of the filtered urea is reabsorbed. The tubular reabsorption of urea in conditions of renal failure, accompanied by a low urine flow (eg, dehydration) in combination with a nearly unchanged excretion of uric acid, causes a disproportionate increase in plasma urea concentration, which results in an elevated urea:uric acid ratio.

Chronic, progressive dehydration may eventually lead to hyperuricemia. This might be caused by reduced tubular blood supply that leads to reduced uric acid secretion or by uric acid precipitation in the tubuli caused by active tubular secretion of uric acid in the absence of urine flow. The latter condition appears similar to acute uric acid nephropathy described in man.

### Postprandial Effects

It has been demonstrated that a significant postprandial increase in plasma uric acid (UA) and urea concentration occurs in Peregrine Falcons and Red-tailed Hawks.<sup>24,25</sup>

Postprandial plasma UA levels were similar to those in birds suffering from hyperuricemia and gout and were well above the theoretical limit of solubility of urate in plasma. It is not clear why at least twelve hours of postprandial hyperuricemia does not result in uric acid deposition in the tissues. The fact that Peregrine Falcons have relatively high plasma sodium concentrations might partially explain their

tolerance of high plasma UA levels. In order to prevent misinterpretation of high plasma UA levels caused by the ingestion of food, it is recommended that repeat samples be evaluated following a fasting period in any bird that initially has a high plasma UA or urea concentration.

### Evaluation of Urate Tophi

Macroscopically, the aspirated material from articular gout looks like toothpaste (Color 21.10). The presence of urate can be confirmed by performing the murexide test or by microscopic examination of aspirates from suspected tophi. The murexide test is performed by mixing a drop of nitric acid with a small amount of the suspected material on a slide. The material is dried by evaporation in a flame and allowed to cool. One drop of concentrated ammonia is added, and if urates are present, a mauve color will develop. Microscopically, sharp, needle-shaped crystals can be seen in smears. A polarizing microscope is helpful in identifying the typical crystals.

### Blood Changes

Apart from elevated concentrations of nonprotein nitrogen substances, a number of other variables are known to change in mammals as a result of acute or chronic renal failure. Hyperkalemia, which may lead to severe electrocardiographic changes and cardiac arrest, is a particular problem in acute renal failure. Hyperkalemia (5.2 mmol/l) was described in a Red-tailed Hawk with acute renal failure.<sup>24</sup> In man, plasma potassium concentration can be lowered promptly and for a number of hours by infusion of one liter of 10% glucose solution containing 10 to 20 IU insulin; however, in birds, insulin may cause acute hypoglycemia, CNS swelling and death. Infusion of 10% calcium gluconate solution may reverse the cardiotoxic effects of severe hyperkalemia without affecting plasma potassium concentration. Hypocalcemia and hyperphosphatemia are common in mammals with renal failure. The former may lead to hypocalcemic tetany, especially with rapid correction of acidosis. Because these variables have significant therapeutic implications, documentation of their occurrence in avian renal disease is necessary. Anemia has also been documented in birds with chronic renal failure.

## Clinicopathologic Diagnosis of Renal Dysfunction

### Urinalysis

Analysis of urine has been shown to be a valuable diagnostic tool in veterinary medicine. Examination of urinary sediment and determination of urinary protein concentration are the most valuable procedures in the differential diagnosis of renal diseases. Renal function tests provide information on the degree of functional impairment. Urinalysis may give an early warning of renal damage or impaired renal function long before there is an increase in plasma nonprotein nitrogen concentrations. Signs of renal damage or impaired renal function include proteinuria, glucosuria without hyperglycemia and casts or cells in urinary sediment.

Despite its high diagnostic value, urinalysis is not routinely performed in avian medicine, perhaps because it seems difficult to separate urine from feces. Practical guidelines for urinalysis in companion birds have been developed and are an indispensable part of the diagnostic workup in polyuric birds.<sup>38,39</sup> The identification of casts in urinary sediment is strongly suggestive of renal disease. In polyuric cases, collection of a urine sample is relatively simple and can be performed by aspirating the fluid part of the excreta into a syringe from a clean enclosure floor covered by wax paper. It is important that the urine sample be relatively free of urates to ensure the diagnostic value of microscopic examination of the sediment. Sediments obtained from the total renal fraction of the excreta will contain excessive urates; the results are of limited diagnostic value. Clinically normal birds have a tendency to become polyuric when in a stressful environment (eg, the veterinary clinic). In these birds, a urine sample is easy to obtain because of the bird's tendency to increase the frequency of cloacal emptying when nervous (Color 21.13). This will result in the excretion of urine fraction that has not moved retrograde into the large intestine where absorption of water and salts typically occurs.

Urate-free urine samples should be examined for specific gravity or osmolality, color, clearness, pH, protein, glucose, hemoglobin and the sediment should be examined microscopically.

Several methods for collecting avian urine from non-polyuric birds have been reported. The modified cloacal cannula method<sup>5,15</sup> is the most appropriate for clinical use in docile birds (eg, racing pigeons) because it is the least invasive and is useful under clinical conditions. Reference values for twelve chemical and physical variables established in supernatants of pigeon urine (7000 G for 2 minutes) collected with the cloacal cannula method have been established (Table 21.1) and might provide a new perspective for the application of urinalysis in avian medicine.

TABLE 21.1 Reference Values (P<sub>2.5</sub>-P<sub>97.5</sub>) for Pigeon Urine<sup>15</sup>

Variable	Reference Values (SI units)
Urine production	2.3-19.7 ml/kg/h
Osmolality	27-193 mOsmol/kg
Flow-osmol factor	237-1847 mOsmol/ml/kg <sup>2</sup> h
Glucose	0-3.2 mmol/liter
Total protein	0.11-1.99 g/liter
Uric acid	1.2-10.1 mmol/liter
pH	5.5-6.9
Na <sup>+</sup>	2.0-27 mmol/liter
K <sup>+</sup>	4.0-27 mmol/liter
Inorganic P	0.2-10.9 mmol/liter
Cl <sup>-</sup>	5.0-56 mmol/liter
NH <sub>4</sub> <sup>+</sup>	4.6-39.5 mmol/liter

### Osmolality and Specific Gravity

The low urine osmolality as reported in Table 21.1 can be explained by the fact that birds can produce urine with a considerably lower osmolality than the osmolality of blood plasma, due to the presence of reptilian-type nephrons as well as mammalian type nephrons.<sup>29,44</sup> High urine osmolalities are common in avian species that are adapted to desert situations (Zebra Finch and budgerigar). Budgerigars can survive long periods (up to a month) without water under certain conditions;<sup>41</sup> however, domesticated budgerigars and finches that are provided free-choice water may lose much of their compensatory ability. Maximum urine osmolalities in birds vary from 500 to 1000 mOsmol/kg.<sup>41</sup> The emu is adapted to the Australian semidesert and has a low turnover rate of water, but has a limited renal concentrating ability with a maximal urine:plasma osmotic ratio of only 1.4:1.5. In this species, the large intestine has been adapted to preserve water. The high resorptive capacity may be related to increased folding of the mucosal surface, which increases the surface area by a factor of five.<sup>43</sup>

## Nephrology

### Color 21.1

In health, the kidneys are dark red-brown and consistent in color. Cranial (k1), middle (k2) and caudal (k3) divisions of the kidney adhere tightly to the synsacrum in the dorsal abdominal wall. The right kidney has been removed to show the relationship of the kidneys with the synsacrum (s) and the sacral nerve plexus (arrow). Other structures that are easily identified include the lung (lu), left ovary (o) and oviduct (open arrow).

### Color 21.2

A Black Palm Cockatoo with a history of progressive rear limb ataxia died and was presented for necropsy. The walls of the left abdominal and caudal thoracic air sacs were thickened, and a velvet-like yellow material was present on the surface of the membranes (arrow). The cranial and middle divisions of the left kidney and the ischiatic nerve (open arrow) were also involved. Aspergillosis air sacculitis with extension to the kidneys and nerves was the cause of death in this bird.

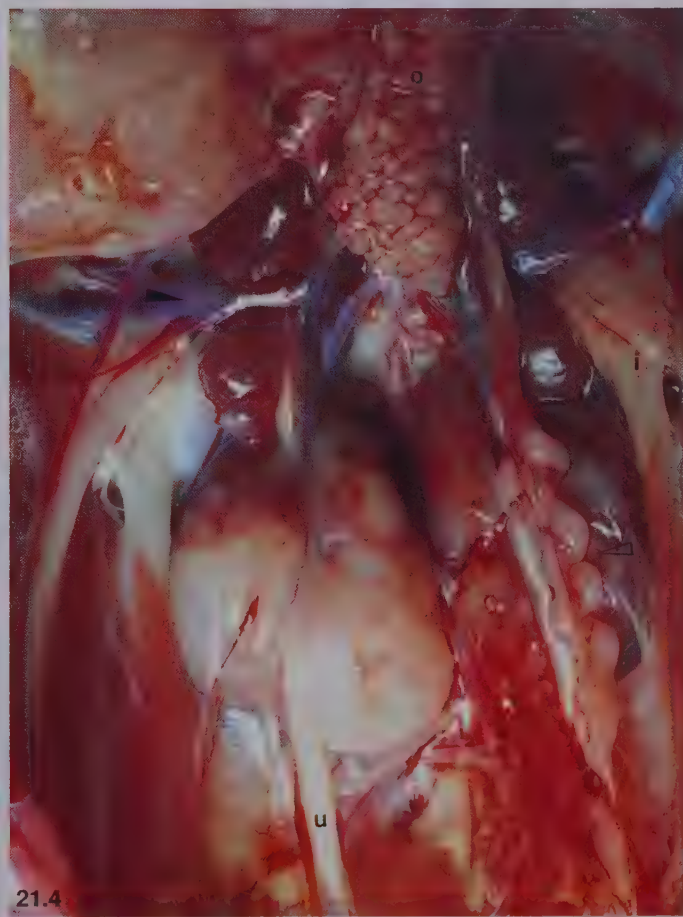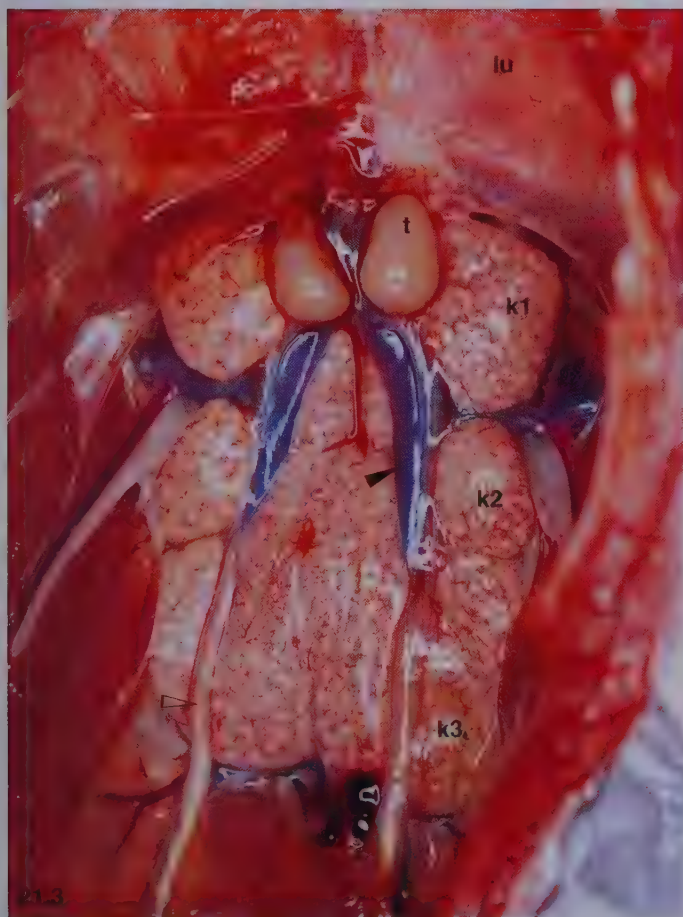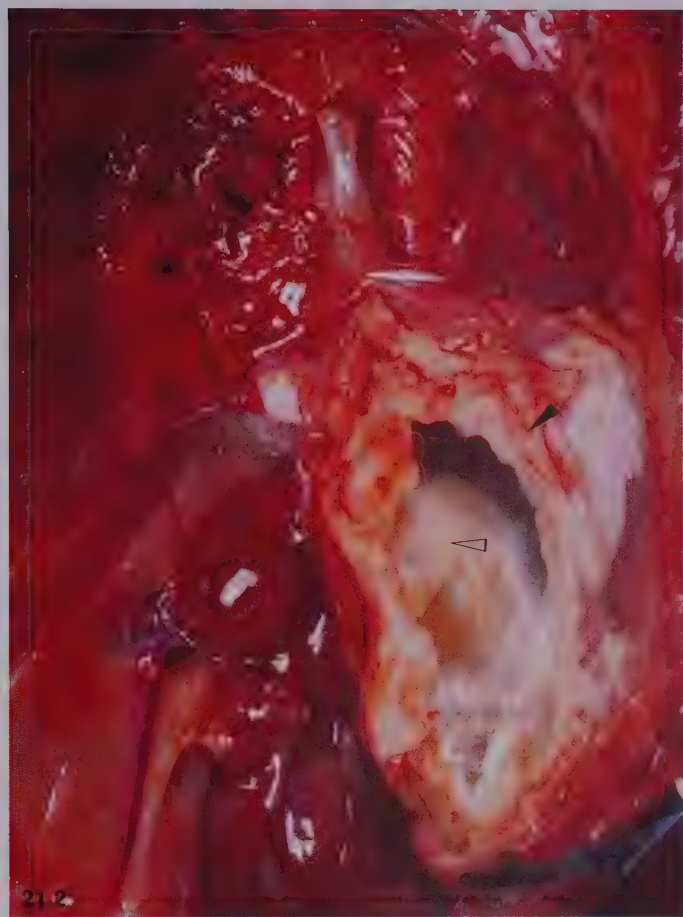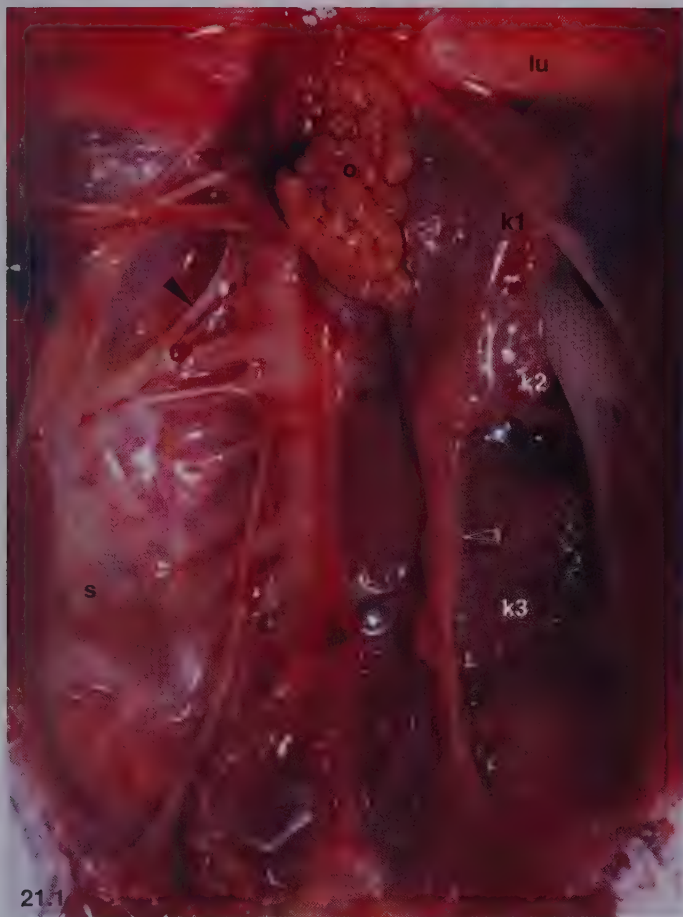### Color 21.3

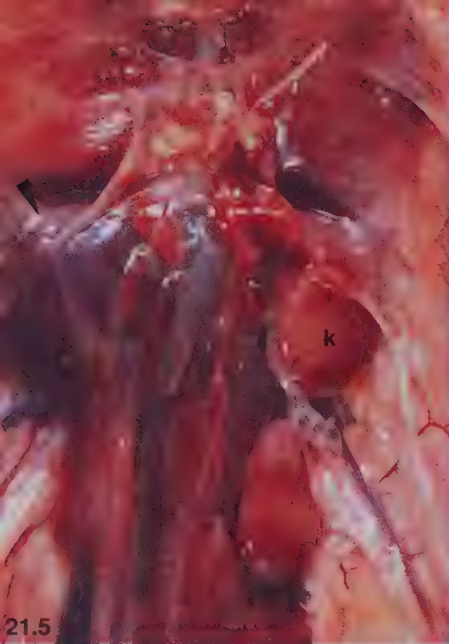
Birds with decreased renal function may develop uric acid deposits (gout) in visceral organs or in joints. The linear white streaks

within the renal parenchyma in this African Grey Parrot are characteristic for gout. This was a breeding male that died after a brief period of severe depression. Uric acid deposits were also present in the pericardium and liver (see Color 21.7). Structures that are clearly visible are cranial (k1), middle (k2) and caudal (k3) divisions of the kidney, right and left testicles (t), lung (lu), ureter (open arrow), caudal renal vein (arrow).

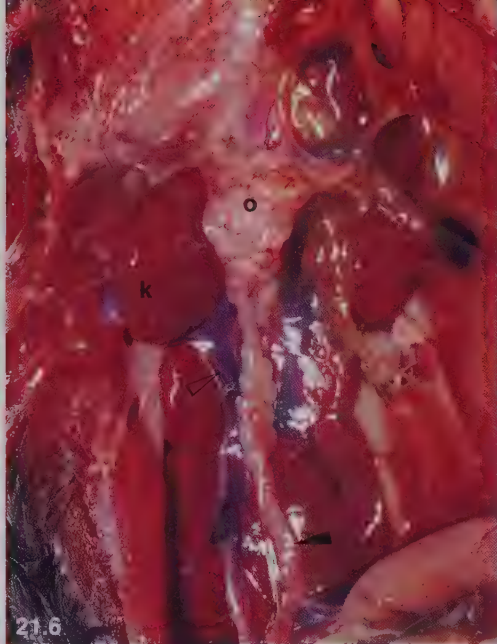
### Color 21.4

A mature, female African Grey Parrot was presented for evaluation of severe dyspnea. Radiographs indicated a large mass in the left thoracic cavity. Histologic evaluation of a fine-needle aspirate was suggestive of adenocarcinoma in the lung. A renal mass identified at gross necropsy was confirmed to be a renal adenocarcinoma. This bird had no clinical changes suggestive of rear limb ataxia or weakness, which frequently accompany renal masses. The ovary (o), oviduct (open arrow), ischium (i), external iliac vein (arrow) and ureter (u) are clearly visible.

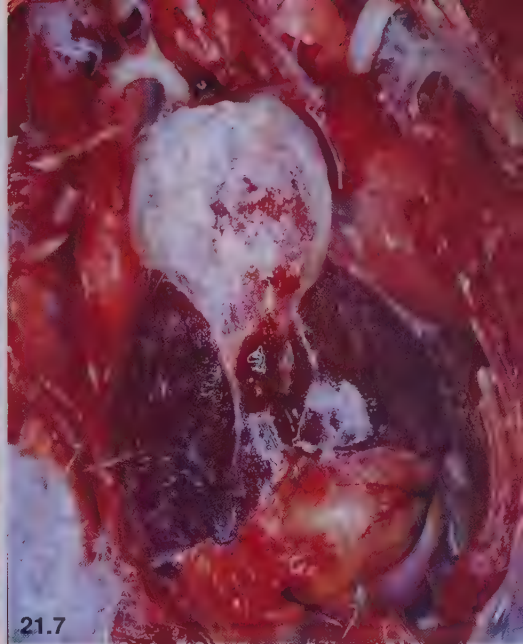




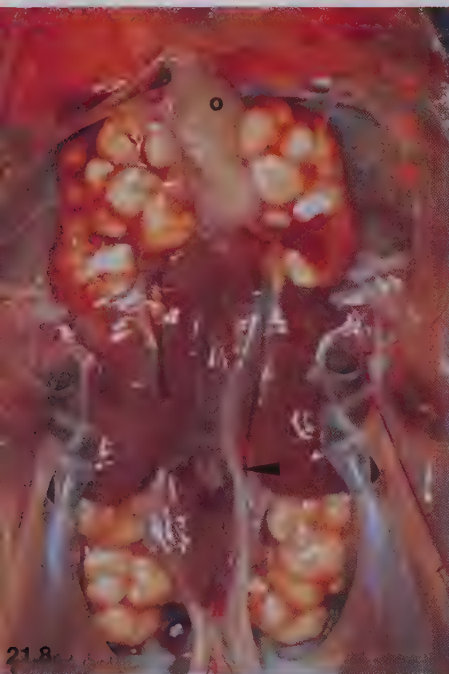
21.5



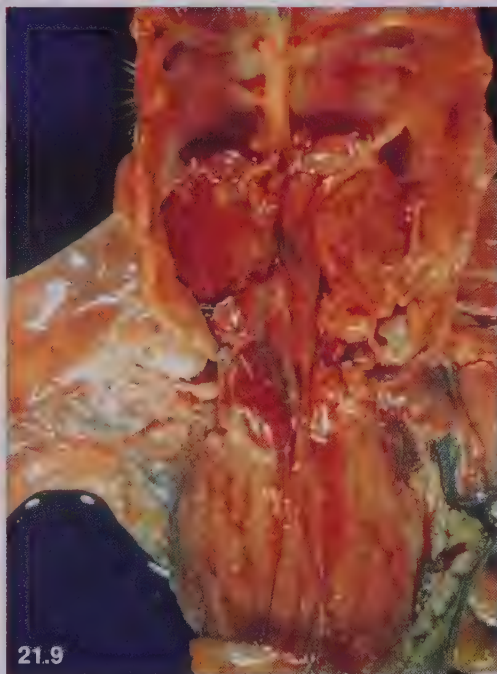21.6



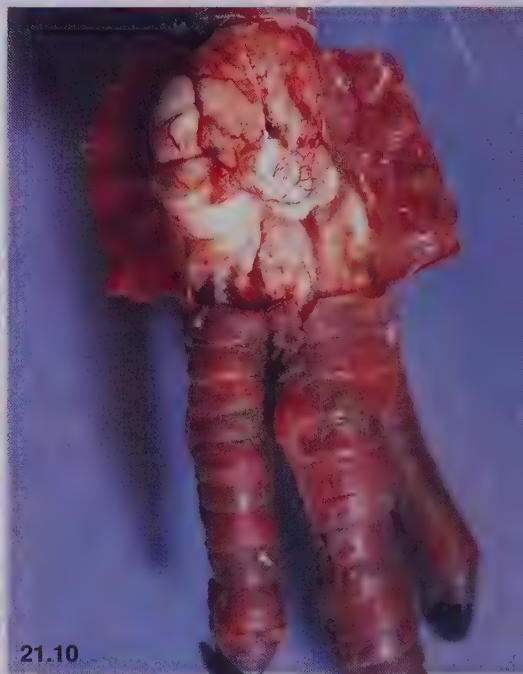21.7



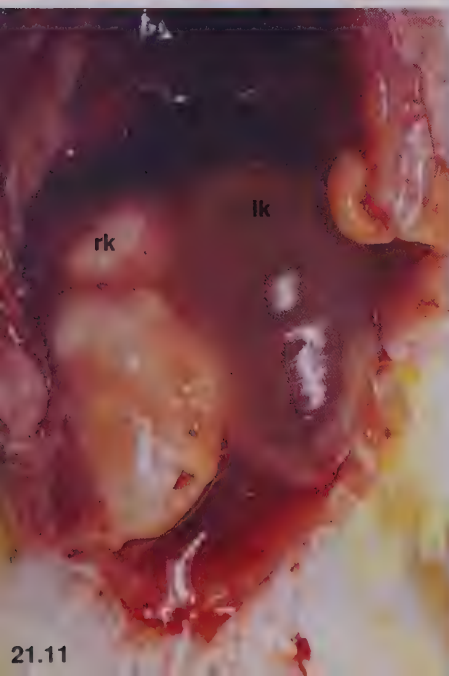21.8



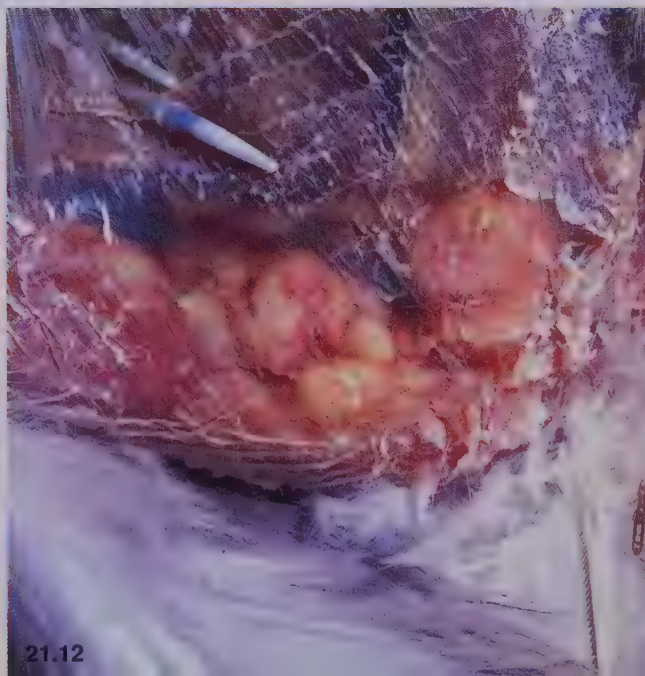
21.9




21.10



21.11




21.12



21.13



21.14



21.15

## Nephrology

### Color 21.5

Hemorrhage and swelling of the right cranial division of the kidney (arrow) in a juvenile Umbrella Cockatoo. The left kidney (k) is unusually pale.

### Color 21.6

Iron storage disease is a common cause of death in toucans and mynahs. Excessive accumulation of iron is usually present in the liver but can also occur in the kidney (k), as seen in this toucan. These affected kidneys are swollen and orange in color. Other structures that are clearly visible include the ovary (o), oviduct (arrow) and the caudal renal vein (open arrow) (courtesy of Robert E. Schmidt).

### Color 21.7

Deposits of uric acid in the pericardium and liver of an African Grey Parrot with renal failure (see Color 21.3).

### Color 21.8

Multiple urate masses in the kidney of an immature gallinaceous hen in end-stage renal failure. Note the immature ovary (o) and oviduct (arrow) coursing over the left ureter; urates are visible near the bottom of the photo (courtesy of R. Korbel).

### Color 21.9

Gout in a five-day-old rhea chick. Note that the tubules are white and filled with urates (courtesy of Brett Hopkins).

### Color 21.10

A mature pigeon was presented for lameness and an inability to fly. Prior to dissection, the firm, white, periarticular masses could be visualized through the skin (as in Color 21.12). Cytology of material collected from the masses revealed numerous uric

acid crystals. Articular gout is common in some birds secondary to renal dysfunction.

### Color 21.11

A three-year-old budgerigar was presented with a two-week history of progressive ataxia and inability to stand. The bird was first noted with dyspnea about three months prior to presentation and was severely dyspneic during the physical examination. A large mass could be palpated in the caudal abdomen. Necropsy revealed large cystic kidneys. Histologic changes in the right kidney (rk) were consistent with a renal adenocarcinoma, and the left kidney (lk) had undergone cystic changes.

### Color 21.12

Articular gout in the elbow of a pigeon with renal failure (see Color 21.10).

### Color 21.13

Polyuria can be caused by excitement, polydipsia, high-moisture diets (fruits) or renal disease. In this case, polyuria in a juvenile Blue and Gold Macaw occurred secondary to the excitement associated with handling.

### Color 21.14

Hematuria is occasionally seen in birds. The blood can originate from the kidney and ureters, which is rare, or from the gastrointestinal tract or cloaca, which is common. In this African Grey Parrot, hematuria was occurring secondary to a bacterial nephritis.

### Color 21.15

The presence of a large concentration of WBCs can cause urine to appear cloudy. In this cockatiel with severe metritis, both WBCs and RBCs were identified in the urine by cytology.

As an alternative to the cloacal cannula method, the fluid part of the excreta (urine) can be recovered immediately after excretion. The values for urine osmolality in excreted samples tend to be higher than those obtained from cloacal cannula samples. This might be explained by water resorption from the urine in the large intestine, which occurs under physiologic conditions<sup>41</sup> but is prevented when using the cloacal cannula method. The cloacal cannula method would be expected to provide a better impression of the renal concentrating capacity of a patient.

A test for urine concentrating capacity of the racing pigeon has been developed as a model for differentiation of polyuric disorders in birds.<sup>1</sup> It was concluded that urine osmolality of 450 mOsmol/kg is indicative of the normal concentrating capacity of the kidneys. In polyuric birds without a diminished concentrating capacity, one day of water deprivation should be sufficient to cause a demonstrable rise in urine osmolality.

Because the specific gravity of urine has a positive correlation with the osmolality, it should be possible to determine specific gravity of avian urine with a refractometer. Further work is needed to establish the correlation between refractometric readings and osmometric values before refractometry can be recommended. Some practitioners believe that they can make an empirical prognostic determination based on the specific gravity of the urine in a patient.

Polyuria is confirmed by demonstrating hypotonic urine (osmolality, mOsmol/l or specific gravity ).

#### Flow-osmol Factor

The flow-osmol factor can be defined as the product of the osmolality and urine volume per hour per kilogram. This value provides the limits within which the combination of both factors can be considered to be normal. There is a negative correlation between osmolality and urine flow. In this way, a low urine osmolality and a low urine flow, while both within their respective limits, should be considered abnormal when their combined value is below the normal values of the flow-osmol factor.

#### Nonprotein Nitrogen and pH

Uric acid concentrations, as mentioned in Table 21.1, are those that are found in supernatants of pigeon urine. The sediment has a much higher concentration of uric acid.

It is known that large quantities of cations are trapped in uric acid precipitates.<sup>32,33,44</sup> The degree of cation trapping varies from 3-75% for Na<sup>+</sup>, 8-84% for

K<sup>+</sup> and 17-32% for Ca<sup>+</sup> and Mg<sup>++</sup>. This should be considered when evaluating the values for these cations provided in Table 21.1. The Cl<sup>-</sup> concentration in the urine mainly depends on the concentration of sodium chloride in the food.

Dietary protein does influence the total ammonia excreted but it has little effect on the urine ammonia concentration.<sup>31</sup> Dehydration produces an increased ammonia concentration in urine, which is caused by the role of ammonia in regulating the acid-base balance.<sup>20</sup> Table 21.1 provides an indication of the pH range to be expected in the urine of granivorous birds. Determination of urine pH can be helpful in the diagnosis of acidosis in birds.<sup>a</sup>

#### Protein

In healthy pigeons, protein concentrations in urine collected with the cloacal cannula method can be as high as 2 g/l. The excretion of mucoproteins and glycoproteins in the distal portion of the nephrons and the ureters is responsible for this low level proteinuria.<sup>30</sup> Severe, persistent proteinuria is a sign of increased glomerular permeability (eg, glomerulonephritis). Proteinuria is usually minimal or absent in diseases that primarily involve the tubules or interstitial tissue. Extreme protein loss through the kidneys can lead to severe hypoproteinemia.

Most urine dip-sticks are too insensitive to distinguish between moderate and severe proteinuria and may not properly detect proteinuria in polyuric patients. A false-positive protein result is common in psittacine birds that have had an alkaline urine. The use of the Ponceau S method<sup>16</sup> for determination of urine protein concentration is recommended. With this method, protein is precipitated with trichloroacetic acid in the presence of the dye Ponceau S. The precipitate is then dissolved in sodium hydroxide, and the color intensity is measured spectrophotometrically at 545 nm.

#### Glucose

Glucose is normally absent from chicken urine,<sup>6,45</sup> though small quantities (1.6 mmol/l) of monosaccharides have been described in ureteral urine samples collected from birds.<sup>42</sup> The glucose concentrations mentioned in Table 21.1 are too low to be detected by rapid screening tests like Testape.<sup>b</sup>

Polyuria and polydipsia accompanied by glucosuria do not always indicate diabetes mellitus. Diabetes mellitus can be diagnosed only if elevated plasma glucose concentrations have been demonstrated. In



mammals, Fanconi's syndrome is characterized by renal glucosuria, hyperaminoaciduria and hyperphosphaturia, as well as renal loss of potassium, bicarbonate, water and other substances conserved by the proximal tubule. Fanconi's syndrome should be considered as the final result of any one of many possible primary insults to proximal tubular function. The syndrome may be inherited or acquired. A case of renal glucosuria and proteinuria in an African Grey Parrot with severe renal damage was considered to be similar to the Faconi's syndrome. Glucosuria is frequently seen in psittacine hens with egg-related peritonitis. The problem is transitory if the peritonitis can be successfully managed.

### Ketonuria

Ketonuria in mammals occurs when fatty acids are used instead of carbohydrates as the body's main energy source. It has been stated that ketonuria is a poor prognostic sign in birds, suggesting that catabolic processes lead to mobilization of fat and ketoacidosis.<sup>39</sup> This statement is probably incorrect for migratory birds. The primary energy source during migration is fat. In the premigratory state, the dry weight basis of some migratory birds is two-thirds fat. When this fat is used for energy during migration, it is broken down to fatty acids and glycerol. The body of migratory birds seems to have a metabolic system for preventing the accumulation of ketone bodies.<sup>12</sup> Diabetes mellitus has been mentioned as a cause of ketonuria in birds;<sup>11,38</sup> however, in the author's opinion, the clinical importance of ketonuria needs further clarification.

### Color

The color of urine varies but is generally white or off-white, pale yellow or light beige. Pigmented food items and medications may alter urinary color. B-complex vitamins can cause a yellow or brownish discoloration of the urine that can be misinterpreted as bilirubinuria (see Color 8). Berries in the diet can cause a blue-red discoloration of the urine (see Color 8). In liver diseases, biliverdinuria may result in a green-tinged urine (see Color 8).

### Microscopic Examination of Urinary Sediment

Microscopic examination of urine sediment is diagnostic only when evaluating urine that contains relatively little uric acid. Furthermore, contamination of the urine with nonrenal components, such as feces or blood originating from the cloaca, must be considered. If performed properly, microscopic evaluation of the urine and protein determination are the most important methods for early detection of renal dis-

ease. Various cast types and cellular elements can be encountered in urinary sediment (Color 21.15). Cellular casts can contain epithelial cells, erythrocytes, leukocytes, bacteria and fungi. Granular casts are composed of degraded cellular components. Casts that have no cellular elements but have a yellow-orange color are suggestive of hemoglobin casts.<sup>38</sup> Eosinophilic tubular casts were suspected to contain myoglobin in an ostrich with acute muscle necrosis and toxic nephropathy.<sup>37</sup> Clinical experience suggests that the transition from cellular or granular casts to hemoglobin casts is a favorable prognostic sign and indicates resolution of the inflammatory process.<sup>39</sup>

Microorganisms found in urine sediments are usually from fecal contamination; however, high bacterial counts in a relatively clean sample, together with urinary cast formation, is indicative of urinary tract infection. In male birds, sperm cells may be seen on routine microscopic examination of urinary sediment. Avian urine contains many amorphous urates, but other crystals may sometimes be noted.

### Urinary Enzymes

Tissue enzyme profile studies in racing pigeons<sup>22</sup> and budgerigars<sup>26</sup> have shown that renal tissues of these birds contain relatively high amounts of various enzymes. LDH, AST, CPK, AP, GLDH and ALT can be found in decreasing concentrations in renal tissue. From studies in dogs,<sup>18</sup> it is known that the enzymes that are released during renal damage do not enter the systemic circulation but are voided with the urine. For this reason, determination of urinary enzyme activities could be of value for the diagnosis of renal cell damage, and the severity of cell damage might be judged by considering the site of origin of the various enzymes. For example, GLDH is known to be a mitochondrial enzyme and is expected to be released only after renal cell necrosis in which the cell organelles are damaged. In renal cell degeneration only the release of cytoplasmic enzymes is expected to occur. Further experimental studies in birds are needed.

### Abnormal Urine Coloration

Hematuria is macroscopically visible when 0.1% of the urine contains blood (Color 21.14). Chemical test strips, like Hemastix,<sup>c</sup> will show a positive reaction when 0.002-0.001% of the urine contains blood. The combination of microscopic examination of the sediment and the use of a test strip is more sensitive for the detection of hematuria than when either test is used alone. In mammals, hematuria is always pathologic. Red blood cells can originate all along the

urinary tract. In birds, hematuria is also possible when blood cells from the gastrointestinal and genital tract or cloaca are mixed with the urine sample. In carnivorous birds, the meat diet frequently results in a positive reaction. Both hematuria and hemoglobinuria can be demonstrated using test strips for hemoglobin. Hemoglobinuria will be seen when there is an increased erythrolysis.

Myoglobinuria can also cause a red coloration of urine, which cannot be distinguished from hemoglobinuria on routine chemical urinalysis. Myoglobinuria can be demonstrated spectrophotometrically. Exertional rhabdomyolysis is well known in a number of mammalian species (eg, man, horse, whippet, kangaroo) and has also been reported in flamingos<sup>9,10</sup> and ostriches.<sup>37</sup> The resulting myoglobinuria can induce a severe toxic nephropathy.

Porphyrinuria is another cause of red coloration of the urine. In birds, the most common cause of porphyrinuria is lead poisoning. Amazon parrots with lead poisoning often produce a red or brown urine, which is assumed to be hemoglobinuria.<sup>38</sup> Lead is known to inhibit the activity of various enzymes involved in heme synthesis, which leads to porphyrinemia and porphyrinuria. Urine that contains high concentrations of porphyrins is wine-red in mammals. It is possible that the red or brown urine seen in Amazon parrots with lead poisoning is caused by porphyrins mixed with urates rather than hemoglobinuria. Porphyrins in urine will show a red fluorescence in ultraviolet light. When the test is negative, a blue fluorescence will be seen.

### Radiology of the Urinary Tract

Survey radiographs provide information about the size, location and radiopacity of the kidneys. The paired kidneys are located in the ventral renal fossae of the synsacrum. The kidneys are surrounded by the abdominal air sacs, which extend as diverticuli between the kidneys and the pelvis. This finding explains why, at least in Psittaciformes, a rim of air can be seen dorsal to the kidneys. The loss of this dorsal rim of air is seen during pathologic swelling of the kidneys.<sup>28</sup> On a lateral radiograph, the kidneys appear as bean-shaped structures posterior to the last rib. The cranial part is more easily visualized radiographically because the caudal part is superimposed by the intestinal tract and pelvis. On a ventrodorsal radiograph, the kidneys are superimposed by the liver and the intestinal tract. Abnormalities that can be detected on survey radiographs include swelling

and crystalline inclusions indicative of urate deposits (Figure 21.3).<sup>19</sup> Nephrocalcinosis or concrements in the kidney, ureters or cloaca can also be detected. Barium sulphate contrast of the gastrointestinal tract may be helpful in localizing intra-abdominal space-occupying lesions such as renal tumors. Occasionally, urate tophi of articular gout are visible on radiographs.<sup>8</sup>

### Endoscopy and Biopsy

Endoscopy allows direct visualization of the complete urinary system (kidneys, ureters and cloaca). The endoscopic approach of choice is through a puncture site dorsal to the pubic bone and caudal to the ischium on the left side of the bird (see Chapter 13).<sup>23</sup> Although it is feasible to take renal biopsies in healthy birds,<sup>23</sup> there is considerable risk of fatal hemorrhage from this procedure, and it should always be performed with the appropriate equipment and ample experience.

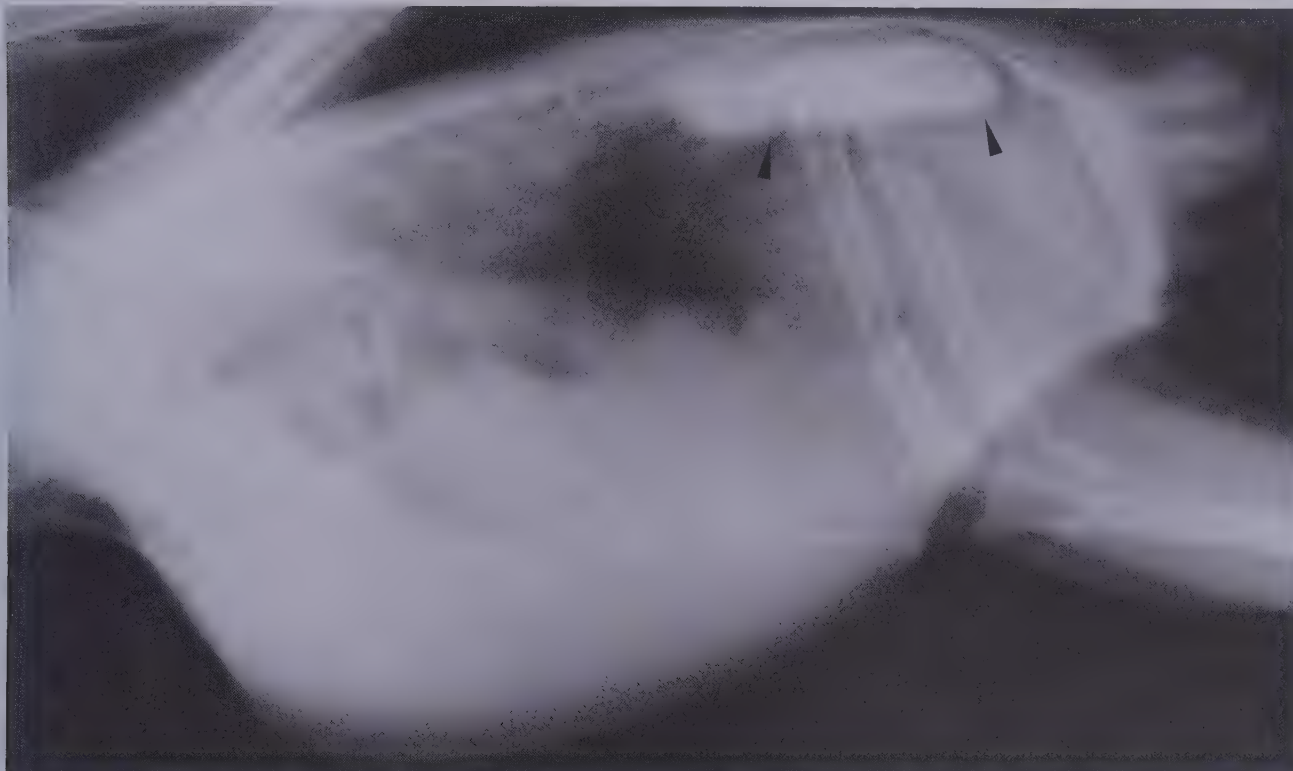
In visceral gout, urate deposits can be seen on visceral organs, especially the pericardium and cranial border of the liver capsule (Color 21.7). A ventral midline approach just caudal to the sternum is preferred to endoscopically evaluate these structures.<sup>23</sup>

## Diseases of the Kidney<sup>2,7,13,14,35,37,40</sup>

### Infectious Diseases

#### Bacterial Infections

Bacterial infections of the kidney often occur secondary to septicemia but may also result from bacteria that ascend from the cloaca. *Staphylococcus*, *Streptococcus*, *Listeria*, *Escherichia coli*, *Klebsiella*, *Salmonella*, *Yersinia*, *Proteus*, *Citrobacter*, *Edwardsiella*, *Enterobacter*, *Morganella*, *Providencia*, *Serratia*, *Pasteurella* and *Mycobacterium* spp. have all been associated with nephritis. Diagnostically, WBC evaluation, total protein and protein electrophoresis provide useful information on the systemic inflammatory reaction. Bacterial cultures of blood and urine may reveal the causative organism. Mycobacterial infections often cause monocytosis that can be demonstrated on a peripheral blood smear.



**FIG 21.3** An African Grey Parrot of unknown age was presented for a pre-purchase examination two years after being imported into the country. A CBC and avian profile were unremarkable. Radiographs indicated nephrocalcinosis (arrows). This is considered an abnormal finding that occurs frequently in African Grey Parrots. Nephrocalcinosis has been associated with hypervitaminosis D.<sup>37</sup>

### Viral Infections

Viral infections are usually multisystemic, although some viruses like avian polyomavirus and infectious bronchitis virus in chickens demonstrate a tropism for the kidney. Other viruses that have been associated with renal lesions include Newcastle disease virus, paramyxovirus of pigeons, reoviruses, viruses belonging to the leukosis/sarcoma group and herpesviruses (eg, Pacheco's disease virus and pigeon herpesvirus).

### Mycotic Infections

Renal infarction as a complication of mycelium invasion of blood vessels secondary to pulmonary mycotic disease is common. Abdominal air sac aspergillosis with renal involvement *per continuitatem* has also been reported (Color 21.12). In the latter case, ischiatic nerve involvement resulted in unilateral paralysis.

### Parasitic Infections

Granulomatous nephritis due to *Isospora*, *Cryptosporidium*, *Microsporidium* and *Encephalitozoon* spp. has been reported in a variety of avian species.

*Eimeria truncata* is a well known cause of renal coccidiosis in geese. Adult trematodes of *Tanaisia bragai* can be found in collecting ducts of chickens, turkeys and pigeons.

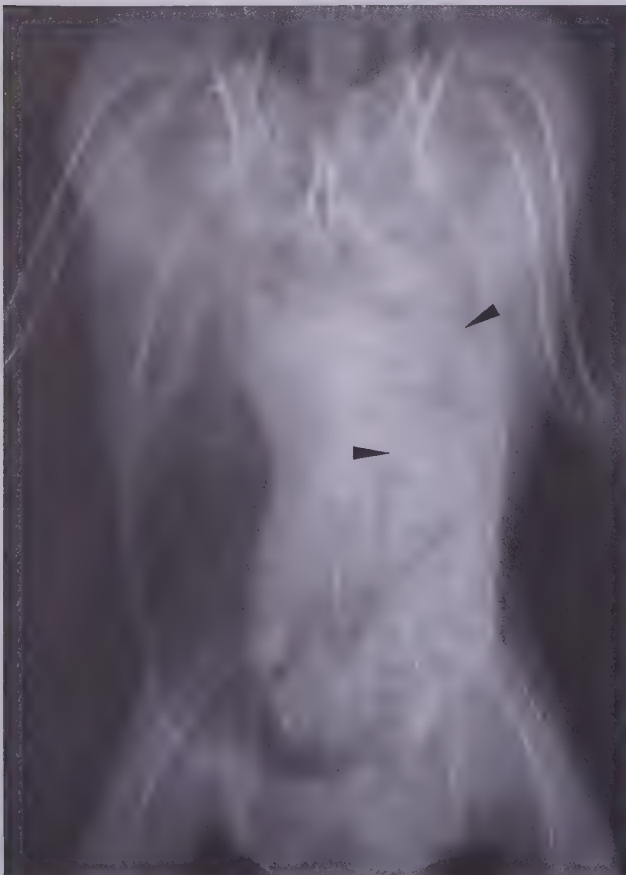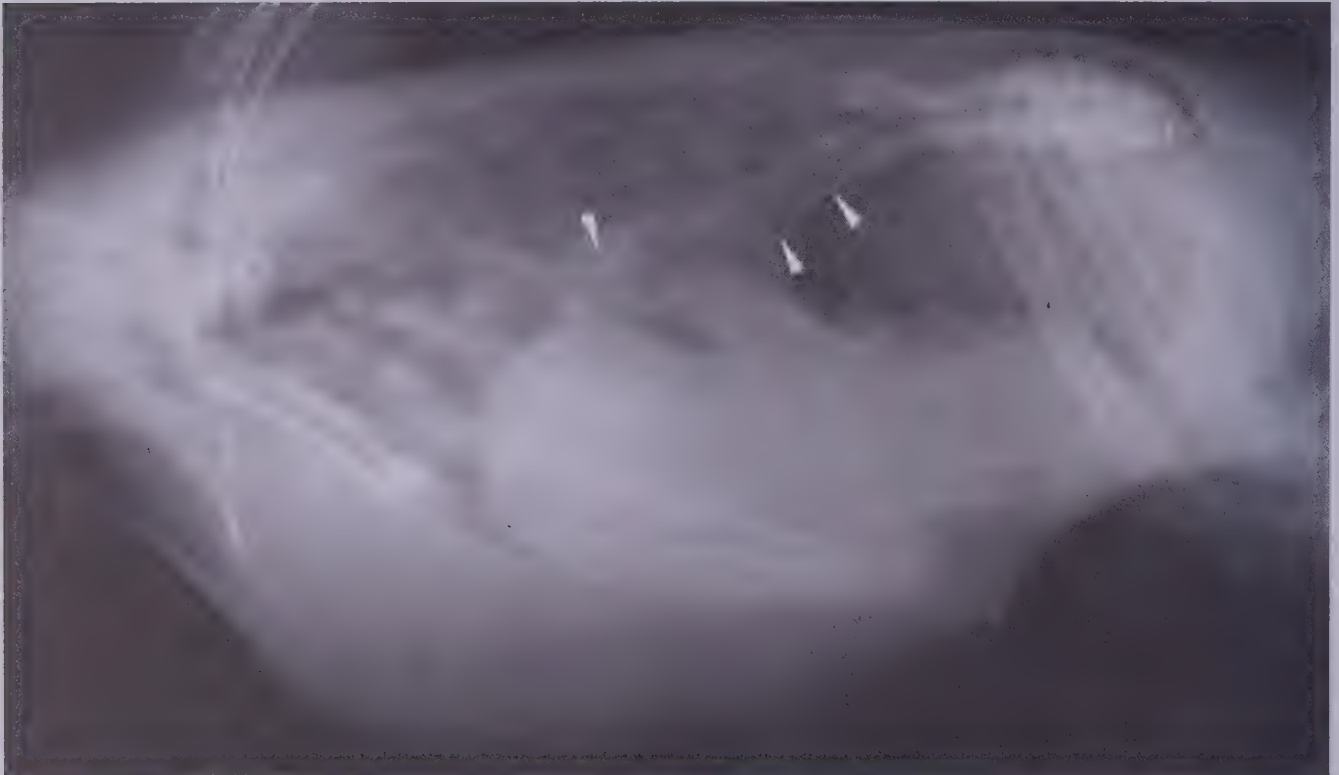
## Noninfectious Diseases

### Congenital Defects

Agensis and hypoplasia of part of the kidneys have been described in birds. Compensatory hypertrophy of the intact poles is common (Figure 21.4). Renal cysts have also been described and may be congenital in origin (Color 21.11). Diagnosis can be made with urography and laparoscopy.

### Metabolic Disorders

Hypervitaminosis D and elevated dietary calcium can both cause hypercalcemia and lead to deposition of calcium salts in the renal parenchyma (nephrocalcinosis). Calcinosis of other organs may also be noted. This condition can be detected radiographically, and the history may indicate oversupplementation of calcium or vitamin D in the diet. Nephrocalcinosis should not be confused with urolithiasis. The latter



**FIG 21.4** An African Grey Parrot with agenesis of the cranial and middle divisions of the right kidney. Visualization of the kidneys is enhanced by the presence of calcium phosphate crystals. Pneumonia and consolidation of the left air sacs (arrows) are also present (courtesy of Marjorie McMillan).

condition is the most prevalent renal disorder of laying hens. Suggested causes include excess dietary calcium, low phosphorous and infectious bronchitis virus. Unilateral or bilateral ureteral concretions of calcium urate can lead to postrenal renal failure. A diagnosis may be possible with cloacal palpation, radiography, excretory urography and endoscopy.

Hypovitaminosis A can cause metaplasia of the epithelium of the ureters and collecting ducts and decreased secretions of mucus in these structures. This may lead to precipitation of urates and ureteral impaction.

#### Amyloidosis

Renal amyloidosis often occurs in Anseriformes in conjunction with amyloidosis of other organs (eg, liver) secondary to chronic inflammation. There is a deposition of amyloid A, a degraded fragment of an acute phase reactant. In ducks, renal amyloidosis can lead to massive proteinuria and nephrotic syndrome due to severe glomerular damage. Clinically, this may be recognized as ascites, or edema of the feet and legs.

### Toxic Nephropathies

Many nephrotoxins cause renal tubular necrosis including aminoglycosides, heavy metals, and mycotoxins such as aflatoxin (*A. flavus* and *A. parasiticus*), ochratoxin (*A. ochraceus* and *Penicillium viridicatum*), oosporein (*Chaetomium trilaterale*) and citrinin (*P. citrinum*).

Salt (NaCl) poisoning has been documented in various species. Salt poisoning via drinking water can lead to right ventricular failure and ascites. Salt poisoning via food leads to acute renal failure with urate impaction of the ureters. Clinical signs include polydipsia and polyuria, or anuria if urate impaction of the ureters occurs. The principal toxic effect is an imbalance in sodium and potassium homeostasis. Right ventricular failure should be suspected with ascites and can be diagnosed by ECG (see Chapters 27 and 37).

### Neoplasia

Budgerigars have a high incidence of primary renal tumors, especially adenocarcinoma and nephroblastoma (younger birds) (Color 21.11). A viral origin has been suggested.<sup>35</sup> The kidney is a potential metastatic site for tumors of nonrenal origin, especially lymphoproliferative diseases (leukosis). Unilateral or bilateral paralysis caused by compression of the ischiatic nerve is a common clinical sign associated with renal malignancies in birds (Color 21.4). Abdominal enlargement is common when a renal mass causes caudoventral displacement of the ventriculus or ascites. A renal tumor may be radiographically detectable with or without the use of barium sulphate to differentiate the margins of the gastrointestinal tract.

### Ureteral Obstruction

Displacement or obstruction of ureteral orifices can occur due to intestinal or cloacal prolapse or cloacal obstruction caused by fecaliths, uroliths, foreign bodies, tumors or inflammatory processes. A bilateral obstruction will rapidly lead to visceral gout. Unilateral obstructions will lead to atrophy and compensatory hypertrophy of the contralateral kidney.

### Renal Hemorrhage

Renal hemorrhage can be caused iatrogenically during endoscopy if improper technique is used. Sporadic renal hemorrhage in male turkeys and *Psittaciformes* has been documented with extravasated blood remaining confined under the renal capsule or retroperitoneally (Color 21.5). It can also occur as a complication of renal pathology (eg, tumor). Peracute mortality is common.

## Therapeutic Considerations

### Prerenal Renal Failure

Treatment of prerenal renal failure caused by dehydration or shock is usually successful; however, the challenge is diagnosing and treating the initial cause of dehydration. Rapidly expanding the circulatory volume with intravenous fluids will usually restore normal renal function within hours (see Chapter 15).

### Postrenal Renal Failure

The treatment of postrenal renal failure caused by urolithiasis requires removal of the uroliths. This is a substantial surgical challenge. Successful extracorporeal shock wave lithotripsy for removal of uric acid concretions in the urinary tract has been reported in a Magellanic Penguin and may be attempted in other affected birds.<sup>27</sup>

### Acute Renal Failure

Once a diagnosis of acute (reversible) renal failure is made, immediate and aggressive therapy is indicated to prevent further damage. Suggested therapy for managing uric acid nephropathy in mammals provides some insight into the treatment of birds with a similar condition but different etiology. Acute oliguric renal failure associated with hyperuricemia and marked hyperuricaciduria in man occurs sporadically due to the precipitation of uric acid crystals in the distal parts of the renal tubules, the collecting ducts, the renal pelvis or the ureters.

This condition most frequently occurs secondary to the administration of cytotoxic drugs or irradiation, whereby the dissolution of a neoplastic mass liberates a heavy load of nucleic acid that must be catabolized and excreted by the kidneys. The uric acid excretion rises suddenly, uric acid precipitates in renal tubules and acute oliguric renal failure ensues. Contributing factors include excretion of an acid urine secondary to metabolic acidosis, dehydration and the use of uricosuric drugs (adrenocorticosteroids). Plasma uric acid concentrations may be as high as 4770  $\mu\text{mol/l}$  (80 mg/dl). Treatment includes maintaining a high alkaline urine flow by infusing mannitol 20% (1000 mg/kg) every 15-20 min and sodium bicarbonate supplemented with intravenous fu-

roseamide. The prognosis for recovery of renal function is good if diuresis can be achieved.<sup>46</sup>

Successful treatment of a Red-tailed Hawk with acute obstructive nephropathy that was induced by administration of allopurinol has been reported.<sup>24</sup> The bird showed signs of depression 18 hours after the third dose of allopurinol was given. Plasma chemistry revealed hyperuricemia (uric acid 5,721.6  $\mu\text{mol/l}$ ). A diagnosis of renal tubular nephrosis caused by oxypurinol, xanthine or uric acid deposits in the tubuli was made. Intravenous and subcutaneous saline, corticosteroids and furosemide (1 mg/kg) were administered twice daily in an attempt to restore renal function. Urine production was restored and, after 24 hours, plasma uric acid concentration had decreased to 3,814  $\mu\text{mol/l}$ . Fluid therapy, corticosteroids and diuretics were continued. Plasma uric acid had decreased to 1,639  $\mu\text{mol/l}$  72 hours later. The bird fully recovered after two weeks of intensive treatment with intravenous fluids and supportive alimentation. Although corticosteroids were used in this case, these drugs have been shown to be uricosuric in man and should be considered contraindicated in most cases of renal failure.

In anuric/oliguric renal failure, fluid intake in the patient should be restricted to fluid loss (renal loss, loss from the gastrointestinal tract and insensible loss of about 20 ml/kg/day). Assessment of fluid requirements can be based on this general outline but must be monitored by daily weight determination and observation for clinical signs that would indicate overhydration or dehydration. In patients that are anorectic and not receiving assisted feedings, some allowance should be made to account for tissue catabolism. Losses of 2.5% body weight per day are possible in totally anorectic parrots. Sodium, potassium and protein intake should be discontinued and calories should be given in the form of fat and carbohydrates. Alternatively, a low-protein diet containing all essential amino acids can be given. Furosemide should be used in an attempt to restore or increase urine flow and potassium excretion.

In the polyuric phase that follows the anuric phase, fluid and electrolyte balance should be carefully monitored to prevent dehydration, hyponatremia and hypokalemia. Intravenous and subcutaneous infusions with lactated Ringer's solution should be continued on a daily basis. Because bacteria are often incriminated as the cause of renal failure, use of non-nephrotoxic bactericidal antibiotics that are effective against the most commonly encountered bac-

teria are indicated. A combination of piperacillin and claforan has been suggested, although these drugs have a similar mode of action.<sup>39</sup> Vitamin A supplementation is always indicated in hyperuricemia, because hypovitaminosis A is a common cause of renal failure.

## Effects of Drugs

### Allopurinol

A recent study<sup>24</sup> has demonstrated that oral administration of allopurinol does not prevent the occurrence of physiologic postprandial hyperuricemia in Red-tailed Hawks. Contrary to expected findings, administration of allopurinol caused a severe hyperuricemia and induced gout in three out of six, clinically normal Red-tailed Hawks. This drug is known to reduce plasma uric acid concentration in man with hyperuricemia. The results of this study seem to indicate that allopurinol is contraindicated for the treatment of hyperuricemia in Red-tailed Hawks. Previous reports discussing effective therapy in parrots with allopurinol may have been coincidental<sup>36</sup> and related to physiologic variations in plasma UA concentrations in relation to food intake. Further work is needed in carnivorous and granivorous birds to establish fasting and postprandial reference intervals of plasma UA concentrations and the possible effects of allopurinol in birds. Recommendations for therapy based on single observations in individual birds must be cautiously applied to the management of any avian disease (including gout) until research can determine that a therapy is safe.

The extreme renal tubular nephrosis observed following allopurinol administration in Red-tailed Hawks<sup>24</sup> might be explained by the formation of oxypurinol, the relatively insoluble and nephrotoxic end-product of allopurinol. Alternatively, renal damage might have been caused by the deposition of xanthine crystals. Xanthine and hypoxanthine are precursors of uric acid, and concentrations of these substances increase when the xanthine oxidase inhibitor, allopurinol, is administered. High-pressure liquid chromatography is necessary to determine which metabolic product is being deposited in the tubules. Histologic techniques are not sufficient to determine the character of the deposits in the tubules, because they are generally washed away during preparation of the tissues for sectioning.

### Corticosteroids

Corticosteroids are known to be uricosuric in man<sup>46</sup> and may be contraindicated in avian hyperuricemic

conditions. Prednisolone has been used in budgerigars with renal tumors. The author states that although she does not know whether the prednisolone prolongs life, it may improve the quality of life by diminishing the pressure on the ischiatic nerve and stimulating appetite.<sup>2</sup>

### Products Mentioned in the Text

- a. Clinistix, Miles Diagnostics, Elkhart, IN
- b. Testape, Eli-Lily Benelux NV, Amsterdam
- c. Hemastix, Miles Diagnostics, Elkhart, IN

### References and Suggested Reading

1. **Alberts H, et al:** A water deprivation test for the differentiation of polyuric disorders in birds. *Avian Pathol* 17:385-389, 1988.
2. **Bauk L:** Renal disease in the budgerigar - A review of cases seen at the Western College of Veterinary Medicine. *Proc Assoc of Avian Vet, Toronto*, 1984, pp 1-8.
3. **Chonko AM, Grantham JJ:** Disorders of urate metabolism and excretion. In Brenner BM, Rector FC (eds): *The Kidney*. Philadelphia, WB Saunders Co, 1981, pp 1023-1055.
4. **Cooper JE, Lawton MPC:** The urogenital system. In Price CJ (ed): *Manual of Parrots, Budgerigars and Other Psittacine Birds*. Cheltenham, Gloucestershire (UK). British Veterinary Small Animal Association, pp 91-101, 1988.
5. **Coulson EJ, Hughes JS:** Collection and analysis of chicken urine. *Poult Sci* 10:53-57, 1930.
6. **Dantzier WH:** Renal response of chickens to infusion of hyperosmotic sodium chloride solution. *Am J Physiol* 210:640-646, 1966.
7. **Eber A, Pallask-Eber R:** Die durch Obduktion feststellbaren Geflügelkrankheiten [Poultry diseases diagnosed postmortally]. Hannover, Verlag von M & H Schaper, 1934, pp 262-268.
8. **Ekstrom DD, Degernes L:** Avian gout. *Proc Assoc Avian Vet, Seattle*, 1989, pp 130-138.
9. **Fowler ME:** Miscellaneous waterbirds. In Fowler ME (ed): *Zoo and Wild Animal Medicine*. Philadelphia, WB Saunders Co, 1978, p 215.
10. **Fowler ME:** Stress. In Fowler ME (ed): *Zoo and Wild Animal Medicine*. Philadelphia, WB Saunders Co, 1978, pp 33-34.
11. **Calvin C:** Laboratory diagnostic aids in pet bird practice. *Proc 47th Ann Meet Am Anim Hosp Assoc*, 1980, pp 41-52.
12. **George JC, Berger AJ:** The energy problem in bird migration. *Avian Myology*. New York, Academic Press, 1966, pp 199-223.
13. **Gratz E, Köhler H:** Spezielle Pathologie und Therapie der Geflügelkrankheiten [Pathology and Therapy of Poultry Diseases]. Stuttgart, Ferdinand Enke Verlag, 1968.
14. **Greenacre CB, Latimer KS, Ritchie BW:** Leg paresis in a black palm cockatoo (*Probosciger aterrimus*). *J Zoo & Wildl Med* 23(1):122-126, 1992.
15. **Halsema WB, et al:** Collection and analysis of urine in racing pigeons (*Columba livia domestica*). *Avian Pathol* 17:221-225, 1988.
16. **Hendriks HJ, Haage A, De Bruijne JJ:** Determination of the protein concentration in canine urine. *Zentralblatt für Veterinärmedizin A* 23: 683-687, 1976.
17. **Johnson OW, Muggaas JN:** Some histological features of the avian kidneys. *Am J Anatomy* 127:423-436, 1970.
18. **Keller P:** Enzymaktivitäten in Organen, Zellfraktionen und Körperflüssigkeiten des Hundes unter speziellen Berücksichtigung klinisch-diagnostischer Aspekte und der anaeroben Glykolyse [Enzyme activities in organs, cell fractions and body fluids with special attention for clinical diagnostic aspects and anaerobic glycolysis]. Basel, F. Hoffmann-La Roche & Co, AG, 1984.
19. **Krautwald-Junghans ME:** Radiographic examination of the urinary system of birds with organic iodinated contrast media. *Proc 1st Intl Conf Zoo & Avian Med, Hawaii*, 1987, pp 177-193.
20. **Long S:** Acid-base balance and urinary acidification in birds. *Comp Biochem Phys* 71(A):519-526, 1982.
21. **Lumeij JT:** Plasma urea, creatinine and uric acid concentrations in response to dehydration in racing pigeons (*Columba livia domestica*). *Avian Pathol* 16:377-382, 1987.
22. **Lumeij JT, et al:** Enzyme activities in tissues and elimination half-lives of homologous muscle and liver enzymes in the racing pigeon (*Columba livia domestica*). *Avian Pathol* 17:851-864, 1988.
23. **Lumeij JT, Hasselaar JC:** Endoscopic approaches for the racing pigeon (*Columba livia domestica*). In Lumeij JT: *A Contribution to Clinical Investigative Methods for Birds, with Special Reference to the Racing Pigeon, Columba livia domestica*. PhD Thesis, Utrecht University, 1987, pp 152-158.
24. **Lumeij JT, Redig PT:** Hyperuricaemia and visceral gout induced by allopurinol in red-tailed hawks (*Buteo jamaicensis*). *Proc Tagung Vogelkrankheiten der Deutsche Veterinärmedizinische Gesellschaft e.V., München*, 1992.
25. **Lumeij JT, Remple JD:** Plasma urea, creatinine and uric acid concentrations in relation to feeding in peregrine falcons (*Falco peregrinus*). *Avian Pathol* 20:79-83, 1991.
26. **Lumeij JT, Wolfswinkel J:** Tissue enzyme profiles of the budgerigar (*Melopsittacus undulatus*). In Lumeij JT: *A Contribution to Clinical Investigative Methods for Birds, with Special Reference to the Racing Pigeon, Columba livia domestica*. PhD Thesis, Utrecht University, 1987, pp 71-77.
27. **Machado C, et al:** Disintegration of kidney stones by extracorporeal shockwave lithotripsy in a penguin. *Proc 1st Intl Conf Zoo & Avian Med, Hawaii*, 1987, pp 343-349.
28. **McMillan MC:** Avian radiographic diagnosis. *Proc Assoc Avian Vet, Houston*, 1988, pp 301-308.
29. **McNabb FMA:** Kidneys. In Abs M (ed): *Physiology and Behaviour of the Pigeon*. London, Academic Press, 1983, pp 42-53.
30. **McNabb FMA, McNabb RA, Steeves HR:** Renal mucoid materials in pigeons fed high and low protein diets. *Aukjaf* 90:14-18, 1973.
31. **McNabb FMA, McNabb RA, Ward JM:** The effects of dietary protein content on water requirements and ammonia excretion in pigeons, *Columba livia*. *Comp Biochem Phys* 43(A):181-185, 1972.
32. **McNabb RA, McNabb FMA:** Urate excretion by the avian kidney. *Comp Biochem Phys* 51(A): 253-258, 1975.
33. **McNabb RA, McNabb FMA:** Avian urinary precipitates: Their physical analysis and their differential inclusion of cations (Ca, Mg) and anions (Cl). *Comp Biochem Phys* 56(A):621-625, 1977.
34. **McNeel SV:** Avian urography. *J Am Vet Med Assoc* 178:366-368, 1981.
35. **Neumann U, Kummerfeld N:** Neoplasms in budgerigars: Clinical, pathomorphological and serological findings with special consideration of kidney tumors. *Avian Pathol* 12:353-362, 1983.
36. **Petrak, ML:** Diseases of Cage and Aviary Birds. Philadelphia, Lea & Febiger, 1982, pp. 643-645.
37. **Phalen DN, Ambrus S, Graham DL:** The avian urinary system: Form, function, diseases. *Proc Assoc Avian Vet, Phoenix*, 1990, pp 44-57.
38. **Roskopf WJ, Woerpel RW, Lane RA:** The practical use and limitations of the urinalysis in diagnostic pet avian medicine: With emphasis on the differential diagnosis of polyuria, the importance of cast formation in the avian urinalysis and case reports. *Proc Assoc Avian Vet, Miami*, 1986, pp 61-73.
39. **Roskopf WJ, Woerpel RW:** Kidney disease in a military macaw, a yellow-naped Amazon parrot, and an umbrella cockatoo. *Proc Assoc Avian Vet, Houston*, 1988, pp 207-218.
40. **Siller WG:** Renal pathology of the fowl - a review. *Avian Pathol* 10:187-262, 1981.
41. **Skadhauge E:** Osmoregulation in birds. Berlin, Springer Verlag, 1981.
42. **Skadhauge E:** Formation and composition of urine. In Freeman BM (ed): *Physiology and Biochemistry of the Domestic Fowl* vol IV. London, Academic Press, 1983, pp 107-133.
43. **Skadhauge E, Maloney SK, Dawson TJ:** Osmotic adaptation of the Emu (*Dromaius novaezelandiae*). *J Comp Phys* B161:173-178, 1991.
44. **Skadhauge E, Schmidt-Nielsen B:** Renal function in domestic fowl. *Am J Phys* 212(4):793-798, 1967.
45. **Sperber I:** Excretion. In Marshal AJ (ed): *Biology and Physiology of Birds* vol 1. London, Academic Press, 1960, pp 469-492.
46. **Watts RWE:** Metabolic and genetic renal disorders and renal calculi. In Scott RB (ed): *Price's Textbook of the Practice of Medicine* 12th ed. Oxford University Press, 1978, pp 1056-1074.

CHAPTER

# 22

## PNEUMONOLOGY

Thomas N. Tully, Jr.  
Greg J. Harrison

**C**ompanion bird clients frequently seek veterinary care when abnormal respiratory signs are noted in their pets.<sup>1</sup> The rapid progression of many avian respiratory diseases makes early recognition by the client and rapid diagnosis and effective treatment by the practitioner critical. Conversely, chronic rhinitis and air sacculitis can fulminate for many years with subtle clinical changes. The difficulty in distinguishing between clinical signs originating from the upper versus the lower respiratory system makes the diagnosis and treatment of these problems challenging.<sup>52</sup> Successful respiratory therapy depends on rapid diagnosis.<sup>36</sup> The primary cause of a respiratory disease may be complicated by a more severe opportunistic infection that takes advantage of damaged respiratory epithelium. Diagnosis and treatment of avian respiratory disease depend on an understanding of the unique anatomy and physiology of the avian respiratory system and the effect these adaptations have on the clinical signs and the progression of disease. Respiratory health is best maintained by frequent exposure to fresh air and sunlight, a proper plane of nutrition and flighted exercise.

During the initial physical examination, the avian patient should be observed from a distance to evaluate subtle changes in posture, wing position, respiratory rate and respiratory pattern that may indicate an abnormality. A bird uses its intercostal musculature to expand and depress its chest, creating a "bellows" action that moves air into and out of the respiratory system. Any compromise in inspiratory or expiratory effort can affect the bird's posture.<sup>24,35,59,64</sup> Normal respiratory effort in the bird should not be noticeable, and the mouth should remain closed. An increase in abdominal effort or head movement may be recognized in association with increased respiration following exercise, but should return to normal within minutes of ceasing exertional activity. See Chapter 8 for normal avian respiratory rates.




Mild upper respiratory or lung-induced dyspnea is frequently accompanied by open-mouthed breathing with a dilated glottis. Lung and lower respiratory tract problems are usually associated with a rhythmic jerking of the tail (tail-bob). A bird in severe respiratory distress may also move its head forward in an effort to increase air intake. If the respiratory problem is associated with excessive fluid production, bubbling and gurgling sounds are common on both inspiration and expiration (Table 22.1).

Overt signs of respiratory disease are easy to identify and include oculonasal discharge, stained or matted feathers around the nares, sneezing, coughing, dyspnea or audible inspirations or expirations (Figure 22.1). Changes in pitch or vocalization of the patient may indicate problems in the glottis, trachea or syrinx.<sup>24</sup> Shallow, labored breathing in a bird with a weak, altered or absent voice is common with acute zinc toxicosis. Many psittacine birds may mimic the sneeze or cough of household members, which should not be misinterpreted as a sign of respiratory disease.

Dyspnea may be caused by chronic lung or air sac consolidation or by an acute reduction in the amount of air being delivered to the lungs. When dyspnea is induced by protracted respiratory disease, it is usually associated with other clinical signs including weight loss, depression, ocular or nasal discharge, sneezing or wheezing. Acute dyspnea in an apparently healthy bird usually results from exposure to aerosolized toxins, dislocation and movement of plaques in the trachea (from malnutrition or infectious agents) or aspiration of foreign bodies (particularly seed husks or cage litter material). Dyspnea may also be caused by rhinoliths, air sac granulomas, tracheal parasites (particularly in canaries, gallinaceous birds, finches), obesity (loss of air sac volume) or thyroid enlargement secondary to an iodine-deficient diet (Table 22.2).

## The Respiratory Tract

Clinically important components of the avian respiratory system include the external nares, operculum, nasal concha, infraorbital sinus, choanal slit, glottis, trachea, syrinx, bronchi, lungs, parabronchi and air sacs (see Anatomy Overlay).



**FIG 22.1** A six-month-old Blue-crowned Conure was presented for suspected sinusitis that was not responsive to antibiotics. The bird had moist, matted feathers and dried debris over most of the head region. The area was thoroughly cleaned and severely matted feathers were removed. The discharge was found to be associated with conjunctivitis and not sinusitis. It was determined that the bird had no nasolacrimal ducts. It also had secondary bacterial and fungal conjunctivitis. The bird was successfully managed by frequently flushing the eyes with sterile saline.

### Nares

The first areas to examine for respiratory disease are the nares and surrounding tissues. Unilateral or bilateral diseases of the upper respiratory tract are indicated by matted or mildly stained feathers around the nostrils, occluded nares, nasal discharge or a growth or change in size of the nasal opening. Bacterial, fungal, chlamydial and viral infections, neoplasia and trauma are common etiologic agents of upper respiratory disease.<sup>24,35,59</sup> Chronic inflammation may lead to disfiguring lesions of the nares, beak and cere (Figure 22.2).<sup>36</sup> Severe *Knemidokoptes* spp. infection may cause proliferation of the cere that blocks the external nares and causes respiratory difficulties (see Color 24).<sup>50</sup>

Some Arabian falconers dilate the nares in their birds to facilitate air intake and improve hunting performance. With the efficiency of the air exchange system in birds, it is unlikely that this procedure is of any value.

The operculum can be seen just inside the nostril; this cornified flap of tissue (frequently referred to



**FIG 22.2** A mature, male Major Mitchell's Cockatoo was presented for a proliferative mass involving the right nostril and beak. No other abnormalities were noted by physical examination, radiography or clinicopathologic evaluation. The mass was removed and was determined to be a well encapsulated fungal granuloma. The presence of a beak defect from the cere to the tip indicates the chronicity of the problem.

improperly as bone) should not be mistaken for a foreign body. The operculum should be smooth and dry. Cellular debris can accumulate between the operculum and the wall of the nasal cavity, leading to substantial necrosis of the rostral nasal passages and its associated bone (see Chapter 41).

A septum divides the nasal cavity into two halves, each containing a rostral, middle and caudal nasal concha in most avian species. Air that enters the external nares is warmed and moistened by the highly vascular rostral and middle nasal concha (turbinates), which lie rostral, caudal and ventral to the operculum. The caudal nasal concha does not connect

directly to the nasal cavity; instead, it opens dorsally into the infraorbital sinus, which is divided into five diverticuli (rostral, periorbital, infraorbital, mandibular and postorbital) that extend into the upper beak, mandible and portions of the pneumatic skull (see Anatomy Overlay). The infraorbital sinus opens caudally into the cranial and cervical portions of the cervicocephalic air sac and dorsally into the middle nasal concha.<sup>44</sup> The fact that the openings from the caudal nasal concha to the infraorbital sinus and from the infraorbital sinus to the middle conchae are both in a dorsal position may contribute to the common accumulation of pus and cellular debris in the infraorbital sinus in birds with upper respiratory tract disease (Colors 22.2, 22.3, 22.5).<sup>44</sup>

In mammals, the sinuses are contained within the bones of the skull. By contrast, avian sinuses are restricted laterally by the skin and subcutaneous tissues of the face. The sinuses have simple mucous glands and are lined by stratified squamous and ciliated columnar epithelium. Hypovitaminosis A commonly causes squamous metaplasia and hyperkeratosis of the sinuses and nasal passages, leading to granuloma formation.

### ■ Sinuses

The infraorbital sinus is the only paranasal sinus in birds and is located lateral to the nasal cavity and surrounding the eyes ventrally.<sup>72</sup> In some birds (insectivorous Passeriformes, Anseriformes and Psittaciformes), the right and left infraorbital sinuses communicate, while in other species (non-insectivorous Passeriformes), the right and left infraorbital sinuses are independent.

The interconnection of the nasal cavity, infraorbital sinuses and the porous calvaria creates a situation in which inflammatory reactions in the sinus or nasal passages can involve most of the anatomic structures of the head. The numerous pockets and extensions of the nasal system make sinus infections difficult to treat. With severe chronic sinusitis, the accumulation of caseous necrotic debris can cause destruction of the nares, nasal cavity, operculum and nasal conchae. This degree of destruction is particularly common in Amazon parrots and African Grey Parrots with aspergillosis sinusitis. Inflammation or accumulation of debris in the infraorbital sinus can lead to periorbital swellings (Color 22.2).

The tube-like nasal cavity turns ventrally at the sinuses, and the air exits the two choanae (internal

TABLE 22.1 Clinical Considerations of Respiratory Disease

UPPER RESPIRATORY DISEASE	LOWER RESPIRATORY DISEASE
<p><b>Clinical Signs</b></p> <ul style="list-style-type: none"> <li>▪ Open-mouthed breathing</li> <li>▪ Change in voice</li> <li>▪ Sneezing</li> <li>▪ Sinus swelling</li> <li>▪ Rhinorrhea</li> <li>▪ Nasal granulomas</li> <li>▪ Exercise intolerance</li> <li>▪ Dyspnea</li> <li>▪ Head-shaking</li> <li>▪ Mucopurulent nasal discharge</li> <li>▪ Inflamed swollen cere</li> <li>▪ Stretching the neck</li> <li>▪ Yawning</li> <li>▪ Epiphora</li> <li>▪ Periophthalmic swellings</li> <li>▪ Plugged nares</li> </ul> <p><b>Diagnostic Protocol</b></p> <ul style="list-style-type: none"> <li>▪ Thorough review of nutritional status</li> <li>▪ Thorough history (exposure to smoke, PTFE)</li> <li>▪ Gram's stain of feces; direct fecal smear for parasites; special pathology stains</li> <li>▪ Sinus flush</li> <li>▪ Cytology of affected area (sinus aspirate, flush, scraping for parasites); Gram's stain</li> <li>▪ Radiographs (whole body, sinus views)</li> <li>▪ Rhinoscopy (foreign body examination)</li> <li>▪ Culture and sensitivity</li> <li>▪ Special bacterial and viral diagnostic testing (also for chlamydia, mollicutes)</li> <li>▪ Biopsy of lesion</li> <li>▪ CBC, biochemistry panels</li> </ul> <p><b>Normal Flora</b></p> <ul style="list-style-type: none"> <li>▪ Gram-positive bacteria (eg, <i>Lactobacillus</i> spp., <i>Streptococcus</i> spp. and <i>Micrococcus</i> spp.)</li> <li>▪ Small numbers of gram-negative organisms (eg, <i>E. coli</i>, <i>Bordetella</i>)</li> <li>▪ Occasional non-budding yeast</li> </ul> <p><b>Abnormal Flora</b></p> <ul style="list-style-type: none"> <li>▪ Large numbers of gram-negative bacteria (over 5%)</li> <li>▪ 10 budding yeast per oil immersion field examined</li> </ul>	<p><b>Clinical Signs</b></p> <ul style="list-style-type: none"> <li>▪ Tail-bobbing</li> <li>▪ Loss of voice</li> <li>▪ Change in vocalization</li> <li>▪ Labored respiration</li> <li>▪ Exercise intolerance</li> <li>▪ Coughing</li> <li>▪ Sounds on auscultation</li> </ul> <p><b>Diagnostic Protocol</b></p> <ul style="list-style-type: none"> <li>▪ Radiographs of lungs, air sacs</li> <li>▪ Transtracheal lavage (cytology of sample)</li> <li>▪ Laparoscopy; tracheoscopy</li> <li>▪ Biopsy of lungs, air sacs</li> <li>▪ Suction and cytology</li> <li>▪ Culture of trachea, lungs and air sacs</li> <li>▪ Surgical intervention (air sac granuloma; tumor; tracheal foreign body)</li> <li>▪ Compression reduction of air sacs</li> </ul> <p><b>Fluid Obtained by Tracheal and Air Sac Lavage</b></p> <ul style="list-style-type: none"> <li>▪ Normal <ul style="list-style-type: none"> <li>Low cellularity and very few pulmonary macrophages or inflammatory cells</li> </ul> </li> <li>▪ Abnormal <ul style="list-style-type: none"> <li>Large numbers of heterophils, pulmonary macrophages and other inflammatory cells, bacteria or yeast</li> </ul> </li> </ul>

nares) at the level of the palate. The middle choanae are just cranial and dorsal to the choanal slit, which courses longitudinally in the dorsal oral cavity or roof of the mouth. The choanae are separated into right and left openings by the nasal septum or vomer bone. The paired entrances of the nasal cavity can be viewed with a rigid or flexible endoscope by directing it through the rostral end of the choanal slit (see Color 13). The choanal slit represents the incomplete fusion of the two bony plates of the hard palate (see Color 8). Birds do not have a soft palate. Instead, air moves from the nasal cavity through the choana via the choanal slit (oropharynx) and then into the rima glottis of the trachea. The configuration of the choanal slit varies with the species, but in all cases the

slit should be slightly moist. On the ventral surface of the palate and along the choana are numerous caudally directed choanal papillae, which are most pronounced in gallinaceous species but are also found in most birds (see Color 13).

Swollen, inflamed choanal tissues, with a sloughing of the protruding papillae, are common with upper respiratory tract infections (particularly chlamydiosis),<sup>30</sup> and secondarily infected with candidiasis in immunosuppressed states following prolonged illness, malnutrition or improper antibiotic administration. The presence or absence of papillae is not a diagnostic indicator of current respiratory disease, as they seldom regrow after sloughing. Laryngeal le-

TABLE 22.2 Clinical Presentations of Avian Respiratory Disease with Associated Differential Diagnoses

Clinical Presentation	Differential Diagnosis
Sunken eye	Chronic bacterial sinusitis
Enlarged cere	Chronic rhinitis; foreign body; trauma; allergy; airborne irritants (eg, cigarette smoke); malnutrition (chronic); avian poxvirus; knemidokoptes mites; normal female budgerigar
Enlarged cere with or without granuloma formation	Bacterial, mycotic, mycoplasma, chlamydial; nutritional rhinitis
Rhinorrhea or sneezing	Bacterial infection; mycotic infection; foreign body; toxic insult (smoke); allergy; virus; malnutrition; chlamydia
Serous sinusitis	Chlamydia or mycoplasma infection; nutritional rhinitis; foreign body; papillomatosis; occluded choana (atresia); uncomplicated viral infections
Mucopurulent sinusitis	Bacterial infection with predominantly gram-negative organisms; mycotic infection (often secondary to serous sinusitis)
Irritated swollen cere with sloughed papillae	Chronic mycotic, bacterial or viral sinusitis; chronic exposure to airborne irritants; chlamydiosis; malnutrition; hypovitaminosis A
Coughing (chronic)	Bacterial, viral, fungal, chlamydial, parasitic, yeast, mycobacterial; ascites; abscess or granuloma; malnutrition; air sac mites; mimicry of humans; airborne toxins (eg, cigarette smoke)
Coughing (acute)	Foreign body inhalation; trauma; upper respiratory infection; abscess or neoplasia in lungs or body cavity; air sac mites; infectious tracheitis; avian viral serositis; mimicry of humans; bleeding into body cavity; sarcocystosis; syringeal granuloma; airborne toxins - PTFE gas
Dyspnea (acute)	Aspergillosis syringeal granuloma; infectious disease; foreign body inhalation; internal bleeding; allergy; toxin inhalation; plugged nares; avian viral serositis; sarcocystosis; anemia
Dyspnea (chronic)	Infectious disease; liver disease; kidney disease; ascites; heart disease; neoplasia; air sacculitis; malnutrition; sarcocystosis (lung edema); proliferative tracheitis; Pacheco's disease virus; pericardial effusion; egg-related peritonitis (binding); hemochromatosis; anemia; obesity; thyroid enlargement, tumors, goiter
Subcutaneous swelling	Overinflation of cervicocephalic air sac; trauma (bite wound); normal (pelicans)
Neonatal sneezing, coughing, dyspnea	Inhalation pneumonia; respiratory foreign body; infections (eg, chlamydia); avian viral serositis; mycotic infection

sions may occur from viral infections (poxvirus, herpesvirus), hyperkeratosis secondary to hypovitaminosis A, candidiasis, trichomoniasis, papillomatosis and neoplasia (Figure 22.3).<sup>24,25,35,36,57,61</sup> Seeds may also become lodged in the choanal slit and cause respiratory signs or constant movement of the tongue in an effort to dislodge the seed.

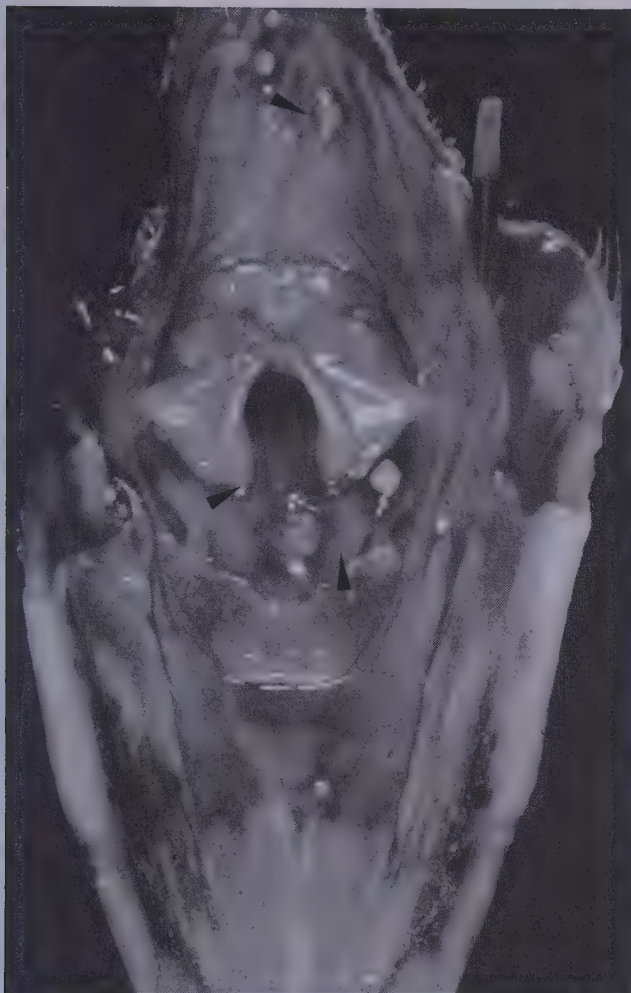
### Trachea

The opening of the larynx, or rima glottis, is not covered by an epiglottis as it is in mammals. The laryngeal cartilages are reduced or absent. The largest laryngeal cartilages are the coracoid cartilages.<sup>9</sup> The larynx does not function for sound production in birds. When a bird breathes, the mouth is closed and the mobile glottis seals with the choanal slit, allowing air to pass into the trachea from the nares (see Anatomy Overlay). There are no vocal cords in the larynx.

The trachea is loosely found on the right side of the neck, ventral to the esophagus. The trachea courses under the crop at the thoracic inlet and terminates into the syrinx. It is the syrinx that serves as the vocal organ (see Anatomy Overlay). The trachea of

birds differs from mammals in that it is longer and has a larger diameter — two anatomic considerations for anesthesia. The trachea consists of complete cartilaginous rings in most avian species. These cartilaginous rings may calcify as the bird grows older.<sup>7</sup> The length, configuration and anatomic position of the trachea vary widely among genera. Some birds, like the Whooping Crane, have a trachea that extends to the cloaca, where it doubles back and returns to the thoracic inlet before connecting to the syrinx. Other species (Helmeted Curassow) have a similar configuration, but the trachea courses subcutaneously outside the confines of the sternum.

At the distal end of the trachea is the syrinx, which can be classified as tracheal, tracheobronchial or bronchial depending on the location of fusion of the cartilages.<sup>51</sup> Most psittacine birds have a tracheobronchial-type syrinx in which the last of the tracheal rings fuse into a syringeal box, which joins to the first of the bronchial rings. The shape of the syrinx and the sound it emits are controlled by the bronchial muscles that attach to the syrinx, the first bronchial rings and the bronchotracheal muscles, which extend from the bronchus to the trachea. Sounds are believed to be produced in the syrinx by



**FIG 22.3** Proliferative lesions of the pharyngeal or oral mucosa (arrows) may be caused by some viruses, hypovitaminosis A, *Trichomonas* spp. or *Candida* spp. (this case). Cytology is a useful technique to establish a clinical diagnosis (courtesy of Louise Bauck).

the turbulent flow of expelled air that is forced through syringeal membranes, which form slots.<sup>44</sup> The pitch of the sound is also controlled by the length of the trachea and whether the air sacs are inflated or flattened. A long trachea and inflated air sacs produce a loud, booming, low-frequency sound.

Pathology involving the syrinx is best diagnosed and treated when signs of disease are first recognized. If a bird stops talking or has a voice change it should be evaluated immediately for lesions developing in the perisyringeal area (frequently aspergillosis). Progressive changes recognized clinically as dyspnea, coughing or tracheal discharge are more difficult to successfully resolve (Figure 22.4). The trachea and primary bronchi contain goblet cells and are lined

with pseudostratified, ciliated, columnar epithelium. The syringeal mucosa contains bistratified squamous or columnar epithelium that is subject to squamous metaplasia and granuloma formation.<sup>4</sup>

## Lungs

The lungs of birds are much different than those of mammals, both morphologically and physiologically (Table 22.3). The paired lungs lie dorsally in the thoracic cavity, extending from the first through the seventh ribs in Psittaciformes; however, the boundaries of the lungs vary, and they may extend to the ilia in some species. The lungs are attached dorsally against the thoracic ribs and vertebrae, where they fill the intercostal space throughout their margins (see Color 14). When removed, the coastal surface of the lung will have an impression of the vertebral ribs (coastal sulci). The sixth rib creates the most caudal sulci in Psittaciformes (see Anatomy Overlay).

There are frequent and inaccurate suggestions that the avian lung is fixed and not expandable. While changes in the size or position of the avian lung are limited, it is a dynamic organ that does undergo expansion and contraction during the respiratory cycle.<sup>44</sup>

The lungs are connected to the distal trachea (syrinx) by the primary bronchi, which progressively divide into secondary bronchi and tertiary bronchi (parabronchi) (Figure 22.5). Parabronchi connect to the secondary bronchi and other parabronchi, which have shallow depressions (atria) evenly displayed along their walls. Each depression has three to six funnel-shaped ducts (infundibula), which lead to the air capillaries. The air capillaries form an anastomosing three-dimensional network.<sup>44</sup> The air capillaries are intermittently interwoven with the blood

**TABLE 22.3** Differences in Avian and Mammalian Respiratory Systems

Bird	Mammal
No diaphragm	Active diaphragm
Air sacs	No air sacs
Communicating air capillaries	Alveoli (blind sacs)
Syrinx	No syrinx
Complete tracheal rings	Open tracheal rings
No thyroid cartilage	Thyroid cartilage
No laryngeal vocal cords	Laryngeal vocal cords
No epiglottis	Epiglottis
Limited lung expansion	Highly expansible lungs

## Pneumonology

### Color 22.1

Chronic sinusitis may cause the globe of the eye to retract into its socket (sunken sinus syndrome). The problem is usually unilateral but on occasion may occur bilaterally. The pathogenesis of this lesion is unclear. Some cases will resolve when the sinusitis is resolved (courtesy of L. Karpinski).

### Color 22.2

An advanced case of mycoplasmosis in a Galliforme associated with symblepharon, infraorbital sinusitis and rhinitis. The avian sinuses are not restricted laterally by bone (as they are in mammals), and sinusitis is frequently associated with facial swelling (courtesy of R. Korbelt).

### Color 22.3

Inflammatory reactions in the sinuses can involve most of the structures of the head. In this Blue-fronted Amazon Parrot, chronic sinusitis is associated with an infraorbital sinus fistula, nostril damage, a beak deformity, conjunctivitis and keratitis. Because of the complex extensions of the nasal system, treatment for chronic sinusitis usually requires surgical drainage (courtesy of R. Korbelt).

### Color 22.4

Cockatiels frequently develop an upper respiratory disease characterized by sinusitis, conjunctivitis or both. *Mycoplasma* spp. and *Chlamydia* sp. are frequently implicated in these cases. Conjunctival scrapings collected for cytology and culture are most useful in identifying an etiologic agent. If an infectious agent cannot be determined, these birds frequently respond to long-term treatment with tylosin eye wash and lincomycin/spectinomycin in the drinking water or an ophthalmic solution containing chlorotetracycline (conjunctivitis only) or doxycycline (conjunctivitis and sinusitis).

### Color 22.5

An adult cockatiel was presented with a two-week history of sneezing, lethargy and a nasal discharge. The bird had been receiving over-the-counter medications in the water for ten days. A severe conjunctivitis and mucopurulent rhinitis were noted on physical examination. Additionally, several pericocular masses were evident. Cytology of samples collected from the masses indicated an accumulation of mixed gram-negative bacteria. The bird did not respond to

therapy. At necropsy, granulomatous infraorbital sinusitis was evident.

### Color 22.6

A gallinaceous bird was presented with a three-day history of progressive lethargy, anorexia and upper respiratory disease. The bird was part of a backyard flock in which intermittent deaths had been occurring in birds with similar clinical signs. This bird did not respond to therapy. Newcastle disease virus was isolated from the bird. A vaccination program was initiated in the flock.

### Color 22.7

A herpesvirus that is serologically distinct from Pacheco's disease virus has been isolated from Amazon parrots with proliferative tracheitis. **a)** The diphtheritic membranes in the trachea cause severe dyspnea and death. In this case, the pharyngeal mucosa is covered with necrotic tissue. **b)** Bronchopneumonia and the presence of necrotic casts in the trachea and bronchi are characteristic (courtesy of Helga Gerlach).

### Color 22.8

A cockatoo neonate died seconds after being hand-fed. The chick had placed its glottis on the ending of the feeding tube, and food was deposited in the trachea and lungs.

### Color 22.9


A five-month-old ostrich had been losing weight for several days. In an attempt to provide supportive care, the client passed a feeding tube and delivered a liquid-based product. The bird began stretching its neck and became frantic. It died several minutes later. The client had passed the tube into the trachea instead of the esophagus, resulting in asphyxiation (courtesy of Brett Hopkins).

### Color 22.10


Mycobacterial pneumonia in a Border Canary (courtesy of Louise Bauck).

### Color 22.11


A breeding Umbrella Cockatoo was found dead in its nest box. The bird was in excellent overall condition and had blood-tinged fluid in the mouth. The lungs were edematous and hemorrhagic. Sarcocystosis was diagnosed histologically. Inhalation of noxious gases and fumes from non-stick cooking surfaces can cause similar gross lesions in the lung.



22.1



22.2



22.3



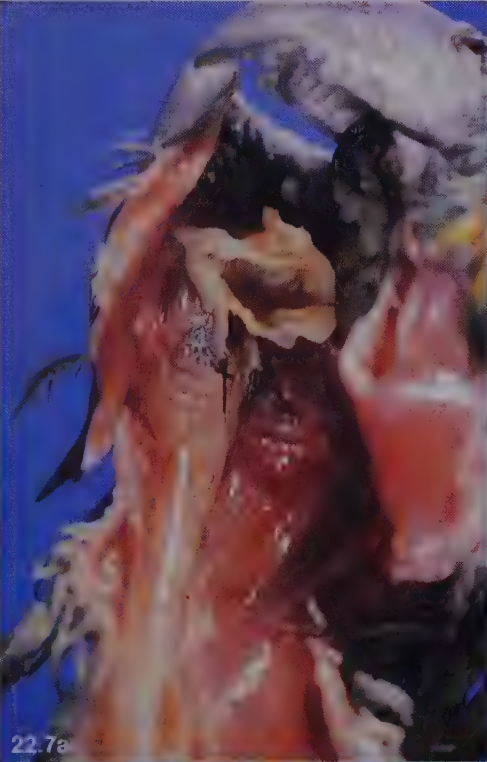22.4



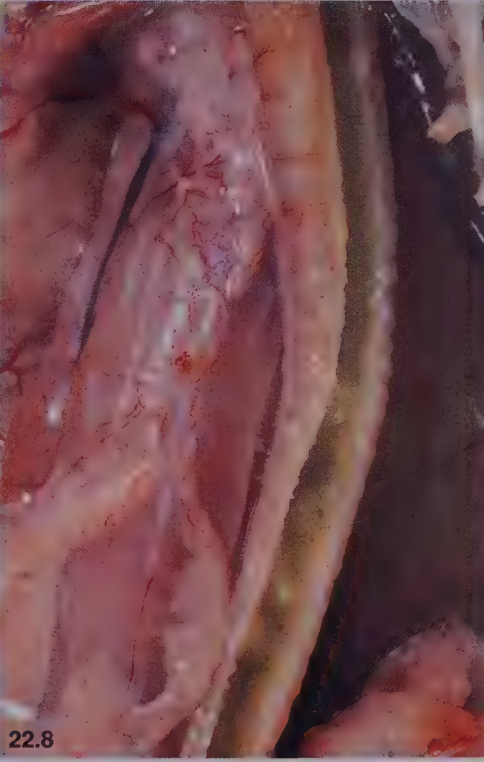22.5




22.6



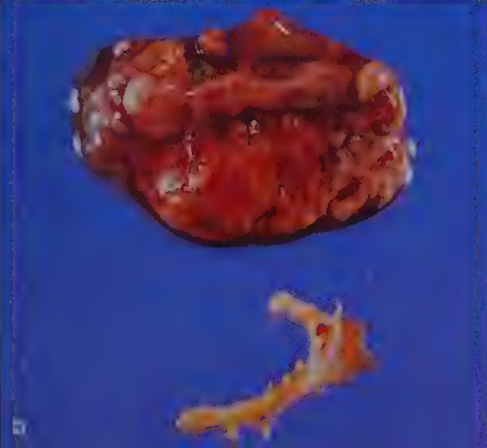22.7a



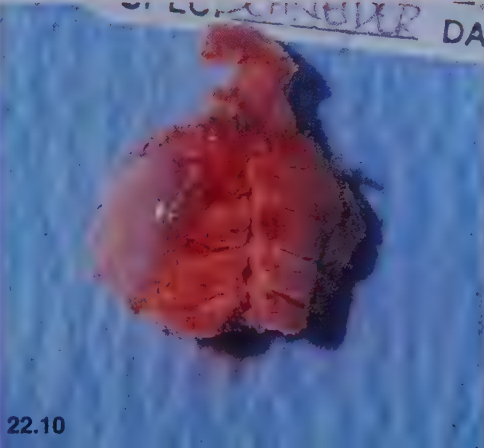22.8



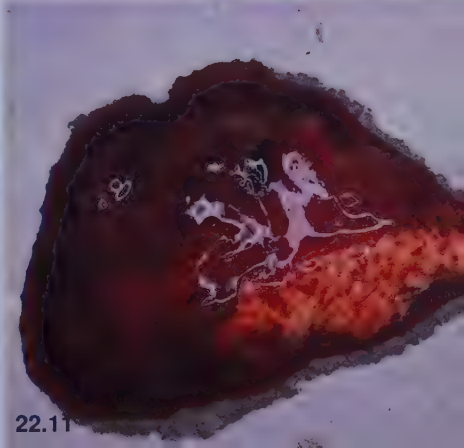
22.9



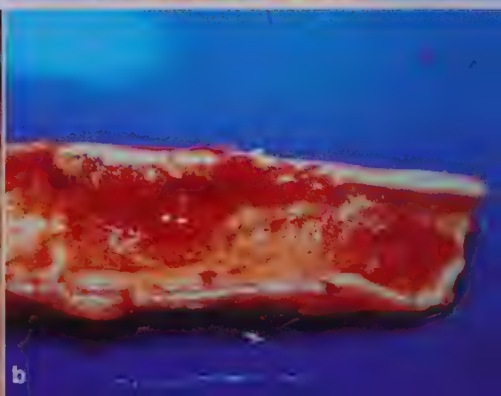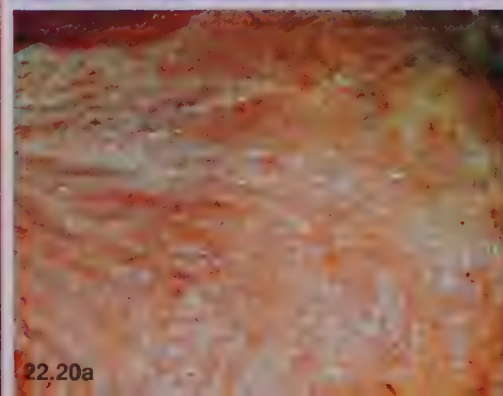
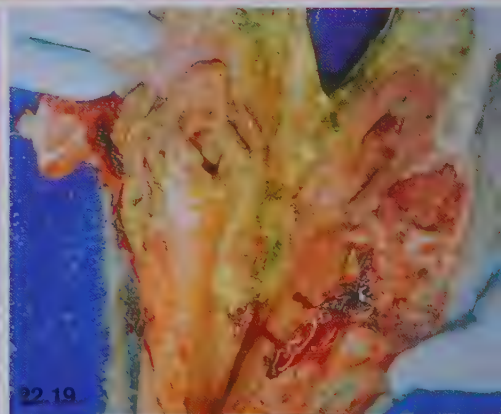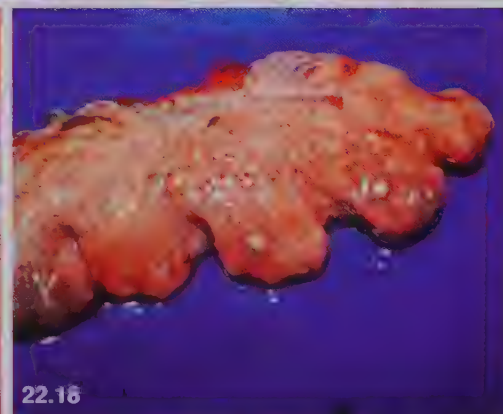
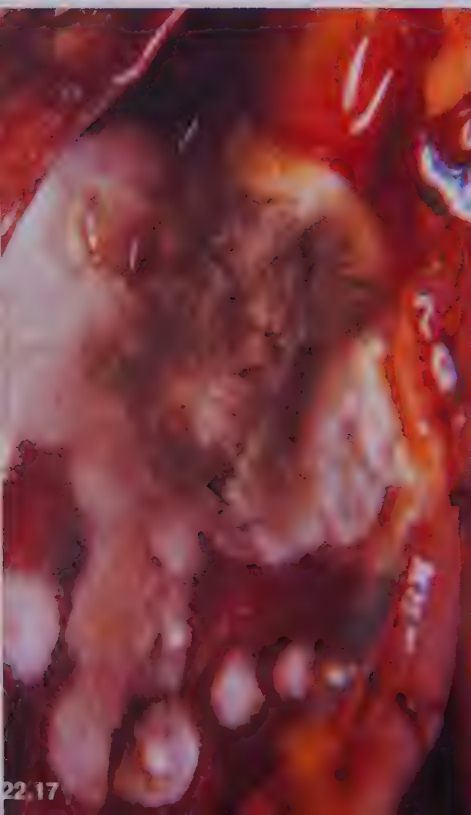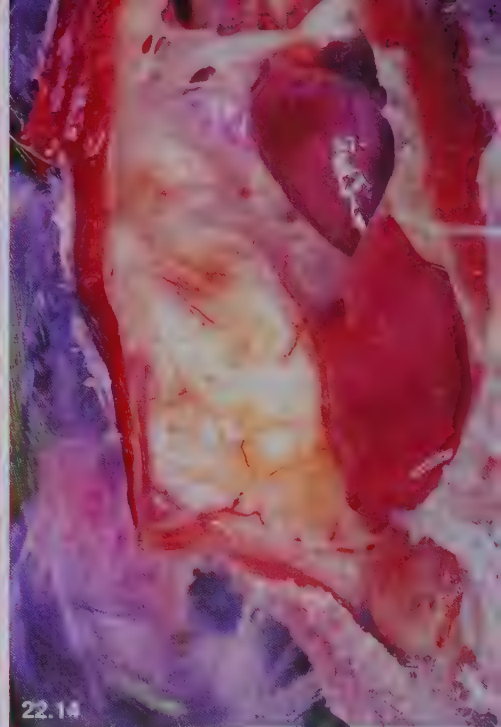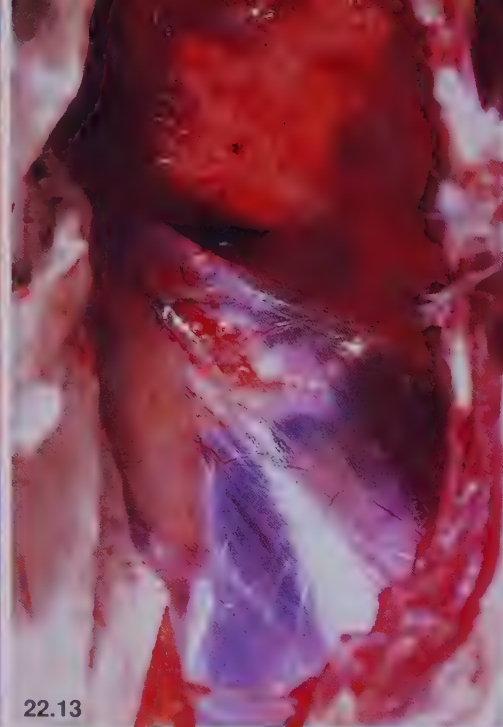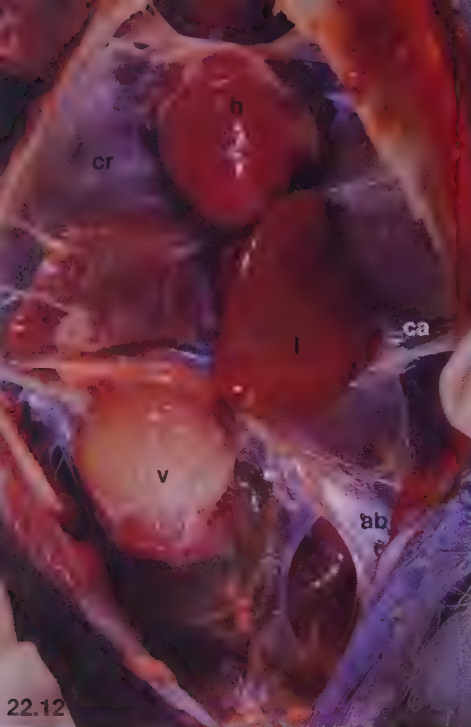
22



22.10



22.11





## Pneumonology

### Color 22.12

Normal air sacs should be completely transparent and lack vascularity. Heart (h), liver (l), ventriculus (v), cranial thoracic air sac (cr), caudal thoracic air sac (ca), abdominal air sac (ab) (image is reversed).

### Color 22.13

Several white proliferative masses were noted on the cranial thoracic air sac during a routine necropsy of a cockatoo with PBF. Impression smears stained with new methylene blue revealed branching septate hyphae characteristic of *Aspergillus* spp. These plaques were considered an incidental finding.

### Color 22.14

A five-month-old Amazon parrot was presented with a history of progressive dyspnea. The bird had a severe tail-bob, was open-mouthed breathing and was in severe distress. The bird was anesthetized with isoflurane and an air sac tube was placed in the abdominal air sac. Radiographs indicated a soft tissue mass in the right thoracoabdominal cavity. The client chose euthanasia because of the extent of the mass. At necropsy, a large, yellow mass that involved portions of the lung and thoracic air sacs was identified. Histopathology indicated bacterial pneumonia and air sacculitis. Ingesta was also noted, confirming a diagnosis of aspiration pneumonia.

### Color 22.15

**a)** Four white plaques suggestive of aspergillosis in a relatively normal thoracic air sac from an ostrich. **b)** Severe, necrotic fungal air sacculitis in a 22-month-old ostrich. The primary isolate was *Aspergillus* sp.,

although other unisolated fungi were suspected to be the cause of the black discoloration. This fungal infection was secondary to aspiration of ingesta. Note kernels of corn (courtesy of Brett Hopkins).

### Color 22.16

Aspergillosis granulomas in the trachea of a Pintail Duck (courtesy of R.J. Montali).

### Color 22.17

Aspergillosis will frequently produce proliferative fluffy lesions in the air sacs. Colonies in the oxygen-rich areas of the lungs and air sacs frequently produce characteristic conidiophores. The aspergillosis lesions in this case were present on the abdominal air sacs of a Buttlehead Duck (courtesy of R.J. Montali).

### Color 22.18

*Aspergillus* spp. pneumonia in a six-month-old emu with progressive dyspnea that was not responsive to antibiotic therapy. Note the multiple white-tan granulomas. The depressions in the lung (coastal sulci) represent the areas where the lung folds around the ribs (courtesy of Brett Hopkins).

### Color 22.19

*Pseudomonas* spp. can cause severe respiratory disease in ratites. A two-year-old ostrich hen with a history of respiratory disease had fibrinonecrotic pharyngitis (courtesy of Brett Hopkins).

### Color 22.20

**a)** Severe emphysema and collapse of the secondary bronchi and **b)** hemorrhagic pseudomembranous tracheitis caused by *Pseudomonas* spp. in an ostrich (courtesy of Brett Hopkins).

capillary network to form the exchange tissue of the lung.<sup>44</sup> On the ventral surface of the lung, secondary bronchi connect directly to the caudal thoracic and abdominal air sacs through ostium that can be visualized during endoscopy (see Color 13).


Surfactants in the parabronchi function to keep fluids from entering the air capillary area and prevent transudation. These functions combine to maintain the integrity of the delicate blood gas barriers.<sup>44</sup> Dilation and contraction of the bronchi and ostium are controlled by smooth muscles. The innervation to these muscles is non-vagal and can be relaxed with adrenergic drugs.<sup>44</sup>

From a functional standpoint, the avian lung is divided into a paleopulmo (which all birds have and which constitutes at least 75% of the lung) and the neopulmo (which some birds have and which makes up no more than 30% of the lung). The neopulmo is absent in penguins, minimally developed in emus, further developed in ducks and psittacine birds and maximally developed in pigeons and gallinaceous and passerine birds. The reasons for this division have not been clearly established, but it has been determined that the neopulmo is less efficient at gas exchange than the paleopulmo.<sup>40</sup> The fact that the neopulmo is less efficient is interesting, considering it is highly developed in one of the fastest flying birds, the pigeon.

## Air Sacs

### Pulmonary

Most birds have four paired and one unpaired pulmonary air sacs that connect to the lung and create a large respiratory capacity (see Anatomy Overlay). The configuration of the air sacs varies with the species. Most birds, including Psittaciformes, are believed to have four paired air sacs that include the cervical, cranial and caudal thoracic and abdominal air sacs. An unpaired clavicular air sac lies dorsal and caudal to the crop in the thoracic inlet and has both intra- and extrathoracic components. The intrathoracic component surrounds the great vessels, esophagus and syrinx with diverticula into the sternum and sternal ribs. The extrathoracic component represents diverticula into the thoracic girdle (see Anatomy Overlay).



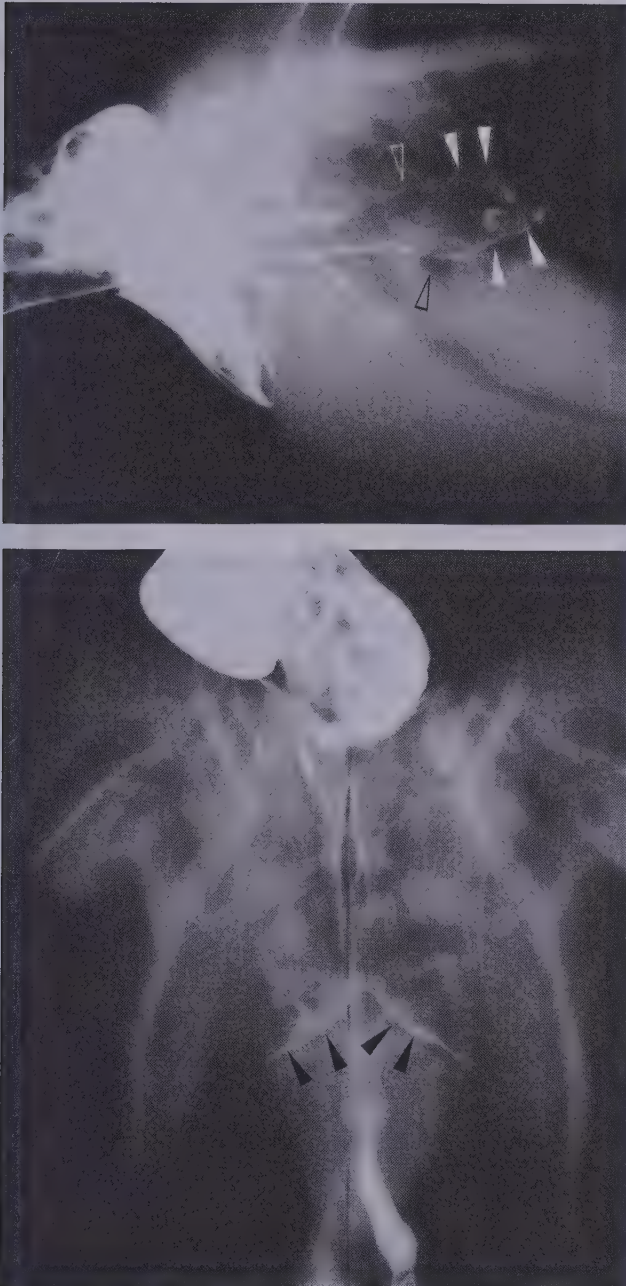
**FIG 22.4** An adult African Grey Parrot was presented with acute onset of severe dyspnea accompanied by open-mouthed breathing. Radiographs revealed a soft tissue mass at the level of the syrinx (arrows). The lungs and air sacs were considered radiographically normal. Tracheoscopy was performed with a 2.7 mm endoscope while the animal was maintained on isoflurane anesthesia delivered through an air sac tube. Cultures taken from a syringeal granuloma were positive for *Aspergillus* spp. (courtesy of M. McMillan).

The cranial air sacs are composed of the cervical, clavicular and cranial thoracic air sacs; the caudal air sacs are composed of the caudal thoracic air sac and abdominal air sac. The cranial thoracic air sacs receive air via the medioventral parabronchi and are physiologically components of the paleopulmonic air sac system. The caudal thoracic air sac, on the other hand, gets its air from lateroventral parabronchi and, along with the abdominal air sacs, is part of the neopulmonic air sac system.<sup>44</sup>

### Cervicocephalic

The cervicocephalic air sacs are not connected to the lung and are divided into cephalic and cervical portions; they connect to caudal aspects of the infraorbital sinus (see Anatomy Overlay). Extensive cervicocephalic air sac development has been noted in budgerigars, cockatiels, conures, Amazon parrots, macaws and cockatoos. This air sac is absent in diving birds, partially developed in ratites, pigeons and chickens and is well developed in strong-flying avian species. The cervicocephalic air sacs may function as insulating air layers for the retention of heat, to control buoyancy, to reduce the force of impact with the water in fish-eating birds and to support the head during sleep or flight.<sup>44</sup>

In some species, the cephalic portion is large, and in others it is minimally developed. Studies involving budgerigars, conures and cockatiels suggest that the cephalic air sacs arise from the infraorbital sinus and extend dorsally to cap the dorsum of the skull.<sup>72</sup> In the Amazon parrot, the cephalic portion of this air sac



**FIG 22.5** The syrinx (open arrow) and primary bronchi (arrows) are clearly visible in this macaw that aspirated barium. The barium could not be detected in the respiratory system on a subsequent radiograph taken 90 minutes later.

extends dorsally adjacent to the occipital bone. The cervical portion extends bilaterally dorsolaterally in the neck from the head to the distal neck (Figure 22.6).<sup>72</sup> The cervical division of the air sac communicates with the cephalic part by a small median pathway. The cervicocephalic air sac covers the lateral

aspect of the head and extends caudally over the dorsal cervical region to the shoulder area.

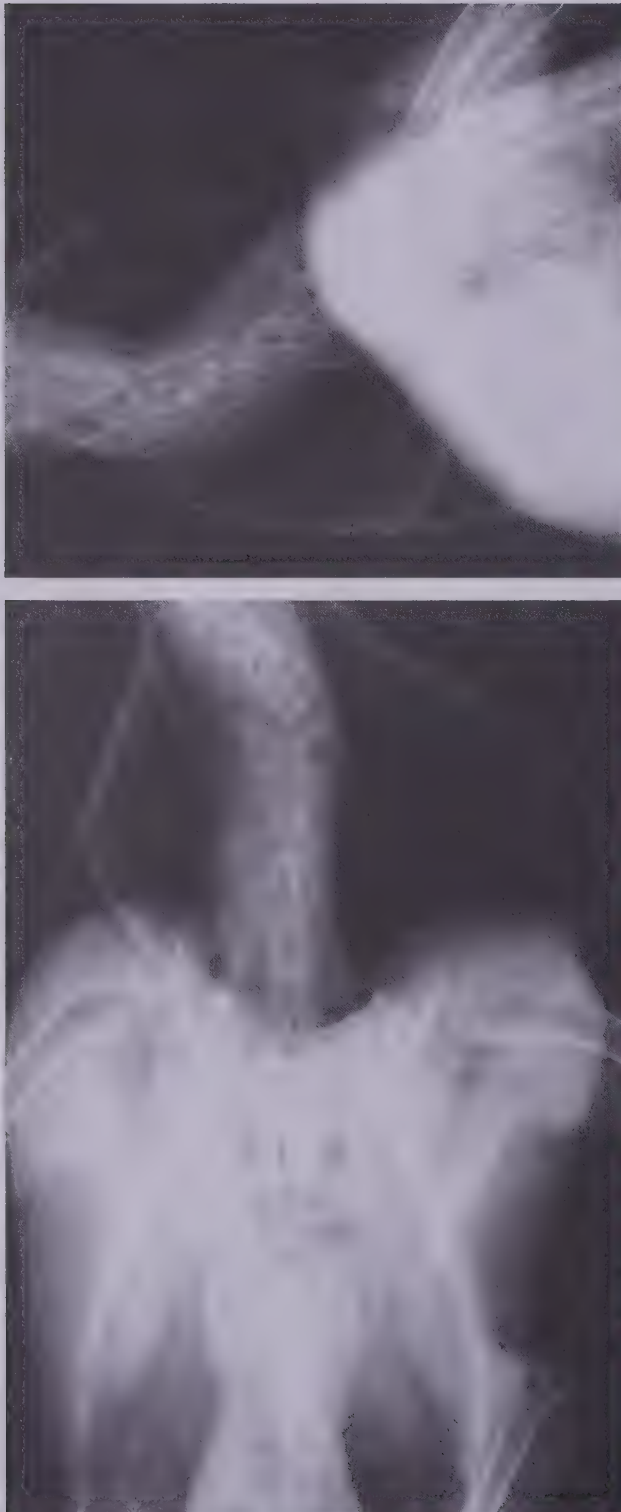No direct connection has been found between the cervicocephalic air sac system and any of the pulmonary air sacs. All air sacs are thin-walled and lack vascularity. The air sacs of a normal bird are completely transparent (appear similar to clear plastic wrap) (Color 22.12). Any alteration in transparency should be considered abnormal. The presence of blood vessels in the air sacs may be an indication of early inflammation. Blood vessels that transverse inflamed abdominal air sacs must be avoided during surgical procedures.<sup>61</sup> Air sac lesions that are localized and do not alter the flow of air in or out of the air sacs may not cause clinical changes (see Color 13.).

The trachea, primary bronchi and larger secondary bronchi are lined with pseudostratified or simple columnar ciliated epithelium, whereas the air sacs distal to the connection with the lungs are lined with a single layer of simple squamous epithelial cells. The area of the air sacs near the lung may contain simple cuboidal and columnar ciliated epithelium.<sup>44</sup> The poor vascular supply and lack of ciliary transport system within the air sacs hinder parenteral treatment of air sacculitis.<sup>52</sup>

Depending on the species of bird, the humerus, clavicles, coracoids and cervical vertebrae are connected to the respiratory system through extrathoracic diverticula. The sternum and sternal ribs are pneumatized through the intrathoracic diverticula that lie between the coracoid bones. The lungs connect directly to the thoracic vertebrae and their associated ribs. The femur may be pneumatized through a connection with the air sac (see Anatomy Overlay).

## Respiratory Physiology

Birds have no functional diaphragm. The thoracic cavity is separated from the abdominal cavity by a thin membrane called the oblique septum. Birds breathe by using the six inspiratory muscles (principally the external intercostales) to pull the ribs cranially, laterally and ventrally and to move the sternum ventrally and cranially, increasing the volume of the thoracoabdominal cavity. These changes in the body wall create a negative pressure with respect to



**FIG 22.6** A Yellow-naped Amazon Parrot was presented for a persistent swelling in the cervical area. Radiographs indicated gaseous distension of the cervical air sac with no other evidence of respiratory disease. Biopsies and cultures of the air sac were unremarkable. A permanent opening (stent) was created in the air sac to resolve the problem (courtesy of Marjorie McMillan).

the atmospheric air pressure surrounding the bird, causing air to pass through the respiratory system and into the inspiratory portion of the respiratory tract.

The nine expiratory muscles (principally the internal intercostals and abdominals) pull the ribs caudally, raising the sternum and pulling the ribs inward, causing expiration by creating increased internal pressure within the air sacs. This forces air out of the air sacs and back through the parabronchi (caudal air sacs) or trachea (cranial air sacs).<sup>44</sup>

It is frequently discussed that the oxygen ( $O_2$ ) and carbon dioxide ( $CO_2$ ) content of air in the caudal air sacs is similar to that in the environment. In reality, the caudal air sacs contain air that is higher in  $CO_2$ , possibly because of some dead space gases that remain in the caudal air sac following expiration.<sup>44</sup> The  $O_2$  and  $CO_2$  content of air in the cranial air sacs is similar to that of expired air. The rapid influx of inspired air into the caudal air sacs and the similarity of this air to environmental air have been used to explain the apparent prevalence of air sac infections and pathology in the caudal air sacs versus the cranial air sacs; however, it should be noted that half the inspired air enters the lungs. The prevalence of caudal air sacculitis may be a reflection of the air layering that occurs in this location.

In pigeons, barely detectable tail movements have been shown to be associated with inspiration (minimally) and expiration. The *M. caudofemoralis*, *M. pubocaudalis internus* and *M. pubocaudalis* were found to be involved with expiration by depressing the pelvis and uropygium and compressing the thoracoabdominal cavity. The *M. longissimus dorsi* was found to be involved in inspiration.<sup>6</sup> These findings would suggest that tail-bobbing is an exaggerated movement of a normal component of inspiration and expiration and is a reflection of an increased amount of work necessary to ventilate the lungs. The tail muscles seem to be most involved in respiration when a bird is resting on its keel, or the sternum is fixed in position.

If a bird is unable to move its ribs, it will rapidly suffocate. This can occur with an overly aggressive restraint or by the surgeon resting his hands on the body cavity during surgery. Bandages that encompass the body cavity can also interfere with breathing, particularly if they are wrapped tightly around the caudal portion of the sternum or ribs.

It is frequently discussed in veterinary literature that inspired air flows through the parabronchi or primary bronchus and directly into the caudal air sacs, thus bypassing the gas exchange portion of the lungs. This statement is not completely accurate. On inspiration, one-half of the inspired air volume goes to the lung and the other half goes to the caudal air sacs. The air that is already in the lungs enters the cranial air sacs. On expiration, the ambient air that is in the caudal air sacs enters the lungs. Although not clearly stated in any physiology reference, the air that is in the lungs must exit through the trachea along with the air that is in the cranial air sac. For this system to function, the volume of the caudal air sacs, the lungs and the cranial air sacs must be equal (each contains one-half of a total volume of inspired air at any one time) (Figure 22.7).

Two respiratory cycles are necessary for the one-half volume of air that enters the air sacs to move totally through the avian respiratory tract. Superficially, this would appear to be relatively inefficient, but in reality, it is much more efficient than the mammalian system. In birds, fresh air (fresh air delivered directly to the lungs on inspiration or fresh air delivered directly to the lungs on expiration from the caudal air sacs) enters the lungs on both inspiration and expiration.<sup>44</sup>

Some studies suggest that birds have a fluid valving system that controls the unidirectional air flow through the lungs and air sacs.<sup>45</sup> Other authors suggest that pressure differentials between the cranial and caudal air sac systems control the movement of air through the respiratory tract.<sup>44</sup>

### ■ Gas Exchange

The air capillaries are present in all birds. In some species, the parabronchi are divided into two systems. In these birds, the paleopulmonic parabronchi are the major sites of gas exchange, and air flows unidirectionally through these passages on inspiration and expiration. In the neoplumonic parabronchi, air passes bidirectionally through both phases of the respiratory cycle. Gas exchange occurs in the air capillaries. These air tubes branch and anastomose with each other, creating an extensive network. They are richly entwined with blood vessels, which form a blood gas barrier.<sup>60</sup> The pulmonary artery transports the less oxygenated blood into the interperibronchial arteries of the lungs. The interperibronchial arteries are located in the area of gas exchange and are

TABLE 22.4 Influences on Respiratory Rate

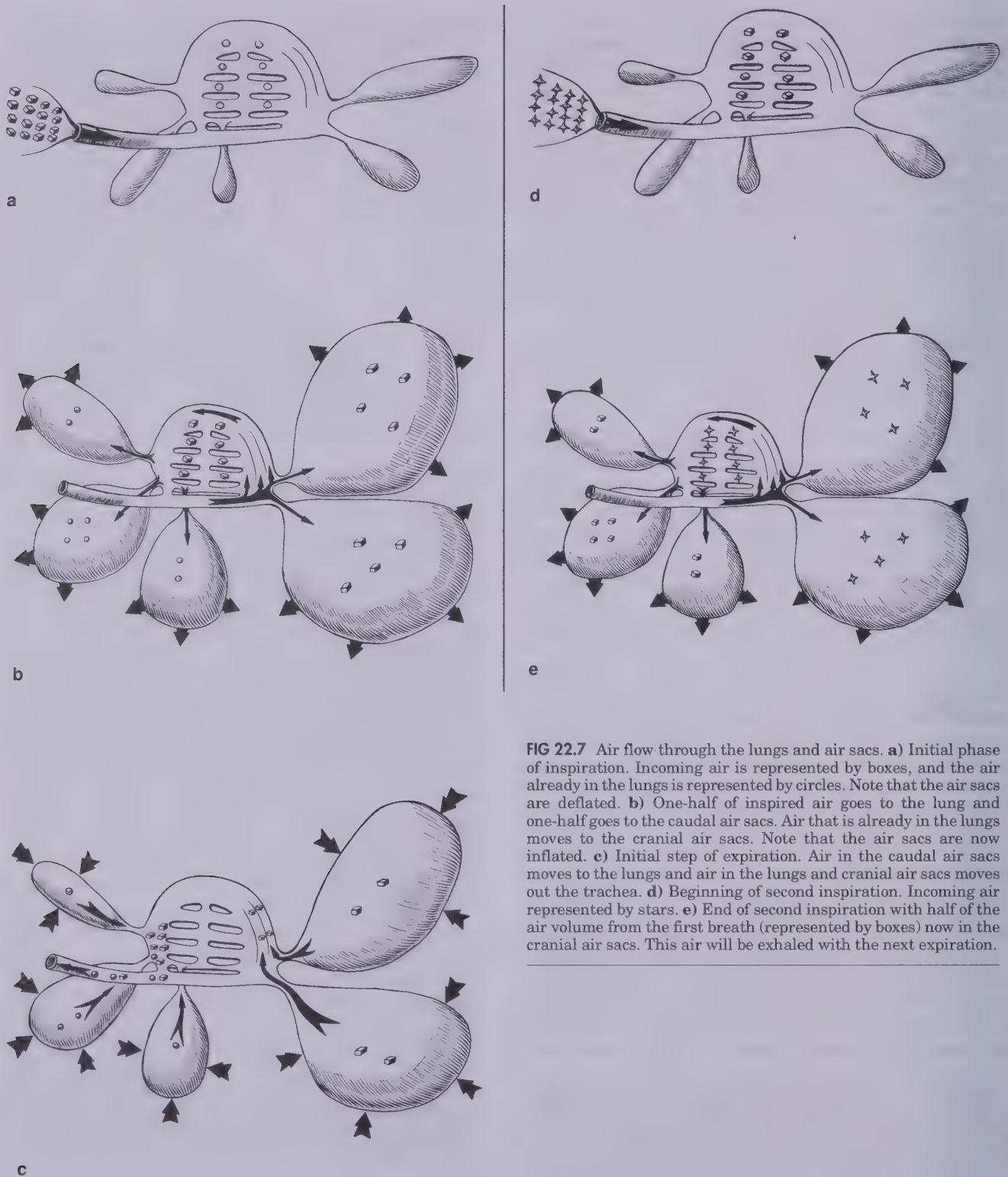
Increase Respiration	Decrease Respiration
Restraint	Anesthesia
Hyperthermia	Hypothermia
Low CO <sub>2</sub> levels in inspired air	Inhalation of toxic fumes
Increased respiratory dead space	High CO <sub>2</sub> levels in inspired air
Obesity	Severing of vagus nerve(s)
Pain	Air sac oxygen administration
Exercise	Sleep

arranged so that blood flows perpendicular to the air capillaries.

This barrier has the same three components as in mammals; however, it is anatomically not as thick as in mammals due to the reduced width of the epithelial cells and decreased tube size, which is much smaller than the mammalian alveolus. The efficiency of gas exchange is thus greater. However, with infection and its associated inflammation, a greater ventilation perfusion mismatch can occur.

In the paleopulmonic system, a current of parallel tubes of air moves in one direction counter to pulmonary vessels, allowing gas exchange to occur with greater efficiency than in the neopulmonic system or in the alveolus of mammals. In the latter case, air moves in both directions in the parabronchi, mixing oxygenated air with air having a higher partial pressure of carbon dioxide. These physiologic and anatomic components account for a 20% increase in the diffusion capacity for oxygen in birds when compared to mammals.<sup>44</sup>

The respiratory cycle is controlled principally by sensitive CO<sub>2</sub> pulmonary receptors. Interestingly, these receptors have been shown to be inhibited by halothane.<sup>44</sup> Other receptors that are integrally involved in controlling respiration include dermal pain receptors, thermoreceptors (control panting), chemoreceptors, baroreceptors in the aorta and mechanoreceptors in the respiratory tract (see Chapter 39).<sup>44</sup>



**FIG 22.7** Air flow through the lungs and air sacs. **a)** Initial phase of inspiration. Incoming air is represented by boxes, and the air already in the lungs is represented by circles. Note that the air sacs are deflated. **b)** One-half of inspired air goes to the lung and one-half goes to the caudal air sacs. Air that is already in the lungs and air in the caudal air sacs moves to the cranial air sacs. Note that the air sacs are now inflated. **c)** Initial step of expiration. Air in the caudal air sacs moves to the lungs and air in the lungs and cranial air sacs moves out the trachea. **d)** Beginning of second inspiration. Incoming air represented by stars. **e)** End of second inspiration with half of the air volume from the first breath (represented by boxes) now in the cranial air sacs. This air will be exhaled with the next expiration.

## Diagnostic Techniques

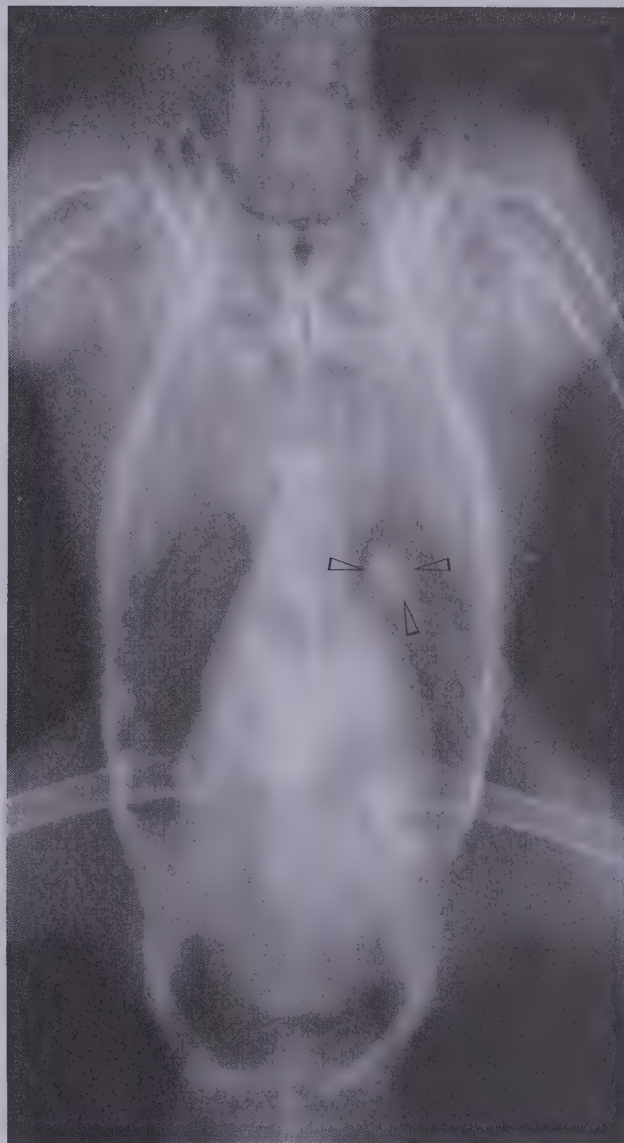### Auscultation

The sinuses, trachea, lung, thoracic air sacs and abdominal air sacs can be auscultated using a pediatric stethoscope. Audible sounds on inspiration generally correlate with upper respiratory tract disease, while sounds on expiration are more commonly associated with lower respiratory tract diseases.<sup>35,53,59</sup> Because air moves through the lungs continuously and the air capillaries do not collapse and expand to the same degree as alveoli, a “smacking” sound characteristic of pneumonia in mammals does not occur in birds (Figure 22.8). However, mild respiratory lesions may be associated with audible respiratory sounds, while auscultation may be normal in patients with severe air sac pathology. Placing a thin towel around the bird and auscultating through the towel will actually enhance the clinician’s ability to detect respiratory sounds.

With bacterial, fungal and parasitic diseases, harsh sounds may be heard on auscultation when air moves through narrowed parabronchi. Air sac pathology is best detected by placing the stethoscope along the lateral and dorsal body wall. An increased respiratory rate, particularly with dyspnea, is indicative of respiratory tract pathology, and harsh sounds may indicate chronic air sac or parabronchi pathology.<sup>65</sup> Use of a small amount of wing flapping (exercise) serves to increase respiratory rate and accentuate pathologic sounds. The amount of time for the bird to return to normal respiration (respiratory recovery time) is usually under two minutes even in obese birds. Prolonged respiratory recovery time is an indication that further diagnostic tests are necessary.

### Imaging

Radiography and endoscopy (with biopsy and culture) are the most effective diagnostic techniques for avian respiratory disease. Radiographically, generalized air sacculitis may be recognized by the appearance of air sac lines on lateral radiographs. Radiographic interpretation of the avian respiratory tract is different from mammals. Interstitial patterns, air bronchograms and atelectasis do not occur in avian radiography.<sup>54</sup> Radiographs are usually of little value in diagnosing acute sinus infections but may be of



**FIG 22.8** A Blue and Gold Macaw was presented with progressive dyspnea of one month’s duration. The bird had stopped eating and was depressed for two days before evaluation. Radiographs indicated a soft tissue mass in the left thoracic air sac region (arrows). The only change that could be detected by auscultation was decreased lung sounds. Endoscopy revealed a granulomatous mass and diffuse air sacculitis. The mass was surgically removed and the bird responded to therapy with broad-spectrum antibiotics.

value, particularly with respect to documenting involvement of bones in the head, with chronic inflammatory processes. Rhinography and sinography are helpful in the diagnosis of upper respiratory tract problems (see Chapter 12).<sup>54</sup>

The ventrodorsal view should be used to assess the subtle disorders of the lung and air sacs. Radiographically, soft tissue masses are commonly associ-

ated with upper respiratory signs, pneumonia and air sacculitis (Figure 22.8).<sup>54</sup> On a lateral radiograph, the trachea of normal toucans and mynah birds deviates ventrally, which should not be misinterpreted as a displacement caused by a soft tissue mass. In many ducks, the male has an enlargement on the left side of the syrinx (syringeal bulla) that is not found in the female.

### ■ Sample Collection

The minimum database for respiratory problems includes cytology of samples collected from the affected area, a CBC, biochemistries, radiographs and, when indicated, endoscopy.

A sinus aspirate is important in determining the cause of sinusitis. There are several techniques that allow for minimal sample contamination and maximum microbial and cytologic examination. A patient must not move during this procedure or severe damage to the globe of the eye can occur (see Chapter 10). Aspiration of the right and left infraorbital sinuses is needed for diagnostic procedures in some passerines.<sup>44</sup> Samples collected from the rostral portion of the choanal slit may provide some useful information on the organisms present in the respiratory passages. Samples collected from the caudal choanal slit are of little diagnostic value with respect to the sinuses or nasal passages.

#### Tracheal Lavage

Tracheal lavage is indicated when pathology of the trachea or lower respiratory system is suspected. The procedure is relatively simple but requires general anesthesia in most avian patients.<sup>40</sup> A normal wash should be low in cellularity with a minimum of pulmonary macrophages or inflammatory cells.<sup>13</sup>

Increased numbers of heterophils, pulmonary macrophages and other inflammatory cells in the lavage fluid are clinically important.<sup>13</sup> In a severely dyspneic bird, a large-gauge hypodermic needle or a respiratory catheter placed in the abdominal air sacs will help the patient breathe while the procedure is performed.

An intratracheal wash is performed by placing the bird in dorsal recumbency and passing a sterile, soft plastic or rubber tube (eg, Rob-nel catheter) through the glottis into the trachea, ending near the syrinx (just caudal to the thoracic inlet). A sterile saline solution (0.5 to 1.0 ml/kg body weight) is infused into

the trachea and reaspirated in the sterile syringe attached to the tube.<sup>40</sup>

A sterile endotracheal tube may be placed within the trachea prior to inserting the lavage tube to prevent sample contamination as the lavage tube is passed through the oral cavity. Tracheal swab samples for microbiology evaluation may be taken by passing a small sterile cotton swab directly into the trachea.

A transtracheal lavage can be performed by sterily placing an 18 to 22 ga Teflon indwelling catheter through the skin and into the trachea. The bird is held parallel to the floor and fluid is instilled and immediately removed. This procedure can be performed in some patients without anesthesia.

### ■ Endoscopy

An endoscope may be used to diagnose respiratory problems associated with the trachea, air sacs or lungs. Small-diameter, rigid or flexible endoscopes can be inserted to the syrinx in some birds. A 1.9 mm endoscope easily passes to the syrinx in a 200 g parrot while a 1.7 mm scope will not reach the syrinx in a cockatiel.

Endoscopic evaluation of the air sacs can be performed on both the right and left side of the patient. The caudal surface of the lung, which normally appears pale pink and spongy, may also be observed during this procedure (see Chapter 13).

Diffuse air sacculitis, recognized endoscopically as vascularized, translucent, thickened air sacs, commonly occurs with chlamydiosis, some viral diseases, poor air quality, bacterial infections and localized fungal infections. Granulomatous air sacculitis is difficult to resolve without surgery.

#### Air Sac Diagnostics

Cultures or biopsies of the air sacs can best be obtained using endoscopically guided procedures. Specially designed brushes are commercially available that will transverse the length of a sterile channel in the endoscope, eliminating the problem of coordinating the position of a separate endoscope and sample collecting device (see Chapter 13). Feather picking over the air sacs may be an indication of irritation that requires further investigation. The lung can also be biopsied using an endoscope (see Chapter 13).

A cytologic sample can be collected from the air sacs by passing a tube through an endoscopic cannula, lavaging with sterile LRS and immediately reaspi-



rating. Sterile cotton swabs may be used to obtain samples for bacterial or fungal cultures using the same technique.<sup>40</sup>

### Lung Biopsy

Lung biopsies may be diagnostic in some cases of toxin inhalation and microbial or parasitic infections. This procedure does create the potential for localized pulmonary hemorrhage and should be performed with minimal trauma to the lungs (see Chapter 13).<sup>41</sup>

The approach to the lung can be achieved through either the caudal thoracic air sac or via an intercostal approach through the third intercostal space. Approaching through the caudal thoracic air sac provides the best view of the caudal aspect of the lungs while the intercostal approach is used to access the dorsolateral portion of the lung. In experimental pigeons, mild to moderate pulmonary hemorrhage occurred at the biopsy site using a 2.7 Fr (best biopsy sample but more severe hemorrhage) or 5 Fr biopsy forceps. The procedure is not without risk and should be considered only when other diagnostic techniques are ineffective or when a biopsy is necessary to determine and initiate life-preserving therapy.<sup>41</sup>

## Aerosol Therapy

The use of a therapeutic solution that has been atomized into a fine mist is effective in treating upper respiratory tract infections.<sup>66</sup> Humidification, vaporization and nebulization are three types of aerosol therapy that have been used successfully to treat avian respiratory problems.

If the relative humidity of the environmental air is low, then humidification of inspired air may improve the efficiency of the mucociliary blanket.<sup>66</sup> In the clinical setting, humidification is used in conjunction with a therapeutic agent but can be prescribed without additives for home treatment. Any source of cool, moist air could be used.

Vaporization is a form of aerosol therapy that utilizes cool or warm mist to deliver topical medications to the mucous membranes.<sup>66</sup> Vaporized particles are large and do not reach the lower respiratory system. Eucalyptus-based products, available as over-the-counter medications for human vaporizers, may

cause mucosal irritation in birds and should not be used.

Nebulization can be used to augment systemic therapy of some respiratory tract diseases. Nebulization can help maintain proper hydration of the respiratory epithelium, break up necrotic debris and deliver antimicrobial agents to the upper respiratory tract and portions of the lower respiratory tract. Nebulization therapy is indicated in birds exhibiting sinusitis, rhinitis, pharyngitis and bronchitis. Depending on the agents delivered, nebulization can be used three to four times per day for 10 to 15 minutes for each session. Therapy should be continued for three days after all clinical signs have been resolved.

The equipment needed for nebulization therapy includes an air compressor or some source of O<sub>2</sub>, an enclosed chamber and an infant (human) nebulizer. The most important piece of equipment is the air compressor. An inexpensive reliable unit is commercially available,<sup>a</sup> which should satisfy most nebulization requirements. At least two sizes of nebulization chambers should be maintained, one for larger patients and one for small birds. It has been shown that nebulization can be used to deliver antimicrobial agents to the lungs and some portions of the air sacs if the particle size is less than 0.5 microns in diameter.

All medications delivered to birds by nebulization are used empirically and should be based at least on results obtained from culture and sensitivity (Table 22.5). Mucolytic agents should be used only with infections localized to the sinuses and trachea. Amphotericin B, gentamicin, polymyxin B and tylosin have been found to be poorly absorbed from the respiratory epithelium, and these agents are used principally for their local effects. However, penetration of nebulized antibiotic particles into avian lung parenchyma and onto air sac surfaces may be effective.

The addition of DMSO to the nebulization solution was found to increase the local and systemic concentration of nebulized tylosin.<sup>40</sup> However, the systemic effects of inhaling DMSO have not been evaluated. Nebulized tylosin required one hour to reach therapeutic concentrations in the air sacs and lungs of pigeons and quail.<sup>67</sup>

Other therapeutic agents that have been reportedly used for nebulization therapy in birds include acetylcysteine, sodium tris-EDTA, levamisole phosphate and corticosteroids.<sup>12</sup> The use of immunosuppressive drugs such as corticosteroids in nebulization therapy should be avoided. Acetylcysteine may be added to

nebulization therapy for upper respiratory diseases in which the exudates can be physiologically removed, but it should not be used for lower respiratory treatment because of a bird's inability to rapidly remove exudates from the air sacs.

TABLE 22.5 Medications Commonly Used in Nebulization Therapy<sup>5</sup>

Drug	Dosage
*Amphotericin B	100 mg in 15 ml saline
Chloramphenicol succinate	200 mg in 15 ml saline
Erythromycin	200 mg in 10 ml saline
*Gentamicin	50 mg in 10 ml saline
*Polymyxin B	333,000 IU in 5 ml saline
Spectinomycin	200 mg in 15 ml saline
Sulfa dimethoxine	200 mg in 15 ml saline
*Tylosin	100 mg in 10 ml saline, 1 g in 50 ml DMSO
*Amikacin	50 mg in 10 ml saline
Enrofloxacin	100 mg in 10 ml saline

These drugs may also be delivered by transtracheal injection.

\*Poorly absorbed from the respiratory epithelium; provides primarily topical therapy.

## Specific Respiratory Diseases

Table 22.6 lists the most common etiologic agents associated with respiratory diseases in birds (see Figure 22.11).

### Nutritional Disorders

Hypovitaminosis A has been associated with hyperkeratosis, abscessation of the palatine salivary glands and other oral salivary glands and respiratory lesions in psittacine birds (see Color 8).<sup>56,68</sup> Improving a bird's diet and providing oral vitamin supplementation and parenteral administration of vitamin A will prevent and eliminate nutritional deficiencies, support ill patients and speed recovery time in patients with respiratory infections. It should be noted that with the widespread use of formulated diets, hypovitaminosis A is less commonly encountered than it was a decade ago.

TABLE 22.6 Selected Etiologic Agents of Avian Respiratory Disease

<b>BACTERIAL</b>	<b>VIRAL</b>
<i>Chlamydia psittaci</i>	Adenovirus
<i>E. coli</i>	Paramyxovirus
<i>Mycoplasma</i>	Laryngotracheitis virus
<i>Pseudomonas</i>	Influenza virus
<i>Klebsiella</i>	Infectious bronchitis virus
<i>Salmonella</i>	Avian poxvirus
<i>Mycobacterium avium</i>	
<i>Proteus</i>	
<i>Haemophilus</i>	<b>PARASITIC</b>
<i>Bordetella avium</i>	<i>Sternostoma</i> (tracheal mites)
<i>Pasteurella</i>	<i>Cytodites</i> (tracheal mites)
<i>Streptococcus</i>	<i>Cyathostoma</i>
<i>Staphylococcus</i>	<i>Syngamus</i>
	<i>Sematospiculum</i> (nematode)
<b>NUTRITIONAL</b>	Cryptosporidia
Vitamin A deficiency	<i>Trichomonas</i>
Iodine deficiency	Coccidia (systemic)
Obesity	Hematozoa
General malnutrition	<i>Knemidokoptes</i> (scaly face mites)
	<i>Sarcocystis</i>
<b>TOXIC</b>	<b>FUNGAL</b>
Polytetrafluoroethylene gas	<i>Aspergillus</i>
Formaldehyde	<i>Candida</i>
Quaternary ammonium	<i>Mucor</i>
Creosote	<i>Cryptococcus</i>
Chlorinated biphenyl	
Carbon monoxide	
Cigarette smoke	
Naphthalene	
High ammonia	
Airborne particulate matter	
Zinc	

### Infectious Organisms

*Chlamydia psittaci* and *Mycoplasma* spp. are obligate intracellular organisms with a predilection for respiratory epithelium and have been implicated in cases of rhinorrhea, infraorbital sinusitis and inflamed choanae.<sup>34,73</sup> Both organisms may persist as low-grade upper respiratory tract infections. This is particularly common in birds that are treated with immunosuppressive, over-the-counter antibiotics.

*Mycoplasma* spp. have been proposed as causes of upper respiratory and ocular infections in cockatiels and budgerigars, although documented cases are rare (see Color 22.2 and Chapter 38).<sup>27,30,36</sup> *C. psittaci* and *Mycoplasma* spp. organisms are difficult to isolate and can cause similar clinical signs, which complicate a definitive diagnosis. These organisms have also been isolated from tissues of clinically asymptomatic birds.<sup>65</sup> Birds with suggestive clinical signs frequently respond to treatment with tetracyclines, tylosin or spectinomycin. These drugs are rarely effective against microbial organisms other than *Chlamydia* or *Mycoplasma* spp.

### Bacteria

*Escherichia coli*, *Klebsiella pneumoniae*, *Pseudomonas aeruginosa*, *Pasteurella multocida*, *Yersinia pseudotuberculosis* and *Salmonella* spp. are gram-negative bacteria frequently isolated from birds with respiratory tract infections (Color 22.1).<sup>55,63</sup> Gram-negative bacterial infections cause a mucopurulent or thick serous drainage in comparison to the rhinorrhea (clear nasal discharge) associated with uncomplicated *C. psittaci* infections (see Chapter 33).

Serous nasal discharges may result from foreign bodies, allergies, uncomplicated viral, bacterial, fungal or chlamydial infections and with developmental defects or injuries that block the normal drainage of the sinuses into the oral cavity. With most infectious agents, the discharge will turn rapidly from serous to mucopurulent.

Pathogenic gram-positive bacteria commonly associated with respiratory infections include strains of *Streptococcus* spp. and *Staphylococcus* spp.<sup>30</sup> *Mycobacterium tuberculosis* was recovered from the nasal cavity and infraorbital sinuses of a Red-lored Amazon Parrot (Color 22.10).<sup>5</sup>

Under most circumstances, *Streptococcus* spp. and *Staphylococcus* spp. would be considered normal bacterial flora. However, pure isolates of *Staphylococcus* spp. and *Streptococcus* spp. have been associated with respiratory and intestinal tract infections.<sup>30</sup> Common nonpathogenic bacteria isolated from the respiratory tract of psittacines include *Bacillus* spp., *Corynebacterium* spp. and *Lactobacillus* spp. (see Chapter 33).<sup>3,65</sup> Upper respiratory infections caused by spirochetes have been seen in cockatiels. This organism can be demonstrated on wet mount smears (see Chapter 10).

### Mycotic Organisms

Systemic avian mycotic infections can be difficult to treat. *Aspergillus* spp. are ubiquitous fungal organisms and are common pathogens in the respiratory system of immune-incompetent birds.<sup>42,55</sup> African Grey Parrots, cockatoos, Amazon parrots, raptors, penguins, turkeys, swans and other waterfowl (see Chapter 37) seem to be more susceptible than most psittacine species to this mycotic infection (see Chapter 35). Birds with a history of stress, unsanitary conditions or malnutrition and birds affected by oil spills or other toxins are most susceptible.<sup>61,65</sup> Infections may be acute, chronic or associated with mycotic tracheitis.<sup>29,33</sup> Mycotic granulomas may be found

in the nasal cavity, oropharynx, glottal opening, tracheal bifurcation (syrinx), lungs or air sacs.<sup>42,55,62,65</sup>

Clinical signs with acute mycotic tracheitis include dyspnea (mild to severe) and a white discharge originating from the glottis (Color 22.16).<sup>41,55</sup> Fungal hyphae may be seen cytologically in specimens taken from the choana or trachea. Tail-bobbing and peracute severe respiratory distress are common with chronic lower respiratory tract involvement if the passages from the air sacs to the lungs is occluded.<sup>65</sup> Secondary infections may occur on organs in contact with infected air sacs, which might include the liver, kidneys, intestinal serosa and gonads (see Chapter 35). *Candida* spp. infections originating in the oral pharyngeal cavity may extend into the proximal trachea and infraorbital sinuses resulting in varying degrees of dyspnea.<sup>14,39,62</sup> Infected birds may temporarily respond to antibiotics (alleviation of secondary bacteria) but fail to recover. In these cases, samples from the affected area should be evaluated by cytology and culture for the presence of fungal pathogens.

Although not common in psittacine birds, a few cases of respiratory cryptococcosis have been described.<sup>15,23,32,69</sup> Affected birds were depressed with severe dyspnea and were unresponsive to treatment. Necropsy findings indicated gelatinous myxomatous material in the nasal cavity, infraorbital sinus and air sacs.<sup>61</sup>

Rhinosporeidiosis is most frequently associated with waterfowl from estuary habitats.<sup>11,17</sup> These and other less common saprophytic fungi have been associated with rhinitis and sinusitis.<sup>11</sup>

*Trichosporon beigelli* (trichosporonosis), *Absidia* sp. (mucormycosis) and *Nocardia asteroides* (nocardiosis) have been isolated from the lungs and air sacs of birds with respiratory signs.<sup>9,19,47,70</sup>

### Parasites

Disseminated cases of trichomoniasis may involve the upper respiratory system, trachea and air sacs causing dyspnea and respiratory distress.<sup>58</sup> In the oropharynx and ventral choanal surface, lesions may appear as white or yellow caseous nodules or ulcers<sup>61</sup> (see Chapter 36).

The tracheal mite, *Sternostoma tracheacolum* may cause severe respiratory signs in finches and canaries. Symptoms include vocalization changes, a characteristic clicking during respiration, tail-bobbing and dyspnea.<sup>50</sup> Severe cases lead to weakness and death. The mite may be present in any location of the

respiratory system. Transtracheal illumination may be helpful in diagnosing infections. The identification of eggs in mucus from the trachea is diagnostic (see Chapter 36).

Gapeworms (*Syngamus trachea*) inhabit the trachea and glottis area of an infected bird. Clinical signs include dyspnea and changes in vocalization. Visualization of large, bright-red helminths that are in a Y-configuration in the glottal opening are indicative of infection.<sup>2</sup> The earthworm is the primary vector for *Syngamus trachea*, and infections occur following ingestion of the worm. This parasite most often infects ground-dwelling species, usually in zoo and aviary situations.

*Sarcocystis falcatula* is a coccidian parasite with an obligatory two-host life cycle.<sup>16,21</sup> This parasite causes an acute, fulminating, hemorrhagic, interstitial pneumonia.<sup>16</sup> The clinical presentation may range from respiratory distress and severe dyspnea to peracute death with no premonitory signs (Color 22.11; see Chapter 36).

Systemic microfilaria, trematodes, nematodes and cryptosporidia are other parasites that have been documented in the respiratory system of companion birds.<sup>2,38</sup> These parasites may be incidental findings on necropsy or may cause varying degrees of upper or lower respiratory distress.

### ■ Inhalation Toxicosis

Birds are sensitive to inhaled toxins and have historically been used as sentinel animals to detect toxic levels of poisonous gases. Clients should be educated with respect to the adverse effects that fumes from common household compounds can have on their companion birds. The clinical changes following inhalation of household fumes may include irritation of mucous membranes, conjunctivitis, rhinitis, dyspnea or peracute death (see Chapter 37).

#### Cigarette Smoke

Passive exposure to cigarette smoke is a common cause of primary respiratory problems in birds as well as a common complicating factor in other respiratory illnesses. Exposure to cigarette smoke can cause a mixture of clinical problems including conjunctivitis, sinusitis, air sacculitis, rhinitis and dermatitis. Diagnosis and treatment of respiratory disease in birds that are exposed to cigarette smoke are difficult, if not impossible. In many cases, complete cessation of all respiratory signs occurs from several

weeks to several months after the bird is removed from an environment contaminated with cigarette smoke.

#### Rhinitis and Sinusitis

Rhinitis may be caused by chemical, bacterial, fungal, chlamydial or viral pathogens. Precipitating environmental factors may include cigarette smoke, excessive powder down, dust from organic debris (bedding, flooring substrate), nutritional deficiencies and inappropriate use of antibiotics, all of which may damage the mucosa of the upper respiratory tract allowing pathogens to colonize. South American Psittaciformes that are exposed to the dander of cockatoos and cockatiels may develop a severe allergic pneumonitis. Antibiotics should be used with caution in mild undiagnosed rhinitis. Prolonged or inappropriate use can predispose the patient to secondary bacterial or fungal infections.

A seasonal occurrence (primarily winter months) of serous nasal discharge, mild sneezing and erythromatous nostrils has been described in some Psittaciformes (particularly South American species) maintained in cold, dry northern environments.<sup>5</sup> Similar lesions are seen when the heat or air conditioning systems are first turned on, which might suggest the accumulation of debris or respiratory irritants (stale gases) in the duct system. These birds can frequently be maintained with conservative therapy by increasing humidity, as long as the discharge remains serous and no pathogens are demonstrated. Birds are susceptible to influenza-A virus and could, theoretically, be infected through exposure to diseased members of the household (see Chapter 32).

### ■ Miscellaneous Conditions

#### Choanal Atresia

An African Grey Parrot chick with bilateral serous nasal discharge starting at four days of age was found to have choanal atresia (Figure 22.9). Fluids introduced into the nasal cavity did not enter the mouth and a rhinogram (nasal sinus contrast study) indicated that there was no communication between the nasal passage and the choanal slit (see Figure 12.42). Endoscopy of the choanal slit and surrounding structures revealed an intact membrane covering the choana at the level of the palate. All other oral structures were normal. Similarly, an Umbrella Cockatoo with a three-year history of intermittent serous to mucopurulent oculonasal discharge was found to have a deformed hard palate with no choanal slit. The roof of the mouth was flat and bony,



**FIG 22.9** An African Grey Parrot was presented with a life-long history of serous to mucopurulent nasal discharge that was unresponsive to antibiotics. Fluid introduced to the nasal cavity would not pass into the oral cavity, and endoscopy and rhinography were used to document choanal atresia (courtesy of Cheryl Greenacre).

with papillae scattered randomly. Sterile saline introduced into the nostrils would not pass from the nares to the oral cavity. Contrast media placed in the nares stopped abruptly at the level of a thickened palate, confirming the diagnosis of choanal atresia (see Figure 12.43).<sup>31</sup>

#### Proliferative Nasal Granulomas (Rhinoliths)

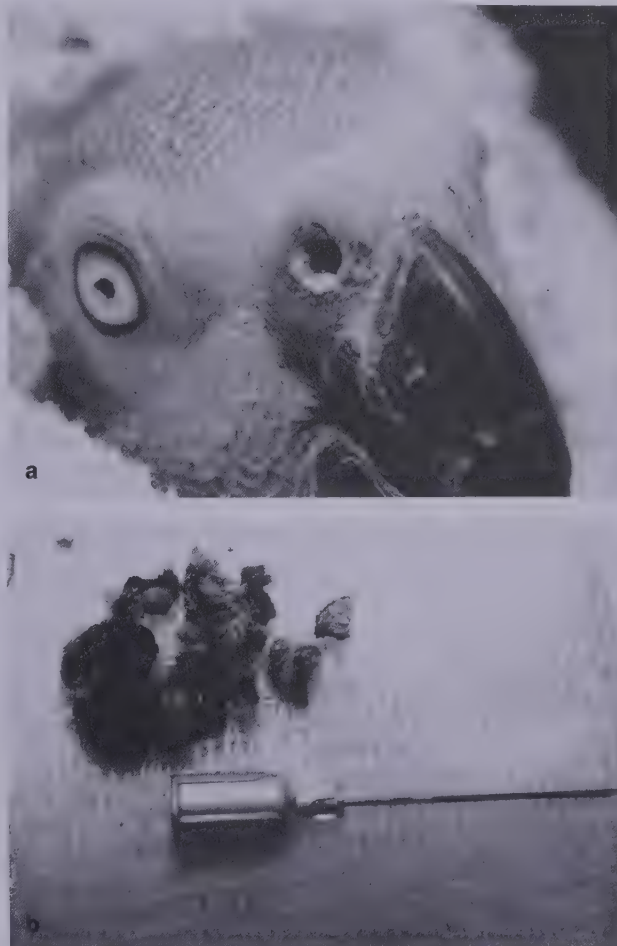Proliferative nasal granulomas have been documented in numerous psittacine species, but are particularly common in African Grey Parrots.<sup>18</sup> Pathogenic organisms isolated from these granulomatous growths included *E. coli*, *Enterobacter* spp., *Pseudomonas* spp., *Klebsiella* spp., *Aspergillus* spp. and *Candida* spp. Malnutrition and poor air quality play principal roles in initiating this lesion.

Upper respiratory disease, wheezing, sneezing and insufflation of the infraorbital air sacs on expiration can be early clinical changes associated with the accumulation of debris in the nares. Subtle lesions can best be detected by examining the area around the operculum using magnification. It is best to remove accumulating necrotic debris by probing and flushing before it accumulates and alters the architecture of the nares or sinus passages (see Chapter 41).<sup>14</sup> Recurrence is common unless dietary and management changes are made in conjunction with aggressive parenteral, topical and nebulization therapy.

Advanced lesions require removal of granulomatous tissue, frequently resulting in a large tissue defect (atrophic rhinitis; Figure 22.10). Given the vascularity of the affected area, manipulation of the affected tissue must be augmented with magnification.

#### Sunken Eye Sinusitis

A syndrome characterized by periorbital depression (sunken sinus syndrome) has been described as a sequela to sinusitis in macaws, conures and emus. Progressive collapse of the epithelium into the infraorbital sinus around the eye is typical (Color 22.1). Gram-negative organisms have been isolated from the infraorbital sinuses and choana of affected birds. The pathogenesis of this lesion is unclear. Ocular pathology or radiologic changes consistent with bone involvement are uncommon.



**FIG 22.10** a) Proliferative nasal granuloma and advanced atrophic rhinitis in an African Grey Parrot. Note the enlargement of the nostril, absence of the operculum and swelling of the perinasal tissues. b) Necrotic material that was removed from the nostril of this bird.

## Upper Respiratory Disease

### Clinical Presentation

Dyspnea, rhinorrhea, purulent nasal discharge, periocular swelling, voice change, open-mouthed breathing, coughing, sneezing

### Diagnostic Techniques

#### History

External examination of nares, choana, pharynx, larynx and trachea for hyperkeratosis, mites, granulomas

Palpation of neck and thoracic inlet, transillumination of trachea

Choanal Gram's stain and culture

Transtracheal wash, suction, cytology

Sinus flush and culture

Radiographs

Endoscopy

#### Rhinitis

1. Bacteria
2. Fungi
3. Reovirus
4. Parasites
5. Malnutrition
6. Chlamydia
7. Toxins

#### Sinusitis

1. Bacteria
2. Fungi
3. Hypovitaminosis A
4. Papilloma
5. Chlamydia
6. Mycoplasma
7. Toxins

#### Tracheitis

1. Amazon Tracheitis Virus
2. Avian Pox
  - a. *Agapornis* Pox
  - b. Psittacine Pox
  - c. Amazon Pox
  - d. Budgerigar Pox
3. Parasites
4. Malnutrition
5. Chlamydia
6. Toxins

#### Laryngitis

1. Herpesvirus
2. Poxviruses
3. Haemophilus-like organisms
4. Hypovitaminosis A

## Lower Respiratory Disease

### Clinical Presentation

Coughing, dyspnea, open-mouthed breathing, tail-bobbing, low exercise tolerance, depression

### Diagnostic Techniques

#### History

Auscultation of lungs and air sacs

Radiography

Laparoscopy

Culture, flush or biopsy

Visualize lungs and air sacs

#### Nonrespiratory Diseases with Respiratory Signs

1. Ascites: liver disease, renal disease, neoplasia
2. Hemocoelom: trauma, vitamin K deficiency
3. Malnutrition
4. Obesity
5. Goiter
6. Cardiomyopathy: heart failure
7. Paramyxovirus, herpesvirus, reovirus
8. Hemochromatosis
9. Egg-related peritonitis

#### Foreign Body Inhalation

#### Parasites

#### Air Sacculitis

1. Bacteria
2. Fungi
3. Canary pox
4. Paramyxovirus
5. Chlamydia
6. Mycoplasma

#### Pneumonia

1. Bacteria
2. Fungi
3. Virus
4. Mycobacterium
5. Parasite (*Sarcocystis*)
6. Toxin

#### Respiratory Abscess

1. Bacteria
2. Fungi

#### Allergy

FIG 22.11 Differential diagnoses of upper and lower respiratory disease.

It has been suggested that this lesion may occur because a vacuum develops within the infraorbital sinus due to blockage of small diverticuli secondary to the host's inflammatory response to infectious agents. Once an infection is resolved and the sinus pathways are patent, the collapsed sinus should return to normal. Within a flock of one hundred six-month-old emus, two birds developed this syndrome, suggesting a low prevalence of the problem in a given population (see Chapter 48).

### Foreign Body Inhalation

The inhalation of foreign bodies (seeds, granulomatous plaques, splinters and toys) occasionally occurs in companion birds.<sup>54</sup> The acute onset of mild to severe dyspnea in an otherwise healthy bird is a suggestive finding (Color 22.8). A thorough endoscopically assisted examination of the nares, choana, glottis, trachea and syrinx is helpful in the diagnosis of foreign body inhalation. Tumors, granulomas, abscesses and papillomas (glottis and choana) may cause varying degrees of dyspnea.<sup>18</sup>

The methods chosen to remove a foreign body will depend on the size of the patient. In birds weighing over 300 g, an endoscope can be used to suction or guide grasping forceps in the removal of some foreign bodies. Once the foreign body is localized, a 30 ga needle can be passed through the trachea distal to the mass to prevent it from moving further down the trachea. Some foreign bodies that cannot be removed by grasping may be flushed out of the trachea by holding the bird upside down and infusing fluids through a small tube placed in the trachea or through a transtracheal needle passed caudal to the mass. In some smaller birds, the distance to the syrinx can be estimated and marked on an appropriate-sized tube. The tube is then passed blindly to this predetermined level and suction is applied to remove accumulated debris.<sup>48</sup> If all other methods of removal fail, a tracheotomy is necessary (see Chapter 41).

### Proliferative Tracheitis

Dyspnea, rales, pseudomembranous tracheitis, conjunctivitis and sinusitis have been described as clinical signs associated with proliferative tracheitis in psittacine birds. A herpesvirus with group-serologic relations to the infectious laryngotracheitis virus (ILT) has been shown to cause this lesion in *Amazona* spp (Color 22.7).<sup>28</sup> Swabs of the glottis and proximal trachea for cytology culture and viral isolation are necessary for diagnosis. Antiviral therapy utilizing acyclovir may be helpful along with supportive therapy and antibiotics.<sup>65</sup> This disease is rarely reported in

the USA, and has been described only in smuggled or recently imported Amazon parrots (see Chapter 32).

### Air Sacculitis

Bacterial and fungal organisms are commonly associated with acute and chronic air sac infections.<sup>62</sup> The air sacs are poorly vascularized and have no clearance mechanism (mucociliary blanket), which complicates the treatment of air sacculitis. Air sac infections are best treated aggressively with therapeutic agents that are chosen based on culture and sensitivity. Surgical debridement may be necessary to resolve air sac infections that result in the formation of masses.

### Subcutaneous Emphysema

Subcutaneous emphysema can occur following damage to any air sac system but is most common with damage to the cervicocephalic, abdominal or caudal thoracic air sacs (Figure 22.12). Trauma, malnutrition and infectious agents have been implicated as causes of subcutaneous emphysema (see Chapter 41). In addition, the cervicocephalic air sac may distend as a result of rhinitis, which causes occlusion of the nasal passage or damage to the outflow tracts. The resulting lesion looks clinically like subcutaneous emphysema as the air sacs progressively inflate with each successive expiration.

When the air is removed with a needle, the sac will deflate but will typically reinflate with subsequent respiratory cycles. Initially, these problems can be managed by wrapping the area with a loose, self-adherent bandage. If the problem persists, long-term management can be achieved by inserting a Teflon stent in the dorsal wall of the air sac that allows air to escape. In some cases, the damage to the sac will repair itself and the stent can be removed. In other cases, the stent must remain in place permanently (see Chapter 41).

---

#### Product Mentioned in the Text

- a. Devilbiss Health Care Inc, Somerset, PA



FIG 22.12 Hyperinflation of the cervical air sacs in a cockatiel. The etiology was not determined. The bird was successfully managed by making an incision into the air sacs allowing them to deflate. The rents were kept open for ten days and the problem resolved.

### References and Suggested Reading

- AAV Practice Survey. *AAV Today* 1(3):98-99, 1987.
- Barnes HJ: Parasitology. In Harrison GJ, Harrison LR (eds): *Clinical Avian Medicine and Surgery*. Philadelphia, WB Saunders Co, 1986, pp 478-479.
- Bangert RL, Cho BR, Widders PR, et al: A survey of aerobic bacteria and fungi in the feces of healthy Psittacine birds. *Avian Dis* 32:46, 1988.
- Banks WJ: *Histology and Comparative Organology: A Text Atlas*. Baltimore, Williams and Wilkins Company, 1974.
- Bauk L, Hillyer E, Hoefler H: Rhinitis: Case reports. *Proc Assoc Avian Vet*, 1992, pp 134-139.
- Baumel JJ: Functional morphology of the tail apparatus of the pigeon. *Adv Anat Embryol Cell Biol* 110:1-115, 1988.
- Bignon F: Contribution to the study of pneumacity of birds: The cervicocephalic air cells of the birds and their relation with the bones of the head. *Mem Soc Zool Franc* 2:260-318, 1889.
- Brown R: Sinus articular and subcutaneous *Mycobacterium tuberculosis* infection in a juvenile red-vented Amazon parrot. *Proc Assoc Avian Vet*, 1990, pp 305-308.
- Burn EV, Huchzermeyer FW, Made VD: Mucormycosis in a parrot. *Mod Vet Pract* 63(12):961-962, 1982.
- Butler JP, Banzell RB, Fredberg JJ: Inspiratory valving in avian bronchi: Aerodynamic considerations. *Resp Physiol* 72:241-256, 1988.
- Campbell T: Mycotic diseases. In Harrison GJ, Harrison LR (eds): *Clinical Avian Medicine and Surgery*. Philadelphia, WB Saunders Co, 1986, pp 464-470.
- Campbell T: EDTA-Tris buffer lavage for treating psittacine birds with *Pseudomonas aeruginosa* infections: A Case Report. *Comp Cont Ed* 7:598-604, 1985.
- Campbell T: Cytology. In Harrison GJ, Harrison LR (eds): *Clinical Avian Medicine and Surgery*. Philadelphia, WB Saunders Co, 1986, pp 250-251.
- Chute HL: Fungal infections. In Hofstad MS, et al (eds): *Diseases of Poultry*. Ames, Iowa State University Press, 1972, pp 458-463.
- Cliphsham RC, Brill TO: Disseminated cytococcosis in a macaw. *J Am Vet Med Assoc* 171(9):989-990, 1977.
- Clubb SL, Frenkel JK, Gardiner CH, Graham DL: An acute fatal illness in old world psittacine birds associated with *Sarcocystis falcatula* of opossums. *Proc Assoc Avian Vet*, 1986, pp 139-150.
- Courtney CH, Forrester DJ, White FH: Rhinosporidiosis in a wood duck. *J Am Vet Med Assoc* 171(9):989-990, 1977.
- Crane SW, Jacobson E, Shields RP: Cryosurgical removal of an intranasal granuloma from an African grey parrot. *Vet Med Sm Anim Clin* 75(3):499-501, 1980.
- Dawson CO, Wheelodon EB, McNeil PE: Air sac and renal mucormycosis in an African grey parrot (*Psittacus erithacus*). *Avian Dis* 20(3):593-600, 1976.
- Drewes LA, Flammer K: Clinical microbiology. In Harrison GJ, Harrison LR (eds): *Clinical Avian Medicine and Surgery*. Philadelphia, WB Saunders, 1986, p 158.
- Dubey JP, Speer CA, Fayer P: Sarcocystosis of animals and man. Boca Raton, CRC Press, 1989.
- Emanouelsson S: Avian trichomoniasis. In Kirk RW (ed): *Current Veterinary Therapy VIII*. Philadelphia, WB Saunders Co, 1983, pp 619-621.
- Ensley PK, Anderson MP, Fletcher KC: Cryptococcosis in a male Becarri's crowned pigeon. *J Am Vet Med Assoc* 175(9):992-994, 1979.
- Filipich L: Examining your birds and giving first aid. In MacWhirter P (ed): *Every Bird: A Guide to Bird Health*. Melbourne, Australia, In Kata Press, 1987, pp 1-17.
- Flammer K: Oropharyngeal diseases in caged birds. In Kirk RW (ed): *Current Veterinary Therapy IX*. Philadelphia, WB Saunders Co, 1983, pp 617-619.
- Frenkel JK: Toxoplasmosis. In Kirk RW (ed): *Current Veterinary Therapy VI*. Philadelphia, WB Saunders Co, pp 1318-1324.
- Gaskin JM: Mycoplasmosis of caged birds. *Proc 1st Intl Conf Zoo & Avian Med*, Hawaii, 1987, p 57.
- Gaskin JM: Psittacine viral diseases: A perspective. *J Zoo Wildl Med* 20(3):249, 1989.
- Gaskin JM, Homer BL, Eskelund KH: Some unofficial thoughts on avian viral serositis. *Proc Assoc Avian Vet*, Chicago, 1991.
- Gerlach H: Bacterial diseases. In Harrison GJ, Harrison LR (eds): *Clinical Avian Medicine and Surgery*. Philadelphia, WB Saunders Co, 1986, pp 408-453.
- Greenacre CB, Watson E, Ritchie BW: Choanal atresia in an African grey parrot (*Psittacus erithacus erithacus*) and an Umbrella Cockatoo (*Cacatua alba*). *J Assoc Avian Vet* 7(1):19-22, 1993.
- Grinder LA, Walch HA: Cryptococcosis in columbiformes at the San Diego Zoo. *J Wildl Dis* 14:389-394, 1978.
- Harris DJ: Laboratory testing in pet avian medicine. *Vet Clin No Am Sm Anim Prac* 21(6):1154, 1991.
- Harris JM: Zoonotic diseases of birds. *Vet Clin No Am Sm Anim Prac* 21(6):1297, 1991.
- Harrison GJ, Harrison LR, Fudge AM: Preliminary evaluation of a case. In Harrison GJ, Harrison LR (eds): *Clinical Avian Medicine and Surgery*. Philadelphia, WB Saunders Co, 1986, pp 107-108.
- Harrison GJ, et al: Symptomatic therapy and emergency medicine. In Harrison GJ, Harrison LR (eds): *Clinical Avian Medicine and Surgery*. Philadelphia, WB Saunders Co, 1986, pp 370-371.
- Hillyer EV, et al: An outbreak of sarcocystis in a collection of psittacines. *J Zoo Wildl Med* 22(4):434-445, 1991.
- Hillyer EV, Quesenberry KE, Baier KE: Systemic microfilariasis in an umbrella cockatoo. *Proc Assoc Avian Vet*, 1988, pp 201-202.
- Humphreys PN: Debilitating syndrome in budgerigars. *Vet Rec* 101:248-249, 1977.
- Hunter DB: An introduction to the avian respiratory system: A diagnostic approach and common diseases. Introduction to Avian Medicine and Surgery. Assoc Avian Vet, New Orleans, 1992.
- Hunter DB, Taylor M: Lung biopsy as a diagnostic technique in avian medicine. *Proc Assoc Avian Vet*, 1992, pp 207-210.
- Jenkins J: Aspergillosis. *Proc Assoc Avian Vet* Chicago, 1991, pp 328-330.
- Klein PN, Galey FD: The challenge of toxicologic investigation in birds. *Proc Assoc Avian Vet*, 1989, 139-142.
- King AS, McIlelland J: Form and Function in Birds Vol 4. San Diego, Academic Press, 1989.
- Kueth DO: Fluid mechanical valving of air flow in bird lungs. *J Exp Biol* 136:1-2, 1988.



46. **Locke D, Bush M:** Tylosin aerosol therapy in quail and pigeons. *J Zoo Anim Med* 15:67-72, 1984.
47. **Long P, Choi G, Silberman M:** Nocardiosis in two Pesquet's parrots (*Psittichas fulgidus*). *Avian Dis* 27(3):855-859, 1983.
48. **Lumeij JT:** A Contribution to Clinical Investigative Methods for Birds with Special Reference to the Racing Pigeon. PhD Thesis. Faculty Vet Med, Univ of Utrecht, The Netherlands, 1987.
49. **Lutz M:** Use of human interferon in a case of systemic papillomatosis. *Proc Assoc Avian Vet, New Orleans*, 1992.
50. **McCluggage DM:** Parasitology in caged birds. *Proc Assoc Avian Vet, Seattle*, 1989, pp 97-100.
51. **McKibben JS, Harrison GJ:** Clinical anatomy with emphasis on the Amazon parrot. In Harrison GJ, Harrison LR (eds): *Clinical Avian Medicine and Surgery*. Philadelphia, WB Saunders Co, 1986, pp 31-66.
52. **McKiern BC:** Principles of respiratory therapy. In Kirk RW (ed): *Current Veterinary Therapy VIII*. Philadelphia, WB Saunders Co, 1983, pp 216-221.
53. **McKiern BC:** Lower respiratory tract diseases. In Ettinger SJ (ed): *Textbook of Veterinary Internal Medicine*. Philadelphia, WB Saunders Co, 1983, pp 760-828.
54. **McMillan MC:** Radiology of avian respiratory diseases. In Johnston DE (ed): *Exotic Animal Medicine in Practice*. Trenton, 1991, pp 88-98.
55. **Olsen GH:** Avian respiratory system disorders. *Proc Assoc Avian Vet, Seattle*, 1989, p 434.
56. **Perry R, Gill J, Cross G:** Disorders of the avian integument. *Vet Clin No Am Sm Anim Pract* 21(6):1307, 1991.
57. **Rae MA, Duimstra JR, Snyder SP:** Pulmonary silicosis in a blue and gold macaw (*Ararauna*). *Proc Assoc Avian Vet, Chicago*, 1991.
58. **Ramsay EC, Drew ML, Johnson B:** Trichomoniasis in a flock of budgerigars. *Proc Assoc Avian Vet*, 1990, pp 309-311.
59. **Rich G:** Basic history taking and the avian physical examination. *Vet Clin No Am Sm Anim Pract Small* 21(6):1135-1145, 1991.
60. **Ringer RK:** Selected physiology for the avian practitioner. In Harrison GJ, Harrison LR (eds): *Clinical Avian Medicine and Surgery*. Philadelphia, WB Saunders Co, 1986, pp 72-73.
61. **Ritchie BW:** Avian therapeutics. *Proc Assoc Avian Vet, Phoenix*, 1990.
62. **Roskopf WJ, Woerpel R:** Pet avian conditions and syndromes of the most frequently presented species seen in practice. *Vet Clin No Am Sm Anim Pract* 21(6):1189-1209, 1991.
63. **Roskopf WJ, Woerpel RW, Lane R, et al:** A survey of antibiotic efficacy for gram negative bacterial isolates from pet psittacine birds from May 1984 to February 1985. *Proc Assoc Avian Vet, Boulder*, 1985.
64. **Schaer M, Akerman N:** Diagnostic approach to the patient with respiratory disease. In Ettinger SJ (ed): *Textbook of Veterinary Internal Medicine* 2nd ed. Philadelphia, WB Saunders, 1983, pp 655-672.
65. **Spenser EL:** Common infectious diseases of psittacine birds seen in practice. *Vet Clin No Am Sm Anim Pract* 21(6):1223-1224, 1991.
66. **Spink RR:** Aerosol therapy. In Harrison GJ, Harrison LR (eds): *Clinical Avian Medicine and Surgery*. Philadelphia, WB Saunders Co, 1986, pp 376-379.
67. **Spink RR:** Nebulization therapy in cage bird medicine. *Vet Med Small Anim Clin* 75:791-795, 1980.
68. **Steiner CV, Davis RB:** *Caged Bird Medicine, Selected Topics*. Ames, Iowa State University Press, 1981, p 42.
69. **Takehita K, Fenwick B, Wong A:** Cryptococcosis in captive cockatoos. *Proc Assoc Avian Vet, Miami*, 1986, pp 133-138.
70. **Taylor MT:** Systemic trichosporonosis in a green-winged macaw. *Proc Assoc Avian Vet, Houston*, 1988.
71. **Tungerman PF, Schwartzman RM:** *Veterinary Medical Mycology*. Philadelphia, Lea and Febiger, 1972, pp 61-74.
72. **Walsh MT:** Clinical manifestations of cervicocephalic air sacs of psittacines. *Comp Cont Ed* 9:783-789, 1984.
73. **Wyrick PB, Richmond SJ:** Biology of chlamydia: Reports from the symposium on avian chlamydiosis. *J Am Vet Med Assoc* 195(11):1507-1511, 1989.

**T**he endocrine system of birds consists of the hypothalamic-hypophyseal complex, the gonads, pancreatic islet cells, adrenal glands, thyroid glands, parathyroid glands, ultimobranchial glands and the endocrine cells of the gut. All these organs release hormones into the bloodstream, which act on target tissues by interacting with receptors on the surface of the cell (peptide hormones) or within the cytoplasm or nucleus of the cell (steroid hormones).

Although endocrinopathies in birds do occur, endocrinology is a subject that is frequently unfamiliar to the avian practitioner. Endocrine system abnormalities may be more frequently diagnosed as practitioners expand their working knowledge of normal avian endocrinology, and appropriate clinical diagnostic tests can be used to document endocrine abnormalities.

A clinical presentation that suggests an endocrine disorder must always be confirmed before treatment is begun. Confirmation of the diagnosis may be difficult once replacement therapy is initiated, and improper or inadequate endocrine therapy can be fatal. Obesity is a good example of a clinical sign that is often misdiagnosed as an endocrine disorder (hypothyroidism) in birds, but is nearly always caused by malnutrition and lack of exercise instead. Feather abnormalities have also been reported in association with endocrine disorders without supporting evidence for an etiology. Polydipsia and polyuria can be of endocrine origin, but may also be psychogenic in origin. Psychologic factors and generalized organic diseases can profoundly affect endocrine function. Suppression of gonadotropin synthesis and reproductive failure may occur with environmental stress, and there can be an inadequate production of vitamin D in chronic renal failure leading to renal secondary hyperparathyroidism. Occasionally, failure of a target organ to respond to hormones may mimic endocrine disease (eg, nephrogenic diabetes insipidus, pseudohyperparathyroidism).

Furthermore, in man, domestic mammals and possibly also in birds, a number of endocrine syndromes may develop in association with tumors of non-endocrine origin, which form hormones that have a biological activity similar to the natural hormones (eg, paraneoplastic syndromes, ectopic hormone production).

This chapter will provide a review of normal endocrine function in birds (mostly based on gallinaceous species)<sup>28,29,93,101</sup> and discuss reported endocrinopathies in birds and some physiologic phenomena of clinical importance. Because there is a strong tendency among veterinarians to extrapolate knowledge of small animal endocrinology to birds, differences between avian and canine endocrinology will be highlighted.

Therapeutic measures are not given for diseases that have not been reported in birds. Guidelines for specific treatments of all endocrine abnormalities can be found in human and veterinary textbooks of internal medicine.<sup>26,109</sup>

## The Hypothalamus and Pituitary Gland

### Anatomy and Physiology

The hypothalamus is a relatively small structure that occupies about three percent of the total brain volume and forms a large portion of the ventral diencephalon. Various neural cell clusters can be recognized in the hypothalamus. Anteriorly, the most prominent are the preoptic nucleus, supraoptic nucleus and paraventricular nucleus. The infundibular nucleus and the medial posterior hypothalamic nucleus are found in the posterior or tuberal hypothalamus (see Chapter 28).

The hypophysis or pituitary gland is intimately connected to the hypothalamus. The pituitary gland consists of an adenohypophysis and a neurohypophysis (pars nervosa, neural lobe). In birds, the adenohypophysis can be divided into the pars distalis (anterior pituitary gland) and the pars tuberalis. The pars distalis forms the bulk of the adenohypophysis and is situated ventral to the neurohypophysis. Two distinct cell types can be distinguished in the cephalic and caudal part of the pars distalis, which therefore are referred to as the cephalic lobe and caudal lobe, respectively. A functional pars intermedia, which occurs in mammals, is not present in birds. The neurohypophysis can be divided into the pars nervosa (equivalent of posterior pituitary gland), the infundibular stalk and the median eminence.

The hypothalamic peptidergic neurons control pituitary gland function, whereby a variety of internal and environmental factors exert their influence by afferent neural stimuli and circulating hormone concentrations (eg, negative feedback). The hypothalamus is extensively innervated by ascending and descending afferent fibers from the rest of the central nervous system. Efferent fibers run to the pars nervosa and the median eminence of the neurohypophysis.

The supraoptic and paraventricular nuclei form the neurohypophyseal hormones, mesotocin and vasotocin, which are transported by axoplasmic flow and stored in depots in the neural lobe. The axons converge into a distinct bundle that is called the supraoptico-(neuro)hypophyseal tract. Axons terminating at the median eminence discharge their chemotransmitters into a portal system of blood vessels, which drain into the anterior pituitary gland.

### Neurohypophyseal Hormones

Avian neurohypophyseal hormones, arginine vasotocin (AVT) and mesotocin (MT), are similar to the mammalian antidiuretic (arginine vasopressin, AVP) and oxytocic (oxytocin) hormones, respectively. The major effect of AVT in birds is to reduce urine production. This is accomplished by decreasing the glomerular filtration rate through constriction of the afferent arterioles of reptilian-type nephrons, and by increasing the permeability of collecting ducts of mammalian-type nephrons. AVT is released in response to plasma osmolality changes, which are registered by peripheral and central osmolality receptors. Dehydration and infusion of hypertonic solutions cause AVT release, while infusions of hypo-osmotic glucose solutions depress plasma AVT concentrations below the detectable limit (<0.5 fmol/ml).

Injections of both AVT and oxytocin increase intrauterine pressure in birds, and a large increase in blood AVT concentration has been observed shortly before oviposition.

Plasma concentrations of AVT can be measured by means of an AVP radioimmunoassay that has been validated for AVT in avian plasma.

### Adenohypophyseal Hormones

Adenohypophyseal hormones are either glycoproteins or polypeptides. The glycoprotein hormones are luteinizing hormone (LH), follicle stimulating hormone (FSH) and thyroid stimulating hormone (TSH; thyrotropin). They consist of two subunits:  $\alpha$  and  $\beta$ .

The  $\beta$  subunit is the same for all three hormones, while the  $\alpha$  subunit is hormone-specific.

The adenohipophyseal polypeptide hormones are growth hormone (GH; somatotropin), prolactin- and proopiomelanocortin (POMC)-derived hormones such as adrenocorticotrophic hormone (ACTH) and  $\beta$ -melanocyte stimulating hormone ( $\alpha$ - and  $\beta$ -MSH),  $\beta$ - and  $\tau$ -lipoprotein ( $\beta$ - and  $\tau$ -LPH),  $\beta$ -endorphin and enkephalin.

LH is secreted mainly from the caudal lobe, while TSH is secreted in the cephalic lobe. The secretion site for FSH is undetermined. Prolactin is secreted in the cephalic lobe, while GH is secreted from the somatotrophic cells in the caudal lobe. The POMC-derived hormones, ACTH and  $\alpha$ -MSH, are secreted in the corticomelanotrophic cells of the cephalic lobe. This differs in mammals in which MSH is produced in specific cells in the intermediate lobe.

Both LH and FSH stimulate ovarian steroid synthesis and are essential for ovarian function in birds. During the ovulatory cycle, plasma FSH concentration shows little change. However, approximately five hours before ovulation, a rise in plasma LH concentration can be observed. Plasma LH concentration is low during egg laying, incubation and care for the chicks. An increase in LH secretion occurs toward the end of the chick-rearing period to prepare the hen for the next laying cycle.

In males, LH stimulates Leydig cell differentiation and testosterone synthesis, while FSH promotes Sertoli cell differentiation and spermatogenesis. A seasonal pattern of gonadal function that is regulated by daylight length has been described in birds. In male Japanese quail, a rise in plasma LH and FSH concentrations followed by increases in testicular size and gonadal steroid synthesis can be observed when the animals are transferred from 8 to 20 hours of daylight. After 50 days of being exposed to long daylight periods, the birds become refractory to photostimulation. Gonadotrophin synthesis is negatively influenced (suppressed) by other factors, such as aggressive encounters, nutritional deficiencies and the stress of restraint.

A chicken LH radioimmunoassay (RIA) can be used to measure plasma LH in other birds. The RIA for mammalian FSH can be used to measure plasma concentrations of avian FSH.

TSH increases the number of colloid droplets in thyroid cells, stimulates the uptake of iodide by the

thyroid and stimulates the release of thyroxine ( $T_4$ ). A human TSH RIA has been used to detect immunoreactive TSH in plasma of Japanese quail.

Avian GH has effects both on growth and on the short-term control of metabolism. Growth in chicks is markedly depressed after the administration of anti-GH antibodies. GH mobilizes stored lipids and increases free fatty acids, which are then available as an energy source. Lipogenesis is decreased. Muscle glycogen is increased and glucose utilization is reduced. GH seems to spare carbohydrates from use as a precursor for lipid synthesis.

An RIA for chicken GH is capable of detecting this hormone in many avian species (see hormonal involvement in avian growth and development).

In birds, prolactin is known to affect reproduction and osmoregulation. Effects on growth and metabolism have been suggested. In pigeons and doves, prolactin stimulates the production of crop milk. Just before the eggs are to hatch, there is a prolactin-induced proliferation and sloughing of mucosal cells in the crop sac. These cells are then regurgitated to feed the young during the first eight to eleven days of life. In other avian species, prolactin induces broodiness and suppresses ovarian function directly and indirectly via the hypothalamus. Prolactin is released after infusion of hypertonic NaCl solutions, and reduced urine flow occurs following the administration of prolactin.

Plasma prolactin concentrations can be measured by means of a homologous or heterologous RIA.

ACTH stimulates corticosterone and aldosterone production by the avian adrenal cortical (interrenal) cells.

At present, the unavailability of an ACTH RIA for avian plasma is an obstacle to studying the hypothalamic-hypophyseal-adrenocortical axis in birds, and plasma concentrations of corticosterone must be used as an indicator of plasma ACTH concentration. In ptarmigan (grouse), feather pigmentation has been shown to be influenced by MSH.<sup>43</sup>

#### Hypothalamic Releasing or Inhibiting Hormones or Factors

The hypothalamic-hypophysiotropic factors are released from the median eminence and are transported to the anterior pituitary gland via the portal blood vessels. If the chemical structure of these hypothalamic chemotransmitters is known they are called

hormones, and when the chemical structure is unknown, they are called factors. These chemotransmitters can have a stimulating or an inhibiting action on the release of the trophic anterior pituitary hormones and hence are called releasing or inhibiting hormones or factors.

The secretion of gonadotropin (LH and FSH) is controlled by LH releasing hormone (LHRH) which differs slightly from its mammalian counterpart. Both mammalian and avian LHRH stimulate avian LH secretion both *in vivo* and *in vitro*. LHRH cell bodies are located in the periventricular preoptic nucleus and in the tuberoinfundibular neurons.

The secretion of TSH is under stimulatory hypothalamic control. The hypophysiotropic factors regulating pituitary TSH release are somatostatin and thyrotropin releasing hormone (TRH), which are also physiologic regulators of GH secretion in birds.

GH release from the adenohypophysis is under hypothalamic control by TRH, growth hormone releasing factor (GRF) and somatostatin (somatotropin release inhibiting factor; SRIF), which inhibits GH secretion. Somatostatin is also formed in the avian pancreas.

Contrary to the situation in mammals, prolactin is under stimulatory hypothalamic control. The identity of avian prolactin releasing factor (PRF) remains undetermined.

The secretion of ACTH in birds is presumably under control of corticotrophin releasing factor (CRF).

#### Hormonal Involvement in Avian Growth and Development

A number of hormones play a major role in the control of growth. These include GH,  $T_4$  (3,5,3',5' – tetraiodothyronine),  $T_3$  (3,5,3' – triiodothyronine) and the sex steroids. The effect of GH on growth is via mediating factors: insulin-like growth factors (IGF) I and II (somatomedins), transforming growth factors (TGF), epidermal growth factors (EGF) and nerve growth factors (NGF).<sup>81</sup> Insulin appears to be available for the embryo all throughout chicken ontogeny, and the gene is expressed before the pancreas differentiates.<sup>88</sup> Plasma concentrations of GH are first detectable on day 17 of chicken embryo development, and responses to injection of GH releasing factor or thyrotropin releasing hormone are not observed until three weeks into incubation.<sup>81</sup>

Three variants of chicken GH have been observed. It has been postulated that some variants are more

specific than others for the distinct activities of GH (eg, growth promotion, lipolysis, inhibition of glucagon-induced lipolysis). Independent control of synthesis and release of the variants of GH may exist. Mammalian and avian GH preparations have both lipolytic and antilipolytic activities; fish GH has no lipolytic effect, yet exerts full antilipolytic effect. This has been regarded as tentative evidence for the existence of two types of GH receptors: a GH receptor that does not recognize fish GH (“lipolytic” receptor) and a GH receptor that recognizes mammalian, avian and fish GH (“antilipolytic” receptor).

In chickens, plasma concentrations of GH are highest from hatching up to eight weeks of age, and then decline to reach a low, relatively static level.

#### Diseases in Relation to the Hypothalamic-Hypophyseal Complex

Although in recent decades major advances have been made in the elucidation of hypothalamic-hypophyseal control of endocrine function in birds, relatively little has been reported with regard to diseases related to the hypothalamic-hypophyseal complex (HHC).

Considering the large number of diseases associated with the HHC in man and domestic animals, and the similarity of the HHC between mammals and birds, it is to be expected that a number of hypothalamic diseases that hitherto have not been reported in birds will be reported in the future.

Diseases may be caused by hypo- or hypersecretion of one or, more commonly, several of the hypothalamic or pituitary hormones. These alterations in secretion may be caused by tumors that are primary or metastatic, benign or malignant, pituitary or parapituitary, or by granulomatous lesions, congenital lesions or trauma. In addition to causing endocrine abnormalities, space-occupying lesions may cause neurologic signs due to pressure on surrounding nerve tissue.

When a diagnosis of hypothalamic disease is based on circulating concentrations of hypothalamic or hypophyseal hormones, it should be considered that primary hypofunction of a target organ will result in hypersecretion of the trophic hormone. This makes it possible to distinguish between a primary disorder of the gland or a disorder of the gland secondary to pituitary dysfunction or a hypothalamic disorder (tertiary dysfunction).

Examples from mammalian medicine of hyperpituitarism include Cushing's syndrome (ACTH), precocious puberty or infertility (gonadotrophin), amenorrhoea in women and infertility in men with galactorrhea (prolactin), hyperthyroidism (TSH), gigantism (GH before puberty) and acromegaly (GH after puberty). Examples of hypopituitarism include dwarfism, secondary hypothyroidism, adrenocortical insufficiency and hypogonadism. An example of a disease associated with a disorder of the hypothalamus or posterior pituitary gland is cranial (central) diabetes insipidus, which is caused by insufficient secretion of antidiuretic hormone.

### Dwarfism

Dwarfism has been reported in various avian species such as the fowl,<sup>46</sup> pheasant,<sup>2</sup> Black-headed Gull<sup>42</sup> and Great Crested Flycatcher.<sup>67</sup> Dwarfism is sex-linked recessive in the fowl.<sup>46</sup> Sex-linked dwarf growing chicks have lower concentrations of somatomedin C (insulin-like growth factor, IGF - I) and T<sub>3</sub>, whereas GH and T<sub>4</sub> are increased, probably due to a decreased negative feedback effect on GH secretion. The dwarfism is not caused by a defective release mechanism of GH because both TRH and GRF stimulate the release of GH to a greater degree in dwarfs than in normal chickens. In normal chickens, GH and TRH stimulate hepatic 5'-monodeiodination activity (conversion of T<sub>4</sub> to T<sub>3</sub>). This conversion does not occur in dwarfs. A lack of GH receptors could be a sufficient cause for deficiencies in IGF-I and T<sub>3</sub> production in dwarfs.<sup>50</sup>

### Diabetes Insipidus

In birds, the main physiologic regulator of body water balance is the octapeptide, arginine vasotocin (AVT). Both arginine vasotocin and the mammalian counterpart, arginine vasopressin (antidiuretic hormone, ADH), produce antidiuresis in birds, but the former is considerably more potent.

Diabetes insipidus has been reported to occur in chickens and might also occur in other avian species. The principal clinical signs of this disease are polyuria and polydipsia (PU/PD) (see Color 8).

Water deprivation test can be used in dogs to distinguish between the causes of PU/PD. The principle of the water deprivation test is to determine whether endogenous ADH is released in response to dehydration and whether the kidney responds to this stimulus. With this test, differentiation between central diabetes insipidus, nephrogenic diabetes insipidus, primary (psychogenic) polydipsia and hyperadreno-

corticism is facilitated. For healthy racing pigeons, it has been established that a urine osmolality of at least 450 mOsm/kg can be expected after 24 hours of water deprivation, which typifies the normal concentrating capacity of the kidneys. In avian patients with PU/PD in which urine osmolality does not increase in response to water deprivation, administration of exogenous ADH or AVT can be used to differentiate between central diabetes insipidus and other causes of PU/PD.<sup>1</sup> A water deprivation test using plasma AVT concentration has recently been developed for use in birds. Plasma AVT concentrations were measured before and during a 72-hour period of water deprivation. It was concluded that an AVT concentration > 2.2 pg/ml after 24 hours of water deprivation is indicative of a normal AVT release from the neurohypophysis in the pigeon.<sup>61</sup>

### Pituitary Tumors in Budgerigars and Cockatiels

Chromophobe adenomas and carcinomas of the pituitary are common in budgerigars (see Chapter 25). In a review of 497 tumors in budgerigars, 156 were either chromophobe adenomas or carcinomas;<sup>85</sup> however, in other reports, the incidence of these tumors was considerably lower.<sup>12</sup> Variations in the reported incidence of pituitary tumors might be caused by the fact that these tumors are easily overlooked during a routine gross necropsy. The pituitary gland is easy to isolate and should always be evaluated. The mandible is removed with the bird in dorsal recumbency. The medial ridge of the sphenoid bone can be broken away with forceps, after which the pituitary will be found lying in the sella turcica of the sphenoid, just posterior to the optic chiasm. The normal pituitary gland from a budgerigar is about 2 mm in diameter,

### CLINICAL APPLICATIONS

Pituitary gland tumors should be suspected in clinical cases with:

- PU/PD
- Reproductive failure
- Feather dystrophy
- Pigmentation abnormalities
- Obesity
- Stupor
- Blindness
- Convulsions
- Uni- and bilateral exophthalmos
- Hyperglycemia.

If these signs are present and a bird dies, the pituitary gland should be submitted for histopathology.

while the diameter can be 7 mm if a pituitary tumor is present. Pituitary tumors have been associated with a ten-fold weight increase of the pituitary gland.<sup>8,12,82</sup>

These tumors may be infectious in nature, which could also explain the variation in the reported incidence of disease. Homologous transplantation of pituitary tumors from budgerigars has been reported, and renal adenocarcinomas occurred in ten percent of the birds.<sup>84</sup> Avian leukosis virus antigen has been demonstrated in budgerigars with kidney tumors.<sup>69</sup> A causal relationship between renal tumors in budgerigars and avian leukosis virus, however, has yet to be demonstrated. Pituitary tumors have also been reported in an *Agapornis* spp.<sup>91</sup> and in two cases in the fowl.<sup>15</sup>

Recently, pituitary adenoma and pituitary adenocarcinoma with metastasis to the liver have been reported in cockatiels.<sup>19,106</sup>

Reported clinical signs of pituitary tumors in budgerigars and cockatiels are related to hormonal imbalance (eg, polyuria, polydipsia, reproductive failure, obesity and feather structure and pigmentation abnormalities) and to compression of surrounding nervous tissue (eg, stupor, blindness, uni- or bilateral exophthalmus, convulsions). Although it has been suggested that the PU/PD is caused by hyposecretion of AVT (diabetes insipidus), hypersecretion of ACTH (Cushing's disease, secondary hyperadrenocorticism), TSH (hyperthyroidism) or GH have not been excluded.

Hyperglycemia and obesity occurred in birds with subcutaneous transplants of pituitary tumors.<sup>84</sup> The obesity was characterized by an accumulation of adipose tissue beneath the skin of the breast and abdomen as well as in the peritoneum and mesentery. The liver was often enlarged, and histologic sections revealed an accumulation of fat in hepatic cells.

In budgerigars with large tumor transplants, blood glucose concentrations exceeded 1000 mg% with one value reaching 1768 mg%. At necropsy, the thyroids, adrenal glands and pancreas were normal.

## Calcium Metabolism

### Anatomy and Physiology

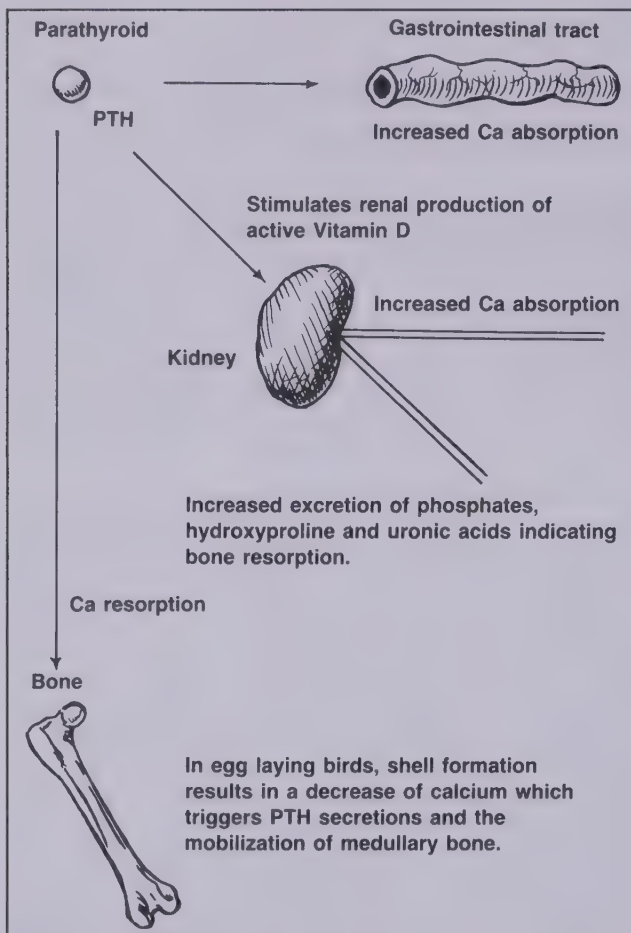
Calcium metabolism in birds is under the control of three major hormones: parathyroid hormone (PTH), calcitonin (CT) and 1,25 dihydrocholecalciferol (1,25(OH)<sub>2</sub>D<sub>3</sub>), the active metabolite of vitamin D<sub>3</sub> (Figure 23.1). Other hormones, however, also alter calcium metabolism, and the amounts of calcium and vitamin D in the diet have profound effects.

#### Parathyroid Hormone

PTH is secreted by the paired parathyroid glands, which consist of cranial and caudal lobes and can be found caudal to the thyroid glands. In the chicken, the left parathyroid gland is not in contact with the thyroid gland, while on the right side the cranial lobe lies next to the thyroid gland. In companion birds, the parathyroids are normally visible as light-colored areas at the caudal end of the thyroid glands (see Anatomy Overlay). The main tools that have been used for studying parathyroid function in birds have been parathyroidectomy and the use of heterologous (usually bovine) PTH. Currently, a sensitive radioimmunoassay for avian PTH is not available and avian PTH (1-84) or PTH (1-34) is also not commercially available. Heterologous and homologous PTH may act differently in birds.

PTH is secreted in response to hypocalcemia. The primary target organs of PTH are the kidney and bone. Calcium excretion in the urine is decreased by increasing tubular reabsorption of calcium, while circumstantial evidence suggests that calcium resorption from bone is increased. During the egg-laying cycle, PTH functions in the resorption of medullary bone. Under the influence of PTH, renal tubular secretion of phosphate is increased, while decreased tubular reabsorption may occur. The net result is a phosphate diuresis and a decrease in plasma phosphate.

PTH regulates vitamin D by stimulating 1-hydroxylase activity and inhibiting 24-hydroxylase activity in the renal cortex, thereby enhancing the production of the key calcium-regulating hormone 1,25(OH)<sub>2</sub>D<sub>3</sub>. Furthermore PTH acts together with 1,25(OH)<sub>2</sub>D<sub>3</sub> to increase calcium absorption from bone.



**FIG 23.1** Control of calcium metabolism. The parathyroid gland secretes PTH, which increases calcium absorption from the gastrointestinal tract, increases calcium absorption by the kidney and causes calcium resorption from the bone.

### Calcitonin (CT)

CT is secreted by the C cells of the ultimobranchial glands. In chickens, the left gland lies caudodorsal to the caudal lobe of the parathyroid gland, while the right ultimobranchial gland lies more caudally and is separate from the caudal lobe of the parathyroid gland. In chickens, the ultimobranchial glands are found in association with the parathyroid tissue; in pigeons, they are found in association with thyroid tissue.

The chromatographic profile of the biologic activity of cultured ultimobranchial glands from embryonic chickens resembles that of purified salmon CT. Furthermore, chicken and salmon CT exhibit immunological identity, which makes it possible to measure avian CT by radioimmunoassay with antibody raised against synthetic salmon CT.<sup>20</sup>

In contrast to its action in mammals, CT does not induce a hypocalcemia in normocalcemic birds. It appears, rather, to control hypercalcemia and to protect the skeleton from excessive calcium resorption.<sup>5</sup> The mode of action is through decreasing calcium resorption from bone.

### Vitamin D<sub>3</sub>

Vitamin D<sub>3</sub> (cholecalciferol) is converted from its precursor, 7-dehydrocholesterol, under the influence of ultraviolet (UV) light. It has been suggested that this process occurs in birds when the oil of the uropygial gland is spread over the feathers and irradiated by UV light before the vitamin is orally ingested during preening. The mechanism of conversion in birds that lack a uropygial gland has not been proposed. The photolysis reaction converts 7-dehydrocholesterol to pre-vitamin D<sub>3</sub>, which is in equilibrium with both its precursor and with vitamin D<sub>3</sub>. The next step occurs mainly in microsomal fractions of liver cells and is the formation of 25-hydroxycholecalciferol. The second and more important step in the activation of D<sub>3</sub> occurs in mitochondria of cells in the renal cortex, and involves the conversion to 1,25-dihydroxyvitamin D<sub>3</sub> [1,25-(OH)<sub>2</sub>D<sub>3</sub>], which is regarded as the key calcium-regulating hormone. When body demands for calcium are low, the major hydroxylation product of 25(OH)D<sub>3</sub> is 24,25(OH)<sub>2</sub>D<sub>3</sub>. There is evidence from studies in mammals that the latter inhibits the secretion of PTH.

Other hormones that stimulate the production of 1,25(OH)<sub>2</sub>D<sub>3</sub> are prolactin and estrogen.

The main role of the active metabolite of vitamin D<sub>3</sub> is to elevate plasma calcium and inorganic phosphorus by increasing small intestinal absorption of these minerals in conditions whereby the plasma concentrations of one of these minerals are too low to sup-

### CLINICAL APPLICATIONS

#### Activities of the parathyroid hormone:

- Decreased renal excretion of calcium
- Increased calcium resorption from bone
- Resorption of medullary bone (egg laying)
- Increased renal excretion of phosphate
- Increased production of active D<sub>3</sub>.

#### Activities of calcitonin and vitamin D<sub>3</sub>:

- Calcitonin decreases calcium resorption from bone.
- Vitamin D<sub>3</sub> increases intestinal absorption of calcium and phosphorous
- In conjunction with the parathyroid, vitamin D<sub>3</sub> mobilizes calcium and phosphorous from bone.



port normal mineralization of bone. Therefore, lack of vitamin D<sub>3</sub> in young birds leads to rickets. In addition, 1,25(OH)<sub>2</sub>D<sub>3</sub> acts together with PTH to mobilize calcium and phosphorus from the skeleton when hypocalcemia occurs.

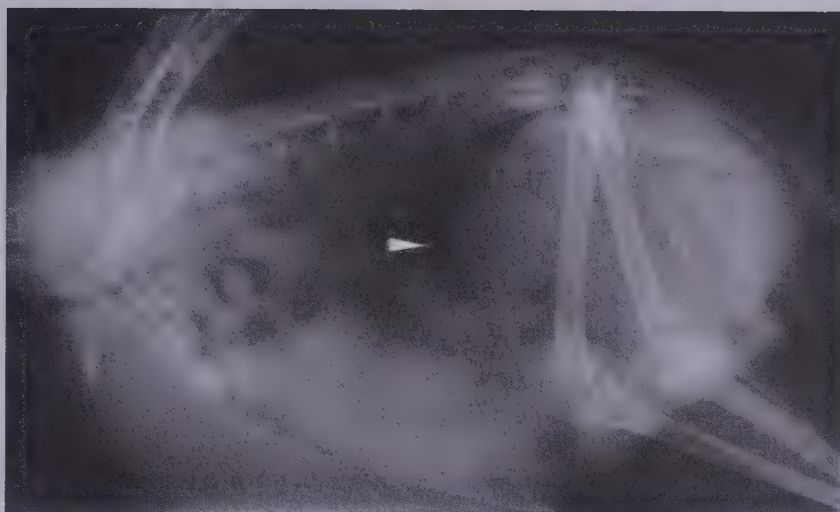
### Vitamin D<sub>2</sub>

Because ergocalciferol (vitamin D<sub>2</sub>) is more rapidly metabolized and excreted than cholecalciferol (vitamin D<sub>3</sub>), the antirachitic properties of the former are 10 to 40 times less than those of vitamin D<sub>3</sub>, despite the equal rate of initial uptake by the target tissues.

### Calcium in Reproductive Physiology

Two independent physiologic phenomena related to calcium metabolism are seen in hens during reproduction. These normal changes should not be misinterpreted as pathologic.<sup>89</sup>

- **Estrogen-induced Hypercalcemia:** About four days before female pigeons are due to ovulate, the blood calcium concentration rises from a normal value of about 2.2 mmol/l (9 mg/dl) to a value of over 5.0 mmol/l (20 mg/dl) at the time of ovulation. This rise is caused by an increase in the protein-bound calcium, secondary to the estrogen-induced transport of yolk proteins to the ovary as calcium complexes. The concentration of ionized calcium remains constant.
- **Physiologic Marrow Ossification:** During egg-laying, there is a large increase in the quantities of calcium and phosphorus that are retained from the diet and deposited in the medullary bone. This medullary bone may completely fill the marrow cavity of long bones, particularly those in the limbs (Figure 23.2). This period of bone deposition coincides with increased osteoblastic activity. When the hen starts to secrete the eggshell, the medullary bone is resorbed by osteoclastic activity. Calcium is deposited in the eggshell as calcium carbonate, and the phosphorus is excreted from the body. Normal medullary bone deposits should not be mistaken for a pathologic condition radiographically. The precise details of the hormonal mechanism by which the supplies of calcium from the gut and from the skeleton are regulated in relation to the requirements for shell formation are not fully understood.



**FIG 23.2** Lateral radiograph of a sexually mature Mexican Red-headed Amazon Parrot hen. Note the spherical mass (arrow) cranioventral to the kidneys, representing a solitary large ovarian follicle. Pre-ovulatory bone deposition is apparent in the medullary cavity of the appendicular skeleton (courtesy of Marjorie McMillan).

### Relation Between Total Calcium and Protein in Avian Plasma

The plasma calcium concentration is normally about 2.0-2.8 mmol/l (8-11.2 mg/dl), depending on the species. About one-third of plasma calcium is protein-bound and is biologically inactive. Total calcium concentration is markedly influenced by plasma protein concentrations. The ionized fraction is important with regard to deposition of calcium salts and excitability of nervous tissues. For technical reasons, most laboratories determine only total calcium. Hence, total plasma calcium should be evaluated in conjunction with plasma protein concentrations.

In man and in dogs, there are significant linear relationships between calcium and albumin, and calcium and total protein. In these species, adjustment formulas have been derived for serum total calcium on the basis of the concentrations of albumin and total protein. Recently, a significant correlation was found between total calcium and albumin concentration in the plasma of 70 healthy African Grey Parrots. Approximately 14% of the variability of calcium was attributable to the change in the concentration of plasma albumin ( $R^2=0.137$ ).<sup>59</sup> A correction formula was derived on the basis of the concentration of albumin:

$$\text{Adjusted Ca (mmol/l)} = \text{Ca (mmol/l)} - 0.015 \text{ albumin (g/l)} + 0.4$$

A significant correlation was also found between total calcium and total protein concentration in 124 plasma samples of Peregrine Falcons. About 42% of

the variability in calcium was attributable to the change in the plasma total protein concentration. The correlation between calcium and albumin was significant, but significantly smaller than the correlation between calcium and total protein. Only 11% of the plasma calcium concentration was attributable to a difference in concentration of albumin. An adjustment formula for plasma calcium concentration in the Peregrine Falcon was derived on the basis of the total protein concentration.<sup>62</sup>

$$\text{Adj. Ca (mmol/l)} = \text{Ca (mmol/l)} - 0.02 \text{ Total Protein (g/l)} + 0.67$$

Application of a correction formula in African Grey Parrots and Peregrine Falcons is indicated when extremely low or extremely high plasma protein concentrations are detected. It should be stressed that the correction formulas mentioned above are based on total protein and albumin determinations with specific analytic methods. For total protein, the biuret method is used with human protein as a standard, and albumin is calculated from total protein and plasma protein electrophoresis on cellulose acetate membranes.<sup>59a</sup>

## Diseases in Relation to the Metabolism of Calcium and Phosphorus

### Hyperparathyroidism

Hyperparathyroidism is a condition whereby there is an increased secretion of PTH. In man primary hyperparathyroidism may occur from hyperplasia, adenoma or carcinoma of the parathyroid gland. The most common presentation is a renal disorder due to recurrent renal calculi (nephrocalcinosis). The second most common presentation is bone disease (osteitis fibrosa generalisata), while the third mode of presentation is related to hypercalcemia. Pseudohyperparathyroidism is a condition characterized by hypercalcemia caused by the release of hormone-like substances from nonendocrine tumors; however, with neoplasm, hypercalcemia may also occur from widespread skeletal deposits of metastatic tumors, with associated increased osteoclastic activity. Contrary to the situation in man and domestic mammals, primary hyperparathyroidism and pseudohyperparathyroidism have not been documented in birds. Because adenoma and carcinoma of the avian parathyroid gland do occur,<sup>36</sup> it is likely that primary hyperparathyroidism will be reported in the future.

Secondary nutritional hyperparathyroidism is commonly reported in birds secondary to a calcium-deficient diet (see Chapter 3).

Diets that contain only seeds or only meat are deficient in calcium. Fruits and most vegetables are also calcium deficient. Nonetheless, many pet food retailers continue to market so-called "complete parrot foods," which consist only of seeds (mainly sunflower seeds). Affected birds have a low or normal plasma calcium concentration, a normal plasma phosphate concentration and increased AP activity. In young birds, rickets or rachitis is seen as a result of calcium-deficient diets, while in adult birds osteomalacia will occur.

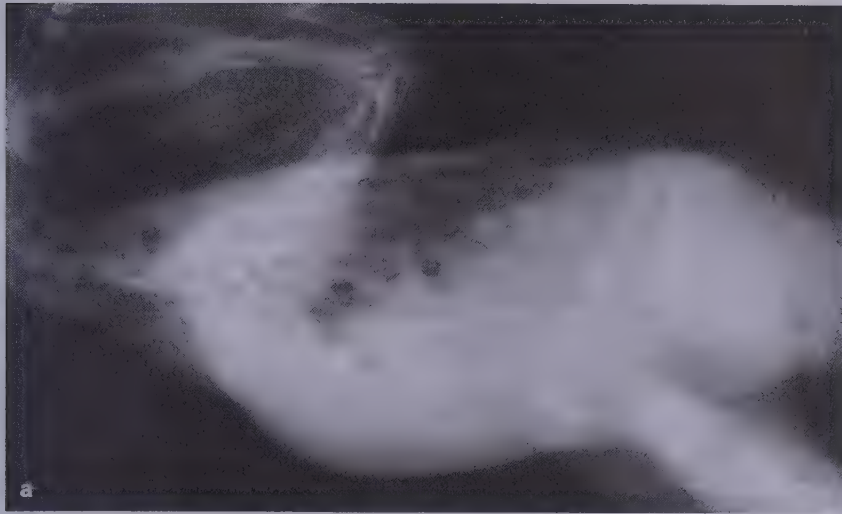
Secondary hyperparathyroidism due to a renal disorder is well known in mammals and possibly occurs also in birds. In chronic renal disease, failure of the conversion of 25-hydroxycholecalciferol to 1,25-dihydroxyvitamin D<sub>3</sub> [1,25-(OH)<sub>2</sub>D<sub>3</sub>], the key calcium-regulating hormone, will result in reduced intestinal absorption of calcium. Under these circumstances, a high plasma phosphate concentration may be seen due to decreased tubular secretion of phosphate. Plasma AP activity will be increased.

Tertiary hyperparathyroidism is known in man as a pathologic extension of the secondary form when adenomas develop in the previously hyperplastic glands and there is accompanying hypercalcemia due to autonomous PTH secretion. This condition has not been reported in birds.

### Rickets

Rickets or rachitis is a metabolically induced bone disease in growing animals. Painful deformities occur throughout the skeleton, particularly in the proximal tibiotarsus, the head of the ribs and sometimes the costochondral junction. The skeleton and the beak (rubber beak) become soft and pliable. Rickets can be caused by inadequate dietary intake of calcium, phosphorus or vitamin D<sub>3</sub> or by an improper calcium:phosphorus ratio. With calcium and vitamin D deficiencies, the resulting hypocalcemia induces enlargement of the parathyroid gland (nutritional secondary hyperparathyroidism). Consistent parathyroid gland changes are not typical with a phosphate deficiency or excessive calcium intake. Histologically, it is possible to differentiate between rickets caused by vitamin D deficiency, hypocalcemia and hypophosphatemia/calcium excess.<sup>53-55</sup>

Tachypnea and polycythemia have been observed in birds with rickets, presumably because of poor rib strength and infolding of ribs.<sup>48</sup> Affected birds died of right ventricular failure, often accompanied by ascites.



### Osteomalacia (Osteodystrophy)

In mature birds, calcium deficiencies will result in parathyroid enlargement and PTH-induced activation of osteoclastic activity, which eventually can result in complete demineralization of medullary bone, followed by cortical bone (Figure 23.3). The resorbed osseous tissue can be replaced by fibrous tissue (osteodystrophia fibrosa). The cortical bone can become so thin that spontaneous fractures may occur, especially in the vertebrae, ribs, tibiotarsus, tarsometatarsus and femur. The fractures are typical for demineralized bone and are called “greenstick fractures.” The beak becomes soft and

pliable. Plasma calcium concentrations remain generally normal until the end stage of the disease, when tetanic convulsions may be observed. Although calcium deficiencies accompanied by pathologic fractures seem relatively common in psittacine birds, nutritional osteodystrophia fibrosa is rarely diagnosed. A possible explanation might be that histologic examination of bones is not often performed.

### Osteoporosis

To a certain degree, osteoporosis (cage layer fatigue) is physiologic during egg production. Osteoporosis is characterized by the progressive reduction of bone mass. It is the most important skeletal disease in

**FIG 23.3** An adult female Amazon parrot was referred for evaluation of bilateral tibiotarsal fractures after flying into a wall. The hen had a three-year history of egg laying and had recently laid her second egg of the year. The bird appeared to have head tremors, was unable to stand and both wings were drooping. The diet consisted of a sunflower seed and peanut mix. **a,b** Radiographs indicated multiple fractures, decreased bone density and soft tissue densities in the abdomen. **c** At necropsy, the parathyroid glands were dramatically enlarged (arrow), and the abdomen was filled with flocculent debris. Histopathology indicated egg-related peritonitis, parathyroid hyperplasia and severe osteoporosis suggestive of secondary nutritional hyperparathyroidism.

chickens used for egg production and is restricted to birds kept in enclosures. Etiologic factors may be immobilization, which is a well known cause for osteoporosis in man, and marginal nutritional calcium deficiency, which can alter the physiologic osteoporosis from high egg production into severe osteoporosis with associated clinical signs. Affected birds are found paralyzed in their enclosures, and have skeletal deformities and enlarged parathyroid glands. Paralysis may be explained by spinal cord compression due to fractures in the thoracic spine and possibly by hypocalcemia, although the latter has not yet been demonstrated.

### Hypervitaminosis D<sub>3</sub>

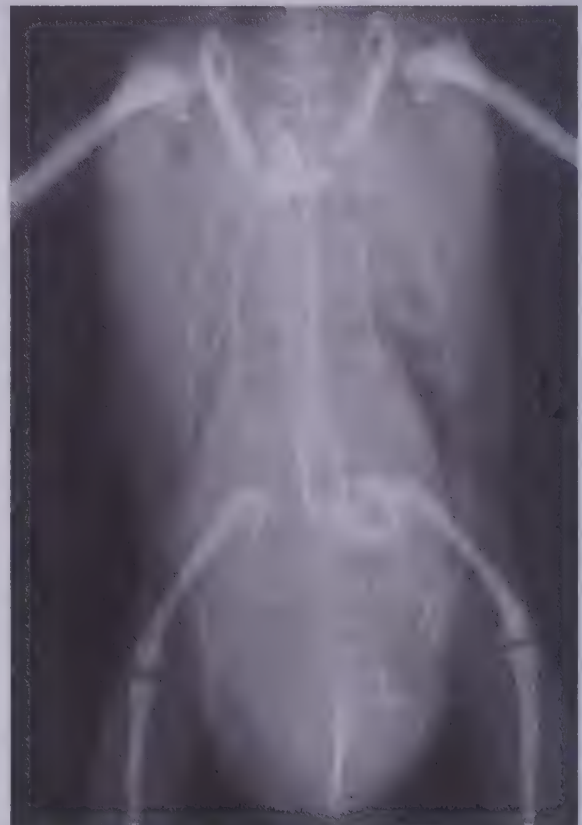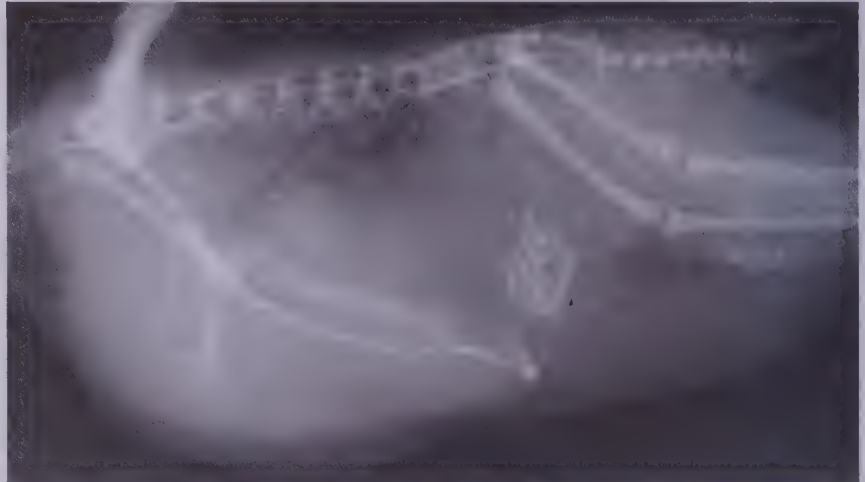
Oversupplementation of the diet with vitamin D<sub>3</sub> (>4 million IU/kg diet) causes dystrophic calcification of kidney tubules. Calcium nephropathy can also occur when birds are raised on diets containing 3% calcium instead of the normal 0.6% (see Chapters 3, 31).

### Hypocalcemia Syndrome in African Grey Parrots

Hypocalcemia characterized by seizures has been described in raptors and African Grey Parrots. A unique feature of this syndrome in African Grey Parrots is that demineralization of the skeleton to maintain normal calcium levels does not occur. Hypocalcemia is an important problem to consider in an African Grey Parrot that repeatedly falls off its perch. Administration of parenteral calcium and sufficient dietary uptake of calcium resolves clinical signs. A dietary calcium deficiency is suspected, but not confirmed as the etiologic agent. In a recent study it was shown that African Grey Parrots have significantly lower calcium, albumin and total protein concentrations compared to Amazon Parrots; however, the significantly lower mean and median values for plasma calcium in African Greys could be explained only partially by the difference in albumin-bound calcium.<sup>59</sup> The higher incidence of hypocalcemia in African Grey Parrots might therefore be associated with lower plasma concentrations of free calcium.


### Polyostotic Hyperostosis

In female budgerigars, polyostotic hyperostosis (Figure 23.4), which resembles physiologic marrow ossification is often seen in association with ovarian tumors. The condition can also be induced by stilbestrol implantation.<sup>86</sup> Physiologic marrow ossification



**FIG 23.4** Radiographs of a budgerigar hen with increased endosteal bone formation and a distended abdomen secondary to oviductal enlargement. These findings are suggestive of hyperestrogenemia (courtesy of Marjorie McMillan).

and polyostotic hyperostosis may be related, and the latter may be a pathologic exacerbation of a physiologic phenomenon caused by hyperestrogenism. Hyperestrogenism has also been associated with abdominal hernias (Figure 23.5).



**FIG 23.5** A mature budgerigar hen was presented with a progressively enlarging abdominal mass, weight loss and a reduced fecal output despite a normal appetite. Radiographs indicated polyostotic hyperostosis and an abdominal hernia suggestive of hyperestrogenemia.

## The Thyroid Glands

### Anatomy and Physiology

The thyroid glands in birds are paired organs that lie on each side of the trachea in the thoracic inlet. A connecting isthmus is absent. The thyroids are in close contact with the common carotid artery, just distal to the origin of the subclavian artery and common carotid artery from the brachiocephalic trunk (see Anatomy Overlay). Blood supply is from the cranial and caudal thyroid arteries that originate from the common carotid artery. Venous return is through the thyroid veins, which empty into the jugular vein. Except for doves and pigeons, the avian thyroid gland lacks calcitonin cells, which are located in the ultimobranchial glands.

The thyroid lobes are composed of follicles surrounded by a single layer of epithelial cells enclosed by a basement membrane. The height of the epithelial cells is dependent on the secretory rate and may vary from flat to columnar. The follicles contain a proteinaceous material called colloid, which is

mainly thyroglobulin, the storage form of the thyroid hormones.

The basement membrane is in contact with the blood vessels, while the opposite cell membrane faces the colloid. The basement membrane is the site of TSH-stimulated iodide uptake from the plasma and secretion of thyroid hormone into the plasma. The cell membrane facing the colloid is the site of thyroglobulin synthesis, oxidation and organification of iodide onto tyrosine residues of preformed thyroglobulin such as of 3-monoiodotyrosine (MIT) and 3-5-diiodotyrosine (DIT). MIT and DIT residues are coupled to form 3,5,3',-triiodo L-thyronine ( $T_3$ ) and 3,5,3',5'-tetraiodo L-thyronine (thyroxine,  $T_4$ ).

Compared to the thyroid gland in mammals, the avian thyroid produces more  $T_4$  than  $T_3$ .<sup>3</sup> It is  $T_3$  that is the principally active hormone,<sup>108</sup> produced mostly by extrathyroidal 5'-monodeiodination of  $T_4$  in liver and kidney. The activity of the 5'-monodeiodination enzyme is hormonally controlled by hypothalamic hormones (TRH, GRF) and GH.<sup>50</sup>

### Pathology

Histologic examination of the thyroid gland is a useful and reliable means of differentiating between various thyroid disorders.

In primary hypothyroidism, there is a loss of follicles resulting either from thyroiditis or atrophy, while in secondary or tertiary hypothyroidism, the thyroid follicles are distended with colloid and the lining epithelial cells become flattened. The colloid is uniformly dense with complete or nearly complete absence of resorption vacuoles at the periphery of the colloid.

In hyperthyroidism, a diffusely hyperplastic epithelium may be observed, with little or no colloid present and possibly with lymphocytic infiltration.

In endemic goiter (caused by iodine deficiency), the thyroid gland is diffusely enlarged because of cellular hyperplasia as a result of TSH stimulation. The accumulation of thyroglobulin occurs because poorly iodinated thyroglobulin is relatively resistant to digestion by endogenous proteases. Some thyroid areas may atrophy with concomitant fibrosis.<sup>44</sup>

In thyroiditis, lymphocytic infiltration is present. Lymphocytic cells are often so numerous that they dominate the microscopic structure of the gland. Secondly, there is some proliferation of thyroid epithelium.

lium. The pathologic changes result in considerable destruction of the thyroid. Lymphocytic infiltration of the thyroid gland is also a common finding with leukosis in chickens, and it may be difficult to differentiate autoimmune thyroiditis from leukosis.

Amyloidosis of the thyroid gland is characterized by amyloid deposits in interfollicular tissue and is often associated with tuberculosis or other chronic infections, especially in Anseriformes.

Normal thyroid histology is also dependent on the stage of plumage development. Increased thyroid activity can be observed in molting pigeons: the height of the thyroid epithelium increases and colloid is resorbed from the follicles.<sup>100</sup>

### Thyroid Disorders

Diseases of the thyroid gland may be accompanied by thyroid enlargement (goiter), hyperfunction or hypofunction. Functional disorders may be primary, secondary or tertiary, depending on the location of the lesion (thyroid gland, pituitary gland or hypothalamus, respectively). Only goiter has been adequately documented in birds and may be caused by neoplastic disease or by iodine deficiency. Hypothyroidism has been documented in chickens, pigeons and one parrot, and it has been suggested that hyperthyroidism may be induced by exposure to iodide-containing disinfectants. Thyroiditis occurs frequently in birds,<sup>112</sup> but clinical signs associated with this condition have not yet been reported.

### Thyroid Tumors

Thyroid neoplasia is rare in birds. Most thyroid enlargements represent thyroid hyperplasia caused by iodine deficiency. Adenomas and adenocarcinomas have been reported in budgerigars,<sup>12</sup> a Scarlet Macaw and some other birds from zoological collections (see Chapter 25).<sup>83,102</sup> Thyroid adenomas and adenocarcinomas have been reported in chickens.<sup>15,33</sup> Leukotic changes have also been documented in chickens.<sup>42</sup>

Clinical signs associated with thyroid enlargement include regurgitation and dyspnea. Like thyroid tumors in man and domestic mammals, it is to be expected that some avian thyroid tumors will have autonomic hormone production and will cause hyperthyroidism; however, no reports are available in birds.

### Goiter in Budgerigars

The most frequent clinical disease of the thyroid gland in birds is goiter in budgerigars, caused by feeding an iodine-deficient diet (usually seed mixtures).<sup>12,49,83</sup> Goiter has occasionally been seen in chickens<sup>33</sup> and other avian species,<sup>12</sup> but is a well known and distinct clinical entity in the domestic pigeon. In budgerigars with goiter, clinical changes are limited to regurgitation and dyspnea caused by gland pressure on the trachea and esophagus (see Color 19). Specific signs of hypothyroid function are absent. Circulatory problems may occur due to compression of the heart and great vessels. The size of the glands can exceed 10 mm compared to a normal size of about 2 mm, while the weight can show a 100-fold increase (normal weight = 3 mg). If the glands are cystic they may weigh 1000 mg and be palpable at the thoracic inlet. Radiographically, a dorsal or ventral displacement of the trachea may be visible.

Goiter can be prevented by placing a bird on a complete formulated diet. The dietary requirement of iodine is about 20 µg per week for a 35 g budgerigar. Affected animals can be treated with a 0.3% Lugol's solution in the drinking water (1 drop per 20 ml water): first week, daily; second week, three times a week; then once weekly.

### Goiter in Domestic Pigeons

Goiter can occur in domestic pigeons on an iodine-deficient diet. Certain breeds (eg, White Carneaux) are more susceptible than others.<sup>44</sup> Soybeans and fat-rich corns (like maize) may increase the iodine demand

## CLINICAL APPLICATIONS

### Clinical findings of thyroid enlargement in budgerigars

- Obesity
- Regurgitation
- Dyspnea
- Dorsal displacement of trachea (radiographs)
- Ventral displacement of trachea (radiographs)
- Circulatory problems

### Clinical findings of goiter in pigeons

- Lethargy
- Obesity
- Palpable mass (thoracic inlet)
- Reduced fertility
- Reduced hatching rate
- Unhealthy squabs
- Myxedema
- Dystrophic feathers

and potentiate goiter.<sup>99</sup> Clinical signs in adult pigeons are different from those in budgerigars and include lethargy, obesity and a palpable thyroid gland in the thoracic inlet. Affected birds show a reduced fertility, reduced hatchability and reduced viability of squabs. Signs of hypothyroidism may include a puffy appearance of the facial skin (myxedema) and abnormal feather development. Tail and wing feathers that are too long and narrow or structural defects in the contour feathers may give the bird a ruffled appearance and an irregular or failing molt. Dyspnea accompanied by a respiratory stridor occurs only in severe cases. Although supporting data is not available clinical signs suggest that contrary to the situation in budgerigars, iodine-deficient goiter in White Carneaux Pigeons is accompanied by hypothyroidism.


### Hypothyroidism

Primary hypothyroidism is a well recognized disorder in birds. In chickens, it occurs as a hereditary autoimmune disorder.<sup>18,92</sup> Low levels of thyroid hormones have also been associated with a malabsorption syndrome.<sup>77</sup> Experimentally induced hypothyroidism is associated with growth retardation, mental retardation and defective plumage development (fringed and elongated feathers with loss of barbules and color). Chickens with genetic hypothyroidism have low  $T_4$  concentrations, obesity, rather silky plumage, delayed sexual development or delayed maturity (Figure 23.6).<sup>17</sup>

In man and dogs, various non-thyroidal illnesses have been shown to favor the formation of  $T_3$  to protect the body from the catabolic state that accompanies many of these diseases. This phenomenon has been designated the "low  $T_3$  syndrome," though affected subjects remain euthyroidic.<sup>52</sup> The same mechanism seems likely in birds.<sup>23</sup> For this reason, measurement of plasma  $T_3$  is of doubtful value for the diagnosis of primary hypothyroidism and could even lead to false conclusions. The measurement of  $T_4$  would seem to be the most logical choice for evaluating birds; however, even plasma  $T_4$  concentrations can be influenced by drugs, handling, bleeding,<sup>107</sup> food intake, environmental temperature,<sup>108</sup> increased plasma corticosterone concentration<sup>23</sup> and infections with *Eimeria maxima*.<sup>22</sup> Normal plasma  $T_4$  concentrations in birds are about one-fifth to one-tenth those characteristic for mammals.<sup>50</sup> In many birds, resting plasma thyroxine concentrations are below the detection limit of the assay.<sup>110</sup>

Thyroid abnormalities have been frequently reported as a common cause of disease in companion and aviary birds; however, the only support for these statements has been a low plasma  $T_4$  when compared with a reference interval established in a single random blood sample.<sup>75,76</sup> Reports of hypothyroidism are therefore questionable at best (Figure 23.7). Documentation that a low plasma  $T_4$  level is caused by primary hypothyroidism requires a TSH stimulation test to rule out other causes for a decreased  $T_4$  concentration.

A TSH test has been reported for chickens,<sup>107</sup> Psittaciformes<sup>56,110</sup> and racing pigeons.<sup>63</sup> Low  $T_4$  levels were documented in a Hyacinth Macaw that responded to L-thyroxine therapy. For evaluation of thyroid function in racing pigeons, blood samples should be collected before and between 4 and 24 hours after administration of 0.1 IU of TSH.<sup>a</sup> If a dose of 1 IU per pigeon is used, samples can be collected up to 32 hours later. In healthy individuals, at least a 2.5-fold increase will be observed over basal  $T_4$  concentrations using these doses and sampling times.<sup>63</sup> The TSH stimulation test can also be used in other avian species using 1 IU/kg. A diagnosis of hypothyroidism should not be based on low baseline thyroxine concentrations or on a "favorable response to administration of thyroxine."<sup>71-75</sup> A diagnosis is based on suggestive clinical signs, especially defective plumage development, in conjunction with failure to respond to TSH.



**FIG 23.6** A mature, obese Amazon parrot was presented with an asymmetric, ulcerative periabdominal mass. Biopsy indicated a lipoma. Obesity and lipoma formation are frequently discussed as signs of hypothyroidism in companion birds; however, affected birds can rarely be shown to have hypothyroidism by determination of  $T_4$  levels following TSH stimulation. Thyroxine supplementation should be used only in birds with documented cases of hypothyroidism (courtesy of Tom Tully).

If secondary and tertiary hypothyroidism occur in birds, these disorders can probably be diagnosed by performing stimulation tests with both TRH and TSH and by measuring of plasma TSH and thyroxine concentrations.

### Hyperthyroidism

Hyperthyroidism or thyrotoxicosis results from over-secretion of thyroid hormones. It is clinically characterized by an increased metabolic rate. In man, it may result from diffuse hyperactivity of the gland (Graves' disease) or as a result of a single hyperplastic nodule (toxic adenoma). Rarer causes are increased TSH secretion from the pituitary gland, ectopic TSH producing tumors, metastatic thyroid carcinoma and ovarian teratoma containing thyroid tissue. The administration of iodides may also induce hyperthyroidism (Jod-Basedow phenomenon), but in these cases the gland is already abnormal.

Two Fairy Blue Penguins developed signs of hyperirritability after the use of iodide-containing disinfectants, and the disease was classified under the term hyperthyroidism.<sup>37,78,79</sup> The histology of the thyroid glands of the affected birds, however, was that of colloid goiter (large follicles with flattened epithelium). Furthermore, it is not likely that excessive amounts of iodide will induce hyperthyroidism. Ex-



**FIG 23.7** An adult Blue and Gold Macaw was evaluated for a chronic feathering problem that had been diagnosed as hypothyroidism. The bird was on an all-seed diet and was restricted to a dark corner of the house. The bird had numerous pin feathers and thin, poorly formed mature feathers. Clinicopathologic, radiographic and TSH stimulation findings were within normal limits. The bird responded to a change in diet and daily exposure to unfiltered sunlight.

posure to excessive amounts of iodide paradoxically may lead to goiter or even hypothyroidism. In normal humans, a small but significant decrease in thyroid hormones with a compensatory rise in serum TSH concentration occurred after excessive dietary intake of iodine. This suggests that the inhibitory effects of iodides on the serum concentrations of the thyroid hormones are probably partially overcome by the increased TSH secretion. Iodide-induced goiter, hypothyroidism or both in subjects with normal underlying thyroid function is uncommon. Most patients who develop disease have received large quantities of iodides for a long period of time.<sup>13</sup> In the author's opinion, the affected penguins should be classified as "iodide goiter" and not "hyperthyroidism."

### Thyroiditis

Various forms of thyroiditis have been described in man. Etiologies include pyogenic organisms, viruses and autoimmune phenomena (Hashimoto's thyroiditis). Clinical signs are variable and may be associated with goiter hyper- or hypothyroidism. Thyroiditis was reported in a large variety of avian species, including an Amazon parrot. At necropsy, 36.9% of avian thyroid lesions were of an inflammatory nature.<sup>112</sup>

In an obese strain (OS) of chickens, circulating thyroglobulin autoantibodies have been shown to be the cause of spontaneous thyroiditis accompanied by hypothyroidism.<sup>17,18</sup> Clinical signs included obesity, silky plumage, delayed sexual development or lack of maturity, thyroid glands that were either smaller or larger than normal and low plasma thyroxine concentrations. Another line of chickens (described as delayed amelanotic, DAM) with similar thyroid abnormalities has been reported.<sup>92</sup> Neonatal bursectomy decreased the incidence and severity of chronic thyroiditis in OS and DAM line chickens.<sup>51</sup> Because neonatal bursectomy, and not thymectomy, prevents the occurrence of the disease, it is likely that the disease is caused by an immunologic response to free particulate fractions of thyroid rather than by antibodies that react with thyroglobulin.<sup>25</sup>

### The Use of Thyroid Hormone in Non-thyroidal Disorders

Thyroid hormone has been frequently recommended for the treatment of obesity in birds. However, no controlled studies have been performed to demonstrate the effectiveness of this treatment. Most studies with physiologic doses of thyroid hormone in man have failed to show any significant effect on weight



reduction. Physiologic replacement of thyroid hormone in a euthyroid individual is compensated for by suppression of the hypothalamic-pituitary-thyroid axis with no net hormonal effect. Pharmacologic doses of thyroid hormone sufficient to raise the basal metabolic rate to a hypermetabolic state undoubtedly result in increased weight loss. If caloric intake is not carefully controlled, however, predominantly fat-free tissue may be lost during treatment. The weight loss may be readily and rapidly reversed after discontinuation of therapy.

The occurrence of toxic effects is unavoidable when pharmacologic doses of thyroid hormone are used. In man, cardiovascular complications were seen in 20% of patients treated with pharmacologic doses. In obese birds without proven hypothyroidism, thyroid hormone therapy can be dangerous and should not be used in lieu of providing a well balanced diet and adequate exercise.

Thyroid hormone can induce molt in a number of species. The molt is more pronounced after administration of a single dose compared with daily administration of small doses equal to the sum of the single dose. A decreasing sensitivity to thyroxine-induced molt is seen in guinea fowl, pigeons, gallinaceous birds, waterbirds, Passeriformes and birds of prey. A number of members of the latter orders either do not molt in response to excess thyroid hormone or show only slight molting of small feathers in response to large or even sublethal doses of the hormone.

## The Adrenal Glands

### Anatomy and Physiology

The right and left avian adrenal glands are yellow organs located craniomedial to the kidneys (see Color 21). The glands receive blood from branches of the renal artery, while the adrenal veins drain into the caudal vena cava. The microanatomy of the avian adrenal gland differs from that of mammals in that the avian adrenal gland is not clearly divided into an outer cortex and inner medulla. In birds, cortical and chromaffin tissue are intermingled. Chromaffin tissue accounts for about 25% of adrenal tissue and can be divided by means of cytochemistry into two types

of chromaffin cells: those releasing epinephrine and those releasing norepinephrine.

Cortical or interrenal cells are arranged in numerous cords composed of a double row of cells. The cords radiate from the center of the gland and loop against the inner surface of the connective tissue capsule. The arrangement of specific cell types along the cords results in some structural zonation with two zones: a subcapsular zone that produces aldosterone and a more extensive inner zone that produces corticosterone. The zonation is the most distinct when corticotrophic stimulation is suppressed or enhanced. The major function of the avian adrenal cortical cells is to produce glucocorticoid and mineralocorticoid hormones, of which corticosterone is the most important corticoid hormone in birds. Aldosterone production is considerably less.

In avian embryos, other corticosteroids like cortisol and cortisone are also synthesized. These compounds decrease in concentration around hatch and are absent in the adrenals of chickens and ducks older than two weeks.<sup>68,96</sup> The embryonic avian adrenal gland is also a site of sex steroid synthesis.<sup>96</sup> The secretion of corticosterone is regulated by ACTH, which is released from the corticomedullary cells from the cephalic lobe of the adenohypophysis in response to hypothalamic CRF. Glucocorticoids exert a negative feedback at the level of the hypothalamus and hypophysis. The hypothalamic-hypophyseal adrenal (HPA) axis has been reviewed by Bayle.<sup>7</sup>

Corticosterone is essential for survival in times of stress and regulates intermediary metabolism and hemodynamic functions. It also has mineralocorticoid activity. Corticosterone balances the production and action of biologically active substances produced during stress (ie, catecholamines, prostaglandins). If left unchecked, the stress-induced release of these compounds would lead to shock. Plasma corticosterone concentrations can reliably be determined using an RIA.

In free-ranging Mallard Ducks living in coastal estuaries and alkaline lake environments, corticosterone functions as an important mineral-regulating hormone. Under these circumstances, it acts simultaneously on three target organs: the small intestine, the nasal salt glands and the kidney. A specific increase in extracellular sodium concentration, an increase in the concentration of an associated anion or an increase in extracellular osmolality activates the hypophysiotropic reflex to cause a release of ACTH.<sup>45,97</sup>

This response is in marked contrast to that seen in birds that do not possess functional nasal glands and cannot tolerate hyperosmotic drinking water. In these birds, like in most mammals, glucocorticoids do not function as mineral-regulating hormones and sodium does not act as a secretagogue for ACTH release.

The regulation of aldosterone secretion in birds and mammals is probably similar. Renin is released from the juxtaglomerular cells of the kidney in response to low plasma sodium concentration or reduced blood volume. The renin acts on circulating angiotensinogen to form angiotensin I, which is converted to angiotensin II. Aldosterone secretion is stimulated by angiotensin II. Angiotensin II appears to stimulate aldosterone synthesis by acting directly on the steroidogenic cells rather than by stimulating the release of ACTH from the adenohypophysis.<sup>45</sup> In contrast to mammals, birds do not release aldosterone in response to elevated extracellular potassium concentrations.<sup>45</sup>

Angiotensin II has been shown to be a potent diuretic in a variety of birds. However, carnivorous birds that ingest most of their water requirement with food, show a much lower sensitivity to angiotensinogen II. In quail, daily water consumption parallels a pattern of change in plasma angiotensin II. Furthermore, the inhibition of endogenous angiotensin II by captopril or by the receptor antagonist Saralasin, decreases natural water intake in quail. In the xerophilous budgerigar, daily patterns of water intake and plasma concentrations of angiotensin II are not parallel.<sup>95</sup>

### ■ Adrenocortical Disorders

Both over- and underproduction of either glucocorticoid (Cushing's syndrome and Addison's disease, respectively) or mineralocorticoid hormones (aldosteronism and hypoaldosteronism) have been reported in man and domestic animals. Although adrenal lesions have been described on postmortem examinations in a high percentage of birds (27% in one study involving psittacine birds), a clinical diagnosis of spontaneous adrenal disease has never been documented. The use of the ACTH stimulation test, dexamethasone screening test and dexamethasone suppression test as reported for dogs<sup>26</sup> should prove useful for the diagnosis of both hypoadrenocorticism and hyperadrenocorticism in birds. The optimal dose for ACTH and sampling times for determination of plasma cor-

ticosterone (not cortisol) concentrations have been established for a number of avian species.

#### Hyperadrenocorticism (Cushing's syndrome)

Spontaneous hyperadrenocorticism has not been reported in birds, but the effects of exogenous glucocorticoids have been well documented. In man and domestic mammals, Cushing's syndrome occurs most commonly in patients receiving glucocorticoids. Hyperadrenocorticism can occur as a result of a primary tumor of the adrenal gland, a pituitary tumor that hypersecretes ACTH, or ectopic ACTH secretion from a nonpituitary tumor. Both of the latter conditions induce bilateral adrenocortical hyperplasia due to continuous ACTH secretion.

Pituitary and adrenal tumors have been reported in birds, and it is not unlikely that a number of these patients were in fact suffering from hyperadrenocorticism. The following conditions have been reported: bilateral adrenal adenoma and adrenal cortical hyperplasia in budgerigar,<sup>8</sup> unilateral adrenal adenoma in a budgerigar,<sup>12</sup> unilateral adrenocortical carcinoma in a pigeon,<sup>33</sup> adrenal carcinoma with metastasis in the liver,<sup>12</sup> and adrenal gland neoplasia in a variety of avian species.<sup>39</sup> An adrenal cortical tumor in an 18-month-old leghorn hen with marked signs of virilism was reported<sup>15</sup> as well as an adrenal cortical adenoma.<sup>16</sup>

Furthermore, a number of stressful situations can increase adrenal size as a result of continuous stimulation by ACTH. Heterotopic adrenal tissue may occur in the ovary, and both cortical and medullary tumors have been tentatively identified in this site.<sup>15</sup>

#### Hypoadrenocorticism

Adrenalectomy in birds results in renal loss of NaCl and death from hyponatremia and hyperkalemia. Affected birds can be maintained with high NaCl intake or corticosterone injections.

In dogs, the ACTH-stimulation test is used to evaluate adrenocortical function. In adrenocortical insufficiency, administration of ACTH will not lead to an increase in plasma cortisol, while in hyperadrenocorticism, an exaggerated response may be seen. In all avian species studied, corticosterone, and not cortisol, is considered to be the major glucocorticoid; therefore, cortisol is not a valid parameter to evaluate adrenocortical function in birds.

It has been demonstrated that Mallard Ducks consuming petroleum-contaminated food (South Louisiana crude oil) developed structural damage to the

mitochondria of the inner zone cells in the adrenal cortex and had decreased circulating corticosterone concentrations.<sup>32</sup> Adrenocortical testing procedures using corticosterone have been reported in Psittaciformes,<sup>57,104,110</sup> raptors<sup>111</sup> and pigeons.<sup>60</sup> In pigeons, ACTH testing was accomplished by taking blood samples before and at 60 or 90 minutes after stimulation with 50 µg of ACTH<sup>b</sup> or at 30, 60, 90 or 120 minutes after stimulation with 125 µg of ACTH. In healthy individuals, a 10- to 100-fold increase over baseline corticosterone concentrations and absolute concentrations in the range of 2.2 to 15 µg/dl should be considered normal for post-stimulation samples.

### The Use of Corticosteroids in Non-endocrine Disease

Glucocorticoids are widely used in human and veterinary medicine for their beneficial effects in a wide variety of diseases, especially those in which inflammation is severe or in which immunologic-induced disease is involved. Occasionally, glucocorticoids are used to reduce hypercalcemia induced by certain types of neoplasms (renal excretion is increased and intestinal absorption reduced). The adverse effects of glucocorticoids should always be considered before they are administered. The clinician has to consider whether the disease is serious enough to warrant long-term glucocorticosteroid therapy.

The majority of knowledge on the effects of corticosteroids on immunity is derived from experimental work on small rodents and rabbits, although some work has also been performed in birds. In mammals the antibody-forming cells ("bone marrow-derived" or "bursa-equivalent" [B-] lymphocytes and plasma cells) are relatively resistant to the suppressive effects of these agents, while thymic-derived (T-) lymphocytes, and therefore cell mediated immunity, are affected.

Pharmacologic concentrations of corticosterone in birds can cause involution of the cloacal bursa, thymus and spleen, resulting in suppression of both humoral and cell-mediated immunity.<sup>35</sup> Corticosterone in the diet causes a dose-dependent lymphopenia in chickens and an increase in susceptibility to viral infections.<sup>35</sup> A single intramuscular injection of dexamethasone or prednisolone in racing pigeons was found to cause lymphopenia.<sup>34</sup> Lymphopenia occurs within a day after glucocorticoid administration,<sup>35</sup> but leukocyte numbers apparently recover.<sup>21</sup> There is a proportional increase in granulocytes that occurs with the lymphopenia. It has been suggested that this may increase the resistance to bacterial infec-

tions through enhanced phagocytosis.<sup>21,35</sup> However, studies in mammals have shown that corticosteroids inhibit neutrophil, macrophage and monocyte migration, chemotaxis, diapedesis, interferon production, processing of antigens, phagocytosis and intracellular killing.<sup>6,27,65</sup>

In man, monocytes are more sensitive to functional suppression by steroids than neutrophils, which may impact the formation of granulomas. Granulomatous hypersensitivity diseases are responsive to glucocorticoid therapy, while tuberculosis and certain fungal diseases associated with granuloma formation are prone to exacerbation and relapse following glucocorticoid therapy. Stress-related aspergillosis is common in oil-contaminated waterfowl.<sup>30,31,87</sup> Aspergillosis has been observed in racing pigeons and budgerigars as a complication of long-term administration of glucocorticosteroids (Westerhof I, unpublished).<sup>84</sup> Aspergillosis in recently captured free-ranging birds may be related to stress-induced hypercorticism with associated suppression of monocyte function (Figure 23.8).

A dose-dependent increase in the excretion of coccidial oocysts can be observed after administration of dexamethasone in infected pigeons.<sup>38</sup>

### Glucocorticoids (Corticosteroids)

The anti-inflammatory activities of therapeutically used glucocorticoids (Table 23.1) have been assessed in mammals.<sup>4</sup>

Appropriate dosages for glucocorticoids in birds have not been fully established and are currently being investigated. Dosage guidelines are based on data in mammals.

TABLE 23.1 Activity of Glucocorticosteroids Used in Mammals

Glucocorticoid	Equivalent Dose (mg) Based on Anti-inflammatory Potency	Mineralocorticoid Potency
Cortisone	25	2+
Hydrocortisone (cortisol)	20	2+
Prednisone	5	1+
Prednisolone	5	1+
Methylprednisolone	4	0
Triamcinolone	4	0
Flumethasone	1.5	0
Dexamethasone	0.75	0
Betamethasone	0.6	0

Mineralocorticoid activity is an undesired side-effect in some glucocorticoid drugs. Cortisone and cortisol (hydrocortisone) have the highest mineralocorticoid activity and are the corticosteroids of choice for replacement therapy after adrenalectomy or in (iatrogenic) hypoadrenocorticism. Supplemental administration of the mineralocorticoid, fludrocortisone, is suggested in these cases.

The cortisol dosage for replacement therapy is about 0.5-1 mg/kg daily. Cortisol is also indicated when stressful procedures are undertaken in patients who have been receiving long-term treatment with corticosteroids and are suffering from iatrogenic secondary hypoadrenocorticism or iatrogenic hyperadrenocorticism-like disease.


Prednisolone is the agent of choice for anti-inflammatory immunosuppression and antineoplastic therapy to reduce the severity of negative feedback at the hypothalamus-hypophyseal level. Anti-inflammatory doses of prednisolone are 0.5-1.0 mg/kg. Immunosuppressive and chemotherapeutic doses are 2-4 mg/kg prednisolone daily. Corticosteroids are used as chemotherapy for lymphoreticular neoplasia because of their antimitotic effects on lymphoid tissue.

Dexamethasone is the steroid of choice for reducing cerebrospinal edema. Dosages used in mammals are 2 mg/kg TID until improvement occurs.

Cortisone and prednisone must be metabolized in the liver to form cortisol (hydrocortisone) and prednisolone, respectively. Therefore, prednisone and cortisone are not effective when applied topically.

In clinical situations where long-term glucocorticoid therapy is indicated, appropriate consideration should be given to exacerbations of subclinical infections (eg, viral, bacterial, mycotic or parasitic) or induction of iatrogenic secondary hypoadrenocorticism or iatrogenic hyperadrenocorticism-like disease. Local corticosteroid therapy should be considered in ophthalmic and dermatologic conditions, and alternate-day therapy should be considered in long-term systemic corticosteroid therapy to reduce these side-effects. However, the clinician should be aware that high or even toxic blood levels of steroids can occur following topical application.

With daily glucocorticosteroid therapy, short-acting agents are used to simulate the normal physiologic corticosterone cycle. Short-acting glucocorticosteroids are administered in man in the morning when endogenous glucocorticoid concentrations are high-



**FIG 23.8** A mature Moluccan Cockatoo male was presented for feather dystrophy and progressive inspiratory dyspnea of several weeks' duration. Endoscopy of the trachea revealed a proliferative mass occluding the majority of the lumen. The bird was euthanized. At necropsy, an aspergilloma was detected in the mid-cervical area of the trachea. The only other gross lesion was bilateral adrenal hypertrophy (three to four times normal size) suggestive of chronic stimulation by ACTH. Blood collected from the bird during the initial evaluation was positive for PBFV virus by DNA probe testing.

est. This induces the most profound negative feedback on ACTH secretion. Low levels late at night release the pituitary from feedback inhibition and permit secretion of ACTH. When the same total amount of glucocorticosteroids is given in divided doses, a greater incidence of complications, particularly suppression of the HPA axis, is to be expected. A nocturnal rise in plasma corticosterone concentrations has been demonstrated in pigeons<sup>47</sup> and chickens,<sup>9</sup> with the acrophase towards the end of the scotoperiod, which is suggestive of an increase of the secretion of corticotrophin (ACTH) at night. There is, however, some controversy about the exact timing of the acrophase in chickens.<sup>28</sup> Considering these findings, it seems logical to administer glucocorticoids in the morning hours in diurnal birds. The situation might be reversed in nocturnal birds.

Corticosteroid therapy in severe inflammatory diseases is best divided into several doses through the day. Once the desired effects are reached, the regimen should be tapered down to the least toxic dose. The divided daily dose is given in a single daily dose in the morning and gradually decreased to the minimal effective dose. Whenever glucocorticosteroid therapy has to be given for periods over two weeks, alternate-day therapy should be considered. The daily dose is doubled and given every other day, while, the dose on the "off" day is gradually decreased to zero. The use of nonsteroidal anti-inflammatory drugs can be used on the "off" days during the tapering period.

Whenever long-term glucocorticoid therapy is discontinued, gradual tapering of glucocorticoid dosage is indicated.

### Iatrogenic Hyperadrenocorticism-like Disease

Exogenous glucocorticoids cause hyperphagia while reducing growth and body weight in birds. There is a marked increase in fat deposition (lipogenesis) and a concomitant increase in protein catabolism. Cholesterol levels increase, and true lipemic conditions may develop as a result of glucocorticoid injections. Furthermore, gluconeogenesis is increased (production of blood glucose at the expense of muscle and adipose tissue) and hence plasma glucose concentrations are elevated. Steroid diabetes may be induced with accompanying glucosuria. Hepatic glycogen is increased. Calcium absorption from the intestinal tract is reduced after administration of betamethasone and cortisol. Corticosterone increases the glomerular filtration rate which, together with glucosuria, may be recognized as polyuria and polydipsia.

### Iatrogenic Secondary Hypoadrenocorticism

Glucocorticoids exert a negative feedback influence at the hypothalamo-hypophyseal level and suppress basal and stress-induced corticosterone release. Failure of the adrenal gland to respond to stress factors may result in adrenocortical insufficiency. Many stressors are known to induce corticosterone secretion in birds: extreme environmental temperatures, handling, immobilization, anesthesia, infection, frustration, fear, housing, noise, food and water deprivation and hypovitaminosis A. Adrenocortical failure and shock may occur in birds exposed to one or more stressful situation following iatrogenic glucocorticoid administration. Sustained suppression of the HPA axis is common in human patients who have received the equivalent of 30 mg prednisone per day for more than one week. Exposure to high doses over a prolonged period of time may lead to HPA axis suppression for up to one year. It has been shown in pigeons that short-term, high-dose glucocorticoid therapy produces only transient suppression of the HPA axis (Westerhof I, unpublished). An ACTH stimulation test can be performed to evaluate the integrity of the HPA axis. Replacement therapy is indicated in stressed birds with hypoadrenocorticism.

### Stress Marks

A common disorder of developing feathers is the symmetrical development of stress marks or hunger traces. These represent a segmental dysplasia in the barbs and barbules. Stress lines can be easily identified by holding the spread wing or tail feathers

against a light and looking for bilateral symmetrical lines perpendicular to the feather shaft (see Color 24). These lesions represent a period of malnutrition or stress while the feathers were developing. They can also be induced by a single injection of a glucocorticoid. Administration of glucocorticoids strongly suppresses growth and increases protein catabolism,<sup>24</sup> and these lesions probably reflect a short period of decreased amino acid available to the developing feather. Chronic malnutrition and chronic stress in birds with developing feathers will result in more severely affected feathers.

## Adrenomedullary Disorders

### Pheochromocytoma (Chromaffinoma)

A benign or malignant tumor of chromaffin tissue may cause hypersecretion of epinephrine or norepinephrine, which in man is known to lead to hypertension and associated symptoms such as profuse sweating and cardiac irregularities. A pheochromocytoma of the adrenal gland in a 14-week-old broiler pullet has been reported.<sup>15</sup> The bird died suddenly. The only obvious abnormality was an enlarged left adrenal gland measuring 15 mm in diameter.

## Endocrine Control of Feather Formation

A basic knowledge of endocrine control of feather formation should direct the clinician away from using endocrine abnormalities as a repository for disturbances in feather formation of unknown etiology. Three basic factors have been discussed in feather formation: the feather-forming tissue itself, the neurohumoral factors in the absence of which the feather-forming tissue is unable to fulfill its specific morphogenetic function, and finally the environmental factors, especially the variation in daylight length, which controls the neurohumoral factors.<sup>100</sup> Neural control of feather formation has been demonstrated by growth retardation of feathers when denervation occurs. The metabolic processes that underlie feather formation are regulated by the thyroid and the gonads.

The development of embryonic, juvenile and adult plumage has three phases: the production of germ

cells, their proliferation and development and the renewal of feathers. The first phase can occur in the absence of thyroid hormone. The presence of thyroid hormone, however, is essential for the growth, differentiation of structure and formation of feather pattern. The importance of thyroid hormone for feather formation is generally similar in young and mature birds. In some birds, this thyroid dependence affects the rate of feather growth and formation of vane structure and in others, it affects the pigmentation and development of feather pattern.

In thyroidectomized birds, the lower parts of the feather are underdeveloped, while in hyperthyroidism, these parts develop most vigorously. In hypothyroidism, the vanes of the feathers are narrower and there is a partial reduction of the barbs. In a number of fowl breeds, hypothyroidism is accompanied by partial or complete replacement of black eumelanin by brown pheomelanin, while in hyperthyroidism eumelanin pigmentation is enhanced. The black pigment can be formed in the bird's body at only a certain concentration of thyroid hormone.

Molting is possible only as the result of complex hormonal influences. Molting occurs during a period of depressed sexual activity. It can be suppressed by sex hormones or induced by administration of progesterone (see Chapter 24).

When the duration of light is decreased, or a long period of artificial daylight is suddenly replaced by a short one, sexual activity declines or ceases and molting begins. Numerous experiments in birds of various species have provided similar results. Short periods of daily light associated with declining sexual activity are needed for the proliferation of feather germ cells and renewal of plumage. Sudden transition to darkness after prolonged exposure to lengthened periods of daily light produces vigorous molting in various birds.

It should be remembered that many avian species must be exposed to natural photoperiods to allow a normal hypothalamic-pituitary control of the molting process. Improper photoperiods may be an important cause of feathering disorders in companion birds kept indoors. Additionally, normal feather development requires that appropriate nutrients for feather development are available in appropriate quantities.

An increase in thyroid gland activity during molting does not cause molting but rather is a response to the body's increased requirements of thyroid hormone in connection with the development of new feathers.

However, thyroid hormone administration in some species will accelerate the molting process.

In some birds (eg, Galliformes, Passeriformes, Anseriformes), feather color and pattern vary with the age, gender and season, and these characteristics are governed by hormonal influences of the gonads. In these birds, the adult plumage, unlike the juvenile plumage, develops under the influence of at least two endocrine glands. In contrast, the plumage of Fringillidae may or may not differ by gender. In these birds the plumage does not change under influence of plasma concentrations of sex hormones but is governed by the autosome: sex chromosome ratio and cannot be overridden by hormonal imbalance. The influence of sex hormone in the former group in each feather-forming process is realized only at a definitive level of metabolism that is maintained by thyroid hormone (female plumage does not develop in thyroidectomized birds given estrogen). When the bird is adequately saturated with thyroid and sex hormones, the feathers that develop should be termed the thyro-sexual type. Under conditions of hypothyroidism or athyreosis, the feathers that develop are uniform in structure and should be termed the athyreoid type of plumage (and consequently also asexual, juvenile type).

The male plumage is potentially an attribute of both genders, and the female hormones play the principal role in gender differences in the plumage of Galliformes and Anseriformes. When a rooster, drake or cock pheasant is castrated, no changes are produced in the pattern of its plumage. Neutered females, however, develop male-type plumage after molting. When a castrated rooster or a neutered hen undergoes an ovarian transplant, female-type plumage develops.

## Diabetes Mellitus

---

---

Spontaneous diabetes mellitus has been reported in a variety of granivorous avian species, including the domestic pigeon. One case of spontaneous diabetes mellitus has been reported in a raptor.<sup>103</sup> Budgerigars and cockatiels frequently develop diabetes mellitus. The most striking clinical signs are PU/PD and loss of weight despite a good appetite. A tentative diagnosis can be made by demonstrating glucosuria while a

definitive diagnosis can be made by finding persistent hyperglycemia.

There are some striking differences between birds and mammals with respect to pancreatic control of carbohydrate metabolism. The insulin content of the pancreas of granivorous birds is about one-sixth that of mammalian pancreata, while the glucagon content is about two to five times greater. Circulating plasma concentrations of glucagon are 10 to 50 times higher in birds than in mammals. In mammals, pancreatectomy results in diabetes mellitus. Reported effects of pancreatectomy in birds are controversial. However, recent experiments performed on granivorous birds indicate that surgical extirpation or destruction of the pancreas with cytotoxic agents leads to hypoglycemic crisis and death. The few reported pancreatectomies performed on carnivorous birds have always led to diabetes mellitus.

It is generally accepted that glucagon is more effective in granivorous birds, which exhibit a marked insulin insensitivity. The limited data available on spontaneous diabetes mellitus in granivorous birds suggest that in these species diabetes mellitus is not caused by an insulin deficiency. Birds of prey may be more insulin-dependent than granivorous birds.<sup>103</sup>

There are several case reports of successful treatment of spontaneous diabetes mellitus in birds with daily injections of insulin using dosages comparable to those used in dogs. These reported "successful treatments" of diabetic birds (disappearance of clinical signs) are surprising, considering the relative insulin insensitivity that has been reported to occur in a variety of avian species.

Plasma insulin and glucagon concentrations have been established in three birds with hyperglycemia.<sup>58</sup> It is not clear whether these determinations were accurate. In all cases, insulin concentrations were similar to controls. Glucagon concentrations on the other hand were extremely high or extremely low. This suggests that the hyperglycemia may have been from varying etiologies.

When speculating on causes of diabetes mellitus in birds, the possible role of the diabetogenic hormones should be considered. Glucocorticoids, epinephrine, glucagon and growth hormone can all induce hyperglycemia and impaired glucose tolerance. Overproduction of these hormones may occur with tumors of the hormone-producing cells or paraneoplastic syndromes ("ectopic" hormone production).

In man, hyperglucagonemia may be associated with bacterial infections, trauma, congestive heart failure, azotemia and functioning tumors of the  $\alpha$ -cells of the islets of the pancreas or of the gastrointestinal tract (eg, glucagonoma).<sup>10,72</sup>

Most avian pancreatic carcinomas are the result of secondary invasion usually via serosal implantation on the duodenal loop of tumors arising in the female reproductive tract.<sup>15</sup> The histology can be most misleading because in the pancreas there is often an appearance of gradation and continuity between epithelium and tumor cells. An islet cell adenoma that was identified as an  $\alpha$ -cell adenoma has been described.<sup>15</sup> No clinical information on this bird was available.

An islet cell carcinoma has been diagnosed in one case of diabetes mellitus in a parakeet. The cellular origin of the tumor was not identified, but it was suggested that it could be an  $\alpha$ -cell tumor.<sup>80</sup> This also may have been a case of a paraneoplastic syndrome. In man, pancreatic islet cell tumors are a well known site of ectopic ACTH production, which can cause an associated Cushing's syndrome.<sup>70</sup> Pancreatic islet cell tumors are also associated with ectopic GH secretion,<sup>70</sup> which can cause diabetes mellitus in dogs.<sup>26</sup> Unfortunately, no endocrine studies were performed in this particular parakeet. Glucagon-like immunoreactivity has been reported from extracts of certain parts of the avian small intestine.<sup>90</sup>

The normal avian pancreas contains extremely high levels of somatostatin (produced in the D-cells of the islets). This compound depresses glucagon secretion (and to a lesser extent insulin and avian pancreatic polypeptide secretion), and it might be hypothesized that elevated glucagon concentrations could be caused by decreased release of somatostatin (SRIF). The hypothesized triggering mechanism for a diminished release of SRIF, however, is not clear.

In intact female dogs, progesterone-induced GH overproduction with subsequent insulin resistance accompanied with hyperinsulinemia can cause diabetes mellitus. The disease can occur spontaneously

**TABLE 23.2 Control of Carbohydrate Metabolism**

	Birds (granivorous)	Mammals
Pancreas	Low insulin High glucagon	High insulin Low glucagon
Plasma glucagon	High	Low
Pancreatectomy	Varies (hypoglycemia)	Diabetes mellitus

during diestrus or as a complication of treatment with medroxyprogesterone acetate. The data available on plasma insulin concentrations in birds with hyperglycemia/glycosuria suggest that the cases were not caused by insulin resistance because insulin concentrations in the birds were similar to controls. Overproduction of GH, therefore, was an unlikely cause of diabetes mellitus in these birds, but might be a cause of diabetes in other birds.

Hyperglycemia was reported in budgerigars with subcutaneous transplants of pituitary adenomas in combination with slightly elevated GH activities.<sup>84</sup>

A cockatiel was reported with what seemed to be subnormal glucagon concentrations and normal insulin concentrations.<sup>58</sup> It is possible that the low glucagon concentration was a response to a hyperglycemia induced by another unknown factor (steroid diabetes caused by primary, secondary or iatrogenic hyperadrenocorticism or ectopic ACTH production).

The association of Cushing's syndrome with carcinoma is the most common ectopic endocrine syndrome in man. Neoplasms associated with this syndrome include lung carcinoma (oat cell and small round cell), pancreas carcinoid and islet cell carcinomas, medullary carcinomas of thyroid and neoplasms derived from the neural crest (pheochromocytoma, neuroblastoma, paraganglioma, ganglioma) (see Color 25). Numerous cases suggest that any carcinoma may induce an ectopic endocrine syndrome. The current theory is that POMC is probably produced in small quantities by all normal nonendocrine tissues. Immunoreactive POMC is found in large quantities in extracts of carcinomas. Some carcinomas metabolize POMC to biologically active ACTH, producing the so-called ectopic ACTH syndrome.<sup>70</sup> Renal carcinomas and pancreatic carcinomas have been seen in association with hyperglycemia in birds, and a paraneoplastic syndrome involving POMC-derived ACTH with subsequent hyperadrenocorticism cannot be excluded.

The single case of diabetes mellitus reported in a raptorial bird was associated with markedly vacuolated B-cells indicative of excessive stimulation.<sup>103</sup> Further findings were four fluid-filled cysts on the kidneys and mildly enlarged adrenals. Histology revealed chronic multifocal lymphocytic interstitial nephritis. The liver had variable-sized, randomly scattered foci of lipidosis.

The pathogenesis of diabetes mellitus in birds remains unclear.

## Polyuria/Polydipsia (PU/PD)

A variety of diseases that cause PU/PD in birds has been defined, but the pathophysiologic mechanisms and etiology are not always clear. The minimal database for an avian patient with PU/PD should include dietary history, social and behavioral history, vaccination status (paramyxovirus in pigeons) and recent medications (eg, corticosteroid therapy), urinary glucose, plasma glucose, urea, uric acid, AST, bile acids, total calcium, total protein, protein electrophoresis and HAI-titer for paramyxovirus in pigeons. Diseases that are known to cause PU/PD in other animals, but that have not been diagnosed in birds, are hyperthyroidism, hyperadrenocorticism and hypercalcemia associated with (pseudo)hyperparathyroidism.

Determining the reproductive history is important in hens with PU/PD. Birds with egg-related peritonitis may have previously laid eggs and then stopped because of the egg-related peritonitis. These birds may have a swollen abdomen in association with PU/PD.

### Polyuria/Polydipsia Syndrome in Pigeons Feeding Squabs

Pigeons feed their young crop milk during the first 7 to 11 days after hatching, at which time the squabs are fed regurgitated grains. The parent birds and the squabs often develop PU/PD for a couple of days during the transition period. When the parents and squabs are separated from each other, PU/PD continues in the adult birds but subsides in the squabs.

The observed PU/PD in the parent birds may be caused by a decrease in the circulating concentrations of prolactin. Apart from being essential for the production of crop milk, it has been shown that prolactin has an influence on water and electrolyte regulation in birds. Experimental administration of prolactin to Mallard Ducks results in a decreased urine production. In chickens, an increase in plasma prolactin concentrations has been observed after infusion of hypertonic saline and with dehydration.

When water intake is restricted in these birds, the PU/PD stops immediately, indicating that the body is capable of correctly concentrating urine.



TABLE 23.3 Some Conditions Associated with Polyuria/Polydipsia

▪ Dietary-induced polyuria	▪ Pigeons feeding squabs
▪ Excitement or nervousness	▪ Paramyxovirus (racing pigeons)
▪ Apparent psychogenic polydipsia	▪ Liver disease
▪ Medications (corticosteroids, diuretics, progestones)	▪ Renal disease
▪ Toxins (eg, gentamicin)	▪ (Hypercalcemia?)
▪ Nephrogenic diabetes insipidus	▪ (Hyperadrenocorticism?)
▪ Diabetes insipidus	▪ (Hyperthyroidism?)
▪ Diabetes mellitus	▪ Hypervitaminosis D <sub>3</sub>
▪ Renal glucosuria	▪ Elevated dietary sodium
	▪ Excess dietary protein
	▪ Excessive fruit consumption

### Renal Glucosuria

Glucosuria is not always associated with hyperglycemia, and the two should occur together to warrant a diagnosis of diabetes mellitus. Glucosuria without hyperglycemia in man is associated with the Fanconi syndrome, which is caused by inherited or acquired damage to the proximal convoluted tubules of the kidney.<sup>105</sup> Glucosuria without hyperglycemia has been observed in an African Grey Parrot.

### References and Suggested Reading

1. **Alberts H, et al:** A water deprivation test for the differentiation of polyuric disorders in birds. *Avian Pathol* 17:385-389, 1988.
2. **Ash JS:** Another dwarf pheasant. *Bulletin British Ornithological Club* 86:95-96, 1966.
3. **Astier H:** Thyroid gland in birds. In *Epple A, Stetson MH (eds): Avian Endocrinology*. London and New York, Academic Press, 1980, pp 167-189.
4. **Axelrod L:** Glucocorticoid therapy. *Medicine* 55:39, 1976.
5. **Bainbridge KG, Taylor TG:** The role of calcitonin in controlling hypercalcemia in the domestic fowl (*Gallus domesticus*). *Comp Biochem Phys A* 68:647-651, 1981.
6. **Baxter JD, Forsham RH:** Tissue effects of glucocorticoids. *Am J Med* 53:573, 1972.
7. **Boyle JD:** The adrenohypophysiotropic mechanisms. In *Epple A, Stetson M (eds): Avian Endocrinology*. New York, Academic Press, 1980, p 117.
8. **Beach JE:** Diseases of budgerigars and other cagebirds. A summary of post mortem findings. *Vet Rec* 74:10-15, 63-68, 134-140, 1962.
9. **Beuving G, Vonder GMA:** Daily rhythm of corticosterone in laying hens and the influence of egg laying. *J Reprod & Fert* 51:169-173, 1977.
10. **Bilbrey GL, et al:** Hyperglucagonaemia of renal failure. *J Clin Invest* 53:841, 1974.
11. **Blackmore DK:** The pathology and incidence of thyroid dysplasia in budgerigars (*Melopsittacus undulatus*). *Vet Rec* 75:1068-1072, 1965.
12. **Blackmore DK:** Diseases of the endocrine system. In *Petrak ML (ed): Diseases of Cage and Aviary Birds* 2nd ed. Philadelphia, Lea & Febiger, 1982, pp 479-490.
13. **Braverman LE:** Normal and abnormal responses to iodine: Disorders of iodine excess. In *Werner SC, Ingbar SH (eds): The Thyroid. A Fundamental and Clinical Text*. New York, Harper and Row, 1978, pp 528-536.
14. **Burrow, GN:** Thyroid hormone therapy in nonthyroid disorders. In *Werner SC, Ingbar SH (eds): The Thyroid. A Fundamental and Clinical Text*. New York, Harper and Row, 1978, pp 974-980.
15. **Campbell JG:** Tumours of the Fowl. Philadelphia, JB Lippincott Company, 1969.
16. **Campbell JG, Appleby EC:** Tumours in young chickens bred for rapid body growth (broiler chickens): A study of 351 cases. *J Pathol & Bact* 92:77-90, 1961.
17. **Cole RK:** Hereditary hypothyroidism in the domestic fowl. *Genetics* 53:1021, 1966.
18. **Cole RK, Kite JH, Witebsky E:** Hereditary autoimmune thyroiditis in the fowl. *Science* 160:1357-1358, 1968.
19. **Curtis-Velasco M:** Pituitary adenoma in a cockatiel (*Nymphicus hollandicus*). *J Assoc Avian Vet* 6(1):21-22, 1992.
20. **Cutler GB, Habener JF, Dee PC, Potts JT:** Comparative immunochemical studies of chicken ultimobranchial calcitonin. *Gen & Compar Endocrin* 24:183, 1974.
21. **Davison TF, Rea J, Powell JG:** Effects of dietary corticosterone on peripheral blood lymphocytes and granulocyte populations in immature domestic fowl. *Res Vet Sci* 34:236, 1983.
22. **Davison TF, Chapman HD, Harvey S:** Endocrine changes in the fowl during infection with *Eimeria maxima*. *Res Vet Sci* 38:296-300, 1985.
23. **Davison TF, Rea J, Freeman BM:** Effect of increased circulating corticosterone on the plasma concentrations of thyroxine and triiodothyronine in chickens. *IRCS Med Sci* 13:692-693, 1985.
24. **De la Cruz LF, Mataix FJ, Illera M:** Effects of glucocorticoids on protein metabolism in laying quails (*Coturnix japonica*). *Comp Biochem Physiol A* 70:649, 1981.
25. **Eisen HN:** Immunology. An Introduction to Molecular and Cellular Principles of the Immune System. New York, Harper and Row, 1974, p 591.
26. **Etinger SJ (ed):** Textbook of Veterinary Internal Medicine Vol 2, 3rd ed. Philadelphia, WB Saunders Co, 1988, pp 1579-1774.
27. **Fauci AS, et al:** Glucocorticosteroid therapy: Mechanisms of action and clinical considerations. *Ann Int Med* 84:304, 1976.
28. **Freeman BM (ed):** Physiology and Biochemistry of the Domestic Fowl Vol 4. London, Academic Press, 1983.
29. **Freeman BM (ed):** Physiology and Biochemistry of the Domestic Fowl Vol 5. London, Academic Press, 1984.
30. **Fowler ME:** Miscellaneous waterbirds. In *Fowler ME (ed): Zoo and Wild Animal Medicine*. Philadelphia, WB Saunders Co, 1978, p 215.
31. **Fowler ME:** Stress. In *Fowler ME (ed): Zoo and Wild Animal Medicine*. Philadelphia, WB Saunders Co, 1978, pp 33-34.
32. **Gorsline J:** The effects of south Louisiana crude oil on adrenocortical function. In *Scanes CG, et al (eds): Aspects of Avian Endocrinology*. Lubbock, Texas Tech Press, 1982, pp 359-364.
33. **Grazl E, Köhler H:** Spezielle Pathologie und Therapie der Geflügelkrankheiten [Pathology and Therapy of Poultry Diseases]. Stuttgart, Ferdinand Enke Verlag, 1968.
34. **Groggier U, Grimm F:** Dexamethason- und Prednisolone Einsatz bei Tauben [The use of dexamethason and prednisolon in pigeons]. VI. Tagung über Vogelkrankheiten der Deutsche veterinärmedizinische Gesellschaft, München, 1988, pp 68-76.
35. **Gross WB, Siegel PB, Dubosse RJ:** Some effects of feeding corticosterone to chickens. *Poult Sci* 59:516-522, 1980.
36. **Guerin M:** Tumeurs spontanees de la poule [Spontaneous tumors in poultry]. In *Tumeurs Spontanees des Animaux de Laboratoire*. Paris, LeGrand, 1954, pp 153-180.
37. **Gylstorff I, Grimm F:** Vogelkrankheiten [Avian Diseases]. Stuttgart, Ulmer, 1987.
38. **Haas L:** Die Auswertung des Paramunitätsinducers PIND ORF auf die Flugleistung sowie auf die Ausschcheidung von Kokzidiennozysten von normalen und immunsupprimierten Brieftauben (*Columba livia*, Gmel., 1789, var. dom.) [The effect of the paramunity inducer PIND ORF on the racing pigeon performance and the excretion of oocysts on normal and immunosuppressed racing pigeons]. PhD Thesis, University of Munich, 1987.
39. **Halloran POC:** A bibliography of references to diseases in wild mammals and birds. Appendix to *Am J Vet Res* 16:306-405, 1955.
40. **Harrap BS, Woods EF:** Species difference in the protein of feathers. *Comp Biochem Physiol* 20:449, 1967.
41. **Hazelwood A, Harrison JM:** A note on *Larus capistratus* Temminck. *Bulletin*

### Apparent Psychogenic Polydipsia

Some avian patients may develop psychogenic polydipsia that results in polyuria. A water deprivation test may be useful in documenting a primary polydipsia or compulsive water drinking. In these patients, water restriction results in disappearance of the clinical signs. It seems that psychogenic polydipsia should be added to the list of behavioral problems that can be encountered in companion birds.<sup>64</sup>

### Paramyxovirus Infection in Racing Pigeons

When a pigeon strain of paramyxovirus serotype-1 infects an unvaccinated flock of pigeons, about 80% of the birds will develop severe PU/PD, which can last for several months and then gradually resolve. The pathophysiologic mechanism for these clinical changes has not been defined.

### Products Mentioned in the Text

- a. Ambinon, Organon, Oss, The Netherlands
- b. Cortrosyn, Organon, Oss, The Netherlands

- tin British Ornithological Club 73: 98-100, 1953.
42. **Hazelwood RL:** Carbohydrate metabolism; Pancreas. In Sturkie PD (ed): *Avian Physiology* 4th ed. New York, Springer Verlag, 1986, pp 303-325; pp 494-501.
  43. **Höhn EO, Braun CE:** Hormonal induction of feather pigmentation in ptarmigan. *Auk* 98:189, 1981.
  44. **Hollander WF, Riddle O:** Goiter in domestic pigeons. *Poult Sci* 25:20-27, 1946.
  45. **Holmes WN, Cronshaw J, Redondo JL:** The ontogeny of adrenal steroidogenic function in the mallard (*Anas platyrhynchos*). In Wada M, Ishii S, Scanes CG: *Endocrinology of Birds. Molecular to Behavioral*. Berlin, Springer Verlag, 1990.
  46. **Hutt FB:** Sex-linked dwarfism in the fowl. *J Heredity* 50:209-221, 1959.
  47. **Joseph MM, Meier AH:** Daily rhythms of plasma corticosterone in the common pigeon *Columba livia*. *Gen & Comp Endocrin* 20:326-330, 1973.
  48. **Julian RJ, Summers J, Wilson JB:** Right ventricular failure, and ascites in broiler chicks caused by phosphorus-deficient diets. *Avian Dis* 30:453-459, 1986.
  49. **Kronberger H:** Haltung von Vögeln, Krankheiten der Vögel [Aviculture and Diseases of Birds]. Jena: VEB Gustav Fischer Verlag, 1974.
  50. **Kühn ER, Decypere E, Huybrechts LM, Darras VM:** Hormonal control of the hepatic 5 $\alpha$ -monodeiodination activity and its relation to the somatomedin production in the chicken. In Wada M, Ishii S, Scanes CG: *Endocrinology of Birds. Molecular to Behavioral*. Berlin, Springer Verlag, 1990, pp 129-142.
  51. **Lamont SJ, Smyth JR, Jr:** Effect of bursectomy on development of a spontaneous postnatal melanosis. *Clin Immunol Immunopath* 21:407, 1981.
  52. **Larsson M:** Diagnostic methods in canine hypothyroidism and influence of non-thyroidal illness on thyroid hormones and thyroxine-binding proteins. Thesis, Uppsala, Sveriges Lantbruksuniversitet, 1987, p 13.
  53. **Lang PH, Lee SR, Rowland GN, Britton WM:** Experimental rickets in broilers: Gross, microscopic, and radiographic lesions. I. Phosphorus deficiency and calcium excess. *Avian Dis* 28:460-474, 1984.
  54. **Lang PH, Lee SR, Rowland GN, Britton WM:** Experimental rickets in broilers: Gross, microscopic, and radiographic lesions. II. Calcium deficiency. *Avian Dis* 28:921-932, 1984.
  55. **Lang PH, Lee SR, Rowland GN, Britton WM:** Experimental rickets in broilers: Gross microscopic, and radiographic lesions. III. Vitamin D deficiency. *Avian Dis* 28:933-943, 1984.
  56. **Lathrop CD, Loomis MR, Olsen JH:** Thyrotropin stimulation test for evaluation of thyroid function in psittacine birds. *J Am Vet Med Assoc* 186:47-48, 1985.
  57. **Lathrop CD, Olsen JH, Loomis MR, et al:** Evaluation of adrenal function in psittacine birds, using the ACTH stimulation test. *J Am Vet Med Assoc* 187:1113-1115, 1985.
  58. **Lathrop C, Harrison G, Schultz D, Uttridge T:** Miscellaneous diseases. In Harrison GJ, Harrison LR (eds): *Clinical Avian Medicine and Surgery*. Philadelphia, WB Saunders Co, 1986, pp.525-536.
  59. **Lumeij JT:** Relation of plasma calcium to total protein and albumin in African grey (*Psittacus erithacus*) and Amazon (*Amazona* spp.) parrots. *Avian Pathol* 19:661-667, 1990.
  - 59a. **Lumeij JT, DeBruijne JJ, Krant M:** Comparison of different methods of measuring protein and albumin in pigeon sera. *Avian Pathol* 19:255-261, 1990.
  60. **Lumeij JT, Boschma Y, Mol J, et al:** Action of ACTH<sup>1-24</sup> upon plasma corticosterone concentrations in racing pigeons (*Columba livia domestica*). *Avian Pathol* 16:199-204, 1987.
  61. **Lumeij JT, Sprang EPM, Mol JA:** Arginine vasotocin measurements before and after water deprivation for the differentiation of polyuric disorders in birds, submitted.
  62. **Lumeij JT, Remple JD, Riddle K:** Relation of plasma total protein and albumin to total calcium in peregrine falcons (*Falco peregrinus*). *Avian Pathol* 22:183-188, 1993.
  63. **Lumeij JT, Westerhof I:** Clinical evaluation of thyroid function in racing pigeons (*Columba livia domestica*). *Avian Pathol* 17:63-70, 1988.
  64. **Lumeij JT, Westerhof I:** The use of the water deprivation test for the diagnosis of apparent psychogenic polydipsia in a socially deprived African grey parrot (*Psittacus erithacus*). *Avian Pathol* 17:875-878, 1988.
  65. **Melby JC:** Clinical pharmacology of systemic corticosteroids. *Ann Rev Pharmacol Toxicol* 17:511, 1977.
  66. **Murton RK, Westwood NJ:** *Avian Breeding Cycles*. Oxford: Clarendon, 1977.
  67. **Murray BG:** A small great-crested flycatcher. *Bird Banding* 42:119, 1971.
  68. **Nakamura T, Tanabe Y, Hirano H:** Evidence of the *in vitro* formation of cortisol by the adrenal gland of embryonic and young chickens (*Gallus domesticus*). *Gen Comp Endocrin* 25:300-308, 1978.
  69. **Neumann U, Kummerfeld N:** Neoplasms in budgerigars: clinical, pathomorphological and serological findings with special consideration of kidney tumors. *Avian Pathol* 12:353-362, 1983.
  70. **Odell WD:** Endocrine manifestations of tumors: "Ectopic" hormone production. In Wijngaarden JB, Smith LH: *Cecil Textbook of Medicine*, 18th ed. Philadelphia, WB Saunders Co, 1988, pp 1100-1104.
  71. **Parrott T:** Pododermatitis in three Amazon parrots and treatment with L-thyroxine. *Proc Assoc Avian Vet*, 1991, pp 263-264.
  72. **Rocha DM, et al:** Abnormal pancreatic-cell function in bacterial infections. *New Engl J Med* 284:621, 1971.
  73. **Roskopf WJ, Woerpel RW, Howard EB, Holshuh HJ:** Chronic endocrine disorder associated with inclusion body hepatitis in a sulfur crested cockatoo. *J Am Vet Med Assoc* 179:1273-1276, 1981.
  74. **Roskopf WJ, Woerpel RW, Rickind M, Howard EB:** Pathogenesis, diagnosis and treatment of adrenal insufficiency in psittacine birds. *Calif Vet* 36:26-30, 1982.
  75. **Roskopf WJ, Woerpel RW:** Remission of lipomatous growth in a hypothyroid budgerigar in response to L-thyroxine therapy. *Vet Med Sm Anim Clin* 9:1415-1418, 1983.
  76. **Roskopf WJ, Woerpel RW, Roskopf G, Van de Water D:** Normal thyroid values for common pet birds. *Vet Med Sm Anim Clin*, March 1982: 409-412, 1982.
  77. **Rudas P, Salyi G, Szabo J:** Decreased thyroxine, triiodothyronine and 5-deiodination levels in malabsorption syndrome. *Avian Dis* 30:293-297, 1985.
  78. **Russel WC:** Iodine goiter in penguins. *J Zoo An Med* 1:24-27, 1970.
  79. **Russel WC:** Iodine-induced goiter in penguins. *J Am Vet Med Assoc* 171:959-960, 1977.
  80. **Ryan CP, Walder EJ, Howard EB:** Diabetes mellitus and islet cell carcinoma in a parakeet. *J Am Anim Hosp Assoc* 18:139-142, 1982.
  81. **Scanes CG, et al:** In Wada M, Ishii S, Scanes CG: *Endocrinology of Birds. Molecular to Behavioral*. Berlin, Springer Verlag, 1990.
  82. **Schlumberger HG:** Neoplasia in the parakeet. I. Spontaneous chromophobe pituitary tumors. *Cancer Res* 14:237, 1954.
  83. **Schlumberger HG:** Spontaneous goiter and cancer of the thyroid in animals. *Ohio J Sci* 55:23-43, 1955.
  84. **Schlumberger HG:** Neoplasia in the parakeet II. Transplantation of the pituitary tumor. *Cancer Res* 16:149-153, 1956.
  85. **Schlumberger HG:** Tumors characteristic for certain animals. A review. *Cancer Res* 17:823-832, 1957.
  86. **Schlumberger HG:** Polystotic hyperostosis in the female parakeet. *Am J Pathol* 35:1-23, 1959.
  87. **Schultz DJ:** Respiratory diseases. *Proc #65 Aviary and Caged Birds. University of Sydney, Australia*, 1981, p 493.
  88. **Serrano J, Scavo L, de Pablo, F:** The ontogeny of insulin gene expression. In Wada M, Ishii S, Scanes CG: *Endocrinology of Birds. Molecular to Behavioral*. Berlin, Springer Verlag, 1990, pp 85-92.
  89. **Simkiss K:** Calcium in Reproductive Physiology. A Comparative Study of Vertebrates. London, Chapman and Hall Ltd, 1967, pp 155-197.
  90. **Sitbon G, Mialhe P:** Pancreatic hormones and plasma glucose: Regulation mechanisms in the goose under physiological conditions. *Horm Metab Res* 11:85, 1979.
  91. **Slye M, Holmes HF, Wells HG:** Intracranial neoplasms in lower animals. Studies on the incidence and inheritability of spontaneous tumors in mice. *Am J Cancer Res* 15:1387-1400, 1931.
  92. **Smyth JR Jr, Boissey RE, Fite KV:** The DAM chicken: A model for spontaneous postnatal cutaneous and ocular melanosis. *J Heredity* 72:150, 1981.
  93. **Sturkie PD (ed):** *Avian Physiology* 4th ed. New York, Springer-Verlag, 1986.
  94. **Suzuki H, Higuchi T, Sawa K, et al:** Endemic coast goitre in Hokkaido, Japan. *Acta Endocrinologica (Kbh)* 50:161, 1965.
  95. **Takei Y, Kobayashi H:** Hormonal regulation of water and sodium intake in birds. In Wada M, Ishii S, Scanes CG: *Endocrinology of Birds. Molecular to Behavioral*. Berlin, Springer Verlag, 1990, pp 171-186.
  96. **Tanabe Y, Nakamura T, Fujiota K, Doi O:** Production and secretion of sex steroid hormone by the testes, ovary, and the adrenal glands of embryonic and young chickens (*Gallus domesticus*). *Gen Comp Endo*, 39: 26-33, 1979.
  97. **Thomas DH, Philips JG:** Studies in avian adrenal steroid function. IV: Adrenalectomy and the response of domestic ducks (*Anas platyrhynchos* L.) to hypertonic saline loading. *Gen & Comp Endocrin* 26:427-439, 1975.
  98. **Visser TJ:** Thyroid Hormone Deiodination. Thesis, Rotterdam, Erasmus University, 1980, p 91.
  99. **Vogel C:** Taubenkrankheiten [Pigeon Diseases]. Berlin: VEB Deutscher Landwirtschaftsverlag, 1982, pp 303-306.
  100. **Vaitkevich AA:** The Feather and Plumage of Birds. London: Sidgwick and Jackson, 1966.
  101. **Wada M, Ishii S, Scanes CG:** *Endocrinology of Birds. Molecular to Behavioral*. Berlin, Springer Verlag, 1990.
  102. **Wadsworth PF, Jones DM:** Some abnormalities of the thyroid gland in non-domesticated birds. *Avian Pathol* 8:279-284, 1979.
  103. **Wallner-Pendleton EA, Rogers D, Eppler A:** Diabetes mellitus in a red-tailed hawk. *Avian Pathol* (in press).
  104. **Walsh MT, Beldegreen RA, Clubb SL, Chen, CL:** Effect of exogenous ACTH on serum corticosterone and cortisol concentrations in the Moluccan cockatoo (*Cacatua moluccensis*). *Am J Vet Res* 46:1584-1589, 1985.
  105. **Watts RWE:** Metabolic and genetic renal disorders and renal calculi. In Scott RB (ed): *Price's Textbook of the Practice of Medicine* 12th ed. Oxford University Press, 1978, 1056-1074.
  106. **Wheler C:** Pituitary tumors in cockatiels. *J Assoc Avian Vet* 6(2):92, 1992.
  107. **Williamson RA, Davison TF:** The effect of a single injection of thyrotrophin on serum concentrations of thyroxine, triiodothyronine and reverse triiodothyronine in the immature chicken (*Gallus domesticus*). *Gen & Comp Endo* 58:109-113, 1985.
  108. **Williamson RA, Misson BH, Davison TF:** The effect of exposure to 40° C on the heat production and the serum concentration of triiodothyronine, thyroxine and corticosterone in immature domestic fowl. *Gen & Comp Endocrin* 60:178-186, 1985.
  109. **Wijngaarden JB, Smith LH (eds):** *Cecil Textbook of Medicine* 18th ed vol 2, Philadelphia, WB Saunders Co, 1988.
  110. **Zenoble RD, Kemppainen RJ, Young DW, Clubb SL:** Endocrine response of healthy parrots to ACTH and thyroid stimulating hormone. *J Am Vet Med Assoc* 187:1116-1118, 1985.
  111. **Zenoble RD, Kemppainen RJ, Young DW, Carpenter JW:** Effect of ACTH on plasma corticosterone and cortisol in eagles and condors. *J Am Vet Med Assoc* 187:1119-1120, 1985.
  112. **Zipper J, Tamaschke CH:** Pathologische Schilddrüsenbefunde bei Vögeln [Pathologic changes of thyroid glands in birds]. In Verhandlungsberichte XIV Intern Symp Krankh Zootiere, Wrocław. Berlin, Akademie Verlag, 1972, pp 113-122.

**T**he condition of the skin and feathers of a bird provides a clinical window to the nutritional plane and environmental conditions to which the patient is exposed. Additionally, systemic diseases (hepatic, renal, pancreatic, gastrointestinal, hematopoietic) can alter the condition of the integument. These changes are frequently detected by observant owners and should be carefully evaluated by the veterinarian. In addition to responding to systemic abnormalities, the feathers and skin are subject to a group of organ-specific diseases.

The unique structure and adaptations of the avian integument have long attracted interest.<sup>26,32,67</sup> The avian integument consists of the skin, scales, feathers, four sets of glands, beak, cere, nails and foot pads. Some species (particularly Galliformes) have highly adapted integumentary appendages that are used for defense or mating rituals. These include wattle, ricti, ear lobes, comb (chickens); dewlap, snood (turkeys); casque (cassowaries); shields (coots and gallinules); knob (goose) and various modifications of the head plumage into crests and bristles. Through selective breeding the comb of the red junglefowl has been modified into dozens of unique shapes, sizes and colors. These unfeathered appendages are particularly susceptible to traumatic injuries and infectious agents. Not all skin appendages are found in any one bird. The only common elements are skin, beak, nails and feathers, which vary in pigmentation, shape, texture, function, location and number, depending on evolutionary adaptations.

---

CHAPTER

---

24

DERMATOLOGY

---

■  
John E. Cooper  
Greg J. Harrison

## Anatomy and Physiology of the Avian Integument

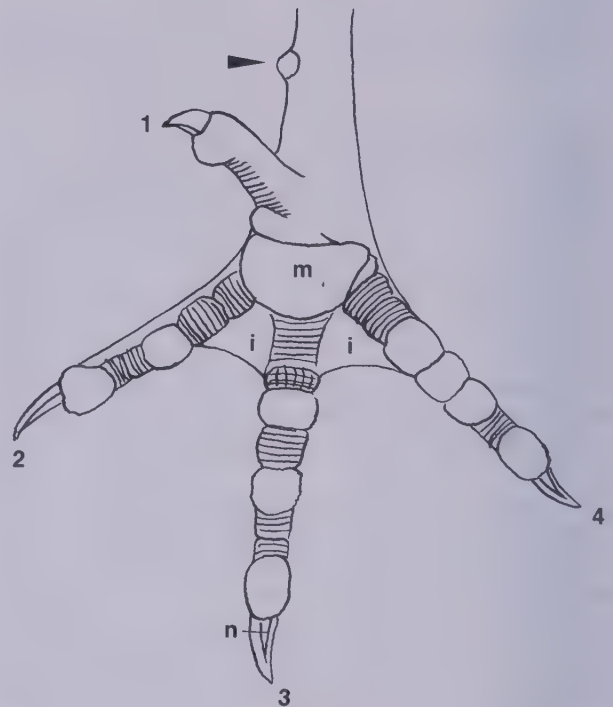
The epidermis of birds consists of three layers including the basal (germinative) layer, intermediate layer and outer cornified layer. The germinative layer is thin (two to four cells thick) in the feathered areas of the body and may be much thicker and interdigitate with the dermis in unfeathered areas of the legs and feet.<sup>26</sup> Striated muscles located in the epidermis move the skin.

The dermis is divided into superficial and deep layers, with the former containing loosely arranged layers of collagen in interwoven bundles and the latter containing fat, feather follicles, smooth muscles that control movement of the feathers and large blood vessels and nerves that supply the dermis and epidermis.<sup>32</sup> A complex mechanoreceptor system (Herbst's corpuscles) occurs in various parts of the avian body including the integument, bones, tendons, muscles, joints and vessels.

The skin overlying the head, extremities and sternum is firmly attached to underlying skeletal structures. Over the remainder of the body, the skin is loosely attached to the underlying muscles. The areas with the most subcutaneous tissues include the dorsal cervical, midline, axillary and groin regions. Footpads are present in many birds, primarily terrestrial species (Figure 24.1). The feet of some birds indigenous to areas with inclement weather are covered with feathers or contain projections (spikes) to facilitate movement in ice and snow.

During the breeding season, many avian species will develop a thickening and increased vascularization of the skin on the ventral abdomen called a brood patch. Depending on the species, one or both genders may develop this brood patch, which should not be mistaken for a featherless, hyperemic skin lesion.

Birds lack sweat glands and most of the skin over the body is thin, dry and inelastic. The feet and, to varying degrees among species, the legs are covered with thick scales. The skin is glandless except for the uropygial (preen) gland, glands of the ear canal and pericloacal glands. The uropygial gland is involved in maintaining feather condition in those species that have this structure. The presence or absence of these



**FIG 24.1** Well developed footpads are common in terrestrial birds. Digits 1, 2, 3 and 4 from the right foot of a gallinaceous bird. The interpad spaces are shaded and the digital pads are unshaded. Metatarsal pads (m), interdigital web (i), nail (n) and metatarsal spur (arrow) (modified from Lucas and Stettenheim<sup>32</sup>).

glands varies widely among species. Pericloacal glands secrete mucus.<sup>28</sup>

The feathers serve a protective function and the unfeathered areas of the integument (cere, beak, face, legs and feet) are common sites for primary skin disease (poxvirus, *Knemidokoptes* spp.). The skin is capable of dissipating some heat through evaporative cooling but the lack of sweat glands makes birds particularly sensitive to hyperthermia. The functional capacity of the evaporative cooling mechanism may be adversely affected by an essential fatty acid deficiency.<sup>35</sup>

Some birds maintain feather quality through dusting, sunning or bathing. "Anting," or the intentional allowing of ants to cover the body, may serve a grooming role in some species. Other species, most notably cockatoos, have specialized feathers (powder down) that produce a fine keratin debris that is involved in maintaining feather condition. Presence of this normal keratin debris should not be confused with a pathologic condition. Additionally, the exsheathed portion of the keratin shaft from a developing feather should not be confused with dandruff. Retention of the sheath is common in birds with systemic disease

and these birds may be pruritic or appear hypersensitive when stroked.

### Cere

The wax-like cere is composed of keratinized skin at the base of the upper beak. Many Anseriformes lack a cere and their nostrils are located in the tip of the soft beak (see Figure 46.7). The cere is affected by a number of conditions, and its appearance can change with the health of the bird. In raptors, the cere may change from bright yellow to pale yellow based on the quantity of carotenoids in the diet.


Brown hypertrophy of the cere may occur in male budgerigars, presumably due to changes in the ratio of sex hormones, and is frequently associated with testicular tumors (Color 24.18). The discolored hyperkeratotic material can be moistened and gently peeled away or removed by scraping or rasping.<sup>3</sup> Hyperkeratosis and flaking of the skin around the cere may be pronounced in malnourished birds. Some hypertrophy is normal in reproductively active hens.

### Beak

The beak (rostrum) consists of the bones of the upper (maxilla) and lower (mandible) jaws and their horny covering (rhamphotheca). The beak (or bill) functionally replaces the lips and teeth of mammals and varies in function, shape, size and length among species. The bone underlying the rhamphotheca is covered by periosteum. The periosteum is covered by the dermis and epidermis. The dermis of the beak does not appear to be divided into layers as it is in the skin, but rather is a single layer of dense connective tissue.<sup>32</sup>

The consistency of the rhamphotheca varies among species. It is horny and firm in Psittaciformes, but soft and pliable in Anseriformes. The rhamphotheca can be viewed as the stratum corneum of the beak, and the dermis is well vascularized and connected to the periosteum of the underlying bone. Trauma or necrosis of the dermis will frequently result in a lesion that induces a beak deformity (inability of the damaged area to regrow) (Figure 24.2).

The beak, nails and spurs grow continuously and are worn down by digging, eating or chewing hard objects (Figure 24.3). The beak is used as a tool, weapon and as a tactile exploratory organ for food discrimination, plumage care, nest-building and feeding of the young.

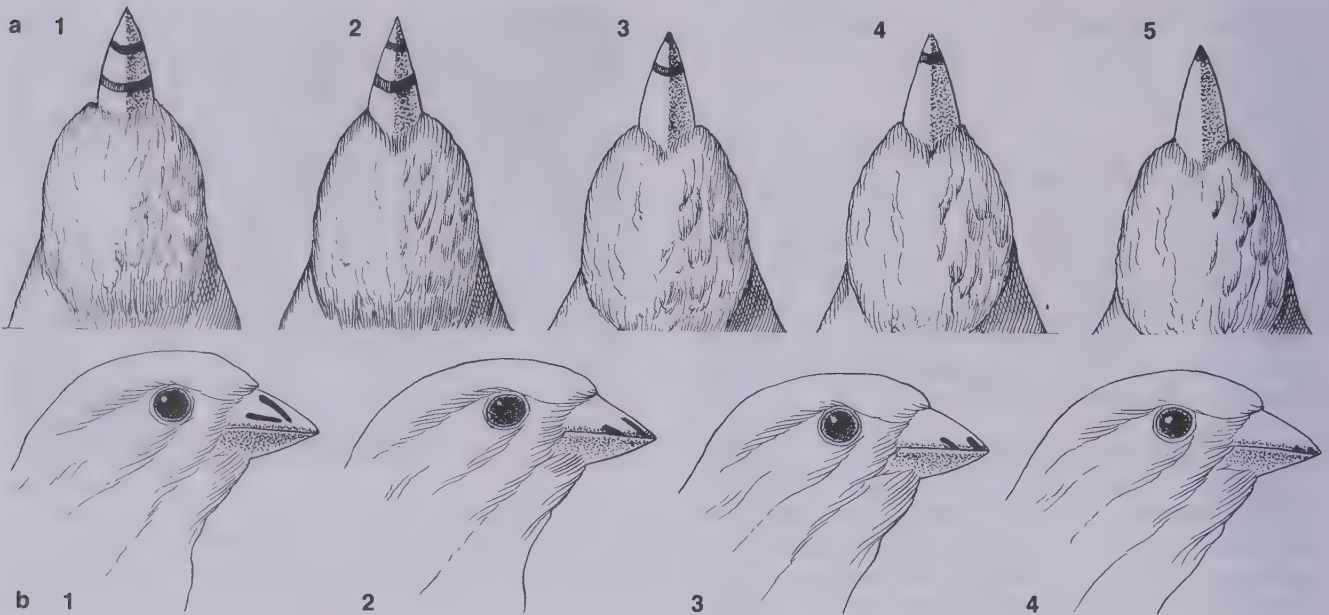


**FIG 24.2** Depending on the severity and location of a beak injury, defects in the rhamphotheca can be permanent or they can heal. In this case, a traumatic beak wound in a Great-billed Parrot has been repaired with cyanoacrylic resin (arrows) (courtesy of Louise Bauck).


The beak is modified to rip (raptors), tear or crush (psittacine birds), sift (flamingos) or probe for food (avocets). The beak of some gallinaceous birds is serrated and resembles teeth in both form and function. The buccal surface of the upper beak of some Psittaciformes has a number of rasp-like ridges (Figure 24.4). These are believed to function in holding nuts, filing down fruits and maintaining a sharp edge on the lower beak.<sup>28</sup>

The skin and beak of birds are sensitive to heat, cold and various degrees of pressure. Cutting the beak of a goose will elicit an increase in blood pressure, heart rate and respiratory rate and initiate a tear flow (pain response).<sup>28</sup> Herbst's corpuscles found in the tip of the beak may serve a tactile function that is independent of the tongue and eyes in the exploration for and sorting of food.

Birds that use the beak to search, catch or select food have a well developed "bill tip organ" that can be recognized as papillae that originate in the dermis and end in crater-like structures at the distal tip of the beak.<sup>28</sup> The location and degree of development of the bill tip organ vary among species. In parrots, the organ is best developed in the lower beak (Figure 24.5). The upper beak in Psittaciformes can be viewed as a probe that is used to move items over the bill tip organ in the lower beak. Granivores that obtain food by pecking (Columbiformes and Passeriformes) do not appear to have this organ. The bill tip organ should be presumed to be extremely sensitive,



**FIG 24.3** Based on beak migration patterns, the clinical progression of rhamphothecal hyperkeratosis secondary to malnutrition must involve dysfunction of multiple growth plates. **a)** Lines were placed on the dorsal rhinotheca to demonstrate the rostral migration of the upper layer of the rhinotheca during growth. Note that the dorsal plates migrate straight to the tip. 1) Marks were placed on the beak and evaluated at: 2) two weeks, 3) one month, 4) two months and 5) ten weeks. **b)** Marks were placed on the lateral rhinotheca to demonstrate the difference in migration of the lateral and dorsal plates of the beak. Note that the lateral plates migrate in a curvilinear fashion toward the cutting edge of the rhinotheca. 1) Marks were placed and evaluated at 2) one month, 3) six weeks and 4) two months (modified from Lüdicke<sup>33</sup>).

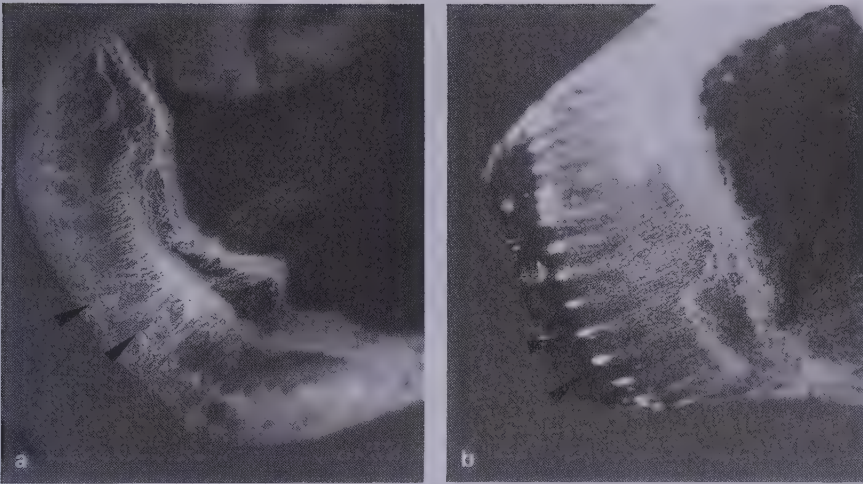


**FIG 24.4** Ridges on the occlusal surface of the upper beak of some psittacine birds are believed to function in holding food and sharpening the edge of the lower beak.

which should be considered when manipulating the tip of the beak.

The horny tissue of the beak is generated from two locations. The hard outer horn is produced by the epidermis and grows toward the rim (cutting surface). A softer keratin that surrounds the papillae of the bill tip organ originates from the keratinized epidermis (Figure 24.3).<sup>28</sup> The beak should remain in proper condition without trimming in birds that are maintained on a formulated diet supplemented with fresh fruits and vegetables, exposed to adequate periods of sunlight, allowed to bathe regularly and provided with hard woods to chew.

Any companion bird that requires repeated beak trimming should receive a thorough diagnostic evaluation to detect the underlying management, nutritional or systemic abnormality that is causing excessive beak growth or improper beak wear. Overgrowth of the lower beak may lead to occlusion of the openings to the bill tip organ and a loss of function. To improve the sensory capacity of the bill tip organ, the lower beak should be included in routine grooming activities if the beak is overgrown.



**FIG 24.5** a) The bill tip organs are barely visible on the occlusal surface of an overgrowing lower beak in a Hyacinth Macaw. b) After trimming, the bill tip organs are distinct (arrows).

The recently hatched neonates of most bird species have a small pointed eminence on the dorsal surface of the upper beak (egg tooth) that is used during the hatching process to penetrate the shell (see Color 30). The egg tooth regresses in Galliformes, Psittaciformes and Passeriformes during the first week of life. Some birds, megapodes for example, lack an egg tooth; these neonates are believed to use the feet to kick their way out of the egg.

Abnormalities of the beak are caused by:

- Malformation (often due to nutritional disorders)
- Primary viral infection
- Overgrowth (associated with a high-protein diet in some frugivorous birds, believed to be secondary to malnutrition or organopathy [liver] in many species)
- Fracture or puncture (usually traumatic).

Color changes in the beak of some species (toucans, lorikeets) may be associated with malnutrition or systemic disease. Bacterial or fungal infections of the beak are usually secondary to injuries that result in damage to the horny layer of the beak<sup>3</sup> (see Chapter 42). Bragnathism and scissors beak occur commonly in some neonatal psittacines (see Chapters 30 and 42). A discussion of the diseases of the beak is provided in Chapter 19.

## ■ Skin

Developing dermal cells (keratinocytes) undergo a metamorphosis from a cuboidal to squamous nature, and in the process lose cellular organelles, produce

lipids and fibrous proteins (keratin) and finally dehydrate and lyse.<sup>62</sup> Although avian skin is noted for its paucity of glands, it has been suggested that the lipid production by the keratinocytes (a function unique to birds) makes the entire skin an oil-producing holocrine gland.<sup>37,44</sup> The lipids produced by the keratinocytes are combined with oils secreted by the uropygial gland to form a thin film that is deposited over the feathers.<sup>62</sup> In poultry, lipid production has been found to be higher in thin skin that must be kept supple than in thicker skin that is relatively rigid.

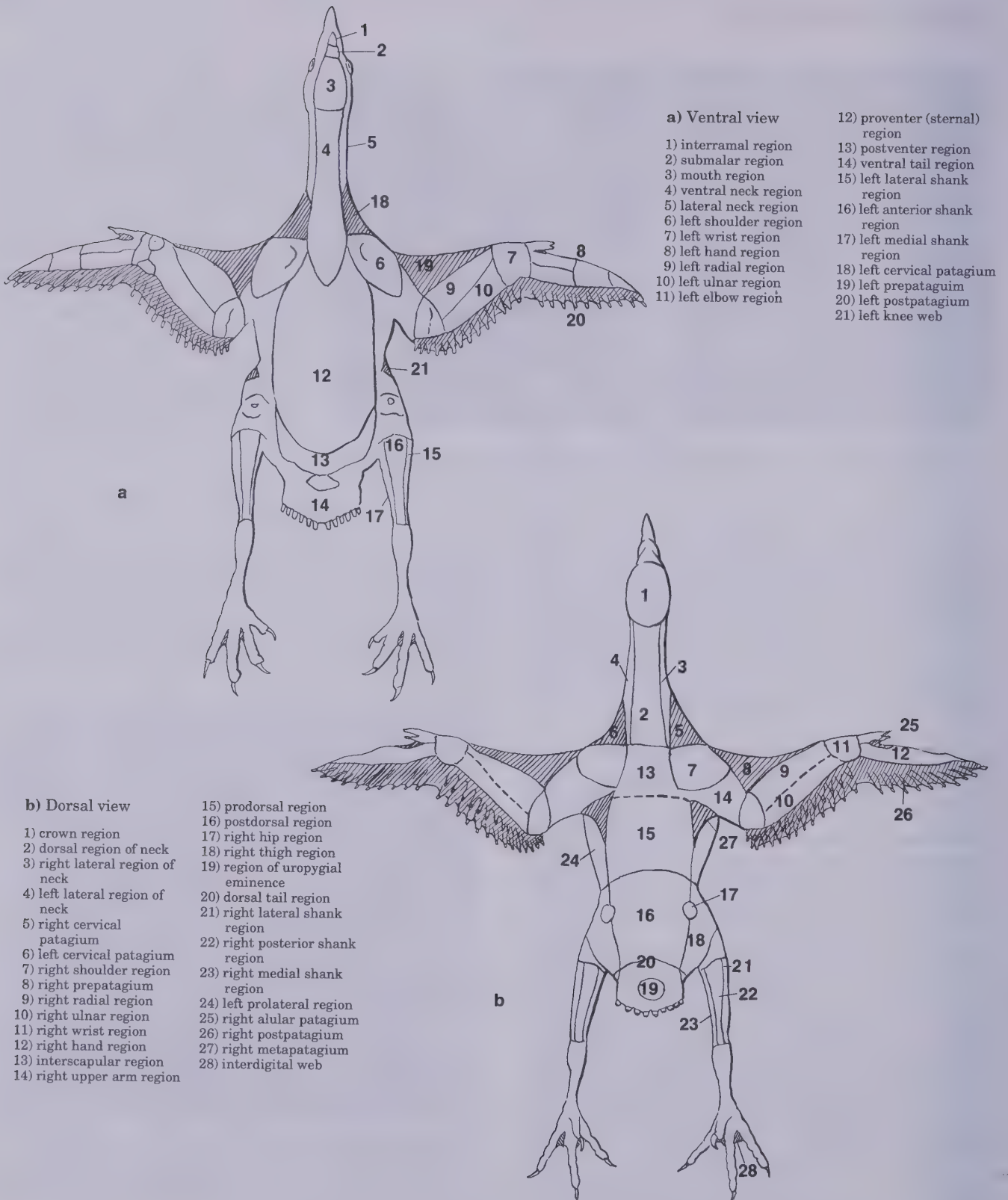
In combination, lipids from the keratinocytes and uropygial gland secretions are believed to waterproof the feathers, inhibit the growth of bacteria and fungi and maintain proper moisture content and pliability of the feathers.<sup>37</sup> It can be theorized that the severe and generalized feather pathology associated with systemic diseases (eg, organopathy, malnutrition) is a result of improperly functioning keratinocytes.

## ■ Patagia

Skin may be reflected into flat, membrane-like structures (patagia) in areas where the wings, legs, neck and tail join the body.<sup>32</sup> The wing has four patagia: the prepatagium (wing web), where the neck and wing join the thorax; the postpatagium, formed at the caudal angle of the wrist; the metapatagium, at the caudal junction of the wing and the thorax; and the alular patagium, at the interspace between the alula and the metacarpi (hand) (Figure 24.6). A cervical patagium is located anterior to the shoulder in the angle between the neck and the scapula.

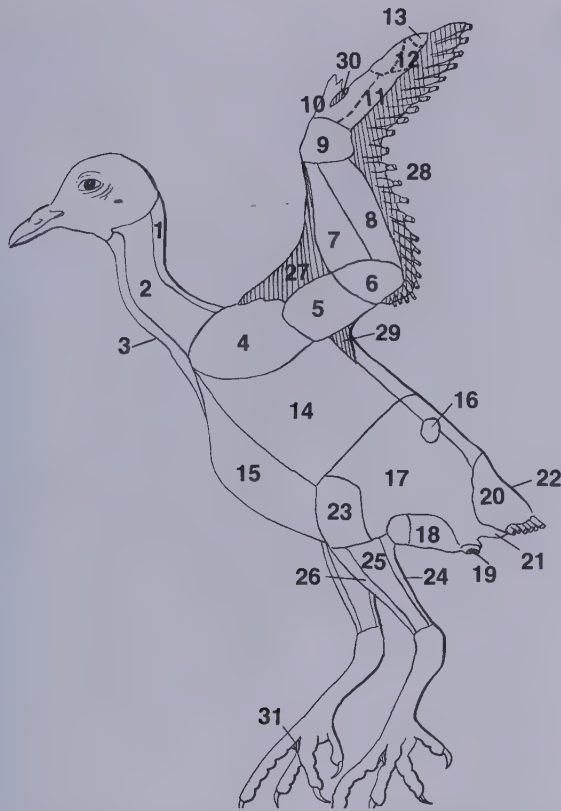
A similar structure is formed by the skin connecting the knee to the prolaral region of the paralumbar area (knee web). This is a transitory structure that is formed when the leg is in certain positions. It is called a web to differentiate it from a patagium, which is always present regardless of the position of the limb.<sup>32</sup> A groin web may be formed by the skin extending from the sternal region to the medial surface of the thigh (Figure 24.6).

Patagia and webs represent sites of major skin flexion and can be used clinically for subcutaneous injection



**FIG 24.6** a) Ventral, b) dorsal and c) lateral (next page) drawings of the pigeon showing the location of patagia, webs and regions of the body that should be used in describing integumentary lesions. Some of the patagia are common sites of chronic ulcerative dermatitis lesions (modified from Lucas and Stettenheim<sup>32</sup>).





## c) Lateral view

- |  |                                 |
|--|---------------------------------|
| 1) dorsal region of neck                 | 15) proventer (sternal) region  |
| 2) lateral region of neck                | 16) hip region                  |
| 3) ventral region of neck                | 17) thigh region                |
| 4) left shoulder region                  | 18) postventer region           |
| 5) left upper arm region                 | 19) vent                        |
| 6) left elbow region                     | 20) dorsal tail region          |
| 7) left radial region                    | 21) ventral tail region         |
| 8) left ulnar region                     | 22) uropygial eminence          |
| 9) left wrist region                     | 23) left knee region            |
| 10) left region of metacarpus, digit III | 24) left posterior shank region |
| 11) left region of metacarpus, digit IV  | 25) left lateral shank region   |
| 12) left region of P1, digit III         | 26) left anterior shank region  |
| 13) left region of P2, digit III         | 27) left prepatagium            |
| 14) left prolatateral region             | 28) left postpatagium           |
|  | 29) left metapatagium           |
|  | 30) alular patagium             |
|  | 31) interdigital web            |

tions or tattooing. These anatomic areas as well as the ventral tail region appear to be frequent sites for the occurrence of ulcerative dermatitis.

### Uropygial Gland

The uropygial gland is a bilobed gland located at the base of the tail dorsal to the pygostyle. The gland is absent in many Columbiformes, Amazon parrots and other Psittaciformes. This holocrine gland opens to the outside through a caudally directed nipple that is frequently surrounded by a tuft of feathers (Figure 24.7). Its secretions are spread by preening (grooming) and are considered to serve a waterproofing

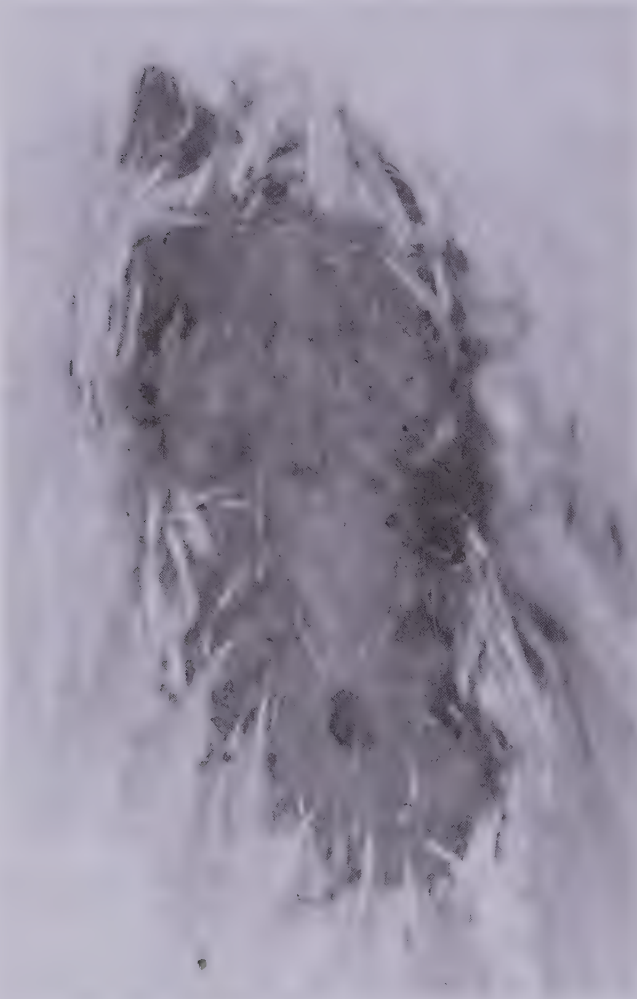

**FIG 24.7** The uropygial gland is located on the dorsal surface of the bird at the base of the tail (arrow). The opening to the gland is frequently surrounded by a tuft of feathers (open arrow).

function. Additional secretions from the skin and the uropygial gland are believed to suppress the growth of microorganisms. Uropygial gland secretions contain vitamin D precursors that are spread through the feathers, converted to an active form following exposure to ultraviolet light and ingested with subsequent preening activity.

Abnormalities associated with the uropygial gland include neoplasm (primarily squamous cell or adenocarcinoma), abscessation and impactions. A presumptive diagnosis of uropygial gland abnormalities can be based on microbiological culture and cytologic examination of exudate, an aspirate or a biopsy.


Impacted glands are frequently discussed in the literature but appear to be uncommon clinically. The gland is normally swollen and appears as though it may need expressing. In some birds, hyperkeratotic plugs may form in the gland. These cases will generally respond to removal of the plug and improving the bird's diet. An African Grey Parrot with widespread feather loss and a cystic uropygial gland failed to



**FIG 24.8** The body is divided into areas that contain feather tracts (pterylae) and areas that do not contain feather tracts (apteria). The division between feather tracts is evident on the back of this lutino cockatiel with pruritic dermatitis (courtesy of Louise Bauck).

respond to extensive treatment that included laser therapy, but recovered three months later after a deficient diet was corrected.<sup>32</sup> Uropygial gland rupture has been described in Gentoo Penguins and in free-living seabirds in Europe (Cooper JE, unpublished).<sup>34</sup>

Surgical extirpation of the gland may be necessary if neoplasia occurs (see Chapter 41). In ducks, removing the gland will cause the birds to lose the ability to waterproof their feathers. In other birds, removal of the gland seems to have few clinically detectable effects.<sup>32</sup>



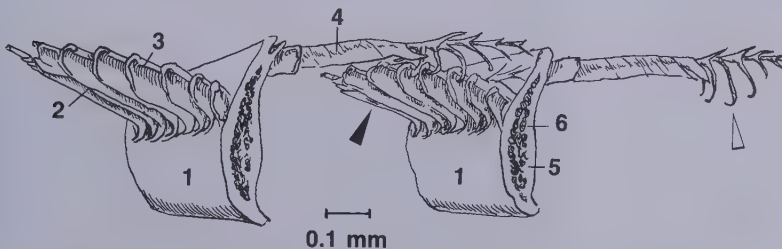
**FIG 24.9** Anatomy of a contour feather: 1) rachis 2) calamus 3) posterior umbilicus and 4) afterfeather. The pennaceous portion of feather (arrow) and plumaceous portion of feather (open arrows) are also evident. The rachis and calamus form the shaft. The pennaceous and plumaceous portions of the feather form the vane (modified from Lucas and Stettenheim<sup>32</sup>).

## Feathers

The three principal functions of the feathers are flight, insulation and waterproofing. Feathers may also function in courtship, defense (color mimicking) and aggressive territorial behaviors. In most birds, the body is divided into areas that contain feather tracts (pterylae) and areas that do not contain feather tracts (apteria) (Figure 24.8). The location of feather tracts varies among avian families. By originating from tracts rather than being scattered randomly over the body, feathers can smoothly overlap each other and conform to the natural contours of the



**FIG 24.10** Damaged feathers in a malnourished cockatoo. These lesions are frequently blamed on an enclosure of insufficient size. The central shaft of the feather is called the rachis (arrow). The barbs (open arrow) branch from the rachis. The barbs are connected to each other by the barbules. Where the barbs are connected, the barbules are intact. Those that are not connected have damaged barbules.



**FIG 24.11** The 1) cut end of two barbs showing the interlocking nature of the barbules (arrow). The 2) posterior barbules contain 3) ridges that connect with the hooks (open arrow) found on the 4) anterior barbules. This interlocking mechanism makes the feathers waterproof and improves their insulating capacity. 5) Cortex and 6) pith (modified from Lucas and Stettenheim<sup>32</sup>).

body. The spaces between the tracts can facilitate the clinical evaluation of the skin. A single featherless region and its underlying integumentary components is called an **apterium**.

Terms used to describe parts of a feather are listed in Table 24.1.

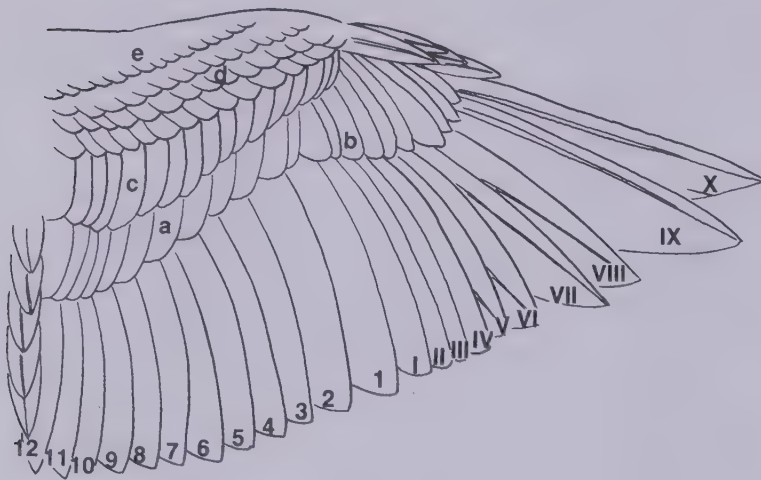
The feather is composed of a long, central tapering shaft that is divided into the hollow base (quill, calamus) and an angular central shaft (rachis) (Figure 24.9). Barbs branch from both sides of the rachis, and barbules branch from both sides of the barbs (Figure 24.10). The anterior, middle and posterior portions of the barbule vary in structure. The anterior and mid-

dle barbules contain barbicels (hooks), which are missing in the posterior barbules. The posterior barbules contain ridges, to which the anterior barbicels are attached in a zipper-like fashion.

A feather appears as a unified sheet of tissue because of the interlocking barbules that hold the barbs together to form the vane on either side of the feather shaft. The interlocking nature of the barbules serves to waterproof the feathers, forming a type of thatched roof (Figure 24.11). The interlocking barbules also serve to improve the insulating capacity of the feathers and create an aerofoil to facilitate flight (see Chapter 8).

The feathers can be characterized based on the structure of the rachis, barbs and barbules, and are divided into ten feather types.<sup>32</sup>

- **Contour feathers** represent the predominant feathers that cover a bird's body. They are the largest feathers and have a well developed shaft, pennaceous and plumulaceous components of the vane and an afterfeather.
- **Coverts** are the small contour feathers that are found in rows on the wing and tail.
- **Remiges** are large, stiff, well developed feathers found in the wing and are principally responsible for flight. These feathers are generally asymmetric in form and have an entirely pennaceous vane. The remiges that arise from the periosteum of the metacarpus are called primaries, and those that arise from the periosteum of the ulna are called secondaries. The primaries are counted from proximal to distal (digits), while the secondaries are counted from distal (carpus) to proximal (elbow) (Figure 24.12). The number of primary and secondary feathers varies among species.
- **Rectrices** are large flight feathers found in the tail. They are structurally similar to the remiges. Tail feathers are counted from the center laterally.



**FIG 24.12** Dorsal view of the feathers of the wing: primaries (Roman numerals); secondaries (numbers). a) greater secondary coverts b) greater primary coverts c) median secondary coverts d) lesser secondary coverts and e) marginal coverts (modified from Lucas and Stettenheim<sup>32</sup>).

- **Downs** (juvenile and definitive) are small, fluffy, wholly plumulaceous feathers with a short or absent rachis. Natal downs are present at or soon after hatching and are replaced during the first molt. Definitive down feathers occur on various parts of the body as part of the adult plumage. They are evenly distributed in parrots and waterfowl, confined to tracts in gallinaceous birds and sparse or absent in some pigeons and passerines.
- **Powder down** are specialized down feathers that disintegrate and produce a powder (keratin) that is spread through the feathers during preening. They are found throughout the body among the down and contour feathers. African Grey Parrots, cockatiels and cockatoos have the most abundant powder down feathers. Birds with damaged powder down feathers frequently have soiled-appearing feathers, suggesting their involvement in the maintenance of normal feather condition.
- **Semiplumes** have a long rachis and entirely plumulaceous vane. They occur in feather tracts of their own or are found along the margins of contour feather tracts. They provide insulation.
- **Hypopnea** (afterfeathers) are structures attached to the underside of a feather at the superior umbilicus. They may consist only of barbs or have a shaft and plumulaceous barbs.
- **Filoplumes** are fine, hair-like feathers with a long rachis and a tuft or barb on the tip. They

generally accompany contour feathers in most species. They are believed to serve a proprioceptive function.

- **Bristles** are characterized by a stiff, tapered rachis with no barbs except at the proximal end. They are usually found around the mouth, nostrils and eyes and are believed to serve a sensory function.

The feather follicles are formed by invaginations of the skin. The follicular wall has an abundant supply of sensory nerve fibers, and the papillae, pulp and feather muscles are also well innervated.<sup>32</sup> Smooth muscles at the base of the feather follicles help maintain body temperature by increasing or decreasing the elevation of the feathers from the skin.

Herbst's corpuscles at the base of feather follicles are believed to detect subtle ground vibrations and changes in air current. Changes in

**TABLE 24.1** Common Terms Used to Describe Portions of a Feather

<b>Calamus</b>	The short, tubular, unpigmented end of the mature feather that is inserted into the feather follicle and is thus present below the skin level.
<b>Rachis</b>	The long, solid, tubular portion of the shaft above the skin. It is a thickened continuation of the calamus external to the skin margin. The rachis contains pith, which is composed of air-filled keratinized epithelial cells surrounded by a solid keratinized outer cortex.
<b>Shaft</b>	The longitudinal central axis of a feather that is composed of the calamus and rachis. The calamus and proximal portion of the rachis are vascularized in the developing feather (pin feather).
<b>Vane or vexillum</b>	The portion of the feather that extends to either side of the rachis and is composed of the barbs and their associated structures. The vane is either plumulaceous (soft, downy) or pennaceous (compact and closely knit) depending on the individual type of feather.
<b>Pulp</b>	The mesodermal component of the growing feather consisting of vascular connective tissue. The pulp regresses as the feather grows and is absent in the normal mature feather.
<b>Pulp caps</b>	Keratinizing epidermis that covers the distal extremity of the pulp. As the pulp regresses, the keratinized caps remain and are visible as horizontal bars crossing the lumen of the calamus.

**TABLE 24.2 Feather Coloration as a Result of Pigments and Structural Features****Pigments**

- **Melanins**  
Alone, dull. When combined, create black, brown, reddish brown, yellow, red, purple and chestnut red-appearing colors. These pigments make feathers more dense and resistant to wear.
- **Carotenoids**  
Bright red, orange, yellow. Cannot be synthesized and must be derived from ingested plants. Carotenoids have growth-promoting properties and impart a green color.
- **Carotenes and xanthophylls**  
Xanthophylls are more readily absorbed from food than carotenes. Yellow = lutein.
- **Porphyryns**  
Red and brown, true green.

**Structured Color**

- Due to the physical separation of the components of white light reflecting from or passing through the feather:  
Iridescent colors change with the angle of view; eg, blue.  
Noniridescent colors do not change with the angle of view (eg, green, purple and violet).

electroencephalographic activity following the removal of feathers suggest that it is a painful procedure.<sup>16</sup> Clinically, the removal of a feather will frequently stimulate movement in an anesthetized bird at the same anesthetic plane that can be used to perform surgery.

### Feather Color

The color of feathers is determined by two factors: the pigments that are deposited at the time of development, and structural features of the feather that alter the absorption or reflection of light (Table 24.2). These structural features of the feather can be inherent in the development of the feather or can be induced by materials that are placed on the feathers after development. If a feather reflects all wavelengths of light, it appears white; if it absorbs all wavelengths of light, it appears black. Dark-colored feathers appear to be more durable than light-colored ones.

The pigmentation of feathers may serve to absorb or repel heat (light), warn predators, act as a camouflage or function in mating displays. The capacity of the barbs and barbules to scatter and reflect varying wavelengths of light causes the iridescent glow of the feathers. Blue colors are created by the barbs interacting to reflect blue light while allowing other wavelengths of light to be absorbed by darker melanin granules. Green colors may be created by pigments, or more commonly through the combination of blue (from structural characteristics) and yellow pigments.

Colors tend to be brightest and boldest on the exposed surfaces of the feathers and paler on the ventral surface. Some red coloration in the appendages of birds is caused by vascularization and not pigment disposition. Pinching the tissue and observing for blanching can be used to determine if an area is vascularized.

The normal iridescent glow of the feathers may be induced in part by lipids derived from the keratinocytes. This “glow” is frequently absent in birds with clinical abnormalities and returns as a bird responds to therapy. The sheen of dark feathers has been suggested to be caused by the fat-soluble red and green pigments that are either synthesized by the bird (melanins and porphyryns) or absorbed from food (carotenes and xanthophylls).<sup>44</sup>

It is interesting to note that abnormally colored feathers may return to normal without a molt. This is particularly common in cockatiels with feathers that are stained yellow secondary to chronic biliverdinuria (liver disease) (see Color 8). As birds respond to therapy for hepatitis, these feathers will return to a normal white coloration, presumably because biliverdin-laden, keratinocyte-produced lipids are replaced with lipids that do not contain biliverdin.

Yellow or red pigments derived from the uropygial gland can be spread on the feathers where the pigment remains bright until it fades due to oxidation from exposure to air and light. In a healthy bird, feathers maintain their bright pigmentation through the addition of newly synthesized oils during preening. These mechanisms for imparting color to a feather would allow changes in feather pigmentation to occur without a bird undergoing a molt.<sup>32</sup> Birds receiving higher fat diets would be expected to produce a lipid-rich, keratinocyte-derived uropygial gland secretion that may enhance the color and sheen of the feathers.

In poultry, a lack of pigmentation (achromia) has been associated with dietary deficiencies in lysine, folic acid and iron.<sup>63</sup> Lysine deficiency has not been found to alter the pigmentation of cockatiel feathers but deficiencies of choline or riboflavin will cause abnormal pigmentation (see Chapter 31). Both melanism and albinism have been reported in a variety of captive and free-ranging species.

Peach-faced Lovebirds may develop red patches on their normally green plumage, and both diet and blood parasites have been suggested as a cause of this

condition. Abnormal yellow, red and pink feathers may be noted in Amazon parrots and African Grey Parrots, and it has been suggested that these are associated with hepatopathies, renal dysfunction or systemic disease. Psittacine beak and feather disease has been implicated in some cases of the abnormal occurrence of red feathers in African Grey Parrots.<sup>29</sup> Excess dietary levels of beta carotene can cause a similar feather change.

### Molt

Soft keratin structures (skin, comb, wattles, cere) undergo constant replacement through the sloughing of the outer cornified layer (Figure 24.13). Old or damaged outer layers of hard keratin structures (rhamphotheca and metatarsal spurs) are replaced through normal wear. The thick, horny heel pads on the back joints of woodpecker, toucan and barbet neonates are molted at fledging. In cases of malnutrition or systemic disease, hyperkeratotic layers of the rhamphotheca can accumulate and be peeled off with a blunt instrument.

Molting is the process whereby the growth of a new feather causes the shedding of an old feather. The single generation of feathers that occurs as a result of a molt is collectively known as plumage. At any one time, a bird may have feathers derived from more than one molt. This is because some molts involve all of the feather tracts, while others involve only certain tracts or specific feathers. Collectively, the feathers present on the body at one time, regardless of when they first appeared, are called the feather coat.

A new feather that is still enclosed in a feather sheath is called a pin feather (Color 24.5). The physical characteristics and appearance of the feather are controlled by factors that affect the development of the feather at the edge of the epidermal collar. Any infectious agent or systemic abnormality that alters the nutrients or blood supply available to the developing feather will alter its appearance. Additionally, damage to the epidermal collar will be manifested clinically as an abnormal feather.

Feathers grow from the base and mature in an upward and outward fashion (Figure 24.14). The developing feather is composed of the outer epidermis and the inner pulp. The barb ridges, rachis and hyporachis are formed by the epidermis as it grows longitudinally. Lateral growth from a basal layer forms the keratinized sheath.

Once a new feather has been stimulated to grow in the follicle, the molting process is purely mechanical

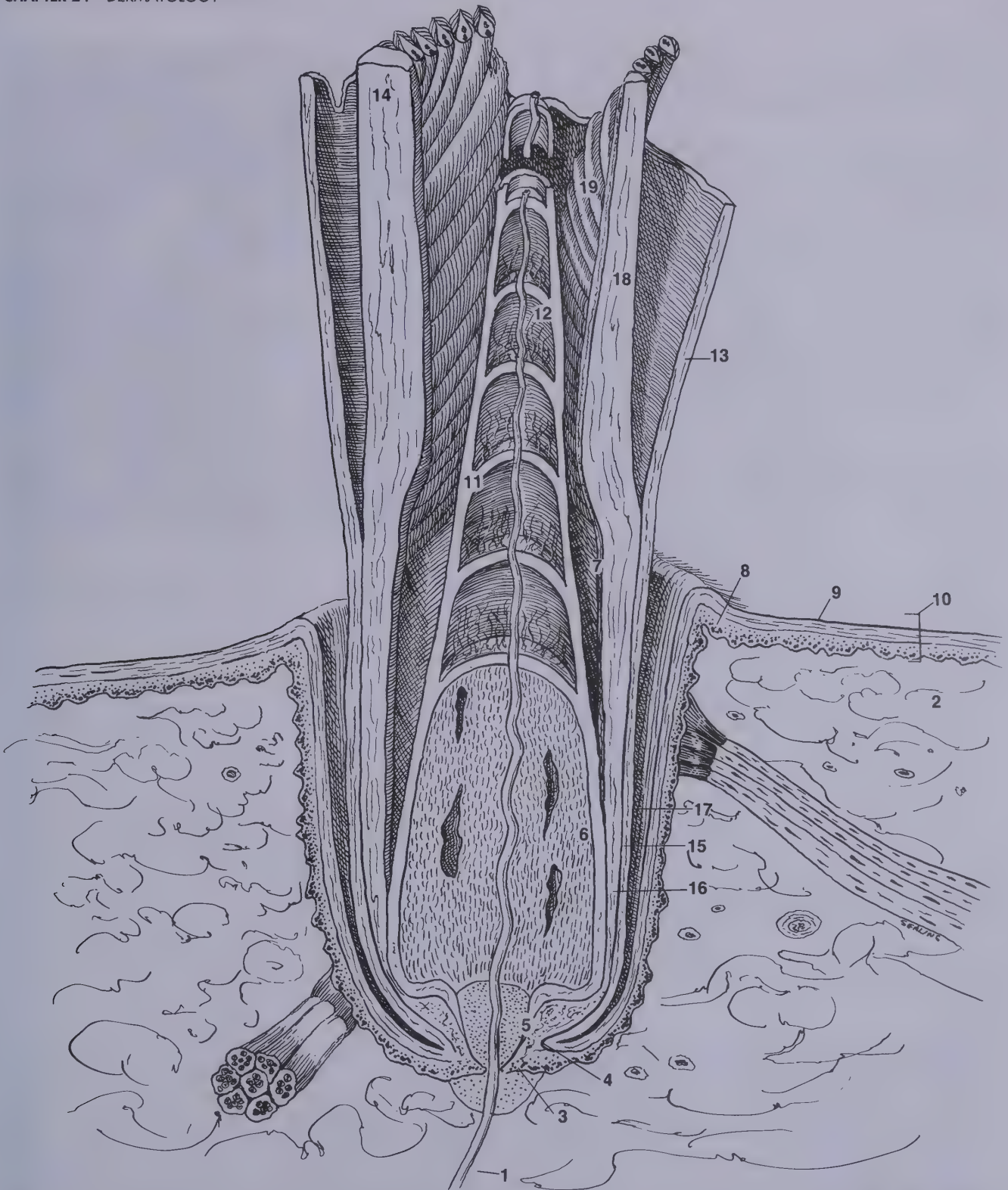


**FIG 24.13** The epidermis of birds is normally replaced on a constant basis. Excessively dry, flaky skin can be an indication of malnutrition or organopathies. In this cockatoo, a heavy molt and sloughing of sheets of the epidermis were induced by changing the bird from a wild-bird seed to a formulated diet.

and is strictly dependent on the developing generation of feathers; thus, the pattern of molt should be defined based on the *developing* feathers (which control the molt cycle) and not on the *shedding* of a feather (which has nothing to do with the molt unless the feather has been mechanically removed).

### Molting Periods

The molting process can be divided into periods. The first molt occurs shortly after hatching and involves the replacement of the natal down, resulting in the second plumage (the first plumage would be the natal down). A parrot in its second plumage appears smaller than an adult because the feathers are reduced in length and width at this stage of development. The second molt in a juvenile leads to the third plumage, which is a divided process with many second and third generation feathers being present at the same time. The third molt occurs with the growth of the fourth generation of feathers, which should



**FIG 24.14** Illustration of the layers of feather development: 1) nutrient (axillary) artery 2) dermis 3) inferior umbilicus 4) epidermal collar 5) dermal papilla 6) pulp 7) calamus 8) germinative layer 9) corneous layer 10) epidermis 11) pulp cap 12) remnant of the axillary artery 13) degenerating feather sheath 14) rachis 15) intermediate follicular epithelium 16) basilar follicular epithelium 17) sheath follicular epithelium 18) hyporachis and 19) barb of vane (modified from Lucas and Stettenheim<sup>32</sup>).

result in the development of mature plumage in a normal bird. Malnutrition may cause the adult plumage to be incomplete or abnormal.

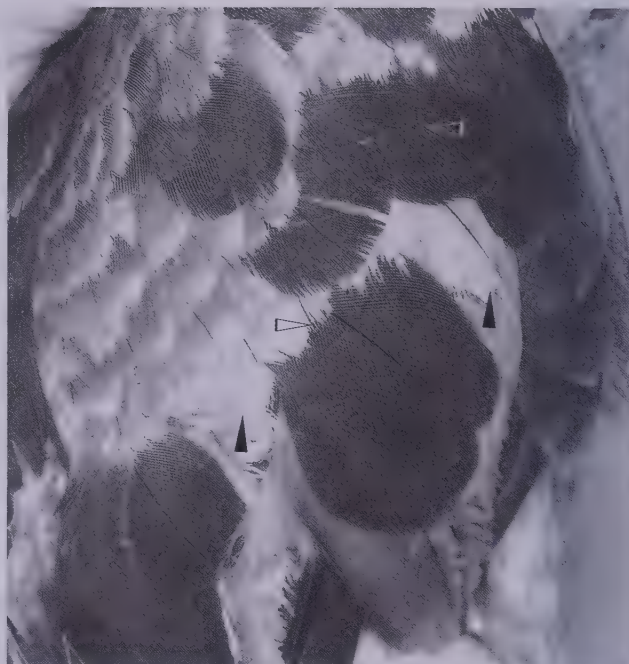
The molting process in adult birds occurs on a cyclic basis. A molt cycle is defined as the period that runs from the appearance of a plumage to the appearance of its replacement. The cycle length for most birds is one year; however, some species will molt throughout the year, while others will molt annually or several times a year during distinct periods. Large Psittaciformes may have a two-year molt cycle. Powder down feathers are shed continuously. Most authors theorize that replacement of the adult plumage is synchronized with the gonadal cycles and will be longer or shorter than one year based on reproductive activity; however, molting may be more dependent on photoperiod. Domesticated birds that reproduce year round under artificial lighting conditions may not undergo the seasonal molt that would be expected to occur in their free-ranging conspecifics.

In general, the molting process of the flight and tail feathers starts with the proximal primaries on both wings and progresses until about half of the primaries are replaced. The secondary feathers are then molted in a distal to proximal progression. The body feathers begin to molt after the wing feathers are actively being replaced. The tail feathers are replaced from the central feathers outward. By having a progressive molt, birds are able to continue flying while the feathers are being replaced. In some waterfowl and seabirds, all of the flight and tail feathers are replaced at one time, and these birds go through a period of flightlessness. Penguins molt randomly.

Malnutrition can impact the speed of molt and the health of the developing feathers. The molt period increases a bird's metabolic rate and demand for protein. Birds that are on diets that contain insufficient energy or protein might undergo a partial molt of shorter than normal duration.<sup>5,65</sup>

Companion and aviary birds may have abnormal molts caused by unnatural lighting conditions, malnutrition and environmental or disease-related stress factors. Many companion birds will have a new generation of feathers on the head and neck, with several generations of old feathers on the wings and body (Figure 24.15).

Molting has been suggested to be an autonomous process within the feather papillae, which may be triggered by seasonal changes. If the physiology of the papillae were to change in preparation for feather



**FIG 24.15** A malnourished African Grey Parrot with light brown feathers (arrows) in place of the normal slate gray feathers. The bird was placed on a formulated diet and the newly developing feathers are correctly pigmented (open arrows).

growth, it might become increasingly sensitive to certain secretions (thyroid hormone, sex hormones) that could then potentiate the growth of a new feather.<sup>32</sup>

The occurrence of a cyclic rather than systemically controlled molt seems clinically feasible given that all the feathers do not molt at the same time from all locations. The feathers appear to molt in sections starting with the head, neck and thorax, followed by the wing and tail feathers. The molt in each anatomic location may occur at varying times, and some pterygiae may undergo several plumage replacements before any feathers are molted from another area.

### Control of Molt

The control of molting is extremely complex and only partially understood. The process probably involves a combination of hormonal, seasonal, nutritional and local (feather follicle) factors. The effects of individual hormones on the molt cycle appear to vary widely among avian genera, and information derived from studies in one species should be cautiously applied when evaluating clinical abnormalities in another species.



Specifically, the precise role that thyroid hormone plays in the molting process appears to vary among species. This hormone may affect the shape, structure, formation of pigment, color patterns and rate of growth of feathers. In fowl, administration of thyroid hormone may induce a molt in seven or eight days. If the thyroid is removed, feather formation on the body stops but the molt of wing feathers will continue, suggesting that their replacement is not controlled by thyroid hormone. Administration of high concentrations of thyroxine will increase the speed of the molt cycle. These findings suggest that thyroid hormone is important in initiating a molt; however, other studies indicate that progesterone and prolactin can induce a molt without a change in circulating levels of thyroid hormone.<sup>32</sup>

In a study of King Penguins, it was found that thyroxine levels rose significantly (five times resting levels) during the molting period, and corticosterone levels increased at the end of the molt.<sup>5</sup> In other studies, it has been demonstrated that thyroid activity (as measured by thyroidal uptake of radioactive iodine) did not differ appreciably between molting and non-molting hens. These apparent conflicts in experimental findings may suggest that research protocols, no matter how effectively conceived, may not accurately reflect the natural mechanism of molting.

Feather formation is prevented by circulating estrogens. Progesterone will stimulate feather growth in follicles that are already replacing a feather but will not stimulate feather development. Molts are sluggish and prolonged in fowl exposed to 12 to 14 hours of light. The effect of photoperiod on normal molt in companion birds that originate from widely varying geographic regions is undetermined. In studies in poultry, plasma prolactin, growth hormone and LH levels decrease, and testosterone and thyroxin levels increase, during the molt. Molting activity can be induced by high doses of medroxyprogesterone, decreased exposure to light or administration of thyroxine or prolactin.<sup>24</sup> Luprolide has been found to decrease the size of the ovary, elevate circulating testosterone levels and induce a molt.<sup>37a</sup>

The nervous system may serve as a mediator between the rhythmic environmental events (principally photoperiod) and the hormonal activities of the thyroid and gonads that all combine to facilitate molting. Birds that are stressed by handling during a molt may lose more feathers than birds that are in a relaxed atmosphere. Some birds are able to release feathers when being restrained (fear or stress molt).

## General Diagnosis and Therapy

### Investigation of Dermatologic Disease

Integumentary diseases can be broadly classified as being caused by infectious or noninfectious agents (Table 24.3). In many cases, dermatologic lesions are secondarily infected with bacterial or fungal agents, and the identification of microbial agents from cultures of the skin does not necessarily implicate these organisms as the precipitating cause of the lesions.

Using a dermatology examination form is a concise way to consistently evaluate and record integumentary lesions. Making drawings or taking photographs is an effective method of recording the precise location and the effects of therapy on skin lesions. By using a standardized form and evaluation system, avian veterinarians and dermatologists can more effectively quantify and compare their findings, which will ultimately lead to improved clinical description, diagnosis and treatment of skin and feather diseases.

The predilection to develop certain types of integumentary diseases may vary among species (Table 24.4). The diagnostic evaluation used for avian dermatologic diseases is similar regardless of the etiology (Table 24.5). The evaluation of feather and skin lesions, particularly in small birds, can be facilitated by the use of a magnifying loupe. Inflammation of the skin can occur as a result of trauma, chemical irritation, bacterial, fungal, viral or parasitic agents. Pericloacal inflammation may be associated with the accumulation of excrement.

Cytology, culture and biopsy are indicated in cases of dermatitis. Cultures should be obtained by removing

TABLE 24.3 An Etiologic Approach to Integumentary Diseases

Infectious	Non-infectious
Viral	Traumatic
Mycoplasmal	Chemical/toxic
Chlamydial	Nutritional
Bacterial	Hormonal
Fungal	Developmental/genetic
Protozoal	Irradiation
Metazoal (parasitic)	Neoplastic
	Immune-mediated
	Behavioral
	Allergic

TABLE 24.4 Common Integumentary Diseases by Order

**Passeriformes**

Poxvirus  
*Knemidokoptes* infection  
 Papillomatosis (pedal)  
 Damaged nails and beak  
 Constricted feet and digits  
 Hyperkeratinization associated with malnutrition  
 Bacterial dermatitis (often secondary to above)  
 Loss of feathers around the head and neck - malnutrition  
 Dermatophytes  
 Trombiculid mites

**Galliformes**

Poxvirus  
*Knemidokoptes* infection  
*Dermatonyssus* and *Ornithonyssus* infection  
*Echidnophaga gallinacea*  
 "Bumblefoot" syndrome  
 Contact dermatitis  
 Malnutrition  
 Skin tumors  
 Xanthomatosis  
 Viral (Marek's disease, reticuloendotheliosis)  
 Genetic  
 Enlarged sternal bursa

**Anseriformes**

Malnutrition  
 "Bumblefoot" syndrome  
 "Wet feather"  
 Vesicular dermatitis and photosensitization  
 Leech infestation

**Raptors**

Malnutrition  
 Poxvirus  
 "Bumblefoot" syndrome  
 Gangrene of wing  
 Tuberculosis  
 "Blain" (bursitis of carpus)  
 Damaged nails and beak

**Columbiformes**

Poxvirus  
 Feather defects associated with PMV infection  
 Salmonellosis  
 Neoplasia including melanomas

**Ratites**

Poxvirus  
 Malnutrition

TABLE 24.5 Dermatology Database

**Systemic**

Physical examination  
 CBC, AST, LDH, UA, bile acids, CPK  
 DNA probe for PBFV virus  
 DNA probe for polyomavirus  
 Gram's stain of feces  
 Fecal examination for parasites  
 Radiographs  
 Thyroid levels - TSH test

**Specific Integumentary Examination**

Microscopic (operating or dissecting) examination of feather for parasites  
 Cytology of pulp cavity (bacterial and fungal)  
 Bacterial and fungal cultures of feather pulp  
 Histopathology of biopsy specimens (skin and follicle)  
 Electron microscopy of feather sections

**General Therapy for Integumentary Lesions**

In most cases, the therapy for feather and skin abnormalities caused by a number of factors is similar, with modifications necessary only to resolve specific disease agents. These general therapeutic considerations include:

- Correcting any nutritional deficiencies by administering parenteral multivitamins, minerals (trace minerals) and placing the bird on a formulated diet supplemented with some fruits and vegetables.
- Removing the bird from all exposure to aerosolized toxins that may accumulate on the feathers and skin and cause irritation (eg, cigarette smoke, kerosene fumes, cooking oils).
- Ensuring that the bird has frequent exposure to sunlight, and that a regular bathing program is instigated.
- Identifying and correcting any behavioral abnormalities that are causing over-grooming (feather picking).

any scabs, moistening the culturette in the sterile transport media and rolling the tip over the lesion. Moistened swabs will yield better results than dry ones, and it is important that the swab be plated as soon as possible after collection. A quick and inexpensive diagnostic technique in practice is to apply a microscope slide to the affected area and to examine it cytologically (see Chapter 10). Skin biopsies are most diagnostic if collected from the center and the periphery of the lesion.

Skin lesions should be kept clean, and creams, lotions or solutions can be used to moisturize and sooth dry, irritated skin and reduce pruritus and discomfort. Any medications placed on a wound should either kill specific target microorganisms or protect healing tissue. Ointments and oily compounds interfere with normal feather function and should be avoided (Color 24.3). Some commonly used lavage agents, povidone iodine compounds for example, are effective in controlling bacteria, but may also impair healing by destroying fibroblasts and white blood cells (see Chapter 40).<sup>64</sup> Hydrophilic compounds are often of value in birds but should not be used on large open

wounds where they may potentiate dehydration and electrolyte imbalance.

Aloe vera gel, human skin softeners with a vanishing cream base, nystatin-neomycin sulfate ointment<sup>a</sup> (for pruritic lesions and moist dermatitis) and silver sulfadiazine cream<sup>b</sup> (for moist dermatitis and burns) are particularly effective topical medications. A mixture of Penetran and aloe vera may relieve severe pruritus in some cases (see Chapter 18). This therapy should be discontinued or the solution should be diluted further if a bird becomes depressed or lethargic. If a bird does not improve within 48 hours of initiating therapy, the preparation should be considered ineffective and discontinued.

If an infectious agent is identified, specific antimicrobial therapy should be initiated. In some cases of severe ulcerative dermatitis, surgical debridement and primary wound management may be necessary; however, surgery should not be considered until all other therapeutic modalities have failed to resolve the lesions over a six-month treatment period. Peeling, flaking skin and heavy molts are common for prolonged periods (up to a year) when a diet change is initiated in a malnourished bird.

Lesions should be evaluated regularly (generally on a weekly basis) to determine if prescribed therapy is effective. Trimming the tip of the beak to prevent a bird from self-mutilating or applying a neck brace is justified only as a last resort.

## Specific Etiologies of Generalized Dermatopathies

### Viral Diseases

Dystrophic feathers may occur in birds infected with PBFD virus, polyomavirus, adenovirus and a parvovirus (waterfowl). Dermatologic lesions may occur with poxvirus, papillomavirus and herpesvirus infections (see Chapter 32).

Young birds are most susceptible to PBFD virus, which is characterized by the progressive appearance of dystrophic feathers after a molt (Colors 24.7, 24.13). The disease progression can be acute or chronic depending on the age and species of bird. A diagnosis of PBFD is

made by demonstrating viral antigens or nucleic acid in affected tissues. DNA probes are available that can be used to detect the virus in circulating white blood cells (see Chapter 32).

Avian polyomavirus (budgerigar fledgling disease) causes feather pathology in some affected budgerigars and occasionally in large Psittaciformes (see Chapter 32).

“French moult” is a descriptive term used to describe feather dystrophy in young psittacine birds, primarily budgerigars.<sup>1</sup> The classic clinical changes include premature molting of the wing and tail feathers and associated hemorrhage and poor plumage (see Color 32). Affected young birds are termed “runners” because they are usually incapable of flying. Feather changes characteristic of “French moult” can be caused by PBFD virus, polyomavirus or both (Color 24.7). It should be noted that any factor (infectious or noninfectious) that damages the epidermal collar can result in a gross lesion resembling that induced by PBFD virus or polyomavirus (see Color 32).

There is no specific treatment for French moult. Techniques that are discussed in the lay literature, including dietary additives and careful selection of breeding stock, are probably futile. Good hygiene is advisable, and birds should be purchased from sources that test free of PBFD virus and polyomavirus (see Chapter 32).

Poxvirus can cause skin lesions in most avian species and may retard wound healing. Uncomplicated lesions are characterized by the formation of nodules on the unfeathered skin. Skin lesions should be kept clean and dry to prevent secondary bacterial or fungal infections (see Chapter 32).

Cutaneous papillomas may occur on the head, neck, beak commissure, feet or uropygial glands. Some of these lesions have been associated with papillomavirus or herpesvirus while others are of undetermined etiology. Therapy is generally limited to removal of the masses in birds in which they cause problems. A herpesvirus has been associated with “feather dusts,” and adenoviral folliculitis has been reported in lovebirds (see Chapter 32).

### Parasites

Wasps, bees or other stinging insects will occasionally attack birds causing characteristic hyperemic swellings (Color 24.17). Most affected birds heal with no therapy; however, in severe cases steroids may be

indicated to reduce inflammation. The likelihood of a bird being stung can be reduced by removing uneaten soft foods (particularly fruits) from the enclosure and destroying wasp nests found near the aviary.

Flies, mosquitoes and gnats can cause severe dermatitis on the face, feet and legs, particularly in birds raised in warm coastal areas (see Color 26.7). Lesions are most common in Amazon parrots and macaws, but can occur in any species. The flies that commonly parasitize cattle and deer can induce small bleeding ulcers on the unfeathered areas of the body (Color 24.17).

Ants (especially fire ants) can be a nuisance to nesting birds. If necessary, five per cent Sevin dust can be used in the nest box to prevent chicks from being eaten alive. Many affected chicks die, and those that survive may have localized necrotic areas that are secondarily infected with *Staphylococcus* spp. Topical application of antibiotic and steroid lotions or creams can be used to reduce swollen or hyperemic lesions. Ant bites also may cause localized necrosis that results in defects in the webs of the feet in waterfowl (Figure 24.16). Some helminths and mites can cause dermatitis (see Chapter 36).

A sarcoptid mite infection was described in a Grey-cheeked Parakeet with feather loss and flaking skin on the head and trunk. Severe pyogranulomatous dermatitis was associated with a sarcoptic mite infection in a Green-winged Macaw. The bird did not respond to ivermectin therapy.<sup>55</sup> Generalized alopecia and thickening of the calamus occurred in a Red-fronted Parakeet infected with *Knemidokoptes* spp. (see Chapter 36).

Mites are more likely to be a primary cause of dermatitis on the head than are lice. Control of ectoparasites, whether on the head or elsewhere, must be undertaken with caution. Only those parasitocidal agents that are licensed or recommended for use in birds should be applied, and such therapy must be accompanied by other measures to exclude the parasites.

In subtropical and tropical areas, the sticktight flea (*Echidnophaga gallinacea*) can be a problem on many species of birds.<sup>10</sup> This is a sessile flea, and large numbers may attach to the skin of the head, especially around the eyes, and cause anemia (see Color 8). This parasite can be controlled with the topical application of a pyrethrin-based product.



FIG 24.16 Defects in the interdigital webs in a duck secondary to multiple fire ant bites.

### Bacterial and Fungal Diseases

There have been remarkably few studies on the bacterial flora of the avian skin other than in poultry and birds of prey.<sup>39</sup> Surprisingly, fungi have attracted more attention, and several surveys on the fungal flora of free-ranging birds have been reported. In one study, 6000 fungi were recovered from the feathers, nests, pellets, droppings and organs of 92 species of free-ranging birds.<sup>23</sup> Several of the fungi isolated were potential pathogens and a number were keratinolytic.

Many authors have suggested theories to explain the apparent paucity of primary skin infections in birds, including a high body temperature, which might inhibit the growth of some organisms, and keratinocyte-derived lipids that may inhibit certain pathogenic bacteria or may provide appropriate nutrients for competitive autochthonous flora.<sup>54</sup> Bacterial and fungal infections of facial skin are usually secondary to trauma or possibly a contact dermatitis. Avian skin abscesses are rare but can be found following wounds or in association with feather cysts. Treatment is routine with surgical drainage or removal.

Although frequently discussed, documented cases of bacterial folliculitis in birds are rare. The pulp can be examined for the presence of bacteria by making impression smears or by culturing the pulp cavity<sup>67</sup> (Figure 24.17). Bacterial pathogens that have been implicated in folliculitis include *Staphylococcus* spp., *Aeromonas* spp. and *Mycobacterium* spp.<sup>13,44,60</sup> Dermatitis of the head and body was associated with mycobacteriosis in an Amazon parrot.<sup>14</sup> *Staphylococ-*



**FIG 24.17** A macaw was presented with dystrophic feathers. Numerous developing feathers were frayed, and the pulp cavities were split and contained dried blood and developing feather components. The pulp cavity of birds with this type of presentation should always be examined cytologically, and cultures should be submitted for bacterial and fungal isolation. The diet should be carefully evaluated in these cases.

*cus* spp. are frequently isolated from exudative ulcerative skin lesions of the patagial area (Color 24.23). The importance of staphylococci in the occurrence of these lesions has not been defined. Secondary fungal agents may also be recovered from these lesions.<sup>18</sup>

*Trichophyton* spp. (*flavus*) have been associated with scaly, crusty lesions of the wattle, comb and legs in gallinaceous birds (see Color 8). *Trichophyton* spp. and *Microsporum gypseum* have been reported as a cause of dermatitis of canaries and budgerigars, respectively.<sup>27</sup> A vesicular dermatitis was reported in chickens following the ingestion of *Cladosporium berbarum* fungus.<sup>47</sup>

*Aspergillus* spp. have been associated with skin and feather lesions, particularly in pigeons. Affected feathers are generally dry, have yellow spots and are scaly.<sup>66</sup> Candidiasis has been associated with skin and feather lesions in gallinaceous birds.<sup>30,66</sup>

*Mucor circinelloides* was recovered from three pigeons experiencing severe feather picking and self-mutilation problems. *Rhizopus arrhizus* was isolated from a lovebird, *Penicillium chrysogenum* from a par-

rot, *A. candidus* from a cockatiel and *A. phoenicis*, *P. cyclopium* and *M. circinelloides* from parakeets that were mutilating feathers. The birds in these cases responded favorably to fungicidal therapy, suggesting that the fungus was involved in the feather picking behavior. The use of STA (3 g salicylic acid, 3 g tannic acid and 100 ml ethyl alcohol) applied bi-weekly is particularly effective in controlling integumentary fungal infections.<sup>66</sup>


### ■ Nutritional Factors

The ability of avian skin to resist infections and to heal properly is related to many factors, the most important of which is the nutritional status of the bird. Malnutrition, particularly hypovitaminosis A, is suggested by the smoothing of the normally papillary surface of the plantar surface of the feet (see Color 8).

Hyperkeratosis of the feather sheath may occur as a result of malnutrition or in association with some infectious agents that affect the developing feather (eg, PBFV virus, polyomavirus). In affected feathers, the sheath on the developing feather is retained, resulting in a bird that appears to have an excess number of pin feathers. The precise effects that malnutrition and organopathy (particularly hepatopathy) have on the quality and pigmentation of feathers remain undetermined; however, their role is suggested clinically by the frequency of abnormal plumage in birds fed marginal diets and with hepatopa-



**FIG 24.18** A grackle that had been fed a baby cereal diet was presented for weakness and poor feather formation. The feather barbs were not connected properly, making the vanes appear like they contained holes. The bird was placed on a formulated diet and molting activity started within several weeks. The newly developing feathers were properly formed (arrow).



**FIG 24.19** a) Chronic ulcerative dermatitis in the cervical patagium and interscapular area of a canary. b) The skin was extremely dry and brittle, and the least flapping motion would cause spontaneous tears and hemorrhage. The etiology of these lesions was not determined, but the bird responded to bandaging, a diet change, frequent exposure to sunlight and keeping the wounds clean with dilute chlorhexidine solution.

thies (Figure 24.18). Further, many generalized feather abnormalities will resolve when a bird is placed on a proper diet or when an organopathy is effectively treated.

A malnutrition-induced loss of feathers on the back of the head and neck is believed to occur in canaries. Affected birds are usually egg-laying females and also may show decreased fertility and produce weak chicks. Dietary changes will usually resolve the lesions.

### ■ Nonspecific Dermatopathies

Many minor scratches and cuts (that are not caused by animal bites) require no medical attention, especially if they are in the non-feathered areas of a healthy bird. If a severe wound occurs, the feathers can be trimmed or pulled from the periphery of a lesion to prevent the accumulation of necrotic debris. Most companion and aviary birds do not pick at skin injuries (see Chapter 16).

Burns occasionally occur in companion birds (Color 24.1, 24.2) Treatment should include debridement and topical antimicrobial agents (see Chapter 15). A “stress-related” dermatitis has been reported in lovebirds, cockatoos and budgerigars. *Staphylococcus* spp. are frequently recovered from these birds, and

topical drying agents and antibiotics may be effective therapy.

### ■ Chronic Ulcerative Dermatitis (CUD)

Chronic ulcerative dermatitis is characterized by septic, edematous and hyperemic ulceration and exudation of the skin (Figure 24.19). Chronic ulcerative dermatitis has been associated with tumors (lipomas, squamous cell carcinomas and papillomas), abscesses, unhealed wounds, hernias, mycobacteriosis, diabetes, nephritis, hepatitis and giardiasis. Biopsies should always be performed on proliferative, chronic skin lesions to determine if they are neoplastic in origin.

Giardiasis and hypovitaminosis E seem to be associated with ulcerative dermatitis in lovebirds and cockatiels (Color 24.24). The precise nutrients that may be missing in the diet have not been defined, but these birds are frequently fed seed-based diets with or without the addition of fruits and vegetables. Many cases of CUD will improve when a bird is placed on a balanced, formulated diet and provided with adequate exposure to sunlight. Complete resolution may not occur for several months after these management changes are initiated.

### Prepatagial CUD

Lovebirds, cockatiels, Grey-cheeked Parakeets and occasionally Amazon parrots and cockatoos may develop chronic ulcerative dermatitis involving the metapatagium or prepatagium (Color 24.23). Lesions may also be noted in the proventer and in the interscapular regions of the body. The lesions appear to be extremely pruritic. Outbreaks of ulcerative dermatitis affecting patagial membranes have been described. In one outbreak, 60% of the lovebirds in a flock were affected, and the progression of the disease suggested an infectious agent.<sup>49</sup>

Treatment for prepatagial CUD should include metronidazole for giardiasis (if identified), administration of parenteral vitamin E, removing the feathers from the periphery of the lesion and placement of a figure-of-eight bandage to prevent mutilation. Secondary bacterial or fungal infections should be treated with appropriate topical medications.


Surgical debridement and primary wound closure may be necessary if the lesions do not heal in five to six weeks. Radiosurgery should not be used to debride or control hemorrhage associated with these lesions. Birds with long-term or severe lesions will replace the normally elastic patagial tissue with scar tissue, which may make the bird more susceptible to future lesions.

### CUD in Other Regions of the Body

Ulcerative dermatitis of the proventer region may occur in heavy-bodied birds (African Grey and Mealy Amazon Parrots) that have had improper wing trims. A bird that attempts to fly from a high perch and has no lift may land on its sternum, resulting in a bruise or open wound over the cranial portion of the keel. These damaged tissues seldom become infected although cellulitis of the area is common (see Color 8).

The skin wounds should be treated as discussed under general therapy for integumentary lesions, and several of the clipped primary and secondary feathers from each wing should be removed to stimulate replacement of the feathers. These new feathers will provide the bird with the necessary lift to prevent further injury. In severe cases, necrotic portions of the keel must be surgically removed. Supportive care is successful in most minor cases and the lesions generally resolve in six to nine weeks.

Birds with chronic ulcerative dermatitis in the caudal aspect of the postventer region may be presented with a history of blood-tinged excrement. Feathers



**FIG 24.20** A mature cockatiel on an all-seed diet was presented for evaluation of bloody diarrhea. An ulcerated lesion was noted in the postventer region. Bilateral ulcerative lesions of the metapatagium were also present. Pruritic skin lesions and ulcerative dermatitis in cockatiels appear to be associated with primary malnutrition or giardiasis. In this case, giardia could not be documented and the bird responded to a change in diet. The tail feathers were transected to reduce the pressure on the postventer skin. The lesions were cleansed daily with chlorhexidine solution and were coated with live yeast derivatives twice a day. Cloaca (arrow).

adjacent to and covering the skin lesion may be stained with blood. This lesion is common in malnourished birds and may begin when a bird with an improper wing clip lands on a hard surface. The impact of the tail with the ground causes a hyperextension of the rectrices and places excessive pressure on the tight skin of the proventer region (Figure 24.20).

### Disorders Affecting the Feet and Legs

Skin on the legs may be damaged by bands (rings) or, in the case of falconers' birds, by badly fitted leather jesses. Secondary bacterial infections of skin wounds can occur and impair healing, particularly when a foreign object is constantly in contact with the wound. The application of a self-adherent wound dressing (see Chapter 16) will keep the wound clean and moist and permit regular visual inspection.<sup>8</sup>

Pox lesions on the feet and legs are characterized by dry, brown plaques. Other viral infections appear to be rare, but a herpesvirus has been implicated in skin lesions in Mallard Ducks and cockatoos (see Chapter

## ■ Dermatology

### Color 24.1

A goose sustained severe burns on the unfeathered portions of the face, feet and legs after being trapped in a yard fire. The wounds were debrided and flushed repeatedly with copious amounts of sterile saline solution.

### Color 24.2

Burns on the legs and feet of a goose were cleaned and treated with silvadene cream TID. This photograph, taken two weeks after the initial burns, shows a healthy bed of granulation tissue over the burns, and the bird healed with no complications.

### Color 24.3

A mature, male budgerigar with dermatitis was presented for progressive shivering and depression. The bird had been treated with an over-the-counter, oil-based antibiotic. The oil-laden feathers had lost their insulation ability, causing the bird to lose excessive amounts of body heat. The oil was removed with repeated washing in warm dishwashing detergent, and the bird was placed in an incubator (94°F) to dry.

### Color 24.4

A proliferative skin mass on the abdominal wall of a cockatoo with PBFD virus. The mass had histologic features characteristic of a papilloma. Part of the diagnostic evaluation for any proliferative skin mass should be a biopsy to rule out neoplasm.

### Color 24.5

Normal primary pin feathers (blood feathers) in a developing Moluccan Cockatoo neonate.

### Color 24.6

Feather cyst in a budgerigar. The cyst was surgically removed and the bird had no further complications.

### Color 24.7

Primary feathers removed from a pious parrot with PBFD virus. The infection was confirmed by DNA probe testing of whole blood and by histopathologic evaluation of dystrophic feathers. Note the constricted

calamus, areas of necrosis and hyperkeratotic feather sheaths. This bird was exposed to PBFD virus when infected neonates from another collection were introduced to the nursery. The fact that part of the distal feather is normal indicates that there was no damage occurring to the follicular epithelium when this part of the feather was developing.

### Color 24.8

Feather cysts are common in canaries, particularly the Norwich, Crested, Crest-bred and new color canaries that have "double-buff" soft feathers. In severely affected birds, feathers emerge in all directions (courtesy of Patricia Macwhirter).

### Color 24.9

Split section of a feather cyst showing the accumulation of cellular debris in multiple follicles (courtesy of John Cooper).

### Color 24.10

Straw-feather disease has been described in canaries and a few other Passeriformes and is believed to be genetic in origin. There is incomplete development of the feather barb and barbules and there may be retention of the feather sheath in some affected feathers (courtesy of Louis Filippich).

### Color 24.11

Segmental discoloration, black lines or transparent areas across the vane of a feather are called stress marks and indicate a dysfunction of the epidermal collar at the time the feather was developing.

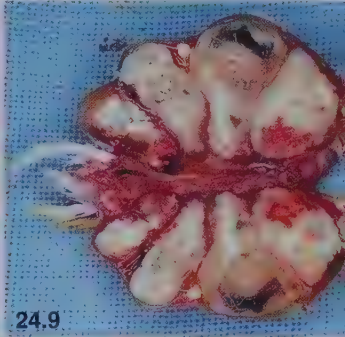
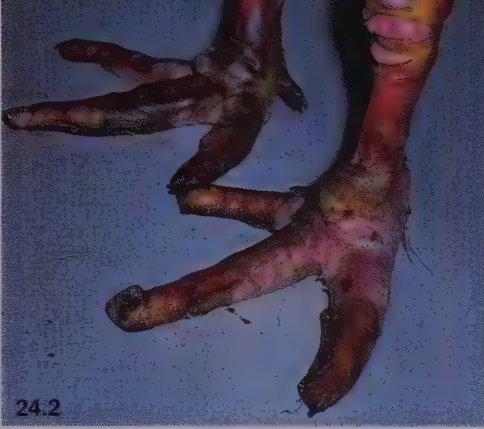


### Color 24.12

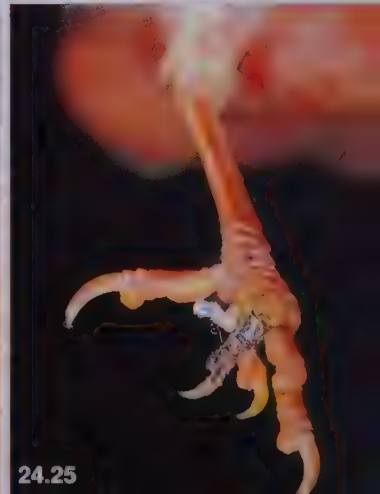
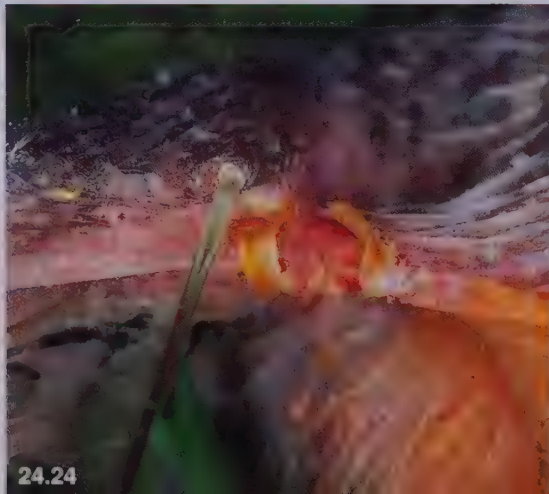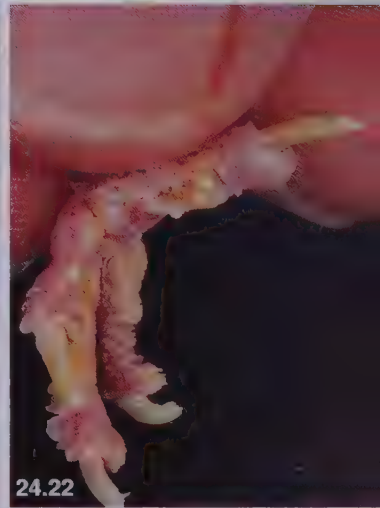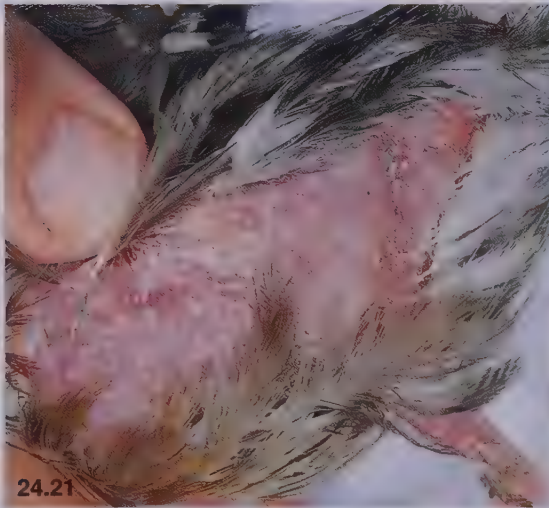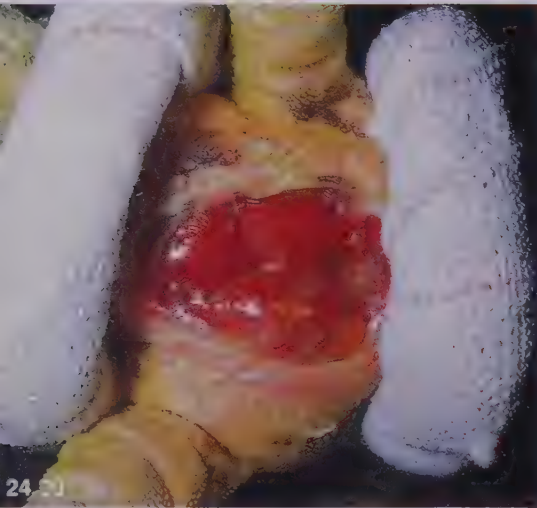Magnified view of stress marks in a developing feather (courtesy of John E. Cooper).

### Color 24.13

Necrotic, dystrophic contour feathers on the body of an adult Umbrella Cockatoo with chronic PBFD virus. Note the dystrophic growth, areas of necrosis and constriction of the feather shaft at its interface with the edge of the epidermis.







## Dermatology

### Color 24.14

*Knemidokoptes* spp. infections are most common in budgerigars and passerine birds, but may also occur in other birds, such as this Sulphur-crested Cockatoo. This bird responded to topical ivermectin therapy, but did have some post-infection feather loss and damage to the eyelids.

### Color 24.15

*Knemidokoptes* spp. may cause severe proliferation and deformity of the beak. Note the skin on the face is also infected.

### Color 24.16

A mature Yellow-collared Macaw was presented for severe depression. The head was covered with normal feathers but the remainder of the body was featherless. Several areas of self-mutilation were present including both feet and legs and the cervical patagium. An etiology could not be determined for this bird's self-mutilation.

### Color 24.17

Hyperemic, indurated masses secondary to wasp stings in a Blue and Gold Macaw.

### Color 24.18

Brown hypertrophy of the cere in a male budgerigar. This syndrome is believed to be caused by imbalances in the ratio of sex hormones.

### Color 24.19

A mature Amazon parrot was presented with an acute onset of picking at the feet and legs. This photograph was taken several hours following the onset of the picking behavior and is characteristic for the acute phase of the Amazon foot necrosis syndrome. The cause of this bird's problem could not be determined, but it responded to general dermatologic therapy.

### Color 24.20

A Golden Eagle was presented with severe bilateral swelling of the metatarsal pads. One pad was ulcerated, and a thick, greenish-yellow discharge was present in the center of the mass. The necrotic material was surgically removed from both feet and the wounds were packed with antibiotic-impregnated gel foam. A healthy granulation

bed was produced within three weeks of initiating therapy, and walking bars that were stabilized in a tarsometatarsal cast were used to allow the bird to ambulate without placing pressure on the plantar surface of the foot.

### Color 24.21

A mature cockatiel hen was presented for severe feather picking. The bird had removed most of its feathers from the axillary and leg regions. *Giardia* sp. was diagnosed by examining a fresh wet mount fecal sample. The bird responded to therapy with metronidazole.

### Color 24.22

*Knemidokoptes* spp. mites have caused proliferative yellowish-colored lesions on the foot of a canary. The bird was presented with a shifting leg lameness.

### Color 24.23

Chronic ulcerative dermatitis in the ventral prepatagium of a mature cockatiel hen. Note that the feathers are melanistic. This bird had biliverdinuria and responded to a dietary change and therapy for liver disease. The feathers returned to normal color with subsequent molts.

### Color 24.24

A lovebird was presented for progressive feather picking. The bird would scream as it picked at the tissues of the chest, back and wings. Ulcerative lesions were present on the cranial edge of both prepatagial membranes. *Staphylococcus* spp. and *Candida* spp. were isolated from the wounds, but they were considered secondary pathogens. The bird responded to therapy for chronic ulcerative dermatitis (and wing splinting), but many of the feather follicles had been destroyed and the bird remained featherless in some areas.

### Color 24.25

Necrotic digits in adult passerine birds are commonly caused by fibers that wrap around the toe. Diagnosis usually requires examining the proximal edge of the affected digit under a dissecting or operating microscope.

32).<sup>70</sup> Proliferative, hyperplastic lesions on the feet of canaries and mynahs have been associated with abrasions, aging and malnutrition. A condition involving cracking of the feet that is responsive to high doses of biotin has been documented in flamingos, ratites and waders (see Color 48) (Greenwood A, unpublished).

Keratomas that appear clinically as digit-like projections composed of hyperkeratotic scales have been described in some species (see Color 48). These callus-like growths may predispose a bird to bumblefoot (see Chapter 43). Virus-induced papillomas are common on the feet of finches in Europe.<sup>2</sup>

“Bumblefoot” or pododermatitis has been reported in many species of birds but is a particular clinical problem in captive birds of prey, Galliformes, Anseriformes, waders, penguins and many Psittaciformes (Color 24.20). In Psittaciformes and Passeriformes, most lesions are believed to be the result of malnutrition, which causes the skin of the foot to become dry and hyperkeratotic. Hepatic dysfunction may also be involved in some cases. Penetrating wounds or bruising of the feet may be predisposing factors in raptors and Anseriformes (see Chapter 16).<sup>8</sup>

A “constricted toe syndrome” has been described in a number of Psittaciforme neonates (see Color 30). The fibrous band can be surgically excised to correct the problem (see Chapter 41). Other causes of ischemic necrosis of the feet or legs may include entangled fibers, hairs, bedding material, leg bands, strings, jesses, dried skin, frostbite or ergot poisoning (Color 24.25).

Pruritic, ulcerative lesions have been described on the feet and legs of Amazon parrots (particularly Yellow-naped and Double Yellow-headed Amazon Parrots). The lesions start with a bird chewing at the feet and legs followed by the formation of hyperemic lesions, sometimes within minutes of the initial pruritic episode. An ulcerative dermatitis occurs as the bird continues to chew on the feet and legs (Color 24.19). Characteristic histopathologic findings associated with this syndrome include ulcerative dermatitis that may contain coccoid bacteria and fungi. The role that the bacteria or fungi play in the pathogenesis of this syndrome is undetermined. Immune-mediated and allergic reactions with secondary involvement of autochthonous skin flora have been proposed as etiologies for these lesions (see Chapter 33).

*Staphylococcus* spp. are frequently isolated from the lesions, but the birds will usually not respond to antibiotic therapy alone. The syndrome appears to be

more common in the spring (suggesting a seasonal allergen), and many affected birds belong to cigarette smokers. In these latter birds, the lesions may spontaneously resolve when the clients stop smoking or wash their hands before handling the birds. Other cases will respond to a change in diet, frequent exposure to sunlight and a topical antimicrobial cream containing steroids. Topical steroids should be applied with caution to prevent toxicity.

Atarax and oral antibiotics were found to be effective in some cases.<sup>21</sup> Seasonal recurrence of the lesions may be prevented by the oral administration of prednisolone about one month prior to the time that lesions typically occur.

A hydroactive dressing can be used to facilitate healing of these wounds. Initially, the bandage may require daily changing. The frequency of bandage changes can be reduced as the wound becomes less exudative. Once granulation tissue forms at the edge of the ulcers, scabs should be removed and the lesions should be kept clean to facilitate healing (see Chapters 15, 16).

Some reports detail the use of thyroid supplementation as a therapeutic regimen for foot necrosis syndrome; however, thyroid levels were not determined in the treated birds and the indiscriminate administration of thyroxine, can cause fatal toxicity (see Chapter 23).

## Diseases of the Feathers

---

The appearance of malformed, broken, bent, dirty, stained or unusually colored feathers should be considered abnormal. Feather conditions can be divided into two main groups: those affecting normal feathers and those in which abnormality of the feather is the primary feature. A simple method to determine if a feather problem occurs during or after development is to remove an affected feather (it should be examined cytologically, microscopically and possibly histologically) and evaluate the growth of the new feather over the next one to three weeks. There are three possibilities with respect to the new feather:

- The feather does not regrow (suggests a systemic or follicular abnormality)

**TABLE 24.6 Common Pathologic Terms Used in Avian Dermatology**

Term	Definition
Acanthosis	Hyperplasia of the stratum germinativum
Acantholysis	Lack of cohesion between epidermal cells, leading to formation of clefts, vesicles and bullae
Atrophy	Decrease in size of a tissue or organ – in dermatology usually refers to thinning of the epidermis
Ballooning degeneration	Intracellular accumulation of fluid (edema)
Depigmentation	Loss of (melanin) pigmentation
Dyskeratosis	Prematurely cornified cells with eosinophilic cytoplasm and small dark nuclei
Excoriation	Secondary ulceration that may occur following self-inflicted trauma
Hyperkeratosis (hyperkeratinization)	Increased thickness of the stratum corneum
Hyperplasia	Thickening of the epidermis
Hypopigmentation	Reduced (melanin) pigmentation
Melanosis	Dark appearance due to increased melanocyte activity and deposition of melanin
Parakeratosis	Retention of pyknotic nuclei in the cells of the stratum corneum, usually associated with defective keratinization
Spongiosis	Extracellular accumulation (edema) causing separation of epithelial cells
Telangiectasis	Persistent vasodilation: skin does not blanch when compressed with a microscope slide

**TABLE 24.7 Incidence of Histologic Lesions in a Group of 213 Feather Biopsies<sup>60</sup>**

Diagnosis	Number of Affected Birds
PBFD virus	32
Suspect PBFD virus	20
Normal skin and feathers	26
Inactive feather follicle - no lesion	22
Epidermal atrophy	6
Staphylococcus dermatitis	3
Other pyodermas	17
Suspected bacterial pulpitis	9
Dermatomycosis	3
Sarcoptic mange	1
Hypersensitivity reaction	78
Trauma	46
Drug eruptions	2

- The feather regrows but is not normal (suggests a problem in the feather follicle or organopathy)
- The feather regrows normally (suggests that the feathers are being damaged after development, eg, feather chewing, enclosure trauma).

Biopsy and histopathology are indispensable for diagnosing the cause of feather lesions. Some common descriptive terms that may be needed by the clinician to interpret the results of pathology reports are listed in Table 24.6. The results of 213 feather biopsies from a group of Psittaciformes are listed in Table 24.7.<sup>60</sup>

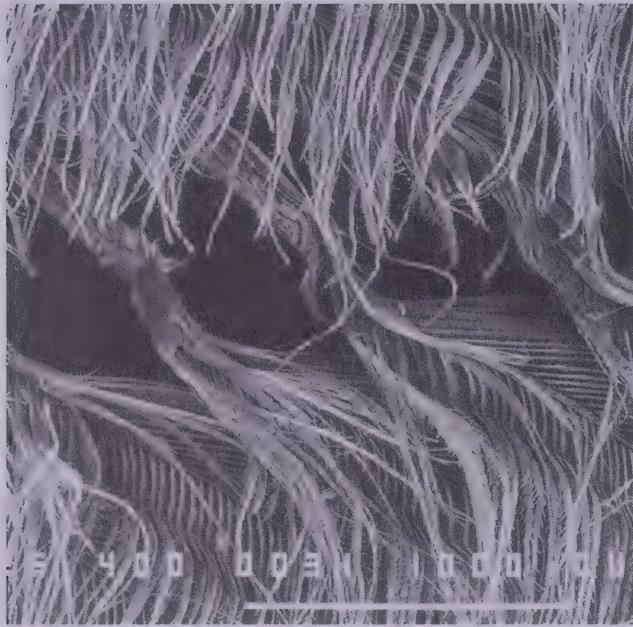
### Stress Marks

Translucent lines across the vane of a feather are frequently referred to as stress marks (Color 24.12). These abnormalities represent segmental dysplasia that occurred in the developing barbs and barbules and represent a brief period of dysfunction in the epidermal collar (Figure 24.21). These marks can be induced by the administration of exogenous corticosteroids, suggesting that they are truly “stress” marks. Restraint, illness, a brief period of food deprivation or exposure to environmental extremes should be expected to induce these lesions. Deficiencies of arginine (curled wing feathers), riboflavin (clubbed down feathers) and pantothenic acid, niacin and selenium (poor feathering) are nutritional causes of poor feather structure in poultry.<sup>63</sup>

### Preening

Much of a bird’s day is spent in feather preening, a natural process for maintaining feather condition. Feather preening appears to be innate, but occasionally a hand-raised neonate will have poor quality feathers or an excess number of pin feathers because of an improper preening response. These birds should be taught to preen the feathers by gently breaking the sheaths while encouraging the bird to pick at an area with its beak. Some wear of the feathers should be considered normal. Over-preening (feather picking) occurs when what is a normal part of feather maintenance becomes a pathologic condition (see Chapter 4).

Some birds may molt feathers on a seasonal basis from the ventral abdomen and lower legs (developing a brood patch). Damage to the feathers of the breast, abdomen and legs during the breeding season may indicate reproductive frustration. Seasonal feather picking associated with breeding activity is usually temporary and no specific therapy is necessary or warranted unless the feather loss is persistent or involves areas other than the lower abdomen.



**FIG 24.21** Scanning electron micrograph of a feather with segmental dysplasia (stress marks). Note that the barbs and barbules that were present in the epidermal collar at the time the stress occurred are improperly formed (courtesy of John Cooper).

### Feather Picking

Feather picking occurs when a bird damages its feathers or skin (or the feather and skin of a companion). Feather picking is a condition of captivity. With the importance of the feathers for thermal regulation and flight, severe, self-induced feather damage would be life-threatening to a free-ranging bird. Clinically, feather picking is characterized by the loss or damage of feathers on the body and neck with normal feathers on the head (Figure 24.22). Feather picking induced by a companion is characterized by loss or damage of feathers around the head and neck. Male cockatiels will occasionally over-preen the orange face patch of the hen.

Feather picking can become an obsessive behavior with a bird progressively damaging all or part of the accessible plumage, leading to abnormalities in normal feather development and molt. Self-mutilation is characterized by over-preening and subsequent damage to the skin or muscle. Mutilation of the skin can cause, or occur secondary to, chronic ulcerative dermatitis.

Many feather-picking or self-mutilating birds are considered to be pruritic, which is difficult to document. Over-preening and scratching an area with the nails is suggestive. Inflammation or irritation associated with internal pathology, including that caused

by infectious agents, has been suggested as a precipitating factor for feather picking.<sup>19</sup> Organopathy, toxins, malnutrition, bacteria, viruses, fungi, parasites (blood or intestinal), boredom, anxiety, lack of sleep, psychosis and undesired contact with strangers or family pets (dogs or cats) have all been implicated in cases of self-mutilation.<sup>55</sup> Feather loss on the neck of lorries and Hyacinth Macaws has been attributed to contact with conifers.

Mutilation is a commonly discussed problem in poultry and has been associated with improper management, crowding and malnutrition. In humans, hepatopathies have been associated with pruritus, and many self-mutilating birds have clinical changes suggestive of liver disease.<sup>21</sup>

Some birds may be mutilated by other birds (canaries, finches, conures, cockatoos). In colony-breeding flocks, reducing the number of birds in the enclosure, increasing the number of hiding places and nest boxes or removing the offending birds may be necessary for control. Cockatoos may occasionally over-preen a mate, but more commonly a male bird will kill its mate with no previous indication of aggressive behavior (see Chapter 2).

### Examination of the Feather-picking Bird

Feather-picking birds should be approached in a systematic fashion.<sup>7,19</sup> A diagnosis of psychologically induced self-mutilation should be reserved for patients in which no cause for the problem can be identified by physical examination, complete blood count (CBC), serum chemistries, feather pulp culture and cytology, skin lesion culture and cytology, radiographs, endoscopy and direct microscopic examination and biopsies of affected feathers. If no etiology can be determined for the over-preening, then behavioral abnormalities should be considered.


There is an apparent species' predilection to feather-picking behavior. African Grey Parrots appear to be particularly prone to feather picking, perhaps as a result of their sensitive natures or need for a highly stimulated environment. Spoiled, improperly socialized, hand-raised birds of any species may also be prone to self-mutilation. Cockatoos and conures frequently develop feather-picking behavior for which an etiology cannot be conclusively identified, necessitating a diagnosis of psychologic feather picking. By comparison, idiopathic feather picking in budgerigars and cockatiels is rare. In these species, feather picking associated with ulcerative dermatitis of the patagial membranes is most common (Color 24.21).



### Treatment of Feather Picking

Once initiated, feather picking can become habitual and continue even though the precipitating cause is no longer present. Chronic feather picking can result in sufficient damage to the follicles to prevent any future feather growth (Figure 24.22). Therapy for self-mutilation of undetermined etiology should be considered effective if the destructive behavior can be reduced. Complete cessation of self-mutilation is rare.

In a retrospective study of 106 feather-picking cases, 31 had no change on follow-up examination; resolution of the problem occurred in 20 cases; 21 showed some improvement; and 34 were lost to follow-up. Amazon parrots and cockatiels appeared most likely to respond to treatment. Excluding birds with confirmed PBFV virus infections, treatment of other feather abnormalities with an etiology that was determined by the minimum database was generally successful. Idiopathic cases of feather picking were less likely to respond to therapy.<sup>60</sup>



**FIG 24.22** a) Feather picking is characterized by normal feathers on the head and neck, with damaged feathers at other locations where over-preening can occur. b) With chronic feather picking, the follicles may be permanently damaged, and feather regrowth cannot occur. c) In severe cases of self-mutilation, a bird may actually induce wounds in the skin or muscle.

Occasionally, a bird will self-mutilate as a result of sexual frustration. Some of these birds will stop mutilating when placed in a breeding situation; however, others will continue self-mutilation activities and may also over-preen a mate. Assuming that idiopathic self-mutilation is a result of some undetectable neurosis, it would be considered unwise for these birds to be added to a breeding collection where they may pass on genes that will predispose their progeny to the same problem.

There are probably as many recommended therapies for the feather-picking bird as there are avian veterinarians. Any underlying medical problems should be identified and corrected. Various foul-tasting substances are frequently applied to the feathers in an unsuccessful attempt to modify the picking behavior. This procedure only masks clinical signs and should not be considered therapeutic. Treatment for feather picking should include the correction of organopathies, specific therapies for folliculitis (bacterial or fungal), improving the diet, removing exposure to cigarette smoke, providing frequent exposure to fresh air and sunlight, providing an 8- to 14-hour photoperiod that varies naturally with the seasons, and behavioral modification (see Chapter 4). If these therapies are determined to be ineffective over a two-month period, then mood-altering drugs may be necessary.

Where feather picking is determined to be psychological (a failure in the ability to diagnose a cause for the problem), a video recorder may be helpful in documenting a bird's behavior in its normal environment. Identifying the specific factors that induce the feather-picking behavior (separation anxiety, a tormenting pet, an unliked child, an abusive adult) can guide the clinician in making specific recommendations to correct the behavior and resolve the problem (see Chapter 4). Striving to improve the human-animal bond may be the most effective therapy in these cases.

Some problems with separation anxiety can be corrected by leaving tape recordings of family activities or a radio or TV playing in the family's absence. With some birds, the addition of new toys or moving an enclosure to a different location will be a stress factor that induces feather-picking, while with other birds these moves are positive and help to keep a bird mentally stimulated. A bird that is properly socialized and adapted early in life to changes in daily routine is less likely to develop emotional problems due to separation anxiety when changes occur later in life.

If psychological feather picking cannot be stopped with behavior modification, drugs may be necessary. Mood-altering drugs that have been suggested for use in feather-picking birds include tricyclic antidepressants and antihistamines (hydroxyzine hydrochloride,<sup>c</sup> 2 mg/kg oral). These therapeutic agents are frequently discussed but are rarely effective. Hormonal therapies including thyroxine, testosterone and medroxyprogesterone have also been suggested for some cases of feather picking; however, all of these agents have undesirable side-effects and should be used only to treat specifically identified problems.<sup>21</sup> Medroxyprogesterone acetate may be effective in stopping some sexually related behavioral disorders including feather picking, aggressiveness and masturbation; however, the drug can have severe side-effects including obesity, polydipsia, polyuria, glucosuria and liver disease.<sup>51</sup>

Ongoing studies suggest that haloperidol<sup>d</sup> may be effective in some feather-picking cases.<sup>31</sup> This drug is used to control hyperactive and impulsive behavior in humans. The dose being used in birds is 0.01 ml (0.02 mg) per 100 g orally BID. It takes two days to stabilize the dose. Side-effects include loss of appetite, incoordination and vomiting. If there are no side-effects and a bird is still picking, the dose can be increased in 0.01 ml increments every two days. The maximum dose should not exceed two times the initial dose.

Successful treatment is generally reported within two to three days when the bird stops over-preening or self-mutilating and begins to play, sing and interact with the client.<sup>31</sup> There is also a haloperidol decanoate (50; 100 mg/ml) injectable repositol for IM administration. Dosed at 1-2 mg/kg, the patients respond for up to 14 to 21 days. Both administration forms have to be used continually unless the initiating cause of the feather picking can be corrected. Clinical experience suggests that cockatoos and Quaker Parakeets may require a lower dose (half that used for other birds).

Feather damage can be prevented by beak trimming or, as a last resort, by applying restrictive collars (Figure 24.23). These procedures only suppress the clinical signs and do not address the underlying problem.

#### ■ Endocrine-related Feather Disorders

In poultry, hypothyroidism causes black, brown and yellow feathers to become red, longer and more pointed and to have less pennaceous barbules than





**FIG 24.23** Collars should be used only in cases of severe self-mutilation that cannot be diagnosed and resolved with specific therapy (courtesy of Louise Bauck).

normal. The feather vanes have a fringed or lacy appearance. Hypothyroidism has been shown to delay wound healing in pigeons.<sup>53</sup> Documented cases of hypothyroidism in companion birds are rare. It should be noted that some species of birds that are deficient in iodine will have a TSH response test that suggests hypothyroidism (see Chapter 23).

In a Scarlet Macaw with reported hypothyroidism, clinical signs included nonpruritic feather loss, mild nonregenerative anemia, mild leukocytosis and heterophilia, hypercholesterolemia, sparse feathers, a history of no molting for over a year, and obesity with fat deposits on the lower abdomen and under the skin of the legs. Although no feather measurements were obtained, photographs of this bird suggest that contour feathers lacked width and were shorter than normal. This bird responded favorably to treatment with 20 mg/kg of L-thyroxine orally BID.<sup>40</sup>

There are no documented cases of feather abnormalities resulting from hyperadrenocorticism or hypoadrenocorticism in birds although both conditions would be expected to occur. Hyperkeratotic dermatitis and feather loss were reported in a macaw that had histologic evidence of adrenal gland degeneration. This bird was on a poor diet and had staphylococcal abscesses of the occipital bone, bacteremia and bilateral pododermatitis.<sup>41</sup> It is likely that the adrenal gland degeneration in this bird was secondary to other medical problems and was not the primary cause of the noted lesions.

Hyperestrogenism is associated with pruritic hair loss in mammals. Hyperestrogenism has been associated with proliferation of endosteal bone in birds, but has not been associated with feather lesions (see Chapter 23). Up to 60% of the male canaries in some flocks may develop baldness that is responsive to a change in the level of nutrition provided.

### ■ Inactive Feather Follicles

A feather follicle is normally inactive between molts. Persistent generalized inactivity of the feather follicles should be considered abnormal. In one study, many birds with inactive follicles had abnormal bacterial populations, elevated CPK activity and toxic heterophils. Some birds had a leukocytosis and elevated calcium levels; a few of these cases responded to antibacterial therapy. Epidermal atrophy accompanied chronic inactive feather follicles, hyperkeratosis and follicular atrophy in some birds.<sup>55</sup>

### ■ Cysts

Cutaneous cysts are characterized by an epithelial wall surrounding keratinaceous contents. Epidermal cysts have been described in the dermis and subcutis of budgerigars (Color 24.6) If the orifice of the feather follicle is occluded from a traumatic or infectious episode, keratinaceous debris will accumulate in the follicle resulting in a follicular cyst (Color 24.9). These lesions are particularly common in canaries. Therapy is excisional (see Chapters 41 and 43). Feather cysts have been reported to occur in free-ranging birds.<sup>11</sup>

### ■ Polyfolliculitis

Pruritic polyfolliculitis and dermatitis that may be caused by a virus have been described in lovebirds and budgerigars. Lesions appear to be particularly common in the feather tracts of the tail and dorsal region of the neck. The newly emerging feathers have short, stout quills with retained sheaths. Some of these birds have been histologically diagnosed with PBFV virus infections, whereas others have not been shown to be infected (Figure 24.24).


Histologically, polyfolliculitis is characterized by the appearance of multiple feather shafts from the same follicle with a thin layer of epidermis separating the shafts. Chronic inflammation occurs beneath the pulp cap, and the feather sheath is thickened. In some cases, large, keratin-filled cysts may also be

noted. Therapy with broad-spectrum antibiotics and corticosteroids is palliative at best.<sup>50</sup>

### Other Feather Abnormalities

Bleeding occurs if the protective keratin sheath of a developing feather (pin or blood feather) is injured or the feather is dislodged from the follicle. Hemorrhage can be severe, particularly in birds with coagulopathies. Experimentally, developing feathers that are removed can be rotated and reinserted and will continue to grow. In the clinical setting, it is best to remove damaged pin feathers (see Chapter 15).

Neonates kept in areas with low humidity may have dystrophic feather growth characterized by failure of the developing feather to exsheath. The lesions will usually resolve when the humidity is increased (and the affected feathers are removed).



**FIG 24.24** Clinical appearance of polyfolliculitis in two lovebirds. Both birds had progressive syndromes that could not be resolved. An etiologic agent could not be detected by histopathology in either case.

### Products Mentioned in the Text

- a. Panalog, Solvay Animal Health, Mendota Heights, MN
- b. Silvadene, Marion Laboratories, Kansas City, MO
- c. Atarax, Roerig, Pfizer Pharmaceuticals, New York, NY
- d. Haloperidol, Schein Pharmaceuticals, Port Washington, NY

### References and Suggested Reading

1. André J-P: "Les maladies des oiseaux de cages et de volières." Point Veterinaire, Maisons-Alfort, 1990.
2. Arnall L, Keymer IF: Bird Diseases. London, Baillière Tindall, 1975, p 459.
3. Allman RB: Conditions affecting the integumentary system. In Petrak ML (ed): Diseases of Cage and Aviary Birds. Philadelphia, Lea & Febiger, 1982.
4. Berners, DJ: "The Boke of St. Albans," 1486.
5. Cheryl Y, et al: Fasting in king penguins: Hormonal and metabolic changes during molt. *Am J Physiol* 252:178-184, 1988.
6. Cooper JE: Introduction to birds. In Poole TB (ed): The UFAW Handbook on the Care and Management of Laboratory Animals 6th ed. Harlow, UK, Longman, 1987.
7. Cooper JE: Caged and wild birds. In Anderson RS, Edney ATB (eds): Practical Animal Handling. Oxford, Pergamon Press, 1991.
8. Cooper JE: Veterinary Aspects of Captive Birds of Prey. Glos, Standfast Press, 1978.
9. Cooper JE, Gschmeissner S, Ion F: The laboratory investigation of feathers. *Proc 2nd Europ Symp Avian Med, Utrecht, Netherlands*, 1989.
10. Cooper JE, Mellau LSB: Sticktight fleas (*Echidnophaga gallinacea*) on birds. *Vet Rec* 130:108, 1992.
11. Couillon CE, Maslin WA, Montgomery RM: Multiple feather follicle cysts in a wild turkey. *J Wildl Dis* 26:122-124, 1990.
12. Davidson WR, et al: Feather damage due to mycotic infections in wild turkeys. *J Wildl Dis* 25(4):534-539, 1989.
13. Dorrestein GM, Van der Hage MH: Veterinary problems in mynah birds. *Proc Assoc Avian Vet*, 1988, pp 263-274.
14. Drew ML, Ramsey E: Dermatitis with *Mycobacterium* spp. in a blue-fronted Amazon parrot. *Proc Assoc Avian Vet*, 1991, pp 252-254.
15. Gaskin JM: Psittacine viral diseases: A perspective. *J Zoo Wildl Med* 20(3):249-264, 1989.
16. Gentle MJ, Hunter LN: Physiological and behavioural responses associated with feather removal in *Gallus gallus var domesticus*. *Res Vet Sci* 50:95-101, 1990.
17. Ginn HB, Melville DS: Molt in Birds. British Trust for Ornithology, Tring, England, 1983.
18. Graham DL: The avian integument. Its structure and selected diseases. *Proc Assoc Avian Vet*, 1985, pp 33-52.
19. Harrison GJ: Feather disorders. *Vet Clin No Am Sm Anim Prac* 14(2):179-199, 1984.
20. Hier RH, Perry PS, Sperry M: Foot tumor found on juvenile common loon. *The Loon* 58:41-42, 1986.
21. Hillyer EV, Quesenberry KE, Boer K: Basic avian dermatology. *Proc Assoc Avian Vet* 1989, 101-121.
22. Hochleitner M: African grey parrot responds to a change in diet. *J Assoc Avian Vet* 6:146, 1992.
23. Hubalek Z: The distribution patterns of fungi in free-living birds. *Acta scientiarum naturalium Academiae scientiarum bohemoslovaca* 8:1-51, 1974.
24. Johnson AL: Reproduction in the female. In Sturkie PD (ed): Avian Physiology, 4th ed. New York, Springer-Verlag, 1986, pp 403-431.
25. Johnson BJ, Castro AE: Canary pox causing high mortality in an aviary. *J Am Vet Med Assoc* 189:1345-1347, 1986.
26. Junge E, MacCoy DM: Amikacin therapy for *Pseudomonas cellulitis* in an Amazon parrot. *J Am Vet Med Assoc* 187:417-418, 1985.
27. Keymer IF: Mycoses. In Petrak ML (ed): Diseases of Cage and Aviary Birds 2nd ed. Philadelphia, Lea and Febiger, 1982, pp 599-605.
28. King AS, McLlland J: Form and Function in Birds Vol 3. Orlando, Academic Press, 1985.
29. Kray RA: Dermatitis and feather discoloration syndromes in psittacines. *Proc Am Assoc Zoo Vet*, 1985, p 12.
30. Kuttin ES, et al: Chicken dermatitis and loss of feathers from *Candida albicans*. *Avian Dis* 20:216-218, 1976.
31. Lennox A, Van Der Heyden N: Haloperidol for use in treatment of psittacine self-mutilation and feather picking. *Proc Assoc Avian Vet*, 1993.
32. Lucas AM, Stettenheim PR: Avian Anatomy. Integument. Agricultural Handbook 362. US Department of Agriculture, Washington DC, 1972.
33. Ludicke M: Wachstum und Abnutzung des Vogel Schnabels. (Growth and wear of the bird's beak). *Zool Jahrb* 57:465-533, 1933.
34. MacCoy DM, Campbell TW: Excision of impacted and ruptured uropygial glands in three gentoo penguins (*Pygoscelis papua*). *Proc Am Assoc Zoo Vet*, 1991, pp 259-260.
- 34a. Mancuso S: African "red" parrots? *Bird Talk* Dec:85-87, 1990.
35. Marder J, Arieli Y, Ben-Asher J: Defense strategies against environmental heat stress in birds. *Israel J Zoo* 36:61-75, 1989.
36. McOrist S: Some diseases of free-living Australian birds. In Cooper JE (ed): Disease and Threatened Birds. Cambridge, England, Intl Coun Bird Pres, 1989.
37. Menon GK, et al: Fine structural basis of the cutaneous water barrier in nestling Zebra finches (*Poephila guttata*). *Ibis* 130:505-511, 1988.
- 37a. Millam J, Finney H: Leuprolide acetate can reversibly prevent egg laying in cockatiels. *Proc Assoc Avian Vet*, 1993.

38. **Muller M, Cooper JE:** Avian dermatology. In von Tscherner C, Halliwell REW (eds): *Advances in Veterinary Dermatology Vol I*. London, Baillière Tindall, 1990.
39. **Needham JR, Cooper JE, Kenward RE:** A survey of the bacterial flora of the feet of free-living goshawks (*Accipiter gentilis*). *Avian Pathol* 8:285-288, 1979.
40. **Oglesbee BL:** Hypothyroidism in a scarlet macaw. *J Am Vet Med Assoc* 201:1599-1601, 1992.
41. **Onderka N, et al:** Adrenal degeneration associated with feather loss in a macaw. *Cand Vet J* 28:193-194, 1987.
42. **Oppenheimer J:** Feather picking: Systematic approach. *Proc Assoc Avian Vet*, 1991, pp 314.
43. **Palmer RS:** Mechanisms and control of molt. In Farner DS, King JR (eds): *Avian Biology Vol 2*. New York and London, Academic Press, 1972.
44. **Pass DA:** The pathology of the avian integument: A review. *Avian Pathol* 18:1-72, 1989.
45. **Pass DA, Perry RA:** Granulomatous dermatitis in peach-faced lovebirds. *Aust Vet J* 64(9):285-287, 1987.
46. **Payne RB:** Mechanisms and control of molt. In Farner DS, King JR (eds): *Avian Biology Vol 2*. New York and London, Academic Press, 1972.
47. **Perek M:** Ergot and and ergot-like fungi as the cause of vesicular dermatitis in chickens. *J Am Vet Med Assoc* 132:529-533, 1958.
48. **Perelman B, Gur-Lavie A, Samberg Y:** Pox in ostriches. *Avian Pathol* 17:735-739, 1988.
49. **Perry RA:** A psittacine combined beak and feather disease syndrome. *Proc Post Graduate Comm Vet Sci, Cage and Aviary Birds*, Sydney, Australia, 1972.
50. **Perry RA:** Pruritic polyfolliculitis and dermatitis in budgerigars (*Melopsittacus undulatus*) and African lovebirds (*Agapornis* spp.). *Proc Assoc Avian Vet*, 1991, pp 32-37.
51. **Perry RA, Gill J, Cross GM:** Disorders of the avian integument. *Vet Clin No Am Sm An Pract* 21(6):1307-1327, 1991.
52. **Phalen DN, Wilson VG, Graham D L:** Epidemiology and diagnosis of avian polyomavirus infection. *Proc Assoc Avian Vet*, 1991, 27-31.
53. **Pilo B, Verma RJ, Shah RV:** Alterations in the lipid content during cutaneous wound healing in hypothyroid pigeons. *Pavo* 25:9-12, 1987.
54. **Purton MD:** Skin surface topography in the domestic fowl and Japanese quail. *Brit Vet J* 142:446-452, 1986.
55. **Reavill DR, Schmidt RE, Fudge AM:** Avian skin and feather disorders: A retrospective study. *Proc Assoc Avian Vet*, 1990, pp 248-255.
56. **Ritchie BW, et al:** A review of psittacine beak and feather disease. *J Assoc Avian Vet* 3(3):143-149, 1989.
57. **Ritchie BW, et al:** Advances in understanding the PBFD virus. *Proc Assoc Avian Vet* 1990, pp 12-24.
58. **Ritchie BW, et al:** PBFD virus: Disease prevention through experimental vaccination. *Proc Assoc Avian Vet*, 1991, pp 50-56.
59. **Roy NA, Threlfall W, Wheeler TA:** Feather loss of unknown etiology in a gull colony in Newfoundland. *Can J Wildl Dis* 22(4):591-594, 1986.
60. **Schmidt RE:** Avian skin diseases: A pathologist's perspective. *Proc Assoc Avian Vet* 1987, pp 117-124.
61. **Spearman RIC:** Physiology and Biochemistry of the Domestic Powl. London, Academic Press, 1971, pp 604-618.
62. **Spearman RIC, Hardy JA:** Integument. In King AS, McLelland J (eds): *Form and Function of Birds Vol. 3* London, Academic Press, 1985.
63. **Scott ML, Ausic R, Gries C:** Nutritional deficiency diseases. In Hofstad M, et al (eds): *Diseases of Poultry* 7th ed. Ames, Iowa State University Press, 1978.
64. **Swain SF:** New concepts in wound management. *Tijdschrift voor Diergeneeskunde* 112:56-58, 1987.
65. **Tollefson CI:** Nutrition. In Petrak ML (ed): *Diseases of Cage and Aviary Birds*. Philadelphia, Lea and Febiger, 1982, pp 361-367.
66. **Tudor DC:** Mycotic infections of feathers as a cause of feather pulling in pigeons and psittacine birds. *Vet Med Sm Anim Clin* 78:249-253, 1983.
67. **Voitkevich AA:** The Feathers and Plumage of Birds. London, Sidgwick and Jackson, 1966.
68. **Wilds C:** The terminology of plumage and molt. *Birding*: 148-154, 1989.
69. **Wertz PW, Downing DT:** Glycolipids in mammalian epidermis: structure and function in the water barrier. *Science* 217:1261-1262, 1982.
70. **Wojcinski ZW, et al:** Cutaneous herpesvirus infection in a mallard duck (*Anas platyrhynchos*). *J Wildl Dis* 27:129-134, 1991.

CHAPTER

# 25

ONCOLOGY

Kenneth S. Latimer

**N**eoplasia is an abnormal, uncontrolled, progressive proliferation of cells in any tissue or organ. Classification of neoplasms is based upon general tissue origin (epithelial vs. mesenchymal), specific cell lineage and whether the neoplasm is benign (-oma) or malignant (sarcoma or carcinoma). Classification of some neoplasms as benign or malignant may require knowledge of the biological behavior of the neoplasm.

The majority of the veterinary medical literature has reported the incidence, gross appearance and microscopic characteristics of neoplasms of domesticated birds, especially poultry.<sup>20,22,23,101,109</sup> Furthermore, the study of retroviral-induced neoplasia in poultry has advanced medical knowledge of retroviral molecular biology, as well as that of neoplasm development, growth and metastasis.<sup>91,101</sup> Similar information concerning neoplasms of captive and free-ranging birds is almost nonexistent. One ultrastructural survey of various budgerigar neoplasms failed to disclose retroviral particles, but sampling errors are a known complication of such studies.<sup>52</sup> More recently, papillomaviruses have been demonstrated as the etiologic agents of cutaneous papillomas in African Grey Parrots, Chaffinches and Bramblings.<sup>73,87,94,96</sup>

Reports of neoplasia are extant for captive as opposed to free-ranging birds,<sup>5,6,7,12,15,49,51,83,102,108</sup> especially budgerigars, where the overall incidence of neoplasia ranges from 16.8% to 24.2%.<sup>12,15,51</sup> In a veterinary diagnostic laboratory with a diverse avian caseload, budgerigars accounted for 69.7% of all psittacine neoplasms and 41% of all avian neoplasms recorded. The overall incidence of neoplasia approximated 3.8% in all avian submissions.<sup>108</sup>

Compared to free-ranging birds, neoplasia is reported more frequently in companion and aviary birds because such birds are observed closely for abnormalities, have a longer life span and may have a genetic predisposition to neoplasia through inbreeding. Little is known, however, concerning the etiology, predisposing factors, development, biological behavior or treatment of neoplasms in companion and aviary birds. As more cases of avian neoplasia are studied and reported, our clinicopathologic knowledge will increase and treatment regimens will improve.

This chapter is written to provide a systems approach to avian neoplasia, with an emphasis on neoplasms of companion, aviary and free-ranging birds. Information is presented to assist the clinician in understanding the complexities and treatment of avian neoplasms (see Table 25.1). Lesions that mimic neoplasia also are discussed briefly. Lastly, the cytologic and histologic features of various neoplasms are presented to assist veterinary pathologists in the diagnosis of these neoplasms (see Table 25.2).

## Integumentary System

Neoplasms of the integumentary system are common and account for 12% to 70% of all avian neoplasms.<sup>6,12,15,108</sup> Of the various neoplasms reported, lipomas and fibrosarcomas are observed most frequently.

### Adipose Neoplasms and Masses

Neoplasms associated with fatty tissue and lipid deposition in companion birds include lipoma, myelolipoma, liposarcoma and hibernoma. Lesions that mimic these neoplasms include xanthomas and lipogranulomas. Definitive diagnosis of each of these neoplasms or masses requires histopathologic examination of surgical biopsy specimens (Figure 25.1).

- **Lipoma:** Lipomas are benign proliferations of well differentiated adipocytes (lipocytes) that may exhibit slow-to-rapid, progressive growth over time. Lipomas are the most frequently observed neoplasm of companion birds, with a reported incidence of 10% to 40% in budgerigars.<sup>143</sup> Besides budgerigars, lipomas may be observed frequently in Rose-breasted Cockatoos (galahs) and Amazon parrots.<sup>98,143</sup> Obesity, advancing age, species of bird and high-energy diets appear to be predisposing factors for tumor development. Based upon clinical observations, a genetic predisposition to lipoma development may exist in budgerigars.

Lipomas usually arise in the subcutis of the sternal or abdominal skin, but may also be observed on the wings, back, neck, legs or near the uropygial gland.<sup>6,12,15,30,49,51,69,72,86,102,108,127</sup> In addition, lipomas may occur in the thoracoabdominal cavity (arising from thoracic or mesenteric fat, ovary, ventriculus and liver) or in association with skeletal mus-



**FIG 25.1** A 15-year-old Amazon parrot was referred for evaluation of a tumor. A previous veterinarian had advised euthanasia. A large, pendulated, ulcerative mass was present on physical examination. The bird was in overall good condition, and abnormal clinicopathologic findings were limited to a mild heterophilia (18,000/ $\mu$ l). Cytology of a fine-needle aspirate revealed an accumulation of necrotic debris and reactive macrophages. The mass was surgically incised, and a piece of wood was found penetrating the esophageal wall. The granuloma was surgically removed, the esophageal defect was repaired and the surgical site was managed as an open wound. A mass should be considered of neoplastic origin only with the cytologic or histologic identification of suggestive cells.

cle.<sup>12,40,102,108,127</sup> Tumor size typically ranges from 0.3 to 4.0 cm in diameter (Color 25.12).

Lipomas occur as single or multiple masses. Affected birds may be presented for diagnosis of a visible skin or subcutaneous mass or abdominal distention. Large tumors may interfere with leg movement, perching or flight. On palpation, lipomas are usually well defined and soft; the overlying skin is freely mobile.<sup>143</sup>

Grossly, excised lipomas appear soft, round-to-multi-lobulated and pale yellow. On cut surface, they are thinly encapsulated and fatty. Histologically, lipomas appear as thinly encapsulated masses composed of lobules of well differentiated adipocytes. Scattered

blood vessels are also present. Central necrosis may be present in larger masses, especially those neoplasms that grow rapidly or are subjected to trauma.

Dietary changes and increased exercise are frequently curative in early cases and should be implemented prior to surgery to reduce the size of the mass. Because lipomas are often accompanied by body fat that may interfere with caudal air sac volume, exercise programs should be initiated with care, especially in tachypneic patients. Surgical excision is necessary if the tumor is causing clinical problems that are not resolved with diet change and increased exercise.<sup>25,30</sup> Lipomas may be vascular; therefore, attention to hemostasis through the use of bipolar radiosurgery is important. Feeding formulated diets should prevent goiter and may also reduce the likelihood of a bird developing lipomas. Non-specific use of thyroxine should be avoided, and treatment of lipomas in the absence of hypothyroidism is not an indication for thyroxine administration.<sup>66,113</sup>

- **Myelolipoma:** Myelolipomas are composed of adipose and hematopoietic tissues that may arise in the subcutis of the trunk, wings and legs. Occasionally they may occur in the liver or spleen. The outward appearance is similar to a lipoma.
- **Liposarcoma:** Liposarcomas are malignant, fatty neoplasms composed of lipoblasts and immature adipocytes. These neoplasms are firm on palpation, poorly encapsulated, highly vascularized and usually arise in the subcutis of the sternum or uropygial gland area.<sup>102</sup> Infrequently, liposarcomas may present as poorly demarcated nodules in the thoracoabdominal cavity, liver or skeletal muscles.<sup>47,108</sup> Liposarcomas are locally invasive, have the potential to metastasize and may arise in a multicentric pattern. Multicentric origin or widespread metastasis is typical.<sup>47</sup>

Histologically, neoplastic cells appear spindle-like, stellate, round or polyhedral. Cell nuclei are round to oval and contain multiple nucleoli. The cytoplasm stains lightly eosinophilic or contains variably sized vacuoles. Larger vacuoles may cause peripheral nuclear displacement. Mitotic figures may be present but are not numerous. The presence of lipid within the cytoplasmic vacuoles may be demonstrated by fat-soluble stains, such as oil red O or Sudan IV, applied to frozen tissue sections. Alternatively, osmicated tissue specimens may be processed routinely and stained with hematoxylin and eosin. In these latter tissue sections, osmicated lipid will appear brown-black.

- **Hibernoma:** A hibernoma is a rare benign tumor of brown fat origin. A subconjunctival hibernoma was successfully excised from a two-year-old male white goose. The neoplasm involved the ventrolateral aspect of the right sclera and protruded through the palpebral fissure, interfering with eyelid closure.<sup>89</sup>

Histologically, neoplastic cells stained faintly eosinophilic, appeared foamy, had central-to-paracentral nuclei and had a voluminous cytoplasm containing numerous, fine vacuoles and birefringent eosinophilic material. The neoplasm was well vascularized and contained a delicate stromal framework. Lipid was demonstrated within the cytoplasmic vacuoles by oil red O staining.<sup>89</sup>

- **Xanthoma/Xanthomatosis:** The term xanthoma means "yellow mass." An xanthoma is not a true neoplasm, but an inflammatory intumescence resulting from the accumulation of lipid-laden macrophages, giant cells, free cholesterol and variable degrees of fibrosis. Xanthomas occur frequently in gallinaceous and psittacine birds, appearing as yellow, single-to-multiple, discrete subcutaneous nodules or diffuse thickenings of skin that may be featherless, ulcerated or hemorrhagic (Color 25.15).<sup>25,143</sup> These masses may occur anywhere on the skin or overlie other neoplasms, especially lipomas (Color 25.2).<sup>143</sup> Infrequently, xanthomas may have a periarticular arrangement or involve the oral cavity.<sup>60,111</sup>

Although the precise etiology of xanthoma formation is unknown, various theories have been proposed including high-lipid diets or ingestion of toxic fat-soluble substances (such as aromatic chlorinated hydrocarbons) that might incite inflammation and trauma.<sup>25,98,117,143</sup> Cellular infiltrates, lipid accumulation and fibroplasia give rise to the nodular or tumorous appearance of these lesions. Unresectable or multiple skin xanthomas may respond to irradiation (low-energy X-rays; 20 to 30 Gy) or hyperthermia.<sup>143</sup> Dietary restriction of oily seeds may be beneficial in the medical management of xanthomatosis.<sup>34</sup>

#### Connective Tissue Neoplasms and Masses

Connective tissue neoplasms (fibrosarcoma, fibroma, myxosarcoma and myxoma) arise from the proliferation of fibroblasts or undifferentiated mesenchymal cells, which frequently assume a spindle-like appearance. These neoplasms contain a collagenous or mucinous stroma. Cellular morphology, mitotic index

and biological behavior are used to classify these neoplasms as benign or malignant.

In chickens, connective tissue neoplasms can arise following infection with specific strains of avian leukosis or sarcoma virus.<sup>101</sup> The etiology of similar neoplasms in aviary and free-ranging birds is unknown.

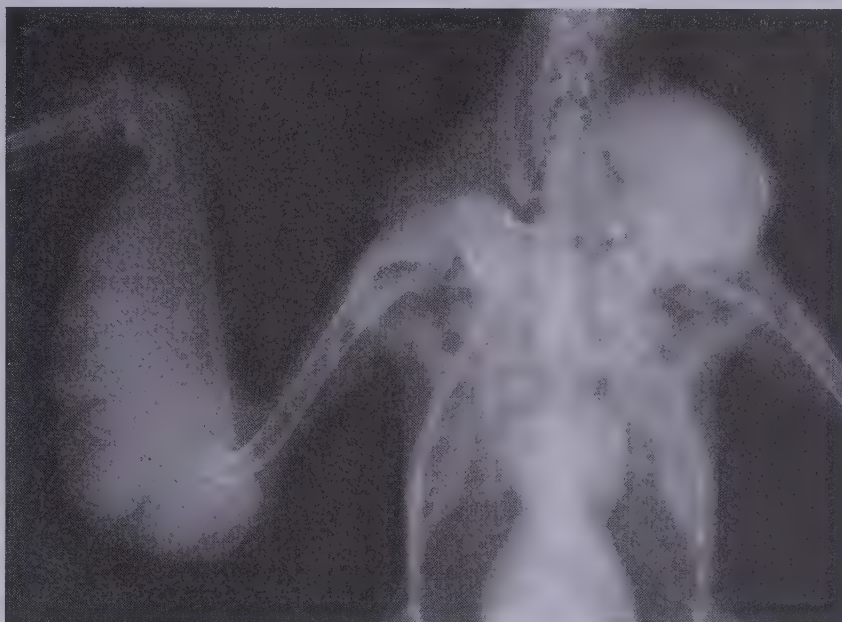
- **Fibrosarcoma:** Fibrosarcoma is a malignant neoplasm of fibroblast or mesenchymal cells, which possess the ability to produce collagen fibers. Fibrosarcomas occur commonly in budgerigars, cockatiels, macaws and parrots.<sup>7, 25, 49, 108, 110, 143</sup> Fibrosarcomas may constitute 3 to 14% of all neoplasms in budgerigars.<sup>143</sup>

Clinically, fibrosarcomas are firm, single-to-multiple, broad-based, relatively immobile nodules or masses. Superficial fibrosarcomas may be covered by an intact-to-ulcerated epidermis accompanied by hemorrhage and secondary bacterial infections. Fibrosarcomas commonly arise from the soft tissues of the wing, leg, head, beak, cere and trunk (Color 25.1, 25.5, 24.19).<sup>6, 11, 12, 15, 72, 75, 102, 108, 110</sup> They also may arise in the viscera and deep tissues including thoracoabdominal cavity, spleen, liver, mouth, tongue, syrinx, lung, small intestine, proventricular wall, testes and ovary (Figure 25.2).<sup>12, 27, 102, 108</sup> These neoplasms are locally invasive and may eventually metastasize, especially to the abdominal cavity, lungs, liver, kidney, heart base and bone (Figure 25.3).<sup>12, 102, 108, 110, 143</sup> Intra-abdominal neoplasms also have been observed enveloping bowel loops and adhering to the pancreas.<sup>82, 127</sup> These neoplasms have been reported as neurofibrosarcomas based upon cellular arrangement or pattern, but a neural origin has not been demonstrated.


- **Fibroma:** A fibroma is an uncommon benign neoplasm composed of well differentiated fibroblasts distributed within a collagenous matrix. Fibromas are firm on palpation and may arise almost anywhere, but usually involve a firm mass in the skin

and subcutaneous tissues of the wing, leg, face, beak, neck or sternum.<sup>12, 32, 69, 72, 143</sup>

- **Myxoma and Myxosarcoma:** These neoplasms are of fibroblast or mesenchymal cell origin, but possess abundant mucinous stroma. These rare neoplasms may arise wherever connective tissue exists including the foot pad, cranium, leg, kidney, commissure of the beak and within the thoracic cavity.<sup>15, 108</sup> Clinically, these masses may appear soft on palpation and gelatinous on cut surface. In myxosarcomas, neoplas-



**FIG 25.2** A ten-year-old Amazon parrot was presented with a one-year history of a progressive swelling of the head and face (see Color 25.1). Physical examination revealed numerous masses throughout the body that were confirmed by radiographs. Histopathology indicated an invasive fibrosarcoma involving the soft tissues and bones of the head (courtesy of Jane Turrel).



**FIG 25.3** An adult female dove was presented with a soft tissue swelling involving the right scapulothoracic region. Radiographically, a large, uniform, soft tissue mass with osteolysis involving the humeral head and diaphysis was noted. The increased medullary bone density was considered normal for a laying hen. Cytology of a fine-needle aspirate confirmed fibrosarcoma (courtesy of Marjorie McMillan).

tic cells appear to be more numerous and contain plump nuclei. Metastasis may occur, but is infrequent to rare.

- **Reactive Fibroplasia:** Granulation tissue exemplifies healing by second intention. Granulation tissue may be highly vascular and proliferative with variable degrees of inflammation. Grossly, granulation tissue may have a proliferative or neoplastic-like appearance. Cytologic specimens often contain a pleomorphic population of immature fibroblasts that mimic neoplasia. Inflammatory cells may be admixed with blood. Histologically, tissue architecture is a differentiating feature of the lesion wherein blood vessels are oriented at right angles to the surface of the lesion, while fibroblasts are oriented parallel to the surface of the lesion. Marked, proliferative fibroplasia with granuloma formation also may be observed in the ceca of gallinaceous birds, especially pheasants, infected with *Heterakis isolonche* (see Color 14). In such instances, nematode-induced reactive fibroplasia may be difficult to distinguish from neoplasia.<sup>57,62</sup>

#### Epithelial Neoplasms and Cysts

- **Papillomas and Papilloma-like Lesions:** Cutaneous papillomas are observed occasionally in domestic, captive and free ranging birds.<sup>4,6,11,15,46,73,98</sup> Multiple papillomas most frequently originate from the skin of the eyelids, at the junction of the beak and face, and on the feet and legs. The anatomic location of these benign neoplasms may interfere with vision, prehension of food or perching if the lesions are severe (Color 25.17). Histologically, these lesions consist of folds of hyperplastic stratified squamous epithelium over a fibrovascular stroma. Cutaneous papillomas are viral-induced, at least in African Grey Parrots, Chaffinches and Bramblings (Color 25.10) (see Chapter 32).<sup>73,87,96</sup>
- **Squamous Cell Carcinoma:** Squamous cell carcinoma is observed most frequently in chickens but has also been described in captive and free-ranging birds in the skin of the head, eyelids, neck, chest, wings or around the beak (Color 25.9).<sup>6,7,15,29,49,59,108,135,142</sup> Grossly, these neoplasms appear as multiple, raised masses with central craters or ulceration (Color 25.7). Multiple neoplasms usually are present, involving both feathered and unfeathered areas of the skin. An interesting recent study indicates that these neoplasms originate as elevated keratin-filled cysts that subsequently ulcerate and flatten. Some lesions may subsequently resolve as dermal scars.<sup>59</sup>

Histologically, these dermal squamous cell carcinomas are characterized by epidermal ulceration and infiltration of the subjacent dermis by squamous cells. These cells are scattered singly or arranged in nests and cords. Infiltration of underlying skeletal muscle is rare. Laminated keratin pearls may be observed within epithelial cell cords in companion and free-ranging birds.<sup>108</sup> The etiology of multifocal, dermal squamous cell carcinoma of chickens has not been determined.


- **Uropygial Gland Adenoma and Adenocarcinoma:** Uropygial gland neoplasms occur sporadically in captive birds, especially budgerigars and canaries.<sup>6,102,108</sup> On physical examination, the uropygial gland may appear enlarged, ulcerated and hemorrhagic (Color 25.11). Neoplasia must be distinguished from adenitis, which usually requires histologic examination. Partial or complete removal of the affected gland is recommended (Figure 25.4).
- **Feather Folliculoma:** Feather folliculomas occur primarily in canaries and budgerigars.<sup>18,108,149</sup> These neoplasms may appear as discrete, mobile, single or multiple dermal nodules that may ulcerate or hemorrhage (see Color 14). Microscopically, these lesions appear multilobulated and are lined with irregular, hyperplastic, basaloid cells that exhibit feather formation. Basal cells are arranged in barb ridges and undergo abrupt squamous differentiation in the center of the mass, forming laminations of free keratin.<sup>108,149</sup>
- **Miscellaneous Basal Cell Tumors and Cutaneous Cysts:** All of these neoplasms present as discrete skin nodules. Basal cell tumors are composed of sheets, nests or cords of basaloid epithelial cells. This cell population does not exhibit terminal cellular or structural differentiation.<sup>5,25,108</sup>

Intradermal cystic lesions occasionally are observed in captive and free-ranging birds. Histologically, these lesions often appear cystic as a result of glandular differentiation or keratin production. Those benign neoplasms that exhibit glandular differentiation are cystadenomas.<sup>67</sup> Cystic lesions with keratin production are classified on the basis of gradual or abrupt keratinization. Gradual keratinization is observed with epidermal inclusion cysts, follicular cysts and intracutaneous cornifying epitheliomas.<sup>88,108,130</sup> Those cystic lesions with abrupt keratinization include trichoepithelioma and pilomatrixoma.<sup>88,108</sup>

#### Miscellaneous Neoplasms

- **Cutaneous Lymphosarcoma:** Cutaneous lymphosarcoma is observed in chickens as a manifestation of





**FIG 25.4** A 36-year-old macaw was presented for evaluation of a progressive mass over the dorsal spine and straining to defecate. On physical examination, a large mass was noted in the area of the uropygial gland and dried excrement had accumulated around the vent. Tenesmus was noted during the physical examination. Radiographs indicated a large mass that had invaded the synsacrum and was displacing the cloaca ventrally. The histopathologic diagnosis was adenocarcinoma of the uropygial gland (courtesy of Jane Turrel).

Marek's disease and may occasionally occur in captive and free-ranging birds.<sup>9,100,105</sup> Neoplastic lymphocytes may exhibit multifocal to diffuse follicular and perifollicular infiltration, producing numerous skin nodules that may ulcerate along feather tracts.<sup>20,98</sup> In psittacine birds, cutaneous neoplasms may develop under the skin of the face or neck, often in association with generalized or systemic lymphosarcoma.<sup>9</sup>

- **Mast Cell Tumor:** Mast cell tumors have been reported in three owls and a chicken.<sup>99,124,139</sup> In owls, mast cell neoplasms usually are associated with the skin of the eyelid or auditory meatus, but may also be observed in the mouth.<sup>124,139</sup> Generally, animal species with a higher circulating basophil count have fewer tissue mast cells, which may explain the rarity of mast cell tumors in avian species. Mast cell tumors appear grossly as raised-to-spherical, pink-to-red, dermal or submucosal masses. In some instances, neoplastic margins may be indistinct or the neoplasm will demonstrate marked local tissue invasion.<sup>124,139</sup> Attempted surgical excision of a mast cell tumor was unsuccessful in one owl.<sup>124</sup>

## Respiratory System

The avian lung serves as a metastatic site for many neoplasms including fibrosarcoma, adenocarcinoma, hemangiosarcoma, malignant melanoma, mesothelioma and osteosarcoma (Figure 25.5).<sup>12,78,81,102,108,127</sup> In contrast, primary neoplasms of the avian respiratory system are rare in species other than chickens.

- **Lymphosarcoma and Hemangiosarcoma:** Chickens with Marek's disease (Marek's lymphoma) often have herpesvirus-induced pulmonary lymphoid tumors.<sup>109</sup> Multicentric hemangiosarcomas of chickens also may originate in the pulmonary parenchyma.<sup>74,129</sup> Hemangiosarcomas occur in fowl infected with retrovirus and are discussed under the circulatory system.

- **Papilloma:** Laryngeal papillomas are observed occasionally in psittacine birds, especially Amazon parrots and macaws.<sup>36,55,102</sup> Papillomas also may occur within the nares and choanal area.<sup>36,55</sup> Clinically, laryngeal papillomas may cause dyspnea. These lesions may be surgically excised, but will recur if excision is incomplete.<sup>102</sup>
- **Bronchiolar Adenoma and Adenocarcinoma:** A bronchiolar adenoma has been reported in a parrot.<sup>108</sup> The neoplasm appeared as a large, lobulated, adenomatous nodule within a major bronchus. A bronchiogenic adenocarcinoma has been reported in a quail, but histologic features of the neoplasm were not described.<sup>49</sup>
- **Fibrosarcoma:** A solitary pulmonary fibrosarcoma has been described in a cockatiel. Due to the absence of other neoplastic nodules, primary pulmonary origin was suggested.<sup>27</sup>
- **Ectopic Pulmonary Ossification:** Ectopic pulmonary ossification may be confused radiographically with pulmonary metastasis. This subject is discussed below (bone proliferation resembling neoplasia; musculoskeletal system).

- **Ultimobranchial Cyst:** Ultimobranchial cysts develop from branchial pouch remnants following embryogenesis. A large ultimobranchial cyst has been observed in the lower neck of a lorikeet. The thyroid gland was displaced by this mass. Histologically, the neoplasm was lined by squamous epithelium and contained laminated keratin material and desquamated cells within the cyst lumen.<sup>108</sup>

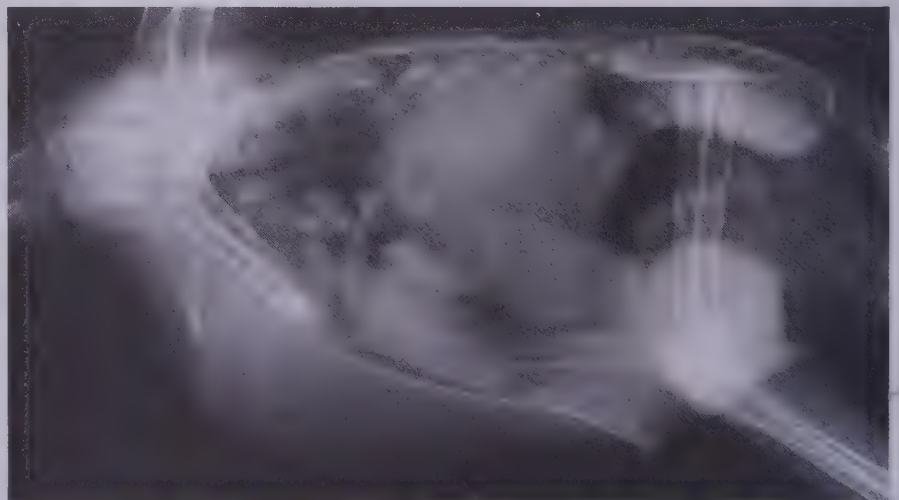
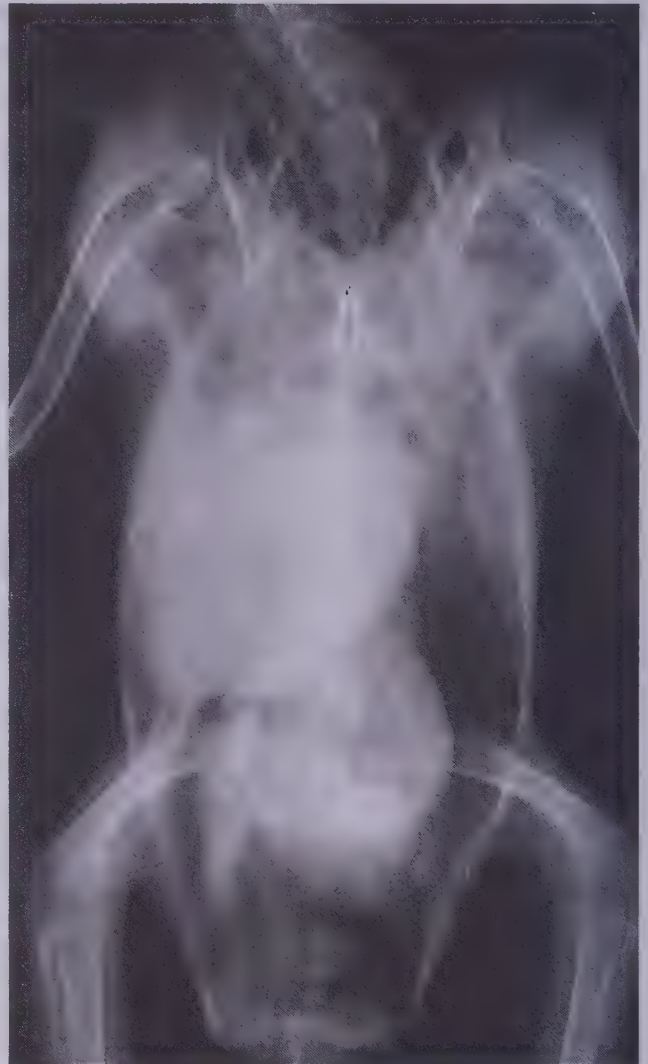## Circulatory System

Vasoformative neoplasms originate from endothelial cell proliferation with subsequent formation of irregular vascular channels and spaces filled with blood (or rarely with lymph). These neoplasms may form wherever endothelium exists; however, preferred sites of origin are apparent. Vasoformative neoplasms are classified as benign (hemangioma, lymphangioma) or malignant (hemangiosarcoma, lymphangiosarcoma).

Vasoformative neoplasms must be distinguished from non-neoplastic conditions such as vascular malformations (arteriovenous fistulas and aneurysms), hematomas, excessively vascularized granulation tissue or other neoplasms with a rich blood supply.<sup>84,88</sup> Definitive diagnosis requires histopathology.

In chickens, vasoformative neoplasms may arise as a sequela to avian leukosis virus, subgroup F infection. These virus-induced neoplasms may progress from benign growths to fibrosarcoma-like neoplasms, analogous to Kaposi's sarcoma in human beings.<sup>42</sup> In contrast, reports of vasoformative neoplasms in captive and free-ranging birds are sporadic and of undetermined etiology.<sup>14,72,85, 102,108,127,143</sup>

On gross inspection, hemangiomas and hemangiosarcomas may appear as single-to-multiple; variably-sized; pink, red or blue-black nodules (blood blisters), swellings or multiloculated masses within the skin or abdominal viscera.<sup>22,74</sup> Internal neo-



**FIG 25.5** Radiographs of a four-year-old female African Grey Parrot indicated a large, soft tissue mass in the right thoracic area. Histopathology revealed a renal tubular adenocarcinoma with metastasis to the lung, liver and myocardium (see Color 25.13).

plasms may present as primary abdominal distention from tumor mass or secondary abdominal distention from hemorrhage (hemoperitoneum). Vasoformative neoplasms may hemorrhage spontaneously or following minor trauma (palpation) resulting in anemia or exsanguination.<sup>19,25,98</sup>

- **Hemangioma:** Cutaneous hemangiomas often arise within subcutaneous tissues of the dorsum of the neck, wing or legs.<sup>15,25,102</sup> Feather follicles also may be involved.<sup>25</sup> Abdominal hemangiomas may arise in the spleen, liver, kidney or testicular capsule. These latter neoplasms may cause abdominal distention by tumor mass or hemorrhage (hemoperitoneum).<sup>22,49,102</sup> External hemangiomas, particularly on the wing tips, are subject to trauma and may bleed profusely.

Cytologic aspirates of hemangiomas are of limited diagnostic value and generally consist of blood. Endothelial cells are rarely observed. Erythrophagocytosis, hemosiderin-laden macrophages and hematoidin crystals may be observed if concomitant hemorrhage is present. Hemosiderin is an iron pigment derived from erythrocyte catabolism. This pigment appears globular and blue, golden-brown or greenish-black in Romanowsky-stained cytology preparations. Hematoidin, a hemoglobin breakdown product, appears as small, bright-yellow, parallelogram-shaped crystals that are observed most frequently within the cytoplasm of macrophages. Hematoma, hemangioma and hemangiosarcoma may be difficult or impossible to distinguish cytologically.

Histologically, hemangiomas are composed of variably-sized vascular spaces and channels that are lined by flattened endothelium. Occasional solid areas of plump endothelial cells also may be observed. Vascular spaces typically contain blood, plasma or fibrin thrombi. On rare occasions, immature hematopoietic precursor cells may be adherent to the endothelium.

- **Hemangiosarcoma:** Hemangiosarcomas may arise singly or in a multicentric pattern. These neoplasms often arise in the skin, liver, lungs, spleen, muscle, mesentery, kidney, heart, oviduct, bone or synovium.<sup>19,49,74,102,108,127,128,129,143</sup> Hemangiosarcomas that develop in the distal diaphysis of long bones may exhibit aggressive osteolysis and surface hemorrhage (Figure 25.6).<sup>143</sup> Hemangiosarcomas may metastasize to distant tissues including lung, liver or myocardium.<sup>102,143</sup>

Cytologic aspirates are similar to those described for hemangiomas; however, widely scattered pleomor-

phic endothelial cells may be present. These endothelial cells usually appear polyhedral-to-spindle-shaped with round-to-oval nuclei and dark-blue, occasionally finely vacuolated, cytoplasm. Aspiration sites may hemorrhage profusely.

Histologically, vascular spaces in hemangiosarcomas are lined by plump endothelial cells with hyperchromatic nuclei. Mitoses may be observed. Neoplastic cells often dissect surrounding structures and exhibit vascular invasion. Secondary hemorrhage is common.

- **Lymphangioma:** Birds possess lymphatic channels but they appear less well developed than corresponding structures in mammals. Lymphangiomas are benign neoplasms wherein endothelial cells form lymphatic channels. These neoplasms are extremely rare in all species, especially birds. Lymphangioma has been reported in the mesentery and spleen of a rhea and budgerigar, respectively.<sup>72,102</sup> However, the budgerigar neoplasm closely resembled a hemangioma.<sup>102</sup>

Histologically, these neoplasms consist of vascular channels lined by flattened epithelium and filled with lymph. Lymph appears as a homogeneous, light-pink substance.



## Musculoskeletal System

### Neoplasms of Smooth and Striated Muscle

Neoplasms originating from striated or smooth muscle that are benign or malignant are observed occasionally in captive and free-ranging birds. Muscle neoplasms presumably arise from embryonic remnants of myotomes, from pluripotential cells of embryologic structures or from neoplastic transformation of myoblasts during degeneration or repair processes.<sup>88</sup> Generally, smooth muscle neoplasms are reported about twice as frequently as striated muscle tumors. Furthermore, malignant neoplasms are reported twice as frequently as their benign counterparts.

- **Leiomyoma:** Leiomyomas are benign neoplasms that generally are nodular and may arise from smooth muscle of the gastrointestinal or female reproductive tract, especially the oviduct. Other sites of origin include smooth muscle trabeculae within the spleen or smooth muscle associated with vessels or



**FIG 25.6** A dove was presented with lameness and a large swelling of the metatarsal area. Radiographically, the mass involved proliferation of soft tissues and osteolysis resulting in a pathologic fracture. The histologic diagnosis was hemangiosarcoma (courtesy of Jane Turrel).

ducts in the pancreas.<sup>15,102,108</sup> Leiomyomas usually exhibit slow growth and may be associated with abdominal distention, gastrointestinal or reproductive tract obstruction, or organ displacement.

Cytologic aspirates and imprints are sparsely cellular, containing only scattered free nuclei or a few spindle cells with elongate nuclei. Histopathology reveals a uniform population of elongate cells arranged in broad, interlacing bands. These cells have cigar-shaped nuclei and eosinophilic cytoplasm. Mitoses are observed infrequently.

- **Leiomyosarcoma:** Leiomyosarcomas are the most common muscle neoplasm reported in captive and free-ranging birds.<sup>15,102</sup> They may arise from smooth muscle in any location, but usually arise from splenic smooth muscle trabeculae.<sup>12,15,102</sup> Other sites of origin include crop, intestinal tract, trachea, pancreas, oviduct, ventral ligament of the oviduct, vas deferens and testicular capsule.<sup>12,15,25,102,133</sup> Leiomyosarcomas may be locally invasive. Metastasis is a late and infrequent event, but has been documented to involve the liver, spleen, thoracic cavity and bone marrow.<sup>15,119</sup>

Cytologic imprints of leiomyosarcomas may contain free nuclei and a pleomorphic but sparse population of spindle cells. Distinguishing leiomyosarcomas from fibrosarcomas may be difficult cytologically. Grossly, excised neoplasms appear firm, pink, poorly delineated and unencapsulated. Microscopically, leiomyosarcomas are hypercellular with spindle cells arranged in sheets, interlacing bundles or whorls. Neoplastic myocytes have plump often pleomorphic nuclei, occasional nucleoli and variable amounts of eosinophilic cytoplasm.

- **Rhabdomyoma:** Rhabdomyomas are benign neoplasms of striated muscle and are the rarest muscle neoplasm reported in captive birds. Reported sites of origin include the wing, tongue and eyelid.<sup>12,15,108</sup> These neoplasms may be solitary or multinodular, blending with surrounding skeletal muscle.

Cytologic aspirates are unrewarding except for possible fragments of striated muscle cells. Histologically, rhabdomyomas are composed of cells ranging from a fibroblast appearance to multinucleated cells. Most cells have distinct fibrillar cross striations. Some cells may appear vacuolated and have high glycogen content demonstrated by diastase-labile, periodic acid Schiff (PAS)-positive granules.<sup>88</sup>

- **Rhabdomyosarcoma:** Rhabdomyosarcomas are of skeletal muscle origin and frequently present as irregular, elevated, lobulated, relatively firm subcutaneous swellings of the wing or shoulder that limit the use of the wing.<sup>12,15,51,102</sup> Because these neoplasms blend with surrounding skeletal muscle, they are immobile or firmly attached on palpation. Less frequently, neoplasms will arise from other sites such as the dorsal lumbar musculature.<sup>107</sup> Metastasis to the abdominal cavity and liver was reported in one bird.<sup>107</sup>

Cytologic studies of rhabdomyosarcomas have not been reported. Microscopically, the neoplasms are composed of a pleomorphic population of fusiform-to-elongated cells. Anisokaryosis may be prominent with plump oval-to-elongated nuclei. Some elongated or "strap cells" will retain cross striations typical of skeletal muscle cells. Phosphotungstic acid hematoxylin (PTAH) staining may facilitate identification of these cross striations.

#### Neoplasms of Cartilage and Bone


Neoplasms arising from cartilage and bone are observed occasionally. Osseous neoplasms usually arise from the long bones, while cartilaginous neoplasms often arise on the foot. Cytology may suggest the

presence of mesenchymal neoplasia by demonstrating a pleomorphic population of spindle-to-polyhedral cells and possible matrix material; however, histopathology is required to determine whether the neoplasm originates from cartilage or bone and to determine whether the neoplasm is benign or malignant.

- **Chondroma:** Chondromas are reported occasionally in captive and free-ranging birds, especially of the order Anseriformes.<sup>108</sup> Grossly, these neoplasms may be single or multiple. They often arise on the plantar surface of the foot pad where they may be subjected to trauma with subsequent hemorrhage and ulceration of the overlying epidermis.<sup>108</sup> Other sites of origin of chondromas include the cranium (especially in canaries) and proximal humerus (Figure 25.7).<sup>108</sup>

Histologically, these neoplasms consist of nodular, encapsulated foci of developing chondrocytes separated by connective tissue septa. Variable amounts of sulfated mucopolysaccharide matrix and lacunae may be observed.

- **Chondrosarcoma:** Chondrosarcomas are very rare in comparison to chondromas. A chondrosarcoma has been reported involving the metatarsal-phalangeal joint of a ruffed grouse; however, the histologic appearance of the lesion is similar to a multilobular chondroma.<sup>25,127</sup>



**FIG 25.7** A mature cockatiel from an aviary flight was presented with a mass that had been progressing in size for a year. The mass was fluid-filled (serosanguinous), and cytologic evaluation of the fluid was nondiagnostic. The mass was excised and the cranium formed the base of the mass. The bird recovered uneventfully. Histopathology indicated a bone cyst. Trauma was considered the most likely cause (courtesy of Tom Tully).

- **Osteoma:** Osteomas are observed infrequently in birds compared to osteosarcomas. Osteomas may originate from the cranium, scapula, tarsometatarsus, plantar foot pad and elbow joint.<sup>6,12,49,51,108</sup> Histologically, osteomas are small, well encapsulated nodules composed of disorganized bony trabeculae and are attached to adjacent bone.<sup>108</sup> Surgical excision is the treatment of choice.

- **Osteosarcoma:** Osteosarcomas occur 3.5 times more frequently than osteomas and usually originate from the proximal or distal portion of long bones including the radius, humerus, femur, tibiotarsus and tarsometatarsus (Figure 25.8).<sup>5,6,12,51,72,81,102,108</sup> Less frequent sites of origin include the ribs, phalanges, cranium, orbit and coccyx.<sup>6,102,108</sup> Osteosarcomas may metastasize widely to such sites as the lungs, liver, kidney, ovary, mesentery and other bones (Color 25.16).<sup>81</sup>

Histologically, osteosarcomas are composed of polyhedral-to-spindle mesenchymal cells that produce osteoid. Bony trabeculae may be present but disorganized. Scattered islands of cartilage, fibrous connective tissue, and myxomatous matrix also may be present.<sup>108</sup> Scattered mitotic figures may be observed.

#### Bone Proliferation Resembling Neoplasia

Radiographically, skeletal hyperostosis is recognized by increased medullary bone density, increased bone thickness and deformities involving one or multiple long bones. The differential diagnosis for increased medullary opacity of long bones includes osteopetrosis, polyostotic hyperostosis, metastatic neoplasia, hypertrophic osteopathy and metabolic bone disease.

- **Osteopetrosis:** Osteopetrosis is defined as marked subperiosteal proliferation of bone resulting in loss of medullary space, increased bone thickness and deformity. Osteopetrosis in chickens occurs sporadically and is caused by leukosis/sarcoma virus infection. Depending upon the strain of virus, osteopetrosis may be experimentally induced within one to three months of virus inoculation with a disease frequency of 60-100%.<sup>125,126</sup>

Histologically, decalcified sections of bone demonstrate marked proliferation of porous subperiosteal bone. Osteoclast numbers are normal, but a marked increase in osteoblastic activity exists.<sup>109,125,126</sup>

▪ **Ovarian and Oviductal Neoplasms and Cysts:**

Cystic ovaries, oviductal carcinoma and ovarian neoplasms may induce generalized or localized bone formation in companion birds.<sup>5,12,132</sup> Increased medullary bone density is apparent on survey radiographs. Histologically, the increased medullary density is the result of formation of bone spicules throughout the marrow cavity.

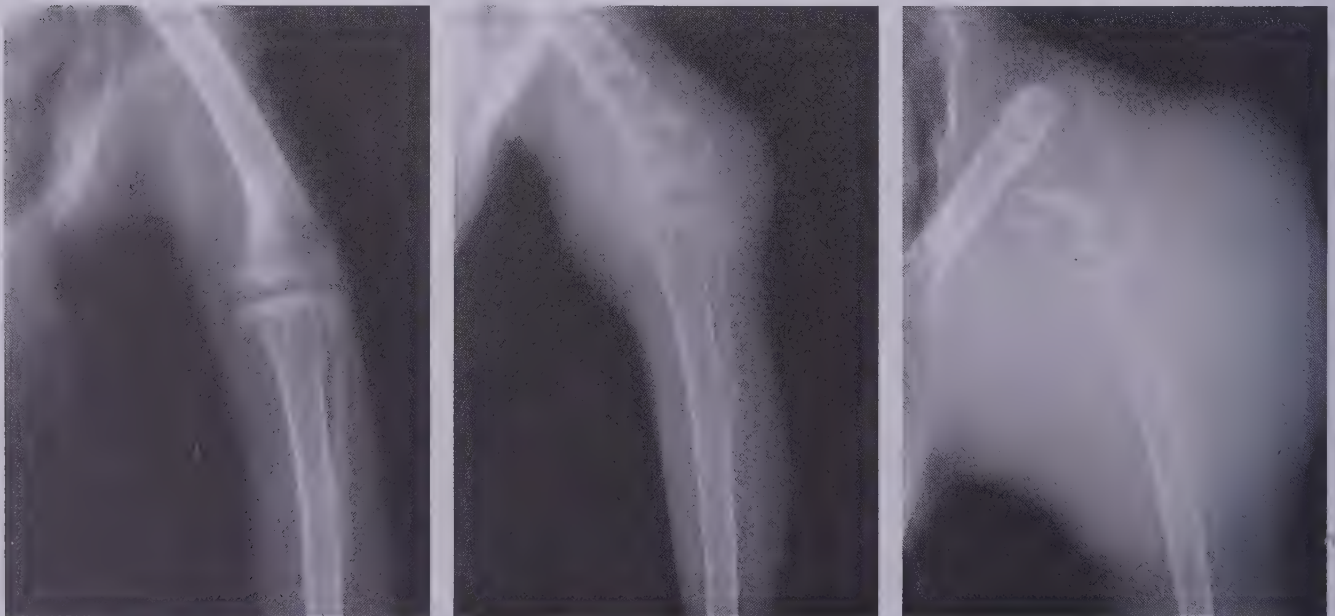
- **Ectopic Pulmonary Cartilage and Bone:** Ectopic pulmonary cartilage and bone formation may be observed in the lung parenchyma of chickens, especially broilers.<sup>16,109,150</sup> The incidence varies with the strain of bird, suggesting a genetic predisposition to this condition. This condition probably represents abnormal embryonic induction of mesenchyme or germ cells displaced from adjacent bronchi during development.<sup>150</sup> Alternatively, osseous or cartilaginous metaplasia also may explain the development of this condition. Histologically, nodules of cartilage or bone are present within the pulmonary parenchyma.<sup>109,150</sup>

Ectopic pulmonary ossification has been observed in an Orange-winged Amazon Parrot and a Senegal Parrot. Survey radiographs in both birds detected multifocal opacities throughout the lung fields, suggesting deep mycosis or metastatic neoplasia. Lung biopsy specimens, however, contained only small foci of osseous tissue within the parenchyma.

## Urogenital System

Neoplasms of the urogenital system are reported frequently, especially in budgerigars. In a recent survey, urogenital tumors accounted for 12.5% (7.3% renal and 5.2% genital) of all neoplasms in a diverse avian population.<sup>108</sup> Surveys in budgerigars indicate an 11.2 to 66.0% incidence of urogenital neoplasia.<sup>7,12,15,92</sup> Testicular neoplasms of captive and free-ranging birds are approximately three times as common as ovarian and oviductal neoplasms. This observation may be explained partially by the presence of bilateral testes in the male but only one functional ovary and oviduct in the normal hen.

Larger neoplasms may cause abdominal distention or respiratory embarrassment. Some renal, testicular, ovarian and oviductal neoplasms may cause unilateral or bilateral leg paresis or paralysis with difficulty or inability to perch.<sup>12,51,92</sup> This occurs because the nerves of the sacral plexus pass through the mid portion of the kidney where they are subject to compression or infiltration by neoplastic cells. Lastly, gonadal neoplasms may be associated with various paraneoplastic syndromes such as feminization or



**FIG 25.8** A nine-year-old Sulphur-crested Cockatoo was presented with a left limb lameness. An initial radiograph (left) indicated osteolysis of the distal femur that was diagnosed as osteomyelitis. A second radiograph (middle) taken seven weeks later indicated increased soft tissue swelling and osteolysis. A biopsy was non-diagnostic. A third radiograph (right) taken three months after initial presentation indicated a pathologic fracture with marked osteolysis. The histologic diagnosis was anaplastic sarcoma.


masculinization and localized or polyostotic hyperostosis (Figure 25.9).<sup>5,6,12,92,102,132</sup> Feminization or masculinization is most apparent in budgerigars where the male's cere may change from blue to brown, or the female's cere may turn from brown to blue (see Color 24).<sup>6,12,102</sup>

### Renal Neoplasms

Renal neoplasms are observed occasionally in free-ranging and captive birds, especially budgerigars. Renal neoplasms usually occur unilaterally, but may occur bilaterally, and presenting complaints generally include an inability to perch or ambulate.<sup>12,51,102,108</sup> Abdominal enlargement and articular gout also may occur.<sup>12</sup>

The etiology of renal neoplasms is obscure, but they may originate from embryonal nests in the avian kidney. In poultry, renal neoplasia is usually a sequela to avian leukosis virus infection.<sup>101</sup>

Renal neoplasms are difficult to manage surgically. Renal carcinomas may aggressively invade adjacent muscle and bone. Because the kidneys are located in the renal fossae, neoplasms are difficult to isolate and excise (Figure 25.10). The sacral plexus passes through the mid portion of the kidney and is subject to trauma. Finally, the kidneys are highly vascular and marked hemorrhage is expected. Treatment of renal neoplasms using radioisotope implants appears promising, but will require further evaluation.<sup>143</sup>



**FIG 25.9** A five-year-old male budgerigar was presented because of a change in cere color (from blue to pink), abdominal distention and unilateral leg paresis. Radiographs indicated a large soft-tissue opacity in the abdomen and polyostotic endosteal hyperostosis of the long bones. The clinical and radiographic findings were highly suggestive of a gonadal tumor. Histopathology confirmed a sertoli cell tumor, which was probably secreting low levels of estrogen (courtesy of Jane Turrel).

- **Renal Carcinoma:** Renal carcinoma is the most frequently observed renal neoplasm in captive and free-ranging birds.<sup>7,12,41,49,69,71,85,102,108,144</sup> Renal adenocarcinomas may infiltrate adjacent muscle and bone with extension into the spinal canal. Distant metastasis to the liver and oviduct may occur, but is unusual (Color 25.13).<sup>69,71</sup>

Affected kidneys contain large, pale, multilobulated masses. Histologically, these neoplasms are composed of vesicular epithelial cells arranged in sheets, nests, cords or tubules. Epithelial cells may be cuboidal to columnar, especially those cells involved in tubular formation. Fibrovascular stroma may be prominent. A few multinucleated cells and scattered mitoses may be observed within the neoplasm.<sup>102,108</sup>

- **Renal Adenoma:** Renal adenomas are benign neoplasms that are observed infrequently compared to renal adenocarcinomas.<sup>7,49,85</sup> Although gross enlargement of a portion of the kidney is apparent, the microscopic appearance of the tissue may be unremarkable-to-subtle in comparison to the normal kidney. Epithelial cell cytoplasm may be slightly more basophilic. Compression of adjacent normal parenchyma occurs as the neoplasm slowly enlarges.
- **Embryonal Nephroma:** Embryonal nephroma (nephroblastoma, Wilms's tumor) has been observed most commonly in chickens infected with leukosis (sarcoma) virus. In chickens, these neoplasms usually are unilateral but may arise bilaterally.<sup>23,101,109</sup> In captive and free-ranging birds, these neoplasms are observed occasionally, especially in budgerigars.<sup>12,15,102</sup> The literature suggests they are more frequent than adenomas but less common than adenocarcinomas. These neoplasms are believed to arise from the metanephric blastema.<sup>88</sup>

On gross inspection, embryonal nephromas cannot be distinguished from renal adenocarcinomas. Histologically, epithelial cells are arranged in solid masses of variably-sized tubules or cords. Characteristic features include the formation of tubules and glomerulus-like structures. Variable quantities of mesenchymal stroma may be present, which further undercores the embryonal nature of the neoplasm.<sup>88,102</sup> Rare metastasis to the liver and

spleen may occur, but is poorly documented.<sup>15</sup>

### Testicular Neoplasms

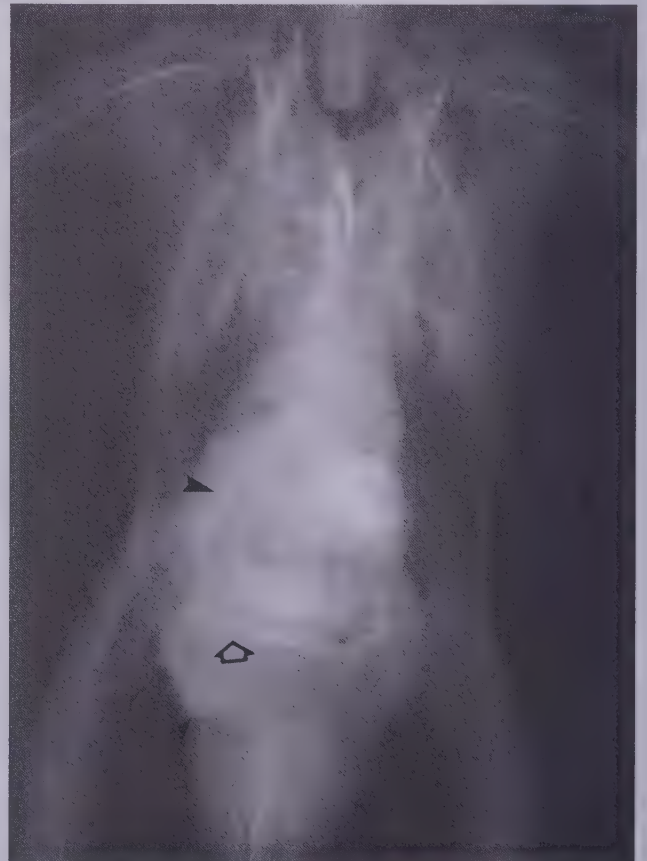

Testicular neoplasms are usually unilateral, but may occur bilaterally. With unilateral neoplasms, atrophy of the contralateral testis may be observed. In rare instances, a collision tumor may be observed in which two or more cell lines are involved in the neoplastic process.<sup>12</sup> Cytologic studies have not been performed on avian testicular neoplasms. Definitive diagnosis of the following neoplasms is dependent upon histopathologic examination. Orchiectomy is the treatment of choice but must be initiated early for a successful outcome.

- **Sertoli Cell Tumor:** Sertoli cell tumor is one of the most frequent testicular neoplasms encountered in captive and free-ranging birds.<sup>5,12,49,51,53,102,108</sup> These cells constitute a portion of the intratubular gonadal stroma, secreting testicular fluid and nourishing developing spermatids. If neoplastic Sertoli cells are synthesizing estrogen, feminization may be present. This phenomenon is most noticeable in male budgerigars in which the cere color changes from blue to brown (Figure 25.11).<sup>12</sup>

Neoplastic testes appear as enlarged, pale, firm, nodular masses. Neoplasms may have a pink tinge secondary to central necrosis and hemorrhage. Variably sized, fluid-filled cystic spaces also may be present.<sup>53,108</sup> Serosal metastases are unusual but may occur.<sup>108</sup>

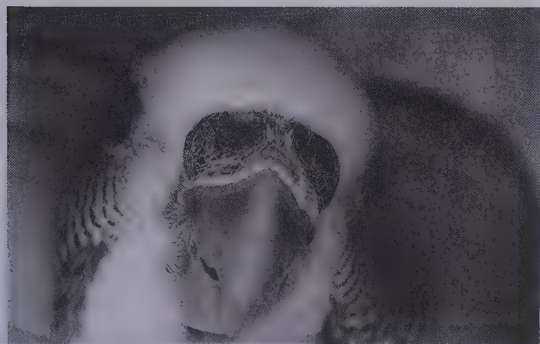
Histologically, Sertoli cell tumors are composed of sheets, lobules and islands of cells. Cells within seminiferous tubule remnants may palisade. Individual neoplastic cells are elongate with round-to-oval basal nuclei. Cytoplasm is abundant, eosinophilic, and occasionally vacuolated. The mitotic rate is variable. A delicate-to-dense fibrovascular stroma is present.<sup>53,108</sup>

- **Seminoma:** Seminomas are neoplasms of germ cell origin. These tumors also occur frequently in captive and free-ranging birds.<sup>5,12,44,49,51,54,85,102,108,141</sup> The most common clinical signs include dyspnea, lethargy, anorexia, ascites and abdominal enlargement (occasionally with a palpable intra-abdominal mass).<sup>44</sup> Seminomas infrequently may be associated with signs of feminization in budgerigars.<sup>12</sup>



**FIG 25.10** A Quaker Parakeet was presented for evaluation of a pericloacal and abdominal swelling. Radiographs indicated a renal mass that had invaded the synsacrum, causing osteolysis cranially and sclerosis caudally. The mass extended dorsally to the synsacrum and ventrally into the abdomen. The histopathologic diagnosis was renal carcinoma (courtesy of Jane Turrel).





**FIG 25.11** A mature male budgerigar was presented with a progressive growth and discoloration of the cere. Brown hypertrophy of the cere is frequently encountered in older budgerigars with gonadal neoplasms. The hypertrophied tissue can be moistened with skin-softening creams and gently peeled away.

Neoplastic testes appear large, white-to-gray, firm and oval. Small cystic spaces also may be present. Occasionally, adherence to the kidneys, ureters and dorsal body wall may be observed.<sup>44,108</sup> Seminomas are generally considered benign; however, metastasis to the liver may occur, presumably as a late event.<sup>5,49,54,102</sup>

Histologically, seminomas are composed of pleomorphic germinal epithelial cells arranged in sheets, nests and irregularly shaped tubules. Seminiferous tubules may be filled, distended or disrupted by neoplastic cells. Nests and tubules of neoplastic germ cells are separated by thin bands of connective tissue. Individual cells are round-to-polygonal and exhibit anisocytosis. Nuclei are large and round with hyperchromatic, coarsely clumped chromatin and indistinct nucleoli. Multinucleated tumor cells and bizarre mitotic figures may be observed frequently.<sup>44</sup>

- **Interstitial Cell Tumor:** Interstitial (Leydig) cell tumor is the least frequently reported gonadal stromal testicular neoplasm of birds.<sup>12,102,108</sup> Neoplastic testes appear enlarged, fleshy, and occasionally cystic.<sup>12,108</sup> The contralateral testis may be atrophied (Color 25.4).<sup>12</sup>

Microscopically, interstitial tumors have a dense fibrovascular stroma that divides the neoplasm into lobules. Individual neoplastic cells are large and polyhedral, containing eccentric nuclei and vacuolated eosinophilic cytoplasm.<sup>108</sup> The vacuolated cytoplasm is a reflection of steroid hormone (testosterone) production.

- **Miscellaneous Testicular Neoplasms:** Lymphosarcoma (Marek's disease, Marek's lymphoma) is the

most frequent testicular neoplasm of chickens. This neoplasm is herpesvirus-induced.<sup>20,109</sup>

The testicular capsule or testis may be the site of origin for hemangioma, fibrosarcoma and leiomyosarcoma.<sup>102,108</sup> Both carcinoma and leiomyosarcoma have been reported to arise from the epididymis and vas deferens, respectively.<sup>12</sup> Teratomas also may arise in the testis and are discussed under neoplasms of the nervous system.<sup>23,63,112</sup>

### Ovarian and Oviductal Neoplasms

Ovarian neoplasms are reported more frequently than neoplasms arising from the oviduct. Clinical signs may include abdominal distention, ascites, dyspnea, intra-abdominal mass and leg paresis or paralysis. Usually the left leg exhibits paresis or paralysis initially, but both limbs ultimately may be affected. Paraneoplastic syndromes that may be observed in conjunction with ovarian and oviductal neoplasms include localized exostosis or polyostotic hyperostosis.<sup>5,132</sup>

Ovarian neoplasms are classified histologically according to cell lineage. Granulosa cell tumors are gonadal stromal neoplasms that originate from supportive tissues and are the most common type of ovarian neoplasm. Ovarian carcinomas are of epithelial cell origin and comprise the second most frequent classification of ovarian neoplasia. Dysgerminomas are germ cell tumors that are analogous to seminoma in males. This neoplasm is very rare and has been reported only in poultry and budgerigars.<sup>7,23</sup> Oviductal neoplasms are also described, and most of these tumors are of epithelial cell origin. Ovariectomy or salpingectomy is the treatment of choice.

- **Granulosa Cell Tumor:** Granulosa cell tumors are the most frequently reported ovarian neoplasm in captive and free-ranging birds.<sup>12,28,49,51,102,108</sup> These gonadal stromal neoplasms appear as large, pale, nodular masses. Central necrosis and hemorrhage may be present and impart a pink color to the neoplasm.

Histologically, these neoplasms are composed of islands of epithelial-like cells separated by fibrovascular stroma. Cells may form tubules or palisades around blood vessels. Individual neoplastic cells have cytoplasmic vacuoles. Plump, theca-like cells may be scattered throughout the neoplasm.<sup>108</sup>

- **Ovarian Carcinoma:** Ovarian carcinomas or adenocarcinomas are the second most frequently reported neoplasm originating in the ovary.<sup>12,28,31,51,102,108,134,145</sup> These neoplasms may appear

as large, firm, cystic, multilobulated-to-pedunculated masses.

Limited cytologic study of one ovarian cystadenocarcinoma in a budgerigar demonstrated putative neoplastic cells in abdominal effusion fluid.<sup>28</sup> A few large epithelial cells were observed that had oval nuclei, prominent nucleoli and abundant blue cytoplasm. Anisocytosis and occasional mitotic figures also were observed.<sup>28</sup> Histologically, ovarian carcinomas are composed of epithelial cells arranged in nests, cords, tubules and cysts. Foci of epithelial cell proliferation are separated by connective tissue septa. Papillary projections of epithelial cells may protrude into the cysts. Cystic spaces may contain a homogeneous eosinophilic secretory product. The mitotic rate is variable.

Ovarian carcinomas may metastasize to the mesentery, intestinal serosa, liver, lung, pancreas, muscle and bone.<sup>31,134,145</sup>

▪ **Miscellaneous Ovarian/Oviductal Neoplasms:**

Stromal tissues of the ovary are infrequent sites of origin for lipomas and fibrosarcomas.<sup>12,108</sup> Teratomas also may originate in the ovary and are discussed under neoplasms of the nervous system.<sup>23</sup>

The oviduct and ventral ligament of the oviduct occasionally are the sites of origin of leiomyomas and leiomyosarcomas.<sup>102,108</sup>

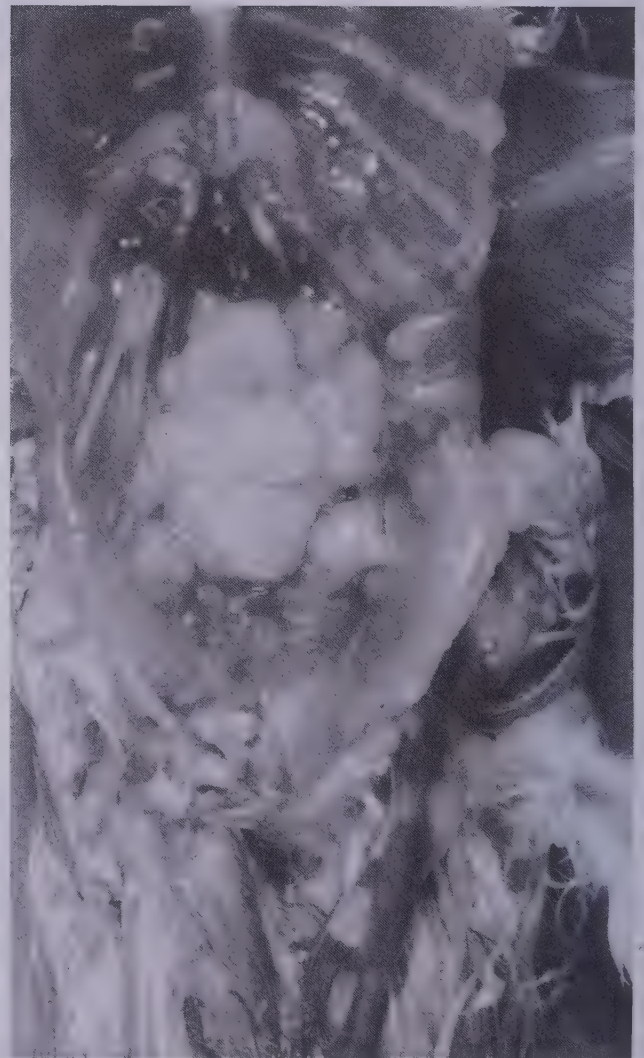- **Oviductal Dysplasia, Adenomatous Hyperplasia, Adenoma and Adenocarcinoma:** Studies of reproductive tracts from turkey hens suggest a progression of oviductal lesions in the development of neoplasia.<sup>13</sup> Preneoplastic changes include epithelial dysplasia and adenomatous hyperplasia. With time, these lesions may progress to oviductal adenoma and adenocarcinoma.<sup>12,13,15,49,108,132</sup> Oviduct adenocarcinomas may metastasize to abdominal serosal surfaces.<sup>15</sup>

Grossly, oviduct adenomas and adenocarcinomas may appear as firm nodular masses. Carcinomatosis, if present, will appear as multiple, small white nodules on serosal surfaces. Polyostotic hyperostosis is a rare paraneoplastic syndrome associated with oviductal adenocarcinoma.<sup>132</sup>

Histologically, oviductal adenomas and adenocarcinomas are composed of sheets, nests, cords and tubules of cuboidal-to-elongate epithelial cells. Fibrovascular stroma is variable, but fibroplasia is more intense with adenocarcinomas.

- **Carcinomatosis:** Carcinomatosis is the seeding of the thoracoabdominal cavity with neoplastic cells

that subsequently proliferate, forming variably sized white nodules. Carcinomatosis may be observed with ovarian and oviductal adenocarcinomas, intestinal adenocarcinoma, pancreatic adenocarcinoma, mesothelioma and undifferentiated adenocarcinoma (Figure 25.12).<sup>15,31,56,77,85,108,127,134</sup> The pattern of metastasis may be governed partially by serosal membranes within the body cavity.<sup>77</sup> Both disseminated mycobacteriosis and egg-related peritonitis of hens may mimic neoplasia clinically and at necropsy. Both cytology and histopathology can confirm the presence of carcinomatosis.<sup>77</sup>



**FIG 25.12** Carcinomatosis secondary to an anaplastic pancreatic carcinoma in a mature cockatiel (see Color 25.6) (courtesy Cheryl Greenacre).

## Digestive System

### Oral Cavity

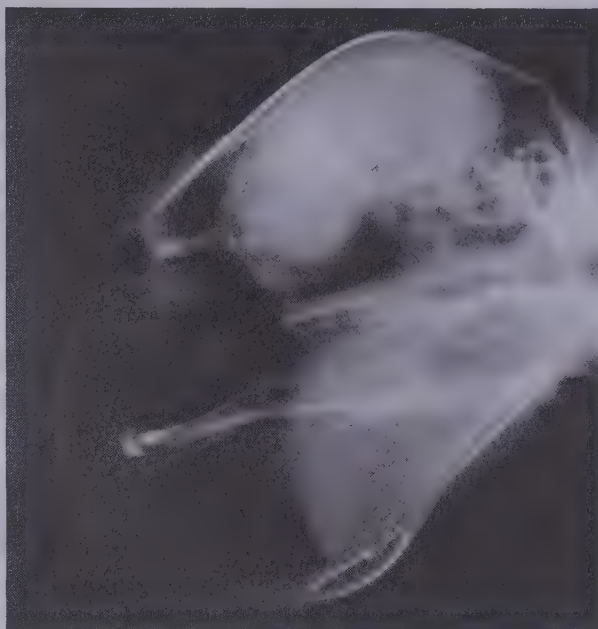
- **Papilloma:** Papillomas are composed of proliferative squamous epithelium with a fibrovascular stroma. Oral papillomas are occasionally encountered, especially in psittacine birds, and may involve the oropharyngeal, choanal or laryngeal regions of the pharynx.<sup>24,36,55</sup> Papillomas may undergo malignant transformation to squamous cell carcinoma.
- **Squamous Cell Carcinoma:** Squamous cell carcinomas are second to papillomas in frequency and may involve the oral cavity and tongue.<sup>3,33,72</sup> These carcinomas appear as ulcerative-to-cauliflower-like, painful lesions or masses that are associated with inappetence, dysphagia, regurgitation, halitosis and frequent head shaking.<sup>3,33,143</sup> The differential diagnosis for this lesion should include oral neoplasia, hypovitaminosis A, trauma, candidiasis or protozoal infection (trichomoniasis).

Cytologic examination may demonstrate a pleomorphic population of epithelial cells, but squamous cell hyperplasia and squamous cell carcinoma may be difficult or impossible to distinguish. Histologically, squamous cell carcinomas are composed of sheets, nests and cords of pleomorphic epithelial cells that infiltrate adjacent tissues. Anisocytosis, anisokaryosis, dyskeratosis and intercellular bridges usually are observed. Keratin pearl formation and adenoid patterns are observed less frequently. The mitotic rate is variable. Squamous cell carcinomas may be accompanied by inflammation and a scirrhous reaction. Local infiltration of surrounding tissues is common, but metastasis is rare.

- **Miscellaneous Neoplasms:** Miscellaneous oral neoplasms include a mast cell tumor in an owl and a fibrosarcoma in a budgerigar.<sup>102,124</sup> These neoplasms are discussed in detail under the integumentary system. Mucinous adenocarcinoma of the tongue also has been described in an owl (Figure 25.13).<sup>45</sup>

### Esophagus and Crop

- **Squamous Plaque:** Squamous plaques are focal or multifocal thickening of stratified squamous epithelium that may be accompanied by dysplastic change. This lesion has been described as an "epithelioma" in the crop of a pigeon.<sup>108</sup> Squamous plaques are caused



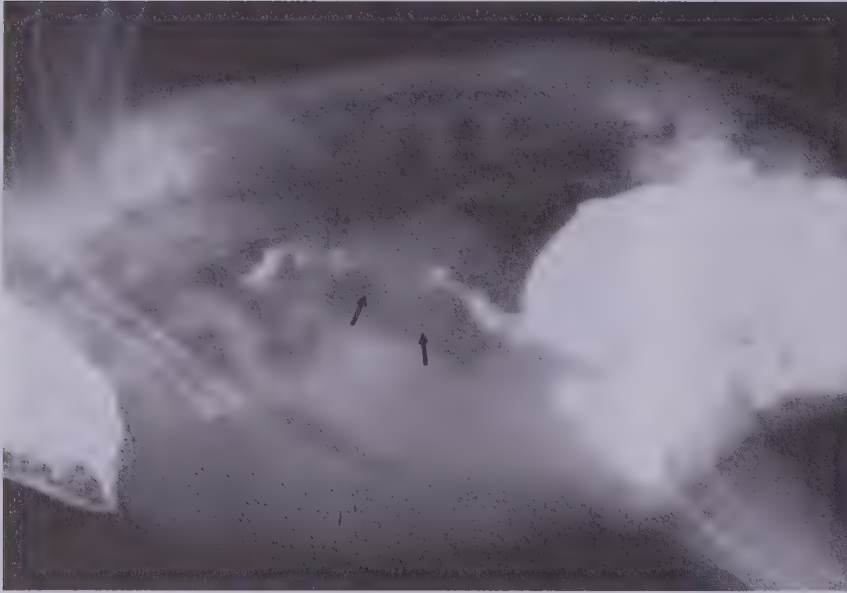
**FIG 25.13** Radiographs of the head of an Umbrella Cockatoo indicate the extent of a sublingual mass. Granulomatous response is considered a precursor to some oral tumors (see Color 25.20).

by chronic irritation and may undergo neoplastic transformation.

- **Papilloma:** Papillomas account for the vast majority of neoplasms observed on the mucosal surfaces of the esophagus and crop, especially in psittacine species.<sup>24,36,55,108</sup> Papillomas may undergo malignant transformation.
- **Squamous Cell Carcinoma:** Squamous cell carcinoma of the crop has been observed in a budgerigar and an Amazon parrot.<sup>15,90</sup> The most detailed description is given for the Amazon parrot.<sup>90</sup> Grossly, the esophageal wall was thickened (Figure 25.14). The neoplasm was circumferential with a dry, white, cauliflower-like surface (Color 25.8). Microscopically, the neoplasm was composed of aggregates of pleomorphic squamous epithelial cells that extended into the submucosa.
- **Leiomyosarcoma:** A multifocal leiomyosarcoma has been reported to originate in the crop wall of a budgerigar. The only clinical sign attributed to this neoplasm was difficulty in swallowing.<sup>102</sup>

### Proventriculus and Ventriculus

Neoplasms of the proventriculus are approximately twice as common compared to neoplasms of the ventriculus. Adenocarcinomas are most commonly ob-



**FIG 25.14** An esophagram of an adult Amazon parrot indicated an irregular mucosal filling pattern in the distal esophagus suggestive of a mass (see Color 25.8) (courtesy of Jane Turrel).

served and often arise from the junction of these two organs.

- **Proventricular Carcinoma:** Proventricular carcinoma is the most frequent neoplasm observed in this organ.<sup>79,80,104,108,123,143</sup> These neoplasms are more common in psittacine species, especially Grey-cheeked Parakeets.<sup>79,104,123</sup>

On gross inspection, proventricular carcinomas appear as ulcerated, thickened, raised or depressed lesions. Clinically, gastrointestinal bleeding, as determined by observation of melena, anemia or a positive fecal occult blood test, should alert the clinician to the possibility of gastrointestinal neoplasia. Severe bleeding, hypovolemic shock or exsanguination may occur.<sup>79,104</sup> Proventricular carcinomas may exhibit rare transmural extension with serosal metastasis to the ventriculus, intestine and pancreas or hematologic metastasis to the spleen, liver, lungs and heart base.<sup>79,108</sup>

Microscopically, these neoplasms are composed of columnar-to-cuboidal-to-squamous epithelial cells arranged in a tubuloacinar pattern. Individual cells have vesicular nuclei and eosinophilic-to-basophilic cytoplasm. Mitotic figures may be observed frequently. Many neoplasms are associated with a scirrhous reaction. The luminal surface of the neoplasm is often ulcerated, while deep margins of the neoplasm exhibit invasion of the muscularis.<sup>79,104,108</sup> Pe-

riodic acid-Schiff (PAS) and alcian blue staining may help differentiate proventricular and ventricular carcinomas. Proventricular carcinoma cells and the secretory product are strongly PAS-positive and stain dark pink. In contrast, the koilin secretory product of ventricular epithelial cells is alcian blue-positive and appears bright blue.<sup>79,104</sup>

#### **Ventricular Carcinoma:**

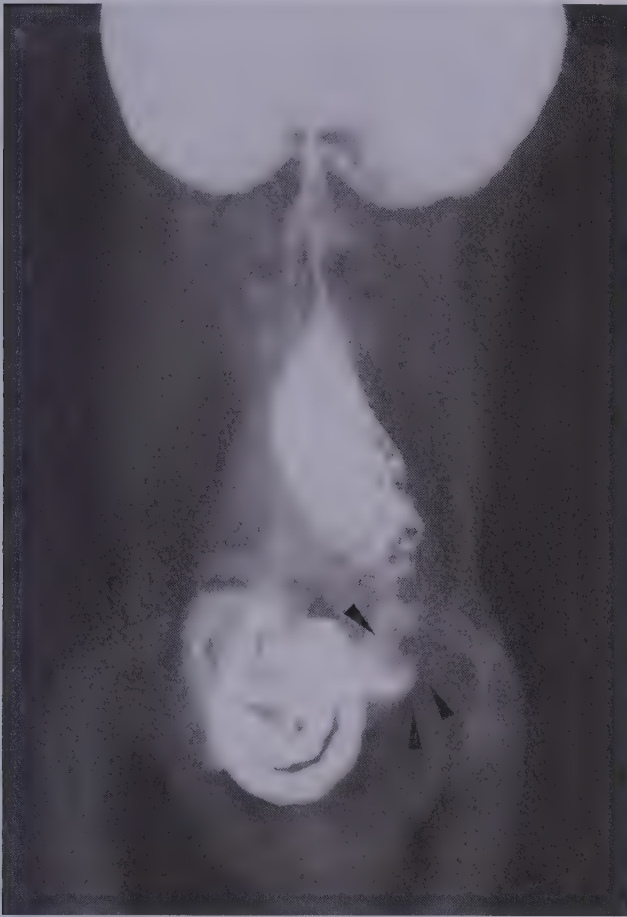
Ventricular carcinomas are infrequent in comparison to proventricular carcinomas but the clinical signs are similar (Figure 25.15).<sup>79,104</sup> These neoplasms have not been reported to metastasize. Microscopically, the appearance of ventricular carcinoma is similar to proventricular carcinoma except secretory cells are PAS-negative. The koilin secretory product is strongly alcian blue-positive. A single ventricular adenoma has been reported in a parrot but the neoplasm

was not characterized.<sup>49</sup>

- **Papillomas:** Papillomas are reported to occur within the proventriculus and ventriculus.<sup>24,55</sup> They are apparently more common in the ventriculus.<sup>55</sup>
- **Proventricular Adenoma:** A proventricular adenoma has been observed in a teal. On gross examination, the proventriculus was spherical instead of fusiform. The luminal surface was covered by a hemorrhagic, fibrillated, plaque-like mass. Histologically, the mass was composed of tubuloacinar structures lined by one-to-four layers of short, columnar epithelial cells. Cellular nuclei were centrally located, vesicular and had a small nucleolus. Cellular cytoplasm was basophilic. Few mitotic figures were observed and fibrovascular stromal tissue was minimal. Hemorrhage and necrosis were present near the luminal surface.<sup>8</sup>

#### **Intestine**

Although rare, some neoplasms originating in the small intestine have been reported. Intestinal neoplasms can best be managed by surgical excision and, intestinal anastomosis if the lesions are diagnosed early, if metastasis has not occurred and if the site can be adequately exposed.



**FIG 25.15** A six-year-old male budgerigar was presented with a history of regurgitation and weight loss. Radiographs taken 30 minutes after the administration of barium sulfate indicated filling defects in the proventriculus (consistent with ingesta) and an indistinct and irregular mucosal pattern in the lateral wall of the ventriculus (arrows) (consistent with neoplasm) (courtesy of Jane Turrel).

- **Leiomyosarcoma:** Primary intestinal leiomyosarcomas have been observed in budgerigars. Metastatic lesions were not observed.<sup>15,133</sup>
- **Intestinal Carcinoma:** Intestinal carcinoma has been reported in a budgerigar, duck and gull.<sup>15,49,72</sup> Metastatic foci were observed within the lung, liver and spleen.<sup>72</sup>

### Cloaca

Cloacal neoplasms and masses, including papillomas, adenocarcinomas, and adenomatous polyps and hyperplasia are observed most commonly in psittacine birds, especially Amazon parrots.<sup>35,37,49,51,55,65,102,136</sup>

- **Cloacal Papilloma:** Cloacal papillomas are recognized frequently in psittacine birds.<sup>37,55,65,102,136</sup> Cloa-

cal papillomas and bile duct carcinoma may show concurrent development, especially in Amazon parrots.<sup>55,65</sup> Grossly, cloacal papillomas appear as broad-based, pink-to-red, proliferative-to-ulcerative masses. They may closely resemble granulation tissue (see Color 19). Major clinical signs associated with cloacal papillomas are straining, bleeding from the vent and cloacal prolapse. A viral etiology has been suggested for these neoplasms, but has yet to be confirmed.<sup>136</sup>

Histologically, cloacal papillomas are composed of hyperplastic epithelium over a base of fibrovascular stroma. The epithelium may vary from 10- to 50-cell layers in thickness. Depending upon the biopsy site, epithelial cells may exhibit a transition from columnar to squamous morphology. Epithelial cells on the luminal surface may contain basophilic intracytoplasmic mucin granules that can be demonstrated by alcian blue and mucicarmine staining.<sup>136</sup>

- **Cloacal Carcinoma:** Cloacal carcinomas are observed infrequently compared to papillomas.<sup>49,51,102,136</sup> Histologically, these neoplasms contain a more pleomorphic epithelium, characterized by dysplasia and bizarre mitoses.<sup>136</sup> Transmural cellular invasion and penetration of the cloaca may be associated with sclerosing fibroplasia.<sup>51,102</sup>
- **Cloacal Adenomatous Polyp or Hyperplasia:** Histologically, these lesions are characterized by epithelial cell hyperplasia resulting in a visible mass.<sup>35,102</sup> It seems reasonable that a progression of cloacal lesions occurs, ranging from hyperplasia to neoplasia (usually benign papillomas). Furthermore, cloacal papillomas may rarely undergo malignant transformation to adenocarcinomas.

### Hepatic Neoplasms

Both primary and metastatic neoplasia occur in the liver. The most frequent primary hepatic neoplasms are hepatocellular carcinoma and bile duct carcinoma. Conditions that must be differentiated from neoplasia include hepatic nodular hyperplasia, bile duct hyperplasia and biliary cysts (see Color 20).

- **Cholangiocarcinoma:** Cholangiocarcinoma (cholangiocellular carcinoma, bile duct carcinoma) originates from bile duct epithelium. This is the most frequent hepatic neoplasm reported in captive and free-ranging birds (lymphoid neoplasms are most common in gallinaceous birds).<sup>1,2,5,49,50,72,102,103,108,147,148</sup> Specific clinical signs are infrequent, although emaciation, weakness, hepatomegaly, ataxia, trembling

and seizures have been observed.<sup>2,50,148</sup> Some neurologic signs are suggestive of hepatoencephalopathy.

On gross inspection, the hepatic parenchyma contains numerous, variably sized, firm, white-to-tan nodules. Histologically, these neoplasms consist of columnar-to-cuboidal epithelial cells arranged in ribbons, cords, tubules or ducts. Infiltration of the hepatic parenchyma is apparent. A few mitotic figures may be observed. In some neoplasms, a scirrhous reaction may be present.<sup>1,2,50,148</sup>

Cholangiocarcinomas may exhibit vascular invasion with subsequent widespread metastasis to the lungs, brain, kidney, pleura and serosa of the ventriculus.<sup>1,43,72,102,147,148</sup> There is no available treatment for cholangiocarcinoma.

- **Cholangioma:** Cholangiomas are of bile duct epithelial origin and are rare in comparison to cholangiocarcinoma.<sup>49,108</sup> Cholangiomas may occur as single or multiple, firm nodules. Histologically, they appear as epithelial-lined tubular structures with a dense fibrous stroma.<sup>108</sup>
- **Bile Duct Hyperplasia:** Bile duct hyperplasia is observed with some frequency in psittacine birds with liver disease. Bile duct hyperplasia is often seen concurrently with hepatic fibrosis and hepatocellular lipidosis. The gross and microscopic appearance of some livers may mimic cholangiocarcinoma. The etiology of bile duct hyperplasia is often undetermined; however, ingestion of mycotoxin-contaminated feed should be considered in the differential diagnosis (see Chapter 20).
- **Biliary Cyst:** Biliary cysts are reported infrequently in birds.<sup>95</sup> Such cysts are generally congenital and may be intra- or extra-hepatic. Biliary cysts may be observed in conjunction with polycystic kidneys.
- **Hepatocellular Carcinoma:** In captive and free-ranging birds, the incidence of hepatocellular carcinoma is superseded only by cholangiocarcinoma.<sup>12,43,51,108</sup> Birds with hepatocellular carcinoma frequently present in a debilitated state with enlargement of one liver lobe. Abdominal enlargement may be apparent on physical examination.

Antemortem liver lobe enlargement may be confirmed by radiography, ultrasound, endoscopy or laparotomy. Postmortem confirmation of liver lobe enlargement is made by visual inspection at necropsy. Neoplasms may vary in size and color, ranging from light tan to a more normal red-brown. Microscopi-

cally, these neoplasms are composed of cords of hepatocyte-like cells with effacement of normal tissue architecture. Bizarre-to-multinucleated hepatocytes may be observed. Variable numbers of mitotic figures are present.<sup>43,108</sup>

Metastases are rare, but when they occur the lungs are usually involved.<sup>43,147</sup> Partial or full hepatic lobectomy may be attempted to excise these neoplasms.


- **Hepatocellular Adenoma:** Hepatocellular adenoma (hepatoma) is poorly documented in birds, having been reported in a cissa, guineafowl, hornbill and mynah bird.<sup>49,72,131,147</sup> The multiple nodules within the hepatic parenchyma of the mynah bird were associated with osseous metaplasia and extramedullary hematopoiesis. These nodules probably represented hepatic nodular hyperplasia.<sup>131</sup>
- **Nodular Hyperplasia:** Nodular hyperplasia of the liver may be viewed as attempted parenchymal regeneration following injury. Nodular hyperplasia is usually an incidental finding at necropsy in birds with evidence of chronic liver disease.<sup>64</sup> The gross appearance of these pale nodules may be mistaken for hepatocellular adenoma or adenocarcinoma. The most common associations with nodular hyperplasia are mycotoxin exposure and iron-accumulating hepatopathy.
- **Miscellaneous Hepatic Neoplasms:** Miscellaneous neoplasms described in the liver include malignant lymphoma, fibrosarcoma, hemangioma, hemangiosarcoma and lipoma.<sup>12,64,102,108,109</sup> Myelolipomas also may arise within the hepatic parenchyma. Furthermore, the liver may be involved in hematologic neoplasia, which can be difficult to distinguish from extramedullary hematopoiesis.

### Pancreatic Neoplasms

Most pancreatic neoplasms reported in birds arise from the exocrine pancreas, especially ductular structures. These neoplasms may be single or multiple. Neoplasms arising from the endocrine pancreas are rare.

- **Pancreatic Adenoma:** Pancreatic adenomas occur in psittacine birds, especially Amazon parrots, macaws and budgerigars.<sup>15,49,56</sup> In Amazon parrots, pancreatic adenomas may be associated with internal papillomas or may be observed as incidental findings at necropsy.<sup>56</sup>

On gross inspection, multifocal pancreatic adenomas usually are observed associated with ductular struc-



**FIG 25.16** Pancreatic carcinoma with involvement of the serosal surface of the intestines in a cockatiel (see Color 25.6) (courtesy of Cheryl Greenacre).

tures. Intraductal neoplasms may cause local distention of affected ducts with concurrent compression atrophy of the adjacent pancreatic parenchyma.<sup>56</sup>

Histologically, these neoplasms are composed of proliferating columnar epithelial cells arranged in cords or papillary projections. Epithelial cell proliferation may be accompanied by fibroplasia.<sup>56</sup>

- **Pancreatic Adenocarcinoma:** Pancreatic adenocarcinoma may be observed in various species of birds including psittacines, doves, Anseriformes and raptites.<sup>49,56,72,108,137</sup> These neoplasms occasionally may be quite large, envelop bowel loops and result in abdominal effusion.<sup>137</sup> They are not amenable to treatment (Figure 25.16).

Histologically, adenocarcinomas are composed of a pleomorphic population of epithelial cells that infiltrate or dissect local tissues. Metastasis may occur, usually by serosal seeding.<sup>56</sup> Pancreatic adenocarcinoma should be a diagnostic consideration when carcinomatosis is observed (Color 25.6).

## Endocrine System

The endocrine system is composed of widely distributed tissues, glands and organs. The endocrine system, in conjunction with the nervous system, maintains homeostasis by the ability to synthesize, store and release various hormones. These hormones are distributed via the blood to effector cells, tissues or organs where their biological effect is mediated. Neoplasms usually affect only one endocrine cell type.

Rarely, neoplasia will involve two or more different endocrine cell lines, a condition called multiple endocrine neoplasia. Evidence suggests that multiple endocrine neoplasia occurs in birds as well as in mammals.<sup>49</sup>

### Pituitary Gland

Pituitary neoplasms are the most frequently reported endocrine neoplasm in birds and there is no effective treatment for them.<sup>10,12,102,121</sup>

- **Pituitary Adenoma:** Pituitary adenoma is the most frequently reported endocrine neoplasm of birds, especially budgerigars.<sup>10,12,15,39,49,102,108,121</sup> These neoplasms often originate from proliferation of chromophobe cells in the anterior lobe. Because of the anatomic location of the pituitary gland, expansive neoplasms follow the path of least resistance, compressing the hypothalamus and optic chiasm. Neurologic signs resulting from compression include incoordination, poor perching or posture, somnolence, seizures and convulsions, and visual impairment including blindness associated with dilated, fixed pupils.<sup>10,12,39,102,108,121</sup> Unilateral or bilateral exophthalmos may result from neoplastic cell infiltration along the optic nerve(s).<sup>121</sup>

Pituitary adenomas also may be associated with polydipsia and polyuria.<sup>10,12,39,102</sup> The mechanisms of polydipsia and polyuria have not been investigated in birds, but may be caused by decreased antidiuretic hormone (ADH) concentrations or by over-production of adrenocorticotrophic hormone (ACTH). Compression of the posterior lobe of the pituitary decreases ADH transport and storage with subsequent diuresis. Excessive production of ACTH might cause adrenal cortical hyperplasia with excess corticosterone secretion and steroid-induced diuresis.

Pigment changes such as alterations in feather coloration pattern and cere color have been reported in a cockatiel and budgerigar; however, hormonal changes were not investigated.<sup>10,39</sup>

Necropsy usually reveals a mass in the location of the pituitary that compresses the overlying hypothalamus. Microscopically, these neoplasms are composed of round-to-cuboidal cells arranged in sheets or sinusoidal patterns containing a delicate fibrovascular stroma. Cells have round nuclei, stippled chromatin and variable quantities of cytoplasm. In chromophobe adenomas, the cytoplasm stains poorly. Mitoses are infrequent and a remnant of the pars distalis may be apparent.<sup>88</sup>

- **Pituitary Carcinoma:** Pituitary carcinomas are rare neoplasms in birds, but have been reported and characterized in two budgerigars.<sup>121</sup> Neoplastic cell invasion of the brain and formation of retrobulbar masses have been observed, along with distant metastasis to the liver and kidney. Histologically, these neoplasms are highly cellular and may contain foci of necrosis and hemorrhage. Confirmation of metastasis supports the presumptive diagnosis.

### Pineal Gland

Neoplasms of the pineal gland are rare. These expansive neoplasms may displace or compress adjacent neural tissue resulting in neurologic deficits. Because of their anatomic location, surgical excision of pineal gland neoplasms is virtually impossible.

- **Pineoblastoma:** A pineoblastoma has been described in a cockatiel.<sup>151</sup> Clinical signs included polydipsia, depression, right-sided head tilt and inability to grasp objects with the right foot.

Necropsy examination disclosed a grey suprachiasmatic mass extending into the right ventricle and compressing the right occipital lobe and thalamus. Microscopically, the mass consisted of sheets, cords and fewer palisades of round cells with round-to-oval nuclei, stippled chromatin and lightly basophilic cytoplasm. A delicate fibrovascular stroma was present. Occasional mitotic figures were observed throughout the mass.

- **Pinealoma:** Pinealoma has been reported in two chickens and a dove.<sup>22,108,138</sup> The neoplasm apparently was an incidental finding in one chicken from a flock exhibiting increased mortality and trembling.<sup>138</sup> The neoplasm in the dove was a serendipitous discovery during postmortem assessment of cranial trauma.<sup>108</sup>

On microscopic examination, the mass was encapsulated, cellular and displaced cerebellar folia and extended deeply between them. The mass had a lobular architecture, with some lobules containing single layers of ciliated columnar-to-pseudostratified-columnar epithelium. Neoplastic cells contained round-to-oval nuclei exhibiting mild anisokaryosis. Mitotic figures were observed occasionally.

### Thyroid Gland

Enlargement of the thyroid glands may be observed with hyperplasia or neoplasia. Signs of thyroid gland enlargement may include dyspnea and a distinctive squawk on vocalization.<sup>6,12,118</sup> Their anatomic location near the thoracic inlet precludes palpation of masses unless glandular enlargements are extreme.<sup>6</sup> Thy-

roid hyperplasia can be managed medically. Theoretically, thyroid neoplasia can be managed surgically, but diagnosis and extirpation of intrathoracic lesions are difficult.

- **Thyroid Hyperplasia:** Thyroid hyperplasia (goiter) may be associated with iodine-deficient diets, ingestion of goitrogenic plants such as *Brassica* species, exposure to iodine-containing disinfectants or excessive dietary iodine.<sup>88,115</sup> Thyroid hyperplasia is manifested by bilateral glandular enlargement. Colloid-distended follicles may result in glandular enlargements reaching 20 mm in diameter.<sup>12</sup> Because of improved diets for companion birds, thyroid hyperplasia is reported less frequently than three decades ago.<sup>6,12,15,118</sup>

On gross necropsy examination, the thyroid glands are bilaterally enlarged and may appear cystic. Histologic sections of thyroid gland contain large, irregular follicles that are lined by columnar epithelium and distended with light-pink colloid. Papillary projections of epithelium may protrude into the lumen of some follicles (see Chapter 23).

- **Thyroid Adenoma:** Thyroid adenomas are usually unilateral but may occasionally cause bilateral glandular enlargement. These neoplasms usually represent incidental necropsy findings in birds.<sup>12,15,49,108</sup>

Histologically, thyroid adenomas are poorly characterized in birds. Most thyroid adenomas appear as nodules of encapsulated glandular tissue.

- **Thyroid Carcinoma:** Thyroid carcinomas are rare and poorly characterized in birds.<sup>12,49,102</sup> Thyroid gland enlargement may be unilateral or bilateral. Dyspnea may be a presenting complaint.<sup>102</sup> Histologically, thyroid carcinomas may appear nodular, poorly encapsulated and invasive. These neoplasms are highly vascular.

### Adrenal Gland

In contrast to mammals, avian adrenal glands have no distinct cortex or medulla. Both interrenal (cortical) and enterochromaffin (medullary) cells are intermingled throughout the gland.<sup>109</sup> Adrenal neoplasms are rare in captive and free-ranging birds and have not been studied in detail. When enlargement of the adrenal glands is observed at necropsy, a primary consideration is adrenal gland hyperplasia.

- **Adrenal Adenoma:** Adrenal adenomas arise from interrenal (cortical) cells and have rarely been re-



ported in birds and generally are not associated with clinical signs of disease.<sup>15,49,108</sup>

Histologically, affected adrenal glands are replaced by a lobulated mass of tubuloacinar tissue. Epithelial cells appear pale with foamy cytoplasm and centrally located nuclei. Mitotic figures are uncommon.<sup>108</sup>

- **Adrenal Carcinoma:** Adrenal carcinoma was described in a Mountain Duck that was depressed and had leg paralysis.<sup>43</sup>

The adrenal gland neoplasm was unilateral and composed of a pleomorphic population of polyhedral-to-elongated cells arranged in a frond-like pattern. Marked anisocytosis and anisokaryosis was apparent, including the presence of tumor giant cells. Mitoses were observed infrequently. Neoplastic cells infiltrated adjacent nerves.<sup>43</sup>

- **Pheochromocytoma:** A single pheochromocytoma has been reported in a Mouflon, but clinical, necropsy and histologic findings were not discussed.<sup>49</sup>

#### Endocrine Pancreas

- **Islet Cell Carcinoma:** The islets of Langerhans constitute the endocrine portion of the pancreas. These scattered islets are composed of a diverse aggregation of alpha, beta and delta cells that secrete glucagon, insulin and gastrin, respectively. Islet cell neoplasms may be secretory or non-secretory. Secretory islet cell neoplasms may have diverse clinical presentations.

An islet cell carcinoma has been reported in a budgerigar with hyperglycemia.<sup>116</sup> The neoplasm was presumed to be of alpha cell origin and associated with glucagon hypersecretion and diabetes mellitus, but this assumption was not proven. It must be noted that in health, birds have higher glucose values than mammals. In stressful situations, avian blood glucose values may temporarily approach or exceed 700 to 800 mg/dl. Therefore, persistent and dramatic hyperglycemia must be present to confirm a diagnosis of avian diabetes mellitus.

Histologically, this islet cell carcinoma consisted of nests and lobules of pleomorphic, pale-staining cells with vesicular nuclei and a moderate mitotic index. The neoplasm was poorly circumscribed and contained a delicate fibrovascular stroma. Both compression and invasion of the adjacent exocrine pancreas were observed.<sup>116</sup>

#### Chemoreceptor Neoplasms

Chemoreceptors, in concert with the parasympathetic and sympathetic nervous systems, regulate blood pH, pCO<sub>2</sub> and pO<sub>2</sub>. These neoplasms are very rare in birds. A carotid body tumor has been reported in a parakeet, but no details of the neoplasm were presented.<sup>15</sup>



## Nervous System and Eye

Nervous system and ocular neoplasms apparently are infrequent in birds with the exception of pituitary adenomas in budgerigars and malignant lymphoma (leukosis) in chickens.<sup>48,49,121</sup>

#### Central Nervous System

Neoplasms of the central nervous system may represent an interesting incidental finding at necropsy or may be related to profound neurologic deficits from compression and infiltration of neural tissue, obstruction of cerebrospinal flow, or secondary edema, hemorrhage or necrosis. These neoplasms have a poor prognosis, and effective treatment regimens have yet to be developed (Color 25.14). The discussion below is confined to those neoplasms recently reported in birds.

- **Astrocytoma:** An astrocytoma is a differentiated neoplasm of astrocytes that exhibits slow but progressive growth. These neoplasms usually arise in the cerebral hemispheres, thalamus, brainstem, cerebellum or spinal cord.<sup>88</sup> A single astrocytoma has been reported in a duck with neurologic signs (especially circling).<sup>108</sup> At necropsy, a lobulated mass was identified in the base of the cerebellum. Histologically, the neoplasm was lobulated and unencapsulated with large globular cells in a fibrillar network.<sup>108</sup> The tumor description suggests a gemistocytic astrocytoma.
- **Glioblastoma:** A glioblastoma is an undifferentiated neoplasm of astrocyte origin. These neoplasms grow rapidly, infiltrate surrounding neural tissue, and are very destructive. A glioblastoma has been described in a budgerigar with weakness, incoordination, inability to perch properly, tremors of the wings and rigidity of the legs.<sup>106</sup> Gross brain lesions were not observed at necropsy. Microscopically, a circumscribed mass occupied a large area of the diencephalon and mesencephalon. Neoplastic cells were pleo-

## Oncology

### Color 25.1

A ten-year-old Amazon parrot was presented with a one-year history of progressive swelling of the head and face. Numerous masses were palpable throughout the body, and their occurrence was confirmed by radiographs (see Figure 25.2). Histopathology indicated an invasive fibrosarcoma involving the soft tissues and bones of the head (courtesy of Jane Turrel).

### Color 25.2

A six-year-old budgerigar was presented with a large, featherless mass involving the ventral abdomen. The mass interfered with the bird's ability to fly and perch. Cytology indicated a lipoma with xanthomatosis of the skin overlying the mass (note the yellowish, thickened skin). The tumor and associated xanthoma were surgically excised (courtesy of Jane Turrel).

### Color 25.3

A four-year-old African Grey Parrot was presented with a history of anorexia, weight loss and depression. The bird did not respond to supportive care. Hepatomegaly and splenomegaly with raised white nodules in the liver were noted at necropsy. Histopathology revealed an accumulation of lymphoid cells in the nodules, consistent with a diagnosis of lymphosarcoma (courtesy of Jane Turrel).

### Color 25.4

A five-year-old male budgerigar was presented for abdominal distention and left limb paresis. The bird did not respond to supportive care. Necropsy findings included seasonal testicular (t) hypertrophy (which should not be confused with neoplasm) and a renal mass (arrow). The renal mass was histologically identified as a renal carcinoma (courtesy of Jane Turrel).

### Color 25.5

A five-year-old budgerigar was presented with a rapidly growing firm mass on the dorsal surface of the wing. Cytology indicated a pleomorphic population of spindle cells suggestive of fibrosarcoma. The mass was limited to the soft tissue of the wing and did not involve the underlying bones. The case was managed by amputating the affected wing (courtesy of Jane Turrel).

### Color 25.6

An adult female cockatiel was presented for weight loss and a distended abdomen. On physical examination, the bird was bright,

alert and responsive, and weighed 91 g but was severely emaciated as detected by pectoral muscle atrophy. The abdomen was severely dilated and had a fluid consistency. Abdominocentesis was used to collect 10 mls of fluid that was used for cytologic evaluation. The fluid had the characteristics of a modified transudate and contained cells suggestive of neoplasm. The bird did not respond to supportive care. At necropsy, 20 mls of fluid were removed from the distended abdomen. A large mass was filling the space between the descending and ascending duodenum that is normally occupied by the pancreas. The histologic diagnosis was multicentric, anaplastic pancreatic carcinoma with carcinomatosis of the serosal surfaces of the abdomen and the tunica muscularis of the intestines (courtesy of Cheryl Greenacre).

### Color 25.7

A captive Blue Jay was presented with a crusty, hemorrhagic, poorly defined mass on the wing. The lesion first appeared as a non-healing wound that progressively enlarged over a period of several months. Biopsy of the lesion revealed a squamous cell carcinoma (courtesy of Jane Turrel).

### Color 25.8

A 50-year-old Amazon parrot was presented with a history of dysphagia, regurgitation and weight loss of several months' duration. Histopathology of the mass confirmed a squamous cell carcinoma (see Figure 25.14) (courtesy of Jane Turrel).

### Color 25.9

A two-year-old Umbrella Cockatoo was presented with epiphora and an ocular mass. The mass was debulked and the histologic diagnosis was squamous cell carcinoma. The tumor margin was irradiated with a strontium-90 ophthalmic probe (courtesy of Jane Turrel).

### Color 25.10

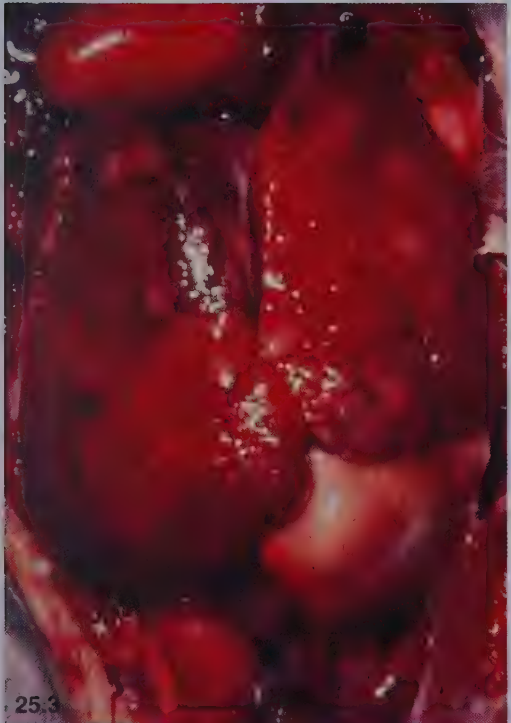A three-year-old cockatoo was presented with bilateral foot lesions characterized by depigmented, scaly, hard, thickened skin. The lesions were suggestive of a viral-induced papilloma. If not associated with any specific dysfunction, lesions such as these can remain untreated (courtesy of Jane Turrel).



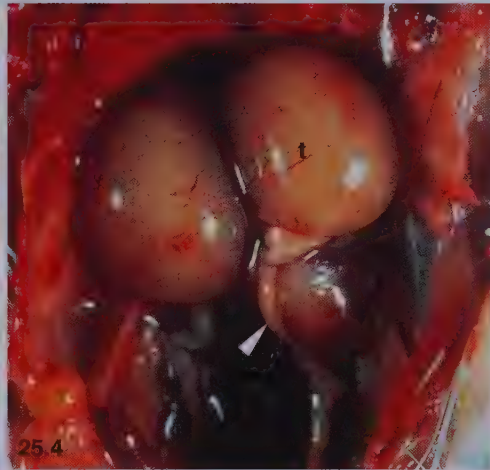25.1



25.2



25.3



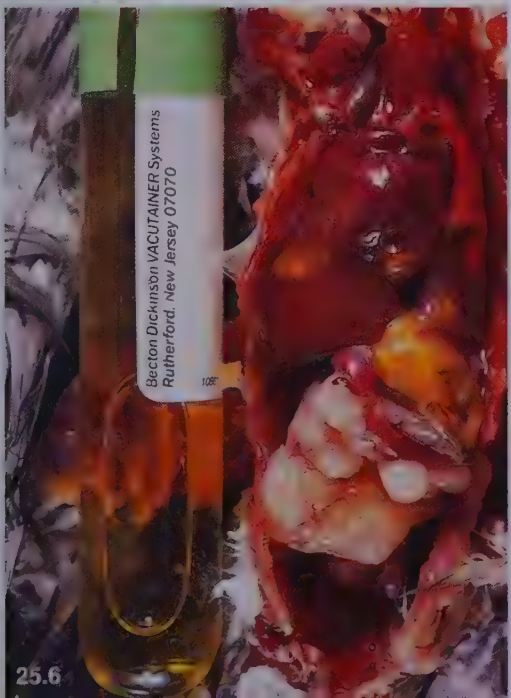
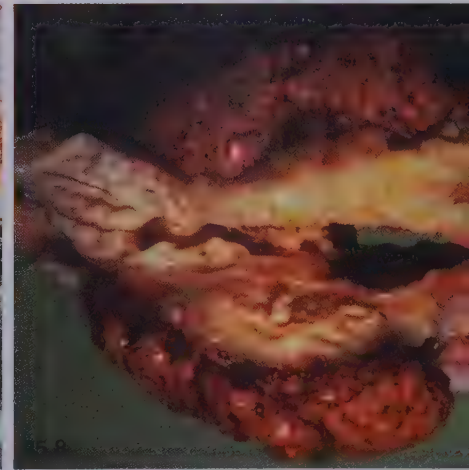25.4



25.5




25.7



Becton Dickinson VACUTAINER Systems  
Rutherford, New Jersey 07070

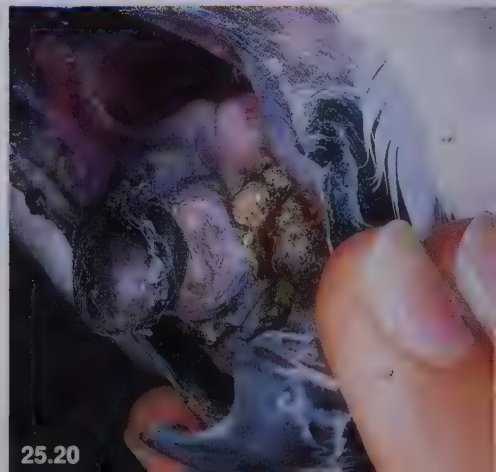
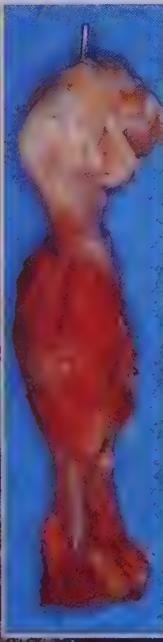
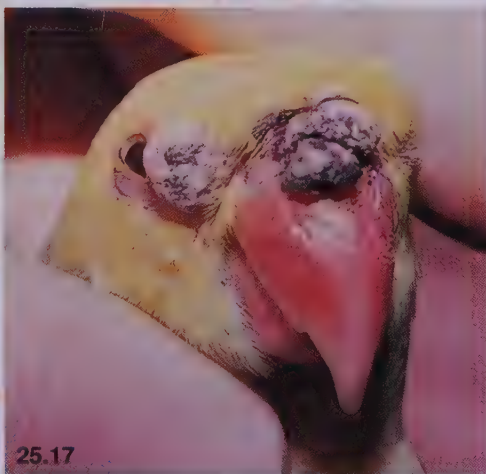
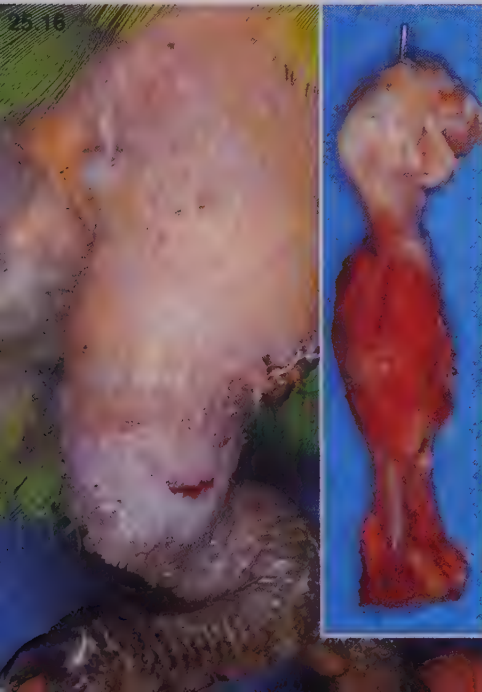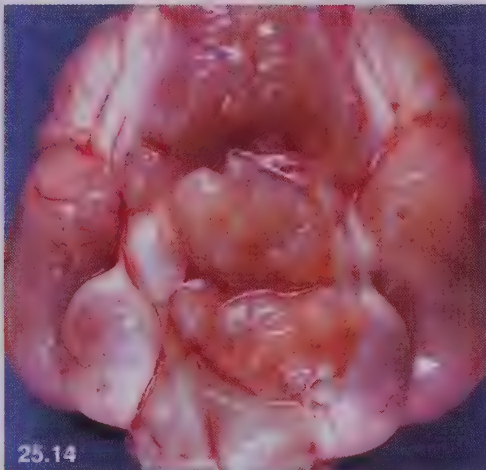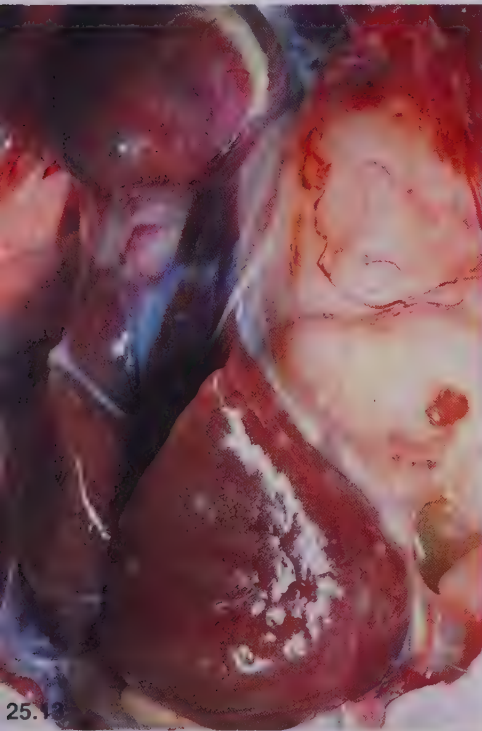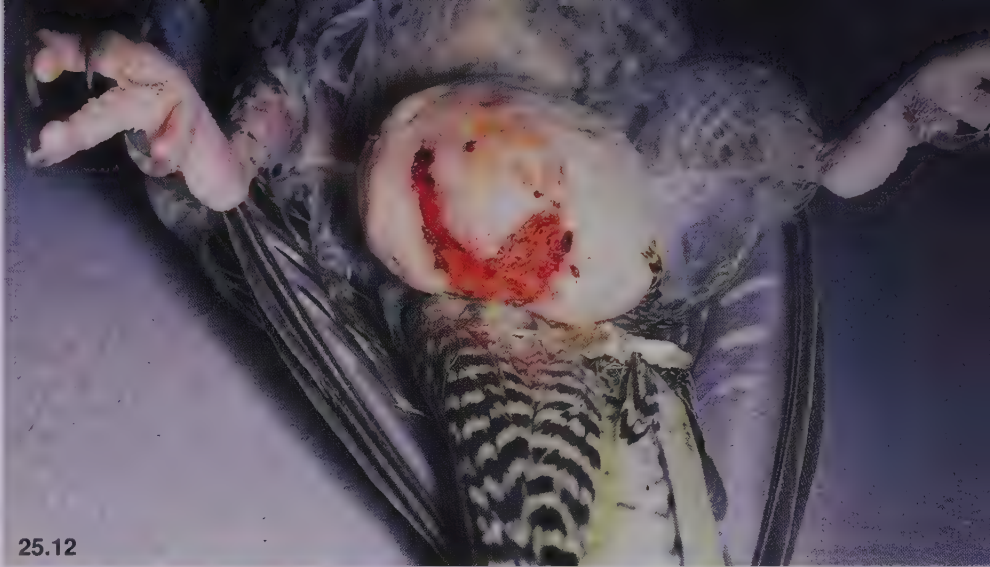25.6



25.9



25.10



## Oncology

### Color 25.11

A mature, male cockatiel was presented with a several-month history of poor generalized feather condition and feather loss around the uropygial gland. A raised, firm, uropygial gland mass was evident. Cytology of the mass revealed multiple mitotic figures. The mass was surgically removed and the histopathologic diagnosis was adenocarcinoma.

### Color 25.12

A four-year-old female cockatiel on an all-seed diet was presented with a three-month history of a progressively enlarging abdominal mass. On presentation, the ventral surface of the mass was dragging on the ground and the bird was having trouble ambulating. The bird weighed 128 g. Note the rotund appearance of the pelvic musculature. This bird responded to a change in diet and increased exercise over a three-month period, followed by surgical excision of the mass that was half its original size at the time of surgery.

### Color 25.13

A four-year-old female African Grey Parrot was presented for removal of a fibrosarcoma from the left dorsal humerus. Surgery was complete and uneventful. The bird was presented one year later with lethargy, anorexia, ataxia and severe dyspnea. Radiographs indicated a large, soft tissue mass in the cranial thorax. Cytology of a fine-needle aspirate indicated ovoid cells with large, eccentric nuclei suggestive of a neoplasm. The bird did not respond to supportive care. Histopathology revealed a renal tubular adenocarcinoma with metastasis to the lung, liver and myocardium. Interestingly, the bird's mate died from adenocarcinoma two years earlier.

### Color 25.14

A four-year-old Blue-fronted Amazon Parrot was presented for an acute onset of depression and apparent blindness. The only abnormal physical examination finding was mild ataxia. Radiographs of the abdomen were unremarkable. Blood lead and zinc levels were normal. A mild heterophilia (19,000 cells/ $\mu$ l) was the only abnormal clinicopathologic finding. EEGs indicated diffuse cerebral inflammation. The bird would maintain weight and condition with supportive care but would deteriorate when the supportive care was stopped. After two months the bird was euthanized. The ventral surface of the brain was nodular in appearance. The histopathologic diagnosis was meningioma.

### Color 25.15

A two-year-old female cockatiel was presented for feather picking associated with

the right carpus. A diffuse, firm, yellow mass was noted in the carpal region on physical examination. The appearance of the lesion was suggestive of xanthoma, and the demonstration of vacuolated macrophages, lipids and cholesterol crystals in a fine-needle aspirate from the mass was confirmatory. The xanthoma was surgically excised.

### Color 25.16

A mature Amazon parrot was presented with a non-weight-bearing lameness of one week's duration. Radiographs indicated a fracture of the mid-diaphyseal tibiotarsal bone. During surgery for placement of an IM pin, it was noted that the bone did not appear normal and a biopsy was performed. Surgical recovery was unremarkable. The biopsy report indicated osteosarcoma, and the client chose to have the bird euthanized. Inset shows the dissected bone, which had healed from the pathologic fracture, with the pin in place.

### Color 25.17

An adult Indian Ring-necked Parakeet was presented with a three-month history of a proliferating mass involving the cere and left periocular area. Note the defect in the rhamphotheca, indicating inflammation of the germinative layers of the beak. The masses were surgically removed. Histopathology was suggestive of a papilloma.

### Color 25.18

A mature budgerigar was presented with progressive dysphagia, and a disfiguring oral lesion was noted on physical examination. Histologic lesions were consistent with adenocarcinoma.

### Color 25.19

A four-year-old budgerigar was presented with a rapidly growing, necrotic mass of the upper beak. The mass was interfering with the bird's ability to eat, and the owners chose euthanasia. Histologic evaluation indicated the mass was a fibrosarcoma (courtesy of Jane Turrel).

### Color 25.20

A ten-year-old Umbrella Cockatoo was presented for dysphagia, weight loss and poor feather formation. On physical examination, a large, pendulated, ulcerative sublingual mass was identified. The bird had dystrophic feathers and was positive for PBFD virus by DNA probe testing of whole blood. Cytology of a fine-needle aspirate of the oral mass was suggestive of a giant cell granuloma. Radiographs of the head indicated the extent of the sublingual mass (see Figure 25.11).

morphic and numerous multinucleated giant cells were observed.

- **Oligodendroglioma:** This neoplasm originates from oligodendroglial cells. These neoplasms usually arise in the cerebral hemispheres. Microscopically, they are composed of small cells with round, hyperchromatic nuclei arranged in a honeycomb pattern.<sup>88</sup> A single “glioma” has been reported in the left cerebral hemisphere of a budgerigar, but microscopic characteristics of the neoplasm were not reported.<sup>6</sup>
- **Choroid Plexus Papilloma:** These benign neoplasms originate from the choroid plexus epithelium, usually in the fourth ventricle at the cerebropontine angle.<sup>88</sup> A choroid plexus papilloma has been observed in a budgerigar with blindness, exophthalmos and seizures.<sup>102</sup> A visible mass was not observed at necropsy; however, the tumor was apparent in tissue section. This neoplasm arose from the choroid plexus of the fourth ventricle. Rows of columnar cells were arranged in irregular papillary projections, small rosettes and contorted cysts. Neoplastic cells were columnar with round-to-oval, basal nuclei.
- **Neuroblastoma and Ganglioneuroma:** These neoplasms are derived from primitive neuroepithelial cells that differentiate toward neuroblasts (neuroblastoma) or neurons (ganglio-neuroma).<sup>88</sup> Ganglioneuromas have been reported in chickens where they may arise in the nervous system, gastrointestinal tract, ovary, muscle or heart.<sup>23</sup> These neoplasms are composed of ovoid, pyramidal or irregular neurons scattered among Schwann cells and fibrous stroma. Ganglioneuromas are usually benign, but may be malignant.
- **Vascular Neoplasms:** The most common vascular neoplasms observed in the central nervous system are hemangiosarcoma and hamartoma. A hamartoma is a benign tumor-like nodule composed of an overgrowth of mature cells. A hamartoma-like lesion has been reported in the brain of an 11-week-old budgerigar. Microscopically, the lesion was composed of blood-filled spaces within the neuropil that compressed adjacent tissue.<sup>12</sup> Vasoformative neoplasms are frequently observed in chickens; however, brain involvement has not been reported.<sup>74,129</sup>
- **Teratoma:** Grossly, these primordial germ cell neoplasms, which may be large and cystic, have been observed in chickens and ducks.<sup>21,23,38,58,61,63,68,76,112</sup> Teratomas have diverse sites of origin including the brain, pineal gland, testis, ovary, kidney, orbit, cranium, thoracoabdominal cavity and retroperitoneal

space. Teratomas arising within the cranial vault may cause neurologic deficits such as head tilt, circling and facial nerve paralysis.<sup>68,76</sup>

The microscopic appearance of these neoplasms is quite striking, containing a mixture of tissue types derived from two or three germ cell layers. The differentiated tissues may include cartilage, bone, fat, keratin cysts, smooth muscle, epithelium, neural cells and melanocytes.

- **Lymphosarcoma:** Lymphosarcoma of the central nervous system may be classified as a primary or secondary disease. Primary lymphosarcoma originates in the CNS, while secondary lymphosarcoma represents a metastatic event. Evidence exists for both of these presentations of lymphoid neoplasia in birds, although metastatic neoplasia is more common.<sup>9,49</sup> Most instances of CNS lymphosarcoma occur in poultry and are viral-induced.<sup>20,101</sup> Lymphosarcoma is discussed in detail under the hemolymphatic system.
- **Meningioma:** Meningiomas originate from neural crest cells or mesenchymal cells in contact with neural crest cells. Microscopically, meningiomas are often characterized by whorls of crescent-shaped cells.<sup>88</sup> Meningiomas have been reported in chickens, but have not been characterized in detail.<sup>23</sup>

### Peripheral Nervous System

Peripheral nervous system neoplasms arise in nervous tissues other than the brain and spinal cord. Localized neoplasms may be amenable to surgical excision based upon their location, size and proximity to vital structures.

- **Schwannoma:** These neoplasms previously have been reported as neurolemmomas or neurofibroma, the latter term being a misnomer.<sup>88</sup> Schwannomas may arise from Schwann cells or perineural cells of the peripheral nerve sheaths in any location including unspecified peripheral nerves, cranial nerves, sciatic plexus, gastrointestinal tract, testis, pineal gland, kidney, skin, muscle and spleen.<sup>17,23,85,108</sup>
- Grossly, these neoplasms appear as single-to-multiple nodular masses or varicose thickenings of the nerve sheath. Histologically, fusiform cells are arranged in interwoven bundles, whorls or palisaded arrangements. Specific diagnosis relies upon observation of the associated nerve of origin.<sup>17,88</sup>
- **Malignant Schwannoma:** Malignant schwannomas (neurofibrosarcoma is a misnomer) also origi-

nate from Schwann cells or perineural cells. These neoplasms have greater cellularity, marked anaplasia, an increased mitotic rate and may metastasize. Malignant schwannomas have been reported to occur in Canada Geese, but histologic studies have failed to demonstrate a neural origin.<sup>82,127</sup> Therefore, those neoplasms should be classified as fibrosarcomas instead of malignant schwannomas.


- **Lymphoid Neoplasia (Lymphosarcoma):** Marek's disease in chickens is often associated with leg paralysis secondary to ischiatic nerve infiltration by neoplastic lymphocytes. Affected nerves appear thickened. Microscopically, the lymphoid infiltrates may vary from small lymphocytes and plasma cells to lymphoblasts.<sup>20</sup> The former infiltrates appear inflammatory, while the latter infiltrates clearly are neoplastic.

### Ocular Neoplasms

The following discussion is concerned with primary and metastatic intraocular neoplasms of birds. Neoplasms involving the eyelids, conjunctiva and orbit are discussed under appropriate organ systems and will not be considered here (Figure 25.17).

Intraocular neoplasms in birds may be associated with blindness, hyphema or aqueous flare. Some neoplasms, such as malignant lymphoma, may be visualized occasionally by ophthalmoscopy. Because the avian eye is reinforced by scleral ossicles, buphthalmos is not expected. In contrast, exophthalmos occurs with some frequency and usually indicates a retrobulbar space-occupying lesion or extension of malignant ocular neoplasia into the retrobulbar area. In birds, exophthalmos has been associated with various retrobulbar neoplasms including malignant lymphoma, pituitary adenoma and adenocarcinoma, malignant intraocular medulloepithelioma, intraocular rhabdomyosarcoma, undifferentiated carcinoma, teratoma, and glioma.<sup>15,23,48,51,100,105,121,122</sup>

- **Lymphosarcoma:** Lymphosarcoma (malignant lymphoma) involving the iris, ciliary body and choroid is observed most frequently in chickens with Marek's disease.<sup>48</sup> When visualized, these neoplasms may appear as yellow-to-white proliferative masses. Most occurrences of ocular lymphoid neoplasia represent metastatic lesions.
- **Rhabdomyosarcoma:** Intraocular rhabdomyosarcomas have been reported in two chickens.<sup>48</sup> These neoplasms may have arisen from the ciliary muscles, which are striated in birds. One neoplasm extended



**FIG 25.17** A mature African Grey Parrot was presented with a space-occupying mass involving the right periorbital area and globe. The mass was surgically removed in conjunction with enucleation. The mass reappeared two years later and the bird was euthanized.

into the retrobulbar space. The other neoplasm replaced the iris, ciliary body and choroid.

- **Malignant Medulloepithelioma:** Intraocular medulloepitheliomas are primitive neoplasms that originate from the optic cup epithelium<sup>88</sup> and have been described in two cockatiels.<sup>122</sup> The neoplasms were composed of tall columnar neuroepithelial cells with well defined limiting membranes. These cells were arranged in nests, sheets and rosettes. Foci of necrosis also were observed. Neoplastic cells extended into the retrobulbar spaces, infiltrating the optic nerve and adjacent skeletal muscle.
- **Malignant Melanoma:** Metastatic ocular malignant melanoma has been reported in a Pintail Duck in association with multiple neoplasms involving adrenal gland, skin, liver, skeletal muscle, heart, lung, kidney, brain and bone.<sup>72</sup>

## Hemolymphatic System

The hemolymphatic system encompasses those tissues and organs that are involved in leukocyte, erythrocyte and thrombocyte production. The bone marrow produces thrombocytes, erythrocytes and most of

the leukocytes with the exception of lymphocytes. Lymphocyte production occurs within lymphoid tissues, which can be divided into primary and secondary lymphoid tissues. The thymus and bursa of Fabricius are the primary lymphoid tissues. The secondary lymphoid tissues are more diverse and, depending upon the species of bird, include the spleen; conjunctival, nasal and bronchial-associated lymphoid tissues; cecal tonsils, Peyer's patches, Meckel's diverticulum and other gut-associated lymphoid tissues; lymph nodes and lymphoid aggregates distributed throughout the body.<sup>109</sup> The majority of the lymphocytes are produced in the secondary lymphoid tissues.

Clinical signs related to hemolymphatic neoplasia are variable and vague including lethargy, anorexia, weight loss, lameness, swellings, dyspnea, loose droppings and petechial-to-ecchymotic hemorrhages. Death often occurs from organ dysfunction secondary to infiltrative disease.

### Lymphoid Neoplasia

Lymphoid neoplasia is the most common form of hemolymphatic neoplasia occurring in domestic, captive, and free-ranging birds.<sup>9,20,49,70,72,97,108,146</sup> This form of neoplasia may originate from the peripheral lymphoid tissues as lymphosarcoma (malignant lymphoma) or in the bone marrow as leukemia.

Lymphoid neoplasia of poultry has been studied extensively. In chickens, lymphoid neoplasms may be induced by herpesvirus or retrovirus infections. Herpesvirus infection causes Marek's disease. In this disease, early lymphoid infiltrates may appear inflammatory and consist of a mixture of small lymphocytes, plasma cells and lymphoblasts. Following neoplastic transformation, lymphoid neoplasms appear more progressive and are composed of lymphoblasts. In contrast, lymphoid leukosis is caused by retroviral-induced neoplastic transformation of B-lymphocytes. The presentations of Marek's disease and lymphoid leukosis may differ considerably.<sup>20</sup>

Lymphoid neoplasia of free-ranging and captive birds has not been studied in detail. A recent pathologic survey subclassified avian lymphoid neoplasia as plasmacytoma or fibrifying, lymphoblastic, lymphocytic or mixed-cell lymphosarcoma.<sup>108</sup> However, the prognostic importance of these subclassifications has not been demonstrated and requires further clinicopathologic study.

Currently, there is no effective treatment for avian lymphoid neoplasia. Radiation therapy may be pal-

liative.<sup>100</sup> Combination chemotherapy with vincristine sulfate, prednisone and chlorambucil appears promising but requires more clinical research.<sup>93</sup>

- **Lymphosarcoma:** Lymphosarcoma (malignant lymphoma) is defined as any lymphoid neoplasm that originates in the peripheral lymphoid tissues. This form of lymphoid neoplasia is commonly observed in birds and is characterized by the formation of white-to-yellow tissue discolorations or sarcomatous masses.

Lymphosarcoma usually presents as a disseminated multisystemic disease that can involve all tissues of the body, including bone marrow.<sup>9,20,97,108,146</sup> The abdominal viscera often are involved (visceral leukosis), especially the liver, spleen and kidney (Color 25.3). Occasionally, lymphosarcoma may show tissue tropism with multiple neoplasms being observed in one tissue such as skin.<sup>9</sup> The rarest presentation of lymphosarcoma is the presence of a single, localized neoplasm. This presentation was documented as a single neoplasm at the optic chiasm of a cockatiel.<sup>9</sup>

A presumptive diagnosis of neoplasia may be apparent after physical examination by observing swellings of the skin or retrobulbar masses.<sup>9,100,105</sup> Abdominal enlargement and hepatomegaly also may be present. In addition, soft tissue masses, hepatomegaly or osteolysis may be detected or confirmed radiographically.<sup>100,105</sup> A complete blood count may be beneficial in diagnosing lymphoid neoplasia by detecting lymphocytosis and demonstrating variable numbers of immature (neoplastic) lymphocytes in the blood film.<sup>9</sup> The latter finding is termed a "leukemic blood picture" and indicates hematogenous dissemination of the neoplasm.

- **Lymphoid Leukemia:** Lymphoid leukemia originates in the bone marrow and disseminates to various body tissues. This presentation of lymphoid neoplasia is rare compared to lymphosarcoma.<sup>93</sup> Birds with lymphocytic leukemia may have anemia, thrombocytopenia and marked lymphocytosis. Lymphocytes in blood smears may be well differentiated or blastic. Bone marrow aspirates contain innumerable lymphocytes. Sarcomatous masses are not observed in tissues at necropsy; however, hepatosplenomegaly may be prominent. Infiltration of various tissues by neoplastic lymphocytes is observed microscopically.
- **Thymoma:** Thymoma is a localized form of lymphoid neoplasia that is confined to one or more thymic lobes. Histologically, thymomas may present as lymphocytic or epithelial masses.



Thymoma has been observed in two budgerigars.<sup>15,152</sup> Only one neoplasm has been described in detail and presented as a palpable mass on the right side of the base of the neck.<sup>152</sup> Histologically, the neoplasm was an epithelial-type thymoma, consisting of aggregates of small lymphocytes and epithelial cells encased in a dense fibrous stroma. The epithelial cells had a “clear cell” morphology.

#### Nonlymphoid Neoplasia

Nonlymphoid hematologic neoplasia is observed most frequently in chickens infected with certain strains of leukosis (sarcoma) retroviruses.<sup>101</sup> Some strains of virus are associated with the development of granulocytic leukemia (myelocytomatosis) or erythremic myelosis (erythroblastosis).

- **Granulocytic Leukemia:** Granulocytic leukemia is the unregulated proliferation of granulocytes. In chickens, this disease (myeloblastosis) is caused by retrovirus infection; the etiology in captive and free-ranging birds has not been identified.<sup>101</sup>

Granulocytic leukemia in birds is sometimes associated with the formation of sarcomatous masses called myelocytomas. These lesions are analogous to chloromas in mammals. More commonly, tissue infiltration by neoplastic granulocytes results in hepatosplenomegaly. Microscopically, the neoplastic cells ap-

pear either blastic (myeloblastosis) or exhibit heterophilic (myelocytic) differentiation.<sup>108</sup> Differentiation is appreciated more readily, however, in blood and bone marrow smears as opposed to histologic sections.

- **Erythremic Myelosis:** Erythremic myelosis is the unregulated production of erythrocyte precursors. This form of leukemia is caused by retrovirus infection in chickens and has been called erythroblastosis.<sup>101</sup>

An erythremic myelosis-like syndrome has been described in conures.<sup>114</sup> Most of these birds appear weak and have a history of spontaneous hemorrhage. Histopathology has documented acute and chronic hemorrhages within various tissues in conjunction with erythrocyte proliferation in the bone marrow, hepatic sinusoids and splenic red pulp.<sup>114</sup> Although the evidence occasionally appears supportive of erythremic myelosis, marked extramedullary erythropoiesis cannot be excluded. In comparison to mammalian erythrocytes, avian erythrocytes have a very short life span (20 to 25 days). Following acute and ongoing hemorrhage, intense extramedullary erythropoiesis could occur, especially with concurrent recycling of iron from internal hemorrhage. Therefore, the conure bleeding syndrome will require further hematologic characterization before it can be classified absolutely as erythremic myelosis.

**TABLE 25.1 Specific Treatment Concerns of Neoplasms\***

Lipomas	Frequently recur following excision
Liposarcomas	Locally invasive and metastatic
Xanthomas	Excise localized masses, amputate limb if deeper tissues involved, irradiation (see text)
Fibrosarcomas	Generally unrewarding, locally invasive, if in extremities amputate ASAP
Hemangioma	Highly vascularized and must be excised with great care
Hemangiosarcomas	Frequently recur after surgical excision, amputate affected limb
Leiomyosarcoma	Must excise before metastasis occurs
Rhabdomyomas	Radical excisions necessary, margins difficult to define
Rhabdomyosarcomas	Radical excision before metastasis, bleed extensively
Chondromas/sarcomas	Difficult to remove without extensive damage to surrounding tissues
Osteosarcomas	Remove affected bone or limb; endoscopy, radiology and biopsy to check for metastasis
Renal adenocarcinomas	Generally considered untreatable, radioisotopes hold some promise
Embryonal nephroma**	Non-reported, difficult to remove because of underlying sacral plexus

\*Surgical excision is the treatment of choice for all tumors that are not listed.

\*\*All renal tumors are difficult to excise because of potential damage to sacral plexus.

**TABLE 25.2 Cytologic and Histologic Differentiation of Integumentary and Connective Tissue Neoplasms and Masses**

Mass	Cytology	Histopathology
Lipoma	Abundant free lipid, some intact adipocytes	See text
Myelolipoma	Hematopoietic precursors, differentiated hematopoietic cells, free lipid and intact adipocytes	Hematopoiesis (particularly heterophils) mixed with mature adipose tissue
Liposarcoma	Free lipid, scattered polyhedral cells with cytoplasmic vacuoles similar to xanthomas	See text
Xanthoma	Vacuolated macrophages, multinucleated giant cells, lipids, cholesterol clefts (appear as parallelograms with notched corners), rarely fibroblasts	Lipid-laden macrophages, multinucleated giant cells, cholesterol clefts, varying fibroplasia <sup>117</sup>
Fibrosarcoma	Pleomorphic spindle cells, multinucleated tumor giant cells, similar to reactive fibroplasia	Pleomorphic to spindle-shaped cells, plump nuclei, eosinophilic fibrillar cytoplasm, cells in bundles, sheets, whorls, mitotic figures may be numerous
Fibromas	Sparsely cellular, similar to fibrosarcomas, reactive fibroplasia	Compressed fibroblasts, dense collagenous stroma cells in sheets, swirls, or interlacing bundles
Myxoma/sarcoma	Viscous aspirate, free nuclei, spindle cells (singular or clusters)	Spindle cells in loose collagen matrix, alcian blue-positive mucinous ground substance, rare mitotic figures
Papilloma	See text	See text
Squamous cell carcinoma	See text	See text
Basal cell tumors	See text	See text
Cutaneous lymphosarcoma	See text	Neoplastic lymphocytes in the dermis or pulp cavity
Mast cell tumors	Round cell population with fine, purple cytoplasmic granules that may obscure nuclear detail (Romanowsky stain)	Uniform population of round cells, central round-to-oval nuclei and abundant eosinophilic cytoplasm, metachromatic granules (Giemsa stain)

Cytology based on fine-needle aspirates unless otherwise noted. The presence of lipid in cells and the background of the smears may be indirectly demonstrated by new methylene blue staining (fat- and aqueous-based stains do not mix). Histopathology is usually necessary to definitively diagnose the type of tumor.

## References and Suggested Reading

- Allen JL, Marin HD, Crowley AM: Metastatic cholangiocarcinoma in a Florida sandhill crane. *J Am Vet Med Assoc* 187:1215, 1985.
- Anderson WI, Dougherty EP, Steinberg H: Cholangiocarcinoma in a four-month-old double yellow-cheeked Amazon parrot (*Amazona autumnalis*). *Avian Dis* 33:594-599, 1989.
- Anderson WI, Steinberg H: Primary gossal squamous-cell carcinoma in a Spanish cochon hen. *Avian Dis* 33:827-828, 1989.
- Arai S, et al: Cutaneous tumour-like lesions due to poxvirus infection in Chilean flamingos. *J Comp Pathol* 104:439-441, 1991.
- Arnall L: Experiences with cage birds. *Vet Rec* 70:120-128, 1968.
- Arnall L: Further experiences with cage birds. *Vet Rec* 73:1146-1154, 1961.
- Baker JR: A survey of the causes of mortality in budgerigars (*Melopsittacus undulatus*). *Vet Rec* 106:10-12, 1980.
- Baker JR: A proventricular adenoma in a Brazilian teal (*Amazonetta brasiliensis*). *Vet Rec* 107:63-64, 1980.
- Bauk L: Lymphosarcoma/avian leukosis in pet birds: Case reports. *Proc Assoc Avian Vet, Miami*, 1986, pp 241-245.
- Bauk L: Pituitary neoplastic disease in nine budgies. *Proc 1st Intl Conf Zoo & Avian Med, Hawaii*, 1987, pp 87-89.
- Bauk LB, Cribb P: Masses of the beak and cere in three budgerigars. *Avian/Exotic Pract* 1:20-24, 1984.
- Beach JE: Disease of budgerigars and other cage birds. A survey of postmortem findings. Parts I, II and III. *Vet Rec* 74:10-15, 63-68, 134-140, 1962.
- Beasley JN, Klopp S, Terry B: Neoplasms in the oviducts of turkeys. *Avian Dis* 30:433-437, 1986.
- Blackmore DK: The incidence and aetiology of thyroid dysplasia in budgerigars (*Melopsittacus undulatus*). *Vet Rec* 75:1068-1072, 1963.
- Blackmore DK: The clinical approach to tumors in cage birds. I. The pathology and incidence of neoplasia in cage birds. *J Small Anim Pract* 6:217-223, 1966.
- Borst GHA, et al: Bone structures in avian and mammalian lungs. *Vet Pathol* 13:98-103, 1976.
- Bossart GD: Neurofibromas in a macaw (*Ara chloroptera*): Morphologic and immunocytochemical diagnosis. *Vet Pathol* 20:773-776, 1983.
- Brightman AH, Burke TJ: Eyelid tumor in a parakeet. *Mod Vet Pract* 59:683, 1978.
- Burstein H, et al: Viral aetiology of haemangiosarcoma outbreaks among layer hens. *Avian Pathol* 13:715-726, 1984.
- Calnek BW, Witter RL: Marek's disease. In Calnek BW, et al (eds): Diseases of Poultry 9th ed. Ames, Iowa State University Press, 1991, pp 342-385.
- Campbell JG: A retro-ocular teratoma containing pinealomatous tissue in a young chicken. *Br J Cancer* 16:258-266, 1962.
- Campbell JG: Tumours of the Fowl. London, William Heinemann Medical Books, Ltd., 1969.
- Campbell JG, Appleby EC: Tumours in young chickens bred for rapid body growth (broiler chickens): A study of 351 cases. *J Path Bact* 92:77-90, 1966.
- Campbell TW: Disorders of the avian crop. *Comp Cont Edu* 5:813-822, 1983.
- Campbell TW: Neoplasia. In Harrison GJ, Harrison LR (eds): Clinical Avian Medicine and Surgery. Philadelphia, WB Saunders Co, 1986, pp 500-508.
- Campbell TW: Avian Hematology and Cytology. Ames, Iowa State University Press, 1988.
- Campbell TW, Kennedy GA: Fibrosarcoma in a cockatiel (*Nymphicus hollandicus*). *AAV Today* 1:19-21, 1987.
- Campbell TW, Stuart LD: Ovarian neoplasia in the budgerigar (*Melopsittacus undulatus*). *Vet Med/Small Anim Clin* 79:215-218, 1984.
- Cardona CJ, Bickford AA, Emanuelson K: Squamous-cell carcinoma on the legs of an Araucana chicken. *Avian Dis* 36:474-479, 1992.
- Chaffee VW: Cervical tumor in a whistling swan (a case report). *Vet Med/Small Anim Clin* 69:98-99, 1974.
- Chalmers GA: Neoplasms in two racing pigeons. *Avian Dis* 30:241-244, 1986.
- Chang PW, Perry MC, Jasty V: Fibroma in a mute swan. *J Am Vet Med Assoc* 155:1039, 1969.
- Chin RP, Barr BC: Squamous-cell carcinoma of the pharyngeal cavity in a Jersey black giant rooster. *Avian Dis* 34:775-778, 1990.
- Choudary C: Neoplasms, cysts, and obstructive diseases. In Burr EW (ed): Companion Bird Medicine. Ames, Iowa State University Press, 1987, pp 231-239.
- Coleman CW: Bile duct carcinoma and cloacal prolapse in an orange-winged Amazon parrot (*Amazona amazonica amazonica*). *J Assoc Avian Vet* 5:87-89, 1991.
- Cooper JE, Lawton MPC, Greenwood AG: Papillomas in psittacine birds. *Vet Rec* 119:535, 1986.
- Cribb PH: Cloacal papilloma in an Amazon parrot. *Proc Assoc Avian Vet, Toronto, Ontario*, 1984, pp 35-36.
- Cullen JM, Newbold JE, Sherman GJ: A teratoma in a duck infected congenitally with duck hepatitis B virus. *Avian Dis* 35:638-641, 1991.
- Curtis-Velasco M: Pituitary adenoma in a cockatiel (*Nymphicus hollandicus*). *J Assoc Avian Vet* 6:21-22, 1992.
- Daoust P-Y, et al: Multicentric intramuscular lipomatosis/fibromatosis in free-flying white-fronted Canada geese. *J Wildl Dis* 27:135-139, 1991.
- Decker RA, Hruska JC: Renal adenocarcinoma in a crane (*Grus antigone*). *J Zoo Anim Med* 9(1):15-16, 1978.
- Dictor M, Jarplid B: The cause of Kaposi's sarcoma: An avian retroviral analog. *J Am Acad Dermatol* 18:398-402, 1988.
- Dillberger JE, Citino SB, Altman NH: Four cases of neoplasia in captive wild birds. *Avian Dis* 31:206-213, 1987.
- Dillehay DL, Lehner NDM: Diagnostic exercise: Abdominal mass in a male pigeon. *Lab Anim Sci* 40:202-203, 1990.
- Dillehay DL, Schoeb TR, Ranglack GS: Mucinous adenocarcinoma of the tongue in a great horned owl. *Vet Pathol* 22:520-521, 1985.
- Docherty DE, et al: Isolation of poxvirus from debilitating cutaneous lesions on four immature crackles (*Quiscalus* sp.). *Avian Dis* 35:244-247, 1991.
- Doster AR, et al: Liposarcoma in a Canada goose (*Branta canadensis*). *Avian Dis* 31:918-920, 1987.
- Dukes TW, Pettit JR: Avian ocular neoplasia: A description of spontaneous occurring cases. *Can J Comp Med* 47:33-36, 1983.
- Effron M, Griner L, Benirschke K: Nature and rate of neoplasia found in captive wild mammals, birds, and reptiles at necropsy. *J Natl Cancer Inst* 59:185-198, 1977.
- Elangbam CS, Panciera RJ: Cholangiocarcinoma in a blue-fronted Amazon parrot (*Amazona aestiva*). *Avian Dis* 32:594-596, 1988.
- Frost C: Experiences with pet budgerigars. *Vet Rec* 73:621-626, 1961.
- Gardner MB, et al: Electron microscopic search for retrovirus particles in spontaneous tumors of the parakeet. *Vet Pathol* 18:700-703, 1981.
- Gorham SL, Ottinger MA: Sertoli cell tumors in Japanese quail. *Avian Dis* 30:337-339, 1986.
- Gotto N, et al: A case of seminoma in a black swan. *Jpn J Vet Sci* 48:1297-1299, 1986.
- Graham DL: Internal papillomatous disease: A pathologist's view or cloacal papillomas - and then some! *Proc Assoc Avian Vet, Chicago*, 1991, pp 141-143.
- Graham DL, Heyer GW: Diseases of the exocrine pancreas in pet, exotic, and wild birds: A pathologist's perspective. *Proc Assoc Avian Vet, New Orleans*, 1992, pp 190-193.
- Greiner LA, et al: Heterakidosis and nodular granulomas caused by *Heterakis isolonche* in the ceca of gallinaceous birds. *Vet Pathol* 14:582-590, 1977.
- Gupta BN: Teratoma in a chicken (*Gallus domesticus*). *Avian Dis* 20:761-768, 1976.
- Hafner S, et al: Spontaneous regression of "dermal squamous cell carcinoma" in young chickens. *Avian Dis* 35:321-327, 1991.
- Haley PJ, Norrdin RW: Periarticular xanthomatosis in an American kestrel. *J Am Vet Med Assoc* 181:1394-1396, 1982.
- Hamir AN: Teratoma in a duck. *Vet Rec* 117:314, 1985.
- Hembolt CF, Wyand DS: Parasitic neoplasia in the golden pheasant. *J Wildl Dis* 8:3-6, 1972.
- Hemboldt CF, et al: Teratoma in a domestic fowl (*Gallus gallus*). *Avian Dis* 18:142-148, 1974.
- Hill JE, Burke DL, Rowland GN: Hepatopathy and lymphosarcoma in a mynah bird with excessive iron storage. *Avian Dis* 30:634-636, 1986.
- Hillyer EV, et al: Bile duct carcinoma in two out of ten Amazon parrots with cloacal papillomas. *J Assoc Avian Vet* 5:91-95, 1991.
- Hillyer EV, Quesenberry KE, Baer K: Basic avian dermatology. *Proc Assoc Avian Vet, Seattle*, 1989, pp 101-121.
- Hochleitner M: Cystadenoma in an African grey parrot (*Psittacus erithacus*). *J Assoc Avian Vet* 4:163-165, 1990.
- Homer BL, Riggs MW: Cranial teratomas in two domestic ducks (*Anas platyrhynchos domesticus*). *Avian Dis* 35:994-998, 1991.
- Howerth EW, Schorr LF, Nettles VF: Neoplasia in free-flying ruffed grouse (*Bonasa umbellus*). *Avian Dis* 30:238-240, 1986.
- Hruban Z, et al: Haematopoietic malignancies in zoo animals. *J Comp Pathol* 106:15-24, 1992.
- Hubbard GB: Renal carcinoma in a captive Edwards lory (*Trichoglossus haematodus capistratus*). *J Wildl Dis* 19:160-161, 1983.
- Hubbard GB, Schmidt RE, Fletcher KC: Neoplasia in zoo animals. *J Zoo Anim Med* 14:33-40, 1983.
- Jacobsen ER, et al: Papilloma-like virus infection in an African grey parrot. *J Am Vet Med Assoc* 189:1307-1308, 1983.
- Jarplid B: Haemangioendotheliomas in poultry. *J Comp Pathol* 71:370-376, 1961.
- Jessup DA: Fibrosarcoma in a burrowing owl (*Speotyto cucularia*). *J Zoo Anim Med* 10:51-52, 1979.
- Jones LD: Avian cerebellar teratoma. *Avian Dis* 8:580-584, 1964.
- Kajjaya H, et al: The influence of celomic membranes and a tunnel between celomic cavities on cancer metastasis in poultry. *Avian Dis* 31:176-186, 1987.
- Kufor-Mensah E, Watson GL: Malignant melanomas in a penguin (*Eudyptes chrysolophus*) and a red-tailed hawk (*Buteo jamaicensis*). *Vet Pathol* 29:354-356, 1992.
- Leach MW, Paul-Murphy J, Lowenstein LJ: Three cases of gastric neoplasia in psittacines. *Avian Dis* 33:204-210, 1989.
- Levine BS: What is your diagnosis? Intramural mass in the proventriculus. *J Am Vet Med Assoc* 185:911-912, 1984.
- Liu S, Dolensek EP, Tappe JP: Osteosarcoma with multiple metastases in a Panama boat-billed heron. *J Am Vet Med Assoc* 181:1396-1398, 1982.
- Locke LN: Multicentric neurofibrosarcoma in a Canada goose, *Branta canadensis*. *Avian Dis* 7:196-202, 1963.
- Lambard LS, Witte EJ: Frequency and types of tumors in mammals and birds of the Philadelphia Zoological Garden. *Cancer Res* 19:127-141, 1959.
- Martin HD: Resection of a false aneurysm in a cockatiel (*Nymphicus hollandicus*). *J Assoc Avian Vet* 5:142-146, 1991.
- Montali RJ: An overview of tumors in zoo animals. In Montali RJ, Migaki G (eds): The Comparative Pathology of Zoo Animals. Washington, DC, Smithsonian Institution Press, 1980, pp 531-542.
- Moore M: Generalized lipomas in a Hispaniolan Amazon. *Vet Med/Small Anim Clin* 79:666-669, 1984.
- Moreno-Lopez J, et al: Genome of an avian papillomavirus. *J Virol* 51:872-875, 1984.
- Moulton JE (ed): Tumors in Domestic Animals 3rd ed. Berkeley, University of California Press, 1990.
- Murphy CJ, Bellhorn RW, Buyukmihci NC: Subconjunctival fibroma in a goose. *J Am Vet Med Assoc* 189:1109-1110, 1986.
- Murtaugh RJ, Ringler DJ, Petrak ML: Squamous cell carcinoma of the esophagus in an Amazon parrot. *J Am Vet Med Assoc* 188:872-873, 1986.
- Nazerian K: An updated list of avian cell lines and transplantable tumours. *Avian Pathol* 16:527-544, 1987.
- Neumann U, Kummerfeld N: Neoplasms in budgerigars (*Melopsittacus undulatus*): Clinical, pathomorphological and serological findings with special consideration of kidney tumours. *Avian Pathol* 12:353-362, 1983.
- Newell SM, McMillan MC, Moore FM: Diagnosis and treatment of lymphocytic leukemia and malignant lymphoma in a Pekin duck (*Anas platyrhynchos domesticus*). *J Assoc Avian Vet* 5:83-86, 1991.
- O'Banion MK, Jacobson ER, Sundberg JP: Molecular cloning and partial characterization of parrot papillomavirus. *Intervirology* 33:91-96, 1992.
- Opengart KN, et al: Congenital extrahepatic biliary cyst in a Congo African grey parrot (*Psittacus erithacus erithacus*). *Avian Dis* 34:497-500, 1990.
- Osterhaus ADME, Ellens DJ, Horzinek MC: Identification and characterization of a papillomavirus from birds (Fringillidae). *Intervirology* 8:351-359, 1977.
- Palmer GH, Stauber E: Visceral lymphoblastic leukosis in an African grey parrot. *Vet Med/Small Anim Clin* 76:1355, 1981.
- Pass DA: The pathology of the avian integument: A review. *Avian Pathol* 18:1-72, 1989.

99. **Patnaik GM, Mohanty D:** A case of avian mastocytosis. *Indian Vet J* 47:298-300, 1970.
100. **Paul-Murphy J, et al:** Malignant lymphoreticular neoplasm in an African grey parrot. *J Am Vet Med Assoc* 187:1216-1217, 1985.
101. **Payne LN, Purchase HG:** Leukosis/sarcoma group. In Calnek BW, et al (eds): *Diseases of Poultry* 9th ed. Ames, Iowa State University Press, 1991, pp 386-349.
102. **Petrak ML, Gilmore CE:** Neoplasms. In Petrak ML (ed): *Diseases of Cage and Aviary Birds* 2nd ed. Philadelphia, Lea & Febiger, 1982, pp 606-637.
103. **Potter K, Connor T, Gallina AM:** Cholangiocarcinoma in a yellow-faced Amazon parrot (*Amazona xanithops*). *Avian Dis* 27:556-558, 1983.
104. **Rae MA, Merryman M, Lintner M:** Gastric neoplasia in caged birds. *Proc Assoc Avian Vet, New Orleans*, 1992, pp 180-189.
105. **Rambow VJ, Murphy JC, Fox JG:** Malignant lymphoma in a pigeon. *J Am Vet Med Assoc* 179:1266-1268, 1981.
106. **Raphael BL, Clemmons RL, Nguyen HT:** Glioblastoma multiforme in a budgerigar. *J Am Vet Med Assoc* 177:923-925, 1980.
107. **Raphael BL, Nguyen HT:** Metastasizing rhabdomyosarcoma in a budgerigar. *J Am Vet Med Assoc* 177:925-926, 1980.
108. **Reece RL:** Observations on naturally occurring neoplasms in birds in the state of Victoria, Australia. *Avian Pathol* 21:3-32, 1992.
109. **Riddell C:** *Avian Histopathology*. New Bolton, American Association of Avian Pathologists, 1987.
110. **Riddell C, Cribb PH:** Fibrosarcoma in an African grey parrot (*Psittacus erithacus*). *Avian Dis* 27:549-555, 1983.
111. **Ridgeway RL:** Oral xanthoma in a budgerigar, *Melopsittacus undulatus* (a case report). *Vet Med/Small Anim Clin* 75:266-267, 1977.
112. **Rigdon RH:** Spontaneous-occurring tumors in the duck: Review of the literature and report of three cases. *Avian Dis* 14:431-444, 1970.
113. **Roskopf WJ, Woerpel RW:** Remission of lipomatous growths in a hypothyroid budgerigar in response to L-thyroxine therapy. *Vet Med/Small Anim Clin* 78:1415-1418, 1983.
114. **Roskopf WJ, Woerpel RW:** Erythremic myelosis in conures. The "hemorrhagic conure syndrome." A preliminary report. *Proc Assoc Avian Vet, Toronto*, 1984, pp 213-228.
115. **Russell WC:** Iodine goiter in penguins. *J Zoo Anim Med* 1:24-27, 1970.
116. **Ryan CP, Walder EJ, Howard EB:** Diabetes mellitus and islet cell carcinoma in a parakeet. *J Am Anim Hosp Assoc* 18:139-142, 1982.
117. **Sanger VI, Lagace A:** Avian xanthomatosis. Etiology and pathogenesis. *Avian Dis* 10:103-111, 1966.
118. **Sasipreeyajan J, Newman JA:** Goiter in a cockatiel (*Nymphicus hollandicus*). *Avian Dis* 32:169-172, 1988.
119. **Sasipreeyajan J, Newman JA, Brown PA:** Leiomyosarcoma in a budgerigar (*Melopsittacus undulatus*). *Avian Dis* 32:163-165, 1988.
120. **Saunders NC, Saunders JK:** Malignant melanoma in a budgerigar (*Melopsittacus undulatus*). *Avian Dis* 35:999-1000, 1991.
121. **Schlumberger HG:** Neoplasias in the parakeet I. Spontaneous chromophobe pituitary tumors. *Cancer Res* 14:237-245, 1954.
122. **Schmidt RE, Becker LL, McElroy JM:** Malignant intraocular medulloepithelioma in two cockatiels. *J Am Vet Med Assoc* 189:1105-1106, 1986.
123. **Schmidt RE, Dustin LR, Slevin RW:** Proventricular adenocarcinoma in a budgerigar (*Melopsittacus undulatus*) and a grey-cheeked parakeet (*Brotogeris pyrrhopterus*). *AAV Today* 2:13-14, 1988.
124. **Schmidt RE, Okimoto B:** Mast cell tumors in two owls. *J Assoc Avian Vet* 6:23-24, 1992.
125. **Schmidt EV, Smith RE:** Skeletal hyperostoses. Viral induction of avian osteopetrosis. *Am J Pathol* 106:297-299, 1982.
126. **Schmidt EV, et al:** A quantitative histologic study of avian osteopetrotic bone demonstrating normal osteoclast numbers and increased osteoblastic activity. *Lab Invest* 44:164-173, 1981.
127. **Siegfried LM:** Neoplasms identified in free-flying birds. *Avian Dis* 27:86-99, 1983.
128. **Simon MC, et al:** Genetic determinants of neoplastic diseases induced by a subgroup F avian leukosis virus. *J Virol* 61:1203-1212, 1987.
129. **Soffer D, et al:** Multifocal vascular tumors in fowl induced by a newly isolated retrovirus. *Cancer Res* 50:4787-4793, 1990.
130. **Speckman G:** Multiple keratomas of a captive pelican (*Pelicanus occidentalis*). *J Zoo Anim Med* 7(4):32-35, 1976.
131. **Spira A:** Hepatoma in a mynah. *Mod Vet Pract* 60:925-928, 1979.
132. **Stauber E, et al:** Polyostotic hyperostosis associated with oviductal tumor in a cockatiel. *J Am Vet Med Assoc* 196:939-940, 1990.
133. **Steinberg H:** Leiomyosarcoma of the jejunum in a budgerigar. *Avian Dis* 32:166-168, 1988.
134. **Stoica G, Russo E, Hoffman JR:** Abdominal tumor in a military macaw (Diagnosis: metastatic ovarian carcinoma). *Lab Anim* 18(5):17-20, 1989.
135. **Sugiyama M, et al:** Dermal squamous cell carcinoma in a laying hen. *Jpn J Vet Sci* 49:1129-1130, 1987.
136. **Sundberg JP, et al:** Cloacal papillomas in psittacines. *Am J Vet Res* 47:928-932, 1986.
137. **Swartout MS, Wyman M:** Pancreatic carcinoma in a cockatiel. *J Am Vet Med Assoc* 191:451-452, 1987.
138. **Swayne DE, Rowland GN, Fletcher OJ:** Pinealoma in a broiler breeder. *Avian Dis* 30:853-855, 1986.
139. **Swayne DE, Weisbrode SE:** Cutaneous mast cell tumor in a great horned owl (*Bubo virginianus*). *Vet Pathol* 27:124-126, 1990.
140. **Tripathy DN:** Pox. In Calnek BW, et al (eds): *Diseases of Poultry*, 9th ed. Ames, Iowa State University Press, 1991, pp 583-596.
141. **Turk JR, Kim J, Gallina AM:** Seminoma in a pigeon. *Avian Dis* 25:752-755, 1981.
142. **Turnquest RU:** Dermal squamous cell carcinoma in young chickens. *Am J Vet Res* 40:1628-1633, 1979.
143. **Turrel JM, McMillan MC, Paul-Murphy J:** Diagnosis and treatment of tumors of companion birds. Parts I & II. *AAV Today* 1:109-116; 159-165, 1987.
144. **Van Toor AJ, Zwart P, Kaal GTF:** Adenocarcinoma of the kidney in two budgerigars. *Avian Pathol* 13:145-150, 1984.
145. **Wadsworth PF, Jones DM:** An ovarian adenocarcinoma in a greater flamingo (*Phoenicopterus ruber roseus*). *Avian Pathol* 10:95-99, 1981.
146. **Wadsworth PF, Jones DM, Pugsley SL:** Some cases of lymphoid leukosis in captive wild birds. *Avian Pathol* 10:499-504, 1981.
147. **Wadsworth PF, et al:** Some hepatic neoplasms in non-domesticated birds. *Avian Pathol* 7:551-555, 1978.
148. **Webster WS, Bullock BC, Prichard RW:** A report of three bile duct carcinomas occurring in pigeons. *J Am Vet Med Assoc* 155:1200-1205, 1969.
149. **Wheeldon EB:** Feather folliculoma in the canary (*Serinus canarius*). *Vet Pathol* 19:204-206, 1982.
150. **Wight PAL, Duff SRI:** Ectopic pulmonary cartilage and bone in domestic fowl. *Res Vet Sci* 39:188-195, 1985.
151. **Wilson RB, et al:** Pineoblastoma in a cockatiel. *Avian Dis* 32:591-593, 1988.
152. **Zubaidy AJ:** An epithelial thymoma in a budgerigar (*Melopsittacus undulatus*). *Avian Pathol* 9:575-581, 1980.

**I**n general, the techniques of evaluating the avian eye are similar to those used in mammals. However, the small size of the eye in companion birds and the striated sphincter muscle of the avian iris necessitate modified procedures to visualize the posterior segment of the eye.

Each ophthalmologist has a particular pattern for ophthalmic examination. The key to effective evaluation is to develop a logical, consistent use of the same pattern of examination for each eye.

Before a bird is agitated by restraint, the eyes should be evaluated from a distance, noting whether the bird will fixate on moving objects, whether both pupils are the same size and whether there are any obvious abnormalities in the periorbital area (Figure 26.1). Vision can be difficult to evaluate because birds can feel slight air movements created by an approaching hand. The detailed examination requires adequate restraint, and a darkened room will calm the bird and improve the illumination provided by a focal light source.

Many disease processes affect the external eye and periorbita. Ocular discharge, conjunctival hyperemia or periorbital swelling can be an indication of a primary ocular disorder or may occur secondary to sinusitis or facial dermatitis (see Chapter 24). Some larger Psittaciformes may inflate a portion of their periorbital sinus as an aggressive gesture, creating a transient swelling in the periorbital region (Color 26.4). This swelling should not be mistaken for periorbital disease. Collapse of the anterior chamber may occur in an otherwise normal eye following a period of head restraint or lateral recumbency during anesthesia. Normal anterior chamber depth is rapidly regained.

Examination of the anterior segment can be performed with a bright pen light, a binocular loupe, an operating microscope, an ophthalmoscope set on +20 diopters or, ideally, a slit lamp (Figure 26.2). Key features to evaluate are the clarity of the cornea, the aqueous, the lens and the color and vascularization of the iris. Aqueous flare, as seen in uveitis, can be detected by looking for scattering of a slit light beam that is passing through the anterior chamber (Colors 26.25, 26.26). Pupillary light reflexes can be determined, but because the avian iris is under conscious control, rapid changes in pupil diameter according to

---

CHAPTER

---

26

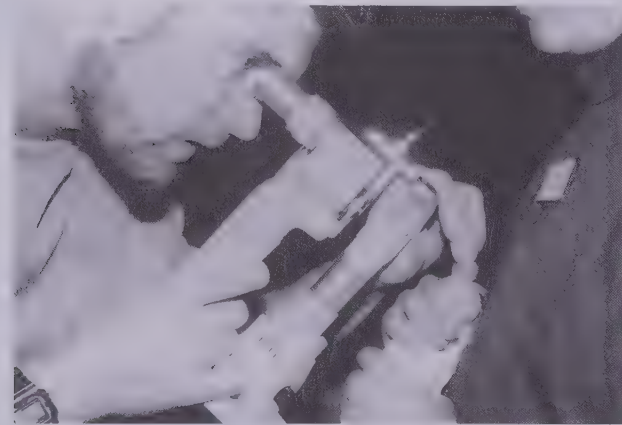OPHTHALMOLOGY

---

David Williams



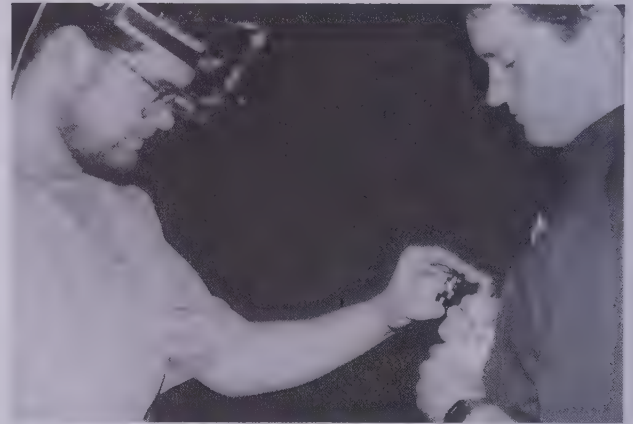**FIG 26.1** Normal periocular area in a Grey-cheeked Parakeet. The eye should be open with a bright, shiny appearance. The lid margins should be evenly colored, dry and symmetrically shaped.



**FIG 26.2** A slit lamp is ideal for examining the anterior segment of the avian eye. The lamp can also be used to facilitate evaluation of oral and dermatologic lesions (courtesy of David Williams).

the degree of alertness of the animal can make evaluation difficult.

Retinal examination is difficult in many birds because of the small size of the eye and the lack of response of the avian iris to conventional parasympathomimetic mydriatics. Mydriasis can be accomplished by intracamerular injection of d-tubocurarine or by the frequent use of a freshly prepared topical 3 mg/ml solution of crystalline d-tubocurarine in 0.025% benzilonium chloride over a fifteen-minute period.<sup>5,56</sup> A more practical approach may be the topical use of commercially available neuromuscular blocking agents commonly used for intravenous in-



**FIG 26.3** Indirect ophthalmoscopy in a cockatiel to evaluate the fundus. A 28 diopter lens is particularly useful but results in an inverted image that requires some practice to interpret (courtesy of David Williams).

jections. The most useful regime in raptors has been found to be vecuronium bromide solution (4 mg/ml) topically every five minutes for fifteen minutes (see Chapter 18).<sup>53</sup>

With or without mydriasis, the easiest way to view the fundus is to start with the direct ophthalmoscope at the +20 dioptre setting, and with the instrument close to the bird's eye, change the dioptre setting gradually back to zero. This will bring the pleated pecten into view. It is then possible to focus on the avascular retina at the posterior of the eye. An indirect ophthalmoscope is excellent (Figure 26.3), although an expensive binocular all-pupil model is needed if adequate mydriasis is not achieved. A 28 or 40 dioptre lens is useful to obtain a good field of view in the small avian eye. A 90 dioptre lens used with a slit-lamp provides excellent visualization of a large area of the fundus.

### ■ Ancillary Tests for Evaluation of the Eye

Further testing can be used to confirm or refute the presence of suspicious lesions detected by gross observation. Corneal ulcerations can be detected by staining with fluorescein dye. The Schirmer Tear Tests can be used on birds, although normal data for psittacine birds have not been published. Conventional 6 mm-wide Schirmer tear test filter paper strips have been found to be difficult to insert in the lower conjunctival sac of the smaller Psittaciformes; thus trimming these to 4 mm is more useful. This also give a higher reading of wetted strip length than the 6 mm-wide filter strips, with which the Schirmer tear test results are rarely over 3 in clinically normal

birds. To date, Schirmer tear test readings have been found to be  $8 \pm 1.5$  mm in the larger Psittaciformes such as the African Grey Parrot, and  $4.5 \pm 1$  mm in smaller species such as lorries and conures.

The difference in tear production between species is presumably related to the size of the orbit and lacrimal gland tissue. These interspecies differences make it difficult to provide standard normal data for all Psittaciformes. With unilateral problems, comparison between the affected and the unaffected eye may be useful. A normal bird of the same species, ideally an enclosure mate, can also be used for comparative purposes.

Tonometry is possible in birds, but little normal data has been published. The simple indentation Schiotz tonometer cannot be used in smaller birds because of its large footplate, which covers the cornea and sclera in all but the largest avian species. However, the portable Tonopen applanation tonometer is ideal for use in birds. One study indicates that this instrument provided reproducible readings in birds with corneal diameters over 9 mm. Some readings in birds with corneal diameters as small as 5 mm were reliable.<sup>40</sup> This tonometric examination of 275 birds (39 species) showed intraocular pressures in normal eyes of between 9.2 and 16.3 mmHg. Among 14 species of psittacine birds, values were found to be  $14.4 \pm 4.2$  mmHg with a sample size of 74 birds.

Avian periorbital and external eye disease is frequently associated with infectious agents. A consistent technique for sample collection should be used to increase the validity of the sample. The best diagnostic bacteriologic samples can be obtained by inserting a sterile swab moistened in transport medium into the upper conjunctival fornix and rubbing it from side to side two or three times. The upper fornix is the preferred site for collecting culture samples because there is less contamination from environmental organisms than in the lower fornix. Conjunctival scrapings can be stained with a modified Wright's stain for general cytology. A Giemsa stain can be used to detect chlamydial elementary bodies (see Chapters 10, 34).<sup>14</sup>

## Anatomy of the Eye

An understanding of the anatomy of the avian eye (Figures 26.4-26.7) and how it differs from the mammalian eye is vital when differentiating between the normal and abnormal.<sup>24,46,52,68,77</sup>

As an overview, the avian eyelids are mobile, the lower more so than the upper. The meibomian glands are absent, but a lacrimal gland (varying in size between species) is present, inferior and lateral to the globe. The Harderian gland acts as a second lacrimal gland at the base of the nictitating membrane (Figure 26.5). The nictitating membrane actively moves over the cornea during blinking and in the menace response (Color 26.1). It has an unusual muscular arrangement; it is drawn across the eye by the pyramidal muscle originating in the posterior sclera and loops over the optic nerve through a sling formed by the bursalis muscle (quadratus muscle.) Inferior and superior nasolacrimal puncta at the medial canthus drain lacrimal secretions into the nasal cavity (Color 26.2).

The orbit is open, but, because the globe occupies the vast majority of the space, the rectus and oblique muscles are not well developed, and torsional movements of the globe are limited in many species to between two and five degrees. A key point in the anatomy of the avian orbit is the close proximity of the tightly packed orbit with the infraorbital diverticulum of the infraorbital sinus (Figure 26.5). Sinusitis and enlargement of this diverticulum will

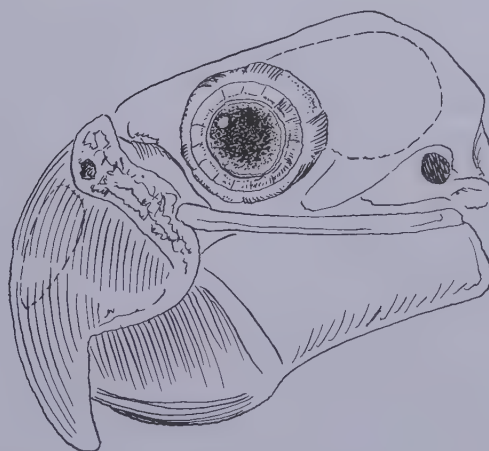
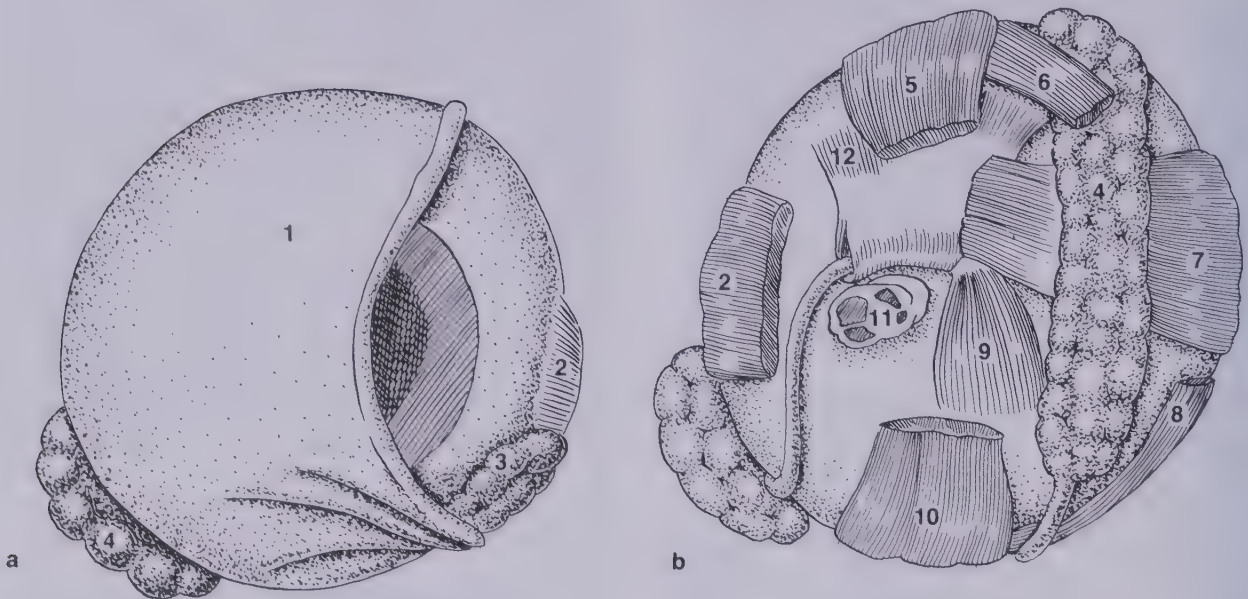


FIG 26.4 Relative size of the globe to the skull.



**FIG 26.5** a) Anterior and b) Posterior view of the avian globe. 1) Nictitating membrane 2) M. lateral rectus 3) lacrimal gland 4) gland of nictitating membrane 5) M. dorsal rectus 6) M. dorsal oblique 7) M. medial rectus 8) M. ventral oblique 9) M. pyramidalis 10) M. ventral rectus 11) optic nerve and 12) M. quadratus (modified from Martin<sup>46</sup>).

therefore lead to periorbital or orbital compression and signs of periorbital swelling, conjunctivitis and sometimes intraocular disease (Color 26.16).

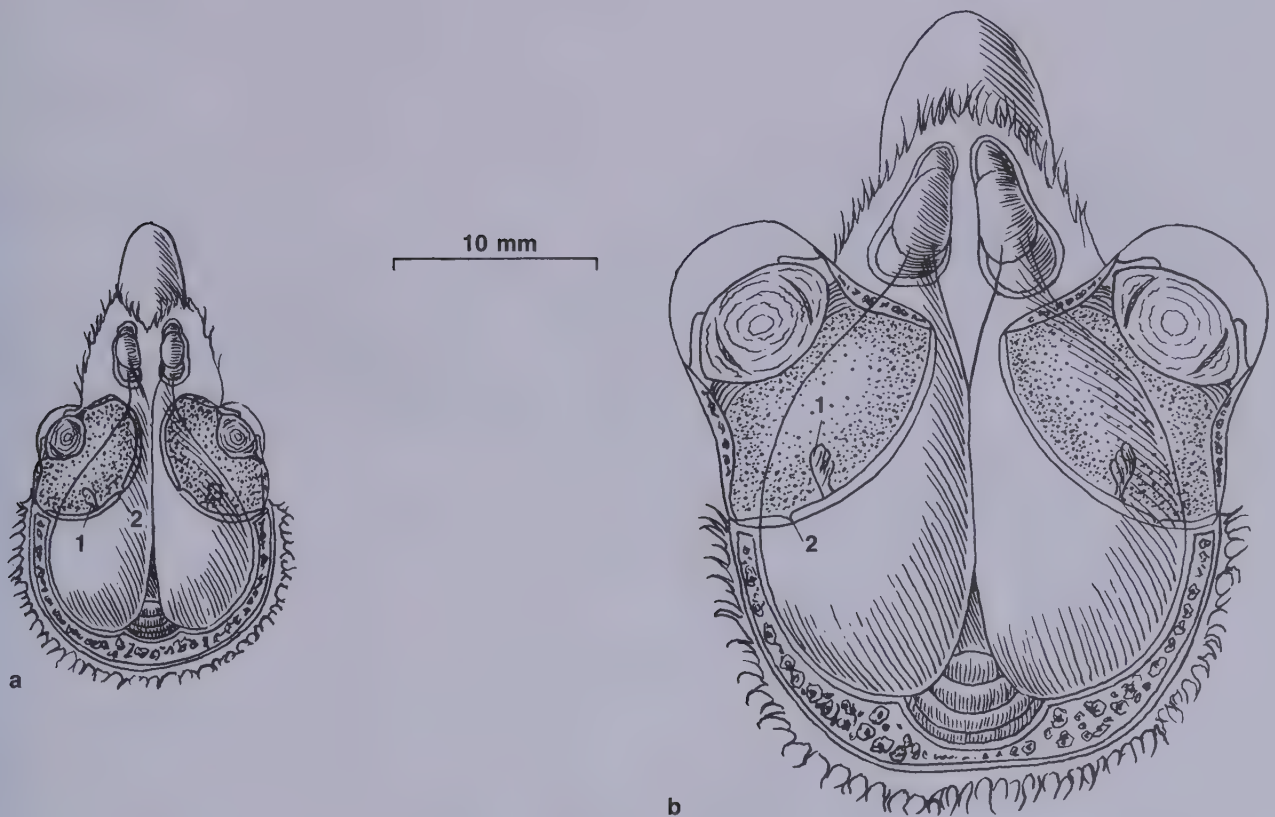
In most birds, including Psittaciformes, the globe is antero-posteriorly flattened, with a hemispherical posterior segment. It is rounded in some diurnal birds and tubular in owls (Figure 26.6). The sclera immediately posterior to the cornea contains scleral ossicles, and through its full circumference, the sclera has a support of hyaline cartilage (Figure 26.7). The avian cornea is similar to that of mammals except that it is considerably thinner, and unlike mammals, it has a Bowman's layer. The thickness of the cornea varies depending on the size of the bird. The anterior segment is relatively shallow compared with the posterior segment, with some anatomic differences noted between species. Owls have an unusually deep anterior chamber (Color 26.21).

The iris is thin and contains striated dilator and constrictor muscles. Varying chromatophores create the different iris colors noted with age, gender and species of some birds. In some white cockatoo species, for example, the iris is dark brown in the adult male

and reddish pink in the adult female. Immature cockatoos of both genders have black irides. In the Moluccan Cockatoo, however, the male has a black iris and the female has a dark brown iris, and in most black cockatoo species and in the Goffin's Cockatoo, there is no gender difference in eye color. Young Blue and Gold Macaws have a dark iris that lightens in the first two to three years and then turns yellow as the bird ages. African Grey Parrots have dark muddy-grey irides as young birds, which turn yellowish-grey and then silver as they mature.

Pupillary light reflexes do occur in birds but their interpretation is complicated by the fact that voluntary constriction and dilation of the pupil is possible, even in the absence of retinal stimulation. Clinically, the complete separation of the optic nerves prevents the elicitation of a consensual pupillary light reflex. The irido-corneal angle is well developed in all birds and drains the aqueous fluid, as in mammals. The lens is soft and is almost spherical in nocturnal birds, or has a flattened anterior face in diurnal species including companion birds. An annular pad lies under the lens capsule in the equatorial region, and can be separated from the center of the lens during cataract surgery.





**FIG 26.6** a) In diurnal birds, like this chickadee and most companion birds, the lens has a flattened anterior surface, whereas b) in nocturnal birds, like this Great Horned Owl, the lens is almost spherical. 1) pecten 2) fovea (modified from Martin<sup>46</sup>)

The color of the fundus varies considerably among species; however, all species have a pecten, a comb-like black or brown projection of choroidal tissue that extends into the vitreous (Color 26.35). Recent work has shown that small, regular torsional movements of the eye sweep the pecten through the relatively fluid vitreous. Blood vessels in the pecten disperse a serum filtrate that extends to the peripheral retina.<sup>62</sup> The pecten is thought to provide oxygen and nutrients to the inner portion of the retina. Most species, including Psittaciformes and Passeriformes, have indistinct foveae. Many raptors have one and some diurnal raptors and hummingbirds have two foveae. Macaws have a particularly distinct foveal area that can be evaluated fundoscopically. It is suggested that in bi-foveate birds, one fovea serves for near vision and the other accommodates long-range vision. Birds can distinguish colors and in most cases have excellent visual acuity. Because a bird's sight is so important behaviorally, it is critical that ophthalmologic problems are accurately diagnosed and rapidly resolved.

## Ophthalmic Disorders

### Lids and Periorbita

One of the most common ocular presentations in large psittacine birds is periorbital disease secondary to upper respiratory infection, particularly chronic rhinitis and sinusitis (Figure 26.8) (see Chapter 22). As stated above, the close proximity of the infraorbital sinus to the orbit predisposes it to physical displacement when the sinus diverticulum is enlarged. In some cases, cellulitis or abscessation occur from spread of organisms from the sinus cavity. Antibiotics alone are rarely efficacious in these cases; flushing the sinus and, in some cases, more aggressive surgical debridement is required (see Chapter 41).

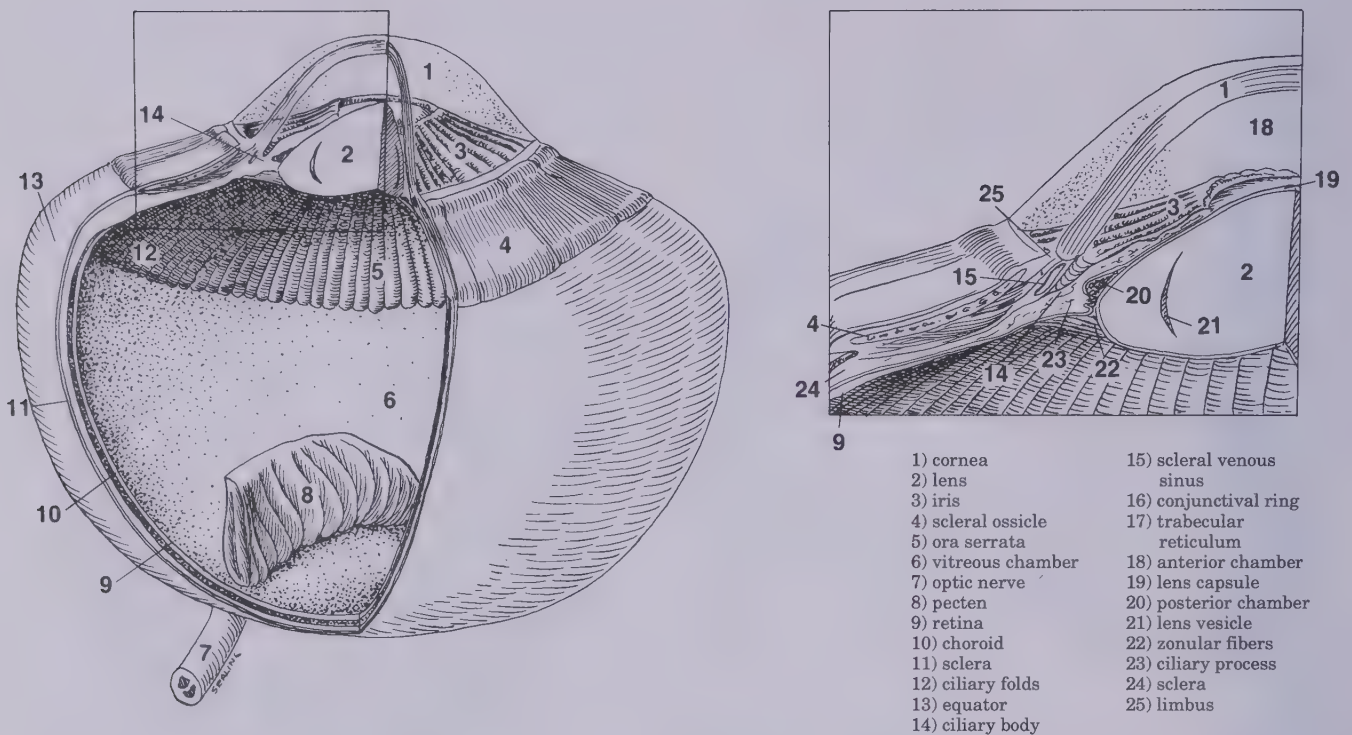


FIG 26.7 Three-dimensional representation of the avian eye; enlarged view of the interior of the eye.




FIG 26.8 An emu (left) was presented with a history of chronic sinusitis. A serous to mucoid oculonasal discharge was noted on physical examination. The sinus was retracted into the skull ("sunken sinus syndrome"). This condition has been most frequently reported in macaws but may also occur with sinusitis in other avian species. Antibiotics were curative (see Chapter 22). A normal emu (right) is shown for comparison (courtesy of Tom Tully).

### Poxvirus

Avian poxvirus may cause lesions in or around the eyes in a number of species (see Chapter 32). The initial changes include a mild, predominantly unilateral blepharitis with eyelid edema and serous discharge starting about 10 to 14 days post-infection

(Color 26.8). As the disease progresses, ulcerative lesions on the lid margins and at the medial or lateral canthus develop; these can become secondarily infected, giving rise to a mucopurulent discharge and transient ankyloblepharon (Color 26.9). The lids be-

come sealed shut with a caseous plug or with dry crusty scabs, which fall off within two weeks.<sup>50</sup>

Clinical lesions provide a tentative diagnosis. An infection can be confirmed through histopathologic identification of eosinophilic intracytoplasmic inclusion bodies (Bollinger bodies) in scabs or scrapings of periocular ulcers.<sup>27,34</sup>

Poxvirus infections may cause keratitis and, less commonly, anterior uveitis. The keratitis can be mild with corneal clouding or severe with ulceration that progresses to panophthalmitis and rupture of the globe. Keratitis may lead to permanent corneal lid scarring. Cicatricial changes in the lid margins can lead to entropion, ankyloblepharon or deformities of the lid edge, resulting in keratitis from corneal abrasion or environmental exposure. These patients may need corrective surgery (lid retraction) or can be placed on life-long therapy with ocular lubricants.

Many affected psittacine birds, particularly Amazons, pionus parrots and mynah birds, have residual problems that cause more important pathology than the primary ocular and periocular lesions. In one study, 46% of the Amazon parrots and pionus parrots with poxvirus had post-infection ocular abnormalities.<sup>35</sup> Eyelid and corneal lesions are most severe if poxvirus lesions are secondarily infected with bacteria or fungus. Treatment of poxvirus lesions should include topical antibiotic ophthalmic ointments to reduce the incidence of these sequelae. Systemic antibiotics may also be required in severely affected birds. Early eye lesions should be flushed with dilute antiseptic solutions. Once scabs have formed they should not be removed. It may be beneficial to soften scabs with hot or cold compresses soaked in nonirritating baby shampoo. It has been reported that prophylactic vitamin A supplementation of exposed birds decreases the severity of infection<sup>36</sup> (see Chapter 18). The importance of subclinical hypovitaminosis A in the progression of the disease has not been determined.

### Hypovitaminosis A

Hypovitaminosis A is less prevalent today than a decade ago; however, it may still be seen as a complicating factor in ocular diseases. Xerophthalmia is said to be the classic sign of hypovitaminosis A in many avian species, but the most common ocular change in psittacine birds is mild periorbital and conjunctival swelling with some discharge (Color 26.14). These signs can be subtle. Hypovitaminosis A

should be considered in cases of unexplained ocular discharge or swelling.

Nasal discharge, sneezing, crusted nares, dry oral membranes and palatine and choanal abscesses are highly suggestive of primary hypovitaminosis A, particularly in Amazon parrots. Response to injectable vitamin A or oral beta carotene supplementation suggests the involvement of a deficiency in the disease process.<sup>42,63</sup>

### Lovebird Eye Disease

A severe and often fatal systemic disease with periocular lesions as the presenting sign has been reported in lovebirds. Generalized depression is accompanied by blepharitis and serous ocular discharge, followed by hyperemia and edema of the periorbital area with a mucopurulent ocular discharge. Affected birds are often attacked by enclosure mates and usually die within a few days of the onset of ocular signs. The disease is most commonly seen in the Peach-faced mutations, and it is in these birds that the lesions are most severe.

No definitive isolation of an infectious agent has been achieved, but an adenovirus-like particle has been demonstrated in renal tissue by electron microscopy. Conjunctival inclusions have been found in some affected birds.<sup>32,36</sup> The histologic lesions reported in one case included proliferative inflammatory reaction of the subconjunctival tissue with lymphoid cell infiltration and concurrent atrophic changes in conjunctival epithelium. Conjunctival edema with minimal cellular infiltrates were characteristic in other cases. The disease occurs most frequently immediately after shipping or introduction into a new aviary, suggesting that stress may be involved in initiating pathologic changes. Symptomatic therapy that includes isolation of affected birds in a stress-free environment and administration of antibiotics has been suggested.

### CLINICAL APPLICATIONS

- Sinusitis frequently causes ocular disease because of the close proximity of the infraorbital sinuses and the globe.
- Hypovitaminosis A may cause mild periorbital swelling.
- Lacrimal sac masses present as mobile swellings anteroventral to the medial canthus.
- Pupillary light reflexes are difficult to interpret because birds can voluntarily constrict and dilate the pupil.

## Ophthalmology

### Color 26.1

A three-month-old Blue and Gold Macaw was presented with a two-week history of serous nasal discharge. Note the accumulation of debris on the feathers of the face. The nictitating membrane, which moves over the cornea during blinking and in the menace response, is normal. This bird's rhinitis was caused by exposure to cigarette smoke.

### Color 26.2

An Umbrella Cockatoo was presented with a two-month history of unilateral discharge. Note the moist, discolored feathers on the face. The nasolacrimal duct in this bird was occluded and was opened by repeated flushing with warm, sterile saline.

### Color 26.3

Depression and hyperemia of the face and eyelids in a gallinaceous bird with sinusitis and pneumonia.

### Color 26.4

Periocular dermatitis in an Amazon parrot from southern Florida. These lesions, frequently encountered in birds in outdoor aviaries, are believed to be caused by biting insects.

### Color 26.5

a) Gross proliferative lesions caused by *Knemidokoptes* sp. infection in a budgeri-

gar. b) *Knemidocoptes* spp. are most frequently associated with beak and cere lesions but can also cause lesions in the peri-orbital tissues (courtesy of the Unit for Continuing Veterinary Education in London and John E. Cooper).

### Color 26.6

A mature cockatiel was presented for diarrhea and weight loss of five days' duration. The bird had partial paresis of the eyelid, mild conjunctivitis and was unable to bite. Partially hulled seeds were common in the bottom of the enclosure. *Giardia* spp. were detected in a fecal smear. The bird responded to treatment with metronidazole and vitamin E.

### Color 26.7

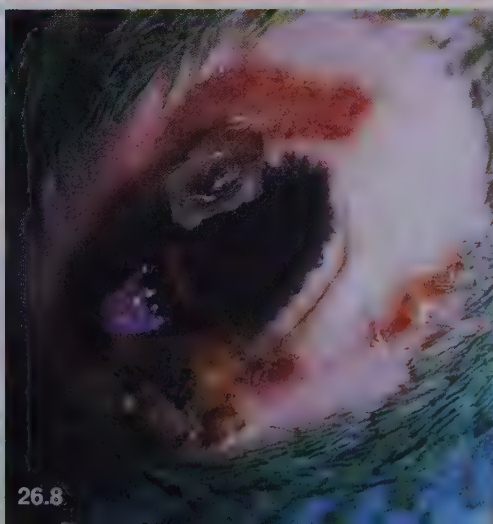


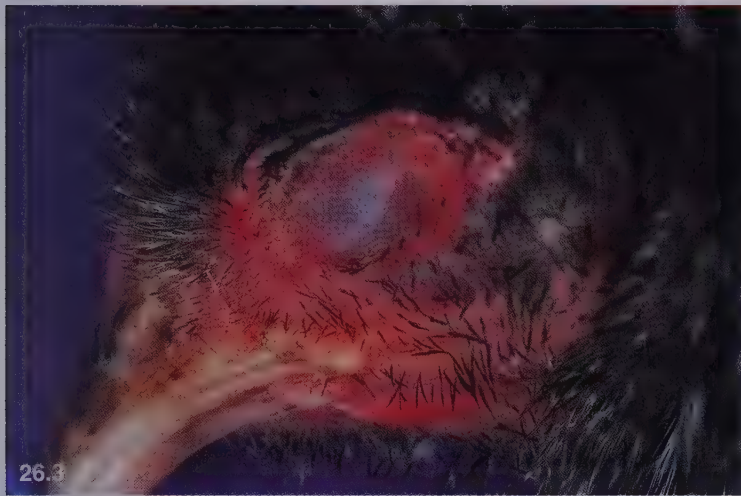

An Amazon parrot with a transient peri-orbital sinus inflation. This inflation is believed to be secondary to stressful events and is not indicative of a pathologic problem.

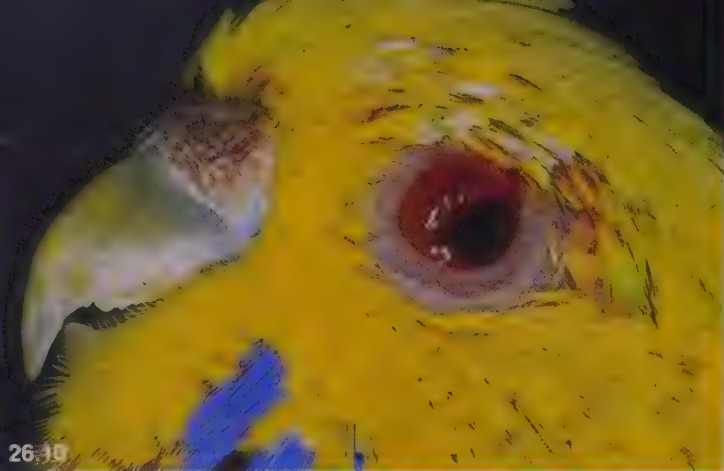
### Color 26.8

Scarring of the palpebral margin secondary to a poxvirus infection (courtesy of David Williams).

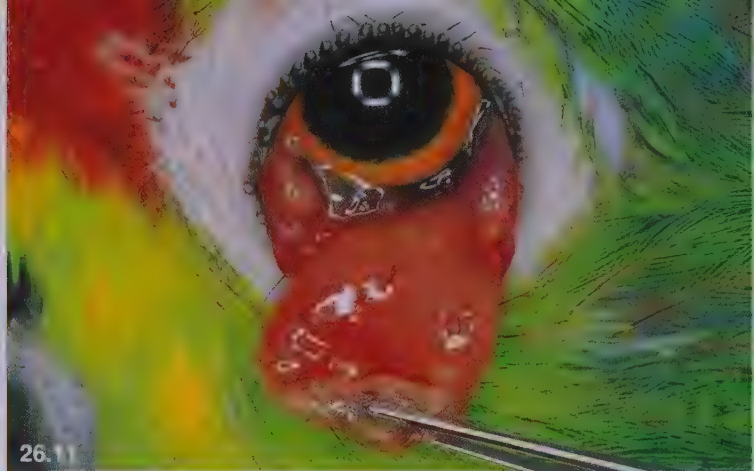
### Color 26.9

Poxvirus in a canary (courtesy of Louise Bauck).

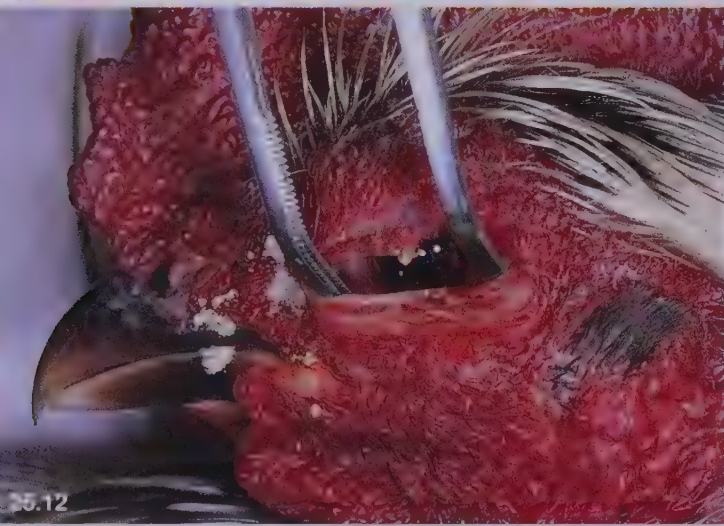



26.10



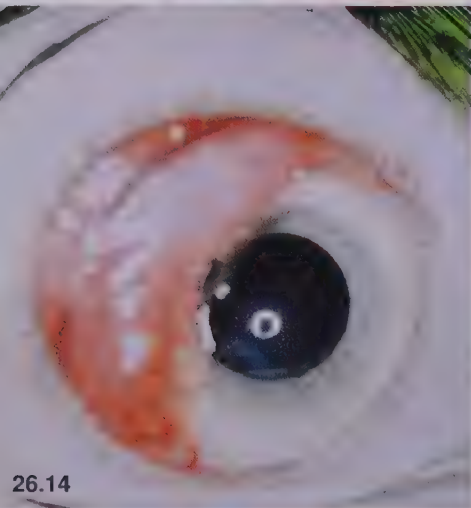26.11



26.12



26.13



26.14



26.15



26.16



26.17



26.18

## Ophthalmology

### Color 26.10

A budgerigar with conjunctivitis, epiphora and chemosis of seven to ten days' duration. The etiology is unknown but the clinical presentation is similar to that described with conjunctivitis in cockatiels. In this case, topical application of enrofloxacin resolved the chemosis within four days (courtesy of R. Korbel).

### Color 26.11

Subconjunctival granuloma in an Amazon parrot. Chemotic conjunctivitis in this bird was not ameliorated with topical or systemic tetracycline and enrofloxacin treatment. Ziehl-Neelsen staining of the granulomatous conjunctival tissue revealed *Mycobacterium* spp. The conjunctiva was surgically removed (courtesy of R. Korbel).

### Color 26.12

An adult *Arcuna* was presented with a two-week history of progressive depression and weight loss. The bird had a bilateral, serous ocular discharge and preferred to keep the eyes shut. *Thelazia* spp. were noted on physical examination. The bulk of the nematodes was removed with copious flushing (LRS), and the bird was successfully treated with topical ivermectin.

### Color 26.13

Conjunctivitis in an ostrich caused by flukes (*Philophthalmus* sp.). This bird was housed in an area that contained a water-fowl pond. Most infected birds are housed in low-lying, damp areas.

### Color 26.14

Hypovitaminosis A in psittacine birds can cause dysplastic lacrimal gland lesions (courtesy of David Williams).

### Color 26.15

Cockatiel conjunctivitis frequently responds to therapy with tetracyclines (courtesy of Louise Bauck).

### Color 26.16

Infraorbital sinusitis in a 2.5-year-old Indian Hill Mynah. Surgical removal of caseous masses followed by treatment with enrofloxacin and vitamin A successfully resolved the lesion (courtesy of R. Korbel).

### Color 26.17

A four-year-old female budgerigar was presented with a three-week history of progressive ocular swelling and ataxia. The bird died shortly after presentation. Abscesses present in the infraorbital sinuses also involved portions of the calvarium.

### Color 26.18

An eight-year-old African Grey Parrot was presented with a twelve-day history of progressive upper respiratory disease. This was the only companion bird in the household, but the bird had been boarded at a pet retailer two months before the onset of clinical signs. The client also had a flu-like disease. Chlamydia was detected by using a fecal antigen test, and the bird responded to doxycycline therapy. Note the rhinolith in the left naris.

*Pasteurella* spp. septicemia and gram-positive cocci have been associated with conjunctivitis in lovebirds. A poxvirus has been described in Masked and Peach-faced Lovebirds.<sup>43</sup>

### Periorbital and Orbital Abscesses

Periorbital disease with exophthalmos or strabismus is most likely to be caused by an abscess of the orbit or lacrimal gland. In some cases, periorbital neoplasia, either primary or secondary, can cause similar clinical changes. Periorbital abscesses generally result from chronic upper respiratory tract infection and sinusitis. They are most often seen in cockatiels, and can occur in any position in the orbit (Color 26.11). Early treatment of sinusitis reduces the incidence of these lesions. Surgical debridement of the abscesses with concomitant systemic antibiotics is the only effective treatment. Lacrimal sac abscesses must be differentiated from periorbital abscesses. The lacrimal sac masses present as mobile swellings at, or immediately anteroventral to, the medial canthus. Early dacryocystitis can sometimes be treated by expressing the inflammatory debris through the lacrimal punctum. More severe cases with firm, necrotic debris require cannulation and regular flushing with antibiotic solutions as dictated by bacteriologic culture and sensitivity. Surgical removal is not recommended because of the potential for scarring and long-term nasolacrimal drainage problems.

### Periorbital Swelling of Neoplastic Origin

Any primary tumor arising in the periorbital or retrobulbar area can cause swelling with or without globe displacement.<sup>7</sup> The periorbital area in birds appears to be a particularly common area for cutaneous manifestations of lymphoreticular neoplasia,<sup>13</sup> represented clinically by periorbital swelling, globe displacement and feather loss.<sup>61,65</sup> Exophthalmia or posteriorly directed strabismus may be noted.

Exophthalmos and globe deviation have been reported secondary to optic nerve glioma, orbital round cell sarcoma,<sup>2,26</sup> and some advanced cases of pituitary chromophobe tumors in budgerigars.<sup>69</sup> Other less common causes of retrobulbar masses include *Mycobacterium* spp.,<sup>79</sup> *Aspergillus* spp. granulomas and disseminated cryptococcosis.<sup>25</sup>

### Hyperplastic Periocular Lesions

Proliferative and hyperplastic periorbital lesions are most commonly seen in budgerigars and canaries in response to *Knemidokoptes* spp. infections. Pitted or honeycombed, scaly and crusting lesions are easily noted in the periorbital area as well as on the beak,

vent and legs (Color 26.5). The periorbital lesions seldom cause problems even though they may be quite severe. Ivermectin can be used topically.

A potential differential diagnosis would include vitamin A deficiency, which can lead to periorbital epithelial hyperplasia and hyperkeratosis, but hypovitaminosis A lesions rarely achieve the size or proliferative extent seen with *knemidokoptes*. Periorbital papilloma-like virus infection in an African Grey Parrot resulted in hyperplastic parakeratotic epithelial proliferations.<sup>33</sup> Other periorbital papillomas have been described without viral isolation.

### Other Periocular Dermatoses


Any dermatosis (eg, allergic, bacterial, fungal) can potentially affect the periorbital skin and occur in the periorbital region (Color 26.19). It should be noted that many periorbital dermal lesions appear to be exceptionally pruritic and that self-trauma can complicate the initial lesions.

### Congenital Deformities

Although rare in birds, congenital eyelid abnormalities do occur and are a surgical challenge to correct. Partial agenesis of the upper eyelid, which was surgically corrected by creating a new lateral canthus at the point at which normal upper eyelid would be found, has been reported in a raptor.<sup>37</sup>

Cryptophthalmos (fusion of the eyelid margins) has been reported in four cockatiels<sup>11</sup> in which dramatically reduced or absent palpebral fissures were described without other ocular abnormalities (Color 26.20). Reconstructive surgery was uniformly unsuccessful. Behaviorally, the birds appeared normal because some vision was possible through one or both eyes. Corneal dermoids have been reported in one goose, in which feathers grew out of the aberrant dermal tissue on the lateral aspect of the globe.<sup>12</sup> Microphthalmia and maldevelopment of ciliary body, retina and pecten, as well as retinal dysplasias and congenital cataracts have been described in raptors.<sup>10</sup> The lacrimal ducts did not drain properly in an Umbrella Cockatoo with choanal atresia, resulting in a chronic ocular discharge (Figure 26.9). Ectropion with secondary exposure keratitis has been seen in cockatiels. This lesion can be resolved with a lateral canthoplasty (see Chapter 41).





**FIG 26.9** A mature Umbrella Cockatoo was presented with a life-long history of ocular nasal discharge. Physical examination indicated the lack of a choanal slit and an abnormally formed infundibular cleft, preventing normal lacrimal drainage. The periorbital tissue was moistened with a serous ocular and nasal discharge. Note the bubbles in the ocular fluids suggesting that air was exiting the lacrimal duct.

## Conjunctiva

### Differential Diagnosis of Conjunctivitis

Conjunctivitis can be classified clinically into three groups. The first are those caused by strictly local factors, such as localized conjunctival infection or foreign bodies. The second are those in which conjunctivitis is a manifestation of periorbital or orbital disease. These are mainly related to sinusitis (see Chapter 22). The third group are those in which conjunctival hyperemia is caused by a septicemia. Almost any organism causing systemic infection can result in conjunctivitis. A careful examination of the bird for upper respiratory disease is mandatory in determining the cause of ocular discharge or conjunctival hyperemia (Color 26.10). Exposure to cigarette smoke, chemical fumes and other aerosolized environmental toxins should always be considered in the differential diagnosis of conjunctivitis, with or without signs of upper respiratory disease.

Various infectious agents have been implicated in conjunctivitis, but mere isolation of a bacteria or protozoan does not imply that it is the cause of the disease. The conjunctival flora of captive exotic birds has been surveyed (Table 26.1).<sup>80</sup> Bacteria was isolated from the upper conjunctival fornix of 71% of the psittacine birds tested. *Staphylococcus* spp. or *Corynebacterium* spp. were isolated from 86% of the birds. Gram-negative bacteria were recovered from 14%

and fungi, from 9% of these clinically normal birds. In another study, 41% of ocular samples were sterile and 50% of the isolates were gram-positive cocci.<sup>82</sup>

**TABLE 26.1** Avian Conjunctival Flora

Family	Gram + Isolates	Gram- Isolates	Fungal Isolates
Anseriformes	36/68 (56%)	30/68 (44%)	2/27 (11%)
Coraciiformes	3/3 (100%)	0/3 (0%)	0/2 (0%)
Falconiformes	17/18 (94%)	1/18 (6%)	4/11 (36%)
Piciformes	6/7 (86%)	1/7 (14%)	1/5 (20%)
Psittaciformes	44/51 (86%)	7/51 (14%)	5/55 (9%)
Rheiformes	6/18 (33%)	12/18 (67%)	2/5 (40%)
Falconiformes	17/18 (94%)	1/18 (6%)	4/11 (36%)

Adapted from Wolf DE, et al: J Am Vet Med Assoc 183:1232-1233, 1983.

The incidence of gram-positive, gram-negative and fungal organisms was determined in a group of 117 birds by swabbing the conjunctiva. The birds sampled were clinically asymptomatic and were housed in zoos or pet shops. *Staphylococcus* spp. or *Corynebacterium* spp. were recovered from 85 of 97 birds in which bacterial organisms were recovered. *Chlamydia* spp. was not identified by cytologic evaluation of conjunctival scrapings in any of the birds.

In one study of domestic ducks, *E. coli* was isolated from the eyes of a majority of clinically asymptomatic ducklings, suggesting that neonatal conjunctival flora are derived from intestinal flora (Color 26.24).<sup>16</sup> The isolation of gram-negative bacteria from the eye or conjunctiva should be considered abnormal except in Anseriformes and Rheiformes, where gram-negative bacteria are considered autochthonous flora. *Haemophilus*-like bacteria have been reported to cause conjunctivitis in cockatiels.<sup>19</sup>

*Chlamydia psittaci* is a frequent cause of keratoconjunctivitis in Australian parakeets<sup>23</sup> and of conjunctivitis without other signs in pigeons and finches. In these cases, treatment with topical oxytetracycline is effective. Clinical chlamydiosis in Psittaciformes is generally associated with conjunctivitis, diarrhea and polyuria.

*Mycoplasma* spp. are important causes of conjunctivitis in pigeons and are suspected in many cases of conjunctivitis in cockatiels. Ocular discharge and conjunctivitis may be the only presenting signs. Other affected birds may develop rales, nasal discharge and sneezing. Unilateral conjunctivitis (one-eyed cold) in pigeons is frequently associated with mycoplasma but can also be caused by chlamydia or salmonella.

Cryptosporidial conjunctivitis has been described in pheasants<sup>66</sup> and ducks.<sup>48</sup> A case of blepharitis and conjunctivitis in a goose yielded *Actinobacillus suis*,<sup>45</sup> while *Mycobacterium avium* was isolated from a conjunctival granuloma in an ostrich.<sup>31</sup>

The presence of foreign bodies in the fornix, or behind the third eyelid, may be a cause of conjunctival irritation and should be suspected in cases of unilateral conjunctivitis that are not responsive to antibiotics. In one study, 7% of the free-ranging Red-shouldered Hawks had grass florets lodged behind the third eyelid.<sup>49</sup> In companion birds, millet seeds, seed husks and feathers have been associated with a foreign body conjunctivitis.

### Cockatiel Conjunctivitis

Cockatiels are frequently presented with a conjunctivitis from which no infectious agent can be isolated. Clinical signs involve blepharitis and serous ocular discharge, progressing to conjunctival chemosis and inflammation with hyperemic conjunctiva protruding in front of the eye. These signs are seen much more frequently in white or albino mutations than in birds of normal gray color (Color 26.15).

The lesions are often associated with upper respiratory tract infection, and *Mycoplasma* spp. and *Chlamydia* spp. have been suggested as agents. Isolating mycoplasma requires specialized techniques, and diagnostic samples should be sent in specific media to qualified laboratories. Many cockatiels with conjunctivitis are not systemically positive for *Chlamydia* spp., shedding some doubt on the importance of this organism in the cockatiel syndrome.<sup>3</sup>

Treatment with topical antibiotics often ameliorates the signs but recurrences are common. Systemic tetracycline is often curative but should be combined with symptomatic treatment of the inflamed periorbital area. Antibiotic ophthalmic ointments may be used or the eyes can be sprayed with tylosin (1:10 dilution in sterile water) or lincomycin and spectinomycin. The problem seems to follow familial lines, suggesting that affected birds should not be used in breeding programs. In some cockatiels, the conjunctivitis is associated with partial lid paresis and reduced jaw tone (Color 26.20). Many of these birds have giardiasis and respond to treatment with metronidazole and vitamin E. A similar condition has been noted in budgerigars, and again, the etiologic agent has yet to be identified.<sup>41</sup>

### Parasitic Conjunctivitis

A number of nematode and trematode parasites can occasionally cause conjunctival irritation in a wide variety of avian species (see Chapter 36). *Oxyuris mansoni* is a nematode that has been associated with conjunctival irritation and pruritus in cockatoos, mynahs and other avian species. This nematode can enter the lacrimal duct and may cause transient epiphora if present in large numbers. Small numbers of nematodes can be manually removed or flushed out of the lower conjunctival sac. Heavy parasite burdens must be treated with a single topical dose of ivermectin.<sup>74</sup> This nematode has an indirect life cycle. Nematode eggs are passed through the nasolacrimal duct, swallowed and passed in the feces, where they are consumed by cockroaches (*Pycnoscellus* spp.). When a bird eats the cockroach, the mature nematode larvae escape into the crop, move up the esophagus and enter the nasolacrimal duct to reach the eye. Companion birds maintained in indoor environments are less likely to be infected. *Thelazia* spp. are reported to cause conjunctivitis in birds but are more common in mammals (Color 26.12).<sup>8</sup>

Trematode flukes of the genus *Philophthalmus* have been reported as a cause of conjunctivitis in many avian species (Color 26.13). The degree of irritation was sufficient in one group of ostriches to cause the birds to show persistent lacrimation, irritation and loss of condition. Repeated applications of topical carbamate powder eliminated the flukes.<sup>29</sup>

## Cornea

### Treating Corneal Ulcers and Keratitis

Most corneal problems seen in Psittaciformes are epithelial erosions secondary to trauma or keratitis secondary to lid abnormalities. Fluorescein dye will stain denuded stroma indicating the presence of an ulcer. In subtle lesions such as Amazon punctate keratitis, an ultraviolet Wood's lamp can be used to augment the detection of fluorescein retention. Keratitis can be difficult to resolve, but, as a rule, topical antibiotics and corneal bandaging techniques provide a sterile environment and time for corneal epithelium to heal (Color 26.22). By extrapolation from other species, anticollagenases should be used in deep ulcers, especially in hotter climates, where corneal melting may be a cause of rupture of the globe. Acetylcysteine can be applied by spray every few hours without having to restrain the bird. A temporary tarsorrhaphy created by placing one or two horizontal mattress sutures of 4-0 or 6-0 nylon

provides a corneal “bandage.” This is preferable to a third eyelid flap because the muscular action moving the third eyelid can cause the suture to pull through. The use of a hydrated collagen shield to provide a medicated corneal bandage has not been reported in birds but may be useful in selected cases. Chronic corneal erosions may occur in older birds. To provide a suitable surface for reattachment of the epithelium, devitalized epithelium can be removed with a dry cotton-tipped applicator or by using a punctate or grid keratotomy.

### Mynah Bird Keratitis

Corneal erosions may be noted secondary to capture and transport in many imported companion birds. The majority of these heal by corneal epithelial migration within 48 hours. Mynahs appear to be especially prone to handling-related keratitis. In one study, 96% of birds examined immediately after shipping were found to have corneal scratches.<sup>36</sup> Blepharospasm or some degree of conjunctival hyperemia is a characteristic finding. Many of these lesions regress spontaneously in a few weeks, but some may lead to corneal scarring and permanent opacity. Some birds develop a chronic keratoconjunctivitis with conjunctival masses, severe geographic corneal ulceration and corneal vascularization. Systemic aspergillosis is found in many chronically affected birds, suggesting an immunosuppressed condition. Acyclovir-responsive herpesvirus lesions have been suggested as complicating factors in some affected birds.

### Amazon Punctate Keratitis

A transient keratitis with a characteristic subtle punctate appearance has been reported in Central American Amazon parrots. Lesions are bilateral, and the presenting signs are normally blepharospasm and a clear ocular discharge. The keratitis normally starts in the medial cornea. In 50% of the birds, lesions progress to cover the cornea but resolve generally within one to two weeks. The lesions are transiently fluorescein-positive. A small minority of birds develop more serious lesions with deep corneal ulceration and anterior uveitis, manifesting either as a flare and “muddiness” of the iris or as a more severe inflammation with fibrin clots and synechiae (Color 26.27). Some birds develop concomitant sinusitis. The use of topical antibiotics or antivirals has not been found to significantly alter the outcome of the disease.<sup>36</sup>

Amazon parrots from northern South America have also been reported with a chronic keratitis. There are

fewer cases reported in this group of birds, but the incidence of long-term corneal scarring is higher.

Treatment of more severely affected birds, such as those with intraocular lesions, includes topical and systemic antibiotics. Topical corticosteroid to control intraocular inflammation can reduce the healing of concurrent corneal ulceration; topical non-steroidal anti-inflammatories such as indomethacin or flurbiprofen may be more appropriate in these cases.


### Uvea

Uveitis in raptors is most commonly seen as a sequel to intraocular trauma<sup>57</sup> and is characterized by aqueous flare, hypopyon and fibrin clots in the anterior chamber, iridal hemorrhages or gross hyphema. The latter was reported to be the most common ophthalmologic finding in injured raptors in one survey.<sup>58</sup> Uveitis can occur following rupture of the crystalline lens<sup>1,54</sup> or secondary to severe extraocular disease in conditions such as poxvirus infection. One case of bilateral intraocular inflammation with concomitant staphylococcus septicemia in a lovebird has been reported.<sup>6</sup> Uveitis has been reported in psittacine birds with reovirus infection in which histopathologic changes suggested disseminated intravascular coagulopathy. Hypopyon and hemorrhage, sometimes with fixed dilated pupils (atypical for uveitis where miosis is more common), are characteristic ocular signs. Birds that recover may have synechiae (Color 26.28).<sup>17</sup>

Clinical signs of uveitis vary, reflecting the diversity of inflammatory states in the eye. Active inflammation may be mild, with increased levels of aqueous proteins causing a flare that reduces the clarity of iris detail and pupil margin. More severe cases may be characterized by accumulation of pus or hemorrhage in the anterior chamber. Subtle signs including a darkened iris or more obvious lesions including posterior synechiae or organized fibrin clots in the anterior chamber suggest a past episode of anterior segment inflammation. Glaucoma is seen secondary to traumatic uveitis in raptors,<sup>58</sup> and has been diagnosed without concurrent ocular disease in a canary. If the eye appears painful, enucleation or evisceration is the only treatment (Figure 26.10) (see Chapter 41).

### Lens

Cataract and lens luxation can occur in birds. Both conditions can be treated surgically in suitable cases. Cataracts are seen relatively frequently<sup>39</sup> and have a



**FIG 26.10** Although evisceration or enucleation can be disfiguring, these procedures may be life-saving in cases of severe infections or neoplasms.

wide variety of causes, although in the majority of cases the etiology is unknown. Senile cataracts have been described in macaws (Color 26.30).<sup>18</sup>

There is clear evidence for familial cataracts in Yorkshire and Norwich Canaries (Color 26.31).<sup>72</sup> A fully penetrant autosomal recessive gene is responsible for the condition. In affected canaries, the cataracts were mature with lens-induced uveitis and posterior synechiae formation (Color 26.32). In one affected bird, lens resorption had taken place. Lens removal by the irrigation-aspiration technique was unsuccessful in these birds. Patients requiring cataract removal should be referred to a veterinary ophthalmologist.

Because of the small size of the avian eye, conventional extracapsular cataract extraction techniques are generally difficult. In small birds, soft lenses can be removed through a 26 ga needle. Phacoemulsification is the technique of choice for avian cataract removal in patients with eyes large enough to accommodate the phacoemulsification probe.<sup>38</sup> The extracapsular technique can be used in intumescent or resorbing cataracts where the lens material can be aspirated or flushed from the anterior chamber (Color 26.33).<sup>55</sup> An intracapsular technique has been used for removal of an anteriorly luxated lens in an owl.<sup>9</sup> In eight aging macaws with senile cataracts, the lens was disrupted and removed with an irrigation aspiration technique, resulting in vision in 77% of the eyes.<sup>18</sup> Post-operative treatment with 17% maxitrol was considered an indispensable part of the therapy. Topical medications, particularly steroids, must be applied cautiously to small birds to prevent intoxication.

Trauma in wild raptors is likely to be a frequent cause for lenticular opacification, and because other intraocular damage may be present, care should be taken in assessing the bird for cataract surgery (Color 26.34). Assessment should include full evaluation of the bird physically, neurologically and, of course, ophthalmoscopically. Ideally, ultrasonic evaluation of the posterior segment should be made to avoid operating on an eye with a concurrent retinal detachment. An electroretinogram gives useful data on retinal function and is suggested prior to surgery in some cases.<sup>30</sup>

## Miscellaneous Eye Conditions

### Retinal Diseases

The difficulties in examining the posterior segment of the avian eye, especially in small companion birds, have delayed investigations into retinal disease in these species. The pioneering work of Casey Wood in the early part of this century on the normal avian fundus has not been surpassed even with the advances in ophthalmoscopic instrumentation and the growing interest in avian ophthalmology.<sup>81</sup>

Nevertheless, some reports of retinal disease in birds have found their way into the literature. Wood himself noted a high prevalence of posterior segment inflammatory lesions in captive raptors, and other authors have confirmed his findings.<sup>28,56,58</sup> Lesions include pigmentary deposits on the otherwise unpigmented peripheral retina, focal scarring, pre-retinal membranes, vitreal opacities and gross inflammatory disease of the entire posterior segment (Color 26.35). Many of these lesions in free-ranging birds may be caused by trauma with hemorrhage that causes vitreal scarring and contraction. Posterior segment bleeding may result from choroidal vessels, a damaged ciliary body, or even in some cases, rupture of the pecten.

Toxoplasmosis has been suggested as a cause of retinal lesions in raptors (see Chapter 36). This report, however, was based on identifying seropositive birds in a population where the seroprevalence is unknown.<sup>28</sup> Toxoplasmosis was confirmed as a cause of retinitis and blindness in canaries. Toxoplasmosis was diagnosed in a group of canaries with crusty, ocular lesions, white lesions in the vitreous humor and, in most cases, collapse of the globe. Several of the infected birds had neurologic signs characterized by circling and head tremors. High latex agglutination antibody titers to *T. gondii* were seen in five of the seven affected birds. Histologically, *T. gondii*

tachyzoites were demonstrated in the detached and intact retina, the lens and in exudate in the vitreous humor.<sup>76</sup>

Retinal detachment can occur through trauma, but idiopathic bilateral detachments have been noted in pheasants unassociated with mechanical damage.<sup>67</sup> Retinal dysplasia has been diagnosed in raptors,<sup>21,60</sup> and a retinal degeneration of unknown origin was reported in a parakeet.<sup>75</sup>

### Intraocular Tumors

Intraocular tumors are rare in birds. Malignant intraocular medulloepithelioma has been reported in two-year-old cockatiels in which, after enucleation for presumed bacterial panophthalmitis and orbital cellulitis, tumor masses grew rapidly in the orbit.<sup>70</sup> An intraocular adenocarcinoma has been reported in a budgerigar.<sup>22</sup>

### Neurophthalmology and Central Blindness

Blindness in birds may be caused by opacity of the visual media, retinal lesions or central neurologic disease. In cases where no obvious ocular cause of blindness can be observed, an electroretinogram can be used to differentiate between retinal or central lesions.<sup>47</sup>

Causes of central blindness may include cataracts, neoplasia or encephalitis that may be localized or related to systemic disease. Heavy metal toxicities can result in blindness, but the visual changes are only one of a number of multifocal nervous signs. Space-occupying brain lesions, particularly pituitary

adenomas, can cause visual deficits from pressure being placed on the optic chiasm. One large survey of 50 chromophobe pituitary tumors reported central blindness in a number of birds with associated neurologic and endocrine signs.<sup>4,69</sup>

Defects of cranial nerves III, IV and VI are somewhat difficult to appreciate in birds because there is relatively little torsional movement of the globe within the orbit. Horner's syndrome was suggested as a diagnosis in one bird in which a unilateral ptosis and mild miosis ameliorated by topical phenylephrine was noted.<sup>78</sup>

- **Evaluating the Blind Bird:** Determining if visually defective birds are sound for release can be difficult. Some birds such as owls perform well with one eye, while releasing a one-eyed diurnal falcon to the wild might be considered unwise. Many companion birds can survive remarkably well with little or no vision, as has been noted with cockatiels with cryptophthalmos<sup>11</sup> and Bobwhite Quail with dense bilateral cataracts;<sup>44</sup> however, blindness can be very debilitating in some smaller Passeriformes where flying from perch to perch is behaviorally important.

### Enucleation

Enucleation is frequently necessary in birds because of trauma, non-responsive inflammation or tumors. Enucleation is difficult because of the large size of the avian eye and the tight fit of the globe into the orbit. For further information on enucleation and other ophthalmic surgeries, see Chapter 41.

### References and Suggested Reading

1. Anderson GA, Buyukmihci N: Phacoanaphylactic endophthalmitis in an owl. *Vet Pathol* 20:776-778, 1983.
2. Arnall L: Anaesthesia and surgery in cage and aviary birds. *Vet Rec* 73:188, 1961.
3. Bauck L: Three treatment protocols for cockatiel conjunctivitis. *Proc Assoc Avian Vet*, 1989, pp 92-96.
4. Bauck L: Pituitary neoplastic disease in budgerigars. *Proc 1st Intl Conf Zool & Avian Med, Hawaii*, 1987, pp 87-90.
5. Bellhorn RW: Laboratory animal ophthalmology. In Gelatt KN (ed): *Veterinary Ophthalmology*. Philadelphia, Lea & Febiger, 1981.
6. Bounous DJ, Schaeffer DO, Roy A: Coagulase-negative *Staphylococcus* sp. septicemia in a lovebird. *J Am Vet Med Assoc* 195:1120-1121, 1989.
7. Brightman AH, Burke TJ: Eyelid tumor in a parakeet. *Mod Vet Pract* 59:683, 1978.
8. Brooks DE, Greiner EC, Walsh MT: Conjunctivitis caused by *Thelazia* sp. in a Senegal parrot. *J Am Vet Med Assoc* 183:1305-1306, 1983.
9. Brooks DE, Murphy CJ, Quesenbury KE, Walsh MT: Surgical correction of a luxated cataractous lens in a barred owl. *J Am Vet Med Assoc* 183:1298-1299, 1983.
10. Buyukmihci NC, Murphy CJ, Schulz T: Developmental ocular disease of raptors. *J Wildl Dis* 24:207-213, 1988.
11. Buyukmihci NC, et al: Eyelid malformation in four cockatiels. *J Am Vet Med Assoc* 196:1490-1492, 1990.
12. Busch TJ: Corneal dermoids in a goose. *New Zeal Vet J* 33:189-190, 1985.
13. Campbell TW: Neoplasia. In Harrison GJ, Harrison LR (eds): *Clinical Avian Medicine and Surgery*. Philadelphia, WB Saunders Co, 1986, p 507.
14. Campbell TW: Conjunctival cytology. In Campbell TW: *Avian Hematology and Cytology*. Ames, Iowa State University Press, 1988.
15. Cavill JP: Canary pox: Report of an outbreak in roller canaries (*Serinus canarius*). *Vet Rec* 76:463-465, 1964.
16. Chalmers WSK, Kewley DR: Bacterial flora of clinically normal conjunctivae in the domestic duckling. *Avian Pathol* 14:69-74, 1985.
17. Clubb SL: A multifactorial disease syndrome in African grey parrots (*Psittacus erithacus*) imported from Ghana. *Proc Intl Conf Avian Med*, 1984, pp 135-149.
18. Clubb SL, Karpinski L: Aging in macaws. *Proc Assoc Avian Vet*, 1992, p 85.
19. Devriese LA, Vianene N, Uytendaele E, et al: Three cases of infection by *Haemophilus*-like bacteria in psittacines. *Avian Pathol* 17: 741-744, 1988.
20. Dorrestein GM, van der Hoge MH: Aviculture and veterinary problems in lovebirds. *Proc 1st Intl Conf Zool & Avian Med, Hawaii*, 1987, pp 243-261.
21. Dukes TW, Fox GA: Blindness associated with retinal dysplasia in a prairie falcon (*Falco mexicanus*). *J Wildl Dis* 19:66-69, 1983.
22. Dukes TW, Petit JR: Avian ocular neoplasia - a description of spontaneously occurring cases. *Can J Comp Med* 47:33-36, 1983.
23. Emanuelson S, Carney J, Saito J: Avian pox in two black-masked cunures. *J Am Vet Med Assoc* 173:1249-1250, 1978.
24. Evans HE: *Organa senoria*. In Baumel JJ, et al (eds): *Nomina Anatomica Avium*. London and New York, Academic Press, 1979.
25. Fenwick B, Takeshita K, Wong A: A Moluccan cockatoo with disseminated cryptococcosis. *J Am Vet Med Assoc* 187:1218-1219, 1985.
26. Frost C: Experiences with pet budgerigars. *Vet Rec* 73:623, 1961.
27. Graham CL: Poxvirus infection in a spectacled Amazon parrot (*Amazona albifrons*). *Avian Dis* 22:340-343, 1978.
28. Greenwood AG, Barnett KC: The investigations of visual defects in raptors. In Cooper JE, Greenwood AG (eds): *Advances in the Study of Raptor Diseases*. Keighley, England, Chiron Publications, 1981.
29. Greve JH, Harrison GJ: Conjunctivitis caused by eye flukes in captive-reared ostriches. *J Am Vet Med Assoc* 177:909-910, 1980.
30. Hacker DV, Shifrin M: Cataract extraction in a Mandarin duck. *J Am Anim Hosp Assoc* 24:679-682, 1988.
31. Hood HB: Eye pathology in an adult male ostrich (*Struthio camelus*). *Proc Am Assoc Zoo Vet*, 1978.

## ■ Ophthalmology

### Color 26.19

**a,b)** A mature Sun Conure was presented with an idiopathic occurrence of unilateral periocular hemorrhage. There was no known trauma and clinicopathologic findings were limited to mild anemia (PCV=35). The bird fully recovered and had no further problems.

### Color 26.20

Cryptophthalmos with ankyloblepharon in a two-year-old male cockatiel. Surgery to restore a normal palpebral aperture was unsuccessful (courtesy of N. Buyukmihci).

### Color 26.21

Snowy Owl with ulcer and corneal calcification caused by trauma. A punctate or grid keratotomy to restore normal epithelization would be indicated (courtesy of K.C. Barnett).

### Color 26.22

Fungal keratopathy in an ostrich secondary to sand contamination of the eye. A third eyelid flap was attempted but the sutures failed because of the muscular action of the nictitating membrane. The bird responded to treatment with topical ketoconazole (courtesy of S. West).

### Color 26.23

Corneal ulceration and globe collapse from unknown etiology in a seagull. The eye was enucleated.

### Color 26.24

Conjunctivitis in a farm duck. Culture yielded *Acinetobacter* sp. and the lesions resolved using topical chloramphenicol ointment.

### Color 26.25

Luxation of the lens and uveitis in an owl that was hit by a car. Luxation of the lens may cause an increase in intraocular pressure that must be resolved with an intracapsular lensectomy. Topical steroids were effective in controlling the uveitis in this case (courtesy of S. West).

### Color 26.26

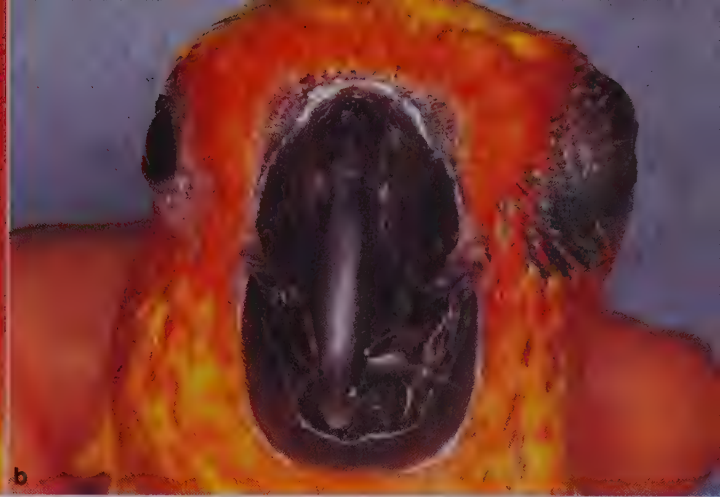Keratic precipitates on the posterior cornea of a Screech Owl with phacolytic uveitis and bilateral cataracts (courtesy of S. West).

### Color 26.27


Uveitis and cataract in an Amazon parrot. Note the darkening and “muddy” appearance of the iris. These changes are characteristic of uveitis not complicated by hypopyon (courtesy of Dan Wolf).




26.19a



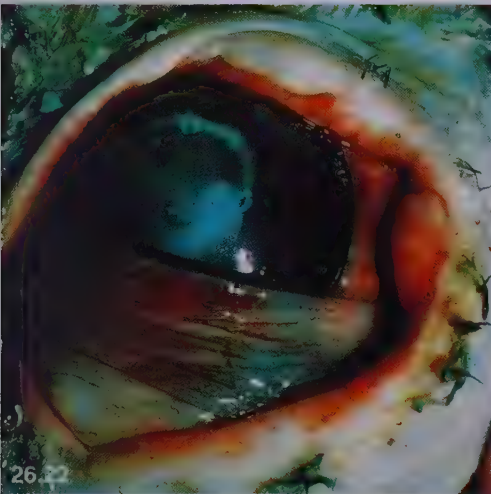
b



26.20



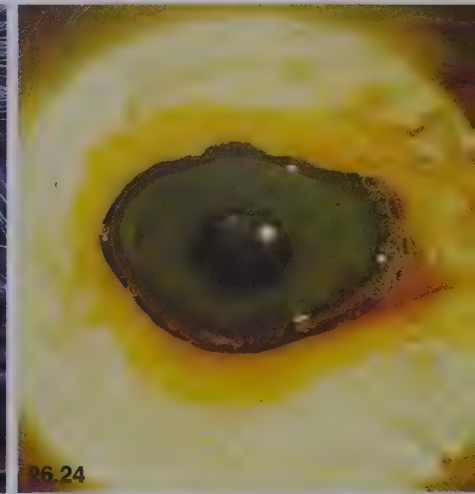
26.21



26.22



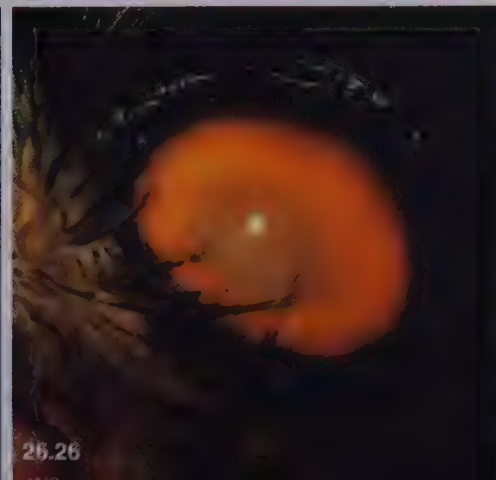
26.23



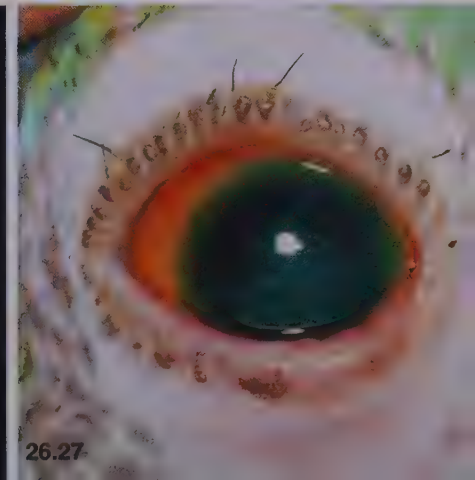26.24



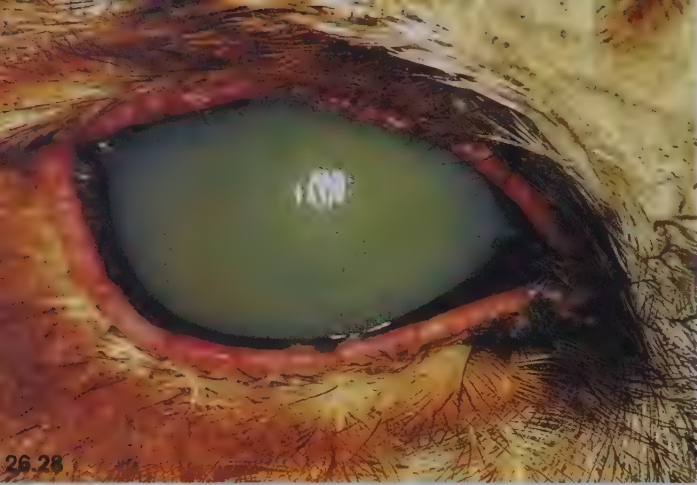
26.25




26.26



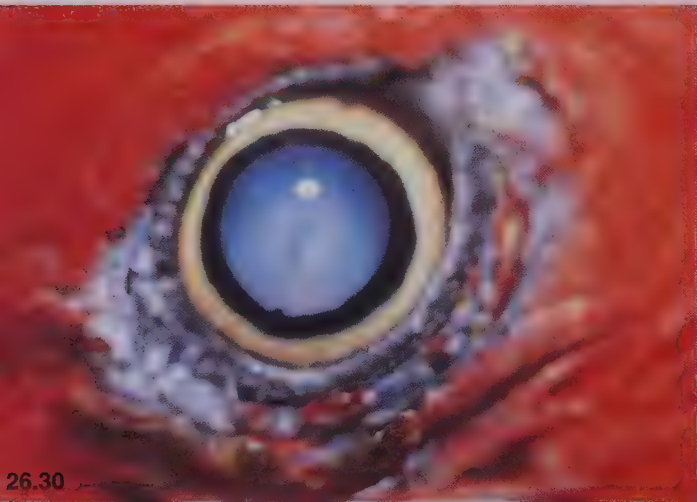26.27



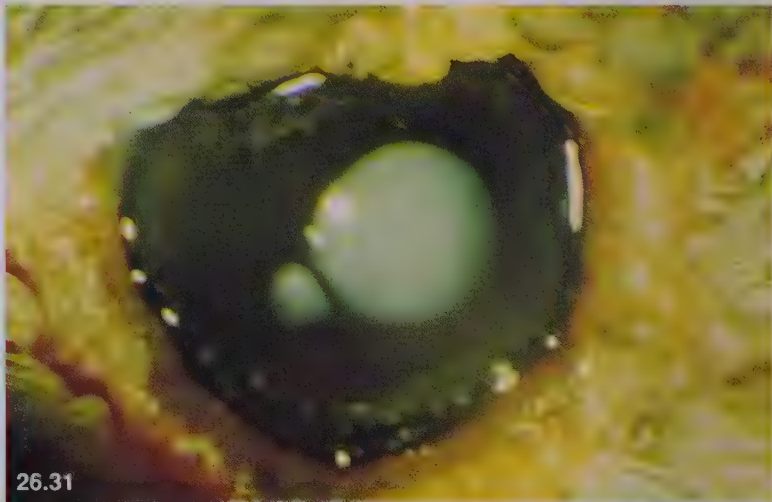
26.28



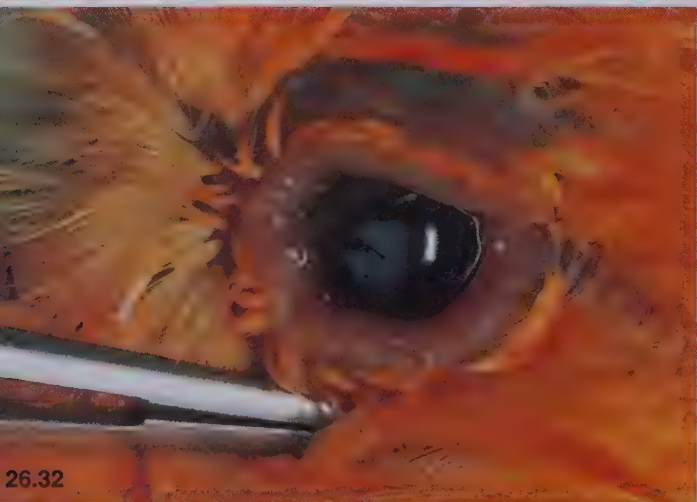26.29



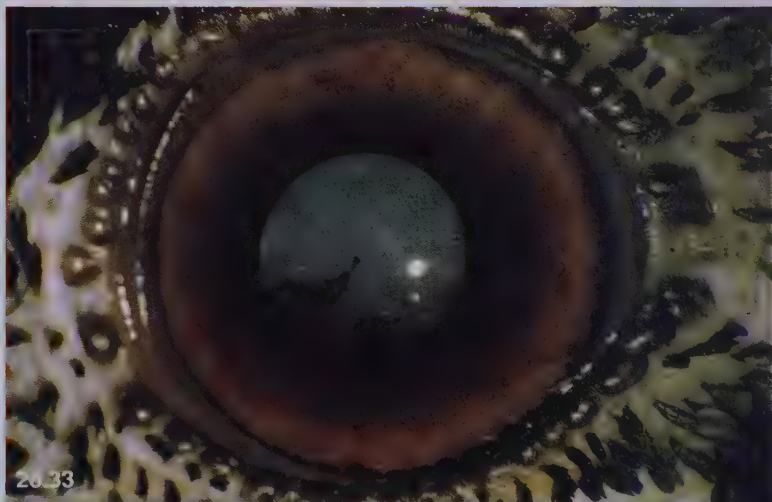
26.30



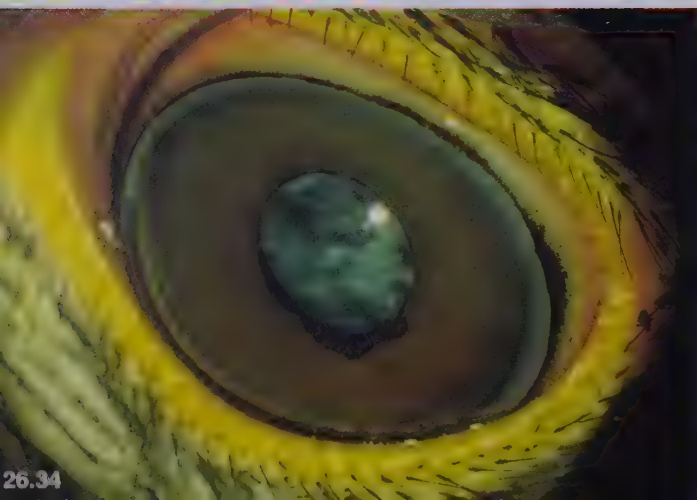26.31



26.32



26.33



26.34



26.35a

b



## Ophthalmology

### Color 26.28

Tawny Owl with uveitis. Examination with a slit lamp showed that the white glistening of the eye was caused by hypopyon and not a corneal lesion. Resolution with topical steroid medication was slow and several synechiae remained. No etiologic agent could be identified (courtesy of David Williams).

### Color 26.29

An adult male cockatiel was presented with a three-week history of ocular discharge and scratching of the face. A severe panophthalmitis was noted on physical examination. The bird's WBC count was 22,000. A conjunctival scraping revealed numerous gram-negative bacteria, both free and within conjunctival cells. The bird was placed on systemic and ophthalmic antibiotics. Cultures indicated *Pseudomonas* spp. The eye did not respond to therapy, and enucleation was performed six days after initial presentation.

### Color 26.30

Cataract in an Eclectus Parrot. The periorbital feather loss is probably secondary to the bird's rubbing the area because of reduced vision in the eye (courtesy of David Williams).

### Color 26.31

Inherited cataract in a Norwich Canary. Note also the polycoria probably sub-

sequent to senile iridal atrophy (courtesy of David Williams).

### Color 26.32

Cataract and posterior synechiae in a thirteen-year-old canary. Phthisis bulbi with wrinkling of the lid margins are also evident (courtesy of R. Korbel).

### Color 26.33

Cataract in a mynah bird with posterior synechiae. In this case, the contralateral eye was unaffected, the bird's behavior was normal and surgical removal of the cataract was not attempted (courtesy of K.C. Barnett).

### Color 26.34

Cataract in a Harris Hawk. Note the scintillating appearance of the cataract, indicating some resorption. The iris ectropion is believed to be a congenital anomaly and not reflective of a uveitis. Extracapsular cataract extraction was performed and the bird regained vision in the eye (courtesy of David Williams).

### Color 26.35

**a)** Normal pecten in an Eagle Owl (courtesy of David Williams). **b)** Gross retinal post-inflammatory scarring in a Tawny Owl. It has been suggested, but not confirmed, that this scarring may be a result of toxoplasmosis (courtesy of K.C. Barnett).

32. **Jacobson ER, Gardiner C, Clubb S:** Adenovirus-like infection in white-masked lovebirds (*Agapornis personata*). *J Assoc Avian Vet* 1:32-34, 1989.
33. **Jacobson ER, et al:** Papilloma-like virus infection in an African grey parrot. *J Am Vet Med Assoc* 183:1307-1308, 1983.
34. **Johnson BJ, Castro AE:** Canary pox causing high mortality in an aviary. *J Am Vet Med Assoc* 189:1345, 1986.
35. **Karpinski LG, Clubb SL:** Post pox ocular problems in blue-fronted and blue-headed pions parrots. *Proc Assoc Avian Vet*, 1985, p 91.
36. **Karpinski LG, Clubb SL:** Clinical aspects of ophthalmology in caged birds. In Kirk RW (ed): *Current Veterinary Therapy IX*. Philadelphia, WB Saunders Co, 1986, pp 616-621.
37. **Kern TJ, Murphy CJ, Heck WR:** Partial upper eyelid agenesis in a peregrine falcon. *J Am Vet Med Assoc* 187:1207, 1985.
38. **Kern TJ, Murphy CJ, Riis RC:** Lens extraction by phacoemulsification in two raptors. *J Am Vet Med Assoc* 185:1403-1406, 1984.
39. **Keymer IF:** Cataracts in birds. *Avian Pathol* 6:335-341, 1977.
40. **Korbel R:** Tonometrie am Vogelauge. III. DVG-Tagung Vogelkrht, München, 1992.
41. **Korbel R, Schäffer EH:** Zum Vorkommen einer konjunktivitis unbekannter Ätiologie bei Wellensittichen (*Melopsittacus undulatus* Shaw, 1805). [Conjunctivitis of unknown pathogenesis in budgeridgars.] *Tierärztl Prax* 19: 659-663, 1991.
42. **Koschmann JR:** Vitamin A deficiency in caged birds. *Texas Vet Med J* 48:25, 1986.
43. **Kraft V, Teufel P:** Nachweis eines Pockenvirus bei Zwergpapageien (*Agapornis personata* und *Agapornis roseicollis*). *Berl Munich Tierarztl Wschr* 84:83-87, 1971.
44. **Krehbiel JD:** Cataracts in bobwhite quail. *J Am Vet Med Assoc* 161:634-637, 1972.
45. **Maddux RL, Cgengappa MM, McLaughlin BG:** Isolation of *Actinobacillus suis* from a Canada goose (*Branta canadensis*). *J Wild Dis* 23:483, 1987.
46. **Martin GR:** Eye. In King AS, McLeland J (eds): *Form and Function in Birds Vol 3*. London and New York, Academic Press, 1985.
47. **Martin GR, Gordon IE, Cadle DR:** Electroretinographically determined spectral sensitivity in the tawny owl (*Strix aluco*). *J Comp Physiol* 89:72-78, 1975.
48. **Mason RW:** Conjunctival cryptosporidium in a duck. *Avian Dis* 30:598, 1986.
49. **McCrary MD, Bloom PH:** Lethal effects of introduced grasses on red-shouldered hawks. *J Wildl Mgt* 48:1005-1008, 1984.
50. **McDonald SE, Lowenstein LJ, Aardans AA:** Avian pox in blue-fronted Amazon parrots. *J Am Vet Med Assoc* 179:1218-1222, 1981.
51. **McGaughey CA, Burnet FM:** Avian pox in wild sparrows. *J Comp Path* 55:201-205, 1945.
52. **Meyer DB:** The avian eye and its adaptations. In Crescietti F (ed): *Handbook of Sensory Physiology VII/5*. Berlin and New York, Springer Verlag, 1977.
53. **Mikaelian I, Paillet I, Williams DL:** Comparative use of various mydriatic drugs in the kestrel (*Falco tinnunculus*). *Proc World Vet Conf*, 1991.
54. **Miller WM, Boosinger TR, Maslin WR:** Granulomatous uveitis in an owl. *J Am Vet Med Assoc* 193:365-366, 1988.
55. **Moore CP, Pickett JP, Beehler B:** Extracapsular extraction of senile cataract in an Andean condor. *J Am Vet Med Assoc* 187:1211-1213, 1985.
56. **Murphy CJ:** Raptor ophthalmology. *Comp Cont Ed* 9:241-260, 1987.
57. **Murphy CJ, Kern TJ, Riis RC:** Intraocular trauma in a red-tailed hawk. *J Am Vet Med Assoc* 181:1390-1391, 1982.
58. **Murphy CJ, et al:** Ocular lesions in free-living raptors. *J Am Vet Med Assoc* 181:1302-1304, 1982.
59. **Murphy CJ, et al:** Eucleation in birds of prey. *J Am Vet Med Assoc* 183:1234-1237, 1983.
60. **Murphy CJ, et al:** Retinal dysplasia in a hybrid falcon. *J Am Vet Med Assoc* 187:1208-1209, 1985.
61. **Paul-Murphy J, et al:** Malignant lymphoreticular neoplasm in an African grey parrot. *J Am Vet Med Assoc* 187:1216-1217, 1985.
62. **Pettigrew JD, Wallman J, Wildsoet CF:** Saccadic oscillations facilitate ocular perfusion from the avian pecten. *Nature* 343:362-363, 1990.
63. **Pitts C:** Hypovitaminosis A in psittacines. In Kirk RW (ed): *Current Veterinary Therapy VIII*. Philadelphia, WB Saunders Co, 1985, pp 622-625.
64. **Poonacha KB, Wilson M:** Avian pox in pen-raised bobwhite quail. *J Am Vet Med Assoc* 179:1264, 1976.
65. **Rambow VJ, Murphy JC, Fox JG:** Malignant lymphoma in a pigeon. *J Am Vet Med Assoc* 179:1266-1268, 1981.
66. **Randall CJ:** Conjunctivitis in pheasants associated with cryptosporidial infection. *Vet Rec* 118: 211, 1986.
67. **Randall CJ, et al:** Retinal detachments in the pheasant (*Phasianus colchicus*). *Avian Pathol* 15:687-695, 1986.
68. **Rochon Duvincaud AJF:** Les yeux et la vision des vertébrés. Paris, 1943.
69. **Schlumberger HG:** Neoplasia in the parakeet I. Spontaneous chromophobe pituitary tumors. *Cancer Res* 14:237-245, 1954.
70. **Schmidt RE, Becker LL, McElroy JM:** Malignant intraocular medulloepithelioma in two cockatiels. *J Am Vet Med Assoc* 189:1105-1106, 1986.
71. **Shimakura S, Sawa H, Yamashita T, Hirai K:** An outbreak of ocular disease caused by staphylococcal infection in Amazon parrots (*Amazona aestiva*) imported into Japan. *Jpn J Vet Sci* 43:273, 1981.
72. **Slatter DH, et al:** Hereditary cataracts in canaries. *J Am Vet Med Assoc* 183:872-874, 1983.
73. **Surman PG, Schultz DJ, Tham VL:** Keratoconjunctivitis and chlamydia in cage birds. *Aust Vet J* 50:356, 1974.
74. **Thomas-Baker B, Dew RD, Patton S:** Ivermectin treatment of ocular nematodiasis in birds. *J Am Vet Med Assoc* 189:1113, 1986.
75. **Tudor DC, Yard C:** Retinal atrophy in a parakeet. *Vet Med Sm Anim Clin* 73:85, 1978.
76. **Vickers MC, et al:** Blindness associated with toxoplasmosis in canaries. *J Am Vet Med Ass* 200:1723-1725.
77. **Walls GL:** The vertebrate eye and its adaptive radiation. Cranbrook Inst Sci, Michigan, 1942.
78. **Williams DL:** A wing guided by an eye: A review of raptor ophthalmology. *Vet International* 1:10-17, 1993.
79. **Woerpel RW, Rosskopf WJ:** Retro-orbital *Mycobacterium tuberculosis* infection in a yellow-naped Amazon parrot (*Amazona ochrocephala auroballiata*) *Avian/Exotic Prac* 1:7-10, 1984.
80. **Wolf ED, Amoss K, Olsen J:** Survey of conjunctival flora in the eye of clinically normal captive exotic birds. *J Am Vet Med Assoc* 183:1232-1233, 1983.
81. **Wood CA:** The fundus oculi of birds especially as viewed by the ophthalmoscope. Lakeside Press, Chicago, 1917.
82. **Zenoble RD, Griffith RW, Clubb SL:** Survey of bacteriological flora of conjunctiva and cornea in healthy psittacine birds. *Am J Vet Res* 44:1966-1967, 1983.

**T**he avian heart is divided into four complete chambers and is located midway in the thoracic cavity in an indentation in the sternum parallel to the long axis of the body.<sup>50,91</sup> The right atrioventricular (AV) valve is a simple muscular flap devoid of chordae tendineae, while the left bicuspid AV valve is thin and membranous. Both the aortic and pulmonary valves are membranous and tricuspid as in mammals. The left ventricle is heavily walled and is about two to three times thicker than the right. The right ventricle works as a volume pump and responds rapidly to an increased workload by dilation and hypertrophy.<sup>48</sup> Rigor mortis in a normal heart always results in complete emptying of the left ventricle. Rigor mortis may not occur if severe degenerative disease of the myocardium is present.<sup>31</sup>

In contrast to mammals, in which the lungs are situated on either side of the heart, the apex of the avian heart is covered ventrally by the cranial portion of the right and left liver lobes (see Color 14). The normal pericardial sac is clear and in contact with the epicardium circumferentially and the mediastinal pleura dorsally (see Color 13). A normal bird should have a small quantity of clear to slightly yellow fluid in the pericardial sac (see Color 14). The muscle fibers in the avian heart are five to ten times smaller than the muscle fibers in mammals, and their internal structure is simple, lacking the T-tubules found in mammals. The small surface area precludes the need for a complex T-tubule system for excitation to occur. The heart is normally even in color and is deep reddish-tan (see Color 14). In neonates, the heart is normally a lighter pink color and may appear pale.

---

CHAPTER

27

CARDIOLOGY

---

J. T. Lumeij  
Branson W. Ritchie

Birds have a proportionately larger heart (1.4 to 2 times larger), higher pulse rate, higher blood pressure and a slightly lower peripheral resistance to blood flow than is found in mammals. These factors contribute to the enhanced circulatory and oxygen transport systems that are necessary to sustain flight. The increased cardiac output requires a higher arterial pressure to produce higher blood flow rates. High blood pressure is a predisposing factor to aneurysm and aortic rupture in male turkeys of hypertensive strains.<sup>53,54</sup> On a body weight basis, smaller birds in general have a bigger heart than larger birds. Systolic blood pressure ranges from 108 to 220 mm Hg depending on the species.

The aorta in birds is derived embryologically from the right fourth arterial arch and right dorsal aorta and therefore the ascending aorta curves to the right and not to the left as in mammals. This structure can be clearly seen radiographically on a ventrodorsal projection. Blood is returned to the heart from the peripheral circulation by the left and right cranial caval veins and a single caudal caval vein. Most of the myocardial blood supply comes from deep branches of the right and left coronary arteries.

## Evaluating the Avian Heart

### ■ Electrophysiology<sup>87</sup>

The electrocardiogram (ECG) reflects the differences in conduction that occur between the avian and mammalian heart. Electrical impulses that precede mechanical contraction of the myocardium are generated in the sinoatrial (SA) node. Because the rate of depolarization of the cells of the SA node is higher than that of any other cardiac muscle cell, the SA node functions normally as the cardiac pacemaker. The SA node is located between the entrance of the right cranial vena cava and the caudal vena cava into the right atrium. Electrical impulses are transported along ordinary muscle fibers in the interatrial septum to the atrioventricular (AV) node. The P-wave in the ECG depicts this part of the electrical conduction (ie, depolarization of the atria).

The AV node is located in the caudoventral part of the interatrial septum or the caudodorsal part of the interventricular septum. Electrical conduction is de-

layed in the AV node, which facilitates filling of the ventricles before they contract. Delay of conduction in the AV node is depicted by the PR-segment in the ECG. The AV node is continuous with the AV bundle branches into right and left crura as it courses into the interventricular septum. The AV bundle electrically separates the atria from the ventricles by penetrating the fibrous tissue. The AV node in birds also gives rise to the right AV ring that encircles the right AV opening and controls the activity of the right muscular AV valve. There are also fibers running to the truncobulbar node at the base of the aorta.

The AV bundles and their branches consist of Purkinje fibers. Electrical conduction in Purkinje fibers is about five times faster than in normal cardiac muscle cells and hence the conduction system plays an important role in regulating myocardial contraction. After transmission of the electrical impulses through the ventricular conduction system, all areas of the ventricles are activated in a coordinated fashion. Depolarization of the ventricles is depicted by the QRS complex in the ECG.

Birds have a mean electrical axis that is negative, while the mean electrical axis in dogs is positive. This difference can be explained by the fact that in birds, the depolarization wave of the ventricles begins subepicardially and spreads through the myocardium to the endocardium, while in the dog, depolarization of the ventricles starts subendocardially. The parasympathetic nervous system (via the vagus nerve) and the sympathetic nervous system (via the cardiac nerve) synapse on the SA node.

### ■ Diagnostic Methods

Primary heart diseases should be included in the differential diagnosis when avian patients are presented with lethargy, periodic weakness, dyspnea, coughing and abdominal swelling (ascites). Any drugs that the patient has received, potential exposure to toxins and concurrent diseases should always be evaluated when determining if the heart is abnormal. Arteriovascular disease was noted in 199 of 1726 mixed avian species necropsied in one zoological collection.<sup>13</sup> Cardiac-induced ascites appears to be less common in Psittaciformes than in Galliformes and Anseriformes.

Auscultation of the avian heart is difficult and the information that can be gained is limited. Subtle murmurs are easiest to detect when birds are under isoflurane anesthesia and the heart rate is de-

creased. Auscultation of the heart can best be performed on the left and right ventral thorax. Pleural or pulmonary fluid accumulation may cause muffled lung sounds or rales when a bird is auscultated over the back between the shoulder blades.

Mild stress, such as occurs in the veterinary examination room or following restraint, may cause a bird's heart rate to increase substantially (two to three times normal). Exercise, age, climatic conditions, stress factors, drug exposure, toxins, diet, percent body fat and blood pressure can all alter the avian heart rate. As a rule, the heart rate in a bird that is being restrained is higher than the heart rate obtained in the same bird if the rate had been determined using telemetry. A stress-induced increase in heart rate should resolve several minutes after the stressing factors are removed.

Diagnostic aids that have proven to be effective in evaluating cardiac diseases include CBC, plasma chemistries (eg, AST, LDH, CPK), cytologic examination of pericardial or peritoneal effusions, plasma electrolytes, blood culture, radiographs (including contrast studies such as nonselective angiocardiography), electrocardiography, cardiac ultrasonography (echocardiography) and color flow doppler. CPK activity from cardiac muscle origin (CPK-MB isoenzyme) was significantly higher in ducklings with furazolidone-induced cardiotoxicosis when compared to controls.<sup>99a</sup>

### Imaging

Radiographic detection of cardiovascular abnormalities may be difficult, although an enlarged cardiac silhouette or microcardia can often be visualized. Radiographic detection of an enlarged cardiac silhouette with muffled heart sounds is suggestive of pericardial effusion. An increased cardiac silhouette with normal heart sounds is suggestive of dilative heart disease.

Electrocardiography (low voltage in pericardial effusion) and ultrasonography may demonstrate free pericardial fluid. Microcardia is indicative of severe dehydration or blood loss that has resulted in hypovolemia (Figure 27.1). Other radiographic changes that suggest cardiac disease include congestion of pulmonary vessels, pulmonary edema, pleural effusion, hepatomegaly and ascites.

Non-selective angiocardiography with rapid sequence serial radiographs has been used to confirm impaired cardiac function in a racing pigeon (Figure 27.2).<sup>57</sup> This technique has also been used to rule out

cardiovascular shunt as the cause of severe dyspnea and hypoxia in a Blue and Gold Macaw. The procedure is performed by injecting a bolus dose of contrast medium into the catheterized basilic vein.<sup>95</sup>

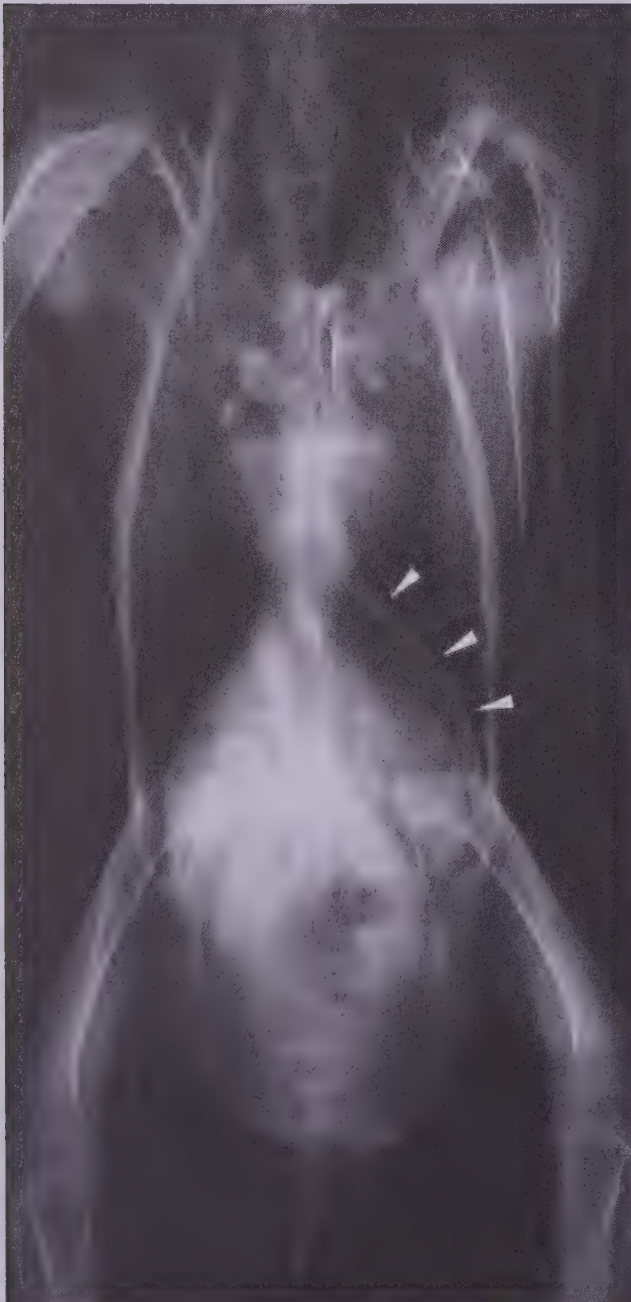
Of the imaging techniques, echocardiograms generally provide the most diagnostic information. Echocardiography was used successfully to detect valvular endocarditis on the aortic valve of a four-year-old female emu suspected of cardiac disease. Staphylococcus was isolated from the vegetative lesion, which was seen as a large mass using this technique.<sup>70</sup> In small birds, the echocardiographic image of the heart is best obtained by sweeping through the liver. Color flow doppler was used to demonstrate mitral regurgitation and right-sided heart failure in a mynah.<sup>76</sup>

## Electrocardiology

Using a capillary electrometer, Buchanan<sup>8</sup> was the first to describe the form of the electrocardiograms in birds. She discovered that "when the mouth is to the acid (+) and the legs to the mercury (-)" the mean deflection of the QRS-complex in birds is negative and not positive as in mammals. In 1915 the first electrocardiogram of a pigeon made with a string galvanometer was published;<sup>49</sup> leads were connected to the neck and abdomen.

It was demonstrated in 1949 that the negative mean electrical axis of ventricular depolarization in birds occurs because the depolarization wave begins subepicardial and then spreads through the myocardium towards the endocardium.<sup>51</sup> Sturkie<sup>83-92</sup> pioneered the use of clinical electrocardiography in birds and described the normal ECG of the chicken using standard bipolar limb leads. Of all avian species, both normal and abnormal ECGs of chicken and turkey have been best characterized. Details of the ECG of gulls,<sup>51</sup> buzzards,<sup>21</sup> parakeets and parrots<sup>101</sup> have also been published.

Despite its great clinical applicability, electrocardiography has received relatively little attention from companion and aviary bird practitioners. This might be due to the scarcity of electrocardiographic reference values in companion birds. To the authors' knowledge these values have been established only in racing pigeons, African Grey Parrots and Amazon



**FIG 27.1** An adult Umbrella Cockatoo was presented for severe depression. The eyes were glazed and partially closed, the ulnar vein refill time was two seconds, and the skin on the toes would stay elevated for several seconds when pinched. All these findings were suggestive of severe dehydration. Radiographs indicated microcardia (indicative of dehydration) and gaseous distention of the proventriculus (arrows), which is common in birds that are anesthetized or are severely dyspneic. The pulmonary arteries are also visible (open arrows).



**FIG 27.2** Angiography can be used to evaluate impaired cardiac function. A single rapid intravenous bolus of contrast agent was administered via a catheter into the cutaneous ulnar vein of a normal Green-winged Macaw. Images were made with a rapid film changer at six films per second. The axillary vein (arrow), cranial vena cava (c), cardiac chambers and pulmonary arteries (open arrows) are clearly visible. Note that contrast media is also present in the kidneys (courtesy of Marjorie McMillan).

TABLE 27.1 Normal Electrocardiograms in Selected Birds\*

Parameter		Racing Pigeon	African Grey Parrot	Amazon Parrot
Normal heart rate		160-300	340-600	340-600
Normal heart rhythms		Normal sinus rhythm Sinus arrhythmia Second degree AV block	Normal sinus rhythm Sinus arrhythmia Ventricular premature beats Second degree AV block	
Normal heart axis		-83° to -99°	-79° to -103°	-90° to -107°
Normal measurements in lead II	P-wave duration	0.015-0.020 s	0.012-0.018 s	0.008-0.017 s
	Amplitude	0.4-0.6 mV	0.25-0.55 mV	0.25-0.60 mV
	PR-interval	0.045-0.070 s	0.040-0.055 s	0.042-0.055 s
	QRS complex duration	0.013-0.016 s	0.010-0.016 s	0.010-0.015 s
	R amplitude		0.00-0.20 mV	0.00-0.65 mV
	(Q)S amplitude	1.5-2.8 mV	0.9-2.2 mV	0.7-2.3 mV
	ST-segment	Very short or absent Elevation 0.1-0.3 mV No ST depression		
T-wave	Always discordant to the ventricular complex			
		0.3-0.8 mV	0.18-0.6 mV	0.3-0.8 mV
QT-interval	Unanesthetized	0.060-0.075 s	0.039-0.070 s	0.038-0.055 s
	Anesthetized		0.048-0.080 s	0.050-0.095 s

\*Criteria for the normal electrocardiogram in racing pigeons (n=60), African Grey Parrots (n=45) and Amazon parrots (n=37). Measurements are derived from ECGs recorded at 200 mm/s and standardized at 1 cm = 1 mV. Reference values (inner limits of the percentiles P<sub>2.5</sub> - P<sub>97.5</sub> with a probability of 90%) modified from Lumeij<sup>66</sup> and Nap, et al.<sup>67</sup>

parrots (Table 27.1).<sup>56,67</sup> Other reports involve only a limited number of birds.

Electrocardiography may be useful for detecting cardiac enlargement from hypertrophy of any of the four cardiac chambers. Electrocardiography is indispensable for the diagnosis and treatment of cardiac arrhythmias and is also useful in monitoring changes in electrolyte concentrations during the treatment of metabolic diseases that alter electrolyte balance. When evaluating cardiac enlargement it is best to compare the electrocardiographic findings with those of cardiac imaging techniques.

The electrocardiogram may be of help in evaluating and diagnosing some of the diseases that cause vague signs of weakness, fatigue, lethargy, fever, collapse or seizures. Metabolic, cardiac, neurologic and systemic diseases that produce toxemia can cause one or all of these clinical changes. The electrocardiograph may be used also to monitor heart rate and rhythm in an anesthetized patient. Because the myocardium is very sensitive to hypoxia, the electrocardiogram can serve as a reliable indicator of the oxygenation of the bird (see Figure 27.15). The clinician should realize, however, that cardiac pathology can occur without electrocardiographic changes.

### The Electrocardiograph and Recording of the ECG

Regardless of the type of electrocardiograph used, it must be able to run electrocardiograms at a paper speed of at least 100 mm/s. Avian heart rates are so rapid that inspecting and measuring the tracing is less accurate at slower speeds. For routine ECGs, the machine is standardized at 1 cm = 1 mV. When dealing with ECGs with a low voltage, the sensitivity of the machine should be doubled. If the complexes are so large that they exceed the edge of the tracing paper, the sensitivity should be halved. The calibration and the paper speed should always be marked on the electrocardiogram together with the date, time, name and case number of the patient.

The electrocardiogram can be recorded in an unanesthetized racing pigeon that is restrained in an upright position, while in parrots, isoflurane anesthesia is recommended. When comparing anesthetized and unanesthetized parrots, only the median heart rate and QT-interval were found to be significantly different ( $P < 0.05$ ) (Table 27.1).<sup>67</sup>

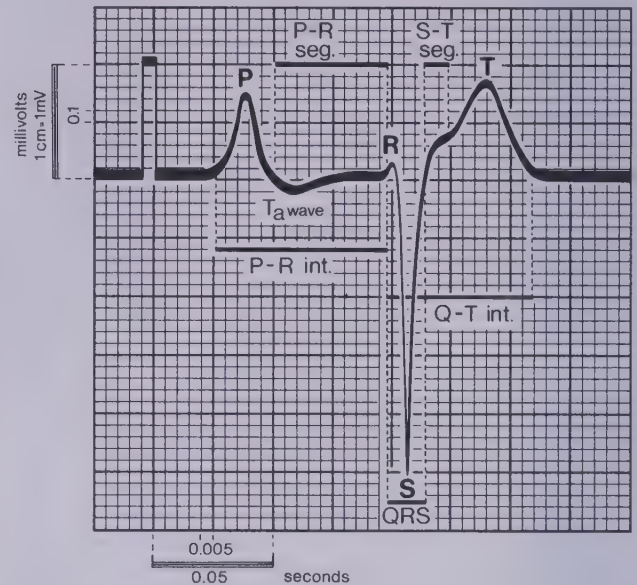
A Mingograph 62 electrocardiograph (Siemens-Elcoma AB) with a paper speed of 25, 100 or 200 mm/s was used by the primary author to establish the reference values listed in Table 27.1. It is easiest to perform an ECG on a bird in dorsal recumbency, but

right lateral or ventral recumbency is equally effective. Needle electrodes placed subcutaneously are superior to alligator clips for use in avian patients.<sup>a</sup>

Lead I in birds is nearly isoelectric. The lead II electrocardiogram in Figure 27.3 is a recording of electrical currents generated during the depolarization and repolarization of the heart. The P-wave signifies that the atria have depolarized, causing contraction and ejection of their complement of blood into the ventricles. The PR-segment indicates the short delay in the atrioventricular node that occurs after the atria contract, which allows complete filling of the ventricles before ventricular contraction occurs. The depression of the initial part of the PR-segment is related to large atrial repolarization forces. In dogs, this is caused by right atrial hypertrophy and is called auricular T-wave or  $T_a$ -wave.<sup>5,24,96</sup> In racing pigeons, this phenomenon is seen in 83% of healthy individuals and depicts the repolarization of the atria.<sup>56</sup> A " $T_a$ -wave" is also normal in some gallinaceous birds.<sup>6</sup>

In parrots, a slight indication of a  $T_a$ -wave may occasionally be noted.<sup>67</sup> The (Q)RS-complex represents ventricular depolarization and contraction with the ejection of blood into the aorta and pulmonary artery. The Q-wave is the first negative deflection, the R-wave is the first positive deflection and the S-wave is the first negative deflection following the R-wave. When there is no R-wave, the negative deflection is called a QS-wave. The largest wave in the QRS-complex is depicted with a capital letter, (ie, Rs or rS). The ST-segment and T-wave depict the repolarization of the ventricles. In clinically asymptomatic racing pigeons and parrots, the ST-segment is often very short or even absent, the S rising directly into the T-wave ("ST-slurring"). When the ST-segment is present, it is often elevated above the baseline (maximum 0.3 mV elevation in the racing pigeon). In mammalian species, these changes are associated with cardiac disease (ie, left ventricular hypertrophy),<sup>5,12</sup> but the cause of ST-slurring in birds remains undetermined.

The duration (measured in hundredths of seconds) and amplitude (measured in millivolts) of the complexes can be measured. When the machine is standardized at 1 cm = 1 mV each small box on the vertical is 0.1 mV. When the electrocardiograph is recorded at a paper speed of 100 mm/s, each small box on the horizontal is 0.01 s and when the ECG is recorded at 200 mm/s, each small box represents 0.005 s. The



**FIG 27.3** Schematic representation of a normal lead II electrocardiographic complex of a racing pigeon. Paper speed 200 mm/s, 1 cm = 1 mV (courtesy of J. T. Lumeij. Reprinted with permission<sup>56</sup>).

determined values can be compared with reference values (Table 27.1).

### ECG Leads

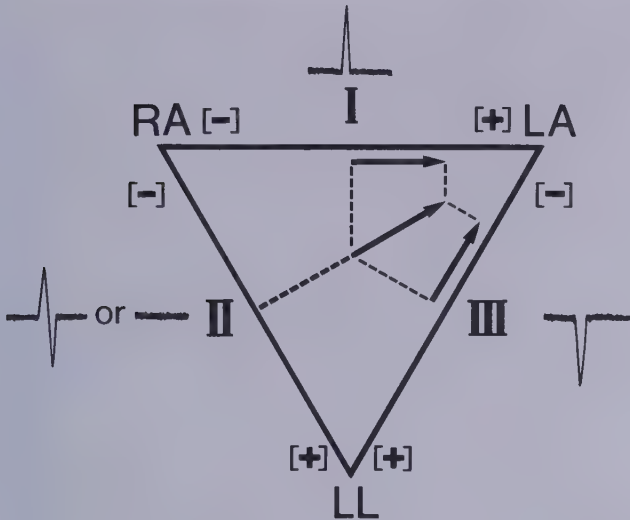
The vector in the frontal plane of the electrical current that is generated during ventricular depolarization is called the mean electrical axis. The various lead systems were developed to measure the direction and force of the cardiac vector accurately. Each lead has a positive and a negative pole. If an electrical impulse is traveling in the direction of a lead's negative pole, a negative deflection results and vice versa (Figure 27.4). If the vector runs perpendicular to a lead, that lead will record either no deflection or an equal number of positive and negative forces. This is called an isoelectric lead. Bailey's hexaxial lead system is most widely used in veterinary electrocardiography (Figure 27.5).<sup>5,24,96</sup> It combines the three bipolar limb leads (I, II and III) from Einthoven's

### CLINICAL APPLICATIONS

#### ECGs can be used to:

- Diagnose primary heart disease
- Monitor therapy of heart disease
- Evaluate cardiac effects of systemic abnormalities
- Monitor anesthesia
- Establish a cardiac database for the subclinical patient





**FIG 27.4** If an electrical impulse is traveling in the direction of a lead's negative pole, a negative deflection results and vice versa. If the vector runs perpendicular to a lead, that lead will record either no deflection or an equal number of positive and negative forces. This is called an isoelectric lead (see Figure 27.8).

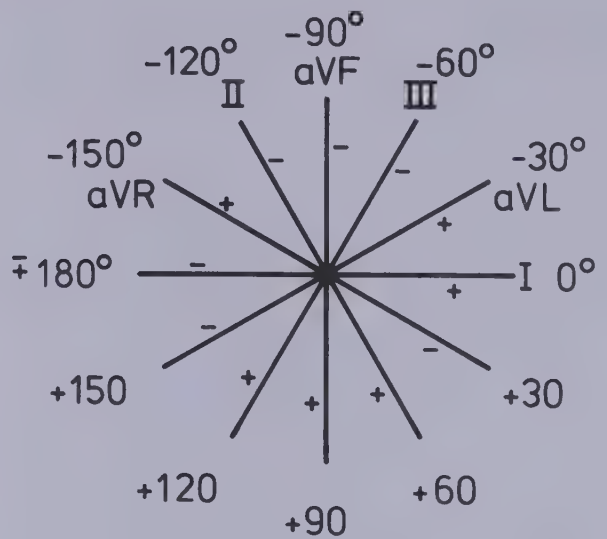
triangle with the augmented unipolar limb leads (Figure 27.6).

The electrodes are attached to the right wing (RA), the left wing (LA) and the left limb (LL). The right hind limb (RL) of the bird is connected to the ground electrode.

- In lead I, RA is the negative pole and LA the positive pole.
- In lead II RA is the negative pole and LL is the positive pole.
- In lead III LA is the negative pole and LL is the positive pole.

In theory, these three leads form an equilateral triangle. The three leads can be redrawn exactly at the same length and polarity by passing each lead through the center point of the triangle. This produces a triaxial system, and angle values can be assigned to both the positive and negative pole of each lead.

The augmented (machine-induced increase in signal strength) unipolar leads (aVR, aVL, aVF) provide three more leads (Figure 27.6). An augmented unipolar lead compares the electrical activity of the reference limb to the sum of the electrical activity at the other limbs. The augmented vector leads are right arm (AVR), left arm (aVL) and frontal plane (aVF);



**FIG 27.5** Bailey's hexaxial system. The three leads from Einthoven's triangle (I, II, III) and the three unipolar leads (aVR, aVL, aVF) can be redrawn exactly at the same length and polarity by passing each lead through the center point of the triangle. This produces a hexaxial system and angle values can be assigned to both the positive and negative pole of each lead. Now there are six leads, with a positive and a negative pole, and each pole has an angle value. This six-lead system is used for determining the mean electrical axis of ventricular depolarization.

"a" = augmented, "V" = vector, "R" = right arm, "L" = left arm and "F" = frontal (represents the left leg).

In lead aVR, RA is the positive pole and the negative pole compares LA and LL. In lead aVL, LA is the positive pole and the negative pole compares RA and LL. In lead aVF, LL is the positive pole and the negative pole compares RA and LA. Now there are six leads, with a positive and a negative pole, and each pole has an angle value. This six-lead system is used for determining the mean electrical axis of ventricular depolarization (see Figure 27.5).

### ■ Interpretation of the ECG

Electrocardiograms should be read in a systematic manner. There are four important steps in the process of interpreting an ECG (Figure 27.7).<sup>5,96</sup>

#### Determination of Heart Rate

All recording paper has a series of marks at the top or bottom of the paper. These marks are spaced so that they are three seconds apart at a 25 mm/s paper speed. To estimate heart rate per minute, the number of complexes that occur in three seconds are counted

and multiplied by 20. A second method of determining heart rate per minute is to count the number of small boxes from S-wave to S-wave and divide into 1500 (there are 1500 small boxes per minute at 25 mm/s paper speed).

#### Determination of Heart Rhythm

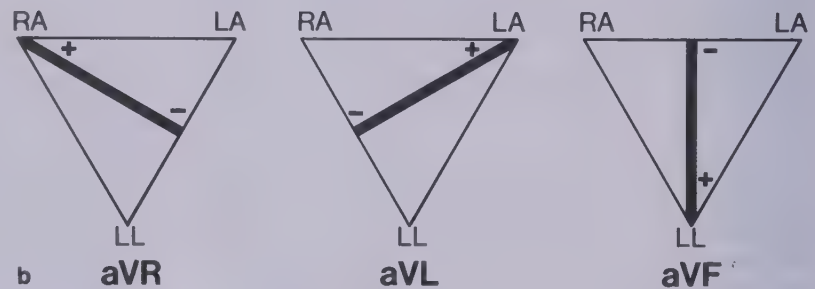
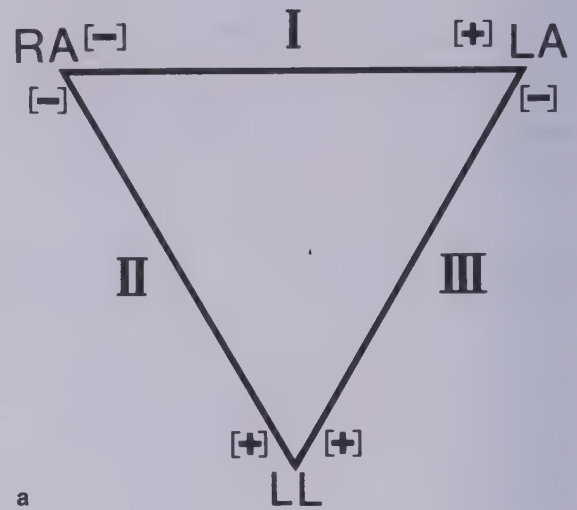
- Is the heart rate normal or abnormal for the species (bradycardia or tachycardia)?
- Is the heart rhythm regular or irregular?
- Is there a P-wave for every QRS-complex, and is there a QRS-complex for every P-wave?
- Are the P-waves related to the QRS-complexes?
- Do all the P-waves and all the QRS-complexes look alike?

#### Determination of Mean Electrical Axis

To determine the heart axis, the mean wave of electrical activity in the frontal plane that occurs when the ventricles depolarize is measured. The procedure for a rough estimation of the axis is simple and involves three steps (Figure 27.7):

- Find an isoelectric lead.
- Use the six-axis reference system chart and find which lead is perpendicular to the isoelectric lead (see Figure 27.5).
- Determine if the perpendicular lead is positive or negative on the tracing and examine the angle value on the six axis reference system. Compare these values with reference values (Table 27.1).

When all leads are isoelectric it is not possible to determine the heart axis and the heart is "electrically vertical" (Figure 27.8). The heart axis can be precisely determined by graphing leads II and III. Alternatively the heart axis can be calculated from the vectors of ventricular depolarization in leads II and III (in Figure 27.9 named **a** and **b** respectively) using Bailey's hexaxial system (see Figure 27.2).<sup>67</sup> The angles  $\beta$  and  $\tau$  are known ( $60^\circ$  and  $30^\circ$ , respectively).



**FIG 27.6** a) Einthoven's triangle depicts the three bipolar limb leads I, II and III. The electrodes are attached to the right wing (RA), the left wing (LA) and the left limb (LL). The right hind limb (RL) of the bird is connected to the ground electrode. In lead I, RA is the negative pole and LA the positive pole. In lead II, RA is the negative pole and LL is the positive pole. In lead III, LA is the negative pole and LL is the positive pole. The three leads form in theory an equilateral triangle. b) The augmented unipolar leads (aVR, aVL and aVF) provide three more leads. In lead aVR, RA is the positive pole and the negative pole compares LA and LL. In lead aVL, LA is the positive pole and the negative pole compares RA and LL. In lead aVF, LL is the positive pole and the negative pole compares RA and LA (courtesy of J. T. Lumeij).

Then:

$$b = p \cos \beta$$

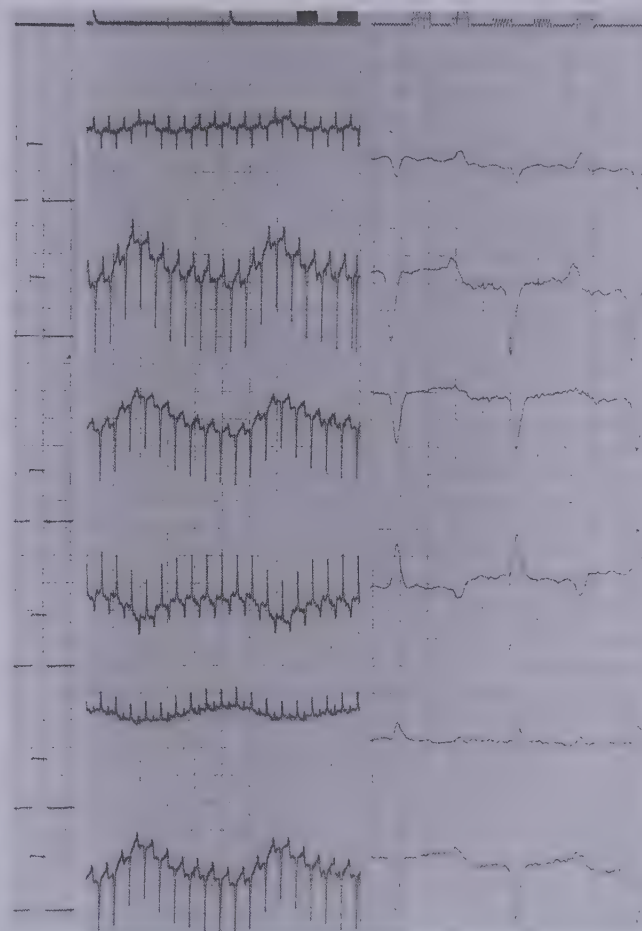
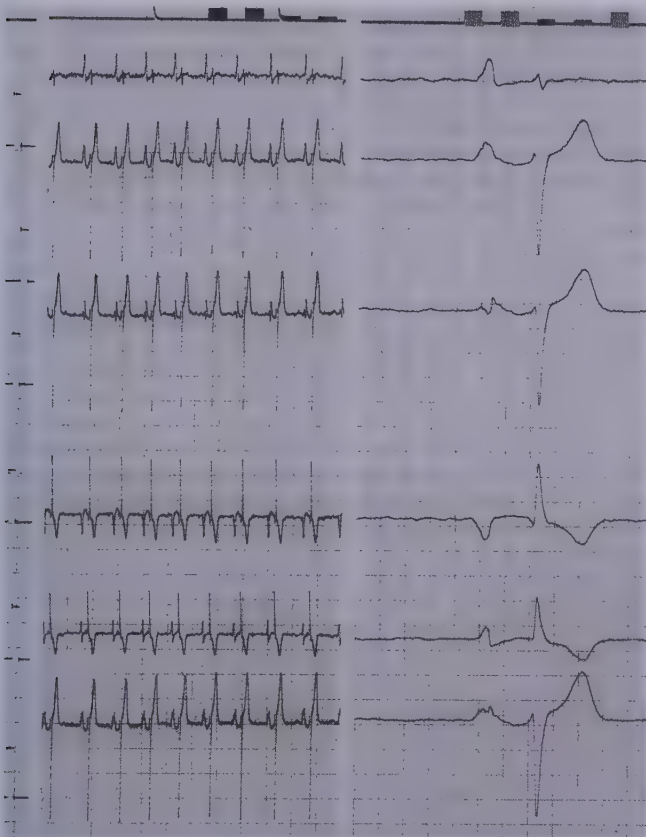
$$q = p - a = [b/\cos \beta] - a$$

$$\tan \tau = h/q$$

$$h = q \tan \tau = q \tan (90 - \beta) = q \cot \beta$$

$$\tan \alpha = h/a = [q/a] \cot \beta = \{([b/a] \cos \beta) - 1\} \cot \beta$$

Thus,  $\alpha$  can be calculated from known parameters and the mean electrical axis can be determined. The calculations have been computerized by the primary author to facilitate the determination of the mean electric axis.<sup>67</sup>



**FIG 27.7** Normal pigeon electrocardiogram. From top to bottom: leads I, II, III, aVR, aVL, aVF. 1 cm = 1 mV. Paper speed 25 mm/s and 200 mm/s (courtesy of J. T. Lumeij).

*Heart Rate:* 250 (SS-interval is six boxes at 25 mm/s paper speed)

*Rhythm:* Sinus arrhythmia (the first two SS intervals are not equidistant)

*Axis:*  $-90^\circ$  (The vector of ventricular depolarization is isoelectric in lead I. In the six-axis reference system (see Figure 27.5) lead aVF is perpendicular to lead I. The ventricular depolarization vector is negative in lead aVF. Angle value on the six-axis ref. chart is  $-90^\circ$ )

*Measuring:* P-wave = 0.02 s, 0.4 mV. PR-interval = 0.06 s. QRS-complex = 0.015 s, 1.9 mV. ST-segment = 0.1 mV elevated, ST-slurring. T-wave discordant and positive in lead II, 0.8 mV. QT-interval = 0.07 s.

*Electrocardiographic Diagnosis:* Normal pigeon electrocardiogram.

Representative ECG of an African Grey Parrot, with six simultaneously recorded leads. From top to bottom: leads I, II, III, aVR, aVL and aVF. Paper speed 25 mm/s and 200 mm/s, 1 cm = 1 mV (courtesy of J. T. Lumeij).

*Heart Rate:* 540

*Rhythm:* Normal sinus rhythm

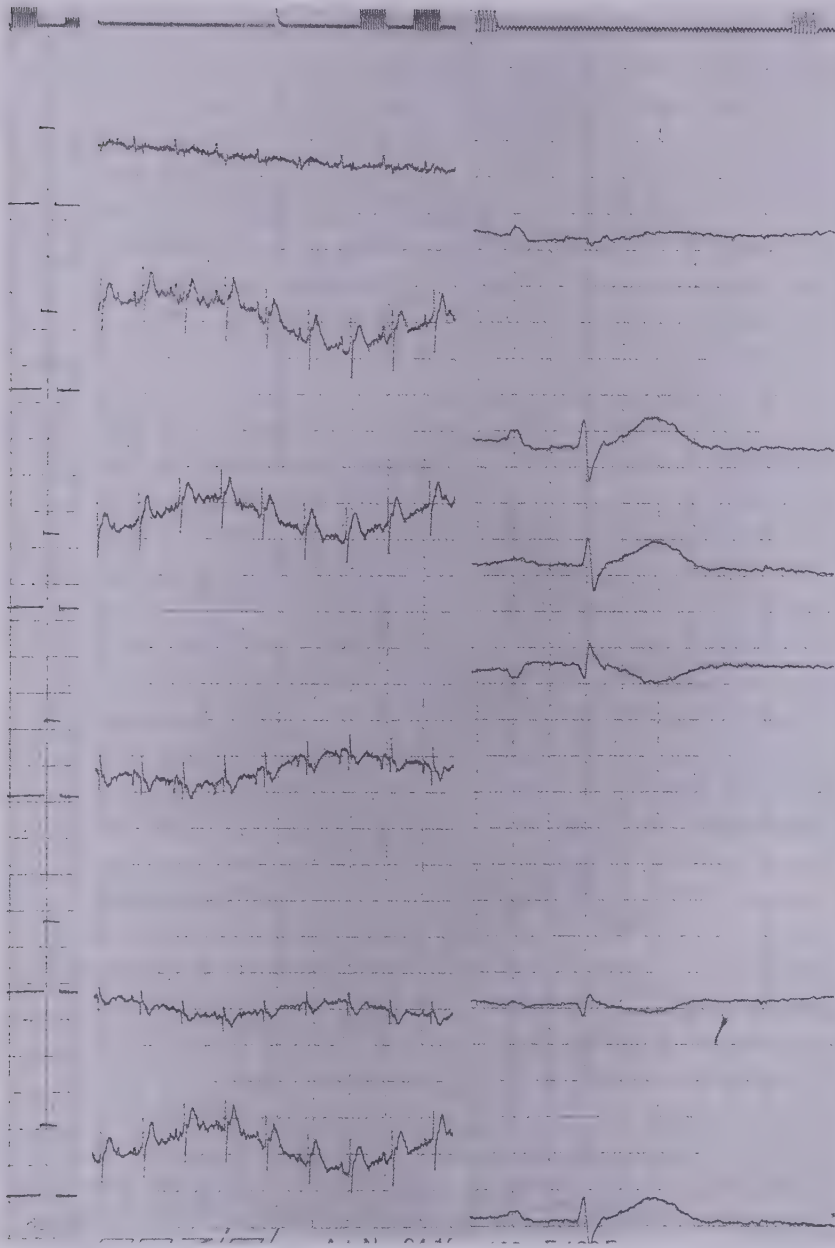
*Axis:*  $-105^\circ$  (leads I and aVL are closest to being isoelectrical. Leads aVF and II are perpendicular to these respective leads and negative. The heart axis is midway between  $-120^\circ$  and  $-90^\circ$ )

*Measuring:* P-wave = 0.015 s, 0.5 mV, slight 'P on T phenomenon'. PR-interval = 0.05 s. QRS-complex = 0.015 s, QS 1.3 mV. T-wave discordant 0.18 mV. QT-interval = 0.06 s

*Electrocardiographic Diagnosis:* Probably a normal electrocardiogram. The axis is borderline compared to reference values for the African Grey Parrot, but no other abnormalities can be identified.

In mammals, right axis deviation occurs when the vector of ventricular depolarization has moved clockwise on Bailey's six-axis reference system from a positive value (eg,  $+40^\circ$  to  $+100^\circ$  in dogs) toward the right side of the body. With left axis deviation, the vector moves counterclockwise toward the left side of the body. In mammals, right axis deviation is seen with enlargement of the right ventricle, while left axis deviation is seen with hypertrophy of the left ventricle.

Deviations in mean electric axis in birds are confusing because the normal heart axis is negative (except for some strains of chickens). More cases of left and right axis deviation in birds, and their associated clinical and pathologic changes, need to be determined before the importance of these electrocardiographic findings can be ascertained (Figures 27.10, 27.11, 27.12).



**FIG 27.8** Electrically vertical heart in an African Grey Parrot. From top to bottom: leads I, II, III, aVR, aVL and aVF. 1 cm = 1 mV; paper speed 25 mm/s and 200 mm/s. This bird was presented with dyspnea and seizures. The heart axis is indeterminate because all leads are isoelectric. Radiographs indicated a dilated proventriculus. Myocarditis has been reported as a possible component of neuropathic gastric dilatation of psittacine birds (courtesy of J. T. Lumeij).<sup>97</sup>

### Measuring

All measurements are made on the lead II rhythm strip. Measurements include the amplitude and the duration of the different electrocardiographic complexes (see Figure 27.3). The values found should be compared with the reference values (Table 27.1).

▪ **P-Wave:** With right atrial hypertrophy the P-wave becomes tall and peaked (P pulmonale), and with left atrial hypertrophy the P-wave becomes too wide (P mitrale). There is an increased number of P waves with tachycardia. P pulmonale has been associated with dyspnea induced by aspergillosis or tracheal obstruction. A tall, wide P-wave is suggestive of biatrial enlargement and is common with influenza virus in gallinaceous birds.

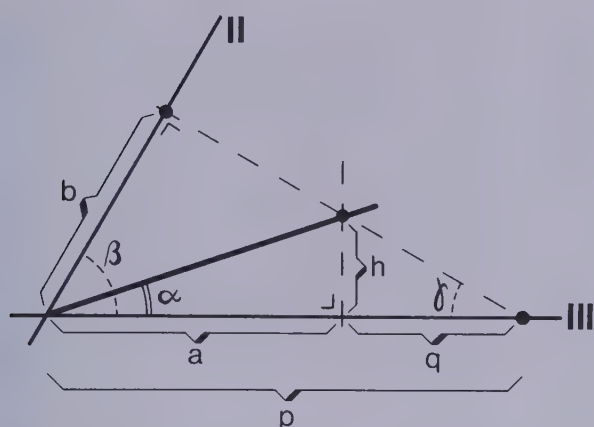
▪ **PR-Interval:** In the normal pigeon ECG, a T<sub>a</sub>-wave can be seen in the PR-segment, indicating repolarization of the atria. A small T<sub>a</sub> may occur also in some asymptomatic parrots. This finding is considered normal and should not be interpreted as a sign of right atrial hypertrophy as it is in the dog.

▪ **QRS-Complex:** Two measurements are made on the QRS-complex. The duration is measured from the beginning of the R-wave to the end of the S-wave. The second measurement is the amplitude of the S-wave, measured from the baseline downwards. Low voltage ECGs occur often in birds with pericardial effusion (Figure 27.13). A QRS-complex that is too wide or too tall indicates left ventricular hypertrophy (Figure 27.14). Prominent R-waves are suggestive for right ventricular hypertrophy<sup>17,41,59</sup> and it might be that a R<sub>1</sub>-R<sub>2</sub>-R<sub>3</sub> pattern is comparable to an S<sub>1</sub>-S<sub>2</sub>-S<sub>3</sub> pattern in dogs (see Figure 27.12)

▪ **ST-Segment:** The ST-segment in the avian electrocardiogram is often short or absent. When present, it may be elevated above the baseline, which should *not* be interpreted as a sign of left ventricular hypertrophy, myocardial hypoxia, myocarditis or hypocalcemia as it is

in the dog.<sup>5,24,56,67,96</sup>

▪ **T-Wave:** In the normal avian ECG, the T-wave is always in the opposite direction to the main vector of the ventricular depolarization complex, and always positive in lead II. When the T-wave changes its



**FIG 27.9** Mathematical derivation of the mean electrical axis of ventricular depolarization in the frontal plane. Known parameters are the vectors in lead II and III (named *b* and *a*, respectively, and the angles  $\beta$  and  $\tau$  ( $60^\circ$  and  $30^\circ$ , respectively),  $\alpha$  can be derived using the formulae described in the text (courtesy of J. T. Lumeij. Reprinted with permission<sup>67</sup>).

polarity, it suggests that myocardial hypoxia is occurring (Figure 27.15). The same is true for a T-wave that progressively increases in size (eg, during anesthesia). T-wave changes may also occur in association with electrolyte changes (eg, increased T-wave amplitude with hyperkalemia).<sup>3</sup>

▪ **QT-Interval:** Prolongation of the QT-interval might be associated with electrolyte disturbances like hypokalemia and hypocalcemia. In African Grey and Amazon parrots, the QT-interval was significantly ( $P < 0.05$ ) prolonged during isoflurane anesthesia (see Table 27.1). The effects of various diseases and compounds on the heart are listed in Table 27.2.

## Arrhythmias

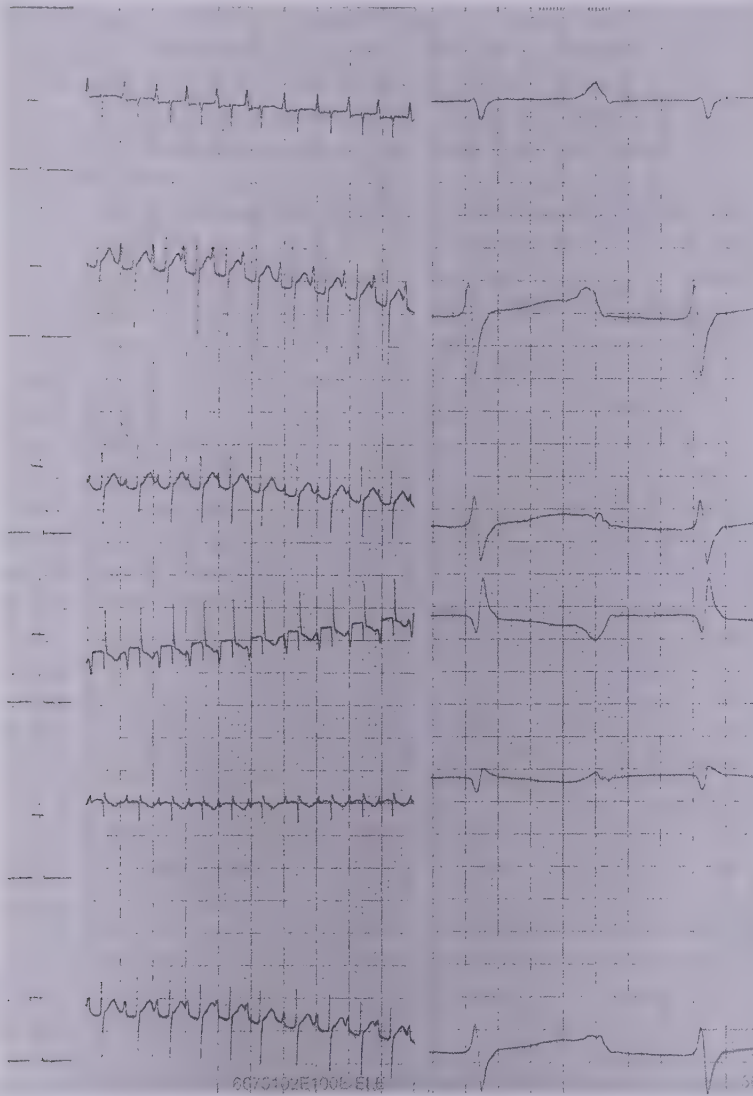
### Sinus Arrhythmias

The normal rhythm of the heart is established by the SA node. A normal sinus rhythm does not vary in rate from beat to beat. An increase in vagal activity may decrease the heart rate, while a decrease in vagal activity may increase the heart rate. Heart rate may increase during inspiration and decrease during expiration and hence the S-S interval may not be equidistant. The associated rhythm is called sinus arrhythmia.

Sinus arrest is an exaggerated form of sinus arrhythmia and can be diagnosed if the pause is greater than

**TABLE 27.2** Cardiovascular Effects of Selected Conditions or Agents<sup>6,17,18,28,30,32,39-41,43,46,53,54,60, 61,64,83-93</sup>

Condition/Agent	Rhythm	SA node	AV node	ECG Changes
Dilated cardiomyopathy	Atrial arrhythmia Ventricular arrhythmia			Increased R-wave Negative T-wave Mean axis $0^\circ$ to $-170^\circ$
<i>E. coli</i> septicemia (Galliformes)				Elevated P-waves Elevated T-waves Elevated S-waves Elevated R-waves
Halothane	Decreased heart rate		First degree AV block	Increased PR-interval
Hyperkalemia (ducks)				Elevated T-waves
Hypokalemia	Sinus arrhythmia Sinus bradycardia VPCs	SA block	Incomplete AV block AV junctional PC	
Influenza virus (Galliformes)	Ventricular tachycardia VPCs		Decreased conduction	Increased ST-segment Increased TP-interval Increased PR-interval Increased RS-interval
Newcastle disease virus (Galliformes)	Ventricular arrhythmias		Decreased conduction	Fusion T- and P-waves Increased T-waves
Thiamine deficiency	Sinus arrhythmia Sinus bradycardia Sinus arrest VPCs			Decreased ST-segment
Vitamin E deficiency	Sinus arrhythmia Sinus bradycardia Sinus arrest VPCs			Decreased PR-interval Elevated ST-segment



**FIG 27.10** *History:* ECG of a 37-year-old African Grey Parrot with congestive heart failure. From top to bottom: leads I, II, III, aVR, aVL and aVF. 1 cm = 1 mV; paper speed 25 mm/s and 200 mm/s.

*Heart Rate:* 320

*Rhythm:* Sinus arrhythmia

*Axis:*  $-150^\circ$  (The vector of ventricular depolarization is isoelectric in lead III. In the six-axis reference system [Figure 27.5], lead aVR is perpendicular to lead III. The ventricular depolarization vector is positive in lead aVR. The angle value on the six-axis reference chart is  $-150^\circ$ )

*Measuring:* P = 0.4 mV, 0.025 s. PR-interval = 0.09 s. QRS-complex = 0.02 s, R = 0.6 mV, QS = 0.9 mV, T = 0.2 mV and QT = 0.11 s.

*Electrocardiographic Diagnosis:* Widening of P-wave (P-mitrale), widening of the QRS-complex and axis deviation are all indicative of left atrial and ventricular enlargement. An increase in the amplitude of the R-wave has been associated with right ventricular failure in chickens.

*Clinical Findings:* This bird was presented with severe dyspnea and inability to perch. Radiographs revealed cardiohepatomegaly and ascites. Ultrasonography confirmed the presence of ascites, but no free pericardial fluid could be seen. A liver biopsy was performed because of elevated bile acids (220  $\mu\text{mol/l}$ ). Histologic examination revealed fibrotic changes, possibly secondary to chronic liver congestion (right-sided heart failure). Treatment of the congestive left and right heart failure with furosemide 1 mg/kg BID and digoxin 0.045 mg/kg SID resolved the clinical signs within ten days (courtesy of J. T. Lumeij).

twice the normal S-S interval. A sinoatrial block occurs when an electrical impulse from the sinoatrial node fails to activate the atria. The pauses are exactly twice the S-S interval. A continuous shifting of the pacemaker site in the SA node or the atrium, and hence a continuously changing configuration of the P-wave, is called wandering pacemaker. Sinus arrhythmia, sinus arrest, sinoatrial block and wandering pacemaker have been reported in association with normal respiratory cycles and are considered physiologic in birds.<sup>4a,39,67,99</sup>

Sinus bradycardia can be induced by vagal stimulation and can be converted by the administration of atropine. Various anesthetics (eg, halothane, methoxyflurane, xylazine and acepromazine) have been reported to cause sinus bradycardia, when atropine is not given simultaneously. Hypothermia, which may accompany long-term anesthesia, may potentiate this arrhythmia.<sup>1,37,58,63</sup>

Pathologic conditions that may induce sinus bradycardia and sinus arrest include hypokalemia,<sup>85,90</sup> hyperkalemia,<sup>3</sup> thiamine deficiency,<sup>11</sup> and vitamin E deficiency.<sup>88</sup> The conduction abnormalities (SA block, AV block) caused by potassium deficiencies can be corrected by administering atropine, suggesting that potassium increases vagal tone to the SA and AV nodes.<sup>87</sup>

Several toxins have been reported to induce bradycardia, including, organophosphorus compounds and polychlorinated biphenyls.<sup>43</sup> Reflex vagal bradycardia may occur when pressure is exerted on the vagus nerve by neoplasms, and space occupying lesions impinging on the vagal nerve should be considered when unexplained atropine responsive bradycardia is seen. One case of sinoatrial arrest in an African Grey Parrot, which was associated with syncopal attacks, was seen at the primary author's clinic. The underlying disorder could not be determined (Figure 27.16).

If the sinoatrial node is sufficiently depressed by vagal stimulation, another part of the conducting system may take over the pacemaker function and escape beats may occur. When an electrical impulse originates

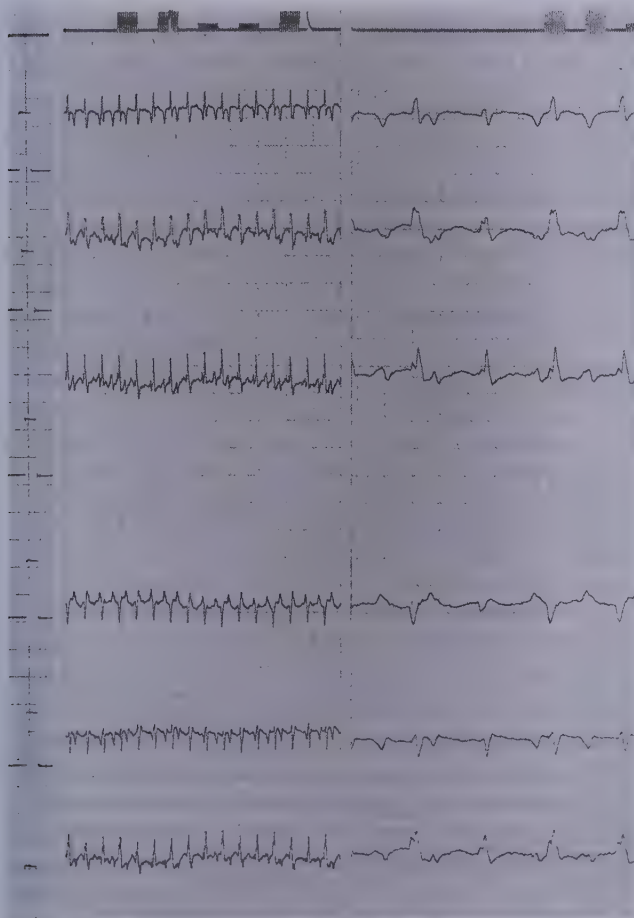
below the SA node in the atria the configuration of the P-wave will be abnormal, but positive in lead II. When an electrical impulse originates in fibers near the AV node (junctional beat), the P-wave may be absent or negative in lead II, indicating retrograde conduction (Figure 27.11). With ventricular beats the ectopic focus is localized in the fibers of the ventricle. The QRS complex is usually abnormal (but may be normal) and is unrelated to the P-wave. Atrioventricular nodal escape rhythm has been reported in ducks with sinus bradycardia induced by hyperkalemia.<sup>3</sup>

### Atrial Arrhythmias

Atrial tachycardias may be seen as a result of pathologic conditions of the atrium. Sinus tachycardia (two times normal) has been reported in chickens infected with avian influenza virus.<sup>64</sup> When the heart rate is rapid, the P-wave may be superimposed on the T-wave (P on T phenomenon). This phenomenon has been recorded in 16% of normal Amazon parrots and in six percent of African Grey Parrots.<sup>67</sup>

When (paroxysmal) supraventricular tachycardia is associated with valvular insufficiency, digoxin therapy is indicated. It is imperative to differentiate between junctional tachycardia (presence of negative P-waves due to retrograde impulse conduction) and ventricular tachycardia/atrioventricular dissociation (presence of normal P-waves that are usually not followed by a QRS complex; no retrograde impulse conduction to the atrium), because administration of digoxin may potentiate ventricular fibrillation in birds with ventricular arrhythmias.

Atrial fibrillation occurs when electrical impulses are generated in the atrium in a rapid and irregular way, and the atrium is in a state of permanent diastole. Impulses reach the AV node in a high frequency and at irregular intervals, and hence the ventricular rhythm is irregular. The ECG is characterized by the absence of normal P-waves, normal QRS complexes (which may have an increased amplitude and duration because of ventricular hypertrophy) and irregular S-S intervals. Instead of the normal P-waves,



**FIG 27.11** *History:* ECG of a 13-year-old African Grey Parrot with congestive heart failure and atherosclerosis. From top to bottom: leads I, II, III, aVR, aVL and aVF. 1 cm = 1 mV; paper speed 25 mm/s and 100 mm/s.

*Heart Rate:* Atrial rate 640, ventricular rate 480.

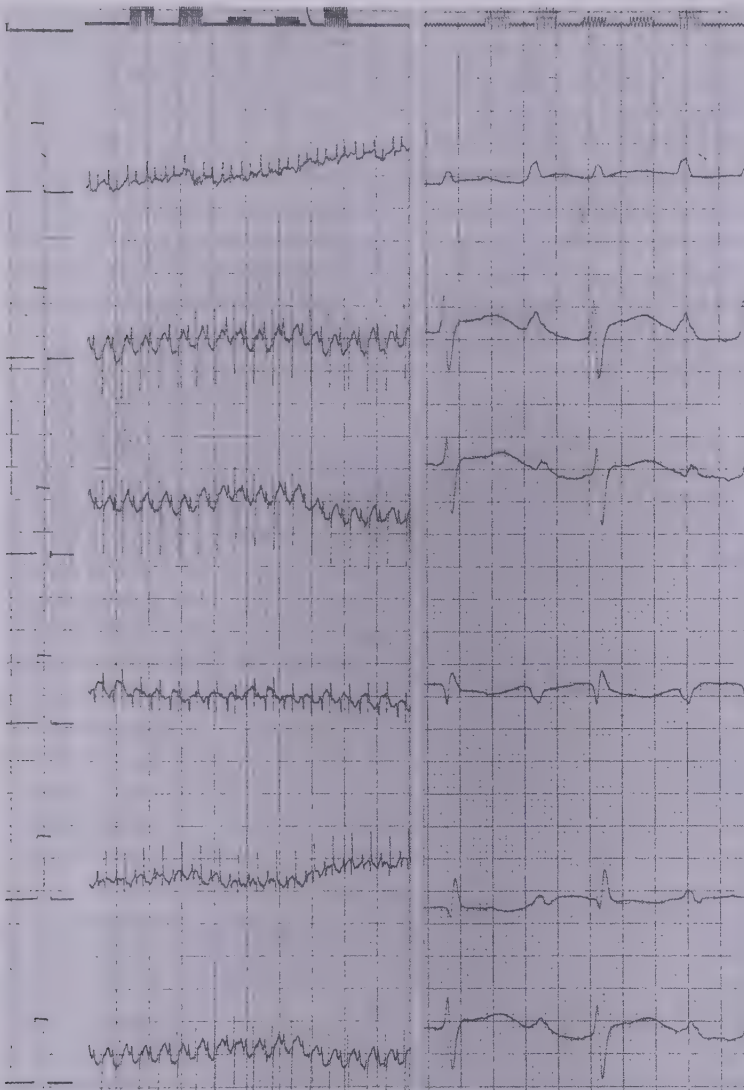
*Rhythm:* Complete AV-block with ventricular escape rhythm. (5 P-waves can be seen in lead I of the 100 mm/s ECG strip as negative deflections evenly spaced at 0.09 s. In this strip there are 4 ventricular complexes spaced at 0.12 s)

*Axis:* +80° (see below).

*Measuring:* P-wave negative in lead I and II. Bizarre ventricular complexes.

*Electrocardiographic Diagnosis:* Severe loss of function of the cardiac conduction system. Negative P-wave in lead I and II is indicative of retrograde conduction from ectopic focus in the atrium or AV-node. An idioventricular rhythm that is less than the atrial rhythm is characteristic for complete AV-block. Although there is dissociation between atrial and ventricular rhythm, the condition is not called atrioventricular dissociation because the ventricular rate is slower than the atrial rate. AV-dissociation is a form of ventricular tachycardia with a ventricular rate higher than the atrial rate. Bizarre ventricular complexes which are wide and positive in lead II are indicative of a focus in the ventricular wall, which acts as the pacemaker for the escape rhythm. The heart axis of +80° is therefore not indicative of ventricular hypertrophy.

*Clinical Findings:* This bird was presented with a two day history of dyspnea and anorexia. Radiographs indicated a marked haziness of the peritoneal cavity and a poorly defined cardiohepatic silhouette. The bird died on the second day of hospitalization. Post mortem examination revealed severe cardiomegaly, ascites and atherosclerosis of large arteries. Pulmonary edema was present also (courtesy of J. T. Lumeij).



**FIG 27.12** History: ECG of three-year-old African Grey Parrot with pericardial effusion and ascites. From top to bottom: leads I, II, III, aVR, aVL and aVF. 1 cm = 1 mV; paper speed 25 mm/s and 200 mm/s.

*Heart Rate:* 480

*Rhythm:* Normal sinus rhythm

*Axis:*  $-30^{\circ}$  to  $-60^{\circ}$

*Measurements:* P-wave = 0.015 s, 0.6 mV. QRS-complex = 0.015 s, R = 0.6 mV, QS = 0.6 mV. T-wave = 0.3 mV. QT-interval = 0.065s

*Electrocardiographic Diagnosis:* P pulmonale and prominent R-waves in leads I, II and III. Heart axis shift to  $-45^{\circ} \pm 15^{\circ}$ . These changes are consistent with right ventricular failure.

*Clinical Finding:* This bird was presented with dyspnea. Radiographs indicated an enlarged cardiac silhouette and ascites. Abnormal clinicopathologic findings included hypoproteinemia (25 g/l) and hypoalbuminemia (6 g/l). Postmortem findings included pale and enlarged kidneys (might explain proteinuria and hypoproteinemia). The pericardial sac contained a large amount of clear yellow fluid, which was also present in the peritoneal cavities. The endocardium, myocardium and epicardium were grossly normal. Renal failure, with secondary hypoalbuminemia, ascites and pericardial effusion, was considered to be the primary disease in this case. Right ventricular failure will develop before left ventricular failure because the weaker right ventricle is less able to compensate for the additional strain induced by pericardial effusion. Both P pulmonale and increased R-waves in lead II have been associated with right ventricular failure in birds (courtesy of J. T. Lumeij).

baseline undulations (F-waves) may be seen on the ECG.<sup>4,24</sup>

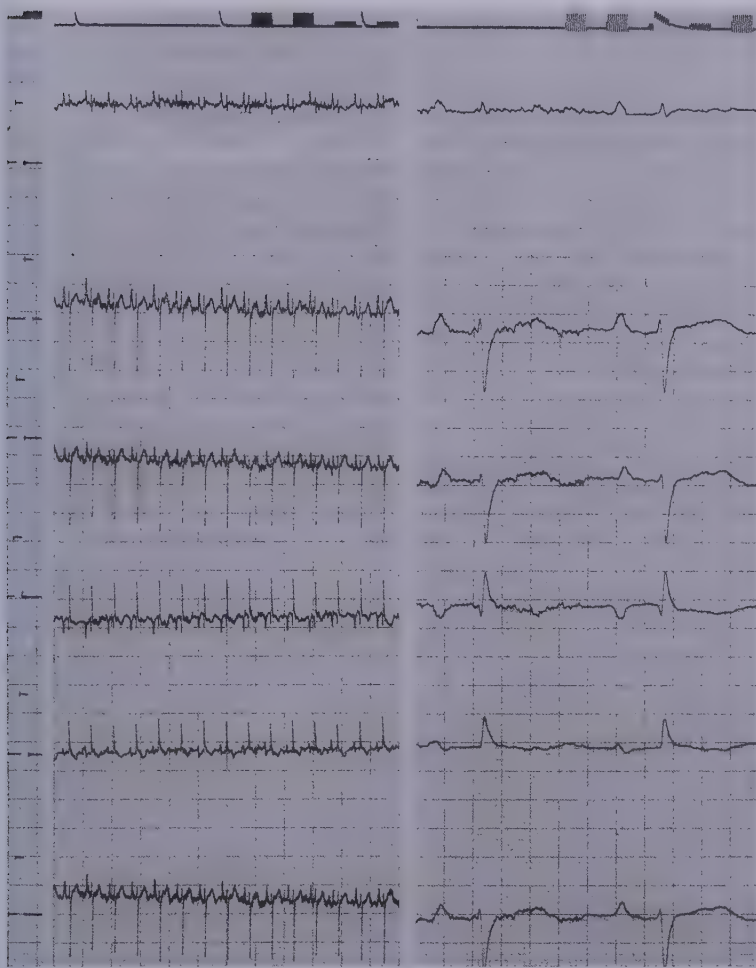
Atrial flutter is characterized by the regular occurrence of symmetrical P-waves, which appear to be saw-toothed. Usually the ventricles respond with some degree of atrioventricular block. The condition has never been reported in birds but artifacts from shivering, thermal polypnea, buccopharyngeal flutter and 60 cycle interference can be confused with atrial flutter. Atrial premature contractions, atrial fibrillation and atrial flutter are usually associated with serious atrial dilatation due to valvular insufficiency. Atrial fibrillation associated with left atrial enlargement due to mitral valve insufficiency has been reported in a Pukeko with congestive heart failure.<sup>4</sup> Digoxin is considered the treatment of choice for atrial fibrillation, but the prognosis should be guarded because of the presence of marked cardiac pathology.<sup>4,24</sup>

### Ventricular Arrhythmias

Supraventricular tachycardias may originate from the sinoatrial node (sinus tachycardia), atrium (atrial tachycardia) or junctional area (junctional tachycardia). Differentiation between sinus tachycardia and atrial tachycardia may be accomplished by measuring the P-P interval. This interval is perfectly equidistant in atrial tachycardia but may be irregular in sinus tachycardia due to vagal effects. Junctional tachycardias can be diagnosed by the presence of inverted P-waves in lead II. The most common cause of sinus tachycardia is nervousness. But it is likely that stress, pain and other known causes of sinus tachycardia in dogs (eg, electrocution) may also precipitate the condition in birds.

Ventricular premature contractions (VPCs) are characterized by QRS complexes that are unrelated to the P-waves. Two, three or four and more premature contractions of the atria, junctional area or ventricle in a row, are called a pair, run and tachycardia respectively. Bigeminy is a rhythm characterized by alternating normal beats and premature contractions, while in trigeminy two normal beats are followed by one premature contraction.





**FIG 27.13** Low voltage ECG caused by pericardial effusion in a pigeon. From top to bottom: leads I, II, III, aVR, aVL and aVF. 1 cm = 1 mV; paper speed 25 mm/s and 200 mm/s.

*Heart Rate:* 375 (SS-interval four boxes at 25 mm/s paper speed).

*Rhythm:* Sinus tachycardia.

*Axis:*  $-90^\circ$  (see Figure 27.7).

*Measuring:* P-wave = 0.015 s, 0.3 mV. PR-interval = 0.04 s. QRS-complex = 1 mV, 0.015 s. ST-segment normal. T-wave discordant, positive in lead II, 0.2 mV. QT-interval = 0.075 s.

*Electrocardiographic Diagnosis:* Sinus tachycardia, shortening of the PR-interval and low voltage QRS-complexes. Possibly pericardial effusion. The PR-interval varies inversely with heart rate, and in general is shorter when the heart rate is rapid. Pericardial effusion is the cardiovascular disease entity most often associated with low voltage complexes. Serofibrinous pericarditis was diagnosed in this bird at necropsy (courtesy of J. T. Lumeij).

Ventricular premature contractions in birds have been associated with hypokalemia,<sup>85,90</sup> thiamine deficiency,<sup>11</sup> vitamin E deficiency,<sup>88</sup> Newcastle disease and avian influenza viruses,<sup>60,64</sup> myocardial infarction due to lead poisoning<sup>80</sup> and digoxin toxicity.<sup>63</sup> The rhythm may be regular or irregular in birds with ventricular tachycardia. Positive P-waves can be identified in lead II at a lower frequency. Ventricular capture beats (normal P-QRS complexes in between

abnormal PVCs) and ventricular fusion beats (a QRS-complex intermediate between a normal P-QRS complex and a bizarre QRS-complex that is formed by the simultaneous discharge of the ectopic ventricular focus and the normal AV node) are characteristic of ventricular tachycardia.

A special form of ventricular tachycardia is atrioventricular dissociation. In this condition, the atrial and ventricular rhythms are independent of each other, whereby the atrial rate is lower than the junctional or idioventricular rate. Runs of multiple VPCs, ventricular tachycardia or a bigeminal rhythm have been reported in birds with Newcastle disease or avian influenza virus infections.<sup>64</sup>

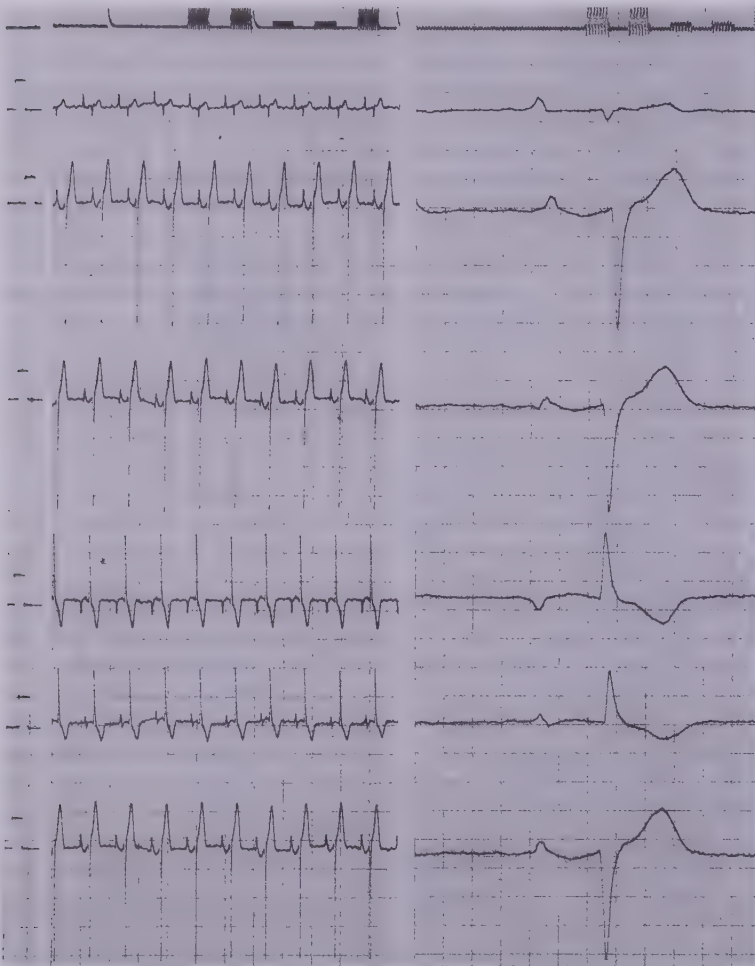
VPCs, ventricular tachycardia and ventricular fibrillation may occur during periods of hypoxia and with the use of halothane (Figure 27.17). Changes in the configuration of the T-wave should alert the clinician that myocardial hypoxia is present and more severe ECG abnormalities are imminent.

### ■ Atrioventricular Node Arrhythmias

Conduction disturbances in the atrioventricular node may lead to various gradations of atrioventricular (AV) heart block. When the impulse through only the AV node is delayed, first degree AV block is present. In second degree AV block some impulses do not reach the ventricles, but the majority of P-waves are followed by a QRS-complex. Third degree AV block or complete heart block is characterized by independent activity of atria and ventricles, whereby the frequency of the atrial depolarizations is higher than the ventricular depolarizations.

#### First-Degree Heart Block

First-degree heart block has been reported as the result of the administration of various anesthetics such as halothane<sup>63</sup> and xylazine,<sup>58</sup> whereby the PR-interval may increase to three to four times its normal value. The condition is associated with severe bradycardia. Atropine may be used to prevent or reverse the condition.<sup>58</sup>



**FIG 27.14** Ventricular hypertrophy in a pigeon. From top to bottom: leads I, II, III, aVR, aVL and aVF. 0.5 cm = 1 mV; paper speed 25 mm/s and 200 mm/s.

Heart Rate: 250.

Rhythm: Normal sinus rhythm.

Axis:  $-100^\circ$ .

Measuring: P-wave = 0.5 mV (0.25 cm at 0.5 cm = 1 mV), 0.015 s. PR-interval = 0.06 s. QRS-complex = 0.02 s (4 boxes at 200 mm/s), 4.2 mV (2.1 cm at 0.5 cm = 1 mV). ST-segment = 0.2 mV elevated. T-wave = 1.4 mV. QT-interval = 0.08 s.

Electrocardiographic Diagnosis: QRS complexes are too wide and too tall, which is suggestive of ventricular hypertrophy. Nonselective angiocardiology was performed in this pigeon. Rapid sequence serial radiographs showed impaired ventricular function (courtesy of J. T. Lumeij).

### Second-Degree Heart Block

Second-degree atrioventricular block Mobitz type 1 (Wenckebach phenomenon) has been reported as a physiologic phenomenon in five percent of trained racing pigeons<sup>56</sup> (Figure 27.18) and is seen occasionally in asymptomatic parrots<sup>67</sup> and raptors.<sup>4a</sup> In this form of AV block the PR-interval lengthens progressively until a ventricular beat is dropped. In a study with racing pigeons, second-degree AV block was observed in 24% of subclinical birds. It should be noted, however, that in the latter study the birds were re-

strained in a mechanical device during recording of the ECG. The birds had been in the device for one to two hours before ECGs were made and some of them were nearly asleep.<sup>99</sup>

Second-degree AV blocks that can be corrected with atropine have been described in several avian species. This stimulatory effect of atropine on the avian heart suggests that this agent functions, as it does in mammals, to decrease parasympathetic tone to the SA and AV nodes.<sup>63</sup> Complete AV dissociation has been documented in a parakeet.<sup>101</sup>

### Third-Degree Heart Block

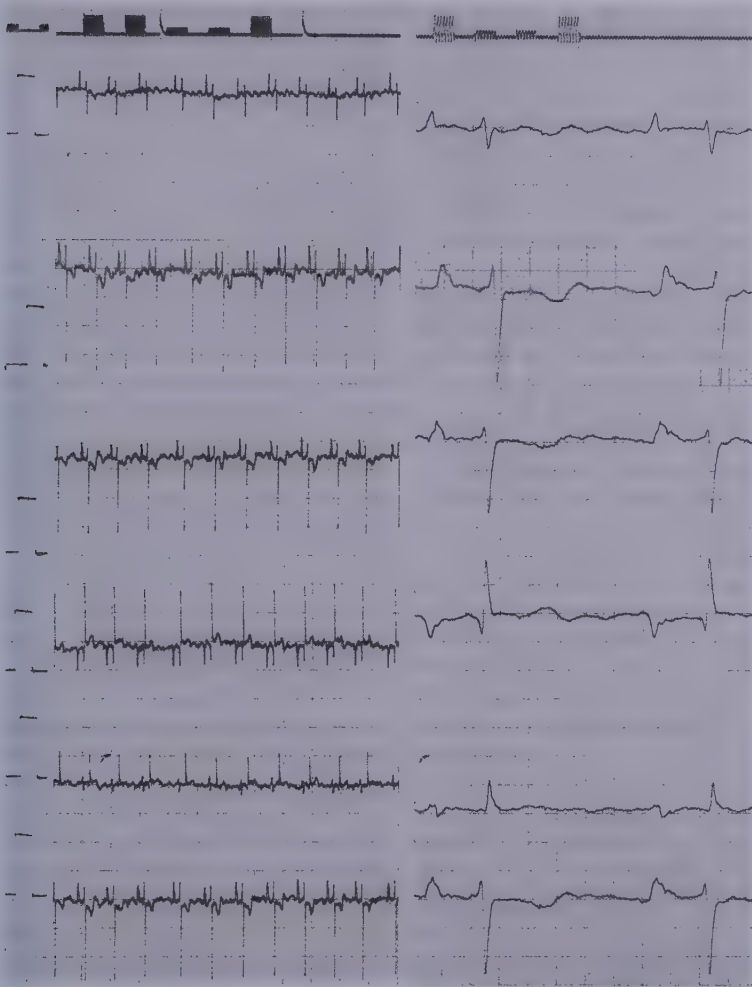
Third-degree AV block is characterized by a slow ventricular (escape) rhythm. The ventricular complexes may have a normal configuration or may be idioventricular depending on the site of ventricular impulse formation. The condition should be differentiated from atrioventricular dissociation and ventricular tachycardia whereby there is also no relation between P-waves and QRS-complexes, but wherein the ventricular rate is higher than the atrial rate.

Complete AV block with an idioventricular rhythm (auricular rate 300 and ventricular rate 200) has been seen in chickens with hypokalemia.<sup>85</sup> Complete AV block with an atrial rate of 640 and a ventricular rate of 480 was diagnosed at the primary author's clinic in an African Grey Parrot with severe cardiomegaly, ascites and atherosclerosis (see Figure 27.11).

### Intraventricular Conduction Disturbances

Intraventricular conduction disturbances such as left bundle branch block and right bundle branch block and the Wolf-Parkinson-White (WPW) syndrome have not been reported in birds. In the latter condition, an accessory pathway bypasses the AV node and conducts atrial impulses directly to the ventricles, which result in a shortened PR-interval and bizarre QRS-complexes.

There are no reports on the clinical use of antiarrhythmic agents in avian medicine, and appropriate veterinary or human textbooks should be consulted for further information.



**FIG 27.15** Electrocardiographic effects of myocardial hypoxia in a pigeon. From top to bottom: leads I, II, III, aVR, aVL and aVF. 1 cm = 1 mV; paper speed 25 mm/s and 200 mm/s.

*Heart Rate:* 300 (SS-interval is 5 boxes at 25 mm/s paper speed).

*Rhythm:* Sinus arrhythmia.

*Axis:*  $-94^\circ$  (see Figure 27.7).

*Measuring:* P-wave = 0.015 s, 0.4 mV. PR-interval = 0.05 s. QRS-complex = 0.015 s, 1.7 mV. ST-segment = 0.1 mV depressed. T-wave concordant and negative in lead II, 0.2 mV. QT-interval = 0.07 s.

*Electrocardiographic Diagnosis:* Myocardial hypoxia. In this patient hypoxia was caused by a local mycotic tracheitis causing an inspiratory stridor and severe dyspnea. ST-depression and reversal of the T-wave during anesthesia are suggestive of myocardial hypoxia (courtesy of J. T. Lumeij).

### Effects of Anesthesia

General anesthesia is typically associated with a time-related and progressive decrease in heart rate and a corresponding decrease in blood pressure. Methoxyflurane and halothane are both cardiac depressants that sensitize the heart to catecholamines. Halothane, methoxyflurane and ketamine have been reported to cause a decrease in heart rate in some

birds and an increase in heart rate in others.<sup>1,87</sup> Xylazine, acepromazine and hypothermia have all been associated with bradycardia. Atropine can be used to increase the heart rate.

With halothane and methoxyflurane, respiratory and cardiac arrest routinely occur at the same time, and recovery from an anesthetic-induced cardiac arrest is rare. With isoflurane, respiratory arrest typically occurs several minutes before cardiac arrest. Birds with severe arrhythmias induced by an overdose of isoflurane may recover with appropriate intermittent partial pressure ventilation.

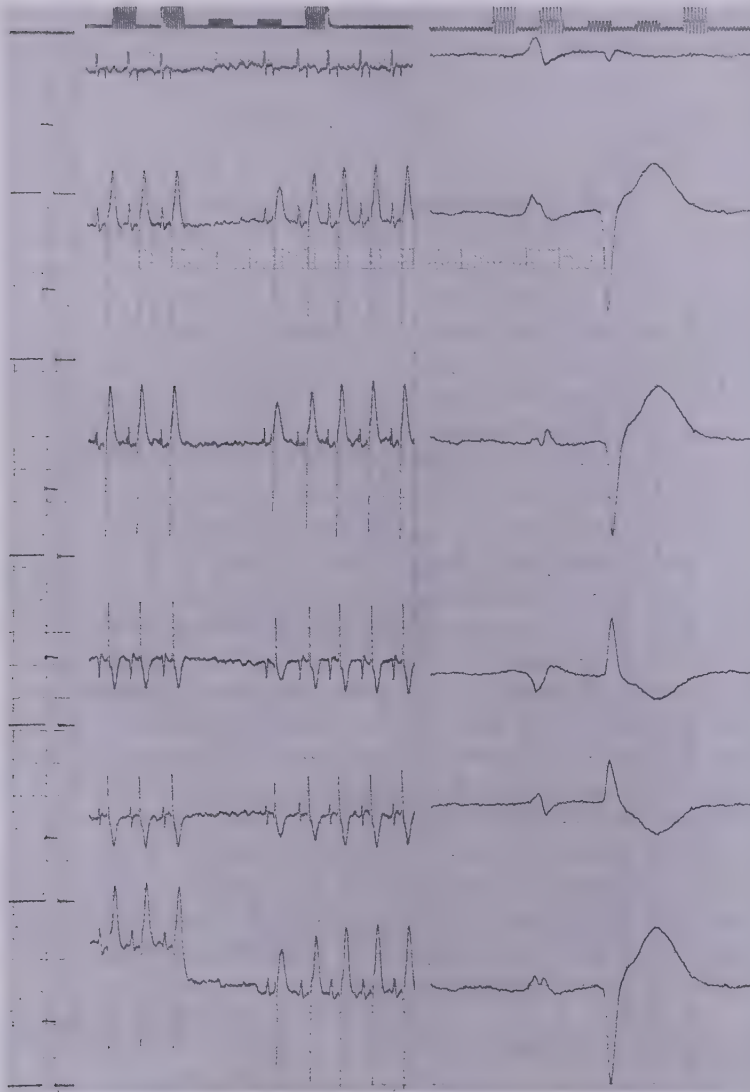
The increased PR-interval, first-degree AV block, decreased heart rate and conduction disturbances that occur with halothane anesthesia can be potentiated by the hypothermia that accompanies long-term anesthesia.<sup>1</sup> With severe hypothermia, the heart rate may decrease to less than 100 bpm with the PR-interval increasing to three to four times its normal value.<sup>63</sup>

## Cardiovascular Diseases

### Congestive Heart Failure

#### Pathogenesis

Congestive heart failure is a clinical syndrome that can be defined as the compensated condition associated with fluid retention that results from a sustained inadequacy of the cardiac output to meet the demands of the body. The causes of congestive heart failure are numerous and include endocardial, epicardial, myocardial and combined diseases. The condition should be differentiated from other causes of fluid retention (see Chapter 19). A diagnosis may be especially difficult in constrictive pericarditis because the heart is not enlarged radiographically (*pericarditis fibrinosa in organisatione* that may lead to *pericarditis adhaesiva*).



**FIG 27.16** History: ECG of a 22-year-old African Grey Parrot with syncopal attacks. From top to bottom: leads I, II, III, aVR, aVL and aVF. 1 cm = 1 mV; paper speed 25 mm/s and 200 mm/s.

Heart Rate: 240.

Rhythm: Sinoatrial arrest.

Axis:  $-90^\circ$ .

Measuring: P-wave = 0.02 s, 0.35 mV. PR-interval = 0.06 s. QRS-complex = 0.013 s. QS = 1.5 mV. T = 0.9 mV. QT-interval = 0.07 s.

**Electrocardiographic Diagnosis:** Sinus bradycardia and sinoatrial arrest. P mitrale indicative of left atrial enlargement. Repolarization changes in the ventricle are depicted by increased amplitude of the T-wave and prolongation of the QT-interval. Sinoatrial arrest and elevated T-waves are suggestive of hyperkalemia. Causes for sinoatrial arrest in birds include excessive vagal stimulation, thiamine deficiency, vitamin E deficiency and poisoning with organophosphorus compounds. The combination of P mitrale and sinoatrial arrest suggest a pathologic condition of the atrium such as atrial fibrosis or dilatation.

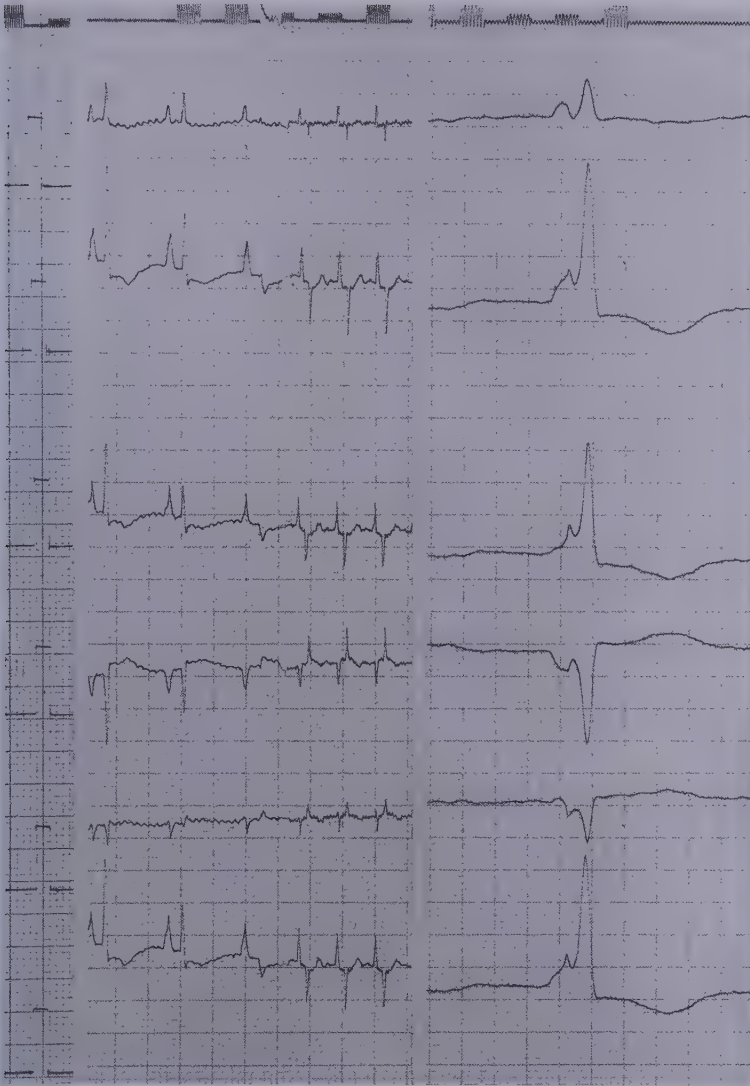
**Clinical Findings:** This bird was presented with short periods (several seconds) of syncope for several hours, two to three times a month. The bird was normal between attacks. Radiographs were unremarkable. Clinicopathologic abnormalities included leukocytosis with a left shift, hyperglobulinemia, and increased activity of AST. Potassium and calcium levels were normal. The sinoatrial arrest was considered to be a possible explanation for the observed syncopal attacks. The tentative diagnosis was bacterial/chlamydial myocarditis (courtesy of J. T. Lumeij).

The pathophysiology of congestive heart failure involves both backward failure and forward failure. Backward failure involves increased atrial and venous pressure due to a failing ventricle, while forward failure involves decreased renal blood flow resulting in sodium and fluid retention. In response to low blood volume, renin is released from the juxtaglomerular cells of the kidney. Renin acts on circulating angiotensinogen to form angiotensin I, which is converted to angiotensin II. Angiotensin II stimulates aldosterone synthesis. Aldosterone causes sodium and fluid retention.<sup>94</sup> Both mechanisms ultimately result in increased venous and capillary pressure, so that more fluid escapes by transudation in the interstitial spaces. The process is cumulative, ultimately leading to death from the local effects of fluid accumulation. (Compensated) congestive heart failure should be differentiated from (uncompensated) cardiogenic shock, which is characterized by acute cardiac dysfunction resulting in reduced arterial pressure and reduced tissue perfusion, without fluid accumulation in tissues.

Pulmonary edema predominates in isolated left ventricular disease. Systemic edema with hepatomegaly and ascites will predominate in isolated right ventricular disease, or when both ventricles are affected.

Left ventricular disease will result in increased pulmonary venous and capillary pressure. The active pulmonary constriction that occurs is known to cause an increase in pulmonary artery pressure and right ventricular failure in man. Atrial fibrillation, which is seen in left ventricular disease, presumably as a result of fibrotic changes disturbing the process of activation in the left atrium, is another contributing factor to the development of right heart failure. Closure of the left atrioventricular valves in man is dependent on the presence of atrial systole, perhaps through the effect of atrial relaxation. The resulting valvular insufficiency leads to pulmonary hypertension.

In birds, the right AV valve (muscular flap) thickens along with the right ventricle in response to an increased workload, and it has been postulated that this predisposes birds



**FIG 27.17** ECG of a Blue and Gold Macaw recovering from halothane anesthesia. From top to bottom: leads I, II, III, aVR, aVL and aVF. 1 cm = 1 mV; paper speed 25 mm/s and 200 mm/s. The 25 mm/s strip shows two idioventricular beats followed by a ventricular fusion beat and three normal P-QRS-T complexes. The 200 mm/s strip shows a bizarre QRS-complex caused by a discharge from an ectopic ventricular focus with a negative repolarization (T) wave. Halothane sensitizes the heart to adrenalin-induced arrhythmias (courtesy of J. T. Lumeij).

to right AV valvular insufficiency and right-sided heart failure.<sup>48</sup>

### Clinical Findings

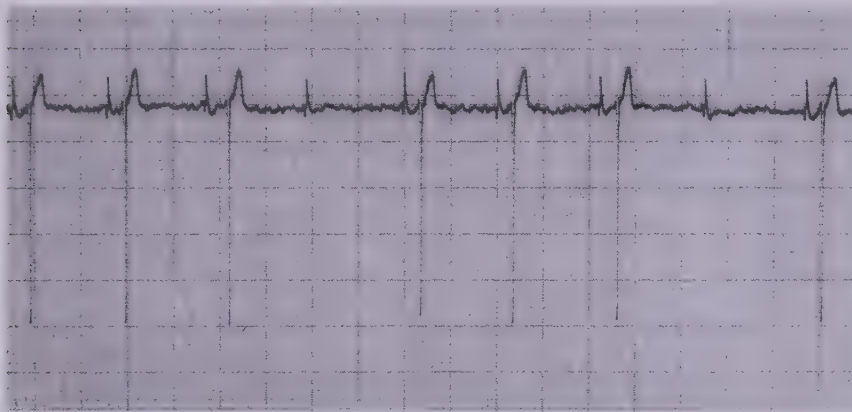
Heart enlargement with a thin left ventricular wall has been reported as a common occurrence in mynah birds.<sup>22</sup> In one study, 12 of 12 mynah birds had an abnormally thin left ventricle and ascites. The predominant clinical sign in affected birds was dyspnea (see Table 27.3). The heart lesions were associated

with liver fibrosis and end-stage iron storage disease.<sup>20</sup>

In another report, an 11-year-old mynah was presented with dyspnea, polyuria and depression. Radiographs indicated cardiohepatomegaly and ascites. Echocardiography indicated biatrial enlargement, distended hepatic vessels and ascites. Color-flow doppler indicated a mitral regurgitation and right sided heart failure. The animal responded to treatment with furosemide (2.2 mg/kg) and digoxin (0.02 mg/kg). Repeated echocardiography indicated a decrease in the size of the heart and liver.<sup>76</sup> Changing to a diet low in iron and vitamin C may have been helpful in resolving these lesions. Congestive heart failure complicated by atrial fibrillation due to mitral valve insufficiency has been reported in a Pukeko.<sup>4</sup> A number of ECGs of parrots with congestive heart failure have been documented by the primary author (Figures 27.10, 27.11, 27.19).

Spontaneous turkey cardiomyopathy (STC), and ascites associated with right ventricular failure (ARVF) in broilers have been well documented. The high incidence of cardiovascular failure in meat-type poultry is probably the result of genetic selection for rapid growth and high breast meat yield, with no attention to cardiovascular health and stress resistance. The practice of inbreeding certain species of companion birds for color or size variations could have a similar effect.

Ascites associated with right ventricular failure seems to be associated with the oxygen demand placed on the body. Ascites associated with right ventricular failure was first described at high altitudes, but it also occurs at low altitudes and is most common in rapidly growing broiler chicks, with an increased incidence in cold weather. The following pathophysiologic mechanism has been suggested for AVRF.<sup>48</sup> The relatively higher oxygen demand causes a hypoxemia, which in turn induces a polycythemia. With polycythemia, the blood is more viscous and more difficult to pump through the lungs. The increased workload results in right ventricular dilatation and hypertrophy. The resulting insufficiency of the right ventricular valve leads to RVF, with associated liver congestion and ascites. Right ventricular failure and ascites have also been reported as a result



**FIG 27.18** Normal lead III from a pigeon electrocardiogram showing Wenckebach block. The PR-interval becomes prolonged just prior to the omission of a QRS-complex.

of sodium toxicity. A moderate increase in dietary sodium for one week may cause congestive heart failure.<sup>48a</sup>

#### Treatment

Once congestive heart failure has been diagnosed, the prognosis for long-term survival is guarded, because a specific therapy is not available. A significant prolongation of life, however, can be achieved by providing timely symptomatic treatment. Treatment of congestive heart failure in birds can best be accomplished with the loop diuretic furosemide. The dosage must be adjusted for the individual bird, but 1-2 mg/kg SID or BID is a general starting point. Response to therapy should be rapid and can be best monitored by weighing the patient daily to establish the degree of fluid loss. Dosages should be tapered down to the minimal effective dose, but continuous therapy is required to prevent recurrence of fluid retention.

Side effects of furosemide administration include hypovolemia and hypokalemia. The latter is especially important when diuretics are used together with cardiac glycosides, because these drugs may also lower plasma potassium concentrations. Hypokalemia may increase the frequency of rhythm disturbances induced by cardiac glycosides.

Cardiac glycosides are indicated in congestive heart failure, especially when accompanied by atrial fibrillation. Ventricular tachycardia may be a contraindication because digitalis may induce ventricular fibrillation in these cases. Cardiac glycosides increase the contractility of the heart muscle and delay conduction through the atrioventricular node that can be seen by prolongation of the PR-interval on the electrocardiogram. Arterial pressure, cardiac output and

stroke volume are increased, while venous pressure is decreased. A decrease of the heart rate can be seen due to improvement of the circulation and parasympathetic (vagal) stimulation. Signs of toxicity include cardiac arrhythmias and gastrointestinal signs.

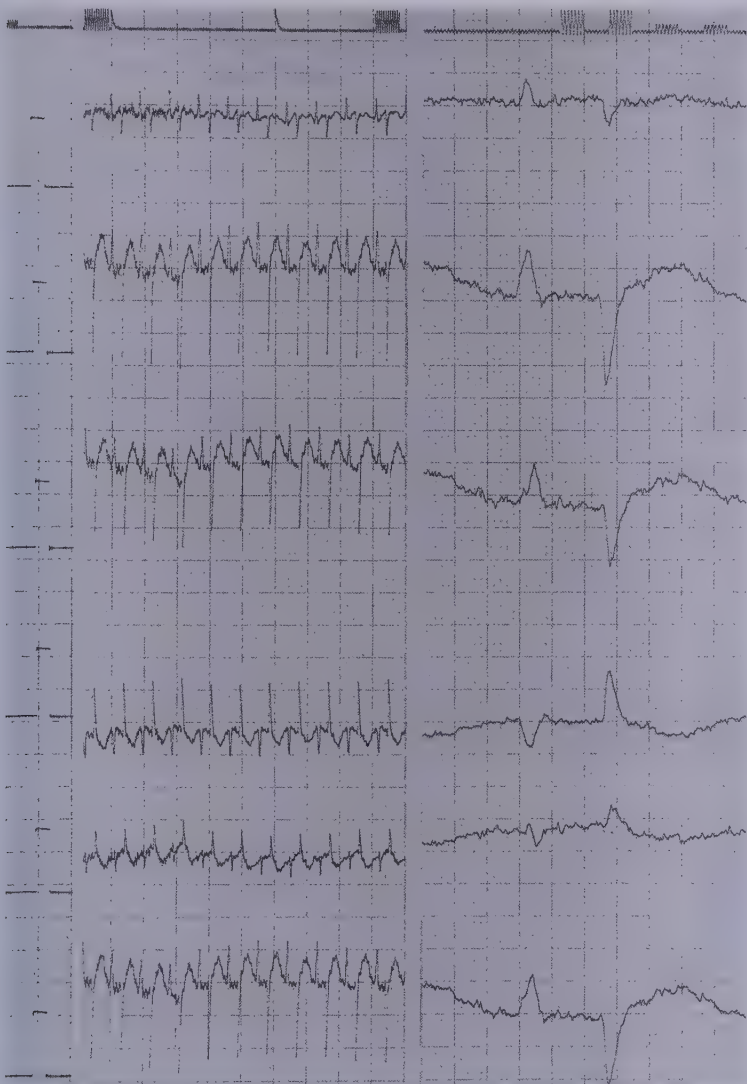
Any type of arrhythmia may result from digoxin poisoning. Digoxin therapy should be discontinued immediately if arrhythmias develop, and a lower dose regimen should be established. Diuretic-induced hypokalemia may precipitate digoxin-induced arrhythmias. Only limited

information is available with regard to digoxin therapy in birds. Digoxin appears to have varying effects among different avian species and the therapeutic index is low. Digoxin pediatric drops, rather than digoxin tablets, should be used in birds to improve the accuracy of dosing. A dose of 0.02 mg/kg daily was considered safe and produced satisfactory plasma levels of digoxin in parakeets and sparrows.<sup>35</sup> A daily dose of 0.01 mg/kg successfully reduced right ventricular enlargement and ascites in chickens.<sup>2</sup> A dose of 0.05 mg/kg/day was considered safe and produced adequate blood plasma levels in Quaker Conures (Monk Parakeet).<sup>100</sup>

Recently, angiotensin converting enzyme (ACE) inhibitors, which reduce the formation of angiotensin II, have gained considerable popularity for the treatment of congestive heart failure in man.<sup>10,15,74,79,81</sup> These drugs, including captopril and enalapril, reduce plasma volume by interfering with the renin-angiotensin-aldosterone system, and should be used in combination with a diuretic. There are no reports of the use of these drugs for the treatment of congestive heart failure in birds, but it has been shown that inhibition of endogenous angiotensin II concentrations in quail by captopril can decrease natural water intake.<sup>94</sup>

#### Vegetative Endocarditis

Endocarditis of the aortic and mitral valves may cause vascular insufficiency, lethargy and dyspnea. Valvular endocarditis is most common in birds with chronic infections (eg, salpingitis, hepatitis and bumblefoot) and has been reported in a large variety of avian species including Galliformes,<sup>7,31,69,73</sup> Anseriformes,<sup>7,96</sup> eagle,<sup>44</sup> emus,<sup>70</sup> curassow,<sup>73</sup> flamingo and a Blue and Gold Macaw.<sup>42</sup> Frequently implicated bacte-



**FIG 27.19** ECG of a 12-year-old Amazon parrot with congestive heart failure. From top to bottom: leads I, II, III, aVR, aVL and aVF. 1 cm = 1 mV; paper speed 25 mm/s and 200 mm/s.

Heart Rate: 320.

Rhythm: Normal sinus rhythm.

Axis:  $-110^\circ$  (In this series of leads there is no true isoelectric lead. The two leads that are closest to being isoelectric are lead I [0.4 mV negative] and lead aVL [0.3 mV positive]. Lead aVF is perpendicular to lead I and negative and lead II is perpendicular to lead aVL and negative. The heart axis is slightly more negative than the average between  $-120^\circ$  and  $-90^\circ$  because the positive value of lead aVL is slightly more than the negative value of lead I.)

Measurements: P-wave = 0.7 mV, 0.02 s. PR-interval = 0.065 s. QRS-complex = 0.02 s, QS = 1.3 mV. T discordant, 0.5 mV. QT-interval = 0.1 s.

Electrocardiographic Diagnosis: P pulmonale and P mitrale are indicative of biatrial enlargement. Widening of the QRS-complex and lengthening of QT-interval are indicative of left ventricular enlargement. Axis deviation to  $-110^\circ$ .

Clinical Findings: This bird was presented with dyspnea of at least four months' duration. The dyspnea had become progressively more severe for the few days before evaluation. Radiographs indicated cardiohepatomegaly. Ultrasonography revealed ascites and dilation of the hepatic veins. Total protein and protein electrophoresis were normal. Unsuccessful treatment with oxygen, gavage feeding, furosemide and digoxin was attempted. Postmortem findings confirmed cardiohepatomegaly and severe ascites. Histologic examination of the liver revealed fibrosis that was thought to have occurred secondary to right ventricular failure (courtesy of J. T. Lumeij).

**TABLE 27.3** Clinical Signs Associated with Heart Disease

Congestive Heart Failure	Arrhythmia
<ul style="list-style-type: none"> <li>▪ Dyspnea</li> <li>▪ Coughing</li> <li>▪ Weakness</li> <li>▪ Syncope</li> <li>▪ Cachexia</li> <li>▪ Reduced exercise tolerance</li> <li>▪ Sudden death</li> <li>▪ Edema and ascites</li> </ul>	<ul style="list-style-type: none"> <li>▪ Asymptomatic</li> <li>▪ Dyspnea</li> <li>▪ Coughing</li> <li>▪ Weakness</li> <li>▪ Syncope</li> <li>▪ Sudden death</li> </ul>

ria include streptococci, staphylococci, *E. coli*, *Pasteurella*, *Pseudomonas aeruginosa* and *Erysipelothrix rhusiopathiae*. In pigeons, trichomoniasis has been reported as a cause of valvular endocarditis.<sup>31</sup>


Lesions consist of yellow irregular masses on any of the heart valves. The disease is associated with bacteremia, and thromboembolisms may occur throughout the vasculature.<sup>31,36,69,70</sup> Secondary lesions have been described in the liver, CNS, spleen, heart, lungs, kidneys, ischiatic artery and external iliac artery (Figure 27.20).<sup>36,70</sup>

Any alteration in blood flow through the heart could predispose a bird to endocarditis. The initial damage to the heart valves that induces vegetative endocarditis is usually unknown. Factors that have been associated with endocardial or valvular lesions include chronic bacterial septicemia, frostbite, congenital lesions (that alter blood flow) and degenerative myocarditis.<sup>4,36,44,70,98</sup>

### Clinical Findings

Valvular endocarditis and vascular insufficiency are frequently associated with lethargy and dyspnea, although the clinical presentation can vary. A six-year-old Blue and Gold Macaw was presented with anorexia, tachypnea, mild dyspnea and weight loss. A mild systolic murmur, which could best be auscultated over the left pectoral muscles, was noted on physical examination. *Enterobacter cloacae* was isolated from the blood in pure culture. Vegetative endocarditis of the left AV valve was diagnosed (Figure 27.21).<sup>42</sup>

*Erysipelothrix rhusiopathiae* was recovered from mitral and tricuspid valve lesions of a subclinical seven-year-old female swan that was found dead in her enclosure.<sup>36</sup>



**FIG 27.20** A four-year-old emu with a six-week history of lethargy, anorexia and inability to stand had a mild systolic murmur. Abnormal clinical pathology findings included an elevated AST (6000 IU/l) and anemia (PCV=27%). Electrocardiography revealed a heart rate = 120, P-wave = 0.3 mV, PR-interval = 150 mS, R-wave = 0.15 mV, S-wave = 1.3 mV, QRS-complex = 40 mS, mean electrical axis =  $-90^\circ$ . Echocardiography indicated a large mass on the aortic valve. **a**) *Staphylococcus* was isolated from vegetative endocardial lesions (arrows). **b**) Ischemic infarcts were found in several large muscle masses, and a thrombus was present in the left external iliac artery (arrow) (courtesy of John Randolph, reprinted with permission<sup>70</sup>).

A six-year-old curassow was presented with lethargy and a cool edematous left leg. Radiography revealed cardiomegaly and enlargement of a brachiocephalic artery. Abnormal clinicopathologic findings included heterophilia (60,000/l with toxic changes), and elevated plasma activities of LDH and CPK (4108 IU/l and 6,692 IU/l, respectively). *Staphylococcus*-induced lesions were found on the left AV valve. Septic thrombi were present in the left brachial artery.<sup>73</sup>

## Myocardial Diseases

### Congenital Heart Disease

A list of common avian heart diseases and some of their etiologies are listed in Table 27.4. Chicken embryos are classic experimental animals to study teratologic effects of drugs on the heart. Various cardiovascular malformations can experimentally be induced, especially intraventricular septal defects. Spontaneous cardiovascular malformations like duplicitas cordis, multiplicatis cordis, ectopia cordis have been reported.<sup>31</sup> Intraventricular septal defects are common, while foramen ovale persistens is of little clinical importance. Intraventricular septal defects are usually functionally closed, but in two percent of cases the condition is associated with congestive heart failure. Blood is shunted from left to right, which leads to right ventricular failure and ascites secondary to valvular insufficiency.

### Acquired Diseases

In mammals, myocarditis can occur secondary to many common viral, bacterial, mycotic and protozoan infections. Cardiomyopathy has been associated with thyroid diseases, anemia, malnutrition, metabolic disorders, parasitic infections, pancreatitis, toxemias and neoplasia.<sup>24</sup> The pathogenesis of cardiomyopathy and myocarditis in birds is similar to that described in mammals.<sup>31</sup> The liver and myocardium can be sites of excessive iron storage in birds with hemochromatosis. Experimental *E. coli* infections have been shown to cause myocarditis and pericarditis with marked electrocardiographic changes, including left axis deviation.<sup>32</sup>

Fowl plague has been associated with myocardial lesions in a variety of avian species.<sup>60</sup> Myocarditis has been reported as a component of neuropathic gastric dilatation in psittacines.<sup>97</sup> Sarcocysts (muscle cysts containing bradyzoites, the asexual generation of *Sarcocystis* spp.) have been reported in the myocardium of a variety of avian species.<sup>23,55,66</sup> A number of idiopathic degenerative conditions of the myocardium have been reported in gallinaceous birds.

Spontaneous turkey cardiomyopathy (STC, round heart disease, cardiohepatic syndrome) in turkey poults one to four weeks of age is characterized by marked dilatation of the right ventricle with extreme thinning of the ventricular wall.<sup>75</sup> Generally, ascites, hydropericardium and liver congestion are present.<sup>41,75</sup> Although the major increase in heart size is caused by the right ventricular dilatation, there is also an increase in total mass of both ventricles, with



TABLE 27.4 Some Common Causes of Heart Lesions in Birds

Pericarditis	Myocarditis
<i>Listeria</i>	<i>Listeria</i>
<i>E. coli</i> septicemia	<i>E. coli</i> septicemia
<i>Chlamydia</i>	<i>Pasteurella</i>
<i>Salmonella</i>	<i>Chlamydia</i>
Reovirus (Galliformes)	Polyomavirus
Concurrent respiratory disease	Avian serositis virus
	<i>Sarcocystis</i>
	Neuropathic gastric dilatation
	Selenium and vitamin E deficiencies
Cardiomegaly	Hydropericardium
Polyomavirus	Polyomavirus
Hemochromatosis	Reovirus (Galliformes)
Epicarditis	Furazolidone toxicity
<i>Salmonella</i>	Genetics
<i>Pasteurella</i>	

a relatively greater increase in the left.<sup>40</sup> Lungs are generally congested and edematous.<sup>75</sup> Although the etiology of STC is unknown, it is clinically associated with rapid growth and hypoxic conditions (eg, low oxygen levels in the incubator and poor ventilation).<sup>47,47b</sup> Lesions induced by feeding ducklings, chicks and turkey poults furazolidone (300 ppm of feed) are indistinguishable from those described with STC.<sup>18,47,72</sup>

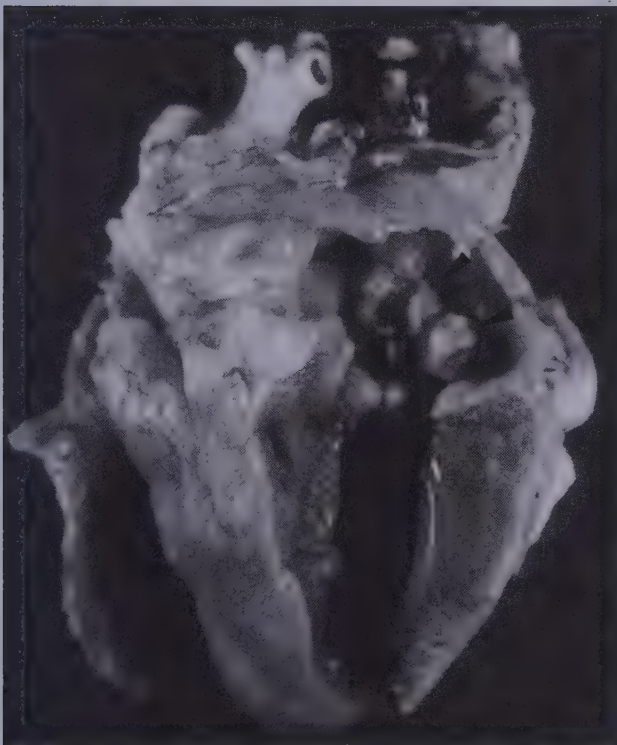

FIG 27.21 Valvular endocarditis on the left atrioventricular valve (arrows) from a Blue and Gold Macaw (courtesy of Ramiro Issaz, reprinted with permission<sup>42</sup>).

Myocardial degeneration (round heart disease) of unknown etiology has been described in backyard poultry. The morbidity is very low, but mortality may reach 50%. Lesions consist generally of an enlarged and yellowish heart. A few affected birds may have an excess of gelatinous fluid in the pericardial sac or peritoneal cavity.<sup>69,75</sup> The disease should not be confused with STC.

Vitamin E and selenium deficiencies are well known as causes for cardiomyopathy in gallinaceous birds.<sup>78</sup> Selenium and vitamin E deficiencies have also been suggested as causes for myocardial and skeletal muscle degeneration in ratites less than six months old that died after a brief period of depression (see Chapter 48). Histologic lesions in the heart of these birds were similar to those reported in poultry with vitamin E and selenium deficiencies.<sup>71</sup> Vitamin E and selenium deficiencies have also been suggested as causes of myocardial degeneration in cockatiels. Affected birds typically have increased activities of SGOT and CPK, decreased heart tone and an increase in pericardial fluid.<sup>38</sup>

Various benign and malignant primary myocardial tumors arising from connective tissue or from muscle have been reported occasionally (see Chapter 25).<sup>31</sup>

Ruptures of the myocardium may occur secondary to degenerative, inflammatory or neoplastic conditions of the myocardium or aneurysms of the myocardial vessels (see Color 48).<sup>31</sup> Myocardial infarctions may result from embolisms originating from valvular endocarditis or heavy metal poisoning.<sup>80,86</sup> In White Carneaux Pigeons, myocardial infarcts have been reported after ulceration and embolism of atheromas in the aortic trunk.<sup>31</sup>

All conditions that lead to cardiomyopathy or myocarditis may result in increased myocardial irritability and cardiac arrhythmias that can be detected by ECG. Radiographs may reveal cardiomegaly (Figure 27.22). Electrocardiography has been shown to be effective for diagnosing both spontaneous and furazolidone-induced cardiomyopathy.<sup>40,46</sup> Characteristic changes include a right axis deviation from negative to positive, ie, from an average of  $-85^\circ$  (range  $-60^\circ$  to  $-120^\circ$ ) to an average of  $70^\circ$  (range  $32^\circ$  to  $95^\circ$ ).<sup>41</sup> The amplitude of the P-wave is increased and the T-wave is negative in leads I, II and III. Similar ECG findings have been reported in psittacine birds with cardiomyopathy.<sup>63</sup>

Treatment of myocardial disease should be aimed at the primary cause. Furthermore, symptomatic treat-

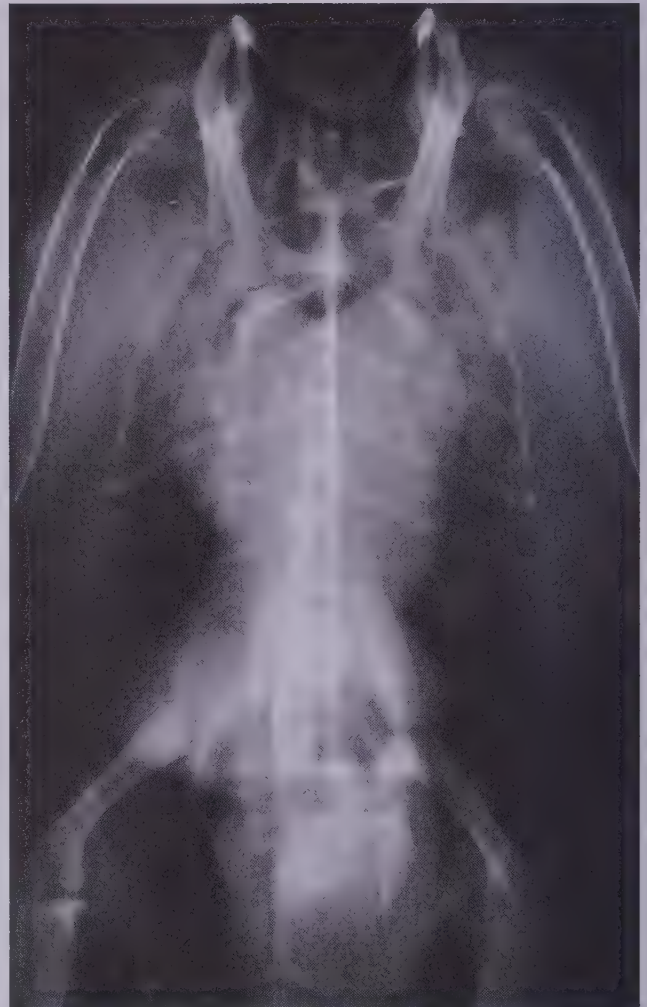ment is indicated. Digoxin can be used when cardiac output is diminished due to myocardial disease, but is contraindicated when persistent ventricular arrhythmias are present. Digoxin treatment should be discontinued if the severity of an arrhythmia increases.

### ■ Epicardial and Pericardial Diseases<sup>31</sup>

Pericardial effusion is a common finding in birds. The accumulated fluid may be a result of cardiac or systemic disease and may be of an inflammatory or noninflammatory nature (see Color 14). Pericardial effusion may be part of generalized ascites. Transudates can occur with congestive heart failure and hypoproteinemia. Exudates may be present in a variety of infectious diseases. Fibrinous pericarditis is most common and may lead to adhesions of the epicardium to the pericardium and to constrictive heart failure (see Color 14). A serofibrinous pericarditis may occur in conjunction with a variety of bacterial (eg, *E. coli*, *Streptococcus* spp., *Listeria*, *Salmonella*) and viral (eg, reovirus in Galliformes, polyomavirus infections in Psittaciformes) diseases, and can also be seen in chlamydiosis and mycoplasmosis. Occasionally tuberculous or mycotic pericarditis can be encountered. *Pericarditis urica* may occur in birds with visceral gout (see Color 21). Hemopericardium may be the result of puncture of the epicardium by a foreign body, iatrogenic puncture of the heart, cardiac tumors, rupture of the left atrium or myocardial rupture.

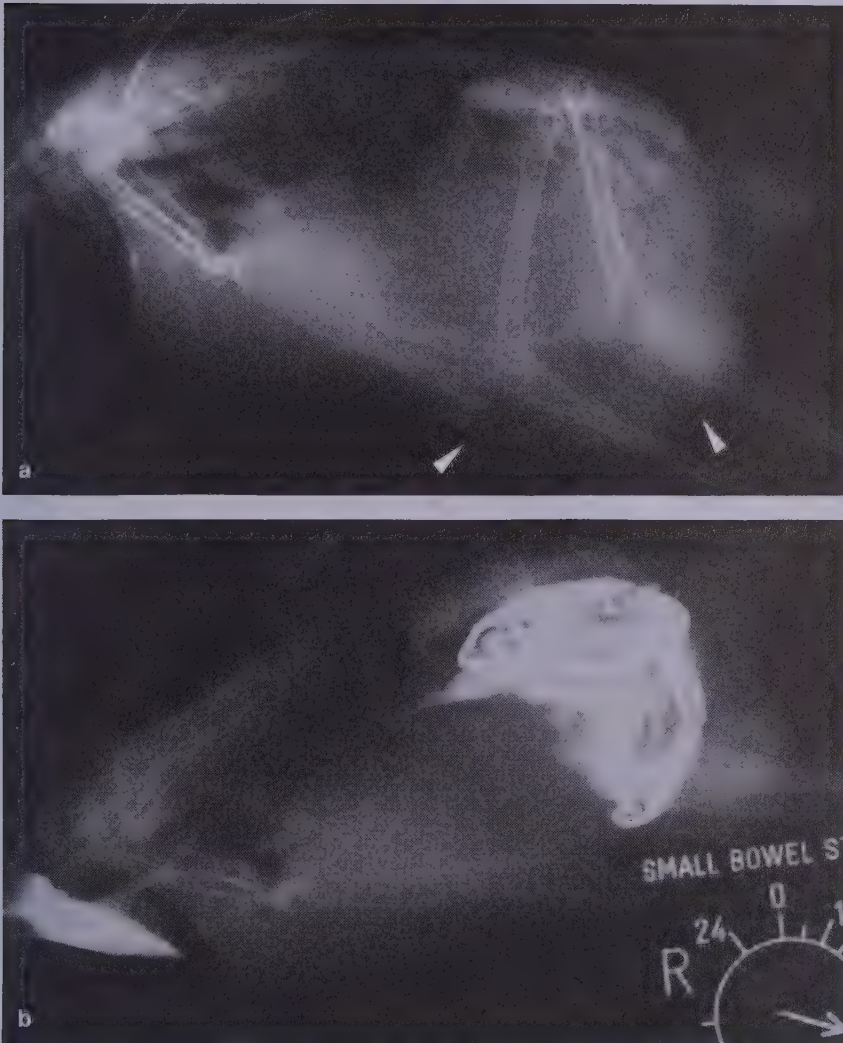
Pericardial effusion may eventually result in heart failure. When a pericardial effusion develops rapidly, the circulatory system will not have time to compensate for the reduced cardiac output, and acute death occurs from cardiac tamponade.

Diagnostic techniques that may be of use in diagnosing pericardial effusion include radiography, electrocardiography, ultrasonography and endoscopy (Figure 27.23). Enlargement of the cardiac silhouette on radiographs may be caused both by cardiomegaly and pericardial effusion, and other techniques are needed to differentiate between these conditions. Ultrasonography is a useful method to demonstrate a pericardial effusion. Electrocardiography may reveal a low voltage ECG. Marked changes in the electrocardiogram, including left axis deviation, have been reported in *E. coli*-induced pericarditis and myocarditis in chickens.<sup>32</sup>



**FIG 27.22** An adult male duck was presented for dyspnea, coughing and syncope. The clinical signs were exaggerated by mild exercise. Radiographs indicated severe cardiomegaly. ECG and ultrasound diagnostics were refused. Other radiographic findings included a large amount of grit in the ventriculus and irregular mineral densities in the medullary canal of the femurs.

Fluid for bacteriology, cytology and clinical chemistries can be collected from the pericardial sac, using endoscopy (see Chapter 13). Treatment for pericardial effusion should be both symptomatic and aimed at treating the underlying condition (eg, antibiotics in bacterial pericarditis). Symptomatic treatment can be attempted with furosemide. If sufficient quantities of nonserosanguinous pericardial fluid cannot be removed by conventional means to avoid the occurrence of cardiac tamponade, then it is necessary to create a surgical window in the pericardium.<sup>24</sup> This technique was used successfully in an African Grey Parrot presented with congestive heart failure and idiopathic pericardial effusion.



**FIG 27.23** An adult Amazon parrot was presented for emaciation (254 g), a swollen abdomen and passing whole seeds. The referring veterinarian diagnosed NGD based on survey radiographs and clinical findings. **a)** Survey radiographs indicated a diffuse soft tissue density in the thorax and abdomen. Note the distension (arrows) of the abdominal wall. **b)** A barium contrast study indicated that the proventriculus was being displaced dorsally, and the intestinal tract was being displaced dorsally and caudally by an abdominal mass (suspected to be the liver). The heart was also considered to be enlarged, and the nondistinct edge of the cardiac silhouette was suggestive of pericardial effusion. Ultrasound confirmed pericardial effusion and hepatomegaly.

### Atherosclerosis

Atherosclerosis can be defined as a diffuse or local degenerative condition of the internal and medial tunics of the wall of muscular and elastic arteries. The degenerative changes include proliferation of smooth muscle cells, deposition of collagen and proteoglycans and deposition of cholesterol (esters).<sup>45</sup> Calcium deposits may sometimes be encountered. The lesions can macroscopically be identified by

thickening and yellow discoloration of the arterial wall (see Color 14).

Atherosclerosis has been reported in many avian orders, but Psittaciformes (parrots)<sup>27,45</sup> and Anseriformes (ducks and geese)<sup>27</sup> appear to be particularly susceptible. Amazon parrots seem to be specifically prone to atherosclerosis, and age appears to be a risk factor.<sup>45</sup> Ciconiiformes (flamingos, herons, storks), Falconiformes (vultures, falcons, eagles), Galliformes (pheasants, turkeys, fowl), Gruiformes (cranes), Columbiformes (pigeons), Cuculiformes, Coraciiformes, and Piciformes (toucans) are moderately susceptible. Atherosclerosis has also been seen in other species such as ostriches, penguins, cormorants, free-ranging owls, and various Passeriformes, including birds of paradise.<sup>27,62,65</sup> In a retrospective study involving 12,072 companion and aviary birds, atherosclerosis was detected in 53 birds of six orders (Table 27.5).<sup>45</sup>

### Pathogenesis

In man, atherosclerosis of the coronary arteries is a major source of morbidity and mortality in affluent societies, and elevated serum lipids (cholesterol, triglycerides, low-density lipoproteins), hypertension and exposure to cigarette smoke are important risk factors.

The accumulation of pathogenic material in the arterial wall has been explained by the insudative theory.<sup>14</sup> Normally a transfer of plasma proteins occurs through the arterial wall with subsequent removal from the

outer coats by lymphatic vessels. During this process of permeation, fibrinogen and very low density lipoproteins are selectively entrapped in the connective tissue of the arterial wall. Their presence stimulates reactive changes that give rise to the production of atherosclerotic lesions. Variations in vascular permeability and arterial blood pressure can explain the preference of atherosclerotic lesions for certain areas of the arterial system.

TABLE 27.5 Retrospective Study of Avian Atherosclerosis<sup>45</sup>

Order	Number Affected	Anatomic Location
Psittaciformes	43	aorta (34) myocardial vessels (8) brachiocephalic trunk (7) splenic arteries (5) pulmonary artery (3)
Falconiformes	6	aorta (6) minor lesions in other vessels
Piciformes	1	aorta
Passeriformes	1	aorta
Strigiformes	1	aorta
Struthioniformes	1	mesenteric artery

In man, systemic hypertension is known to accelerate atherosclerotic diseases and atherosclerotic lesions are often seen in high pressure areas of the arterial system. Atherosclerosis in the pulmonary arteries is rare and seen only with pulmonary hypertension.

In birds, atherosclerotic lesions are usually found in the brachiocephalic trunk and abdominal aorta (Figure 27.24). Lesions in the internal carotid arteries also occur with some frequency. Atherosclerotic lesions in the coronary artery are not as common in birds as in man, but have been reported.<sup>45</sup> Atherosclerotic lesions have not been described in the brain, and lesions in the pulmonary artery are rare.

The risk factors associated with development of atherosclerosis in birds have been insufficiently studied;



FIG 27.24 Atherosclerosis can be macroscopically identified by thickening and yellow discoloration of the arterial wall. Note the irregular margins to the great vessels in this 20-year-old rosella.

however, at least three of the risk factors that occur in humans (ie, obesity, high-fat diets and exposure to cigarette smoke) frequently occur in companion birds. In one study of birds from a zoological collection, the incidence of atherosclerosis was higher in females and carnivores than in males and granivores.<sup>65</sup> Free-ranging turkeys from colder environments have a higher incidence of atherosclerosis than birds from warmer environments, suggesting that cold stress may play a role in the pathogenesis of this disease.<sup>54</sup>

In one study, 86% of the Amazon parrots with atherosclerosis were over five years;<sup>45</sup> however, in another study an age or species predilection to atherosclerosis among zoo and aviary birds was not found to occur. Atherosclerosis and congestive heart failure should be considered in any geriatric patient with lethargy, dyspnea, coughing or abdominal swelling (ascites).<sup>65</sup>

Marek's disease virus infections of arterial smooth muscle cells induce an altered lipid metabolism that can result in the accumulation of phospholipids, free fatty acids, cholesterol and cholesterol esters.<sup>26,34</sup> White Carneaux Pigeons that are genetically predisposed to atherosclerosis are extensively used in studies of this disease.<sup>77</sup>

### Clinical Changes

Clinical signs associated with atherosclerosis are caused by decreased blood flow through the affected vessels and plaque-induced thrombi that cause vascular accidents.

Clinical signs of atherosclerosis are rarely reported in birds, and the condition is often associated with sudden death; however, subtle and intermittent signs that include dyspnea, weakness and neurologic signs may be present. Regurgitation from an undocumented cause is common. Blood chemistry may reveal elevated plasma cholesterol. Radiologic examination may reveal an increased density and size of the right aortic arch. Nodular densities cranial to the heart may be caused by large arteries with atherosclerotic changes that are seen end on.<sup>45</sup>

Galliformes and Anseriformes may die acutely from dissecting aneurysms that result in aortic rupture secondary to hypertension and atherosclerosis. The abdominal aorta and aortic arch are the two vessels that are most frequently affected. In some species, males tend to have more severe lesions in the abdominal aorta, while females most frequently develop lesions in the aortic arch.

Atherosclerosis was diagnosed at necropsy in a seven-year-old female Blue-fronted Amazon with a two-month history of regurgitation and stupor. Lesions were noted over the entire length of the aorta and brachiocephalic trunk. The lumen of the carotid arteries were reduced up to 95%. Lesions were noted also in the small arteries in the epicardium, myocardium and the renal artery. Clinicopathologic findings were unremarkable. Radiographs indicated a prominent aortic arch and pulmonary vein.<sup>45</sup>

Atherosclerosis involving the aorta, brachiocephalic trunk and axillary arteries was described in an 18-year-old male African Grey Parrot with weight loss, dyspnea and rhinitis. A concomitant respiratory bacterial infection was also present.<sup>45</sup>

Coronary atherosclerosis was documented in 75% of the birds that were necropsied in one zoological collection. The most severe vascular lesions occurred in birds that also had thyroid abnormalities.<sup>65</sup> A few birds, including an ostrich and a hornbill with atherosclerosis, showed signs of chronic weakness prior to death. Lesions in parrots have been described most frequently in the aorta and its major branches.<sup>13</sup>

## Aortic Rupture

Aortic rupture in turkeys is a condition associated with fatal hemorrhage from a ruptured aorta. The disease is especially common in male turkeys between 6 and 24 weeks of age with the highest mortality seen between three and four months. The location between the external iliac and ischiatic arteries is the most common site, but the aorta may rupture at another site just dorsal to the heart. In turkey hens a rupture of the left atrium may occur. The precise etiology is unknown, but the disease is associated with hypertension, degenerative changes of the aorta wall (atherosclerosis, qv), copper deficiency and high levels of protein and fat in the diet (see Color 48). Similar lesions may be induced in turkeys by ingestion of the sweet pea (*Lathyrus odoratus*).<sup>48,75</sup>

### Product Mentioned in the Text

- a. Platinum Subdermal Electrodes Type E2. Grass Instrument Company, Quincy MA.

### References and Suggested Reading

1. **Altman RB, Miller MS:** Effects of anesthesia on the temperature and electrocardiogram of birds. *Proc Assoc Zoo Vet*, 1979, pp 61-62.
2. **Alvarez Maldonado MVZ:** Report preeliminar. Digitalizacion en pollos de engorda como metodo preventivo en el sindrome ascitico. *Proc 35th West Poult Dis Conf*, 1986.
3. **Andersen HT:** Hyperpotassemia and electrocardiographic changes in the duck during prolonged diving. *Acta Physiol Scand* 63:292-295, 1975.
4. **Beehler BA, Montali RJ, Bush M:** Mitral valve insufficiency with congestive heart failure in a Pukeko. *J Am Vet Med Assoc* 177:934-937, 1980.
- 4a. **Blanco JM:** Avian electrocardiography: A contribution for the practitioner. *Proc Europ Assoc Avian Vet*, Utrecht, 1993, pp 137-154.
5. **Bolton GR:** Handbook of Canine Electrocardiography. Philadelphia, WB Saunders Co, 1975.
6. **Boulianne M, et al:** Cardiac muscle mass distribution in the domestic turkey and relationship to electrocardiogram. *Avian Dis* 36:582-589, 1992.
7. **Bricker JM, Saif YM:** Erysipelas. In Calnek BW, et al (eds): *Diseases of Poultry*. Ames, Iowa State University Press, 1991, pp 247-257.
8. **Buchanan F:** The frequency of the heart beat and the form of the electrocardiogram in birds. *Proc Physiol Soc*, J Physiol 38:lxii-lxvi, 1909.
9. **Calnek BW, et al (eds):** *Diseases of Poultry*. Ames, Iowa State University Press, 1991.
10. **Captopril Multicenter Research Group:** A placebo-controlled trial in refractory chronic congestive heart failure. *J Am Coll Cardiol* 2:765-763, 1983.
11. **Carter CW, Drury AN:** Heart block in rice fed pigeons. *J Physiol* 68:i-ii (Proc), 1929.
12. **Castellanos A, Meyerburg RJ:** The resting electrocardiogram. In Hurst JE (ed): *The Heart* 6th ed. New York, McGraw Hill Book Company, 1986, pp 206-229.
13. **Coffin DL:** Angell Memorial Parakeet and Parrot Book. Boston, Angell Memorial Veterinary Hospital, 1953.
14. **Colhart DJ:** Ischaemic heart disease. In Scott RB (ed): *Price's Textbook on the Practice of Medicine* 12th ed. Oxford, Oxford University Press, 1978, pp 787-802.
15. **Consensus Trial Study Group:** Effects of enalapril on mortality in severe congestive heart failure. *N Engl J Med* 316:1429-1435, 1987.
16. **Crawley RR, Ernst JV, Milton JL:** Sarcocystis in a bald eagle. *J Wildl Dis* 18:253-255, 1992.
17. **Czarnecki CM, Good AL:** Electrocardiographic technique for identifying developing cardiomyopathies in young turkey poults. *Poult Sci* 59:1515-1520, 1980.
18. **Czarnecki CM:** Cardiomyopathy in turkeys (a review). *Comp Biochem Physiol* 77A:591-598, 1984.
19. **Domingo M et al:** Heart rupture and haemopericardium in capercaillie (*Tetrao urogallus*) reared in captivity. *Avian Pathol* 20:363-366, 1991.
20. **Dorrestein GM, Van der Hage MH:** Veterinary problems in mynah birds. *Proc Assoc Avian Vet*, 1983, pp 263-274.
21. **Edjehadi M, Rezakhani A, Szabuniewicz M:** The electrocardiogram of the Buzzard (*Buteo*). *Zentralblatt fuer Veterinaermedizin A* 24:597-600, 1977.
22. **Ensley PK, Hatkin J, Silverman S:** Congestive heart failure in a greater hill mynah. *J Am Vet Med Assoc* 175:1010-1013, 1979.
23. **Erickson AB:** Sarcocystis in birds. *Auk* 57:514-519, 1940.
24. **Etinger SJ, Suter PF:** *Canine Cardiology*. Philadelphia, WB Saunders Co, 1970.
25. **Fabricant CG, et al:** Virus-induced atherosclerosis. *J Exp Med* 148:335-340, 1978.
26. **Fabricant CG, et al:** Herpesvirus infection enhances cholesterol and cholesteryl ester accumulation in cultured arterial smooth muscle cells. *Am J Pathol* 105:176-184, 1981.
27. **Fiennes RN T-W:** Diseases of the cardiovascular system. In Petrak ML (ed): *Diseases of Cage and Aviary Birds* 2nd ed. Philadelphia, Lea & Febiger, 1982, pp 422-431.
28. **Gabrashanski P, Georgiev Ch:** Untersuchungen ueber die Perikarditis, 'Rundherzkrankheit' und Endokarditis bei den Truthuehnern unter besonderer Beruecksichtigung der Veraenderungen im Elektrokardiogramm. *Deutsche tieraerztliche Wochenschrift* 78:389-412, 1971).
29. **Gaskin JM, Homer BL, Eskelund KH:** Preliminary findings in avian viral serositis, a newly recognized syndrome in psittacines. *J Assoc Avian Vet* 5:27-34, 1991.
30. **Good AL, Czarnecki CM:** The production of cardiomyopathy in turkey poults by the oral administration of furazolidone. *Avian Dis* 24:980-988, 1980.
31. **Gratzl E, Koehler H:** Spezielle Pathologie und Therapie der Gefluesselkrankheiten. [Pathology and Therapy of Poultry Diseases]. Stuttgart, Ferdinand Enke Verlag, 1968, pp 1028-1038.
32. **Gross WB:** Electrocardiographic changes of *Escherichia coli* infected birds. *Am J Vet Res* 27:1427-1436, 1966.
33. **Grubb B:** Allometric relations of cardiovascular function in birds. *Am J Physiol* 245:H567, 1983.
34. **Hajjar PP et al:** Virus-induced atherosclerosis. *Am J Pathol* 122:62-70, 1986.
35. **Hamlin RL, Stalnaker P5:** Basis for use of digoxin in small birds. *J Vet Pharmacol Therap* 10:354-356, 1987.
36. **Harari J, Miller D:** Ventricular septal defect and bacterial endocarditis in a whistling swan. *Avian Pathol* 183:1296-1297, 1983.
37. **Harrison GJ et al:** A clinical comparison of anesthetics in domestic pigeons and cockatiels. *Proc Assoc Avian Vet*, Boulder, 1985, pp 7-22.
38. **Harrison GJ:** Preliminary work with selenium vitamin E responsive conditions in cockatiels and other psittacines. *Proc Assoc Avian Vet*, 1986, pp 257-262.
39. **Hill JR, Goldberg JM:** P-wave morphology and atrial activation in the domestic fowl. *Am J Physiol* 239:R483, 1980.
40. **Hunsaker WG:** Round heart disease in four commercial strains of turkeys. *Poult Sci* 50:1720-1724, 1971.
41. **Hunsaker WG, Robertson A, Magwood SE:** The effect of round heart disease on the electrocardiogram and heart weight of turkey poults. *Poult Sci* 50:1712-1720, 1971.
42. **Isaza R, Buergelt C, Kolias GV:** Bacteremia and vegetative endocarditis associated with a heart murmur in a blue and gold macaw. *Avian Dis* 36:1112-1116, 1992.

43. **hurri SJ, Ringer RK:** The effect of dietary PCB on the electrocardiogram of cockerels. *IRCS Med Sci* 7:254, 1979.
44. **Jessup DA:** Valvular endocarditis and bacteremia in a bald eagle. *Med Vet Pract* 61:49-51, 1980.
45. **Johnson JA, et al:** Atherosclerosis in psittacine birds. *Proc Assoc Avian Vet*, New Orleans, 1992, pp 87-93.
46. **Jordan KA, et al:** Cardiography of turkeys with round heart involvement. Conference on Engineering in Medicine and Biology, Houston, Texas, 1968 (November 18-21), # 407.
47. **Julian RJ:** Poisons and toxins. In Calnek BW et al (eds): *Diseases of Poultry* 9th ed. Ames, Iowa State University Press, 1991, pp 863-915.
48. **Julian RJ:** Cardiovascular disease. In Jordan FTW (ed): *Poultry Diseases* 3rd ed. London, Ballière Tindall, 1990, pp 330-353.
- 48a. **Julian RJ:** The effect of increased sodium in the drinking water on right ventricular hypertrophy, right ventricular failure and ascites in broiler chickens. *Avian Pathol* 16:61-71, 1987.
- 48b. **Julian RJ, et al:** Effects of hypoxia and diet on spontaneous turkey cardiomyopathy (round heart disease). *Avian Dis* 36:1043-1047, 1992.
49. **Kahn RH:** Das Vogel-Ekg. *Arch. fuer den Gesamten Physiologie* 162:67-93, 1915.
50. **King AS, McLelland J:** Birds. Their Structure and Function. London, Ballière Tindall, 1984, pp 214-228.
51. **Kish B:** Electrocardiographic studies in seagulls. *Exp Med Surg* 7:103-124, 1949.
52. **Kollias GV:** Drug-induced cardiomyopathy in birds. *Proc Assoc Avian Vet*, 1986, p 263.
53. **Krista LM, et al:** Comparison of electrocardiograms of hypertensive and hypotensive male turkeys. *Poult Sci* 49:700-703, 1970.
54. **Krista LM, McQuire JA:** Atherosclerosis in coronary, aortic, and sciatic arteries from wild male turkeys. *Am J Vet Res* 49:1582-1588, 1988.
55. **Lalimer KS, Perry RW, Mo IA, et al:** Myocardial sarcocystosis in a grand egyptian parrot and a moluccan cockatoo. *Avian Dis* 34:501-505, 1990.
56. **Lumeij JT, Stokhof AA:** Electrocardiogram of the racing pigeon (*Columba livia domestica*). *Res Vet Sci* 38:275-278, 1985.
57. **Lumeij JT:** Clinical electrocardiography in racing pigeons. *Proc V. Tagung ueber Vogelkrankheiten der Deutsche veterinaermedizinische Gesellschaft eV*, München, 1986, pp 19-33.
58. **Lumeij JT:** Anesthetic fatalities in goshawks. *Proceedings V. Tagung ueber Vogelkrankheiten der Deutsche veterinaermedizinische Gesellschaft eV*, München, 1986, pp 201-207.
59. **Magwood SE, Bray DF:** Diseases conditions of turkey poults characterized by enlarged and rounded hearts. *Can J Comp Med Vet Sci* 26:268-272, 1962.
60. **McKenzie BE, Will JA:** Electrocardiographic changes following influenza infection in turkeys. *Avian Dis* 16:308-318, 1972.
61. **McKenzie BE, Will JA, Hardie A:** The electrocardiogram of the turkey. *Avian Dis* 15:737-744, 1971.
62. **McOrist S:** Some diseases of free living Australian birds. *ICBP publication No 10*, 1989.
63. **Miller MS:** Electrocardiography. In Harrison GJ, Harrison LR (eds): *Clinical Avian Medicine and Surgery*. Philadelphia, Saunders, 1986, pp 286-292.
64. **Mitchell BW, Brugh M:** Comparison of electrocardiograms of chickens infected with viscerotropic velogenic Newcastle disease virus and virulent avian influenza virus. *Am J Vet Res* 43:2274-2278, 1982.
65. **Mueller RW, Rapley WA, Mehren KG:** Pathology of thyroid disease and arteriosclerosis in captive wild birds. In Montali RJ (ed): *Comparative Pathology of Zoo Animals*. Washington DC, Smithsonian Institution Press, 1980, pp 523-527.
66. **Munday BL, Hartley WJ, Harrigan KE, et al:** Sarcocystis and related organisms in Australian wildlife. *J Wildl Dis* 15:57-73, 1979.
67. **Nap A, Lumeij JT, Stokhof AA:** Electrocardiogram of the African grey (*Psittacus erithacus*) and Amazon (*Amazona spp.*) parrot. *Avian Pathol* 21:45-53, 1992.
- 67a. **Odom TW, Hargis BM, Lopez CC, et al:** Use of electrocardiographic analysis for investigation of ascites syndrome in broiler chickens. *Avian Dis* 35:738-744, 1991.
68. **Orr JP et al:** Ascites in broiler chickens. *Can Vet J* 27:99-100, 1986.
69. **Peckham MC:** Vices and miscellaneous diseases. In Hofstad MS, et al (eds): *Diseases of Poultry* 7th ed. Ames, Iowa State University Press, 1978, pp 847-893.
70. **Randolph JR, Moise S, Graham DL, et al:** Bacterial endocarditis and thromboembolism of a pelvic limb in an emu. *J Am Vet Med Assoc* 185:1409-1410, 1984.
71. **Reo M:** Degenerative myopathy in rats. *Proc Assoc Avian Vet*, New Orleans, 1992, pp 328-335.
72. **Reed WM et al:** Furazolidone-associated cardiomyopathy in two Indiana flocks of ducklings. *Avian Dis* 31:666-672, 1987.
73. **Reavill DR:** Septic thrombosis in a great curassow. *Proc Assoc Avian Vet*, New Orleans, 1992, pp 174-176.
75. **Riddel C:** Developmental, metabolic, and miscellaneous disorders. In Calnek BW et al (eds): *Diseases of Poultry*. Ames, Iowa State University Press, 1991, pp 827-862.
76. **Rosenthal K, Stamoulis M:** Congestive heart failure due to mitral regurgitation in an Indian Hill mynah bird. *Proc Assoc Avian Vet*, New Orleans, 1992, pp 171-173.
77. **Santerre RF, Wight TN, Smith SC, et al:** Spontaneous atherosclerosis in pigeons. *Am J Pathol* 67:1-22, 1972.
78. **Scott ML et al:** Selenium responsive myopathies of myocardium and smooth muscle in the young pout. *J Nutr* 91:573-583, 1967.
79. **Sharpe DN et al:** Enalapril in patients with chronic heart failure: A placebo-controlled randomized double-blind study. *Circulation* 70:271-278, 1984.
80. **Sileo L, Jones RN, Hatch RC:** The effect of ingested lead shot on the electrocardiogram of Canada geese. *Avian Dis* 17:308-313, 1973.
81. **SOLVD Investigators:** Effect of enalapril on survival in patients with reduced left ventricular ejection fractions and congestive heart failure. *N Engl J Med* 325:293-302, 1991.
82. **Steel RGD, Torrie JH:** Principles and Procedures of Statistics. New York, McGraw-Hill Book Co, 1960.
83. **Sturkie PD:** The electrocardiogram of the chicken. *Am J Vet Res* 10:168-175, 1949.
84. **Sturkie PD:** Effects of changes in position of the heart of the chicken on the electrocardiogram. *Am J Physiol* 154:251-257, 1949.
85. **Sturkie PD:** Abnormal electrocardiograms of chickens produced by potassium deficiency and effects of certain drugs on the abnormalities. *Am J Physiol* 162:538-544, 1950.
86. **Sturkie PD:** Effects of cadmium on electrocardiogram, blood pressure, and hematocrit of chickens. *Avian Dis* 117:106-110, 1973.
87. **Sturkie PD (ed):** *Avian Physiology* 4th ed. New York, Springer, 1986, pp 167-191.
88. **Sturkie PD, et al:** The effects of dietary deficiencies of vitamin E and the B-complex vitamins on the electrocardiogram of chickens. *Am J Vet Res* 15:457-462, 1954.
89. **Sturkie PD:** Effects of acute thiamine deficiency on the electrocardiogram of the chick. *Poult Sci* 31:648-650, 1952.
90. **Sturkie PD:** Further studies on potassium deficiency on the electrocardiogram of chickens. *Poult Sci* 31:648-650, 1952.
91. **Sturkie PD:** Heart. In Sturkie PD (ed): *Avian Physiology*. New York, Springer Verlag, 1986, pp 130-190.
92. **Sturkie PD:** Role of estrogen on sex differences of the electrocardiogram of the chicken. *Proc Soc Exp Biol Med* 94:731-733, 1957.
93. **Szabuniewicz M, McCrady JD:** The electrocardiogram of the chicken. *Southwestern Veterinarian* 20:287-294, 1967.
94. **Takei Y, Kobayashi H:** Hormonal regulation of water and sodium intake in birds. In Wada M, Ishii S, Scanes CG (eds): *Endocrinology of Birds. Molecular to Behavioral*. Berlin, Springer Verlag, 1990, pp 171-186.
95. **Taylor M:** Polycythemia in the blue and gold macaw. *Proc Assoc Avian Vet*, 1987, pp 95-104.
96. **Tilley LP:** Essentials of Canine and Feline Electrocardiography. London, CV Mosby, 1979.
97. **Vice CA Cazayoux:** Myocarditis as a component of psittacine proventricular dilatation syndrome. *Avian Dis* 36:1117-1119, 1992.
98. **Wallach JD, Flieg GM:** Frostbite and its sequelae in captive exotic birds. *J Am Vet Med Assoc* 155:1035-1038, 1969.
99. **Warzecha M:** Physiological arrhythmias in pigeons. *Proc Europ Assoc Avian Vet*, Utrecht, 1993, pp 367-387.
- 99a. **Webb DM, Denicola DB, Van Vleet JF:** Serum chemistry alterations, including creatine kinase isoenzymes, in furazolidone toxicosis of ducklings: Preliminary findings. *Avian Dis* 35:662-667, 1991.
100. **Wilson RC, Zenoble RD, Horton CR, et al:** Single dose digoxin pharmacokinetics in the quaker conure. *J Zoo Wildl Med* 20:432-434, 1989.
101. **Zenoble RD, Graham DL:** Electrocardiography in the parakeet and parrot. *Comp Cont Ed Prac Vet* 3:711-716, 1981.

**C**ompanion and aviary birds frequently develop clinical signs associated with the central or peripheral nervous system. These changes may include depression, blindness, opisthotonos, head tilt, circling, tremors, ataxia, convulsions, paresis and paralysis. Neurologic changes in birds may occur from primary or secondary diseases including genetic abnormalities, neoplasms, metabolic diseases, malnutrition, exposure to toxins, trauma and bacterial, viral, fungal or parasitic infections.

In a retrospective study of avian patients with neurologic disorders, the clinical signs most frequently observed were seizures, ataxia, paresis, paralysis, intention tremors, circling, head tilt, nystagmus, abnormal mentation and visual deficits. General supportive care for patients in this study included antibiotic therapy, fluid support, parenteral vitamin therapy and gavage feeding for nutritional support. The two most common etiologies were lead toxicity and hypocalcemia/vitamin D<sub>3</sub> deficiency. Many other neurologic problems resolved with general supportive care and vitamin supplementation.<sup>87</sup>

Diagnostic tests that may be of value in determining the etiology of neural lesions, as well as the prognosis for recovery in some cases, include CBC, biochemistries, specific tests for detecting levels of toxins, radiographs, electroencephalograms, electromyograms, auditory evoke potentials, CT scans and MRI. Some of these diagnostic techniques require specialized equipment, but their efficacy in diagnosing neurologic diseases in birds has been documented. Many of the advanced neurologic diagnostic tests are available at veterinary colleges, and case referral should be considered when one of these techniques is needed to evaluate a patient.

---

CHAPTER

28

NEUROLOGY

---

R. Avery Bennett

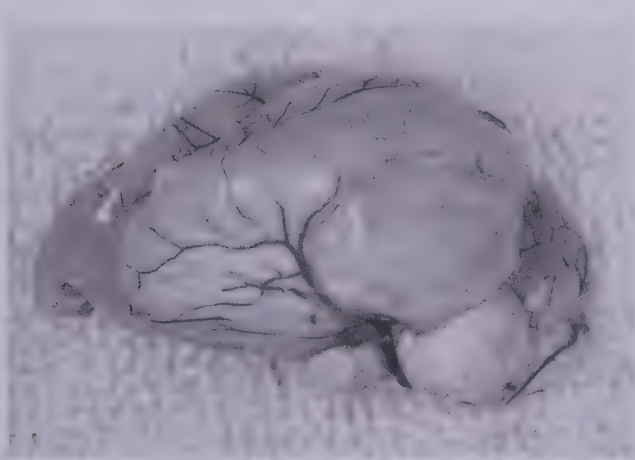
## Neuroanatomy<sup>69</sup>

### Meninges

As in mammals, birds have three meninges: pia mater, arachnoid and dura mater. The subarachnoid space contains cerebrospinal fluid that may be collected from the cisterna magna; however, birds have a large venous sinus located dorsal to the cisterna that is easily damaged during a spinal tapping procedure and, if disrupted, will cause severe hemorrhage.

### Brain

The brain of birds is lissencephalic, with virtually no convolutions (Figure 28.1). The vallicula arises near the rostral end of the median fissure and extends caudad. The sagittal eminence is a prominence medial to the vallicula. The lateral ventricles are displaced dorsally by the large corpus striatum.<sup>83</sup> The olfactory bulbs are pointed at the rostral extent of the brain, and the olfactory center of the brain is rather underdeveloped.<sup>28</sup> The cerebral cortex is also underdeveloped (being two to three cell-layers thick, <1 mm); however, when compared with mammals, the corpus striatum is well developed and is considered the main center for association in birds (Figure 28.2). Consequently, instincts dominate avian behavior, which may account for some of the self-mutilation that occurs in companion birds. Birds have no corpus callosum nor septum pellucidum.



**FIG 28.1** The brain of birds is lissencephalic with virtually no convolutions.

The diencephalon is the location of the pineal body, which lies dorsal and medial between the caudal aspects of the cerebral hemispheres. It is composed of secretory cells, which resemble rudimentary photoreceptors. The nonmyelinated axons are responsive to light. The pathway for stimulation courses from the optic nerve to the cranial cervical ganglion, which has axons to the pineal body. Interestingly, these axons are still responsive to light even if the bird's eyes are removed and the cranial cervical ganglion is removed. The pineal body is involved in reproduction, migration and circadian rhythms. Its secretions exert their effect on the hypothalamus. The hypothalamus is located caudal (or ventral) to the optic chiasm.

### Midbrain

The midbrain is the location of the optic tectum. The avian optic lobes are massive and responsible for the well developed, though monocular, vision of most birds (Figure 28.2). The optic tectum is equivalent to the rostral colliculus of mammals and birds have no caudal colliculus. Cranial nerves III and IV exit from the midbrain. Large motor afferent, efferent and optic fiber systems originate, decussate and terminate in the mesencephalon and myelencephalon. There is complete decussation of tectospinal (motor) and rubrospinal (modulation) tracts in the midbrain, while the tracts of the pons and medulla do not decussate.<sup>1</sup>

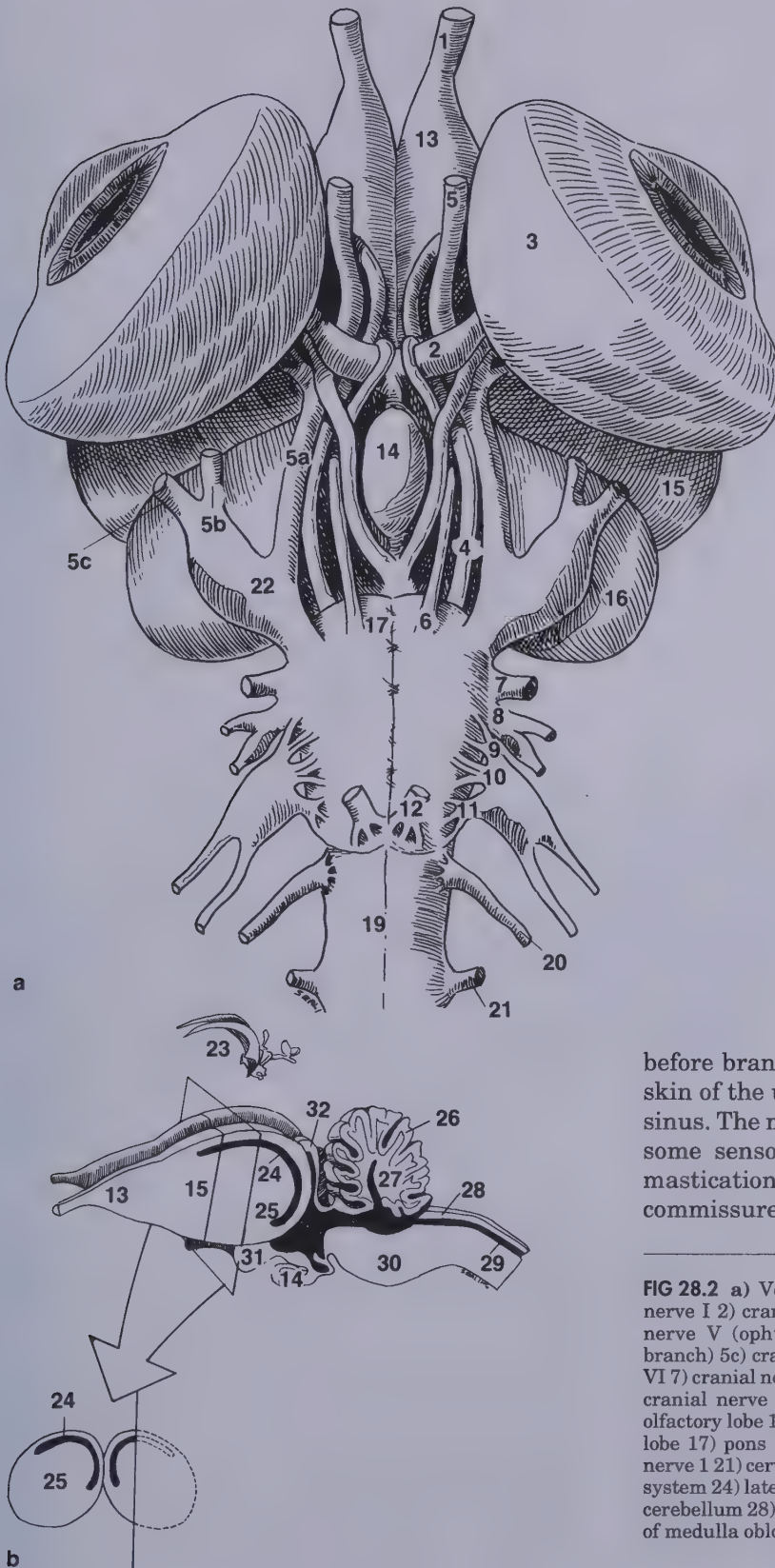
### Cerebellum

As in mammals, the cerebellum is the center for coordination of movements and is correspondingly large. It has a single median lobe with transverse sulci and is divided into three main lobes (not four as in mammals) by the fissura prima and fissura secunda, which are deeper transverse sulci. Smaller transverse sulci divide it into ten primary lobules. Each lobule is believed to be responsible for coordination of a specific part of the body. For example, lobules II and III control leg coordination. The lateral flocculus (lobule X) with the paraflocculus (lobule IX) are located at the rostral aspect. The rostral and caudal cerebellar peduncles attach the cerebellum to the medulla. There may also be a cerebellar peduncle.

### Pons

The pons is poorly developed and is present only as a broad band of fibers at the rostral portion of the medulla oblongata. There is no pyramid as found in mammals. Cranial nerves V through XII arise from the medulla.





**Cranial Nerves**

The cranial nerves of birds correspond to those found in mammals (Figure 28.3). The olfactory nerve (CN I) is sensory and passes through a single hole in the skull (the olfactory foramen) rather than a cribriform plate. The optic nerve (CN II) is sensory and large in order to accommodate the visual acuity birds require. It is usually more than half the diameter of the spinal cord. The oculomotor nerve (CN III) is motor to the dorsal, ventral and medial rectus muscles and the ventral oblique muscle of the eye. It also supplies the muscles of the eyelids. It has parasympathetic fibers to the gland of the third eyelid, the choroid, the iris and the pecten (triangular pleated membrane extending forward from the optic disc). The trochlear nerve (CN IV) is motor to the dorsal oblique muscle of the eye.

The trigeminal nerve (CN V) contains both sensory and motor fibers. The ophthalmic branch is sensory and consists of two components. The dorsal component innervates the upper eyelid and the skin of the forehead. The ventral component is sensory to the nasal cavity and upper beak. The maxillary branch is sensory and innervates the upper eyelid

before branching to supply the lower eyelid, palate, skin of the upper beak, nasal cavity and infraorbital sinus. The mandibular branch is motor but may have some sensory fibers. It innervates the muscles of mastication and the skin and the mucosa at the commissures of the beak.

**FIG 28.2** a) Ventral and b) lateral view of the brain. 1) cranial nerve I 2) cranial nerve II 3) eye 4) cranial nerve IV 5a) cranial nerve V (ophthalmic branch) 5b) cranial nerve V (maxillary branch) 5c) cranial nerve V (mandibular branch) 6) cranial nerve VI 7) cranial nerve VII 8) cranial nerve VIII 9) cranial nerve IX 10) cranial nerve X 11) cranial nerve XI 12) cranial nerve XII 13) olfactory lobe 14) pituitary gland 15) cerebral hemisphere 16) optic lobe 17) pons 18) medulla oblongata 19) spinal cord 20) cervical nerve 1 21) cervical nerve 2 22) trigeminal ganglion 23) ventricular system 24) lateral ventricle 25) corpus striatum 26) arbor vitae 27) cerebellum 28) roof of medulla oblongata 29) central canal 30) floor of medulla oblongata 31) optic chiasm and 32) pineal body.

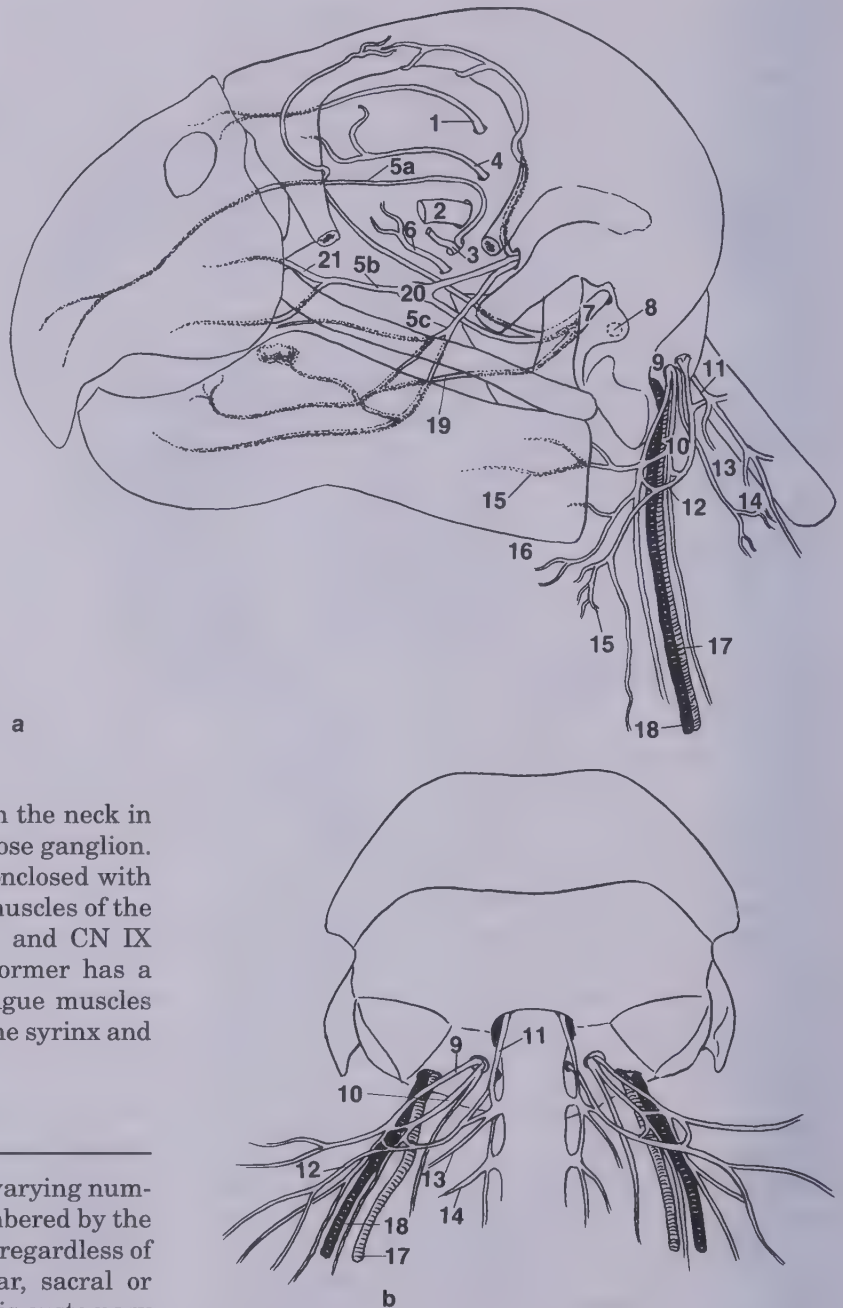
The abducent nerve (CN VI) is motor to the lateral rectus muscles and muscles of the third eyelid. The facial nerve (CN VII) is motor with a small sensory component and parasympathetic fibers. It is not involved in taste as in mammals, but supplies the hyoid and the cutaneous neck muscles. The vestibulocochlear nerve (CN VIII) has separate ganglia for the vestibular and the cochlear nerves. The glossopharyngeal nerve (CN IX) is sensory and motor. Cranial nerves IX, X, XI arise from a row of small roots. Cranial nerves X and XI combine in a common ganglion. The lingual branch of the glossopharyngeal nerve receives sensory input from taste fibers.

The pharyngeal branch has fibers that join with the vagus nerve to innervate the larynx and trachea. The esophageal branch courses along the neck with the jugular vein, supplying the esophagus. The vagus nerve (CN X), CN XI and jugular vein course down the neck in a common sheath to the level of the nodose ganglion. The spinal accessory nerve (CN XI) is enclosed with the vagus and supplies the superficial muscles of the neck. The hypoglossal nerve (CN XII) and CN IX innervate the tracheal muscles. The former has a lingual branch that innervates the tongue muscles and a syringeal branch that courses to the syrinx and tracheal muscles.

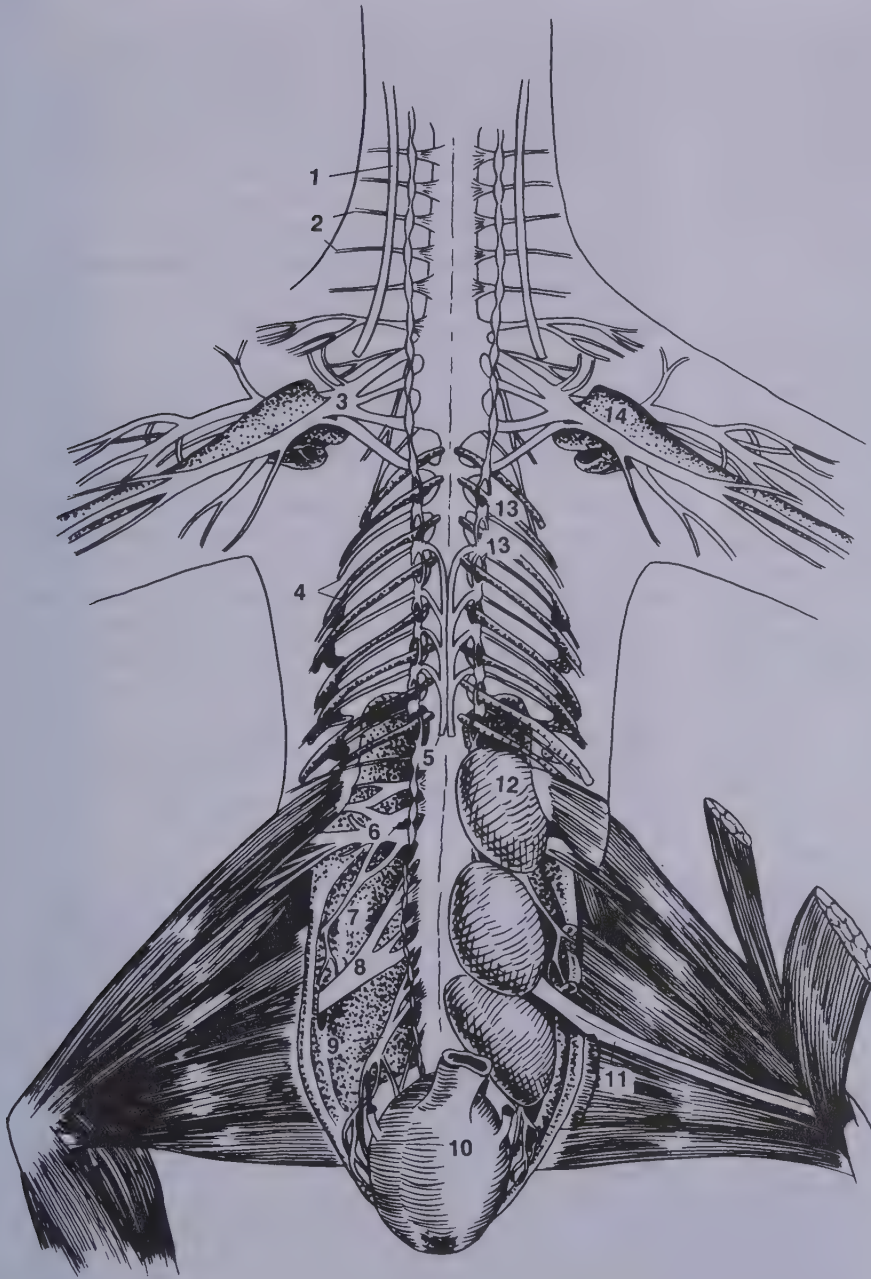
### Spinal Nerves

Because birds of different species have varying numbers of vertebrae, spinal nerves are numbered by the vertebra caudal to it in numerical order regardless of whether it is cervical, thoracic, lumbar, sacral or coccygeal. In discussions of plexuses, it is customary to refer to the roots making up the plexus by the ordinal number of their cranial to caudal location (Figure 28.4). The lumbar spinal cord contains a dorsal gelatinous structure (glycogen body), which is nestled in a deep cleft between the dorsal columns.<sup>83</sup>

The brachial plexus is formed by ventral branches of three to five spinal nerves. The ram communicans lateralis and medialis connect the second to the third nerve roots and the fourth to the fifth roots (if present). These are sympathetic nerve fibers. The sec-



**FIG 28.3** a) Lateral and b) caudal view of the cranium showing the position of the cranial nerves. 1) cranial nerve I 2) cranial nerve II 3) cranial nerve III 4) cranial nerve IV 5a) cranial nerve V (ophthalmic branch) 5b) cranial nerve V (maxillary branch) 5c) cranial nerve V (mandibular branch) 6) cranial nerve VI 7) cranial nerve VII 8) cranial nerve VIII 9) cranial nerve IX 10) cranial nerve X 11) cranial nerve XI 12) cranial nerve XII 13) cervical nerve 1 14) cervical nerve 2 15) lingual branch 16) pharyngeal branch 17) internal carotid artery 18) jugular vein 19) corda tympani 20) sphenopalatine ganglion and 21) infraorbital nerve.



**FIG 28.4** Ventrodorsal view of the spinal nerves and autonomic nervous system. The right kidney has been removed to show their relationship with the lumbar plexuses. 1) vagus 2) cervical spinal nerves 3) brachial plexus 4) thoracic spinal nerves 5) greater splanchnic nerves 6) lumbar plexus 7) obturator nerve 8) sacral plexus 9) pudendal plexus 10) cloaca 11) ischiatic nerve 12) cranial division of kidney 13) autonomic ganglion and 14) humerus.

and through fourth roots give off rami musculares to innervate the neck muscles. The nerves arising from this plexus innervate the muscles of the wing.

There are three nerve plexuses in the lumbosacral region (lumbar, ischiatic and pudendal). These nerve roots lie embedded in the foveae of the pelvis surrounded by the kidneys (see Anatomy Overlay). All

three plexuses are connected to the sympathetic chain. The lumbar plexus is composed of three to four nerve roots (the last two lumbar and first sacral roots). It innervates the cranial thigh muscles and the muscles of the body wall. The obturator nerve, femoral nerve, cranial gluteal nerve and saphenous nerve arise from this plexus.

The ischiatic plexus or sacral plexus is usually made up of six sacral nerve roots, but occasionally four, five or seven roots. The first root arises with the last root of the lumbar plexus. The roots combine to form the ischiatic nerve, which is the largest nerve in body. This nerve should be faintly striated and a loss of striations is suggestive of an inflammatory process. The caudal gluteal nerve also arises from the sacral plexus.<sup>83</sup>

The pudendal plexus is formed by five thin coccygeal nerve roots and supplies the cloaca and tail.

## Neurologic Examination

Two of the primary objectives in performing a neurologic examination are to determine if the neuropathy is focal or diffuse, and to localize focal lesions. The examination should be performed in a consistent, logical manner that starts with a complete history (see Chapter 8). Neuropathies are particularly common secondary to trauma, exposure to toxins and malnutrition. Subtle changes in cranial nerve function and abnormal reflexes are difficult to appreciate and interpret in birds. Assessment of segmental reflexes may be difficult in avian patients, making evaluation of muscle tone, strength and atrophy an essential part of the neurologic examination.

Neurologic evaluation of neonates is particularly difficult, and making a "side-by-side" comparison with a "normal" clutchmate is the best way to detect subtle changes. Useful tests include evaluation of the feeding response, menace reflex, use of wings to balance, vocalization, perching ability, pain perception and hopping response.<sup>65</sup>

### ■ Mental Status

The patient's mental status and level of consciousness should be evaluated. Any personality changes reported by the owner should be noted. The bird's ability to perform normal activities and its awareness of its surroundings should be assessed. Clients may indicate that the bird acts sleepy, dull, uneasy, nervous, anxious, aggressive or dizzy. It is difficult to differentiate between seizures and syncope based on the history; however, either may suggest an intracranial lesion. Seizures may be characterized by ataxia, disorientation and falling off a perch followed by tonic clonic convulsions.

### ■ Cranial Nerves

An evaluation of the cranial nerves may help localize a focal brain lesion (individual nerves involved) or a generalized encephalopathy (several nerves involved). Olfaction (CN I) is difficult to assess because birds have a poor sense of smell; however, most normal birds will react negatively to noxious odors (eg, alcohol pledget). Birds with CN I dysfunction may exhibit an altered appetite or feeding response.

An ophthalmic examination is essential for detecting neurologic abnormalities (see Chapter 26). Failure to avoid obstacles may indicate vision impairment. Bilateral blindness without ocular lesions may indicate neoplasm, abscess or granuloma formation in the brain.<sup>97</sup> The menace reflex can be used to evaluate CN II and VII; however, depending on the circumstances, the absence of a menace response does not always indicate dysfunction of these cranial nerves. The pupillary light response evaluates CN II and III. Because there is complete decussation of the optic nerves at the chiasm, birds do not have a consensual pupillary light response.<sup>68</sup>

Birds have some degree of voluntary control of pupil size because of skeletal muscles in the iris.<sup>28,68</sup> Excited birds will voluntarily dilate and constrict their pupils. The presence of anisocoria may indicate dysfunction of CN III or a sympathetic neuropathy. Normal eye movements require the coordination of CN

III, IV, VI and VIII as well as the cerebellum and brain stem.<sup>87</sup> The presence of nystagmus or strabismus may indicate an abnormality in this system (vestibular). A fundic examination may be performed with the aid of d-tubocurarine. Its action on the avian pupil may be to inhibit the iris constrictor muscles allowing the myoepithelial dilator action to dominate.<sup>68</sup> In some birds, intracameral injection of 0.045-0.09 mg d-tubocurarine chloride produces mydriasis within five minutes without systemic effects.<sup>68</sup>

Cranial nerve V is responsible for facial sensation, movement of the mandible and blinking of the eyelids. Diminished beak strength may indicate an abnormality in CN V. Eye blink involves both CN V and VII. A defect in CN VIII will cause deafness or a head tilt toward the affected side. Cranial nerves IX through XII are involved in normal tongue movement, swallowing and beak strength. Dysfunction is manifested by dysphagia. Deviation of the tongue or atrophy of its muscles is observed with damage to CN XII.

Loss of normal physiologic nystagmus may occur with bilateral CN VIII lesions or with severe brain stem lesions.<sup>87</sup> Altered consciousness is usually an accompanying sign with brain stem lesions. Abnormal, spontaneous nystagmus may result from vestibular lesions. Strabismus may indicate vestibular system dysfunction or a lesion in CN III, IV or VI.<sup>87</sup>

Horner's syndrome may occur with intracranial lesions or with a lesion in the cervical sympathetic tract or the brachial plexus.<sup>87</sup>

### ■ Locating Lesions


Reflexes are evaluated to help determine if a lesion is central (upper motor neuron) or peripheral (lower motor neuron). Wing droop, inability to fly and diminished or absent pain perception may be present with either central or peripheral lesions. Pain perception in the wing requires intact peripheral nerves and the cervical spinal cord. Wing withdrawal is a segmental reflex that is present with intact peripheral nerves, but does not require an intact cervical spinal cord. A spinal cord lesion should cause hyperreflexia; however, hyperreflexia is difficult to distinguish from normoreflexia.

In most situations, it is sufficient to determine if a reflex is present or absent. Weakness in the legs, knuckling over and an inability to grasp perches with the feet may be observed with either upper motor

neuron lesions or lower motor neuron lesions. The patellar reflex is difficult to assess in birds; however, the withdrawal reflex is also a segmental reflex and should be intact with lesions affecting only the spinal cord.<sup>87</sup>

Conscious proprioception requires an intact peripheral and central nervous system. A lesion in either will result in the bird knuckling over. The vent response is a segmental reflex, and the sphincter should be responsive to stimulation if a spinal cord lesion is present and the nerve roots are not affected. A crossed extensor reflex generally indicates a lesion in the spinal cord with a loss of normal central inhibitory pathways.

With cervical spinal cord lesions, dysfunction of the wings, legs and cloaca may be observed while head function and cranial nerves appear normal (Figure 28.5). Weakness in the wings and legs with intact leg and wing withdrawal and vent response would be indicative of a cervical spinal cord lesion. Lesions affecting the thoracolumbar spinal cord will cause leg and cloacal dysfunction without affecting the head, cranial nerves or wings. Cloacal sphincter hypertonia, incontinence and soiling of the vent without



**FIG 28.5** A mature Amazon parrot was presented for emergency evaluation after being bitten by a dog. The bird had several large puncture wounds in the thorax. The bird was recumbent, and a deep pain response could not be elicited from either pelvic limb. Radiographs indicated a puncture wound through the lung (arrow) with an increased soft tissue density (blood) in portions of the lung parenchyma. The bird was placed on broad-spectrum antibiotics and steroids. A deep pain response was noted five days after the initial injury, and the bird slowly improved with a complete return to normal function over a three-month period.

signs of head, wing or leg dysfunction are indicative of a lumbosacral spinal cord lesion.

Loss of pain perception indicates a poor prognosis for recovery.<sup>87</sup> It is crucial to differentiate pain perception from withdrawal reflex. Because withdrawal of a stimulated extremity is a segmental reflex and does not require an intact spinal cord for a normal response, movement does not indicate the patient is able to feel the stimulus. Some type of conscious recognition of the stimulus must be identified (eg, vocalization, attempting to bite or escape behavior). This part of the examination is generally reserved for last so that the painful stimulus does not influence the patient's response to other segments of the neurologic examination.

## Diagnostic Techniques

The results of the neurologic examination will suggest which diagnostic tests should be performed. A

CBC and serum chemistry profile are indicated if an infectious or metabolic neuropathy is considered. Laparoscopy and organ biopsy may be indicated to further define metabolic neuropathies. Serum for viral diseases or chlamydiosis, and blood levels for heavy metals are indicated in some cases. Radiographs are indicated if spinal trauma or heavy metal intoxication is suspected. TSH stimulation test may be helpful if hypothyroidism is suspected. Electromyograms, nerve conduction velocities, spinal evoked potentials and nerve or muscle biopsies are helpful in evaluating neuropathies.

### Electrodiagnostics

Electrodiagnostic studies are used commonly in mammals for localizing neurologic lesions and aiding in prognostic assessment. When available, electrodiagnostic techniques are valuable in avian patients for distinguishing between a neuropathy and a myopathy, localization of

neurologic lesions and determining the prognosis for return to normal function.

### Electromyogram (EMG)

Diseases of motor neuron cell bodies, ventral nerve roots, nerve plexuses, peripheral nerves, neuromuscular junctions and muscle fibers may alter the electromyogram (EMG), which is a recording of the electrical activity in striated muscle.<sup>27</sup> Normal activity consists of insertion potentials, motor unit potentials and spontaneous waves, which occur infrequently. When the electrode is inserted into the muscle, the intrafascicular nerve branches and muscle fibers are stimulated, creating a brief burst of electrical activity, which ceases immediately after the electrode stops moving. If the electrode is moved, insertional activity will again be recorded. Large positive waves are occasionally observed. If the electrode is inserted coincidentally near a motor endplate, a low continuous level of electrical activity will be recorded with an auditory component sounding like a distant beach surf. Motor unit potentials occur during involuntary muscle contraction or when a motor nerve is stimulated (an M response). The M response has two phases and represents the sum of the electrical activity of all of the muscle fibers in that motor unit.

Fibrillation potentials, positive sharp waves, myopathic potentials and reinnervation potentials are abnormal EMG recordings. Prolonged insertional activity due to muscle hyperexcitability occurs six to ten days following peripheral nerve injury, then gradually decreases. Fibrillation potentials are mono- or biphasic and occur five to seven days following denervation. These spontaneous, repetitive action potentials from muscle fibers, not produced by nerve impulses, occur because of the instability of the cell membrane at the endplate. Fibrillation potentials increase for several weeks after denervation, then decrease as muscle atrophy and fibrosis occur. They stop if reinnervation occurs.

Positive sharp waves are generally associated with denervation, but may be observed with primary myopathies. They are characterized by an initial positive deflection followed by a slower negative potential with a "dive bomber engine" auditory component. They may be single or multiple. Myopathic potentials are generally indicative of a primary myopathy but may be observed with fibrillation potentials following denervation. They are continuous discharges with varying amplitude, duration and frequency with a waxing and waning auditory component sounding like an attacking then retreating dive

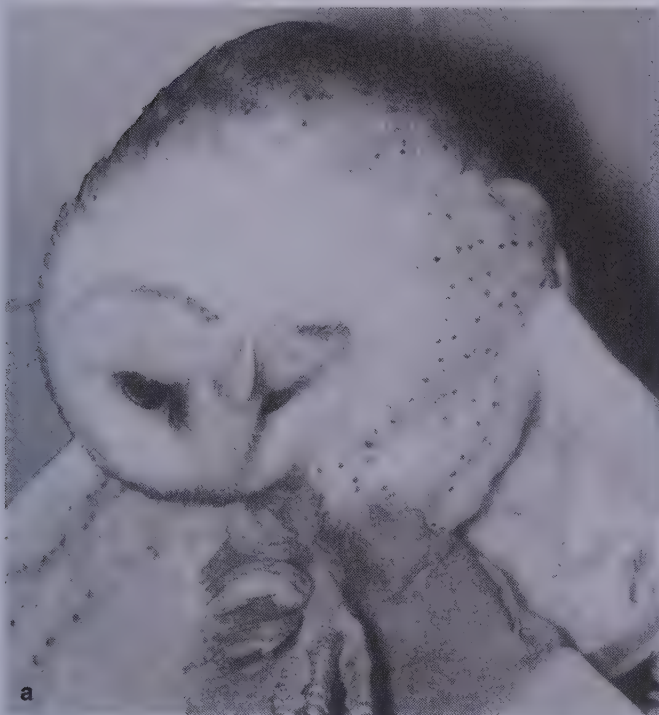bomber. As reinnervation occurs, motor unit potentials are initially low amplitude and polyphasic but become larger than normal motor unit potentials and are an indicator of a good prognosis for recovery.

Nerve conduction velocities (NCV) can provide information regarding delayed transmission along a nerve as well as the location of a peripheral nerve lesion. A nerve stimulator is used to generate an M response at two different locations along the course of a peripheral nerve. The distance between the sites is divided by the latency difference in the two M responses to determine the velocity with which the impulse travels along the nerve (m/s). Where there is a peripheral neuropathy such as demyelination, the velocity is slow and the M responses are polyphasic and prolonged. If the nerve has been transected, the stimulation distal to the site will produce an M response, while stimulation of the site proximal to the lesion will not.

Standard EMG equipment may be used to evaluate H-wave and F-wave reflexes. The H-wave reflex evaluates both the afferent and efferent pathways. A peripheral site is stimulated and sensory impulses are carried to the spinal cord, where the alpha motor neurons are activated and discharged, resulting in a compound muscle section potential. The F-wave reflex is evaluated by stimulating the peripheral nerve with a lower intensity than that required to cause an H-wave production, activating the motor neuron to generate an efferent impulse. The H-wave and F-wave reflexes are used in combination to evaluate nerve root avulsion.

Signal-averaging capabilities are required for somatosensory-evoked potentials, spinal-evoked potentials and motor-evoked potentials. Somatosensory-evoked potentials correspond clinically to the presence or absence of pain perception. They may be utilized to determine if failure to react to a painful stimulus is the result of other more painful injuries, stoicism or denervation. This procedure is performed by stimulating a peripheral nerve and recording the response in the cervical spinal cord or cerebral cortex. It is important to recognize that these evoked potentials evaluate sensory, not motor nerve function. A response may persist after permanent loss of motor function.

Spinal-evoked potentials are utilized to determine the location of a spinal cord lesion. Stimuli are applied to peripheral nerves and the responses are recorded by an electrode inserted near the spinal



**FIG 28.6 a)** A Barn Owl was presented with a progressive head tilt and ataxia. Physical examination revealed a discharge of necrotic debris from the right ear canal that contained gram-negative rods. **b)** Auditory-evoked potentials indicated a centralized inflammatory disease (see Color 14).

cord. They can discretely evaluate the sensory pathway of a focal segment of spinal cord such that loss of response cranial to a specific vertebra identifies the location of the lesion. Spinal-evoked potentials also evaluate only sensory function. Motor-evoked potentials are capable of evaluating motor function, but techniques are not well established for animal use. They are currently being evaluated for safety, effects of anesthetics and correlation with injury.

#### Electroencephalograms

Electroencephalograms (EEG) are continuous recordings of the electrical activity of the cerebral cortex. They vary with head size, environment, restraint techniques and state of consciousness of the patient. They may be beneficial in monitoring progress in response to brain lesions or injury. Auditory-evoked potentials evaluate the brainstem response to auditory stimuli. They may be used to assess hearing ability and brainstem function (Figure 28.6).



## Neuropathies

### Nutritional

#### Hypovitaminosis E and Selenium Deficiency

Deficiencies of vitamin E and selenium have been reported to cause a wide variety of clinical signs and pathologic lesions in birds of all ages. In a survey of central nervous system lesions from animals in a zoological collection, birds had a higher incidence of disease than mammals, and encephalomalacia histologically compatible with hypovitaminosis E was the most common lesion observed.<sup>130</sup>

Vitamin E is a fat-soluble vitamin and depletion of body stores occurs slowly in adult birds, while young birds may develop clinical signs associated with acute deficiency. In young birds, hypovitaminosis E may cause encephalomalacia, exudative diathesis or muscular dystrophy. Encephalomalacia results in ataxia, head tilt, circling and occasionally convulsions and is particularly common in hatching budgerigars.<sup>51</sup> Exudative diathesis and muscular dystrophy (white muscle disease) occur also with deficiency of vitamin E or selenium. The myositis associated with hypovitaminosis E may cause clinical changes difficult to distinguish from neurologic signs.

Clinical signs associated with vitamin E and selenium deficiencies include tremors, ataxia, incoordination, abnormal head movements, reluctance to walk and recumbency.<sup>14,63</sup> Postmortem findings suggestive of encephalomalacia include cerebellar edema or hemorrhage (petechia) with flattening of the convolutions.<sup>14</sup> Histologically, there is edema, interruption of vascular integrity with associated capillary hemorrhage and hyaline thrombosis, and cerebellar demyelination with degeneration and necrosis of neurons.<sup>14</sup> Focal or multifocal poliomyelomalacia of the spinal cord may also occur.<sup>40,63</sup> Diagnosis of hypovitaminosis E is frequently presumptive based on clinical signs, history and gross and microscopic pathology. Hypovitaminosis E and selenium deficiency should be considered with pathologic lesions of demyelination and malacia in birds with vague clinical signs or in birds that are found dead in their enclosures with no premonitory signs.

Muscular dystrophy is characterized by light-colored streaks in the muscle fibers (Figure 28.7). Early histologic changes include hyaline degeneration, mitochondrial swelling, loss of striations and central migration of the nucleus.<sup>14</sup> In more chronic cases, muscle fibers are disrupted transversely and macrophages are present engulfing debris from necrotic myocytes.

This deficiency has also been incriminated as the etiology of cockatiel paralysis syndrome. This condition appears to occur most frequently in lutino cockatiels infected with *Giardia* sp. or *Hexamita* sp. Vitamin E- and selenium-responsive neuropathies have



a



b

**FIG 28.7** a) A two-year-old domestically raised Eclectus Parrot was presented with a one-month history of progressive difficulties in ambulating. At presentation, the bird was recumbent and had stiff, nonmotile thoracic and pelvic limbs, but was bright, alert and responsive. The muscle masses associated with all limbs were atrophied and firm. b) EMG findings included fibrillation potentials and positive sharp waves suggestive of denervation. Histopathology indicated severe, progressive, generalized muscle fibrosis of undetermined etiology.

been reported in a variety of other species including Blue and Gold Macaws, Severe Macaws, Eclectus Parrots and African Grey Parrots.

Clinical signs include slow or incomplete eye blink due to paresis of the lower eyelid, weak jaw muscles, paresis of the tongue, poor digestion with passage of partially digested food, diminished playful activity, hyperactivity, clumsiness and weak grip, low-pitched and weak vocalization, delayed crop-emptying, spraddle leg, death of young in nest, weak hatchlings,



increased dead-in-shell, increased egg binding that is not responsive to vitamin A and calcium supplementation and decreased fertility. Cockatiels and other psittacine birds showing these clinical signs have responded to vitamin E and selenium supplementation and antiprotozoal therapy. In one study, treatment of giardiasis resulted in an increase in serum vitamin E levels from a deficiency state into the normal range.<sup>49</sup>

A selenium-responsive progressive ascending paralysis in fledgling mocking birds fed a commercial cat food has been reported.<sup>85</sup> Necropsy findings were suggestive of a viral encephalitis; however, clinical signs were similar to vitamin E- and selenium-responsive paralysis in cockatiels. All affected birds responded to parenteral administration of selenium followed by oral vitamin supplementation. Other species of birds being raised at this facility were not affected.

Vitamin E deficiency also occurs in piscivorous birds fed an unsupplemented diet of frozen fish (especially smelt). In birds of the family Ardeidae (herons and bitterns), the deficiency manifests initially as fat necrosis accompanied by steatitis. In pelicans, myodystrophy predominates.<sup>105</sup>

Supplementation with injectable and oral vitamin E is the recommended treatment; however, the patient may or may not respond depending on the severity of damage. Muscular dystrophy may resolve with supplementation, but encephalomalacia rarely responds to therapy.<sup>14</sup>

#### **Hypovitaminosis B<sub>1</sub> (Thiamine)**

Clinical signs of hypovitaminosis include anorexia, ataxia, ascending paralysis and opisthotonos.<sup>51</sup> Opisthotonos ("star-gazing") may result from paralysis of the anterior muscles of the neck resulting in pseudo-hypertonus of the muscles of the dorsal aspect of the neck (see Color 48). Histologically, thiamine deficiency causes a polyneuritis with myelin degeneration of peripheral nerves. Adrenal hypertrophy and edema of the skin are also characteristic of thiamine deficiency. Affected birds generally respond within hours of oral or parenteral administration of vitamin B<sub>1</sub>. A response to treatment provides a presumptive diagnosis. Administration of thiamine is a useful adjunct to therapy in many nonspecific neurologic disorders.

#### **Hypovitaminosis B<sub>2</sub> (Riboflavin)**

Curled toe paralysis occurs in poultry and is seen in nestling budgerigars with riboflavin deficiency (see Color 48). Other signs include weakness, emaciation in the presence of a good appetite, diarrhea, walking on the hocks with toes curled inward and atrophy of leg muscles. Chicks fed a deficient diet may develop clinical signs as early as 12 days of age.<sup>61</sup> Histologically, a demyelinating peripheral neuritis is observed with edema of the nerves (especially the ischiatic and brachial nerves). There is Schwann cell proliferation and swelling, perivascular leukocytic infiltration and segmental demyelination accompanied by accumulation of osmophilic debris in the cytoplasm of Schwann cells.<sup>61</sup> Gliosis, chromatolysis in the spinal cord and degeneration at the neuromuscular endplate may also be observed. Treatment involves administration of oral or parenteral riboflavin and diet correction; however, many of the changes are irreversible, especially in chronic cases.

#### **Hypovitaminosis B<sub>6</sub> (Pyridoxine)**

Neurologic signs associated hypovitaminosis B<sub>6</sub> are characteristic, with the bird exhibiting a jerky, nervous walk progressing to running and flapping the wings. The bird then falls with rapid, clonic tonic head and leg movements. These convulsions are severe and may result in death due to exhaustion.<sup>51</sup>

#### **Hypovitaminosis B<sub>12</sub> (Cyanocobalamin)**

Deficiency in a Nanday Conure was reported to cause subacute, multifocal white matter necrosis.<sup>51</sup>

### **Traumatic**

#### **Concussion Lesions**

Concussive head trauma is fairly common in free-ranging as well as companion and aviary birds. Head trauma may occur at night when a panicked bird flies into an enclosure wall or if birds fly into windows or mirrors. Injured birds may remain on the bottom of the enclosure and exhibit depression, head tilt, circling or paresis of a wing or leg. Blood may be present in the mouth, ears or anterior or posterior chamber of the eye. Anisocoria and delayed pupillary light response may be present and convulsions may occur if the bird is disturbed.

Fractures of the skull or scleral ossicles may be detected radiographically. In some cases, a bruise might be visualized on the head that is the result of meningeal hemorrhage seen through the cranium. Blood actually leaks into bone and is not subdural (see Color 14).<sup>51</sup> If the vessels in the neck are rup-

tured, the pneumatic spaces in the skull may fill with blood obscuring evidence of trauma. It is very rare for hemorrhage to occur within the brain parenchyma. Unconsciousness with a loss of normal physiologic nystagmus indicates a brainstem lesion with a poor prognosis.<sup>88</sup>

Treatment is supportive and involves maintaining the bird in a dark, quiet, cool area with no disturbances. Dexamethasone appears to be the most important therapeutic agent. The prognosis is guarded-to-poor if the bird is convulsing.

### Compressive Lesions

Pigmented calvarium is characterized by a yellow discoloration (hemosiderin) in the skull, especially the pneumatic spaces of the temporal bones. These pneumatic cavities help regulate CSF pressure. There is no definitive correlation as yet between this condition and neurologic signs. Inflammation of the frontal bone was reported as a cause of opisthotonos and depression with violent convulsions.<sup>51</sup> Jugular stasis occurs secondary to thyroid enlargement and results in increased intracranial pressure. Hydrocephalus and intracranial masses cause compressive injury to the brain or spinal cord. With hydrocephalus, the cortex over the lateral ventricles has a "blister-like" appearance at necropsy.<sup>84</sup> Imaging techniques (CT or MRI) and EEG studies may be helpful in diagnosing these conditions.

### Spinal Abnormalities

Spinal fractures may be the result of injury or metabolic bone disease and may cause compression of the spinal cord. Tumors may affect the spinal cord by direct invasion or compression. MRI, CT scans and scintigraphy are useful imaging modalities for identifying these lesions, which may not be visible with plain radiographs, especially in the acute phase.

The junction of the fixed synsacrum with the more flexible portion of the thoracolumbar spine is a location susceptible to mechanical stress and vertebral subluxation. In broiler chickens, a congenital defect of the vertebral facets of T<sub>6</sub> and T<sub>7</sub> allows ventral displacement of T<sub>7</sub>, producing spondylolisthesis and varying degrees of spinal cord compression.<sup>148</sup> In a King Penguin, spondylolisthesis was believed to be the result of trauma because no articular defects were observed.

The intervertebral discs of birds differ from those of mammals. They consist of a fibrocartilaginous central region surrounded by a "C"-shaped synovial cav-

ity that extends around the dorsal and lateral margins of the disc. A fibrocartilaginous, wedge-shaped meniscus protrudes into the joint cavity from the dorsal and lateral margins.<sup>37</sup> This zygapophyseal joint has hyaline cartilage with an intervening synovial cavity. With intervertebral disc rupture, this meniscus is driven into the spinal canal along with the fibrocartilaginous disc material (see Color 14).

In a Black Swan, cervical intervertebral degenerative joint disease and spondylosis caused spinal cord compression and associated neurologic signs. In mammals with spondylosis, ventral and lateral osteophyte formation result in osseous bridging between adjacent vertebrae, while dorsal and dorsolateral osteophyte formation, as occurred in this swan, are rare. Spondylosis is believed to be the result of degenerative changes in the annulus fibrosis and intervertebral disc as a result of continuous heavy stress. In birds, the joints between vertebral bodies are synovial and in this swan, noninflammatory, degenerative changes were associated with the spondylosis. The degeneration, rupture and atrophy of the synovial-lined, fibrous intervertebral meniscus may have been involved in the pathogenesis of this disease.<sup>57</sup>

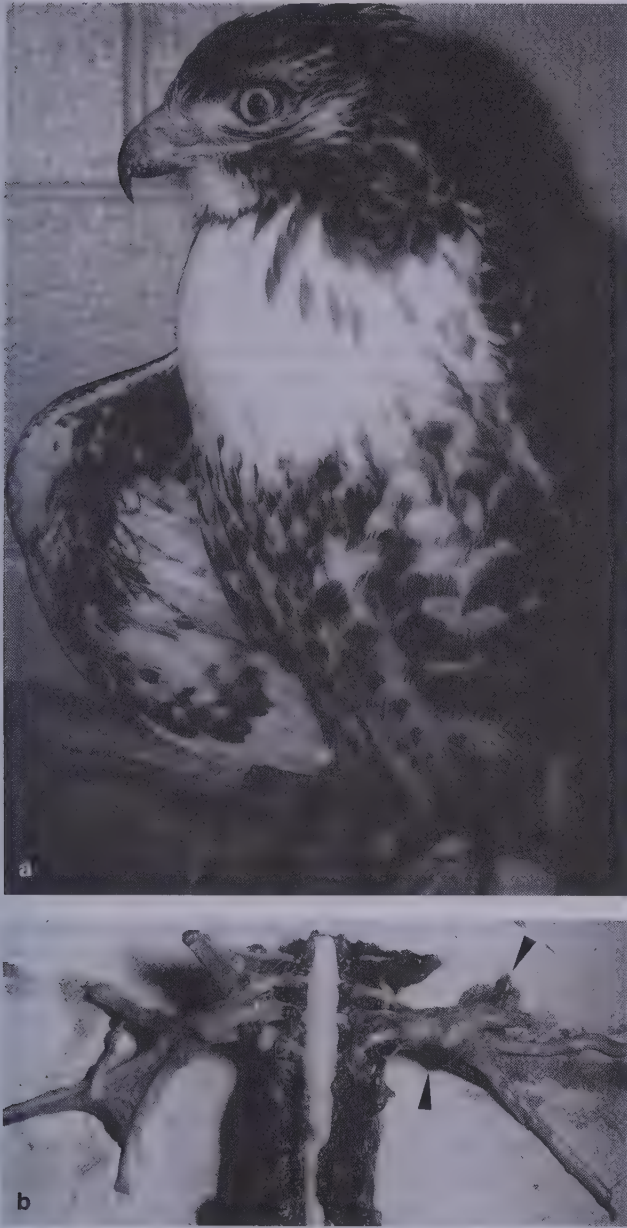
Dexamethasone and forced rest are the only recommended therapies for birds with spinal lesions. Myelography and spinal surgery have rarely been performed in birds. Naloxone and thyrotropin releasing hormone are beneficial in mammalian patients with spinal cord trauma, but their effects in avian patients are unknown.

## Peripheral Nervous System

### Trauma

Concussive peripheral nerve trauma occurs as a result of long bone fractures or impact trauma. The level of nerve injury (eg, neurapraxia, neurotmesis, axonotmesis or complete transection) determines the prognosis. In many instances, nerve dysfunction is transient; however, as in the case of brachial plexus avulsion, the damage may be permanent.

Brachial plexus avulsion occurs most commonly in traumatized free-ranging birds (Figure 28.8).<sup>34,46</sup> Clinically, there is evidence of denervation of the affected wing including lack of pain perception, paralysis with loss of withdrawal reflex and atrophy of the muscles of the affected wing and the ipsilateral pectoral muscles. Signs of Horner's syndrome may be present including ptosis and a dropped "horn" on the affected side of "horned" owls such as Screech and



**FIG 28.8** a) An immature Red-tailed Hawk was found down and unable to fly near a highway. A severe wing droop was present and radiographs indicated a fractured coracoid. The wing was placed in a figure-of-eight bandage and the fracture healed without complication. When the bandage was removed, the bird still had a severe wing droop, no deep pain and muscle atrophy involving most of the palpable muscle masses. b) At necropsy, swelling (arrows) and discoloration were present in the brachial plexus suggestive of an avulsion-type injury.

Great Horned Owls. Because of the skeletal muscle in the avian iris, miosis is not a consistent feature of Horner's syndrome. Interruption of the sympathetic pathway from T<sub>1</sub> and occasionally T<sub>2</sub> segments results in these clinical signs.

A long bone fracture may or may not be associated with peripheral nerve injuries. It may be difficult to determine the level of nerve injury in birds presented with clinical signs associated with a unilateral peripheral neuropathy involving one extremity. Typically, birds with neurapraxia improve clinically within two to four weeks, while those with axonotmesis and neurotmesis (as with avulsion injury) would not.<sup>34</sup> EMG and spinal-evoked potentials can help determine the degree of injury. If these are not available, it is prudent to treat with supportive care for approximately one month, with weekly evaluation for signs of improved neurologic function.

### Abdominal Masses

Compressive peripheral nerve trauma generally occurs secondary to an expanding mass that applies pressure to the nerve (see Figure 25.10). Because the pelvic nerves pass through the renal parenchyma, tumors or infection of the kidneys can damage the nerves (see Color 21). Ovarian tumors, if very large or invasive, have also been reported to damage these nerves. Of 74 budgerigars with abdominal tumors, 64 had paresis of one or both legs.<sup>104</sup> Paresis is usually unilateral in the early stages and is accompanied by abdominal distention.

Renal adenocarcinomas occur more commonly in males than females and the incidence is higher in psittacine than passerine birds (see Color 25). The most common sign is a unilateral leg paresis progressing to paralysis. Affected birds may demonstrate an abdominal lift. The paresis may become bilateral, but systemic signs usually develop before the contralateral limb is affected. The bird may have a palpable abdominal mass with polydipsia and polyuria. Grossly, these tumors are 1 to 2.5 cm in diameter, irregular, ovoid, globular, white or off-white with cysts or necrotic foci. They may metastasize to the liver (see Color 20).

The biologic behavior, clinical signs and gross appearance of embryonal nephromas are similar to renal adenocarcinoma. They usually contain more cysts and necrotic foci and are less frequently associated with paralysis. They occur in younger birds (three to five years old). Ovarian adenocarcinomas and granulosa cell tumors usually cause anorexia, weight loss and diarrhea, but can invade the kidneys and compress the pelvic nerves. If these tumors cause paralysis, the patient is likely to show an abdominal lift.

All of these tumors are associated with a poor prognosis. Excision may be attempted but if neurologic signs are present, the neoplasm is generally not amenable to resection. These tumors cause a peripheral neuropathy with a loss of withdrawal reflex not observed with a spinal cord lesion.

Egg binding or internal trauma associated with oviposition may result in hemorrhage and swelling around the area of the pelvic plexus, causing a transient paresis or paralysis secondary to neurapraxia.

### Circulatory Disturbances

Both peripheral and central neuropathies have been associated with diminished circulation. Atherosclerosis occurs with some degree of frequency in birds. Most commonly, no clinical signs are associated with this condition, and affected birds are simply found dead in their enclosure. In some cases, however, neurologic signs may be observed. Atherosclerosis of the carotid arteries has been described as a cause of ischemia and cerebral hypertension.<sup>22,51,64</sup>

Neurologic signs associated with atherosclerosis include a sudden onset of blindness, ataxia, paresis and seizures. A Blue-fronted Amazon Parrot, which had a 90 to 95% reduction in lumen diameter in one carotid artery and a 60 to 70% reduction in the other due to atherosclerosis, presented with clinical signs of regurgitation once daily, an "aura-like" behavior and holding the right leg in front of the body while going into a semiconscious state. Another Blue-fronted Amazon Parrot with progressive hind limb paresis was found to have severe atherosclerosis at necropsy.<sup>64</sup>

Signs ranging from blindness and ataxia to opisthotonos and seizures have been associated with cerebrovascular accidents and ischemic infarction.<sup>22,46,51,130</sup> MRI, CT scans and EEG may be useful in diagnosing these lesions.

### Primary Neoplasms of the Nervous System

Glioblastoma multiforme, choroid plexus tumors, Schwannomas and astrocytomas, pineal body tumors, undifferentiated sarcomas and hemangiomas have been described in the nervous system of companion birds.<sup>51,116,118,140</sup> Clinical signs vary with the location of the neoplasm. Imaging with MRI or CT may be useful in determining the location of the mass; however, all neural tumors are associated with a grave prognosis. Phenobarbital for control of seizures and dexamethasone to decrease cerebrospinal

fluid production (thus, intracranial pressure) may provide symptomatic relief.

Pituitary adenoma or pituitary chromophobe adenoma occurs in young (four years old), predominantly male budgerigars with a two to three percent prevalence. These tumors arise from chromophobe cells and may or may not be functional, secreting tumors. The avian pituitary gland secretes LH, FSH, TSH, ACTH, growth hormone, melanocyte stimulating hormone (MSH) and prolactin (in Columbiformes). These tumors are reported to cause a classic clinical syndrome described as somnolence with occasional convulsions, uncoordinated wing-flapping and clonic leg twitches, followed by unconsciousness.<sup>51</sup> Clinical signs are usually the result of compression of the brain and cranial nerves. Incoordination, tremors and inability to perch have also been reported.<sup>91</sup> Polydipsia and polyuria, cere color change, feather abnormalities and obesity may occur with functional tumors. Exophthalmos, visual deficits, lack of pupillary light response and mydriasis may be present also.<sup>97,140</sup>

A tentative diagnosis may be confirmed with contrast-enhanced CT scanning of the skull. Because clinical signs are primarily related to compression of the brain and not to adrenal hypersecretion, therapy with o,p'-DDD is not generally indicated.<sup>140</sup> Radiation therapy is effective in treating human and canine pituitary tumors and may be efficacious in birds. A report suggests that this tumor is transmissible; however, this theory has not been confirmed.<sup>54</sup>

## Metabolic Neuropathies

### Hepatic Encephalopathy

Birds with severe liver disease may demonstrate signs of hepatic encephalopathy. Hepatic lipidosis, mycotoxicosis, hemochromatosis and vaccine-induced hepatopathy have been reported to cause clinical signs of depression, ataxia, diminished conscious proprioception and seizures (see Color 20).<sup>98,110,135,146</sup> With hepatic encephalopathy, these signs usually occur shortly after eating when the blood levels of neurotoxins absorbed from the gastrointestinal tract (and not properly processed by the liver) are high. Various compounds are believed to contribute to the clinical signs associated with hepatic encephalopathy including ammonia, glutamine, glutamate, alpha ketoglutarate, aromatic amino acids, methionine, mercaptans and short chain fatty acids.<sup>18</sup> In addition, abnormal neurotransmitters, alterations in the blood-brain barrier, alterations in neuroreceptors, al-

tered cerebral sensitivity and hypoglycemia contribute to the development of clinical signs associated with hepatic encephalopathy.

Postprandial blood ammonia concentrations may be elevated and can be determined using a conspecific control bird.<sup>135</sup> In a Toco Toucan with hepatic encephalopathy, the three-hour postprandial blood ammonia level was 350 µg/dl, while the conspecific control was only 86 µg/dl. Ammonia tolerance tests may be beneficial in diagnosing some cases; however, a parallel test should be performed on an asymptomatic bird of the same species. Serum bile acids assays are a more reliable and safer test of hepatic function.

Treatment should be directed toward the underlying cause of hepatic failure. Lactulose syrup and a low-protein, high-carbohydrate, high-quality protein diet with a vitamin supplement may provide symptomatic relief while the underlying hepatopathy is corrected.<sup>135</sup> Neomycin sulfate may decrease the formation of ammonia by reducing the quantity of gram-negative bacteria in the colon.

### Hypocalcemia

A syndrome characterized by opisthotonos, tonic extension of the limbs and convulsions has been described in young (two- to five-year-old) African Grey Parrots.<sup>43,53,95,101,122,123</sup> Initially, an affected bird may only seem uncoordinated and fall from its perch. The frequency gradually increases, seeming to be precipitated by some external stimulation. Eventually, seizure activity is pronounced and may become constant or prolonged. Serum calcium levels are below 6.0 mg/dl with concentrations as low as 2.4 mg/dl reported. It has been shown that parathyroidectomized birds begin to have seizures when the serum calcium concentration falls below 5.0 mg/dl.<sup>127</sup> Birds demon-

strating only intermittent incoordination may still have normal serum calcium levels. This condition has also been observed in Amazon parrots and conures.<sup>122</sup>

At necropsy, the parathyroid glands of affected African Grey Parrots are grossly enlarged, presumably in response to the low serum calcium concentrations (see Color 14). Parathyroid hyperplasia and degeneration are prominent histologic findings. Vacuolation of the cells of the adrenal glands is a consistent feature and may be an indication of stress. There is no skeletal demineralization present in this syndrome.<sup>122</sup> In most birds with signs of nutritional secondary hyperparathyroidism, serum alkaline phosphatase activity is increased; however, this change has not been found to occur with the hypocalcemia syndrome in African Grey Parrots.<sup>53</sup>

The etiology and pathogenesis of this condition remains speculative. Affected birds are usually wild-caught and are maintained on a diet deficient in calcium and vitamin D<sub>3</sub> (usually a whole-seed diet). It appears that these birds are not able to mobilize body calcium stores (as occurs in cows with "milk fever"). Vitamin A deficiency may also play a role, as hypovitaminosis A has been shown to inhibit osteoclast activity.<sup>123</sup> It has been postulated that a virus that affects parathyroid function is the cause of this problem; however, attempts to demonstrate viral particles using electron microscopy have failed. Another hypothesis suggests that there is increased renal excretion of calcium.<sup>95,122</sup>

Diazepam may be used as an anticonvulsant, but birds generally rapidly respond to the parenteral administration of calcium gluconate. Seizure activity would be expected to cease well before serum calcium levels return to normal.<sup>53</sup> Corticosteroids should not be used in these patients because they increase urinary excretion and decrease intestinal absorption of calcium.

Once the serum calcium concentration has returned to within normal limits, the patient should be placed on a proper diet with calcium and vitamin supplementation. Foods such as dairy products should be encouraged, while those high in fat such as seeds should be eliminated. Serum calcium concentration should be evaluated periodically (every two to four months) to determine if alterations in therapy are indicated. The prognosis for full recovery appears to depend on the severity of damage to the parathyroid glands. If the condition is detected before complete

### CLINICAL APPLICATIONS

- The corpus striatum is well developed and is considered the main center for association in birds; consequently, instincts dominate avian behavior, which may account for some of the self-mutilation that occurs in companion birds.
- Birds are ten to twenty times more susceptible than mammals to acetylcholine inhibitors found in organophosphate and carbamate pesticides. Young birds and males are also more susceptible.
- Because withdrawal of an extremity following stimulation is a segmental reflex that does not require an intact cervical spinal cord for normal response, movement does not indicate the patient is able to feel the stimulus.

degeneration of the glands has occurred, the prognosis is favorable.

Because it appears that these birds cannot mobilize body stores of calcium, long-term prevention of recurring problems requires that birds receive adequate levels of calcium in proper balance with phosphorus, as well as sufficient levels of vitamins A, D<sub>3</sub> and E.

### Hypoglycemia

Hypoglycemia may occur as a result of starvation or malnutrition, hepatopathy, endocrinopathies and septicemia. Blood glucose less than 150 mg/dl (or half the species' normal value) may be an indication of hypoglycemia.<sup>146</sup> Seizure activity usually occurs once the blood glucose level falls below 100 mg/dl. Therapy should consist of 1.0 ml/kg IV of a 50% dextrose solution for acute relief of clinical signs, while the underlying cause of the problem is being determined and corrected. Dextrose solutions (>2.5%) should be administered intravenously with caution because they are hypertonic and may cause tissue damage if perivascular leaking occurs. Dextrose will compromise a patient's acid-base balance and should not be used in dehydrated birds.

### Seizures and Idiopathic Epilepsy

Seizures in birds can have numerous etiologies and various clinical presentations (Table 28.1). A typical seizure may consist of a short period of disorientation with ataxia followed by falling to the enclosure floor as a result of the loss of the ability to grip the perch (Figure 28.9). The bird may remain rigid or have major motor activity for a few seconds or a few minutes. Voiding may or may not occur. The postictal phase is variable.

**TABLE 28.1 Common Causes of Seizures in Birds**

- Nutritional (Calcium, phosphorus and vitamin D<sub>3</sub> imbalances, vitamin E and selenium deficiencies, thiamine deficiency, hypovitaminosis B<sub>6</sub>)
- Metabolic (Heat stress, hypocalcemia, hypoglycemia, hepatic encephalopathy)
- Toxic (Heavy metals, insecticides)
- Infectious (Bacterial, fungal or parasitic meningitis or encephalitis)
- Traumatic
- Neoplastic
- Hypocalcemic (African Grey Parrots)
- Hypoglycemic (Raptors)

### Idiopathic Epilepsy

Idiopathic epilepsy is used as a diagnosis when other causes of seizures have been ruled out. A syndrome of idiopathic epilepsy has been described in Red-lored Amazon Parrots that has been suggested to have a genetic basis.<sup>124</sup> Seizures of undetermined cause occur with some degree of frequency in Greater Indian Hill Mynahs as well. Mild to severe seizure activity may occur in these birds with signs ranging from "periodic trance-like states" and "stiffening up" to grand mal-type seizures.

Diazepam can be used to temporarily interrupt seizure activity.<sup>125,126,146</sup> Long-term phenobarbital at a dose of 4.5-6.0 mg/kg PO BID titrated to effect, appears to be beneficial in reducing the frequency and severity of seizures in these birds.<sup>124</sup> Blood phenobarbital concentration should be determined approximately one month after institution of therapy to evaluate the dosage. Owners should be advised that the therapy does not "cure" the condition, and they should keep a calendar recording seizure activity and severity.

The use of electroencephalograms in diagnosing epilepsy is difficult in any species of animal. The knowledge of normal electroencephalogram patterns for avian species is limited as is the availability of the equipment and trained personnel to make and evaluate the EEG. Even in species where EEG patterns indicative of epilepsy are established, it is recognized that between seizures, the EEG may be normal.<sup>146</sup>

### Lafora Body Neuropathy

Lafora body neuropathy has been reported as a cause of fine, continuous myoclonus in one cockatiel and weakness, anorexia and dyspnea in another cockatiel.<sup>1,9,11</sup> This disease is characterized by the formation of glycoprotein-containing cytoplasmic inclusion bodies within neurons. This accumulation of glycoproteins is believed to be the result of a defect in intracellular metabolism. In humans, the condition is known as familial progressive myoclonic epilepsy. It has also been diagnosed as a cause of spontaneous convulsions or epilepsy in beagles, miniature poodles and basset hounds. The inclusions may be found in other organs including the liver, heart, skeletal muscle and sweat glands. In the affected cockatiel, Lafora-like particles were identified diffusely throughout the liver.<sup>9,11</sup>



**FIG 28.9** A mature Umbrella Cockatoo that was maintained in a dark room on a wild-bird-seed diet was presented for an acute onset of convulsions. The bird was severely depressed and was unable to stand. Note the poor general condition of the feathers. The bird did not respond to supportive therapy. Necropsy findings included microhepatia, hypertrophy of the parathyroid glands and enlarged adrenal glands.

weakness, ataxia, paresis, paralysis, loss of voice, head tilt, blindness, circling and seizures.

Lead intoxication causes a demyelination of the vagus nerve and a block of presynaptic transmission by competitive inhibition of calcium. Demyelination produces the clinical signs associated with peripheral neuropathy. Lead encephalopathy is the result of diffuse perivascular edema, increases in cerebrospinal fluid and necrosis of nerve cells.<sup>100</sup>

Histologically, neurologic lesions associated with plumbism include neuronal degeneration with shrunken, angular, basophilic neurons of the cerebral cortex and edema of Virchow-Robin spaces and leptomeninges.<sup>59,106</sup> Vacuolation of the neuropil of the cerebral cortex, optic lobes and medulla may be present. Gross and microscopic neurologic lesions may be absent, even in birds with neurologic signs.<sup>92</sup>

### Xanthomatosis

The etiology of xanthomatosis is unknown but it seems to develop as a response to deep inflammation (see Chapter 25). The clinical manifestation is thick yellow skin usually in the area of the sternum and ventral abdomen. Xanthomatosis may affect the brain where it appears in association with blood vessels.<sup>51</sup>

### Toxic Neuropathies

#### Heavy Metals

Lead and zinc poisoning are the most common causes of toxicity in birds (see Chapter 37).<sup>92</sup> In addition to common sources of lead contamination, chronic exposure to automobile exhaust has been shown to contribute to the cumulative lead concentrations in body tissues.<sup>88</sup>

Clinical signs associated with lead intoxication are dependent on the amount ingested and the chronicity of the intoxication. Lead adversely affects all body systems by inhibiting enzyme activity and protein formation.<sup>100</sup> Nervous, digestive and hematopoietic systems are most affected. Neurologic changes suggestive of plumbism include lethargy, depression,

#### Botulism (Limber Neck)

Botulism in birds is usually the result of ingestion of the exotoxin of *Clostridium botulinum* type C. Occasionally *C. botulinum* type A and type E are involved. The organism is an anaerobic, spore-forming bacillus. Spores are present in the soil of many wetlands and are numerous in marsh areas with a history of the disease. The spores are environmentally stable, can survive in the soil for years and are resistant to heat and chemical disinfectants.

Botulism is uncommon in companion birds, but occurs with some degree of frequency in waterfowl. Decaying organic matter provides adequate substrate for development of the clostridial spores. The toxin can persist for months under alkaline conditions (pH 9). Intoxication occurs following ingestion of contaminated food such as necrotic tissue (plant or animal) or dipterous maggots and other invertebrates. Maggots concentrate the toxin without being affected. Birds eat the toxin-laden maggots and disseminate the disease. It is generally the larval stages of blowflies and fleshflies (Calliphoridae and Sarcophagidae) that are found in high concentrations on decomposing carcasses and carry the greatest concentrations of toxin.<sup>89</sup> In an outbreak in pheasants,

20,000 maggots were collected from one carcass, each containing  $4 \times 10^4$  mouse MLD of type C toxin/g of maggots. It has been estimated that one ounce of type C toxin could kill the entire population of the United States.<sup>95</sup>

The toxin interferes with the release of acetylcholine at motor endplates causing signs of peripheral neuropathy. All peripheral nerves, including cranial nerves, are affected. The classic clinical sign is a limber neck resulting from paralysis of the cervical musculature. Most birds exhibit hindlimb paresis first, which is characterized by sitting on their sternum with legs extended behind their body.<sup>12</sup> Paralysis of the wings followed by loss of control of the neck and head are observed in the terminal stages. Green diarrhea with pasting of the vent are also common with botulism.<sup>12,39,48</sup> Inconsistent clinical findings with botulism are chemosis, swelling of the eyelids and nictitans, ocular discharge and hypersalivation.<sup>12,48</sup>

Gross and histologic examination generally fail to reveal any lesions. In some cases, maggots may be observed within the proventriculus, and some birds have a pericardial effusion.<sup>12,48</sup> The toxin can be detected in stomach contents, serum or plasma. The mouse protection test is used to provide an ante-mortem diagnosis in most cases. Mice are challenged with the serum of an affected bird and control mice are left untreated while others receive antitoxin. A positive diagnosis is made if only unprotected mice die. This test is accurate approximately 75% of the time.<sup>48,62</sup> In an outbreak where toxin was not detected in serum, the toxin was recovered from the spleen and liver.<sup>39</sup>

Therapy is primarily supportive. Cathartics, laxatives and drenches are used to flush unabsorbed toxins through the gastrointestinal tract. Tube-feeding provides nutritional support for birds that are unable to eat and drink. Antitoxin may be administered intraperitoneally, but it is not commercially available and its benefits are equivocal.<sup>12,48,72</sup>

Efforts should be made to prevent exposure of birds to maggots and other sources of botulism toxin. Ponds and lakes should not be used for disposal of carcasses and organic debris. They should be dredged periodically, and a fountain or other means of aeration should be provided.

### Pesticides

The United States Environmental Protection Agency has registered 36 different organophosphate and 46

carbamate compounds such as carbaryl (Sevin dust), dursban (chlorpyrifos), diazanon, malathion, dichlorvos and methyl carbamate.<sup>113</sup> Both of these compound classes are acetylcholinesterase inhibitors that bind to and subsequently inactivate acetylcholinesterase causing an accumulation of acetylcholine at the postsynaptic receptors. Organophosphate bonds are considered irreversible, while carbamate bonds are slowly reversible (spontaneous decay in several days). Acetylcholine is the neurotransmitter found at autonomic ganglia (both sympathetic and parasympathetic); postganglionic parasympathetic nerves affecting smooth muscle, cardiac muscle and exocrine glands; and at neuromuscular junctions of the somatic (skeletal muscle) nervous system.<sup>72,119</sup>

Birds are 10 to 20 times more susceptible to these acetylcholine inhibitors than mammals. Young birds and males are also more susceptible.<sup>94</sup> The development of clinical signs is dependent on the concentration of the pesticide, the route and proximity of exposure, the amount of ventilation, the species of bird and its physical condition.<sup>72</sup> Exposure in companion birds is generally accidental or the result of inappropriate use of insecticide products. The most common route of exposure is inhalation.

Two types of neuropathy and corresponding clinical signs have been described related to toxicosis with acetylcholinesterase inhibitors.<sup>72</sup> Acutely, clinical signs are related to excessive stimulation of acetylcholine receptors. Signs include anorexia, crop stasis, ptyalism, diarrhea, weakness, ataxia, wing twitching and muscle tremors, opisthotonos, seizures, bradycardia and prolapse of the nictitans.<sup>72,94,113,119</sup> Bradycardia and dyspnea with crackles and wheezes may occur as the toxicosis progresses. Respiratory failure is usually the cause of death and results from increased mucus secretion, bronchoconstriction and paralysis of respiratory musculature.

The second type of neuropathy is an organophosphate ester-induced neuropathy, which is not associated with an inhibition of acetylcholine.<sup>73</sup> The onset of clinical signs is delayed (7 to 21 days after exposure) and is the result of a symmetric distal primary axonal degeneration of the central and peripheral nervous systems, with secondary myelin degeneration. Clinical signs include weakness, ataxia, decreased proprioception and paralysis.

Diagnosis of acetylcholinesterase inhibition is usually based on clinical signs and a history of exposure



to these compounds. Cholinesterase assay may be performed on blood, plasma, serum or brain tissue. A decrease in acetylcholinesterase of 50% from normal is considered diagnostic.<sup>73</sup> Normal avian plasma cholinesterase levels are reported to be greater than 2000 IU/l. A new cholinesterase test requires only 0.01 ml of serum and results may be available in five minutes.<sup>113</sup>

Intoxication is best treated with atropine, pralidoxime chloride (2 PAM) and supportive care (see Chapter 37).<sup>119</sup>

The exact mechanism of action of organochloride insecticides, such as DDT, is unknown, but clinical signs are usually neuromuscular, resulting from either stimulation or depression of the central nervous system.<sup>11</sup> There is no known antidote for organochloride intoxication. Birds with seizures or other signs of CNS stimulation should be tranquilized or lightly anesthetized with a long-acting agent such as phenobarbital. In cases of CNS depression, stimulants may be beneficial. Cathartics, activated charcoal and general supportive care should be provided as necessary (see Chapter 37).

#### Therapeutic Agents

Dimetridazole was commonly used to treat trichomoniasis, giardiasis and histomoniasis. Toxicity results in birds with increased water consumption (increased intake of drug). Convulsions, wing flapping and opisthotonos have been reported in budgerigars, goshawks, pigeons and ducks. Histologically, large clear spaces are present around blood vessels, neurons and glial cells. Neurons have a pyknotic nucleus and eosinophilic cytoplasm. Dimetridazole is no longer commercially available in the United States.

Metronidazole toxicity has been reported in dogs and cats, but not in companion birds. Clinical signs relate primarily to the vestibular system and include ataxia, incoordination, proprioceptive deficits, nystagmus, depression, paresis, tremors and seizures. Treatment involves limiting further absorption of the drug (eg, absorptives, emetics and cathartics), fluid therapy to increase renal excretion, control of seizure activity and supportive care.

#### Other Neurotoxins

Many plants are toxic to the nervous and digestive systems. Generally, birds are more resistant than mammals to plant-derived toxins (see Chapter 37).

Citreoviridin and tremorgens are two types of mycotoxins that primarily affect the neural system. Fusa-

riotoxins and ochratoxins also produce nervous disorders. A syndrome characterized by cervical paresis in free-ranging Sandhill Cranes has been associated with mycotoxicosis.<sup>107</sup>

Domoic acid poisoning was diagnosed as the cause of death in Brown Pelicans and Brandt's Cormorants exhibiting neurologic signs. Twenty-seven of 39 affected birds died within 24 hours.<sup>153</sup> Domoic acid is a neurotoxin produced by marine diatoms. It is an excitatory toxin that binds to both pre- and postsynaptic kainate receptors in the brain, resulting in continuous depolarization of neurons until cell death occurs. It was theorized that this epornitic was caused by the ingestion of contaminated anchovies, which had fed on the diatoms.

## Infectious Neuropathies

### Fungal

The nervous system may be a secondary site for aspergillosis lesions that may cause ataxia, opisthotonos and paralysis. In infected birds, yellowish, mycotic nodules may be grossly visible within the brain or spinal canal. Fungal granulomas may compress or invade peripheral nerves and cause unilateral or bilateral paresis or paralysis (see Color 14).<sup>47</sup> Spinal aspergillosis has been diagnosed in several penguins at the San Francisco Zoological Gardens. Fungal elements are usually detected histologically (see Chapter 35).

*Dactylaria gallopava* has been reported in Grey-winged Trumpeter Swans and gallinaceous birds. The organism is present in wood chips and bark litter. Infections characterized by encephalomyelitis occur following the inhalation of fungal spores. *Cladosporium (Exophiala)* and *Mucomyces* have also been reported to cause meningoencephalitis.<sup>31</sup>

### Parasitic

#### Toxoplasma

*Toxoplasma gondii* infections are reported primarily in Galliformes and Passeriformes with lesions involving the brain and skeletal muscles. Cats are the only host known to excrete infectious oocysts.<sup>36</sup> Considering avian species, it would seem that raptors are

most likely to become infected because they prey on the same types of animals as cats. Although toxoplasmosis has been reported in raptors, they appear to be more resistant to infection than other birds.<sup>36,78</sup>

Clinical signs include anorexia, pallor, diarrhea, blindness, conjunctivitis, head tilt, circling and ataxia. Infection may occur from ingestion of coprophagic arthropods or food and water supplies contaminated with feces from infected cats. Encapsulated cysts (round or oval) are found in the brain histologically. A definitive diagnosis is made using a latex agglutination serum test or immunohistochemical staining of affected tissues. There is variation among avian species with respect to the antibody response generated against *Toxoplasma* sp. Chickens do not develop antibodies, while raptors, pigeons, canaries and finches have been shown to develop positive agglutination antibody titers.<sup>36,70,144</sup> In experimentally infected raptors, cysts were found in the brain and muscles (skeletal and cardiac) even when no clinical abnormalities were noted.

In canaries and finches, toxoplasmosis has been shown to cause loss of myelinated axons in the optic nerve resulting in blindness and conjunctivitis.<sup>144</sup> Tachyzoites could be demonstrated in the detached and intact retinae, lenses and exudate from the vitreous humor. Focal, disseminated, chronic inflammation with accumulations of tachyzoites characterized the histologic findings in the brains (see Chapter 36).

### Sarcocystis

*Sarcocystis* spp. infect a broad range of hosts in several orders of birds. Infection in birds is reported to be less common than in mammals; however, infection has been reported in over 60 species of birds, with Old World psittacines apparently more susceptible (see Chapter 36). Unlike many other species of *Sarcocystis*, *S. falcatula* schizonts can persist in avian tissues for up to 5.5 months.<sup>36</sup> It is believed that cockroaches and flies may be transport hosts for the parasite.<sup>26,52</sup> Raptorial species may become infected by ingestion of prey containing the encysted organism.<sup>1,36</sup>

Histologically, the organisms are elongated, spindle- or banana-shaped, and grouped into packets within a spherical- to spindle-shaped cyst. Granulomatous inflammation consisting of macrophages and lymphocytes forming nodular and diffuse aggregates is associated with these cysts. With electron microscopy, characteristic polar rings and micronemes may be discernable.<sup>58</sup>

### Schistosomiasis

Granulomatous encephalitis caused by the blood fluke *Dendritobilharzia* sp. has been reported in swans.<sup>77,147</sup> Neurologic signs included head tilt, circling, weakness and extension of the head and neck. Granulomas containing macrophages, giant cells, lymphocytes and occasional heterophils and fibroblasts were identified within the cerebrum and cerebellum of affected birds. Ova of the parasite were identified within these lesions. Adult flukes were identified within the blood vessels in one bird. Adult schistosomes usually live within veins; however, those of the genus *Dendritobilharzia* live within arteries. Adults have little host-specificity.

### Baylisascaris sp.

*Baylisascaris procyonis* is the ascarid of raccoons and is a zoonotic organism that can cause fatal meningoencephalitis in humans. Over 40 species of mammals and birds have been shown to develop clinical cerebrospinal nematodiasis following infection.<sup>4,5,68,99</sup> Free-ranging birds are infected by ingesting raccoon feces, while companion birds may become infected by ingestion of food contaminated with parasite eggs. The eggs may remain viable and infective in the environment for years.

Clinical signs are nonspecific and include depression, ataxia and torticollis. The onset may be acute or chronic, possibly related to the number of larvae involved. Prolonged migration of a single larva within the brain could produce chronic, progressive signs. Treatment with ivermectin has been completely ineffective.<sup>5</sup>

Gross lesions are generally absent. Edema of the brain and spinal cord, encephalitis, encephalomalacia, eosinophilia around sections of larvae, degenerative foci with heterophils in the neuropil, perivascular cuffing and glial cell proliferation are observed histologically.<sup>4,5,38,67,99</sup> In some cases, a cross section of the parasite may not be observed as the larvae migrate even after host death.<sup>99</sup>

### Filaria

*Chandlerella quiscalis* is a filariid nematode of grackles that has been reported to cause cerebrospinal nematodiasis in emus.<sup>7</sup> Gnats are the vectors for natural infection. The gnat is ingested and the larvae migrate into the brain or spinal cord and then into the lateral ventricles of the cerebrum where they mature and produce microfilaria. Affected emu chicks demonstrated torticollis, ataxia, recumbency

and death. Circulating microfilaria were not detected (see Chapter 36).

### ■ Viral Neuropathies

The following viral diseases of birds have neurologic clinical or histologic abnormalities as part of their pathophysiology; most produce lesions in other systems as well. Only their effects on the nervous system will be discussed here. For a more complete discussion of these viruses, see Chapter 32.

#### Paramyxovirus

Paramyxoviruses (PMV) 1, 2, 3 and 5 have been isolated from companion birds, and groups 1 and 3 have been associated with lesions of the central nervous system.<sup>75</sup> Pigeon paramyxovirus causes a non-suppurative encephalitis similar to that described with Newcastle disease virus.<sup>129</sup>

Clinical signs associated with PMV-1 in companion birds are variable depending on the virulence of the strain and the species of bird affected. In some cases, the only signs may be acute death and high mortality. Other signs are associated with abnormalities of the respiratory, digestive and nervous systems.<sup>23,24,30</sup> Neurologic signs including depression, hyperexcitability, ataxia, incoordination, torticollis, head tremor, opisthotonos, muscle tremors and unilateral or bilateral wing or leg paresis or paralysis occur more commonly in older birds and with chronic infections.<sup>24,30</sup> Some birds clench their feet while others lose control of the tongue and their ability to grip with the beak.<sup>23</sup>

All reflexes are depressed but neurologic signs are exacerbated by excitement. Seizures and running movements are often observed just prior to death. Neurologic signs generally persist in birds that survive the acute infection.<sup>142</sup>

At necropsy, there may be petechiae on the surface of the cerebrum and cerebellum.<sup>23</sup> Histologically, central nervous system lesions are commonly observed in the cerebellum, brainstem, midbrain and spinal cord. Neuronal degeneration, gliosis, endothelial cell hypertrophy and lymphocytic perivascular cuffing characterize the lesions.<sup>30,114</sup>

Lymphoplasmacytic meningoencephalitis outbreaks have been described in *Pionus* species and *Neophema* species from a quarantine station. These deaths were caused by an unclassified hemagglutinating virus that morphologically resembles paramyxovirus.<sup>82,84</sup> The disease produced high morbidity and moderate

mortality. Muscle tremors, circling, ataxia, torticollis, weakness, depression, paresis and paralysis were the major clinical signs.

A yellowish periventricular discoloration was the only abnormal gross brain lesion noted. Histologically, there was lymphoplasmacytic perivascular cuffing adjacent to the ventricles, within the choroid plexus and around the central canal of the spinal cord, sometimes accompanied by edema of the neuropil. Some ependymal cells and few subependymal glial cells had equivocal eosinophilic Cowdry type A inclusions. On electron microscopy, these contained virions compatible with paramyxovirus.

#### Neuropathic Gastric Dilatation

There is strong evidence that neuropathic gastric dilatation is caused by a virus (possibly a paramyxovirus). Anorexia, regurgitation, changes in fecal consistency, weight loss, pectoral muscle atrophy and depression are presenting clinical signs.<sup>55,64,90,139,151</sup> The clinical signs of this disease primarily relate to the gastrointestinal system, with central and peripheral neurologic signs occurring only occasionally.<sup>64,150</sup> However, the main histologic lesions involve the nervous system.

Creatine kinase is an enzyme released from damaged nerves and muscles. It has been reported that some birds with neuropathic gastric dilatation have elevated serum CK levels; however, an elevation of serum CK activity is not specific for this disease and may occur with septicemia, neuropathies and myopathies.<sup>60</sup>

Microscopic lesions generally involve the brainstem, the ventriculus and the proventriculus. Multifocal lymphocytic encephalitis with lymphocytic perivascular cuffing, gliosis and neuronophagia characterize the brainstem lesions.<sup>55</sup> Asymmetric lymphocytic poliomyelitis, lymphocytic perivascular cuffing and gliosis are present in the spinal cord. Multifocal lymphocytic leiomyositis with smooth muscle degeneration and fibrosis are common in the ventriculus and proventriculus.

There is a general loss or depletion of myenteric ganglion cells (myenteric ganglioneuritis). The ganglia of gastric and duodenal myenteric plexuses demonstrate round cell accumulations (lymphocytes, plasma cells, macrophages). Intranuclear and intracytoplasmic eosinophilic inclusion bodies have been described within the perikaryon of the celiac ganglion and myenteric plexus.<sup>90</sup> Virus particles associ-

ated with the inclusions have been morphologically similar to paramyxovirus particles.

### Avian (Picornavirus) Encephalomyelitis

This picornavirus has been associated with gastrointestinal and neurologic signs in Galliformes, Anseriformes and Columbiformes.<sup>8,51,89,132,133</sup> Only one serotype is recognized but strains vary in neurotropism. Clinical signs include depression, ataxia, paresis or paralysis and severe, but fine head and neck tremors. Neurologic signs occur only in birds less than 28 days of age.<sup>51</sup> No characteristic gross lesions are noted at necropsy. Neuronal degeneration with lymphocytic perivascular cuffing and gliosis in the brain and spinal cord characterize the disease histologically.<sup>89</sup>

### Polyomavirus (Budgerigar Fledgling Disease)

Although not the primary lesions, tremors of the head, neck and limbs, incoordination and ataxia have been associated with polyomavirus in infected birds. Histologically, large, slightly basophilic intranuclear inclusion bodies can be identified in the cerebellar ganglionic layers.<sup>88,91,131</sup>

### Reovirus

Reovirus is commonly reported in imported birds and primarily affects African Greys, cockatoos and other Old World Psittaciformes. Clinical signs include uveitis, depression, emaciation, anorexia, incoordination, ataxia, paresis and diarrhea. Histologically, multifocal necrosis of the liver is present. This is not a neurotropic virus, and the paresis or paralysis is the result of vascular thrombosis of the extremities.

### Togaviridae

Viral encephalitis caused by a number of togaviruses has been reported in numerous species of birds. Clinical signs include depression, ruffled feathers, decreased appetite, dyspnea, profuse hemorrhagic diarrhea (in emus), ataxia, muscle tremors, weakness, unilateral or bilateral paresis or paralysis, torticollis and death. At necropsy, the cerebral hemispheres may be softened. Histologically, lesions include non-suppurative encephalitis, patchy neural necrosis, cerebral vasculitis, leukocytic perivascular infiltrates, microgliosis, meningitis, neuronal degeneration and myocardial necrosis.<sup>121</sup> These changes have a rostral distribution contrary to most avian viral encephalitides. Vaccines are available and appear to be beneficial in outbreaks.<sup>15,51,56,21,121,138</sup>

### Marek's Disease

This lymphoproliferative disease is caused by a herpesvirus. Peripheral nerve dysfunction occurs second-

dary to lymphoid infiltrates. Often birds display a spraddle-leg paralysis with one leg extended forward and the other back. Grossly, the ischiatic nerves appear enlarged with a loss of striations and a gray discoloration. In a study of neoplasms of budgerigars, many birds with abdominal tumors also had evidence of infection with avian leukosis virus; however, similar findings were not confirmed in another study.<sup>43,104</sup>

### Encephalomyelitis in Lorikeets

Encephalomyelitis was described in free-ranging Australian lorikeets.<sup>102</sup> Affected birds demonstrated a progressive bilateral paralysis with clenched feet. Perivascular macrophage infiltrates, vascular endothelial cell proliferation, gliosis, neuronal necrosis and neuronophagia were observed in the brainstem and spinal cord of affected birds. Edema of the ischiatic nerve was also a feature. A viral or protozoal etiology has been suggested.

### Duck Viral Enteritis

Duck viral enteritis is primarily a concern where feral populations of ducks mingle with captive birds. Clinical signs include photophobia, ataxia, seizures, penile prolapse, lethargy, hemorrhagic diarrhea and serosanguinous nasal discharge. The most notable finding at necropsy is hemorrhagic bands on the small intestine (see Color 14).

### Duck Viral Hepatitis

Duck viral hepatitis is caused by a picornavirus. Clinical signs include lethargy, seizures, opisthotonos and death. Ducklings suffer the highest mortality, and Muscovy Ducks appear to be resistant to infection with this virus. At necropsy, the liver, spleen and kidneys are enlarged with petechial hemorrhages. It is recommended to vaccinate breeders before the onset of laying.

## Bacterial Neuropathies

### Listeriosis

*Listeria monocytogenes* is a small, gram-positive, nonsporulating, motile rod that is frequently confused with a hemolytic *Streptococcus* sp. The organism is ubiquitous and can survive for years in the environment. Intracranial infections cause opisthotonos, ataxia and torticollis (Figure 28.10).<sup>29</sup> Brain lesions consist of microabscesses with heterophil and giant cell infiltrates, diffuse gliosis, meningeal hyperemia, degeneration of Purkinje cells and perivascular cuffing (see Chapter 33).



**FIG 28.10** An adult Amazon parrot was presented with a history of progressive depression, weight loss and ataxia. When undisturbed, the bird would exhibit repeated periods of opisthotonos with shifting phase nystagmus. Abnormal clinicopathologic findings included WBC=26,000 (toxic heterophils), PCV=26, total protein=7.5 and CPK=1200. The bird did not respond to supportive care. Histopathology indicated a severe perivascular cuffing with neuronal necrosis of undetermined etiology.

### Chlamydiosis

Occasionally, *Chlamydia psittaci* will cause neurologic signs in birds that survive the acute respiratory or gastrointestinal phase of the disease. Signs

include seizures, torticollis, tremors and opisthotonos (see Chapter 34).<sup>88</sup>

### Granulomas

Avian tuberculosis can cause neurologic signs if the granulomas occur intracranially or adjacent to peripheral nerves.<sup>51,108</sup> Osteomyelitis caused by mycobacterium may produce a lameness that could be misinterpreted as a neuropathy. Abscesses, granulomas, encephalitis, myelitis and meningitis may be caused by any bacterial organism. *Salmonella*, *Streptococcus*, *Staphylococcus*, *Pasteurella multocida*, *Mycoplasma* and *Clostridium* spp. have been isolated.<sup>19,46,51,73</sup> Clinical signs depend on the location and extent of the lesions.

### Otitis

Otitis media and interna in companion birds may cause neurologic signs. Otitis interna produces a head tilt and circling toward the affected side (see Figure 28.6). If the infection progresses, other cranial nerves and the midbrain may become affected.

## Congenital Abnormalities

The incidence of developmental abnormalities of the avian nervous system is not well established. Studies in poultry suggest that meningocele and other related anomalies result from early malformation and forking of the neural tube during embryonic development.<sup>79</sup> In turkeys, hydrocephalus, shortened beaks and absence of the terminal digits have

been linked to an autosomal recessive semilethal gene.<sup>103</sup> In laboratory animals, virus infections, certain chemicals and malnutrition (hypovitaminosis A, hypervitaminosis A, hypovitaminosis B<sub>12</sub> and B<sub>6</sub> and

zinc deficiency) may cause hydrocephalus. The chemotherapeutic agent cyclophosphamide and alkaloids from the plant *Veratrum californicum* cause hydrocephalus, microphthalmia, meningocoele, encephalocele, cebocephaly and cyclopia in chick em-

bryos. Other cephalic and cerebral abnormalities have been induced by petroleum distillates, phenylmercuric acetate, tellurium and 6 amino-nicotinamide.<sup>10,66</sup> Hydrocephalus of unknown etiology has been described in psittacine birds.<sup>51,145</sup>

## References and Suggested Reading

- Aguilar R, et al: Sarcocystis-associated encephalitis in an immature northern goshawk. *J Zoo Wildl Med* 22(4):466-469, 1991.
- Alexander DJ: Influenza A isolations from exotic caged birds. *Vet Rec* 123:442, 1988.
- Anderson WJ, et al: Neurofibrosarcoma and leiomyosarcoma in slaughterhouse broilers. *Avian Dis* 29(2):521-527, 1985.
- Armstrong DL, et al: Cerebrospinal nematodiasis in blue and gold macaws and scarlet macaws associated with *Balisascaris procyonis*. *Proc 1st Intl Conf Zoo & Avian Med*, 1987, pp 489-491.
- Armstrong D, et al: Cerebrospinal nematodiasis in macaws due to *Balisascaris procyonis*. *J Zoo Wildl Med* 20(3):354-359, 1989.
- Beasley VR, Trammel HL: Incidence of poisonings in small animals. In Kirk RW (ed): *Current Veterinary Therapy X*. Philadelphia, WB Saunders Co, 1989, pp 110.
- Blue-McLendon A, et al: Cerebrospinal nematodiasis in emus. *Proc Assoc Avian Vet*, 1992, pp 326-327.
- Browne MO, Gentry RF: Avian encephalomyelitis virus. *Avian Dis* 15:638-653, 1971.
- Britt JO, et al: Lafora body neuropathy in a cockatiel. *Comp Anim Pract* 19(3):31-33, 1989.
- Bryden MM, et al: Effects of alkaloids of *Veratrum californicum* on chick embryos. *Teratology* 8:19-28, 1973.
- Buck WB: Organochlorine insecticides. In *Clinical and Diagnostic Veterinary Toxicology* 2nd ed. Dubuque, Kendall Hunt Publishing Co, 1980, pp 191-204.
- Cambre RC: Consecutive avian botulism outbreaks in a zoological garden. *Proc Am Assoc Zoo Vet*, 1988, pp 43-47.
- Campbell TW: Mycotoxicosis: A potential threat to captive birds. *Proc Assoc Avian Vet*, 1986, pp 129-131.
- Campbell TW: Hypovitaminosis E: Its effects on birds. *First Intl Conf Zoo & Avian Med*, 1987, pp 75-77.
- Carpenter JW, Dein JF: Use of an inactivated eastern equine encephalitis virus vaccine in cranes. *Proc Assoc Avian Vet*, 1986, p 88.
- Carpenter JW, et al: Disease in captive cranes caused by mycotoxin contaminated feed. *Proc Am Assoc Zoo Vet*, 1988, pp 48.
- Carpenter JW, et al: The impact of eastern equine encephalitis virus on efforts to recover the endangered whooping crane. In Cooper JE (ed): *Disease and Threatened Birds*. Cambridge, Intl Conserv Bird Preserv Tech Pub #10, 1989.
- Center SA: Pathophysiology and laboratory diagnosis of liver disease. In Ettinger SJ (ed): *Textbook of Veterinary Internal Medicine*. Philadelphia, WB Saunders Co, 1989, pp 1462-1466.
- Chin RP, et al: Isolation of *Mycoplasma synoviae* from the brains of commercial meat turkeys with meningeal vasculitis. *Avian Dis* 35:631-637, 1991.
- Cho BR, Mathew WJ: Tremors of nestling budgerigars with BFD. *Proc 33rd West Poult Dis Conf*, Davis, CA, 1984, p 102.
- Clark GC, et al: Antibody response of sandhill and whooping cranes to an eastern equine encephalitis virus vaccine. *J Wildl Dis* 24:539-544, 1987.
- Clubb SL, Karpinski L: Aging in macaws. *Proc Assoc Avian Vet*, 1992, pp 83-86.
- Clubb SL, Levine B, Graham DL: An outbreak of viscerotropic velogenic Newcastle's disease in pet birds. *Proc Am Assoc Zoo Vet*, 1980, pp 105-109.
- Clubb SL: Viscerotropic velogenic Newcastle's disease in pet birds. In Kirk RW (ed): *Current Veterinary Therapy VIII*. Philadelphia, WB Saunders Co, 1983, pp 628-630.
- Clubb SL, et al: Psittacine reovirus: An update including a clinical description and vaccination. *Proc Assoc Avian Vet*, 1985, pp 83-90.
- Clubb SL, et al: An acute fatal illness in old world psittacine birds associated with *Sarcocystis falcatula* of opossoms. *Proc Assoc Avian Vet*, 1986, pp 139-149.
- Cook JR: Electrodiagnostic. In Slatler DM (ed): *Textbook of Small Animal Surgery* 2nd ed. Philadelphia, WB Saunders Co, 1993, pp 1003-1007.
- Cooper JE, Clay JT: Nerves and sensory organs. In Cooper JE, Clay JT (eds): *First Aid and Care of Wild Birds*. London, David and Charles, 1979, pp 46-49.
- Cooper GL: Case report: An encephalitic form of listeriosis in broiler chickens. *Avian Dis* 33:182-185, 1989.
- Cross GM: Newcastle's disease. *Vet Clin North Am Sm Anim Pract* 21(6):1231-1239, 1991.
- Danneman P, et al: Fungal meningoencephalitis in a hand raised snowy owl chick (*Nyctea scandiaca*). *Proc Am Assoc Zoo Vet*, 1989, p 208.
- Degernes LA, et al: Lead poisoning in trumpeter swans. *Proc Assoc Avian Vet*, 1989, pp 144-155.
- Dein JF, Clark G: Outbreak and control of eastern equine encephalitis virus in whooping cranes. *Proc Assoc Avian Vet*, 1985, pp 175-176.
- delahunta A, et al: Avulsion of the roots of the brachial plexus in five birds. *Comp Anim Pract* 12(2):38-40, 1988.
- Dubey JP, et al: Sarcocystis-associated clinical encephalitis in a golden eagle (*Aquila chrysalos*). *J Zoo Wildl Med* 22(2):233-236, 1991.
- Dubey JP, et al: Toxoplasmosis in owls. *J Zoo Wildl Med* 23(1):98-102, 1992.
- Emerson CL, et al: Ruptured intervertebral disc in a juvenile king penguin. *J Zoo Wildl Med* 21(3):345-350, 1990.
- Evans RH, Tangredi B: Cerebrospinal nematodiasis in free-ranging birds. *J Am Vet Med Assoc* 187(11):1213-1214, 1985.
- Foreyt WJ, Abinanti FR: Maggot-associated type C botulism in game farm pheasants. *J Am Vet Med Assoc* 177(9):827-828, 1980.
- Frank RK, Bergeland ME: Case report: Poliomyelomalacia, pancreatic necrosis, and cerebellar malacia in turkey poults. *Avian Dis* 32:574-582, 1988.
- Friend M, et al: Avian Botulism. U.S. Fish & Wildlife Service/National Park Service joint publication. US Government Printing Office, 1985.
- Fudge AM: Clinical nutrition of companion birds. *Calif Vet* 42:7-8, 30, 1988.
- Gardner MB, et al: Electron microscope search for retrovirus particles in spontaneous tumors of the parakeet. *Vet Pathol* 18:700-703, 1981.
- Garnham PCC, et al: A new species of *Sarcocystis* in the brain of two exotic birds. *Annales de Parasitologie* 54(4):393-400, 1979.
- Graham DL: Parrot reovirus and papovavirus infections and feather and beak syndrome. *Proc 34th West Poult Dis Conf*, Davis, CA, 1985, pp 118-120.
- Graham D: Surprises at necropsy. *Assoc Avian Vet Today* 2(4):192-195, 1988.
- Greenacre C, et al: Leg paresis in a black palm cockatoo caused by aspergillosis. *J Zoo Wildl Med* 23(1):122-126, 1992.
- Harrison GJ: *Clostridium botulinum* type C infection on a game fowl farm. *Proc Am Assoc Zoo Vet*, 1974, pp 221-224.
- Harrison GJ: Preliminary work with selenium/vitamin E responsive conditions in cockatiels and other psittacines. *Proc Assoc Avian Vet*, 1986, pp 257-262.
- Hardy RM: Hepatic encephalopathy. In Kirk RW, Bonagura JD (eds): *Current Veterinary Therapy XI*. Philadelphia, WB Saunders Co, 1992, pp 639-645.
- Hasholt J, Petrak ML: Diseases of the nervous system. In Petrak ML (ed): *Diseases of Cage and Aviary Birds* 2nd ed. Philadelphia, Lea & Febiger, 1982, pp 468-477.
- Hillyer E, et al: An outbreak of sarcocystis in a collection of psittacines. *J Zoo Wildl Med* 22(4):434-445, 1991.
- Hochleifner M: Convulsions in African grey parrots. *Proc Assoc Avian Vet*, 1989, pp 78-81.
- Hubben K, et al: Transmissible pituitary chromophore adenoma in the parakeet. *Avian Dis* 8:203-208, 1964.
- Hughes PE: The pathology of myenteric ganglioneuritis, psittacine encephalomyelitis, proventricular dilatation of psittacines, and macaw wasting syndrome. *Proc 33rd West Poult Dis Conf*, Davis, 1984, pp 85-87.
- Hughes PE, Ryan CP: Birds and the 1984 St Louis encephalitis epidemic in southern California. *Proc 34th West Poult Dis Conf*, Davis, 1985, pp 69.
- Hultgren BD, et al: Cervical dorsal spondylolysis with spinal cord compression in a black swan (*Cygnus atratus*). *J Wildl Dis* 23(4):705-708, 1987.
- Jacobson ER, et al: Sarcocystis encephalitis in a cockatiel. *J Am Vet Med Assoc* 185(8):904-906, 1984.
- Jonsson DL, et al: Lead toxicosis in three captive avian species. *Proc Am Assoc Zoo Vet*, 1979, pp 40-42.
- Jenkins T: Creatine kinase as a diagnostic indicator of splanchnic neuropathy. *J Assoc Avian Vet* 5(1):49, 1991.
- Johnson WD, Storts RW: Peripheral neuropathy associated with dietary riboflavin deficiency in the chicken I. Light microscopic study. *Vet Pathol* 25:9-16, 1988.
- Johnson JH, et al: Atherosclerosis in psittacine birds. *Proc Assoc Avian Vet*, 1992, pp 87-93.
- Jortner BS, et al: Encephalomalacia associated with hypovitaminosis E in turkey poults. *Avian Dis* 29(2):488-498, 1985.
- Joyner KL, et al: Encephalitis, proventricular and ventricular myositis and myenteric ganglioneuritis in an umbrella cockatoo. *Avian Dis* 33:379-381, 1989.
- Joyner KL, et al: Psittacine pediatric diagnostics. *Proc Assoc Avian Vet*, 1990, pp 60-68.
- Kar AK, et al: Cyclophosphamide induced hydrocephalus in chick embryos. *Indian J Med Res* 62:905-908, 1974.
- Kazacos K, et al: *Balisascaris procyonis* as a cause of cerebrospinal nematodiasis in raptors. *J Zoo Wildl Med* 22(4):460-465, 1991.
- Kern TJ, et al: Lens extraction by phacoemulsification in two raptors. *J Am Vet Med Assoc* 185(11):1403-1406, 1984.
- King AL, McLelland J: *Birds: Their Structure and Function*. Bailliere Tindall, London, 1984.
- Kirkpatrick CE, et al: *Toxoplasma gondii* antibodies in common barn owls (*Tyto alba*) and pigeons (*Columba livia*) in New Jersey. *Vet Parasitol* 36:177-180, 1990.
- Klein PN: The challenge of toxicologic investigation in birds. *Proc Assoc Avian Vet*, 1989, pp 139-143.
- LaBonde J: The medical and surgical management of domestic waterfowl collections. *Proc Assoc Avian Vet*, 1992, pp 223-233.
- LaBonde J: Two clinical cases of exposure to household use of organophosphate and carbamate insecticides. *Proc Assoc Avian Vet* 1992, pp 113-118.
- Langelier K: Poisoning by lead shot in trumpeter swans. *Can Vet J* 31:221-222, 1990.
- Leach MW, et al: Paramyxovirus infection in a Moluccan cockatoo (*Cacatua moluccensis*) with neurologic signs. *Assoc Avian Vet* 2(2):87-90, 1988.
- Leighton FA: Pollution and wild birds: North America in the 1980's. *Can Vet J* 30(Oct):783-785, 1989.
- Levine ND, et al: Encephalitis in a swan due to *Denditobilharzia* sp (Trematoda: Schistosomatidae). *J Parasitol* 42:496-500, 1956.
- Lindsay DS, et al: *Toxoplasma gondii* infections in red tailed hawks inoculated orally with tissue cysts. *J Parasitol* 72:322-325, 1991.
- Linnehar R: Congenital encephalocele in a mandarin duckling. *J Zoo Wildl Med* 20(2):231-233, 1989.
- Lloyd M: Heavy metal ingestion: Medical management and gastroscopic foreign body removal. *J Assoc Avian Vet* 6(1):25-29, 1992.
- Loupal VG: Über eine der myoklonuskörperkrankheit (morbus Lafora) des menschen und des hun-

- des morphologische ähnliche speicherkrankheit bei einem nymphenstich (*Nymphicus hollandicus*). Zentral Vet 32:502-511, 1985.
82. **Lowestine LJ, et al:** Lymphoplasmacytic encephalitis, myelitis and meningitis in a group of *Pionus* spp parrots. Proc 34th West Poul Dis Conf, 1985, pp 91-93.
  83. **Lowestine L:** Normal and morbid gross anatomy. Proc 1st Int Conf Zoo & Avian Med, 1987, pp 547.
  84. **Lowestine LJ:** A potpourri of interesting avian cases. Proc 1st Int Conf Zoo & Avian Med, 1987, pp 105-108.
  85. **Lutz M:** Ascending paralysis in fledgling mockingbirds. J Assoc Avian Vet 5(3):128, 1991.
  86. **Lutz ME:** Crown vetch intoxication. J Assoc Avian Vet 5(2):73, 1991.
  87. **Lyman R:** Neurologic examination. In Harrison GJ, Harrison LR (eds): Clinical Avian Medicine and Surgery, Philadelphia, WB Saunders Co, 1986, pp 282-285.
  88. **Lyman R:** Neurologic disorders. In Harrison GJ, Harrison LR (eds): Clinical Avian Medicine and Surgery, Philadelphia, WB Saunders Co, 1986, pp 486-490.
  89. **Manktelow, et al:** Avian encephalomyelitis, avian reovirus infection, Marek's disease, Newcastle's disease. Found Cont Ed New Zeal Vet Assoc Pub #120, Massey University, North New Zealand, 1988, pp 75-99.
  90. **Mannl A, et al:** Neuropathic gastric dilatation in Psittaciformes. Assoc Avian Vet Today 1(2):72, 1987.
  91. **Mathey VJ, et al:** Brain tumors in young male budgerigar breeders. Proc 33rd West Poul Dis Conf, 1984, pp 103-105.
  92. **Mautino M:** Avian lead intoxication. Proc Assoc Avian Vet, 1990, pp 245-247.
  93. **Miller NL, et al:** Oral infections with *Toxoplasma* cysts and oocysts in felines, other mammals, and birds. J Parasitol 58:928-937, 1972.
  94. **Mohan R:** Dursban toxicosis in a pet bird breeding operation. Proc Assoc Avian Vet, 1990, pp 112-114.
  95. **Munro B:** The Parrot in Health and Illness: An Owner's Guide. New York, Doane Co, 1991.
  96. **Murase T, et al:** Treatment of lead poisoning in wild geese. J Am Vet Med Assoc 200(11):1726-1729, 1992.
  97. **Murphy C:** Consider brain lesion with blindness. Assoc Avian Vet Today 1(1):11, 1987.
  98. **Murphy J:** Psittacine fatty liver syndrome. Proc Assoc Avian Vet, 1992, pp 78-82.
  99. **Myers RK, et al:** Cerebrospinal nematodiasis in a cockatiel. J Am Vet Med Assoc 183(10):1089-1090, 1983.
  100. **McDonald SE:** Lead poisoning in psittacine birds. In Kirk RW(ed): Current Veterinary Therapy IX, Philadelphia, WB Saunders Co, 1986, pp 713-718.
  101. **McDonald LJ:** Hypocalcemic seizures in African grey parrots. Can Vet J 29(11):928-930, 1988.
  102. **McCrister S, Perry RA:** Encephalomyelitis in free-living rainbow lorikeets (*Trichoglossus hematodus*). Avian Pathol 15:783-789, 1986.
  103. **Nestor KE:** Hereditary chondrodystrophy in the turkey. Poul Sci 57:577-580, 1978.
  104. **Neumann U, Kummerfeld N:** Neoplasms in budgerigars. Avian Pathol 12:353-362, 1983.
  105. **Nichols DK, Montali RJ:** Vitamin E deficiency in captive and wild piscivorous birds. 1st Intl Conf Zoo & Avian Med, 1987, pp 419-421.
  106. **Nielsen SW:** Lead poisoning in free-living birds. Proc Am Assoc Zoo Vet, 1988, pp 7.
  107. **Norton TM, Nesbitt S:** Diseases of free-ranging Florida sandhill cranes (*Grus canadensis pratensis*). Proc Am Assoc Zoo Vet, 1988, pp 10.
  108. **Odiawo GO, Mukuriva JM:** Avian cerebral tuberculosis. Vet Rec 122:279-280, 1988.
  109. **Otsuki K, et al:** Intracerebral pathogenicity for chickens of avian influenza viruses isolated from free-living waterfowl in Japan. Vet Micro 18:357-362, 1988.
  110. **Parrot T:** Hepatopathy and neurologic abnormalities in an umbrella cockatoo after vaccination with Pacheco's killed virus vaccine. Proc Assoc Avian Vet, 1992, pp 140.
  111. **Paster MB, Britt JO:** Severe degenerative neuronal encephalomyelopathy in a cockatiel: Lafora's disease or myoclonus epilepsy. Proc Assoc Avian Vet, 1985, pp 133-140.
  112. **Pokras M, Chafel R:** Lead toxicosis from ingested fishing sinkers in adult common loons (*Gavia immer*) in New England. J Zoo Wildl Med 23(1):92-97, 1992.
  113. **Porter SL:** Organophosphate/carbamate poisoning in birds of prey. Proc Am Assoc Zoo Vet, 1992, pp 176-177.
  114. **Proctor SJ, et al:** Neurologic lesions of velogenic viscerotropic Newcastle's disease in parrots, budgerigars, and canaries. Proc Am Assoc Vet Lab Diagn, 1974, pp 115-122.
  115. **Quesenberry KE, et al:** Neurologic disorders in caged birds: A retrospective review of cases. Proc Assoc Avian Vet, 1988, pp 175-176.
  116. **Raphael BL, et al:** Glioblastoma multiforme in a budgerigar. J Am Vet Med Assoc 177(9):923-925, 1980.
  117. **Redig PT, et al:** The diagnosis and treatment of lead poisoning in bald eagles and trumpeter swans. Proc 1st Int Conf Zoo & Avian Med, 1987, pp 401-402.
  118. **Rich GA:** Neoplasia in pet birds. Proc Assoc Avian Vet: Basic Avian Symposium, 1989, pp 425-428.
  119. **Ritchie BW:** Treatment of organophosphate toxicosis. Assoc Avian Vet Today 1(1):23, 1987.
  120. **Ritchie BW:** A review of eastern equine encephalomyelitis in pheasants. Assoc Avian Vet Today 1(4):152-154, 1987.
  121. **Ritchie BW, Dreesen DW:** Avian zoonoses: proven and potential diseases. Part II. Viral, fungal, and miscellaneous diseases. Comp Cont Ed Pract Vet 10(6):688-697, 1988.
  122. **Roskopf WJ, et al:** Hypocalcemia syndrome in an African grey parrot: A case report. Avian/Exotic Pract 2(1):22-25, 1985.
  123. **Roskopf WJ, et al:** The hypocalcemia syndrome in African greys: An updated clinical viewpoint with current recommendations for treatment. Proc Assoc Avian Vet, 1985, pp 129-131.
  124. **Roskopf WJ, et al:** Epilepsy in red-lore Amazons (*Amazona autumnalis*). Proc Assoc Avian Vet, 1985, pp 141-145.
  125. **Roskopf WJ, Woerpel RW:** Avian emergency care. Comp Anim Pract 1(7):19-34, 1987.
  126. **Roskopf WJ, Woerpel RW:** Successful treatment of a convulsive disorder in an umbrella cockatoo: A case report. Proc 1st Int Conf Zoo & Avian Med, 1987, pp 267-271.
  127. **Ryan T:** Calcium in the avian species. Comp Anim Pract 19(4 & 5):38-40, 1989.
  128. **Ryan T:** Hypovitaminosis E in a cockatoo. Comp Anim Pract 19(8 & 9):31-32, 1989.
  129. **Sanford SE, Hampson RJ:** Pigeon paramyxovirus. Can Vet J 30:523, 1989.
  130. **Schmidt R, et al:** Systematic survey of lesions from animals in a zoological collection. 1. Central nervous system. J Zoo Wildl Med 17:8-11, 1986.
  131. **Schmidt RE, et al:** Morphologic identification of papovavirus in a Moluccan cockatoo with neurologic signs. Assoc Avian Vet Today 1(3):107-108, 1987.
  132. **Shafren DR, Tannock GA:** An enzyme-linked immunosorbent assay for the detection of avian encephalomyelitis virus antigens. Avian Dis 32:209-214, 1988.
  133. **Shafren DR, et al:** Diagnosis of a field outbreak of avian encephalomyelitis by enzyme-linked immunosorbent assay. Aust Vet J 66(7):224-225, 1989.
  134. **Smith RE:** Avian diseases that antibiotics won't cure. Assoc Avian Vet Today 1(2):69-70, 1987.
  135. **Spalding MG, et al:** Hepatic encephalopathy associated with hemochromatosis in a toucan. J Am Vet Med Assoc 189(9):1122-1124, 1986.
  136. **Tangredi B:** Clinical observations of paramyxovirus in pigeons. Assoc Avian Vet Newsletter 6(1):29, 1985.
  137. **Tangredi BP, Stone W:** Organochlorine toxicosis in wild birds on Long Island, NY. Proc Assoc Avian Vet, 1988, pp 11.
  138. **Tully J, Shane S:** Eastern equine encephalitis in emus. Proc Assoc Avian Vet, 1992, pp 316-317.
  139. **Turner R:** Macaw fading or wasting syndrome. Proc 33rd West Poul Dis Conf, 1984, pp 87-88.
  140. **Turrel JM, et al:** Diagnosis and treatment of tumors in companion birds I. Assoc Avian Vet Today 1(3):109-116, 1987.
  141. **VanDerHeyden N, Reed WM:** Paramyxovirus group 3 infection in cockatiels. Assoc Avian Vet Today 1:53-54, 1987.
  142. **VanDerHeyden N:** Velogenic viscerotropic Newcastle's disease in three Amazon chicks. Proc Assoc Avian Vet, 1992, pp 158-161.
  143. **Van Sant F:** Zinc toxicosis in a hyacinth macaw. Proc Assoc Avian Vet, 1991, pp 255-259.
  144. **Vickers MC, et al:** Blindness associated with toxoplasmosis in canaries. J Am Vet Med Assoc 200(11):1723-1725, 1992.
  145. **Wack RF, et al:** Internal hydrocephalus in an African Grey parrot (*Psittacus erithacus timneh*). J Assoc Avian Vet 3(2):94-96, 1989.
  146. **Walsh MT:** Seizuring in pet birds. Proc Assoc Avian Vet, 1985, pp 121-128.
  147. **Wilson RB, Scholten RG:** Granulomatous encephalitis caused by schistosomiasis in swans. J Am Vet Med Assoc 181(11):1386-1387, 1982.
  148. **Wise DR:** Spondylolisthesis ("kinky back") in broiler chickens. Res Vet Sci 11:447-451, 1970.
  149. **Wobeser G:** Botulism in waterfowl. Proc Am Assoc Zoo Vet, 1988, pp 2.
  150. **Woerpel RW, Roskopf WJ:** Proventricular dilatation and wasting syndrome: Myenteric ganglioneuritis and encephalomyelitis of psittacines; an update. Proc Assoc Avian Vet, 1984, pp 25.
  151. **Woerpel RW, Roskopf WJ:** Clinical and pathologic features of macaw wasting disease (proventricular dilatation syndrome). Proc 33rd West Poul Dis Conf, 1984, pp 89-90.
  152. **Work TM, et al:** Epizootiology of domoic acid poisoning in brown pelicans and Brandt's cormorants in California. Proc Am Assoc Zoo Vet, 1992, pp 181.
  153. **Work TM, et al:** Epizootiology of domoic acid poisoning in brown pelicans (*Pelecanus occidentalis*) and Brandt's cormorants (*Phalacrocorax penicillatus*) in California. J Zoo Wildl Med 24(1):54-62, 1993.

CHAPTER

# 29

## THERIOGENOLOGY

Kim L. Joyner

**T**heriogenology in mammals includes obstetrics, genital diseases and reproductive physiology. Theriogenology in birds includes these topics as well as egg anatomy, physiology and incubation. With the rising interest in captive propagation for avicultural and conservation purposes, modern avian theriogenology also includes veterinary and avicultural techniques designed to maintain optimal production. Many factors, including complex reproductive behaviors, affect avian reproduction. Avian clinicians can serve the avicultural community by developing a thorough understanding of the avicultural techniques, anatomy, physiology, nutrition and behavior necessary to maintain long-term reproductive health for individual pairs and the flock.

Reproductive disorders occur with surprising frequency but can be difficult to diagnose because the cloaca serves as the endpoint of the gastrointestinal, urinary and reproductive systems in birds. In 24 avian orders, an 8.9% prevalence of reproductive disease was described in necropsy specimens.<sup>84</sup> The most commonly affected companion bird species was the budgerigar, although this observation was probably skewed by biased sampling in this particular study. Domestic poultry that have been genetically selected for productivity traits are probably more susceptible to reproductive disorders than companion bird species. Poultry hens have been reported to have a reproductive disease prevalence of 27.5% and 53.3%<sup>155,159</sup> with senility, malnutrition and infectious agents being the most often incriminated causes of disease. The most common infectious agent affecting the reproductive tract of laying hens appears to be *E. coli*.<sup>159</sup> Reproductive disease in hens is frequently multifactorial, complicating diagnosis and therapy. Additionally, more than one type of reproductive disorder is often present; however, because of the common pathogenesis of many of these disorders, preventive and therapeutic considerations are generally similar irrespective of the etiology.



## Female Reproductive Anatomy and Egg Formation

### Ovary

The normal reproductive tract of a mature hen consists of a left ovary and oviduct. The right ovary and oviduct are present in embryonic stages, but these tissues normally regress before hatching in most species (Color 29.10). In some species and individuals (raptors), these organs may be vestigial or functional post-hatching. The left ovary is located at the cranial end of the kidney and is attached to the abdominal wall by the mesovarian ligament. In young birds the ovary is flattened, in an inverted “L”-shape. It has nearly inappreciable folds and resembles a piece of fat (see Color 13). As birds mature and the gyri become more prominent, small primary oocytes give the ovary a cobblestone appearance (Color 29.24). This process occurs by about 25 weeks of age in Blue and Gold Macaws (see Color 13).<sup>171</sup> Ovarian tissue can be more or less melanistic, especially in cockatoos, macaws and some conures. Gonadotropin secretion in maturing hens causes a hierarchy of follicles to develop, giving the ovary the appearance of a cluster of variably sized grapes (Color 29.20). As the breeding season approaches, the follicles undergo a period of rapid growth with the deposition of yolk proteins and lipid produced by the liver. At this point the yellow yolk is clearly visible through the highly vascularized follicular wall. The large follicle is suspended by a stalk. The normal post-ovulatory follicle becomes a thin-walled sac devoid of blood clots.<sup>86</sup> The hypertrophied granulosa cells are metabolically active for several days and may not be reabsorbed until eight to ten days post-ovulation in the chicken, and up to several months in the Mallard Duck.<sup>100</sup> The post-ovulatory follicle is thought to secrete non-steroidal hormones that are involved in oviposition and nesting behavior.<sup>86</sup>

During the non-breeding season, the ovarian follicles normally collapse and exhibit atresia. Two kinds of atresia have been described.<sup>86</sup> Bursting atresia occurs when the follicle wall ruptures and yolk is harmlessly released into the peritoneal cavity where it is absorbed. Invasion atresia involves granulosa and theca cells invading the ovum with subsequent *in situ* yolk absorption. The earliest detectable indica-

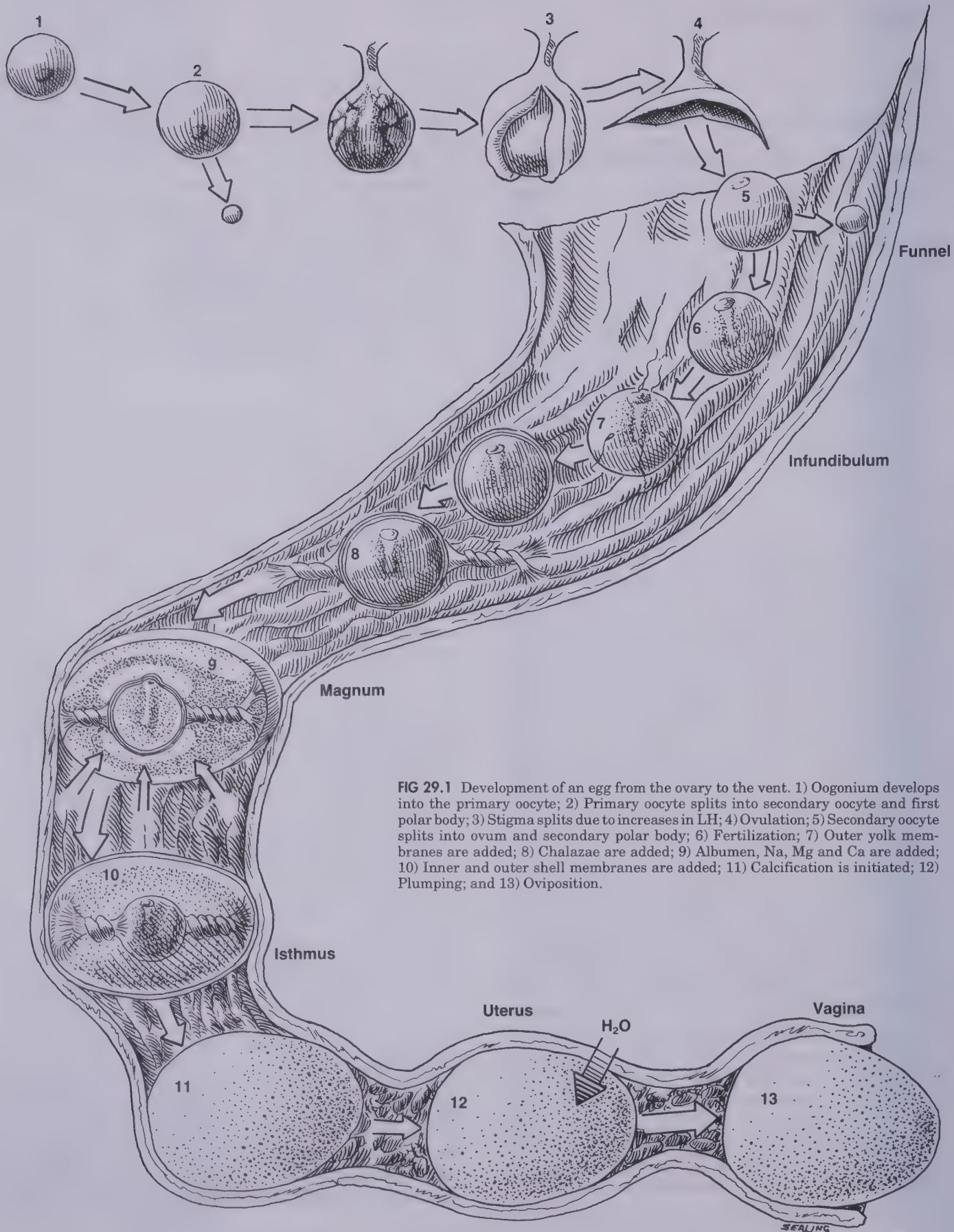
tion that a large follicle is undergoing normal atresia is the appearance of a vesicular lesion. This vesicle formation continues until the entire follicle is covered. As the largest follicle is absorbed, the smaller follicles will progress similarly.<sup>38</sup> Small follicles can be covered by connective tissue, sometimes leaving a scar-like area (see Color 13). Large follicles may undergo cystic degeneration (Color 29.22).<sup>46,176</sup> If ovulation ceases suddenly due to trauma or stress, then developing follicles may be hemorrhagic and result in regression of the developing follicle. Aging hens can exhibit permanent ovarian involution, which is believed to be a normal physiologic process. Aflatoxicosis can also cause follicular atresia.<sup>52</sup>

### Oviduct

Understanding the anatomic divisions of the oviduct and their associated functions is important when discerning pathologic changes in the reproductive tract. During active egg laying, the oviduct enlarges and occupies much of the left abdomen. During the non-breeding season, the oviduct shrinks considerably in length and width. The oviduct of a preovulatory hen is usually thin, straight and uniform in diameter, and can be confused with the laterally tracking ureters (Color 29.19). An ovary and oviduct can regress to a point where it is difficult to determine if a hen has ever been reproductively active.

The oviduct consists of five microscopically distinguishable regions: infundibulum, magnum, isthmus, uterus (shell gland) and vagina (Figure 29.1). Dorsal and ventral ligaments attach the oviduct in the peritoneal cavity.<sup>79</sup> In psittacine birds, the dorsal ligament is clearly visible crossing the cranial division of the kidney (see Color 13).<sup>172</sup> Peristaltic activity in the cranial oviduct and stronger smooth muscle contractions in the uterus and vagina move the ovum down and the sperm up the reproductive tract. Oviduct transit time varies among species and is approximately 24 hours in the chicken. Similar transit times are discussed in companion and aviary birds, with the egg spending varying but proportional times in each section of the oviduct.

The cranial infundibulum consists of a thin, nearly transparent finger-like funnel that engulfs the ovum into an ovarian pouch (see Anatomy Overlay). More distally, the infundibular wall thickens as it becomes tubular. In domestic fowl, the infundibulum is about seven centimeters long, while in the Brown Kiwi it extends the width of the peritoneal cavity to receive oocytes from functional left and right ovaries.<sup>86</sup> Fer-



**FIG 29.1** Development of an egg from the ovary to the vent. 1) Oogonium develops into the primary oocyte; 2) Primary oocyte splits into secondary oocyte and first polar body; 3) Stigma splits due to increases in LH; 4) Ovulation; 5) Secondary oocyte splits into ovum and secondary polar body; 6) Fertilization; 7) Outer yolk membranes are added; 8) Chalazae are added; 9) Albumen, Na, Mg and Ca are added; 10) Inner and outer shell membranes are added; 11) Calcification is initiated; 12) Plumping; and 13) Oviposition.

tilization occurs in the tubular portion of the infundibulum, where sperm may reside in glandular grooves awaiting the arrival of the ovum. Production of the chalaziferous layer of the albumen and the paired chalazae occurs also in the tubular portion of the infundibulum. Less than an hour later, the ovum exits the infundibulum and enters the highly glandular magnum that is differentiated from the infundibulum by its sudden enlargement in the mucosal folds. It is the largest and most coiled portion of the oviduct and deposits most of the albumen, sodium, magnesium and calcium used in egg development. The egg may remain in the magnum for three hours. Inner and outer shell membranes are added to the developing egg during its one to two hours in the isthmus. The isthmus has less well developed circular muscle and glandular tissue compared to the magnum.

The short uterus has numerous leaf-like lamellae composed of longitudinal folds, consisting of prominent longitudinal muscles and underlying tubular gland cells. This part of the uterus is ovoid in shape and holds the egg during shell deposition. The more cranial aspect of the uterus is difficult to differentiate from the isthmus. The egg remains in the uterus for 20 to 26 hours and receives salts, water, the shell and shell pigment. The uterus is highly vascularized during egg laying and must be carefully manipulated during any surgical procedure to prevent excessive hemorrhage (see Chapter 40 for considerations prior to performing uterine surgery). The egg is oriented in the uterus with its sharp end pointing caudally. In most species the egg is laid in this direction, although in some species the egg turns in the uterus just before oviposition.<sup>86</sup> The S-shaped vagina is the thickest walled portion of the oviduct; it begins at the uterovaginal sphincter muscle and terminates in the cloaca. The vagina is distinguishable by its numerous thin folds of mucosa. In juvenile chickens and some Anseriformes, the vagina is separated from the cloaca by a membrane that deteriorates at sexual maturity.<sup>86</sup> The vagina does not contribute to the formation of the egg, which passes through the vaginal lumen in seconds during normal oviposition. Along with the uterus, the vagina contributes to the muscular expulsion of the egg. Cranes that are disturbed during oviposition may retain an egg in the vagina for four days, followed by a normal egg delivery (Gee GF, unpublished).

Gallinaceous hens can store sperm in the spermatid fossulae (sperm host glands) at the uterovaginal junction and the glandular grooves and tubular

glands of the infundibulum. Other species may have only one set of these glands. Sperm located in these glands remain fertile for 7 to 14 days in the chicken and for 40 to 50 days in the turkey.<sup>79</sup> Anecdotal evidence suggests that sperm can remain viable for over a week in psittacine species.

### Female Hormonal and Physiologic Factors

Primary oogenesis begins in the embryo when secondary oocytes are formed. Meiosis is arrested until adult life when follicles become active and grow in three phases, the first of which can last months to years.<sup>75</sup> This long initial stage represents the resting pre-nuptial period that occurs in all species. Stage two lasts about 60 days in the domestic hen, and during this period some yolk is deposited in vacuoles within the oocyte. This stage corresponds with ovarian regression that occurs in the non-breeding season in free-ranging species. Stage two growth in nondomestic species is influenced by luteinizing hormone (LH) and follicle stimulating hormone (FSH), which are both produced by the adenohypophysis under the control of the hypothalamus. Stage three involves rapid yolk deposition and normally occurs in free-ranging birds only when a mate is present. Courtship and nest-building activity seem to precede stage three follicular development, which terminates with either normal follicular atresia or ovulation.

Developing ovarian follicles consist of concentric layers of yolk, the oocyte, perivitelline lamina, granulosa cells, basal lamina and theca. Ovarian thecal and interstitial cells produce estrogen while the granulosa cells produce progesterone. Increasing concentrations of circulating estrogen stimulate an LH surge that is responsible for the continuation of meiosis two hours before ovulation. At this time, LH causes extrusion of the first polar body, the follicular wall ruptures and ovulation occurs. Extrusion of the second polar body occurs in the infundibulum, and the ovum is formed. The remaining granulosa cells of the ruptured follicle are under the control of LH and prolactin. These cells continue to produce progesterone, which inhibits further ovulation and induces behavioral and physiologic changes associated with incubation and brood care. During this time, the ovary and accessory reproductive tissues, such as the oviduct and comb, regress. Broody behavior is accompanied by the development of a brood patch in some species. Prolactin secreted by the anterior pituitary stimulates the production of "crop milk" in both genders of Columbiformes. In some avian species, pro-

lactin levels are usually higher in the parent providing the majority of the care.

In photoperiodic species, day length changes may terminate reproduction; however, in most species a photorefractory state develops that is controlled at the level of the hypothalamus.<sup>42</sup> Long day length as a stimulus is blocked, and serum gonadotropin and gonadal steroid hormones decrease to minimum levels. Photorefractoriness is then terminated by shorter daylight periods. This change often corresponds to a surge in reproductive behavior in the fall in some species. Circadian rhythms are also involved in the photoperiodic control of synthesis and release of FSH and LH.

Domestic hens are continuous layers (indeterminate layers) and under optimum conditions are reproductively active year round. Hormonal mechanisms controlling continuous egg production have been artificially induced through selective breeding. In contrast, free-ranging birds lay one or more eggs in a clutch and then terminate egg production to begin incubation. The onset of reproductive activity is influenced by increasing photoperiod in temperate climates.<sup>79</sup> Photoperiod is less important in equatorial birds where day length is similar all year. Photoperiodic pathways are controlled by light passing through the eye via the optic nerve to the hypothalamus, and by light passing through the spongy calvarium stimulating the hypothalamus or pineal body. Photoperiod also affects the time of ovulation and oviposition. In poultry, the maximum effect of photostimulation occurs when birds are provided 12 to 14 hours of light; however, normal egg production can occur when hens receive 12 to 18 hours of light. Because reproductive activity continues even when hens are placed in continuous darkness, other factors also control egg laying.<sup>79</sup>

Hypothalamic control of reproduction is influenced by environmental factors other than light, especially in periodic breeders of equatorial climates. In arid-dwelling species, such as the budgerigar and Zebra Finch, the rostral pituitary is constantly stimulated by the hypothalamus to release gonadotropins except when inhibited by negative external conditions such as drought. During these dry conditions when food would be scarce, the hypothalamic secretions suppress reproductive activity.

Ovulation in the domestic hen occurs shortly after oviposition allowing a 24 hour lay interval. In psittacine birds, the laying interval is generally two

days.<sup>4</sup> In most Passeriformes, lay intervals are 24 hours, but they can extend up to four to five days in the Andean Condor and up to 44 days in the Brown Kiwi.<sup>86</sup> It is not clear whether transit time in the oviduct, a delay in ovulation or both are responsible for longer lay intervals.

Several hormones secreted by the follicle affect the oviduct. Progesterone in large doses may inhibit ovulation or, if given 36 hours before expected ovulation, will induce follicular atresia.<sup>75,79</sup> If given 2 to 24 hours pre-ovulation, progesterone can induce a preovulatory surge of LH and premature ovulation. The dose and critical period for exogenous progesterone administration appear to vary among species and experimental designs. The extrapolation of any data collected in gallinaceous birds should be applied to companion bird species with caution. If progesterone is used to prevent egg laying, it should be administered when a complete clutch has been laid. Premature administration can cause an abnormal ovulatory process that may lead to soft-shelled eggs, mummification, peritonitis and death (Harrison GJ, unpublished). In general, the seasonal hypertrophy of the oviduct in free-ranging birds is dependent on estrogen secreted from the ovary. Progesterone and prolactin also interact with estrogen in stimulating the growth and secretory activity of the oviduct. In the oviduct, estrogens influence the synthesis of oviductal proteins, oviduct growth and the formation of tubular glands. Androgens in estrogen-primed birds influence the synthesis of proteins in the oviduct and in conjunction with estrogen initiate medullary ossification.

Ovum transport in the oviduct is primarily accomplished by contractions of the oviduct in response to a stretch stimulus. Prostaglandins, which contract the smooth muscle of the oviduct and vagina, may also influence egg transport and expulsion.<sup>79</sup> Arginine vasotocin released by the posterior pituitary stimulates uterus contractility *in vitro*, but it is not clear what role it plays in oviposition. The effect of oxytocin, also produced by the posterior pituitary, in inducing premature oviposition may be mediated *in vivo* by prostaglandins. It is likely that oviposition is a complicated process involving neurohypophyseal hormones, prostaglandins and hormones of the pre- and postovulatory follicles. Oviposition may last from seconds to hours depending on the species. Before expulsion of the egg can occur, the abdominal muscles and cervix must relax.

The thecal cells of the pre-ovulatory follicle and the ovarian stromal interstitial cells (homologous with the interstitial Leydig cells of the testis) produce androgens.<sup>75</sup> Sexual behavior and secondary sexual characteristics are influenced by androgens in the female and may become apparent depending on the stage of ovarian regression or growth. Examples of androgen-controlled characteristics include comb growth, bill growth and aggressive male-type behavior (territoriality).

LH levels increase in female cockatiels when they start nest-searching behavior and reach their highest levels during egg laying.<sup>116</sup> LH levels decline during incubation, hatching and chick-raising, but increase again in both genders if a second clutch of eggs is laid. In male cockatiels, LH levels are highest during nest inspection and are lowest during egg laying. Prolactin levels increase in both genders during egg laying, peak during incubation and then decline to a resting level.

### Calcium Metabolism

High levels of circulating calcium are needed for shell formation. Estrogen increases total plasma calcium by increasing the production of blood calcium-binding proteins.<sup>5</sup> During the laying process in psittacine birds, the calcium levels can become extremely high, reaching levels of 30 mg/dl.<sup>82</sup> However, increased blood calcium levels alone are insufficient for shell formation because hens can deplete the entire blood calcium in 8 to 18 minutes during the time the egg is in the uterus. Increased intestinal absorption and bone mobilization of calcium are needed to constantly replenish blood calcium. Laying hens will preferentially consume calcium-rich diets. This has also been observed in reproductively active psittacine hens. For psittacine birds, it is recommended that laying hens be offered at least 0.3% calcium (1:1 or 2:1 ratio with phosphorous) in their diet to prevent bone mobilization, but no more than 1% to ensure that egg shells are not excessively thick.<sup>142</sup> For continuous layers, higher levels of dietary calcium (up to 3.34% in turkey hens) are necessary for maximum egg production and hatchability.<sup>109</sup> In domestic fowl, most of the egg shell calcium is obtained from the intestine, and bone calcium is used only when blood calcium levels are low.

Bone calcium does serve as a source of calcium for shell development in hens that lay eggs during morning hours when food intake and subsequent intestinal absorption of calcium is decreased.<sup>79</sup> Calcification of the medullary spaces of the long bones, particu-

larly the femur and tibia, occurs in female birds approximately ten days before egg formation (see Figure 15.16). In budgerigars, the primary sites of medullary calcification are the humerus and femur.<sup>149</sup> If insufficient calcium is consumed, cortical bone will be mobilized. At some point in the mobilization process, calcium deficiency causes a reduction in FSH secretion that stops the laying process. High-fat, low-calcium diets exacerbate a calcium deficiency by decreasing calcium absorption from the intestines. Increased activity and concentrations of renal and circulating Vitamin D<sub>3</sub> occur prior to and during egg laying. In budgerigars, it is theorized that polyostotic hyperostosis in non-laying females results from aberrant estrogen metabolism. Affected budgerigar hens have been shown to have normal ovaries and no evidence of hormone-secreting tumors or other endocrine diseases. The liver is responsible for inactivating estrogens, and it has been suggested that impaired liver function may be responsible for this disease.

### Other Metabolic Changes

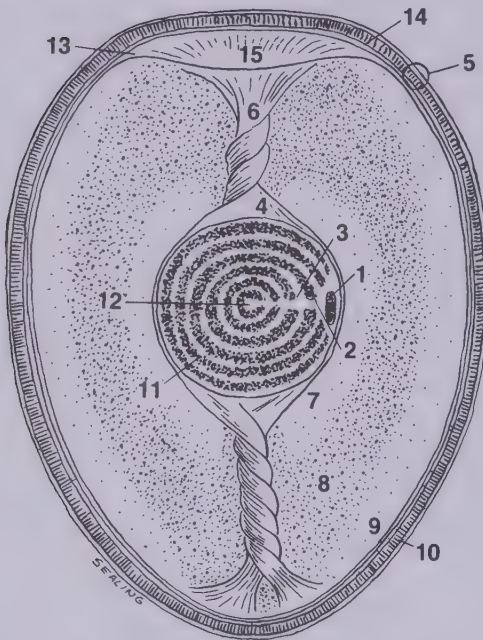
Hematogenic changes associated with egg laying include a slight increase in white blood cell count, packed cell volume, total serum solids and total protein. Total serum solids and total protein are increased because of a need for protein for calcium transport as well as from the estrogen-controlled liver synthesis of lipid and proteins produced during yolk formation (Table 29.1). Alkaline phosphatase levels may also increase due to estrogen stimulation. This has been shown to occur in budgerigars with estrogen implants.<sup>149</sup> Alkaline phosphatase levels were also shown to be elevated in egg-laying cockatiels and pigeons.<sup>57</sup>

TABLE 29.1 Typical Hemogram of Normal Laying Cockatoo Hen

	Values	Change from Non-laying Status
WBC	15-18 x 10 <sup>3</sup> /mm <sup>3</sup>	Increased
PCV	48-55%	High range of normal
Total protein	4 - 6.5 gm/dl	Increased
Calcium	15-20 mg/dl	Increased
AP	>500	Increased

### Egg Structure and Physiology

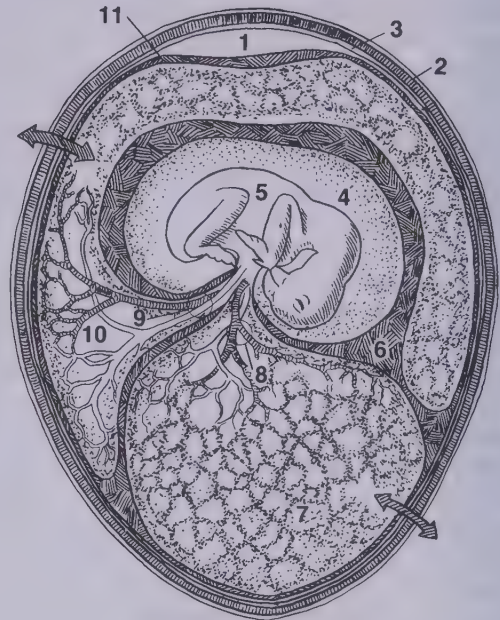
The avian egg is made of concentric layers of tissue that originate from different portions of the oviduct (Figure 29.2). Each component of the egg is responsi-



**FIG 29.2** Components of an egg: 1) blastoderm before fertilization, 2) disc of latebra 3) neck of latebra 4) chalaziferous layer 5) shell (testa) 6) chalazae 7) internal layer of thin albumen 8) thick outer albumen 9) external layer of thin albumen 10) cuticle 11) vitellus aureus 12) center of latebra 13) internal shell membrane 14) outer shell membrane 15) air space (modified from Stoodley).<sup>165</sup>

ble for various physiologic functions needed to support the growing embryo (Figure 29.3) (Table 29.2).<sup>79,86</sup> Understanding normal egg anatomy allows the clinician to recognize abnormalities and instigate appropriate therapeutic or preventive measures to resolve embryonic death problems and female reproductive disorders.

The germinal disc is a small, circular, opaque white spot on the surface of the yolk that contains cytoplasm and the oocyte (Color 29.1). The yolk is classified as either “white” or “yellow” and is layered in strata that are visible when stained with potassium dichromate.<sup>49</sup> The yolk is 50% solids, 99% of which are proteins.<sup>86</sup> Maternal antibodies (IgG) are present in the yolk. These antibodies are absorbed by the chick and provide waning passive immunity until it becomes immunocompetent. The concentration and longevity of specific immunoglobulins in psittacine egg yolk are not known. It has been demonstrated that vaccinated hens pass anti-PBFD virus antibod-



**FIG 29.3** Compartments and components of developing egg: 1) air space 2) shell 3) outer shell membrane 4) amniotic sac 5) embryo 6) albumen sac 7) yolk sac 8) omphalomesenteric artery and vein 9) allantoic artery and vein 10) chorioallantois formed from the fusion of the chorion and the allantois 11) inner shell membrane (modified from Stoodley).<sup>165</sup>

ies to their chicks and that these antibodies wane to undetectable levels between 30 and 45 days of age.<sup>134</sup>

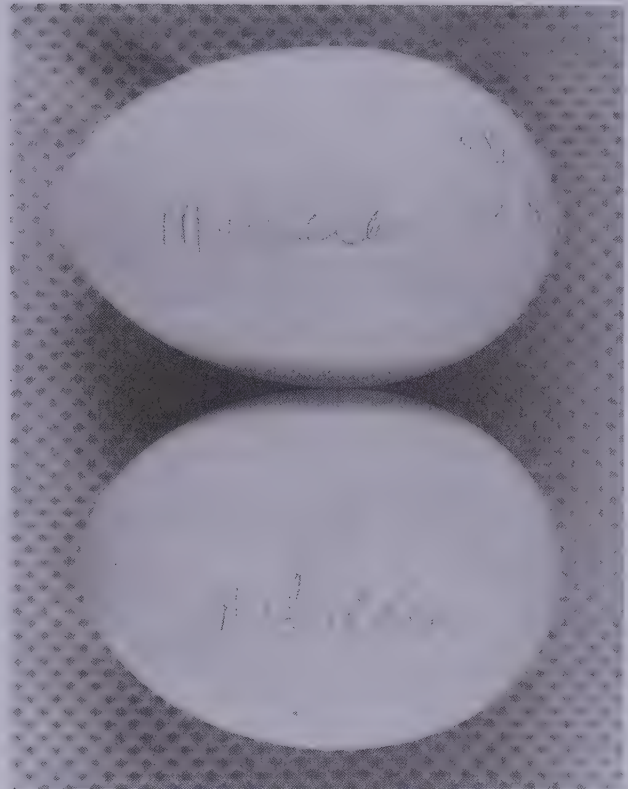
The yolk is surrounded by layers of membranes, collectively called the vitelline membrane. The normal yolk is various shades of yellow (depending on the diet and species of hen), firm, intact and separate from the albumen. The albumen is made of the chalaziferous layer, chalazae, and inner, middle and outer layers. The outer clear and inner layers are thinner than the middle layer, which can be macroscopically distinguished (see Figure 29.2). Although less viscous than the yolk, the middle layer of albumen is quite viscous, which makes it appear as a whitish-clear gel. It remains adhered to the yolk through the chalazae and albumen ligaments. At the blunt end of the egg the two shell membranes separate from each other, forming the air cell. The outer layer is adhered to the testa layer of the shell and the inner layer is attached to the dense portion of the albumen. The outermost surface of the egg is covered by a thin, sometimes waxy, cuticle. Microscopic pores in the egg shell allow for passive diffusion of oxygen,

TABLE 29.2 Embryonic Structures and Their Physiologic Function

Structure	Function
Shell	Physical protection, protects embryo from microorganisms, transpiration, regulate evaporation, source of calcium carbonate for bone formation.
Shell membrane (outer and inner)	Transpiration, protects embryo from microorganisms.
Air cell (between two shell membranes)	Transpiration.
Albumen	Nutrition, protects embryo from microorganisms
Chalazae (thick strands of albumen)	Stabilization and centralization of the yolk.
Yolk	Nutrition, maternal antibodies.
Vitelline membrane (yolk sac membrane)	Protects embryo from microorganisms.
Germinal disc	Infertile - blastodisc; Fertile - blastoderm.
Positive development	No embryo, only extra-embryonic structures.
Blastoderm without embryo	No embryo, only extra-embryonic structures, including blood islets and some vessels.
Chorioallantoic membrane	Transpiration, metabolism, waste collection, calcium transfer (shell to embryo).
Amnion	Structure around embryo, provides protective fluid environment, muscles gently rock embryo for five to twelve days of incubation, protein source (albumen drains into amnion, which embryo drinks late in incubation).
Cuticle	Regulates evaporation, protects embryo from microorganisms.

carbon dioxide and water during embryo development (see Color 48).

The shell thickness, size, shape and pigmentation vary depending on the species of bird, and a certain amount of individual variation occurs intraspecies (Figure 29.4). Hens that produce precocial young generally have larger, thicker-shelled eggs. Larger eggs usually have thicker shells. This can be clearly noted with conure eggs that have thinner shells than their somewhat close relatives, the macaws. Eggs may be conical, spherical, oval or cylindrical in shape. Cockatoos have more spherical-shaped eggs than macaws. In most species, the egg has a blunt end, which contains the air cell and is the point of exit for the emerging chick (Color 29.18). Other eggs, like those of ratites, are almost spherical. Psittacine eggs are generally smooth, but depending on the species, may be glossy (such as in macaws), greasy, chalky, powdery, ridged or pitted.



**FIG 29.4** Egg morphology and size vary dramatically among species and individuals in the same species. Normal eggs from two different Moluccan Cockatoo hens illustrate the difference in egg shape. The egg is normally passed with the pointed end caudally. A soft pencil is nontoxic and can be used to mark eggs for record-keeping purposes.


Most avian embryology has been investigated in domestic species, but embryogenesis is thought to be similar for all species (Color 29.1 to 29.13).<sup>12,55</sup>

## Male Reproductive Anatomy

The paired testes are located within the body cavity ventral to and near the cranial border of the kidney and the abdominal air sac (see Anatomy Overlay). The testis is attached to the body wall by the mesorchium and is encapsulated by two fibrous coats. Occasionally, one testis may be larger but both should be functional in mature birds.<sup>86</sup> The author has noted testes of unequal size on numerous occasions in young and mature psittacines, the importance of which is unknown. The bilateral testes are not al-

ways symmetrically located within the body cavity. One can be located more caudally than the other. Dimensions, color and shape can vary, not only by age but also among species. During the resting stage, most testes are small, yellow-white and bean-shaped. In young birds, the testes can appear flattened and pointed when compared to the rounded shape of the mature testicle. Melanistic testes, like melanistic ovaries, can occur in some species of Psittaciformes (Golden Conure, Blue and Gold Macaw, some cockatoos), Passeriformes and Piciformes (Keel-billed Toucans). Under hormonal control the testes can increase in size by 300- to 500-fold (Figure 29.5).<sup>168</sup> The increase in size appears to be proportionally greater in finches and Columbiformes than in Psittaciformes (Harrison GJ, unpublished). Vascular supply increases during reproduction, resulting in a more prominent pattern of blood vessels on the testicular serosal surface. During the breeding season, yellowish testes may turn white, while melanistic testes may change from black-grey to grey-white.<sup>86</sup> The testes normally atrophy during periods of sexual inactivity; however, the testes never become as small as they were in the prenuptial stage.

Convoluting seminiferous tubules comprised of germ (spermatogonia) and Sertoli cells make up the bulk of the testes and are responsible for spermatogenesis. Leydig cells, also called interstitial cells, produce male androgens and occupy the interstitial spaces between the tubules. Melanistic cells responsible for the color of the testicles are found in the same location. Mature spermatozoa exit via straight tubules into the rete testis, which connects the testis to the cranial aspect of the epididymis. The rete testis is not present in all birds. The epididymis, considered vestigial in birds, lies along the dorsomedial aspect of the testes and is concealed from view during laparoscopic examination, even during the breeding season when it enlarges considerably. In some species of birds, the epididymis is connected throughout its length by tubules to the rete testis.<sup>86</sup> Spermatozoa exit the epididymis and enter the ductus deferens, which forms a zigzag tubule running parallel with the ureter just medial to the kidneys. The ductus deferens is under hormonal control and is more convoluted during the breeding season. In the non-breeding season, it blends indistinguishably with the ureter and kidneys. The ductus deferens penetrates the dorsal wall of the urodeum, which functions as a receptacle for sperm. The last two to three millimeters of the ductus deferens project into the urodeum forming a papilla. In passerine birds and budgerigars, the caudal end of the ductus deferens forms the



**FIG 29.5** The testicle of a normal bird can increase substantially in size during the breeding season. In this Eclectus Parrot, the right testicle was of normal size and enlargement of the left testicle was caused by a seminoma (courtesy of Kim Joyner).

seminal glomus, which enlarges during the breeding season to form a prominent projection in the cloacal wall for the storage of sperm.<sup>85</sup> This prominence allows passerines to be easily sexed during the breeding season. Birds that do not have this structure have little sperm storage capacity. Proctodeal glands develop to varying degrees in birds and undergo hypertrophy in response to increases in steroid sex hormones.<sup>117</sup>

The ejaculatory papillae (terminal projectory papillae of the ductus deferens), paracloacal vascular bodies, cloacal folds and the phallus are involved with male copulation and are variably developed in avian species. The cloacal lymph folds and paracloacal vascular bodies contribute to the lymphatic erection of either cloacal or phallic tissue, and release a lymph-like transparent transudate when engorged.<sup>80</sup> Although not all avian species have been adequately studied, it is known that ratites, tinamous, Anseriformes, some members of the family Cracidae and one Passeriforme, the Black Buffalo Weaver, have phalli that are intromittent (inserted into the female).<sup>11,86</sup> Other species have phalli that may become engorged during copulation, but semen transfer occurs by direct cloaca-to-cloaca contact without intromission.

The phallus, if present, is located ventrally in the proctodeum. Dysfunction or disease of the phallus can cause reproductive failure. Psittacine birds do not have a phallus, and copulation is accomplished by an eversion of the cloacal wall, which contains the slightly raised papilla that transfers semen to the everted orifice of the oviduct.<sup>106</sup> Determination of



gender can be accomplished by identifying the seminal papilla in the male of many cockatoos but not in Amazon parrots and macaws (Harrison GJ, unpublished).

### Semen

In domestic fowl, spermatozoa undergo maturation and become fully fertile in the ductus deferens. The transient time required for sperm to pass from the testes to the distal ductus deferens is estimated to be from one to four days. Seminal plasma that is formed in the efferent and connecting ductules of the epididymis and ductus deferens accompanies the spermatozoa. Seminal plasma composition can vary among species but is similar in concentration and constituents in the budgerigar and domestic fowl.<sup>145</sup> In most birds, semen is stored in the ductus deferens. In Passeriformes, semen is also stored in the seminal glomus, which is the enlarged terminus of the ductus deferens. A lymph-like fluid, called "transparent fluid," originates in the proctodeum and mixes with the semen during ejaculation. The function of this fluid is uncertain, but it does contain blood clotting agents that are deleterious to the spermatozoa.<sup>86</sup>

In Passeriformes, spermatozoa are of the complex type, which can be differentiated from the simple type of sperm found in other birds by their predominantly spiral structure.

Semen can be collected from birds for artificial insemination, to evaluate its reproductive potential, to detect disease and to distinguish species or subspecies.<sup>154</sup> The consistency of normal semen ranges from that of water to that of heavy cream. Watery semen may indicate high volumes of transparent fluid in the sample. Normal semen is light white to milky, and brown, green or red discoloration may be due to fecal contamination or cloacal hemorrhage from over-exuberant semen collection. Production of fertile eggs is the best indicator of sperm viability, but determining sperm count and motility can be used to estimate function (Table 29.3).<sup>45</sup> One million sperm are required for optimal fertility in the domestic fowl.

Sperm concentration can be determined by mounting semen on a hanging drop slide, use of a spermatocrit or direct counting in a hemocytometer. In those species with higher sperm concentrations, dilution with artificial insemination semen extender may be necessary prior to evaluation. Motility is estimated as the percentage of spermatozoa moving in a forward motion as seen under high magnification. Live-dead counts using an eosin-nigrosin stain make it possible


**TABLE 29.3** Volume and Concentration of Ejaculates from Selected Birds <sup>21,69,80,106,147</sup>

Bird	Sperm Concentration	Ejaculate Volume
Chicken	1.7-3.5 billion/ml	500-1000 $\mu$ l
Budgerigar	9.5-11.3 billion/ml	3.5-13 $\mu$ l
Pheasant	$10 \times 10^9/\mu$ l	50-250 $\mu$ l
Large Psittaciformes	9-10 million/ml	50-100 $\mu$ l
Emu	4.4 billion/ml	1200 $\mu$ l

to evaluate the concentration of live sperm. Live-dead counts, computer-assisted measurement of spermatozoal swimming speed and metabolic rates of semen can also be used to determine semen quality.

### Male Hormonal and Physiologic Factors

In the male, FSH and LH exert gonadotrophic properties similar to those described in the hen. FSH initiates the growth of seminiferous tubules and results in increased spermatogenesis. LH promotes development of the testosterone-producing cells of Leydig. Testicular growth is approximately logarithmic until half of the ultimate size is attained.<sup>42</sup> Higher levels of testosterone are then responsible for male sexual behavior. Testosterone increases spermatogenesis and growth of accessory reproductive organs, such as the epididymis and cloacal gland. Testosterone also causes manifestation of secondary sexual characteristics such as comb growth, plumage and



**FIG 29.6** Male cockatoos will frequently attack and sometimes kill their hens. This behavior can occur in pairs that have been stable and producing young for years. The precise cause of these attacks is unknown, but they are most common in the early part of the breeding season. Males generally become reproductively active earlier than the females, and a hen's failure to respond to a soliciting male may facilitate an attack. In this cockatoo hen, most of the beak and a part of the skull had been removed by the male.

bill color, structure of feathers, vocalizations and reproductive behavior. Specific reproductive behavior affected by testosterone, and probably mediated by other hormones, includes territorial aggression, courtship, copulation, nest building, incubation and care of the young. Testosterone levels are highest in many species at the time of establishment and defense of territory, courtship and nesting activity.<sup>42</sup> Substantial field observations suggest that the testes become functional earlier than the ovaries, and that coordination of the reproductive effort is mediated by environmental and photoperiodic stimulation in the female.<sup>42</sup> As in the hen, prolactin, progesterone, estrogen and androgens are all involved with incubation and brood care. This complex control of the reproduction cycle may account for breeding failures and mate aggression in captive Psittaciformes (Figure 29.6).

## Female Reproductive Disorders

### ■ Egg Binding and Dystocia

Two of the most common clinically recognized reproductive disorders seen in avian species are egg binding and dystocia. Egg binding is defined as the failure of an egg to pass through the oviduct at a normal rate. Most companion bird species lay eggs at intervals greater than 24 hours, and individuals within a species may vary by more than one day from the normal oviposition rate.<sup>4</sup> Variability in egg transit times makes it difficult to determine when a problem is occurring.

Dystocia defines a condition in which the developing egg is in the caudal oviduct and is either obstructing the cloaca or has caused oviduct tissue to prolapse through the oviduct-cloacal opening. Egg movement through the oviduct can stop at various locations. The most common anatomic areas for problems to occur are the caudal uterus, vagina and vaginal-cloacal junction.

The pathogenesis of egg binding in a particular case can be multifactorial. The pubic bones are not fused in birds, and pelvic deformities seldom play a role in dystocia. Common causes of dystocias are oviduct muscle dysfunction (calcium metabolic disease, selenium and vitamin E deficiencies), malformed eggs,

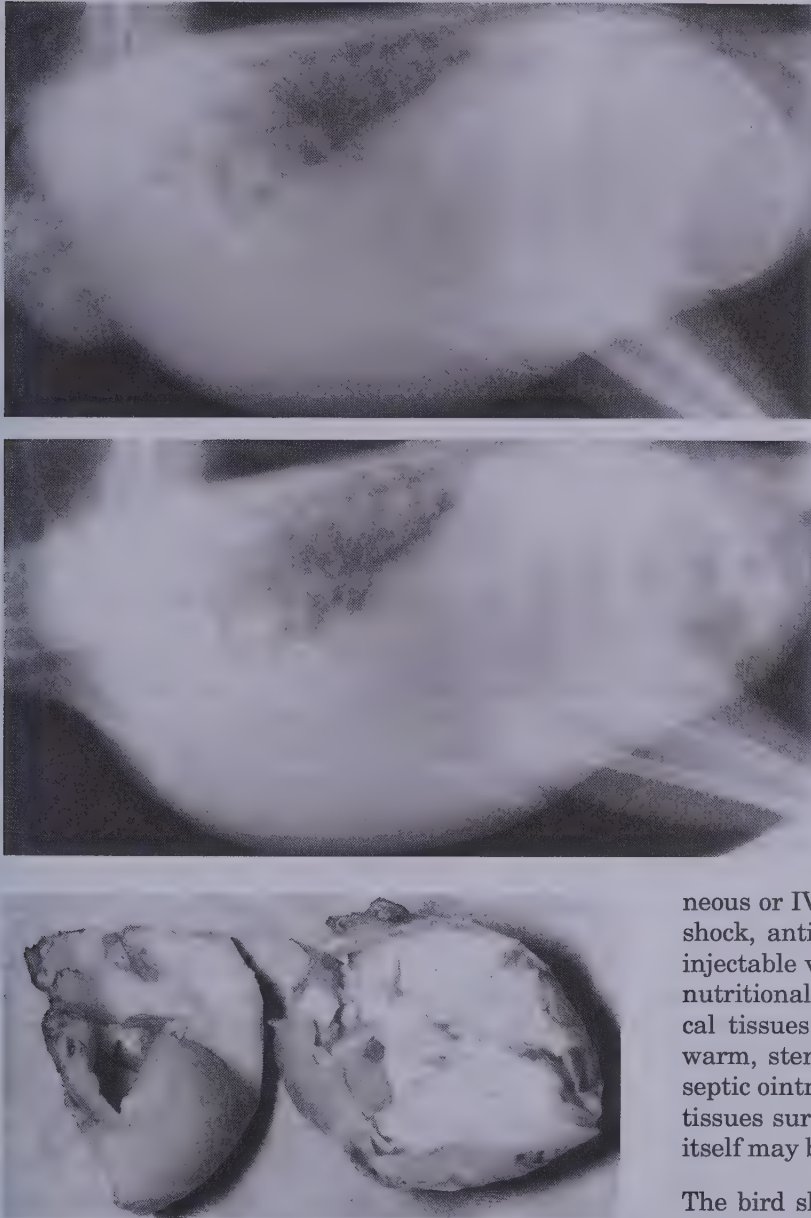excessive egg production, previous oviduct damage or infection, nutritional insufficiencies, obesity, lack of exercise, heredity, senility and concurrent stress such as environmental temperature changes or systemic disease.<sup>62,66,140,160</sup> Dystocia can also result from breeding birds out of season, egg production in virginal hens and a persistent cystic right oviduct (Color 29.20).<sup>72</sup>

Abnormally prolonged presence of an egg in the oviduct causes a multitude of complications in the hen (Figure 29.7). The severity of these complications depends on the species, the bird's previous health, the cause of egg binding, the egg's location in the oviduct and the time elapsed since egg development began. An egg lodged in the pelvic canal may compress the pelvic vessels and kidneys, causing circulatory disorders and shock.<sup>140</sup> An impacted egg may cause metabolic disturbances by interfering with normal defecation and micturition, inducing ileus and renal dysfunction.<sup>66</sup> Pressure necrosis may occur to all three layers of the oviduct wall and lead to rupture.

### Clinical Signs

Budgerigars, canaries, finches, cockatiels and lovebirds most frequently have problems with dystocia.<sup>141</sup> This is probably because the presentation of a palpable egg for more than a few hours in small birds is generally more serious than it is in larger birds. The patient's clinical signs will depend on the severity of the complications. Generally, the hen appears depressed, has an abnormally wide stance, is reluctant to fly or perch and may show persistent wagging of the tail and straining movements of the abdomen. Canaries often exhibit drooped wings. Rear limb paresis or paralysis may occur. Egg-related peritonitis, septicemia, leg injuries and abdominal neoplasia show similar clinical signs (Color 29.27). Any depression can lead to anorexia, which further compromises the bird's condition.

Hens with dystocia frequently present with depression and secondary complications that require emergency therapy. A complete history including information of past breeding activity and the diet "consumed" will often suggest a pathogenesis. A thorough but rapid physical examination can also establish contributing factors such as obesity, concurrent disease or a malformed egg. Dystocias are most critical in passerines<sup>4</sup> and other small birds, many of which can survive only a few hours without aggressive therapy.<sup>66</sup> Initially the therapeutic plan is to stabilize the patient (see Chapter 15) with an emphasis being placed on correcting the most likely etiology for the dystocia.



**FIG 29.7** An Amazon parrot hen was presented for depression, a hunched stance and tenesmus. A firm palpable mass was present in the caudal abdomen. Radiographs revealed two calcified eggs. The caudal egg could not be located through the cloaca. The contents of the eggs were removed by oocentesis, and the eggs were collapsed. Radiographic appearance of the collapsed eggs. The hen's attitude improved immediately and she began eating normally. The fragmented egg shells were passed two days after they were collapsed.

The severity of the dystocia, and speed of correction that will be required, can be partially estimated by the level of depression. Careful abdominal palpation and a cloacal examination are required to determine

the egg's position in the reproductive tract. In smaller birds the displaced ventriculus may make palpation of an egg difficult. Soft-shelled eggs, shell-less eggs or eggs located cranial to the uterus can also be difficult to palpate. Suspected egg masses must be differentiated from palpable hernias, lipomas or ascites. Radiographs are a useful confirmatory tool but may not delineate a shell-less egg. Radiographically identifying more than one egg in various stages of development is common.

### Therapy

The most important consideration in initiating therapy for dystocia is to establish a physiologic normal state. Attempts to remove the egg are secondary to stabilizing a patient in shock. In minimally depressed patients with few complications, the egg will usually pass if the hen is provided with supplemental heat, injectable calcium, selenium, vitamin E, vitamin D<sub>3</sub> and easy access to food and water.<sup>56</sup> Others require subcutaneous or IV fluids, rapidly acting steroids to combat shock, antibiotics to treat sepsis or peritonitis and injectable vitamins and minerals to address further nutritional deficiencies. Prolapsed oviductal or cloacal tissues should be moistened and cleaned with warm, sterile saline washes and water-based antiseptic ointments, such as chlorhexidine. Lubricating tissues surrounding the egg or the cloaca or vagina itself may be of some help to egg expulsion.

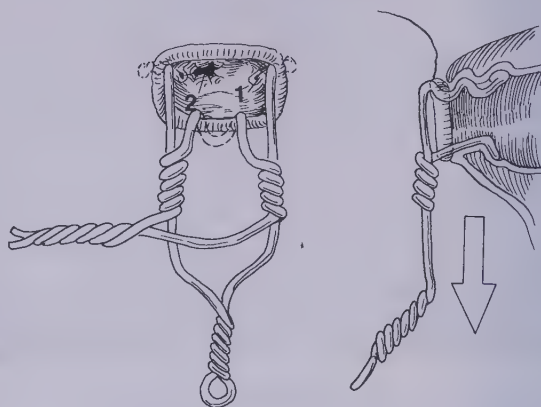
The bird should be placed in an incubator at 85 to 95°F with an inflow of heated, moisturized air. If the egg is not expelled within a few hours, then a prostaglandin injectable product (dinoprost tromethamine) can be administered IM or applied topically to the oviductal tissue. This compound appears to be superior to oxytocin because it has the combined effect of inducing uterine contraction while relaxing the uterovaginal sphincter (see Chapter 18).<sup>73</sup> Prostaglandin or oxytocin should be used only in cases where the uterus is thought to be intact and no adhesions to the oviduct are suspected. A hen receiving these agents must be able to withstand the increased contractions of the oviduct and abdomen that occur following the administration of oxytocin. Clinical signs

of oxytocin response include tail pumping, panting, abdominal contractions and elimination of the egg. Increasing and repeated doses of oxytocin can be given if initial injections have no effect. Experimental use of prostaglandins and arginine vasotocin in domestic species has shown that injections of either of these drugs may result in oviposition.<sup>144,157</sup> Arginine vasotocin likely causes the release of prostaglandins from the uterus. Clinical use of vasotocin in reptiles suggests that this drug may be of some value in birds (0.01 to 1.0 mg/kg BW) (Lloyd M, personal communication). It has been shown that uteri are more sensitive to vasotocin than to oxytocin.<sup>97</sup> Complications of oxytocin or vasotocin use include oviduct rupture.

If medical therapies fail to elicit oviposition, then more aggressive approaches that require manual manipulation of the patient may be necessary. Massaging the abdomen or cervix may help stimulate egg passage or relax the cervix so that the egg can be passed. The egg itself can be digitally manipulated caudally for expulsion (Color 29.30). The use of warmed water-soluble solutions or ointments (saline with methyl cellulose) to lubricate the urodeum or vagina is equivocal. Gentle, persistent, caudally directed pressure on the egg may supplement weakened muscular contractions and loosen any recently formed adhesions. Only gentle traction should be used to prevent rupture of the oviduct. As long as the bird remains stable, repeated attempts at digital egg removal should continue. The cervix can be dilated by using a speculum to insert a blunt probe that is advanced in gentle, twirling motions (Figure 29.8). Eggs may be fertile and viable and should be incubated following expulsion. Digital manipulation and contracting therapy should not be used if one suspects ectopic eggs, uterine torsion, uterine rupture, or uterine constrictions due to adhesions (mucosal adhesions to the egg or the opposite uterine wall or serosal adhesions to other abdominal structures).

### Ovocentesis

If the bird's condition is deteriorating or if an inappropriate period of time has passed since the dystocia was first noted, then more aggressive therapy such as ovocentesis must be considered. Ovocentesis is performed by aspirating the contents of the egg with a large needle (18 ga).<sup>141</sup> Preferably the egg is manipulated with the use of a speculum so that it is observable and tapped through the cloaca.<sup>2</sup> If this is not possible, the egg is brought in juxtaposition to the abdominal wall so that other organs are not damaged during a transabdominal aspiration procedure. Fol-

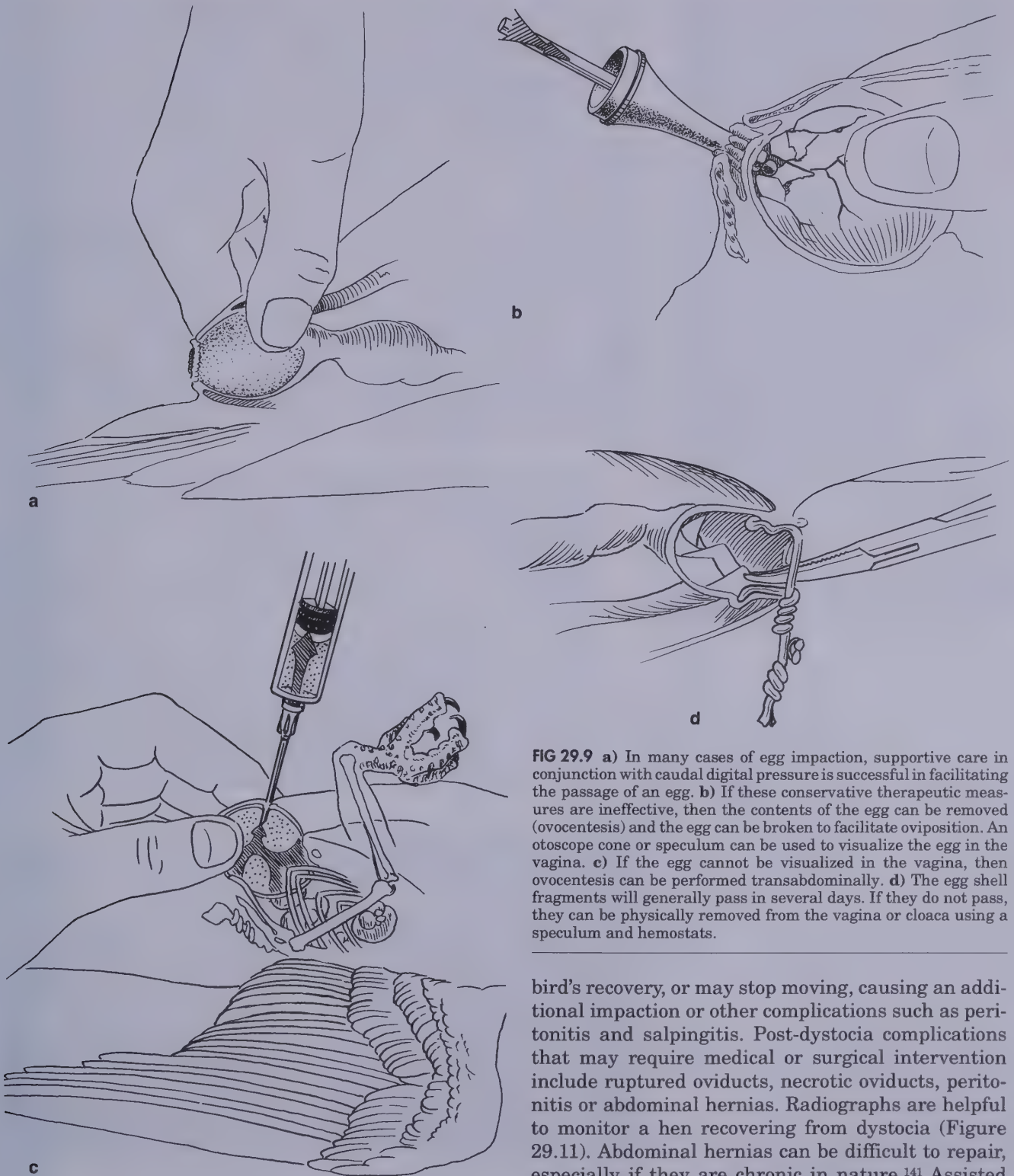


**FIG 29.8** A speculum can be used to facilitate evaluation of the cloaca and removal of eggs. 1) opening of the ureter and 2) vaginal opening.

lowing aspiration of the egg contents, the egg can be gently collapsed (Figure 29.9). The risk of tearing the oviduct and producing peritonitis does exist but appears to be minor (see Chapter 48). The shell fragments and remaining contents of the egg should pass within several days (see Figure 29.7). Fragments that are visible through the cloaca can be gently removed. Some clinicians advocate flushing the uterus post-oviposition with an iodine, chlorhexidine or saline solution to help remove egg fragments and to decrease the incidence of metritis.<sup>56</sup> A Brunswick feeding catheter (3 to 5 Fr) can be placed through the cervix for this procedure (Figure 29.10). A course of broad-spectrum antibiotics, chosen based on the results of a Gram's stain collected from the uterus and confirmed as the correct choice by culture and sensitivity, is also recommended.

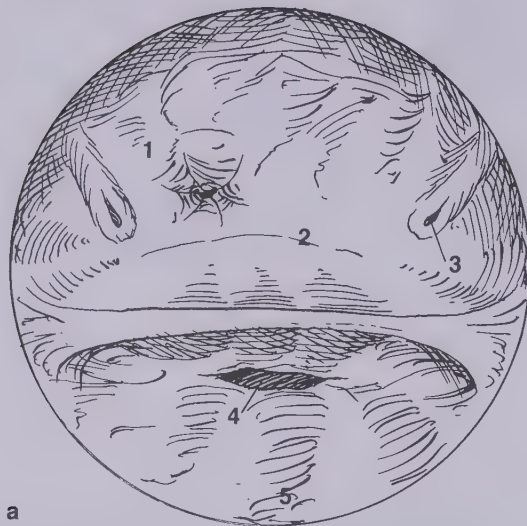
If the egg is lodged in the caudal oviduct or cloaca and the survivability of the egg is critical, then an episiotomy may be beneficial in delivering the egg.<sup>141</sup> A laparotomy may be necessary to remove egg material or to perform a hysterectomy in cases where the uterus is ruptured or severe adhesions exist. Soft-shelled eggs located cranial to the uterus or ectopic eggs also require surgery.<sup>104,140</sup>

Many hens with dystocia will attempt to lay another egg. Administration of medroxyprogesterone will stop ovulation, but there are side effects and its use is controversial. Following medroxyprogesterone administration, eggs already present in the proximal oviduct may continue to descend, complicating the

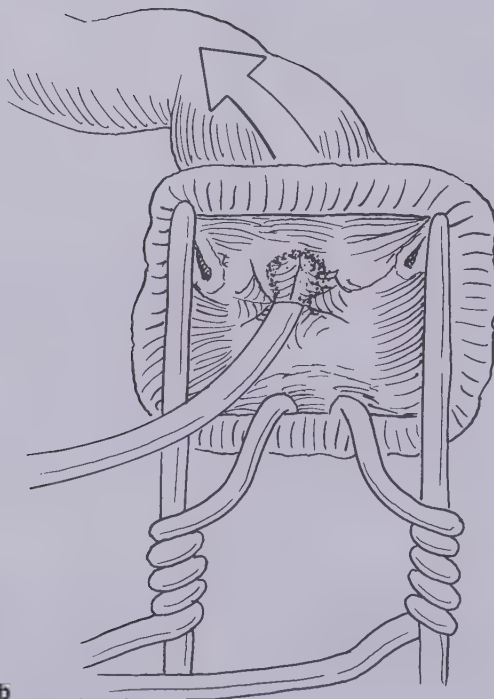


**FIG 29.9** **a)** In many cases of egg impaction, supportive care in conjunction with caudal digital pressure is successful in facilitating the passage of an egg. **b)** If these conservative therapeutic measures are ineffective, then the contents of the egg can be removed (ovocentesis) and the egg can be broken to facilitate oviposition. An otoscope cone or speculum can be used to visualize the egg in the vagina. **c)** If the egg cannot be visualized in the vagina, then ovocentesis can be performed transabdominally. **d)** The egg shell fragments will generally pass in several days. If they do not pass, they can be physically removed from the vagina or cloaca using a speculum and hemostats.

bird's recovery, or may stop moving, causing an additional impaction or other complications such as peritonitis and salpingitis. Post-dystocia complications that may require medical or surgical intervention include ruptured oviducts, necrotic oviducts, peritonitis or abdominal hernias. Radiographs are helpful to monitor a hen recovering from dystocia (Figure 29.11). Abdominal hernias can be difficult to repair, especially if they are chronic in nature.<sup>141</sup> Assisted oviposition may cause a flaccid cervix, allowing reflux of feces and urine into the uterus. Daily flushing and Gram's staining of the uterus to monitor pro-



a



b

**FIG 29.10** **a)** Caudal to cranial view of the normal cloacal anatomy of a hen: 1) vaginal opening, 2) urodeum, 3) opening of ureter, 4) rectal opening and 5) coprodeum. **b)** Post-dystocia flushing of the uterus with chlorhexidine or sterile saline may reduce the occurrence of salpingitis.

gress following the removal of an egg appears to reduce the occurrence of metritis (Harrison GJ, unpublished).

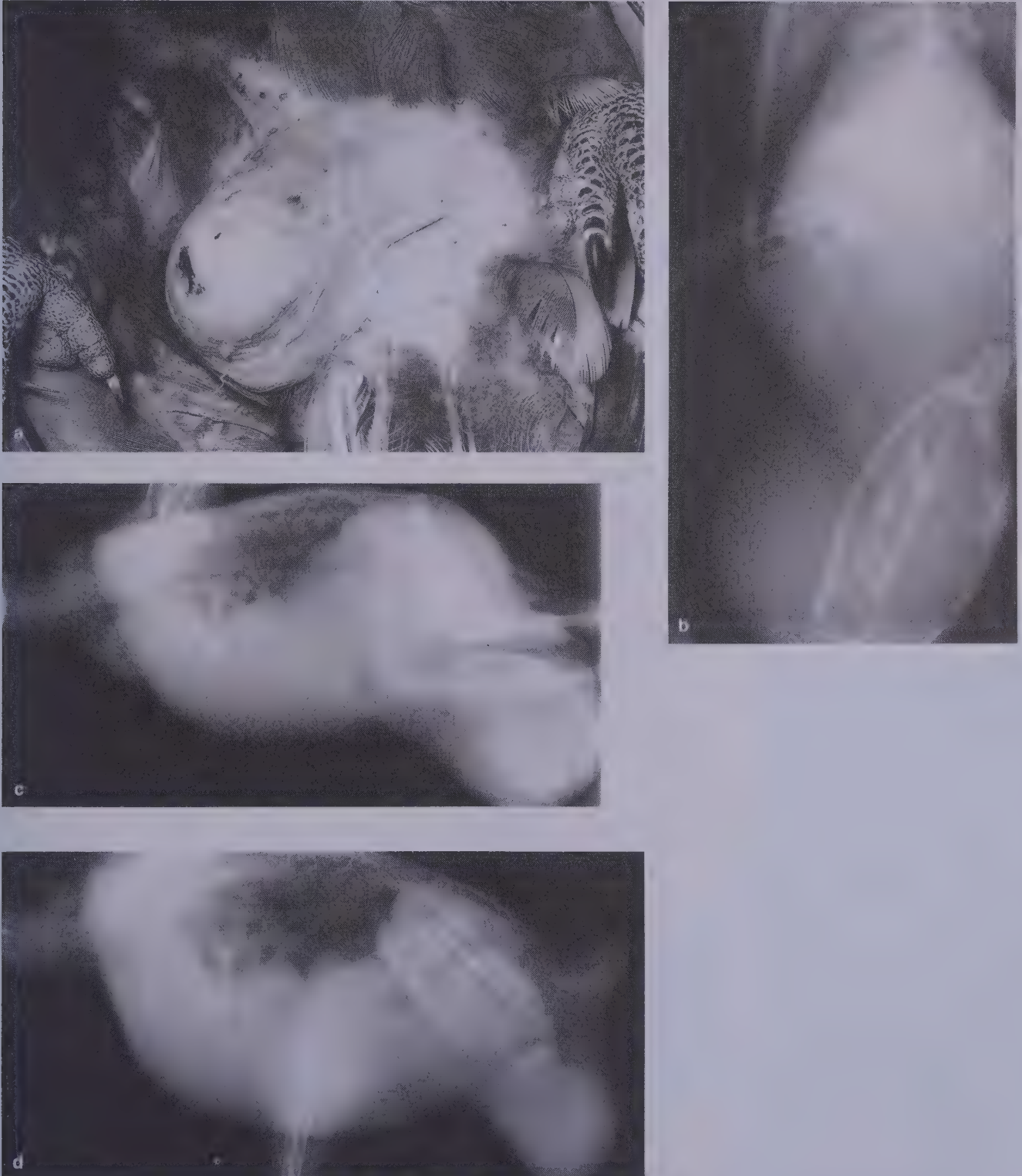
### ■ Prolapsed Oviduct and Cloaca

Prolapse of the oviduct may occur secondary to normal physiologic hyperplasia and egg laying or as a sequela to dystocia (particularly in canaries and budgerigars) (Color 29.31 and 29.32).<sup>6</sup> Excessive contraction of the abdominal muscles, perhaps exacerbated by poor physical condition and malnutrition, may cause these prolapses.<sup>14</sup> Usually the uterus protrudes through the cloaca, often together with a partial prolapse of the vagina and cloaca. Distal portions of the oviduct may also prolapse, and frequently an egg is present (Color 29.30). Oviduct prolapses have been associated with deformed, soft-shelled and shell-less eggs.<sup>84</sup> Timely, aggressive therapy is needed to prevent devitalization of uterine tissues and secondary infections. All exposed tissue must be kept as moist as possible and cleaned thoroughly with sterile saline solution. Topical steroid preparations containing antibiotics or dimethyl sulfoxide gel can be used to reduce swelling so that prolapsed tissues can be replaced. If no egg is present, tissue replacement is accomplished by gently guiding the tissues through the cloaca with pressure from a lubricated swab or thermometer. Repeated replacement of tissues may be required, as prolapses often recur. Stay sutures placed in the cloaca or percutaneous retention sutures may prevent further prolapsing while uterine tissues regress in size, abdominal tissues regain structural integrity and the hen has a chance to regain normal muscle tone and strength.<sup>104,139</sup> The prognosis for birds with uterine prolapses is good as long as they are treated immediately.<sup>66</sup>

If an egg is present in the prolapsed tissue, it must be removed before the tissue is replaced in the abdomen (Color 29.31). Digital manipulation or implosion of the egg as discussed under dystocia may be effective. Chronically displaced tissue that contains eggs or egg material may require surgical debridement due to adhesions and shell abnormalities. In severe cases of uterine damage and necrosis, a partial or complete hysterectomy may be necessary, but is best delayed until the bird's condition is stable (see Chapter 41).<sup>141\*</sup>

### ■ Salpingitis and Metritis

Salpingitis may occur from air sacculitis, pneumonia, liver disease or retrograde infections of the lower



**FIG 29.11** a) An adult Amazon parrot hen was presented for evaluation of a ventral abdominal mass. b,c) Radiographs indicated a herniated egg and a second abnormally formed egg in the dorsal abdomen. Surgical correction of the hernia and a salpingohysterectomy were recommended but refused. d) Additional radiographs taken eight weeks after the initial presentation indicated that the herniated egg was being resorbed, and that the second egg was increasing in density.

## Theriogenology

### Egg Incubation

From the poster of Cockatiel Embryonic Development, reprinted with permission. Posters are available from the University of California, ANR Publications, 6701 San Pablo Avenue, Oakland, CA 94608-1239.

#### Color 29.1

**a)** The unincubated fertile egg has a distinct ring consisting of a white peripheral region (area opaca) surrounding a clear central region (area pellucida). **b)** The same area in the unincubated infertile egg is small in size, lacks cellular organization and looks like a small piece of cotton on the surface of the yolk. The diameter of the fertile blastodisc is four to five times that of the same area in an infertile egg.

#### Color 29.2

Unincubated egg with a large blood spot indicative of bleeding from the follicle during ovulation.

#### Color 29.3

Incubated fertile egg showing two common types of first-day failures. Neither shows development of embryonic structures. **a)** Eggs with positive development fail before blood formation, while **b)** eggs with blastoderm without embryo continue cell division until blood-forming stages. Blastoderms without embryos can be seen during candling, when a blood ring is usually present. Positive developments and blastoderms without embryos may vary in size depending on the length of incubation.

#### Color 29.4

A profile shot of a yolk 48 hours after the onset of incubation showing a bleb that represents the embryonic area. This bleb can also be seen by candling.

#### Color 29.5

Cockatiel egg at approximately three days of incubation (embryo stage 17). The heart

and major blood vessels of the yolk sac are visible. The embryo has turned to its left side.

#### Color 29.6

Cockatiel egg at approximately 4.5 to 5 days of incubation (embryo stage 24). The subdivisions of the brain, the developing pigmented eye, increased yolk sac circulation, developing wing, leg buds and the allantois (arrow) are visible.

#### Color 29.7

Embryo removed from an egg at 4.5 to 5 days of incubation. The divisions of the brain are pronounced. The limb buds and tail fold are prominent.

#### Color 29.8

Normal cockatiel embryo approximately six days of incubation (embryo stage 28-29). The characteristic cockatiel-shaped head shows prominent mid-brain divisions. There is further development of the eye, including appearance of the choroid fissure (arrow). Outlines of the digits can be seen on the developing wings and legs.


#### Color 29.9

Normal embryo at approximately 7 to 7.5 days of incubation (stage 31). The egg tooth, beak and scleral papillae of the eye are evident. The limbs are developing and the bones are beginning to calcify. The first feather follicles can be seen.


#### Color 29.10

Normal cockatiel embryo approximately nine days of incubation (embryo stage 35). A prominent egg tooth and early development of the upper beak are evident. Scleral papillae in the eye form a complete ring. The head shape is square with a less prominent mid-brain. Note the feather formation on the dorsal body surface and calcification in the long bones and toes.







29.1a



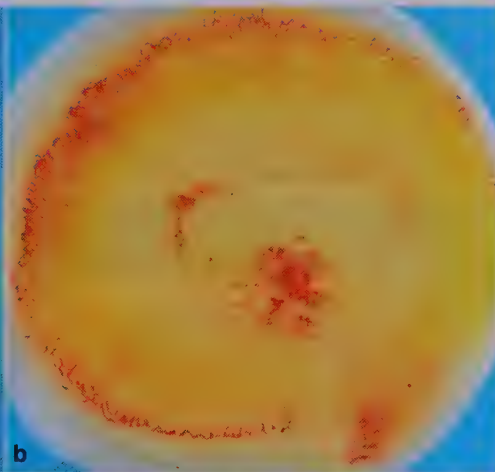
b




29.2



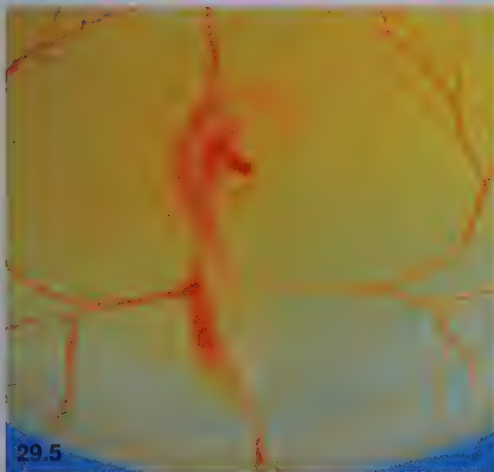
29.3a



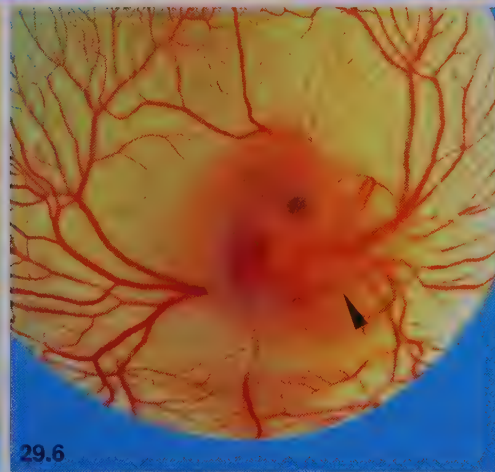
b




29.4



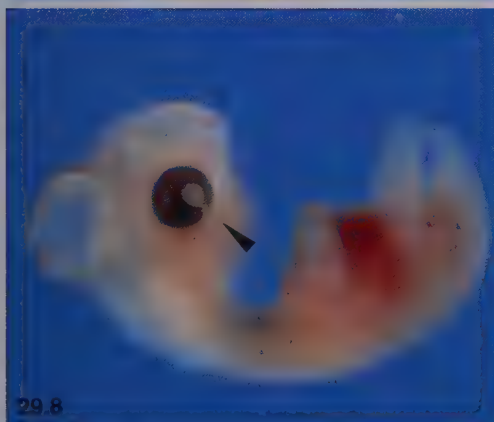
29.5



29.6




29.7



29.8



29.9



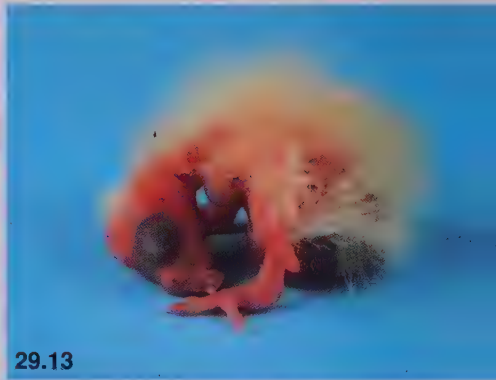
29.10



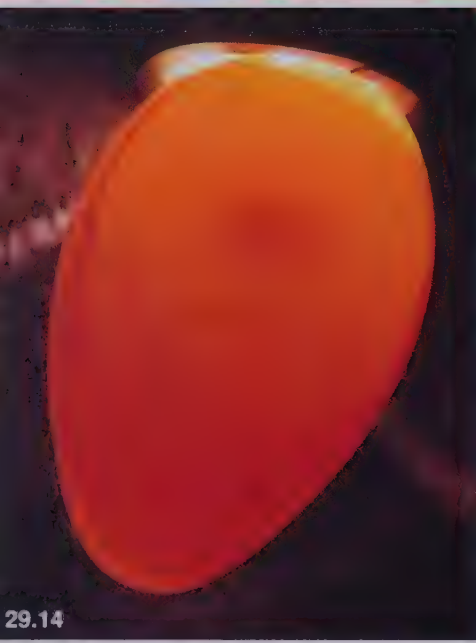29.11



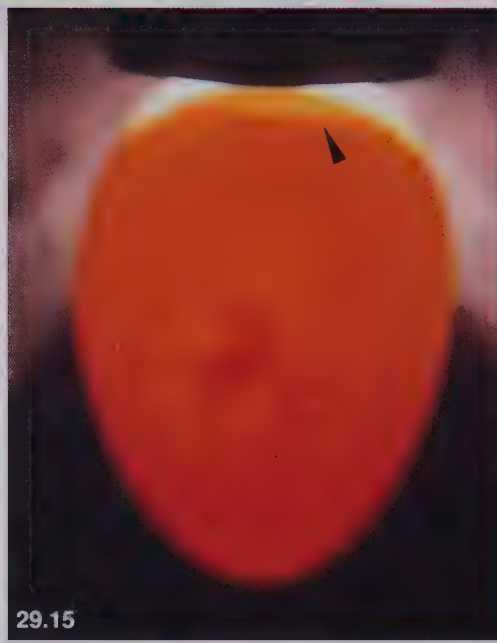29.12



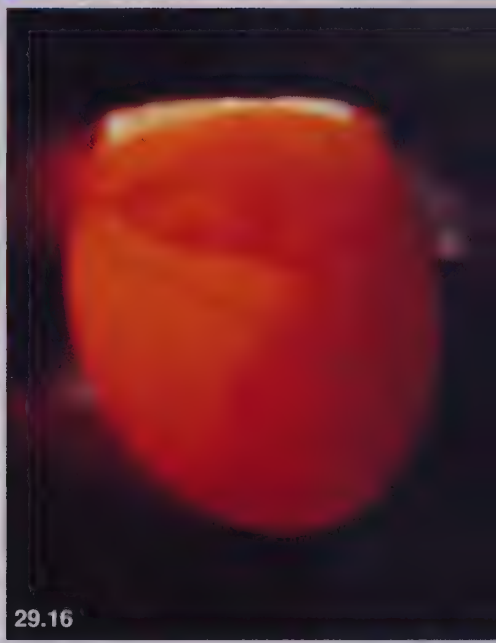29.13



29.14



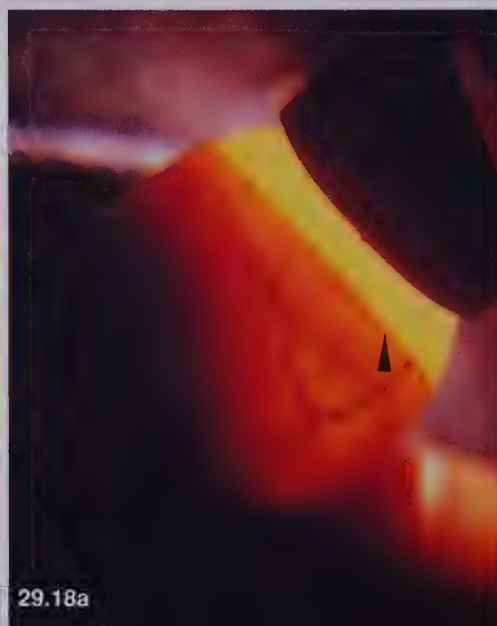
29.15



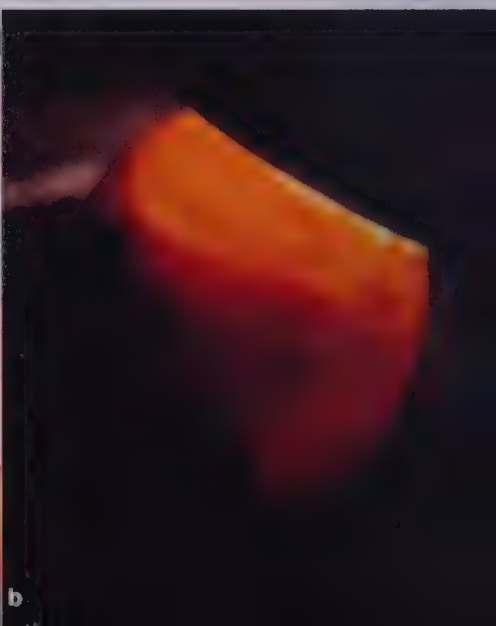29.16



29.17



29.18a



b

## Theriology

### Color 29.11

Normal embryo at 12 to 13 days of incubation illustrates features unique to cockatiels. The lower beak is shorter than the large square upper beak. Note the serrations on the inner surface of both beaks. The scleral papillae can no longer be seen as the eyelid is now nearly closed. Calcification of the characteristic psittacine toes and growth of sparse feathers are evident.

### Color 29.12

Normal cockatiel embryo at approximately 16 to 17 days of incubation (stage 42). The eyelids are closed, the beak is enlarged and the egg tooth and toenails are almost completely formed. The yellow pigmentation of the skin reflects the metabolism of fat. The extremities may appear pinker than illustrated.

### Color 29.13

Normal cockatiel chick at hatching (18 days of incubation). The yolk sac is completely resorbed and the umbilicus is sealed. Hatchlings would not be expected to appear as hyperemic as illustrated.

### Color 29.14

The appearance of a blood spot in this egg indicates that the egg was fertile. The de-

velopment of a blood ring is characteristic for early embryonic death (courtesy of Kim Joyner).

### Color 29.15

Day ten of incubation in a Black Palm Cockatoo egg. Note the centrally located embryo with the developing blood vessels and the small air cell (arrow) (courtesy of Kim Joyner).

### Color 29.16

Day 14 of incubation in an Umbrella Cockatoo egg (courtesy of Kim Joyner).

### Color 29.17

Day 12 of incubation in an Eclectus Parrot egg (courtesy of Kim Joyner).

### Color 29.18

**a)** Day 21 of incubation in a Military Macaw egg. Note the development of the air cell (arrow) and the still prominent blood vessels. **b)** Day 26 of incubation in the same egg. The shell is pipped and the blood vessels are collapsing as the bird switches from chorioallantoic to pulmonary respiration (courtesy of Kim Joyner).

uterus, vagina or cloaca. In Passeriformes, salpingitis has been associated with impaction of the oviduct and egg-related peritonitis.<sup>65</sup> Foreign bodies such as wheat grains located in the oviduct can cause metritis and salpingitis.<sup>132</sup> Excessive abdominal fat has been associated with many cases of salpingitis in domestic fowl.<sup>127</sup> The etiologic agent most frequently isolated from birds with salpingitis is *E. coli*.<sup>132</sup> Other bacteria such as *Mycoplasma gallisepticum*, *Salmonella* spp. and *Pasteurella multocida* can affect other organ systems simultaneously with the salpinx. In raptors, *E. coli* and *Streptococcus* spp. have been described as causes of salpingitis.<sup>32</sup> Ascending infections from the cloaca induced by copulation, inappropriate treatment for egg binding or uterine prolapse may induce salpingitis.<sup>66</sup>

While salpingitis is most common in adult hens, it can also occur in young birds.<sup>132</sup> Salpingitis reportedly occurs less frequently than oophoropathies, obstruction of the oviduct and ectopic ovulation in a variety of avian species.<sup>84</sup> Depression, anorexia, weight loss and abdominal enlargement can occur with salpingitis. A discharge from the cloaca may also occur. Acute salpingitis in poultry is characterized by an enlarged, dark red oviduct with involvement of the infundibulum.<sup>155</sup> The lumen may contain cream-colored, slimy fluid or cheesy, yellowish fibrinous exudate. The oviduct may be thin-walled or decreased in length (common with Newcastle disease virus or infectious bronchitis virus).<sup>13,19</sup> Congestion may be the only grossly observable change, although salpingitis may not be recognized macroscopically.<sup>119</sup> Bacteriologic and histologic examinations are necessary to establish a diagnosis.

Cockatiel hens that have a history of egg laying followed by mild depression and weight loss may have a low grade salpingitis or focal egg-related peritonitis (Harrison GJ, unpublished).

Metritis is a localized problem within the uterine portion of the oviduct. It can be a sequela to dystocia, egg binding or chronic oviduct impaction. Bacterial metritis is often secondary to systemic infections.<sup>141</sup> Metritis may affect shell formation or uterine contractility or cause infections in embryos (embryonic death) or neonates (weak chicks). Metritis can also cause egg binding, uterine rupture, peritonitis and septicemia. Coliforms, especially *E. coli*, are frequently implicated. Coliform metritis may be complicated by poor diet, and death rates are highest in hens during the ovulatory and egg-laying period.<sup>62</sup>

In more advanced cases, birds may be depressed and have an enlarged abdomen and a palpable turgid uterus. Radiographs often reveal indistinct abdominal detail with a diffuse increase in soft tissue density. Ultrasound has been used in ostriches.<sup>69</sup> An affected ostrich hen may have a history of erratic production, malformed or odoriferous eggs or a sudden drop in production. An odoriferous cloacal discharge may occur, and the WBC may range from 20,000 to 100,000 mm<sup>3</sup>. Metritis and salpingitis are treated aggressively with parenteral antibiotics, supportive care and therapy for shock (see Chapters 15 and 18). In non-responsive cases, a laparotomy may be necessary to remove necrotic tissue, inflammatory exudates or egg material. The oviduct may be flushed directly with lactated Ringer's solution (with or without antibiotics) by placing an IV fluid tube or soft catheter into the vagina.<sup>62</sup> Visualizing placement of the tube can be augmented by use of a cloacal protractor (see Figure 29.10).

### ■ Oviduct Impaction

Impaction of the oviduct is often a sequela to salpingitis (most frequently), metritis or egg binding. One study found that impactions were nearly always associated with obvious salpingitis in older birds.<sup>84</sup> Impactions may occur from excess secretion of mucin and albumen associated with cystic hyperplasia or inspissated egg material in the magnum. Soft-shelled, malformed or fully formed eggs can impact in the distal oviduct. Cockatiels, canaries and budgerigars are frequently affected, and the condition has been documented in raptors and an African Grey Parrot.<sup>6,14,35,66,83,85</sup> Clinical changes are not always obvious and may include a cessation of egg production, progressive loss of condition and alternation between constipation and diarrhea. Chronic deterioration is particularly common if concurrent peritonitis or salpingitis is present. The abdomen may be diffusely or unilaterally (usually left side) enlarged, birds may be reluctant to fly or walk and periodic anorexia may occur.<sup>66</sup> Radiology can be helpful in some cases, but many oviduct impactions can be diagnosed only through endoscopy or exploratory laparotomy or at necropsy. Impacted oviducts may contain obvious egg material, gray or yellow purulent material, calcareous deposits or albumen. Diffuse peritonitis with adhesions can also occur with oviduct impactions. Treatment consists of parenteral antibiotics and in most cases, surgery to clean, repair or remove necrotic portions of the oviduct.<sup>3,66</sup>

## Oophoritis

The ovary can reflect the general health of a mature hen because many infectious diseases and physiologic abnormalities cause retrogressive changes in this organ.<sup>127</sup> Endoscopic evaluation of the female reproductive tract should include the ovum as well as the ovary. The normal ovary with mature follicles has yellow, turgid ova (Color 29.21). When diseased, the ovum can be wrinkled, black, enlarged, firm or hemorrhagic. In addition, abnormal yolk may appear coagulated or “cooked” and flake off onto the ovary or into the abdominal cavity.<sup>155</sup> Adhesions may exist between follicles and the follicles may be slightly stalked.<sup>159</sup> Pullorum disease of domestic fowl is characterized by discolored, pedunculated and inspissated ova. Other bacteremias may cause congestion, distortion and atresia of the follicles.<sup>132</sup> Peritonitis commonly occurs with oophoritis.

Clinical signs of oophoritis include depression, anorexia, chronic wasting and sudden death. Therapy includes supportive care and parenteral antimicrobial agents as dictated by the etiologic agent.

## Parasites

Eggs may contain adult ascarids that probably enter the oviduct from the cloaca due to reverse peristalsis.<sup>74</sup> Flukes (*Prosthogonimus ovatus* and related trematodes) inhabit the oviduct of Anseriformes and Galliformes. Heavy infections may cause soft-shelled or shell-less eggs, resulting in salpingitis.<sup>87</sup> Adult flukes less than 1 cm long may be passed in the eggs. Prevention involves the control of aquatic snails and dragonflies that serve as intermediate hosts.


## Cloacal Problems

Cloacitis, cloacal strictures, cloacal liths and chronic prolapse of the cloaca can interfere with egg laying and copulation (Figure 29.12). These conditions may in turn result from traumatic egg laying. The cloaca may become chronically impacted with an egg, resulting in severe cloacitis and abdominal adhesions.<sup>84</sup> Feathers, fat and abdominal lipomas may occlude the vent, inhibiting reproductive ability.<sup>139</sup> Both medical and surgical approaches are helpful in treating cloacal problems (see Chapter 19). It is interesting to note that the cloaca prolapses normally in the Vasa Parrot during the breeding season.

In some cases, cloacal papillomas may interfere with copulation and semen transport (see Color 19). Pain-

ful lesions in the cloaca may also discourage individuals from mating; however, healthy chicks can be produced by breeding pairs of psittacine birds where one or both adults have mild to moderate cloacal papillomatosis.<sup>107</sup> The etiology of these lesions is unknown and it is recommended to exclude birds with this condition from a breeding aviary. Affected birds in a collection should be isolated from unaffected birds. Affected parents may or may not produce affected offspring, but regardless, chicks from affected parents should be hand-raised in isolation. Results from various treatment regimes for cloacal papillomatosis vary.<sup>139,180</sup> A diet low in fat and high in fresh fruit and vegetables with high vitamin A or beta carotene was considered useful in resolving cloacal papillomatosis and cloacal adhesions in one case.<sup>178</sup>

Cystic ova (reported in budgerigars, canaries and pheasants) may be single or multiple and may be noted during laparoscopy in apparently healthy psittacine hens (Color 29.22).<sup>66,84</sup> Ovarian tumors and cystic hyperplasia of the oviduct can occur secondarily.<sup>14,66</sup> The etiology of this condition and its clinical importance are unknown, but a primary endocrine disturbance is suspected because this lesion is frequently associated with hyperostosis.<sup>6</sup> In affected birds, dyspnea, altered movement and diffuse distention (ascites) of the abdomen are common.<sup>132</sup> Although not always palpable, abnormal ova may be firm, soft, fluctuating or pedunculated. Cysts may rupture, so palpation should proceed carefully. Radiographs may show a diffuse soft tissue density near the cranial lobe of the left kidney. Endoscopically, the ovary may be enlarged with many thin-walled cysts full of straw-colored fluid. Respiratory distress may be eliminated by transabdominally aspirating cystic



**FIG 29.12** Voluminous stools are common in hens that are preparing to lay or that are incubating a clutch of eggs. Similar quantities of feces may be produced by birds with cloacal pathology that interferes with the normal passage of excrement.

fluid with a needle and syringe.<sup>132</sup> Cystic ovaries were successfully treated in two budgerigars with oral testosterone.<sup>14</sup> Removal of the ovaries, although technically difficult, may be the only long-term treatment.

### ■ Cystic Hyperplasia of the Oviduct

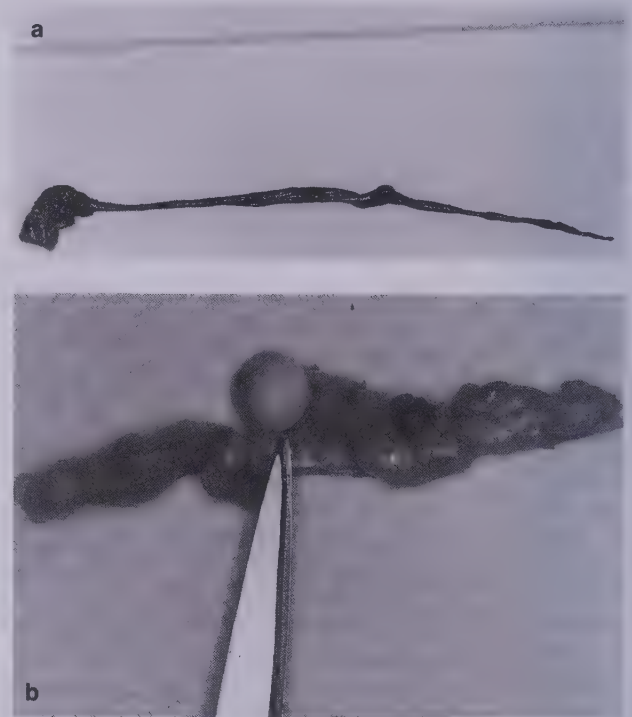
Most reports of cystic hyperplasia of the oviduct are in budgerigars and domestic fowl.<sup>14</sup> The entire oviduct is dilated with a white or brown mucoid fluid, white or creamy masses or occasionally secondary cysts (Figure 29.13). Cysts also can occur secondary to improper formation of the left oviduct (possible degeneration during embryonic development) or from adhered lips of the infundibulum.<sup>127</sup> The ovary in affected hens may also have cystic changes suggesting an endocrine abnormality. Progressive abdominal distention, ascites and respiratory distress are the most common clinical changes. Palpation and radiographs may reveal the distended oviduct. Abdominal paracentesis may be attempted either for diagnosis or for relief of respiratory distress. Laparotomy will provide a conclusive diagnosis. Hormonal therapy with testosterone may prove effective in resolving the immediate problem, but a hysterectomy may be necessary to prevent future problems.

If a rudimentary right oviduct (or ovary) exists, it may also become cystic (Color 29.20).<sup>86,127</sup> Cysts are of walnut size, contain watery or milky fluid and are situated near the cloaca in domestic fowl.<sup>119</sup> Small cysts may go undetected, but large cysts may place pressure on abdominal organs. Egg binding has occurred secondary to a fully developed right oviduct in a budgerigar.<sup>72</sup> The hen was depressed and thin and had a distended abdomen. Successful bilateral hysterectomies were performed to remove the egg-filled left oviduct and the right oviduct that contained a walnut-sized cyst with gelatinous fluid.

### ■ Neoplasia

In one study, neoplasia of the reproductive tract accounted for up to 4.3% of all reproductive disorders.<sup>84</sup> Budgerigars often have neoplasia in the ovary or oviduct.<sup>14</sup> Ovarian neoplasia has been reported less frequently in other Psittaciformes. Ovarian and oviduct neoplasia occur more commonly in gallinaceous birds<sup>155,159</sup> and occasionally in waterfowl and have been reported in a free-ranging Great Tit and a Mauritius Kestrel.<sup>31,120</sup>

Presenting signs are similar to those seen with cystic ovaries or oviduct impactions.<sup>66</sup> In small birds, ascites



**FIG 29.13** a) Normal oviduct from a cockatiel (cranial is to the left) b) and an oviduct from a hen filled with creamy masses and a mummified egg.

and peritonitis can produce clinical changes similar to those associated with reproductive neoplasias. Ovarian tumors can be very large and represent up to one-third of the body weight. Egg retention,<sup>141</sup> concurrent cysts,<sup>6</sup> ascites and herniation are common sequelae to reproductive tract neoplasias. Changes in secondary sex characteristics (cere color change in the budgerigar) may also occur. Radiographs can be helpful, although an enlarged ovary or oviduct creates an image similar to that seen when uncalcified eggs are present. A confirmatory diagnosis requires exploratory laparotomy and histopathologic examination of biopsy samples. Lymphomatosis is suggested by cauliflower-like growths of the ovary in domestic fowl.<sup>119</sup> A variety of other tumor types have been reported including adenocarcinomas, leiomyomas, leiomyosarcomas, adenomas<sup>119</sup> and granulosa cell tumors. Excisional surgery is the traditional therapy, although prognosis for long-term recovery is poor.

### ■ Ectopic Eggs and Non-septic Peritonitis

Egg material may gain access to the abdomen through ectopic ovulation and discontinuous or ruptured oviducts (Color 29.25). Ectopic ovulation occurs when the infundibulum fails to engulf an ovum. It

may be caused by reverse peristalsis of the oviduct, which occurs during normal egg laying, or by trauma to the oviduct that interferes with normal function.<sup>141</sup> Restraining or stressing a hen during egg laying has been incriminated as a cause of ectopic ovulation.<sup>132</sup> Ectopic ovulation is thought to occur frequently, and in one study it was the most common reproductive disorder (28.6%) described in necropsy specimens from nine avian orders.<sup>84</sup> Peritonitis may or may not develop from ectopic ovulation. If present, it can occur in either a septic or non-septic form. Yolk itself only causes a mild histiocytic response and if free of pathogens will gradually be reabsorbed by the peritoneum.<sup>102</sup>

Depending on the location of rents in the oviduct, completely or partially shelled eggs may be deposited in the abdomen. Ruptured oviducts can result from acute and chronic oviduct impaction, including egg binding, cystic hyperplasia, neoplasia and salpingitis. Large, misshapen eggs may cause uterine disintegration and rupture resulting in ectopic eggs.<sup>182</sup>

Ectopic eggs have been reported in Passeriformes and Psittaciformes.<sup>141</sup> Uncomplicated ectopic ovulation may go unnoticed for a protracted period of time. Abdominal distension, a penguin-like stance and weight loss may be the only clinical changes. Free yolk in the abdomen may be absorbed and systemic antibiotics may be needed until the abdomen clears itself of yolk. The condition may recur if predisposing factors are still present. Excessive accumulations of egg material or fully formed eggs should be removed surgically. Damaged oviduct tissue should be repaired or removed.

Cockatiel hens with a history of egg laying frequently present with gradual weight loss, intermittent depression and ascites. If the abdominal fluid is sterile (rules out septic peritonitis), these birds will frequently respond to therapy that includes dexamethasone and medroxyprogesterone acetate.<sup>140</sup> The dose of medroxyprogesterone varies with the size of the bird (150 g [0.05 mg/g]; 150 to 300 g [0.04 mg/g]; 300-700 g [0.03 mg/g]; 700 g [0.025 mg/g]; Umbrella Cockatoo [0.018 mg/g]). Some hens may not cease egg laying activity with the administration of medroxyprogesterone alone and require administration of testosterone as well (Harrison GJ, unpublished). Scientific investigations are necessary to determine the pathogenesis of ascites in these hens and what role the empirically derived therapeutic regime plays in resolving this problem.

### ■ Egg-related Septic Peritonitis

Peritonitis is the most frequent cause of death associated with reproductive disorders.<sup>84</sup> It may not be a single disease but part of several syndromes, including ectopic ovulation, ruptured oviducts and salpingitis. It is theorized that it may be the cause instead of the result of a ruptured oviduct.<sup>14</sup> It is uncertain which component of the egg is most important in inducing peritonitis but it is likely to be the yolk that is secondarily contaminated with bacteria. Frequently, hens that have been hysterectomized behave as if they have ovulated but do not develop egg-related peritonitis. Experimentally, egg yolks from other hens can be placed near the infundibulum of a laying hen and the yolk will be delivered normally. Peritonitis was never induced by the yolk (Ringer RK, unpublished). In another study, 87% of hens with ectopic ovulation also had egg-related peritonitis (Color 29.28).<sup>84</sup> In domestic fowl, fatal peritonitis can occur alone.<sup>129</sup> The peritoneum is commonly congested and edematous and appears lusterless; adhesions may be present. Peritonitis appears to be described most frequently in cockatiels, budgerigars, lovebirds, ducks and macaws.<sup>141</sup>

Presenting clinical signs include sudden death, abdominal swelling, respiratory distress, depression, anorexia and cessation of reproduction. The hemogram may show a severe inflammatory response. Radiology, abdominocentesis and laparotomy are helpful diagnostic aids. Septic peritonitis leading to severe debilitation, sepsis and death can occur if the yolk is contaminated with bacteria. Egg yolk in the peritoneal cavity is thought to be a predisposing factor to septic peritonitis.<sup>156</sup> Turbid yellow, green or brown yolk fluid or cheese-like yellowish masses of inspissated yolk material in the abdomen are indications of ectopic ovulation or a ruptured oviduct. Peritonitis may lead to secondary infection of other abdominal organs, and in advanced cases, extensive adhesions may form in the abdomen. Egg-related pancreatitis may cause temporary diabetes mellitus, especially in cockatiels.<sup>141</sup> A temporary stroke-like syndrome has been described in cockatiels with yolk peritonitis, possibly due to yolk emboli. Aspirin may be used as an anticoagulant in cases where yolk emboli are suspected (1 tablet/30 cc water, 0.5 cc/kg PO TID). The etiologic agent of egg-related peritonitis is often coliforms, especially *E. coli*.<sup>129</sup> In cockatiels, *Yersinia pseudotuberculosis* and *Staphylococcus* spp. have also been reported in association with egg-related peritonitis.<sup>84</sup>

Treatment consists of antibiotics, steroids to reduce inflammation and supportive care (heat, fluids, nutritional supplements). Long-term antibiotic therapy may be necessary and diet correction is advised. Most cases resolve with medical therapy alone, but early diagnosis is essential. If surgery is required to remove egg material or perform abdominal irrigation, the patient should be stabilized first with supportive care and antibiotics.

### ■ Chronic Egg Laying

Chronic egg laying occurs when a hen lays eggs beyond the normal clutch size or has repeated clutches regardless of the existence of a suitable mate or breeding season. Humans, inanimate objects (stuffed animals, enclosure toys) or birds of another species may act as substitute mates and stimulate excessive egg laying. This problem is particularly common in hand-raised hens that are imprinted on humans. The chronically reproductively active female may exhibit weight loss from constant regurgitation and feather loss or mild dermatitis around the cloaca in association with masturbatory behavior. Removing eggs from the hen effectively induces a form of double clutching and can facilitate the problem. The continuation of egg laying is ultimately hormonally controlled. The most domesticated psittacine birds, cockatiels, lovebirds and budgerigars, are notorious chronic egg layers. Perhaps the high incidence of problems in these species indicates a lack of hormonal balance in controlling egg laying that has occurred due to selective pressures designed to make birds produce continually in a variety of environmental situations.

Hens on a completely nutritious diet can continuously lay eggs for years without deleterious effects. In most cases, however, malnutrition and the progressive stress and physiologic demands of egg laying ultimately will compromise the hen. Calcium deficits lead to abnormal egg production, reduced oviduct inertia and generalized muscular weakness. Egg binding is common in hens that chronically lay eggs. Behavior modification can be attempted to stop the laying cycle (see Chapter 4). The stronger the environmental stimulus to cease egg laying activity, the better. Diminishing exposure to light to only eight to ten hours a day should interrupt the hormonal cycle, and egg laying should cease. Objects stimulating masturbatory behavior or sexually oriented regurgitation should be removed, although many birds will continue reproductive behavior despite this environmental change. Nest boxes and possibly enclosure

mates should be removed. Changing the location of the enclosure may also be helpful. Owners may discourage reproductive behavior by decreasing the amount of time spent with a hen until egg laying ceases.

Medical therapy is designed to correct any nutritional imbalances or reproductive tract abnormalities. Mineral and vitamin supplements should be given parenterally and added to the diet. Caloric intake with adequate protein levels should be increased. Medroxyprogesterone injections can be used to interrupt the ovulatory cycle. Depression, polyuria, weight gain, liver damage, immunosuppression and occasionally diabetes mellitus (especially in cockatiels) can occur with use of medroxyprogesterone. Egg laying may be stopped from two weeks to several months following therapy and repeat injections are often necessary. Some patients experience no problems, while others experience continual or permanent side effects. Dangerous spikes in drug concentrations can be prevented by implanting a progesterone pellet that allows for continual drug delivery.<sup>61</sup> Despite behavioral and medical therapy, affected hens may continue to lay eggs. The long-term solution in these cases is a salpingohysterectomy (see Chapter 41).

### ■ Over-production

Maximal safe levels of egg production and chick care have not been determined for companion bird species. Dietary and environmental conditions in different aviaries would be a factor in determining safe production levels. Free-ranging psittacine hens may produce only one, at the most two, clutches per year. Egg production in excess of two clutches a year would thus be considered unnatural. Many captive psittacine birds (particularly Blue and Gold Macaws, cockatoos and Eclectus Parrots) routinely produce four clutches of eggs per year with no apparent side effects; however, continued levels of unnatural clutch production may lead to reproductive tract disease or other disorders precipitated by poor body condition. Over-producing hens may be thin and in poor feather condition, have poor muscular tone and be unable to quickly involute the uterus after egg laying has stopped. To ensure the long-term health of a reproductively active hen, egg production should be limited to two clutches a year in birds exhibiting medical problems secondary to excessive egg production.



### Anatomic Abnormalities

Congenital atresia of the oviduct has been described in domestic fowl and is one of the causes of egg-related peritonitis. Oviduct discontinuity can occur due to degeneration of part of the Muellerian duct during embryonic development.

Normally, only the left ovary is present in birds, except in Falconiformes and Kiwis,<sup>86</sup> where both ovaries are frequently present.<sup>84</sup> Persistence of the right ovary has been reported in corvidae, ducks, swans, a Funereal Cockatoo, owls and grouse without mention of the presence of a right oviduct.<sup>84,86</sup> The author has repeatedly seen right ovaries in young macaws and cockatoos and once in a mature Golden Conure, all without evidence of a functional right oviduct. In these birds, the right ovary appeared vestigial as has been reported in other cockatoos and owls.<sup>84</sup> A right ovary and oviduct were present at necropsy in a mature Scarlet Macaw that died from complications of egg impaction in the left oviduct (Color 29.20) (Ritchie BW, unpublished). In domestic fowl, about 90% of enlarged right ovaries are the result of damage to the left ovary. Occasionally, fertile eggs can result from ovulatory activity from the right ovary.<sup>86</sup>

All early embryos have bilateral oviducts. After the first trimester of incubation, growth of the right oviduct appears to be inhibited. Persistent right oviducts without right ovaries (although they could have been rudimentary and overlooked) have been described in penguins and budgerigars.<sup>72,84</sup> Right oviducts, occasionally paired with right ovaries and oviductal orifices, have been reported in domestic fowl.<sup>151</sup> The incidence is highest in inbred strains, probably due to hormonal imbalances or abnormal genes that affect growth and differentiation of the Muellerian duct.<sup>113</sup> Functional right oviducts have been reported in the domestic fowl, occasionally associated with cystic changes.<sup>86,119,127,151</sup> A fully developed cystic right oviduct has also been observed in a budgerigar. Some domestic fowl with bilateral reproductive tracts can lay two eggs a day, and this unusual condition has also been reported in a duck. A functional-appearing right oviduct that is not altering the health of a companion bird can remain intact.

### Abnormal Eggs

Dietary problems, environmental factors and reproductive tract abnormalities can all result in the production of abnormal eggs. Soft-shelled eggs may be an incidental occurrence or may indicate an underlying

ing nutritional or medical disorder. Nutritional deficiencies of calcium and vitamins A and D<sub>3</sub> have been associated with soft-shelled eggs. Therapy consists of both parenteral and oral nutritional supplements.

Oviduct pathology may also cause abnormal egg production. Suggestive abnormalities include thin-shelled eggs, irregular external calcium deposits, or overly thick-shelled eggs. Uterine infections may cause rough-shelled eggs, which can be corrected by flushing the uterus with appropriate antibiotics (Harrison GJ, unpublished). Organochloride pesticides (DDE) cause egg shell thinning by inhibiting deposition of calcium by the shell gland.<sup>30,126,131</sup> Contaminated free-ranging birds in captive breeding projects may have reproductive abnormalities for many years due to the residual activity of these poisons and the long-term storage of these chemicals in body fat.

Domestically bred birds may be exposed to chemical toxins that may cause abnormal eggs through contaminated feed and agricultural spraying. In fact, it is legal to divert contaminated feeds from human food production into food used for animals, directly or by dilution, if the process of manufacturing or cooking will deplete the pesticide to "safe" levels.<sup>50</sup>

Metritis, ectopic ovulation and ovarian disease may cause yolkless, small or sterile eggs that appear grossly normal. Inconsistent transient times of the egg passing through the oviduct may cause abnormally sized eggs due to deposition of differing amounts of albumen. A slow passage time of a preceding egg may allow for double ovulation to occur and result in a double-yolked egg.<sup>62</sup> This occurs with some frequency in domestic fowl but has also been observed in psittacine birds. The problem is usually self-limiting. Hatchability is decreased in moderately abnormal eggs, but these eggs may still produce normal chicks.

Blood clots (meat spots) are described in poultry eggs in association with hemorrhage at ovulation or at other locations in the reproductive tract (Color 29.2). Shell color, yolk color and the odor of an egg can be influenced by diet, hereditary factors and microbial contamination. Some drugs and environmental toxins may cause abnormal egg production, resulting in early embryonic death or weak chicks. Examples include crude oil, exhaust fumes, nicotine, chlorinated hydrocarbons and certain antibiotics (furozolidone).<sup>121</sup>

## Male Reproductive Disorders

---

### ■ Toxins

Numerous toxins can affect spermatogenesis in mammals. Reduced spermatogenesis has been reported in Japanese quail exposed to mercury.<sup>174</sup> Copper fungicides in feed have been found to suppress spermatogenesis and induce testicular atrophy.<sup>148</sup> Cystic testicular degeneration occurs in ducklings given feed with furazolidone.<sup>185</sup>

### ■ Anatomical Abnormalities

Cyclic seasonal testicular atrophy occurs in many species (up to 500-fold in Passeriformes). Following the correct environmental stimuli, the testicles can undergo hypertrophy in preparation for breeding. Because of the seasonal change in testicular size, pathologic cases of atrophy can be difficult to diagnose (see Color 25). Serial laparotomies may be indicated to evaluate changes in testicular size. Testicular atrophy can be caused by orchitis as a result of trauma or genital infection or can be due to progressive infertility. Malnutrition, toxicity or bacteremia may also cause testicular degeneration. Affected birds may demonstrate a lack of libido or be infertile. Therapy is limited to addressing infectious or behavioral problems. If fibrotic or infiltrative changes have occurred, spermatogenesis may be permanently altered.

Testes can be abnormally joined at their anterior ends, which may not prevent spermatogenesis.<sup>119</sup> Testicular hypoplasia may be attributable to congenital or hereditary conditions. Similarly, true agenesis may occur, causing parts of the genital tract to be absent (monorchidism).

### ■ Orchitis

A variety of bacteria can cause orchitis in birds, including *E. coli*, *Salmonella* spp. and *Pasteurella multocida*.<sup>132</sup> Infections may originate from prolapsed or ulcerated phalli, renal obstruction, cloacitis and septicemia. Clinical signs are similar to those expected for any generalized infection. Antibiotics

may be helpful in resolving the active infection but may not prevent or reverse infertility.

### ■ Neoplasia

Testicular tumors commonly occur in older budgerigars but can also be found in larger Psittaciformes and other birds.<sup>14</sup> A seminoma of the testes was reported in a Collared Turtle Dove<sup>133</sup> with progressive emaciation for several months before death. The author diagnosed a seminoma in an Eclectus Parrot that died suddenly with an enlarged left testicle that occupied much of the left peritoneal cavity (see Figure 29.5). The surface of the testicle was smooth, which is typical of primary tumors. This bird had a long history of aggressive behavior (atypical for the species) toward numerous hens. It was theorized that hormonal imbalances associated with this tumor were responsible for the behavioral changes.

Sertoli and interstitial cell tumors have been described in birds (see Chapter 25).<sup>47</sup> Lymphoproliferative diseases, such as leukosis, can also affect the testes resulting in infertility.<sup>99</sup> Regardless of the tumor type, testicular neoplasias can involve one or both testes. Unilateral paresis, progressive weight loss and abdominal enlargement are typical clinical signs. Affected birds may have reduced secondary sex characteristics and become more feminine in nature (cere of the male budgerigar turning from a blue to brown color). Metastasis from testicular tumors usually affects the liver.<sup>14</sup> Surgery may be successful if the tumor is easily approached and unilateral and the cock is in good health. Long-term prognosis is guarded due to the possibility of metastasis.

### ■ Phallic Prolapse

Birds with large phalli may develop partial or complete prolapses, which are frequently secondary to trauma, infection or extreme weather fluctuations.<sup>69</sup> Infections may be secondary to mucosal irritation (over-exuberant mating or vent sexing) or fecal contamination. The phallus may become enlarged and ulcerated. In geese, *Neisseria* spp. have been isolated from erosions of the phallus, oviduct and cloaca and are believed to be sexually transmitted.<sup>118</sup> Occasionally, a prolapsed phallus will revert preventing evaluation of secondary infections. In severe cases of phallic prolapse, the birds may be severely depressed, anorectic and disinterested in copulation. Permanent infertility is a common sequela. In ostriches, frostbite and necrotizing dermatitis may occur secondary to a prolapse.



**FIG 29.14** Environmental factors that would make a pair of birds feel insecure should always be considered when evaluating a lack of breeding success. The design and location of the nest box, enclosure and aviary are all critical factors to consider. This male Sulphur-crested Cockatoo with fertile eggs was eliciting proper nest box defense behavior in response to an intruder.

Exposed tissue should be thoroughly cleaned with a sterile saline solution, carefully debrided and covered with antibiotic cream. Topical DMSO may help reduce swelling, making replacement of the phallus easier and more permanent. Daily therapy and cloacal mattress suture may be necessary to prevent recurring prolapses (see Chapter 41). Systemic antibiotics should be considered due to the possibility of ascending urogenital infections. If large areas of necrosis are present, then surgery is necessary to debride the wound. Nodular ejaculatory papillae have been described as abnormal in pigeons.<sup>11</sup>

### Behavioral Abnormalities

Reproductively active males and females (particularly budgerigars and cockatiels) may exhibit masturbatory behavior or excessive regurgitation. These are normal reproductive behaviors that may become pathologic in birds that are isolated. Cockatiel cocks incubate the eggs, and a single male may spend much of the time on the enclosure floor mimicking incubation activities. Removing the bird from its enclosure for long periods of time (with available food and water sources) or changing the enclosure or enclosure

location may stop this behavior. In other cases, displaced reproductive behavior may occur in males housed with females. In these cases, the male is often “imprinted” on humans and cannot complete the reproductive cycle with its own species. Exchanging mates may prove helpful, but usually these males should be removed from the breeding program. Human imprinting can also occur in females, and in both genders behavioral abnormalities due to improper imprinting may not be obvious. Indeed, lack of pair-bonding, lack of egg production or infertility may be the only signs associated with the use of hand-raised imprinted birds in a breeding program. The interaction of a chick with its parents and nesting conditions may be critical for successful reproduction in some species (see Chapter 4).

### Under-production

Establishing the existing level of production is the first step to managing a breeding pair. This includes calculating levels of fertility, hatchability and chick fledging rates. Average clutch sizes have been reported for many species of birds;<sup>4,43</sup> unfortunately, clutch size can vary among individuals and within genera. Under-production is particularly important with endangered species where maximum production is critical to ensure the survival of the species.

If production from a breeding pair does not approach the average, then medical, physical or behavior problems should be addressed. Correction of any medical or physical abnormalities, such as clipping overgrown feathers near the cloaca, dieting overweight birds or treating birds for localized infections can be instituted. The diet should be carefully analyzed and any deficiencies should be corrected. Environmental deterrents to breeding may be determined by using a video camera to observe the pair’s daily behavioral patterns. Some changes that may be necessary include re-pairing birds, improved enclosures, different nest boxes, varied diet, altered climate, different lighting or reducing aviary disturbances induced by humans, other birds or vermin (Figure 29.14).

Endocrine manipulation for improving reproductive success in birds has been studied with marginal success. The dependence of the avian endocrine system on environmental stimuli makes clinical manipulation of the avian reproductive system difficult. Specific behavioral manifestations of endocrine abnormalities have been treated medically, such as testosterone injections in timid male *Eclectus Par-*

rots, but such therapy is experimental in nature and long-term use can cause testicular atrophy.

Testosterone has been suggested to induce singing in male canaries but can cause serious side effects. Male canaries that do not sing are usually sick or malnourished. PMSG (gonadotrophin serum) administered to canary hens induced defeathering and vascularity of the brood patch and accelerated reproductive tract development with accompanying increased incidences of egg binding and oviposition on the enclosure floor.<sup>164</sup> In another study, PMSG administration stimulated reproductive activity in birds maintained in both long and short daylight cycles.<sup>163</sup>

Birds that consistently fail to produce should be removed from the breeding program.

## Artificial Insemination

Artificial insemination (AI) has been used successfully in cranes, cassowaries, raptors, gamebirds, Anseriformes, Columbiformes, Galliformes and some psittacine species, including budgerigars, a cockatiel and Hispaniolan Amazon Parrots.<sup>45,60,146</sup> This technique may be beneficial in endangered species, especially when a limited number of individuals of a species is available. Problems with incompatible pairs, poor fertility due to physical or behavioral difficulties and large distances between individuals housed at different breeding facilities may be resolved using AI.

### Collection Technique

Successful collection techniques include cooperation, massage and electroejaculation. Cooperative AI requires human-imprinted males that are encouraged to copulate and deposit semen in or on a suitable receptacle.<sup>16</sup> This technique is extensively used in raptor breeding.<sup>173,184</sup> Using imprinted birds requires a tremendous amount of time and effort and may not be possible in all species.<sup>17</sup> Semen may also be collected during or after natural copulation or through the use of dummy mounting devices and artificial vaginas.<sup>11</sup> Semen collected with these techniques is usually free from contamination.

The massage collection technique requires two people, one to restrain the bird and the other to collect the semen. The inner thigh, ventral abdomen, tail, vent and synsacral area are stroked. The tail is positioned dorsally and with continued stroking pressure is placed laterally on the cloaca to encourage ejaculation. Even without ejaculation, semen can be expressed from the cloacal region with this technique. Contaminated semen samples often contain feces and urine and should be discarded. Contamination can be reduced by fasting the birds and evacuating the cloaca before semen collection. Visualization of semen volumes in small Psittaciformes can be augmented using a strong light source. Massage has been used successfully in poultry, Casuariiformes, Anseriformes, Columbiformes, Falconiformes, Gruiformes, Passeriformes and Psittaciformes including budgerigars, Hispaniolan Amazon Parrots, Maroon-bellied Conures and Monk Parakeets.<sup>11,21,45,78,147</sup>

Five to fifteen  $\mu$ l of semen could be artificially collected from budgerigars twice weekly using a modified massage technique where the semen is collected by simply applying pressure on both sides of the cloaca to empty the contents of the seminal glomus. Hispaniolan Amazon Parrot males were collected three times a week during the months corresponding with the natural breeding season although semen yields remained high in one individual for several months after the normal breeding season. In Hispaniolan Amazon Parrots, paired and unpaired males yielded statistically similar semen volumes, sperm motility and sperm concentrations. Collection of semen from males paired with reproductively active hens did not affect their breeding performance.

Electroejaculation under anesthesia is not a common method for collecting avian semen although it has been successfully used with a variety of birds including waterfowl, domestic fowl,<sup>91</sup> psittacine birds<sup>58</sup> and pigeons.<sup>11</sup> Electroejaculation may cause semen samples to be expelled with feces and urine.<sup>11</sup> This technique, however, can be attempted if massage and cooperative techniques fail. Electroejaculation was successful in 95% of mature pigeons when used in conjunction with a cloacal retractor.<sup>10</sup> A combination of massage and electrostimulation was used to collect semen from macaws, cockatiels and Amazon parrots.<sup>58</sup>

The volume and sperm concentration of semen varies among species (see Table 29.3).<sup>45</sup> Semen volume can be increased by multiple collections in a week. Excessively frequent collection can cause cloacal irritation, swelling and hyperemia of the vent. Adding diluent

to the semen may help preserve sperm viability in low-volume samples.<sup>45</sup> Semen should be evaluated before and after any storage or preservation and before insemination. The phallus, anal gland secretions, urine, feces and transparent fluid can all interfere with semen collection and viability.

Higher fertility levels are achieved when semen is used for insemination immediately following collection. Uncontaminated semen in chickens can be stored for 1.5 days and still result in 37% fertility.<sup>95</sup> Short-term storage requires temperatures near freezing and protection from drying and contamination. Diluents should be used when semen is stored for more than one hour. Commercially available poultry diluents have been used successfully in non-domestic species.<sup>21,78</sup> Long-term semen storage requires cryopreservation using either glycerol or dimethylsulfoxide (DMSO) as a cryoprotectant. Glycerol must be removed prior to insemination using dialysis. Frozen-thawed semen has proven to be viable in Sandhill Cranes, American Kestrels, Peregrine Falcons and budgerigars.<sup>20,124,146,152</sup> Modifications in cryopreservation methods and fluids may be necessary when handling semen of other avian species.

### Insemination Technique

Cooperative techniques may be used to inseminate females that are encouraged to respond to handlers allowing semen to be deposited in the cloaca or oviduct.<sup>184</sup> Massage techniques involve manual stimulation, eversion of the cloaca and placement of the semen via a tube, straw or catheter through the cloaca into the vagina. Anatomical structures can be better visualized using speculums and specially designed cloacal retractors.<sup>10</sup> Deep vaginal insemination results in the best fertility levels; however, with frequent and timely inseminations fertile eggs can occur when semen is deposited in the cloaca.

Fertile eggs were produced by budgerigar hens using five to ten  $\mu$ l of fresh semen or 40  $\mu$ l of frozen-thawed dialyzed semen placed by cannula into the oviduct two hours post-oviposition. Determining when to inseminate is crucial for fertilization to occur. It is best to inseminate every other day after the first egg in a clutch is laid or after each egg is laid.<sup>184</sup> The frequency of insemination is governed by the species, sperm concentration, durability of the sperm, method of insemination and ovulation patterns. Hispaniolan Amazon Parrots were successfully inseminated before egg laying started but fertile eggs were not laid until insemination procedures were discontinued.

Initiating egg laying usually requires behavioral stimulation provided by the presence of a mate. Female budgerigars were successfully inseminated only after they began laying when stimulated by the presence of a vasectomized male.<sup>146</sup> Vasectomized cocks show normal male sexual behavior, including courtship and copulation. Hispaniolan Amazon Parrot hens begin egg laying when housed separately but adjacent to males.

## Non-disease Factors Affecting Reproduction

### Gender

The most common cause of reproductive failure in companion birds is pairing of two birds of the same gender. Several techniques for determining the gender of birds have been described. The appropriate method to use depends on the species, age of the bird and the information to be derived from the procedure.

### Physical Characteristics

Many species of birds are sexually dimorphic, with visual characteristics that distinguish males from females. The degree of dimorphism varies with species and may not always be obvious. Even with monomorphic species, subtle differences may exist that allow determination of gender. With most monomorphic species, definitive gender differentiation requires laboratory or laparoscopic procedures.

With birds of prey, the female is generally 30% larger than the male, although some size overlap occurs in the intermediate weight ranges.<sup>188</sup> In other groups of birds, the male is generally heavier and has a larger frame than the female. Head size as well as bill breadth, length and depth are often greater in males. Differences in beak size are usually obvious in toucans but may require calipers to appreciate in smaller species. The majority of psittacine birds are monomorphic although there are many exceptions (Table 29.4).

In dimorphic birds, feather color, iris color and bill characteristics typically differentiate hens from cocks.<sup>43,64,101,158,167</sup> These secondary sexual characteristics become more obvious as birds reach reproductive maturity. Immature birds typically have

color patterns similar to adult females. Feather shape and length may also be different. For instance, male Racket-tailed Parrots have much longer central retrices than females, and male Princess Parrots have a spatula extension at the end of the ninth primary feather. In general, red to brown iris color is more common in female cockatoos; however, this technique is not always reliable, especially in Moluccan, Rose-breasted, Bare-eyed, Goffin and immature cockatoos. At maturity, wild-type (green) male budgerigars have lavender to dark-blue ceres while females have light-blue to tan or brown ceres. Gender determination based on cere color may not be effective in inbred color mutations. The White-fronted Amazon is clearly sexually dimorphic. Males have numerous red secondary wing coverts while females have few to none.

### Vent Sexing

Gender can be determined in most Galliformes, Anseriformes, some game birds, ratites and some species of Cracidae by looking for the phallus on the wall of the cloaca. In Columbiformes and Passeriformes, which have prominent papillae of the ductus deferens, gender can be determined if these structures can be visualized using general anesthesia and a cloacal protractor.<sup>10</sup> The clitoris is located at the same location as the phallus, and differentiating the phallus from the clitoris can be difficult in chicks and immature cocks (see Chapters 46 and 48).

Determining the distance between the pelvic bones (gapped in females, close together in males) has been discussed as a method of gender determination. The distance between the pelvic bones increases in post-ovipositional females but may narrow considerably in the months following oviposition. In larger psittacine birds, this is an unreliable method of gender determination. Some practitioners feel that this is a reliable method for gender determination in mature lovebirds.

### Behavioral Characteristics

Behavioral characteristics generally vary with gender; however, birds can develop homosexual pair bonds with one bird behaving more like a hen than the other. Males are generally more aggressive and are responsible for territorial defense. The songs of the male finch, canary and cockatiel differentiate them from females. With some free-ranging psittacine species, the hen incubates while the male is perched nearby as a sentry. Depending on the cycle of incubation and the age of chicks, the hen may join the male in inter- and intraspecific territorial confronta-

tions. In cockatiels and some other species of psittacines, the male shares in incubation duties.

Observing copulation in species in which the male completely mounts the female may indicate a successful pair bonding. Complete mounting is typical of raptors, waterfowl and Passeriformes. In New World Psittaciformes, copulation occurs side by side, and homosexual pairs have been observed precisely mimicking this procedure. The male usually places one foot on the caudal tail region of the female and has the more dorsally placed tail during cloacal contact. It is theorized that females exhibiting masturbatory or courtship behavior with inanimate objects, other species of birds or humans will often lay eggs. If no eggs are produced, it may indicate that the bird is a cock, but some masturbating hens have been known to wait twelve years after the onset of this behavior before laying an egg.

### Laparoscopic Sexing

Although subject to error when used in young birds with undifferentiated gonads, laparoscopic examination is a definitive method of gender determination when performed by an experienced practitioner (see Chapter 13). Its major advantage over other gender determination techniques is that it allows for direct inspection of abdominal structures, especially reproductive organs, for evidence of disease or dysfunction. Its disadvantage is that it is an invasive procedure that requires anesthesia.

### Laboratory Methods

Genetic determination of gender in birds is considered the most reliable of the available noninvasive techniques. One method employs feather pulp as a source of chromosomes. After culturing, staining and careful examination, the gender chromosomes can be identified in most species. The disadvantage of this technique is the difficulty of collecting an adequate number of growing feathers that will produce a viable culture that is not contaminated. Other problems include overnight mailing and a lag time in obtaining results, as only one laboratory<sup>a</sup> offers this service commercially in the United States.

Determination of gender can also be accomplished by evaluating differences in the DNA composition between males and females. A small volume of red blood cells is necessary for this procedure, and advantages include easy and relatively non-traumatic sample collection and a long sample shelf life without refrigeration. Lag time in obtaining results is a disadvan-

TABLE 29.4 Examples of Sexual Dimorphic Differences in Psittacines\*

Species	Male	Female
Budgerigar	Cere lavender to dark-blue	Cere pink-brown to light-blue
Cockatiel	Lacks barring, bright yellow face and cheek patch	Tail and flight feathers have barring on underside
Malee Ring-necked Parrot, Adelaide Rosella, Red-rumped Parrot, Bourke's Parrot	Lacks barring when mature	Barring on underside of wings
Red-rumped Parrot	Red rump patch	Green rump patch, paler
Scarlet-chested Parrot	Scarlet breast	Green breast
Regent Parrot, Superb Parrot	Yellow feather patches	Green throughout
Princess Parrot	Spatular extension on the end of the ninth primary flight feather, coral beak	Lacks spatular extension, brownish beak
Red-bellied Parrot	Red belly	Scattered red feathers on green belly
King Parrot	Red head feathers	Green head feathers
Red-winged Parrot	Blue crown feathers, bright yellow-green underparts, black shoulder mantle, coral bill, orange-red iris	Duller green feathers, pale-brown iris
Duchess Lorikeet	Red side rump patch	Yellow side rump patch
Fairy Lorikeet	Blue rump patch	Yellow side rump patch
Josephine's Lory	Red lower back	Green lower back
Whiskered Lory	Red face-crown and crown	Green face-crown and crown
<i>Cacatua</i> spp.	Brown to black iris	Red to reddish-brown iris
Eclectus Parrot	Green	Red and purple
Pesquet's Parrot	Red spot behind eye	No red spot
Grey-headed Lovebird	Grey head, neck and breast	Green head, neck and breast
Ring-necked Parakeet	Colored ring around the neck	No ring
Mueller's Parrot	Red beak	White beak
White-fronted Amazon Parrot	Red alula and primary covert feathers	Slight to no red in primary covert feathers
Mountain Parakeet	Yellow forehead, lores, cheeks and throat	Green forehead, lores, cheeks and throat
Mexican Parrotlet	Blue lower rump and underwing coverts	Yellow-green lower rump and underwing coverts
Pileated Parrot	Red forehead	Green forehead
African Grey Parrot	Red vent and rump feathers	Grey tips on red feathers or mostly grey

\* Not all members within a genus will portray the listed sexual differences. One representative species is listed for each genus. Differences are usually observable only in mature species.)

tage, as only one laboratory<sup>b</sup> offers this service in the United States.

Fecal steroid assays have been used to determine gender in birds.<sup>8</sup> Steroid hormone levels including estrogens and androgens (mostly testosterone) are measured by radioimmunoassay, and an estrogen/testosterone ratio is used to estimate the sex of the bird. An individual bird's production of steroid hormones varies with age and sexual activity and leads to some overlap in the estrogen/testosterone ratios. Commercial laboratories<sup>c</sup> claim high accuracy, although no blind studies have been performed to validate the test. One recent report suggests that fecal sex steroid determination in most parrots is not effective, especially in small birds.<sup>7</sup> This technique of gender determination requires that a bird be sexually mature.

### Sexual Maturity

In birds, the female is the heterogametic gender (ZW), and the gender of the embryo is determined prior to ovulation and not at fertilization as occurs in mammals. Males are homogametic (ZZ). Sex differentiation occurs in the developing embryo during the first trimester of development. Secondary sexual characteristics under hormonal control may be obvious before functional sexual maturity is achieved.

The age of sexual maturity varies greatly between species. For example, Zebra Finches and captive Japanese Quail are sexually active by two months of age. By comparison, the Fumar begins breeding at about eight years of age.<sup>86</sup> Many smaller Passeriformes begin breeding in the first or second spring after hatching. In larger Psittaciformes (Amazon parrots, African Grey Parrots, large cockatoos and macaws),

viable eggs can be produced when the birds reach three to six years of age. Pionus and smaller cockatoos and macaws may be sexually mature by two to four years. Lories and lorikeets produce young at two to three years, conures at one and one-half to two years, and budgerigars, lovebirds and cockatiels at six months to one year of age.<sup>107</sup> Initial clutches of eggs may be infertile in young birds due to immaturity of reproductive tissues or reproductive inexperience.

## Environment

### Light

The most important factor for reproductive stimulation of free-ranging birds in mid to high latitudes is day length. Neuroendocrine systems control the annual development of the reproductive system with sufficient precision to assure that young will be produced when trophic resources are optimal. Lengthening photoperiods elevates LH secretion, which is the primary reproductive hormone. The effect of photoperiod on certain species of captive companion birds has been partially studied, and this information may be applicable to other related species.

Female budgerigars have been found to lay eggs when exposed to male vocalizations even when kept in continuous darkness.<sup>71</sup> Male song appears to be a strong factor for successful oviposition, but a dark nest box is also important. Photoperiod can have a direct effect on male vocalizations, which in turn stimulates the female reproductive cycle. In poultry, the onset of sexual maturity is affected by lighting.<sup>40</sup>

### Climate

High environmental temperature combined with high humidity increases the physiological stress on birds and can decrease reproductive activity. An ambient temperature greater than 27°C induces a state of thermal stress in pullets<sup>67</sup> and decreases egg production, feed consumption and feed efficiency. Increases in humidity appear to have less effect on reproductive activity than increases in dry bulb temperature. Temperature extremes have been shown to decrease semen production and cause thinner egg shells. The use of misters in hot weather can alleviate this problem.

Rainfall triggers courtship behavior in male Zebra Finches. Juvenile finches may form pair bonds before the rainy season so that they are ready for breeding when rain occurs. Finches are thought to maintain testicular function throughout the year, making

rapid reproduction post-rainfall possible.<sup>179</sup> Cold temperatures inhibit Zebra Finch reproduction.

### Season

Effects of environmental conditions on reproduction may be similar in captive birds and free-ranging birds; however, heavily domesticated species like canaries, budgerigars and finches react differently than their free-ranging conspecifics.<sup>179</sup> For larger Psittaciformes, insufficient information has been collected to make comparisons between the reproductive characteristics of free-ranging and captive birds. In Central America, free-ranging Yellow-naped Amazon Parrots have been found to produce eggs as early as December and can have eggs hatch as late as April. Conures in the same area have roughly the same cycle although in both species, the majority of eggs hatch in January (dry, cooler weather). Budgerigars in Australia breed throughout the year, but in each geological or ecological area only produce young for a set number of months each year.<sup>189</sup>

Individual pairs of a particular species have the capacity to re-nest if necessary to account for yearly changes in environmental conditions as well as to adjust to geographic or ecologic changes in a region. This same adaptability may be expressed in captivity.

Egg production was monitored for one year at a large Psittaciforme breeding facility in California.<sup>169</sup> Amazon parrots were found to breed during a 17-week period from early March to early July. Blue and Gold Macaws had the longest breeding season, with eggs being produced year round, although egg numbers decreased in September and November. Rose-breasted Cockatoos had the shortest season, which lasted nine weeks from late winter to early spring. Amazon parrots bred at a time when the mean high temperature and humidity was highest (87.9°F and 44.4% RH), as opposed to the cockatoos, which bred with a mean high temperature of 79°F and RH of 27%. Blue and Gold Macaws bred during the broadest range of temperature and humidity.

The Amazon parrots quit producing when day length began to decrease and did not breed again until day length had increased considerably. Blue and Gold Macaws could breed in both increasing and decreasing light. Cockatoos produced only during periods of increasing day length. It could not be determined from this study if temperature, humidity, day length, a combination of all three or other unrecorded factors controlled reproduction. All three of the evaluated species originate from temperate climates and are



probably affected by other factors as well as day length. In Hyacinth Macaws in a Florida aviary, eggs are produced between May and October.

### Mate Presence

In cockatiels, mate access is essential to ensure nesting behavior.<sup>156</sup> Increases in LH levels necessary for oviposition occurred only in females given full mate and nest box access. Visual, but not auditory, isolation of mates did not negatively affect cockatiel reproduction in one study.<sup>190</sup> Testicular development was found to be greater in starlings when males were housed with females. In other species, sufficient photoperiods will induce testicular development regardless of whether a female is present.<sup>179</sup>

Separating a pair during the non-breeding season may not affect reproductive success in a subsequent season, and mates will usually reunite, especially if they have previously been reproductively successful. Mate retention has been found to be associated with greater reproductive success than mate replacement in a variety of species that naturally separate in the non-breeding season.

Orange-winged Amazon Parrots in one study were stimulated to breed by separating them from their self-selected mates for three months and then placing them into enclosures with nest boxes that permitted them to “chew” an entrance hole into the nest box.<sup>111</sup> In addition, these “enriched pairs” were given fruit instead of a complete crumble diet and were exposed to water misters on alternate days. The reproductive success in these birds was better than in a control group, but no one factor could be identified as being responsible for the increased egg production.

### Mate Selection

In some monogamous birds, such as California Quail and Turtle Doves, forced pairing of mates can result in successful breeding. In other species like cockatiels, forced pairing was found to result in decreased reproductive activity.<sup>190</sup> In some species, force-pairing may result in increased mate aggression.

Specific mate characteristics may affect mate acceptance and the strength of the pair bond. Rather startling is the fact that leg band color is important in determining mate preference in finches. This is just one indication that color of feathers and beaks, which often changes seasonally, can be an important reproductive stimulant. External physical characteristics of birds can be dependent on health and nutrition as well as environmental cues that influence the pro-

duction of hormones responsible for secondary sex characteristics.

Aggressive mates can inhibit reproduction by preventing the opposite sex from eating or through direct physical abuse. Aggressive behavior is most noteworthy in cockatoos and is seen occasionally in Eclectus Parrots. Male cockatoos, even in long-term successful pairs, may suddenly attack and sometimes kill their mates. The beak, eyes, skull, feet and cloaca are most commonly traumatized.


Old World Psittaciforme males completely mount the female during copulation, and male aggression may occur from failures in proper copulatory behavior. Evidence suggests that males become sexually active before hens, which may precipitate the aggressive behavior. If a free-ranging male cockatoo becomes aggressive, the hen is able to escape to prevent serious injury.

Lighting, food and the presence of other birds may induce aggressive behavior. As a solution, male cockatoo flight feathers are often clipped, and the nest box is provided with a lower “escape” hatch so that the female cannot be trapped within the nest box. Males should be introduced into the hen’s enclosure by being placed within a smaller enclosure. After mate acceptance, the male can be released into the female’s enclosure. In the case of Eclectus Parrots, females are more aggressive than males, although they rarely seriously injure a mate. Excessively aggressive males or timid females should be removed from the breeding program.

### Mate Pair-bonding

Pair-bonding refers to the behavioral acceptance that exists between a compatible hen and cock and is evident in all successful pairs, although considerable species and individual variation exists. Strong territorial defense coordinated between the male and female, such as lunging at the front of the cage with upraised wings in macaws and tail-fanning with crown and nape feather ruffing in Amazon parrots, are examples of proper pair-bonding (Figure 29.15). Other behaviors include mutual preening (see Chapter 4), feeding, nest box inspection and copulation (see Color 8). Homosexual pairs may also bond and exhibit these same behaviors.

Evaluating a breeding pair through the aid of video recorders will help identify causes of behavior-induced infertility. Some copulatory efforts may be handicapped by physical, medical or behavioral abnormalities. Abbreviated copulatory efforts may nor-



**FIG 29.15** Using a video camera to observe a pair of birds' daily behavior can help determine if an effective pair bond exists and may help identify environmental factors that are inhibiting breeding. These strongly pair-bonded Green-winged Macaws are displaying proper territorial defense behavior in response to an intruder.

mally precede successful copulation. Birds should be allowed to choose their own mates to increase the likelihood of pair-bonding.

#### Mate Vocalization

Male auditory signals stimulate female reproduction in several species. In turn, males will maintain spermatogenesis longer when paired with sexually active females. Budgerigars may be the only avian species in which an auditory stimulus promotes ovarian development and ovulation.<sup>22</sup> Isolation of budgerigar pairs both visually and auditorially from other budgerigars will cause reduced reproductive behavior.<sup>22</sup> A similar effect has been hypothesized in macaws, Amazon parrots, cockatoos and African Grey Parrots (Harrison GJ, unpublished).

#### Social Interaction

The presence of other breeding birds is a reproductive stimulus in highly social and colony breeding species. Social birds such as budgerigars should be housed within hearing, if not visual, range of the same species to stimulate successful reproduction.

Social behavior varies during the breeding season in some species. For example, some parrots will feed only in pairs during the breeding season while cocka-

toos will interact daily with other pairs and feed in larger groups. Free-ranging populations of Zebra Finches are highly social until courtship behavior begins.

In captivity, housing similar species near each other may reinforce the pair bond and strengthen endocrine controls by eliciting territorial defense behavior. In contrast, excessive territorial defense may waste energy and interfere with pair interactions that are critical for reproductive success. Monitoring of a pair's behavior and analysis of enclosure diagrams in multiple-pair and multiple-species aviaries will help define proper housing for each species and individual pair.

#### Human Interaction

Human interference can affect reproduction. Circulating levels of prolactin are easily altered by stressful events; stress is one method used to discourage incubation in egg-producing turkeys.<sup>38</sup> Aviary disturbances and handling birds near the breeding season may disrupt endocrine control of the reproductive cycle or disturb the birds so that mating is not initiated or completed, incubation is interrupted, eggs are damaged or chicks are cared for improperly. Successful territorial defense appears to have a positive effect on reproduction, and males that feel they have defended their nest from humans may be more reproductively active. Although evidence is rather anecdotal, barren pairs have been induced to breed by disturbing, handling or relocating the pairs. Some species of birds are withdrawn and display fear as opposed to aggression when approached by humans, indicating improper territorial defense. These pairs may be more productive once conditioned to human activity or if placed in an isolated, protected area. Annual physical exams can be performed on properly conditioned birds and do not appear to negatively affect reproduction.

#### Nests

Availability and acquisition of a proper nest site and nesting material may be a strong environmental stimulus for breeding particularly in male cockatiels and finches.<sup>77,110,179</sup> In fact, LH surges that stimulate reproduction and spermatogenesis may be induced

because of male defense behavior and not because of the presence of a female. Starling males that did not defend their nest boxes were found to have similar LH levels to males without a nest box.<sup>51</sup> The relationship of the perch to the nest box hole (perch ten cm below the hole) played a significant role in reproductive success in budgerigars.<sup>23</sup> This phenomenon may be applicable to considerations of nest box design in other species as well.

Birds are generally classified as being either determinate or indeterminate layers. Determinate layers will lay only a set number of eggs in a clutch regardless of whether any egg is removed or destroyed. Indeterminate layers will continue to lay until they "recognize" the correct number of eggs. Prolactin is released from the pituitary gland in response to the incubating bird's physical contact with eggs in the nest. The concentration of prolactin, which is responsible for regression of the ovary and incubation behavior, was found to increase gradually in cockatiels that were incubating eggs.<sup>112</sup> These cockatiels were also found to be able to continue to lay additional eggs if previous eggs were removed from the nest. In turkeys, follicular atresia occurs when egg incubation starts.<sup>38</sup>

Applying these principles to companion birds, it is logical that if birds are thought to be indeterminate layers, eggs should be removed before incubation starts if production of more eggs is desired. The longer incubation is allowed to proceed the more complete the ovarian regression would be, which would make a hen less likely to lay another clutch. Budgerigars are believed to be determinant layers.

### Territory

In finches, males with a breeding territory had larger testes with a longer functional period than males that were photo-stimulated without a breeding territory.<sup>42</sup> The presence of sexually active females may also affect the influence of breeding territory in stimulating male reproductive activity. The male's reproductive condition appears to be more easily synchronized by environmental cues than does that of the female. Female reproductive performance appears to be more affected by captivity than does that of males. The presence of a sexually active male probably has a positive effect on females in many species, even though the effect may not be recognizable because of the lack of stimulation in the female from other cues.

### Enclosures

Enclosure design can affect reproduction. Some species of birds appear to breed better in flights as opposed to flight enclosures. The actual dimensions may be important, but longer, wider and higher enclosures may not always be better, as a larger enclosure may represent a territory that a pair feels it cannot adequately defend. Enclosure design in general and nest position, including whether it is within the enclosure, how high it is and whether it is open or obscured by walls, may all influence a pair's feeling of security (see Chapter 2).

### Reproductive Experience

Previous reproductive activity may decrease the requirement for environmental cues to stimulate breeding. This has been shown to occur in budgerigars and is suspected in Orange-winged Amazon Parrots.<sup>18</sup> Mate familiarity increases reproductive success in cockatiels,<sup>190</sup> and mate retention throughout successive breeding seasons has been correlated with greater reproductive success in monogamous birds. Mate familiarity may improve pair coordination, decrease aggression between mates and increase male reproductive behavior.<sup>39</sup>

Hand-raising neonates may result in imprinting on humans or a lack of early environmental "learning," which may affect future reproductive success. Imprinting often appears stronger in males than in females. Hand-raised cockatiel hens were more likely to lay eggs (and more of them) than parent-raised birds; however, eggs were often laid on the floor of the enclosure. Pairs with hand-raised male cockatiels were less likely to inspect nest boxes or produce fertile eggs.<sup>116</sup> The behavioral deficits of hand-raising can be attenuated by successful and repeated breeding experience. Imprinting on the wrong species is common in birds and has been reported to occur when Rose-breasted Cockatoo chicks are foster-raised by Major Mitchell's Cockatoos.<sup>143</sup> During fledging, chicks are thought to imprint on habitat, which will later control nest site selection.

### Nutrition

Low dietary calcium levels (0.056% to 0.3%) have been shown to cause a complete cessation of egg laying in gallinaceous birds. Decreased energy intake causes decreased LH levels followed by ovarian atresia. Low-sodium diets also result in cessation of egg laying. Zinc-rich diets decrease feed intake and

may directly decrease egg laying by altering metabolism and endocrine functions.

Psittacine birds being fed largely seed diets should be expected to consume low levels of vitamin A, D<sub>3</sub> and E as well as other nutrients (see Chapters 3 and 31). Vitamin E deficiency can cause reduced spermatogenesis in domestic fowl and Coturnix Quail. Vitamins A and D<sub>3</sub> are needed for proper reproductive gland secretions and calcium metabolism, respectively. Over-nutrition may precipitate infertility by either mechanically blocking the cloaca or reducing successful ovulation. Abdominal fat and lack of condition may contribute to oviduct inertia and egg-laying problems. Amazon parrots, Scarlet Macaws and Rose-breasted Cockatoos are commonly obese and should be carefully monitored to prevent weight-related infertility. Fat can accumulate in pendulous folds near the cloaca and crop, often differentiating into lipomas (see Color 8). Subcutaneous fat deposits over the coxofemoral and flank regions are more subtle indications of excessive energy intake.

The availability of certain food items and not simply energy consumption may be one of the many stimulants needed to begin or strengthen reproductive activity. Aviculturists can mimic naturally occurring variations in food availability by reducing food intake and variability in the non-breeding season and then dramatically increasing the quality, quantity and variety of foods before the breeding season. The success of this method is equivocal but suggests the need for further study.

In White-crowned Sparrows, consumption of green wheat enhanced photo-stimulated ovarian growth. Testicular growth was not affected.<sup>41</sup> It was not shown if the ovarian stimulatory effects of green leaves were ecologically significant or if specific substances in the green plants induced the change.

Aflatoxins and mycotoxins in feed have been shown to reduce egg production and cause infertility. Thiotepa, although mutagenic, teratogenic and carcinogenic in large doses, proved in one experiment to be a safe, effective temporary chemosterilant when fed to free-ranging male Red-winged Blackbirds.<sup>128</sup>

### Physical and Medical Characteristics

Adequate exercise is important to reproductive success and decreases the likelihood of reproductive disorders, such as egg-binding. Any physical abnormality or medical condition affecting mobility, balance,

the cloacal region or the reproductive tract can cause infertility or decreased reproductive success. Heavy cloacal feathering, such as in Rose-breasted Cockatoos and fancy pigeon breeds, may prevent copulation resulting in infertility. A female Golden Conure with an abscessed preen gland repeatedly attacked her mate when he attempted copulation. The pair laid fertile eggs three weeks after the abscess was resolved. Medications, especially certain antibiotics, can cause infertility or decreased or abnormal egg production. For example, testosterone injections in males can cause infertility, and an entire season of reproduction can be interrupted after the use of injectable doxycycline therapy.<sup>162</sup> These changes may have been due to the stress of restraint and injection; however, similar cessations of reproductive activity have been noted following the administration of doxycycline in other psittacine species (Harrison GJ, unpublished).

### Inbreeding

Males inherit fertility and semen quality characteristics. Some mating behavior is learned and some is inherited. Inbreeding may lead to infertility or decreased production due to genetically controlled physical or behavioral deficits. Lethal and sub-lethal genes that are more frequently expressed during inbreeding can cause decreased hatching rates. Genetic selection for large body types (budgerigars and turkeys) may cause a physical inability to breed.

### General

Frequently, the positive environmental factors that stimulate breeding and the negative factors that prevent it cannot be discerned. Successful captive breeding depends on establishing environmentally enriching conditions that stimulate reproductive activity.

In environmentally stimulated cockatiels, the period from ovarian development to first oviposition was independent of environmental conditions.<sup>110</sup> In pair-bonded cockatiels, a combination of diet, photoperiod, light intensity, ambient temperature and misters increased breeding activity. It was found that changing from a low-quality to a high-quality diet was not necessary to elicit a strong reproductive response. Of the remaining four factors it could not be determined if a non-stimulatory period was necessary or if the presence of any or all of the four factors was necessary to induce breeding.

Free-ranging populations of budgerigars were found to have minimal requirements for reproduction, including correct ambient temperature, day length and

water and food availability.<sup>179</sup> Captive budgerigars have similar requirements, which include sufficient food and water, a nest box with an opening at least ten cm below the nest box hole, combination of loud and soft warbles from the males and, in some cases, exposure to short photoperiods before the breeding season. Budgerigars are strongly stimulated by the vocalizations of other pairs.

Canaries respond principally to photoperiods, with low ambient temperatures causing a delay in egg laying.<sup>179</sup> Inducing reproductive activity in canaries requires exposure to a sequence of short photoperiods to abolish photorefractoriness followed by increasing day length to 14 hours of light. Providing a nest pan is not a prerequisite for ovulation and egg-laying in canaries but improves egg production.<sup>182</sup> In reproductive success in canaries, the presence of a male or male vocalizations plays only a modifying role compared to photoperiod.

### Natural Incubation

Natural incubation is a behavior under hormonal control that can be externally affected by many factors. Improper parental incubation can lead to a complete lack of egg development, arrestment of embryo development, late embryo death or abnormal or weak chicks at hatch. Additionally, many species such as macaws tend to be rather nervous in captivity and are notorious for breaking eggs. Minor punctures and hairline cracks can cause the death of a developing embryo. Foster parents or artificial incubation can be used in pairs with incubation problems. Failures in incubation can also originate from embryo-related problems, diet or environmental factors. In a group of Hyacinth Macaws, natural incubation of the eggs and chick-raising did not occur until the diet contained 15% fat and 2.5% fiber with limited seeds and nuts (Harrison GJ, unpublished). Studying pertinent egg information and performing thorough diagnostic procedures can help determine the cause of some of these incubation failures.

### Information Collection

The attending veterinarian should review existing records concerning the parent's reproductive and medical history and fate of any eggs or chicks. Developing an accurate and consistent record-keeping system and regularly scheduling on-site visits will help identify factors that could explain incubation failures (see Chapter 2).

Reproductive information from each pair including numbers of eggs per clutch, number of clutches per

year, time of day eggs are laid, previous fertility and hatchability statistics, causes of egg failure and chick survivability will all help in evaluating a collection. To get a true fertility rate for a pair, one must necropsy all eggs as soon as possible after they are determined to be dead.

### Fertility

Documenting if an egg is infertile or was fertile and died in early incubation is the first step in investigating egg problems. Eggs that are fertile but were not incubated or that failed to develop past two to five days of incubation will generally appear infertile when candled. These eggs should be opened to determine if they were fertile. Fresh, infertile eggs have a well organized small blastodisc, which in domestic species can be easily differentiated from the large, sometimes cottony or doughnut-shaped fertile blastoderm (Color 29.1). Old, addled or infected eggs in which fertility cannot be determined should not be included in fertility calculations. Additionally, any misshapen, mis-sized or otherwise abnormal eggs that are discarded should not be used in calculating fertility rates. The preferred method would be to include these eggs, as they can be fertile, or to calculate a separate fertility rate for abnormal eggs. Hybrid eggs should also be discounted, as they may have decreased fertility. Fertility rates can be calculated by finding what percentage of the total number of eggs laid were fertile. Undetermined eggs should not be included.

Fertility rates can be useful for discerning problems within a flock or individual pair. Infertility can be a result of behavioral, environmental, nutritional and medical problems (Table 29.5). Factors that should be considered include age of the birds, time the pair has been together, time the pair has been in the aviary, enclosure type, enclosure location, production of eggs in the past, past fertility and hatchability, hybrids, inbreeding, date of lay, environmental parameters (temperature, humidity, day length, rainfall) and behavioral characteristics of the pair. Fertility within an aviary should be evaluated on an individual pair and species basis within an aviary. Fertility rates of free-ranging birds may vary among species due to natural physiological processes. Fertility is normally reduced in older birds, in younger birds and at the beginning and end of a breeding season. Infertility in these cases may be a natural occurrence and not an indication of disease.

Domestic poultry have been genetically selected to produce high fertility rates of approximately 95%.

TABLE 29.5 Causes of Infertility

- **Behavioral:**

Immaturity, pair incompatibility, normal species differences, normal occurrence as part of clutch, sexual inexperience, lack of early learning, aviary disturbances, lack of social interaction, excess social interaction, homosexual pairs, lack of pair-bonding, asynchronous breeding condition, improper imprinting, infrequent matings.

- **Environmental:**

Incorrect photoperiod, incorrect nest box design or nesting materials, incorrect enclosure design, lack of visual barriers, excessive rain, insufficient rain, temperature, humidity, availability of correct foods, loose or incorrect perches.

- **Medical:**

Obesity, age (young or old breeders), inbreeding, vent feathers, drug therapy (causing vitamin deficiency or direct, decreased fertility), previous hormonal therapy (testosterone injections), musculoskeletal, neuromuscular or other disease (causing pain, paresis, ataxia, weakness, decreased muscle tone or incoordination), neurologic disease (causing paresis, ataxia, lack of muscle control), reproductive tract disease, nutritional deficiencies or excesses, systemic disease, parasitic disease leading to malnutrition, cloacal abnormalities, abnormal cloacal pH, possible thyroid deficiency, toxins (pesticides, chemicals, mycotoxins).

The fertility rates of most free-ranging companion birds have not been determined, although in some species studies have indicated that fertility can be quite high. Captive companion and aviary birds have the potential for similar fertility rates but more commonly the rates are lower, probably due to a combination of environmental and dietary factors.<sup>92</sup> Free-ranging macaws do not necessarily nest and produce offspring each year. This cyclic production is probably related to environmental factors and not due to disease-related infertility. Aviculturists should establish their own fertility rates and standardize data so that comparisons can be made among similar aviaries.

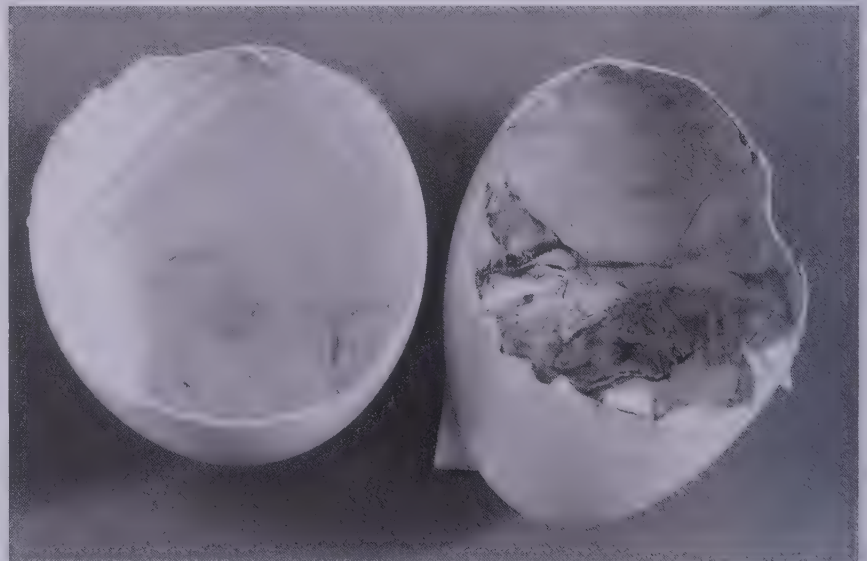
### Hatchability

Hatchability rates are determined from eggs that were known to be fertile. Including infertile eggs in hatchability statistics will artificially lower hatchability rates and confuse diagnostic efforts. Hatchability rates are calculated by finding the percentage of fertile eggs that successfully hatched.

“Successfully hatched” may or may not include chicks that were weak and died soon after hatching from pre-nursery-associated problems. Hatchability rates can be calculated for individual pairs, separate clutches, different species, eggs incubated naturally, eggs incubated artificially and eggs that had various kinds of physical problems or that were manipulated during incubation or hatching. The more precise the hatchability statistic, the more diagnostic the information that is provided (Figure 29.16).

In domestic fowl, the hatchability of naturally and artificially incubated fertile eggs approaches 85 to 90%. With companion and aviary birds, this figure may be much lower, and ranges from 8% to 100% have been discussed.<sup>29,92</sup> Lower hatchability rates are probably due mostly to improper parent or artificial incubation techniques. Aviculturists should be encouraged to develop their own standards for hatchability and then strive annually to improve their level of success.

The number of lethal or chromosomal abnormalities reported in companion bird species is low when compared to domestic species. Evaluating fertility and hatchability statistics from parents and sisters of breeding males may help identify lethal or semi-lethal genes in some family trees. Breeding tests may



**FIG 29.16** Complete and accurate hatching records can be indispensable in helping a veterinarian identify reproductive or neonatal problems. The egg on the left was from a normal unassisted hatch, and the chick from this egg was strong and developed normally post-hatching. The egg on the right was from a difficult hatch that required assistance. Note the retained blood within the membranes and excrement in the egg. The chick from this egg had intermittent problems with depression and slowed gastric emptying times for the first week of life.

TABLE 29.6 Causes of Death or Abnormalities in Embryos<sup>92</sup>**FIRST TRIMESTER**

- Egg handling
  - Eggs stored too long
  - Eggs stored under incorrect conditions
  - Incorrect egg fumigation or sanitation (dirty hands)
  - Excessive vibrations (jarring)
  - Rapid temperature change
- High temperature in early incubation
- Incubation faults
  - Temperature, humidity, turning
  - Cooling after development has begun
  - Suffocation due to incorrect ventilation
- Inbreeding
- Chromosome abnormalities
- Egg-transmitted infectious diseases
- Parenteral nutritional deficiencies
- Abnormal or aged sperm
- Idiopathic developmental abnormalities
- Drugs, toxins, pesticides
- Cracked eggs
- Small holes in eggs

**SECOND TRIMESTER**

- Parenteral nutritional deficiencies
  - Riboflavin, vitamin B<sub>12</sub>, folic acid, biotin, manganese, pyridoxine, pantothenic acid, phosphorous, boron, linoleic acid, vitamin K, vitamin D
- Secondary vitamin deficiencies
  - Antibiotic therapy destroying vitamin-producing flora
  - Diet imbalances, inadequate food intake
- Viral diseases
- Bacterial infections
- Fungal infections
- Egg jarring or shaking in the first trimester
- Incubator faults
  - Incorrect turning, temperature, humidity and ventilation
- Inbreeding resulting in lethal genes

**THIRD TRIMESTER**

- Malpositions
  - Inadequate or incorrect turning
  - Abnormal egg size or shape
  - Incorrect incubator temperature
- Incubator faults
  - Poor incubator ventilation
  - Egg cooling early in incubation
  - Inadequate or incorrect turning
  - Incorrect temperature
  - Incorrect humidity
- Incorrect hatcher temperature or humidity
- Long storage time pre-incubation
- Infectious disease
- Nutritional deficiencies
  - Vitamin A, D, E, K, pantothenic acid, folic acid
- Lethal genes
- Chromosomal abnormalities
- Idiopathic developmental abnormalities

be required to establish whether such genes are sex-linked or autosomal, dominant or recessive.

#### Parental Factors

The medical history of each parent should be examined to identify factors that may affect fertility and hatchability. Table 29.6 lists factors associated with

embryonic death according to the stage of incubation (first to third trimester). A pair with persistent fertility or hatchability problems should be completely evaluated by performing physical examinations, complete cloacal examinations, cloacal and choanal cultures, Gram's staining and culturing of uterine samples (many uterine problems are anaerobic), complete blood counts, serum chemistries, radiographs, exploratory laparoscopies and evaluation of sperm. Exposure to toxic compounds, either directly or in the food or water, should be considered. Behavioral problems including lack of pair-bonding, inconsistent parental incubation and egg trauma in the nest may also cause hatchability problems.

#### Diet

Diets should be analyzed for adequate levels of protein, fat, carbohydrates, calorie content, minerals, fiber, calcium and vitamins and for the presence of aflatoxins. Total caloric intake and food selection behavior for each individual bird should be evaluated. Nutritionally deficient hens can produce eggs, but the low level of nutrients may prevent the eggs from hatching. The age of embryonic mortality will usually depend on the degree and type of deficiency or toxicity.

Severe hypovitaminosis A causes a complete cessation of egg production. Partial hypovitaminosis A may cause circulatory collapse and embryo death and has been suggested as a cause of egg binding. Vitamin E deficiencies can cause lethal rings in which the embryo is seen surrounded by a ring of separated tissue. Vitamin D<sub>3</sub> deficiencies can cause small eggs with poorly calcified shells. Ultraviolet light exposure may improve hatchability in these cases while excess D<sub>3</sub> may lead to a complete cessation of egg production. Embryonic hemorrhage is common with deficiencies in vitamins E and K. Vitamin K is also involved with calcium transport, and vitamin K deficiencies can mimic the clinical signs associated with hypocalcemia.

Calcium-deficient eggs exhibit reduced hatchability, poor shell calcification, embryos with rickets and excessive loss of water and weight during incubation. The calcium/manganese ratio regulates the rate of hatching, and imbalances of these minerals may cause early or late hatching. Given the wide variability in the types of food (and thus the composition of these foods) consumed by free-ranging birds of different species, it is not surprising that a single commercially available diet cannot meet the needs of all captive companion birds. For example, free-ranging

Hyacinth Macaws that feed on high-fat nuts may require nutrients contained in these foods for successful reproduction and embryo health. It is speculated that breeding third and fourth generations of companion bird species will result in higher fertility and hatchability rates in birds fed commonly available commercial diets (see Chapters 3 and 31).

### Environmental Factors

Perches should be stable enough for breeding, and nest boxes of suitable size should be easily accessible (see Chapter 2). Nest box size and shape and bedding material should be evaluated. The microclimate of the nesting area, including temperature and humidity, is important for proper incubation and is adversely affected by soiled bedding and improper nest box design. Cultures from bedding material may help identify infectious agents. Ambient temperature, humidity and to a lesser degree rainfall, wind and barometric pressure may affect the success of parental incubation.

### Pre-incubation Factors

Non-incubated, fertile eggs will not develop if held at 55°F to 75°F. Cockatiel eggs stored at 55°F and 60% relative humidity did not show decreased hatchability until after three to four days of storage.<sup>33</sup> Eggs can be incubated for two days, removed and placed at 55°F, and placed back in an incubator without a decrease in hatchability. These temperature manipulations are convenient for shipping eggs and for synchronizing hatching times.

Parents may not initiate incubation until more than one egg is laid. Under natural conditions, the failure of a parent to incubate the first egg when temperatures are not within safe preincubation ranges can result in the death of the egg. Exposure of eggs to temperatures that are higher than 55 to 75°F but below optimal incubation temperatures can cause death of the embryo. Parent behavior, climate and nest box characteristics may be responsible for lack of development or deaths in embryos during the first and last trimesters.

## Artificial Incubation

Hatchability of artificially incubated eggs is frequently lower than naturally incubated eggs.<sup>36</sup> Eggs

that have been naturally incubated for the first five to ten days may have higher hatchability levels than eggs that are artificially incubated for the entire developmental period (Figure 29.17). The fact that different hatchability rates exist between natural and artificially incubated eggs highlights the need for a wider dissemination of information on successful incubation protocols.<sup>1,24,33,53,65,81,122,165,166,184</sup>

Many aviculturists prefer to use foster parents rather than artificial incubators, particularly during the first week to ten days of incubation. Foster parents must exhibit broodiness and be accepting of the shape, size and color of the foster eggs (see Chapter 6). Bantam and Silkie chickens have been used successfully to foster eggs from many psittacine species. The number of eggs under each foster parent should not exceed the number that the hen can adequately incubate.

### Incubation Requirements

Important incubation factors include temperature, humidity, air flow in the incubator and hatcher, egg position during incubation, the angle for egg turning and the number of times per day the egg is turned. Incubator temperature and humidity affect the incubation period, and published incubation periods may vary with different incubation parameters (Table 29.7). Substantial research is necessary to establish the optimal incubator parameters for companion bird species. Most psittacine eggs are incubated at 99.1° to 99.5°F (37.3°



**FIG 29.17** A plastic soup ladle makes an ideal tool for removing eggs from the nest. It has smooth edges and a long handle and can be easily sterilized between uses (courtesy of Apalachee River Aviary).



to 37.5°C) and 80° to 82°F (26.7° to 27.8°C) wet bulb, and hatched at 98.5°F (36.9°C) and 88° to 90°F (31.1° to 32.2°C) degrees wet bulb. Lower incubator humidities and higher hatcher humidities have also been described (Jordan R, unpublished). Research involving fertile cockatiel eggs determined that 99.5°F (37.5°C) with 56% relative humidity and 98.4°F (36.9°C) with 67% relative humidity were optimal settings for incubation and hatching, respectively.<sup>33</sup>

Temporary shifts in temperature (as long as not excessively hot or cold) probably have no effect on hatchability. Such fluctuations are common when the incubator door is opened and the eggs are candled. It is best to turn off the fan when the incubator door is opened. Daily temperature and humidity charts should be maintained for each incubator. Individual incubators may have hot or cold spots that affect hatchability, and placing numerous thermometers at different locations within an incubator can help to identify these areas. Thermometers and hygrometers should be calibrated frequently to make certain that they are accurate.

A 2°F excess in temperature during the first few critical days of incubation can result in embryonic death.<sup>122</sup> Increasing or decreasing the incubation temperature by 1.4°C caused poor hatchability and increased the incidence of abnormalities in cockatiel chicks.<sup>33</sup> Chicks produced by higher than optimal incubation temperatures were small, weak and dehydrated and frequently had umbilical openings and exposed yolk sacs. Scissor beaks, curled toes and wry necks were also common. Slightly higher temperatures will further increase mortality, and temperatures approaching 104°F (40°C) will kill all embryos.

Marginally lower-than-optimum temperatures may cause a delay in hatching. Temperatures that are constantly a degree or so lower than optimum have been shown to cause an increased number of "late dead" embryos, and if hatching occurs, chicks are weak with large, soft bodies and unabsorbed yolk sacs. Some chicks may be ataxic post-hatching. Hatching may occur several days later than expected. Low humidity results in lower egg weight, larger air cell size and small dehydrated chicks, possibly due to inadequate calcium mobilization for bone development.

Chicks from eggs incubated at high humidities may have excessive amounts of fluid, including residual albumen, that may obstruct the nostrils causing asphyxiation. Eggs should be turned at least five to eight times a day for at least two-thirds of the incu-

TABLE 29.7 Incubation Periods for Psittacine Species Common in Aviculture

Species	Incubation Period (days)	Pip to Hatch Interval (hours)
African Grey Parrot	26-28	24-72
African parrots (small)	24-26	24-48
Amboina King Parrot	20	24-48
<i>Aratinga conures</i>	24	24-48
Blue-fronted Amazon Parrot	26	24-48
<i>Brotogeris</i> parakeets	22	24-36
Budgerigars	18	12-24
Caiques	25	24-48
Cockatiels	21	24-48
Cockatoos (large)	26-29	24-72
Cockatoos (small)	24-25	24-72
Eclectus Parrot	28	24-72
Goldie's Lorikeet	24	24-48
Grass Parakeet	18	24-48
Green-cheeked Amazon Parrot	24	24-48
Hyacinth Macaw	26-28	24-72
King Parrot	20-21	24-36
Lories	26-27	24-36
Lovebirds	22	24-48
Macaws (medium)	24-28	24-72
Macaws (miniature)	23-27	24-60
<i>Amazona ochrocephala</i> parrots	26-28	24-48
Parrotlets	19	24-36
<i>Pionus</i> parrots	25-26	24-48
<i>Psittacula</i> parakeets	24-26	24-48
<i>Pyrrhura conures</i>	23	24-48
Quaker Parakeet	23	24-48
Red-lored Amazon Parrot	24	24-48
Rose-breasted Cockatoo	22-24	24-72
Palm Cockatoo	28-30	24-72
White-fronted Amazon Parrot	24	24-48

Compiled by Susan Clubb and Keven Flammer

bation period. More frequent turning, up to 24 times a day, may improve hatchability in Psittaciformes or with embryos suspected to have a lack of vigor or delayed development. Eggs should be positioned on their sides with the round or air-cell end slightly elevated. Poultry eggs tilted or placed in a horizontal position were found to have an increased incidence of malposition of embryos.<sup>76</sup>

Still-air incubator temperature requirements are usually higher than forced-draft incubators. Placing incubators in a room that maintains a relatively cool (70-80°F; 21-26°C), dry (50-60% relative humidity), environment is ideal. Extreme temperature and hu-


midity fluctuations (5°F or 5% relative humidity) in the incubation room should be avoided. Incubator ventilation, sanitation, abnormal vibrations, improper mechanized egg turning, inaccurate thermometers, inaccurate hygrometers and placement of incubators near walls and windows can all affect incubator function.<sup>89</sup> Incubators with horizontal grill-type turners may be too rough for sensitive embryos. Excessive jarring and shaking, particularly during the early stages of development, can result in embryo death or malformation. Improper egg position and faulty egg turning during development may result in malpositions and incomplete closure of the ventral body wall.

Hatchers should be evaluated in a manner similar to incubators (Figure 29.18). The success of the sanitation program and the presence of microbial contamination can be estimated with cultures of the incubator surfaces, water trays, egg trays, and incubator room floor, shelves and instruments.

#### Incubation Preventive Techniques

Prevention of most incubation problems involves correcting the three most common causes for decreased hatchability in artificially incubated eggs: improper temperature, humidity and egg turning.<sup>89</sup> Accurate record-keeping is mandatory for identifying hatching-related problems. A protocol for carefully evaluating incubator performance and stability should be followed.<sup>89</sup> Pre-conditioning incubators a month prior to breeding season and evaluating daily fluctuations in temperature and humidity in the incubator room and in the incubators may help identify problem areas. The egg-turning mechanism should be checked periodically to confirm that it functions at the correct time interval, maintains the necessary egg angle and does not excessively vibrate the eggs. Excessive vibrations have been associated with reduced hatchability.<sup>184</sup>

Bacterial and fungal agents infrequently cause problems in psittacine eggs, but occasionally a contaminated incubator, hatcher or incubator room can cause high egg losses. Water trays should be removed and disinfected daily and should be filled with distilled water. In the non-breeding season incubators should be dismantled, and non-sensitive parts should be thoroughly cleaned with a glutaraldehyde solution followed by a long period of air drying. Disinfecting incubators with formalin and potassium permanganate is extremely dangerous and cannot be recommended.



**FIG 29.18** Plastic strawberry baskets with a section of small plastic mesh in the bottom make ideal hatching containers. They are safe, have no sharp edges and can be easily sterilized between uses. This hatching basket contains the perfectly opened egg from a Greater Sulphur-crested Cockatoo chick (courtesy of Apalachee River Aviary).

Periodic culturing of newly hatched chicks, eggs and incubator surfaces will indicate if bacterial contamination is occurring. A sterile contact tape can be used to culture nursery surfaces and eggs. An open microbiological agar plate can be placed in an incubator to determine what bacteria are present in the air. Incubators can be tested for the presence of PBFD virus or polyomavirus by taking swabs for DNA probing.

The incubator room should be kept scrupulously clean to prevent particulate matter from contaminating egg shell surfaces. Clothes and shoes worn around other birds should be removed or covered before entering the incubation area. Hands should be thoroughly washed with a disinfectant or gloved before handling eggs. Problems associated with incubation are listed in Table 29.8.

Eggs are relatively resistant to bacterial invasion, but eggs that may have been contaminated with infectious agents should be incubated separately from non-contaminated eggs. Feces and dried particulate matter can be gently sanded off the egg surface, although over-exuberant sanding should be avoided.

Chlorine dioxide foam may be a safe sanitizing agent for contaminated eggs,<sup>125</sup> or eggs can be washed with a warmed iodine solution (104°F) or immersed in warm water baths (110°F) for up to five minutes. Bacterially contaminated eggs can be dipped into a cold water antibiotic solution by warming the eggs to 37°C, and placing them in cold water (4°C) containing 1000 µg/ml of gentamicin solution.<sup>161</sup> Psittacine eggs should not be incubated with eggs from other species.

## Monitoring the Embryo

### Candling

A candling program allows one to follow developmental progression of an embryo and detect any abnormalities that may occur. Chicken eggs can be used for practice. Periodic candling will ensure the removal of non-developing eggs as soon as they are identified. This increases the likelihood that the cause of an embryo's death can be determined and reduces the possibility of an infected egg contaminating the incubator. Daily candling will improve an individual's ability to recognize developmental stages of the various species.

Initial candling of psittacine eggs should occur no later than six to seven days into incubation. The eggs should be handled with care to prevent sudden jarring or chilling from inducing embryonic death or malformation.<sup>175</sup> Shortly after oviposition, an egg may not have an air cell; this develops as the egg cools and the internal volume is reduced. It is during this initial cooling process that surface contaminants can be drawn into the egg. Eggs can be marked for identification using a #2 pencil (see Figure 29.4). Candling between the seventh and tenth day of incubation will indicate if an egg is fertile and whether it is developing normally. After the initial candling, eggs can be evaluated every two or three days if desired, and should be examined at least once just before transfer to the hatcher.

Candling naturally incubated eggs should be considered; however, the disadvantages of disturbing the adults and eggs must be weighed against the possible advantages of identifying eggs that need manipulation or intervention for hatching to occur. Candling to determine if the egg is fertile (five to seven days post-laying) followed by evaluation just prior to the expected date of pipping will usually be sufficient for evaluating parent-incubated eggs.


Extended flashlight type candler may not satisfactorily illuminate eggs when ambient light is present, and more specialized tools may be required (Figure

TABLE 29.8 Chick Abnormalities Caused by Incubation Problems

Abnormalities	Possible Causes
Early hatch, thin, excessive vocalizations	Small eggs, species differences, high incubator temperature, low incubator humidity, high incubator or hatcher temperatures (bloody navels).
Late hatch	Large eggs, old parents, eggs stored too long pre-incubation, low incubator temperature, inbreeding.
Sticky chicks, albumen present	Low incubation temperature, high incubation humidity, incorrect turning, very large eggs.
Dry chicks, stuck to shell	Low humidity during egg storage, incubation or hatching, incorrect turning, cracked eggs, poor shell quality, high incubator temperatures.
Small chicks	Small eggs, low humidity during egg storage or incubation, high incubator temperature, high altitude, thin or porous shell, tetracycline used in hen.
Weak chicks	Variety of causes including incorrect humidity and parental malnutrition.
Umbilicus fails to close with varying degrees of unretracted yolk sac	Incorrect incubation temperature, low hatcher temperature, high hatcher humidity, parental malnutrition, omphalitis (can be caused by contamination or incorrect incubation temperature), inadequate ventilation.
Short, wiry down (species dependent)	Nutritional deficiencies, toxins (eg, mycotoxins), high incubation temperature first two trimesters.
Dwarf embryos, stunting in growing chicks	Egg contamination, heredity, parental malnutrition, possible hypothyroidism.
Short beak, missing beak, face, eye or head abnormalities	High incubator temperatures early first trimester, lethal genes, idiopathic developmental abnormalities, parental nutritional deficiencies (eg, niacin), low oxygen early first trimester, sulfa drug use in hen, insecticides, herbicides, excess dietary selenium, nicotine, viral.
Red hocks	Prolonged pushing on shell during pipping and hatching, parental vitamin deficiencies, thick shells, high incubator humidity, low incubator temperature.
Musculoskeletal or neurologic abnormalities	Incorrect incubation temperature (curled or crooked toes, splayed legs), low incubation temperature (bent necks, nervous disorders), high incubation temperature (ataxia, star gazing), low humidity, unsuitable hatching substrate, sulfa drug use in hen, insecticides (scoliosis, lordosis).

29.19).<sup>103</sup> High intensity lights (heat) may injure embryos during early development.

- Candling Data:** Candling helps identify the degree of egg shell thinning, egg shell cracks, blood rings, meat spots, membrane and blood vessel integrity, heart rate, stage of development, development progression, air cell size and shape, and yolk size, color and shape (Colors 29.14 to 29.16). Candling later in incubation helps to evaluate malpositions, chick movement, size, shape and location, and internal pip-to-hatch interval (Colors 29.17, 29.18). Lack of embryo vitality can be recognized by poor vessel integrity, decreased movement and retarded development. Embryo death in early incubation results in cessation of development, blood rings and loss of membrane and vessel integrity. Late embryo death is somewhat harder to recognize due to the natural opaqueness of the developing embryo, but lack of



**FIG 29.19** Small utility lights (below) can be used to perform basic candling tasks in dark areas, but have limited application for performing in-depth diagnostic evaluation of an egg. It is best to use a commercial candler (above) when detailed information on the developmental state of an egg is required (courtesy of Apalachee River Aviary).

vessel integrity and movement are indicative of late incubation deaths.

### Egg Weights

Eggs should be weighed when they are candled, and weight loss rates can be recalculated throughout the incubation cycle. Air cell dimensions can be evaluated to provide an estimate of weight loss. Eggs from most Psittaciformes should lose an average of 12% to 13% of their weight from the beginning of incubation to the point of transfer to a hatcher. An additional 3% of weight should be lost during pipping.<sup>24,81,130</sup> Desired egg weight loss can be determined using a variety of mathematical formulas.<sup>24,68,81,130</sup> Egg weight loss is affected by egg shell porosity, air circulation, altitude, temperature and humidity.<sup>24,26</sup> Egg weight loss rates can be used to detect incubation problems and can also be used to manipulate the humidity or egg to ensure proper weight loss.

### Egg Necropsy

Every egg that fails to develop or that dies should be necropsied. ("Breakout" refers to opening eggs for diagnostic purposes.) Candling cannot distinguish very early embryonic deaths from infertile eggs, and the presence of fertility is an important criteria when proceeding with a diagnostic program in avian reproduction. All data relating to the egg should be reviewed prior to necropsy. The veterinarian should be able to identify various embryologic structures and understand the physiological purpose of each structure that might be related to embryo death (see Table 29.2, Figures 29.2, 29.3).<sup>1,44,55,135,137</sup>

Necropsy should be performed on eggs or chicks as soon after death as possible to prevent rapid autolysis from destroying valuable information; however, one should always make certain that an embryo has stopped developing before initiating a necropsy. The majority of eggs for necropsy will fall into two distinct age groups: embryonic death at three to five days of incubation and death perihatching.<sup>135</sup> Early embryonic mortality is common with improper incubation temperature, jarring, inbreeding and chromosomal abnormalities. Deaths at the end of incubation are usually associated with hatching, and the stressful period of switching from allantoic to pulmonary respiration. Factors including improper incubation humidity, temperature and turning are thought to be the leading causes of late embryonic death in psittacines. Mid-incubation deaths occur in poultry embryos when the hen is fed a diet deficient in proteins, minerals or vitamins.

- **Technique:** All eggs should be candled before necropsy to determine the best point for entering the egg. This also permits the correlation of candling with necropsy findings. Eggs should be weighed and measured, and external shell characteristics (egg shape, egg size, external calcium deposits, cracks or thinning) should be noted. Pip marks should be evaluated for turning direction, location and size. Chicks normally pip counter-clockwise from the round end of the egg. The egg necropsy should be performed under sterile conditions until cultures have been taken of embryonic fluids and tissues.

The egg is opened over the air cell with sharp-blunt scissors. Shell membranes are examined for abnormalities and then carefully peeled back to expose the internal egg contents (Color 29.36). When exposed, the albumen and amnion can be cultured and visible microbial growth may be noted (Color 29.28). The chorioallantoic membrane (CAM) normally adheres to the inner shell membranes after the first trimester

### CLINICAL APPLICATIONS

#### Egg Weight Formulas — Weight loss trend to pip:

$$\frac{([\text{laid weight}] - [\text{current weight}]) \div (\# \text{ days incubated})}{\text{daily weight loss}} = (\text{average daily weight loss})$$

$$(\text{average daily weight loss}) \times (\text{total incubation period prior to pip}) \div (\text{laid weight}) = (\text{decimal percentage})$$

$$(\text{decimal percentage}) \times 100 = (\text{weight loss trend to pip})$$

$$(\text{laid weight}) = (\text{species specific coefficient}^{81}) \times (\text{length egg in mm} \times \text{breadth}^2)$$

of development. Adhesions of the embryo to the CAM are abnormal. Eggs that are not necropsied shortly after death may develop adhesions or sticky membranes. Late-term embryos have anatomical differences from adults, but are similar to young chicks.<sup>114</sup>

Internal egg membranes and structures should be evaluated before being altered by manipulation or culture techniques. A ruptured yolk sac can obscure the necropsy field. Color, size and location of the albumen, yolk and allantois is recorded. Presence and characteristics of the circulatory tree are observed. Abnormal odors should be noted.

Enlarging the hole over the round end of the egg is performed by careful removal of egg shell fragments with thumb forceps. If a small chick or no chick is identified, the contents of the egg can be carefully poured into a sterile container (Color 29.38). If a well developed chick is present, the position of the air cell with respect to the egg, orientation of the embryo as a whole within the egg, position of the head, beak and neck in relation to the body and position of the beak in relation to the air cell should be evaluated (Color 29.34).

Different malpositions have various success rates for hatching in domestic species, and many can hatch unassisted (Table 29.9). Although only six malposition classifications are traditionally discussed, there is an almost endless variety of malpositions that can occur, some of which are very subtle and require close inspection.

Psittaciformes appear to have different malpositions than domestic species.<sup>28,29</sup> Frequently the head appears on an even plane with the right wing, and the entire body may be rotated such that the spine is on a horizontal plane with the short axis of the egg. The significance of this malposition is not known. Common causes of malpositions include turning problems, incorrect position in the incubator, oxygen deprivation, excess CO<sub>2</sub>, lack of embryo vigor and delayed development.<sup>37</sup>

If a chick can be seen in the egg, it should be weighed, measured and staged according to standards.<sup>55</sup> Remaining albumen, chorioallantoic membrane blood vessels and ruptured yolk or allantoic contents may adhere to the shell once the chick is removed. If size permits, the chick should have a full necropsy performed, being careful to keep the yolk sac membrane intact. Special attention should be given to the hatching muscle for size, edema and hemorrhage. Other gross evaluations, including skin color and hemor-

rhage, musculoskeletal deviations, internal hemorrhages and contents of the mouth, nares, crop and esophagus, should be made. The liver may be hemorrhagic from exuberant kicking, especially if a chick was malpositioned (Color 29.39).

The hatching muscle (*Muscularis complexus*) is a primary storage site for lymph in the embryo and is normally enlarged perihatching. Lungs are evaluated for evidence of air intake or for the presence of fluid, although this differentiation usually requires histopathology. Tissues should be fixed in formalin for histopathologic evaluation. Eggs can be frozen for future analysis of toxic substances.<sup>96</sup>

At hatching, a chick's weight, activity, vocalizations, body measurements and degree of yolk sac retraction and the presence of any abnormalities should be recorded. Monitoring chick growth rates, food intake, behavior and development progression can help detect any subtle problems that may occur.

### Microbiology of Eggs

External egg structures prevent but do not stop microorganisms from entering the egg. Bacteria located in an egg could suggest environmental contamination that occurred after embryonic death. If the ne-

TABLE 29.9 Classic Malpositions of Chick Embryos

<b>Malposition 1:</b>	Head between the thighs. Failure of the chick to lift and turn its head to the right in the middle of the last trimester. Completely lethal. Incidence increased by high incubation temperature.
<b>Malposition 2:</b>	Head in the small end of the egg. Chick is upside down in the egg. Hatchability reduced by 50% in domestic species. Incidence increased by incubator egg position and low temperature.
<b>Malposition 3:</b>	Head is under the left wing. Chick rotates its head to the left as opposed to the right. Usually lethal. Incidence increased by incubator egg position, temperature and parental malnutrition.
<b>Malposition 4:</b>	Beak is away from the air cell. Upward turned aspect of maxilla and egg tooth is not near the air cell; however, the rest of the embryo is normally positioned. Slightly reduced hatchability. Incidence increased by incubator egg position.
<b>Malposition 5:</b>	Feet over head. Usually lethal.
<b>Malposition 6:</b>	Head is over the right wing. Normally the head is under the right wing in domestic species. Psittacines may normally hold the head in the same plane as the wing. Reduces hatchability slightly in domestic species. Incidence may be increased by parental malnutrition.

croscopy is performed immediately following embryonic death, finding bacteria in the embryo can indicate bacteremia or an infected ovary or oviduct in the hen. Bacterial contamination of an egg usually originates from the atmosphere, the nesting area or the surface of the cloaca.<sup>25</sup>

In poultry, reducing microbial loads in nest shavings does not increase hatchability, although it does decrease bacterial contamination in dead or dying eggs. With duck eggs, however, hatchability and chick hatch weight could be increased by having clean eggs (not visibly soiled).<sup>82a</sup> Generally, egg infection is not caused by environmental contamination although the type and concentration of bacteria in the nest box can definitely increase the likelihood of an egg infection. Eggs with hairline cracks, pinpoint punctures and thin shells are more prone to colonization by microorganisms. Reduced cuticle deposition, which occurs in older birds, does not affect hatchability except in extreme instances, but will affect the number of dead or dying eggs that are bacterially contaminated.

Egg structures are affected by bacteria in different ways. The source of persistent egg infections may be identified by culturing the hen's cloaca, nest box contents, the exterior egg shell, albumen, yolk and embryonic tissues. Gram-positive bacteria occur mostly on the surface of the egg, and the insides of contaminated eggs contain mostly gram-negative bacteria.<sup>15</sup> Chicks that are infected in the egg usually die with macroscopic yolk lesions (coagulated yolk and yolk sac hemorrhages) (Color 29.39). In other cases, embryos may die before the production of macroscopic changes in the yolk and a histological examination is necessary to establish the presence of an infection.<sup>63</sup>

### ■ Egg Therapeutics

Treatment of bacterially infected eggs is possible although preventing infections is more effective. Medical intervention should be attempted only in those cases where the embryo is at risk of dying. Perpetuation of weak genetic lines in companion birds may be exacerbated by assisting in the hatching of troubled eggs.

#### Pre-incubation

Defects in egg shells can be repaired by using sparing amounts of Elmer's glue, surgical glue or paraffin. Thick or excessively large applications of these substances can retard air exchange or create difficulty

for the chick during hatching. It has been suggested that large defects can be covered with egg shell remnants from other eggs, although the prognosis for these eggs should be considered poor.<sup>165</sup> Tremulous air cells resulting from trauma or weak shell membranes may indicate blastoderm shock and ruptured shell membranes. Eggs with tremulous air cells usually have reduced hatchability but should not be discarded because embryos may develop and hatch normally.<sup>90</sup> These eggs should be hand-turned as should all eggs with suspected shell or membrane defects.

#### Incubation

Manipulation of eggs before the point of hatching should be limited. The most frequently used techniques are designed to change the weight loss of an egg. Eggs can be moved to higher or lower humidity incubators based on weight loss. Eggs can also be gently sanded or have small holes placed in them over the air cell to increase weight loss. Paraffin can be used to partially cover the egg to reduce weight loss although no more than 60% of the area above the air cell or total air cell surface should be coated.<sup>26</sup> Sealing a large portion of the air cell may decrease oxygen intake and cause the embryo to invert within the egg. Eggs that have had their shell altered should be hand turned to keep the sealant intact and to reduce chances of damaging the shell. Irregular or weak vascular patterns may be corrected by increasing the turning frequency (Thormahlen M, unpublished).

Injecting sterile lactated Ringer's solution into severely dehydrated eggs has proven successful in some cases.<sup>26</sup> Injection of sterile water into the small end of the egg (albumen) during the first half of incubation led to addled eggs in one study<sup>150</sup> but was of benefit if given later in incubation. Replacement volumes to be given are calculated from egg weight deficits. Injecting antibiotics (piperacillin 200 mg/ml, 0.02 ml for macaw eggs, 0.01 ml for cockatoo eggs) into bacterially contaminated eggs has been attempted with some success.<sup>108</sup> If done properly, injecting gentamicin into the albumen was not found to lower hatchability.<sup>27</sup>

Small dental drills or needle puncture holes can be used to make a pathway for delivering injections into either the small end of the egg or over the air cell. Holes should be resealed with paraffin or glue. Pre-incubatory egg injections with 2.4 mg of tylosin and 0.6 mg of gentamicin was successful in eliminating *Mycoplasma meleagridis* from turkey poults.<sup>105</sup> Ap-

appropriate drugs, dosages, site of inoculation and timing of inoculation for companion bird species have not been determined, and egg injections should be avoided except in special cases.

### Late Incubation

As the expected hatch date approaches, the egg should be candled frequently to monitor changes in the configuration of the air cell. As the chick develops, the head comes to lie under the right wing, with the tip of its beak directed towards the air cell.<sup>122</sup> When the air cell drops and enlarges, the hatching process has begun and a chick begins the transition from chorioallantoic circulatory respiration to pulmonic respiration. As the circulation to the allantois no longer has the capacity to meet the embryo's needs for gas exchange, the chick begins to move its head to the air-filled end of the egg. This stage of hatching can be observed only by candling. Some chicks will begin to vocalize during this period. The CO<sub>2</sub> level in the embryo rises causing the neck muscles to twitch, and the embryo will penetrate the membrane into the air cell. At this point, the embryo begins to breathe air, and the patent right-to-left cardiovascular shunts close.<sup>122</sup> The muscle twitching also occurs in the abdominal musculature initiating retraction of the yolk sac into the coelomic cavity.<sup>122</sup> As the chick becomes more active and depletes the oxygen in the air cell, its carbon dioxide level increases to 10%, producing even stronger muscle contractions of the neck until the beak creates a puncture in the shell.<sup>122</sup> At this point the chick is breathing room air and vocalizations can be heard. External embryo structures such as the yolk sac or enlarged allantois can be accidentally ruptured during the pipping process.

Once eggs have started to pip and are transferred to the hatcher, they should be left undisturbed. As it hatches, the chick alternates between jerking head movements, which continue to chip the shell, and prolonged muscle contractions of the neck and back, which straighten the neck and force the body to rotate slightly counterclockwise. When these muscles relax, the head is in a new position, and additional jerking movements chip a different portion of the shell. During this process, called cutting out, the chick rotates within the shell 360°, cracking the shell circumferentially (see Figure 29.16). Eventually, the chick will push off the top of the shell and emerge. In most cases the process proceeds normally and a healthy chick emerges.

The average incubation period and pip-to-hatch interval of each species varies (see Table 29.7) and eggs

that deviate from these average values can successfully hatch without assistance. Premature intervention in the hatching process can cause embryonic death. Proper intervention at the correct time can definitely result in a hatched chick that would have otherwise died. The amount of assistance required is difficult to determine but it is generally best not to rush the hatching process, but to gently assist each stage as necessary. Pip-to-hatch intervals are 36 to 48 hours in most species and hatching times of less than 24 hours and greater than 80 hours usually indicate a problem.<sup>54</sup> Chicks that pip one-fourth to one-half of the egg and then stop for an extended period of time, or that reverse direction and return to the pip site, usually require assistance.<sup>68</sup>

Eggs that lose an abnormal amount of weight or contain a malpositioned chick can hatch, although hatchability is generally reduced. The timing and degree of intervention is dictated by the recession of active blood vessels, yolk sac retraction and extent of delayed hatching. A weak chick may also require assistance with hatching. Weak chicks will emit faint and infrequent vocalizations. These chicks may be normally positioned and may have appropriately entered the air cell; however, if the hatching process is delayed, the embryo may be in jeopardy.

Chicks can be safely removed from their eggs if the yolk sac and blood vessels have retracted. In general, chicks that have made one quarter of a turn during pipping can usually be safely removed from the egg. Chicks can bleed to death or rupture their yolk sacs if removed prematurely, although in some cases minor bleeding and a partially unabsorbed yolk sac must be accepted to remove a chick before death occurs. Candling or dampening the inner shell membrane with sterile water will help elucidate the position of unretracted blood vessels. Once chicks pip internally, it is important that they have an unoccluded path for air intake. Malpositioned chicks or chicks with delayed albumen ingestion may need egg shell fragments removed and fluid cleared from their nares.

If drawdown fails to occur, little can be done to assist the chick. The transition from allantoic respiration to breathing air is delicate and timely. Forcing the process will result in the death of the chick. If internal pip has occurred but external pip does not, a small hole can be safely created in the air cell to provide a source of fresh air. If there are no signs of external pip after 36 hours from drawdown, a breathing hole should be created. The breathing hole need only be a few milli-

meters in diameter and can be created using a bur with or without magnification depending on the size of the egg.

To perform an ovotomy, the egg is candled and the air cell identified and marked with a soft pencil. The shell over the air cell is cleaned with dilute chlorhexidine or povidone iodine. It is important to keep the ovotomy site totally over the air cell where there are relatively few blood vessels in the outer shell membrane. If the shell is opened over any other area of the egg, severe, life-threatening hemorrhage may occur. Vessels that are regressing take on a ghostlike appearance and are often only partially filled with blood.

If, after providing a breathing hole, external pip still does not occur, the shell should be removed over the air cell. This procedure is usually performed 48 hours after drawdown or early on the scheduled hatch date if it is accurately known.<sup>81</sup> Using a bur, the shell is removed without disrupting the outer shell membrane, which lies directly below and attached to the shell. A circular area of shell 0.5 to 1.5 cm in diameter should be removed, depending on the size of the egg. Once the shell has been removed, the outer shell membrane should be moistened with saline on a cotton-tipped applicator. Once moistened, the membrane becomes translucent, making it easy to identify any vessels that might need to be coagulated using bipolar radiosurgical forceps. After the vessels are coagulated, the membrane can be opened with the bipolar forceps revealing the chick within the air cell.

If the chick has entered the air cell, there will be a small nick in the inner membrane through which the beak has penetrated allowing respiration. The inner membrane is generally moister and more translucent than the outer shell membrane, except in the area where the beak has penetrated. In this region, the vessels retract and the membrane will usually appear dry and white. The inner shell membrane is delicate and highly vascular. The membrane should be carefully manipulated to prevent tearing. The entire exposed inner shell membrane will rapidly desiccate and should be kept moist by adding drops of warm, sterile saline or lactated Ringer's solution. Small quantities of fluids should be used to keep the chick from drowning. If the membrane is opaque, it is not properly hydrated.

At this point the position and status of the chick may be assessed. A major cause of late embryonal death is suffocation caused by occlusion of the nares by the

inner shell membrane. The bipolar forceps may be used to coagulate the vessels around the site of membrane penetration followed by the creation of a small circular defect in the membranes. Removing this tissue allows the chick to breathe and prevents the membranes from occluding the nares.

For a successful hatch to occur, there must be an increase in CO<sub>2</sub> within the air cell to stimulate the chick to struggle, which ensures retraction of the yolk sac and the break out from the egg. The hole created in the shell can be partially sealed to allow this increase in CO<sub>2</sub> to occur. A stretchable, wax type test tube sealant can be used to effectively seal the hole created in the shell. The edges should be smoothed out and the egg returned to the incubator. An alternative solution is to place the egg in a small plastic bag with moistened sterile gauze. The bag can be partially sealed to allow an increase in CO<sub>2</sub> to develop, and the moistened gauze will ensure adequate humidity.

Chicks that are slightly malpositioned may create an external pip below the air cell. Strong chicks will continue to move their head toward the air cell creating additional external pips along the way. Appearance of more than one external pip may be an indication that the chick is malpositioned and may need assistance. If the pip is properly located, the egg should be returned to the incubator with the pip up. If the pip is on the opposite end of the egg from the air cell, it is likely that the chick is inverted and will need major assistance. If the pip is close to, but not within the air cell, intervention is indicated (see Chapter 41).

### Embryo Extraction

The time period between external pip and hatching varies with species, shell thickness, incubation regimen, genetics and the strength of the chick. These factors make it difficult to determine when intervention is indicated. Embryos that enter the air cell prematurely may defecate inside the shell causing a compromise in the normal metabolic management of waste (see Figure 29.16).

When sufficient time has passed that the risk of fecal contamination is high or if the chick appears to be weakening based on decreased vocalizations and movements, the hole in the shell and shell membranes should be enlarged to allow gentle extraction of the chick's head and neck. The chick should be grasped by the beak and gently pulled out of the shell to allow visual inspection of the yolk sac (Figure

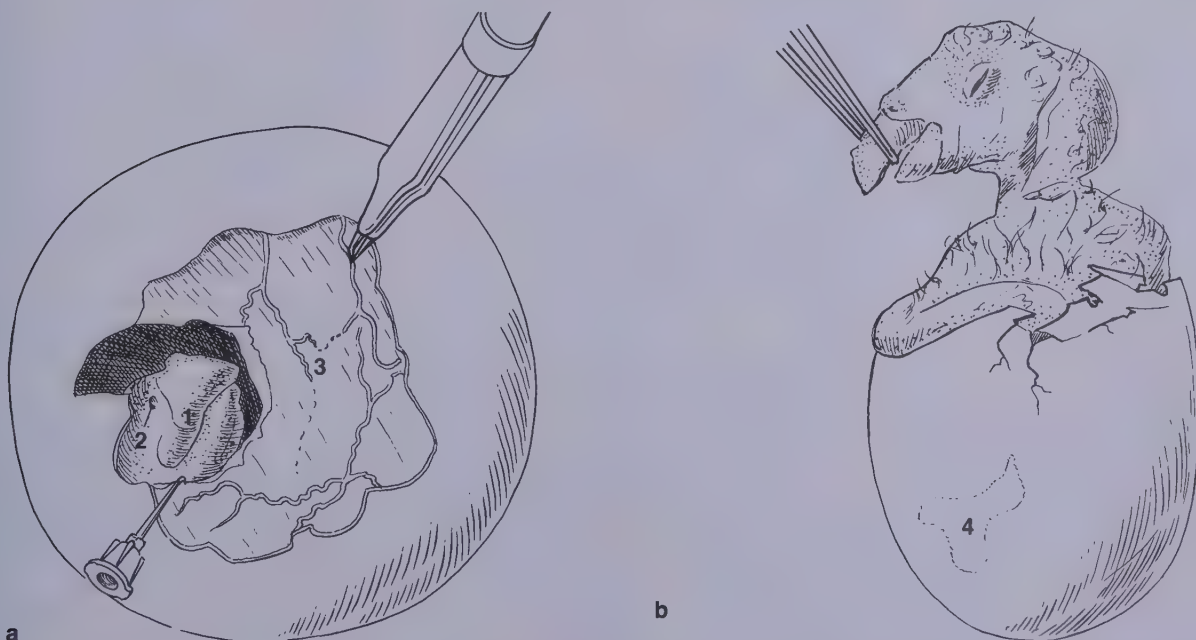


29.20). If the inner shell membranes have not adequately retracted, the yolk sac will still be visible, (incompletely absorbed). If no feces are found, the chick is gently replaced and the egg is sealed to allow hatching to proceed. The chick should be re-evaluated every one to three hours for the presence of feces. If the chick appears weak, oral administration of 5% dextrose solution may be beneficial. This can be alternated with lactated Ringer's solution to provide additional electrolytes. Since embryos are very susceptible to drowning, it is best if the solution can be placed into the esophagus or ingluvies using a 1 mm diameter silicone catheter or metal feeding tube. Excessive quantities of fluid should be avoided to prevent the accumulation of fluids in the allantois, which may increase the potential for membrane ruptures or delayed yolk sac absorption.

Once feces are observed within the shell, the chick should be removed. The chick is gently extracted with care taken to control hemorrhage from any unretracted vessels. The major attachment of the chick to the shell is in the area of the umbilicus where the vessels of the inner shell membrane attach to the yolk sac and umbilicus. The chick is extracted to a point where these vessels are visible and a vascular clip can be easily applied. The vessels are transected

using radiosurgery and the chick is completely removed from the shell.

Aggressive hatching assistance is indicated for inverted chicks to prevent their dying of hypoxia or drowning. The earliest indication that a chick is inverted is an external pip at the small end of the egg. In approximately one of three inverted chicks, the air cell will have drawn down far enough to supply the chick with air. This is beneficial as the key to saving inverted embryos is providing air and enough time to allow retraction of the yolk sac. A breathing hole should be created over the air cell, which will change the pressures within the egg and allow the embryo to slide down into the large end of the egg and the air cell to migrate to the small end of the shell.<sup>81</sup> The original pip site should be enlarged, with care taken not to damage the vessels within the membranes. If bleeding occurs it should stop in ten seconds. Sustained bleeding of chorioallantoic membranes can be stopped by applying pressure with sterile swabs or with the careful and specific application of a chemical coagulant such as silver nitrate. Experimentally, excessive bleeding can be controlled by placing injectable vitamin K sparingly on the bleeding CAM. Dehydrated chicks can be given fluids orally or subcutaneously while still in the egg. A small amount



**FIG 29.20** a) Assisting with the hatching procedure can be a life-saving procedure in some situations. The most important factor is to ensure that the chick's nostrils are clear of the shell membranes so that it can breathe. The avascular membranes can be gently teased away from the nostrils using a hooked needle. Radiocautery is used as needed to control bleeding. b) Smooth, plain pick-ups can be used to grasp the egg-tooth to elevate the head and evaluate the progression of yolk sac absorption. If the yolk sac is not absorbed, the head should be replaced, the end of the egg should be partially covered with parafilm and the egg should be returned to the hatcher. If the yolk sac is absorbed, the chick can be removed. 1) egg tooth, 2) nare, 3) receding vessels and 4) ghosted yolk sac (modified from Stoodley).<sup>165</sup>

## Theriogenology

### Color 29.19

Normal left melanistic ovary in a mature Umbrella Cockatoo hen (open arrow). The cranial, middle and caudal divisions of the kidney are clearly visible. The inactive ovary is found in its normal location at the cranial medial border of the cranial division of the kidney. The right and left adrenal glands (arrows), the ischium (i), the pubis (p) and the ureter (u) are also visible.

### Color 29.20

A 25-year-old Scarlet Macaw hen was referred with a history of egg binding that had supposedly been resolved with a hysterectomy. The hen was losing weight, regurgitating and had a distended, painful abdomen. An exploratory laparotomy indicated peritonitis and a fibrous constriction of the bowel. A side-by-side intestinal anastomosis was performed, but the bird did not recover. Necropsy findings included an abdominal egg yolk (arrow) and a fully developed left oviduct (open arrow). The abnormal development of a right ovary (also present here) can predispose a hen to reproductive problems.

### Color 29.21

Infectious salpingitis with secondary infection of the ovary. A normal follicle (arrow) is seen adjacent to degenerating, hemorrhagic follicles (open arrows). The lungs (l) are also visible (courtesy of R. Korbel).

### Color 29.22

A 23-year-old Amazon parrot hen was presented with a history of progressive abdominal swelling and weight loss. Cytology of fluid collected by abdominocentesis revealed a modified transudate. Radiographs indicated a diffuse soft tissue opacity in the intestinal peritoneal cavity that was pushing the ventriculus cranially. The bird did not respond to supportive care. The ovary (arrow) was reddish-brown, enlarged, firm and contained numerous hemorrhagic follicles. Histopathology indicated cystic follicular degeneration and bacterial hepatitis.

### Color 29.23

Grayish-yellow, nodular follicles in a gallinaceous hen with a Marek's disease virus-induced ovarian neoplasm (courtesy of R. Korbel).

### Color 29.24

a) Ovary and oviduct from a normal 22-month-old ostrich hen. Note the size of the oviduct and suspensory ligament. b) Close-up view of the ovary showing several follicles that are beginning to mature (courtesy of Brett Hopkins).

### Color 29.25

A reproductively active Sun Conure was found dead in the nest box. The bird was in excellent overall condition and had delivered a normal fertile egg two days prior to presentation. The liver was enlarged, friable and congested. Histopathology indicated acute gram-negative bacterial hepatitis. Several active ovarian follicles (arrow) and the size of the oviduct (open arrows) in a reproductively active hen are evident.

### Color 29.26

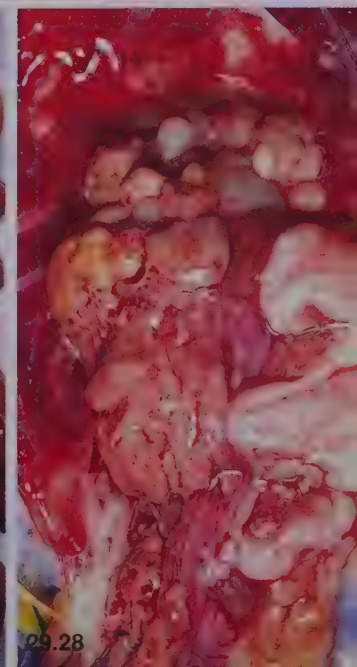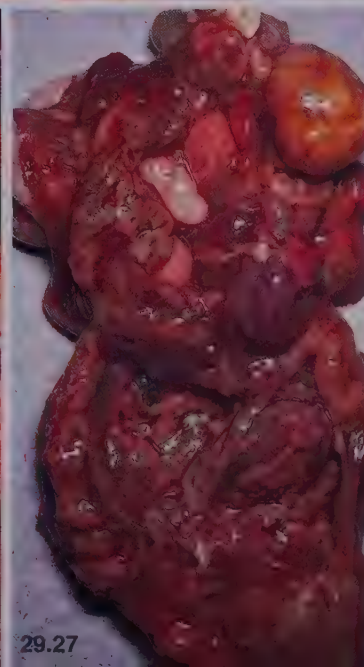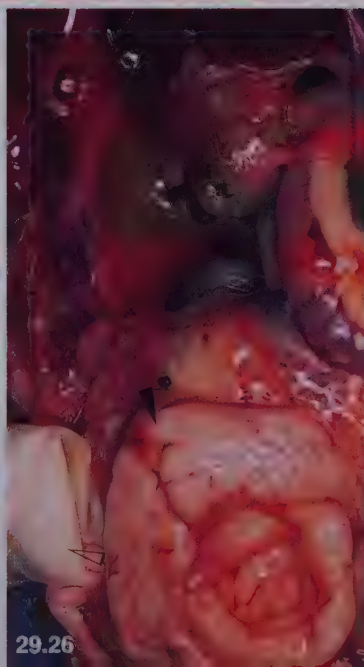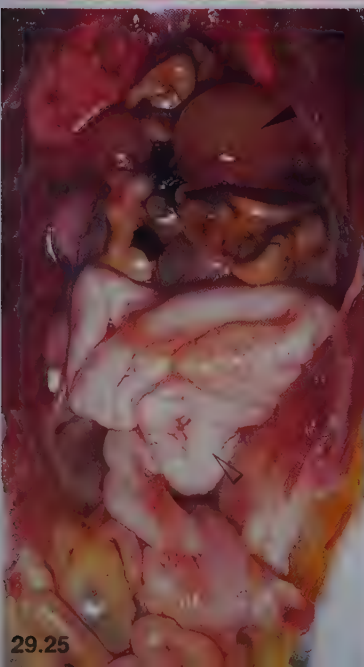
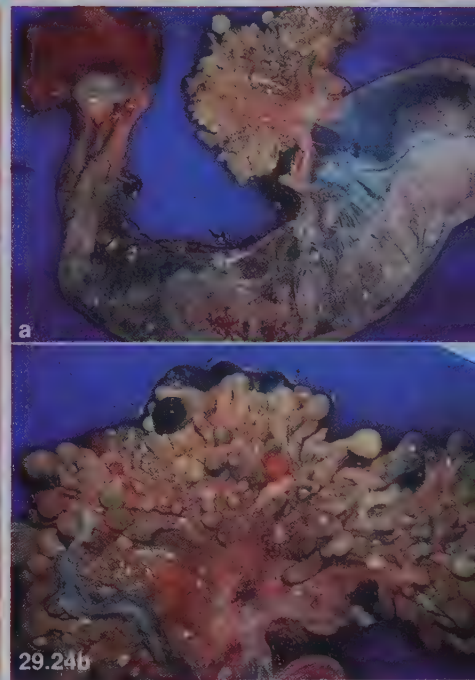

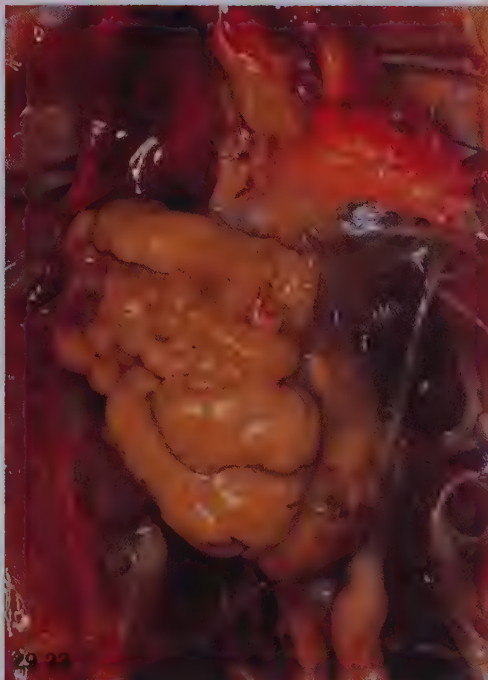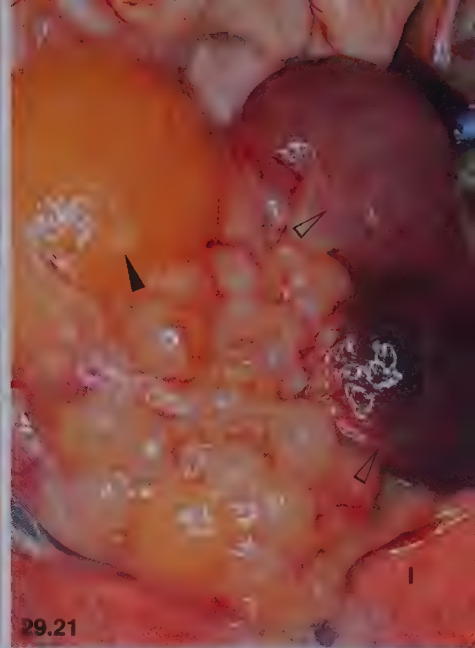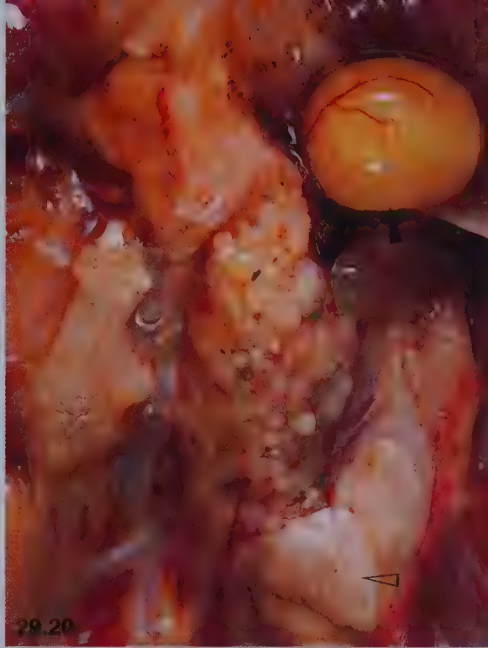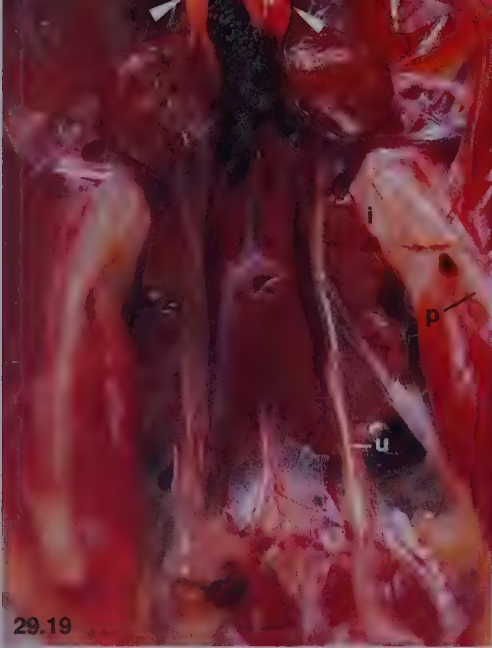An Amazon parrot hen was presented for necropsy following several days of anorexia, depression and straining to defecate. A firm mass was present in the caudal abdomen. Necropsy indicated the retention of an egg (open arrow) in the caudal portion of the uterus. The degree of dilatation and hyperemia of the uterus (arrow) are evident. Histopathology indicated bacterial salpingitis.

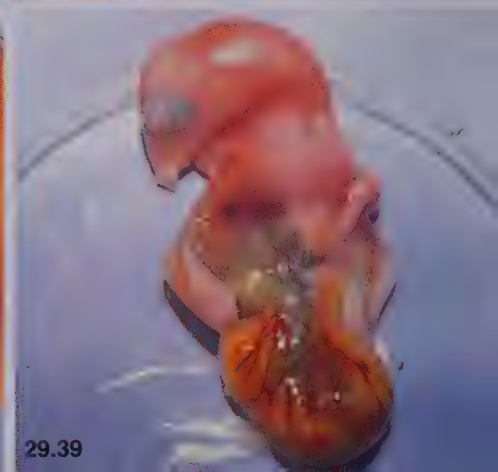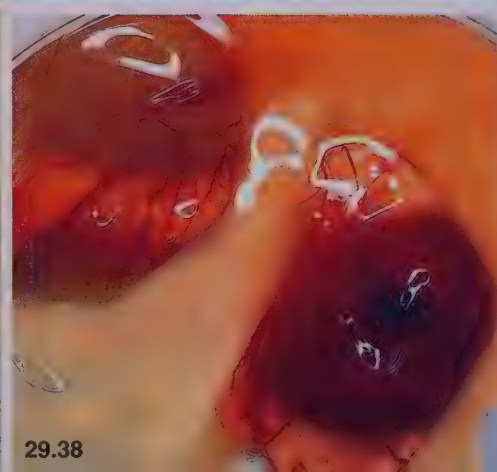
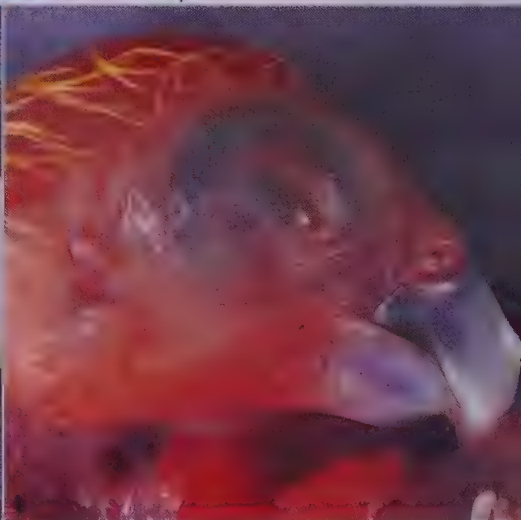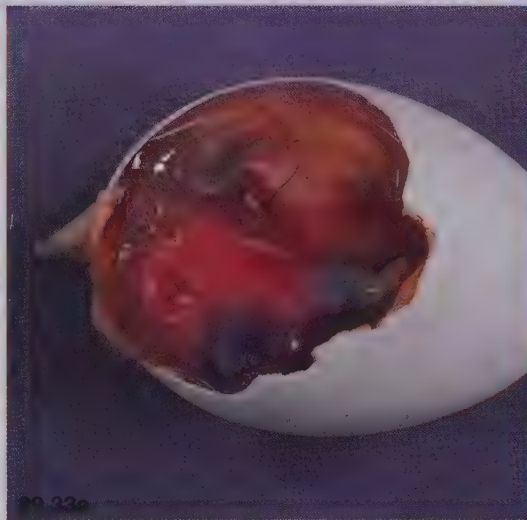
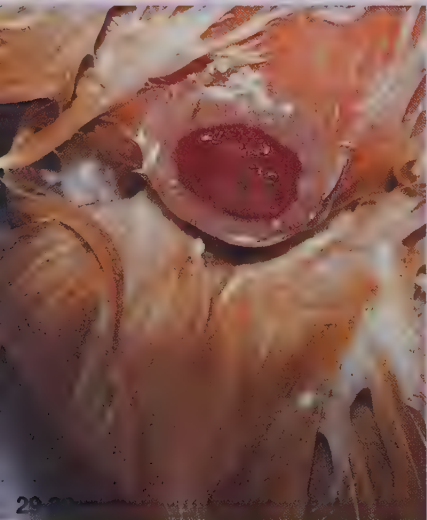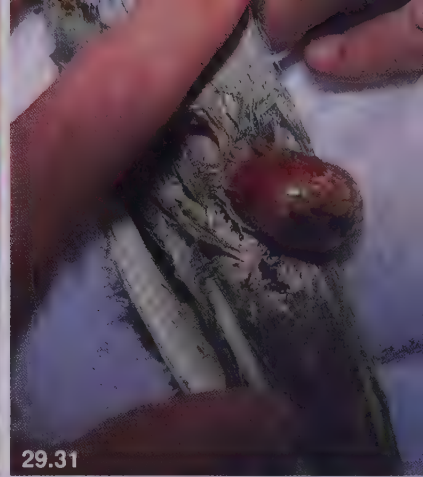
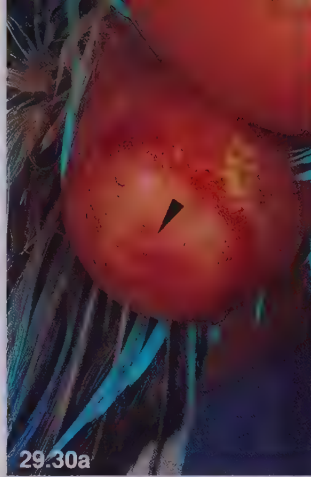
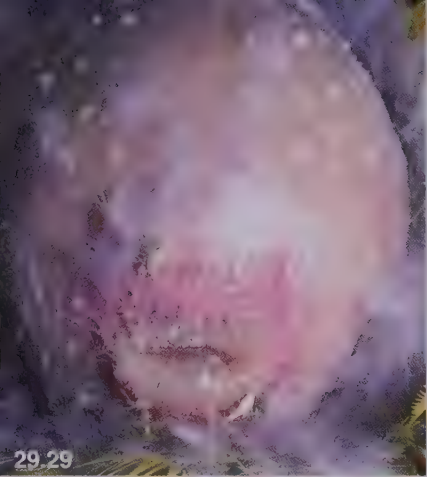### Color 29.27

An Umbrella Cockatoo hen was presented with a three-day history of depression following the delivery of its first egg of the season. Radiographs indicated a granular, soft tissue opacity in the intestinal peritoneal cavity that was pushing the proventriculus and ventriculus cranially. Clinicopathologic changes included WBC=35,000 (toxic heterophils), AST=1500, LDH=1200 and calcium=8 mg/dl. An exploratory laparotomy indicated diffuse peritonitis with adhesions throughout most of the abdominal cavity. The bird was euthanized. At necropsy, necrotic, brown, fibrous, peritonitis-related material was located on most of the abdominal organs.

### Color 29.28

Egg-related peritonitis in an Amazon parrot hen with chlamydiosis. The bacterial peritonitis was considered to have occurred secondary to the chlamydial infection.





## Theriology

### Color 29.29

Typical presentation of an impacted egg. In this conure, the excessively large egg was lodged in the caudal uterus and vagina. The egg was removed by performing oocentesis through the cloaca and collapsing the egg.

### Color 29.30

a) An impacted egg in the cloaca of a budgerigar. Note the vagina (arrow). b) The egg could be seen through the vent and was removed by performing oocentesis and gently removing the fractured portions of the eggshell.

### Color 29.31

A mature cockatiel hen was presented with a one-day history of depression and tenesmus. The client became extremely concerned when blood was noted in association with a mass protruding from the cloaca. The hen had a prolapsed uterus that contained an egg. The egg was removed and the uterus was coated with a steroid-containing antibiotic ointment and was gently replaced in the cloaca with a moistened cotton-tipped applicator. Retention sutures were placed on both sides of the cloaca. These sutures were removed two days later, and the hen had no further problems.

### Color 29.32

Mild prolapse of the vagina in the immediate post-oviposition period (courtesy of Kim Joyner).

### Color 29.33

a) A necropsy should be performed on every egg that fails to hatch. In this case, a Moluccan Cockatoo embryo pipped three days earlier than expected. The embryo was properly positioned, but the excessively large embryo was preventing the development of a normal air cell. b) Hyperemia in newly hatched chicks is characteristic of dehydration or septicemia. In this exces-

sively large (32 g) Moluccan Cockatoo embryo, the hyperemia was believed to have been caused by struggling in the egg and anoxia.

### Color 29.34

Malposition 2 in an Umbrella Cockatoo chick. Note that the head is positioned at the pointed end of the egg opposite the air cell (courtesy of Kim Joyner).

### Color 29.35

Soft-shelled eggs with depigmentation from a gallinaceous hen with salpingitis (courtesy of R. Korb).

### Color 29.36

During an egg necropsy, the membranes should be gently peeled away using fine-tipped forceps to ensure that all underlying structures are examined (courtesy of Kim Joyner).

### Color 29.37

Fungal infection in a macaw egg. Note the proliferative growths on the eggshell membranes (courtesy of Kim Joyner).

### Color 29.38

Examination of a dead-in-shell embryo should be performed sterilely to allow the collection of diagnostic culture samples. In this case, the egg has been opened and its contents have been placed in a sterile petri dish for further evaluation. The partially autolyzed, 20-day-old embryo and the yolk sac are easily distinguishable. Note the blood-tinged fluid, indicative of hemolysis.

### Color 29.39

A dead-in-shell Eclectus Parrot embryo with hemorrhage of the liver and a ruptured yolk sac. These are common findings in embryos from bacterially contaminated eggs. Note the well developed pipping muscle that is a major storage site of lymph in the developing embryo.

of air (depending upon the size of the egg) may be injected into the egg through the original pip site to infiltrate under the membrane and expand it in any areas not trapped by the shell.

The egg should then be returned to the incubator with the pip site elevated at a 45° angle. Air should be injected through the pip site every two hours for the first day. On the second day, the pip site should be enlarged. The membranes should be left dry allowing the shell to separate from the membranes more easily. During the second and third days, the membrane should be gently and very gradually torn around the pip site allowing vessels to retract between manipulations. Eventually, as the shell is removed from the small end of the egg, the yolk sac should be visualized to determine if it has retracted. Once the end of the shell and its associated membranes are removed and the yolk has retracted, the chick will usually emerge without further assistance.

Altricial birds have a relatively small yolk sac at hatching because the parent birds begin to feed the hatchlings almost immediately. Conversely, precocial birds have a relatively large internal yolk sac because they leave the nest soon after hatching. Over the subsequent several days they learn to select food items by observing the parent birds. During this time period, they maintain their nitrogen balance with the aid of the residual internalized yolk sac. The internalized yolk sac of altricial birds comprises five to ten percent of their total body weight and of precocial birds is 12 to 25%. Additionally, altricial birds use their internalized yolk sac faster than precocial birds.

Unabsorbed yolk sacs are best left unattended and allowed to fully retract. This may require leaving a chick in the egg for several hours longer than normal so that the shell protects this fragile sac. Small umbilical protuberances can generally be ignored although the chick should be handled carefully until the umbilicus is sealed. Frequent application of disinfectants such as iodine solutions will prevent infec-

tions of the umbilicus and yolk sac. Larger protuberances can be carefully placed into the abdomen with the aid of a swab dipped in a water-based sterile ointment. The umbilicus is then sutured or surgically sealed with glue.

Surgical ligation and removal of the yolk sac may be needed in cases with a persistent or very large external yolk sac (see Chapter 48). Chicks that require amputation of the yolk sac can survive but have higher mortality levels. The chick is anesthetized with isoflurane to prevent traumatic injuries to the yolk sac and a hemostatic clip is applied to the umbilicus between the chick and the yolk sac. Two sutures (8-0 to 10-0) are placed to aid in closure of the umbilical opening with care taken to place them shallow enough to avoid penetrating umbilical vessels. The hemostatic clip is outside the body and an occlusive dressing is applied to protect the umbilicus. Occasionally, herniation of intestinal contents can occur through the umbilical opening while the chick is still within the egg. The prognosis is poor in these cases, although surgical resolution of the hernia should be attempted. Exteriorized tissues should be adequately cleaned with sterile saline and kept moist with the application of ointments if necessary. Umbilical openings can be surgically enlarged if necessary to replace herniated intestines (see Chapter 41).<sup>68</sup>

*Appreciation is extended to G. J. Harrison and R. Avery Bennett for detailing the surgical aspects of assisted hatches.*

---

■ **Laboratories Mentioned in the Text**

- a. Avian Genetic Sexing Laboratory, Barlette, TN
- b. Zoogen Inc., Davis, CA
- c. A.U.D. Laboratory, Aztec, NM

## References and Suggested Reading

1. **Abbott UK:** Incubating and hatching game bird eggs. Pro Gamebird Workshop, University of Calif Cooperative Publication, 1983, pp 22-27.
2. **Alman RB:** Noninfectious diseases. In Fowler ME (ed): Zoo and Wild Animal Medicine 2nd ed. Philadelphia, WB Saunders Co, 1986, pp 497-512.
3. **Arnall I:** Further experiences with cagebirds. Vet Rec 73:1146-1154, 1961.
4. **Ashmeier LB:** Long laying intervals: A possible mechanism and its implications. Auk 102:401-409, 1985.
5. **Bacon WL, et al:** Changes in plasma calcium, phosphorus, lipids, and estrogens in turkey hens with reproductive status. Poultry Sci 59:444-, 1980.
6. **Beach JE:** Diseases of budgerigars and other cage birds. A summary of postmortem findings. Vet Rec 74:63-68, 1962.
7. **Bendheim U, et al:** Hormonal sexing versus surgical sexing in birds. Proc Europ Assoc Avian Vets, 1991, pp 115-117.
8. **Bercovitz AB, et al:** A new method of sex determination in monomorphic birds. J Zoo Anim Med 9(4):114-124, 1978.
9. **Bercovitz AB, et al:** Applications for fecal steroid analysis. Proc Intl Found Conserv Birds/Jean Delacour Symp, 1983, pp 513-523.
10. **Betzen KM:** Research report applications for an avian cloacal retractor. Assoc Avian Vet Today 1(2):61-62, 1987.
11. **Betzen KM:** Techniques for Electrical Semen Collection From Birds. Thesis, 1985, Oklahoma State University, Oklahoma.
12. **Bird DM, et al:** Embryonic death of American kestrels. Auk 101:392-396, 1984.
13. **Biswal G, Morill CC:** Pathology of reproductive tract of laying pullets affected with Newcastle disease. Poultry Sci 33:880-897, 1953.
14. **Blackmore DK, Cooper JE:** Diseases of the reproductive system. In Petrak ML (ed): Diseases of Cage and Aviary Birds 2nd ed. Philadelphia, Lea and Febiger, 1982, pp 458-467.
15. **Boord RG:** Review article: The course of microbial infection of the hen's egg. J Appl Bact 29(2):319-341, 1966.
16. **Boyd LL, et al:** Reproduction of prairie falcons by artificial insemination. J Wild Mgmt 41:266-271, 1977.
17. **Boyd LL, Schwartz CH:** Training imprinted semen donors. In Weaver JD, Cade TJ (eds): Falcon Propagation. Boise, Peregrine Fund, 1991, pp 24-31.
18. **Brice AF:** Orange-winged Amazon breeding trial. Univ Calif Exotic Bird Rpt 3(2):1-2, 1991.
19. **Broadfoot DJ, et al:** Effects of infectious bronchitis in baby chicks. Poultry Sci 35:757-760, 1956.
20. **Brock MK, et al:** Cryogenic preservation of spermatozoa of the American kestrel. Intl Zoo Yrbok 23:67-71, 1984.
21. **Brock MS:** Semen collection and artificial insemination in the Hispaniolan parrot (*Amazona ventralis*). J Zoo Wild Med 22(1):107-114, 1991.
22. **Brockway B:** Stimulation of ovarian development and egg laying by male courtship vocalization in budgerigars (*Melopsittacus undulatus*). Anim Behav 13(4):575-578, 1965.
23. **Brockway BF:** The effects of nest-entrance positions and male vocalizations on reproduction in budgerigars. The Living Bird, 1st Ann Cornell Lab Ornithol, 1962, pp 93-101.
24. **Brown AF, Anderson:** The Incubation Book. Surrey, England, Saiga Pub Co, 1983.
25. **Burley RW, Vadehra DV:** The Avian Egg Chemistry and Biology. New York, John Wiley and Sons, 1989.
26. **Burnham W:** Artificial incubation of falcon eggs. J Wild Manag 47(1):158-168, 1983.
27. **Calle PP, et al:** Gentamicin injection of incubating avian eggs. Proc Am Assoc Zoo Vets, 1989, pp 83.
28. **Clubb K, Swiger T:** Common sense incubation. In Schubot R, et al (eds): Psittacine Aviculture. Loxahatchee, ABRC, 1992, pp 9.1-9.15.
29. **Clubb S, Phillips A:** Psittacine embryonic mortality. In Schubot R, et al (eds): Psittacine Aviculture. Loxahatchee, ABRC, 1992, 10.1-10.7.
30. **Coake AS:** Shell thinning in avian eggs by environmental pollutants. Environ Pollut 4:85-152, 1979.
31. **Cooper JE:** An oviduct adenocarcinoma in a Mauritius kestrel (*Falco punctatus*). Avian Pathol 8:187-191, 1979.
32. **Cooper JE:** Veterinary problems of captive breeding and possible reinduction of birds of prey. Intl Zoo Yb 17:32-38, 1977.
33. **Cutler BA, Abbott UK:** Effects of temperature on the hatchability of artificially incubated cockatiel eggs (*Nymphicus hollandicus*). Proc 35th West Poultry Dis Conf, 1986, pp 33-34.
34. **Cutler BA, et al:** Viability of cockatiel (*Nymphicus hollandicus*) eggs stored up to ten days under various conditions. Proc 34th West Poultry Dis Conf, 1985, pp 104-106.
35. **Degernes LA:** Chronic oviduct obstruction and salpingitis in an African grey parrot. Proc Assoc Avian Vets, 1992, pp 156-157.
36. **Doty HA:** Hatchability tests with eggs from captive wood ducks. Poultry Sci 51:849-853, 1972.
37. **Dove WF:** Classification of chick-embryo positions at different ages and malposition as a cause of mortality. J Agricult Res 50(11):923-931, 1935.
38. **El-Haalawani, et al:** Incubation behavior in the domestic turkey: Physiological correlates. CJRC Crit Rev Pout Biol 1(4):285-314, 1988.
39. **Erickson CJ, Morris RL:** Effects of mate familiarity in the courtship and reproductive success of the Ring dove (*Streptopelia risoria*). Anim Behav 20:341-344, 1972.
40. **Ernst RA, Mather FB:** A review of research pertinent to life cycle lighting programs for commercial laying chickens. Proc 35th West Poultry Dis Conf, 1986, pp 43-46.
41. **Eminger AO, King JR:** Consumption of green wheat enhances photo-stimulated ovarian growth in white-crowned sparrows. Auk 98:832-833, 1981.
42. **Famer DS, Wingfield JC:** Reproductive endocrinology of birds. Ann Rev Physiol 42:457-472, 1980.
43. **Forshaw JM, Cooper WT:** Parrots of the World. New York, Doubleday & Company, Inc, 1973.
44. **Freeman BM, Vince MA:** The Development of the Avian Embryo. New York, John Wiley & Sons, 1974.
45. **Gee GF:** Avian artificial insemination and semen preservation. Proc Intl Found Conserv Birds/Jean Delacour Conf, 1983, pp 375-398.
46. **Gilbert AB, et al:** Role of atresia in establishing the follicular hierarchy in the ovary of the domestic hen (*Gallus domesticus*). J Reprod Fert 69:221-227, 1983.
47. **Gorham SL, Olinger MA:** Sertoli cell tumors in Japanese quail. Avian Dis 30(2):337-339, 1986.
48. **Graham DL:** Internal papillomatous disease. Proc Assoc Avian Vets, 1988, p 31.
49. **Grau CR:** Egg formation. In Whitlow GC, Rahn H (eds): Seabird Energetics, 1984, pp 33-57.
50. **Grisamore SB, Hile JP, Ohen RS:** Pesticide residues on grain products. A Assoc Cereal Chemists 36:434-437, 1991.
51. **Gwinner H, et al:** Effects of nestboxes on LH, testosterone, testicular size, and the reproductive behavior of male European starlings in spring. Behavior 103:68-82, 1987.
52. **Hafez, et al:** Aflatoxin and aflatoxicosis II. Effects of aflatoxins on ovaries and testicles in mature domestic fowls. Mycopathologia 77, 137-139, 1982.
53. **Hagen MH:** Artificial incubation applied to small numbers of altricial bird eggs. Proc Avian Pediat Sem Avian Res Fund, 1990, pp 91-105.
54. **Haigh R:** The breeding and artificial incubation of hawks, buzzards, and falcons. Intl Zoo Yearbook 23:51-58, 1984.
55. **Hamburger V, Hamilton HL:** A series of normal stages in the development of the chick embryo. J Morphol 88:49-89, 1951.
56. **Harrison G, et al:** Roundtable discussion: Emergency medicine. J Assoc Avian Vet 6(1):10-15, 1992.
57. **Harrison GJ, et al:** A clinical comparison of anesthetics in domestic pigeons and cockatiels. Proc Assoc Avian Vet, 1985, pp 7-22.
58. **Harrison GJ, Wasmund D:** Preliminary electrostimulation to facilitate manual semen collection in psittacines. Proc Assoc Avian Vets, 1983, pp 207-213.
59. **Harrison GJ:** Clinical use of cloacal retractor. Assoc Avian Vet Today 1(2):62, 1987.
60. **Harrison GJ:** First psittacine produced by artificial insemination. Watchbird 9:36, 1982.
61. **Harrison GJ:** Progesterone implants in cases of chronic egg laying. Proc Assoc Avian Vets, 1989, pp 6-10.
62. **Harrison, GJ:** Reproductive medicine. In Harrison GJ, Harrison LR (eds): Clinical Avian Medicine and Surgery. Philadelphia, WB Saunders, 1986, pp 620-633.
63. **Harry EG:** The effect on embryonic and chick mortality of yolk contamination with bacteria from the hen. Vet Rec 69:1433-1439, 1957.
64. **Hartz N:** A guide to birds with sexual color differences. Bird World 14(2):10-15, 1991.
65. **Harvey R:** Practical Incubation. Sudbury, Suffolk England, Payn Essex Printers Ltd, 1990.
66. **Hasholt J:** Disease of the female reproductive organs of pet birds. J Small Anim Pract 32:313-320, 1966.
67. **Hassan A, Al-Rawi BA:** Importance of temperature and humidity for layers. World Rev Anim Prod 18(3):43-48, 1982.
68. **Heck WR, Konkel D:** Incubation and rearing. In Weaver JD, Cade TJ (eds): Falcon Propagation. Boise, Peregrine Fund, 1991, pp 34-76.
69. **Hicks KD:** Ratite reproduction. Proc Assoc Avian Vets, 1992, pp 318-325.
70. **Hicks KD:** Ratite Reproduction. Proc Avian Exotic Animal Med Symp, 1991, pp 182-187.
71. **Hinde RA, Putman RJ:** Why budgerigars breed in continuous darkness. J Zool Lond 170:485-491, 1973.
72. **Hochleitner M, Lechner C:** Egg binding in a budgerigar caused by a cyst of the right oviduct. Assoc Avian Vet Today 2(3):136-138, 1988.
73. **Hudelson S, Hudelson P:** Egg binding, hormonal control and therapeutic considerations. Comp Cont Ed 15:427-432, 1993.
74. **Hungerford TG:** Diseases of Poultry, Including Cage Birds and Pigeons 4th ed. Sydney Australia, Angus and Robertson, 1969.
75. **Huntingdon:** Reproductive apparatus of the female. In Murton RK, Westwood NJ (eds): Avian Breeding Cycles. Oxford, England, Oxford University Press, 1977.
76. **Hutt FB, Pilkey AM:** Studies in embryonic mortality in the fowl. V. Relationships between positions of the egg and frequencies of malpositions. Poultry Sci 13:3-13, 1934.
77. **Immelmann K:** Ecological aspects of periodic reproduction. In Farnar DS, et al (eds): Avian Biology Vol 1. 1971, pp 341-389.
78. **Irwin LN, Crawford WC:** Psittacine artificial insemination. Watchbird Aug/Sept:43-47, 1990.
79. **Johnson AL:** Reproduction in the female. In Sturkie PD (ed): Avian Physiology 4th ed. New York, Springer-Verlag, 1986, pp 403-431.
80. **Johnson AL:** Reproduction in the male. In Sturkie PD (ed): Avian Physiology 4th ed. New York, Springer-Verlag, 1986, pp 432-451.
81. **Jordan R:** Parrot Incubation Procedures. Ontario, Canada, Silvio Mattachione and Co, 1989.
82. **Joyner KL:** Health parameters of wild psittacines in Guatemala: A preliminary report. Proc Assoc Avian Vets, 1992, pp 146-152.
- 82a. **Joyce DA, Chaplin NRC:** Hygiene and hatchability of duck eggs—a field study. Vet Rec 103:9-12, 1978.
83. **Keymer IF:** Diseases of birds of prey. Vet Rec 90:579-594, 1972.
84. **Keymer IF:** Disorders of the avian female reproductive system. Avian Pathol 9:405-419, 1980.
85. **Keymer IF:** The diagnosis and treatment of some diseases of seed-eating passerine birds. Mod Vet Pract 40:30-34, 1959.
86. **King AS, McLelland J:** Birds - Their Structure and Function 2nd ed. London, Bailliere Tindall, 1984.
87. **Kingston N:** Trematodes. In Hofstad MS et al (eds): Diseases of Poultry 8th ed. Ames, Iowa State University Press, 1984, pp 668-690.
88. **Kirkwood JK:** Management of a colony of common kestrels (*Falco tinnunculus*) in captivity. Lab Anim 14:313-316, 1980.
89. **Klea JA:** Incubation, incubators, and problem solving. Proc Avian Pediat Sem Avian Res Fund, 1990, pp 79-88.
90. **Knox CW, Olsen MW:** The effect of tremulous air cells upon the hatchability of eggs. Poultry Sci 15:345-348, 1936.
91. **Kono K, Hiura Y:** Semen collection by rectal electro ejaculation of the domestic fowl. Jap Poultry Sci 20:267-270, 1983.
92. **Kuehler C, Good J:** Artificial incubation of bird eggs at the Zoological Society of San Diego. Intl Zoo Yb 29:118-136, 1990.
93. **Kuehler C, Witman PN:** Artificial incubation of California Condor *Gymnogyps californianus* eggs removed from the wild. Zoo Biol 7:123-132, 1988.
94. **Kuehler C:** Artificial incubation and hand-rearing of pigeons and doves. Proc Am Assoc Zoo Parks & Aquar, 1989, pp 679-685.
95. **Lake PE, et al:** Long distance transportation of fowl semen by air. Vet Rec 71:52, 1959.
96. **Langenberg J:** Pathological evaluation of the avian egg. Proc Am Assoc Zoo Vet, 1989, pp 78-82.
97. **LaPointe J:** Comparative physiology of neurohypophysial hormone action

- on the vertebrate oviduct-uterus. *Amer Zool* 17:763-773, 1977.
98. **LaRue C, Hoffman K:** Artificial incubation and hand-rearing cranes. *Intl Zoo Yearbook* 21:215-217, 1981.
99. **Lies J, Grone D:** A reproductive disorder occurring in post-puberal cocks. *Teirarztl Umsch* 18:443-445, 1963.
100. **Lofts B, Murton RK:** In Farmer DS, King JR (eds): *Avian Biology* Vol 3. New York, Academic Press, 1973, pp 1-107.
101. **Low R:** Parrots. Their Care and Breeding 2nd ed. Poole, Blandford Press, 1986.
102. **Lowenshine LJ:** Avian anatomy and its relation to disease processes. *Proc Assoc Avian Vets*, 1983, pp 1-9.
103. **Mace ME:** A self-contained portable candler used for monitoring embryonic development in avian eggs. *Avicult Mag* 95(2):87-91, 1989.
104. **Martin HD:** Avian reproductive emergency surgical management. *Vet Med Report* 2:250-253, 1990.
105. **McCaples, et al:** Antibiotic egg injection to eliminate disease. I. Effect of injection methods on turkey hatchability and *Mycoplasma meleagridis* infection. *Avian Dis* 21(1):57-68, 1977.
106. **McDonald SE:** Anatomy and physiology of avian reproductive systems. *Proc Am Fed Avic Vet Sem*, 1989, pp 37-50.
107. **McDonald SE:** Clinical experiences with cloaca papillomas. *Proc Assoc Avian Vets*, 1988, pp 27-30.
108. **McDonald SE:** Injecting eggs with antibiotics. *J Assoc Avian Vet* 1(1):9, 1989.
109. **Menge H, et al:** Effect of vitamin D<sub>3</sub> and calcium on the reproductive characteristics of the turkey hen. *Poult Sci* 56(5):1472-1480, 1977.
110. **Millam JR, et al:** Influence of environmental manipulation and nest-box availability on reproductive success of captive cockatiels (*Nymphicus hollandicus*). *Zoo Biol* 7:25-34, 1988.
111. **Millam JR:** Stimulating reproduction in orange-winged Amazons. *Univ Calif Exotic Bird Rpt* 2(2):1-2, 1990.
112. **Millam JR:** Turning off egg production: The role of eggs in the nest. *Univ Calif Exotic Bird Rpt* 2(3):1-2, 1990.
113. **Morgan WC, Greb RJ:** Genetic and evolutionary aspects of double oviducts in gallus. *Poult Sci* 88:1456-1462, 1989.
114. **Muser KK, Parrott T:** Necropsy techniques on baby birds. *Proc Assoc Avian Vets*, 1990, pp 115.
115. **Myers SA, et al:** Plasma LH and prolactin levels during the reproductive cycle of the cockatiel (*Nymphicus hollandicus*). *Gen & Comp Endoc* 73:85-91, 1988.
116. **Myers SA, et al:** Reproductive success of hand-reared vs. parent-reared cockatiels (*Nymphicus hollandicus*). *Auk* 105:536-542, 1988.
117. **Nagra KE, et al:** Cloacal glands in Japanese quail (*Coturnix coturnix japonica*): Histogenesis and response to sex steroids. *Anatom Rec* 133:415, 1959.
118. **Nalivaiko LK:** A disease of the genital organs of geese caused by species of neisseria. *Veterinariia (Moskva)* 10:60-61, 1983.
119. **Nath R, Singh CM:** Studies on pathology of urogenital tract of poultry I. Pathology of genital tract. *Haryana Agricult Univ J Res*:1106-111, 1971.
120. **Ojane M, et al:** Metastaseous adenocarcinoma in the oviduct of a great tit (*Papua major*) preventing laying. *Acta Zoologica et Pathologica Antverpiensia* 62:143-148, 1975.
121. **Olsen GH, et al:** A review of some causes of death of avian embryos. *Proc Assoc Avian Vets*, 1990, pp 106.
122. **Olsen GH:** Problems associated with incubation and hatching. *Proc Assoc Avian Vets*, 1989, pp 262.
123. **Orosz SE:** Avian reproductive medicine: A review. *Proc Assoc Avian Vets*, 1990, pp 365-368.
124. **Parks JE, et al:** Cryopreservation of peregrine falcon semen and post-thaw dialysis to remove glycerol. *Raptor Res* 20:16-20, 1986.
125. **Patterson PH, et al:** Hatching eggs sanitized with chlorinedioxide foam: Egg hatchability and bactericidal properties. *Avian Dis* 34:1-6, 1990.
126. **Peakall DB, et al:** Blood calcium levels and the mechanism of DDE-induced eggshell thinning. *Environ Pollut* 9:289-294, 1975.
127. **Peckham MC:** Reproductive disorders. In Biester HE, Peckham MC (eds): *Diseases of Poultry* 5th ed. Ames, Iowa State University Press, 1965, pp 1201-1205.
128. **Povlin N, et al:** Evaluation of the sterile male method on red-winged blackbirds: Effects of the chemosterilant thioptea on the reproduction of clinically treated birds under field conditions. *Can J Zool* 60(10):2337-2343, 1982.
129. **Pradhan HK, Nayak BC:** Studies on pathology of the female reproductive tract of domestic fowls. II. Experimentally induced oophoritis and egg peritonitis with *E. coli* organisms. *Indian J Vet Med & Anim Husb* 38:737-746, 1968.
130. **Rahn H, Ar A:** The avian egg: Incubation time and water loss. *Condor* 76:147-152, 1974.
131. **Ratcliffe DA:** Changes attributable to pesticides in egg breakage frequency and eggshell thickness in some British birds.
132. **Reece, RL:** Reproductive diseases. In Burr E (ed): *Companion Bird Medicine*. Ames, Iowa State University Press, 1987, pp 89-100.
133. **Rewell RE:** Seminoma of the testis in a collared turtle dove. *J Path Bact* 60:155, 1948.
134. **Richie BW, Niagro FD, Latimer KS, et al:** Antibody response to and maternal immunity from an experimental PFD virus vaccine. *Am J Vet Res* 53:1512-1518, 1992.
135. **Romanoff AL, Romanoff AJ:** Pathogenesis of the Avian Embryo. New York, Wiley-Interscience, 1972.
136. **Romanoff AL:** Critical periods and causes of death in avian embryonic development. *Auk* 66:264-271, 1966.
137. **Romanoff AL:** The Avian Embryo. New York, MacMillan Co, New York, 1960.
138. **Romijn C, Roos J:** The air space of the hen's egg and its changes during the period of incubation. *J of Physiol (London)* 94:365-379, 1938.
139. **Roskopf WJ, Woerpel RW:** Cloacal conditions in pet birds with a cloacexy update. *Proc Assoc Avian Vets*, 1989, pp 156-163.
140. **Roskopf WJ, Woerpel RW:** Egg binding in caged and aviary birds. *Mod Vet Pract* 65:437-440, 1985.
141. **Roskopf, WJ, Woerpel, RW:** Pet avian obstetrics. *Proc 1st Intl Conf Zool & Avian Med*, 1987, pp 213-231.
142. **Roudybush TE, Grau CR:** Calcium requirements for egg laying in cockatiels. *Am Fed Avic Watchbird* 18(1):10-13, 1991.
143. **Rowley I, Chapman G:** Cross-fostering, imprinting and learning in two sympatric species of cockatoo. *Behavior* 96:1-16, 1986.
144. **Rzasa, J:** The effect of arginine vasotocin on prostaglandin production of the hen uterus. *Gen Comp Endocrin* 53:260-263, 1984.
145. **Samour JH, et al:** Semen collection and spermatozoa characteristics in budgerigars (*Melopsittacus undulatus*). *Vet Rec* 118:397-399, 1986.
146. **Samour JH, et al:** Semen cryopreservation and artificial insemination in budgerigars. *J Zool Lond* 216:169-176, 1988.
147. **Samour JH et al:** Seminal plasma composition in budgerigars (*Melopsittacus undulatus*). *Comp Biochem Physiol* 84A(4):735-738, 1986.
148. **Schivanandappa TM, et al:** Testicular dystrophy in *Gallus domesticus* fed acute doses of copper fungicides. *Poult Sci* 62:405-408, 1983.
149. **Schlumberger HG:** Polyostotic hyperostosis in the female parakeet. *Am J Path* 35(1):1-23, 1959.
150. **Schmitz C:** Incubation and troubleshooting the "problem" egg. *Am Fed Avic Watchbird* 16(5):26-32, 1989.
151. **Sell J:** Incidence of persistent right oviducts in the chicken. *Poult Sci* 38:33-35, 1959.
152. **Sexton TJ, Gee GF:** A comparative study on the cryogenic preservation of semen from the sandhill crane and the domestic fowl. *Symp Zool Soc Lond* 43:89-95, 1978.
153. **Sharlin JS, et al:** Effect of dietary aflatoxin on reproductive performance of white leghorn males. *Poult Sci* 57(4):1162, 1978.
154. **Sharlin JS, et al:** Sperm head length as a predictor of ecundity in the sandhill crane, *Grus canadensis*. *J Reprod Fert* 55:411-413, 1979.
155. **Sharma DN, Singh, CM:** Studies on pathology of female genital tract of poultry with special reference to egg peritonitis incidence, patho-anatomy and experimental study. *Indian J Poultry Sci* 8:81-86, 1973.
156. **Shields KM, et al:** Reproductive behavior and LH levels of cockatiels (*Nymphicus hollandicus*) associated with photo-stimulation, nest-box presentation, and degree of mate access. *Hormones and Behav* 23:68-92, 1989.
157. **Shimada K, Asai I:** Effects of prostaglandin E<sub>2</sub> alpha and indomethacin on uterine contraction in hens. *Biol Reprod* 21:523-527, 1979.
158. **Silva T:** Psitticulture, Breeding, Rearing, and Management of Parrots. Pickering, Canada, Silvio Mattacchione & Co., 1991.
159. **Singh MP, et al:** Studies on the incidence of egg-peritonitis, salpingitis and oophoritis in laying hens. *Indian Vet Med J* 1:38-42, 1977.
160. **Smith RE:** Hysterectomy to relieve reproductive disorders in birds. *Avian Exotic Prac* 2:40-43, 1985.
161. **Snayenbos GH, Carlson VL:** Gentamicin efficacy against *Salmonella* and *Arizona* in eggs as influenced by administration route and test organism. *Avian Dis* :673-682, 1973.
162. **Speer BL:** A clinical approach to psittacine infertility. *Proc Assoc Avian Vets*, 1991, pp 173-187.
163. **Steel E, Hinde RA:** Effect of exogenous serum gonadotrophin (PMS) on aspects of reproductive development in female domesticated canaries. *J Zool Lond* 149:12-30, 1966.
164. **Steel E, Hinde RA:** *J Reprod Fert* 31:425-431, 1972.
165. **Stoodley J, Stoodley P:** Parrot Production. Portsmouth, England, Bezel Pub, 1983.
166. **Stromberg J:** A Guide to Better Hatching. Stromberg Publishing Co, Fort Dodge, Iowa, 1975.
167. **Stromberg L:** Sexing all Fowl, Baby Chicks, Gamebirds, Cage Birds. Pine River Minnesota, Stromberg Publ Comp, 1977.
168. **Sturkie PD, Opel H:** Reproduction of the male, fertilization, and early embryonic development. In Sturkie PD (ed): *Avian Physiology* 3rd ed. New York, Springer-Verlag, 1976, pp 331-347.
169. **Takehita K:** Correlation of weather changes and egg production in large parrots. Aviculture Institute, Newhall, unpublished, 1985.
170. **Tarsnane S:** Waterfowl: A Guide to Management and Propagation. Tarsnane Productions, Billings, Montana, 1985.
171. **Taylor M:** Endoscopic examination of ovarian morphology in juvenile psittacine birds - preliminary findings. *Proc Assoc Avian Vets*, 1988, pp 33-34.
172. **Taylor M:** Endoscopy. *Proc Assoc Avian Vets*, 1991, pp 21-26.
173. **Temple SA:** Artificial insemination with imprinted birds of prey. *Nature* 237:287-288, 1972.
174. **Thaxton JP, Paarkhurst CR:** Abnormal mating behavior and reproductive dysfunction caused by mercury in Japanese quail. *Proc Soc Exp Biol Med* 144:252-255, 1973.
175. **Toone-Kuehler C:** Causes of embryonic malformations and mortality. *Proc Am Assoc Zoo Vet*, 1983, pp 167-170.
176. **Uhrin V:** Follicle atresia in the growing ovary of fowl. *Vet Med (Praha)* 29(3):181-188, 1984.
177. **Valsala KU, Sivadas CG:** Salpingitis in the hen. *Kerala J Vet Sci* 2:105-108, 1971.
178. **Van Sant F:** Resolution of a cloacal adhesion in a blue-fronted Amazon. *Proc Assoc Avian Vets*, 1992, pp 162-164.
179. **Van Tienhoven A:** Environment and reproduction of pet birds. *Proc Assoc Avian Vets*, 1983, pp 110-161.
180. **VanderHeyden N:** Psittacine papilloma. *Proc Assoc Avian Vet*, 1988, pp 23-25.
181. **Warburton T:** Breeding and reintroduction of the barn owl. *Intl Zoo Yearbook* 23:88-96, 1984.
182. **Warren RP, Hinde RA:** Does the male stimulate oestrogen secretion in female canaries? *Science* 133:1354-1355, 1961.
183. **Weaver JD, Cade TJ:** Falcon Propagation. Ithaca, The Peregrine Fund Inc, 1985.
184. **Weaver JD:** Artificial insemination. In Weaver JD, Cade TJ (eds) *Falcon Propagation*. Boise, Peregrine Fund, 1991, pp 19-23.
185. **Webb DH, et al:** Cystic testicular degeneration in furazolidone toxicosis of sexually immature ducks. *Avian Dis* 34:693-709, 1990.
186. **Windle WF, Scharpenburg LG, Steel AG:** Influence of CO<sub>2</sub> and anoxemia upon respiration in the chick at hatching. *Am J Phys* 121:692-699, 1938.
187. **Wisman MA:** Unusual C-section and hysterectomy in the Isle of Pines Amazon. *Proc Assoc Avian Vets*, 1991, pp 265-266.
188. **Woodford MH:** A Manual of Falconry. Surrey, England, Gresham Press, 1966, p 33.
189. **Wyndham E:** Aspects of biorhythms in the budgerigar *Melopsittacus undulatus*, a parrot of inland Australia. *Proc XVII Intl Ornithol Cong*, 1978, Vol 1, pp 485-491.
190. **Yamamoto JT, et al:** Reproductive activity of force-paired cockatiels (*Nymphicus hollandicus*). *Auk* 106:86-93, 1989.
191. **Yokoyama K, Farmer DS:** Photoperiodic responses in bilaterally enucleated female white-crowned sparrows. *Zonotrichia leucophrys gambelii*. *Gen Comp Endocrin* 30:528-533, 1976.



**C**are of pediatric patients is becoming an important segment of avian medicine as legislation and economic factors continue to restrict the importation of wild-caught psittacine birds. Because most birds entering the pet trade come from domestic sources, it is to the advantage of avian practitioners to become knowledgeable in avicultural and pediatric medicine.

Birds may be classified according to their state of maturity at hatching. Precocial birds such as pheasants, ostriches and waterfowl are covered with down and are able to see, walk and feed themselves at hatching. Altricial species such as psittacine birds, song birds and pigeons are helpless at hatch. Most altricial birds are born naked with their eyes closed and depend totally on their parents for food and warmth. Neonates lack a fully competent immune system and are more susceptible to disease than older birds. Because they are helpless, the conditions under which they are maintained, the diet they are fed and the amount of parental care they receive all have a profound influence on their health.

Genetics, incubation and nutrition all affect the early survivability and growth of the chick. A chick with a poor start may develop clinical problems much later in life.

CHAPTER

---

# 30

NEONATOLOGY

---

■  
**Keven Flammer**  
**Susan L. Clubb**

## Options for Raising Birds

Chicks can be raised by their parents, by avian foster parents or by humans (hand-raised). Each of these options has particular advantages and disadvantages.<sup>9,18</sup>

### Parent-raising

Allowing the parents to raise their own offspring has some advantages if the parents provide adequate care. It saves the considerable labor associated with hand-feeding, and parent-raised chicks usually develop faster (Figure 30.1). Parent-raised birds may also acquire species-specific behavioral traits that may be lacking in hand-raised chicks. For example, hand-raised Thick-billed Parrot chicks failed to show normal flocking behavior, suggesting that parent-raised chicks may be more desirable for reintroduction programs. Roudybush found that compared to parent-raised birds, hand-raised male cockatiels inseminated females less frequently, and hand-raised females laid more eggs but often failed to lay them in the nest box.<sup>30</sup> This work has not been repeated in other psittacine species. It is known that hand-raising does not prevent normal breeding behavior, and many aviculturists believe that hand-raised chicks are better adapted to captivity and will breed sooner than chicks raised by other means.

There are disadvantages to leaving nestlings with the parents. Captive parents do not always provide optimal care and may traumatize, fail to feed, improperly feed or abandon chicks, especially if there



**FIG 30.1** Allowing parents to raise neonates saves time and would be indicated for any offspring being considered for breeding or reintroduction to the wild. Hand-raised birds may make better pets (courtesy of Deanna Shafar).

are disturbances in the aviary (Color 30.9). The chicks may also be exposed to diseases carried by the parents. Chicks that are parent-raised beyond the pin-feather stage are also more difficult to tame and are less suitable as pets. Many aviculturists elect to hand-raise the larger, more expensive psittacine birds. Parent-raising is most often used with small, highly productive species such as cockatiels, lovebirds and budgerigars where the cost of hand-raising is difficult to recover upon sale of the bird.

### Fostering

Fostering refers to moving eggs or babies from one nest to another. Some bird species (eg, Society Finches and canaries) make excellent foster parents and will feed neonates from species other than their own. Fostering is necessary when chicks are from neglectful or abusive parents or when there are large differences in the sizes of the chicks or between the times the eggs hatch. Fostering may also be used to increase production by removing eggs from a productive pair, which will stimulate them to lay more eggs. In most cases it is desirable to foster eggs rather than chicks, and the foster nest should have eggs or chicks of a similar age. Society Finches may foster chicks of any age. Fostering may spread disease, and the medical histories of both sets of parents should be established before considering cross-fostering.

### Hand-raising

Aviculturists may hand-raise birds for the following reasons:

- To produce a tame bird that will socialize with people.
- To increase production by encouraging a pair of birds to lay additional clutches.
- To raise offspring hatched from artificially incubated eggs.
- To save sick or abandoned offspring.
- To reduce the burden of parental care on a compromised parent.
- To prevent or reduce the transmission of diseases from the parents to the neonate.

The disadvantages of hand-raising include the intensive labor required to feed birds and the threat of disease outbreaks that can occur when multiple nestlings from different pairs are concentrated in a nursery. Hand-raised birds seldom gain weight as quickly in the initial week of growth as parent-raised chicks; however, they usually compensate later and wean at a normal weight.

### Problems Associated with Parent-raised Birds

Nestling birds are most likely to have medical problems during the first week of life, at fledging and at weaning. Monitoring the condition of parent-raised offspring in the nest box can be difficult. Semi-domesticated species such as budgerigars, cockatiels, finches and lovebirds may tolerate repeated evaluation and handling of their offspring. Larger psittacine birds are usually protective of the nest box, and the aviculturist should establish a routine of examining the nest box daily to condition the birds to this procedure. Nest boxes should be constructed with a small door that can be used for viewing the chicks and examining the eggs. A fiberoptic light and mirror may be helpful.

Chicks receiving adequate parental care will have food in their crops and yellowish-pink skin (Color 30.3). Chicks that have empty crops, act listless and are cool to the touch are receiving inadequate care and should receive immediate attention. These chicks may be hypothermic, hypoglycemic, dehydrated or have bacterial or yeast infections. The solution to many of the problems associated with parent-raised neonates is to remove them for hand-raising. Care of the critically ill neonate is described in the section on hand-raising.

#### Parental Problems

Parenting is a learned process and captive birds do not always make ideal parents, especially with the first few clutches. Parents may eat, traumatize or abandon the eggs or the chicks. Some parents never learn to provide adequate care; others may learn to provide improved care with subsequent clutches. Disturbances in the aviary will increase parental problems. Most psittacine birds lay eggs every two to three days and start incubation when the first egg is laid. Highly productive species such as cockatiels may lay an additional clutch before fledging chicks from the previous lay. These adults may remove the feathers from the chicks in an attempt to encourage them to leave the nest.

#### Nestling Problems

A healthy nestling will interact with the parents and elicit feeding activity by displaying a food-begging behavior. Any factor that decreases the vigor of the chicks (disease, cold,

competition) can decrease their chances of being properly fed. Often the older and more vigorous chicks will compete most efficiently for food and parental attention, causing younger chicks to be neglected and undernourished.

#### Environmental Problems


Nestlings in a hot, cold or damp nest box may be stressed, fail to beg for food or be abandoned (Figure 30.2). Improper nest material may be ingested or inhaled or may support the growth of bacteria and fungi. Rats, snakes and other predators may consume nestlings or disturb the parents and prevent regular feedings. Disturbances of the nest box may cause parents to neglect or traumatize chicks.

#### Injuries

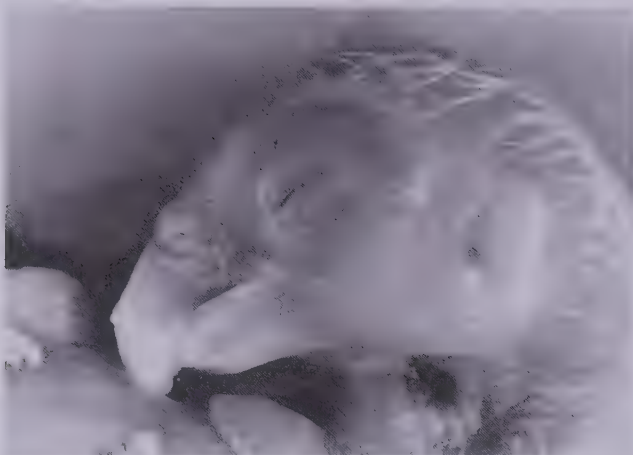
Nestlings may be injured by their parents, other nestlings or improper nest box construction (eg, exposed nails, slippery nest material). Poor nutrition can cause metabolic bone disease and make the chicks more susceptible to fractures. Many of the larger psittacines are territorial and may traumatize the nestlings when defending the nest. To prevent these injuries, the nest box can be equipped with a sliding door over the entrance hole to exclude the parents from the nest box while chicks are being examined. Chicks may also traumatize each other, most frequently injuring the beak, face and wing tips.

#### Infectious Diseases

Microbial infections (gram-negative bacteria, chlamydia, viruses and yeast) and internal parasites (eg, giardia and trichomoniasis) are frequent causes of mortality in nestling birds (Figure 30.3). Common sources include adult birds (which may be asympto-



**FIG 30.2** Chicks may be abandoned in the nest if the parents are inexperienced, if insufficient types and quantities of food are available, if the neonate does not properly beg for food, or if the nest box is cold, hot, damp or infested with vermin. Chicks that are being raised by the parents should be observed daily, if the parents will allow it, to ensure they are receiving proper care. Neonatal mortalities may indicate disease or management-related problems within the collection that can be identified by postmortem examination.



**FIG 30.3** Any neonate or embryo that dies should be submitted for necropsy and histopathologic evaluation. This is particularly true of incubated eggs. These deaths may indicate underlying bacterial or viral infections in the flock. Note the egg tooth and membrane covering the ear in this 28-day-old Moluccan Cockatoo embryo.

matic carriers) and contaminated food, water or nest material. Ill nestlings should be pulled for hand-feeding and appropriate treatment. These birds should be raised separately from other neonates and should not be fed by the same person who cares for the other birds in the nursery. If this is not possible, *some* microbial infections can be treated by offering medicated food to the parents who will then feed it to the nestlings. Fortunately, adult birds are often less selective of their diet while feeding offspring and may accept foods that they would ordinarily refuse. Parents preferentially feed nestlings soft, moist food, which should be offered fresh two to three times daily. Only highly susceptible microbial infections can be treated by offering medicated food to the parents, because it is difficult to achieve adequate antibiotic concentrations in the chick by using this technique (see Chapter 17). It is also possible that a parent could feed toxic amounts of the antimicrobial agent to the chicks. Viral infections such as polyomavirus and beak and feather disease virus (Pbfd) can also affect parent-raised chicks.

#### External Parasites

Red mites (*Dermanyssus gallinae*), Northern fowl mites (*Ornithonyssus sylvarium*), fire ants, Africanized bees and mosquitoes can infest the nest box and cause discomfort, anemia and even death of chicks. Mites can be controlled by dusting the birds with 5% carbaryl or pyrethrin powders and spraying the cage and nest box with 5% carbaryl or 5-10% malathion. Adding a small amount of 5% carbaryl powder to the nest material will aid in control, but care should be

taken in areas where insect vectors (eg, cockroaches) might carry *Sarcocystis* sp. If cockroaches enter the nest box and die from the insecticide, they may be eaten by either the parents or nestlings and subsequently transmit *Sarcocystis* sp.<sup>9</sup> Control of other pests is described in Chapter 2. Insecticides should be used only if indicated by the infestation of a parasite. They should not be used prophylactically.

## Hand-raising Birds

### Husbandry and Preventive Medicine

Psittacine chicks are altricial, and as neonates they are unable to thermoregulate, unable to feed themselves and have a poorly developed immune system. Consequently, diet and environmental conditions have a profound impact on health. When faced with a neonatal health problem, it is essential for the clinician to carefully evaluate the environmental conditions, hygiene practices and feeding methods in the nursery. Books are available on hand-feeding practices and it is beyond the scope of this chapter to completely discuss all aspects of hand-raising. The purpose of this section is to introduce the avian veterinarian to the most important factors to consider when investigating neonatal health problems (Table 30.1). Possibly one of the most overlooked factors in raising healthy psittacine chicks is providing them with ample rest periods in which they are not disturbed between feedings.

#### Nursery Design

Careful design can increase the function of the nursery and aid in disease prevention. The nursery should be separated from any contact with adult birds, and the aviculturist should take steps to prevent disease transmission from the adult flock. It is best to have separate caretakers for the adults and the babies. If this is impossible, the aviculturist should shower and change clothes between caring for adults and young. It is advantageous to have several potential nursery rooms in case there is a disease outbreak. If possible, valuable or endangered species should be raised in a room separate from common species that have a high incidence of infectious diseases (eg, budgerigars, cockatiels, lovebirds and conures). The nursery room(s) should have adequate

**TABLE 30.1 Guidelines for Nursery Management**

1. Every nursery should have a separate room where sick birds can be isolated. This room should not share air flow with the primary nursery. Nestlings showing signs of disease should be immediately moved from the primary nursery and isolated.
2. If a baby leaves the nursery for any reason and is exposed to other birds, it should not be returned to the primary nursery.
3. A nestling should never be added from another facility.
4. The same people should not care for both the adults and the neonates, unless special precautions are taken to avoid disease transmission.
5. Visitors, especially people who own birds, should be restricted from entering the nursery. People can act as mechanical vectors of infectious agents.
6. Ideally, every bird that is sold should be tested for microbial diseases, PBFV virus and polyomavirus before shipment.
7. Thorough cleaning of nursery facilities and equipment is better than partial cleaning followed by the use of disinfectants. Disinfectants are toxic, and exposure to the nestlings should be minimized (both direct contact and fumes).
8. Proper feeding practices can minimize problems.
  - a. Use a proven diet and constantly evaluate growth by assessing development and comparing weight gains with a growth chart.
  - b. Store dry nestling diet in a cool, dry, rodent-free area. Opened food containers should be stored in the freezer.
  - c. Feeding formula should be carefully measured and mixed, and the temperature checked before feeding.
  - d. Mix food fresh for each feeding. Do not store mixed food in the refrigerator and feed it at a later time.
  - e. Use an individual syringe for each nestling.
  - f. Never feed a bird and place the syringe back in the feeding formula.

temperature control and be self-contained with a large sink for washing hands and feeding utensils, a scale for weighing birds, a coffee-maker or hot plate for heating water or food and simple shelves for holding the brooders and enclosures. The room should be kept uncluttered to allow easy and complete cleaning, and the walls should be covered or painted with a durable, non-porous surface that can be easily disinfected. In areas where power outages are common, an alarm or back-up electrical system should be considered. An evacuation and emergency plan is best designed prior to a disaster.

### Age at Time of Removal from the Nest

For most species, nestlings less than two to three weeks of age are easiest to adapt to the hand-feeding process. Older birds may be fearful of people and more difficult to feed, while younger chicks more readily accept hand-feeding but must be fed more frequently. Chicks hatched from artificially incu-

bated eggs must be hand-raised or fostered from the first day. To help control some diseases, many aviculturists feed only babies hatched from artificially incubated eggs and are careful to exclude parent-hatched nestlings. Several viral infections (eg, PBFV and polyomavirus) that can be egg-transmitted may not be prevented by incubating eggs.<sup>27,28</sup>

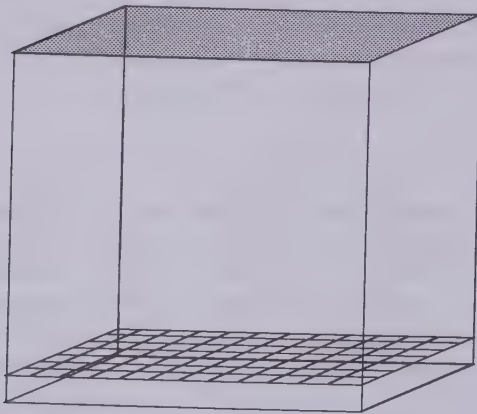
### Housing

Chicks should be housed in brooders in order to provide the precise temperature and humidity control required for optimal development of young neonates. Older chicks can tolerate wider temperature fluctuations. Commercially available brooders vary widely in quality and design. Solid state thermostats are more reliable than wafer types, and a back up thermostat should turn the unit off if the temperature becomes too high. Air should be circulated with a gentle fan. Commercial models with powerful fans should be avoided because they can dehydrate the chicks. Inside the brooder the chick should be kept in a small plastic container lined on the bottom with soft, absorbable paper toweling to aid in support and provide security. Slick surfaces can cause leg deformities. Chicks can also be housed in containers with a raised floor made of plastic-coated wire. These units keep the neonates clean and dry by allowing excrement to fall through the wire mesh; however, the mesh must be small enough to prevent the leg (especially the tibiotarsal joint) from extending through the wire. The container should have smooth walls to prevent the chick from entrapping its wings or beak (Figure 30.4).

Partially feathered chicks can be housed in open plastic pans or aquariums if the nursery is properly heated. Fully feathered chicks are capable of flight and should be kept in secure enclosures. Their wing feathers should be clipped after they are fully developed.

### Temperature and Humidity

The nestling's age and amount of feathering determine the optimal environmental conditions. The relative humidity for tropical species should be above 50 percent. Temperature should be adjusted for the behavior of the particular bird. Birds that are too hot will pant and hold their wings away from their bodies; those that are too cold will huddle, shiver and may have slow crop-emptying times. Chicks housed at temperatures outside the optimal range will grow more slowly. Some suggested temperatures for psittacine chicks are provided in Table 30.2.



**FIG 30.4** Plastic-coated wire baskets with raised floors are excellent for housing psittacine neonates greater than ten days of age. The size of the floor mesh can be varied to accommodate different sized chicks. This enclosure design keeps the neonates clean and dry, and can be placed inside most commercially available brooders (courtesy of Apalachee River Aviary).

**TABLE 30.2 Suggested Ambient Temperature Ranges for Psittacine Chicks**

Recent hatchlings	92-94°F
Unfeathered chicks	90-92°F
Chicks with some pin feathers	85-90°F
Fully feathered chicks	75-80°F
Weaned chicks	68-75°F

The actual temperature should be adjusted according to the needs of the individual chick.

### Substrate

The substrate on the floor of the “nest” should absorb moisture from the droppings, provide firm footing and not cause major digestive problems if ingested. Cloth diapers or unfrayed cotton woven towels and coated wire screens can be used with few problems. Problem substrates include tissue paper (provides



**FIG 30.5** Drop-through, raised floor units are preferable for housing growing chicks in the nursery. If other types of containers are used, the bottom should be covered with cloth diapers or woven cotton towels. Wood shavings, wood chips, cat litter and pelleted bedding can cause respiratory, gastrointestinal or dermatologic problems.

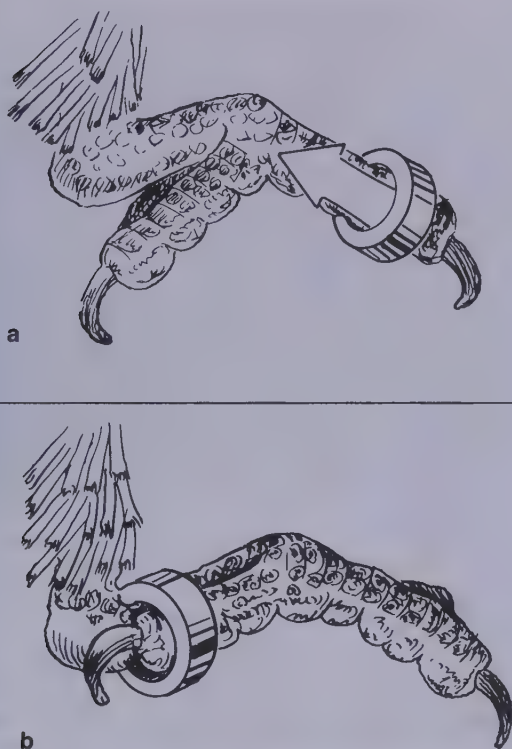
poor traction), soft, crumpled or shredded paper, wood shavings or chips (cause impactions if ingested), sawdust (causes respiratory problems if inhaled), and coarse pelleted bedding (causes GI irritation or blockage if ingested) (Figure 30.5). Substrate consumption may even result in malnutrition.

### Housing Multiple Chicks

Nestlings seem to grow best if they are housed with their clutch mates; however, chicks should be separated if there are substantial differences in body size, or if a bird becomes ill. Housing birds from different clutches together is discouraged because of the threat of disease transmission. Chicks should be housed individually if there is a disease outbreak in the nursery. Neonates or visitors from another collection should be discouraged from entering the nursery.

### Chick Identification

Chicks should be assigned individual identification numbers upon entering the nursery and identified by closed banding or transponder implants when they are large enough. Closed bands are rings that are slipped over the foot at the mid-pin feather stage and become fixed in place over the metatarsus as the foot grows too large for the band to be removed (Figure 30.6).<sup>10,21</sup> Electronic microchip transponders can be intramuscularly or subcutaneously implanted and provide permanent identification.<sup>10</sup> At a minimum, the aviculturist should record the following information in a log book: egg number if artificially hatched, identification of siblings and parents and location of



**FIG 30.6** Many states require that domestically raised neonates be closed banded. The band is applied by **a)** placing digits 2 and 3 together facing forward and **b)** slipping the band over the metatarsus. The size recommendations of the manufacturer of various bands should be carefully followed.

the parents' enclosure. Recording the health history of the parents and siblings is also helpful if epidemiologic information is required for disease investigation. Permanent identification is required for international sale of CITES-listed species and shipment into some states.

### Diets

Numerous hand-feeding diets are available, and a diet that works for one facility may not work well in another. Apparently, the idiosyncracies of the feeder's techniques and the amount and frequency of feeding influence growth as much as the composition of the diet. Therefore, a *carte blanche* recommendation for a particular diet cannot be made. Manufacturers of commercial diets are listed in Table 30.3 and examples of homemade diets are given in Table 30.4. The major advantages of commercial diets are that they are easier to prepare and have more consistent nutritional content.

Most of the nutritional requirements of psittacine chicks are not known, and the development of successful hand-feeding diets has been based largely on

**TABLE 30.3** Manufacturers\* of Hand-feeding Diets for Psittacine Chicks

1. AviSci Inc., P.O. Box 598, Okemos, MI 48805
2. Harrison's Bird Diets, Omaha, NE, (800) 346-0269
3. John Vanderhoof, P.O. Box 575, Woodlake, CA 93286
4. Kaytee Products, 292 Grand, P.O. Box 230, Chilton, WI 53014
5. Kellogg's Inc., P.O. Box 684, Milwaukee, WI 53020
6. Lafeber Co., RR #2, Odell, IL 60460
7. Lake's Minnesota Macaws, Inc., 639 Stryker Ave., St. Paul, MN 55107
8. Marion Zoological Inc., 113 N. First, P.O. Box 212, Marion, KS 66861
9. Pretty Bird International, 1170 Eagan Industrial Rd., Eagan, MN 55121
10. Rolf C. Hagen Inc., 3225 Sartelon St., Montreal, Quebec, Canada H4RIE8
11. Roudybush Inc., P.O. Box 908, Templeton, CA 33465-0908
12. Topper Bird Ranch Diets, 1466 N. Carpenter Rd., Modesto, CA 95351
13. Zeigler Brothers, P.O. Box 95, Gardners, PA 17324

Listed in alphabetical order.

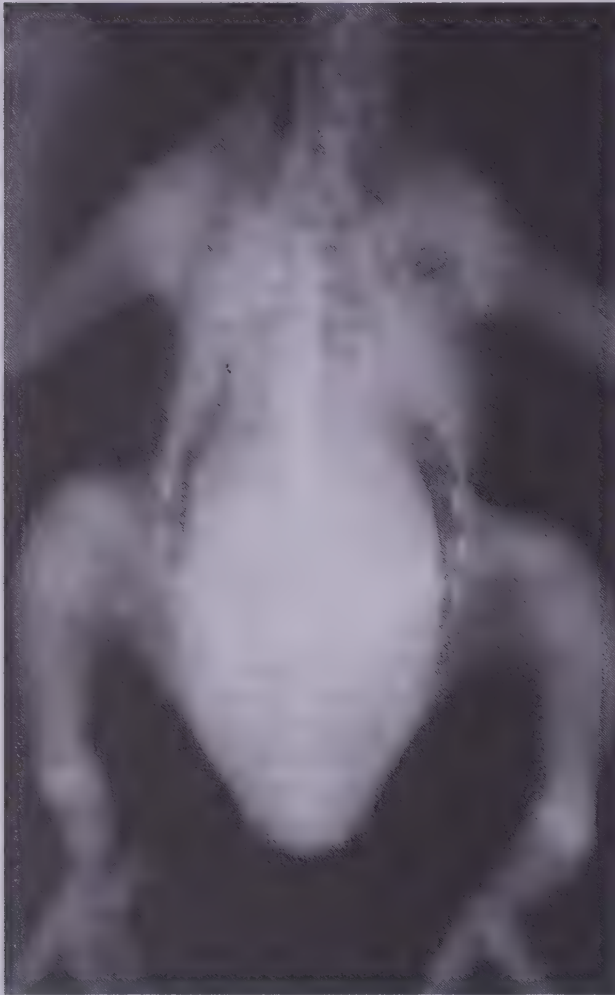\* Listing or absence of listing in this table does not imply endorsement or non-endorsement by the authors or editors.

trial and error and extrapolation from the dietary requirements of poultry (Figure 30.7). Some generalizations regarding neonatal nutrition can be made. Investigations in cockatiels<sup>30</sup> and the observations of numerous aviculturists indicate that the protein content should be approximately 18 to 22%, calcium 1%, and calcium and phosphorus should be balanced in approximately a 2:1 ratio. Lists of specific nutrient deficiencies and associated clinical signs are often published for poultry but may not be applicable to psittacine birds. For example, lysine deficiency causes depigmented feathers in poultry but not in cockatiels. Choline deficiency has been shown to be associated with feather depigmentation in cockatiels.<sup>30</sup>

The water content, consistency and temperature of the feeding formula are also important. A diet containing approximately 25 to 30% solids (70-75% water) should be fed to nestlings older than one or


**TABLE 30.4** Primate Diet Hand-feeding Formula Used With Success in Some Nurseries

1. Grind primate diet.
2. Mix (by weight)
  - Ground primate diet 50%
  - Commercial hand-feeding formula 25%
  - Dry oatmeal baby cereal 25%
3. Store mixed dry diet in a sealed bag in the freezer.
4. Heat water to approximately 120°F. Add 20 to 25 mls of the heated water to 25-30 gms of the dry mixture. Stir in 1 teaspoon of creamed carrots and 1 teaspoon of mixed baby cereal (from a jar).
5. Mix thoroughly and feed at a temperature of 102 to 105°F.



**FIG 30.7** A three-week-old Blue and Gold Macaw chick was presented with a three-day history of inability to ambulate and the appearance of ulcerations on the abdominal body wall. The bird was being fed a homemade diet. The limbs were soft and pliable. Radiographs indicated osteopenia and pathologic fractures in the humerus and tibiotarsus suggestive of metabolic bone disease (rickets). Note the soft tissue opacity of the abdomen, a relatively normal finding in young chicks. The liver, proventriculus, ventriculus and intestines (the last three of which stay filled with food) generally fill the entire abdominal cavity (courtesy of Marjorie McMillan).

two days.<sup>30</sup> It may be beneficial to feed a more dilute diet for the first day after hatching because the chick will be using the contents of its yolk sac for nutrition. Inexperienced hand-feeders should actually weigh the solid and liquid portions of the diet to ensure a proper dilution is fed. Evaluating a cooked diet according to visual consistency is inaccurate. Cooked starches may cause the formula to appear thick even though the percentage of solids is very low. The food should be warmed to 101°-104°F and the temperature measured with an accurate thermometer. The instructions provided with commercial diets should



**FIG 30.8** Coffee makers and hot plates are better for heating water for formula for neonates than microwave ovens. Microwave ovens tend to create super hot spots in the formula that can cause full-thickness burns in the crop (see Color 13).

be carefully followed. Cooler food may be refused, hot food may scald the crop. A hot plate or coffee maker should be used for heating formula. The use of a microwave oven for heating food frequently results in severe crop burns (Figure 30.8).

### Feeding Methods

Most aviculturists now use syringes for feeding, although bent spoons or crop tubes are occasionally used. Catheter-tipped syringes are especially popular. Hungry nestling birds display a feeding response that consists of rapid, thrusting head movements and bobbing up and down. These movements can be stimulated by touching the commissures of the beak or pressing lightly under the mandible (Figure 30.9). While the bird is displaying this behavior, the glottis is closed and large amounts of food can be delivered quickly with less fear of passing food into the trachea. If a neonate resists feeding or a feeding response is not displayed, the chance of tracheal aspiration is greater. If a young bird that is not eating on its own refuses to eat for two to three feedings in a row, it may be having a medical problem that should be evaluated. As some birds get older, they display less of a feeding response and are more difficult to feed. This may be an indication that weaning is beginning to occur. If an older bird resists feeding, that feeding should be skipped. The chick may be hungrier and more willing to eat at the next scheduled feeding. A long, soft tube can be used to feed recalcitrant birds. Short tubes should not be used, as they may become detached from the syringe and swallowed.





**FIG 30.9** A neonate with an active feeding response will rapidly thrust the head up and down on a syringe. The head should be gently supported to prevent injuries during the feeding process (courtesy of Apalachee River Aviary).

### Feeding Amounts and Frequency

Younger birds should be fed more often than older, larger birds. Adequate weight gain and good morphologic development are more important indicators of adequate nutrition than the amount or number of feedings. The amount of food and frequency of feeding depends on the age and development of the chick and the particular diet fed. Birds one to five days old should be fed six to ten times daily; chicks with eyes closed, four to six times daily; chicks with eyes opened, three to four times daily; and birds with feathers emerging, two to three times daily. Chicks less than one week old may benefit from around-the-clock feeding, but it is not necessary to feed older chicks through the night. The last feeding can be given between 10:00 p.m. and 12:00 a.m. and the first between 6:00 and 7:00 a.m. The crop should be filled to capacity and allowed to nearly empty before the next meal. The crop should be allowed to completely empty at least once each day (usually in the morning following the final night feeding). It is important to feed young birds the maximum amounts of food early to stimulate good growth and increase crop capacity. However, excessively large meals in very small birds

can predispose them to regurgitation and subsequent aspiration. In these birds, it is best to feed smaller quantities of food on a more frequent basis. Some formulas have higher fiber content that allows for longer periods between feedings and less total food volume per day due to improved feed efficiency.

### Weaning

Weaning is a stressful time for both the bird and the hand-feeder. Some birds wean themselves at the appropriate body weight by refusing to be hand-fed, but many others must be encouraged to wean (particularly cockatoos and large macaws).<sup>30</sup> Several weeks prior to the expected age of weaning, the bird should be offered a variety of foods such as corn, cooked vegetables, various fruits, soaked monkey chow, formulated diet, spray millet, hulled seeds and peanut butter and jelly sandwiches. Seeds with hulls and large chunks of food should be avoided because at this stage the bird may consume them whole. Most birds will pick up and play with food long before they actually consume the material. To encourage experimentation, food bowls should be easily accessible and placed at perch height. The presence of an older, self-feeding bird may encourage younger birds to wean more quickly. It is best to accustom a weaning baby to a wide variety of formulated diets and fresh fruits and vegetables. This will make them more likely to accept the varied diets that they may be offered when they leave the nursery. If birds are weaned onto a specific diet, it is important that a new owner continue feeding the same diet until the bird is accustomed to its new surroundings and the diet can be safely changed.

When the bird is at the right weight and development or consuming some solid food, the midday feeding should be gradually eliminated, followed by the morning and then the evening meals. If the bird was fed properly to begin with, weight loss in the range of 10 to 15% of the peak body weight may be expected during the weaning process. If the bird was underweight to begin with, any weight loss may be abnormal. Subclinical illness (especially gram-negative bacterial infections of the alimentary tract) may become apparent during weaning. Clinical signs could include excessive weight loss, slowed crop-emptying times, depression, diarrhea, regurgitation or simply a failure to wean. If problems are noted, weaning should be postponed and the underlying problem diagnosed and treated. If the weight loss is severe, it may be necessary to resume hand-feeding two to three times daily, and weaning should not be re-attempted until the bird has gained adequate weight.

Some birds will resist hand-feeding before they are capable of maintaining adequate body weight on their own. This is especially common in malnourished birds that are stunted in growth but of weaning age. It may be necessary to tube-feed these birds, because forcing them to hand-feed increases the risk of aspiration and causes severe stress.

### Hygiene

Careful control of environmental sources of pathogenic bacteria and yeast are essential for maintaining healthy chicks. A diligent, thorough, common-sense approach that includes minimum exposure to harmful chemicals works best. The most important sources of microbial contamination include the food, water supply, feeding and food preparation utensils, other birds in the nursery and the hand-feeder. If microbial infections are repeatedly encountered in a nursery, these areas should be cultured in order to identify and eliminate the source of contamination.

Microbes in the food and water that would have little effect on adult birds can cause life-threatening infections in neonates. Yeast, *Escherichia coli*, *Klebsiella*, *Enterobacter* and *Pseudomonas* spp. are common contaminants. To avoid these microbes, the components of the diet should be carefully selected. Most commercial diets are relatively clean. Products intended for poultry, however, may contain high levels of bacterial contamination and should be excluded from the diet.<sup>17</sup> Monkey chow is a common ingredient in homemade diets and can be used successfully if properly stored (Figure 30.10). Yeast and bacterial contamination of any formulated diet can occur if it is improperly stored. *Pseudomonas* is a frequent contaminant of water taps and bottled water dispensers.

The diet should be mixed fresh before each feeding. As a guide, the standards for cleanliness in a nursery should be higher than the feeders would maintain for themselves. Opened containers of dry baby formula should be stored in sealed containers in the freezer. Powdered baby formula that has been mixed with water should never be stored and fed to babies in subsequent feedings. Hands should be washed between birds or groups of birds to avoid transmitting diseases (Figure 30.11). A separate syringe should be used for each bird and the syringes should be filled in advance. Under no circumstances should a syringe used to feed a bird be dipped back into the food for a refill; this will result in the spread of infectious agents throughout the nursery. The syringes and all implements used for preparing food should be kept clean by disassembling, scrubbing and disinfecting



**FIG 30.10** All avian food stuffs should be maintained in sealed containers in cool, moisture-free areas. All rodent, insect or feral bird exposure to the food must be prevented. Several bacterial disease outbreaks in nurseries have been blamed on specific types of manufactured food when, in fact, the outbreaks were the result of careless food handling (eg, wet food or food contaminated by rodent droppings) on the part of the aviculturist (courtesy of Apalachee River Aviary).



**FIG 30.11** Nursery hygiene is critical in preventing infectious disease outbreaks. In addition to maintaining the neonates in a clean, dry environment, aviculturists must also make certain they do not serve as sources of infection for their neonates. Part of personnel hygiene involves thoroughly washing the hands before handling any neonate. Hands should also be washed when moving from one group of neonates to the next.

after each use. Quaternary ammonium products containing a detergent are recommended for disinfection since they will cause less drying of the syringe

plunger than Clorox.<sup>10</sup> The syringe plunger should be periodically removed and scrubbed to avoid a build-up of food and pathogens. Feeding implements must be thoroughly rinsed to reduce exposure of chicks to residual disinfectants.

### New Additions

New additions to the nursery should be placed in separate brooders, fed last and monitored carefully until it is apparent that they are healthy. It is prudent to culture the cloaca of new birds at the time they enter the nursery to diagnose and eliminate potential microbial infections that might spread to other chicks. A cloacal swab can also be submitted to make certain that the neonates are not shedding polyomavirus. Detecting an infectious agent in a newly introduced chick also indicates that the parents and egg incubator should be evaluated. In this manner, chicks can be used to monitor the health of the adult collection. A clinical workup and brief isolation period of all new arrivals to the nursery will help prevent some diseases but will not eliminate all risks. For example, chicks infected with PBFV virus or polyomavirus may not show clinical signs of disease for weeks to months after exposure. Antigen detection tests may be used to identify potential carriers of these diseases<sup>28</sup> (see Chapter 6). Birds from other collections should *never* be brought into a nursery.

### Evaluating Nestling Birds

Nestling psittacine birds can be evaluated in the same way as adult birds. A complete history, thorough physical examination and appropriate laboratory tests should be completed. The unique features of neonatal psittacine birds are emphasized in the sections below.

#### History


Avicultural clients should be asked to prepare a written summary prior to taking a nestling psittacine chick to the veterinarian. The history should include the following:

1. The past breeding and health history of the parents and condition of the chick's siblings.
2. Problems during incubation or hatching if the chick was artificially incubated. (Chicks that have problems hatching frequently grow poorly during the first few weeks of life and may be stunted).
3. Brooder temperature, substrate, hygiene practices (including exposure to any disinfectants) and condition of other birds in the nursery.

4. The type of diet, percent solids content, how the diet is prepared, amount and frequency of feedings and implement used to feed the chick.
5. The identification number and method used to identify the chick.

### Body Weight Charts

One of the most valuable tools for evaluating nestling birds is a chart recording daily body weight. Birds should be weighed prior to the morning feeding when the crop and GI tract should be relatively empty (Figure 30.12). At most stages of development, juvenile birds should gain a certain amount of weight daily. Failure to gain this amount of weight is cause for concern. Almost any disorder will affect the weight gain, and lack of a normal weight gain is often one of the earliest signs of problems. Body weight can be compared to weight charts developed from records of morphologically normal birds to access normal development; however, it must be stressed that there is wide natural variation in the normal growth rates of chicks depending on individual body conformation, gender and feeding practices. See Table 30.5 for suggested normal growth rates for selected psittacine species.



**FIG 30.12** Chicks should be weighed each day before the morning feeding to monitor growth and to detect problems in an early stage.

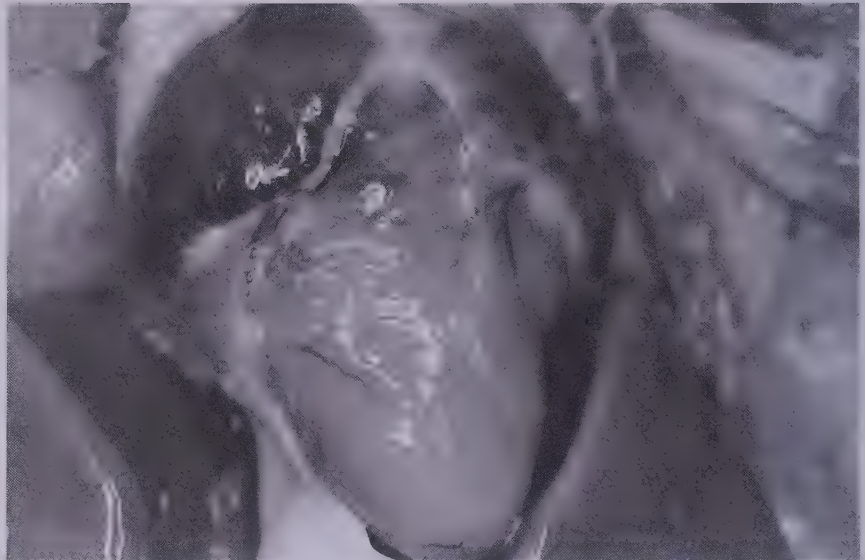
Extensive discussion of the normal growth of psittacines has been published.<sup>11,21</sup> Growth is slow for approximately one to four days following hatching and then accelerates logarithmically until a second plateau stage just prior to weaning, when many birds will achieve body weights that exceed their adult weight. During weaning, this extra weight is lost as the bird exercises more and assumes more adult proportions.

### Developmental Characteristics

Recording developmental characteristics, such as the date the eyes open, the first appearance of head, wing and tail feathers and any other physical changes will help in assessing the growth of a chick. As a generalization, growth characteristics vary with body size, and larger species develop more slowly. The growth rate may be as high as 17% a day during the first week. Growth characteristics for a number of psittacine species have been reported.<sup>11</sup> Delayed developmental characteristics usually indicate delayed overall growth and stunting.

### Physical Examination


A thorough physical examination is as important in nestlings as it is in adults. During the examination, chilling and stress should be avoided by warming hands, warming the room and keeping handling times to a minimum. Birds with food in the crop should be handled carefully to avoid regurgitation and aspiration. The heart and lungs should be auscultated to detect cardiac murmurs and moist respiratory sounds (Figure 30.13). The eyes and ears should be carefully examined to evaluate normal development and opening. It is normal to have a clear discharge from the eyes when they open. In macaws, the eyes usually open between 14 and 28 days following hatching; in cockatoos, between ten and 21 days;



**FIG 30.13** A five-week-old Blue and Gold Macaw chick was presented for regurgitation and retarded growth (the younger sibling weighed 120 g more than the patient). The bird was severely dyspneic and depressed. The crop was partially filled with food but peristaltic activity appeared to be normal. Auscultation of the heart revealed a severe murmur. The bird did not respond to supportive therapy. At necropsy, the heart was enlarged and a ventricular septal defect was identified.



**FIG 30.14** **a)** An eight-week-old African Grey Parrot was presented with severe torticollis (the top of the head rested on the ground when the bird stood upright). The bird's head had been turned at a 180° angle since hatching. Radiographs indicated a rotational deformity in the cervical vertebrae. A clutchmate was unaffected. Improper incubation parameters, nutritional deficiencies in the hen, infectious diseases, improper chick position in the egg and genetic flaws have all been proposed as etiologies of spinal deformities. **b)** A three-day-old Blue and Gold Macaw chick was presented for severe torticollis. The abnormality was corrected within two weeks of applying a neck brace (courtesy of Martin Orr).



**FIG 30.15** Until weaning, neonates like these a) two-week-old and b) four-week-old Moluccan Cockatoo chicks will stand on their hocks with their abdomen on the ground for support. A normal chick will be bright and alert, with the head raised in response to any activity that may suggest that it is feeding time.

and in Amazon parrots, from 14 to 21 days. The ears are open at hatching in Old World Psittaciformes, and open from ten to 35 days of age in neotropical species. Nestlings can be examined in the same manner as adults but have physical characteristics that differ from adult birds. Particular attention should be paid to body conformation, spine and neck curvature and beak alignment and curvature (Figure 30.14).

#### Posture

Nestling birds sleep much of the time and are most active when hungry. They may sleep in almost any position, including sprawled with their legs in the air. Until weaning, they sit on their hock joints, rather than up on their feet, using their protuberant abdomen to create a tripod stance (Figure 30.15). Young birds may be uncoordinated and splay their legs when trying to walk. This should be considered normal unless a limb is held consistently in an abnormal position.

#### Body Conformation

Nestlings have relatively little muscle mass and a large, protuberant abdomen. The pectoral muscles are almost nonexistent. As the bird ages, the muscle mass will increase, but even at weaning they will be thinner than in an adult. Body mass in young nestlings is best assessed by noting the thickness of the muscle and subcutaneous fat covering the elbows, toes and hips. In contrast to adults, nestlings have a very full abdomen because the ventriculus and proventriculus are greatly enlarged at this age.



**FIG 30.16** The normal skin of a nestling should be yellowish-pink, supple and warm. A neonate that is being properly cared for by the parents will always have a full crop, as seen in this neonatal Umbrella Cockatoo.

TABLE 30.5 Sample Weight Gains (in grams) of Selected Hand-raised Psittacine Birds and Normal Adults

Age (in days)	0	3	7	14	21	28	35	42	49	Adult
Cockatiel	4-6	5-6	12-14	45-65	72-108	80-120	80-90	80-95	90-110	90-110
Golden Conure	7-11	10-12	12-23	20-25	30-100	45-150	90-240	125-270	180-310	262
Green-cheeked Amazon Parrot	10-14	15-22	30-50	90-135	200-250	225-310	280-350	290-350	***	360
Lilac-crowned Amazon Parrot	11-13	15-20	25-35	75-140	160-240	250-300	300-350	310-350	***	360
Blue-fronted Amazon Parrot	14-17	20-25	35-60	100-170	240-280	280-370	350-420	380-440	380-430	432
Yellow-headed Amazon Parrot	12-21	16-30	25-50	75-200	140-300	230-450	270-580	310-560	380-565	568
Yellow-crowned Amazon Parrot	12-15	15-33	25-55	70-170	175-260	250-360	350-440	400-480	***	500
Yellow-naped Amazon Parrot	11-18	16-35	28-75	60-200	170-360	275-500	420-600	500-650	500-650	596
Eclectus Parrot	12-20	16-35	23-60	60-150	110-240	190-350	260-440	300-450	320-480	432
African Grey Parrot	11-17	15-211	25-40	70-120	135-250	240-335	300-440	380-470	435-500	554
Red-vented Cockatoo	11	16-20	25-30	70-100	145-200	230-280	250-300	275-350	230-350	298
Citron-crested Cockatoo	12-15	15-23	26-84	78-144	148-265	208-366	292-430	319-445	320-464	357
Bare-eyed Cockatoo	8-14	11-35	18-70	48-170	99-308	167-363	238-415	283-410	289-415	375
Goffin's Cockatoo	8-11	10-15	20-45	70-100	125-240	175-275	220-325	250-350	250-350	255
Lesser Sulphur-crested Cockatoo	8-15	12-22	25-60	65-120	140-250	225-320	280-340	315-380	320-410	450
Rose-breasted Cockatoo	7-12	10-17	15-40	35-100	70-200	115-300	175-370	220-400	240-423	403
Medium Sulphur-crested Cockatoo	12-15	18-25	35-70	65-140	160-250	240-350	340-450	400-525	450-550	465
Major Mitchell's Cockatoo	9-13	13-22	25-55	55-130	140-220	210-300	270-375	290-450	340-500	423
Umbrella Cockatoo	12-20	15-20	25-55	75-150	170-300	280-400	350-530	450-600	500-725	577
Triton Cockatoo	11-19	15-30	30-70	90-170	200-325	290-475	400-650	450-750	490-800	643
Moluccan Cockatoo	16-22	21-30	35-55	90-170	190-300	330-450	470-650	600-750	680-825	853
Greater Sulphur-crested Cockatoo	16-20	18-35	35-80	100-200	220-330	370-525	450-625	500-725	550-880	843
Yellow-collared Macaw	9-15	12-20	25-35	60-90	110-160	190-240	230-280	250-290	270-300	250
Red-fronted Macaw	12-16	18-25	25-45	70-130	140-250	230-360	330-470	405-530	465-580	490
Caninde Macaw	14-22	19-25	30-45	70-120	165-250	275-420	420-600	520-725	600-800	752
Military Macaw	17-26	24-45	35-170	85-300	220-425	360-650	500-800	600-950	680-1050	925
Scarlet Macaw	17-26	25-45	40-65	90-175	200-400	380-625	540-800	720-1050	830-1150	1001
Blue and Gold Macaw	16-27	25-40	40-100	90-250	200-450	350-650	525-900	670-1100	800-1200	1039
Green-winged Macaw	17-28	30-55	45-80	100-250	225-450	400-650	610-900	830-1030	990-1190	1194
Buffon's Macaw	20-26	25-35	40-70	100-170	250-500	450-750	650-900	850-1100	1050-1350	1290
Hyacinth Macaw	20-27	25-35	45-75	110-180	250-400	450-600	600-750	800-1000	900-1200	1355

Weight ranges were derived from the weight gain records of birds hand-raised from hatching to weaning. They are provided as suggested ranges only, as growth of an individual chick is dependent on hatch weight, body structure, sex, diet and feeding and husbandry practices. Comparison of data from two successful nurseries has indicated that birds with widely divergent body weights can successfully wean.<sup>10,20</sup> Birds in the lower end of the weight range are more prone to stunting and should be carefully observed. Birds in the upper end of the weight range may shed excess weight at weaning. Data from this table should be combined with observation of the conformation and physical condition of the chick before deciding if an individual is stunted in growth. All weights are given in grams.

### Skin


It is important to evaluate both texture and color of the skin. Normal nestlings have yellowish-pink skin with a supple, warm feel (Figure 30.16). Dehydrated nestlings will have dry, hyperemic skin that feels sticky to the touch (Color 30.4). Nestlings with white, cool skin are either hypothermic or moribund and need immediate attention. Some flaking of the skin is normal; excessive amounts of flaking indicate dehydration or exposure to high temperature, low humidity or malnutrition.

### Feather Growth

Most psittacine chicks are naked at hatch except for a sparse coating of down (Color 30.1). The first feathers appear on the head, wings, and tail, followed by feather emergence on the rest of the body (Figure 30.17). Gross discrepancies in the pattern of feather development may indicate stunted growth. Feather dysplasia (eg, pinched off feathers, constrictive bands, blood in the rachis) or epilation may indicate polyomavirus, PBFD virus, adenovirus or bacterial folliculitis. Neonates being treated with antibiotics may also have abnormally developed feathers.<sup>28</sup>

### Crop

Nestling birds have a greater crop capacity per body weight than adults, sometimes as much as two to three times the adult volume (Figure 30.18). The crop should empty at least once daily; overstretched, damaged and atonic crops will not empty properly. The



**FIG 30.17** Feather growth occurs rapidly in neonatal birds and follows a set pattern that varies among species. In general, feather growth starts with the head, wings and tail, followed by feather emergence on the rest of the body. This figure shows normal pin feather development in the carpus and distal portion of the radius and ulna of a five-week-old Umbrella Cockatoo.



**FIG 30.18** The crop capacity of neonatal birds is larger than in an adult when compared on a per weight basis. Neonates should be fed the maximum volume of food that does not over-stretch the crop (courtesy of Apalachee River Aviary).

crop should be palpated for foreign objects and trapped, doughy food, and examined externally for redness or scabs that might indicate a burn or puncture (Color 30.12).

### Droppings

Nestlings often have polyuric droppings. This usually results from the liquid diet they are fed. The fiber content of some formulated diets is higher than homemade formulas, and the droppings from birds fed those diets are less watery and more formed.

## Diagnostic Procedures

### Clinical Pathology

The clinical pathology of nestling psittacine birds is poorly documented; however, recent publications have established reference intervals for some species.<sup>12-14</sup> In general, nestling birds normally have lower packed cell volumes (20's-30's), lower total protein (1-3 g/dl), and higher white blood cell counts (20,000-40,000) when compared to adults of the same species (see Appendix). Young chicks also have lower plasma concentrations of albumin and uric acid and higher concentrations of alkaline phosphatase and creatine phosphokinase. It is very important to note these age-related differences in hematology so that

misinterpretation of laboratory values does not result in the unnecessary treatment of a normal chick.

### Microbiology

Young birds are highly prone to microbial infections and cloacal cultures, and fecal Gram's stains should be routinely evaluated during development. Normal aerobic cloacal flora is gram-positive and consists of *Lactobacillus*, *Corynebacteria*, *Staphylococcus*, non-hemolytic *Streptococcus* and *Bacillus* spp.<sup>16</sup> Common pathogens include gram-negative bacteria and yeast. Many commercial diets contain nonpathogenic brewer's yeast that can be seen on Gram's stains of the crop or feces. Yeast that is contained in the diet should not be budding (an indication that the yeast is alive). Choanal cultures can be used to evaluate the microflora of the upper respiratory tract.

### Radiography

The anatomic differences of nestling birds must be considered when interpreting radiographs. The proventriculus and ventriculus are normally much larger than in an adult and may fill most of the abdominal cavity, especially if food is present. Intestinal loops may also be filled with food. Filling of the digestive tract with food reduces the volume of the air sacs. Growth plates in the bones may be open and the general muscle mass will be reduced.

### Endoscopy

The techniques and indications for endoscopy are similar to those for adults. An endoscope can be used to identify foreign bodies, inhaled food or aspergillosis in the trachea. Flexible or rigid endoscopes are useful for visualizing the crop when foreign bodies or burns are suspected. The proventriculus and ventriculus are best visualized with flexible scopes passed per os. Great care must be used when scoping the coelomic cavity of nestling birds because the relatively large digestive tract reduces the free space in which the scope can be safely introduced to the air sac. The bird should be fasted for several hours (depending on age) before attempting this procedure. Indications for laparoscopy include surgical sexing, documentation of aspiration or pneumonia and identification of abdominal or thoracic masses not confined to the digestive tract. Nestling birds can be endoscopically sexed as young as six weeks of age.

## Common Problems of Neonates


### Neonatal Problems

#### Perinatal Problems

Diagnosis, treatment and prevention of premature hatch, difficult hatch, unabsorbed yolk sac, hemorrhage of the complexus muscle and other developmental problems associated with incubation and hatching are described in Chapter 29. All of these problems may affect the growth and development of the chick (Figure 30.19).

#### Failure to Absorb the Yolk Sac

The yolk sac is a diverticulum of the intestine and is internalized into the abdomen just prior to hatch. Following hatch, the yolk is normally absorbed and provides nourishment and maternal antibodies during the first days of life. Once the yolk is absorbed, only a small remnant of scar tissue should remain. A common cause of death in artificially hatched chicks during the first week of life is retention of the yolk sac, which may be associated with primary or secondary infections of the navel (omphalo-vitellitis) (Color 30.2). Infections, improper incubator conditions and idiopathic causes can result in a failure of the yolk sac to be absorbed. In a retrospective review of 59 yolk sac cultures at the Denver Zoological Gardens, *E. coli*, *Proteus*, *Streptococcus fecalis*, and *Clos-*



**FIG 30.19** A healthy, vibrant neonate should hatch unassisted. The pipping muscle (arrow) located on the dorsal cervical area should not be misinterpreted as an abnormal swelling.



*tridium* sp. were the most common bacterial isolates associated with yolk-related problems.<sup>6</sup> In pigeons, there is an increased occurrence of omphalitis and bacterial septicemia in eggs that are washed prior to incubation.

Yolk sac infections can occur secondary to infections of the navel if it is poorly internalized prior to hatching. Alternatively, bacteria can multiply in the hatching egg following fecal contamination of the shell. In squab, omphalo-vitellititis may be caused by trichomonas. Affected animals have enormous yolk sacs that are 20 to 40% of the total body weight. The navel may be thickened, prominent and necrotic. Failure of yolk absorption is reported primarily in ratite and waterfowl chicks, but also occurs in companion birds. The normal interval for complete absorption of the yolk varies in different species. Precocial young use the yolk more quickly than altricial neonates. The yolk sac is no longer visible at six days in macaws, is absent in the ostrich in eight or more days and is palpable in emus for approximately seven days. Birds with unabsorbed yolk will have enlarged, doughy abdomens, and the large yolk sac may be visible through the abdominal wall or via radiography (Color 30.10). Dyspnea, exercise intolerance, depression, anorexia and inability to stand have also been reported.<sup>6</sup>

A surgical procedure has been described for removing the yolk sac in ratites and waterfowl.<sup>6</sup> The yolk sac is exteriorized and the yolk stalk and associated vessels ligated close to the jejunal/ileal junction of the small intestine. The body wall and skin are closed in separate layers (see Chapter 48).

### Critical Care of the Neonate


Nestling birds have little reserve capacity and sick neonates are often presented in critical condition, regardless of the underlying cause. Ill or abandoned nestlings are frequently hypothermic, dehydrated, hypoglycemic and may be septicemic. Supportive care to correct these physiologic imbalances should be implemented immediately (Table 30.6).

### Stunted Growth

Poor development and stunted growth is a common problem in both parent and hand-fed birds. Any factor that interferes with the homeostasis of the chick can alter growth (Figure 30.20). The leading causes of stunting are suspected to be underfeeding, chronic microbial infections and polyomavirus. Other possible causes of stunting include:

TABLE 30.6 Critical Care of the Neonate

1. **Collect samples for diagnostic blood work** and microbiology if this will not compromise the patient.
2. **Correct hypothermia.** Hypothermic neonates may be unresponsive and appear dead. They should be gradually warmed in an incubator set at 92°-95°F and monitored to make sure they do not become hyperthermic. The response to warming can be quite dramatic.
3. **Correct dehydration.** Dehydrated chicks will have sunken facial features, dry, reddened, wrinkled skin and feel sticky to the touch. The preferred route of fluid administration depends on the condition and size of the chick. If the chick is severely depressed and potentially hypovolemic, intravenous lactated Ringer's solution can be given by slow bolus administration at a rate of 10-15 ml/kg. An alternative to IV administration is to place an intraosseous catheter in the tibia using a butterfly catheter for small birds and an indwelling catheter for large ones.<sup>19</sup> If a catheter is used, the fluid deficit plus maintenance (40-60 ml/kg/day) should be replaced in a 48-hour period. Once the hypovolemia is corrected, subcutaneous fluids can be administered between the shoulder blades and into the groin. Lactated Ringer's solution, with or without added dextrose, is the preferred fluid because the lactate will provide some buffering of the metabolic acidosis assumed to occur in most dehydrated birds. Oral fluids can be used in birds that are responsive and are not having problems with crop stasis or regurgitation. Solutions containing dilute complex carbohydrates and electrolytes work best. Jarred baby cereal containing oatmeal, applesauce and bananas diluted 50 percent with water, the juice of boiled rice or commercial human infant fluid replacers have been successfully used as oral fluids.
4. **Correct hypoglycemia.** Chicks that have not been fed and those suffering crop stasis may be marginally hypoglycemic. Psittacine birds rarely seizure because of hypoglycemia; the most common clinical sign is depression. A solution of 2.5-5% dextrose can be added to IV fluids once the hypovolemia has been corrected. Dextrose should not be added to the fluids of a dehydrated neonate to prevent the induction of metabolic acidosis and the movement of fluids out of the intracellular space causing more severe dehydration. Glucose can also be added to oral rehydration fluids.
5. **Treat the septicemia.** Primary and secondary bacterial infections are very common in nestling birds. If suspected, treatment should begin immediately, because waiting for cultures may be fatal. If the bird is severely depressed or has crop stasis, parenteral antibiotics should be administered via the SC or IM route. They can also be added to IV fluids. The advanced generation penicillins (eg, piperacillin) and cephalosporins (eg, cefotaxime and ceftiofur) have excellent gram-negative activity and are relatively nontoxic. To avoid renal toxicity, the aminoglycosides should not be used in dehydrated patients. If the bird is capable of taking oral antibiotics, enrofloxacin or trimethoprim-sulfa provide good gram-negative bacterial activity. Enrofloxacin has been safely used in many nurseries but should still be used with caution in growing birds because joint abnormalities have been reported in mammals. Trimethoprim-sulfa combinations can cause regurgitation in some birds, especially macaws. Nystatin can be used to treat yeast infections of the alimentary tract (see Chapter 18).



**FIG 30.20** The African Grey Parrot (left) and Blue and Gold Macaw chick are approximately the same age. The birds were fed the same diet, which had been used successfully in many other macaw chicks. The cause of stunting in this macaw chick could not be determined. Note the large head compared to the rest of the body.

- Improper feeding: unbalanced nutrition, not feeding enough volume, not feeding frequently enough and feeding a diet with low total solids.
- Poor environmental conditions in early development: low or high temperature, low humidity.
- Diseases: any disease may cause a chick to expend energy fighting the disease, rather than using energy for growth. Clinical and subclinical microbial diseases caused by gram-negative bacteria and yeast are commonly implicated. These organisms may be secondary problems indicating primary viral infections, environmental inadequacies, immunosuppression or malnutrition. Stunted birds may also be infected with polyomavirus or PBFD virus.

### CLINICAL APPLICATIONS

Clinical signs of a sick, stunted chick include:

- Subnormal weight gain.
- Reduced muscle mass and subcutaneous fat deposits — thin toes, elbows and hips.
- Mal-proportioned body — head large in proportion to the rest of the body.
- Feather problems: delayed feathering in particular areas, a spiral pattern to the feathers on the back of the head, a "mohawk" pattern in macaw head feathers and excessive numbers of stress marks.
- Chronic, recurrent, microbial infections.
- General illness, including sluggish behavior, dehydration and pale skin color.
- Constant vocalization and begging for food.
- Failure of the palpebral slit to open at the normal time.

- Hyacinth Macaw, Palm Cockatoo and Queen of Bavaria Conure neonates appear to have a higher incidence of stunting than other species, possibly because they have dietary requirements that are not met with commonly used diets. Currently, these species do best when fed high-fiber, high-fat formulated diets throughout development, with the addition of nuts at weaning.

Malnourished birds can often be salvaged by correcting the underlying problems and gradually increasing their plane of nutrition. If the stunting is mild and the cause is corrected early, many birds will wean normally. Moderate stunting may result in a smaller bird with a globose head and slender beak. If the stunting is severe, the bird may survive for a long time without growing but will eventually die. Euthanasia should be considered for nestlings that are confirmed positive for PBFD virus.

### Congenital Abnormalities

Congenital abnormalities have been infrequently reported in psittacine chicks. The lack of documented congenital abnormalities could be a result of under-reporting, rapid death in embryos with abnormalities or undiagnosed congenital abnormalities in dead neonates. Additionally, the fact that psittacine birds have been domesticated only recently (and thus show a relatively low level of inbreeding) may result in a reduced expression of genes responsible for congenital abnormalities. If the latter were true, one would expect a higher incidence of abnormalities in budgerigars and cockatiels, which have been domesticated longer than other psittacine birds. Reports in the literature would suggest that budgerigars, cockatiels and African Grey Parrots have a greater incidence of congenital deformities than do other psittacine species.<sup>2,5,20</sup> However, this apparent propensity for genetic malformation may simply represent a higher prevalence of these birds in captivity.

Documented cases of congenital abnormalities in psittacine chicks include bilateral anophthalmia in a budgerigar,<sup>2</sup> varying degrees of cryptophthalmus and ankyloblepharon in four cockatiels,<sup>5</sup> congenital extra-hepatic biliary cysts in an African Grey Parrot<sup>26</sup> and familial cataracts in Scarlet Macaws.<sup>24</sup> Skeletal deformities are considered to be the most common congenital abnormalities in psittacine birds,<sup>32</sup> but specific cases rarely have been reported in the literature. Other reported, but poorly documented, deformities include hydrocephalus,<sup>25</sup> and abnormalities of the pelvis, hock, feet, sternum and jaw,<sup>2</sup> stifle and hips,<sup>2,3</sup> tarsus,<sup>3</sup> long bones of the legs<sup>1</sup> and the beak.<sup>4</sup>

A congenital extra-hepatic biliary cyst in an African Grey Parrot was diagnosed by postmortem examination. The neonate was presented with a history of abdominal enlargement since hatch. Radiography and ultrasound indicated marked hepatomegaly.<sup>26</sup> Choanal atresia was diagnosed in an African Grey Parrot and an Umbrella Cockatoo with histories of chronic (four months and four years, respectively) ocular nasal discharge since hatch. The absence of a communication between the sinus passages and glottis was confirmed by endoscopy and positive contrast rhinograms (see Figure 12.42).<sup>20</sup>

## Infectious Diseases

### Microbial Infections

Microbial infections of the alimentary and respiratory tract are among the most common problems seen in nestling psittacines and are diagnosed by examining Gram's-stained smears and culturing the crop, choana or cloaca. The interpretation of culture results in nestling birds is controversial. Strains of *E. coli*, *Klebsiella* and *Enterobacter* spp. vary widely in pathogenicity; many cause disease, but some strains can be isolated from completely normal chicks. Some veterinarians believe that gram-negative bacteria and yeast should be treated only if a nestling is showing clinical signs of disease with or without an elevated white blood cell count. Other veterinarians believe all gram-negative bacteria and yeast are potential pathogens and should always be eliminated by antimicrobial therapy. The authors' personal opinions lie in the middle. If only a few organisms are cultured in a healthy nestling, treatment should be delayed unless clinical signs are evident. Mild microbial infections that are asymptomatic at one stage of growth may become symptomatic if the bird is stressed. Infections may be asymptomatic during the growth phase but become symptomatic during the stress of weaning. Because psittacine chicks are relatively easy to medicate prior to weaning, it may be prudent to treat and eliminate mild infections during the growth phase, especially if the hand-feeder is less experienced.

Treatment of microbial infections in nestling birds should be approached in the same manner as in adults (see Chapter 17), with a few special considerations. Medication is more easily delivered via the oral route because nestling birds are fed and handled frequently. If possible, antibiotics should be administered when the alimentary tract is relatively empty. Food in the alimentary tract reduces the absorption of most antibiotics, and calcium in the diet will sig-

TABLE 30.7 Procedures During a Nursery Disease Outbreak

- 1. Plan ahead:** Aviculturists should have a plan before an outbreak occurs. As explained below, at least three separate nursery rooms will be required in a disease outbreak. Friends and families can sometimes be enlisted to take birds into their homes and feed them, but it is best if they are trained before they are actually needed.
- 2. Isolate clinically ill birds:** At the first signs of illness, a chick should be isolated in a separate room, preferably one with air flow that is separate from the main nursery. Some aviculturists will question why isolation is necessary because the sick bird has already exposed the rest of the nursery to the disease. Sick birds should be immediately isolated because they shed higher quantities of infectious agents than asymptomatic carriers. Isolation of clinically ill birds can greatly reduce the load of infectious material in the nursery.
- 3. Do not bring new birds into the nursery:** New hatchlings should go to a separate nursery room to avoid exposure. Ideally, a separate caretaker would be available for these birds.
- 4. Maximize good hygiene practices:** If good hygiene practices are not in effect, they should be implemented immediately. Great care should be taken to reduce disease exposure when feeding chicks. If the same feeders must feed ill and healthy chicks, they should shower between groups and wear separate protective clothing in each room.
- 5. Determine the cause:** Polyomavirus is the most common cause of nursery outbreaks; PBFD virus, chlamydial, yeast and some bacterial infections can also spread rapidly through a nursery. In some cases, it is best to sacrifice and necropsy an ill nestling to rapidly determine the etiology of the disease problem. This may provide information that can save the other birds. Many microbial infections are secondary to diseases that are difficult to diagnose (such as polyomavirus, PBFD virus and chlamydia).
- 6. Treat the birds:** If microbial infections are identified, treatment should be initiated with appropriate drugs. If viral infections are identified, consider euthanasia or isolate sick birds and provide supportive care.
- 7. Eliminate the cause:** Find and treat or eliminate asymptomatic disease shedders. Investigate hygiene and feeding practices if microbial infections are confirmed.
- 8. Consider all-in all-out procedures:** Consider the primary nursery to be an isolation area. Do not add new birds until all nestlings that were exposed to the disease are moved to another area. This practice is essential with diseases with a long incubation or latency period (eg, polyomavirus and PBFD virus).
- 9. Decontaminate the environment:** During the outbreak, clean the facility, brooders and air control system frequently to decrease environmental contamination. At the end of the outbreak, thoroughly clean and disinfect the room before using it as a nursery. If polyomavirus or PBFD virus were encountered, pay particular attention to cleaning the air control system (see Chapter 32).
- 10. Do not sell chicks until proven healthy:** As noted above, many diseases (especially polyomavirus and PBFD virus) have a long incubation period. Some birds that are infected early in development will not show clinical signs until weaning. Ideally, neonates should not be sold until they are tested for these two viral diseases.

nificantly reduce the absorption of tetracyclines. However, some oral antibiotics cause local GI irritation (eg, trimethoprim/sulfonamide combinations and doxycycline), and birds will regurgitate unless the drug is administered with a small amount of food. A bird should not be fasted for antimicrobial administration if this will reduce the number of feedings and slow growth. If injectable drugs must be used, the subcutaneous route is preferred, because young nestling birds have little muscle mass and it is difficult (but not impossible) to deliver intramuscular injections. Injections should be carefully given into the pectoral muscle of young chicks, as the sternum is soft and easily penetrated with a needle. To prevent secondary yeast infections, neonates should be screened with fecal Gram's stains, or nystatin should be administered prophylactically. The source of the microbial infection and contributing causes such as malnutrition should be identified and eliminated.

### Viral Infections

Nestling birds are prone to viral infections that may be carried symptomatically or asymptotically by adult birds. These diseases are more completely described in Chapter 32; the salient points in nestlings are described in this section.

Polyomavirus is the most common viral infection described in psittacine nurseries. The onset of clinical signs is usually acute and includes crop stasis, listlessness, regurgitation and vomiting. Hemorrhages may be observed on the skin, and injection sites and broken or plucked feathers will bleed excessively (see Color 32). Most birds are nonresponsive to therapy and die within 24-48 hours. Survivors fail to gain normal weight, are prone to secondary microbial infections and often fail to wean. Feather abnormalities can occur that are grossly similar to those seen with PBFV virus infections. Epilation of all of the large flight feathers of the wings and tail has been observed in older cockatoos. Mortality in the nursery can be widespread or sporadic, depending on the immune status of the chicks and husbandry practices in the nursery. A more common and subtle clinical presentation has been identified. Slow growth, abnormal flora (gram-negative and yeast), beak malalign-

ment, leg deformities and hepatomegaly may be the only clinical signs present (Harrison GJ, unpublished).

Polyomavirus can be controlled in an aviary by testing adult birds and raising neonates from carriers separately from neonates from non-carriers. Neonates can be tested as they are pulled from the nest to determine if they are shedding polyomavirus. Shedders should be raised separately from non-shedders.

Psittacine beak and feather disease also occurs in neonates (see Color 32). Cockatoos and African Grey Parrots are most commonly affected. Clinical signs are most often seen in older, fully feathered chicks just prior or at the time of weaning (Figure 30.21). The onset is subacute and clinical signs include weight loss, listlessness and feather abnormalities. Many neonates showing clinical signs will have reduced red and white blood cell counts. For example, an affected African Grey Parrot with severe bone marrow necrosis had a total white blood cell count of 2000 and a PCV of 4. Idiosyncratic syndromes are seen in some species; loss of only the tail feathers has been observed in *Poicephalus* spp. and lorries. The course of disease is often chronic. PBFV virus can be eliminated from a collection by testing adult birds and removing those that are subclinically infected.



**FIG 30.21** A group of 14 African Grey Parrots developed PBFV after being exposed to the virus by a hand-feeder who worked in a pet shop where a PBFV virus-infected bird was housed. The neonates were of varied age when exposed to the virus and had different gross presentations of the disease. The two chicks on the right were clutchmates that were about ten days old when exposure to the virus was suspected to have occurred. In these chicks, most of the tail, flight and body feathers were affected. The chick on the left was about five weeks old when exposure occurred, and in this bird, only a few of the flight and tail feathers were initially involved. All of the birds were confirmed to have PBFV virus by immunoperoxidase staining of feather biopsies and by DNA probe detection of PBFV virus nucleic acid in circulating white blood cells. This outbreak indicates the varied clinical signs that occur with PBFV virus infections depending on the age of the bird when virus exposure occurs. It also emphasizes the danger in having individuals that are exposed to other birds (those outside of the closed nursery) having contact with neonates.

Any neonate that is transferred from a facility should be tested negative before shipment. This will protect the aviculturist from allegations that they sold a subclinically infected bird.

Other viral infections are rarely reported in nestling birds. Herpesvirus infection (Pacheco's disease) occasionally causes nursery outbreaks. Poxvirus occurs primarily in lovebirds and imported South American psittacines such as Amazon and *Pionus* parrots. Poxvirus outbreaks may occur in tropical regions (eg, southern Florida) with high bird and mosquito populations (Harrison GJ, unpublished). Poxvirus is also common in free-ranging passerine birds and Columbiformes. The clinical signs and management are similar to those in adults (see Chapter 32).

Diseases of suspected viral etiology are occasionally observed in pediatric patients. Neuropathic gastric dilatation has been described in birds of all ages. Care should be taken when interpreting juvenile bird radiographs since the proventriculus is normally larger than in adults. Avian viral serositis is a neonatal problem characterized by the accumulation of serous fluid in the abdominal cavity (see Color 32).<sup>19</sup> Large amounts of fluid may accumulate and cause severe abdominal distension. Liver, bursal and lymphoid necrosis may also occur. This problem has been suspected to be caused by a togavirus that is related to eastern equine encephalomyelitis virus.

### Parasitic Infections

With a few exceptions, internal parasites are an infrequent cause of disease in nestling psittacines in the United States, but are commonly found in countries where parrots are raised in flights with dirt floors. They are also found in finches, zoological avian species and free-ranging birds. *Trichomonas* and *giardia* are frequent causes of death in young budgerigars, cockatiels, finches and Columbiformes. *Coccidia* are commonly recovered from lorries, lorikeets, passerines, Columbiformes, and finches; their importance appears to depend on the chick's immune status. *Atoxoplasma serini* is a common cause of mortality in juvenile canaries. The safety of many parasitocidal drugs has not been investigated in nestling birds, and care should be exercised when selecting a treatment regimen. For example, furacin has a low therapeutic index in lory neonates (see Chapter 37).

## Disorders of the Alimentary Tract

### Pharyngeal and Esophageal Trauma

Damage to the pharyngeal or esophageal wall can occur during metal tube- or syringe-feeding when a nestling lunges against the feeding instrument. This can be prevented by being careful or by use of a soft crop tube when administering food to birds with a strong feeding response, such as macaws. When a puncture occurs, food may be deposited into the subcutaneous tissues and will often migrate caudal to the puncture site (Color 30.8). Liquid food can drain all the way to the base of the crop and be confused with crop contents. If the puncture is in the pharyngeal cavity, food will usually collect in the space ventral to the mandibles. Extravasated food causes a massive inflammatory response and should be treated aggressively and quickly. The bird should be stabilized, and the food pockets surgically opened, curetted and thoroughly flushed (see Chapter 41). Antimicrobial therapy designed for both gram-positive and gram-negative organisms should continue for at least 14 days.

### Air in the Crop

Bubbles or filling of the crop with air is usually caused by aerophagia. It occurs most often in stunted birds that beg constantly for food, but has also been observed in young birds of many species (especially cockatiels). Slowly delivering food will contribute to aerophagia because the chick attempts to gulp the feeding formula faster than the food is provided. Some inexperienced hand-feeders will confuse this condition with crop stasis, subcutaneous emphysema and filling of the cervicocephalic air sac. Air is easily distinguished from food or fluid by transilluminating the crop. Visualization of blood vessels in the crop wall can help differentiate between air located in the crop and air located in the subcutaneous space.

Severe aerophagia decreases the amount of food the bird can consume and may contribute to stunted growth. Feeding a nutritious formula at a steady rate will correct the problem in some birds. If aerophagia is persistent, the ingested air can be carefully removed ("burped out") and the bird immediately fed before it can gulp more air. In some cases it may be necessary to tube-feed these neonates.

### Crop Stasis

Failure of the crop to empty normally is a common sign of illness in nestling birds. The problem is usually related to generalized gut stasis (often caused by a yeast or gram-negative bacterial infection) rather

than a primary crop disorder, but there are numerous possible etiologies. Food that remains in the crop will ferment and have a sour odor — hence the lay term “sour crop” (Color 30.14).

Causes of crop stasis include:

- Primary crop disorders: foreign bodies, crop infections; crop atony caused by overstretching; crop burns; crop impactions caused by fibrous food, large food chunks (eg, raw carrots) or bedding; and dehydration of food in the crop leading to formation of a concretion or doughy mass.
- Delayed transit time or obstruction of the distal gut: intestinal ileus due to generalized infection, neuropathic gastric dilatation, polyomavirus, GI foreign bodies or hypothermia.
- Cold food.

The motility of a normally functioning crop that is free of infectious agents should not be altered by the consistency of the food. The crop should be examined and gently palpated to determine if it is atonic or burned, or if foreign material or an impaction is present. A CBC, serum chemistries, cloacal culture and radiographs are indicated if the bird has clinical signs of disease. Whole body radiographs can be used to evaluate the distal alimentary tract and barium contrast studies can be used to determine gastrointestinal transit time. The crop can be swabbed or flushed for culture and cytology.

A bird with crop-emptying problems should be fed carefully. The crop should not be overstretched, as this will cause atony and compound the problem. Mild cases of crop stasis caused by a dehydrated food mass or overfeeding can often be solved by administering a small amount of warm water and gently massaging the crop. If the food does not pass in three to five hours, the crop should be emptied and flushed with warm saline. This removes the old food, which acts as a growth media for microbial proliferation. To flush the crop, a lubricated soft feeding tube with an open end is gently passed into the crop, and a small amount of saline is flushed in and out to draw crop material into the syringe. It may be necessary to palpate the tube and direct it toward the food mass and away from the crop wall. When moving or withdrawing the tube, negative pressure on the syringe should be released to make sure the tube does not attach to the crop wall and cause damage. The removal procedure should be accomplished in stages if the bird becomes overly stressed.

Crop stasis caused by generalized ileus is a serious problem that requires immediate attention. Complete stasis may be one of the early signs associated with fatal diseases such as polyomavirus, PBFV virus, septicemia or sarcocystis infection. With these progressive diseases, treatment may not be successful. If the stasis is caused by a microbial infection (yeast, bacteria or chlamydia), intensive medical management may be effective. Treatment consists of antimicrobial therapy targeting the etiologic agent, correcting the dehydration and malnutrition that result from stasis and providing a complex carbohydrate diet to provide energy and gently re-stimulate gastrointestinal motility (Table 30.8).

### Crop Burns and Fistulas

Crop burns can occur when excessively heated food is fed or if a bird contacts a heating pad or hot light. Severe burns can result from a single, overly heated meal (eg, greater than 120°F), or by repeated exposure to food that is slightly hot (115°F). Birds will readily accept hot food, and the feeder may not recognize a problem for days to weeks after the burn occurs. If one bird in a nursery has a crop burn, all of the other neonates should be carefully examined to determine if they have also sustained injuries.

The method of treatment depends on the degree of tissue damage and stage of healing. Mild burns result in tissue swelling, erythema and blister formation, and can be treated with antibiotics and topical application of soothing vitamin A and E ointments (Color 30.11, 30.12). The bird should be fed reduced volumes more frequently during the healing process.

Severe crop burns cause greater tissue damage. In the early stages the crop will adhere to the overlying skin; the skin will be hyperemic and the site may be covered with a scab. Eventually the crop may fistulate, and food and water will leak from the crop soiling the bird's chest. Bird owners are frequently puzzled by this odd phenomenon. Crop fistulas are treated by removing the scab, surgically excising the necrotic portion of the skin and crop and then separating and individually closing the crop and skin (see Chapter 41) (Color 30.12). The timing of surgery is important. Birds with this condition are often debilitated and should receive supportive care and enteral alimentation to build their strength prior to anesthesia and surgery. Ideally, the tissues surrounding the fistula should be given as much time as possible to heal before surgery, and the scab should be left in place as long as possible to encourage wound contraction that will reduce the size of the fistula (Color

**TABLE 30.8 Treatment for Crop Stasis**

1. Empty and flush the crop with LRS using a feeding tube. Repeat every six to twelve hours if the crop does not empty. Digestive enzymes are often beneficial.
2. Give intravenous, intraosseous or subcutaneous fluids. Most birds with crop stasis are dehydrated and require parenteral fluid administration. A Gram's stain of a crop swab can be used to determine the microbial agents that are present.
3. If a generalized microbial infection is suspected, start treatment with a broad-spectrum antibiotic and antifungal drug. Cephalosporins and penicillins are the safest drugs to use; aminoglycosides and sulfas should be avoided due to potential dehydration and renal toxicity. Injectable antibiotics should be used if there is severe stasis because oral antibiotics would not be properly absorbed. Oral antifungals (nystatin) should be used because the parenteral antifungal drugs (eg, amphotericin B) may be toxic. If chlamydiosis is diagnosed, a single SC injection of oxytetracycline or doxycycline IV can be used to initiate therapy, followed by oral doxycycline (see Chapter 17).
4. If the bird has generalized ileus, a motility stimulant such as metoclopramide or D-panthenol can be administered. Response to these stimulants is highly variable.
5. Once the crop starts to partially empty and the bird is stabilized, limited feeding should resume. The bird should be fed a liquid, complex carbohydrate, medium-fiber-content diet until the crop is emptying normally (see Chapter 15). Gerber's oatmeal with applesauce and bananas baby cereal mixed 50:50 by volume with water works well. The bird should be fed less volume, more frequently. As the crop starts to empty normally, the diet that is normally fed should be gradually substituted (provided it is nutritionally adequate). It is important to restore normal feeding as quickly as possible because dilute baby food diets do not provide sufficient nutrition for growth. Subcutaneous fluid administration and antibiotics should continue until the bird is clinically normal.
6. If the crop is overstretched or atonic it is beneficial to apply a "bra" to elevate the crop and facilitate emptying (Figure 30.22). The bra can be constructed from elastic bandage material or baby tube socks and should be applied while the crop is full to make sure it is not too tight. The neonate should be confined to a small container for a few days if it objects to the bra and falls over backwards. Most chicks will eventually accept the bra.
7. Parenteral nutrition would be beneficial in cases of crop stasis; however, at the time of this publication this is still a highly experimental procedure and specific recommendations are speculative at best (see Chapter 15).

30.12). If surgery is attempted before the tissues surrounding the burn have healed, it is difficult to accurately assess the extent of devitalized tissue that must be debrided. Surgical adhesives can be used to close the crop and allow feeding or a pharyngotomy tube can be passed (see Chapter 41). It has been estimated that it takes seven to ten days following a burn to determine the extent of tissue injury.<sup>8</sup>

Large crop defects (greater than one-third the size of the crop) can be difficult to repair. Closure frequently



**FIG 30.22** In an overstretched, pendulous crop, the distended crop hangs over the thoracic inlet where food cannot enter the thoracic portion of the esophagus. A crop bra can be used to elevate the crop and increase the gravitational forces that encourage food to pass through the thoracic portion of the esophagus and into the proventriculus (courtesy of Kim Joyner).

results in a reduced crop capacity. Following repair, the bird should be fed small amounts of food frequently to prevent reflux and aspiration. The amount of food offered can be gradually increased to stretch the crop. If the esophagus was involved, a pharyngotomy tube may be necessary to allow feeding yet protect the wound during healing. An alternative to a pharyngotomy tube is to place a mushroom-tipped jejunal catheter in the crop and tunnel it subcutaneously up the side of the neck. If it is impossible to close the skin over the defect, the wound should be covered with a permeable dressing and allowed to heal as an open wound.

### Regurgitation

Hand-fed birds (especially macaws and African Grey Parrots) commonly regurgitate at weaning, and it is important to differentiate this relatively normal phenomena from a pathologic condition. Causes of regurgitation include overfeeding, crop stasis, alimentary tract infections (especially candidiasis), alimentary tract foreign bodies, blockage of the alimentary tract and use of some drugs such as trimethoprim-sulfa compounds and doxycycline. Treatment consists of correcting the underlying cause.

### Foreign Body Ingestion or Impaction

Nestling birds are curious and may ingest foreign objects. Preventing neonates from consuming foreign bodies is far easier than treating them. The feeder should be very selective about the objects the birds are allowed to contact (Color 30.9).

If a consumed foreign object is located in the crop, the bird should be treated immediately to prevent the object from entering the proventriculus. It is much easier to retrieve objects from the crop than the proventriculus, and birds have a remarkable capacity for passing even relatively huge objects such as feeding catheters into the proventriculus. Some objects can be "milked" up the esophagus and retrieved from the caudal oral cavity with forceps. Forceps can also be introduced into the crop to retrieve foreign bodies, with or without the aid of endoscopy. Objects can also be retrieved via an ingluviotomy incision (see Chapter 41).

Objects in the proventriculus or ventriculus can be tolerated for long periods<sup>8</sup> but should be retrieved if they have the potential to erode the stomach wall or can be digested, resulting in toxicity. Foreign bodies may be removed using an endoscope, or forceps can be passed into the proventriculus via an ingluviotomy incision with the aid of air insufflation (via a rubber catheter) (see Chapters 13, 15). The endoscope must be carefully passed to prevent rupture of the thoracic esophagus or proventricular wall.<sup>8</sup> The proventriculus and ventriculus can also be opened surgically as described for adult birds (see Chapter 41).

Proventricular or ventricular impactions caused by grit or bedding material are serious and require urgent attention.<sup>8</sup> Mild accumulation of material in the ventriculus (that does not impede passage of ingesta) can be treated by hydrating the patient and administering laxatives (dioctyl sodium sulfosuccinate or psyllium or digestive enzymes). Psyllium should be limited to no more than one percent of the dry weight of the tubed formula to prevent it from causing an impaction. If this does not work, mineral oil should be administered into the crop, followed 30 minutes later by a large volume of barium sulfate (10 to 15 ml/kg) that may help force the mineral oil through the GI tract by gravitational pressure. The patient should be kept well hydrated with SC fluids due to the hygroscopic nature of barium sulfate. Serial radiographs can be used to evaluate the success of the therapy. If this treatment fails, proventriculotomy (see Chapter 41) or gastric lavage (see Chapters

13,15) can be attempted but are associated with a guarded prognosis.

### Intestinal Intussusception

This condition is occasionally reported in macaws and is associated with diarrhea and possibly intestinal hypermotility.<sup>15</sup> In severe cases the ileum may telescope into the colon and protrude through the cloaca. Mild cases are diagnosed radiographically and may respond to antimicrobial and supportive therapy. Severe cases with a visible cloacal prolapse are usually fatal.<sup>8,15</sup> Successful jejunostomy and jejunocloacal anastomosis has been reported.<sup>35</sup>

## Disorders of the Respiratory Tract

### Upper Respiratory Infections

Nestling birds can pass food through the choanal slit, resulting in clogged nostrils and upper respiratory problems. These can be treated by removing the food plug with a feathered wooden applicator (see Chapter 8) or dull needle, and gently flushing the nares with saline until clear. Microbial infections of the upper respiratory tract are treated in the same manner as in adult birds (see Chapter 22).

### Aspiration Pneumonia

Birds may aspirate food during feeding or following regurgitation. Aspiration occurs most often in birds that are reluctant to feed or if the aviculturist introduces food when there is no feeding response. If large amounts of food are inhaled, the bird will die from asphyxiation (see Color 22). Rapid placement of an air sac cannula and aggressive antimicrobial (eg, trimethoprim-sulfa, ketoconazole) and steroid therapy may save the patient, but the prognosis is poor. Some birds respond to such aggressive treatment and die months later due to a chronic fungal infection. If small amounts of food are aspirated, the event may not be noted at the time but the bird may later develop a foreign body pneumonia. An affected bird will show poor weight gain, a persistently elevated white blood cell count and may or may not show respiratory signs. Often, the pneumonia may be noted only by radiology or at necropsy.

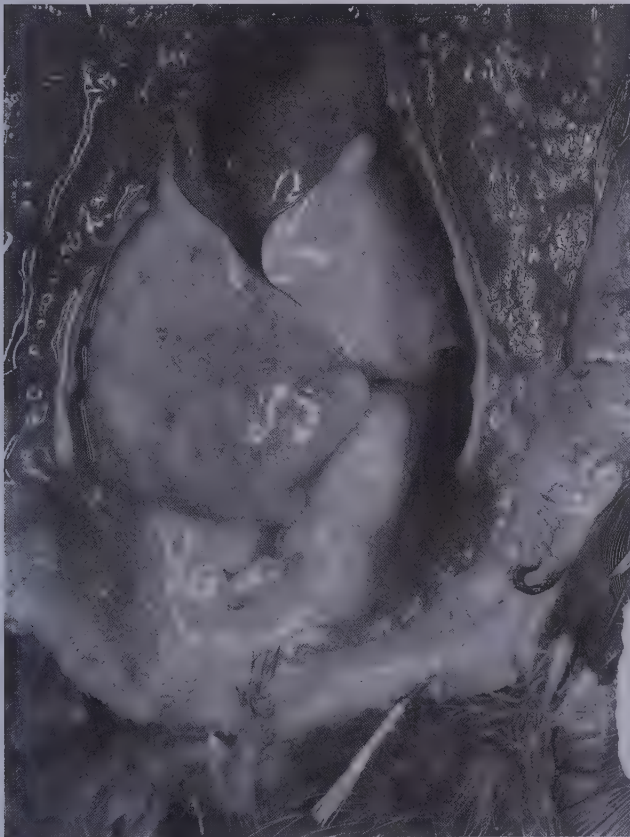
## Miscellaneous Disorders

### Hepatic Lipidosis

In most cases, hand-fed birds gain weight slower than parent-fed birds, and the hand-feeder should be instructed to maintain the maximum weight gain possible. Umbrella Cockatoos, Moluccan Cockatoos



and Blue and Gold Macaws may be an exception to this recommendation. In these species, and possibly others, it is possible to overfeed (especially in the later development stages) and cause massive weight gains and hepatic lipidosis. It has been suggested that multiple deficiencies of fiber, vitamins and minerals and nutritional excesses combine to cause this problem (Harrison GJ, unpublished). Affected birds are usually dyspneic, especially when food in the digestive tract places additional pressure on the respiratory system following feeding (Figure 30.23). The abdomen is usually protuberant and the pale, enlarged liver may be visible through the skin. In these cases, the amount of food fed should be *gradually* reduced and small meals should be fed more often to avoid respiratory distress. Hyperthermia will aggravate the respiratory distress and should be avoided. If identified early, the birds may wean normally, but



**FIG 30.23** A six-week-old Blue and Gold Macaw was presented for a swollen, fluid-filled abdomen and severe dyspnea. The bird was 30% heavier than normal when compared to standard weight charts. The neonate was being fed a homemade formula that consisted of a peanut butter base supplemented with numerous herbs and vitamins. The owners requested euthanasia. On post-mortem the bird had large accumulations of fat throughout the abdomen, and the liver was whitish-yellow with a roughened, irregular surface suggestive of hepatic lipidosis.

in severe cases the liver will be massively enlarged and the bird will die. This condition can be prevented by feeding a proven diet and comparing the bird's weight gain to establish growth charts. If the bird is normal in body size but substantially heavier than the upper limit on the chart, the possibility of hepatic lipidosis should be considered.

### Hepatomas

Hepatic hepatoma has been described primarily in macaws, and may occur when blunt trauma ruptures the liver and causes hemorrhage.<sup>15</sup> The trauma may occur when the bird is lifted with pressure over the liver or it may simply be idiopathic. Affected birds are pale with extremely low hematocrits and may be saved by repeated blood transfusions within the first few days following the traumatic event.

### Gout

Deposition of uric acid crystals in the tissues is called visceral gout and is usually due to end-stage renal disease. Clinical signs include crop stasis and vomiting followed by death. Excess vitamin D<sub>3</sub> results in dystrophic calcification of numerous organs including the kidney, which then may result in gout (see Chapters 3, 21). Macaws seem to be particularly sensitive to excessive dietary consumption of vitamin D<sub>3</sub> and calcium (see Color 21).<sup>33</sup>

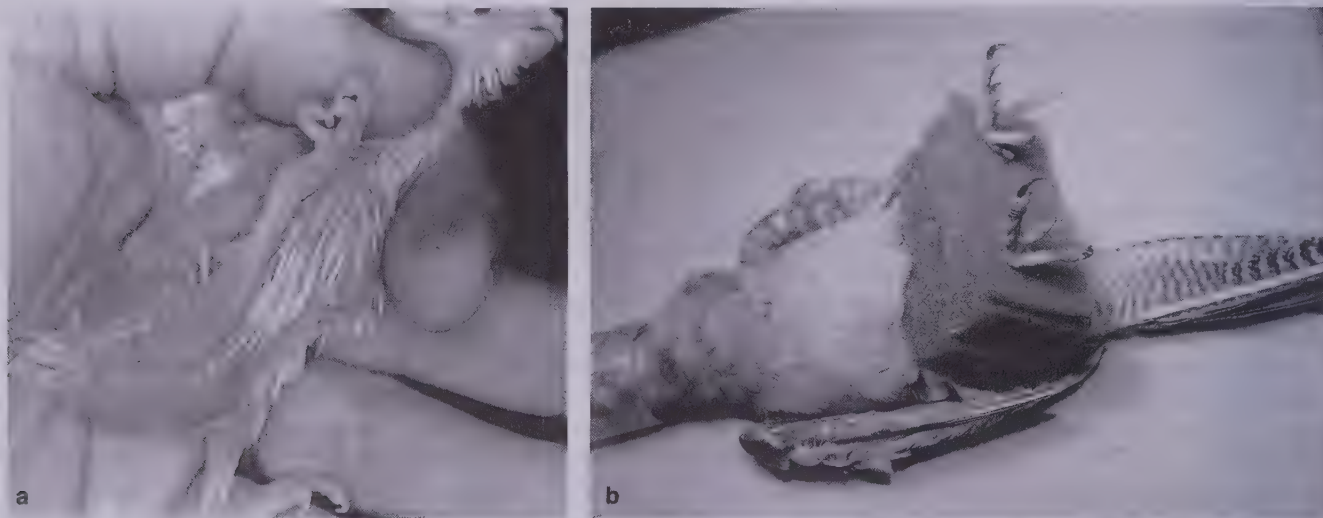
### Wine-colored Urine

Reddish urine and urates have been described in juvenile African Grey Parrots and some Amazon and Pionus parrots. It can be distinguished from hematuria by a fecal occult blood test. It occurs sporadically with several hand-feeding formulas, and the pigment may be more pronounced on some bedding materials, especially certain brands of paper towels. This condition has not been associated with pathology or other clinical signs.

## Musculoskeletal Disorders

### Leg Deformities

Orthopedic problems in nestling birds are poorly understood and the causes are believed to be multifactorial. Nutritional deficiencies (especially of vitamin D<sub>3</sub> and calcium), trauma and housing the birds on slippery surfaces are the most common causes. Genetic and incubation abnormalities probably also occur. Polyomavirus may be a common underlying cause (Harrison GJ, unpublished). In general, leg deformities are challenging to repair and the earlier the diagnosis and the younger the bird, the better the prognosis<sup>8,15</sup> (see Chapter 42).



**FIG 30.24** a) The cause of splay leg in psittacine birds has not been confirmed. Suggested etiologies include nutritional deficiencies, trauma, poor footing, improper incubation and genetic defects. Severe deformities, like the one in this cockatiel chick, are difficult to treat without surgery. b) In mild cases that are treated early, splinting or foam rubber hobbles may be effective in correcting the lesion (courtesy of Robert Clipsham).

▪ **Spraddle or Splay Leg:** Birds with this condition will have one or both legs splayed laterally from the hip or stifle (Figure 30.24). Mild deformities can be treated by packing the bird in a deep cup with tissue or towel padding to take pressure off the legs. More severe deformities and those in older birds require a fixation device in addition to packing in a cup. The chick can be taped over a foam rubber pad or sanitary napkin, or placed in a piece of foam with slits cut for the legs. As an alternative, the legs can be hobbled together with elastic tape at the tarsometatarsus and if needed across the tibiotarsus. The hobble sites should be padded with cotton and care should be taken not to tape too tightly. The hobble should be changed every two to four days to allow growth. More severe deformities require more rigid fixation.<sup>8,15</sup> A suspension method of treating this condition has been reported.

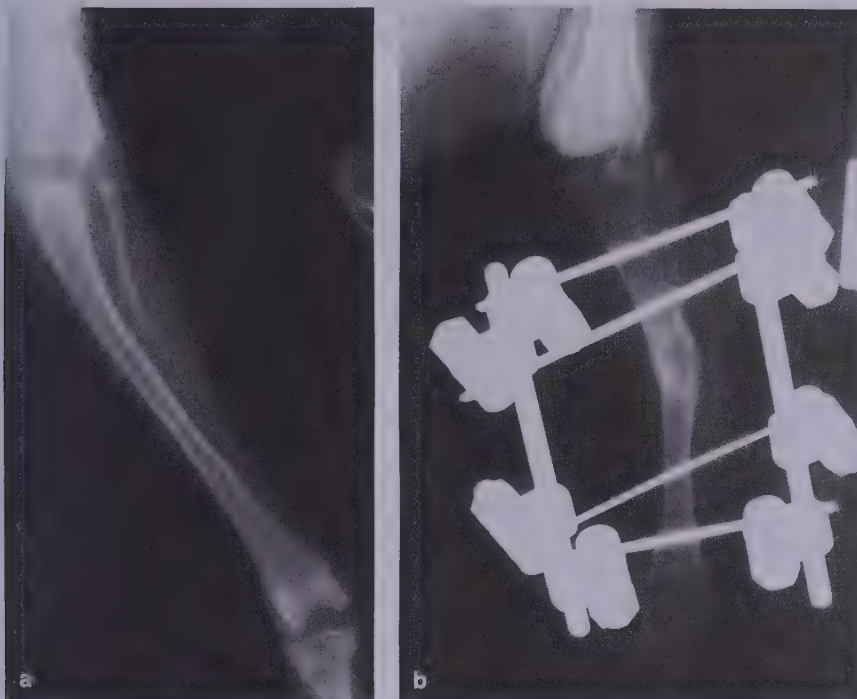
▪ **Valgus Deformity** (Bowing of the tibiotarsus with lateral rotation of the femur or tibiotarsus): This is usually caused by premature closure of one side of the growth plate of the proximal or distal tibiotarsus. This causes uneven bone growth and bowing and twisting in the tibiotarsus (Color 30.6). It is a serious condition that may not respond to conservative treatment. Surgically closing the opposite side of the growth plate or periosteal stripping to even out the growth, followed by a dome osteotomy and realignment of the tibiotarsus may be necessary.<sup>15</sup> The osteotomy is repaired with a biplaner KE apparatus. The osteotomy is best performed after the bones have

ossified (Figure 30.25). Macaws and cockatoos should be approximately 65-70 days old before attempting an osteotomy procedure.

#### Toe Malposition

Malposition of digits in neonatal birds is believed to be secondary to malnutrition. Reducing the dietary protein content and slowing the growth of some chicks may aid in correcting the problem.<sup>8</sup> Affected chicks should receive parenteral and dietary vitamins and mineral supplements including vitamins A, D<sub>3</sub>, E, B complex, C, K<sub>1</sub>, calcium, iodine, selenium, iron, copper and cobalt. Other proposed etiologies include virus infection and improper incubation.

Improving the substrate is also beneficial. The chick should be placed in a smaller, padded environment such as a teacup lined with a towel. This will help diminish the tendency for the legs to splay and the toes to curl. In some patients, this alone may be adequate to correct the condition without splinting.<sup>8</sup> In many cases, taping the affected toes in a normal position is necessary. This condition develops quickly, often in a matter of hours, and when the toes are taped in a normal position, the condition is corrected quickly. Generally, the affected digits should be maintained in the supported position for approximately as long as they were malpositioned (usually a maximum of several days). If the condition is recognized early, corrective measures may be required for only a few hours. This must be monitored closely as deformities can be caused by leaving bandages or splints on too



**FIG 30.25** a) An eight-week-old Moluccan Cockatoo was presented with a valgus deformity of the left tibiotarsus. Radiographs indicated bowing of the tibiotarsus starting in the proximal third of the bone. b) The defect was repaired using a dome osteotomy that was stabilized with a bilateral KE apparatus. This radiograph was taken four weeks post-surgery. Note the stable bone union and minimal callus formation suggestive of primary bone repair. The stabilizing pins used in this bird were positive-profile threaded pins that provide maximum strength and tend to form a tight, long lasting pin/bone interface. All of the pins in this bird remained secure and had to be removed by “unscrewing” them from the bone.

long. Additionally, the developing circulatory system and muscle mass of neonates make them more susceptible to edema and pressure necrosis. Their skin is friable and sensitive, so all forms of external coaptation should be adequately padded.<sup>8</sup>

A corrective shoe may be made from a piece of firm material such as thin cardboard or radiographic film. The shoe should be made to properly fit the foot of the affected individual with a notch in the shoe into which each toenail will be placed. Once the shoe is made, the foot is placed in the shoe and each digit is taped into a normal position using very thin strips of masking tape. A hydroactive dressing may be used to make a corrective shoe. The material is cut to fit the foot as described above. The plantar aspect of each toe is placed on the sticky surface of the hydroactive dressing in a normal position. A second piece of hydroactive dressing is applied dorsally to sandwich the toes in place and to maintain reduction. This material is especially appropriate as it is soft, unlikely to cause pressure problems and easy to remove.

### Constricted Toe Syndrome

This condition is most commonly reported in Eclectus Parrots, macaws and African Grey Parrots. Any toe may be affected, but the distal phalanx of the outer digits (1 and 4) is most often reported. The lesion consists of an annular ring of constriction that eventually causes swelling and necrosis of the distal segment of the toe (Color 30.7). It appears similar to the lesion induced by wrapping a thread around the toe, but this is seldom the cause. The etiology is unknown but may be related to low brooder humidity<sup>22</sup> or fracture of the digits. Histology usually demonstrates edema and inflammation; microbial infections are rare except as secondary invaders. The condition can be corrected and the digit saved if identified early. If the degree of constriction and swelling of the distal segment is mild, warm water soaks and frequent massage may restore circulation and correct the condition. If a fibrous annular ring is present, it should be carefully incised and accumulated serum and tissue debris gently debrided (see Chapter 41). The toe should be

soaked in warm, dilute, povidone-iodine solution and bandaged. A DMSO dressing may reduce inflammation and antibiotic ointments help soften and prevent reformation of the annular ring. If the distal segment is severely swollen or necrotic it should be surgically removed, preferably at a joint proximal to the constricting lesion. Toe constrictions can often be prevented by keeping susceptible species on non-desiccating surfaces and in brooders where the humidity is maintained above 50%. Commercial forced air brooders with rapid air changes tend to desiccate the chicks and should be avoided.

### Stifle Subluxation

Stifle luxation or subluxation in both juvenile and adult birds has been reported.<sup>8</sup> This condition may occur when a bird gets a leg caught in the enclosure and struggles to free itself. Idiopathic luxation of the stifles may also occur and appear to be particularly common in cockatiels (Figure 30.26). Rigid fixation of the stifle by applying a KE apparatus to the distal femur and proximal tibiotarsus may fuse the joint

## ■ Neonatology

### Color 30.1

Psittacine chicks are hatched basically naked with the exception of a sparse natal down. Neonates should be hatched in a warm brooder (94°F), and the feathers should dry shortly after hatching. This neonate exited the egg five minutes before this photograph was taken (courtesy of Apalachee River Aviary).

### Color 30.2

A Moluccan Cockatoo egg was presented for evaluation. The embryo internally pipped three days earlier than anticipated and died the day after entering the air cell. The embryo was hyperemic and the yolk sac had not started to absorb. The embryo weighed 32 g (the average weight for chicks from this pair was 22 g) and was considered to be large for the egg (fetal monster). Aerobic and anaerobic cultures of the yolk sac did not indicate the presence of bacteria. There was no histologic indication of abnormalities in any tissues.

### Color 30.3

Healthy neonates that are receiving proper care will be bright and alert and have full crops. Development is rapid in large psittacine chicks, like this five-week-old Umbrella Cockatoo. This neonate will grow from a hatching weight of 18 g to its adult size of 600 g in eight to ten weeks.

### Color 30.4

Healthy neonates should have yellowish-pink skin with a supple warm feel. Dehy-

drated nestlings like this Rose-breasted Cockatoo have dry, hyperemic skin that feels "sticky."

### Color 30.5

The normal liver of a recently hatched chick may appear large, pale yellow or light red. As the bird matures, the liver becomes its normal brownish-red color and assumes a more proportional size within the abdomen.

### Color 30.6

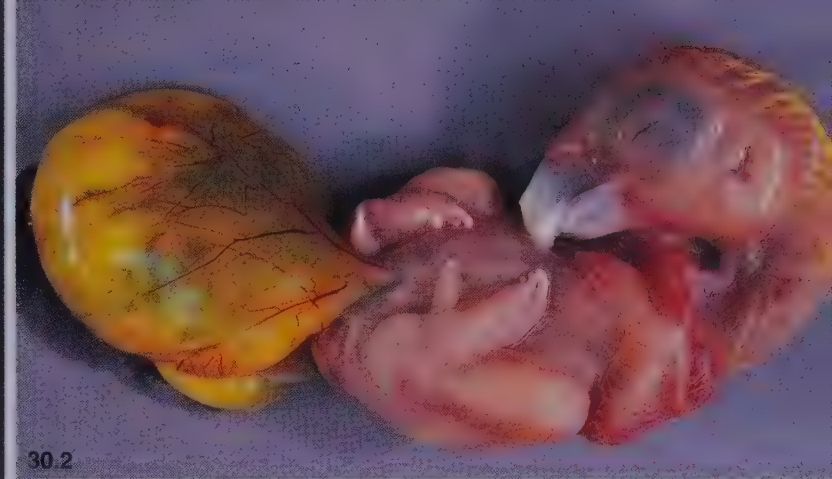
An eight-week-old Moluccan Cockatoo was presented for evaluation of a valgus deformity of the left tibiotarsus. The deformity had first been noticed at one week of age. The defect was managed conservatively by placing the bird in a vertical container; rolled towels positioned around the edges supported the bird in a continuous standing position. Physical therapy was performed on the leg for ten minutes at each feeding. The bird was presented at seven weeks of age for a corrective dome osteotomy (see Chapter 42).

### Color 30.7

A three-week-old Eclectus Parrot was presented for swelling of the distal phalanx in several digits. Numerous constrictive lesions were present in the affected digits. Examination of the constrictions with a dissecting microscope failed to demonstrate the presence of constrictive fibers. The defects were repaired surgically and the brooder humidity was increased (see Chapter 41).



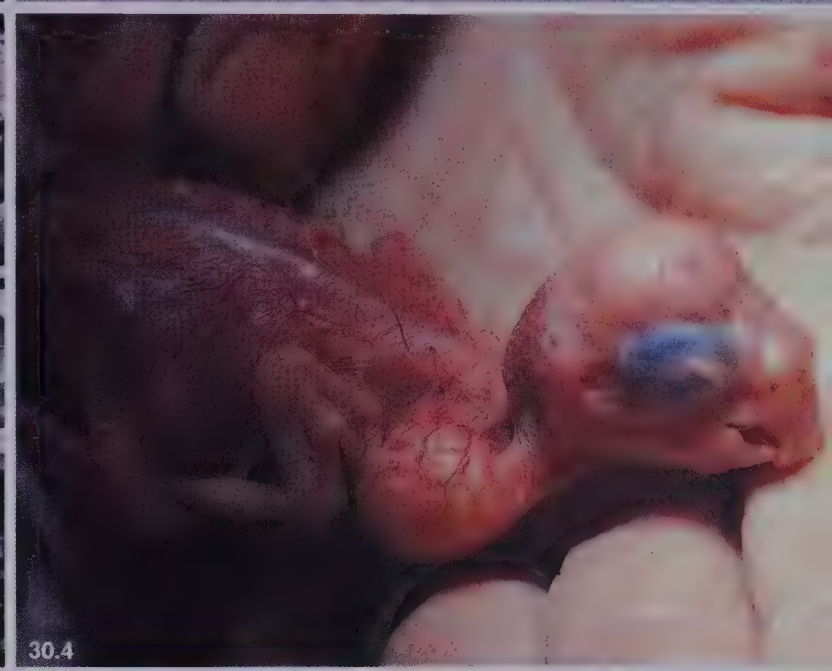30.1



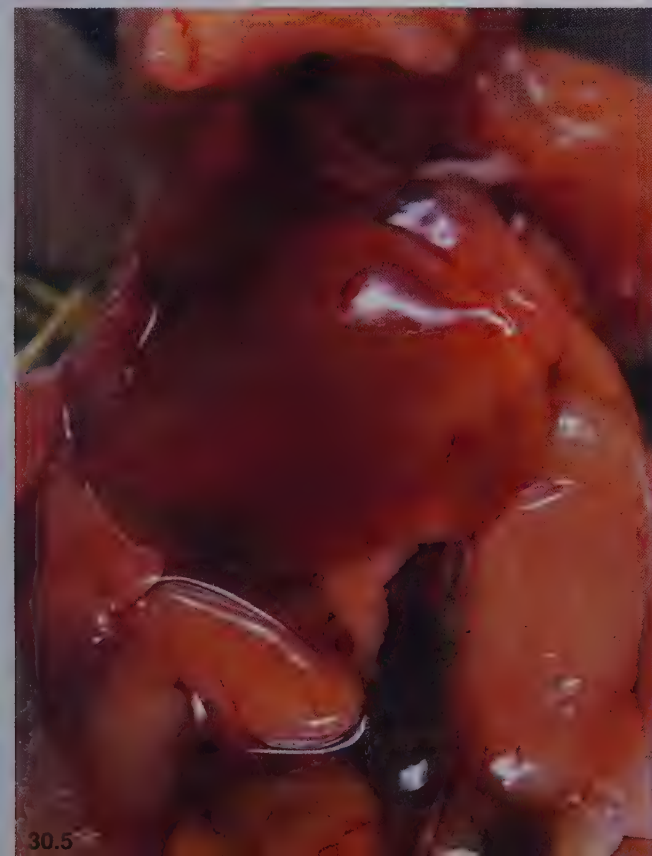30.2



30.3



30.4



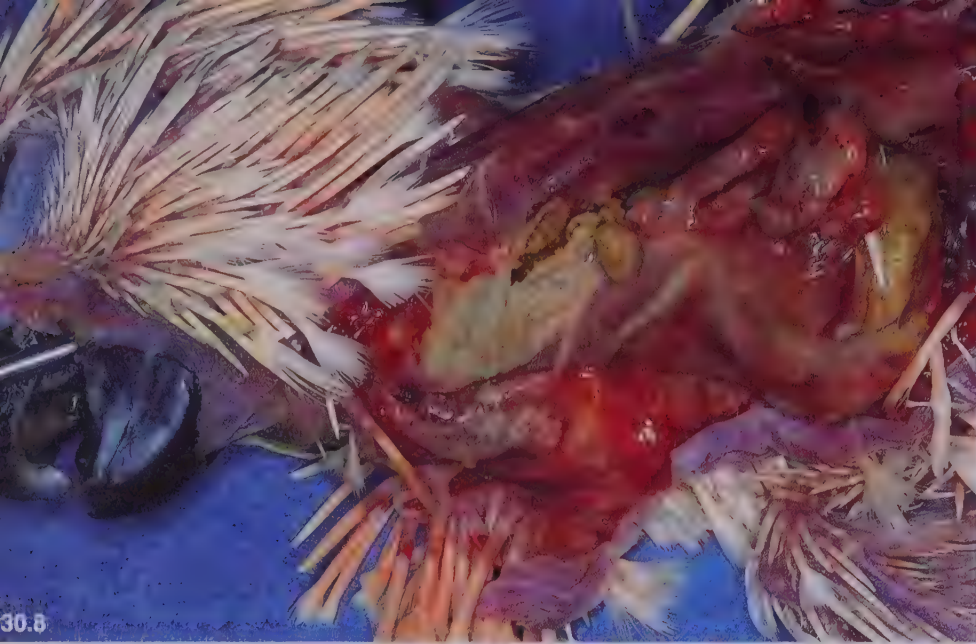
30.5



30.6



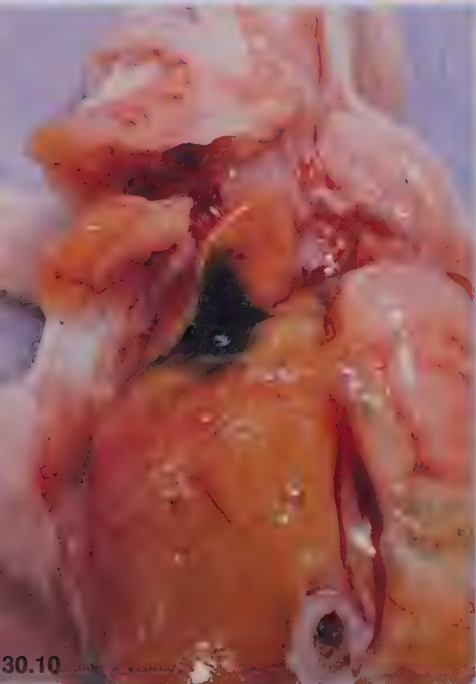30.7



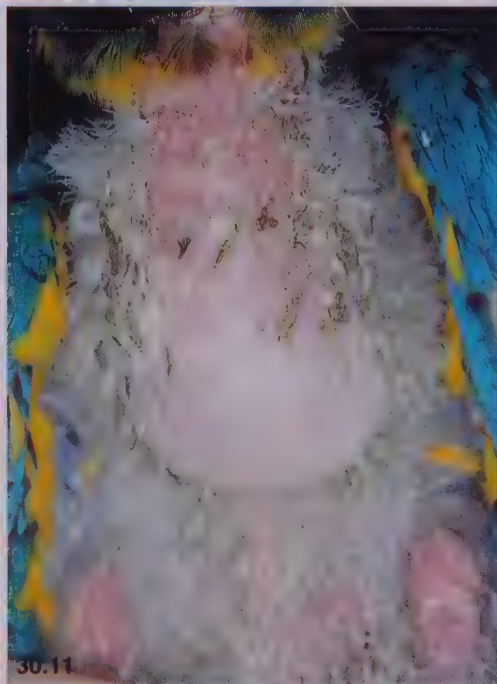30.8



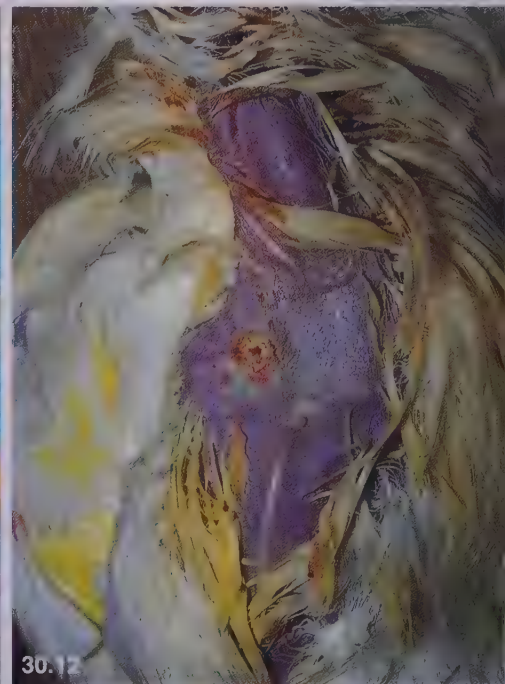
30.9



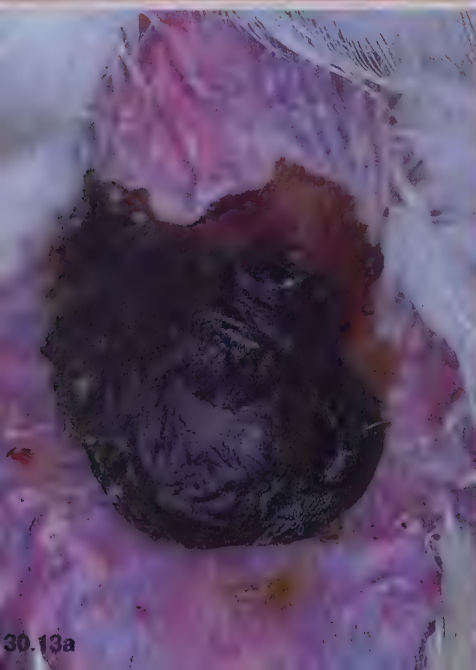30.10



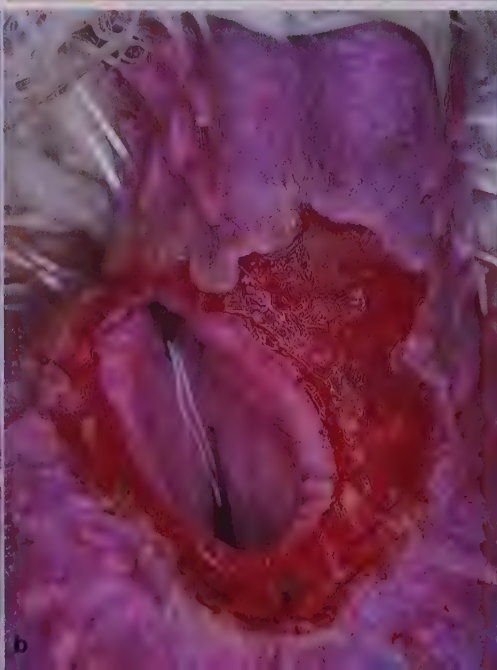30.11



30.12



30.13a



b



30.14

## Neonatology

### Color 30.8

A feeding tube or syringe tip can penetrate the pharyngeal or esophageal wall if a neonate has an over-zealous feeding response or if the feeder has a rough, careless feeding technique. Once the wall has been penetrated, food will be deposited in the subcutaneous tissues causing severe cellulitis. These cases are difficult to treat, but some birds can be saved by early and aggressive therapy that includes surgical debridement, flushing of the involved tissues and systemic antimicrobial therapy. In this photograph, a feeding tube has been placed in the esophagus to demonstrate the location of the periesophageal food.

### Color 30.9

A neonatal cockatoo was presented for necropsy after being found dead in the nest several days after hatch. This was the parents' first clutch of eggs. The parents had a broad assortment of soft foods available, including soaked monkey biscuit and mixed vegetables. The baby died from an esophageal and ingluvial impaction after being fed pieces of wood chips and dirt from the substrate in the nest box.

### Color 30.10

A 1.5-day-old Umbrella Cockatoo chick died suddenly after failing to thrive (poor feeding response, lethargic). The yolk sac had not started to absorb. The umbilicus was dry and considered to be normal. Bile pigment accumulations were noted on the dorsal surface of the liver. Aerobic and anaerobic cultures of the yolk sac revealed *Streptococcus* spp. Histopathologic findings were limited to mild hepatitis and myocarditis.

### Color 30.11

Mild crop burns may be recognized clinically as swelling, erythema and edema of the crop and esophagus.

### Color 30.12


In some cases, full-thickness crop and skin burns may cause relatively small fistulas that are easy to repair (see Chapter 41) (courtesy of Elizabeth Hillyer).

### Color 30.13

Some burns can result in massive thermal necrosis of the crop and esophagus. In any crop burn, the wounds should be treated conservatively, and surgical correction should be delayed as long as possible for differentiation to occur between damaged and healthy tissue. **a)** In this case the aviculturist noted a hyperemic area in the skin over most of the crop in a six-week-old Umbrella Cockatoo. The bird was placed on smaller feedings provided more frequently to decrease crop stretching. A large scab formed over the crop and caudal esophagus over a ten-day to two-week period. Food began to leak from the caudal-most edge of the scab. The bird's overall condition was excellent, and weight gain had continued normally since the burn had first been noticed. **b)** The scab was removed, revealing the extent of the damage. A healthy bed of granulation tissue was available to facilitate repair. The wound was thoroughly cleansed and the crop was bluntly separated from the skin. The crop and skin were closed in separate layers as described in Chapter 41.

### Color 30.14

An eight-week-old Amazon chick was presented for regurgitation, weight loss and anorexia of four days' duration. The chick was the most affected of a group of 12 psittacine neonates that were having varied clinical problems associated with poor weight gain and failure to thrive. Cytologic evaluation of crop samples indicated numerous (30/HPF) budding yeast and gram-negative bacteria (40%). Abnormal clinicopathologic findings included PCV=20, WBC=4000 (numerous toxic heterophils) and TP=2.2. The crop was distended with a doughy, solid mass. The bird died shortly after presentation despite extensive supportive care. Histopathology revealed diffuse gastrointestinal candidiasis and gram-negative bacterial septicemia. The neonates in this nursery were fed from a single syringe with a single food supply that was mixed in the morning and maintained in the refrigerator between feedings.




**FIG 30.26** Idiopathic stifle luxation appears to be common in some species of smaller psittacine birds, especially cockatiels. The problem may be congenital, and therapy is usually ineffective (courtesy of Louise Bauck).

and permit limited, but less painful ambulation. The knee should be fixed in a slightly flexed position. Tolerance of the device is variable and it should be left in place for 30-40 days in large birds and 21 days in smaller species. Flunixin can be used for one to three days after placement and removal of the fixation device to reduce pain and inflammation.

## Beak Problems

### Beak Trauma

Chicks may damage their own or a sibling's beak when they lock beaks and pump against each other, or if they pump against the brooder container.<sup>15</sup> Perlingual wounds are common and should be cleaned daily with a cotton-tipped applicator. Topical amphotericin B cream can be applied if a secondary yeast infection occurs, and antibiotics can be used to control bacterial infections. Occasionally the beak itself is damaged, creating an indentation through the beak wall. The wound should be debrided, flushed with saline, dried, and then filled with a dental acrylic. If the damaged portion of the beak is indented, it should be elevated to the level of the rest of the beak with a bent needle before applying the acrylic patch. The acrylic patch will eventually loosen as granulation tissue fills the wound. Damage and fractures of the tip of the maxillary beak should be



**FIG 30.27** A ten-week-old Umbrella Cockatoo was presented for lateral deviation of the upper beak. This defect is best corrected early when physical therapy or beak trimming procedures can be effective in resolving the problem. In older birds, like this chick, surgical techniques or implants are necessary to correct the defect (see Chapter 42).

repaired by applying dental acrylic with or without small pins to stabilize the beak tip. If the germinal center at the base of the beak is damaged, the tip will not regrow and the defect will be permanent. Birds with this condition will require frequent beak trims, as the mandibular beak will continue to grow upward.<sup>15</sup>

### Lateral Beak Deviation (Scissors Beak)

Lateral deviation of the upper beak is most often diagnosed in macaws but also occurs in other psittacine birds (Figure 30.27). In most cases, it does not interfere with eating, but it is unsightly. The etiology is unknown and may be multifactorial. Suggested causes include low or unbalanced calcium in the diet, viral diseases, trauma, abnormal pressure applied by the aviculturist during hand-feeding, incubation problems and alterations in the mandibular occlusal surface.


Early recognition is critical for easy and successful correction. If noted early (ie, a few days after hatch), the lower beak should be trimmed in a ramp-like fashion to encourage the upper beak to slide over to the side opposite the curvature. Differences in the height of the occlusal surfaces of the mandibular beak should be corrected, and digital pressure should be applied to the beak two to four times daily to gently push the beak back in position. If the beak is calcified or if conservative therapy fails, a ramp built



from dental acrylic over a stainless steel mesh can be attached to the lower beak to apply pressure to correct the upper beak<sup>7</sup> (see Chapter 42). The acrylic device should be left in place for one to twelve weeks, depending on the bird's age and the severity of the defect. Correction of severe beak deformities in older birds is seldom complete, but substantial improvement can be made.

### Mandibular Prognathism

Mandibular prognathism (underbite), in which the upper beak tucks within the lower, is seen primarily in cockatoos (Figure 30.28). Severe prognathism can interfere with self-feeding. The etiology of this condition is unknown. It has been suggested that the parent bird may hook the maxilla during feeding and help extend it, an event that may not occur during hand-feeding.<sup>15</sup> Contraction of cartilaginous extensions of the beak tip may also contribute to the underbite. If the beak is still soft, physical therapy may correct the condition. A finger or loop of gauze can be used at each feeding to apply traction and extend the maxillary beak rostrally. The cartilaginous extensions should be clipped if they are contracted. If the beak is calcified, physical therapy combined with trimming of the lower beak to allow the upper to extend into a notch may help. If this fails, a dental acrylic prosthesis can be applied to the rostral end of the maxillary beak to stretch the maxilla and force it



**FIG 30.28** A three-week-old Umbrella Cockatoo was presented with severe mandibular prognathism. The problem had been present since hatching, and the aviculturist had been incorrectly told that this was normal and would resolve with age. If corrected from hatching, this problem can be resolved by gently pulling the upper beak forward and placing it over the lower beak for about ten minutes between each feeding. If allowed to progress, as in this cockatoo, repair requires surgical intervention (see Chapter 42).

over the mandibular beak<sup>22</sup> (see Chapter 42). The prosthesis can be removed once normal occlusion is achieved.

### Compression Deformities of the Mandible of Macaw Beaks

An elongated, shovel-like deformity of the mandible may occur in macaws when the hand-feeder compresses the lateral sides of the lower beak by holding it during feeding or cleaning. If noted before the beak calcifies, it can be corrected by trimming beak tissue from the lateral walls and manually reshaping the lower beak. Once the beak calcifies, it is difficult to repair.

### Traumatic Subluxation of the Premaxilla-frontal Joint

Juvenile birds will occasionally subluxate the upper beak when playing or flying. The upper beak will usually be displaced dorsally, and fractures of the premaxilla or frontal bone may be apparent. It is extremely painful, and the bird should be anesthetized while the beak is placed back in a normal position (see Chapter 42). Most birds have been reported to heal well, although some may need to be hand fed for a few days.<sup>8</sup> Antibiotics and anti-inflammatory drugs should be used where indicated.

## Integumentary Problems

### Feather Stress Bars

Stress bars are horizontal defects in the feathers that occur when there is endogenous release of corticosteroids or when corticosteroids are administered during feather growth (see Chapter 24). A few stress bars in an otherwise normal bird are of only temporary cosmetic concern. Large numbers of stress bars may indicate malnutrition, stunting or a disease problem. Determining the cause of stress bars is often difficult because they represent a problem that occurred when the feather was developing.

### Feather Dysplasia

Malformed feathers, feathers that fail to grow, and feathers that are easily epilated are most often caused by polyomavirus or PBFV virus. Hyperthermia, drug reactions and bacterial folliculitis are less common causes.

### Occluded Ear Openings

Occlusions of the external openings of the ears are most often seen in macaws, (especially Military Macaws). Macaws are born with a thin membrane covering the ear canal that should start to open between



**FIG 30.29** A four-week-old Green-winged Macaw was presented for depression and failure to grow. The bird was being fed a homemade diet with a baby cereal base that was nutritionally deficient. The bird grew normally when placed on a commercial hand-feeding formula. Note the membrane over the ear that has not yet opened.

12 and 35 days of age (Figure 30.29). If the canal fails to open, it should be explored with blunt forceps and an opening surgically created if necessary. If a small hole is found, it can often be enlarged by stretching it with the tips of a pair of hemostats. Occasionally the

canal will become infected and fill with inspissated pus. This material should be removed by curettage and flushing, cultured for bacteria and fungus, and the ear treated with appropriate topical and systemic antibiotics. *Pseudomonas* sp. is a common contaminant and ointments containing an aminoglycoside antibiotic should be used until culture results are available.

### Eyelid Malformation

Malformation of the eyelids resulting in a narrow aperture is occasionally seen in cockatiels. Several surgical techniques and means of chemical debridement have been attempted with little success.<sup>5</sup> In all reported cases, the aperture closed following treatment. Affected birds can often adapt to this handicap (see Chapter 26).

### References and Suggested Reading

- Altman RB:** Disorders of the skeletal system. In Petrak ML (ed): *Diseases of Cage and Aviary Birds* 2nd ed. Philadelphia, Lea and Febiger, 1982, pp 382-394.
- Arnall L:** Anesthesia and surgery in cage and aviary birds III. A systemic outline of surgical conditions. *Vet Rec* 73:188-192, 1961.
- Beach JE:** Diseases of budgerigars and other cage birds, a survey of post-mortem findings. *Vet Rec* 74:134-140, 1962.
- Bond MW:** Avian pediatrics. *Proc Assoc Avian Vet*, Chicago, 1991, pp 153-160.
- Buyukmihci NC, et al:** Eyelid malformation in four cockatiels. *J Am Vet Med Assoc* 196(9):1490-1492, 1990.
- Cambre RC:** Indications and technique for surgical removal of the avian yolk sac. *J Zoo Wildlife Med* 23:55-61, 1992.
- Clipsham R:** Correction of pediatric leg disorders. *Proc Assoc Avian Vet*, 1991, pp 200-204.
- Clipsham R:** Introduction to psittacine pediatrics. *Vet Clin No Am Sm Anim Pract* 21:1361-1392, 1991.
- Clubb K, Clubb S:** Management of psittacine chicks and eggs in the nest. In Schubot RM, Clubb K, Clubb SL: *Psittacine Aviculture. Perspectives, Techniques and Research*. Loxahatchee, Avicultural Breeding and Research Center, 1992, pp 151-156.
- Clubb K, Clubb S:** Psittacine neonatal care and handfeeding. In Schubot RM, Clubb K, Clubb SL: *Psittacine Aviculture. Perspectives, Techniques and Research*. Loxahatchee, Avicultural Breeding and Research Center, 1992, pp 11/1-11/12.
- Clubb K, et al:** Growth rates of hand-fed psittacine chicks. In Schubot RM, Clubb K, Clubb SL: *Psittacine Aviculture. Perspectives, Techniques and Research*. Loxahatchee, Avicultural Breeding and Research Center, 1992, pp 14/1-14/19.
- Clubb SL, et al:** Hematological and serum biochemical reference intervals in juvenile Eclectus parrots (*Eclectus roratus*). *J Assoc Avian Vet* 4:218-225, 1991.
- Clubb SL, et al:** Hematological and serum biochemical reference intervals in juvenile cockatoos. *J Assoc Avian Vet* 5:5-16, 1991.
- Clubb SL, et al:** Hematological and serum biochemical reference intervals in juvenile macaws. *J Assoc Avian Vet* 5:154-162, 1991.
- Clubb SL, Wolf S, Phillips A:** Psittacine pediatric medicine. In Schubot RM, Clubb K, Clubb SL: *Psittacine Aviculture. Perspectives, Techniques and Research*. Loxahatchee, Avicultural Breeding and Research Center, 1992, pp 16/1-16/26.
- Drewes LA, Flammer K:** Preliminary data on aerobic microflora of baby psittacine birds. *Proc Jean Delacour/International Foundation for Conservation of Birds, Intl Symp Breed Birds in Captivity*, 1983, pp 73-81.
- Flammer K, Drewes LA:** Environmental sources of gram-negative bacteria in an exotic bird farm. *Proc Jean Delacour/Intl Foundation for the Conservation of Birds, Intl Symp Breed Birds in Captivity*, 1983, pp 83-93.
- Flammer K:** Pediatric medicine. In Harrison GJ, Harrison LR (eds): *Clinical Avian Medicine and Surgery*. Philadelphia, WB Saunders Co, 1986, pp 634-650.
- Gaskin JM, Horner BL, Eskelund KH:** Preliminary findings in avian viral serositis: A newly recognized syndrome of psittacine birds. *J Assoc Avian Vet* 5:27-33, 1991.
- Greenacre CB, Watson E, Ritchie BW:** Congenital atresia of the choanae in an African grey parrot and an umbrella cockatoo. *J Assoc Avian Vet* 7:19-22, 1993.
- Hanson JT:** Handraising large parrots: Methodology and expected weight gains. *Zoo Biol* 6:139-160, 1987.
- Joyner KL, Abbott U:** Egg necropsy technique. *Proc Assoc Avian Vet*, 1991, pp 146-152.
- Joyner KL:** Psittacine pediatric diagnostics. *Sem Avian and Exotic Pet Medicine* 1:11-21, 1992.
- Karpinski IG, Clubb SL:** Further investigations into the ocular problems of caged birds. *Proc Assoc Avian Vet*, Boulder, 1985, pp 101-108.
- Lyman R:** Neurological disorders. In Harrison GJ, Harrison LR (eds): *Clinical Avian Medicine and Surgery*. Philadelphia, WB Saunders, 1986, pp 486-490.
- Opengart KN, et al:** Congenital extrahepatic biliary cyst in a congo African grey parrot (*Psittacus erithacus erithacus*). *Avian Dis* 34:497-500, 1990.
- Phillips A, Clubb SL:** Psittacine neonatal development. In Schubot RM, Clubb K, Clubb SL: *Psittacine Aviculture. Perspectives, Techniques and Research*. Loxahatchee, Avicultural Breeding and Research Center, 1992, pp 12/1-12/26.
- Ritchie BW, et al:** Avian polyomavirus: An overview. *J Assoc Avian Vets* 5:147-153, 1991.
- Ritche BW, et al:** Advances in understanding the PBFV virus. *Proc Assoc Avian Vet* 1990, 12-24.
- Roudybush TE:** Growth, signs of deficiency, and weaning in cockatiels fed deficient diets. *Proc Assoc Avian Vet*, 1986, pp 333-340.
- Roudybush TE, Grau CR:** Solids in the diets for hand raising cockatiels. 32nd West Poultry Dis Conf, 1983, pp 94-95.
- Small E, Burke TJ:** Diseases of the organs of special sense. In Petrak ML (ed): *Diseases of Cage and Aviary Birds* 2nd ed. Philadelphia, Lea and Febiger, 1982, pp 491-496.
- Takeshita K:** Hypervitaminosis D in baby macaws. *Proc Assoc Avian Vet*, 1986, pp 341-346.
- Pediatrics:** Part 1. Seminars in Avian and Exotic Pet Medicine. 1(1), 1992.
- VanDerHeyden N:** Jejunostomy and jejunocecal anastomosis in macaws. *Proc Assoc Avian Vet* 1993, 72-77.



---

## ■ C H A P T E R S

- 31 MALNUTRITION**  
Patricia Macwhirter
- 32 VIRUSES**  
Helga Gerlach
- 33 BACTERIA**  
Helga Gerlach
- 34 CHLAMYDIA**  
Helga Gerlach
- 35 MYCOSES**  
Louise Bauck
- 36 PARASITES**  
Ellis C. Greiner  
Branson W. Ritchie
- 37 TOXINS**  
Genevieve Dumonceaux  
Greg J. Harrison
- 38 MYCOPLASMA AND RICKETTSIA**  
Helga Gerlach

V

---

## SECTION FIVE

# DISEASE ETIOLOGIES

---

V



**M**alnutrition can cause a specific problem or suppress a bird's immune system, decrease response to therapeutic agents, decrease reproductive performance and prolong the period of surgical recovery.

The diet of every avian patient should be carefully evaluated, even if the bird appears clinically to be well nourished. Marginal nutritional inadequacies frequently occur (see Chapter 8), and correcting the diet will improve a bird's general health and its ability to resist infectious diseases. Gastrointestinal malabsorption, hepatitis or renal disease can increase nutrient requirements so that diets that are sufficient in healthy birds may be insufficient for unhealthy birds. Interestingly, free-ranging granivorous birds that are offered both organic (no pesticides) and pesticide-treated grains will preferentially consume the organic foods. Test birds would not eat the pesticide-treated foods until all of the organic grains were gone.

Birds with signs of malnutrition have often developed strong preferences for unbalanced diets. Most seed diets, for example, contain excessive levels of fat and may be deficient in vitamins A, D<sub>3</sub>, E, B<sub>12</sub> and K<sub>1</sub>, plus riboflavin, pantothenic acid, niacin, biotin, choline, iodine, iron, copper, manganese, selenium, sodium, calcium, zinc and some amino acids (eg, lysine and methionine).<sup>6</sup>

Birds can be encouraged to accept new foods by offering them first thing in the morning when the appetite is strongest. Favorite items can be withheld until later in the day. New foods may also be mixed with the bird's normal familiar diet. Gradually decreasing the quantity of old food items and increasing the quantity of new foods in the mixture will allow for a smooth transition in the diet. The size of food items offered should be appropriate to the species of bird.<sup>10</sup>

Some birds may be encouraged to eat an unfamiliar food if they can observe its consumption by other birds (Figure 31.1). Converting birds housed in large groups to a new diet is often easier than converting individual birds.<sup>55</sup>


Nutritional requirements vary depending on a bird's species, age, reproductive state, molting status, the external temperature and amount of daily exercise. Formulated diets supplemented with some fresh

fruits and vegetables will improve the nutritional state of birds (see Chapter 3).

While a diet change is occurring, it is important that the bird be carefully monitored for weight loss. Radical, unsupervised changes in the diet can lead to starvation. Most birds will have some degree of diarrhea or polyuria during a diet change. Ketosis was seen in some cockatoos that refused to eat during the transition to formulated diets. Affected birds showed acute weight loss, diarrhea, weakness, lethargy and possible vomiting. Ketonuria can be demonstrated by a reagent strip examination of the urine. Therapy should include dextrose, supportive alimentation and placing the bird back on its regular diet. The diet should then be changed gradually to prevent anorexia.

## Clinical Conditions Associated with Malnutrition

Avian veterinarians encounter a different type of malnutrition today than was described five to ten years ago. Nutrient deficiencies were historically common, but with the use of formulated diets in combination with vitamin and mineral supplementation, many malnutrition problems noted today are a



**FIG 31.1** A bird that is already adapted to a specific diet can be used to “teach” a reluctant eater to accept a new diet. In this case, a cockatiel is being used to acclimate a parakeet to a formulated food.

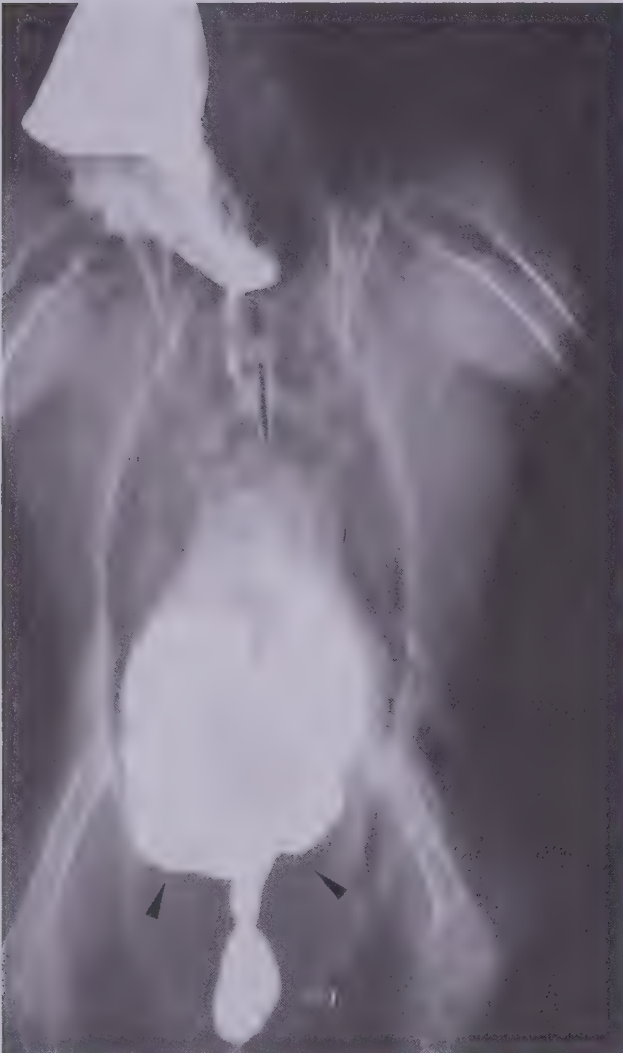result of excessive nutrients.<sup>30</sup> In some cases clinical signs believed to be caused by malnutrition are actually complex diseases that involve nutritional, environmental and species-specific factors.

### Obesity

Obesity is the most common and the most severe malnutrition-related problem recognized in avian practice (see Color 8). Obesity occurs if the energy content of the diet is excessive for the energy demands created by normal metabolic functions and the amount of exercise. In some cases, obesity will be secondary to the over-consumption of food in a bird attempting to consume missing nutrients. However, in most cases, obesity in companion birds is a result of feeding excess quantities of improper foods (eg, cookies, crackers, sweets) or high oil seeds (sunflower, safflower, hemp, rape, niger), a lack of exercise and increased food intake due to boredom (Figure 31.2).

Because companion birds frequently have limited opportunities for exercise, the energy content of their diet needs to be monitored closely. In species prone to obesity, it is important to avoid offering foods that have high caloric densities and to avoid excessive quantities of attractive, palatable food. Fats have twice the caloric density of either carbohydrates or proteins, and foods containing high levels of fats (such as peanuts or sunflower seeds) should be limited. Fresh fruit and vegetables have lower caloric densities than dried foods or seeds and should make up a sizable portion of a low-energy diet. Decreasing caloric intake can also be achieved by restricting feeding times (eg, ten minutes in the morning and evening) rather than offering food ad lib. Ideally, companion birds should be fed pelleted or extruded foods supplemented with small quantities of fresh fruit and vegetables. Some formulated diets may be helpful in controlling obesity and fatty liver problems.<sup>30</sup>

Some species, such as Rose-breasted Cockatoos, Sulphur-crested Cockatoos, Amazon parrots and budgerigars, are particularly prone to becoming obese and may develop secondary lipomas, fatty liver degeneration and heart disease (see Colors 20 and 27). Pancreatitis has been associated with obesity and high fat diets.<sup>40</sup> Hypothyroidism, which can be associated with low dietary iodine, has been correlated with obesity and lipoma formation, particularly in budgerigars. In birds that are confirmed to have hypothyroidism, thyroxine supplementation is recommended (see Chapter 23).<sup>32,44,48</sup>



**FIG 31.2** A two-year-old female Sulphur-crested Cockatoo was presented with a one-month history of progressive dyspnea (particularly following mild exercise) and abdominal wall masses. The bird was fed a seed diet ad lib and was frequently given treats (eg, crackers, potato chips). Several large pendulated masses were located pericloacally and in the ventral abdominal area. The bird weighed 1050 g. Cytologic evaluation of fine-needle aspirates from a mass was suggestive of adipose tissue. Abnormal clinical pathology findings included lipemic serum and hypercholesteremia. Radiographs indicated a diffuse soft tissue mass in the caudal abdomen. Barium contrast radiography indicated that the mass was displacing the abdominal organs cranially (arrow). Note that the cloaca is being compressed and the colon is oriented in a cranial, rather than its normal right lateral position (open arrow). The bird responded to a diet change (formulated diet, fruits and vegetables and no treats) and increased exercise (an outdoor flight enclosure).

A decrease in photoperiod may induce polyphagia and weight gain in pre-migratory birds. The increased food intake and weight gains appear to be mediated by thyroid hormones, prolactin and gonadotrophins. The role that neurohumoral signals, such

as a changing photoperiod, plays in weight regulation in companion birds is unknown.<sup>56</sup> It is common for pre-ovulatory females to have up to a ten percent increase in weight.

### Low Body Weight/Poor Growth

Low body weight or poor growth can be the result of inadequate food intake, which in turn can be caused by an insufficient quantity of food, inappropriate diet, unfamiliar food items, infrequent feeding, weaning onto solid foods too early, or loss of appetite, maldigestion or malassimilation of food caused by medical problems.<sup>20</sup>

Poor growth and low body weight occur with nutritionally deficient diets when the energy content of the food is insufficient to meet the energy demands of ongoing metabolic processes.

Low body weight or poor weight gain independent of organopathy can generally be corrected by placing the bird on a high-energy diet (high in fat and carbohydrates). Digestive enzymes and fiber hemicellulose may increase the digestibility and absorbability of the diet. Procedures for calculating daily energy requirements for birds are discussed in Chapter 15. It is important to note that formulas to calculate energy requirements are based on averages, and the nutritional requirements of individual species and individual birds will vary. A bird's clinical response to a particular diet should be carefully evaluated and adjustments should be made as necessary.<sup>42,48</sup>

### Diets for Birds with Malabsorption and Diarrheal Syndromes

Parasites, bacterial infections, mycotoxins and pancreatic disease may interfere with the absorption of nutrients from the digestive tract. In addition to correcting the primary problem, these birds need foods that are easily digested and absorbed to facilitate healing of the gastrointestinal tract. Lactose and excessive amounts of green vegetables should be avoided. Diets should be moderately low in fiber and provide easily digested carbohydrate (eg, canary seeds, millet, panicum, corn or hulled oats) and a moderate amount of highly digestible protein. Vitamin and mineral supplementation, particularly of vitamins A and E, may be needed. The addition of digestive enzymes to the diet may be useful (see Chapter 18). In some cases, feeding a small quantity of grit may improve digestion and aid absorption, but should be supplied only in low quantities to prevent gastrointestinal impaction.



### ■ Polyphagia

Occasionally birds will overeat fibrous food or grit, causing crop or ventricular impactions. These problems are more likely to occur if young birds are suddenly introduced to new food items (unhulled seeds, particularly). Birds that are exposed to a number of food items at an early age are less likely to overeat infrequently offered foods. Ostriches may eat constantly following relocation, leading to foreign body ingestion and impaction (see Chapter 48).<sup>4</sup>

Feigned polyphagia, in which a bird hulls seeds and appears to be eating but the crop remains empty, may occur in some birds that are very weak or that are offered inappropriate food items. Vitamin E and selenium deficiencies have been suggested as possible causes of this problem.<sup>26</sup> Clients should not rely on the husking of seeds to indicate food intake. Monitoring body weight and fecal output is more effective.

When changed to a formulated diet, older, obese budgerigars and cockatiels may lose weight, yet eat constantly. Obese birds should lose weight slowly to prevent hepatopathies associated with overwhelming fat metabolism. The weight loss can be tempered by adding some millet to the diet. Multivitamin injections and lactulose can be used to suppress progressive hepatopathies in some cases (see Chapter 8).

### ■ Polydipsia/Polyuria

Nutritional causes of polydipsia and polyuria include hypovitaminosis A, calcium deficiency, excess protein, hypervitaminosis D<sub>3</sub>, excessive dietary salt, dry seed diet, formulated diets or a high percentage of dietary fiber.

Polyuria alone may occur in birds fed moist foods such as fruit, vegetables and semi-liquid diets. Urine or urate color may change from a normal white or cream to yellow or brown when birds are supplemented with B vitamins. Consumption of food dyes, berries and other fruits can also alter the urine color (see Color 8).

### ■ Digestive Disorders

White plaques in the mouth or swelling in the salivary ducts may be associated with hypovitaminosis A (see Colors 8 and 13).

Oral paralysis in cockatiels may be related to vitamin E and selenium deficiencies and a malabsorption syndrome secondary to giardiasis.<sup>28</sup>

Nutritional causes of crop impaction include high fiber diets, foreign material ingestion (eg, juveniles eating various substrates such as wood shavings) and excess grit consumption. Cold food, a cold environment or infrequent feeding of large amounts of food may increase the risk of crop impaction in juvenile or debilitated birds. Repeated crop impactions may result in an atonic, pendulous crop. Degeneration of ventricular musculature has been associated with vitamin E and selenium deficiencies and calcinosis due to hypervitaminosis D.<sup>28,52</sup> Crop liths may develop in birds on marginal diets. The etiology is undetermined (see Color 19).

Diarrhea may occur in birds fed low-fiber or high-fat foods, particularly highly processed human foods (eg, cakes, desserts, crackers). Bacteria or parasitic enteritis may occur in birds that eat foods contaminated with excrement. Food and water containers should be positioned so that contamination with droppings will not occur.

Nutritional cases of malabsorption or maldigestion (passing undigested food) include vitamin E and selenium deficiencies (sometimes associated with giardia infection), excess oil in the diet or dehydration. A lack of grit has been frequently discussed as a cause of maldigestion; however, companion birds on formulated diets do not appear to require grit. Studies in poultry indicate that the addition of grit increases the digestibility of feed by as much as ten percent,<sup>14</sup> but similar studies have not been performed in companion birds. Given that obesity is more of a problem than maldigestion in companion birds, increasing the digestibility of a formulated diet that exceeds suggested nutritional requirements is probably unnecessary. Charcoal that is used in some grit mixtures may interfere with the absorption of vitamins A, B<sub>2</sub> and K and contribute to deficiencies of these compounds.

Birds should not be offered grit on an ad libitum basis. If offered free choice, some birds may over-consume grit, leading to crop, proventricular or ventricular impactions. This problem is reported commonly in North America but appears to be uncommon in Australia. The cause for a regional variation in the occurrence of this condition is unknown. Birds showing compulsive grit consumption should be evaluated for hepatopathy, pancreatitis, renal dysfunction and general malnutrition.

There is a difference between grit and crushed shell. Grit is composed of minute stones and commonly

contains silicates and sandstone. Crushed shell is almost entirely composed of limestone (calcium carbonate) and is readily digested by acids in the proventriculus. Crushed shell will provide a source of calcium, and is not effective in aiding in the mechanical breakdown of dietary plant material. Heavy metal toxicity has been associated with feeding crushed shell derived from contaminated sources (oysters raised in polluted waters).

Regurgitation has been associated with feeding high-protein diets to cockatiels.<sup>46</sup>

### Respiratory Disorders

Dyspnea (extended neck) and wheezing may be associated with goiter, particularly in budgerigars.<sup>53</sup> Hypovitaminosis A leads to squamous metaplasia of epithelial surfaces causing obstruction of respiratory passages or sinusitis (see Color 8). Dyspnea may be caused by calcium or vitamin D<sub>3</sub> deficiency if severe enough to demineralize bone, causing thoracic or spinal deformities.


Asphyxiation may occur from aspiration of feeding formula into the respiratory tract. This can occur if a tube is accidentally placed in the trachea when attempting crop feeding or if a bird (particularly a weak bird) is fed large amounts or excessively thin formula.

### Plumage Abnormalities

Dark, horizontal lines (stress marks) on feathers have been associated with nutritional deficiencies (particularly methionine) and indicate that a release of corticosteroid hormone occurred while the feather was developing. Stress lines are common in neonates that have had a disrupted feeding schedule or in raptors that are molting while in a training period (see Color 24). Molting abnormalities, retained feather sheaths and dry flaking beaks have also been associated with overall nutritional deficiencies (Figure 31.3).

Feather picking may be initiated by dry, flaky, pruritic skin, which in turn can be caused by nutritional deficiencies, particularly deficiencies of vitamin A, sulfur-containing amino acids, arginine, niacin, pantothenic acid, biotin, folic acid and salt. Excessive dietary fat has been incriminated as a possible cause of self mutilation (Figure 31.4).

Deficiencies of minerals such as calcium, zinc, selenium, manganese and magnesium may be associated




**FIG 31.3** An 18-month-old Amazon parrot on an all-seed diet was presented for a beak trim. The bird was maintained indoors and had no exposure to sunlight or water for bathing. Horny beak material that is dry and flaky, as well as black discoloration of the feathers are typical of malnutrition. This bird responded to a change in diet and daily exposure to direct (unfiltered through glass) sunlight.

with brittle, frayed feathers and dermatitis.<sup>29</sup> Arginine deficiency may cause wing feathers to curl upward in chicks. In broilers, pantothenic acid deficiency causes the formation of ragged feathers, while a deficiency in growing cockatiels has been associated with a lack of contour feathers.<sup>46</sup>

The association between diet and feather pigment has long been recognized by canary breeders. Carotene and xanthophyll pigments, which originate from plant material, are found in fat globules in the feathers and give rise to yellow, orange and red colors (see Chapter 24). Birds lacking a dietary source of carotenoids may develop muted feather or skin colors, while dietary supplementation of carotenoids in birds with suitable genetic backgrounds will result in increased depth of color.

Prolonged feeding of bacon rind and bone marrow has been associated with an oily feather and stool texture (steatorrhea) and an increase in depth of the pink feathers in Rose-breasted Cockatoos. Raptors fed laboratory rats and mice (reduced carotenes) may lose the yellow coloration of their cere, feet and legs that is characteristic in free-ranging birds.<sup>32,38,39</sup> Porphyrins are aromatic compounds synthesized by birds that may produce colors such as red, green or brown. Porphyrins are less sensitive to dietary influences than carotenoids, but both are present in edible blue-green algae, and enhanced feather coloration would be expected in birds fed a diet containing this material.




**FIG 31.4** Feather picking and dry, thin, pruritic skin are common signs of malnutrition in Psittaciformes. Note the loss of papillae on the dorsal surface of the feet and toes.

Melanin occurs in granules in the skin and feathers and produces black, brown and red-brown colors. This pigment is derived from tyrosine in an enzymatic reaction requiring copper. Consequently, deficiencies of tyrosine (or other related amino acids) or copper could interfere with melanin production and cause dark-colored feathers to become lighter.<sup>25</sup>

Blue and white are structural colors in feathers. In most cases, their occurrence depends on a scattering of light caused by the structure of the keratin in the spongy layer of the feather rami rather than on the presence of pigments. Essential amino acids that occur in keratin include methionine, histidine, lysine, tryptophan, threonine, isoleucine and valine. It is possible that amino acid deficiencies could alter the structure of keratin and consequently alter feather color. A change in feather color from green to yellow is usually caused by a loss of structural blue color, which may be associated with essential amino acid deficiencies. While this color change is commonly seen in nutritionally deficient Psittaciformes, the exact nature of the deficiency has not been clarified, and it is possible that more than one amino acid could be involved (see Color 24). Lysine deficiency has been discussed as one possible cause of green-to-yellow feather discoloration because many affected birds are consuming all-seed diets that are low in lysine.

Feather color may change from blue to black, green to black or grey to black in birds that are sick or malnourished. These color changes are associated with altered keratin structure in the spongy layer that prevents normal light scattering. When this




**FIG 31.5** Feathers that turn black are an indication of altered keratin structure in the spongy layer of the feather. The black feathers in this Amazon parrot resolved with a change in diet (seeds to formulated diet) and correction of chronic active hepatitis.

occurs, melanin granules in the middle of the feather, if present, would absorb all wave lengths of light, giving the visual effect of black (Figure 31.5).

Nutritionally related alterations in feather color may vary based on the species of bird, specific nutrient deficiency, timing of the deficiency in relation to feather development and the initial color of the affected feathers. While lysine deficiency in chickens, turkeys and quail produces achromatosis, there was no loss of feather color in young cockatiels fed a lysine-deficient diet. However, choline and riboflavin deficiencies produced feather changes in young cockatiels that resembled achromatosis caused by lysine deficiency in poultry.<sup>46</sup> White streaks (usually associated with breakage) in feathers may be associated with a hypovitaminosis B (Figure 31.6).<sup>29</sup>

### ■ Skin Changes

Plantar corns and pododermatitis have been associated with biotin and vitamin A deficiencies, particularly in obese birds (Figure 31.7).<sup>29</sup> Edema of subcutaneous tissues has been seen with vitamin E and selenium deficiencies. Exfoliative dermatitis on the face and legs has been associated with biotin, pantothenic acid, riboflavin or zinc deficiency<sup>1</sup> (see Color 48.). If a formulated diet is not available, a diet can be supplemented with multivitamins to compensate for any nutritional deficiencies. Several kiwis in a New Zealand zoo developed a scaly dermatitis over their necks and legs when a multivitamin supple-



**FIG 31.6** White streaking in feathers that are normally colored may be associated with a B vitamin deficiency. These feathers are frequently brittle and may break at the site of abnormal coloration.

ment that was routinely included in their diet was omitted. The clinical problem resolved when the multivitamin supplement was again added to the diet.<sup>5</sup> Formulated diets should not be supplemented with vitamin products. Over-supplementation may cause problems with excess vitamin, mineral, fat or protein consumption.

### ■ Skeletal and Muscular Disorders

Demineralized, bent bones and pathologic fractures may occur in birds with hypovitaminosis D and calcium, phosphorus or magnesium deficiencies or imbalances.

Airplane wing in waterfowl (rotation of the distal carpi due to heavy, developing feathers being supported by non-rigid, developing bones) may be caused by rapid growth or excessive levels of protein or low levels of calcium (see Chapter 46).<sup>17</sup>

Slipped tendon of the hock (perosis) may occur with manganese, biotin, pantothenic acid or folic acid deficiencies (see Color 8). Obese birds that are not allowed sufficient exercise and birds fed high-mineral diets may be prone to this condition. There is gross enlargement of the tibio-metatarsal joint, twisting and bending of the distal tibia and slipping of the gastrocnemius muscle from its condyles. Young gallinaceous birds, cranes and ratites are particularly susceptible to this condition.<sup>34</sup> The author has seen a similar condition in raptors, cockatiels and rosellas. In some cases, surgical correction is possible (see Chapter 46).



**FIG 31.7** A mature female cockatiel was presented with a complaint of intermittent lameness. The bird was on an all-seed diet with no supplementation and was kept in a small enclosure. The bird weighed 138 g and had severe ulcerative lesions on both metatarsal pads. Changing the diet, increasing the exercise (outdoor flight enclosure) and standard treatment for grade 4 bumblefoot were effective in resolving the lesions.

Enlargement of the hock, without tendon slipping, may occur with zinc deficiency.

Tibial dyschondroplasia is characterized by uncalcified masses or plugs of avascular hyperplastic cartilage in the proximal metaphyses, particularly of the tibiotarsus. The condition is seen in poultry and ratites. A genetic predisposition along with electrolyte imbalances involving sodium, potassium and chloride are thought to be involved in the development of tibial dyschondroplasia. A relative excess of chloride may increase the incidence of disease.<sup>33</sup>

### ■ Neurologic Signs

Seizures or localized paralysis have been associated with salt toxicity and low levels of thiamine, calcium and vitamin E. Leg paralysis has been associated with calcium, chloride or riboflavin deficiency.

Cervical paralysis has been associated with a folic acid deficiency. Jerky leg movements have been associated with pyridoxine deficiency.

Sudden collapse or fainting has been associated with hypoglycemia in raptors or in other species when a bird has not eaten and is acutely stressed. Syncope is characteristic of advanced hypocalcemia in African Grey Parrots.

Behavioral changes including aggressiveness (biting), nervousness, rejection of food and regurgitation occurred in cockatiels placed on a high-protein diet.<sup>46</sup>

Frequently, companion birds that are switched from an unbalanced all-seed diet to a balanced formulated diet will undergo a corresponding change in behavior characterized by decreased biting, screaming and chewing, and increased activity and playfulness.<sup>30</sup>

### Reproductive Disorders

Many dietary deficiencies or excesses may result in reduced reproductive performance due to infertility, poor hatchability or nestling deaths. Calcium, vitamin E and selenium deficiencies may be associated with egg binding.

### General Ill Health or Sudden Death

Fatty liver infiltration may occur due to high fat diets, fatty acid or B vitamin deficiencies and high-energy diets in exercise-deprived birds (see Color 20). Gout may be a precipitating cause or an end result of systemic diseases (see Color 21). Ascites may be associated with excessive dietary levels of iron in birds susceptible to iron storage disease (hemochromatosis). Atherosclerosis may be associated with diets high in fat and cholesterol (see Color 14).

Aortic rupture has been associated with copper deficiency in poultry and is suspected to occur in ratites (see Color 48).

### Immune Response

Adequate levels of both B complex (particularly pantothenic acid and riboflavin) and vitamin E have been shown to improve the body's response to pathogens. In poultry, vitamin C and zinc are involved in T-cell response, and vitamin C stimulates macrophages and helps to counter the immunosuppressant effects of stress. Low vitamin A levels may result in a sub-optimal immune response and have been associated with the occurrence of aspergillosis in psittacines.<sup>3,13</sup>

## Deficiencies of Specific Nutrients

When one considers the array of ecological niches to which different species of birds are adapted, it is not surprising that there are major species differences in


the ability to metabolize proteins, fats, carbohydrates and other nutrients.

To date, comprehensive nutritional requirements have been established only for domestic fowl. In spite of the absence of complete data for companion birds, anecdotal findings and scientifically supported investigations suggest that general health and reproductive success will be greater in birds fed "balanced" formulated diets supplemented with limited fresh fruits and vegetables compared to birds fed seeds supplemented with fresh fruits and vegetables (Figure 31.8).<sup>30,54</sup>

Research findings and clinical experience suggest that there is considerable interspecies variation in nutrient requirements and in clinical signs of malnutrition. For example, some finches may consume up to 30% of their body weight, budgerigars, 25% of body weight and domestic chickens, 6% of body weight on a daily basis. These differences point to the dangers of extrapolating nutrient requirements, particularly of minerals, from poultry data when the level of food consumption varies dramatically. Requirements will also vary depending on the bird's age and physiologic state, interactions with other dietary components and the presence of concurrent diseases.

### Protein and Amino Acids

Protein in the diet is broken down into component amino acids before being absorbed by the intestine.



**FIG 31.8** Birds appear to be healthiest when supplied a formulated diet supplemented with some fresh fruits and vegetables. Over-supplementation with fresh foods, as is the case with this daily vegetable bowl for a cockatoo, can actually cause malnutrition through insufficient consumption of a formulated diet. For a bird the size of an Umbrella Cockatoo, the formulated diet should be supplemented with the equivalent of several slices of carrot (or dark squash or sweet potato), one-eighth cup of spinach (or broccoli or endive) and several small slices of favorite fruits as a treat.

Amino acids are needed by the body to reconstruct proteins that make enzymes, hormones, muscles, bones and feathers. Birds are uricotelic, ie, the product of protein breakdown is uric acid, which is excreted as a slurry (urates) by the kidneys.

### Excess Dietary Protein

Dietary protein requirements vary dramatically between species. Broiler chickens and turkeys have been genetically selected for rapid growth and are fed high protein levels to achieve maximum growth rates. These feeding practices are rarely appropriate in other species. Starter rations for turkey poults or pheasants may contain nearly 30% protein, but young ratites, waterfowl and psittacine birds require much lower levels. Using a high-protein diet in these latter species may result in clinical problems such as airplane wing in ducks, deformed legs in ratites, poor growth rates in psittacine birds and increased susceptibility to disease in all species.

Inappropriate calcium levels in the diet may compound problems caused by excessive dietary protein. A group of macaw neonates being fed a human, high-protein baby cereal with added vitamins and calcium showed suboptimal growth rates. When the protein level in the diet was reduced by adding pureed fruits and vegetables, the growth rate and the chick's general health improved dramatically (see Chapter 30).

Nutritional data collected in juvenile cockatiels indicated that a protein level of 20% was optimal for this species. Levels of 10% produced stunting, poor growth and high mortality; levels over 25% produced transient behavioral changes such as biting, nervousness, rejection of food and regurgitation.<sup>46</sup>

In budgerigars, one study showed that a protein level of 17 to 20% was optimal. Birds on low-protein seed diets increased their food intake and gained weight in the form of excessive body fat. Those on low protein (12%) mash diets lost weight, but some died with their crops packed with food. This finding suggests that the birds unsuccessfully attempted to consume enough food volume to compensate for the protein deficiency. Birds fed high-protein diets were very thin.<sup>55</sup> Other studies in budgerigars indicate that a diet with 2% lysine and 10% protein (13 kcal/kg of body weight) is ideal.<sup>12</sup>

Gout is the deposition of uric acid crystals on body organs (visceral gout), in joints (articular gout) or in the ureters (renal constipation) (see Color 21). High dietary levels of protein and calcium, hypervitaminosis D<sub>3</sub>, poor kidney response, dehydration, cold

weather and other stress factors work in concert to interfere with the kidney's ability to adequately excrete uric acid.<sup>15,35</sup> Hypervitaminosis D<sub>3</sub> causing renal calcinosis or vitamin A deficiency causing squamous metaplasia of the ureters may exacerbate blockage of the ureters.

### Diets for Birds with Renal Disease or Gout

Birds with renal disease or gout should be provided diets that decrease the workload of the kidneys and slow the loss of renal function. These diets should be lower in protein and meet energy needs with non-protein calories. Calcium, phosphorus, magnesium, sodium and vitamin D<sub>3</sub> levels should be reduced to avoid renal mineralization. Vitamin A should be present in adequate amounts to ensure proper function of the mucous membranes lining the ureters. B vitamins should be increased to compensate for losses associated with polyuria.

### Protein and Amino Acid Deficiencies

Protein or specific amino acid deficiencies are occasionally encountered in companion birds, particularly in insectivorous birds (softbills). Insectivorous birds require higher protein levels than granivores and generally require live food such as crickets or mealworms. If these insects are reared exclusively on bran, their total body protein may be low, and consequently the level and quality of protein that they provide to birds will also be low. Clinically, insectivores receiving low-protein insects will have a history of recurrent disease problems. Feeding crickets that have been raised on dried dog food or encouraging insectivores to consume artificial diets with appropriate levels of high quality protein prevents the problem.

Many seeds are relatively low in total protein and may also be deficient in some essential amino acids such as tryptophan, methionine, arginine or lysine. Free-ranging, seed-eating birds will frequently eat insects, particularly during the breeding season and when raising young.

Deficiencies of individual amino acids may cause abnormal feathers as well as suboptimal growth and poor breeding performance. Deficiencies of essential amino acids are most likely to occur if birds are fed a diet restricted to one or two individual types of seeds.

Serine, glycine and proline are the most abundant amino acids in feather keratin while methionine, histidine, lysine and tryptophan occur at lower levels. Methionine content of chicken feathers decreases

with age, while that of threonine, isoleucine and valine increases. Lysine deficiencies have been associated with impaired feather pigmentation in poultry, but not in cockatiels.<sup>46</sup>

Methionine deficiency has been associated with stress lines on feathers and fatty liver change. Cystine and methionine act as sources of glutathione, which has a sparing effect on vitamin E.

### ■ Fats and Essential Fatty Acids

Fats provide a concentrated source of energy. Linoleic and arachidonic acids are essential fatty acids needed for the formation of membranes and cell organelles. Deficiencies of linoleic acid may be associated with decreased metabolic efficiency, decreased growth, hepatomegaly, increased fat storage, decreased reproduction, embryonic mortality and decreased hatchability. In mammals, lipogenesis occurs mainly in adipose tissue while in birds, it nearly all occurs in the liver. T<sub>3</sub> is believed to be associated with lipogenesis and calorogenesis, especially during migration, while T<sub>4</sub> is associated with reproduction and molt (see Chapter 23).<sup>56</sup>

Lipogenic liver function in birds predisposes them to the occurrence of conditions involving excessive accumulation of liver fats, for example, fatty liver and kidney syndrome in young chickens and fatty liver hemorrhagic syndrome in laying hens (FLHS).<sup>33</sup> Geese that are force-fed cream and not allowed to exercise in preparation for *pate de foie gras* may have a six-fold increase in liver weight with only a two-thirds increase in weight.<sup>24</sup>

Fatty liver syndromes of undetermined etiologies are common in companion birds (see Color 20). In addition to fatty liver, excessive levels of fat in the diet are known to cause obesity, diarrhea and oily feather texture, and to interfere with the absorption of other nutrients such as calcium. Paradoxically, lack of fatty acids can also result in fatty liver infiltration because essential fatty acids are needed for lipid metabolism. Poor growth and reduced resistance to disease also occur with essential fatty acid deficiencies. FLHS in poultry is associated with high carbohydrate, low-fat, selenium-deficient diets given ad lib.

If fats become rancid, essential fatty acids may be destroyed, amino acid availability may be reduced and peroxidases may be produced that interfere with the activities of fat- and water-soluble vitamins (biotin). Rancid foods have been shown to reduce growth

and egg production in poultry. Levels of peroxide exceeding 15 mEq/kg were found to be toxic. Changes in the taste or odor of rancid food stuffs did not occur until the peroxide level reached 90 mEq/kg. Rice and oats are particularly susceptible to becoming rancid and are processed for foods through extrusion, rolling or roasting. Many commercial diets contain antioxidants (propylene glycol or ethoxyquin) to prevent foods from becoming rancid. The long-term effect of these products on birds is unknown.

Ventricular erosion may occur in birds fed highly polyunsaturated fatty acids (such as those present in cod liver oil), if the fatty acids are not protected by an adequate dietary level of vitamin E. "Gizzerosine" has been associated with ventricular ulceration in poultry fed heated fish meal. Because of these problems, fish liver oils are not recommended as dietary components in companion birds.<sup>26,49</sup> Soybean oil is a good source of fatty acids that is less likely to spoil.

Atherosclerosis may be induced by diets high in saturated fats and cholesterol. This problem is occasionally seen in aged Psittaciformes and may be associated with long-term feeding of high-oil seeds such as sunflower and safflower (see Chapter 27).<sup>34</sup>

Young cockatiels were able to tolerate fat levels from 1 to 60% of the diet with no effect on growth. However, about half of the birds fed a 60% fat diet developed a necrotic crop infection and died.<sup>46</sup>

### ■ Carbohydrates

Carbohydrates are a source of energy in the diet and are readily converted into fats in the liver. Exercise-deprived birds on high-energy diets may develop fatty liver infiltration even though carbohydrates, rather than fats, form the major component of energy consumed.

Clostridial infections, in which gas fermentation occurs along the gastrointestinal tract, have been associated with high-sugar diets in nectivorous birds.<sup>20,23</sup>

Birds have blood glucose levels that are several times higher than those of mammals. Some species, such as penguins and sea birds, are adapted to tolerate long fasting periods during molting, egg incubation or migration. Small companion birds (eg, finches) may collapse from hypoglycemia if they are deprived of food for even short periods. Food restriction prior to anesthesia should not exceed several hours. Raptors that are fed small quantities of food as part of their training program may experience hypoglycemic col-

lapse and may require emergency therapy with oral or parenteral glucose. Glucagon, rather than insulin, is the principal director of carbohydrate metabolism in birds.<sup>56</sup>

### Diets for Birds with Hypoglycemia

Birds prone to hypoglycemia should be fed frequently with nutrients that are slowly converted to glucose (a high-protein, high-energy diet). In most cases, hypoglycemia is dietary-induced, and placing the bird on a diet appropriate for that species is all that is required.

### Vitamins

Vitamins are a mixed group of organic compounds that are essential for a variety of metabolic processes. Most birds require the same vitamins as mammals with the exception that vitamin D<sub>3</sub> (not vitamin D<sub>2</sub>, as in mammals) is the active form of this compound. Exogenous vitamin C is required in fruit-eating birds such as bulbuls, but seed-eating species are generally able to synthesize vitamin C. Debilitated birds may have higher requirements and a reduced ability to synthesize vitamin C, and should be supplemented orally or parenterally.

Birds with vitamin deficiencies may have life-threatening clinical signs (eg, seizing associated with thiamine deficiency) or simply appear ruffled and in poor condition. Vitamins A, C, E and B complex are all involved with immune responses, and deficiencies in these compounds may increase the severity of infectious diseases.

Antibiotics may induce vitamin deficiencies by interfering with normal intestinal microflora. In most cases, birds given long-term antibiotics should also receive multivitamin supplementation. Protozoan infections such as coccidiosis or giardiasis may interfere with the absorption of vitamins (such as vitamins A or E) from the intestinal tract. Vitamins are sensitive to heat and light, so overheated or outdated commercial foods may be vitamin deficient.

Hypervitaminosis, particularly with fat-soluble vitamins, is becoming increasingly common as clients over-supplement improved, formulated avian diets.

#### Fat-soluble Vitamins

- Vitamin A:** Vitamin A is formed in the liver from beta carotene. It is involved in mucopolysaccharide biosynthesis and is needed for the formation of normal mucous membranes and epithelial surfaces, for

growth, for vision, for the development of the vascular system in embryos, for the production of adrenal hormones and for the formation of red and orange pigments in feathers. Beta carotene and vitamin A, themselves, are colorless. It is their derivatives that are responsible for feather pigmentation. Low vitamin A in the diet may result in a suboptimal immune response.<sup>3</sup>

Numerous clinical problems may be associated with hypovitaminosis A. Squamous metaplasia of mucous membranes may occur, altering the function of the respiratory, gastrointestinal or urogenital systems. Hyperkeratosis, a related condition, may affect epithelial surfaces (Figure 31.9).<sup>13</sup>

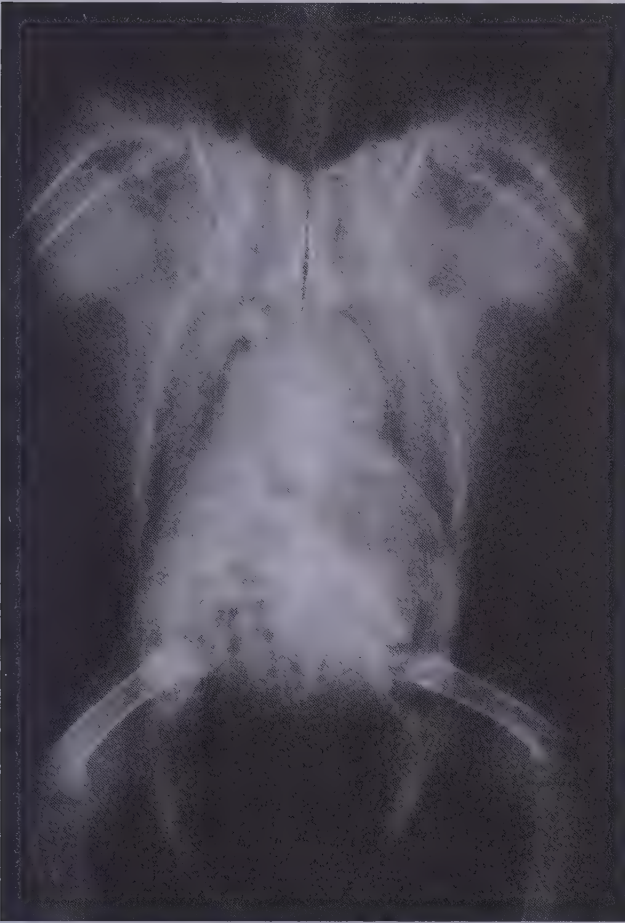Small white pustules may be seen in the mouth, esophagus, crop or nasal passages. If squamous metaplasia causes blockage of salivary ducts, small swellings (often symmetrical) may be noted dorsally around the choana, around the larynx and laterally under the tongue or mandibles (see Figure 19.3). White caseous material may accumulate in the bird's sinuses, particularly if hypovitaminosis A is associated with a concurrent sinus infection. Squamous metaplasia may also lead to thickening and sloughing of part of the lining of the syrinx with subsequent partial or complete tracheal obstruction (see Color 8). Xerophthalmia occurs if squamous metaplasia affects the eyes. There may be lacrimation, and caseous material may accumulate under the eyes (see Color 26). In chicks, acute hypovitaminosis A has been associated with weakness, incoordination and ataxia. These symptoms must be differentiated from "crazy chick disease" caused by hypovitaminosis E.

In mild cases of hypovitaminosis A, particularly in budgerigars, the only clinical signs may be polyuria and polydypsia, but squamous metaplasia may be seen histologically along the gastrointestinal and urinary tracts. Kidney damage and gout may occur if squamous metaplasia causes partial or complete occlusion of the ureters.

Reduced egg production, egg binding or poorly formed egg shells (pitted) are common in hens with hypovitaminosis A. In cocks, hypovitaminosis A may cause decreased sperm motility, reduced sperm counts and a high level of abnormal sperm.

Hypovitaminosis A may cause hyperkeratosis of the plantar skin of the metatarsal and digital pads (see Color 8). The normal papillary scale structure is lost and the corneum is thickened. Focal hyperkeratosis (corns) often occurs on the metatarsal pads (see Fig-






ure 31.7). These changes predispose birds to pododermatitis (bumblefoot). Other factors apart from malnutrition are also associated with this condition.<sup>22,27</sup> In young ducks, hypovitaminosis A has been shown to cause retardation of endochondral bone growth.

In a number of avian species, vitamin A levels in the liver of less than 50 IU/gm have been found to correlate with the occurrence of squamous metaplasia elsewhere in the body.<sup>34</sup>

Hypovitaminosis A should be initially treated with parenteral supplementation, which establishes rapid blood levels and does not rely on intestinal absorption. In limited clinical trials, some birds may respond just as quickly to supplementation of the diet with spirulina (Harrison GJ, unpublished). Oral administration in the food and modification of the diet to include natural sources of beta carotene is recommended. Zinc levels in the diet should be sufficient to allow for normal vitamin A function. Liver disease may decrease the bird's ability to store vitamin A.

- **Vitamin D** helps to stimulate gastrointestinal absorption of calcium, has a hormonal effect on regulation of calcium and phosphorus excretion in the renal tubules and may be involved in controlling alkaline phosphatase in the blood. An increase in alkaline phosphatase may be an early indication of hypovitaminosis D<sub>3</sub>.



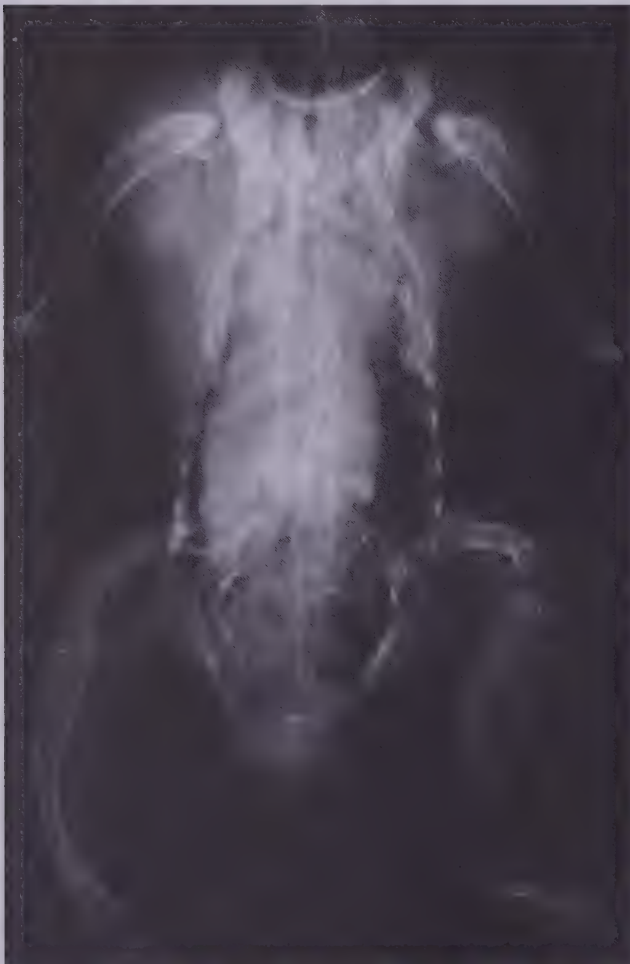**FIG 31.9** An adult female Amazon parrot was presented for severe dyspnea (open-mouthed gasping) and diarrhea. A large, ulcerated pharyngeal mass was evident on physical examination. Radiographic changes included gaseous distension of the crop, gastrointestinal tract and cloaca. The gaseous distension (aerophagia) was related to gasping for air associated with an occluded glottis. The bird did not respond to emergency care. The oval mass was characterized by marked epithelial acanthosis and parakeratosis (see Color 8). The lungs were congested and hemorrhagic. Cystic hyperplasia was evident in the pancreatic ducts. The diagnosis was severe hypovitaminosis A and syringal granuloma.

Ingested vitamin D precursors are converted to the active form of the vitamin (vitamin D<sub>3</sub> in birds) in the skin. Alternatively, vitamin D precursors in the uropygial gland may be spread on the feathers, activated by UV light and then consumed during preening activities. This process requires natural sunlight or appropriate artificial ultraviolet light. Low levels of calcium in the diet, particularly if associated with high levels of phosphorus, will precipitate hypovitaminosis D<sub>3</sub>.<sup>53</sup> If groups of juvenile birds are fed diets low in calcium and vitamin D<sub>3</sub>, birds in shady flights may show overt signs of rickets while those in sunny flights will be normal. Hypovitaminosis D<sub>3</sub> can easily occur in birds raised indoors. It is advisable to sup-

plement indoor birds that do not have access to natural sunlight with exogenous vitamin D<sub>3</sub>.

Signs of vitamin D<sub>3</sub> deficiency parallel those of calcium deficiency. Adult hens may show thin-shelled or soft-shelled eggs, decreased egg production and poor hatchability. Seizuring or leg weakness may occur due to pathologic bone fractures or if an already low blood calcium level is further exacerbated by metabolic demands of egg laying (Figure 31.10).

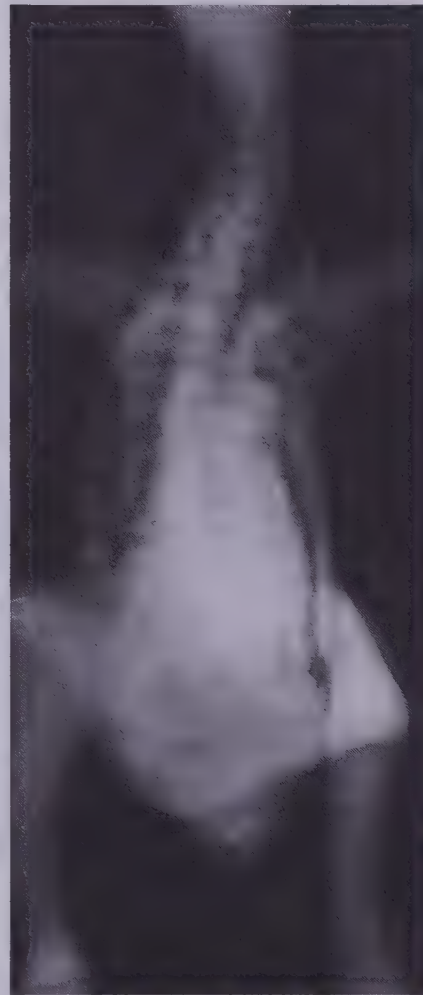Hypovitaminosis D<sub>3</sub> in neonates is characterized by demineralized and easily broken bones. Leg bones will frequently be bent into grossly distorted posi-




**FIG 31.10** Metabolic bone disease is common in birds with hypovitaminosis D<sub>3</sub> and hypocalcemia, as well as in birds consuming diets with low calcium to phosphorus ratios. An 11-week-old African Grey Parrot was presented for limb deformities. The bird was being fed a commercial hand-feeding formula that was rendered ineffective with the addition of oatmeal, strained meat, mashed fruit, baby vegetables and neo-calglucon. Radiographs indicated bending type deformities in the right humerus, pelvis and both femurs and tibiotarsal bones. The case was managed by removing the supplements from the hand-feeding formula.

tions. The sternum may be bent laterally or indented. The spinal column may undergo lordosis or fracture easily, causing pressure on nerves and subsequent paralysis. Radiographically, bones will show poor density and pathologic fractures may be apparent (Figure 31.11).

High levels of vitamin D<sub>3</sub> (>10<sup>6</sup> IU/kg of food compared with recommended levels of around 2000 IU/kg of food) in chickens may cause calcification of renal tubules and arteries, visceral calcinosis, urate nephrosis and visceral gout. Excessive levels of vitamin D precursors may also be toxic. Clinical evidence suggests that young macaws may be particularly susceptible to hypervitaminosis D. Nephrocalcinosis, suspected to be associated with hypervitaminosis D, has been reported in a dove, a toucan, a cardinal and a variety of Psittaciformes (Figure 31.12).<sup>30</sup> Home-



**FIG 31.11** Rickets in a juvenile Blue and Gold Macaw. Note the lack of bone density, bending of the bones and pathologic fractures (courtesy of Marjorie McMillan).



**FIG 31.12** An African Grey Parrot was presented for a pre-purchase examination. Physical and clinical pathology findings were unremarkable. The bird was negative for PBFV virus and polyomavirus by DNA probe testing. Radiographs indicated mineral densities in the kidneys. This is a frequent finding in African Grey Parrots and its clinical importance is unknown. However, calcium supplementation and injectable vitamin A and D<sub>3</sub> in a bird with this condition are contraindicated. Note the extensive air sac capacity, which appears to be normal in African Grey Parrots.

made dietary formulas (particularly those for neonates) are likely to contain improper levels of many nutrients.<sup>41,52</sup> Neonatal birds are best fed proven formulas (see Chapter 30).

- **Vitamin E:** Vitamin E is an antioxidant that acts to prevent fat rancidity and fatty acid degeneration in foodstuffs, as well as acting in concert with selenium and sulfur-containing amino acids to prevent peroxidative damage to cell membranes. Birds on high-fat diets, particularly if the fat has become rancid, require higher amounts of antioxidants, and consequently are more likely to show signs of vitamin E deficiency than birds on diets low in fat.

If accompanied by deficiencies in sulfur-containing amino acids or selenium, hypovitaminosis E may result in skeletal muscle dystrophy as well as muscular dystrophy of the heart or ventriculus. Electrocardiographic changes may accompany heart muscle dystrophy. Undigested seed in the droppings may occur with ventricular muscular dystrophy. Degeneration of the pipping muscle may occur in neonates, resulting in decreased hatchability. Exertional rhabdomyolysis or spraddle legs may be associated with vitamin E and selenium deficiencies (see Chapter 48).<sup>11,34</sup>

Muscle weakness, localized wing paralysis, poor digestion and embryonic and hatchling mortality have been described in cockatiels that responded clinically to vitamin E and selenium therapy. Giardiasis may

have been a predisposing factor. Elevated levels of serum creatinine phosphokinase may suggest nutritional myopathy.<sup>28</sup>

Hypovitaminosis E may cause encephalomalacia in poultry and other species. This condition can be prevented by supplementing the diet with linoleic acid but not arachidonate. *Neophema* parrots fed a dog food that contained a high amount of rancid fat and seed soaked in cod liver oil showed incoordination, abnormal body movements and torticollis. At necropsy, affected birds showed cerebellar demyelination and muscular dystrophy of the heart and skeletal muscle typical of vitamin E deficiency.<sup>8</sup> A similar vitamin E and selenium-responsive syndrome has been reported in *Eclectus* Parrots in Switzerland.<sup>47</sup>

Deficiencies in vitamin E and selenium may cause exudative diathesis, which results in edema of ventral subcutaneous tissue in poultry. Hypovitaminosis E is one of a number of dietary factors that has been associated with enlarged hocks in turkeys. Prolonged hypovitaminosis E may cause testicular degeneration in males, and in hens it may result in infertility or early embryonic deaths.

In mammals, a degenerative disease of fat (yellow fat disease, steatitis) has been associated with hypovitaminosis E. A similar condition has been recognized in birds fed fish with high fat content such as herring, smelt or red meat tuna. Ceroid, a pigment that is

considered pathognomonic for yellow fat disease in mammals, was identified histochemically in the fat from affected birds.<sup>9</sup>

Birds suspected of hypovitaminosis E should receive parenteral supplementation. Mild conditions may respond dramatically to this treatment. In cases where there is irreversible nerve or muscle damage, response is poor (see Chapter 18).

- **Vitamin K:** Vitamin K is required for the synthesis of prothrombin. Deficiency of vitamin K results in prolonged prothrombin time and delayed blood clotting. Affected birds may exsanguinate from minor traumatic injuries. Bacterial flora in the intestine are the natural source of vitamin K. Clinical problems associated with bleeding or petechia from pulled feathers may respond to injectable vitamin K, but naturally occurring hypovitaminosis K has not been proven in companion birds.<sup>18</sup> Sulfaquinolone has been reported to induce hypovitaminosis K in poultry, and it is possible that long-term antibiotics used in aviary birds could do likewise.

#### Water-soluble Vitamins

- **Thiamine (Vitamin B<sub>1</sub>):** Thiamine deficiency may lead to loss of appetite, opisthotonos, seizures and death. Deficiency of thiamine is uncommon in birds on a seed diet because seeds and grains generally contain sufficient thiamine. Thiamine deficiency-induced seizures and neurologic signs may occur in carnivorous birds fed solely on meat or day-old chickens, and in fish-eating birds fed fish containing thiaminase.<sup>17</sup> Free-ranging honey-eaters in urban areas of southern Australia may develop thiamine deficiency during the winter. This is thought to be associated with the planting of exotic ornamental trees that provide inadequate nutrition but encourage the birds to remain in an urban area rather than properly migrate.

Response to treatment in thiamine deficiency cases can be dramatic. Affected birds will respond within minutes to injectable thiamine. Response to oral thiamine may also be rapid.

- **Riboflavin (Vitamin B<sub>2</sub>):** In young chicks, riboflavin deficiency causes weakness and diarrhea, but the bird's appetite remains normal. Affected birds have toes curled inward both when walking and resting. The skin is rough and dry. Similar clinical signs thought to be associated with riboflavin deficiency have been reported in young waterfowl, an eagle and ratites (see Color 48).<sup>34</sup> Turkey poults with riboflavin deficiency show poor growth with dermatitis around

the face and feet. Cockatiels fed riboflavin-deficient diets failed to incorporate pigment into their primary feathers.<sup>46</sup>

Older birds are more resistant to riboflavin deficiency than juveniles. Breeding hens fed riboflavin-deficient diets may show fatty infiltration of the liver as well as decreased hatchability of their eggs and increased embryo mortality. Heterophil counts may increase and lymphocyte counts decrease. Primary wing feathers may be excessively long.<sup>36,51</sup> Early treatment with riboflavin will resolve clinical signs; however, in chronic cases permanent nerve damage may occur.

- **Niacin (Nicotinic Acid):** Clinical signs of niacin deficiency are fairly nonspecific and include poor feathering, nervousness, diarrhea and stomatitis. Young chickens, turkeys and ducks with niacin deficiency may show enlargement of the hock and bowed legs similar to those seen with perosis, but the gastrocnemius tendon does not slip from the condyles. Chickens showing signs of hysteria have responded clinically to niacin supplementation in the drinking water.<sup>3</sup> Niacin deficiency has not been described in Psittaciformes.
- **Pyridoxine (Vitamin B<sub>6</sub>):** Chicks with pyridoxine deficiency may show depressed appetites, poor growth, perosis, jerky movements and spasmodic convulsions. As with riboflavin deficiency, heterophil counts may increase while lymphocyte counts decrease.

Because pyridoxine is involved in amino acid metabolism, signs of deficiency rarely occur unless dietary protein levels are high. In adult chickens, pyridoxine deficiency causes reduced egg production and poor hatchability. Pyridoxine deficiency was suspected in juvenile rheas that developed "goose-stepping" gaits.<sup>16</sup>

- **Pantothenic Acid:** Symptoms of pantothenic acid deficiency in chicks are similar to those of biotin deficiency and include dermatitis on the face and feet, perosis, poor growth, poor feathering and ataxia (see Color 48). Severe edema and subcutaneous hemorrhages are signs of pantothenic acid deficiency in developing chicken embryos.<sup>1</sup> Similar signs have also been seen in developing ostrich embryos. High incubator humidity may contribute to this problem. Cockatiels reared on pantothenic acid-deficient diets failed to grow contour feathers on their chests and backs, and many died at three weeks of age. Affected birds had the appearance of feather-picked chicks.<sup>46</sup>

- **Biotin:** Natural sources of the vitamin are the same as those for pantothenic acid, and signs of biotin deficiency may parallel those of pantothenic acid: dermatitis on the face and feet, perosis, poor growth, poor feathering and ataxia. Biotin deficiency may also be associated with swelling and ulceration of the foot pads, and biotin-deficient embryos may show syndactylia and chondrodysplastic changes in the skeleton. Fatty liver and kidney syndrome in chickens has been associated with marginal biotin deficiency. Although egg yolk is a rich source of biotin, uncooked egg white contains a biotin antagonist called avidin, and biotin supplementation of a diet containing raw egg white may not correct the deficiency unless the biotin-binding capacity of the egg white has been exceeded. Mycotoxins may also interfere with biotin uptake.
- **Folic Acid:** In poultry, folic acid deficiency has been associated with embryonic mortality, deformation of the upper mandible, poor growth, macrocytic anemia, bending of the tibiotarsi and perosis. Folic acid, lysine and iron appear to be needed for the production of feather pigments in colored breeds of poultry. Folic acid is synthesized by bacteria in the digestive tract, so antibiotic therapy, particularly with sulfonamides, could induce a deficiency.
- **Choline:** A deficiency of choline caused poor growth and perosis in juvenile turkeys and chickens. In older birds, fatty liver infiltration may occur. Cockatiels reared on choline-deficient diets showed unpigmented wing and tail feathers but no signs of perosis.<sup>46</sup>
- **Vitamin C:** Bulbuls and fruit-eating birds may require exogenous vitamin C (ascorbic acid) but in chickens, and probably most species of seed-eating birds, vitamin C is synthesized in the liver. Birds with vitamin E and selenium deficiencies, heat stress, trace element toxicity or parasitic infections would be expected to have an increased requirement and decreased production of vitamin C.<sup>3</sup> In these situations, parenteral supplementation of vitamin C would be indicated. Natural sources of vitamin C include fresh fruits and vegetables (eg, citrus fruits, broccoli, green peppers). High dietary intake of ascorbic acid improves albumen quality and egg shell thickness in chickens. Signs of vitamin C deficiency have not been documented in companion birds.

## Minerals

### Calcium and Phosphorus

Calcium in the diet is used for bone formation, egg shell production, blood clotting, nerve impulse transmission, glandular secretion and muscle contraction. Phosphorus is important in many body functions including bone formation, the maintenance of acid-base balance, fat and carbohydrate metabolism and calcium transport in egg formation. Separate vitamin D-dependent mechanisms are believed to be responsible for calcium and phosphorus absorption from the intestine.

If calcium utilization exceeds absorption from the intestine over a prolonged period of time, parathyroid hormone excretion will increase and the parathyroid glands will enlarge (see Color 14). This condition, called secondary nutritional hyperparathyroidism (SNH), allows normal blood calcium levels to be maintained. High levels of phosphorus or low levels of vitamin D in the diet may exacerbate SNH. Symptoms of the syndrome may include weakness, polydipsia, anorexia and regurgitation. In breeding hens, SNH may result in decreased egg production, production of soft-shelled eggs, egg binding and fragile bones (see Chapter 23).

Hypocalcemic seizures associated with severe parathyroid enlargement and degeneration occur as a syndrome in African Grey Parrots.<sup>45</sup> Affected birds are generally between the ages of two to five years. Abnormal clinical pathology findings include leukocytosis and hypocalcemia. Calcium levels may be below 6.0 mg/dl and sometimes as low as 2.4 mg/dl. At necropsy, there is no apparent calcium mobilization from bones as would be expected when blood calcium levels decrease in normal birds. Affected birds have difficulty in mobilizing calcium from body stores, and should be supplemented constantly with dietary calcium. There has been some undocumented discussion that the syndrome is limited to imported birds, and that some naturally occurring environmental factor may initiate the syndrome. Additionally, the problem may be regional in nature because it appears to be more prevalent on the West Coast, as compared to the East Coast, of the United States.

- **Diets for Birds with Hypocalcemia:** Calcium syrup may be used in the drinking water, sprinkled on seeds or soft foods or administered directly. Foods containing high levels of calcium such as bones, cheese or yogurt may be provided. Calcium powder may be sprinkled on soft food. High-fat seeds (eg, sunflower,

safflower) may interfere with calcium uptake from the intestine. Levels of vitamin D<sub>3</sub> in the diet should be evaluated and supplemented if needed.

High-calcium diets are generally required only until normal body reserves are restored. The addition of psyllium to the diet may increase the absorption of calcium.<sup>30</sup> Long-term consumption of high levels of calcium may interfere with manganese or zinc absorption and may result in renal calcium deposition, reduced numbers of glomeruli per kidney and subsequent renal failure.<sup>41</sup> Because of these problems, care should be taken to provide correct supplementation levels. Laying hens and rapidly growing juveniles will require higher levels of calcium than non-breeding adults.

Hypocalcemic seizures are rare in species other than African Grey Parrots. Occasionally, companion birds on an all-seed diet will be presented with seizing caused by hypocalcemia. These birds usually respond dramatically (within minutes) to intramuscular calcium and multivitamin therapy.

Because calcium metabolism is closely linked with vitamin D metabolism, many changes caused by calcium deficiency in juveniles are identical to those caused by hypovitaminosis D. Appropriate amounts of calcium, phosphorus and vitamin D are necessary for optimal bone and egg shell formation. The normal calcium to phosphorus ration for chickens is 2:1. It is likely that a similar ratio would be appropriate for most species of birds although specific research data is lacking. Most available commercial seeds are extremely calcium deficient: corn=1:37, millet=1:6, milo=1:14, oats=1:8 and sunflower seeds=1:7. High-fat content in oil seeds may also interfere with calcium absorption from the intestine and exacerbate the problem.<sup>46</sup>

Muscle meat is low in calcium and high in phosphorus with a ratio of 1:20. Carnivorous birds fed an all-meat diet, day-old chicks or pinky mice may show signs of calcium deficiency and SNH. Feeding whole adult mice, older chicks, quail or rats to carnivorous birds should provide better calcium balance. It is important to provide variety in the type of food fed.<sup>38</sup>

Long bone deformities in juvenile birds, particularly ratites, may be associated with high protein, low calcium diets; however, reducing dietary protein and supplementing calcium may not always correct the problem. In these situations, the overall suitability of the diet, including the calcium to phosphorus ratio, the level of magnesium and electrolytes and the en-

ergy level in the diet should be evaluated. The birds should be encouraged to exercise more and the rate of weight gain should be reduced (see Chapter 48).

Excess phosphorus consumption can exacerbate SNH. Decreases in egg production, poor egg shell quality and rickets could occur with phosphorus deficiency, but this is unlikely because the mineral is very widely distributed in common food items.

### Magnesium

Magnesium is necessary for bone formation, for carbohydrate metabolism and for activation of many enzymes. Its metabolism is closely associated with that of calcium and phosphorus. Deficiencies in young chicks may result in poor growth, lethargy, convulsions and death. Excessive amounts may cause diarrhea, irritability, decreased egg production and thin-shelled eggs.

### Iron

Iron is needed for the production of hemoglobin and many enzymes. Iron deficiency may result in hypochromic, microcytic anemia. Normal levels of non-heme iron in the plasma are necessary for feather pigmentation.

- **Diets for Birds with Anemia:** Birds with anemia should receive a diet that is high in energy and protein, and be supplemented with B complex vitamins (including B<sub>12</sub>, pyridoxine, niacin and folic acid), iron, cobalt and copper.
- **Diets for Birds with Hepatopathies:** Iron storage disorders have been reported in a variety of non-psittacine species, particularly Indian Hill Mynahs, birds of paradise, hornbills and toucans.<sup>34</sup> In some cases, the disease has been correlated with diets high in iron, and problems with the condition decreased when dietary iron levels were lowered to less than 40 ppm (see Chapters 20, 47).

Liver disease may decrease the absorption and storage of fat-soluble vitamins A and D and inhibit the synthesis of vitamin C necessitating supplementation.<sup>21</sup> Other objectives in designing diets for birds with liver disease include reducing the work load on the liver (fat conversion, gluconeogenesis, deamination and nitrogen conversion), preventing sodium retention and hypokalemia, restoring liver glycogen and minimizing the possibility of hepatic encephalopathy. The diet should contain a readily available energy source such as dextrose or other easily digested carbohydrate. Canary seeds, millet, panicum, corn or hulled oats are relatively high in carbohy-

drate and low in protein and fat. These should be used in preference to sunflower seed, rape or niger, all of which are much higher in fat and protein and lower in carbohydrate. Birds with hepatopathy should be offered a variety of fresh fruit and vegetables that are generally high in easily digestible carbohydrates. These fruits and vegetables should be organically grown to prevent exposing the compromised liver to pesticides. The diet should contain a low level of protein of high biologic value such as chopped hard-cooked egg, cottage cheese or cooked chicken. For carnivorous birds, purine-containing foods (offal) should be avoided. The bird should receive a sufficient volume of food to meet caloric needs (see Chapter 20).

### Copper

Copper is necessary for heme synthesis and is an important component of several enzymes including lysyl oxidase, an enzyme involved in the formation of cross-linking in elastin and tyrosine o-diphenol oxidase, which catalyzes the early stages of melanin synthesis. Copper deficiency has been associated with aortic rupture in poultry as well as being associated with increased bone fragility and impaired feather pigmentation. In laying hens, copper deficiency may cause decreased egg production and shell abnormalities including shell-less, misshapen, wrinkled eggs and large eggs with thin shells.

### Selenium

In addition to having a vitamin E-sparing effect in the prevention of ventricular myopathy, white muscle disease and exudative diathesis, selenium is also linked with exocrine pancreatic function and the production of thyroid hormones. In young chickens, selenium deficiency causes poor growth and poor feathering, impaired fat digestion and pancreatic atrophy. Similar problems are occasionally seen in companion birds, but a link with selenium deficiency has not been established. Excess dietary selenium (above four ppm) in ducks can impair hatching success and may be teratogenic<sup>37</sup> (see Chapter 48).

### Manganese

Manganese is required for normal bone and egg shell formation and for growth, reproduction and the prevention of perosis. Poultry embryos and young chicks with a manganese deficiency develop chondrodystrophia: short, thickened limbs, parrot beak, protruding abdomen and retarded growth. Ataxia may also be noted. Seed diets may be deficient in manganese.

### Zinc

Zinc is needed for the formation of insulin and many enzymes in the body. In poultry, zinc deficiency may cause short, thickened long bones, enlargement of the hock, dermatitis and impaired T-cell function. Ducks may develop hyperkeratosis of the feet and oral cavity. Zinc is also necessary for proper function of vitamin A. Patients with hypovitaminosis A must receive adequate levels of dietary zinc for therapy to be successful. Excess levels of zinc may cause pancreatic cell necrosis secondary to interference with cellular protein synthesis.

### Iodine

Iodine is needed for the formation of thyroxine and related compounds in the thyroid gland. Iodine deficiency may result in goiter (enlargement of the thyroid glands). The thyroid glands in birds are located in the thoracic inlet and usually cannot be palpated (see Anatomy Overlays).

Clinical signs of goiter are the result of pressure on organs adjacent to the gland. A loud, wheezing respiration with neck extended may occur if there is pressure against the trachea. Crop dilation and vomiting may occur if the goiter obstructs the outlet to the crop. Iodine-deficient budgerigars are particularly prone to goiter (see Color 19). Goiter has occasionally been reported in other species of birds<sup>53</sup> (see Chapter 23).

Birds with goiter must be handled with care. Excessive stress may cause regurgitation and subsequent aspiration of vomitus. Conservative therapy should include the administration of a drop of iodine orally each day. Injectable iodine and dexamethasone may be necessary in more advanced cases. Once stabilized, the bird should be changed to a formulated diet.

Excess dietary iodine has also been reported to induce goiter (eg, birds consuming iodine-based cleaning agents). High levels of iodine may also antagonize chloride, depress growth rates and induce CNS signs. Goitrogens in plants of the genus *Brassica* (eg, broccoli, cabbage or mustard greens) have been implicated as a cause of goiter in mammals; however, companion birds frequently consume these plants with no side effects.

The iodine content of seed depends on the iodine content of the soil on which it is grown. Seed grown in "goiter belt" regions of the world are likely to be deficient. The problem can be eliminated if iodine is

added to the seed. Alternatively and preferably, the birds should be changed to a formulated diet.

Budgerigars with thyroid tumors may have clinical signs identical to those seen with goiter. While goiter will generally respond quickly to iodine supplementation, thyroid tumors will not. It has been suggested that iodine-deficient diets may be associated with signs of hypothyroidism (eg, lethargy, obesity or dermatitis); however, these signs are rarely seen in companion birds with goiter (see Chapter 23).<sup>32</sup>

### Potassium

Potassium is the principal cation in intracellular fluid and is required for glucose and protein metabolism. The mineral is widely distributed in food of both plant and animal origin. Symptoms associated with deficiency are unlikely to occur, but in chickens these may include decreased egg production, egg shell thinning, muscle and cardiac weakness, tetanic convulsion and death.

### Sodium and Chloride

In poultry, salt deficiency causes weight loss, decreased egg production, small eggs and increased cannibalism. In psittacine birds, it has been suggested that salt deficiency may play a role in some cases of self-mutilation. Sodium deficiency alone may cause a decrease in cardiac output, hemoconcentration, reduced utilization of protein and carbohydrates, soft bones, corneal keratinization, gonadal inactivity and adrenal hypertrophy.

Chloride deficiency in chickens produces dehydration and characteristic CNS signs, in which chicks fall forward with their feet stretched out behind them for several minutes. Tibial dyschondroplasia in meat poultry has been associated with excess dietary chloride. This problem is seen occasionally in young ratites, although the cause has not been clearly defined.

Demineralized bone formation was seen in a variety of juvenile Australian parrots fed a homemade mineral block containing apparently adequate calcium and phosphorus levels, but an excess level of salt. The problem stopped when the mineral block was removed.

Excessive amounts of salt may be acutely toxic. Affected birds show intense polydipsia, muscle weakness and convulsions. Ducks are more sensitive to salt intoxication than are poultry. Sea birds have a nasal salt gland that is controlled by the ATPase pump in the gastrointestinal tract, and is used to excrete excessive exogenous salt. Oil contamination may suppress the ATPase pump and cause clinical signs of salt toxicity. The salt gland of sea birds provided fresh water becomes nonfunctional. Prior to release into a marine environment, these birds should receive gradually increasing levels of salt to ensure that their glands are functional.<sup>57</sup>

### Water

Water consumption in birds varies dramatically among species and among individuals of the same species. Budgerigars and Zebra Finches (species that evolved in desert regions) have been reported to survive several months without drinking, apparently relying on water derived from metabolic sources.<sup>7</sup> On the other hand, healthy companion birds may consume significant amounts of water daily and become distressed if water is withheld.

Some birds that have not evolved for desert living (eg, canaries), may die if they do not drink water for 48 hours. The addition of any compound to the drinking water can cause these birds to stop consuming water, resulting in a rapid dehydration and death.

### References and Suggested Reading

1. **Austic RE, Scott ML:** Nutritional deficiency diseases. In Hofstad MS, et al (ed): *Diseases of Poultry* 8th ed. Ames, Iowa State University Press, 1984, pp 38-64.
2. **Axelsson DR:** Avian nutrition from a practitioner's viewpoint. *Proc Assoc Avian Vet*, 1986, pp 401-417.
3. **Bains BS:** Vitamin and mineral deficiency diseases of poultry. *Proc No. 92 Post Grad Comm in Vet Sci, Univ Sydney*, 1986, pp 43-90.
4. **Blue-McLendon A:** Surgical procedure for performing a proventriculotomy in ostriches. *Proc Assoc Avian Vet*, 1990, pp 150-152.
5. **Boardman, W:** Personal communication, 1991.
6. **Brue RN:** Nutritional deficiencies of seed diets. Nutritional lecture series handout. Kaytee Products, 1980.
7. **Cade TJ, James CM:** Water economy of the budgerigar. *Auk* 79:345-364, 1962.
8. **Campbell TW:** Hypovitaminosis E: Its effect on birds. *Proc 1st Intl Conf Zoo Avian Med, Hawaii*, 1987, pp 75-78.
9. **Carpenter JW, et al:** Diet related die-off of captive black crowned night herons. *Proc Am Assoc Zoo Vet*, 1979, pp 51-55.
10. **Davies PA:** An overview of psittacine diets and the technician's role in avian nutrition education. *Proc Assoc Avian Vet*, 1990, pp 534-537.
11. **Dolensk EP, et al:** Hatching problems in exotic birds. *Proc Am Assoc Zoo Vet*, 1979, pp 63-64.
12. **Drepper K, et al:** Untersuchungen zum Protein- und energi be darf adu- ter Wellensittche (*Melopsittacus undulatus*) in Kafighaltung. In *Klein- tierpraxis* 33:57-62, 1988.
13. **Dorrestein GM, et al:** Metaplastic alterations in the salivary glands of parrots in relation to liver vitamin A levels. *Proc 1st Intl Conf Zoo & Avian Med, Hawaii*, 1987, pp 69-74.
14. **Duke GE:** Alimentary canal: Secretion and digestion, special digestive functions and absorption. In *Sturkie PD (ed): Avian Physiology* 4th ed. New York, Springer-Verlag, 1986, pp 289-302.
15. **Ekstrom DL:** Avian gout. *Proc Assoc Avian Vet*, 1989, pp 130-138.
16. **Fleig GM:** Nutritional problems in young ratites. *Intl Zoo Yearbook* 13:158, 1973.
17. **Fowler ME:** Miscellaneous water-birds. In *Fowler ME (ed): Zoo and Wild Animal Medicine*. Philadelphia, WB Saunders Co, 1978, pp 211-217.
18. **Fudge AM:** Avian hematology identification and interpretation. *Proc Assoc Avian Vet*, 1989, pp 284-292.
19. **Gerlach H:** So-called iron storage disease in mynahs. *Proc 1st Intl Conf Zoo & Avian Med, Hawaii*, 1987, pp 79-86.
20. **Gill J:** Parrot diseases and nutrition. *Caged Bird Med & Surg Sem, Univ Sydney*, 1989, pp 233-261.



21. **Gould J:** Liver disease in psittacines. *Proc Assoc Avian Vet*, 1989, pp 125-129.
22. **Graham DL:** The avian integument: Its structure and selected diseases. *Proc Assoc Avian Vet*, 1985, pp 33-52.
23. **Graham DL:** Structure, function and disorders of the avian alimentary tract (an outline from stem to stern). *Proc Assoc Avian Vet*, 1986, pp 307-316.
24. **Griminger P:** Lipid metabolism. *In* Sturkie PD (ed): *Avian Physiology* 4th ed. New York, Springer-Verlag, 1986, pp 345-358.
25. **Griminger P:** Protein metabolism. *In* Sturkie PD (ed): *Avian Physiology* 4th ed. New York, Springer-Verlag, 1986, pp 326-344.
26. **Harrison GJ, Harrison LR:** Nutritional diseases. *In* Harrison GJ, Harrison LR (eds): *Clinical Avian Medicine and Surgery*. Philadelphia, WB Saunders Co, 1986, pp 397-407.
27. **Harrison GJ:** Disorders of the integument. *In* Harrison GJ, Harrison LR (eds): *Clinical Avian Medicine and Surgery*. Philadelphia, WB Saunders Co, 1986, pp 509-524.
28. **Harrison GJ:** Preliminary work with selenium/vitamin E responsive conditions in cockatiels and other psittacines. *Proc Assoc Avian Vet*, 1986, pp 257-262.
29. **Harrison GJ:** Feather disorders. *Vet Clin No Am* 14(2):179-200, 1984.
30. **Harrison GJ:** Psittacine feeding and malnutrition in the USA. *Proc Europ Assoc Avian Vet*, 1991, pp 230-240.
31. **Hazelwood RL:** Carbohydrate metabolism. *In* Sturkie PD (ed): *Avian Physiology* 4th ed. New York, Springer-Verlag, 1986, pp 303-325.
32. **Hillyer EV, Quesenberry KE:** Basic avian dermatology. *Proc Assoc Avian Vet*, 1989, pp 101-121.
33. **Jordan FTW:** Nutritional disorders. *In* *Poultry Diseases* 3rd ed. London, Baillière Tindall, 1990, pp 295-319.
34. **Lowenstine LJ:** Nutritional disorders of birds. *In* Fowler MF (ed): *Zoo and Wild Animal Medicine*. Philadelphia, WB Saunders Co, 1986, pp 202-212.
35. **Minsky L, Petrak ML:** Metabolic and miscellaneous conditions. *In* Petrak ML (ed): *Diseases of Cage and Aviary Birds* 2nd ed. Philadelphia, Lea & Febiger, 1982, pp 638-645.
36. **Morishita TY:** Establishing a differential diagnosis for backyard poultry flocks. *Proc Assoc Avian Vet*, 1990, pp 106-111.
37. **Olsen G:** A review of some causes of death of avian embryos. *Proc Assoc Avian Vet*, 1990, pp 106-111.
38. **Olsen J:** Caring for Birds of Prey. Occasional Publication of the Applied Ecology Research Group, 1990, pp 27-29.
39. **Perry R:** Skin, beak, claw and feather disorders. *In* Macwhirter PJ (ed): *Everybird, A Guide to Bird Health*. Melbourne, Australia, Inkata, 1987, pp 98-121.
40. **Phalen DN:** Acute pancreatic necrosis in an umbrella cockatoo. *Proc Assoc Avian Vet*, 1988, pp 203-205.
41. **Phalen DN, et al:** The avian urinary tract, form, function, diseases. *Proc Assoc Avian Vet*, 1990, pp 44-57.
42. **Quesenberry KE, et al:** Nutritional support of the avian patient. *Proc Assoc Avian Vet*, 1989, pp 11-18.
44. **Roskopf WJ, Woerpel RJ:** Remission of lipomatous growths in a hypothyroid budgerigar in response to L-thyroxine therapy. *Vet Med Sm Anim Clin*, Sept, 1983.
45. **Roskopf WJ, et al:** The hypocalcemia syndrome in African greys: An updated clinical viewpoint with current recommendations for treatment. *Proc Assoc Avian Vet*, 1985, pp 129-131.
46. **Roudybush T:** Growth, signs of deficiency and weaning in cockatiels fed deficient diets. *Proc Assoc Avian Vet*, 1986, pp 333-340.
47. **Rübel A:** Avian medicine in Switzerland. *Proc Assoc Avian Vet*, 1990, pp 38-41.
48. **Schultz D:** Nutrition and orphan rearing young birds. *In* Macwhirter PJ (ed): *Everybird, A Guide to Bird Health*. Melbourne, Australia, Inkata, 1987, pp 30-44.
49. **Scott ML:** Gizzard erosion. *Avian Health & Nutrition*, 1985, pp 22-29.
50. **Shephard M:** Aviculture in Australia. Prahran, Vic. Australia, Black Cockatoo Press, 1989, pp 18-32.
51. **Sturkie PD:** Body fluids: Blood. *In* Sturkie PD (ed): *Avian Physiology* 4th ed. New York, Springer-Verlag, 1986, pp 102-129.
52. **Takeshita K, et al:** Hypervitaminosis D in baby macaws. *Proc Assoc Avian Vet*, 1986, pp 341-345.
53. **Tollefson IC:** Nutrition. *In* Petrak ML (ed): *Diseases of Cage and Aviary Birds* 2nd ed. Philadelphia, Lea & Febiger, 1982, pp 220-249.
54. **Ullrey DE:** Dietary husbandry of psittacines. *Proc Assoc Avian Vet*, 1991, pp 224-226.
55. **Underwood MS, et al:** Short term energy and protein utilization by budgerigars (*Melopsittacus undulatus*) fed isocaloric diets of varying protein concentrations. *Proc Assoc Avian Vet*, 1991, pp 227-236.
56. **Wentworth BC, Ringer RK:** Thyroids. *In* Sturkie PD (ed): *Avian Physiology* 4th ed. New York, Springer-Verlag, 1986, pp 452-465.
57. **White J:** Protocol for the rehabilitation of oil-affected waterbirds. *Proc Assoc Avian Vet*, 1990, pp 153-163.
58. **Whitow GC:** Energy metabolism. *In* Sturkie PD (ed): *Avian Physiology* 4th ed. New York, Springer-Verlag, 1986, pp 253-268.
59. **Worell A:** Phlebotomy for treatment of hemochromatosis in two sulphur-breasted toucans. *Proc Assoc Avian Vet*, 1991, pp 9-14.
60. **Worell A:** Serum iron levels in rhamphastids. *Proc Assoc Avian Vet*, 1991, pp 120-130.

CHAPTER

# 32

VIRUSES

■  
Helga Gerlach

**W**orldwide movement of birds for the pet market can cause a blending of different populations with the possibility of carrying widely varying microorganisms or antibodies against them. If one group of birds is exposed to another with a latent infection, then a severe disease outbreak can occur. Such latently infected birds create a diagnostic and flock management dilemma. While the carrier birds may be clinically inconspicuous, the virus may propagate at a low level and shed through the feces, urine, respiratory secretions or exfoliated epithelial cells from the feathers or skin. In some cases, latently infected birds may succumb to disease, with the virus replicating very rapidly, and both groups of birds may become sick. Artificial incubation and shipping of eggs has been suggested as a method to protect a given population from introduction of an exogenous virus. However, this concept is flawed because a hen can pass antibodies and some viruses to her offspring while the egg is developing. Infected neonates can cause severe epornitics with high mortality in a nursery situation.

In general, viral infections remain untreatable. Non-specific supportive care, antimicrobials to prevent secondary bacterial and fungal infections and good nutritional support, including the supplementation of vitamin C, remain the only available therapeutic regimens for most viral infections. Newly emerging concepts in the use of antisense RNA will undoubtedly result in more specific therapies for many infectious diseases (see Chapter 6). Interferon has been suggested for treatment of viral infections. Paramunity inducers have proven effective with some viral diseases.<sup>334,365</sup> Acyclovir has proven to be effective with some strains of avian herpesvirus and may have positive effects in treating poxvirus infections (see Table 32.18). Substantial viral disease outbreaks may be prevented by having a working knowledge of the transmission routes and pathogenesis of a particular virus, by using specific diagnostic tests to detect clinical or subclinical infections, by practicing sound hygiene and by maintaining closed aviaries. Virus adaptation on specific host cells may be difficult to overcome with the routine avian culture systems, and great patience might be necessary when trying adaptation passages (at least ten or more). Continued international cooperation will be mandatory for the expansion of knowledge in the field of avian virology. The application of molecular biology

techniques seems to improve the researcher's ability to diagnose infections and to establish the role that viruses play in the disease process.

## Diagnostic Principles

An unequivocal diagnosis of a particular viral infection can be made only through specific laboratory diagnostic methods. Clinical, pathologic and histologic changes are perhaps suggestive of a diagnosis but pathognomonic lesions are rare, and in-depth diagnostic tools are necessary to confirm a virus as a cause of morbidity or mortality in an avian host (Table 32.1). There are several procedures that can be used to confirm the presence of a viral infection: 1) Isolation of the pathogen from the test material; 2) Demonstration of viral particles or inclusion bodies by histopathology; 3) Demonstration of viral antigen (Ag) in infected tissues using viral-specific antibodies (Ab); 4) Demonstration of viral nucleic acid in infected tissues using viral-specific nucleic acid probes; 5) Indirect demonstration of a viral infection by detection of humoral antibodies. A viral disease can sometimes be demonstrated by a rise in antibody titers in paired serum samples.

Viral-specific nucleic acid probes are more sensitive than other techniques and allow the detection of small concentrations of virus as well as the ability to detect the presence of viral nucleic acid before substantial histologic changes may have occurred.

### Virus Cultures

Choosing an optimum culture system for avian viruses is difficult. There are over 8,700 avian species, which probably have an equally large number of specifically host-adapted viruses. Primary cell cultures from fibroblasts, kidney or liver cells collected from embryos of the test species normally provide the best chance of isolating a host-adapted virus. Unfortunately, such embryos (which should ideally be free of specific pathogens) are rarely available for the bird species seen in private practice. Cell cultures derived from chickens, ducks and geese are most often used as an alternative choice because of their wide availability; however, these sources of cells have inherent problems. Not every newly prepared cell culture is identical to its predecessor, which may affect virus propagation. If pathogens from heterologous bird

TABLE 32.1 Virus Identification Tests

#### Immunodiffusion (ID)

The ID is a common, inexpensive method to demonstrate mainly group-specific soluble antigens (primarily IgM). The antigen and antibody diffuse toward each other in an agar gel. Where reactive partners meet, they form a precipitate that is visible as one or several pale lines. This technique is relatively simple and adequately fulfills several objectives. It is, however, relatively insensitive when compared to other techniques. The gel should contain 8% NaCl when testing avian serum (Figure 32.1).

#### Hemagglutination Inhibition Test (HI)

Proteins present on the surface of some viruses agglutinate erythrocytes from certain avian or mammalian species. By adding antibodies directed against the agglutinating portion of the virus, hemagglutinin activity is neutralized so that hemagglutination cannot take place (hemagglutination inhibition - HI). The HI test recognizes surface antigens (primarily IgG) (Figure 32.2).

#### Virus Neutralization Test (VN)

Test serum is mixed with an antigen. If viral-specific neutralizing antibodies are present in the test serum, and the quantitative ratio is correct, then virus in a sample will be neutralized. Determining that an Ag-Ab reaction has occurred must then be demonstrated by showing that the neutralized virus is incapable of inducing disease in a test system (usually cell culture). Although VN tests can be performed for many viruses, they are time-consuming and require a series of dilutions that consume a large quantity of raw materials and reagents. The VN test is suitable for serotyping depending on the virus species and the type of antibody used.

#### Complement-Fixation (CF)

Complement is necessary for binding to occur between Ag and Ab. If an Ag-Ab reaction occurs with test material then complement is fixed (used up), and a second reaction with an Ag-Ab indicator system can no longer take place. This system is just as complicated as the ELISA test, which is much more sensitive. Furthermore, commercially available guinea pig complement is inappropriate for use with many bird species. The CF test is generally used for demonstrating group-specific antigens.

#### ELISA

Antigen or antibody is bound firmly to a plate. A test material is added (can be serum for detecting Ab or tissue samples for detecting Ag). The occurrence of an Ag-Ab reaction is demonstrated by adding a third Ag or Ab that is conjugated with an enzyme. A substrate that is converted by the bound enzyme is added to the system and a color change occurs. This system is highly sensitive and technically simple to operate. However, preparation of the appropriate enzyme conjugate with a correspondingly high degree of specificity is demanding. Nonspecific reactions are frequently observed. Generally, the ELISA recognizes group-specific antigens; however, with the use of monoclonal antibodies, serotypes, biovars or mutants can be demonstrated.

#### Immunofluorescence (IF)

Antigen or Ab is conjugated with fluorescent dyes. If an Ag-Ab reaction occurs with test material then fluorescence is present after washing off the superplus reagents. Nonspecific fluorescence that complicates interpretation of the test is common. The IF is best suited for demonstration of group-specific antigens.


#### Radioimmunoassay (RIA)

Either antigens or antibodies are radioactively labelled. The technique itself is essentially similar to that of IF. Although this method is very sensitive, it presents inherent dangers to personnel dealing with radioactive materials as well as creating disposal problems for radioactive waste. Identification of group-specific antigens, serovars or individual antigenic sites is possible with the correct antibodies.

species will grow in non-host cell cultures at all, they often require repeated passages for adaptation to the cells, prolonging the recovery of a virus from weeks to months. Many viral pathogens have never been successfully isolated in cell culture.



**FIG 32.1** Agar-gel diffusion test using serum from an adult psittacine bird three weeks after vaccination with an experimental inactivated PBF D virus vaccine. The initial precipitating antibody titer was 0. The presence of a precipitation line at 1/80 (arrow) indicates that the bird seroconverted following vaccination and produced anti-PBF D virus precipitating antibodies.



**FIG 32.2** Some viruses will cause the agglutination (no button forms) of certain types of erythrocytes. Noted examples of avian viruses that will agglutinate some erythrocytes include PBF D virus, polyomavirus and paramyxovirus. Antibodies to these viruses can be detected by determining if serum from a patient prevents agglutination (the antibodies bind to the hemagglutination site on the RBC and allow a button to form). In this photograph, decreasing dilutions of PBF D virus were used to agglutinate (HA) guinea pig and cockatoo erythrocytes. The point at which the diluted virus will no longer agglutinate the cells (button forms) is the HA titer for the virus. Anti-PBF D virus antibodies could be detected by showing that serum would block (hemagglutination inhibition-HI) the virus from causing agglutination, which allows a button to form (reprinted with permission from *Am J Vet Res* 52:1991).

In addition to tissue cultures, embryonated eggs have been used to recover avian viruses. In contrast to tissue culture, they offer a complete biologic system with cells of endo-, meso- and ectodermal origin. The flocks from which these eggs are obtained should be free of viruses and virus antibodies in order to allow a particular virus to grow.

### Virus Identification

Direct identification of a virus by electron microscopy is possible only with a relatively high concentration of the virus (generally  $>10^6$  particles/ml). As a rapid but insensitive survey, fresh tissue samples fixed on grids (stained with osmium or another appropriate stain) can be examined by electron microscopy for the presence of viruses. Viral-specific nucleic acid probes allow the detection of very small concentrations of a virus in infected tissues or contaminated samples (crop washing, feces, respiratory excretions). Analytic methods such as electrophoresis without blot systems (Ab-dependent with blots), chromatography and nucleic acid probes are the most sensitive methods of demonstrating virus. They function independent of Ag-Ab reactions. The recent advances in genetic engineering will certainly have profound effects on virus detection in the future. DNA probes are currently available for detecting polyomavirus and psittacine beak and feather disease virus. Other similar diagnostic tests will ultimately be developed. All other methods of virus identification are based on changes induced by the virus, such as histologically discernible inclusion bodies. Viral-specific antibody preparations can be used to confirm the presence of a

virus. Depending on the test objective, either polyclonal or monoclonal antibodies can be used. Monoclonal antibodies are normally used for identifying specific antigen structures and to differentiate between serotypes, subtypes, variants and mutants. Polyclonal antibodies are generally adequate for routine diagnostic tests. The identification of viruses using known antibodies inevitably requires an appropriate system to show that an antigen-antibody reaction has taken place. A test is chosen based on the objective of the test (group-specific antigens, serotyping) and the type of antibody (polyvalent, monovalent, monoclonal) available. Frequently used tests to demonstrate the presence of a virus or antibodies against a virus are listed in Table 32.2.

### Indirect Virus Identification

Indirect virus identification techniques require the demonstration of specific antibodies in a patient's serum. To differentiate between Ab's that have been induced by prior exposure to an agent and those caused by a current infection, it is necessary to test two serum samples collected at two- to three-week intervals. A rise or fall in Ab concentrations or a switch from IgM to IgG are indicative of an active infection. Egg yolk (containing IgG) can be used in place of serum for some diagnostic tests.

Serologic cross-reactions caused by closely related antigens or epitopes with an identical structure can cause false-positive results when using indirect virus identification techniques. Precipitating Ab's (as used in the immunodiffusion test) consist primarily of IgM and are present relatively quickly after an infection and are broken down equally rapidly once the pathogen has been eliminated. The immunodiffusion test; therefore, is useful in diagnosing an actively occurring antibody response. It should be noted that not all infected individuals will produce precipitating Ab's.

### Test Material

The proper test material for diagnosing viral infections depends on whether antemortem or postmortem samples are available and which viral disease is suspected. Antemortem samples may include feces, skin, organ or feather biopsy, blood or serum, or mucosal swabs from the trachea, cloaca, pharynx or conjunctiva. When flock problems occur, collecting fresh postmortem samples from a recently affected

bird is the best way to achieve an accurate diagnosis. Samples for culture should be transported quickly and well cooled in a transport medium containing antibiotics. A relevant anamnestic report is valuable to help guide the laboratory diagnostic efforts.

## Avipoxvirus

Members of the Poxviridae family (*Avipoxvirus* genus) cause a variety of diseases in birds. These large DNA viruses (250 to 300 nm) induce intracytoplasmic, lipophilic inclusion bodies called Bollinger bodies (pathognomonic). These inclusion bodies may be identified in affected epithelial cells of the integument, respiratory tract and oral cavity. Many bird species are considered to be susceptible to some strain of poxvirus, and isolates from different bird species have been classified into taxons. Biologic and serologic-immunologic properties for many avian poxviruses have not been determined, and the currently described taxons are probably incomplete.

The genus *Avipox* seems to be restricted to birds. Most of the members of the genus seem to be species-specific, but some taxons appear to be able to pass the species, genus or even family barrier. Although certain poxvirus strains will experimentally infect a variety of host species, cross-immunity may not al-

TABLE 32.2 Characteristic Histologic Lesions and Diagnostic Techniques of Selected Avian Viruses

Virus	Characteristic Lesions	Diagnostic Methods
Adenovirus	Basophilic intranuclear inclusions	Histopathology, serology (AGID)
EEE	Non-suppurative encephalitis, "descending" encephalitis	Histopathology, serology (HI)
Herpesvirus	Basophilic to eosinophilic intranuclear inclusion bodies (Cowdry type A)	Histopathology, virus isolation (Ab titers inconsistent)
Papillomavirus	Hyperkeratotic epidermis, intranuclear inclusions	Histopathology
Polyomavirus	Enlarged cells containing clear basophilic or amphophilic inclusions	Histopathology suggestive, virus isolation, viral-specific DNA probes (detecting shedders and confirming infections), <i>in situ</i> hybridization of tissues
PBFD virus	Basophilic intranuclear inclusions in epithelial cells, basophilic intracytoplasmic inclusions in macrophages	Histopathology, viral-specific DNA probes (detecting symptomatic or asymptomatic infections in blood), <i>in situ</i> hybridization of tissues
Paramyxovirus		Electron microscopy (EM), serology (HI), viral isolation
Poxvirus	Epithelial ballooning degeneration, intracytoplasmic inclusions (Bollinger bodies) pathognomonic, intranuclear inclusion bodies (Juncos)	Histopathology, viral culture, virus detection in feces by culture or EM
Reovirus	Necrotizing hepatitis, rarely intracytoplasmic inclusions	Virus isolation

## Viruses

### Color 32.1

A young pionus parrot was confirmed to have PBFD virus by demonstrating viral antigen in infected tissues with viral-specific antibodies and by demonstrating viral nucleic acid in circulating white blood cells using a DNA probe test. This bird was infected as a neonate when the breeder unknowingly added some infected African Grey Parrot chicks to the nursery.

### Color 32.2

An Umbrella Cockatoo chick shows the first clinical feather changes associated with PBFD virus a minimum of 34 days after being exposed to the virus. The bird was depressed for two days before necrotic feathers became apparent. All of this bird's primary and secondary feathers were affected within a week after this photograph was taken.

### Color 32.3

PBFD virus in older birds is characterized by progressive feather dystrophy and loss that typically starts with the powder down feathers as seen in this Umbrella Cockatoo. The disease then progresses during the ensuing molts to a point where the flight and tail feathers are also involved.

### Color 32.4

Scarlet Macaw with the progressive form of PBFD virus causing dystrophic changes in the primary and secondary feathers.

### Color 32.5

An experimental PBFD virus vaccine has been shown to be effective in preventing infections in neonates. In this photograph, an infected (right) and a vaccinated, protected African Grey Parrot chick of the same age dramatically illustrate the effects of the PBFD virus on a developing chick.

### Color 32.6

PBFD virus antigen and nucleic acid can be demonstrated in infected white blood cells

using viral-specific antibodies (shown here) or viral-specific DNA probes. The circulating white blood cells that are brown contain PBFD virus antigen. The other white blood cells in this preparation do not contain viral protein, suggesting that both infected and uninfected white blood cells are present in the circulation (courtesy of Kenneth Latimer).

### Color 32.7

Immunoperoxidase staining of a feather from a bird with PBFD virus. Viral antigen is demonstrated in intranuclear (arrow) and intracytoplasmic (open arrow) inclusion bodies (courtesy of Kenneth Latimer).

### Color 32.8

**a)** Large, basophilic intranuclear inclusion bodies are suggestive of avian polyomavirus. Infections can be confirmed only by documenting viral antigen or nucleic acid in suspect lesions using viral-specific antibodies (shown here) or **b)** DNA probes, respectively.

### Color 32.9

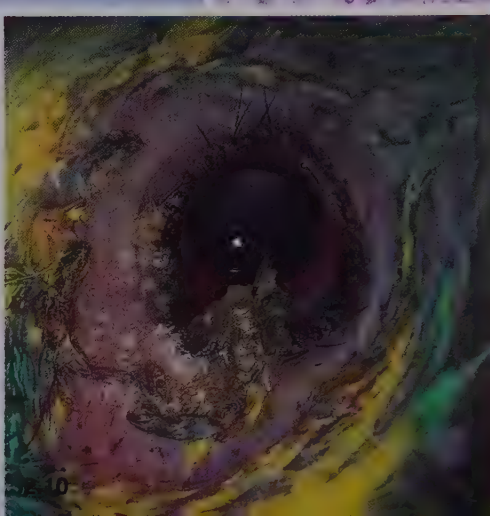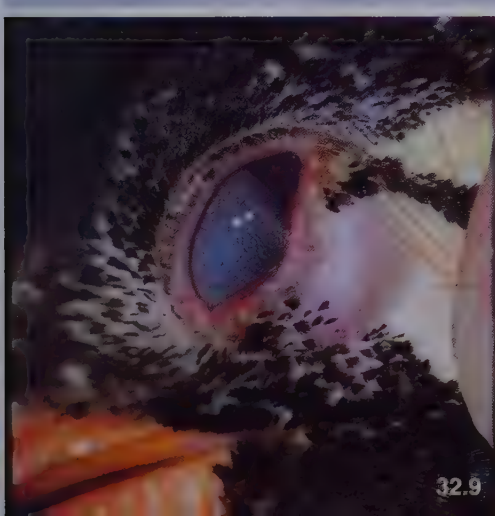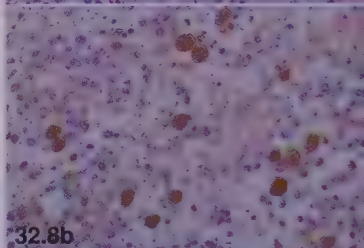
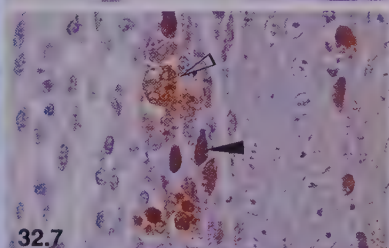
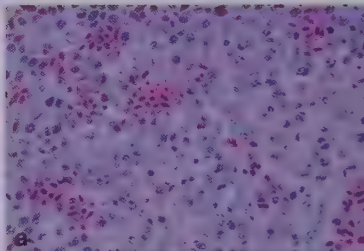
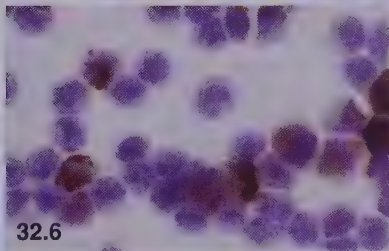


Early poxvirus lesions on the lid margin of a mynah bird.

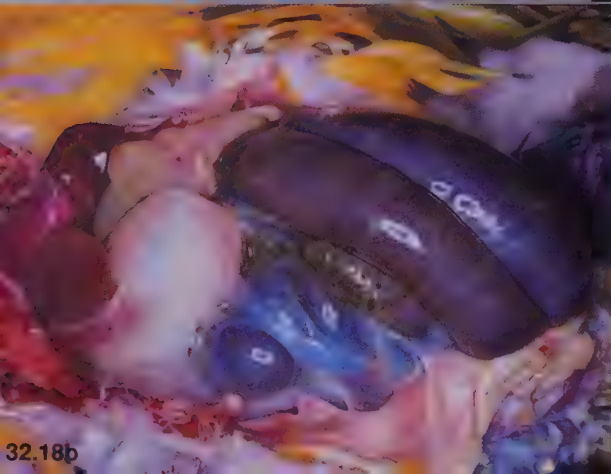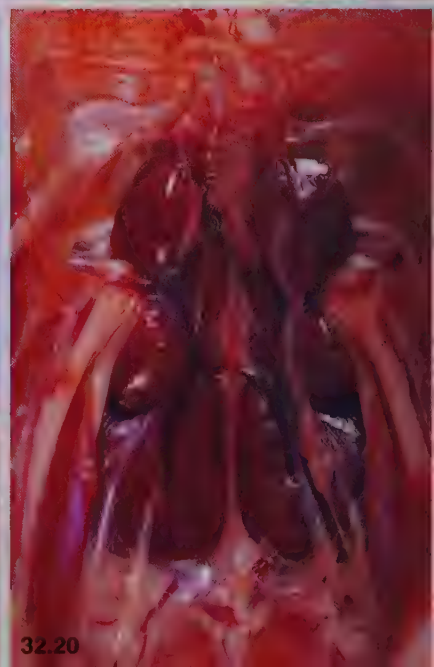

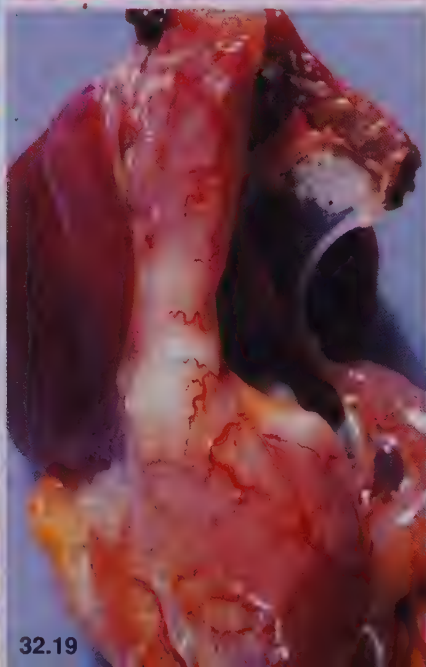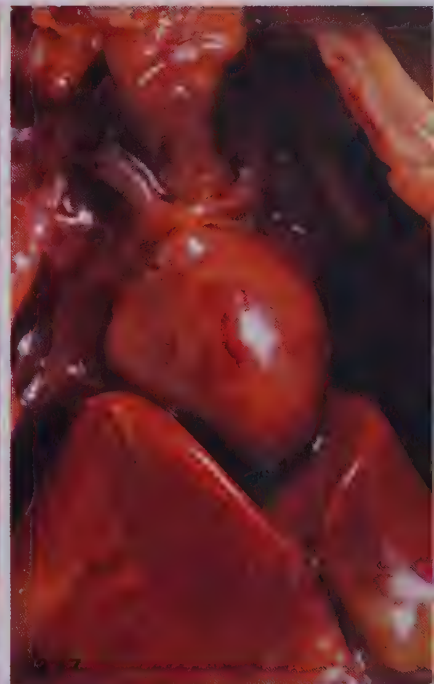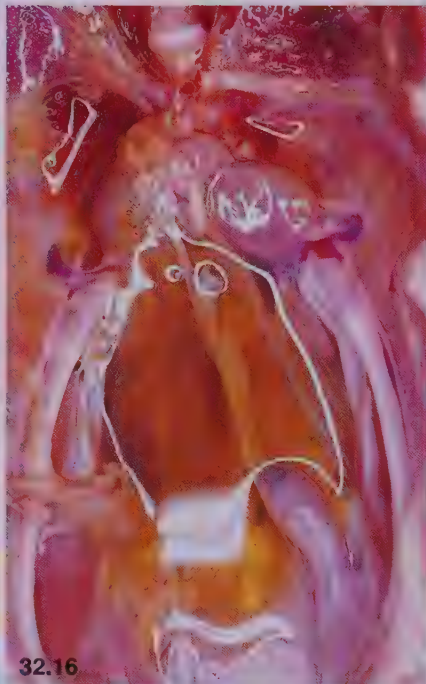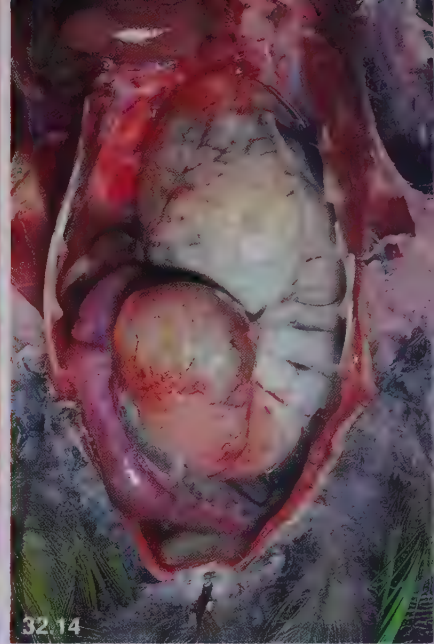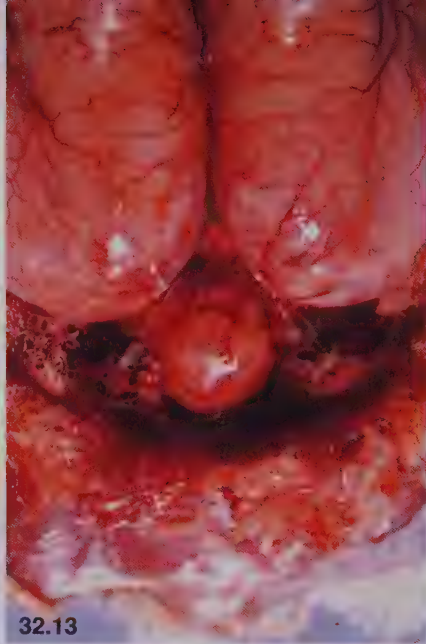### Color 32.10

A recently imported Blue-fronted Amazon Parrot was presented with oculonasal discharge. Ulcerative lesions of the lid margins with accumulation of necrotic debris were characteristic for poxvirus. The bird responded to supportive care that included flushing the ocular lesions with sterile saline QID and administration of broad spectrum antibiotics to prevent secondary bacterial infections.

### Color 32.11

Beak changes may or may not occur in birds with PBFD virus infections. If they occur, they generally start as palatine necrosis.







## Viruses

### Color 32.12

Subcutaneous hemorrhage in a Blue and Gold Macaw chick suggestive of a polyomavirus infection.

### Color 32.13

A Moluccan Cockatoo was presented with a progressive neurologic disease that started with ataxia and tremors several months before presentation. The bird had an upper respiratory disease about two weeks before the CNS signs were first noted. The bird's feather condition was marginal. DNA probe testing for PBFV virus and polyomavirus were negative. Radiographs were normal. Abnormal clinicopathologic findings included WBC=25,000 (lymphocytosis) and CPK=1500. EEG indicated an inflammatory disease. The bird died despite extensive supportive care. Several milliliters of yellow fluid were collected from the brain cavity at necropsy. The brain was hyperemic. Histopathology indicated basophilic intranuclear inclusion bodies similar to those caused by adenovirus.

### Color 32.14

Finding a dilated, thin-walled proventriculus is suggestive of neuropathic gastric dilatation. The diagnosis can be confirmed only by demonstrating characteristic histopathologic lesions including lymphoplasmacytic ganglioneuritis.

### Color 32.15

A 25-day-old budgerigar with PBFV virus. The feather lesions caused by PBFV virus are grossly similar to those caused by polyomavirus. French moult may be caused by either the PBFV virus or polyomavirus. Differentiation of these viral diseases requires detection of viral-specific antibodies or viral-specific DNA probe testing.

### Color 32.16

Typical fluid accumulation in the abdomen of a Blue and Gold Macaw with avian viral serositis.

### Color 32.17

A Blue and Gold Macaw chick was presented for evaluation. The bird was in a comatose state and was the sixth baby from a psittacine nursery to die acutely. The bird had subcutaneous hemorrhages, hepatomegaly and swollen hemorrhagic kidneys, all suggestive of polyomavirus. The bird was confirmed to have avian polyomavirus by identifying suggestive intranuclear inclusion bodies in the liver, spleen, kidneys and heart and by DNA probe detection of viral nucleic acid on a swab taken from the cut surface of the liver and spleen.

### Color 32.18

An 18-week-old Blue and Gold Macaw was presented with a one-week history of lethargy and regurgitation. **a)** The abdomen was severely enlarged and filled with fluid. Abnormal clinicopathologic findings included TP=0.7, PCV=19, WBC=3,000. Radiographs indicated ileus with severe bowel loop distension. **b)** Gross necropsy findings included distension of the black, congested intestines. Histopathology indicated multifocal nonsuppurative serosities and lymphocytic proventriculus suggestive of avian viral serositis. The bird's clutch mate died several weeks later with the same lesions.

### Color 32.19

A cockatoo that had been exposed to birds with neuropathic gastric dilatation (NGD) was suspected to have the disease based on clinical signs of diarrhea, hypermotility of gastrointestinal tract (as detected by contrast radiography) and weight loss. The bird died acutely. The only gross necropsy lesion was congestion of the gastric vasculature. The bird had histologic lesions consistent with NGD.

### Color 32.20

Congestion and hemorrhage of the kidneys in a female Blue and Gold Macaw chick with avian polyomavirus.

ways be inducible. Further, the *Avipox* genus has a high capacity for recombination, which has been shown to occur between field and vaccine strains of virus when actively infected flocks are vaccinated. Many experimental infections have been performed without determining the strain of virus, which probably adds to confusion about poxvirus epizootiology.

Various *Avipox* spp. demonstrate serologic cross-reactions (VN and ID). Hemagglutinins are not produced. Species differentiation is based on host spectrum, plaque morphology of primary isolates, thermostability, optimal propagation temperature, serology, cross-immunity and ultrastructural characteristics (Tables 32.3, 32.4).

Waterfowlpox probably does not form a uniform group. Therefore, it can be expected that the full protection provided by fowlpoxvirus is not effective in all waterfowl species.

Peacock poxvirus can experimentally infect chickens but not domesticated pigeons and probably not turkeys. However, peafowl vaccinated with fowlpoxvirus were not protected against peacockpox.<sup>16</sup>

Poxvirus lesions have been documented on the feet, beak and periorbitally in numerous Passeriformes.<sup>216,403</sup>

### Transmission

Transmission occurs through latently infected birds and biting arthropods in the habitat. In many areas, mosquitoes serve as the primary vectors, and infections are most common during late summer and autumn when mosquitoes are prevalent. Birds of any age are considered susceptible, although young birds are most frequently affected. A mosquito that feeds on an infected bird can retain infectious virus in the salivary glands two to eight weeks. Direct transmission of the virus between birds is linked to traumatic injuries induced by territorial behavior, which allows the virus access to the host through damaged epithelium.

### Pathogenesis

Most members of the Poxviridae stimulate the synthesis of DNA in the host's epithelial cells resulting in hyperplasia of the affected epithelium. Avipoxvirus cannot penetrate intact epithelium. Traumatic lesions that may be induced by biting insects (mosquitoes, mites and ticks) can cause sufficient damage to the epithelial barrier to allow viral entrance to the host. Infections may be restricted to the portal of entry, or viremia and subsequent distribution to tar-

get organs may occur. The factors that control the type of infection have not been determined; however, it is known that a severe generalized disease occurs only if the infection takes the two-cyclic course (Figure 32.3).

This replication cycle occurs only with pathogenic strains, and the secondary viremia does not occur with nonpathogenic, slightly pathogenic or modified live virus vaccine strains. These strains generally induce an infection restricted to the inoculation site.

Avian poxvirus infections, particularly in a flock situation, can remain latent for years.<sup>155,216</sup> Non-specific stress factors are associated with viral reactivation. It has been suggested that latent poxvirus infections (including vaccine strains) can be egg transmitted (at least in the chicken).<sup>155</sup> Fowlpoxvirus (including vaccine strains) is known to induce a mild immunodepression that potentiates secondary infections.<sup>25</sup>

### Clinical Disease and Pathology

Infections induced by poxvirus vary in clinical expression based on the virulence of the virus strain, the mode of transmission and the susceptibility of the host. The course of the disease is generally subacute, and it takes three to four weeks for an individual to recover. Flock outbreaks require two to three months to run their course. Clinically recognized symptoms include:

- **Cutaneous Form ("Dry Pox"):** The cutaneous form is the most common form of disease in many raptors and Passeriformes but not in Psittaciformes. Changes are characterized by papular lesions mainly on unfeathered skin around the eyes, beak, nares and distal to the tarsometatarsus. The interdigital webs are most frequently affected in waterfowl and the Shearwater. As lesions progress, papules change

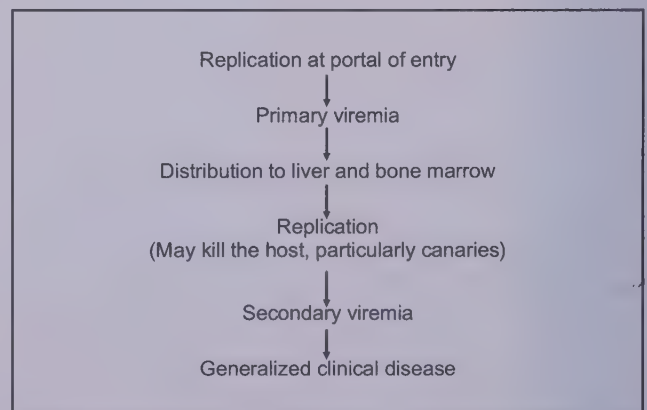


FIG 32.3 Two-cycle stage of infectivity of avian poxvirus infection.

TABLE 32.3 Survey of Avian Poxvirus

Virus	Host Spectrum	Virus	Host Spectrum
Fowlpox	Chicken, Blue Grouse, Sage-Grouse, Black Grouse, Ruffed Grouse, Prairie-Chicken	Bustardpox	Houbara Bustard, Great Bustard
Pigeonpox	Pigeon, Wood Pigeon, Chilean Pigeon, Collared Dove, Mourning Dove, Common Pheasant, Golden Pheasant	Murrepox	Murre = Guillemot
Turkeypox	Turkey, Ostrich, Humboldt Penguin	Shearwaterpox	Manx Shearwater
Canarypox	Canary and all the species that can be crossed with them	Shorebirdpox	Shore birds
Quailpox	Japanese Quail	Gullpox	Royal Tern
Juncopox	Dark-eyed Junco	Pelicanpox	No particular species given
Sparrowpox	House Sparrow	Penguinpox	Humbolt Penguin and related species
Starlingpox	Common Starling	Peacockpox	Indian Peafowl
Waterfowlpox	Mute Swan, Common Teal, Canada Goose, rarely other Anatiformes	Partridgepox	Common Partridge
Falconpox	Peregrine Falcon, Saker Falcon, Gyrfalcon, Golden Eagle, Red-tailed Hawk, Goshawk, Broad-winged Hawk	Colinusquailpox <sup>331</sup>	Bobwhite Quail, California Quail, Gambel's Quail
Agapornispox	Genus Agapornis	Guineafowlpox	No particular species given
Ostrichpox	Ostrich (probably related to turkeypox)	Swiftpox	Chimney Swift
Psittacinepox	South American parrots and parakeets	Woodpeckerpox	Common Flicker
Budgerigarpox	Budgerigar	Mynahpox <sup>331</sup>	Greater Hill Mynah
Rheapox	Greater Rhea	White-eyepox	Oriental White-eye, Silver-eye, Society Finch
Cranepox	Sandhill Crane	Creeperpox	Common Tree Creeper
		Song Sparrow Pox	Song Sparrow
		Field Sparrow Pox	Field Sparrow, Chipping Sparrow
		Thrushpox	Swainson's Thrush, Grey-cheeked Thrush, Wood Thrush
		Robin poxvirus	American Robin

TABLE 32.4 Cross-reactions of Poxviruses from Various Avian Species

		x axis									
		Pigeonpox	Fowlpox	Turkeypox	Canarypox	Quailpox	Waterfowlpox	Falconpox	Agapornispox	Psittacinepox	VACCINE
y axis	Pigeonpox	X	X								Homologous
	Fowlpox		X	X		X	X	X			Homologous, heterologous (pigeonpox)
	Turkeypox			X							Homologous, heterologous (fowlpox)
	Canarypox				X						Homologous
	Quailpox					X					Heterologous (fowlpox)
	Waterfowlpox		X				X				Heterologous (fowlpox)
	Falconpox	X	X	X				X			Heterologous (turkeypox)
	Agapornispox								X		None
	Psittacinepox									X	Homologous

Read as Pigeonpox (y axis) reacts with individual strain (x axis). Vaccines available are listed as homologous or heterologous.


color from yellowish to dark brown and develop into vesicles that open spontaneously, dry and form crusts (Figure 32.4). Spontaneous desquamation may require weeks and occurs without scarring in uncomplicated cases. Pigmented skin will frequently be discolored following an infection. Secondary bacterial or fungal colonization of lesions can substantially alter the appearance and progression of the disease.

In some cases, vesicles may not form and papules become hyperplastic, remaining in the periorbital region, nares, sinus infraorbitalis or on the tongue. These nodules may cause dyspnea (or asphyxia) or dysphagia depending on their location in the oral cavity. This progression is particularly common in the Bobwhite Quail, Canada Goose and Humboldt Penguin.<sup>228</sup> Periorbital lesions may cause blepharitis, symblepharon, keratitis, uveitis and ultimately ophthalmophthisis. Blue-fronted Amazons and Indian Hill Mynahs frequently develop ocular lesions (Color 32.9).<sup>208</sup> In domesticated male turkeys, papular infections may occur in the vent and pericloacal area without involving the cloacal mucosa or phallus. Infectivity levels may approach 75% of the flock. Virus transmission is suspected to occur during collection of semen for artificial insemination.<sup>17</sup>

- **Diphtheroid Form (“Wet Pox”):** Poxviral lesions that occur on the mucosa of the tongue, pharynx and larynx (rarely in the bronchi, esophagus and crop) cause fibrinous lesions that are grey to brown and caseous. Disturbing the exudates covering these lesions will induce severe bleeding. Multiple foci that coalesce may prevent a bird from swallowing food or result in dyspnea (or asphyxiation) if the larynx is involved. Oral lesions are frequently seen in Psittaciformes, Phasianiformes, Bobwhite Quail, some Columbiformes and Starlings.<sup>71</sup>

Cutaneous and diphtheroid lesions may occur in the same bird or either or both types of lesions may be noted in a flock outbreak. The septicemic form can also occur in conjunction with either cutaneous or diphtheritic forms of this disease.

- **Septicemic Form:** An acute onset of ruffled plumage, somnolence, cyanosis and anorexia characterize septicemic poxvirus infections. Most birds (mortality rates of 70-99%) die within three days of developing clinical signs. Cutaneous lesions are rare and ante-mortem documentation of infections is difficult. Septicemic infections are most common in canaries and canary and finch crosses. Canarypox frequently causes a desquamative pneumonia with occlusion of the air capillaries resulting in dyspnea. Clinical signs



**FIG 32.4** The cutaneous form of poxvirus can cause mild to severe nodular lesions on the unfeathered areas of the face, feet and legs of companion and free-ranging birds of most orders.

can last for months, and death may occur by exhaustion. It has been suggested but not proven that the massive cellular proliferation of interstitial mesenchyme induced by the virus can cause neoplastic changes.<sup>160</sup> Postmortem lesions in affected canaries include small pneumonic foci and hemorrhages, as well as fatty liver degeneration and jejunitis.

- **Tumors:** Some Avipoxvirus strains have oncogenic properties. Passeriformes and Columbiformes that survive infections are prone to tumor formation. These rapidly growing, wart-like efflorescent tumors of the skin are generally void of normal epithelium and hemorrhage readily when disturbed. Bollinger bodies are usually present in the neoplastic tissue but viable virus may not be demonstrated. Surgical removal of the skin tumors is an effective therapy.

### Specific Poxviral Symptoms

Psittacinepoxvirus infections have been documented in numerous South American parrots and parakeets. *Amazona* spp. and *Ara* spp. are most severely affected. Coryza and ocular lesions are frequently the dominating clinical signs in the genus *Amazona*; however, postmortem findings usually include diphtheroid enteritis or myocardial necrosis. Ocular lesions begin as dry areas on the eyelid that become crusty with exudate, sealing the lids closed. Secondary infections frequently cause keratitis, followed by ulceration, perforation of the globe, panophthalmia and finally ophthalmophthisis. When compared to other Psittaciformes, the unique clinical signs that occur in Amazon parrots are thought to be caused by virulence factors and not differences in virus strains.

Cutaneous lesions coupled with central nervous system signs (CNS) have been described in the Mourning Dove and falcons from the Persian Gulf. Cutaneous lesions in raptorial birds from most regions are relatively mild and self-limiting. In contrast, cutaneous lesions in Persian Gulf falcons were characterized by inflammatory necrotic processes that inhibited feeding. In some of these birds, CNS signs including somnolence, anorexia, opisthotonus, tonic-clonic cramps of the tail muscles and paresis and paralysis of the feet occurred. Histopathology revealed a distinct cribriform state, fresh hemorrhages in the white matter, mild inflammation of the meninges and no distinct inclusion bodies.<sup>212</sup> Mild CNS signs caused by poxvirus have also been described in turkeys.

Poxvirus infections in lovebirds usually cause cutaneous lesions although diphtheroid lesions ("wet pox") have also been described. Skin lesions rarely erupt, and the affected skin appears dehydrated and brownish in color. Ocular lesions characterized by serous conjunctivitis with heavy vascularization are common. The skin of the lower lid and of the facial angular palpebra may be yellow-brown with palpable induration. Serous exudate may become mucopurulent or fibrinous if secondary bacterial or fungal infections occur. Blepharosynechia caused by dried, crusty exudates can occur.<sup>223</sup> Morbidity and mortality in lovebirds may reach 75% of the at-risk population.

A budgerigar poxvirus was isolated from "feather dusters;" however, experimental infections with the isolated virus caused only a mild dyspnea of three to four days duration with no skin or feather lesions.

Poxvirus infections in 10- to 60-day-old ostrich chicks are characterized by small vesicles containing yellowish fluid on the eyelids and face. Lesions become dry and form a scale within six to ten days of forming. Diphtheroid lesions may also occur on the larynx, oral mucosa and the base of the tongue.

## Diagnosis

A definitive diagnosis of poxvirus can be made through the histologic demonstration of Bollinger bodies in biopsy samples of suspect lesions.

Culture is usually necessary to document the septicemic or coryzal forms of the disease. Cutaneous tumors are histologically characterized by a palisade-like arrangement of epithelial cords containing Bollinger bodies. Virus may be intermittently shed in the feces of asymptomatic carriers that may be identified by repeated culturing of feces. Serology is of little value in diagnosing poxvirus infections. Host recovery is primarily a function of cell-mediated immunity, and humoral antibodies are rarely and irregularly produced. If antibodies are present, they can be demonstrated by ID or VN.

## Control

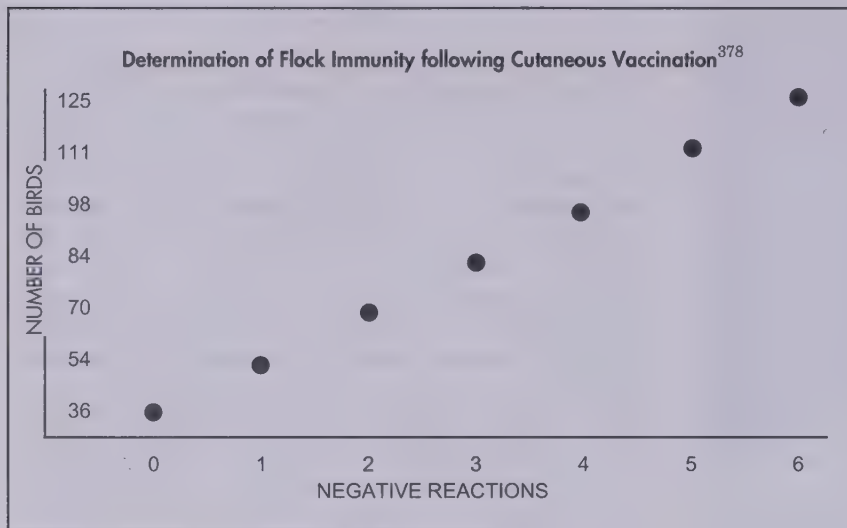
Birds that recover from pox should be protected from further disease for at least eight months, but many reports indicate shorter durations of immunity.<sup>216</sup> Cellular immunity is primarily responsible for recovery, and only small amounts of humoral antibodies are produced. Vaccination is the best method for controlling poxviral infections. Taxon-specific vaccines are available for only a few of the avian poxviruses (see Table 32.4 for the known cross immunities, which might be helpful for vaccination). Vaccines are commercially available for psittacine poxvirus, and should be considered to prevent infections in high-risk populations (imported birds, pet shop birds exposed to imported birds, areas with high densities of mosquitoes).<sup>431</sup> The manufacturer's guidelines for vaccination should be carefully followed. Canaries (and crosses) should be immunized with an appropriate vaccine. Only healthy flocks of these birds should be vaccinated. The use of a vaccine in an actively infected flock of canaries and other birds may result in recombination between the field and vaccine virus strains, inducing a severe disease in the entire flock. A new or freshly sterilized needle must be used for each bird to prevent the vaccination procedure from spreading the virus. Canaries should be immune for three to six months following vaccination.

Cutaneous vaccination (wingweb, feather follicle) is normally used in gallinaceous birds. This method of vaccination causes the formation of a typical pox lesion at the site of inoculation. These lesions correlate with immunity, and vaccinated birds should be inspected nine or ten days following vaccination to be certain that lesions have formed. The statistical portion of a group of birds that must properly serocon-

## CLINICAL APPLICATION

### Differential Diagnosis for Pox

Cutaneous Form	Diphtheroid Form
▪ Trauma	▪ Trichomoniasis
▪ <i>Trichophyton</i> spp.	▪ Candidiasis
▪ <i>Knemidokoptes</i> spp.	▪ Aspergillosis
	▪ Pigeon herpesvirus
	▪ Hypovitaminosis A
	▪ Amazon tracheitis virus



**FIG 32.5** Chart for determining the number of successful poxvirus vaccination reactions necessary to ensure flock immunity.

vert in order to impart flock immunity is illustrated in Figure 32.5. For example, the statistical limits for full flock protection for 54 birds is 1.

Fowlpox vaccine has been found to provide protection for ostriches. Vaccination at 10-14 days old is recommended in areas with high densities of mosquitoes.

## Herpesviridae

Herpesviridae are 120 and 220 nm diameter, double-stranded DNA viruses. Replication occurs in the nucleus. In some cells, an envelope may be obtained as the virus passes through the cytoplasmic membrane. Herpesvirus is not always restricted to a specific host or tissue. Crossing over a host- or tissue-specific barrier can alter the pathogenicity of the virus considerably. Herpesviruses primarily infect lymphatic tissue (either B- or T-cells), epithelial cells (skin, mucosa, hepatocytes) and nerve cells. Herpesviridae are considered a phylogenetic old group of viruses and as such are typically well adapted to their hosts. It should be expected that more avian herpesviridae strains will be isolated, adding further confusion to the already tangled classification system. As a group, herpesviruses generally induce latent and persistent infections (for weeks, months, years or lifetime) in an adapted host with irregular periods of recrudescence

and shedding. Latently infected birds can remain asymptomatic for years.

Concomitant disease, environmental stressors or hormonal changes have all been associated with induction of disease and activation of shedding. Reactivation does not always lead to clinical disease. Latently infected birds may shed virions via the feces, nasal discharge or desquamated skin (thereby endangering neighboring birds) without developing clinical signs. Virus can be transferred from cell to cell within an infected host with no invasion of the intracellular space, which protects the virus from humoral antibodies and antigen-processing cells. Because humoral antibodies decrease with time, indi-

rect diagnosis of herpesvirus infections by detection of antibodies may give false-negative results. Herpesviruses generally produce Cowdry type A intranuclear inclusion bodies in target cells.

The Herpesviridae family is divided into three subfamilies:

- $\alpha$ -Herpesvirinae (hemorrhagic lesions)
- $\beta$ -Herpesvirinae (necrotic lesions)
- $\tau$ -Herpesvirinae (lytic/neoplastic lesions)

Of the herpesvirus strains isolated from birds, only Marek's disease virus has been officially named. Table 32.5 shows the various herpesvirus taxons (it is questionable whether or not these have the status of a species), their respective subfamilies and the currently documented host spectrum. More detailed investigations may lead to further taxons, particularly with "Pacheco's disease-like" virus strains (the original Pacheco's disease virus has been lost). Table 32.6 shows the immunologic interactions.

### Transmission

Transmission routes for avian herpesviruses in companion birds have not been thoroughly investigated. Vertical transmission has been confirmed only with budgerigar herpesvirus and duck plague herpesvirus. Epizootics result in high concentrations of virus being released to the environment. Budgerigars infected experimentally with Pacheco's disease virus shed virus with the feces for 48 hours post-infection. Birds in direct contact (same enclosure) and within

TABLE 32.5 Survey of Avian Herpesviridae

DISEASE	SUSCEPTIBLE SPECIES
<b>Subfamily - <math>\alpha</math></b>	
Infectious laryngotracheitis	Chickens, pheasants, peafowl, canaries
Amazon tracheitis	Genus <i>Amazona</i> , Bourke's parrot
Duck Plague (syn. Duck virus enteritis)	Ducks, geese, swans
<b>Subfamily - <math>\beta</math></b>	
Pacheco's disease virus, "Pacheco's disease-like" virus	All Psittaciformes considered susceptible to varying degrees. At least three different serotypes. Host spectrum of two recent isolates is unknown.
Budgerigar herpesvirus	Budgerigar, pigeon, Double Yellow-headed Amazon
Pigeon inclusion body hepatitis (Esophagitis)	Pigeons, falcons, owls, budgerigar
Pigeon herpes encephalomyelitis	Pigeons
Falcon herpesvirus inclusion body hepatitis	Peregrine Falcon, Prairie Falcon, Common Kestrel, American Kestrel, Merlin, Red-necked Falcon Experimentally susceptible birds (see text)
Owl herpesvirus Hepatosplenitis infectiosa strigum	Eagle Owl, Great Horned Owl, Forest Eagle Owl, Snowy Owl, Striped Owl, Long-eared Owl, Little Owl, Tengmalm's Owl. Experimentally susceptible birds (see text)
Bald Eagle Herpesvirus	Bald Eagle
Lake Victoria Cormorant virus	Little Pied Cormorant
Crane inclusion body hepatitis	Demoiselle Crane, Crowned Crane, Whooping Crane, Sandhill Crane
Stork inclusion body hepatitis	Black Stork, White Stork
Colinus herpesvirus	Bobwhite Quail
<b>Subfamily - not classified</b>	
Marek's disease virus	Gallinaceous birds
Turkey herpesvirus	Gallinaceous birds
Canary herpesvirus	Canary
Gouldian Finch herpesvirus	Gouldian Finch
"Local" herpesvirus causing papilloma-like lesions on feet	Cockatoo, Macaw
Herpesvirus associated with papilloma	Conures

the same air space (adjacent enclosures) shed virus in the feces 48 hours later than the experimentally infected birds, suggesting an incubation period of 48 hours.

Fecal virus concentrations in clinically affected birds reached levels of up to  $10^6$  to  $10^7$  tissue culture infectious dose (TCID)<sub>50</sub>/g of feces. Experimentally in-

fectured birds that remained asymptomatic shed virus in the feces for approximately three weeks. Virus concentration in the lungs was  $10^6$  TCID<sub>50</sub>/g and in the liver was  $10^7$  TCID<sub>50</sub>/g.<sup>445</sup> These findings would suggest that the gastrointestinal tract (virus excreted from the liver) and the respiratory tract could be the primary points of entrance and release of the virus. Rapid spread through the aviary is common with virulent strains. The acute onset of clinical signs in several members of the flock may occur three to five days after the initial case is recognized.

### Pathogenesis

Necrotizing lesions in the parenchymatous organs are characteristic of virulent herpesvirus infections. Hemorrhagic lesions may occur with some strains in various companion and aviary birds. Details on the pathogenicity of herpesvirus infections, particularly with respect to host and tissue specificity, are scarce.

### Infectious Laryngotracheitis (ILT)

The herpesvirus responsible for ILT is distributed worldwide and appears to be serologically uniform. It is normally associated with acute disease of the respiratory tract, has a relatively small host spectrum and affects predominantly adult or growing birds older than eight weeks of age. Strain virulence varies widely from apathogenic to highly virulent. Several gallinaceous species (including peafowl and pheasants) have been found to be susceptible. The canary may also be susceptible to ILT as well as to its own herpesvirus strain (Kaleta EF, unpublished).<sup>87,227</sup>

Unlike other herpesviridae, natural transmission is exclusively aerogenic. The virus has an affinity for respiratory epithelium, and viremia does not develop. Occasionally, the virus is recovered from the esophagus and intestine.

### Clinical Disease, Pathology and Diagnosis

Virulent strains of ILT cause severe dyspnea, gasping and coughing-like sounds. During inspiration, loud wheezing sounds may occur with the neck extended and the head raised. Expectoration of bloody mucus is common, and infected birds shake their heads to expulse the mucus. In severe cases, bloody fibrin may be discharged. Affected birds become progressively weak and cyanotic and die from asphyxiation. Conjunctival and nasal discharge (mucoid, purulent, rarely hemorrhagic), increased lacrimation and swelling of the sinus infraorbitalis frequently occur. These may be the only clinical signs associated with less virulent strains. A similar clinical picture has

TABLE 32.6 Cross-reactions of Herpesviruses from Various Avian Species

	x axis											VACCINE	
	Marek's disease virus	ILT	Turkeyherpes	Duck plague	Pigeonherpes	Falconherpes	Owlherpes	Pacheco's disease virus	Amazon tracheitis	Budgerigarherpes	Lake Victoria Cormorant		Craneherpes
Marek's disease virus	X												Homologous
ILT		X											Heterologous (Turkeyherpes)
Turkeyherpes	X		X										Homologous
Duck plague				X									Homologous
Pigeonherpes					X	X	X						Homologous
Falconherpes					X	X	X						
Owlherpes					X	X	X						
Pacheco's disease virus								X					Homologous
Amazon tracheitis									X				
Budgerigarherpes										X			
Lake Victoria Cormorant											X		
Craneherpes												X	

Read as Marek's disease virus (y axis) reacts with individual strain (x axis). Vaccines available are listed as homologous or heterologous.

been described in canaries. Primary ILT infections may be complicated by bacteria or fungi that colonize the necrotic respiratory epithelium.

Depending on the chronicity of the infection, post-mortem findings may include hemorrhagic or fibrinous inflammation of a thickened mucosa of the larynx, trachea and in some cases, the bronchi. Caseous plugs or fibrinonecrotic pseudomembranes may also be noted.

Early histopathology lesions show ballooning degeneration of the mucosal epithelium followed by desquamation and inflammatory infiltrates as disease progression occurs. Prior to the desquamation stage, typical intranuclear eosinophilic inclusion bodies (Seifried's bodies) may be found. Air capillaries occluded with detritus and pneumonia have been occasionally reported.<sup>156</sup>

Immunodiffusion, VN, IF and ELISA can be used to identify isolates. In infected birds, precipitating antibodies can be demonstrated as early as eight to ten days post-infection. The occurrence of intranuclear inclusion bodies in the respiratory epithelial cell is

indicative, but confirmation of the disease requires virus isolation.

### Control

Cell-adapted vaccines that have a considerable residual pathogenicity and may induce vaccinal reaction are available for chickens. Pheasants are considered to be more susceptible to ILT than chickens. Particular caution should be exercised in vaccinating pheasants with these products (this warning is not normally stated in the product insert).<sup>67</sup> Vaccine strains may induce life-long latency with reactivation following immunosuppression events.

### Amazon Tracheitis (AT)

Chickens and the Common Pheasant are experimentally susceptible to the Amazon tracheitis virus. The disease that occurs in gallinaceous birds is mild in comparison to the clinical changes in Amazon parrots (see Color 22). The AT virus shares a serologic relationship with ILT and is considered a mutant of this virus. A herpesvirus pathologically similar to the ILT virus has been described in Bourke's Parrots; but no



comparisons between AT, ILT and this virus have been performed.<sup>169,245,433</sup>

The serologic relationship of AT and ILT allows the assumption (partly verified by clinical experience) that AT primarily infects the respiratory epithelium. The virus spreads quickly through an affected flock. Experimentally, clinical signs evolve within three to four days, and peracute death occurs within six days post-infection in the Green-cheeked Amazon.

### Clinical Disease, Pathology and Diagnosis

Varying species of Amazon parrots develop similar clinical disease following natural infection. Peracute, acute, subacute and chronic (up to nine months duration) infections have been described. Fibronecrotic ocular, nasal or oral discharges accompanied by open-beaked breathing, rales, rattles and coughing are common. As a rule, the disease in Bourke's Parrots takes a less florid course.

Postmortem findings include serous, mucoid or fibrous to pseudomembranous rhinitis, pharyngitis, laryngitis and tracheitis. A hemorrhagic inflammation is also possible. Affected birds typically die from asphyxiation caused by blockage of the trachea with fibronecrotic debris. Bronchopneumonia, conjunctivitis, blepharitis, glossitis, ingluveitis and air sacculitis may occur as a result of secondary bacterial and fungal invaders that take advantage of an immunocompromised host.

Histopathologic lesions resemble those induced by ILT. Demonstration of intranuclear inclusion bodies is possible only early in the disease process prior to exfoliation of the affected mucosal epithelium. Pharyngeal or laryngeal swabs submitted for culture are suitable for confirming a diagnosis.

### ■ Duck Plague (DP — syn. Duck Virus Enteritis)

Duck plague virus seems to be distributed worldwide with the exception of Australia, and has been documented in free-ranging and captive Anatidae (ducks, geese and swans). DP is caused by a serologic uniform herpesvirus that does not cross-react with other avian Herpesviridae. The disease is characterized by damage to the endothelial lining of vessels resulting in tissue hemorrhage, gastrointestinal bleeding and free blood in body cavities.

Susceptibility varies considerably according to the host species and virulence of the virus strain. Mallards and to a lesser extent, the Common Teal and the Common Pintail, are relatively resistant; however,

they do produce antibodies post-exposure and are considered to be important reservoirs of the virus (particularly Mallards). Other Anatidae are considered relatively susceptible.<sup>427</sup>

Intermittent virus shedding in clinically healthy birds has been noted for up to five years. Outbreaks in zoological collections have been linked to free-ranging waterfowl that have access to exhibit ponds. Once infected, the captive birds can maintain the infection in the absence of an open body of water. Vertical transmission occurs, but does not seem to play an important epizootiologic role, perhaps because egg production is severely reduced in clinically affected flocks. Virus stability in water is temperature-dependent (4°C for approximately two months, 22°C for about one month).

### Pathogenesis

The DP virus has an affinity for the reticuloendothelial system, propagates preferentially in undifferentiated epithelial cells and causes the destruction of B- and T-lymphocytes. Transovarially infected ducklings die during the first two weeks of life. Survivors are clinically healthy, partially immunotolerant and excrete large quantities of virus up to the sixth month of life. Although DP may occur clinically in only a single individual within a flock, it can also cause the death of 100% of the exposed birds. Climatic factors (heat, cold) are epizootiologically important. Birds (Mallards) with host-adapted strains serve as asymptomatic reservoirs and rarely develop clinical disease, but expose highly susceptible non-indigenous waterfowl to the virus.

### Clinical Disease, Pathology and Diagnosis

Peracute death may occur without clinical signs. A more acute course is characterized by polydipsia, photophobia, nasal discharge, serous to hemorrhagic lacrimation, anorexia, cyanosis and greenish, watery (occasionally hemorrhagic) diarrhea. Mature birds generally have a more prolonged course of disease. Many birds swim in circles and are unable to fly. Paralysis of the phallus, convulsions or tremor of the neck and head muscles are occasionally noted. Affected free-ranging waterfowl may sit on the water with neck and head in extreme extension.

Postmortem lesions differ according to species susceptibility, degree of virus exposure and virulence of the infecting strain. Suggestive lesions include petechia and ecchymosis on the epicardium (see Color 14), serous membranes and the large blood vessels of the body; annular hemorrhagic bands on the mucosa

of the intestinal tract; necrosis in the cloacal wall and long parallel diphtheroid eruptions or confluent necrosis in the lower third of the esophagus. Nonspecific lesions include necrotic foci in the liver and hemorrhage of developing egg follicles.<sup>234</sup>

Histopathologic examination reveals eosinophilic intranuclear inclusion bodies (Cowdry A type) in hepatocytes, bile duct epithelial cells and the epithelial cells of the cloacal and esophageal mucosa. In the Muscovy Duck, erosions may be observed in the transition zone between the proventriculus and ventriculus. A definitive diagnosis requires virus isolation. VN is recommended for virus identification and to demonstrate antibodies in the host.

### ■ Pacheco's Disease Virus (PDV)

Pacheco's disease virus (PDV) has been described all over the world and is associated with a systemic, in many instances acute, disease that affects the liver, spleen and kidneys.

This disease was first described in parrots from Brazil.<sup>301,380</sup> The affected birds died after eight days of somnolence and ruffled plumage.

Since its initial description, there have been numerous cases of a Pacheco's-like disease induced by a herpesvirus. Susceptibility to PDV seems to be restricted to the Psittaciformes. Naturally susceptible hosts include macaws, Amazon parrots, conures, African Grey Parrots, *Poicephalus* spp., lovebirds, lorries of the genus *Eos*, parakeets of the genus *Psittacula*, cockatoos, budgerigars, King Parrots and cockatiels. Patagonian and Nanday Conures are frequently discussed as asymptomatic carriers that intermittently shed virus; however, any bird that recovers from a PDV infection should be considered a carrier.

There are indications that inclusion body hepatitis in Psittaciformes (described and diagnosed as Pacheco's disease) is caused by several herpesviruses that are serologically distinct from the "original" virus.<sup>38</sup> Two serologically distinct herpesviruses (isolated from Blue-fronted Amazon Parrots, African Grey Parrots and a Moustache Parakeet) that induced lesions characteristic of Pacheco's disease have been described.<sup>225</sup> Further investigations are necessary to clarify the relationship between these antigenically distinct strains and to determine the efficacy of currently available monovalent PDV vaccines.

### Clinical Disease


PDV generally induces an acute, nonspecific disease characterized by somnolence, lethargy, anorexia, ruffled plumage and intermittent diarrhea, polyuria and polydipsia (Figure 32.6). Biliverdin staining of liquefied feces and urates is indicative of the severe liver necrosis caused by the virus (see Color 8). Sinusitis, hemorrhagic diarrhea, conjunctivitis and convulsions or tremors in the neck, wings and legs have occasionally been described. Many outbreaks are linked to a stressful event such as a change in the environment or the onset of breeding season. Stress factors are thought to induce recrudescence in asymptomatic carriers resulting in virus excretion and an epornitic in exposed birds. In other cases, only a single bird may suddenly die while the rest of the flock remains unaffected. The intensity and course of the clinical disease varies widely according to species susceptibility. Some macaws and *Amazona* spp. are considered highly susceptible, while others in the same group appear to be relatively resistant. Old World Psittaciformes appear to be more resistant to PDV than do New World Psittaciformes.

### Pathology and Diagnosis

With peracute or acute disease, birds are in generally good condition at the time of death. A massively swollen, tawny, light-red or greenish-colored liver with subserosal hemorrhages or necrotic foci is common (see Color 20). The spleen and kidneys are also distinctly swollen, and the intestinal mucosa may be hyperemic (Figure 32.7). Histologic lesions include congestion, hemorrhage and coagulative necrosis of the hepatocytes. The term "inclusion body hepatitis" is often misleading, because birds frequently die from massive liver necrosis before an inflammatory reaction occurs. Intranuclear eosinophilic inclusion bodies may be noted in hepatocytes (particularly around necrotic foci), bile duct and renal tubular epithelial cells and in splenic reticular cells. Virus identification is possible by VN, ELISA and IF. Precipitation with the ID is useful as a screening test. The use of monoclonal antibodies allows differentiation between the various PDV serotypes. Antibodies to PDV are difficult to demonstrate and provide no clinically relevant information.

### Treatment

Natural immunity can be induced with paramunity inducers. Acyclovir has been shown to be effective for treating at least some strains of PDV. The recommended treatment regimen is to administer the water-soluble powder at a dose of 80 mg/kg TID by




**FIG 32.6** The clinical course of Pacheco's disease virus (PDV) depends on the host species. Some birds die peracutely with no clinical signs of disease, while others die following a brief period of depression, ruffled plumage, diarrhea and polyuria. Other species may survive an infection and become asymptomatic carriers. This infected bird died shortly after presentation.

gavage tube. Severe muscle necrosis will occur if the intravenous product is injected IM. If gavage administration is not practical, the powdered acyclovir can be added to the food at a dose as high as 240 mg/kg.<sup>294</sup> Treatment is most effective if started before clinical signs develop. Acyclovir may cause considerable nephrotoxicity, and this drug should be administered carefully in patients with nephropathies. The role that acyclovir may play in inducing asymptomatic carriers has not been determined.

#### Control

An inactivated PDV vaccine is commercially available in the USA. There have been frequent reports of granulomas and paralysis following the use of this vaccine, particularly in cockatoos (Figure 32.8), African Grey Parrots and Blue and Gold Macaws.<sup>24,103,159,261,323,373</sup> The vaccine is intended for use in high risk patients (import stations, pet shops that handle imported birds). The instructions for use provided by the manufacturer should be carefully followed.



**FIG 32.7** A young, recently imported female Blue and Gold Macaw was presented for anorexia, yellow discoloration of the stool and ruffled plumage. A doughy mass was palpable in the caudal abdomen. Abnormal clinical pathology findings included WBC=4000, AST=1200, LDH=980. Radiographs indicated an enlarged liver that occupied much of the abdomen and displaced the proventriculus dorsally and caused the caudal border of the heart to appear indistinct. The bird died shortly after presentation. At necropsy, the liver was enlarged (three to four times normal), mottled, red and had numerous subserosal hemorrhages. Histopathology confirmed the presence of hepatocellular necrosis and intranuclear inclusion bodies suggestive of Pacheco's disease virus.

### ■ Budgerigar Herpesvirus

A vertically transmitted herpesvirus has been isolated from the feathers of budgerigars. The virus is occasionally recoverable from parenchymatous organs, blood or feces. Decreased egg hatchability is the principal problem associated with this virus, which is serologically related to the pigeon herpesvirus, but not to Pacheco's disease virus or related strains.

Most isolates of this virus have been from so-called "feather dusters." It is unknown what role, if any, herpesvirus plays in this genetic problem of English Show Budgerigars.


A herpes-like virus was reported in a Yellow-crowned Amazon that died acutely following exposure to budgerigars. At necropsy, the thickened crop mucosa showed parakeratotic lesions with basophilic intranuclear inclusion bodies in the epithelial cells. Cells of the exogenic pancreas revealed degeneration accompanied by the formation of syncytial cells. The peripancreatic fat was necrotic. In addition, chronic hepatitis and proliferation of reticular cells in the spleen were noted. Intranuclear virus particles were present in the crop and pancreas, and enveloped virions with spiked outer membranes (unlike Pacheco's disease virus or ILT virus) were present in the cytoplasm.<sup>245</sup>

Virus isolated in cell culture can be identified using antibodies in the VN or ID tests. In infected flocks of English Standards, breeding should be interrupted to allow hens to develop immunity, which should provide some protection for the chicks.

### ■ Inclusion Body Hepatitis in Pigeons (Infectious Esophagitis)

This herpesvirus has a worldwide distribution, and various strains show morphologic, pathogenic and serologic differences (plaque formation in CEF). Small plaque variants are less pathogenic or apathogenic.<sup>207</sup> The large and small plaque-forming viruses may be two different strains.<sup>206</sup> This virus is serologically related to the falcon and owl herpesviruses. The host spectrum of this virus is uncertain, but pigeons and budgerigars are known to be susceptible.<sup>417</sup> Falcons and owls might also be susceptible and could be infected through contact with diseased pigeons. The susceptibility of falcons and owls varies with the species.

Squabs 4 to 16 weeks of age are most susceptible, but any age bird can be infected, particularly if immuno-



**FIG 32.8** Some species of birds (particularly cockatoos) have been found to develop severe granulomas following vaccination with the killed oil-emulsion Pacheco's disease virus vaccine. Birds vaccinated subcutaneously with the oil-emulsion portion of this vaccine were found to develop granulomas suggesting that it is the vaccine adjuvant and not the viral protein that is inducing an unacceptable reaction. Occasionally, birds injected IM (bottom) with the Pacheco's disease virus vaccine can develop severe granulomas and muscle necrosis that require surgical debridement.

suppressed. Annual outbreaks have been described in some flocks. Transmission can occur through contact with contaminated feed or water, through direct contact between mates and through parenteral feeding of offspring.

### Clinical Disease, Pathology and Diagnosis

In the flock, morbidity is typically 50%, with a 10 to 15% mortality rate. Serous rhinitis and conjunctivitis are usually the first clinical signs of disease. The nares become occluded, and a grayish-mucoid exudate causes dyspnea. Paresis of the third eyelid is possible. Small diphtheroid foci on the pharynx and larynx (which develop into so-called sialoliths) are indicative of an active infection.<sup>450</sup> Mild diarrhea, anorexia, vomiting and polydipsia may also occur. Affected squabs may die within one to two weeks or slowly recover. Tremors, ataxia and an inability to fly may occur in some birds.<sup>418</sup> Recurring trichomoniasis is common in flocks with endemic herpesvirus.

Small, grayish-greenish diphtheroid foci on the mucosa of the upper airways, pharynx and occasionally the crop and intestine are characteristic necropsy findings. Air sacculitis, peritonitis, necrotic hepatitis and occasionally necrosis in the kidney, pancreas and spleen are observed. This virus may also induce only necrotic hepatitis.

Histopathology reveals necrosis (liver, kidney, pancreas, spleen) and desquamative lesions of epithelial cells (pharynx, larynx, esophagus). Cells around these lesions contain intranuclear eosinophilic and basophilic inclusion bodies.

The formation of sialoliths is suggestive of an infection, as are high morbidity rates in offspring. The virus may be identified by ID, but strain differentiation requires VN, ELISA or electrophoresis.

### Contagious Paralysis of Pigeons (PHEV - Pigeon Herpes Encephalomyelitis Virus)

Pigeon herpes encephalomyelitis virus was first described in Iraq.<sup>277</sup> The distribution of the virus is undetermined. Paramyxovirus-1-pigeon was also present in the initial isolate, and it is uncertain which of the central nervous system signs described were caused by herpesvirus and which were caused by paramyxovirus. Some of the reported neurologic lesions were atypical for those described with paramyxovirus-1-pigeon.<sup>196,333</sup> In Germany, two strains of herpesvirus have been isolated from the brains of pigeons suffering from neurologic disease (Schneeganss D, unpublished).

### Clinical Disease, Pathology and Diagnosis

Affected birds develop progressive, chronic central nervous signs that start with incoordination and end with an inability to fly and paralysis. Circling and torticollis, which were described in the initial report of the virus<sup>217</sup> have not been observed by other investigators (Schneeganss D, unpublished).

Gross necropsy findings are similar to those described with paramyxovirus-1-pigeon. The meningoencephalitis that is common with paramyxovirus has not been described with PHEV. The Purkinje cells of the cerebellum showed degeneration, lysis and eosinophilic intranuclear inclusion bodies. Paramyxovirus-1-pigeon, salmonellosis and listeriosis are the main rule-outs. A study to describe the pathohistology of PHEV is necessary.

## CLINICAL APPLICATION

### Differential Diagnosis for Avian Herpesviruses

#### Infectious Laryngotracheitis

- Infectious coryza (Haemophilus paragallinarium)
- Mycoplasmosis
- Poxvirus (diphtheroid form)
- Syngamus spp.

#### Amazon Tracheitis

- Most respiratory diseases
- Avianpox (diphtheroid form)
- Newcastle disease
- Chlamydiosis
- Influenza A virus
- Candida
- Aspergillosis
- Trichomoniasis
- Syngamus spp.
- Hypovitaminosis A

#### Pacheco's Disease Virus

- Bacterial hepatitis
- Chlamydiosis
- Lead toxicosis
- Salmonellosis
- Paramyxovirus

#### Inclusion Body Hepatitis of Cranes

- Visceral coccidiosis

#### Duck Plague Virus

- Macroscopic lesions characteristic
- Influenza virus
- Duck hepatitis virus (ducklings)

#### Pigeon Herpesvirus

- Poxvirus (diphtheritic form)
- Trichomoniasis
- Chlamydiosis (respiratory form)
- Salmonellosis (liver form)

#### Pigeon Infectious Paralysis

- Paramyxovirus-1-pigeon
- CNS form of salmonellosis
- Listeriosis

#### Falcon Inclusion Body Hepatitis

- Many other infectious and non-infectious liver lesions

#### Hepatosplenitis Infectiosa Strigum

- Mycobacteriosis
- Trichomoniasis
- Candidiasis

### Inclusion Body Hepatitis of the Falcon (FHV - Falcon Herpesvirus)

Falcon herpesvirus seems to be distributed in the northern hemisphere of the Old and New Worlds. The host spectrum is not fully known. There is a close antigenic relationship between FHV and the pigeon and owl herpesviruses. These three viral taxons show a certain independence, particularly with respect to host spectrum and clinical signs (see Table 32.5). Field cases of falcon herpesvirus have been described in the Peregrine Falcon, Common Kestrel, Merlin, Red-necked Falcon, Prairie Falcon and American Kestrel. Experimentally, the African Collared Dove, immature budgerigar, Striated Heron, Lone-eared Owl, Screech Owl, Great Horned Owl and Muscovy Duck have been shown to be susceptible.<sup>254</sup>

The falcon herpesvirus has an affinity for reticuloendothelial cells and hepatocytes. There is no confirmed information on the natural transmission of this virus. It has been suggested that the consumption of infected prey may be involved in transmission. There is no evidence that inhalation of the virus is involved in natural transmission.<sup>131</sup>

#### Clinical Disease, Pathology and Diagnosis

Generally, an acute disease develops with mild to severe depression, weakness and anorexia. Mortality may approach 100%.<sup>131</sup> At necropsy, light-to-tan colored necrotic foci are seen in the liver, spleen, bone marrow and lymph follicles of the intestine.

Histopathology shows focal or disseminated degeneration and necrosis in the liver, pancreas, lung, kidney and brain. The adrenal, thyroid and parathyroid glands, as well as the ovary, testes and thymus may also be affected. Necrotic foci may be surrounded by parenchymatous cells containing intranuclear (mainly eosinophilic) inclusion bodies. Inflammatory cellular reactions are rare due to the acute nature of the disease and the rapid death of the host.

The clinical signs and gross findings of falcon herpesvirus are nonspecific. Because of the close serologic relationship between pigeon herpesvirus and owl herpesvirus, serologic identification is not possible. Separation of specific proteins using SDS-gel-electrophoresis can be used to differentiate between strains.

### Hepatosplenitis Infectiosa Strigum (OHV - Owl Herpesvirus)

Owl herpesvirus has a limited host spectrum and occurs in free-ranging and captive owls.<sup>138</sup> The virus

is distributed across Europe, Asia and the United States. Natural infections are mainly seen in owls with yellow- or orange-colored irises including: Eagle Owl, Great Horned Owl, Striped Owl, Long-eared Owl, Snowy Owl, Little Owl, Tengmalm's Owl and Forest Eagle Owl.

Antibodies against OHV have been demonstrated in 24 species of Strigiformes.<sup>205</sup> The American Kestrel, Common Kestrel, Turtle Dove and African Collared Dove can be infected experimentally. Because OHV is serologically related to the pigeon herpesvirus and the falcon herpesvirus, the currently recognized host spectrum may be incomplete.

In contrast to other avian Herpesviridae, OHV affects both epithelial and mesenchymal cells. Virus is excreted from the oral cavity and in urine.<sup>371</sup> Consumption of infected prey should be considered a potential method of transmission. Infection does not take place via the tracheal mucosa. Owl herpesvirus antigen has been demonstrated within the epithelium of feather follicles. Compared with other avian Herpesviridae, the incubation period for OHV is prolonged (seven to ten days) rather than the more typical three to five days.

#### Clinical Disease and Pathology

Clinical signs including depression, anorexia and weakness may last for two to five days. Infrequently, yellowish nodules the size of millet seeds may develop on the pharyngeal mucosa.<sup>49</sup> These lesions may be secondarily infected with *Trichomonas* spp. In captivity, mortality rates may approach 100%. The demonstration of antibodies in free-ranging owls indicates that birds can survive infections. Leukopenia has been described during active infections.

The necropsy reveals numerous necrotic foci in the liver, spleen and bone marrow.<sup>49</sup> Other suggestive lesions include diphtheroid (frequent) and hemorrhagic (rare) enteritis, diphtheroid stomatitis, esophagitis, proventriculitis and laryngitis (less frequent) as well as single necrotic foci in the lungs and kidneys. Moniliform necrotic nodules may be found along the jugular vein, probably emanating from the remains of thymic tissue.

Necrotic foci in various organs are characterized by a basophilic center with a zone of nuclear debris surrounded by eosinophilic necrotic material. Intranuclear eosinophilic inclusion bodies can be found adjacent to these necrotic areas. Inclusion bodies are rare in natural infections. Amyloidosis has been described in chronic cases.

### Diagnosis

The necrotic foci in the liver, spleen, intestine and along the jugular vein should be differentiated from those caused by mycobacteriosis. Although the morphology is strikingly similar, the foci caused by herpesvirus are soft and are not demarcated from the surrounding tissue. In comparison, mycobacteria-induced tubercles are caseous, crumbly and normally well demarcated. Trichomoniasis-induced diphtheroid pharyngitis appears similar to that caused by herpesvirus. Additionally, *Trichomonas* spp. and fungi can be secondary invaders of pharyngeal lesions induced by herpesvirus.

Apparently, owl herpesvirus cannot be transmitted free of cells.<sup>361</sup> This finding would suggest that OHV is a separate taxon from PHV and FHV. It also implies that tissues submitted for virus isolation must contain intact cells (shipped at 4°C as quickly as possible). The bone marrow of the femur is the best tissue to submit for virus isolation.<sup>371</sup> Differentiation of OHV, FHV and PHV requires electrophoresis to delineate strain-specific proteins.

### Eagle Herpesvirus

A herpesvirus was isolated from a clinically healthy, free-ranging Bald Eagle nestling.<sup>76</sup> The strain is not related to DPV, herpes simplex, FHV or crane herpesvirus. Eagle herpesvirus was also recovered from a South American eagle (probably a Grey Eagle-Buzzard) that developed lesions similar to those described in owls and falcons.<sup>206</sup>

### Lake Victoria Cormorant Herpesvirus

A herpesvirus has been isolated from the blood of a clinically healthy Little Pied Cormorant nestling. This virus was not serologically related to other avian Herpesviridae.<sup>102</sup> Attempts to recover this virus from other Australian birds in the same area were unsuccessful, and it has been suggested that this herpesvirus has a very narrow host range. Chickens, pigeons and budgerigars experimentally infected with the virus did not develop pathologic lesions.

### Inclusion Body Disease of Cranes (Crane Herpesvirus)

Crane herpesvirus is probably distributed worldwide (except Australia). There is evidence that infections can be latent and persist for years. To date, disease has been described only in captive birds. Birds maintained by the International Crane Foundation were

found to have antibodies to the virus three years before a disease outbreak occurred.<sup>77</sup> Morbidity and mortality were described only in some parts of the premises, and serologic data indicated that susceptibility varied among crane species. The natural host spectrum includes Sandhill, Manchurian, Blue, Hooded, Demoiselle and Crowned Cranes. The Sandhill and Blue Cranes seem to be most susceptible, followed by the Manchurian and Hooded Cranes. The Sarus and Common Cranes seroconverted following infection without developing signs of disease. White-naped Cranes, Demoiselle Cranes and Brolga survived exposure but generally did not seroconvert.<sup>76</sup>

The crane herpesvirus is considered to be a  $\beta$ -herpesvirus with a relatively narrow host spectrum and cytopathology characterized by slowly progressive, lytic lesions within enlarged infected cells and Cowdry type A intranuclear inclusion bodies.<sup>347</sup> Serologically, the crane herpesvirus is closely related to or identical to the Bobwhite Quail herpesvirus.<sup>97</sup>

### Clinical Disease and Pathology

Clinical disease is usually acute, with birds seeking solitude and developing depression, anorexia and diarrhea. At necropsy, the liver, spleen and kidneys are swollen with miliary necrotic foci. Diphtheroid layers develop on the mucosa of the oral cavity, choanal slit and esophagus. Striated hemorrhages can be observed in the upper part of the esophagus. The mucosa of the duodenum, jejunum and colon may be covered with a layer of diphtheroid material. Histopathology reveals necrotic foci, which react basophilic or eosinophilic with hematoxylin and eosin (H & E) stain. Intranuclear eosinophilic inclusion bodies are rare.

Visceral coccidiosis may also cause swelling of various parenchymatous organs in cranes. Giemsa staining can be used to delineate merozoites in infected hosts.

### Inclusion Body Hepatitis of Bobwhite Quail (Colinus Herpesvirus)

A herpesvirus was initially isolated from Bobwhite Quail.<sup>200</sup> Nothing is known about the distribution of the virus, but because the Bobwhite Quail is a New World species, the virus would be expected to occur in the United States and Canada. The virus is serologically related to the crane herpesvirus.

### Clinical Disease and Pathology

Clinical signs are nonspecific and include ruffled plumage, diarrhea and anorexia. The disease takes an acute course, and death occurs within two to three days of developing clinical signs. None of the birds affected by this virus have been over four weeks old. Gross lesions include hepatomegaly and splenomegaly, both of which contain numerous small yellowish foci. Catarrhal enteritis and ulcers were evident in the jejunum, and a *Clostridium* sp. was isolated from birds with intestinal lesions. Histopathology revealed multiple necrotic hepatic foci with rod-like bacteria at the center, as well as perivascular lymphocytic infiltrates. Lesions described in quail vary from those caused by other members of the avian Herpesviridae. It is thus questionable whether or not infection with a *Clostridium* sp. has caused most of the tissue changes and activation of a latent herpesvirus infection. Conversely, the herpesvirus infection could have triggered the *Clostridium* sp. infection.

#### Inclusion Body Hepatitis of Storks (Stork Herpesvirus)

A pathogenic herpesvirus that affects White and Black Storks has been described.<sup>198,201</sup> Infections have been described only in Germany, but the virus should be expected to occur in Europe, populated regions of Asia and the African winter quarters. The host spectrum is thought to be restricted, but investigations are incomplete.

The virus is serologically unrelated to other avian Herpesviridae, is cell-associated and can be demonstrated in leukocytes in the presence of humoral antibodies. Cell-free virus can be demonstrated as well. All attempts to recover virus from the feather follicles of White and Black Storks have failed. In addition, attempts to isolate virus from the pharyngeal and cloacal mucosa of viremic storks were not successful (Kaleta EF, unpublished). Studies involving humoral antibodies have indicated that titers vary from negative to positive, year to year and among individuals.

Clinical signs are limited to sudden death. Pathologic lesions consist of small yellowish-white foci in the liver, spleen and bone marrow. There may also be diphtheroid changes in the mucosa of the esophagus, choana and larynx.

#### Marek's Disease Virus (MDV)

This agent, officially named the thalymphokryptovirus, is distributed worldwide and is the best known avian herpesvirus because of its importance to the poultry industry and its use in comparative oncology research. Marek's disease virus has been shown to have direct and indirect routes of transmission.<sup>53,176,312</sup> Marek's disease is characterized by lymphocytic proliferation in the peripheral nerves that results in varying degrees of paresis and paralysis. The disease is common in gallinaceous species, and suggestive lesions have been reported in Great Horned Owls, ducks, a kestrel and swans. Tumors associated with MDV may occur in any organ but are commonly found in the viscera, skin, eyes, muscle and bones. Enlarged peripheral nerves are a common postmortem finding.

In a Great Horned Owl, lesions suggestive of MDV were associated with paralysis, ataxia, emaciation and formation of enlarged gray-white masses in the splenic, renal, pancreatic and mesenteric tissues. The sciatic nerves were two to three times normal size. Lymphoblastic cells could be identified in the liver, kidney, pancreas, mesentery, spleen and sciatic nerves.<sup>154a</sup>

Marek's disease virus antigen was demonstrated by an agarose gel diffusion test in the spinal cord and pudendal nerves in a toucan that exhibited a chronic slowly progressive peripheral ataxia with kidney enlargement. The histologic lesions that occurred in this bird were consistent with Marek's disease virus, but a virus could not be isolated (Latimer KS, unpublished).

#### Gouldian Finch Herpesvirus

An uncharacterized virus suggestive of herpesvirus has been identified by electron microscopy in clinically affected Crimson Finches, Red-faced Waxbills and Zebra Finches.<sup>74</sup> In a mixed species aviary, Gouldian Finches died from lesions caused by a herpesvirus, while other Passeriformes in the collection remained unaffected. Mortality in Gouldian Finch flocks may reach 70% of the birds at risk.<sup>353,369</sup>

### Clinical Disease and Pathology

Listless birds with ruffled plumage develop increasingly severe dyspnea with minimal discharge from the nostrils. Swollen and edematous eyelids and conjunctivae may be sealed with crusts in the lid cleft. Despite severe dyspnea, affected birds may continue



to try to eat, although sometimes unsuccessfully. Death is common five to ten days following the first clinical signs and all Gouldian Finches from one aviary died over a period of two weeks.<sup>74</sup>

Necropsy findings included severe emaciation even though some affected birds continued to eat. Swollen eyelids and conjunctivae, serous discharge in the conjunctival sacs and fibrinoid thickening of the air sacs were the only characteristic findings. Apart from congestion, parenchymal organs appeared normal.


In one outbreak, hyperemic foci and fibrinous deposits were visible on the serosa of the jejunum, the lumen of which was filled with melena-like contents in one bird. The oviduct contained a yellowish fluid with desquamated epithelial cells.<sup>74</sup>

Histopathology is characterized by ballooning degeneration and detachment from the basal membrane of conjunctival and respiratory epithelial cells. The epithelium may be thickened by increased numbers of the ballooning cells. Large, homogeneous, either basophilic or eosinophilic intranuclear inclusion bodies are characteristic. The submucosa may be congested and contain massive diffuse perivascular infiltration with mononuclear cells and few heterophils. The lower respiratory tract and the trachea may have similar but less severe lesions. Cilia may be damaged in affected tracheal mucosa. Hepatocytes are rarely affected.<sup>74</sup>

### Other Herpesviruses

A herpesvirus has been described in lovebirds with malformed feathers, but the involvement of this virus in causing the lesions has not been determined.<sup>137</sup>

Papilloma-like lesions thought to be caused by a herpesvirus have been described on the feet of cockatoos (Figure 32.9). Affected birds are usually clinically normal except for the wart-like growths on their feet. Histopathology is consistent with squamous papillomas. The nuclei of affected epithelial cells are homogeneously basophilic with a smudged appearance, and the superficial cells are vacuolated. Electron microscopy has been used to demonstrate virus particles suggestive of herpesvirus. A herpes-like virus was observed by electron microscopy in association with a cloacal papilloma in an Orange-fronted Conure.<sup>118</sup> Squamous papillomas are common with poxvirus and papillomavirus but rather unusual for herpesvirus infections.



**FIG 32.9** An adult Moluccan Cockatoo was presented for evaluation of progressive feather dysplasia. The bird was positive for PBFV virus by feather biopsy (intranuclear and intracytoplasmic inclusion bodies) and by DNA probe (whole blood). The bird also had proliferative (wart-like) growths on several digits. Electron microscopy revealed virus particles suggestive of herpesvirus.

## Papovaviridae

The Papovaviridae family of viruses consists of two genera, which vary in virion size, genome size and organization. These two genera are *Papillomavirus*, which is characterized by a 55 nm diameter nonenveloped icosahedral virion with a 7.5-8 kbp circular double strand DNA genome, and *Polyomavirus*, characterized by a 40-50 nm icosahedral nonenveloped virion with a 4.8-5.5 kbp circular double strand DNA genome.<sup>93</sup>

As a group, the papovaviruses tend to cause persistent infections that become active following stressful events.<sup>428</sup> Papillomaviruses are generally associated with the formation of benign skin tumors (warts).<sup>190,298</sup> The first acute, generalized infection associated with a polyomavirus was described in young psittacine birds and was called budgerigar fledgling disease (BFD).<sup>38,39,44</sup> A similar virus has been shown to be associated with high levels of morbidity and mortality in finches (Estrildidae) and in a number of different genera of Psittaciformes. The acute nature of avian polyomavirus infections is most unusual for Papovaviridae, the members of which are classically associated with nonpathogenic subclinical infections and chronic diseases characterized by tumor formation.<sup>428</sup>

## Papillomavirus

Papillomavirus has been associated with the formation of benign epithelial tumors (papillomata) on the skin and epithelial mucosa of many mammalian species. The papillomaviruses that infect mammals appear to be species-specific.

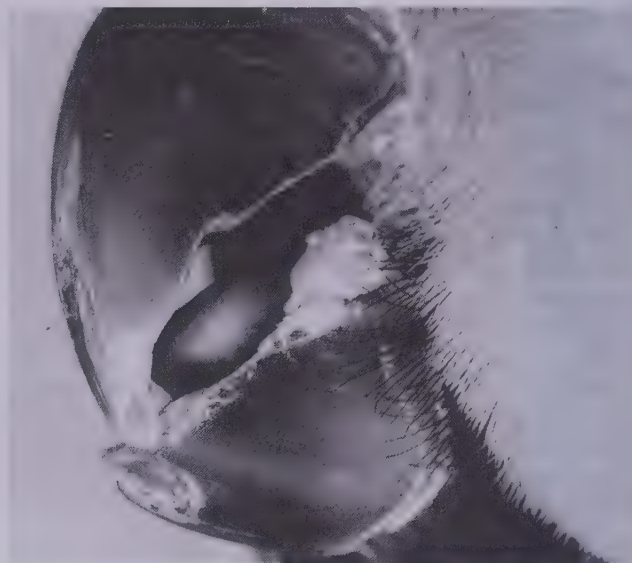Papillomavirus has been associated with proliferative growths on the unfeathered skin of some birds. In addition, clinical and pathologic lesions suggestive of those caused by papillomavirus have been described at various locations along the gastrointestinal tract, particularly in the cloaca (see Color 19). To date, no virus has been associated with these papilloma-like growths in the gastrointestinal tract of Psittaciformes.

### Clinical Features

The first demonstration of a papovavirus in a non-mammalian species involved the recovery and characterization of a papillomavirus from proliferative skin masses found on the legs of finches in the family Fringillidae. Virus recovered from these birds was found to be antigenically similar to some types of papillomaviruses documented in humans. Papillomavirus was found to be common in finches, causing proliferative lesions on 330 of 25,000 Chaffinches examined. In contrast, the virus appears to be rare in other avian species.<sup>240,298</sup> Lesions clinically appear as slow-growing, dry, sappy, wart-like epithelial proliferations on the skin of the feet and legs. Severe proliferations can result in the loss of digits or the foot. Histologic changes are typical for papillomas.

A papillomavirus was demonstrated in a Timneh African Grey Parrot with proliferative skin lesions on the head and palpebrae. Histologic evaluation of biopsies from this bird indicated long, thin folds of hyperplastic epidermis, which were moderately acanthotic and parakeratotic. Papillomavirus particles were demonstrated by electron microscopy and by staining with viral-specific antibodies within retained nuclei in the stratum corneum.<sup>190</sup>


Papillomatous lesions have been diagnosed histologically from proliferative growths originating from skin overlying the phalanges, uropygial gland, mandible, neck, wing, eyelids and beak commissure from various Psittaciformes including Amazon parrots, African Grey Parrots, Quaker Parakeets, cockatiels and budgerigars (Figure 32.10). While a viral etiology has been assumed for these epidermal proliferations, virus has not been demonstrated in association with any of these lesions.<sup>318,412</sup>



**FIG 32.10** A papilloma-like growth at the commissure of the beak in an Alexandrian Parakeet hen. The bird was on a marginal diet and had numerous rhamphothecal and gnathecal defects. The growth was surgically removed. Histopathology indicated long, thin folds of hyperplastic epidermis with acanthosis. This lesion was considered suggestive of a papilloma; however, virus could not be identified histologically.

Histologic lesions suggestive of papillomas have been described at numerous locations along the avian gastrointestinal tract. These papillomatous lesions most frequently occur at the transition between mucosa and cutaneous epithelium in the cloaca. In one study involving 19 species of New World parrots, papillomatous lesions were documented in decreasing frequency in the cloaca, glottis, choanal slit, oropharynx, esophagus, proventriculus and ventriculus. Lesions are commonly reported in Hawk-headed Parrots and Green-winged Macaws, but have also been described in other macaws, African Grey Parrots, *Amazona* spp., caiques, conures, budgerigars, Barraband's Parrot, cockatiels and *Pionus* spp.<sup>65,135,318,399,412</sup>

Clinically, many affected birds may appear normal with no changes in CBC or clinical chemistries. In other birds, intestinal papillomas mechanically interfere with normal physiologic activities (Table 32.7). Cloacal papillomas may cause or mimic recurrent prolapses. Droppings may be loose, causing feathers around the vent to be stained or covered with fecal material. In chronic cases, melena may be noted. Depending on the location and severity of the lesions, some birds with cloacal papillomas are able to breed normally while others may not be able to copulate.



**FIG 32.11** A six-year-old Blue-fronted Amazon hen was presented for tenesmus and diarrhea. The bird weighed 425 g and was in overall good condition. Excrement was accumulated on the pericloacal feathers. An irregular pink mass was present on the dorsal mucosa of the cloaca. The area was coated with five percent acetic acid, and the large mass along with several smaller raised lesions on the mucosa turned white. CBC and clinical chemistries were normal. The bird was not found to be shedding polyomavirus using a DNA probe test. These findings were suggestive of cloacal papillomatosis. The mass was removed with staged cauterization using silver nitrate.

Grossly, papillomatous lesions may appear as large, distinct masses or may occur as numerous small, raised lesions covering the mucosa (Figure 32.11). These friable growths may be pink or white and have a tendency to bleed easily when bruised (see Color 19). Acetic acid (5%) will turn papillomatous tissue white, helping to identify suspect lesions.<sup>260,412</sup> Many internal papillomatous lesions are not recognized until necropsy. Suspicious lesions in the oral or cloacal cavity can be viewed directly. Endoscopy is necessary to identify and obtain diagnostic biopsies of suspect papillomatous lesions in the esophagus or proventriculus or high in the cloaca or proctodeum.

Attempts to demonstrate papillomavirus in suspect lesions by electron microscopy, low stringency southern blotting techniques or immunocytochemical procedures have all failed. Attempts to induce lesions in Amazon parrots, macaws and cockatoos using ho-

mogenized lesions have also been unsuccessful,<sup>399</sup> however, the disease has features that suggest an infectious agent.<sup>260,412</sup> Chronic irritation of the cloacal mucosa with epithelial cell hypertrophy or hyperplasia could result in a histologic lesion that morphologically resembles those induced by papillomavirus and has been suggested as an alternate cause of these lesions.<sup>135,399</sup> Herpes-like virus particles were described in a cloacal papilloma in a conure.<sup>118</sup> Malnutrition, particularly with respect to vitamin A, has been suggested to potentiate lesions.

Histologic examination is necessary to confirm a diagnosis in any suspect lesions. Proliferations of epithelial cells on a fibrovascular stalk are suggestive. The neoplasms may show numerous projections covered by a hyperplastic tessellated epithelium or a non-keratinized columnar epithelium containing some mucous glands. The stroma may show some inflammatory cells. Mitotic figures may be present in the basal cells or upper layers of hyperplastic epithelium.<sup>399</sup> Amazon parrots with papillomatous lesions have been described as having a high incidence of malignant pancreatic or bile duct carcinomas.<sup>135,171</sup> The differential diagnoses for papillomatosis should include the wart-like growths in cockatoos, in which herpesvirus-like particles have been identified, and the tumorous forms of avian pox (skin or oral mucosa).<sup>245</sup>

### Therapy

Suggested therapeutic measures for cloacal papillomas have been based on the physical removal of the masses through cryotherapy, radiocautery or surgical excision. These procedures have been performed alone or in combination with the use of autogenous vaccines. None of the proposed therapies is consistently effective, and papillomatous tissue often recurs. The use of autogenous vaccines has been described but is generally not effective.<sup>78,260,352,412</sup> Spontaneous regression of papillomatous tissue has been described.<sup>139,260,412</sup>

With any removal technique, care should be exercised to prevent excessive tissue damage that may result in severe scarring and reduction in the size of

**TABLE 32.7** Clinical Signs Associated with Internal Papillomatosis

Cloaca	Tenesmus, infertility, recurrent enteritis, hematochezia, flatulence, odoriferous stool, cloacoliths, acid pH
Oral Cavity	Dysphagia, dyspnea, wheezing
Upper GI	GI blockage, anorexia, chronic weight loss, vomiting, dilatation of the proventriculus or ventriculus, passing whole seeds

the cloacal lumen. Scarring can result in incontinence, reproductive failure or blockage of the urodeum or proctodeum.

Staged cauterization with silver nitrate sticks may prove to be the easiest, safest and best way to remove papillomatous lesions from the cloaca (see Color 19).<sup>194</sup> Lesions should be exteriorized by inserting a moistened cotton swab followed by carefully rubbing a small area of the lesion with a silver nitrate stick. The silver nitrate should be immediately inactivated with copious fluids to prevent the liquified material from burning unaffected mucosal tissues. The procedure is repeated at two-week intervals until the lesions have been removed.

Epizootiologic evidence has been used to suggest that intestinal papillomas are caused by an infectious agent even though no etiology has been confirmed. Mutual preening and sexual contact have been suggested as methods of transmission. However, other investigations suggest that the disease is not infectious (Clubb, S unpublished). Several large parrot aviaries have had epizootic outbreaks of the disease following the introduction of a clinically positive bird.<sup>260,412</sup> Until further information on the etiology of this disease is available, it is prudent to isolate birds with lesions from the remainder of a collection.

### ■ Polyomavirus

Budgerigar fledgling disease (BFD) is caused by the first avian polyomavirus to be characterized (Color 32.15).<sup>85,376</sup> Polyomaviruses that infect various avian hosts appear to be morphologically and antigenically similar; however, the clinical presentation, distribution of lesions and epidemiologic effects of the virus are dramatically different among susceptible species.<sup>38,39,130,175,188</sup>

The capsid antigens from the BFD virus and other polyomaviruses have been shown to be antigenically related. Comparison of nucleic acid from avian and mammalian polyomaviruses indicates that there are similarities; however, the genomes are not identical. Polyomaviruses recovered from several species of Psittaciformes have been shown to be similar by comparing restriction maps of viral DNA and by using viral-specific DNA probes (Color 32.8).<sup>233,281,292,321</sup>

It has been suggested that the avian strains of polyomavirus be placed into the subgenus avipolyomavirus. This is based on the finding that strains of polyomavirus recovered from budgerigars

(BFDV-1), chickens (BFDV-2) and Blue and Gold Macaws (BFDV-3) had distinct degrees of tropism.<sup>397</sup> This supports the findings that polyomavirus recovered from budgerigars did not cause disease in experimentally infected Blue and Gold Macaws (Ritchie, BW unpublished). It is suspected that strains from Passeriformes are also different. DNA probes designed to detect polyomavirus from Psittaciformes do not detect some strains of polyomavirus found in passerine birds.

BFDV-2 antibodies could be detected in a flock of clinically healthy broiler chickens in Central Europe that were also infected with infectious bursal disease virus. The role that this immunosuppressive virus played in the pathogenesis of the polyomavirus infection was undetermined.<sup>397</sup>

### Transmission

The epizootiology of polyomavirus infections is not fully understood. The factors involved in the duration and induction of viral shedding remain unresolved. Some asymptomatic adults produce persistently infected young, while others have neonates that intermittently may develop clinical signs and die. It has been suggested that persistently infected birds may be immunotolerant as a result of being infected before they are immunocompetent. Some birds are known to shed virus in the presence of high antibody titers. Asymptomatic adults that intermittently shed the virus are thought to be responsible for the persistence, transmission and spread of the virus through various avian populations.<sup>38,39,44,85,105,106</sup> In polyomavirus outbreaks involving 23 different budgerigar aviaries, the onset of disease could be traced to the addition of new, clinically normal breeders.<sup>38,39</sup>

Experimental data and observations with the natural disease suggest that polyomavirus transmission may occur by both horizontal and vertical routes.<sup>38,44,63,188,233</sup> Parents may transmit virus to offspring through the regurgitation of exfoliated crop epithelial cells. Virus can replicate in the epidermal cells of the feather follicles resulting in the presence of virus in "feather dust," which may enter a susceptible host through the respiratory or gastrointestinal tract. Virus has been isolated from lung tissue supporting the possibility of an aerogenous transmission. The presence of virus in the renal tubular epithelial cells suggests passage of virus in the urine. Polyomavirus nucleic acid can be detected in cloacal swabs taken from birds during polyomavirus outbreaks. The recovery of viral DNA from the cloaca

suggests that the virus could be shed from gastrointestinal, renal or reproductive tissues.<sup>292,293</sup>

Seronegative young adult birds will seroconvert when housed adjacent to seropositive breeding birds, implicating indirect transmission of the virus.<sup>63,72,188</sup> Aviary personnel, technicians, veterinarians, pet owners and any aviary equipment should be considered important vectors for this environmentally stable virus.

Findings in support of vertical transmission include the identification of intranuclear inclusion bodies in one-day-old budgerigars and the occurrence of infections when eggs from parents that consistently produce diseased neonates are cross-fostered to parents producing normal young.<sup>38,39,125</sup>

Theoretically, a persistently infected hen could pass maternally derived antibodies, virus or both to its young. The clinical status of the chick could then depend on the level of maternally derived antibodies and the stage of immunocompetency when viral exposure occurs. Chicks that have protective levels of maternal antibodies as well as infections derived from the parents may serve to infect susceptible neonates in the nursery.<sup>105,106</sup> Persistent infections with intermittent shedding and vertical transmission are also suspected to occur in finches and result in early embryonic death.<sup>192,256</sup>

The incubation period is not known. Affected budgerigar fledglings show peak mortality rates between the 15th and 19th day of life. In larger parrots, death may occur from 20 to 140 days of age, with most deaths occurring between 20 to 56 days of age.

### Pathogenesis

As a group, polyomaviruses typically reside in a latent state, and infections become patent following periods of suffering from stressors.<sup>428</sup> The age of a bird at the time of viral exposure may be a major factor in the pathogenesis of polyomavirus infections. Budgerigars that die shortly after hatch have more severe and widespread lesions than do birds in which the morbid state is more prolonged.<sup>38</sup> When 11- to 12-day-old chicken embryos are experimentally infected with polyomavirus, the hatched chicks remain normal and produce detectable antibodies by two weeks of age; in contrast, embryos infected at ten days of age are susceptible to the virus and develop pansystemic lesions.<sup>63</sup> It is theorized that persistently infected birds may be those that are infected before they are immunocompetent.<sup>105,106,424</sup>

Field studies have shown that birds that die from avian polyomavirus frequently have antibodies to the virus. These findings, along with the frequent occurrence of glomerulopathy (immune complex induced) have led to the theory that death from avian polyomavirus in large psittacine birds is caused by an immune complex disease;<sup>321</sup> however, Blue and Gold Macaws that were seronegative for avian polyomavirus remained subclinical after being infected with BFD virus. These birds did seroconvert and developed high neutralizing antibody titers (>1:640) indicating that they were susceptible. DNA probe-testing of whole blood indicated intermittent viremia. The experimentally infected birds remained asymptomatic a year after infection, suggesting that other factors may precipitate the formation of immune complexes in field cases (Ritchie BW, unpublished). Further, massive hepatocellular necrosis (with intranuclear inclusion in hepatocytes) is the most frequent histologic lesion in larger psittacine birds that die from avian polyomavirus, and an immune complex theory of avian polyomavirus-induced death does not explain the principal histologic lesion.

The BFD virus can replicate in a variety of target cells of many avian species including chicken embryo cells.<sup>281</sup> The virus appears to require host cells that are dividing and temperatures of at least 39°C. Following the primary viremia, inclusion bodies can develop in most internal organs as well as the skin and developing feathers (Figure 32.13). The highest virus concentration is usually found in the brain. Tissue lesions can be severe and are directly related to the level of morbidity and mortality. The virus has been associated with immunosuppression through its ability to destroy or inhibit the normal development of lymphoid tissue. Infections in adult Estrildidae or Ploceidae have been suggested to be dependent on immunosuppression.<sup>440</sup>

Polyomaviruses in mammals are natural tumor inducers. There has thus far been no association between polyomavirus infections in birds and an increased incidence of tumors, although more in-depth studies are necessary.<sup>38,39,44,63,130,190,281</sup> Some mammalian polyomavirus infections are known to persist by incorporating viral genome into host cell DNA.

### Clinical Features

An avian polyomavirus appears to be distributed worldwide, but there are some apparent strain differences. For example in Europe, a more chronic form of the disease is common in budgerigars, while in the United States and Canada an acute form of disease

with high mortality prevails. Most members of the Papovaviridae family have a restricted host range.<sup>281</sup> In contrast, the avian polyomavirus appears to infect a wide variety of Psittaciformes, Estrilidae and Ploceidae including macaws, Amazon parrots, conures, White-bellied Caiques, parrotlets, African Grey Parrots, lovebirds, Ring-necked Parakeets, Eclectus Parrots,<sup>392</sup> Scarlet-chested Parrots, Bourke's Parrots,<sup>311</sup> cockatoos<sup>311,363</sup> and finches.<sup>381,382,440</sup>

- **Budgerigars:** The type of clinical disease induced by polyomavirus in budgerigars appears to depend on the age and condition of the bird when exposure to the virus occurs. Neonates from infected flocks may develop normally for 10-15 days and then suddenly die with no premonitory signs. Other infected hatchlings may develop clinical signs, which include abdominal distension, subcutaneous hemorrhage, tremors of the head and neck, ataxia and reduced formation of down and contour feathers.<sup>38,39,72,175,257</sup> Infections have also been associated with decreased hatchability and embryonic death.<sup>125</sup>

Infected budgerigars may die rapidly once clinical signs develop, and reports on mortality rates vary from 30 to 100% of affected hatchlings. Mortality rates are highest in budgerigars less than 15 days of age. Survivors may exhibit symmetrical feather abnormalities characterized by dystrophic primary and tail feathers, lack of down feathers on the back and abdomen and lack of filoplumes on the head and neck (Color 32.15).<sup>39,44,72,175,281</sup> Birds often die acutely with the crop and gastrointestinal tract full of food. Surviving fledglings frequently have dystrophic feathers (French moult). Developing primary and secondary feathers may break or fall out, resulting in substantial blood loss. Affected birds are unable to fly and are often called runners or hoppers. Similar feather lesions can be caused by the psittacinebeak and feather disease (PBFD) virus. In general, feather lesions in budgerigars caused by polyomavirus resolve after several months, while those induced by PBFD virus will continue to progress.

It has been previously speculated that French moult represents a nonfatal form of BFD;<sup>38,39,175</sup> however, budgerigars with classic French moult lesions are often seronegative for polyomavirus antibodies.<sup>226</sup> In North America and Europe, lesions attributable to French moult are thought to be caused either by the polyomavirus or by the PBFD virus. Investigations in Australian budgerigars have demonstrated that clinical signs associated with French moult are associated with the PBFD virus and not with avian

polyomavirus.<sup>38,39,175</sup> Immunohistochemical staining of infected tissues with viral-specific antibodies or DNA probes is required to differentiate between intranuclear inclusion bodies induced by polyomavirus and those caused by PBFD virus.

- **Other Psittaciformes:** In larger psittacine birds, polyomavirus infections may cause peracute death with no premonitory signs or acute death after development of clinical changes including depression, anorexia, weight loss, delayed crop emptying, regurgitation, diarrhea, dehydration, subcutaneous hemorrhages, dyspnea and polyuria (Color 32.12).<sup>63,130,190,363</sup> Intramuscular injection sites or damaged feathers may bleed profusely. Neurologic signs characterized by ataxia, tremors and paralysis have been described in some Psittaciformes.<sup>63</sup> Clinical signs are common at the time of weaning, and infected fledglings typically die 12 to 48 hours after developing clinical signs. Infections may occur in both parent-raised and hand-raised neonates.<sup>63,130,190</sup> In one outbreak, mortality rates in exposed neonates ranged from 31 to 41% of the at-risk population.<sup>63</sup> Infected birds that recover are thought to become asymptomatic virus carriers. Infections in adult birds are thought to result in the formation of subclinical carriers with only occasional development of clinical signs. Blue and Gold Macaw neonates experimentally infected with budgerigar fledgling disease virus (derived from cell culture) did not develop clinical signs of infection but did seroconvert, indicating that they were subclinically infected (Figure 32.12) (Ritchie BW, unpublished).

A chronic form of polyomavirus has also been described and is typified by weight loss, intermittent anorexia, polyuria, recurrent bacterial or fungal infections and poor feather formation.<sup>63,190</sup> Birds that recover appear normal, although some birds have been found to die months later from renal failure.<sup>63</sup> The feather abnormalities that are relatively common with polyomavirus infections in budgerigars have been less frequently described in other psittacine birds.<sup>63,130,190,307</sup>

In the Eclectus Parrot, transient gastrointestinal stasis, melena and abdominal pain have been described in older chicks. Occult hematuria has been suggested as an indication of a polyomavirus infection in this species.<sup>392</sup> Cloacal swabs from suspect patients can be screened for the presence of polyomavirus nucleic acid using viral-specific DNA probes. Affected birds may have increased activities of LDH, AST and alkaline phosphatase.<sup>63</sup>



**FIG 32.12** Blue and Gold Macaw chicks that did not have avian polyomavirus VN antibodies were experimentally vaccinated with a killed vaccine. The vaccinated birds seroconverted and were protected from subsequent infection. Non-vaccinated birds remained asymptomatic following experimental inoculation even though they developed high VN antibody titers, indicating that they had been infected.

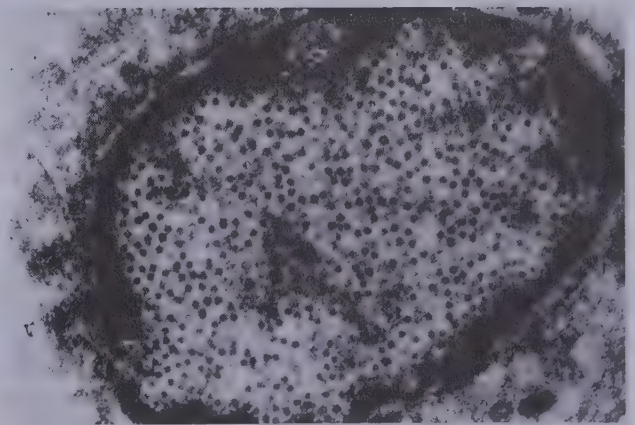
In addition to clinical changes in neonates, polyomavirus infections have also been documented in an eight-month-old Splendid Parakeet and in sporadic, acute deaths in fully fledged lovebirds less than one year old.<sup>307,310</sup> An adult Moluccan Cockatoo with neurologic signs was diagnosed as having polyomavirus based on the ultrastructural morphology of inclusion bodies in the brain.<sup>363</sup> An outbreak of polyomaviral disease in an aviary with numerous Psittaciformes resulted in the deaths of an adult Eclectus Parrot, a Painted Conure and 3 of 11 adult White-bellied Caiques. The affected birds were 2 to 2.5 years old and had lesions similar to those seen with polyomavirus infections in psittacine fledglings.<sup>344</sup> These cases suggest that some older Psittaciformes may be susceptible to polyomavirus infections during epornitics.

- **Finches:** Lesions suggestive of a polyomavirus infection have been described as a cause of acute mortality in two- to three-day-old fledgling, young adult and mature finches.<sup>98,192,256,440</sup> Affected birds had nonspecific signs of illness 24 to 48 hrs before death.<sup>98,256</sup> In one outbreak, 36 of 70 two- to three-day-old birds died. Many of the fledglings that survived had poor feather development, long tubular misshapen lower mandibles, and fledged several days later than normal young (see Figure 43.13).<sup>256</sup>

### Pathology

The gross lesions associated with polyomavirus infections are summarized in Table 32.8 (Colors 32.17, 32.20). Neonates presented for necropsy are usually in excellent overall condition and may have full crops and gastrointestinal tracts, indicating the speed of disease progression. Karyomegaly in various tissues and hepatic necrosis are the most consistent histologic lesions in larger psittacine birds.<sup>38,44,63,130,132,188,190</sup> Other suggestive histologic lesions are listed in Table 32.9. Viral antigen present within inclusion bodies from infected Psittaciformes has been confirmed to be antigenically related to the polyomavirus isolated from budgerigars through the use of fluorescent antibody staining techniques.<sup>130,132,175,440</sup>

Polyomavirus-infected finches may die acutely with no detectable pathology or can have gross and histologic lesions similar to those described for other birds (Tables 32.8, 32.9).<sup>98,188,256,440</sup> Inclusion bodies from some finches have been confirmed to contain polyomavirus antigen by fluorescent-antibody staining techniques.<sup>440</sup>



**FIG 32.13** Intranuclear inclusion body in the brain of a Ducorps' Cockatoo that died after several days of depression and progressive neurologic signs (ataxia, paresis, paralysis, coma). The inclusion bodies in the brain were confirmed to contain polyomavirus antigen using viral-specific antibodies (immunoperoxidase technique) and polyomavirus nucleic acid using viral-specific DNA probes (*in situ* hybridization). This electron micrograph shows characteristic 50 nm icosahedral viral particles.

TABLE 32.8 Gross Lesions Associated with Polyomavirus Infections

	Budgerigars	Lovebirds	Other Psittaciformes	Finches
<b>Heart</b>	Hydropericardium, cardiomegaly, myocardial hemorrhage		Myocardial hemorrhage, epicardial hemorrhage, pale myocardium	
<b>Liver</b>	Hepatomegaly, yellow-white foci	Pallor, congestion, mottled hemorrhage	Hepatomegaly, red and yellow mottling, friable	Swollen, pallor, mottled hemorrhage
<b>Spleen</b>		Small, pallor	Splenomegaly, friable	Splenomegaly, congestion
<b>GI tract</b>	Intestinal hemorrhage		Intestinal hemorrhage	Serosal or subserosal intestinal hemorrhage
<b>Kidney</b>	Swelling, pallor or congestion, white foci, petechiation		Pallor, swollen	Perirenal hemorrhage
<b>Skin</b>	Subcutaneous hemorrhage, feather dystrophy		Feather dystrophy, petechial hemorrhage, ecchymotic hemorrhage	
<b>Other</b>	Ascites, lung congestion	Increased serosal fluids	Pale skeletal muscle, ascites, serosal and subcutaneous hemorrhage, pallor	

TABLE 32.9 Histologic Lesions Associated with Polyomavirus Infections

	Budgerigars	Lovebirds	Other Psittaciformes	Finches
<b>Heart</b>	Coagulative necrosis, myocardial degeneration, inclusion bodies	Enlarged endothelial cells	Myocarditis, epicardial hemorrhage, inclusion bodies (myocardium)	Myocarditis, inclusion bodies
<b>Liver</b>	Coagulative necrosis, vacuolar degeneration, inclusion bodies	Hepatic necrosis, hemorrhage, inclusion bodies	Hepatic necrosis, inclusion bodies	Kupffer's cell hyperplasia, hepatocellular necrosis, periportal heterophils and lymphocytes, vacuolar degeneration, inclusion bodies (hepatocytes, Kupffer's cells)
<b>Spleen</b>	Lymphatic atrophy, inclusion bodies, (reticulo-endothelial [RE] cells)	Lymphoid depletion, necrosis, inclusion bodies	Karyomegaly of RE cells, multifocal necrosis, inclusion bodies	Macrophage hyperplasia, necrosis, lymph depletion, inclusion bodies
<b>GI Tract</b>	Inclusion bodies (crop, intestines)		Serosal hemorrhage, epithelial desquamation of crop and esophagus, inclusion bodies (esophagus, proventriculus, intestines)	Necrosis and plasma cell infiltrates of lamina propria, enlarged vacuolated epithelial cells, inclusion bodies, mainly enterocytes
<b>Kidney</b>	Focal nephrosis, vacuolar degeneration, inclusion bodies (renal tubular epithelium)	Enlarged endothelial cells, enlarged epithelial cells, karyomegaly of renal tubules	Membranous glomerulopathy, thickened glomerular capillaries, inclusion bodies (glomerulus interstitium, collecting tubules)	Inclusion bodies (endothelium, tubular epithelium)
<b>Skin</b>	Ballooning degeneration (follicular epithelium, lateral and axial plate cells, epidermis) follicular and epidermal hyperplasia, inclusion bodies (epidermis, follicular epithelium, uropygial gland)		Ballooning degeneration and karyomegaly in epithelium of growing feathers, inclusion bodies (follicular epithelium)	
<b>Other</b>	Bone marrow necrosis, lymphatic atrophy, cerebellar lesions (particularly in the Purkinje cells), inclusion bodies (pancreas, adrenals, lung, gonads, brain)		Generalized hemorrhage, bursal medullary necrosis, bone marrow necrosis, inclusion bodies (bone marrow, pancreas, adrenals, skeletal muscle, lungs)	Bone marrow necrosis, inclusion bodies



### Diagnosis

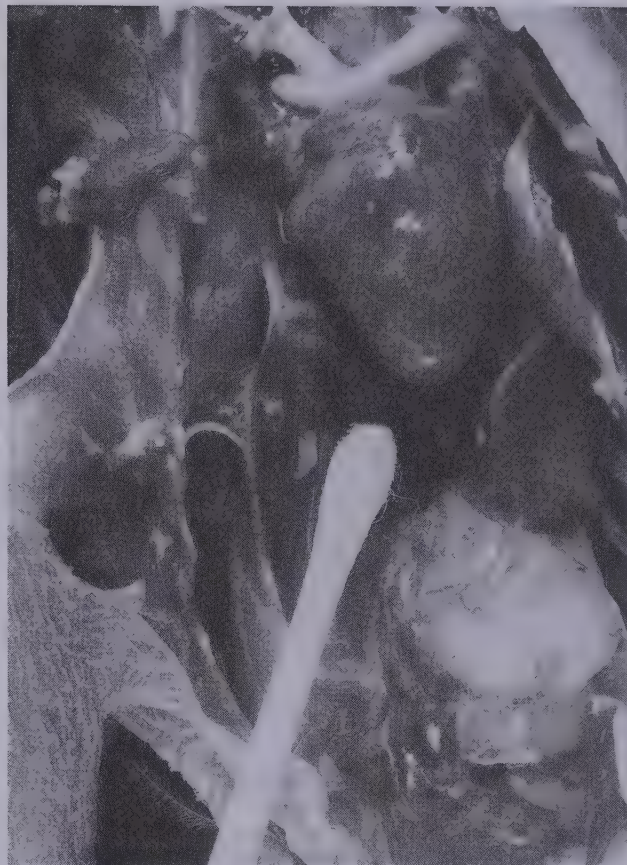Feather lesions in surviving budgerigars cannot be macroscopically distinguished from changes caused by the PBFV virus. Malnutrition can also cause feather lesions, which might be difficult to evaluate clinically. Organ lesions can be induced by a variety of infectious agents, particularly bacteria.

Demonstration of large clear basophilic or amphiphilic intranuclear inclusion bodies is considered suggestive of a polyomavirus infection. A confirmed diagnosis requires immunohistochemical staining of suspected lesions using viral-specific antibodies or the detection of viral nucleic acid using polyomavirus-specific DNA probes.<sup>188,292,293,440</sup> The VN can be used to identify virus isolated in cell culture.<sup>281</sup>

Immunodiffusion and virus neutralization techniques have been used to demonstrate polyomavirus antibodies in exposed birds. During outbreaks in mixed psittacine bird collections, infected survivors and asymptomatic birds exposed to them developed anti-BFD virus neutralizing antibodies.<sup>63,188</sup> The prevalence of neutralizing antibodies against BFD virus in aviaries containing cockatoos, macaws, Amazon parrots and conures ranged from 11 to 45%. These titers were found to decrease over a two-month period. The demonstration of waning antibody titers suggests a transient serologic response in exposed birds. Adults from an infected flock that were exposed to diseased birds developed titers and subsequently raised seronegative, clinically normal young.<sup>63,105,106,188,424</sup>

Subclinical carriers that intermittently shed polyomavirus have been thought to maintain high antibody titers in serial serologic assays.<sup>105,424</sup> Based on these suppositions, the demonstration of sustained high antibody titers has been used to screen for polyomavirus carriers;<sup>63,105,106,292,424</sup> however, polyomavirus-specific DNA probes have been used to demonstrate that there is no correlation between the shedding of polyomavirus in excrement and the titers of neutralizing antibodies.<sup>292,293,320</sup>

Viral-specific DNA probes have been used to demonstrate polyomavirus nucleic acid in various tissues including liver, spleen, kidney, cloacal secretions, intestinal secretions, serum and blood. Viral nucleic acid occasionally can be detected in the blood or serum of some infected birds; however, the best antemortem sample for detecting polyomavirus shedders in larger psittacine birds is a cloacal swab. Testing birds twice per year (before and after the breeding season) is recommended to detect intermittent viral shedders.



**FIG 32.14** The use of a DNA probe test is the best method to confirm the presence of polyomavirus in postmortem samples. A swab is used to collect a sample from the cut surface of the liver, spleen and kidney.

DNA probes can also be used to detect viral nucleic acid in fresh tissues from birds that are suspected to have died from polyomaviral infections. In suspect cases, duplicate tissue samples can be sent for histopathology as a tentative diagnosis and for DNA probing to confirm a polyomavirus infection. The best sample to submit for postmortem confirmation of polyomavirus is a swab of the cut surface of the spleen, liver and kidney (same swab for all three tissues) (Figure 32.14).

### Therapy

In chicks that are hemorrhaging, injection of 0.2-2.5 mg/kg bodyweight of vitamin K IM may be helpful and can increase survival rates favorably, although prognosis in birds with heavy hemorrhaging is poor.

Several immunostimulants have been anecdotally suggested as effective in the treatment of birds with clinical signs suggestive of avian polyomavirus; however, suggested therapies have not been confirmed to

be effective in birds that were documented (liver biopsy) to have an active avian polyomavirus infection.

### Control

Polyomavirus virions are small, nonenveloped particles that are resistant to severe environmental conditions, many disinfectants and heat at 56°C for two hours.<sup>44,376,428</sup> Stability of the virus causes a considerable problem in the aviary because persistently infected adult birds can shed virus in their feather dust or excrement. Manual removal of any organic debris followed by the use of appropriate disinfectants is required to prevent or contain outbreaks. Sodium hypochlorite (5%) is thought to be effective against the BFD virus at a concentration of 50 ml/liter of diluent.<sup>93,281</sup> A polyomavirus DNA probe test can be used to screen walls, caging, air circulating ducts and equipment in the home or hospital to determine if this virus is contaminating a bird's environment. This is accomplished by rubbing a swab across the surfaces intended to be evaluated for the presence of polyomavirus nucleic acid.

With the highly infectious nature of avian polyomavirus, particularly to young Psittaciformes, closed breeding operations that do not allow visitors should be encouraged. A cloacal swab of any bird that is being added to a collection should be analyzed during the quarantine period to determine whether a bird is shedding polyomavirus. During an epornitic, birds that are actively shedding the virus can be identified by using DNA probes.<sup>292,293,344</sup> All birds being sold from an aviary should be tested to determine if they are shedding polyomavirus before shipment. Birds also should be tested for viral shedding during the post-purchase examination.

A bird that is shedding polyomavirus could be maintained as a pet if it does not expose other birds, particularly neonates, to the virus. Breeding birds shedding polyomavirus should be separated from the remainder of the collection, and offspring from these birds should be raised separately from birds that are not shedding the virus. Offspring from shedders should also be raised separately from birds that are not shedding the virus. The applicability of killed and recombinant polyomavirus vaccines is being evaluated.

A killed avian polyomavirus vaccine was found to induce virus-neutralizing antibodies in Blue and Gold Macaw chicks that were sufficient to protect them from subsequent challenge. This suggests that a vaccine could be effective in preventing infections (Ritchie BW, unpublished).

Outbreaks of polyomavirus tend to be persistent in budgerigar aviaries that utilize a constant breeding cycle, while the disease appears to be self-limiting in aviaries raising larger Psittaciformes where breeding cycles are discontinuous.<sup>63</sup> High levels of fledgling mortality can be reduced in budgerigar aviaries by stopping the breeding cycle and resting the birds for several months. The exact mechanisms involved in stopping new cases remains undetermined.

Depopulation of budgerigar aviaries experiencing outbreaks followed by restocking with sero-negative birds has been suggested as a method of controlling enzootic infections in this species. It has been suggested that polyomavirus-free budgerigar nestlings can be produced by interrupting the breeding cycle, removing all but the older breeding birds and disinfecting the aviary.<sup>321</sup> This technique has been reported to be successful in some flocks, while in others, infections resume when breeding is initiated.<sup>125</sup> Depopulation is not a practical, nor recommended procedure for controlling polyomavirus in larger Psittaciformes.

## Circoviridae

### Psittacine Beak and Feather Disease Virus

A chronic disease characterized by symmetric feather dystrophy and loss, development of beak deformities and eventual death was first described in various species of Australian cockatoos in the early 1970's.<sup>315a</sup> Free-ranging Psittaciformes with feather abnormalities suggestive of this disease were noted by Australian explorers at the turn of the century. The disease has been diagnosed in numerous Psittaciforme species in addition to cockatoos. The currently used name, coined by Perry in 1981, is "psittacine beak and feather disease" (Pbfd).<sup>316</sup>

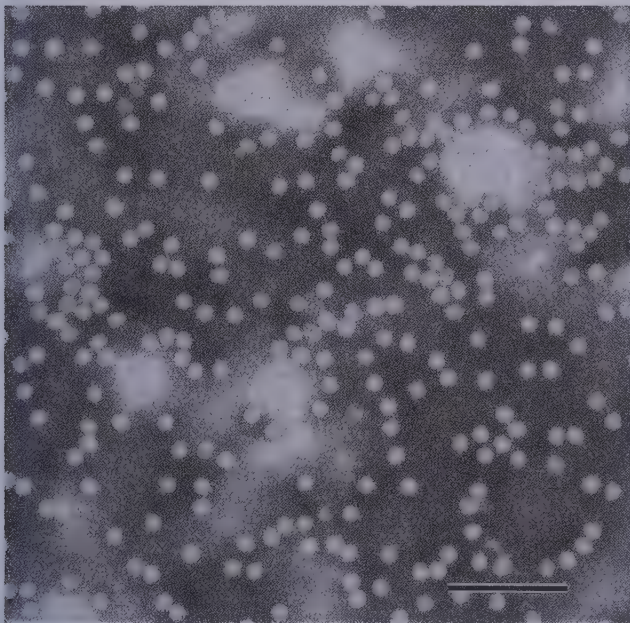
This disease has been experimentally reproduced in neonatal budgerigars and Rose-breasted Cockatoos using feather homogenates containing 19-22 nm viral particles, and in neonatal budgerigars, cockatiels, African Grey Parrots and Umbrella Cockatoos using purified concentrated Pbfd virions (Color 32.5).<sup>339,443</sup>

The Pbfd virus is a 14 to 17 nm icosahedral nonenveloped virion associated with two major proteins that have molecular weights of 27,000 and 23,000

daltons. Virus with similar ultrastructural characteristics, protein composition and antigenic similarities can be consistently recovered from numerous different species of psittacine birds with clinical or histologic lesions of PBFD (Figure 32.15).<sup>339,343,345</sup>

The PBFD virus infecting different hosts is antigenically similar and has sufficiently conserved nucleic acid sequences to allow detection of the virus using viral-specific DNA probes. The virus hemagglutinates erythrocytes from cockatoos and some guinea pigs (see Figure 32.2).<sup>340</sup>

Based on the virion dimension, polypeptide composition and nucleic acid size and experimental conformation, it has been suggested that the etiologic agent of PBFD is a member of a new family of pathogenic animal viruses.<sup>345</sup> The virion size and nucleic acid characteristics described for the PBFD virus are similar to those found for the chicken anemia agent (CAA) and for the apparently nonpathogenic porcine circovirus (PCV).<sup>404</sup> On the basis of these similarities, it has been suggested that these viruses be placed in the same family to be called *Circoviridae*. Because the PBFD virus does not readily grow in cell culture, nothing is known about its replication mode. The



**FIG 32.15** High concentrations of PBFD virus can be recovered from dust in rooms where PBFD-positive birds are housed. With the ease with which contaminated dust could be transferred from bird to bird through natural air circulation or through fomites (clothing, hair, skin, caging, nets), it is theorized that contaminated feather dust serves as the major method of environmental persistence and natural transmission of the virus. Areas suspected to be contaminated with PBFD virus can be tested for the presence of virus using viral-specific DNA probes.

**TABLE 32.10** Psittaciformes Currently Considered Susceptible to PBFD virus

Sulphur-crested Cockatoo	Triton Cockatoo
Major Mitchell's Cockatoo	Citron Cockatoo
Galah	Goffin's Cockatoo
Little Corella	Vasa Parrot
Long-billed Corella	Blue-fronted Amazon Parrot
Budgerigar	Red-lored Amazon
Cockatiel	Red-vented Cockatoo
Rainbow Lorikeet	Senegal Parrot
Western Rosella	African Grey Parrot
Hooded Parrot	Meyer's Parrot
Malee Ring-necked Parakeet	Black Palm Cockatoo
Port Lincoln Parrot	Red-bellied Parrot
Red-rumped Parrot	Gang-gang Cockatoo
Bourke Parrot	Scarlet Macaw
Eclectus Parrot	Rose-ringed Parakeet
Princess Parrot	Pale-headed Rosella
Peach-faced Lovebird	Golden-shouldered Parrot
Nyassa Lovebird	Northern Rosella
Fisher's Lovebird	Jenday Conure
Masked Lovebird	Green-winged Macaw
King Parrot	Pionus Parrot
Moluccan Cockatoo	
Umbrella Cockatoo	
Indian Ring-necked Parakeet	

CAA and PCV replicate in the nucleus of the host cells.

A virus that morphologically resembles PBFD virus has been described in pigeons.<sup>134</sup> When compared to PBFD virus, the pigeon circovirus is antigenically unique and has some differences in nucleic acid sequence.<sup>439</sup>

### Epizootiology

Histologic or clinically suggestive lesions of PBFD have now been described in 42 species of Psittaciformes. Historically, PBFD was thought to be restricted to Old World and South Pacific psittacine birds, with the white and pink cockatoos being particularly susceptible. However, the disease has been documented in several black cockatoos and New World psittacine birds including Amazon parrots, macaws and pionus parrots (Table 32.10) (Color 32.1). Investigations indicate that the actual host range of the PBFD virus remains largely unknown. Psittacine beak and feather disease has been documented only in Psittaciformes.<sup>139,178,187,309,343</sup>

Epizootiologic studies in one import station in the United States showed that 0.5% of imported Lesser Sulphur-crested Cockatoos, Umbrella Cockatoos, Citron Cockatoos and Moluccan Cockatoos had gross lesions consistent with PBFD, suggesting that these birds had been infected in their country of origin.<sup>187</sup> It is postulated that PBFD has historically been enzootic in free-ranging populations of Old World and

South Pacific psittacine birds, and that the disease has been introduced to other susceptible populations of both free-ranging and captive birds through the worldwide movement of birds for the pet market.<sup>271,273</sup>

In Australia, 75% of the captive Sulphur-crested Cockatoos examined in one veterinary hospital had clinical signs consistent with PBFD. The incidence of the disease in other commonly maintained captive psittacine birds in Australia, including galahs and budgerigars, is thought to be much lower.<sup>316</sup> Psittacine beak and feather disease is reportedly enzootic in free-ranging populations of Sulphur-crested Cockatoos, Rose-breasted Cockatoos, Little Corellas, Major Mitchell's Cockatoos, Crimson Rosellas, budgerigars and Rainbow Lorikeets.<sup>271,272,308,316</sup>

As many as 20% of free-ranging Sulphur-crested Cockatoos have clinical signs of PBFD in any one year. One flock of Sulfur-crested Cockatoos decreased from 120 individuals to 20 over a nine-month period. Many of the dead or dying members of this flock were diagnosed with PBFD. Half of the 20 birds in a free-ranging flock of Crimson Rosellas were found to have PBFD.<sup>273</sup> There does seem to be an increased occurrence of PBFD late in the breeding season in both captive and free-ranging cockatoo populations.<sup>315,316</sup>

### Transmission

Susceptible birds can be experimentally infected with the PBFD virus through the combined oral, intracloacal and intranasal routes.<sup>339,443</sup> Psittacine beak and feather disease virus was recovered in the feces and crop washings from various species of psittacine birds diagnosed with PBFD. During the test period, 26% (8 of 31) of the birds screened were found to be excreting PBFD virus in their feces, and 21% (3 of 14) of crop washings were positive for the PBFD virus. While the concentration of PBFD virus demonstrated in the crops of positive birds was low, the possibility of an adult transmitting the virus to neonates during feeding activities that involve the regurgitation of food and exfoliated crop epithelium deserves consideration. Virus that was recovered from the crop may have originated from infected cells located in the crop or esophageal epithelium, or may have been deposited in the crop after swallowing of exfoliated epithelium from beak or oral mucosal lesions. High concentrations of the virus also can be demonstrated in feather dust collected from a room where birds with active cases of PBFD are housed (see Figure 32.13).<sup>342</sup> It has been postulated that the

frequent demonstration of PBFD inclusions in tissues of the palate, esophagus, crop, intestines, bursa and liver probably accounts for viral shedding in the feces.<sup>282</sup>


The demonstration of high concentrations of virus recovered from a room where PBFD birds were being maintained implicates contaminated dust from any source as a major vehicle for the environmental persistence and natural transmission of the virus.<sup>342</sup>

Artificially incubated chicks from a PBFD-infected hen consistently develop PBFD suggesting that vertical transmission of the virus occurs. Because viremia has been shown to occur in infected birds, vertical transmission would be suspected.

Several reports suggest the possibility of asymptomatic adults producing progeny with clinical signs of PBFD in successive breeding seasons. These findings suggest a carrier state may exist with vertical or horizontal transmission of PBFD virus from parent to offspring or a genetic predisposition to the disease;<sup>187,316,317,386</sup> however, in most suspected cases of parent-to-offspring transmission, epizootiologic investigations indicate probable exposure to the PBFD virus occurring through sources other than the parents. The widespread use of viral-specific DNA probes to detect subclinically infected birds may provide more information on what role, if any, these birds play in transmitting the virus.

### Pathogenesis and Immunity

PBFD is a progressive disease with temporary remission in the occurrence of new lesions in the periods of nonmolting. Irregular photoperiods to which many companion birds are subjected may influence regular molting periods or the lack of them. The lesions of the beak may progress during the intermolt period.<sup>134</sup> It has been suggested that the virus depends on the multiplication of the host cells for its replication.<sup>236</sup> Except for reported recoveries in budgerigars, lorikeets, lovebirds, a pionus parrot and some macaw neonates, the clinically apparent form of PBFD virus is considered fatal (Ritchie BW, unpublished).<sup>306,309,316</sup> Most infected birds survive less than six months to one year after the onset of clinical signs, though some birds have been known to live over ten years in a featherless state. Death usually occurs either from changes induced by secondary bacterial, chlamydial, fungal or other viral agents, or from terminal changes that necessitate euthanasia.<sup>187,316,317,443</sup> Cockatoos with PBFD have been diagnosed with severe cryptosporidiosis infections, which are generally



**FIG 32.16** Cryptosporidiosis was diagnosed in a group of cockatoos with PBFV virus. In one bird, the infection was severe and extended from the small intestine to the cloaca. In general, cryptosporidiosis occurs only in animals that are immunosuppressed (courtesy of Kenneth Latimer).

considered to occur only in patients with immunodeficiencies (Figure 32.16).<sup>232</sup>

The predilection for birds to die from secondary or opportunistic pathogens has been interpreted to indicate an immunosuppression that is thought to be induced by damage to the thymus and bursa.<sup>187,308,316,386</sup> Only limited work has been performed to document the suspected immunosuppression; however, PBFV patients were found to have low concentrations of pre-albumin and gammaglobulin as indicated by serum electrophoresis.<sup>187</sup> Other investigations with serum electrophoresis in birds with PBFV virus indicated that some birds had hypogammaglobulinemia (usually birds with severe beak necrosis or other clinical abnormalities) and some birds had hypergammaglobulinemia (Ritchie BW, unpublished).

PBFV-positive birds with inclusion bodies located only within the nucleus of infected epithelial cells have been found to spontaneously recover. On the other hand, larger psittacine birds with intracytoplasmic inclusion bodies located in macrophages usually succumb to the disease. Because the macrophage is critical for the initial processing and presentation of viral antigen to the immune system, it can be postulated that the determining factor in whether an infected bird develops a chronic fatal PBFV virus

infection, or develops a protective immune response is based on how the body processes the virus before it begins to persist in the cytoplasm of macrophages (see Figure 5.4).<sup>339</sup>

Some birds exposed to the PBFV virus remain clinically normal and develop HI and precipitating antibody titers. In fact, the detection of anti-PBFV virus antibodies in most adult Psittaciformes of a susceptible species suggests that these birds were exposed to the virus at some point in their lives and that the exposure resulted in a subclinical infection with the development of an effective immunologic response (Table 32.11). The factors that determine whether a bird mounts an immune response or is fatally infected could depend on the age at the time of exposure, the presence and levels of maternal antibodies, the route of viral exposure and the titer of the infecting virus.

An age-related susceptibility to the virus has been suggested by some experimental transmission studies. Neonatal budgerigars infected at less than seven days of age were found to develop severe disease, while birds infected at 10 to 14 days were reported to experience lower levels of morbidity, and some remained asymptomatic.<sup>339,443</sup> It was suggested that this age-related susceptibility might be due to the ability of the neonatal bursa to take up particulate matter from the cloaca.<sup>355</sup> Other transmission studies have indicated that the apparent age-related resistance to the virus was due to the birds' not being followed through an appropriate incubation period and may have had nothing to do with an age-related resistance.<sup>339</sup>

#### Incubation Period

Infected chicks and fledglings may show the first signs of disease during their feather development after replacing the neonatal down. Following experimental infection, the minimum incubation period is 21 to 25 days.<sup>339</sup> The maximum incubation period may be months to years (Figure 32.17).

Rose-breasted Cockatoo chicks experimentally infected with PBFV virus have been reported to develop clinical signs of PBFV approximately four weeks after infection.<sup>443</sup> African Grey Parrot chicks infected at three to eight days of age became depressed by 30 days old and developed progressive feather dystrophy by 33 to 44 days old. Umbrella Cockatoo chicks infected at three to eight days of age became depressed by 40 days old and developed progressive feather dystrophy from 42 to 47 days old.

**TABLE 32.11** Information and HI titer of Clinically Normal, PBFD-Negative Birds Naturally Exposed to PBFD Virus

Species	PBFD Virus Exposure	HI titer
Umbrella Cockatoo	PBFD+ mate	1,280
Moluccan Cockatoo	PBFD+ bird in collection	2,560
Moluccan Cockatoo	PBFD+ bird in collection	1,280
Umbrella Cockatoo	PBFD+ bird in collection	80
Umbrella Cockatoo	PBFD+ bird in collection	640
Umbrella Cockatoo	PBFD+ mate	>5,120
Goffin's Cockatoo	PBFD+ mate	2,560
Cockatoo species	PBFD+ bird in collection	160
Cockatoo species	PBFD+ bird in collection	>5,120
Moluccan Cockatoo	PBFD+ mate	2,560


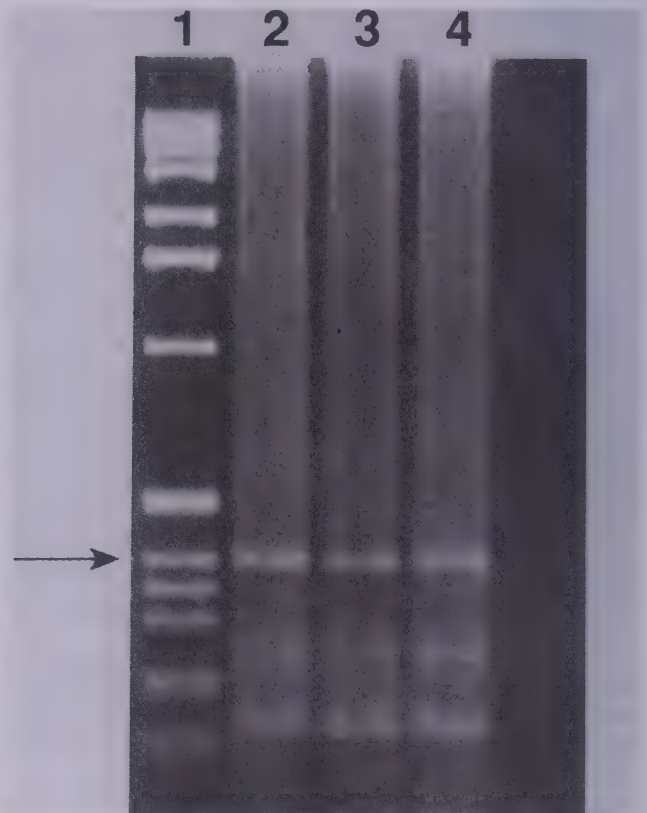
The time variance in developing clinical signs associated with PBFD among different psittacine chicks may be attributed to differences in concentrations of maternally transmitted antibodies, titer of virus in the inoculum or host responses to the virus.<sup>339</sup>

#### Clinical Disease

It appears that the avian species listed in Table 32.10 are of various susceptibilities; therefore, clinical (and pathological) signs may vary greatly. Generally, PBFD is a disease of young birds (up to three years), but older individuals (up to 20 years of age) may also develop clinical lesions. Older birds that develop clinical signs later in life may have been infected at a young age and remained latently infected.

In some Psittaciformes with pigmented feathers, abnormal coloration has been associated with histologic lesions consistent with PBFD virus infection. This is particularly true in African Grey Parrots, where affected feathers may be red instead of grey.<sup>18,338</sup>

The feather changes, typical lesions of the beak (if present), and more rarely also of the nails, occur symmetrically in most instances. Based on markedly different clinical presentations, peracute, acute and chronic forms of PBFD have been described (Figure 32.18).<sup>315,316</sup> The type of clinical disease appears to be influenced by the age of the bird when clinical signs first appear.



**FIG 32.17** Three eggs from a Bare-eyed Cockatoo hen with PBFD virus were artificially incubated. PBFD virus nucleic acid was detected in the blood of all three of the chicks by DNA probe at 20 days of age (lanes 2,3,4; lane 1 is a control). The lane 1 and lane 3 chicks developed clinical signs of PBFD starting at 32 days of age, and infections were characterized by a two- to three-week course of progressive feather changes followed by death. The lane 2 chick (below), shown here with the lane 1 chick, did not develop clinical signs of disease until 80 days of age. Because all three of these chicks were presumably infected by the hen, and all three chicks were blood-positive at 20 days of age, these findings suggest that the time from infection to the development of clinical signs can vary.



**FIG 32.18** Some birds can live with PBFV virus for many years. Birds with long-term infections frequently appear bald as feather pathology progresses through successive molts.

Peracute disease is suspected in neonatal psittacines that show signs of septicemia accompanied by pneumonia, enteritis, rapid weight loss and death.<sup>308</sup> Histologic lesions in these cases may be limited. The peracute syndrome appears to be particularly common in young cockatoos and African Grey Parrots. Peracute cases of PBFV may be missed if a complete necropsy and thorough histologic exam are not performed on young of susceptible species that die suddenly.

The acute form of PBFV, commonly called French moult in Australia, is most frequently reported in young or fledgling birds during their first feather formation after replacement of the neonatal down, and chicks as young as 28 to 32 days of age have been described with classic lesions (Color 32.2).<sup>309,315,339</sup> Acute infections are characterized by several days of depression followed by sudden changes in developing feathers, including necrosis, fractures, bending, bleeding or premature shedding of diseased feathers. In some acute cases of PBFV, birds with minimal feather changes may be depressed, develop crop stasis and have diarrhea, followed by death in one to two weeks.<sup>230</sup> Gross feather lesions in the acute form of the disease can be quite subtle with only a few feathers showing dystrophic changes. This clinical picture is particularly common in young Sulphur-crested Cockatoos and lovebirds.<sup>316</sup> In African Grey Parrots a non-regenerative anemia is reported (PCV=14-25%)

with typical inclusion bodies in the bone marrow;<sup>391</sup> however, it has not been determined if these changes are caused by the PBFV virus or if they are a result of secondary pathogens. Another observation is the irregular necrosis of the reticular cells in the lymphocytically depleted spleen, which would suggest permanent immunosuppression.

Experimentally infected Rose-breasted Cockatoo neonates became acutely depressed and anorectic approximately four weeks post-infection. Twenty-four hours later, the feathers appeared to lose their luster and became pale and brittle. Subsequently, dystrophic feathers began to appear as the neonates developed their adult plumage.<sup>443</sup> A similar disease progression has been defined for experimentally infected Umbrella Cockatoos and African Grey Parrot chicks (Color 32.5).<sup>339</sup> Chicks that develop clinical lesions while the majority of feathers are still in a developmental stage exhibit the most severe feather pathology. These birds may appear totally normal one day and exhibit 80 to 100% feather dystrophy within a week (Color 32.2).<sup>339</sup> The clinical progression of disease is less dramatic in neonates that develop clinical signs after body contour feathers are mature. In these birds, feather changes may be limited to the still-developing flight and tail feathers.<sup>309,317</sup>

Chronic PBFV is characterized by the progressive appearance of abnormally developed feathers during each successive molt. Gross changes include retention of feather sheaths, hemorrhage within the pulp cavity, fractures of the proximal rachis and failure of developing feathers to exsheathe. Short, clubbed feathers, deformed, curled feathers, stress lines within vanes and circumferential constrictions may also be present (Figure 32.19) (Color 32.3).<sup>309,317,443</sup> Replacement feathers become increasingly abnormal, and if birds live long enough they will eventually develop baldness as the feather follicles become inactive.<sup>309,317,443</sup> Free-ranging birds with severe feather pathology may have an accompanying brownish discoloration of the skin that is thought to occur from exposure of normally sheltered skin to sunlight.<sup>271,309</sup>

The distribution of dystrophic feathers within individual pterygia is variable and depends upon the stage of molt when the bird begins to develop clinical signs. In older birds, the first sign of PBFV is the replacement of normal powder down and contour feathers with dystrophic, necrotic, non-viable feathers that stop growing shortly after emerging from the follicle (Color 32.3). The disease then progresses to involve the contour feathers in most tracts, followed

by dystrophic changes in the primary, secondary, tail and crest feathers (Color 32.4). Primary feathers are usually the last to manifest the disease.<sup>187,309,317,339</sup> It has been assumed that the susceptibility of the powder down feathers is based on their consistent molt pattern, compared to the seasonal molt found in other feather tracts. In contrast to the classic presentation just described, some birds have substantial involvement of the flight, tail and crest feathers, with only minimal changes in the powder down feathers.<sup>187,271,309</sup>


Clinical changes in the beak and oral mucosa of PBFD-positive birds are characterized by progressive elongation, transverse or longitudinal fractures, palatine necrosis and oral ulceration (Color 32.11).<sup>187,309,317</sup> Necrosis of the upper beak progresses proximally to the palatine area and may involve the premaxilla in severe cases. The distal end of the lower beak is less severely involved.<sup>187</sup> If the powder down feathers in cockatoos are dystrophic, the beak may appear to be semi-gloss or gloss black, instead of its normal grey color. The beak may elongate or show transverse delamination or fractures, with or without bacterial or fungal infections in the clefts (see Figure 19.5). Necrosis of the palatine may follow. Likewise, deformities, fractures, necrosis and sloughing of the nails can be seen occasionally.<sup>230</sup>

Classically, beak deformities develop in birds following a protracted course of PBFD where substantial feather changes have occurred; however, some individuals develop severe beak lesions with relatively minor feather pathology, and cracking of the hard corneum at the distal portion of the beak may be the initial complaint requiring veterinary attention.<sup>187,309,317</sup>

Depending on the avian species involved and other factors that remain unresolved, beak changes may or may not be present. In one study involving 22 cockatoos of mixed Asian origin, birds older than one year of age had a lower incidence of beak lesions than did birds that were under one year of age.<sup>187</sup> Beak pathology does not routinely occur with some affected species, while with others, such as the Sulphur-crested Cockatoo, Rose-breasted Cockatoo, Bare-eyed Cockatoo and Moluccan Cockatoo, beak lesions are relatively common.<sup>187,271,309,316,317</sup>

### Pathology

Gross feather and beak changes associated with PBFD are described under clinical features. Predominant histologic lesions have been described in



**FIG 32.19** Feather lesions suggestive of PBFD virus include retention of the feather sheaths, hemorrhage within the pulp cavity, fractures of the proximal rachis and failure of the developing feather to exsheath; however, it must be stressed that any damage to the follicular epithelium can cause a similar appearing gross lesion. DNA probe testing (whole blood) or feather biopsy is necessary to confirm a diagnosis. Polyomaviral, adenoviral, bacterial and fungal folliculitis can cause similar lesions.

the feather shaft, where necrosis and ballooning degeneration of epithelial cells in the epidermal collar and epidermal, basal and intermediate zones of the developing rachis are seen.<sup>187,229,271,309,317</sup> The follicular epithelium may also be necrotic, but this lesion is less commonly reported.<sup>229</sup> Feather sheath hyperkeratosis prevents the feather from exsheathing and results in the terminal clubbing and midshaft constrictions of the developing feather, which are clinically evident.<sup>187</sup> Feather pulp lesions are characterized by suppurative inflammation, including perivascular accumulations of heterophils, plasma cells, macrophages and rarely lymphocytes. Granulomatous dermatitis with vesicle formation was described in a group of infected lovebirds.<sup>305</sup>

In peracute cases, histologic lesions may be limited to severe bursal or thymic necrosis with the presence of viral-induced inclusion bodies. Feather pathology in these cases may not occur, or may be limited to edema in the follicular epithelium (if present).<sup>187,229,271,306</sup>

Histologic lesions in the beak of PBFD birds are similar to those described in their feathers, including necrosis and hyperplasia of epithelial cells in the basal and intermediate epithelial layers. Hyperkeratosis and separation of the cornified outer layer from the underlying tissues and bone may also be evident, and are often accompanied by secondary necrosis and osteitis of associated tissues.<sup>187,271,306,309</sup>



In birds with beak pathology, necrosis and inflammation of the epithelial lining of the tongue, beak cavity and crop have also been reported.<sup>187,306,317</sup> Secondary gram-negative bacteria and fungi are commonly isolated from beak lesions and may be associated with acute or chronic inflammatory reactions.<sup>187,306,309,316</sup>

At necropsy, internal lesions are variable and differ with age and the type of secondary infection. In young birds, the cloacal bursa may be small with poorly developed folds and the thymus may reveal small lobes with pale necrotic tissue. In mature birds the spleen is frequently small and depleted of lymphocytes, and occasionally necrosis of the reticular cells can be observed. Extracutaneous inclusions demonstrated to be PBFD virus were found mainly in macrophages in the beak, palate, esophagus, crop, nail, tongue, parathyroid gland, bone marrow, Kupfer's star cells of the liver, spleen and thyroid gland. In the intestinal tract inclusion bodies were mainly found in epithelial cells.<sup>232</sup>

#### Inclusion Bodies

Basophilic intranuclear and intracytoplasmic inclusion bodies have been consistently demonstrated by hematoxylin and eosin staining in sections of the feathers, beak, thymus and bursa taken from birds with clinical signs of PBFD.<sup>187,229,271,306,317</sup> Immunohistochemical staining with viral-specific antibodies was used to confirm that intracytoplasmic basophilic inclusion bodies and some intranuclear inclusion bodies observed in hematoxylin and eosin-stained tissue sections contain PBFD viral antigen (Color 32.7).<sup>232</sup>

Intracytoplasmic inclusion bodies have been reported to be more consistently demonstrated, particularly in early cases, than are intranuclear inclusion bodies.<sup>187,271</sup> Intranuclear and intracytoplasmic inclusion bodies were identified in 23 of 32 birds examined in one study. In this group, intranuclear inclusion bodies were restricted to epithelial cells, and intracytoplasmic inclusion bodies were found only within macrophages.<sup>229</sup> Inclusion bodies have not been demonstrated in feather or beak samples taken from clinically normal birds.<sup>187,271,306,309</sup>

In addition to being localized in the feather and follicle epithelium and lymphatic tissues, PBFD viral inclusion bodies have also been demonstrated by viral-specific antibody staining in the beak, hard palate, bursa, thymus, tongue, parathyroid gland, crop, esophagus, spleen, intestines, bone marrow, liver, thyroid and adrenal glands.<sup>232</sup>

Intracytoplasmic inclusions are thought to originate in epidermal cells and attain their greatest size within macrophages, which engulf these infected cells.<sup>187,229,306,309</sup> It has been postulated that PBFD virus replicates in the nuclei of infected epidermal cells, and inclusions are then released when necrotic cells are phagocytized by macrophage-like cells in the pulp and epidermis;<sup>187,232,309</sup> however, the occurrence of viral antigen within macrophages in the bone marrow and within circulating monocytes suggests that these cells may be directly infected (Color 32.6).

#### Diagnosis

Feather lesions that appear grossly similar can be caused by PBFD virus and avian polyomavirus. Feather lesions seen with polyomavirus typically resolve after one or two molts whereas PBFD lesions as a rule progress from molt to molt. Dual infections with PBFD virus and polyomavirus do occur. Noninfectious causes of similarly appearing feather lesions include nutritional deficiencies, endocrine abnormalities and drug reactions.

PBFD should be suspected in any psittacine bird with progressive feather loss involving malformed feathers. A tentative diagnosis of PBFD involves the identification of basophilic intracytoplasmic or intranuclear inclusion bodies in the feather pulp or follicular epithelium from birds with clinical signs of dystrophic, nonviable feathers.<sup>187,229,271,306,316</sup> Basophilic intracytoplasmic inclusion bodies are considered diagnostic. Because several viruses may result in similarly appearing intranuclear inclusion bodies, a confirmatory diagnosis of PBFD requires the use of viral-specific antibodies to demonstrate PBFD virus antigen or the use of DNA probes to detect PBFD virus nucleic acid (Colors 32.6, 32.7).<sup>230,341</sup> Viral-specific DNA probes are most sensitive for detecting PBFD virus and can be used on biopsy samples to confirm an infection or on blood samples from a live bird to detect viremia (Color 32.6).

PBFD virus has hemagglutination activity for cockatoo and guinea pig, but not chicken or sheep erythrocytes. The HA test can be used to demonstrate and quantify the amount of virus recovered from PBFD-positive birds. The hemagglutination-inhibition (HI) test was found to provide a rapid, specific technique to assess the immunologic response of psittacine birds to the PBFD virus (see Figure 32.2). Precipitating antibodies can be demonstrated using an agar-gel immunodiffusion test (see Figure 32.1).<sup>340</sup> A suitable culture system for the PBFD virus has yet to be discovered.

The recommended sample to submit for DNA probe detection of active or subclinical (birds that are showing no feather abnormalities) infections is whole anticoagulated blood (0.2 to 1.0 ml of blood in heparin). In addition, in birds that have feather abnormalities, biopsy samples of diseased feathers should be placed in 10% formalin and held for further diagnostic testing should any be needed.

### Therapy

Numerous therapeutic trials have been attempted for PBFD virus-infected birds. Recoveries have been reported principally in birds with only intranuclear inclusion bodies. While feather lesions can be tolerated as long as the animal is kept in a controlled environment, beak lesions (also nail lesions) can be painful, particularly when secondarily infected. Euthanasia is suggested under these conditions. Secondary infections should be treated accordingly, and special examinations for cryptosporidiosis might be indicated.<sup>231</sup>

### Control

The chicken anemia agent (CAA), which is similar in ultrastructure and DNA composition to the PBFD virus, has been found to be environmentally stable, and infectivity remains unchanged when the virus is heated to 60°C for one hour and following treatment with detergents, enzymes and many commercial disinfectants.<sup>446</sup> While the environmental stability of the PBFD virus is unknown, it would be prudent to consider its stability to be similar to that described for CAA. Psittacine neonates, which seem to be most susceptible to the PBFD virus, should definitely not be exposed to areas that may have been contaminated by feces or feather dust from a PBFD-positive bird.<sup>339,342,443</sup>

A DNA probe for PBFD virus provides the best technique available for controlling infections until a vaccine is available (see Chapter 6). In an effort to reduce the number of cases of PBFD, all birds of a susceptible species should be tested to determine if they are latently infected with the PBFD virus. This is particularly true with respect to breeding birds, birds being sent to pet shops and birds being evaluated during post-purchase examinations. The test is simple, inexpensive and relatively noninvasive.

The DNA probe can also be used to screen walls, caging, air circulating ducts and equipment in the home or hospital to determine if PBFD virus is contaminating these surfaces. The appropriate sample for this test is a swab collected from the test location.

A negative DNA probe test for PBFD virus indicates that viral nucleic acid was not detected in the submitted sample. A positive DNA probe test for PBFD virus indicates that viral nucleic acid has been detected in the submitted sample. A positive test in a bird that has feather abnormalities suggests that the bird has an active PBFD viral infection. A positive blood test in a bird that does not have feather abnormalities may indicate that the bird is latently infected or that it recently has been exposed to the PBFD virus and is viremic. A bird that tests positive and has no feather abnormalities must be retested in 90 days. If the bird is still positive, then it should be considered to be latently infected. A negative test 90 days later would indicate that the viral nucleic acid was no longer detected in the blood and that the bird has probably eliminated the virus.

A companion bird that is diagnosed as a PBFD virus carrier can live a long life when provided a stressor-free environment and supportive medical care. These birds should be restricted from contact with other susceptible birds, particularly neonates. PBFD virus-infected birds should not be maintained in breeding facilities or where they may expose susceptible neonates or adults. Infected birds should be removed from the breeding collection and nursery immediately (see Figure 30.21).

It has been suggested by one author that this disease can be eradicated from a collection by removing patients with clinical signs of disease;<sup>134</sup> however, in the same discussion, this author mentions that the virus may have a two- to three-year incubation period, and that the virus genome can be detected in cells from clinically asymptomatic birds (carrier state). It is obvious that these conclusions are contradictory, and true eradication can be achieved only by testing for carriers.

High HI and precipitating antibody titers can be induced by injecting birds with beta-propiolactone-treated PBFD virus by the intramuscular or subcutaneous routes (Table 32.12). Immunized hens pass maternally derived antibodies to their chicks that offer at least temporary immunity to the virus (Color 32.5).

Because PBFD appears to be restricted in host range to psittacine birds and most of these birds are restricted to enclosures, it is likely that a widespread and continued testing and vaccination program can be used to control this disease in companion birds.

TABLE 32.12 Post-vaccination PBFD Titers

Species	Age	0	21
Moluccan Cockatoo	Adult	640/10	5120/80
Umbrella Cockatoo	Adult	160/1	5120/80
African Grey Parrot	Adult	320/0	5120/80
Moluccan Cockatoo	Adult	160/1	1280/10
Umbrella Cockatoo	Adult	80/0	1280/80
Umbrella Cockatoo	Adult	320/1	2560/80
Umbrella Cockatoo	Adult	80/1	2560/10
Amazon parrot	Adult	320/0	2560/10
African Grey Parrot	Adult	160/0	5120/80
Umbrella Cockatoo	45 days	<40/0	1280/0
Sulphur-crested Cockatoo	45 days	80/0	2560/0
African Grey Parrot	45 days	160/0	5120/0
African Grey Parrot	45 days	80/0	2560/0
African Grey Parrot	30 days	640/0	5120/0
African Grey Parrot	30 days	640/0	2560/0

Hemagglutination inhibition (HI) and precipitating antibody titers before and 21 days after vaccination with B-propiolactone-treated PBFD virus. Titers are listed as HI/precipitating.<sup>340</sup>

## Adenovirus

The Adenoviridae family consists of two genera: Mastadenovirus (contains mammalian strains) and Aviadenovirus. The two genera have a distinct group antigen. Most mastadenovirus strains have hemagglutination activity; most aviadenovirus strains do not. Aviadenovirus are divided into three groups according to common group antigens as detected by virus neutralization, growth in cell culture and nucleic acid characteristics.<sup>267,419,449</sup>

**Group I:** Fowl adenovirus (FAV) consists of 12 serotypes (numbered 1-12) that have been isolated from chickens, turkeys (3 serotypes), pigeons, budgerigars, Mallard Ducks, guineafowl, pheasants, geese (3 serotypes) and Muscovy Ducks.<sup>43,51,264,265,304,449</sup>

**Group II:** Turkey hemorrhagic enteritis virus, marble spleen disease virus and chicken splenomegaly virus. The common group antigen is distinct from that of group I.

**Group III:** contains only the virus associated with infectious salpingitis (Galliformes) and a similar virus isolated from ducks (see Color 29). This virus

subtype shares some common antigenic sites with group I adenoviruses. This group of aviadenoviruses has hemagglutination activity.

Adenovirus particles are 70 to 90 nm, nonenveloped and contain double-stranded DNA. Virions are icosahedral and are composed of 252 capsomeres arranged in triangular facets with six capsomeres along each edge. There are 240 nonvertex capsomeres (hexons) and 12 vertex capsomeres (penton bases). The latter contain projections (called fibers). Members of Aviadenovirus group III contain one fiber and group I has two fibers (one long and one small). There appears to be a relative relationship between the length of the fibers and the antigenicity of the virus.<sup>109,267</sup>

Adenovirus replicates in the nucleus producing basophilic intranuclear inclusions. The strains have been divided into two subgroups, A and B, on the basis of their cytopathogenicity (the same as with human strains): Subgroup A (eg, FAV 1, FAV 2, FAV 4, FAV 5, FAV 8); Subgroup B (eg, FAV 5, FAV 6, FAV 7, FAV 9, Turkey [TAV] 1, TAV 2,). The differentiation in subgroups A and B may also reflect some differences in pathogenicity. Subgroup A viruses induce refractive, small, roundish inclusions surrounded by a clear halo and tend to cause persistent infections with sporadic disease. Subgroup B viruses induce nonrefractive, irregular, eosinophilic inclusions that fill the nucleus and may cause epornitics, with a tendency not to persist in the host.



Aviadenovirus are distributed around the world, and many avian species of all age groups are known to be susceptible. Because the isolation of previously uncharacterized aviadenovirus is to be expected, it is likely that the current host range is incomplete.

### Transmission

Transmission is known to occur through the oral route, and inhalation is suspected. The virus is excreted mainly in the feces. Latently infected birds experience cyclic changes of the amount of humoral antibodies and virus titers and vice versa. Egg transmission plays a role in the maintenance of infections in a flock. A breeder hen may pass either virus or antibodies to the egg. The primary change in infected eggs is reduced hatchability.

### Pathogenesis

Infection with aviadenovirus does not necessarily produce clinical disease, although defined diseases have been characterized, and variability in virulence is known to occur. The factors that govern virulence



**FIG 32.20** A Moluccan Cockatoo was presented with a progressive neurologic disease characterized by ataxia, tremors, head pressing and death. Intranuclear inclusion bodies suggestive of adenovirus were demonstrated by histopathology (see Color 32.13).

have not been conclusively defined; however, in addition to intrinsic damage caused by virus replication in the cells, the structural proteins of the pentons are thought to be directly toxic to host cells. During the lytic cycle of many adenoviral infections, host synthesis of macromolecules (cellular DNA, various proteins, mRNA) stops causing the host cells to die.<sup>177</sup>

Aviadenovirus is generally considered to be an opportunistic pathogen. Identified triggering factors in chickens include immunosuppression caused by infectious bursal disease and the chicken anemia virus.<sup>267</sup> Reoviridae have been implicated as factors in nondomesticated avian species. Some highly virulent strains of aviadenovirus are capable of producing disease alone (hydropericardium syndrome). Aviadenovirus can trigger secondary infections by inducing mild histopathologic lesions without clinical signs. Common microscopic lesions are degeneration of hepatocytes, enterocytes and respiratory epithelial cells. These lesions allow secondary bacteria, fungi and protozoa to enter the host. Parvoviruses that require an adenovirus for replication have decreased *in vitro* growth and pathogenicity.<sup>29,267</sup>

#### Clinical Disease and Pathology - Group I

Many avian species are known or are suspected to harbor adenovirus. A large number of strains have not been typed and in many instances, the etiologic importance of the virus is unknown. Group I strains have been associated with respiratory signs, anemia, inclusion body hepatitis, intestinal disease, pancreatitis and nephropathies. Histopathologic lesions without clinical signs are also common. The majority of aviadenovirus infections may be latent and subclinical. In other cases, adenoviruses have been iso-

lated or detected by inclusion bodies or electron microscopy from birds with CNS signs (Figure 32.20) (Color 32.13).<sup>143</sup>

Gross lesions are nonspecific including tracheitis, swelling of the liver or kidneys and catarrhal enteritis. Histopathology reveals mononuclear cellular infiltrates in the lamina propria of the trachea, hypertrophy of the mucosal glands and finally loss of the epithelium. Liver lesions vary with the virulence of the strain, but may include vacuolated degeneration of the hepatocytic cytoplasm with lymphocytic infiltration in Glisson's triangles. In more severe cases, hepatocytes show intranuclear eosinophilic inclusions, which increase in size and become basophilic before developing a halo around the inclusion. In the pancreas, irregular necrosis, mainly of the exogenic cells, with and without intranuclear inclusions, has been described.<sup>143</sup> It should be emphasized that in avian species, inflammatory lesions generally develop more slowly than in mammals, and in many cases death occurs prior to inflammation so that hepatitis and enteritis may not occur.

#### Species-specific Considerations

- **Guineafowl:** FAV 1 is the principal isolate and will experimentally cause disease. The main lesion is necrotic pancreatitis, but some respiratory signs (air sacculitis) also occur. Intracerebral infections induce clonic-tonic type CNS signs. Young chicks are highly susceptible. Older birds are more resistant, and disease has been established only by parenteral routes.<sup>304,329,447</sup>
- **Japanese Quail:** An adenovirus was isolated from chicks with CNS signs. The strain could not be se-

rologically typed, but nucleic acid analysis showed that it is closely related to FAV 4.<sup>243</sup>

- **Quail Bronchitis (QB):** Quail bronchitis virus was first described in 1950 and only Bobwhite Quail (captive and free-ranging) are susceptible.<sup>297</sup> Mortality can reach 90% in young birds up to six weeks of age. Older quail show an age-linked resistance. The virus is serologically related to FAV 1, but nucleic acid sequences are different.<sup>243</sup> These nucleic acid differences might be the cause of an adaptation to Bobwhite Quail, a slow replication in chicken tissue and the failure of vaccination with CELO-type vaccines.

QB is highly infectious and spreads to young quail mainly through direct contact. Vertical transmission should be expected, although this route has not yet been confirmed.

Clinical signs include sudden death or signs of respiratory disease, such as tracheal rales, coughing, ballooning skin over the infraorbital sinus, sneezing, increased lacrimation and conjunctivitis. The severity of disease depends on the age of the host, and milder signs may be observed in birds older than three weeks. Gross lesions may not occur or can include catarrhal tracheitis with an excess of clear mucus in the air sacs or pulmonary edema.<sup>143,186,432</sup> Hepatic necrosis has been described.<sup>214</sup> Intranuclear inclusion bodies suggestive of adenovirus may be seen in the tracheal epithelium two to five days post-infection as well as in the epithelial cells of the bronchi. Proliferation of lymph follicles and lymphocytic infiltrations are evident.

- **Pigeons:** FAV 8 has been isolated from pigeons, and other reports have suggested infections based on histologic lesions from cases in which virus could not be isolated.<sup>121,265</sup> Virus particles morphologically suggestive of adenovirus have been reported in the nuclei of hepatocytes from pigeons although the typical paracrystalline arrays could not be demonstrated. The adenovirus failed to grow in culture but reovirus was isolated.<sup>120</sup> Pigeon herpesvirus has also been isolated from birds suspected of having adenovirus, suggesting that the role of FAV strains in causing inclusion body hepatitis and inclusion body enteritis in pigeons requires further documentation.<sup>265,411</sup> An FAV strain isolated from pigeons<sup>267</sup> did not cause lesions in chickens following experimental infection.<sup>259</sup>

Pigeons have been described with clinical signs of anorexia, a "crouching position" for one to two days, ruffled plumage, slimy green droppings, polydipsia,

polyuria, watery overload of the crop, vomiting and respiratory distress.<sup>80</sup> At necropsy, affected birds had hepatomegaly and splenomegaly, with the former being friable and mottled. In one case, the only lesion was swelling of the respiratory tract mucosa and in another, hemorrhagic enteritis and ecchymosis in the liver were observed. Histopathologically, liver degeneration or coagulative necrosis with basophilic intranuclear inclusion bodies was the main lesion. The kidneys sometimes showed degeneration of the tubular epithelium. In one case, intranuclear inclusions were also found in the pancreas.

Six strains of an adenovirus were recovered from these birds, four of which were serologically related to chicken adenovirus, and two of which could not be serologically typed. Interestingly, these strains were isolated from the pigeons with atypical macroscopic lesions.

A chronic enteritis was described in mainly young pigeons with some adults affected.<sup>36</sup> Diarrhea and lethargy were the main clinical signs. Necropsy lesions were nonspecific. Histopathologically, club-shaped, damaged villi in the duodenum and jejunum became vacuolated, pycnotic and desquamated. Intranuclear inclusion bodies containing adeno-like virus particles (basophilic and in part eosinophilic) may be seen in apical and medial enterocytes. Lymphocytic, heterophilic infiltrates occur in the intestine, liver and other parenchymatous organs.

Differences in clinical signs and pathology associated with adenovirus infections in pigeons suggest that more than one virus with varied organ affinity may infect these birds. Further studies are needed to elucidate the importance of adenovirus in pigeons.

- **Goshawk:** FAV 1 was isolated from a free-ranging Goshawk that experienced clonic-tonic type CNS signs and died shortly after being recovered from the wild. The brain showed neuronal necrosis, satellitosis and proliferation of glial cells.<sup>396</sup> Adenovirus was suspected in a captive American Kestrel with hemorrhagic enteritis and in a Merlin with hepatitis.<sup>379</sup>
- **Psittaciformes:** Clinical and histopathologic lesions suggestive of adenovirus infections have been described in several members of the order.

Pancreatitis and nephropathies have been the two main lesions described in lovebirds. Gross necropsy findings were enlargement of the proventriculus and the duodenum. Acute necrotizing pancreatitis with large basophilic intranuclear inclusion bodies in the

exocrine cells was the main histopathologic lesion. Similar inclusions were described in enterocytes. Adenovirus (serotype not reported) was isolated from Nyassa Lovebirds with inclusions in hepatocytes and splenocytes.<sup>132,143</sup>

Adenovirus-like intranuclear inclusions have also been described in the otherwise normal renal tubular epithelium of clinically normal lovebirds. In other birds, numerous inclusions were associated with tubular necrosis and subacute interstitial nephritis.<sup>246</sup> Renal lesions were also described in Masked Lovebirds with a severe edematous conjunctivitis (30% mortality).<sup>189</sup> The endothelial cells of the conjunctiva and renal epithelium contained inclusion bodies suggestive of adenovirus. Inclusions in the renal tubules have been shown to be located also within the rami ureterici.<sup>280</sup>

Adenovirus-like particles have been connected with acute onsets of mild diarrhea and lethargy in Eclectus Parrots. Hepatitis with subcapsular hemorrhage and enteritis (in some birds hemorrhagic) were the main lesions. Inclusions were evident in hepatocytes and enterocytes together with diffuse inflammatory invasion of the intestinal mucosa. Irregular, discrete interstitial pneumonia and rapid death were also described.<sup>326</sup>

Basophilic intranuclear inclusions were observed mainly in enterocytes of *Pionus* spp. and *Neophema* spp. with persistent torticollis and other CNS signs.<sup>247</sup> Clinical changes were similar to those described with paramyxovirus infections. Lymphoplasmacytic meningoencephalomyelitis and pancreatitis were the main histologic lesions.

Adenovirus was isolated from two budgerigars with individual histories of enteritis and sudden death.<sup>265</sup> An adenovirus epizootic of one year's duration was described in budgerigars, generally adults one to three years old, in Germany. Clinical signs included acute torticollis, opisthotonus, tremor and convulsions. Birds that were able to maintain sufficient orientation to eat and drink usually survived. Gross lesions were unremarkable. Nonpurulent encephalitis, proliferation of glial cells and degeneration and lysis of ganglion cells were the principle histologic lesions. Nonspecific hepatitis with infiltration of mononuclear cells was evident in prolonged cases. Adenovirus was isolated from two affected birds. One isolate was serologically related to FAV 2 and FAV 11, and the other to FAV 4.<sup>107</sup>

Restriction enzyme analysis of the DNA from these isolates revealed similarities to other FAV isolates; however, the budgerigar strains were found to contain unique nucleic acid sequences. Experimental infections resulted in the induction of histopathologic lesions in the absence of clinical disease. Adenovirus-like particles were demonstrated by electron microscopy in large basophilic intranuclear inclusion bodies in the hepatocytes of cockatiels with enlarged necrotic livers.<sup>372</sup>

An epizootic of adenovirus-induced hepatitis has been described in a group of Psittaciformes in a collection of zoo birds.<sup>47</sup> Affected birds included Green-cheeked Amazon, Patagonian Conure, Eastern Rosella, Hyacinth Macaw and a Lesser Sulphur-crested Cockatoo. Hepatitis and enteritis suspected to be caused by adenovirus has been described in Moluccan and Rose-breasted Cockatoos. Adenovirus was described as the cause of acute pancreatic necrosis in an Umbrella Cockatoo.<sup>122,305a,320a</sup>

- **Waterfowl:** An epornitic of adenovirus was described in captive Muscovy ducklings in France. Affected animals were lame and emaciated. Birds began to die suddenly at about 35 days of age, and mortality rates averaged 1 to 1.5% of the flock daily for about ten days. A serologically distinct adenovirus was isolated from affected birds.<sup>43</sup> Tracheitis (diphtheroid) accompanied in some cases by bronchitis and pneumonia was described in 10% of two- to three-week-old Muscovy ducklings in another outbreak. Adenovirus-like particles were located within the epithelial cells of the trachea.<sup>37</sup>

Three serotypes of adenovirus have been described in goslings;<sup>449</sup> but virus isolated from the cases did not produce clinical or pathologic lesions in experimentally infected birds. Inclusion body hepatitis was described in goslings with high mortality and adenovirus-like particles in the nuclei of the hepatocytes.<sup>335</sup> Adenovirus-like inclusion bodies have been found in hepatocytes of free-ranging Herring Gulls<sup>235</sup> and the Tawny Frogmouth.<sup>328</sup>

### Diagnosis

A definitive diagnosis based on clinical or pathologic changes is not possible. Virus isolation is best achieved from the feces, pharynx, kidneys and liver. Chicken embryo liver or kidney cells and embryonated chicken eggs are suitable for recovering FAV 1 (chickens). Serotypes can be identified using VN or plaque reduction assays. Adenovirus-specific DNA probes have been developed for demonstrating viral

nucleic acid in infected tissues and clinical samples (Niagro FD, unpublished).

Group-specific antibodies can be demonstrated by ID and ELISA. The presence of antibodies indicates that an infection has occurred but does not indicate what part, if any, an Aviadenovirus may have played in a disease process. Histopathology, together with *in situ* hybridization, electron microscopy or virus isolation are necessary for this differentiation. With the number of adenovirus serotypes, a monovalent vaccine would be of questionable value. Vertical transmission and the continuous cycle of viremia followed by antibody production in infected birds makes it exceedingly difficult to produce uninfected offspring.

### Group II

The adenovirus that cause hemorrhagic enteritis in turkeys, marble spleen disease (MSD) in pheasants (captive birds only, not documented in free-ranging birds), and chicken adenovirus group II splenomegaly are considered serologically identical;<sup>78,185</sup> however, restriction endonucleases can be used to show that there are genetic differences between the viruses isolated from varying hosts.<sup>78,448</sup>

In the Common Pheasant, MSD virus replicates mainly in reticular cells of the spleen. Young birds are most frequently infected between ten to twelve weeks of age. Acute death may occur without clinical signs or preceded by a brief period of anorexia and dyspnea caused by severe pulmonary edema. Grossly, the spleen may be enlarged two to three times its normal size and is frequently mottled with multiple, grayish, confluent foci. The lung may be congested, edematous and in rare cases, hemorrhagic. Histopathologically, the spleen shows a distinct lymphoreticular hyperplasia with intranuclear inclusion bodies in RES cells (also in liver, lung and proventriculus).<sup>143</sup> Extensive deposits of a slightly fibrinous material (moderately PAS-positive) may be present. These deposits are considered to be amyloid.<sup>185,442</sup> Multiple small foci of necrosis may be present in epithelial and endothelial cells in the lungs.

Suspected adenovirus infections in White and Pearl Guinea fowl are characterized by acute pulmonary edema, splenomegaly and ascites. The postmortem and histopathologic findings resemble those seen with MSD and avian adenovirus group II splenomegaly in chickens. Suggestive intranuclear inclusion bodies may be seen in hepatocytes, splenocytes and pneumocytes. Antigen could not be demon-

strated by cultural and serologic methods. Pearl Guinea fowl experimentally infected with pheasant or turkey group II adenovirus developed lesions that were identical to those described in a natural outbreak.<sup>66</sup>

### Diagnosis

The clinical and pathologic signs are suggestive of the disease. The principal rule-outs are various intoxications and reticuloendotheliosis. The virus is difficult to demonstrate in culture (lymphoblastoid B-cells derived from Marek-induced tumors are best for isolation). The agent forms intranuclear inclusion bodies, particularly in splenic cells, and the presence of viral particles consistent with adenovirus can be demonstrated by electron microscopy. Adenovirus-specific DNA probes designed to document infections in Psittaciforme birds can also be used in pheasants and chickens (Niagro FD, unpublished).

### Group III

The natural host of adenovirus group III appears to include various ducks from Europe and Asia that are asymptotically infected.<sup>30,54</sup> In contrast to other aviadenoviruses, group III strains have hemagglutination activity. Serologic evidence suggests group III strains may also infect turkeys, domesticated geese, Muscovy Ducks, chickens and Cattle Egret.<sup>142,251,267</sup> Like ducks, these hosts appear to become infected without developing clinical or pathologic signs. Adenovirus antibodies were demonstrated in flocks of guinea fowl laying soft-shelled eggs. Similar problems occurred when 86-week-old guinea fowl were infected orally with EDS 76 strain 127 adenovirus.<sup>141</sup> Experimental birds seroconverted following infection. Virus recovery is necessary for a definitive diagnosis. Cloacal swabs or material from the female genital tract are good diagnostic samples. HI using virus-specific antibodies can be used to confirm the presence of the virus in a cell culture. Group-specific antibodies cross-react with FAV, and the HI test is best suited for demonstrating group III specific antibodies.<sup>279</sup>

### Unclassified

Viral particles suggestive of adenovirus have been demonstrated electron microscopically from captive American Kestrels with hemorrhagic enteritis. The antigen does not react with aviadenovirus group II antibodies. Clinical signs include melena, regenerative anemia and high mortality. Gross lesions include

hyperplasia of the white pulp in the spleen and petechiation in the mucosa of the esophagus, colon and coprodeum. Histopathology reveals diffuse hepatocellular necrosis with two types of intranuclear inclusions: eosinophilic Cowdry type A and basophilic Cowdry type B. In addition, disseminated intravascular thrombi and necrosis of the myocardium may be evident.

A disease that clinically mimics MSD has been described in Blue Grouse. Nonenveloped, 100-110 nm viral particles have been observed in the nuclei of splenocytes. The disease has not been experimentally reproduced and it is uncertain if an adenovirus is involved. Clinical signs are lethargy, ruffled plumage, foamy, watery diarrhea and death. Some birds may develop rales or other respiratory signs. At necropsy, the lungs are dark, red and firm, and the spleen is enlarged with whitish foci. The lumen of the intestines may be filled with a brownish, liquid material. Histopathology reveals multifocal fibrinoid necrosis, destruction of lymphocytes and reticular cells with basophilic or eosinophilic inclusions within the nuclei of RES cells. In addition to congestion and edema of the lungs, interstitial pneumonia and fibrinous pleuritis may also be noted.<sup>143</sup>

## Parvoviridae

The family Parvoviridae consists of nonenveloped, single-stranded DNA viruses of hexagonal morphology with an estimated 32 capsomeres and a size of 19 to 25 nm. Members of the genus Parvovirus are self-replicating, in contrast to the genus Dependovirus, which require helper viruses. Parvovirus replicates in the nucleus of the host cells and depends on rapidly dividing host cells. Avian parvoviruses induce intranuclear inclusion bodies of the Cowdry A type, and form syncytia in cell cultures. Among others, parvovirus has been associated with disease in chickens and enteropathy in turkeys.<sup>218,406</sup>

### Goose Parvovirus Infection (Derzsy's Disease)

This virus has been associated with all major goose-farming countries in Europe and Asia. The main host is probably the domesticated goose, but the Canada Goose, Snow Goose and Muscovy Duck are also susceptible. Experimental infection is possible in cyg-

nets of the Mute Swan. The virus is strongly host-specific and requires rapidly dividing cells (DNA synthesis) to replicate. Currently, the virus is considered serologically uniform.

### Transmission and Pathogenesis

This virus is highly infectious, and transmission is possible horizontally via oral and nasal routes and transovarially by freshly infected, non-immune breeder geese. Latent infections in adults is epizootologically important. Non-immune goslings or Muscovy ducklings between 1 to 21 days of age are most susceptible to infection. In older birds (two to ten weeks), infections are characterized by mild, protracted signs or are subclinical and latent. Following entry into the host, virus is distributed to the target organs including the liver, spleen, heart, adrenal gland, thyroid gland and thymus. Therefore, viremia is normally not demonstrable. Virus is shed from the fifth to sixth day following infection, and shedding may persist in some individuals for approximately six months. The intensity, course and mortality rate of the disease is governed by maternal immunity; however, age-related resistance is independent of humoral antibodies beyond the age of four to six weeks. The half-life of the maternal antibodies is between two and one-half to three days.<sup>360</sup>

### Clinical Disease and Pathology

Anorexia and polydipsia followed by cessation of water intake are the earliest clinical signs. Goslings appear chilled and occasionally develop conjunctivitis, diarrhea and diphtheroid membranes on the tongue. Somnolence, weakness and giddiness occur prior to death (up to 100% mortality). In older birds that survive, down feathers may fall out, particularly on the neck, wings and back. The skin may be hyperemic and the uropygial gland swollen. The chronic disease is characterized by growth retardation, difficulties in standing or walking and occasionally, convulsions. An accumulation of ascitic fluid may cause a penguin-like posture. Newly developing feathers may be brittle.<sup>123,143,359</sup>

Clinical and pathologic signs may be influenced by the age and immune status of the host as well as concomitant infections with other goose viruses (see reovirus or "nephroenteritis") or opportunistic pathogens including bacteria, *Mycoplasma* spp. and fungi.

Gross lesions include hepatomegaly with subcapsular petechial hemorrhage and bile congestion together with a small, limp spleen and a highly enlarged thyroid gland. Chronic disease can cause the



formation of serofibrinous fluid in the abdominal cavity. Hemorrhagic fibrinous enteritis, pin head-sized necrotic foci in the pancreas, hemorrhage within the cloacal bursa, degeneration of the myocardium and viscous mucus in the nasal cavity and on the surface of the proventriculus may be noted.<sup>146</sup>

Histopathology reveals a serous hepatitis with necrosis of the hepatocytes and intranuclear inclusion bodies, which can stain eosinophilic or basophilic with HE. Perivascular infiltrations of inflammatory cells occur in prolonged cases and occasionally proliferations of connective tissue occur. Necrosis of the pancreas and edema of the lung are typical of the acute disease. Hyperactive follicular epithelium with a large quantity of cytoplasm and large, lightly colored nuclei are common in the thyroid gland. The follicles are either completely filled with colloid or empty. Bud-like proliferation of the epithelium can be seen at certain sites. There is no interstitial cellular reaction with inflammatory cells. Lesions in the myocardium including degeneration with loss of the striation and interstitial edema, especially around the capillaries, are common with chronic disease. An increase in histiocytes and lymphocytes can be observed in these areas.<sup>146</sup>

### Diagnosis

Liver, pancreas and thyroid glands are suitable material for virus isolation. Virus identification can be carried out with VN, ELISA or IF. Latently infected birds can be identified by demonstrating humoral antibodies. Antibodies appear five to ten days following infection and persist for approximately one year. Persistent titers indicate that the animal in question is a carrier or has been exposed.

Clinical signs associated with parvovirus in goslings are similar to those caused by reovirus and nephroenteritis, but the three diseases can be differentiated. Because mixed infections are possible, virus isolation might be necessary to clarify the inciting organisms. Reovirus infection of goslings causes predominantly respiratory signs and changes on the cutaneous mucosa and striated muscles (including heart muscle). Parvovirus infection of the gosling is a hepatic disease (with intranuclear inclusion bodies), small spleen and changes in the thyroid gland. Nephroenteritis of the gosling occurs later in life than the other two diseases and is characterized by hemorrhagic nephritis and enteritis.<sup>123,359,407</sup>

### Control

Because maternal antibodies successfully prevent the disease in goslings, vaccination of the breeder geese at least six weeks before the beginning of egg production is recommended. An attenuated strain, which is actually an apathogenic mutant, is available as a vaccine. This strain is effective only when given intramuscularly.<sup>217</sup> Breeding geese without antibody titers should be vaccinated twice. A booster vaccination might be necessary for the second half of the breeding season to prevent hepatitis in goslings hatched late in the breeding season.

### Myocarditis and Encephalopathy in Canaries

Myocarditis and encephalitis were described in association with a virus that morphologically resembled parvovirus in three adult canaries from different origins. It is unusual, however, that a parvovirus would cause disease in an adult bird.<sup>168</sup>

The clinical picture was different among affected birds and ranged from sudden death to depression, emaciation and ruffled plumage. Some birds had no gross lesions while others had splenomegaly (three times normal size). Histopathology revealed nonsuppurative myocarditis with intranuclear eosinophilic inclusion bodies. Neurons in the brain stem contained similar inclusions, but there was no inflammatory reaction in the brain. The enlarged spleen of one bird showed increased numbers of macrophages and amyloid deposits.<sup>168</sup>

## Hepadnaviridae

The Hepadnaviridae virion is 40 to 60 nm in diameter with an icosahedric, enveloped, symmetric nucleocapsid consisting of one highly immunogenic protein. The virus contains partially double-stranded circular DNA.<sup>368,430</sup>

Closely related taxons of Orthohepadnavirus (formerly hepatitis B virus) have been recovered from humans, ground squirrels, woodchucks and tree squirrels. Related avian taxons (formerly duck hepatitis B group now in the newly formed genus Avihepadnavirus) have been described in the Pekin Duck and domestic goose.<sup>177a</sup> Another strain has been recovered from the Grey Heron. Avihepadnavirus is

strongly host-specific, and infected birds should pose no danger to humans. Avihepadnavirus is less oncogenic than mammalian strains. It has been suggested that avian strains require co-carcinogenic factors to induce neoplasms. One of those hypothetical co-carcinogens could be, for instance, high doses of aflatoxins.<sup>393</sup> Infection with Avihepadnavirus is a triggering factor for clinical and pathologic changes of the new duck syndrome (see Chapter 33).

The Avihepadnavirus are distributed worldwide in commercial duck and goose farms. Generally, infections are subclinical in ducks and geese. Transmission takes place vertically and leads to chronic viremia without the development of humoral antibodies. This pathogenesis is different from human infections in which lesions are partially induced by the elimination of virus-infected cells by the immune system. This mechanism explains why experimentally infected ducks can develop mild hepatic lesions. The Grey Heron strains are different but related to duck and goose strains.

Infected birds with chronic viremia have extremely high viral titers ( $10^{11}$  particles/ml serum) so that the virus is directly demonstrable without enrichment procedures.<sup>430</sup> Demonstration of antibodies in birds with vertically derived infections is not possible. Serum and egg yolk are suitable material for diagnosis.

## Reoviridae

The family Reoviridae consists of three genera: Orthoreovirus,<sup>176a</sup> Orbivirus and Rotavirus.

### Avian Orthoreovirus

Members of the genus Orthoreovirus are divided into mammalian or avian strains. Orthoreovirus virions are nonenveloped, icosahedral, double-capsid particles measuring 75 nm in diameter. The genome is a double-stranded RNA segregated into at least three size classes.<sup>349</sup> The virus replicates in the cytoplasm of the host cells. Avian orthoreoviruses are serologically different, although most strains share a common antigen, which can be demonstrated by immunodiffusion. Hemagglutination activity is not present in avian strains. Because frequent cross-reactions are reported, it seems that avian orthoreovirus

strains exist as antigenic subtypes rather than as distinct serotypes.<sup>349</sup> At least 11 of these subtypes have been differentiated.

Avian orthoreoviruses occur worldwide; the current host range include chickens, pheasants, quail, turkeys, ducks, geese, pigeons, birds of prey, Psittaciformes and other companion and aviary birds. Two reovirus strains isolated from Muscovy Ducks were found to be closely related to each other, but did not cross-react with a chicken strain (BIII3). One of the isolated strains was found to be virulent for Muscovy ducklings while the other strain was avirulent.<sup>164</sup>

### Transmission

Ingestion of viral particles is probably an important route of infection, but respiratory transmission is also possible. Vertical transmission is epornitically fundamental in chickens and turkeys and has been proven to occur in Muscovy Ducks and domesticated geese. The methods of transmission for many avian reovirus strains are only speculative. Psittacine birds experimentally infected by IM injection were found to shed virus in the feces two days post-infection, with shedding persisting for 15 days. Pigeons infected orally with reovirus were found to shed virus in the feces two to five days post-infection.

### Pathogenicity

Orthoreovirus infections are prevalent in many avian species, but their role in the disease process for most hosts is uncertain. Replication of the virus takes place in the intestinal tract, and the role of orthoreovirus in a variety of enteric conditions in poultry has been discussed.<sup>349</sup> The pathogenesis of orthoreovirus infections has not been clearly defined, although strain differences in virulence are known to occur. Many strains may induce latent infections, which may impair the immune system and result in immunosuppression.<sup>350</sup> Chicks infected during the first week of life have a depletion of lymphocytes in the cloacal bursa, hyperplasia of various reticular cells and inhibition of lymphocyte immigration as well as hyperplasia of reticular cells in the spleen (Montgomery, unpublished). The occurrence of cryptosporidiosis in Bobwhite Quail infected with orthoreovirus also suggests an immunosuppressed state.<sup>237,239</sup> Infected chickens develop hypoglycemia presumably caused by lesions in the pancreas.<sup>112,258</sup>

Development of humoral antibodies may provide protection from the disease; however, fecal shedding occurs in persistently infected birds even though antibody titers are present.<sup>112,211</sup>

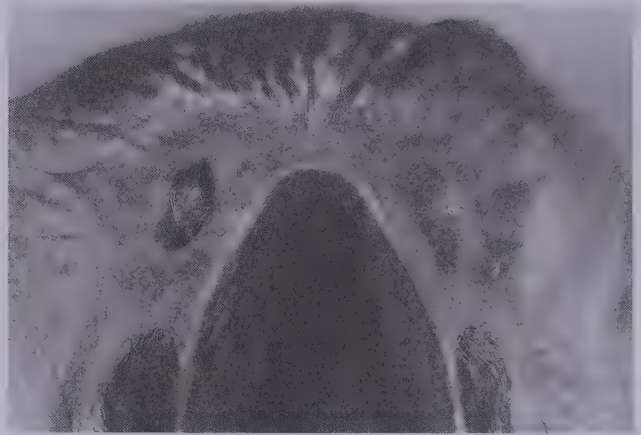
### Clinical Disease and Pathology

- **Psittaciformes:** The clinical signs reported in Psittaciformes vary among infected hosts. An infected cockatoo (species not given) and Grey-cheeked Parakeet developed non-specific clinical signs including emaciation, incoordination, labored breathing and diarrhea. Reovirus and *Chlamydia* sp., were recovered from the Grey-cheeked Parakeet. Only reovirus was recovered from the cockatoo.<sup>278</sup> Enteritis, liver congestion, necrosis and in some cases, a swollen spleen are common pathologic changes in African Grey Parrots (mortality up to 100%), Senegal Parrots, Jardine's Parrots, Alexandrine Parakeets (mortality up to 70%), Rose-ringed Parakeets, Hawk-headed Parrots, Rosy-faced Lovebirds, rosellas (up to 69% mortality) and Yellow-fronted Parakeets.<sup>61,62,275,423</sup> Chronic respiratory infections have been described in Amazon parrots (Figure 32.21).<sup>423</sup> African Grey Parrots may develop uveitis, although this is rare in uncomplicated reovirus infections.<sup>61,62</sup> Ophthalmic lesions are characterized by a fixed, dilated pupil and reticular hemorrhages followed by uveitis, hypopyon and fibrous exudates in the anterior and posterior chambers.

It has been suggested that Old World Psittaciformes are highly susceptible to orthoreovirus, while New World Psittaciformes may be infected but are more resistant to disease.<sup>61</sup> Clinical pathology associated with infections include anemia, leucopenia (with 90-100% lymphocytes), hypoalbuminemia, hyperglobulinemia and increased levels of AST and LDH late in the disease process. In many cases, orthoreovirus is not the only infectious agent involved in a disease process, complicating the interpretation of lesions; however, African Grey Parrots have been infected with isolated virus, fulfilling Koch's postulates.<sup>133</sup>

Necropsy findings in affected cockatoos, African Grey Parrots and other Psittaciformes include exsiccosis, swollen liver, swollen kidneys with urate depositions and splenomegaly.<sup>61,133</sup> Necrotic foci may be located in the lungs in association with thrombi.

Histopathologic findings include multifocal coagulative necrosis of the liver and occasionally nephritis with infiltrates of macrophages, heterophils and lymphocytes. Similar infiltrates may be noted in the lamina propria of the intestine.<sup>278</sup> The spleen is frequently congested with necrosis of the reticular sheaths around blood vessels. Splenic lymphocyte depletion may occur and is probably governed by the chronicity of the infection. The frequent occurrence of



**FIG 32.21** Reovirus has been suggested as a cause of chronic respiratory infections in Amazon parrots. Diagnosis requires virus isolation from samples collected from affected respiratory tissues.

thrombi are indicative of a consumptive coagulopathy.<sup>133</sup>

- **Pigeons:** In infected pigeons, the most frequent clinical signs are diarrhea and dyspnea.<sup>265,370,408</sup> Virus is found mainly in the cloaca, but can occasionally be recovered from the respiratory system. A catarrhal enteritis is a common necropsy finding. A strain isolated from a pigeon liver lesion did not produce recognizable macroscopic or histopathologic lesions following oral inoculation.<sup>161,416</sup> A serologic survey in Belgium and West Germany revealed carriers of antibodies among homing pigeons as 8% and 16%, respectively.<sup>161,416</sup>
- **Muscovy Ducks and Mullards:** Mullards are a cross between Muscovy Ducks and Mallards, raised (particularly in France) as table birds because of their fine meat. While Mallards are resistant to the disease, Mullards are highly susceptible. Growth inhibition and impaired development of the plumage has been described in affected three-week-old Muscovy ducklings. In severe outbreaks, up to 90% mortality may occur. At necropsy, pericarditis and air sacculitis of the anterior air sacs are the main findings, frequently accompanied by hyperplasia of the spleen and perihepatitis.<sup>108</sup> A similar disease has been described in Muscovy ducklings between ten days and six weeks of age.<sup>250</sup> Hepatomegaly and splenomegaly with slightly elevated pinhead-sized necrotic foci were consistent lesions. Histopathologic lesions, if present, included coagulative necrosis and a mild lymphocytic infiltration. Experimentally exposed geese, Pekin Ducks and chickens did not succumb to disease.

- **Geese:** A reovirus has been found to cause infectious myocarditis in geese.<sup>224</sup> Five- to twenty-one-day-old goslings may develop clinical signs following infection. Older birds appear to be resistant. After an incubation time of three to six days, sudden death or somnolence, anorexia, increased water consumption, mild nasal discharge and conjunctivitis, dyspnea and, more rarely, watery, grayish-white diarrhea can be observed. The body temperature decreases to 38°C. The skin of the beak and feet becomes brownish and peels off. Weakness of the legs caused by myositis and occasionally paresis of the neck musculature or tremors can be observed. Survivors are stunted. Muscovy Ducks were also found to be susceptible. In these birds, the virus replicates in the intestinal tract but does not cause clinical or pathologic lesions.

At necropsy, besides dehydration, a distinct dilatation and gray discoloration of the heart is seen, as well as pericarditis, catarrhal rhinosinusitis, pulmonary edema, air sacculitis of the thoracic air sacs and dystrophy of the liver.

Histopathology reveals Zenker's degeneration and necrosis of the myocardium and skeletal muscle, proliferation of the myocardial syncytium, inflammation that is restricted to the subepicardial connective tissue and as pericardial and subendocardial edema. Hemorrhagic interstitial nephritis or coagulative necrosis may also be noted.<sup>150</sup>

- **Finches (*Estrildidae* and *Ploceidae*):** Clinical signs in finches are associated with enteritis and swelling of the liver, which can be severe enough to be noted through the abdominal skin. At necropsy, disseminated yellowish, greasy or soft foci, which histopathologically represent focal coagulative necrosis, can be observed. Infiltration by monocytes and lymphocytes is seen in the liver, the kidneys and the lamina propria of the intestinal tract. In the spleen, destruction of the reticular cells can be observed as well as ecchymosis in the subcutis, epicardium and other serosal membranes.<sup>150</sup>

### Diagnosis

Lesions in ducks and geese can be similar to those caused by parvovirus and nephroenteritis, respectively. Cloacal swabs and samples from the rectum and affected parenchymatous organs are best for viral isolation. Demonstration of viral antigen in affected tissues is possible by IF; however, only positive results provide conclusive evidence because the test is not sensitive enough to demonstrate small numbers of viral particles.

The presence of virus in cell culture can be confirmed by the detection of group specific antigen in the ID test.

Most reovirus strains isolated from Psittaciformes show no serologic relationship with those in gallinaeous birds.<sup>61,275</sup>

Specific antibodies can be demonstrated by ID, but their presence is difficult to interpret because of the frequent occurrence of strains that are not pathogenic. A more than four-fold increase in titer of paired serum samples would be indicative of an active infection, but there might be some doubt as to the importance in a recent disease process.

### Control

Commercially available vaccines for poultry are ineffective in Psittaciformes because of antigenic variance among strains. An inactivated vaccine produced from a reovirus recovered from parrots was found to reduce losses associated with an outbreak. Live vaccines designed for use in chickens (viral arthritis) increased survivability (85% survivors if given 100 chicken doses per bird) when used in Muscovy ducklings.<sup>255</sup> Goslings may be provided with passive immunity at hatch by subcutaneous administration of hyperimmune serum.

The use of chlorhexidine in the drinking water (20 ml per gallon of water) was thought to reduce the transmission of reovirus infection in a flock of African Grey Parrots. Long-term use (up to 30 days) may be necessary, and there were no observable side effects from this length of chlorhexidine exposure.<sup>61</sup>

### Orbivirus

Orbivirus is a genus of the Reoviridae that depends on insects such as culicoides, phlebotomus and ticks for transmission. An orbivirus has been isolated from a cockatiel and a budgerigar.<sup>174</sup> The cockatiel died suddenly and at necropsy displayed degeneration of the myocardium, a swollen liver and spleen and cloudy air sacs. In the case of the budgerigar, dyspnea, photophobia and ruffled plumage was observed prior to death. Postmortem examination revealed atrophy of the pectoral muscles, catarrhal enteritis and a slightly swollen liver. Experimentally infected budgerigars developed severe greenish diarrhea for four to eight days with no pathologic lesions noted on postmortem examination. Infected birds seroconverted, and reisolation of the virus was possible from the feces.

The viruses isolated from both these birds were serologically related but were distinct from other orbiviruses tested.<sup>174</sup>

### Rotavirus

Rotaviruses have more clearly defined outer edges than other Reoviridae, which can be used to differentiate them by electron microscopy. The outer capsid may not be present in noninfectious single-shelled particles. These can morphologically resemble orbivirus and are about 10 nm smaller than the intact virus. The double-stranded genome has 11 segments. During replication within the cytoplasm, some particles appear to bud through ribosome-free areas of endoplasmic reticulum. Virus is released by cell lysis.<sup>270</sup>

Avian rotaviruses are thought to be serologically unique from each other and from mammalian rotaviruses. Only chicken and turkey strains have been classified.<sup>270</sup> Some avian group A rotaviruses agglutinate erythrocytes (human type 0 or guinea pig).

Rotaviruses are distributed worldwide and have been documented in chickens, turkeys, Helmeted Guineafowl, pheasants, ducks, pigeons and lovebirds. Avian strains are resistant to ether, chloroform, sodium deoxycholate, pH 3 and 56°C for 30 minutes.<sup>270,276</sup> The persistence of infectivity in the environment is not known.

#### Transmission and Pathogenesis

Rotavirus is excreted in the feces in high numbers, and can be transmitted by both direct and indirect contact. Ingestion may be the most important portal of entry. Infections in three-day-old poults suggest egg transmission, which has not been proven. The cross transmissibility between mammalian (including human strains) and avian strains is undetermined.

Rotavirus is a cause of enteritis and diarrhea in a variety of mammalian and avian species. The virus replicates mainly within the enterocytes of the small intestines. Some strains are known to replicate in the colon and cecum. Certain strains prefer the duodenum for replication, while others replicate in the upper portion of the jejunum. The virulence of the strains varies (in ducks they are nonvirulent). Because viral replication causes lysis of the host cell, the intestinal absorption in infected birds is dependent on the number of infected enterocytes. A decrease in the absorption of D-xylosis has been suggested as an indicator of enterocyte damage. Birds that over-

come infections develop intestinal immunity via IgA and humoral antibodies (IgG), which are also transferred via egg yolk to the chick. Humoral antibodies do not protect against infection, even in the newly hatched chick.<sup>270,286,357</sup> Cell-mediated immunity is necessary for full protection.<sup>357</sup>

Incubation periods are short (one to three days) in chickens and turkeys. No information is available for companion or aviary birds.<sup>270</sup>

#### Clinical Signs and Pathology

Infected ducks do not develop clinical or pathologic signs of disease.<sup>400</sup> A short-term (five- to eight-day), self-limiting, transmissible enteritis has been described in the Helmeted Guineafowl.<sup>303</sup> This virus was serologically not related to a bovine strain as other strains were. Pheasants and partridges, especially those infected as chicks, may develop diarrhea and stunting and have increased levels of mortality (up to 30%).<sup>129,408</sup> In infected pigeons, a watery diarrhea may occur.<sup>415</sup> Rotavirus antibodies have been demonstrated in approximately 10% of the pigeons examined. A rotavirus isolated from a lovebird caused the death of a chicken embryo following yolk sac inoculation. The lovebird showed no clinical signs.<sup>128</sup>

Necropsy findings are nonspecific and are restricted to the intestinal tract in uncomplicated cases. The lumen of the intestine is filled with watery fluid and some gas, and the walls may appear pale. Histopathology reveals cellular infiltrates into the lamina propria, vacuolization of the epithelial cells of the villi and loss of enterocytes from the villi.

#### Diagnosis

Infection with astrovirus and several genera of the Picornaviridae can cause similar clinical signs. The rotavirus causes a shortened disease with a rapid recovery. Survival depends on the titer of infecting virus and the age and species of the host. Because many avian strains have not been grown in cell culture, electron microscopy is still a common method of identification. The contents of the colon and cecae are examined following treatment with fluorocarbon and ultracentrifugation. The demonstration of viral RNA by means of electrophoresis is also possible. Serologic diversity among strains, difficulties in propagating the virus and the widespread occurrence of the virus make the detection of antibodies to the virus difficult to interpret.

## Birnaviridae

The virus of the infectious bursal disease is a member of this family. Disease is seen only in chickens. The virus destroys mainly the cloacal bursa of growing chicks causing a passing or (rarely) permanent immunosuppression (refer to textbooks on poultry disease).

## Coronaviridae

The family Coronaviridae contains only the genus Coronavirus. Recognized taxons are the infectious bronchitis virus (IBV), turkey coronavirus and at least nine mammalian species. A coronalike-virus isolated from Japanese Quail has not yet been characterized.<sup>302</sup> Isolates from guineafowl and pheasants are serologically different from chicken strains.<sup>124,287</sup> Coronavirus has been reported as a cause of disease in Psittaciformes.<sup>174</sup> An enterotropic IBV was recently recognized as being distinct from other serotypes of IBV.<sup>193</sup>

Coronavirus has a pleomorphic but mainly rounded morphology and is 90 to 200 nm in diameter. It is enveloped with club-shaped surface projections (peptomers) about 20 nm long. It contains a single-stranded RNA.<sup>213</sup> Coronavirus replicates in the cytoplasm of the host cells.

Coronavirus is rather unstable at room temperature and samples for isolation should be stored below -20°C. Shipment of infected material is recommended on dry ice or in 50% glycerol. Lyophilization, preferably in 10% glucose (also for deep freezing), provides adequate stability; however, lyophilized IBV has to be stored in a refrigerator for long-term survival. Coronavirus is sensitive to ether and chloroform, and it is assumed to be sensitive to commonly used disinfectants.<sup>213</sup>

IBV is distributed worldwide and is not antigenically uniform. Chickens are the main host and may develop respiratory signs, interstitial nephritis, visceral gout or egg shell problems with decreased albu-

men quality. In central Europe, antibodies against IBV have been demonstrated in owls and some Passeriformes.<sup>145</sup>

Coronal enteritis is distributed primarily in turkey-raising countries, and the turkey is the only recognized host.<sup>324</sup>

- **Pheasants:** IBV has been isolated from pheasants in Great Britain with some regularity.<sup>124,324</sup> Seven isolates are antigenically closely related, but differ considerably from 12 chicken IBV reference and field strains.

In adult birds, reduced egg production, poor egg quality, slight to moderate respiratory signs and low mortality associated with egg peritonitis, urolithiasis, visceral gout and swollen kidneys are typical. Mortality is highest in eight- to ten-week-old birds (up to 40%) with renal lesions being conspicuous.<sup>124,241,389</sup> An experimental infection of two-week-old pheasant chicks resulted in a short-term respiratory disease and production of long-term high antibody titers. Virus could not be recovered from the infected birds.<sup>124</sup>

- **Guineafowl:** IBV has been recovered from guineafowl with enteritis and hepatopancreatitis.<sup>20,96</sup> Anorexia and high mortality in young birds were common in affected flocks. Emaciation, pancreatitis, enteritis, dehydration and nephritis are common findings at necropsy. Clinical signs may start as early as three days of age. Experimental infections of chicks and guineafowl poults by the intranasal route resulted in mild respiratory distress and polyuria. The virus was characterized as an avian coronavirus but distinct from the Massachusetts serotype.
- **Psittaciformes:** Two coronavirus strains have been isolated from parrots (one unspecified species and a Cape Parrot). The two parrot strains appeared to be in the same taxon (which was not related to IBV and several mammalian coronaviruses).<sup>173</sup>

Preliminary studies indicated that the virus is pathogenic for both chickens and budgerigars. The Japanese Quail proved to be refractory. Principal lesions were associated with necrotic hepatosplenitis. One-day-old chicks were particularly susceptible and died. Older chicks and budgerigars survived at least four weeks in spite of severe lesions in the liver and spleen. Interestingly, the experimental infection was easily established by ocular exposure, and contact spread occurred with both chickens and budgerigars.<sup>173</sup>

- **Pigeons:** IBV has been isolated from racing pigeons.<sup>26</sup> The strain was serologically identical to chicken strains in Australia (ie, subtype B). Isolated virus caused respiratory disease in experimentally infected chickens.

Clinically affected pigeons showed ruffled plumage, dyspnea and excess mucus at the commissures of the beak. Eleven birds died during the first 24 hours following clinical signs. The rest of the flock (size not mentioned) recovered over the next two to three weeks. At necropsy, the birds were in average condition and had recently eaten, but the linings of the crop and esophagus were ulcerated. Mucoïd pharyngitis and tracheitis were seen, and the lower intestines contained fluid. Secondary trichomoniasis was probably responsible for part of the lesions in the upper digestive tract.

- **Ostrich Chicks:** A coronavirus was identified by electron microscopy in a group of two-week-old ostrich chicks with enteritis.<sup>99</sup> The history revealed weight loss, anorexia, lethargy and weakness. Several affected chicks died. Clinically, two chicks were approximately 5% dehydrated and showed loose droppings. Clinical pathology findings included hypoalbuminemia, low albumin globulin ratio, elevated AST activities, hyperglycemia, hyperkalemia, anemia and normal WBC counts with degranulating heterophils.

At necropsy, the proventriculus was enlarged, thin-walled and filled with ingesta. The ventriculus was empty. The lower jejunum was filled with a thick brownish paste and had thickened walls. The kidneys were mottled pinkish-white. Both tibiotarsal bones were soft and contained a large band of cartilage extending from the proximal growth plate into the metaphysis. Histopathology revealed hypotrophic villi and crypts of Lieberkühn containing cellular debris in the distal jejunum. Eosinophilic inclusion bodies could be recognized in the apical cytoplasm of enterocytes. The proventricular mucosa was thin and depleted in glands. The moderately swollen hepatocytes revealed increased, clear intracytoplasmic spaces. A pectoral focal myodegeneration, necrosis and mild mineralization was considered to be a nutritional myopathy. The bone lesions were comparable with tibial dystrophy in chickens. The cloacal bursa showed a depletion of lymphocytes. *E. coli*, *Aeromonas* sp. and *D-Streptococcus* sp. were isolated from the intestine and the liver. Unsuccessful therapy included systemic support (fluids, bis-

muth subsalicylate, tube-feeding and trimethoprim-sulfamethoxazole).

- **Japanese Quail:** A coronalike-virus was isolated from Japanese Quail with respiratory signs.<sup>302</sup> The virus replicates in the yolk sac of the embryonated chicken egg and in chicken embryo liver or kidney cells. It was classified as a coronavirus based on morphologic and physicochemical studies. Serologic examinations revealed that the virus is not related to other avian or mammalian strains.

## Togaviridae and Flaviviridae (Arborvirus A and B)

These viruses are spheroid, enveloped (lipid-containing) particles, 40 to 70 nm in diameter, with a genome of a positive-sense, single-stranded RNA. The virus replicates in the cytoplasm. Most of the Togaviridae and Flaviviridae isolated from birds are arthropod-borne viral taxons, which implies that they can be transmitted by arthropod vectors and that the virus in question can replicate in the arthropod host. In birds, ornithophilic arthropods are the main vectors. A strict host specificity might be confused with "spillover" hosts because of a habitat rich in potential arthropod vectors. Only the more important members of the group are described. For other avian arborviruses refer to Ianconescu.<sup>182</sup>

### Eastern and Western Equine Encephalomyelitis (EEE, WEE)

EEE (genus Alphavirus of the Togaviridae) is mainly transmitted by *Culiseta melanura*, but may also be transmitted by other mosquitoes (*Aedes* spp. and *Culex* spp.). For WEE (genus Alphavirus of the Togaviridae) the main vector appears to be *Culex tarsalis*. Both viral taxons are serologically distinct but some cross-reaction does occur. EEE and WEE occur mainly in the Americas, but cases have been reported on other continents. Viral isolates or antibodies against both EEE and WEE viruses have been recovered from more than 60 avian species, with antibody titers being common in various species of birds from aquatic habitats. Rates of infection vary from 25 to 100% depending on the host. Ducklings of *Anas platyrhynchos* are susceptible to natural infection

only during the first 18 days of life, while many gallinaceous birds are always susceptible.

Infections in quail species, pheasant species and many New World finch species are characterized by a short, low-titered viremic phase in which birds remain clinically normal and develop effective antibody titers. The House Sparrow, which has been introduced only recently in the New World, develops a long and high-titered viremia, and chronic carriers may be observed. In addition to the natural host, (the Yellow-crowned Night Heron), the House Sparrow is also considered a reservoir of the virus. EEE and WEE produce cross-reacting antibodies, which may reduce the duration and titer of viremia and result in a rapid antibody response in birds that are immune to one virus and infected with the other.<sup>114,182,346</sup>

### Pathogenesis

The virus can be ingested by mosquitoes with the blood of infected hosts from 24 hours post-infection throughout the viremic period (average two to five days) and transmitted to new hosts 7 to 20 days later. The hemagglutinating virus is probably distributed by erythrocytes through the whole body including the brain. Encephalomyelitis mainly develops in young birds.<sup>152</sup> Infections principally occur through insect bites, but horizontal spread following feather picking and other forms of cannibalism have been shown to occur in pheasants. The virus is shed in the feces and occurs in the feather quills. Debeaking, which is not recommended for humane reasons, helps to limit the horizontal distribution of the virus in pheasants.<sup>346</sup>

### Clinical Disease, Pathology and Diagnosis

Outbreaks of EEE are seen mainly in pheasants, but also have been documented in ducks, Chukars, turkeys, Whooping Cranes, emus, finches and pigeons. These birds may die peracutely or acutely with mortality of up to 80%, depending on the age. An age-linked resistance has been demonstrated in pheasants beginning at 28 days. Clinical changes in a group of infected Lady Gouldian Finches included severe paresis and dyspnea.<sup>69</sup> Lesions caused by WEE are rare, but are essentially the same as those due to EEE: depression, incoordination, paresis and paralysis, torticollis, tremor, polydipsia and somnolence. Mortality rates in turkeys with ataxia and paralysis is about 6% whereas quail show up to 90% mortality. Clinical chemistry tests reveal anemia with normal numbers of leukocytes. AST, LDH and uric acid values are distinctly elevated. EEE has been associated with the acute onset of depression, profuse hemorrhagic enteritis, anorexia and ataxia,

followed by prostration and hyperemesis prior to death in emus.<sup>409</sup>

At necropsy, EEE and WEE lesions are similar (swollen liver, mucoid duodenitis, dehydration) in most species. In the Whooping Crane, a clear yellow fluid is seen in the anterior abdominal air sac, and diffuse necrosis is present in many parenchymatous organs. Pheasants typically develop a neurotropic disease, while lesions in chickens are mainly myocardiotropic.<sup>346</sup> Histopathology reveals a nonpurulent encephalitis with edema, meningitis, perivascular infiltrates, diffuse gliosis (also in the spinal cord) and necrosis in the cerebral cortex.<sup>152</sup> Histologic changes occur principally in the rostral brain with a "descending" tendency, which stands in contrast to other avian encephalitis with a typically "ascending" encephalitis.<sup>346</sup>

In Lady Gouldian Finches, necropsy findings included consolidation in the lungs and a pale liver and kidney. Histologic lesions included hemorrhage, bronchopneumonia and multifocal centrolobular hepatitis (brain was not submitted for histopathology).<sup>69</sup>

### Diagnosis

Because EEE and WEE viruses are sensitive to temperature, pH and many solvents, transport of virus for isolation is difficult. Homogenates of blood, liver, spleen and brain are best for virus isolation. The virus can be identified in cell culture by HI, ELISA, radioimmune assay or molecular hybridization. Humoral antibodies can be identified by the same methods; however, IgM can persist longer than IgG and methods for demonstrating IgM should also be used.<sup>140</sup>

### Treatment

Administration of hyperimmune serum was not shown to have any effect on mortality levels in infected pheasants.<sup>346</sup> Emus should be treated symptomatically with fluids, vitamins (probably vitamin K) and supportive alimentation.<sup>409</sup>

### Control

Control of insects, mites and ticks is important in preventing infections. Sentinel birds (some pheasant chicks) may be used to indicate the presence of infected mosquitos. There is some conflicting evidence on the use of vaccines. Formol-inactivated vaccine for horses (five pheasants per one horse dose) is reported to be efficacious (national legal implications notwithstanding). A formalized bivalent chicken embryo vac-



cine was found to protect only 60% of the experimentally vaccinated birds.<sup>346</sup>

Several recommendations have been made to vaccinate ratites in endemic areas with an inactivated equine EEE vaccine.<sup>b</sup> Neither the efficacy nor safety of this vaccine when used in ostriches has been established. Written permission should be obtained from the insurance carrier of an ostrich before vaccination is carried out. The recommended vaccination protocol includes vaccination at three months of age followed by a booster one month later and every six months thereafter.<sup>409</sup>

### Zoonotic Potential

Human disease is rare and occurs following bites from infected mosquitoes. EEE and WEE both cause an acute infection of the CNS ranging from mild meningoencephalitis to lethal encephalitis or encephalomyelitis. In endemic areas, extensive vaccination of horses has reduced the levels of infection in humans.

### Venezuela Equine Encephalomyelitis (VEE)

The causative agent of EEE is a member of the genus Alphavirus (Togaviridae). Birds play a minor role; the main reservoir is rodents. Vectors are *Culex* spp. with preference for rodents. However, in swamp areas some egrets and herons are known to be carriers. The main avian reservoir is the Striated Heron.<sup>114</sup> Human cases are characterized by a general benign course with acute but short fever, headache, myalgia, athralgia, lymphadenopathy and frequently exanthema, but rarely CNS signs or hemorrhage.

### Avian Viral Serositis (AVS)

A toga-like virus is suspected to cause a disseminated serositis in some Psittaciformes.<sup>104</sup> Electron microscopic studies of infected cell cultures revealed viral nucleocapsids (25-31 nm in diameter) accumulating near intracytoplasmic and plasmatic membranes. Mature enveloped particles are 45 to 54 nm in size.

The host spectrum currently includes several juvenile macaw species, macaw hybrids and a Rose-ringed Parakeet. Experimentally, chickens, mice and rats were susceptible to infections. Interestingly, all the naturally affected birds came from nurseries or were parent-raised on farms where neuropathic gastric dilatation was endemic, and many of the contact birds were known to have died from this disease.

TABLE 32.13 Pathologic Changes Associated with AVS

Liver	Multifocal degeneration (may be vacuolar), hepatocellular necrosis
Lung	Interstitial pneumonia and edema, bronchitis, pleuritis
Proventriculus/ventriculus	Lymphocytic proventriculitis, multifocal myositis and necrosis, lymphohistiocytic myositis
Serosa	Mesenteritis and serositis (intestinal, hepatic)
Spleen	Heterophilic infiltrates, multifocal lipogranulomas, lymphoid necrosis
Brain	Focal cerebral meningitis, necrotizing encephalitis, nonsuppurative encephalitis
Bursa	Lymphoid necrosis
Heart	Fibrinous epicarditis, lymphohistiocytic epicarditis and myocarditis, degenerative necrosis
Skeletal muscle	Multifocal myositis with necrosis, lymphohistiocytic myositis

Various histologic findings in a group of naturally infected macaws and a Ring-necked Parakeet and experimentally infected chicks with avian serositis virus. Adapted from Gaskin J, JAAV 5:27-34, 1991.<sup>104</sup>

### Clinical Signs and Pathology

Affected birds die acutely or lose weight and have distended abdomens containing ascitic fluid (Color 32.18). Some birds develop respiratory distress (Figure 32.22).

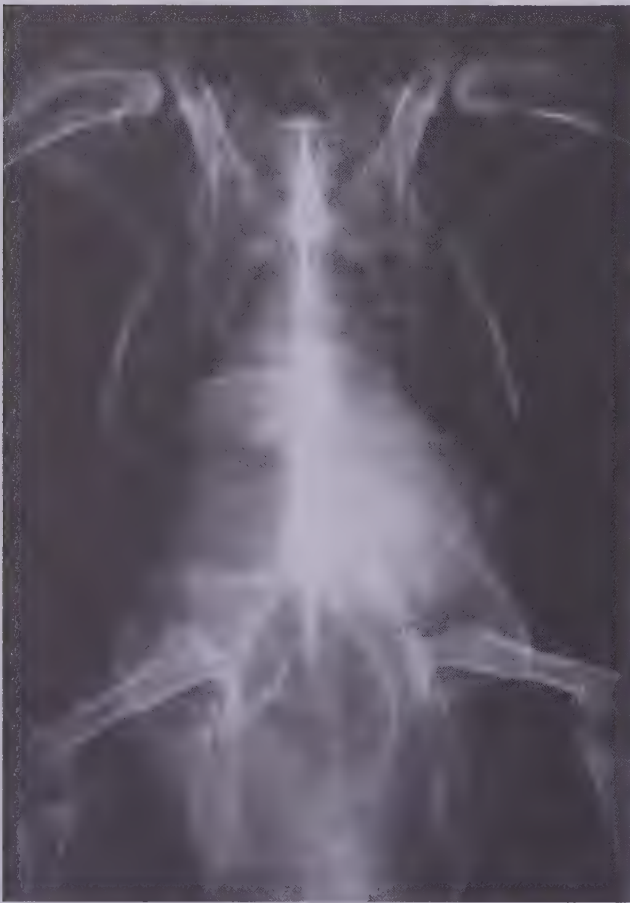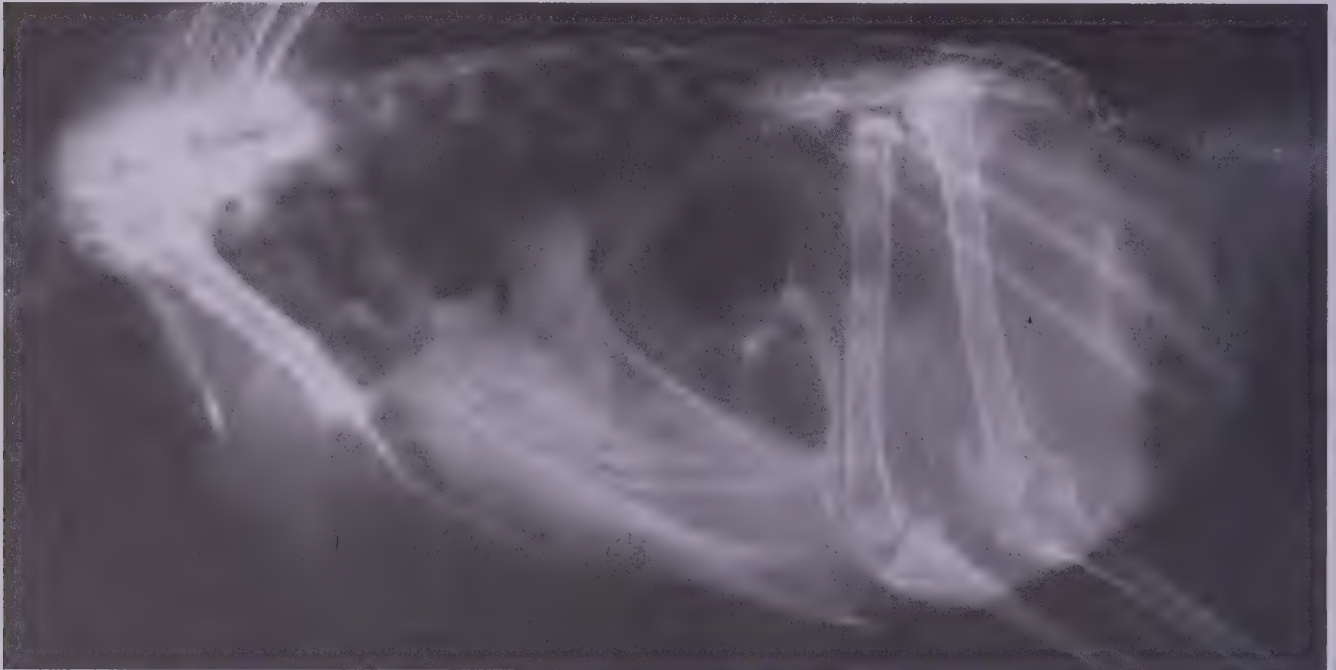
At necropsy, the presence of serosal fluid in the abdomen with or without fibrinous clots was the prominent finding. In some cases, the liver was swollen and the lungs edematous (Color 32.16).

Histopathology revealed multifocal degenerative lesions (some vacuolated), necrosis of hepatocytes, interstitial pneumonia and edema, lymphocytic proventriculitis and splenic lymphoid necrosis (Table 32.13).<sup>104</sup> In experimentally infected chicks lymphoid necrosis was common, which may result in immunocompromised birds.

The importance of this virus for parrots and any role this virus may play in neuropathic gastric dilatation require further investigation. Viral particles assumed to belong to the Togaviridae have been described in chicken embryo fibroblasts and also in the epithelial cells of the jejunum and the pancreatic duct in broiler chickens.<sup>100</sup>

### Rubivirus, German Measles

Rubivirus (formerly rubellavirus) is classified as a member of the Togaviridae. It is not known to cause disease in any avian species. However, antibodies indicating a carrier state with possible shedding of



**FIG 32.22** Ileus and severe bowel loop distension in a Blue and Gold Macaw with avian viral serositis (see Color 32.18). Note the cranial displacement of the proventriculus and ventriculus.

the virus have been found in urban pigeons (1.2% of population) in Germany.<sup>161</sup> In Munich, antibody titers average 1:16 and the carriers may average 7% of the birds examined.<sup>79</sup> Because rubivirus is a human pathogen, the occurrence of antibodies in free-flying urban pigeons suggests that these birds may be a reservoir for human infections. On the other hand, it has been suggested that pigeons may be infected by virus-shedding humans.<sup>161</sup>

#### ■ Israel Turkey Meningoencephalitis (ITM)

ITM virus belongs to the flaviviridae. *Aedes aegypti* and *Culex molestus* are the main vectors. The disease was initially described in northern Israel (in season with its vectors), but has now been documented in southern Israel and South Africa. The main host is the domesticated turkey, which under field conditions becomes sick after ten weeks of age. Poults and Japanese Quail are highly susceptible experimentally. The incubation period is five to eight days following experimental infection.

Clinical changes include progressive paresis and paralysis and spastic, uncoordinated movements. Mortality averages 10 to 30%, but can reach 80% in some flocks. Breeders can show a significant drop in egg production. Necropsy findings are unremarkable. Histopathology reveals a meningoencephalitis with perivascular and submeningeal lymphoid infiltration. Clinical and histologic changes are similar to

those described with EEE virus, WEE virus and Newcastle disease virus.

The ITM virus can be detected in the blood and various organs from 24 hours up to 8 days following infection. Blood and parenchymal organs can be used for virus isolation. Virus identification in cell culture can be accomplished by VN. Serologic diagnosis can be made in survivors by using the HI test with goose erythrocytes and an antigen made from infected mouse brains.<sup>182</sup> An attenuated (quail) live vaccine is available and reported to be effective.

### ■ Louping Ill Virus Infection

The Louping Ill virus belongs to the Flaviviridae and is serologically related to the Siberian tick encephalitis virus (Russian spring-summer encephalitis) and the Central European tick-borne encephalitis virus. *Ixodes ricinus* ticks are the main vector.<sup>332</sup> The established avian host spectrum includes the Willow Grouse and the subspecies Red Grouse, Rock Ptarmigan, capercaillie, Black Grouse and the Common Pheasant. The first three birds discussed are very susceptible and usually develop CNS signs. The most susceptible birds inhabit moorland and tundra, compared to the less susceptible species that inhabit woodland and forest areas.<sup>332</sup>

### ■ St. Louis Encephalitis (SLE), Japanese B-Encephalitis (JBE), Murray Valley Encephalitis (MVE)

The agents belong to the family Flaviviridae. They occur on three different continents and are serologically related. Birds living in the breeding grounds of the vectors (for SLE: *Culex quinquefasciatus*, *C. pipiens*, *C. tarsalis*; for JBE: *C. tritaeniorhynchus*, *C. pipiens*, *C. gelidus*; for MEV: *C. annulirostis*, *C. tarsalis*, *Aedes* spp.) are important reservoirs. There are more than 30 species of susceptible birds that do not become sick. Avian reservoirs include Brown-headed Cowbird, House Sparrow, some egret and heron species, and in Australia, ibises and cormorants.<sup>114</sup> Outbreaks of SLE in humans can be predicted by an increase of seroconversion in sentinel birds and can be prevented or abated by controlling mosquitoes.<sup>182</sup> The human disease is similar to EEE.

### ■ Other Arboviruses

Table 32.13a gives a survey on the viral groups, the host spectrum and the main vectors. None of the birds cited in the table develop disease, even if viremic. Migrating birds are responsible for the distribu-

tion of the West-Nil virus outside the African endemic area. Because virus or antibodies can be documented in nonmigratory birds in new areas, endemic vectors are at least transitory transmitters. The influence of birds in distributing virus of the Bunyamvera group is limited to the function of transport hosts. Migrating birds carry infected ticks. The Crimean-Congo hemorrhagic fever is transmitted this way.<sup>114,182</sup>

The human disease by Siberian tick encephalitis virus resembles EEE. West-Nil fever is a mild febrile disease in humans and has a promising prognosis. CNS signs occur only rarely, but maculopapular exanthema and lymphadenitis are more common. Crimean-Congo hemorrhagic fever causes clinical signs in humans. The Uukuniemi virus can cause febrile conditions partly with hemorrhage and CNS signs. The California encephalitis group virus (important member: LaCrosse fever) causes clinical conditions similar to VEE. The Tahyna virus shows signs such as fever, headache, vomiting, pharyngitis and more rarely, interstitial pneumonia.

TABLE 32.13a Avian Arboviruses — Zoonotic Potential

Viral Group	Avian Hosts	Important Vectors
Flaviviridae Tick-borne encephalitis; European, Far Eastern subtype	Guillemot; probably other bird species	<i>Ceratixodes putes</i> , <i>Ixodes</i> spp.
West-Nil virus	At least 27 avian species, including migratory birds and domestic pigeons	<i>Aedes</i> spp., <i>Culex univittatus</i>
Bunyaviridae Crimean-Congo hemorrhagic fever	Birds refractory, only transport host for infected ticks	<i>Hyalomma</i> spp.
Uukuniemi virus	Passerine migratory birds (5 species)	<i>Ixodes</i> spp.
California encephalitis virus	Chicken, Canada Goose	<i>Aedes triseriatus</i>
Tahyna fever virus	Chicken, Starling	<i>Aedes</i> spp., <i>Culex modestus</i>
Reoviridae Kemerovo virus	Passerine migratory birds particularly Redstarts	<i>Ixodes</i> spp.

## Rhabdoviridae

Birds are not considered natural reservoirs for the rabies virus, but they can nonetheless develop active infections while remaining asymptomatic. Virus isolation has been reported from common buzzards, Goshawks, ducks, a Red Kite and a Barn Owl.<sup>152</sup> Rabies virus infections have been experimentally reproduced in hawks, falcons, ravens, songbirds, pigeons, geese, ducks, chickens and peafowl.

Rabies antibodies have been described in free-ranging populations including Prairie Falcon, Goshawk, Golden Eagle, Short-eared Owl, crow, raven and starling.<sup>126</sup> In one survey, rabies virus titers were detected in six orders of birds representing 22 species. Twenty-three percent of the raptors had titers and eight percent of the non-predatory scavengers including starlings, crows and ravens had rabies antibody titers. These findings suggest that viral exposure occurs through contact with infected prey species.

Infection may occur from bites or from ingestion of infected prey. The virus spreads from the area of trauma via endoneural lymphatic vessels into the gray matter of the CNS. The self-limiting nature of the virus in avian species is believed to be due to a rapid production of antibodies. VN antibodies can be demonstrated within the neural tissue and can neutralize freshly replicated virus released from the neural cells. This explains the limitation of the infection to one area and the inhibition of viral distribution throughout the body.

The natural incubation period in ducks is three weeks to eleven months.<sup>152</sup>

### Clinical Disease and Pathology

The clinical course in species naturally and experimentally infected can take 2 to 42 days. A short excitable period with jumping, crying, trying to flee, aggressiveness toward humans and epileptiform convulsions is followed 24 hours later by ataxia, weakness of the limbs, falling on the flanks and, finally, flaccid paresis (including head and neck). Two weeks later somnolence, apathy, compulsive movements and death can occur. Spontaneous recovery has also been reported.<sup>152</sup>

At necropsy, anemia, cachexia and hyperemia of the brain are noted. Histopathology reveals a nonpuru-

lent encephalitis, which is distinct only two weeks after the outbreak of the clinical disease. Negri bodies are not regularly found. There has been no documented case of human rabies from an avian exposure.

## Paramyxoviridae

The Paramyxoviridae family consists of two subfamilies:<sup>325a</sup> Paramyxovirinae with the genera Paramyxovirus and Morbillivirus (mammalian only); and Pneumovirinae with the mammalian respiratory syncytial viruses and turkey rhinotracheitis virus.

Members of this family have nonsegmented single-stranded RNA of negative polarity and an enveloped, helical, capsid symmetry. Virions are generally pleomorphic, rounded and 100 to 500 nm in diameter. A filamentous form 100 nm wide and variable in length has been described but may be an artifact. The virion surface is covered with 8 nm projections (so-called "herring bone") nucleocapsids that may be released from disrupted particles. The members of the Paramyxovirus (PMV) genus have neuraminidase, which is absent in the other genus.<sup>9</sup>

Virus replication takes place entirely in the cytoplasm in accordance with the scheme employed by negative-strand RNA viruses. Virus attaches to host cells through the "HN" polypeptide of the virus. Fusion of the virus and host cell membranes takes place (mediated by the "F" protein of the virus) and the nucleocapsid enters the host cell. The "F" and "HN" proteins require cleavage by host-derived enzymes and these procedures control pathogenicity in some strains.

### Avian Paramyxovirus

Newcastle disease virus (NDV) is the type strain for avian paramyxoviruses. Numerous, serologically different strains of this virus have been isolated worldwide.<sup>81</sup> Hemagglutination inhibition (HI) tests, neuraminidase inhibition tests, serum neutralization tests and comparison of structural polypeptides have resulted in the identification of nine serotypes (PMV-1 to PMV-9).<sup>4</sup> Strains are designated according to serotype: species or type of birds from which virus was isolated/geographic location of isolation (usually

TABLE 32.14 Avian PMV Prototypes<sup>73</sup>

Virus Strain	Host Spectrum
PMV-1 (Newcastle Disease)	Hundreds of species/27 orders
PMV-1/pigeon/Munich/14/83	Pigeons, doves (see text)
PMV-2/chicken/California/Yucaipa/56	Passeriformes, turkeys, chickens, Psittaciformes, rails
PMV-3/turkey/Wisconsin/68**	Turkeys
PMV-3/parakeet/Netherlands 75**	Psittaciformes, Passeriformes
PMV-4/duck/Hong Kong/D3/75	Ducks, geese, rails
PMV-5/budgerigar/Japan/Kunitachi/75	Budgerigar
PMV-6/duck/Hong Kong/18/199/77	Ducks, geese
PMV-7/dove/Tennessee/4/75	Pigeons, doves
PMV-8/goose/Delaware/1953/76	Ducks, geese
PMV-9/duck/New York/22/78	Domestic duck

\*\* Host-related differences shown by monoclonal antibodies

country or state)/reference number or name/year of isolation.<sup>8</sup> Table 32.14 lists the prototypes of various avian PMV serotypes.

Avian PMV, particularly NDV, are important pathogens in domestic poultry and have prompted control measures that have had serious effects on international trade and movement of birds. Environmental and chemical stability, routes of transmission and pathogenesis of infections have been studied only with NDV. Comparisons with other serotypes are subjectively based.

### PMV-1

PMV-1 consists of NDV and related strains that are serologically, molecular biologically and pathogenically unique. They are found in Columbiformes and some Psittaciformes. Strain-specific monoclonal antibodies are necessary to distinguish infection caused by these strains of PMV-1, which have been divided into nine distinct groups.<sup>8</sup> Group P contains the pigeon isolates, which are no longer considered to be classic NDV.

#### Newcastle Disease

NDV is distributed worldwide with the possible exception of the various islands of Oceania. Birds from these islands should be considered immunologically naive with respect to NDV. NDV is serologically uniform and isolates are divided based on their virulence and epizootiologic importance (velogenic, mesogenic or lentogenic). These divisions are applicable only to the domestic chicken. Virulence is host-specific and varies considerably with experimental infections in other species.<sup>46</sup>

The host spectrum includes hundreds of species from at least 27 orders.<sup>195</sup> Susceptibility and the clinical course of disease are highly variable between species and apparently depend on the epitopes and the enzymatic status of the host. Birds of all ages are susceptible to infection. Although overheating may be a triggering factor, no real seasonal peaks have been described. Table 32.15 shows the susceptibility of a variety of orders.<sup>91,148</sup> Some mammals are susceptible to NDV, and humans may develop a severe conjunctivitis.

#### Transmission

Virus enters the host mainly through the respiratory and gastrointestinal tracts. Embryos can be infected if their shells are contaminated with virus. Vertical transmission can occur, but is rare with velogenic strains because viremic hens usually stop laying. Lentogenic and apathogenic NDV might be egg transmitted via the vitelline membrane. This route of transmission is thought to occur regularly following vaccination with live lentogenic strains (Hitchner B<sub>1</sub>). Although virus can be found in respiratory secretions, the main route of viral shedding is the feces.

Mechanical vectors that may spread the virus include wind, insects, equipment and humans. Immune birds can function as carriers and intermittently shed virus. Persistent infections are limited to weeks or months. The most common carriers (reservoirs) include free-ranging waterfowl, pittida, Psittaciformes, some Passeriformes and Strigiformes.<sup>21,45,59,90,157,158,183,249,269,296,354,366,394</sup>

#### Pathogenesis

NDV has an affinity for erythrocytes allowing the virus to be widely distributed throughout the host's body. Dyspnea may be caused by lung congestion and damage to the respiratory center. Petechiation results from viral adherence and damage to the vascular endothelium. The highly variable virulence of a given strain in a particular host is governed by the amino acid sequences of the "F" and "HN" viral proteins and the type of proteases available in the host for cleavage of the protein precursors.<sup>13</sup> The incubation period varies depending on the host species, previous virus exposure, pathotype of virus and titer of infecting virus.

#### Clinical Disease and Pathology

Lentogenic, mesogenic and velogenic strains of NDV produce varying clinical disease in chickens. The clinical expression varies widely in other birds, even between two species of the same genus. Several clini-

TABLE 32.15 Newcastle Disease (ND) Susceptibility\*

Order	Susceptibility
Struthioniformes (ratite)	Moderate (10,11)
Cariamiformes (seriema)	Low (13) to high (1)
Gruiformes (crane)	Latency (14)
Ralliformes (rail)	Latency (2)
Lariformes (gull, tern)	Low (13)
Sphenisciformes (penguin)	Low (13) to high (12)
Pelecaniformes (pelican)	Low (13)
Columbiformes (pigeon, dove)	Low (5), moderate (4), high (1 - experimental)
Psittaciformes	
Lovebird	Low (13), high (7 - experimental)
Macaw, conure	High (5 or 7 - experimental)
Amazon parrot	High (5 or 6)
Caique	Moderate
Psittaculidae	High (5)
Eclectus Parrot	Moderate
Lory	Refractory
Platycercidae	Latency
Budgerigar	Low (natural), high (6 - experimental)
Cockatoo	High (5)
Cockatiel	Moderate
Strigiformes (owl)	Latency, low (16), high
Falconiformes (falcon)	Low (13), moderate (9)
Accipitriformes (vulture, hawk)	Low (13 or 15), moderate (8)
Sagittariiformes (secretary bird)	Low (13)
Ciconiformes (stork)	Low (13)
Anatiformes	
Geese	Latency (17), moderate (3)
Surface ducks	Latency (20,21)
Bay ducks	Latency
Phasianiformes	
Guineafowl	Moderate (1)
Peafowl	High (1)
Pheasant	High (1 or 2)
Grouse	Latency (15), high (1)
Cuculiformes (cuckoo)	Latency (13)
Upupiformes (hornbill)	Low (16), moderate (10)
Alcediniformes (kingfisher)	Low (15)
Piciformes (toucan)	Low (16)
Passeriformes	
Crow	Latency (17), moderate (12 or 19)
Finch	Latency, low (11 or 17)
Weaver finch	Latency, high (18), low (22)
Others	Latency, low (23), moderate (16)

\*The clinical presentations and associated pathology are listed by a number. The number corresponds to the first column of Table 32.16.

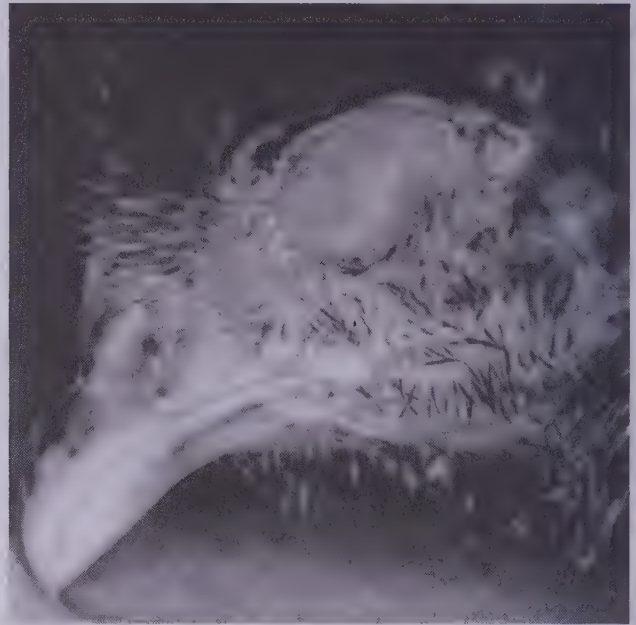


FIG 32.23 The clinical signs associated with Newcastle disease virus vary with the virulence of the virus and the infected host. Acute respiratory infections with clinical changes, including depression and dyspnea, are characteristic.

cal presentations are characteristic, but may vary considerably in their severity. In short, these can be summarized as follows:

- Peracute death; several hours of depression caused by viremia.
- Acute gastrointestinal disease (VVND); voluminous greenish diarrhea accompanied by anorexia, lethargy and cyanosis.
- Acute respiratory disease; upper respiratory exudates, rales and dyspnea.
- Acute gastrointestinal and respiratory disease.
- Chronic central nervous system (CNS) disease characterized by opisthotonos, torticollis, tremors and clonic-tonic paralysis of the limbs.

CNS signs generally occur with the development of humoral antibodies and may occur following an acute or subclinical infection. Virus may not be recovered once CNS signs develop. Partial immunity can alter the clinical progression of disease and pathologic lesions (Figure 32.23).

Affected birds typically have petechia on serosal surfaces and fatty tissues and on the mucosa of the larynx, trachea and proventriculus. Egg follicle hemorrhage may also be noted in protracted cases. Hemorrhagic necrotizing enteritis, mainly within the je-

junum, is common with virulent strains. Lymphatic tissue in association with the hemorrhagic lesions forms "boutons," which are pathognomonic in Phasianiformes. Birds with CNS signs may have no gross lesions, or hyperemia of the brain may occur.

The histopathologic lesions are as variable as the clinical signs. Table 32.16 provides a summary of gross and microscopic changes in a variety of birds. CNS lesions are generally characterized by a nonpurulent encephalitis with vascular and perivascular infiltrates of mononuclear cells. Increased numbers of glial cells and pseudoneuronophagia may occur. Histologic lesions rarely correlate with the severity of clinical signs.

### Diagnosis

For the rule-out list, infectious and noninfectious causes of gastrointestinal or respiratory tract disease should be considered. One differentiating factor is that ND is not associated with sinusitis. CNS lesions are typical for ND in a variety of bird species. As a rule, the incubation time is prolonged in these cases, and histopathologic lesions may be difficult to document. Comparable clinical signs may be seen with chlamydiosis (meningitis), salmonellosis (encephalitis purulenta) encephalomalacia, lead toxicity and calcium deficiencies. Histopathologic differentiation is only possible following thorough examination of a variety of affected tissues.

Antemortem diagnosis of NDV can be performed by culturing virus from feces or respiratory discharge (swabs) from affected birds. The number of samples required for a diagnosis depends on the size of the flock, the clinical signs (CNS) and the quarantine situation.

Feces or respiratory swabs should be placed in appropriate transport media, and any sample for virus isolation or serology should be shipped on ice (4°C). Serology results (HI or AGP) generally require two days, while culture results may take from three to five days to several weeks. Postmortem samples for virus isolation should include trachea, lung, spleen, liver and brain shipped in transport media on ice. Fixed tissues from the brain and trachea can be used for histopathology. Cryofrozen sections of the nasal or tracheal mucosa may be processed for staining with fluorescent antibodies (nonspecific reactions can occur). Fluid from the aqueous humor can be collected for HA (detect virus) and HI (antibodies to virus) and can provide the most rapid diagnosis (hours to days), if sufficient antigen is present in the sample.

▪ **Direct Virus Demonstration:** Virus isolation can be achieved using feces, cloacal swabs or discharge from the respiratory tract. Isolation of the virus is required for complete classification. The ability of NDV to adapt to a variety of host systems can make it difficult to demonstrate directly. The fact that latently infected birds have low virus titers and that vaccine strains (even mesogenic ones in imported or migratory birds) may be present, complicate the evaluation of virus isolations.

Isolates determined to be PMV-1 by HI should be sent to designated laboratories for further differentiation. Specific characterization can be accomplished with monoclonal Abs and by determining virulence for chickens (mean death time of chicken embryos, intracerebral pathogenicity index [Hansen Test], intravenous pathogenicity index, plaque formation test).

▪ **Indirect Virus Demonstration:** The response to antigens by the production of humoral antibodies varies within taxonomic groups and individually. Therefore, indirect virus demonstration by humoral antibodies may be difficult. HI titers can be present by the fourth day post-infection and may vary considerably. Titers may be nonexistent or low (birds of prey, domesticated pigeons, budgerigars), even in birds that have survived the disease. The development of HI antibodies may be delayed, and latent infections can result in the formation of antibodies. The HI titers that develop in Psittaciformes may be low with Amazon parrots and Psittaculidae, having average titers of 1:8 to 1:64, while cockatoos may have titers of 1:320.

### Treatment

Hyperimmune serum (2 ml/kg body weight IM) can be used to protect exposed birds but is of no benefit once clinical signs are present. CNS signs occur in the presence of humoral antibodies. Use of B vitamins and anticonvulsants for treating NDV-induced nonpurulent encephalitis is discouraging; in controlled studies, there was no difference in treated or untreated groups. Following improvement (which may take a year), any disturbance or stressful event may cause a bird to have severe convulsions or tremors.<sup>111</sup>

### Control

NDV occurs worldwide and many free-ranging birds can function as carriers. Effective vaccination regimens would be helpful in controlling infections in aviaries, breeding farms and zoo collections; however, ND is a notifiable disease in many countries and governmental regulations may control vaccination protocols. Most birds in orders other than Phasiani-

TABLE 32.16 Newcastle Disease Clinical Signs and Pathology

Number-strain	Clinical Signs	Pathology
1-velogenic strains	Systemic disease (peracute-acute) with fever, depression, dull plumage, cyanosis, edema of eyelids and face, severe dyspnea caused by pulmonary edema and catarrhal or fibrinous tracheitis, watery diarrhea. Nervous signs only in survivors after 1-2 weeks. Mortality: 50-90% in 4-8 days.	Gross: muscles conspicuously dark, petechia of serous membranes, edema, tracheitis, cloudy air sacs, enteritis, necrotizing ulcers in Peyer's patches and cecal tonsils (pathognomonic); petechia of mucosa of proventriculus, ventriculus and intestine; leukopenia. Histology: Hyperemia of parenchyma, larynx, ovary, brain and endothelium of blood vessels; hyperemia and necrosis of lymph follicles; tracheitis with epithelial hyperplasia, lymph follicle proliferation or necrosis; with acute death no brain lesions.
1-mesogenic strains	Acute respiratory signs, discharge of mucus, nervous signs (paresis and paralysis of limbs, ataxia, torticollis, myoclonia, tremor) after 2-3 weeks. Mortality: 5-50%.	Gross: dehydration, catarrhal enteritis, airsacculitis, tracheitis, pneumonia, cloudiness of the cornea, petechia of serous membranes and adipose tissue, necrotic foci at the sides of the choanal cleft. Histology: nonpurulent encephalitis with dense cellular infiltration (monocytes, lymphocytes, plasma cells, rarely heterophils) into the walls of the blood vessels (cuffing). CNS lesions are seen in the gray and white matter particularly in the basal parts (thalamus, cerebral peduncle, medulla oblongata); swelling and karyorrhexis of capillary endothelia, hyalinization of the arteriolar walls; frequent degeneration of ganglionic cells, but rarely gliosis; neuronophagia within the lumbar spinal cord (posterior gray matter). Proliferation of the tracheal epithelium and slight desquamation. In the lymphatic tissue, edema and necrosis of the reticular cells situated within the lymph-follicles, disappearance of lymphocytes. Pulmonary hyperemia, edema and hemorrhage; edema and cellular exudate in bronchioles and parabronchi.
2-velogenic	Free-ranging pheasants contract the disease rarely; they are unable to stand and refuse to feed; dyspnea (acute tracheitis) may be distinct or totally absent; occasionally hemorrhagic diarrhea.	See number 1.
3	Spontaneous disease rare and without respiratory signs; ataxia and paresis; in geese spontaneous drowning is typical; ducks may develop CNS signs.	Often no lesions, rarely encephalitis.
4-velogenic	CNS signs only; the acute disease is, as a rule, not observed, but if so: emaciation, whitish diarrhea, paresis of one wing, tremor, convulsions of the head muscles, later total paralysis; failure of positioning reflexes; may recover within 1-2 days or death within 5-6 days.	Gross: petechia, hemorrhagic to diphtheritic enteritis. Histology: nonpurulent encephalitis.
5-velogenic or mesogenic	CNS signs such as tremor, enlargement of the pupils, torticollis, reluctance to fly, incoordination of movement, cramps of the toes, convulsive dyspnea, general convulsions and paralysis; bloody feces occasionally; death 4-5 hours following total paralysis. Mortality: up to 100% within 2 weeks.	Gross: hyperemia within the skull's lacunae, hemorrhages in the brain, swollen spleen; hyperemia, petechia or ecchymosis in the intestinal tract (only rarely necrosis); rarely hemorrhagic enteritis or tracheitis, air sacculitis, fibrinous serositis. Histology: only in birds that have been sick for some time: disseminated nonpurulent encephalitis with perivascular cuffing, gliosis in the cerebellum and brain stem, status cribrosus in the medulla of the cerebellum and in the corpus striatum. Degeneration of ganglion cells and pseudoneuronophagia. Hyperemia and perivascular infiltration in the gray matter of the spinal cord. Hemorrhage and necrosis in spleen, liver and intestine.
6-velogenic or mesogenic	CNS signs, see number 5.	Enteral lesions caused by velogenic strains are not distinct.
7-velogenic or mesogenic	Slight ataxia, but high mortality up to 55%.	
8-velogenic or mesogenic	CNS signs 5-7 days post-infection. Starvation due to incoordination (accidents). Birds may recover with supportive care.	See number 5.
9-velogenic or mesogenic	Birds become sick after incubation of 5-13 days and die soon after the onset of CNS signs.	Cause of death is cerebral hemorrhage.

table continued on next page



Number-strain	Clinical signs	Pathology
10-mesogenic	Onset of disease with enteritis followed by sudden ataxia with a body temperature of 41°C, may hold the neck in a corkscrew-like fashion. Spontaneous healing can occur after weeks.	Gross: Petechia, hemorrhagic to diphtheroid enteritis. Histology: Nonpurulent encephalitis.
11-mesogenic	Respiratory signs and watery diarrhea.	Massive hyperemia of the pulmonary vessels with hemorrhage into the interstitium; edema in some parabronchi.
12-velogenic	Peracute death without clinical signs during viremia.	Petechia of serous membranes.
13-velogenic or mesogenic	Totally atypical course of disease, slight apathy, failure of heart and circulation.	Gross: bird in good condition; enteritis, swollen spleen, traumatic skin lesions, rarely tracheitis. Histology: hyaline degeneration of cordal muscle fibers; pulmonary edema and hemorrhage.
14-mesogenic	Anorexia, apathy, diarrhea.	
15-mesogenic	Conjunctivitis, impairment of general condition.	
16-velogenic or mesogenic	Apparently harmless disease (anorexia, torticollis) followed by sudden death. Clinical signs may be completely absent; fecal excretion for months.	Histology: nonpurulent encephalitis.
17-velogenic, mesogenic or lentogenic	As a rule, no clinical disease, but virus is propagated and excreted from the third day onward and totally eliminated by the sixth day; antibodies are present; occasionally signs as with number 11.	No pathologic lesions.
18-velogenic or mesogenic	Acute course of disease, edema of the eyelids with watery to purulent discharge from narrowed lid clefts; photophobia, no CNS signs; cause of death is asphyxia. Mortality: about 40%.	Gross: icterus, catarrhal enteritis, swollen liver and spleen, fibrinous plugs filling syrinx or larynx. Histology: cellular infiltration into iris, edema of cornea, hyperemia of the choroidea, protein and erythrocytes in the aqueous humor.
19-velogenic or mesogenic	Sudden death without prior clinical signs. Mortality: about 20%.	
20-mesogenic	Stable coexistence between mallard and ND virus; virus may be excreted for six months (probably in a few specimens only).	
21-velogenic	Normal latent infection only, but may be 4% mortality in some free-ranging birds.	Pectoral muscles and leg muscles dark. Hemorrhages of serous membranes and fatty tissues.
22-mesogenic	CNS signs following experimental infection.	
23-mesogenic	Mortality up to 20% without prior clinical signs following experimental infection.	

formes must be vaccinated parenterally for an effective antibody response to occur. Inactivated vaccines produced for chickens are useful, provided that there are no governmental regulations that restrict vaccination. Oil-adjuvanted vaccines have been shown to cause abscesses surrounding the injection site in some birds and must be used with caution. Abscesses secondary to subcutaneous infections are easier to treat than those that occur following IM injections.<sup>111</sup>

Live vaccines produced for chickens (and used for other Galliformes) should not be used in other avian orders. The potential infectivity of the vaccine strain of virus in a non-adapted host has not been determined. Vaccines administered to Psittaciformes in the drinking water have been shown to be ineffective.

As a general consideration in an active outbreak, emergency vaccination with Hitchner B<sub>1</sub> and truly

apathogenic LaSota strains is possible via ocular or nasal drops (five chicken doses per bird). These strains function as competitive inhibitors, and the local protection induced cannot be determined by an increase in humoral antibodies. In a recent outbreak on a farm with ornamental birds (more than 2000 birds of more than 200 species), this vaccination method successfully protected birds that were not yet clinically sick.<sup>65a</sup>

Dosing with live virus vaccine followed by a booster after three weeks provides three to four months of immunity. Inactivated vaccines provide five to seven months of immunity. A live vaccine followed two to three weeks later by an inactivated vaccine might provide 9 to 12 months of protection. These data are applicable only to gallinaceous birds. Increases in HI titers following vaccination are indicative of a host response and may not correlate with immunity.

### Zoonotic Potential

Virulent poultry as well as vaccine strains of NDV can cause severe conjunctivitis in humans. Infected people usually recover with few problems.

### PMV-1 Pigeon

A PMV-1 strain that is closely related to NDV but serologically, biochemically and pathogenically unique was first recognized in domesticated pigeons in the late 1970's, probably having arisen in the Middle East.<sup>4,10,196</sup> The virus reached Europe by 1981 and spread all over the world, affecting particularly racing and show pigeons.<sup>40,333</sup>

Monoclonal antibodies have shown PMV-1 pigeon strains recovered in many European countries to be fairly uniform. The host spectrum includes domesticated pigeons, feral doves and the Wood Pigeon. Sensitive (but more or less inadvertently infected) species include Cracidae, Pavoidea, Phasianidae, Common Blackbird, House Sparrow, Barn Swallow, European Kestrel, Common Buzzard, Vinaceous Amazon and Eastern Rosella.<sup>367</sup> The virus is infectious to chickens, particularly immunocompromised individuals.<sup>333,414</sup> Experimentally infected chickens do not become latent carriers.<sup>274</sup> Some infections occur from ingestion of contaminated feces. Feed contaminated with pigeon or dove feces can be a source of infection for other avian species, particularly chickens.<sup>7</sup>

### Clinical Disease and Pathology

Affected Columbiformes have nondescript clinical signs including polydipsia, polyuria, anorexia, diarrhea and vomiting. These frequently unrecognized acute signs are followed by clonic-tonic paralysis of the wings (more rarely the hind limbs), head tremors and torticollis. In contrast to ND, flaccid paresis and paralysis may occur, probably from a peripheral neuropathy.<sup>95</sup> Other less frequent signs are unilateral blepharodema, egg deformation, embryo mortality and dystrophic molt. Dyspnea, which is common with ND, does not occur. Mortality is highest in nestlings. Affected older birds may spontaneously recover within three to four weeks after the onset of clinical signs. Gross lesions include hyperemia of the brain and large parenchymatous organs, catarrhal enteritis, swelling of the kidneys and hemorrhage and necrosis of the pancreas.

Histologic lesions are variable. Edema of the meninges and brain and swelling of the vascular endothelium in the meningeal vessels may be noted. Lymphocytic perivascular infiltrates and demyelination of

the white matter may occur in the cerebrum, diencephalon, optic lobe, medulla oblongata, intumescencia cervicalis and lumbaris of the spinal cord. Degenerative and inflammatory lesions also occur in the peripheral nerves (plexus brachialis, plexus ischiadicus).<sup>95</sup> Lysis of Purkinje cells in the cerebrum, which was reported initially with PMV-1 pigeon, may have been caused by herpesvirus that was also isolated from affected birds.<sup>277</sup>

### Diagnosis

Procedures designed for isolating NDV are effective for PMV-1 pigeon. The HI test can be used to differentiate between NDV and PMV-1 pigeon. Final differentiation is possible only by the use of monoclonal antibodies.

### Treatment

LaSota vaccine strains administered via eye or nasal drop are not as efficacious in protecting from infections as expected. The LaSota strains replicate poorly in pigeon tissue so that high vaccine doses are necessary for interference and antibody production (protection only for 8 to 12 weeks).<sup>170</sup> Vaccination with live vaccines may exacerbate latent chlamydia or pigeon herpesvirus infections.<sup>222</sup> Parenteral administration of live Hitchner B<sub>1</sub> vaccine has similar side effects but may provide six months of immunity.

Inactivated vaccines are preferable for pigeons. In an active outbreak, vaccination with an inactivated vaccine will decrease the length of the disease and mitigate the clinical signs.<sup>170</sup> Once CNS signs develop, vaccination is of no value; however, spontaneous recoveries do occur.

### Control

For vaccination, homologous, inactivated oil emulsion vaccines are commercially available.<sup>220</sup> Annual boosters are necessary.<sup>220</sup> All birds in a loft, and competitive traveling groups of homing pigeons, should be vaccinated. Squabs from hens vaccinated three months before laying may not have protective antibodies.<sup>220</sup> Squabs can be vaccinated with homologous vaccine by four weeks of age.<sup>222</sup> Inactivated NDV vaccines provide only six months of protection.<sup>166</sup>

Vaccines are best applied subcutaneously in the neck. Intramuscular injections in homing pigeons can cause severe irritation of the pectoral muscles. To prevent fatal hemorrhage from the plexus subcutaneous collaris (see Chapter 44), injections must be given in the caudal third of the neck, near the middle of the dorsal aspect. Oil-emulsion adjuvants produce

superior antibody titers and have fewer side effects than aqueous carbomers.<sup>48,319</sup> An effective oral vaccine has not been developed and requires the isolation of an apathogenic PMV-1 pigeon strain.

### PMV-2

PMV-2 strains that occur worldwide display considerable antigenic and structural diversity.<sup>9</sup> Preliminary classification using monoclonal antibodies has identified four groups.<sup>300</sup> Isolates from Psittaciformes, some Passeriformes, one Gadwall as well as several turkey isolates from Israel together with a Mallard and a Coot strain belong to group 1. Group 2 consists of chicken strains from the Arabic Peninsula, and two strains from Passeriformes have been assigned to group 3. In group 4, a variety of strains from Passeriformes has been placed. The type strain PMV-2/Chicken/California/Yucaipa/56 belongs to group 1. The host spectrum includes chickens, turkeys, Passeriformes, Psittaciformes and more rarely, rails and ducks.

PMV-2 strains are endemic in Passeriformes (Ploceidae, Zonotrichiinae, Zosteropidae and Estrildidae), particularly those originating from Senegal. Isolates have been recovered from clinically healthy imported companion and aviary birds (Estrildidae, Viduidae, Ploceidae and Carduelidae). Experimentally, these isolates cause a mild upper respiratory tract disease. PMV-2 infections are more severe in Psittaciformes, particularly in African Grey Parrots, where emaciation, weakness, pneumonia, mucoid tracheitis and mortality are common findings.<sup>64</sup> The Bangor isolate from finches was proposed as a cause of death in a Blue Waxbill. Experimentally the Bangor isolate caused only mild respiratory signs and no pathologic lesions.<sup>263</sup> Further investigations in a variety of bird species are necessary in order to evaluate the virulence of the various strains.

The host spectrum may be much wider than has been shown by direct virus demonstration. Antibodies against PMV-2 have been demonstrated in homing pigeons, healthy Passeriformes (many of them free-ranging) and some birds of prey. Isolates from various finches have not been shown to be pathogenic for chicks.<sup>116,204</sup> Diagnostic methods used for PMV-1 are also applicable to PMV-2.

### PMV-3

PMV-3 strains have been isolated from chickens and turkeys in North America, Great Britain, France and

Germany. Most isolates from nondomesticated species originated from imported Psittaciformes (lovebirds, cockatiels, budgerigars, macaws, *Psittacula* spp, *Neophema* spp.). Some Passeriformes are also susceptible. Antibodies to PMV-3 have not been documented in feral birds, but a free-ranging avian reservoir probably exists.

Two groups of PMV-3 strains, one consisting mainly of turkey strains and the other of strains isolated from companion birds, can be differentiated using monoclonal antibodies.<sup>19</sup> The virus is serologically related to NDV. PMV-3/Parakeet/Netherlands/449/75 will protect chickens against NDV.<sup>8</sup> Intracerebral pathogenicity indices vary from 0.25 to 0.35<sup>358</sup> up to 1.3.<sup>385</sup>

### Clinical Disease and Pathology

The pathogenicity of this virus group varies with the infected species and (probably) virus strain. Conjunctivitis is the initial clinical sign in finches and Weaver Finches (eg, Gouldian Finch, Red-cheeked Blue Waxbill, Canary, White-rumped Canary, Orange-cheeked Waxbill, Black-throated Grassfinch, Double-barred Finch and Avadavat). Yellowish diarrhea, dyspnea and dysphagia occur as the disease progresses. Some affected birds die within a few days, while others recover over a period of weeks.<sup>358</sup> CNS signs are not regularly seen in finches (Black-eared Wheater, Grey-headed Wheater, Red-breasted Flycatcher).<sup>367</sup> Infected Psittaciformes develop CNS signs similar to those with ND. Susceptibility in Psittaciformes is variable. African Grey Parrots may develop ocular lesions (dilated pupils, hemorrhages around the pecten, uveitis and fibrinous exudate into the anterior chamber), unilateral or bilateral paralyses and hemorrhagic nasal discharge.<sup>148</sup>

Latent carriers have been described in Siberian Rubythroat, Long-tailed Grass Finch, Nutmeg-Manikin and Cutthroat Finch; Japanese Quail and domesticated pigeon.<sup>358,367,385</sup>

Detailed pathologic descriptions are not available. Liver and kidney lesions accompanied by an enteritis with blood in the intestinal lumen are common. Small birds are frequently cachectic, suggesting a chronic disease course or the inability to eat and drink. Histopathologically, hyperemia and a mild proliferation of glial cells in the brain may be seen. The typical nonpurulent encephalitis described with the CNS form of ND is not recognized with PMV-3 infections.

### Diagnosis and Control

*Salmonella* spp., NDV, chlamydia and mycotoxins should be considered in the list of differential diagnoses. The methods for demonstration of the virus are the same as with other PMV groups. Serologically, there are cross reactions with PMV-1. An exact differentiation is possible with monoclonal antibodies. An oil emulsion vaccine was developed in Great Britain to counteract the decrease of egg production in affected turkeys. Another inactivated vaccine produced sufficient immunity in budgerigars and canaries to withstand challenge.<sup>35</sup>

#### PMV-5

Budgerigars are considered the host of PMV-5. The type strain is called Kunitachi virus<sup>289</sup> and has been since lost. Possibly related strains have been isolated from free-ranging Rainbow Lorries and budgerigars from the same area of Australia.<sup>284,285</sup>

Natural and experimental infections in budgerigars are characterized by acute diarrhea, dyspnea, torticollis and death. Affected budgerigars in Australia had severe diarrhea with a 50% mortality rate. Affected Rainbow Lorries became depressed, lethargic and had three to four days of diarrhea followed by death. Birds were typically anorexic but drank liberally.

Necropsy findings in budgerigars were limited to hyperemia of the parenchymatous organs. Rainbow Lorries had swollen livers and spleens and necrotizing-to-ulcerative or diphtheroid-to-hemorrhagic enteritis, with hemorrhages within the mucosa of the ventriculus and proventriculus as well as edema of the intestinal wall.

Histopathologic lesions included multiple necrotic foci in the liver and kidney with the development of giant cells. In Rainbow Lorries, extensive loss of the intestinal epithelium with desquamated necrotic material and erythrocytes in the lumen was common. Mild perivascular infiltration with lymphocytes was common in edematous intestinal walls. The differential diagnosis list should include *Salmonella* spp., NDV, *E. coli* and nutritional deficiencies. PMV-5 cannot be isolated via all the same methods as other PMV strains.

#### PMV-7

PMV-7 has been isolated only from Columbiformes. The type strain was isolated from doves in Tennessee,

and another isolate from the Rock Pigeon in Japan. All strains have a heat-stable hemagglutinin, and are considered apathogenic. Whether or not the Japanese and the New World strains are the same has not been determined.<sup>6</sup>

#### PMV-4, PMV-6, PMV-8 and PMV-9

These groups contain virus strains recovered from clinically healthy waterfowl located in the United States and Asia. PMV-4 is rather uniform and is apathogenic in chickens.<sup>5</sup> The duck strains of PMV-6 may cause a mild respiratory disease and decreased egg production in turkeys.<sup>13</sup> Isolates have been recovered by culture of tracheal and cloacal swabs.<sup>377</sup> Details on PMV-8 and PMV-9 are limited. Carriers of PMV-4 and PMV-6 include Canada Goose, Common Teal, Common Pintail, Mallard, American Black Duck, Ring-necked Duck and Hooded Merganser.<sup>148</sup>

#### Parainfluenza-2-virus (PI-2-virus)

The PI-2-virus, which belongs to the genus PMV, does not cause clinical disease or decrease in egg production in chickens. The virus can, however, be egg transmitted without influencing the embryonal development. The chicken PI-2-virus is identical to the agent that causes croupous pneumonia in humans. The PI-2-virus is important because it is not easily recognizable as a source of human infections and may be a contaminant in embryonated chicken eggs used for vaccine production.<sup>203,421,422</sup>

#### Twirling Syndrome

This disease of uncertain etiology has been described in the African Silverbill, Zebra Finch, Gouldian Finch and related species.<sup>27</sup> Clinically, the sudden onset of torticollis and circling is conspicuous, but depression and weight loss are also evident. Clinical signs typically occur within one week of shipment from their place of origin. Some birds will be affected while others from the same shipment remain unaffected. Mortality may reach 20%. Some birds recover completely while others retain a permanent head tilt. Individual companion birds are also known to suffer from this disease. WBC may range between 2,000 and 14,000. Antibiotic therapy does not change the course of the disease. Pathology and histopathology have failed to implicate a specific etiologic agent, but a virus is suspected. PMV should always be considered in Passeriformes with neurologic signs.

### ■ Avian Pneumoviruses

The viruses of turkey rhinotracheitis and the swollen head syndrome in chickens are considered to belong to the same group and are classified as avian pneumoviruses. No other hosts have been incriminated as carrying this virus.<sup>14</sup>

## Orthomyxovirus

The family Orthomyxoviridae consists of avian influenza virus (AIV) and all other influenzavirus taxons. Orthomyxoviridae are 80 to 120 nm diameter, segmented RNA viruses with helical symmetry containing glycoproteins that project from the envelope and have hemagglutinating and neuraminidase activity. Influenzavirus can be classified into two groups designated A and C.<sup>141</sup> The specificity is provided by the nucleoprotein and matrix antigens. The nucleoprotein and matrix antigens of the influenza A virus isolated from birds, humans, pigs, horses, mink, seals and whales are closely related. Influenzavirus has a high rate of genetic recombination (particularly with regard to the hemagglutinins), so that “new” sero- and pathotypes (antigenic shift) frequently appear.<sup>86</sup>

Hemagglutinin and neuraminidase antigenic sites may also vary slightly, possibly as expression of mutant selection under the pressure of increasing immunity within a given population (ie, antigenic drift).<sup>283,364</sup> Many avian species, particularly large congregations of migrating birds, may serve as main reservoirs for virus recombination.<sup>22,23,88,154,209,210,221,288,322,387,398</sup>

Influenza C is usually restricted to humans, but there are exceptions.<sup>86</sup> During a human outbreak of influenza (formerly called B) in Hungary, 4.1% of zoo and free-ranging birds examined had antibodies against the same virus type. Infections could be experimentally induced in Common Pheasants and Mallard Ducks.<sup>348</sup>

### ■ Avian Influenza A (AIV)

Infections with influenza A virus can cause subclinical to mild respiratory diseases, loss of egg production or generalized acute lethal disease. Acute lethal infection in domesticated chickens is called fowl

plague and is a reportable disease in many countries. The recovery of numerous virus strains of identical antigenicity from many avian populations for up to ten years indicates a continuing circulation of those strains.

Influenza A virus is divided into subtypes according to the antigenicity of its hemagglutinin and neuraminidase. Thirteen hemagglutinins and nine neuraminidases have been distinguished to date (H1 to H13 and N1 to N9).<sup>429</sup> The nomenclature proposed by the same committee includes the type (A or C), host of origin (except human), geographic origin, strain number (if any), the year of isolation, and in parenthesis, the antigenic description of the hemagglutinin (H) and neuraminidase (N).

The presence of closely related surface antigens does not correlate with virulence in various avian species;<sup>2</sup> therefore, attempts to classify them according to virulence have been made. However, the interaction among a given virus strain, the host species and environmental factors is poorly understood. AIV with H1, H5 and H7 antigens are considered pathogenic for chickens but there are many exceptions.<sup>2</sup>

A/turkey/Ontario/7732/66/H5N is highly virulent for chickens and turkeys (up to 100% mortality) but is avirulent for ducks. One reason for this difference may be the tissue affinity. Strains staying “locally” in the respiratory or digestive tract usually have a low virulence; those that generalize have a high virulence. Tissue receptors in humans and many mammals differ, and this may be also true in birds. Highly virulent AIV strains possess a hemagglutinin that is readily cleaved and recombined in various host cells. The type of host proteases is important to cleavage and governs the extent of virus replication.<sup>86</sup>

AIV is distributed worldwide and has a large host spectrum that includes domesticated ducks and geese, free-ranging ducks and geese, chickens, turkeys, guineafowl, chukars, quail, pheasants, sandpipers and sanderlings, turnstones, terns, swans, gulls, herons, guillemots, puffins and shearwaters.<sup>3,32,33,34,147,172,374,383</sup> Latent infected carriers also occur. AIV has been isolated from captive birds including Indian Hill Mynahs, various Psittaciformes (Sulphur-crested Cockatoo, African Grey Parrot, budgerigar), Passeriformes, Accipitriformes and Musophagiformes (Lady Ross’s Turaco, Purple-crested Turaco, White-crested Turaco, Black-billed Turaco, Guinea Turaco).<sup>86,87,147</sup>

### Transmission and Pathogenesis

AIV is distributed around the world by migration of many avian species. Infected birds can shed the virus via respiratory secretions, conjunctiva and feces. Transmission through direct contact and indirect transmission through vectors is possible. There is no information on vertical transmission, although contaminated egg shells can distribute the agent (probable exception is the Helmeted Guineafowl). Clinically normal free-ranging birds such as ducks, geese and Passeriformes (mainly starlings) have been shown to transmit the virus to chickens and turkeys. Clinically affected free-ranging birds have been known to infect domesticated birds. Birds can serve as reservoirs for human and mammalian influenza A infections. Theoretically, humans may also be able to infect their companion birds.

Highly virulent strains of influenza A induce a viremia that is more prolonged than that caused by paramyxovirus. Thrombocytopenia occurs and is followed by a terminal hemorrhagic diathesis. The pathogenesis of less virulent strains in avian species has not been determined.

### Clinical Signs and Pathology

For chickens and turkeys refer to Easterday, et al.<sup>86</sup>

A/Tern/South Africa/1961/H5N3 was isolated from common terns and caused an acute to peracute disease in these birds in South Africa. The AIV strain was very closely related to A/chicken/Scotland/1959/H5N3 which, 17 months earlier, had caused a serious epornitic in chickens that was traced to sea birds (Herring Gulls and Kittiwakes). Experimental infections of chickens with the ternvirus caused clinical signs and pathologic lesions similar to fowl plague.<sup>34</sup>

A/pheasant/Washington/1985/H9N9 was isolated from young (two- to eight-week-old) Common Pheasants experiencing a 25 to 35% mortality rate. Adult birds did not show any clinical signs although they were infected and probably excreted the virus over several weeks. Gross pathology included severe air sacculitis, catarrhal tracheitis, purulent rhinitis, fibrinopurulent polyserositis and splenomegaly. Histopathology revealed fibrinous polyserositis with predominant infiltrations of heterophils. Diffuse congestion and interstitial fibrinous secretion were evident in the lungs. The tunica propria of the ventriculus contained multifocal aggregations of lymphocytes.<sup>75</sup> The strain was nonvirulent for chickens and domesticated ducks.

Several flocks of Helmeted Guineafowl in Hungary had decreased egg production (30 and 40%) with normal and reduced hatchability (40 to 50%). Embryonic death following two weeks of incubation was common. Birds died with no clinical signs or following a period of respiratory disease characterized by listlessness and cyanosis. Nervous involvement was observed in the form of incoordination. Some affected birds had no pathologic lesions while others had air sacculitis and petechiation of the serosal and mucosal surfaces of the proventriculus. The virus could not be transmitted experimentally to chickens, ducks, mice or guinea pigs. The virus strains isolated from two flocks were antigenically variable.<sup>402</sup> The strains were closely related to A/quail/Italy/1117/65.<sup>336</sup>

Infections have been documented in breeding flocks of Japanese Quail in Northern Italy. Two different AIV strains have been isolated, with one being A/quail/Italy/1117/65. Environmental factors influence the severity of an outbreak with mortality varying from 15 to 80%. Clinical signs are somnolence, sneezing, nasal discharge, swelling of the sinus infraorbitalis, lacrimation and dyspnea. A few birds are ataxic and have convulsions. At necropsy, a catarrhal-to-fibrinous-to-purulent rhinosinusitis and tracheobronchitis is seen as well as a focal-to-confluent, disseminated, cellular, fibrinous pneumonia. Fibrinous pericarditis, air sacculitis, submiliary pancreatic necrosis, hyperemia and edema of the brain with focal demyelination may also be seen.<sup>147</sup>

The clinical and pathologic lesions associated with AIV infections in Psittaciformes vary with the virus strain. A/Sittich/Germany/433/70 was isolated from a Sulphur-crested Cockatoo.<sup>147</sup> The majority of viruses isolated from parakeets and parrots have H5- or H7-related hemagglutinins. Affected birds have a two-week course of lethargy and CNS signs (loss of balance, ataxia, torticollis). Mortality rates may reach 30% with virulent strains. At necropsy, hemorrhages in the brain and swelling of the spleen are characteristic. Encephalitis is usually not present.

An AIV related to A/chicken/Brescia/65 was isolated from an African Grey Parrot. The bird was depressed, had dark green feces and died a few days after clinical signs developed. Congestion of the digestive tract was the only gross lesion noted. AIV was also isolated from Yellow-crowned Amazons, Plum-headed Parakeets, Rose-ringed Parakeets, Singing Parrots and Lesser Sulphur-crested Cockatoos.<sup>147</sup>

Experimental infections of budgerigars with A/Budgerigar/Hokkaido/1/77/H4N1 showed that virus replication occurred principally within the nasopharyngeal cavity, trachea, esophagus and lungs. Only birds that were in poor condition developed clinical signs including rough plumage, diarrhea and death. The infected budgerigars did not develop HI antibody titers, which were also poor following booster infection. Generally, budgerigars do not have good humoral antibody responses to many antigens.

Anatiformes are relatively resistant to influenza and are considered a natural reservoir.<sup>299</sup> About 25 to 30% of all free-ranging ducks and geese in the Northern hemisphere carry AIV. The isolated strains have highly variable hemagglutinin and neuraminidase antigens. Chariidrifomes (21.4% in Russia) are also considered to be reservoirs.<sup>147</sup> Infected waterfowl may not show clinical signs unless severely stressed by concomitant infections or transportation. Birds shed the virus by the fifth day post-infection and continue to shed for several weeks.

If clinical signs occur, they include depression, anorexia, dyspnea, swelling of the sinus infraorbitalis, lacrimation and diarrhea. Occasionally, CNS signs occur, but because these are a common premortal finding in ducks and geese, these CNS signs are considered nonspecific. The disease lasts about three weeks with mortality rates from 10 to 40%.<sup>147</sup> At necropsy, caseous exudation within the sinus infraorbitalis, fibrinous air sacculitis, polyserositis and tracheitis are common. Microscopically, an interstitial pneumonia may be present.

Replication of AIV in waterfowl takes place in the mucosa of the caudal part of the intestinal tract. Affected birds do not develop humoral antibodies, suggesting that the antigen does not contact cells of the immune system or does not elicit an immunologic reaction (Kösters, unpublished).

AIV with H3 or H11 has been isolated from Musophagiformes (turacos). These strains are pathogenic only for Musophagiformes and experimentally are not transmissible to Gruiformes, Columbiformes, Psittaciformes or Piciformes. Clinically, anorexia, somnolence and severe dyspnea occur. Mortality can reach 20%. The disease takes a course of approximately two weeks and survivors develop HI antibodies. Pathology reveals a heavy bilateral congestion of the lungs as well as hyperemia of the liver and kidneys.<sup>147</sup>

A/carduelis/Hannover/1/72/H1N also designated Co-Ca-Virus (Co=conjunctivitis; Ca=Carduelis-Canary)

has been isolated from a Siskin and is experimentally infectious to canaries.<sup>87</sup> Severe conjunctivitis is the principal clinical sign. Death occurs after two to four days. The postmortem examination does not reveal any lesions.

### Diagnosis

The differential diagnosis list should include respiratory and gastrointestinal pathogens as well as PMV, *Chlamydia* sp. and *Mycoplasma* spp.

A definite diagnosis depends on the isolation and identification of the strain in question. Fowl plague-like conditions caused by highly virulent strains may be suspected due to the acute to peracute course and the hemorrhages at necropsy. Swabs from the cloaca and the upper respiratory tract are suitable for direct virus demonstration from live birds. Parenchymatous organs (lungs, liver, spleen, brain) provide the best postmortem sample for virus isolation. Samples are to be placed in sterile transport medium containing high levels of antibiotics to inhibit bacterial growth and shipped at no more than 4°C. For storage, -70°C or lyophilization is recommended. The final classification must be made by specialized laboratories (WHO reference laboratories).<sup>429</sup> With high titer infections, virus can be demonstrated in the tissues by IF.

Indirect virus demonstration by serology is hampered by the fact that HI test does not recognize all antibody classes and reacts with nonspecific inhibitors. An ELISA is very sensitive but is no more specific than the ID (only group-specific antigen recognized), which is easier to run.<sup>86,401</sup> Paired samples (acute and convalescent phase) are necessary to document an infection. A four-fold rise in titer is indicative of a recent infection. Sera should be kept frozen (-20°C) and 0.01% sodium azide should be added as a preservative.



## Retroviridae

Avian retrovirus is separated into two genera. Avian type C retrovirus group (avian leukosis-related viruses) includes avian sarcoma and leukemia virus (SLV). The type species is avian leukosis virus.<sup>63a</sup> A type C retrovirus that is unrelated to SLV is the causative agent of the lymphoproliferative disease

(LPD) in turkeys.<sup>41,63a,291</sup> The avian reticuloendotheliosis virus is now a species within the genus mammalian type C viruses in the subgenus reticuloendotheliosis viruses.<sup>63a</sup>

Retroviridae are enveloped viruses with knobs on the surface that form the outer part of membrane-associated protein spikes, which connect the capsid membrane and envelope. The helical virion measures 90-120 nm in diameter. The genome consists of a negative-sensed, single-stranded RNA. Retrovirus is further characterized by a reverse transcriptase (reverse transcriptase) that is necessary for the formation of a DNA provirus during viral replication, which takes place in the cytoplasm. Some retroviruses, particularly the sarcomaviruses, have an incomplete genetic code and need a helper virus (frequently an avian leukosis virus) for the production of infectious viral particles. The helper viruses serve mainly for the development of the envelope, and in such cases the new envelope can contain antigens from the helper virus. Type C retrovirus is assumed to have oncogenic taxons. Defective virus can transform the host cells, but infectious particles are not produced (ie, nonproducer cells). In addition to inducing neoplasms, avian retrovirus can also be immunosuppressive, which is enhanced by concomitant infection with other tumor-inducing viruses or infectious agents. All the immunologic organs can be involved (anemia, bone marrow fibrosis and bursal and thymic atrophy). Immunosuppression is probably due to cessation of B-cell maturation and a block in the development of T-cells, possibly because of interference with the synthesis of interleukin-2.<sup>313</sup>

### ■ Avian Sarcoma/Leukosis Virus (SLV)

Avian SLV's share a common group-specific (gs) antigen and can induce neoplasms in chickens and to a lesser extent in other avian species. The group is differentiated into several types or subspecies based on susceptibility of genetically varied chicken fibroblasts, interference patterns with members of the same and different subgroups and viral envelope antigens recognized by VN antibodies.<sup>313</sup>

Subgroup A and B occur as common exogenous viruses (infective viruses released by host cells without damage to the cell). Subgroup A is more commonly encountered. Antibodies to subgroup A and B are common among free-ranging wild fowl and domestic chickens. Subgroup C and D are rare. Subgroup E includes the ubiquitous, endogenous (retroviral genes that are integrated in the genome of gonad

cells and can be vertically transmitted to the offspring) leukosis virus. This virus has a low pathogenicity and functions principally as a helper virus for defective avian leukosis virus, allowing the production of group-specific antigens. Subgroup F has been isolated from the Common Pheasant and the Green Pheasant. Subgroup G is assumed to be different from the chicken strains. These strains have been recognized in Lady Amherst's Pheasant, Golden Pheasant and Silver Pheasant. Subgroup H consists of an endogenous virus isolated from a Hungarian Partridge. Subgroup I was isolated as an endogenous virus from Gambel's Quail. Endogenous viruses isolated from the Mongolian Pheasant, Swinhoe Pheasant, Painted Quail and chickens have not been classified.

The host spectrum is dependent on autosomally transmitted susceptibility or resistance of avian cells to receptors of avian retroviral subgroups (susceptibility = dominant, resistance = recessive). Genetic resistance can be selected for or manipulated.<sup>101,313</sup> Subgroups may produce varying types of tumors, and many neoplasms occur in connection with defective viral strains that require a helper virus for replication.<sup>165</sup> Despite high rates of infection (more than 50% in some flocks), few birds (1 to 3%) actually die from a neoplastic disease. The types of neoplasias induced by the avian SL group include fibrosarcoma/mesenchymoma, chondroma, osteochondrosarcoma, osteopetrosis, mesothelioma, endothelioma, hemangioma, undifferentiated stem-cell leukosis, lymphoid leukosis, myeloblastosis/monocyte leukosis, myelocytosis, myelocytomatosis, erythroblastosis (medullary or leukemic), nephroblastoma, renal adenoma/adenocarcinoma, ovarian cystadenoma/adenocarcinoma, thecoma, granulosa cell tumor, seminoma, hepatoma, pancreatic adenoma and carcino-/fibrosarcoma of the intestinal mesentery.<sup>31</sup>

Etiologic confirmation of neoplastic induction has been conducted only for the chicken and turkey. In all other species, the leukotic sarcomatous disease processes are classified according to pathomorphologic and histologic lesions. Virus isolation has been successful only within the order Phasianiformes. Some neoplasms documented in captive-bred companion and aviary birds may prove to be induced by SLV. Because many birds bred in captivity are endangered, more investigations are necessary in order to recognize genetically resistant host groups. The gs antigen of SLV has been described in budgerigars; however, the birds in question were aleukotic.<sup>290</sup>



Lymphoid leukosis is the most common type of retroviral-induced tumor seen in birds. This neoplastic condition has been described in Gruiformes, Sphenisciformes, Columbiformes, Psittaciformes, Strigiformes, Falconiformes, Cinconiiformes, Anati-formes and Passeriformes.<sup>28,55,150,179,420</sup>

Erythroblastosis, myeloblastosis and stem-cell leukosis have been documented in canaries, and erythroblastosis has been diagnosed in a Sulphur-crested Cockatoo. Myeloblastic leukosis has been reported in the Sulphur-crested Cockatoo, budgerigar, Turquoise Parrot and Pacific Parrotlet. Leukemic erythroblastosis has been observed in the Rufous-tailed Weaver and Ultramarine Grosbeak. It is unclear if "erythremic myelosis" in conures (hemorrhagic conure syndrome)<sup>351</sup> should be classified with this group of tumors.

Osteopetrosis has been induced experimentally in guineafowl chicks infected with a virus originating from chickens. Beside the typical bone lesions, the infected birds developed epithelial tumors of the pancreas and the duodenal mucosa.<sup>215</sup>

#### Transmission

Vertical transmission by gonadal cells (virus in the albumen of the egg) or virus genome (also incomplete) in the haploid egg and semen cells is important. Chicks infected as embryos or very early post-natally remain viremic and do not produce antibodies (immune tolerance). Horizontal infection takes place through contaminated feces and saliva, and antibodies are produced that are not protective. Life-long infections are common.

Decisive age resistance is probably due to the regression of the cloacal bursa. Females are more susceptible to infection than males. Testosterone administration decreases susceptibility and castration of males increases susceptibility. SL affects birds mainly at the time of sexual maturity or later. The incubation period requires months; however, depending on the species involved, virus strain, dose and susceptibility of the host, the incubation period can be short, resulting in an "acute" onset of disease.

#### Pathogenesis

Depending on the type of oncogenic genes (erythroblastosis, myeloblastosis, myelocytoblastosis), infections with oncogenic strains produce either very small foci of transformed B-lymphocytes (lymphoid strains that have no specific oncogene) in the cloacal bursa or leukocyte precursor cells in other organs,

which can disappear or metastasize into a variety of organs (mainly liver, spleen, kidneys) where macroscopic neoplasms are being developed. These tumors are usually malignant and ultimately kill the affected bird.

#### Clinical Disease and Pathology

A clinical diagnosis depends on identifying visible or palpable tumors. The patient's general condition and ability to fly are frequently undisturbed for a relatively long time. Abdominal enlargement and dyspnea caused by the space-occupying tumors can occur in advanced cases. A massively distended liver may be palpable. Hematology, especially differential smears, are frequently nondiagnostic because avian leukosis rarely results in a leukemic blood picture (ie, tumorous blood cells or their precursors in the peripheral blood). An increase in leukocytes (heterophilia, lymphocytosis and monocytosis) is common. In many instances, the lymphocytes are mature, but in Amazon parrots and chickens, bow-formed pseudopodia may be visible. The AST may be increased if the liver is affected.

SLV causes a variety of non-neoplastic conditions, of which immunosuppressive disorders and suppression of thyroid function are the most important. The latter is considered one cause of stunting in growing chickens.<sup>313</sup> At necropsy, multiple tumors of the liver and spleen, more rarely the kidneys, subcutis, periorbital cavity, heart, lungs, ovary, intestine and cloacal wall are seen. A retained cloacal bursa is suggestive. Affected organs are diffusely swollen with or without a grayish mottled surface and a soft consistency.<sup>244,313</sup> The differentiation of myeloblasts is difficult. One method is based on location: erythrocyte-series myeloblasts develop intravascularly, myeloblasts of the other series develop extravascularly.

#### Diagnosis

Neoplasms induced by other agents are solitary, while SLV generally causes multiple tumors. In chickens, Marek's disease virus usually affects younger birds and involves nervous tissue, which is rare with SLV-induced tumors (see Chapter 25).

Plasma, serum and neoplastic tissues are best for demonstrating the presence of virus. The virus can also be isolated from oral washings, feces, feather pulp and from the albumen of freshly laid eggs. Samples should be shipped immediately in cooled containers because the virus is heat labile.<sup>244,313</sup> Antemortem diagnosis can be determined using biopsy, endoscopy or differential blood smears. Pathologic

and histopathologic lesions are suggestive. The presence of a retrovirus can indirectly be determined by the demonstration of the reverse transcriptase from neoplastic organs.

### Treatment and Control

Treatment is generally ineffective in advanced cases. Experimental application of an androgen analogue "mibolerone" in chicks between the 1st and 49th days of life has been shown to prevent leukosis. The drug is anabolic and had no deleterious effect on egg production.<sup>313</sup> This drug has not been investigated in companion birds. Selection of genetic resistance in the presence of the virus is a useful tool and should be applied wherever possible. The subtype in question should be determined, and the help of a geneticist is necessary. Another hypothetical method includes testing of all breeders for antibodies and antigen in the reproductive cells (female: egg albumen; male: semen), and infected birds should be excluded from breeding. This would allow the production of virus-free flocks; however, this situation may increase the susceptibility of the flock. Vaccines are not available.

### Erythremic Myelosis in Conures (Hemorrhagic Conure Syndrome)

This condition has been recognized as an endemic disease in Blue-crowned Conures, Peach-fronted Conures, Orange-fronted Conures and Patagonian Conures. Periodic recurrence of eventually fatal bleeding is characteristic of the disease.<sup>351</sup> During these bleeding episodes, proliferations of erythroblasts are present in the hepatic sinus and in the pancreas. Normal bone marrow is replaced by immature red blood cells suggesting erythroleukosis. A viral etiology (retrovirus) has been suggested, but has not been proven. Calcium deficiencies are believed to trigger the disease.

### Clinical Disease, Pathology and Diagnosis

Epistaxis, dyspnea, severe weakness, intermittent polyuria and diarrhea and occasionally ataxia are common. Clinical pathologic changes include packed cell volume of approximately 26%, leukocytosis represented by heterophilia (84%), severe polychromasia and anisocytosis, decrease of the total protein, hypoglycemia and hypocalcemia, elevated creatinine and large numbers of immature erythrocytes in the peripheral blood.

At necropsy, multiple pulmonary hemorrhage, development of pseudocysts in the pectoral muscles and

pericarditis are common. Histopathology reveals large numbers of erythroblasts in the sinus of the liver and in the pancreas. Hemorrhages may be noted in the lungs, and hemosiderin has been described in pulmonary macrophages around blood vessels, bronchi and in the air sacs. Hyperplasia of the bone marrow by proliferation of immature erythrocytes can take place.

Clinical pathology changes, bone marrow aspiration and histopathology are the only currently available diagnostic tests. All therapeutic regimes have been unsuccessful. Administration of calcium can prolong a bird's life and may stabilize the patient's condition.

### Avian Reticuloendotheliosis Virus (REV)

REV differs from SLV and is related to certain mammalian REV. As with SLV, several subspecies or subgroups that are closely related, but differ in antigenicity and pathogenicity exist. These include reticuloendotheliosis virus (Twiehaus),<sup>84,436</sup> duck infectious anemia virus, spleen necrosis virus, chicken syncytial virus (CSV),<sup>84,436</sup> nonclassified isolates from Muscovy Duck, visceral lymphomatosis of the Common Shelduck<sup>151</sup> and racing pigeon (serologic evidence in 0.1% of examined sera).<sup>161</sup>

Some of the viruses in this group have oncogenic properties and induce tumors principally of lymphoreticular or reticuloendothelial cells. Occasionally, these viruses are associated with other neoplasms such as histiocytic sarcoma, fibrosarcoma or myxosarcoma.<sup>434,435</sup> Non-neoplastic lesions due to degenerative-inflammatory processes are common. As with SLV, defective strains that require helper viruses to replicate do occur.<sup>84,436</sup>

The natural hosts are probably turkeys and waterfowl; however, chickens, ducks, geese and Japanese Quail are also susceptible to natural infection. Experimental infection is possible in pheasants and guinea fowl.

### Transmission and Pathogenesis

Horizontal transmission occurs among young birds when viremic animals shed the virus via feces or in body fluids. Mosquitos, particularly *Culex annulirostis*, are reported to be capable of transmitting the virus after feeding on a viremic bird. Vertical transmission is possible, but only at a low rate with eggs (albumen) and semen. The virus replicates primarily in the reticular and endothelial cells along the capillary walls. There is no detailed knowledge on the

mechanisms for entering the host cells, but differentiated receptors are indicated by different reactions in various genetic host lines. Following adhesion of the virus there is a proliferation of cells originating from primitive mesenchymal type or the reticulum associated with lymphoid tissue. The type of cells is the same in all susceptible bird species. These proliferating cells can also invade nervous tissues but, in contrast to Marek's disease virus, are not lymphocytes. In contrast to SL, most REV-induced neoplasms occur in young birds, although some chronic cases have been reported. Infections of neonates or young birds that are not immunocompetent result in immunosuppression triggering a rapid proliferation of cells carrying the appropriate oncogene. Infection with REV induces a transient or permanent disturbance of the immune system. The mitogenic stimulation of B- and T-cells is inhibited, as is the activity of the cytotoxic T-lymphocytes (the portion of the immune system directed against neoplastic cells). Suppressor T-lymphocytes are activated, which inhibits the normal proliferation of lymphocytes.<sup>84</sup>

#### Diseases by the Twiehaus-type Strains

Twiehaus-type strains are transmissible to chickens, Japanese Quail, ducks, pheasants and guinea fowl.

- **Turkeys:** A case in a free-ranging turkey has been reported.<sup>238</sup> Incubation period in turkeys is 8 to 11 weeks. Morbidity can reach 10 to 33%, but the mortality of clinically ill birds is high (30 to 60%). Turkeys suffer from diarrhea and occasionally from lameness. Some animals die without prior clinical signs. The highly distended liver is palpable. Clinical chemistry shows an increase in serum transferrin and globulin levels, but a decrease in albumin. Hematologic changes are evident only shortly before death.<sup>436</sup>

At necropsy the liver is several times larger than normal or it may show multiple small tumors that may also be present in the spleen, kidneys, gonads, thymus, cloacal bursa and bone marrow.

Histopathology shows infiltration of lymphoreticular cells (vesicular nucleus with mainly two nucleoli, light blue cytoplasm following HE staining and numerous mitoses) that replace a high amount of the parenchymal tissue. These cellular infiltrates are also present in peribronchial and pulmonary interstitial tissue as well as in the mucosa, submucosa, tunica muscularis and serosa of the intestine. The villi may be club-shaped. Focal infiltrates may occur in the kidneys and peripheral nerves.

- **Differential Diagnosis:** The rule-out list includes SL and LPD. In addition to microbiologic methods for viral demonstration and identification, SL can be suggested histopathologically by the appearance of uniform cells in tumorous tissues. RE and LPD are difficult to differentiate. Splenomegaly (pale pink, mottled surface) and minor swelling of the liver are characteristic for LPD. In many cases of LPD, the thymus is enlarged, although the cloacal bursa is normal. RE usually induces neoplasia in the digestive tract, which is less common with LPD, in which more severe lesions occur in the pancreas. In both diseases, pleomorphic cells (lymphocytes, lymphoblasts, RES cells and plasma cell) are common; however, in LPD, less mitosis is present in the more mature cells.<sup>181</sup>

- **Japanese Quail:** It is assumed that strains from these birds belong to the Twiehaus-type because of their high neoplastic potential. Because the REV are serologically related, cross-reactions between subgroups are to be expected.<sup>57,356</sup> In contrast to outbreaks in other birds, the disease appears shortly after sexual maturity (six weeks in Japanese Quail) and lasts for several months. Mortality can reach 100% in birds with depression, anorexia and dyspnea.<sup>57</sup>

The most striking and consistent lesions are thickenings and nodular foci along the digestive tract (crop, proventriculus, ventriculus and intestine, including the ceca), liver, spleen, lung, heart, pancreas, kidney, ovary, testes, mesentery, thyroid gland, skin and ischiatic nerve. Histopathologic examination reveals the same type of cells as described in turkeys.

- **Pheasants:** An etiologic agent related to the REV Twiehaus-type strains has been isolated from pheasants (Pheasant-REV-Hungary-1) (Ph-REV-H-1).<sup>83</sup> The disease occurred in approximately six-month-old pheasants that displayed compact nodules in the skin of the head and on the oral mucosa. The infraorbital sinuses were filled with inspissated material, which caused bulging of the cheeks and the anterior aspect of the eye sockets. The surface of the nodules was occasionally necrotic and covered with pseudomembranous deposits reminiscent of fowl pox. Small grayish nodules in many other organs (ingluveal wall, spleen, liver, kidney, lung, air sacs and skeletal muscles) were evident at necropsy. Histopathology revealed extensive infiltration of neoplastic lymphoblast cells into the corium of the skin or the oral mucosa. Hemorrhage and inflammatory cells were infrequently recognizable in the neoplastic tissue. The presence of a few PSA-positive cells suggests

Russel bodies consistent with plasma cells. No Bollinger bodies were demonstrable in the epithelial cells of the affected cutaneous regions.<sup>83</sup>

▪ **Ducks:** The disease has been observed mainly in Australian free-ranging and domestic ducks. The incubation period is estimated at five to nine weeks. The final classification of the virus is still pending. Clinically, depression and ruffled plumage are noted prior to death. At necropsy, the liver and spleen are soft and enlarged. The surface and cross-sections display multiple, yellow-white foci. Tumors in heart and skeletal muscles are present as well as in the duodenum, pancreas, ventriculus and proventriculus. Histopathology reveals the same type of cells as described for turkeys in the form of perivascular foci in the liver, spleen, lungs, kidneys, brain, spinal cord and the sciatic plexus.

▪ **Domesticated Goose:** The virus is related to the Twiehaus-type strains and is designated REV-Hungary-2.<sup>82</sup> The disease starts at 17 weeks of age and the mortality rate increases to 40% by the 22nd week of life. Affected birds are listless, emaciated, have ruffled plumage and are frequently lame. The spleen and liver are usually enlarged and mottled with irregular yellow-white areas throughout the organs. Other organs show predominantly nodular foci (pancreas, intestine and occasionally heart, kidney and lung). Histopathology reveals primarily lymphoblast-type cells in the organs affected by visible tumors, but the adrenal and thyroid glands, bone marrow, gonads, thymus and cloacal bursa may also be involved. The nervous system is unaffected. Occasionally, amyloid deposits are seen in the walls of the capillaries in the liver and spleen.<sup>82</sup>

#### ■ Duck Infectious Anemia Virus (DIA)

DIA can be transmitted by *Plasmodium lophurae*, one of the agents of avian malaria. Its main host is the Crested Fireback, but it can also parasitize chickens and ducks. The virus remains present even if the *Plasmodium* is experimentally passaged through canaries, turkeys or mosquitoes. In ducks, the virus can be found in peripheral blood cells and in the plasma. The disease is extremely rare and non-neoplastic.<sup>248</sup>

Anemia is severe and frequently followed by death, even if the plasmodium infection has been treated successfully. The virus can be neutralized by antiserum.

#### ■ Spleen Necrosis Virus (SNV)

Transmission of SNV takes place by direct contact. The incubation period is seven to ten days. Clinically affected birds have a short course of depression, anorexia and anemia, followed by exitus. Anemia may be diagnosed shortly before death. At necropsy, the birds display conspicuous hemorrhages and necrotic lesions of the spleen. Histopathologically, a proliferation of reticuloendothelial cells in the liver, spleen and kidneys is evident.

#### ■ Unclassified Isolates

##### Muscovy Ducks

About 10% of six-month-old Muscovy Ducks (700 birds) died within a 13-week period. Nucleic acid hybridization experiments indicated the presence of REV.<sup>252</sup> After one year without any new cases, a second outbreak occurred at the beginning of the next laying period. Undifferentiated blast cells, assumed to be of lymphoid origin, were prominent in peripheral blood smears of affected birds. These cells were cytochrome-oxidase negative and contained coarse and fine granules of PAS-positive material.

At necropsy, tumors were seen in the thymus (40%), liver, spleen, lung, kidney, pancreas and intestines. Histologic examination showed virtually all organs to be diffusely infiltrated by cells of a fairly uniform appearance with intensely basophilic cytoplasm (can be indented) and nuclei with distinct nucleoli. Numerous mitotic figures were evident. Electron microscopy revealed neoplastic cells consistent with undifferentiated lymphoblasts.<sup>252</sup>

#### ■ Diagnosis (All REV)

The lack of characteristic lesions, variability of lesions and similarity of lesions caused by different etiologies make diagnosis difficult. Direct and indirect methods of viral demonstration are necessary. Heparinized blood, plasma, leukocytes or homogenates from tumorous tissues are suitable for virus isolation. Cell-free material should be stored at minus 60°C. Cellular material can be stabilized by being treated with 7.5 to 10% dimethylsulfoxide followed by storage in liquid nitrogen. REV normally does not cause CPE, necessitating IF or ELISA to demonstrate the presence of intracellular antigen in cell culture. Monoclonal antibodies have been used to classify antigenic relationships between the groups. ELISA, IF or ID can be used for demonstrating antibodies.

## Picornaviridae

Picornaviridae are the second smallest RNA virus known, with a diameter of 20-40 nm. They are nonenveloped, have a cubic morphology with 32 capsomeres and single-stranded RNA. Five genera (Enterovirus, Hepatovirus, Rhinovirus, Aphthovirus and Cardiovirus) can be distinguished.<sup>276a</sup> Of the five genera only Enterovirus has been shown to cause problems in birds. Infections may be asymptomatic or can be characterized by gastrointestinal involvement; CNS signs and hepatopathy may or may not occur.

Information is available elsewhere on turkey viral hepatitis and infectious nephritis.<sup>388,184</sup>

### Avian Encephalomyelitis (AE)

The classification of AE is still uncertain. The four virus-specific proteins are larger than those usually associated with Picornaviridae.<sup>52</sup> The AE virus is distributed worldwide. The main host is the chicken, but natural infections have been documented in pheasants, Japanese Quail, waterfowl and turkeys. Antibodies following natural infection (without clinical disease) were found in partridges, probably Rock Partridge and Red-legged Partridge, as well as pheasants and turkeys.<sup>42,395</sup> Egg transmission plays the main role in epornitics. Horizontal transmission distributes the virus within the flock inducing latent carriers. Flocks infected during the breeding season will produce two to four infected clutches.

#### Pathogenesis

Age resistance occurs by six weeks. Only young birds without maternal antibodies or those that are not immunocompetent develop CNS signs, probably because these circumstances allow the virus to reach the brain. Virus in the intestinal tract does not induce clinical signs in nonproducing birds. Infected layers will have a decrease in egg production (five to ten percent). Humoral antibodies induce immunity. Vertical transmission in chickens results in life-long CNS signs (such as incoordination and visual defects) together with good egg production. These birds have no detectable antibodies (Kösters J, unpublished).

#### Clinical Disease and Pathology

Descriptions are available only for the chicken.<sup>52</sup> Survivors can develop ocular lesions including enlarge-

ment of the eyeball, marked opacity of the lens, seemingly fixed pupils and total blindness. Blindness may also occur in Black Grouse and capercaillie raised with AE-vaccinated chickens. In domesticated turkeys, 1% of the poults may show CNS signs including tremors, ataxia and incoordination. About 30% of the sick turkeys may die.<sup>144</sup> It is unknown if free-ranging turkeys in the United States have contracted the disease. Spontaneous recovery from CNS signs has been observed, especially in non-chickens.

#### Differential Diagnosis and Diagnosis

Encephalomalacia (vitamin E and selenium deficiencies) is the main rule-out. Diagnostic therapy might be indicated. Intoxications, particularly those with a heavy metal (lead) must be considered. In pheasants, infections with Togaviridae are possible in the appropriate season.

Histologic changes are strongly suggestive. Nonpurulent encephalitis, degeneration of the large motoric nerve cells within the cervical and lumbar medullary marrow, central chromolysis and degeneration of Purkinje cells, focal proliferation of microglia (particularly in the cerebellum) and perivascular mononuclear cell infiltrates in the proventriculus, pancreas and heart are characteristic. Perivascular infiltrates consist mainly of lymphocytes, and proliferation of lymph follicles may also be noted.<sup>144</sup> Virus can also be demonstrated indirectly by serologic means (IF).

For confirming the immunity of breeding flocks, an egg neutralization test with an egg-adapted virus strain can be performed. In eggs that are free of antibodies, a characteristic dystrophy of the skeletal muscles is seen. Serologic examinations are possible with ID and ELISA.

#### Control

Several types of vaccine are available. Inactivated vaccine injected IM is suitable for birds without humoral antibodies that are ready for breeding and under conditions where the spread of the virus is to be prevented. Live vaccines given orally may also be suitable, but the vaccine should not contain egg-adapted strains, because these have lost the ability to infect via the intestinal tract. Live, adapted, field strains given by wing web can cause clinical signs, and therefore are not recommended for fancy chicken breeds or non-gallinaceous birds.

### ■ Duck Virus Hepatitis (DH)

Three types of DH infection are distinguished.

Type I has a worldwide distribution and causes high mortality (up to 100%) in domesticated *Anas platyrhynchos* ducklings, mainly during the first week of life. A distinct age resistance (three to six weeks) is seen in which younger birds are protected by maternal antibodies. In Europe, where chlamydial infections are endemic in ducks, the typical course of the disease can be altered. Infection with *Chlamydia psittaci* concurrently with DH virus can overcome the immunity to DH virus in ducklings older than four weeks. In these birds, hepatopathy as well as duck fatty kidney syndrome and focal pancreatic necrosis have been described.<sup>92</sup> Clinical signs include peracute onset of depression followed by CNS signs (nonspecific) and death. Postmortem findings include hepatomegaly, splenomegaly and petechial hemorrhages on most parenchymatous organs.

Mallard ducklings are susceptible to the virus, but generally remain asymptomatic.<sup>129</sup> The same is true for domesticated *Anser anser* goslings. Experimental infection in turkeys and quails induces low mortality. High mortality occurs in experimentally infected pheasants, geese and guineafowl.<sup>180</sup> The virus has been isolated occasionally from several duck species maintained in zoos, although it is questionable whether or not this virus was the cause of death. The Brown Rat may serve as a vector. Two variant strains have been isolated; their relationship to Type I has not been established.<sup>441</sup>

Type II has been isolated only in East Anglia, United Kingdom. In contrast to Types I and III, it is an astrovirus (antigenically different from astrovirus isolated from chickens and turkeys) that has been associated with 10-50% mortality in ducklings, depending on their age. All the recorded outbreaks have initially involved ducks kept in open enclosures, so that all free-ranging birds and gulls are suspected to be vectors.<sup>441</sup>

Type III has been isolated only in the United States. The virus is not related to Type I. Diseases are generally less severe than those caused by type I with mortality rates rarely exceeding 30%. *Anas platyrhynchos* ducklings appear to be the only susceptible species.<sup>441</sup>

### Control

Viral-specific convalescent serum can be used in newly hatched ducklings. A vaccine is available for

Type I that can be used in breeder stock to ensure high titers of maternal antibodies. A live avirulent vaccine can also be used in ducklings in the face of an outbreak.<sup>441</sup> Recovered ducklings are considered immune.

### ■ Viral Enteritis in Cockatoos

Free-ranging Sulphur-crested Cockatoo and galah (Rose-breasted Cockatoo) chicks (seven to nine weeks old) developed profuse diarrhea and wasting and died shortly after being captured. The incidence of this disease (1,000 to 2,000 birds) is considered to be 10-20% annually in which galahs represented the higher percentage of affected birds. Clinical signs included yellow-green and mucoid feces beginning two to seven days after capture. Affected birds were anorexic, depressed, lost weight and became dehydrated following the onset of diarrhea. All affected birds eventually died or were euthanatized after one to four weeks of clinical disease. The birds failed to respond to treatment with various antibiotics and electrolytes.<sup>272</sup>

At necropsy, the duodenum and the upper jejunum were dilated by yellow-green mucoid fluid and gas, and the walls were distinctly thickened. The birds were dehydrated, and the liver, kidneys, thymus and cloacal bursa were hypoplastic.

Histopathologically, the villi of the duodenum and the upper jejunum were short, occasionally with some fusions. The crypts of Lieberkühn were markedly elongated. Proliferation of the epithelial cells in the crypts resulted in a thickened layer of enterocytes. Mild-to-moderate infiltrates of macrophages and lymphocytes were present in the lamina propria. Hyperplasia of cortical cells in the adrenal gland was seen in some birds.<sup>72</sup>

Particles with the morphologic features of an enterovirus were detected in 18 out of 31 birds by electron microscopy. Because no virus could be isolated in embryonated chicken eggs, as is frequently the case with entero-like virus, the etiologic importance of the particles could not be determined.

**TABLE 32.17 Reference Data on Common Avian Viruses**

Virus	Incubation	Environmental Stability	Disinfectants	Control
Adenovirus	Natural infection 24-48 hours, slow spread in flock	Stability varies with isolate, resistant to many disinfectants, resistant to chloroform, 60-70°C, pH 3, pH 9	Formalin, aldehydes, iodophors (requires 1 hour of contact)	No vaccine, vertical transmission, continuous infectivity cycle
EEE & WEE virus	1-7 days	Stable when refrigerated	0.2% formalin, 3% phenol	Horse vaccine for pheasants
Enterovirus	1-7 days transovarial, 11 days with horizontal transmission	Extremely stable, resistant to chloroform, pH 3, 56-62°C for hours	1% formaldehyde, 2% caustic soda, 2% calcium hypochlorite (3 hours), 5% phenol, undiluted clorox	AE vaccine, several types, see text
Herpesvirus - PDV	Natural outbreak, 3-7 days, experimental, 48 hours	Unstable, cell associated or mucus coated virus more stable, 56°C for 1-5 minutes	Most disinfectants probably effective	Killed vaccine
Herpesvirus - AT	Experimental, 3-4 days			ILT vaccine protects chickens from AT, efficacy of ILT vaccine in Amazon parrots is unknown
Budgerigarherpes	Unknown	Unknown		Interrupt breeding to increase Ab titers
Herpesvirus - DVE	3-4 days			Live attenuated vaccine, protect ponds from free-ranging waterfowl
Herpesvirus - ILT	6-15 days			Chicken vaccine, but not for pheasants
Herpesvirus - PHV	Experimental, 7 days Natural outbreaks, 5-10 days	56°C for 30 minutes		Experimental vaccines decrease clinical signs
Herpesvirus - FHV/OHV	Experimental, 3-10 days depending on virus and host			No vaccine, avoid mixing infected and non-infected birds, artificial incubation and hand-rearing
Influenza	Few hours to 3 days, varies with virulence, route of exposure and avian species	Unstable	Most disinfectants	Ultraviolet radiation, temperature increases
MSD pheasants Adenovirus Group II	6 days with oral infection			Oral vaccination of chicks (4-6 wks), chicks with THE or avirulent MSD
Newcastle disease virus	Experimental, 3-7 days, 25 days in some	Daylight, up to 4 weeks room temperature, 56°C sensitive	Lysol, cresol, phenol, 2% formalin, oxygen, cleaving compound, resistant to most disinfectants	
Orbivirus	Experimental, 4-8 days	Extremely stable	pH 3, resistant to lipolytics	
Papillomavirus	Unknown, probably prolonged	Stable, ether, temperature extremes	See text	
Polyomavirus	Unknown, suspected to be days to weeks	Stable, 56°C for 2 hours	Chlorine dioxide, phenolic disinfectants, Clorox	Experimental vaccine protects macaws from BFD virus
Parvovirus	5-15 days, varies with age and antibody titer	Stable, resistant to organic solvents, pH 3, 56°C for 3 hours, Na hypochlorite, H <sub>2</sub> O <sub>2</sub> (1%)	Resistant to many disinfectants	Vaccinate breeder geese six weeks before egg laying (IM vaccine)
PBFD virus	Experimental (min 2-4 weeks), maximum unknown, may be months to years	Probably very stable, CAV stable to 60°C for 1 hour	Unknown	Experimental killed vaccine effective
Poxvirus	Varies (virus strain and host species) generally 1-2 weeks, canaries 4 days (10-12 days for hybrids)	Stable in soil for one year	Steam, 1% KOH, 2% NaOH, 5% phenol	Homologous or heterologous vaccines (see text)
Reovirus	Psittacine infected IM shed virus 2 days PI, geese 3-6 days, experimental, 3-9 days post-infection	Stable, pH 3, H <sub>2</sub> O <sub>2</sub> , 60°C for 8-10 hours	70% ethanol, 0.59% iodine, aldehydes/alcohols (2 hours)	Experimental inactivated vaccine may be effective
Retrovirus	Unknown	Unstable, stable pH 5 to pH 9, moderate ultraviolet radiation stability	Lipid solvents (detergents), thermolabile, freeze-thawing destroys	

## Diseases with Infectious Characteristics but Uncertain Etiology

There are many clinical conditions that suggest a viral infection, and new ones are certain to be recognized with the advent of better diagnostic methods. Few of these conditions have been described sufficiently to be considered as reproducible pathologic processes. The so-called twirling syndrome<sup>27</sup> in the African Silverbill, Zebra Finch, Gouldian Finch and closely related species manifests signs that indicate the possibility of a paramyxovirus as the etiologic agent. The most important disease described in Psittaciformes of uncertain etiology but suspected to be a virus is the neuropathic gastric dilatation or proventricular dilatation (see Chapter 19).

### Neuropathic Gastric Dilatation (NGD)

This disease has been observed since 1977.<sup>132</sup> It is suggested that the problem has been imported with macaws from Bolivia. The various *Ara* spp. are considered most susceptible but the disease has been described in many other Psittaciformes including *Aratinga* spp., Nanday Conure and other conures, *Amazona* spp., *Pionus* spp., Hawk-headed Parrot, Grey-cheeked Parakeet, African Grey Parrot, Senegal Parrot and other *Poicephalus* spp., Eclectus Parrot, *Coracopsis* spp., *Alisterus* spp., *Cacatuninae* spp. and cockatiel.<sup>115</sup> A disease with clinical and histologic lesions similar to those described with Psittaciformes has also been confirmed in free-ranging Canada Geese.<sup>70</sup>

Since its first description in South America, the disease has spread to North America and European countries (United Kingdom, Germany, Switzerland, The Netherlands). Several possible viral agents have been described by electron microscopy, but none has been confirmed as the etiologic agent. Approximately 100 nm-sized particles were described in the neuronal perikaryon of the spinal cord.<sup>50</sup> Virus-like particles of 70-80 nm were described in the nuclei of the tubular epithelium of the kidney which were morphologically consistent with an adenovirus.<sup>167</sup> Intranuclear and extranuclear eosinophilic inclusion bodies were described in the neuronal perikaryon of the

celiac ganglion and the myenteric plexus, which revealed electron microscopically virus-like particles both inside and outside those inclusions. The morphology of those particles is consistent with paramyxovirus.<sup>253</sup>

### Pathogenesis

The pathogenesis can be reconstructed only by means of the lesions. Generally, this is a disease of young birds (nestlings to juveniles),<sup>390</sup> but adults may also develop clinical signs. The destruction of the intramural ganglia of the proventriculus, ventriculus and to a lesser extent the descending loop of the duodenum explains the loss of peristalsis followed by obstruction of the proventriculus, atrophy of the ventricular wall and insufficiently digested food. The obstruction of the proventriculus can cause vomiting (see Color 8). The involvement of autonomic ganglia of the heart, brain, particularly the cerebellum and medulla oblongata, and the spinal cord may cause acute death with 100% mortality in affected birds. It has been suggested that the neurologic lesions may be caused by an autoimmune reaction.<sup>132</sup>

Destruction of the intramural ganglia of the organs mentioned is considered pathognomonic for the disease, and allows morphologic differentiation from other conditions in the region, even those with the loss of peristalsis. Secondary infections may complicate the diagnosis. Because the etiologic agent has not been confirmed, it is impossible to define an "incubation period." Epizootiologic evidence suggest that clinical changes may take from four to twenty-four months to develop.

### Clinical Disease and Pathology

NGD is a chronic disease that may be associated with an acute onset of clinical signs. Clinical signs vary with the host and the severity of the condition, but generally include depression, progressive weight loss, vomiting or the passing of undigested food in the droppings (Figure 32.24) (see Color 8). Some birds have an excellent appetite yet continue to lose weight. Anorexia may occur shortly before death. Polydipsia and polyuria may occur as well as neurologic signs such as leg weakness, incoordination and lameness. Diarrhea may occur late in the disease process and is usually the result of secondary bacterial or fungal enteritis. The obstruction of the proventriculus can lead to pressure atrophy of the mucosa, sometimes followed by ulceration and even rupture (Colors 32.14, 32.19). Cachexia may induce cardiovascular failure due to energy deficiencies.<sup>153,167,253</sup>



The hemogram reveals a two- to three-fold increase in leukocytes (heterophils, monocytes and basophilic granulocytes). The negative caloric balance results in hypoglycemia and anemia.<sup>153</sup> An elevation in creatine phosphokinase (CPK) levels has been suggested as a diagnostic tool;<sup>191</sup> however, CPK concentrations are not believed to increase from damage to smooth muscles, and atrophy of striated muscle usually does not cause increased CPK activities.

Necropsy findings include emaciation, cachexia and a distended, frequently impacted proventriculus, ventriculus or crop (Color 32.14). Erosions and ulcerations with or without hemorrhage can be observed on the proventricular mucosa, occasionally even causing ruptures. The muscular layer of the hypotrophic ventriculus appears whitish in color.

Histopathologically, the proventriculus, ventriculus and the descending loop of the duodenum exhibit varying degrees of loss of nervous cells in the myenteric plexus (Auerbach) and substitution by infiltrates of lymphocytes, monocytes and sometimes plasma cells. Similar lesions are present in the minimally developed submucosal plexus (Meissner) and the celiac ganglion; however, not all ganglia are affected, and some are only partially involved. The ventriculus shows multifocal lymphocytic leiomyositis with degeneration of the smooth muscle cells and lymphocytic infiltration of the intrinsic nerves of the tunica muscularis. In some cases, extrinsic nerves are involved as well. A nonpurulent myocarditis with mononuclear infiltration of the ganglia occurs occasionally. Independent of clinical signs, lymphocytic encephalitis with perivascular cuffing can be detected in the cerebellum and medulla oblongata, but rarely in the cerebrum. Gliosis and pseudoneurophagia have been described in the brain stem. Occasionally asymmetric lymphocytic poliomyelitis or leukomalacia are observed in the lumbar spinal cord. Intranuclear (with halo) and intracytoplasmic inclusion bodies have been described in nerve cells.<sup>153,167,253</sup>

### Diagnosis

In the experience of the author, about 10% of dead birds with signs indicative of NGD are not suffering from that disease (see Chapter 19). Any cause of intestinal blockage can cause similar-appearing clinical changes and gross necropsy findings. Neoplasms, scars or larvae migrans have also been found as the cause of impeded passage either in the ventriculus or the jejunum. Clinical signs in combination with contrast radiographs that indicate a dilated proventriculus and slowed gastric emptying time

provide only a suggestive diagnosis. In some early cases, hypermotility of the gastrointestinal tract may be noted.<sup>167</sup> Antemortem diagnosis requires histopathologic examination of biopsies of the ventriculus, which is difficult to sample. The absence of histologic lesions with suggestive clinical signs can indicate that the proventricular dilatation is of another etiology, or that the biopsy sample was collected from unaffected tissue.

### Treatment and Control

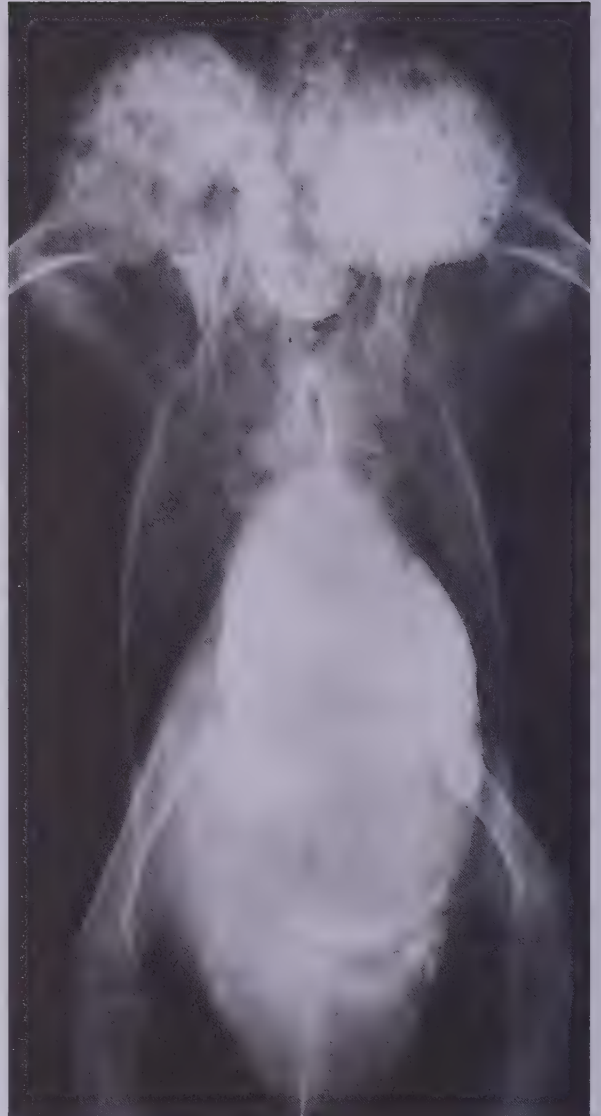
Apart from hygienic considerations, symptomatic treatment can be attempted consisting of removal of stagnant ingesta, feeding soft or liquid feed and control of secondary infections. Supportive care has been efficacious in keeping birds alive for more than one year. In breeding flocks, affected birds should be removed as soon as possible. Birds that are in contact with patients that have confirmed infections should be placed in quarantine for at least six months together with cockatiel fledglings or breeding pairs as sentinels. New additions to the aviary should be quarantined for at least six months; however, this quarantine period may be insufficient to detect latently infected birds. Numerous cases have occurred in birds from stable flocks with no access to birds outside the collection (with the exception of free-ranging birds) for many months to years. These findings may cast a doubt on the infectious etiology.

### Nephroenteritis of the Domestic Goose

This disease has been described in Hungary and was differentiated from goose hepatitis and goose myocarditis.<sup>360,407</sup> Although the agent has not been isolated to date, it is possible to reproduce the disease with filtrated material from the kidneys and intestine of sick goslings. The agent does not serologically react with duck plague virus. The incubation period following experimental infection with organ homogenates of ill birds is 6 to 18 days. Contact birds need six weeks and sometimes even more before clinical signs develop.<sup>359</sup>

### Clinical Disease and Pathology

Affected goslings seem to develop normally. The watery feces observed at the onset of the disease is frequently overlooked. Lethargy occurs only a few hours prior to death. Eight to ten hours before death, the feces become malodorous, fibrinous or bloody. In natural outbreaks, the peak of the mortality (up to 100%, but dependant on age) is reached at between 18 to 21 days of age. In contrast to the other diseases mentioned, mortality in contact birds can be ob-



**FIG 32.24** A Severe Macaw hen was presented for an acute onset of severe depression and reluctance to move. The bird had been part of a closed breeding aviary for over eight years and had recently fledged a clutch of chicks. The bird was severely emaciated (above). Survey radiographs indicated a large ventral abdominal soft tissue mass. Radiographs (right and below) taken three hours after administration of barium indicated dilatation of the proventriculus and a slowed gastric-emptying time. The histologic diagnosis was neuropathic gastric dilatation.

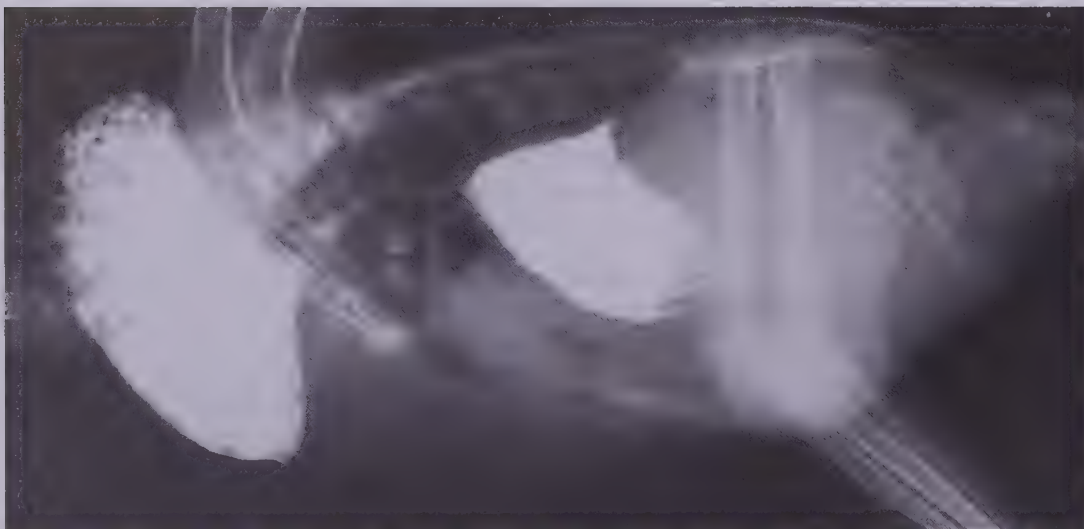

TABLE 32.18 Viruses with Specific Treatments.

Virus	Therapy
Avipoxvirus	See text
Herpesvirus	Herpesviruses that code for their own DNA polymerase are sensitive to acyclovir; Baypamun* IM 3 injections within 2 days, 1ml/kg
PDV	Both Baypamun* and acyclovir can be tried
ILT	None reported
DEV	None reported
AT	Not attempted
PHV	Try Baypamun,* treat secondary trichomoniasis
FHV	Try Baypamun,* acyclovir has renal toxicity; pay special care to birds that consume little water

Therapy for other virus infections consists of supportive care and antimicrobials to control secondary infections.

\*Available only in Europe.

served beyond the sixth week of age. At necropsy, a massive mucoid-hemorrhagic, fibrinoid necrotizing enteritis as well as hemorrhagic nephritis is typical. The intestinal mucosa displays irregularly distributed confluent necrotic areas. The kidneys are enlarged, dark red in color and have multiple gray-greasy foci. Edema of the mesentery is considered to be typical as well as edema of the subcutis. Petechia and ecchymosis may be seen in the subcutis and the skeletal musculature. The spleen is moderate to massively enlarged. The consistency of the liver is friable.

A hemorrhagic change of the cloacal bursa and the thymus is considered characteristic for the disease. In goslings older than six weeks, the kidney is more severely affected than the intestine. Visceral gout is seen in these birds frequently as a sign of the renal tubular damage.<sup>359,360,407</sup> Uricemia is considered to be a major cause of death.

Histopathology shows serous-to-hemorrhagic interstitial "nephritis." Cellular reactions are rarely seen, because the birds die before the immigration of inflammatory cells into the damaged tissue. The tubular epithelium is exfoliated, causing detritus casts in the lumina. The intestinal lesions consist of loss of epithelial cells and the structure of the villi. The result is necrotizing-to-pseudomembranous hemorrhagic enteritis. Lymphocytic cells can be seen in increased numbers in the submucosa. Hyperemia and edema can also be observed in other parenchymatous organs. Details on the daily course of an experimental infection have been reported.<sup>407</sup> Parvoviral hepatitis and reoviral myocarditis should be ruled out. Because of the intestinal lesions duck plague must be considered. The age of the goslings, clinical signs and histopathology, including lesions of the cloacal bursa and the thymus, are indicative. Attempts at viral isolation are encouraged and experimental infections with cell-containing material might be necessary.

## References and Suggested Reading

1. **Adair BM:** Studies on the development of avian adenoviruses in cell cultures. *Avian Pathol* 7:541-550, 1978.
2. **Alexander DJ, et al:** Experimental assessment of the pathogenicity of eight avian influenza A viruses of H5 subtype for chickens, turkeys, ducks and quail. *Avian Pathol* 15:647-662, 1986.
3. **Alexander DJ, et al:** Isolation of avian influenza virus from birds in Great Britain. *Vet Rec* 118:537-538, 1986.
4. **Alexander DJ, et al:** Antigenic and biological characterization of avian paramyxovirus type 1 isolates from pigeons 7 an international collaborative study. *Avian Pathol* 14:365-376, 1985.
5. **Alexander DJ, et al:** Antigenic and structural relationship between avian paramyxoviruses isolated from ducks in Hong Kong and Mississippi. *J Gen Virol* 44:8339-842, 1979.
6. **Alexander DJ, et al:** Identification of paramyxoviruses isolated from birds dying in quarantine during 1980-1981. *Vet Rec* 111:571, 1982.
7. **Alexander DJ, et al:** Newcastle disease outbreaks in fowl in Great Britain during 1984. *Vet Rec* 117:429-434, 1985.
8. **Alexander DJ, et al:** Relationship of parakeet/Netherlands/449/75 virus to other avian paramyxoviruses. *Res Vet Sci* 25:105-106, 1978.
9. **Alexander DJ, et al:** The structural polypeptides of avian paramyxoviruses. *Arch Virol* 67:309-323, 1981.
10. **Alexander DJ, et al:** The use of monoclonal antibodies in the characterization of avian paramyxovirus type 1 (Newcastle disease virus) isolates submitted to an international reference laboratory. *Avian Pathol* 16:553-565, 1987.
11. **Alexander DJ:** Avian influenza: Recent developments. *Vet Bull* 52:341-359, 1982.
12. **Alexander DJ:** Avian paramyxoviruses. *Proc 34th West Poult Dis Conf*, 1985, pp 121-124.
13. **Alexander DJ:** Newcastle disease and other paramyxovirus infections. *In* Calnek BW, et al (eds): *Diseases of Poultry* 9th ed. Ames, Iowa State University Press, 1991, pp 496-519.
14. **Alexander DJ:** Pneumovirus infections (turkey rhinotracheitis and swollen head syndrome of chickens). *In* Calnek BW, et al (eds): *Diseases of Poultry* 9th ed. Ames, Iowa State University Press, 1991, pp 669-673.
15. **Alexander DJ:** Taxonomy and nomenclature of avian paramyxoviruses. *Avian Pathol* 16:547-552, 1987.
16. **Alfallujj HH, et al:** Pox infection among captive peacocks. *J Wildl Dis* 15:597-600, 1979.
17. **Allen B, et al:** An unusual presentation of avian poxvirus in breeder toms. *Proc 39th West Poult Dis Conf*, 1990, pp 41-42.
18. **Allen SK:** Psittacine beak and feather disease in an African grey parrot. *J Assoc Avian Vet* 4:18-19, 1990.
19. **Anderson C, et al:** Antigenic variation in avian paramyxovirus type 3 isolates detected by mouse monoclonal antibodies. *Avian Pathol* 16:691-698, 1987.
20. **Andral B, et al:** Maladie foudroyante de la pintade: Recherche étiologique. *La Point Vétérinaire* 19:515-520, 1987.
21. **Arenas A, et al:** Prevalence of antibodies to PMV-1 (NDV) in wildfowl captured in southern Spain. *Verh Bericht 33. Intl Symp Erkrankungen Wild- und Zootiere*, 1991, pp 221-223.
22. **Arenas AJ, et al:** Circulation of some strains of avian influenza in wild waterfowl in Donana (Spain). *Verh Berichte 33. Intl Symp Erkrankungen Wild- und Zoovogel*, 1991, pp 217-224.
23. **Arenas AJ, et al:** Type A influenza viruses in birds in southern Spain: serological survey by enzyme-linked immunosorbent assay and hemagglutination inhibition tests. *Avian Pathol* 19:539-546, 1990.
24. **Arnold ID:** An outbreak of psittacine herpesvirus in rosellas. *Proc Assoc Avian Vet*, 1990, pp 283-291.
25. **Bagust TJ:** Immunodepressive diseases of poultry. *Proc Austral Vet Poul Assoc* 66:285-293, 1983.
26. **Barr DA, et al:** Isolation of infectious bronchitis virus from a flock of racing pigeons. *Aust Vet* 65:228, 1988.
27. **Bauck L:** Diseases of the finch as seen in a commercial import station. *Proc Assoc Avian Vet*, 1989, pp 196-202.
28. **Bauck L:** Lymphosarcoma/avian leucosis in pet birds: Case reports. *Proc Assoc Avian Vet*, 1986, pp 241-245.
29. **Bauer HJ, et al:** Avian adeno-associated virus (AAAV) and fowl adenovirus (FAV): Studies of viral interactions in chicken cell cultures. *Avian Pathol* 15:357-366, 1986.
30. **Baxendale W:** Egg drop syndrome 76. *Vet Rec* 102:285-286, 1978.
31. **Beard JW:** Biology of avian oncoviruses. *In* Klein G: *Viral Oncology*. New York, Raven Press, 1980, pp 55-87.
32. **Becker WB, et al:** Experimental infection of Common Terns with Tern virus: Influenza virus A/Tern/South Africa/1961. *J Hyg Camb* 65:61-65, 1967.
33. **Becker WB et al:** Experimental Infection of chickens with Influenza A/Tern /South Africa/1961 and Chicken/Scotland/1959 viruses. *J Comp Path* 77:159-165, 1967.
34. **Becker WB:** The isolation and classification of tern virus: influenza virus A/tern/South Africa/1961. *J Hyg Camb* 64:309-320, 1966.
35. **Bennewitz D:** Zur Immunprophylaxe der Paramyxovirus-3-Infektion bei Sittichen und Passeriformes. VI. DVG-Tagung Vogelkrrht. München, 1988, pp 86-103.
36. **Bergmann V, et al:** Einschlußkörperchenenteritis bei Tauben, hervorgerufen durch Adeno- und Parovirus. *Arch Exper Vet Med* 36:445-453, 1982.
37. **Bergmann V, et al:** Pathomorphologische und elektronenmikroskopische Feststellung einer Adenovirus-Tracheitis bei Morschusenten

- (*Cairina moschata*). *Mh Vet Med* 40:313-315, 1985.
38. **Bernier G, Morin M, Marsolais G:** A generalized inclusion body disease in the budgerigar (*Melopsittacus undulatus*) caused by a papovavirus-like agent. *Avian Dis* 25:1083-1092, 1981.
  39. **Bernier G, Morin M, Marsolais G:** Papovavirus-induced feather abnormalities and skin lesions in the budgerigar: Clinical and pathological findings. *Can Vet J* 25:307-310, 1984.
  40. **Biancifiore F, et al:** An occurrence of Newcastle disease in pigeons: Virological and serological studies on the isolates. *Comp Immunol Microbiol Infect Dis* 6:247-252, 1983.
  41. **Biggs PM:** Lymphoproliferative disease of turkeys. In Calnek BW, et al (eds): *Disease of Poultry* 9th ed. Ames, Iowa State University Press, 1991, pp 456-459.
  42. **Bodin G, et al:** Etude de la contamination expérimentale du gibier à plumes (faisans, perdrix rouges, perdrix grises) par le virus de l'encephalomyélite infectieuse aviaire. *Rev Med Vet* 132:805-816, 1981.
  43. **Bouquet JF, et al:** Isolation and characterization of an adenovirus isolated from muscovy ducks. *Avian Pathol* 11:301-307, 1982.
  44. **Bozeman LH, et al:** Characterization of a papovavirus isolated from fledgling budgerigars. *Avian Dis* 25:972-980, 1981.
  45. **Bozorgmehr-Fard MH, et al:** Isolation of Newcastle disease virus from teals (*Anas crecca*) in Iran. *J Wildl Dis* 15:335-337, 1979.
  46. **Brugh M, et al:** Atypical disease produced in chickens by Newcastle disease virus isolated from exotic birds. *Avian Dis* 28:482-488, 1984.
  47. **Bryant WM, et al:** Outbreak of a fatal inclusion body hepatitis in zoo psittacines. *Proc 1st Intl Conf Zool & Avian Med*, 1987, p 473.
  48. **Bückner D:** Topographie der Blutgefäße von Kopf und Hals der Taube und deren Bedeutung bei der Injektion von Paramyxovirus-1-Impfstoffen. *Europ Symp Bird Diseases*, 1987, pp 47-57.
  49. **Burtscher H:** Die virusbedingte Hepatosplenitis infectiosa strigum. 1. Mitteilung: Morphologische Untersuchungen. *Path Vet* 2:227-255, 1965.
  50. **Busche R, et al:** Zur Pathologie des Macaw wasting syndromes. *Verhandlungsbericht 27. Internat Symp Erkrankungen Zootiere*, 1985, pp 325-329.
  51. **Cakala A:** Szczep wirusa CELO wysochniony z bazantow. *Med Vet* 22:261-264, 1966.
  52. **Calnek BW, et al:** Avian encephalomyelitis. In Calnek BW, et al (eds): *Diseases of Poultry* 9th ed. Ames, Iowa State University Press, 1991, pp 520-531.
  53. **Calnek BW, et al:** Marek's disease. In Calnek BW, et al (eds): *Diseases of Poultry* 9th ed. Ames, Iowa State University Press, 1991, pp 342-385.
  54. **Calnek BW:** Hemagglutination-inhibition antibodies against an adenovirus (virus 127) in white Pekin ducks in the United States. *Avian Dis* 22:798-801, 1978.
  55. **Campbell TR:** Lymphoid leukemia in an Amazon parrot: A case report. *Proc Intl Conf Avian Med*, 1985, pp 229-234.
  56. **Cappucci DT, et al:** Highlights on rabies, including Mid-Atlantic States outbreak in Raccoons. *Military Medicine* 151:1ff, 1986.
  57. **Carlson HC, et al:** Reticuloendotheliosis in Japanese quail. *Avian Pathol* 3:169-175, 1974.
  58. **Carson AE, et al:** Isolation and identification of a strain of influenza virus A/quail/California/4794/90(H4N6) antigenically similar to A/duck/Czechoslovakia/56(H4N6) from a quail flock in California. *Proc 40th West Poultry Dis Conf*, 1991, pp 42-43.
  59. **Chu HP, et al:** Isolation of Newcastle disease virus from birds of prey. *Avian Pathol* 5:227-233, 1976.
  60. **Clipham R:** Degenerative anemia in African greys. *J Assoc Avian Vet* 3:73, 1989.
  61. **Clubb S, et al:** Psittacine reovirus: An update including a clinical description and vaccination. *Proc Assoc Avian Vet*, 1985, pp 83-90.
  62. **Clubb S:** A multifactorial disease syndrome in African Grey parrots (*Psittacus erithacus*) imported from Ghana. *Proc Intl Conf Avian Med*, 1984, pp 135-149.
  63. **Clubb SL, et al:** Outbreak of a papovavirus-like infection in a psittacine nursery: A retrospective view. *Proc Intl Conf Avian Med*, 1984, pp 121-129.
  64. **Coffin MJ:** Retroviridae. In: Francki RIB, et al (eds): *Classification and nomenclature of viruses*. Springer Verlag Wien-New York pp. 290-295, 1991.
  65. **Collins BF, et al:** Preliminary characterization of a paramyxovirus isolated from a parrot. *Res Vet Sci* 19:219-221, 1975.
  66. **Cooper JE:** Papillomas in psittacine birds. *Vet Rec Nov*, 1986.
  67. **Cornelissen H:** Vaccination of over 200 bird species against Newcastle disease: methods and vaccination reactions. *Proc Europ Conf Avian Med & Surf* pp. 275-287, 1993.
  68. **Cowen BS, et al:** A case of acute pulmonary edema, splenomegaly and ascites in guinea fowl. *Avian Dis* 32:151-156, 1988.
  69. **Crowshaw, et al:** Infectious laryngotracheitis in peafowl and pheasants. *Avian Dis* 26:397-401, 1982.
  70. **Cribb PH:** Cloacal papilloma in an amazon parrot. *Proc Intl Conf Avian Med*, 1984, pp 35-37.
  71. **Curtis-Velasco M:** Eastern equine encephalomyelitis in a lady gouldian finch. *J Assoc Avian Vet* 6(4):227-228, 1992.
  72. **Daoust PY, et al:** Proventricular impaction associated with nonsuppurative encephalomyelitis and ganglioneuritis in two Canada geese. *J Wildl Dis* 27(3):513-517, 1991.
  73. **Davidson, WR, et al:** An epornitis of avian pox in wild Bobwhite quail. *J Wildl Dis* 16:293-298, 1980.
  74. **Davis RB, et al:** Budgerigar fledgling disease (BFD). *Proc 32nd West Poultry Dis Conf*, 1983, p 104.
  75. **Decaesstecker M, et al:** An ELISA for the detection of antibodies to avian nephritis virus and related enterovirus-like viruses. *Avian Pathol* 20:523-530, 1991.
  76. **Desmidt M, et al:** Cytomegalovirus-like conjunctivitis in Australian finches. *J Assoc Avian Vet* 5:132-136, 1991.
  77. **Dhillon AS, et al:** Mortality in young pheasants and avian influenza infection. *Proc 35th West Poultry Dis Conf*, 1986, p 38.
  78. **Docherty DE, et al:** Isolation of a herpesvirus from a bald eagle nestling. *Avian Dis* 27:1162-1165, 1983.
  79. **Docherty DE, et al:** The isolation of a herpesvirus from captive cranes with an inclusion body disease. *Research Note Avian Dis* 24:278-283, 1980.
  80. **Domermuth CH, et al:** Hemorrhagic enteritis and related infections. In Calnek BW, et al (eds): *Diseases of Poultry* 9th ed. Ames, Iowa State University Press, 1991, pp 567-572.
  81. **Dorrestein G, et al:** Einige Befunde zum Gesundheitszustand von freilebenden Stadttauben (*Columba livia*). *DVG VII. Tagung Vogelkrankheiten*, München, 1990, pp 77-87.
  82. **Dorrestein GM, et al:** Adenovirus inclusion body hepatitis: A new pigeon disease? *VII DVG-Tagung Vogelkrankheit*, München, 1992, pp 7-14.
  83. **Doyle TM:** A hitherto unrecorded disease of fowl due to a filter-passing virus. *J Comp Pathol Ther* 40:144-169, 1927.
  84. **Dren, CS, et al:** Isolation of a reticuloendotheliosis-like virus from naturally occurring lymphoreticular tumors of domestic geese. *Avian Pathol* 17:259-277, 1988.
  85. **Dren CS, et al:** Lymphoreticular tumor in pen-raised pheasants associated with a reticuloendotheliosis like virus infection. *Avian Pathol* 12:55-71, 1983.
  86. **Dren CS:** Reticuloendothelioses. In Heider G, et al: *Krankheiten des Wirtschaftsvogelgeflügs, ein Handbuch für Wissenschaft und Praxis*. Stuttgart, Gustav Fischer Verlag Jena, 1992, pp 770-781.
  87. **Dykstra MJ, Bozeman LH:** A light and electron microscopic examination of budgerigar fledgling disease virus in tissue and in cell culture. *Avian Pathol* 11:11-18, 1982.
  88. **Easterday BC, et al:** Influenza. In Calnek BW, et al (eds): *Diseases of Poultry* 9th ed. Ames, Iowa State University Press, 1991, pp 532-551.
  89. **Eckert A:** Charakterisierung eines hämagglutinierenden Agens aus einem Erlenzeisig (*Carduelis spinus*) - Beitrag zur Ätiologie einer Erkrankung von Sperlingsvögeln (Passeriformes). *Vet Diss*, Hannover, 1979.
  90. **Eleazer TH:** Avian flu spread by wild waterfowl. *Poultry Dig*, 1984, p 16.
  91. **Engelhard E:** Charakterisierung eines aus einem Wellensittich (*Melopsittacus undulatus*) isolierten paramyxovirus. *Vet Med Siss*, München 1982.
  92. **Erickson DA, et al:** Velogenic viscerotropic Newcastle disease in selected captive avian species. *Proc Am Assoc Zoo Vet*, 1975, pp 133-136.
  93. **Estudillo J:** A Newcastle disease outbreak in captive exotic birds. *Proc 21th West Poultry Dis Conf*, 1972, pp 70-73.
  94. **Farmer H, et al:** Aspects of the pathogenesis of duck viral hepatitis. *Proc VII Intl Congr WVPA Jerusalem*, 1985, p 38.
  95. **Fenner F, et al (eds):** *Veterinary Virology*. Orlando, Academic Press, 1987.
  96. **Fischer E, et al:** Zur Histopathologie der spontanen PMV-1 Infektion der Taube. *DVG V Tagung Vogelkrankheiten*, München, 1986, pp 141-149.
  97. **Flcury HJA, et al:** Unidentified viral particles could be associated with enteritis of various commercial bird species. *Ann Inst Pasteur/Virol* 139:449-453, 1988.
  98. **Foerster S:** Untersuchungen an Kranich-Hepatitis-Herpesviren. *VI DVG-Tagung Vogelkrankheit*, München, 1988, pp 204-211.
  99. **Forshaw D, et al:** Infection with a virus resembling papovavirus in gouldian finches (*Eythymia gouldiae*). *Aust Vet J* 65:26-28, 1988.
  100. **Frank RK, et al:** Coronaviral enteritis in an ostrich (*Struthio camelus*) chick. *J Zoo Wildl Med* 23:103-107, 1992.
  101. **Frazier JA, et al:** The ultrastructure of cultures of chick embryo fibroblasts containing togavirus-like particles. *Avian Pathol* 16:679-689, 1987.
  102. **Freeman BM, et al:** Breeding for disease resistance: The prospective role of genetic manipulation. *Avian Pathol* 16:353-365, 1987.
  103. **French EL, et al:** A new herpesvirus isolated from a nestling cormorant (*Phalacrocorax melanoleucus*). *Avian Pathol* 2:3-15, 1973.
  104. **Fudge AM:** Psittacine vaccines. *Proc Assoc Avian Vet*, 1990, pp 292-300.
  105. **Gaskin JM, et al:** Preliminary findings in avian viral serostitis: A newly recognized syndrome of psittacine birds. *J Assoc Avian Vet* 5:27-34, 1991.
  106. **Gaskin JM:** Psittacine viral disease: A perspective. *J Zoo Wildl Med* 20:249-264, 1989.
  107. **Gaskin JM:** The serodiagnosis of psittacine viral infections. *Proc Assoc Avian Vet*, 1988, pp 7-10.
  108. **Gassmann R, et al:** Isolierung von Adenoviren bei Wellensittichen mit zentralnervösen Ausfallserscheinungen. *II. DVG-Tagung Vogelkrankheit*, 1981, München, pp 44-47.
  109. **Gaudry D, et al:** Essential characteristics of three viral strains isolated from Muscovy Ducks. *5th Intl Kongr WVPA* pp 1400-1405, 1973.
  110. **Gelderblom H, et al:** The fibers of fowl adenoviruses. *Arch Virol* 72:289-298, 1982.
  111. **Gerlach H:** Papovavirus. In Harrison GJ, Harrison LR (eds): *Clinical Avian Medicine and Surgery*. Philadelphia, WB Saunders Co, 1986, pp 426-428.
  112. **Gerlach H:** Paramyxovirus. In Harrison GJ, Harrison LR (eds): *Clinical Avian Medicine and Surgery*. Philadelphia, WB Saunders Co, 1986, pp 421-426.
  113. **Gerlach H:** Reovirus. In Harrison GJ, Harrison LR (eds): *Clinical Avian Medicine and Surgery*. Philadelphia, WB Saunders Co, 1986, pp 430-431.
  114. **Gerlach H:** Viral diseases. In Harrison GJ, Harrison LR (eds): *Clinical Avian Medicine and Surgery*. Philadelphia, WB Saunders Co, 1986, pp 409-414.
  115. **Gerlach H:** Vögel als Reservoire und Verbreiter von Krankheitsserregern. *Berl Münch Tierärztl Wschr* 92:169-173, 1979.
  116. **Gerlach S:** Macaw wasting disease: A 4-year study on clinical case histories, epizootiology, analyses of species, diagnosis and differential diagnosis, microbiological and virological results. *Proc 1st Conf Europ*, 1991, pp 273-281.
  117. **Goodman BB, et al:** Isolation of avian paramyxovirus-2 from domestic and wild birds in Costa Rica. *Avian Dis* 32:713-717, 1988.
  118. **Goodpasture EW, et al:** Isolation of a wild avian pox virus inducing both cytoplasmic and nuclear inclusions. *Am J Path* 40:437-453, 1962.
  119. **Goodwin MA, McGee ED:** Herpes-like virus associated with a cloacal papilloma in an orange-fronted conure (*Aratinga canicularis*). *J Assoc Avian Vet* 7(1):23-26, 1993.
  120. **Gough RE:** Adenovirus particles and inclusion body hepatitis in pigeons. *J Assoc Avian Vet* 6:37-39, 1992.
  121. **Goryu M, et al:** Inclusion body hepatitis due to adenovirus in pigeons. *Avian Pathol* 17:391-401, 1988.
  122. **Gough RE, et al:** Routine virus isolation or detection in the diagnosis of diseases in birds. *Avian Pathol* 17:893-907, 1988.
  123. **Gough RE:** Goose parvovirus infection. In Calnek BW, et al (eds): *Diseases of Poultry* 9th ed. Ames, Iowa State University Press, 1991, pp 684-690.
  124. **Gough, et al:** Pheasant coronavirus in Great Britain. *WVPA II Intl Symp IB Rauschholzschlangen Germany*, 1991, pp 308-314.
  125. **Gough JF:** Outbreaks of budgerigar fledgling disease in three aviaries in Ontario. *Can Vet J* 30:672-674, 1989.
  126. **Gough PH, et al:** Rabies antibodies in Wild-birds. *J Wildl Dis* 12:392-395, 1976.
  127. **Gough RE, Collins MS, Gresham AC:** A parvovirus-like agent associated with psittacine beak and feather disease. *Vet Rec* 125:41, 1989.
  128. **Gough RE, et al:** Isolation of a chicken embryo-lethal rotavirus from a Lovebird (*Agapornis* sp.). *Vet Rec* 122:363-364, 1988.
  129. **Gough RE, et al:** Viruses and virus-like particles detected in samples from diseased game birds in Great

- Britain during 1988. *Avian Pathol* 19:331-342, 1990.
130. **Graham DL, Calnek BW:** Papovavirus infection in hand-fed parrots: Virus isolation and pathology. *Avian Dis* 31:398-410, 1986.
  131. **Graham DL, et al:** Herpesvirus infections in captive birds. 1st Intl Birds in Captivity Symp, Seattle USA, 1978, pp 526-530.
  132. **Graham DL:** An update on selected pet bird virus infections. *Proc Intl Conf Assoc Avian Vet*, 1984, pp 267-270.
  133. **Graham DL:** Characterization of a reovirus and its isolations and pathogenicity for parrots. *Avian Dis* 31:441-449, 1987.
  - 133a. **Graham DL:** Internal papillomatous disease (abstract). *Proc Assoc Avian Vet* 1988, p 31.
  134. **Graham DL:** Feather and beak disease: Its biology, management and an experiment in its eradication from a breeding aviary. *Proc Assoc Avian Vet*, 1990, pp 8-11.
  135. **Graham DL:** Papillomatous disease: A pathologist's view or cloacal papillomas and then some! *Proc Assoc Avian Vet*, 1991, pp 141-143.
  136. **Graham DL:** Infiltrative splanchic neuropathy, a component of the "wasting macaw" complex. *proc Intl Conf Avian Med*, 1984, p 275.
  137. **Graham DL:** Update on pet avian viral diseases. *Proc 34th West Poultry Dis Conf*, 1985, pp 75.
  138. **Green RG, et al:** A virus disease of owls. *J Immunol* 29:68-69, 1935.
  139. **Greenece C, et al:** Psittacine beak and feather disease is a scarlet macaw (*Ara macaw*). *J Assoc Avian Vet* 6(2):95-98, 1992.
  140. **Griffiths BB, et al:** Immunological response of chickens to eastern equine encephalomyelitis virus. *Res Vet Sci* 38:65-68, 1985.
  141. **Guittel M, et al:** Experimental soft-shelled eggs disease (EDS<sub>96</sub>) in guineafowl (*Numida meleagris*). Abstracts VII th Internat Cong WVPA, 1981, p 22.
  142. **Gulka CM, et al:** Evidence of exposure of waterfowl and other aquatic birds to the hemagglutinating duck Adenovirus identical to EDS 76 virus. *J Wildl Dis* 20:1-5, 1984.
  143. **Gylstorff I:** Adenoviridae. In Gylstorff I, Grimm F: Vogelkrankheiten. Stuttgart, Eugen Ulmer, 1987, pp 275-278.
  144. **Gylstorff I:** Aviäre Encephalomyelitis. In Gylstorff I, Grimm F: Vogelkrankheiten, 1987, pp 253-254.
  145. **Gylstorff I:** Coronavirus. In Gylstorff I, Grimm F: Vogelkrankheiten, Stuttgart, Verlag Eugen Ulmer, 1987, p 263.
  146. **Gylstorff I:** Derzsy's Krankheit - Hepatitis der Gänse. In Gylstorff I, Grimm F: Vogelkrankheiten. Stuttgart, Verlag Eugen Ulmer, 1987, pp 279-280.
  147. **Gylstorff I:** Orthomyxoviren. In Gylstorff I, Grimm F: Vogelkrankheiten, Stuttgart, Verlag Eugen Ulmer, 1987, pp 249-253.
  148. **Gylstorff I:** Paramyxoviren. In Gylstorff I, Grimm F: Vogelkrankheiten. Stuttgart, Verlag Eugen Ulmer, 1987, pp 210-249.
  149. **Gylstorff I:** Poxviridae. In Gylstorff I, Grimm F: Vogelkrankheiten. Stuttgart, Verlag Eugen Ulmer, 1987, pp 263-267.
  150. **Gylstorff I:** Reoviridae. In Gylstorff I, Grimm F: Vogelkrankheiten. Stuttgart, Verlag Eugen Ulmer, 1987, pp 257-259.
  151. **Gylstorff I:** Retroviridae. In Gylstorff I, Grimm F: Vogelkrankheiten. Stuttgart, Verlag Eugen Ulmer, 1987, pp 259-263.
  152. **Gylstorff I:** Virusinfektionen. In Gylstorff I, Grimm F: Vogelkrankheiten. Stuttgart, Verlag Eugen Ulmer, 1987, pp 255-257.
  153. **Gylstorff I:** Vormagendilatation und Auszehrung (Macaw-Wasting-Syndrom): Myenteritische Ganglio und Encephalomyelitis der Psittaciden. In Gylstorff I, Grimm F: Vogelkrankheiten. Stuttgart, Verlag Eugen Ulmer, 1987, pp 285-286.
  - 154a. **Halliwell WH:** Lesions of Marek's disease in a great-horned owl. *Avian Dis* 15:49-55, 1971.
  154. **Halvorson D:** Epizootiology of avian influenza. *Avian Dis* 27:77-85, 1983.
  155. **Hanson LE, et al:** Fowlpox and latency. *Proc 24th West Poultry Dis Conf*, 1975, pp 43-45.
  156. **Hanson LE, et al:** Laryngotracheitis. In Calnek BW, et al (eds): Diseases of Poultry 9th ed. Ames, Iowa State University Press, 1991, pp 485-495.
  157. **Hanson RP:** Avian reservoirs of Newcastle disease. *Proc 3rd Intl Wildl Dis Conf*, Munich, 1975.
  158. **Hanson RP:** Issues related to control of velogenic viscerotropic Newcastle Disease (VVD) and the importation of pet birds. *Proc 31th West Poultry Dis Conf*, 1982, pp 165-166.
  159. **Harrison GJ:** The vaccine dilemma. *J Assoc Avian Vet* 5:10-14, 1991.
  160. **Hartig F, et al:** Beitrag zur Pathologie der Lungenform der Kanarienvogel. *Berl Münch Tierärztl Wschr* 85:352-355, 1972.
  161. **Heffels U, et al:** Serologische Untersuchungen zum Nachweis virusbedingter Infektionen bei der Taube in der Bundesrepublik Deutschland. *Dtsch tierärztl Wschr* 88:97-102, 1981.
  163. **Heffels-Redmann U, et al:** Infektiose Myocarditis der Gans. In Heider, et al: Krankheiten des Wirtschaftsgeflügel, ein Handbuch zur Wissenschaft und Praxis. Stuttgart, Gustav Fischer Verlag Jena, 1992, pp 538-540.
  164. **Heffels-Redmann U, et al:** Structural and biological characteristics of reovirus isolated from muscovy ducks. *Avian Pathol* 21:481-491, 1992.
  165. **Heider G:** Molekulare Grundlagen aviärer Retrovirusinfektionen. In Heider G, et al: Krankheiten des Wirtschaftsgeflügel, ein Handbuch zur Wissenschaft und Praxis. Stuttgart, Gustav Fischer Verlag Jena, 1992, pp 683-695.
  166. **Heil U:** Untersuchungen zur Charakterisierung und Klassifizierung des "Tauben-Paramyxovirus" sowie Überprüfung der Schutzwirkung verschiedener Newcastle-Disease-Impfstoffe bei Tauben (*Columba livia* Gmel. 1789 var. dom.). *Vet Diss*, München, 1984.
  167. **Heldstab A, et al:** Pathologie einer endemisch verlaufenden Neuritis im Magen/Darmbereich bei Großpapageien (wasting macaw complex, infiltrative splanchic neuropathy). *Verhandlungsberichte 27 Intl Symp Erkrankungen Zootiere*, 1985, pp 317-324.
  168. **Helfer DH, et al:** Myocarditis-encephalopathy in canaries. *Proc 30th West Poultry Dis Conf*, 1981, p 92.
  169. **Helfer DH:** A new viral respiratory infection in parakeets. *Avian Dis* 24:781-783, 1980.
  170. **Hermann-Dekkers, et al:** Vaccination of pigeons against Paramyxovirus infection in infected areas, a comparative trial. *Europ Symp Avian Dis*, Beerse, 1987, pp 32-38.
  171. **Hillyer EV:** Cholangiocarcinoma in association with cloacal papilloma in two amazon parrots. 1st Conf Europ Assoc Avian Vet, 1991, p 332.
  172. **Hinshaw, et al:** Antigenic and genetic characterization of a novel hemagglutinin subtype of Influenza A viruses from gulls. *J Virol* 42:865-872, 1982.
  173. **Hirai K, et al:** Characterization of a new corona-like agent isolation from parrots. *Avian Dis* 23:515-515, 1979.
  174. **Hirai K, et al:** Characterization of paramyxovirus, herpes- and orbiviruses isolated from psittacine birds. *Avian Dis* 23:148-163, 1979.
  175. **Hirai K, et al:** Isolation of a papovavirus-like agent from young budgerigars with feather abnormalities. *J Vet Sci* 46:577-587, 1984.
  176. **Hofstad ML (ed):** Diseases of Poultry 8th ed. Ames, Iowa State University Press, 1986.
  - 176a. **Holmes LF:** Reoviridae. In: Francki RIB, et al (eds): Classification and nomenclature of viruses. Springer Verlag Wien-New York pp 186-192, 1991.
  177. **Horwitz MS:** Adenovirus. In: Fields NB, et al: Virology 2nd ed. New York, Raven Press Ltd, 1990, pp 1723-1740.
  - 177a. **Howard CR:** Hepadnaviridae. In: Francki RIB, et al (eds): Classification and nomenclature of viruses. Springer Verlag Wien-New York pp 186-192, 1991.
  178. **Huff DG, et al:** Psittacine beak and feather syndrome in a blue-fronted Amazon (*Amazona aestiva*). *Assoc Avian Vet Today* 2:84-86, 1988.
  179. **Hughes EP, et al:** Hemoproliferative disease in captive and wild birds. *Proc 35th West Poultry Dis Conf*, 1986, pp 83-84.
  180. **Hwang J:** Active immunization against duck hepatitis virus. *Am J Vet Res* 33:2539-2544, 1972.
  181. **Januszko M, et al:** Reticuloendotheliosis and lymphoproliferative disease of turkeys - pathology and differential diagnosis. *Refuah Veterinarith* 36:2-9, 1979.
  182. **Ianculescu M:** Arbovirus infections. In Calnek BW, et al (eds): Diseases of Poultry. Ames, Iowa State University Press, 1991, pp 674-679, 1991.
  183. **Ibrahim AI:** Issues related to control of velogenic viscerotropic Newcastle disease (VVD) and the importation of pet birds. *Proc 31th West Poultry Dis Conf*, 1982, pp 165.
  184. **Imada T, et al:** Infectious nephritis. In Calnek BW, et al (eds): Diseases of poultry. Iowa State University Press pp 680-682, 1991.
  185. **Ishibashi M, et al:** Adenoviruses of animals. In Ginsberg HS (ed): The Adenoviruses. New York, Plenum Press, pp 497-562.
  186. **Jack SW, et al:** Pathology of quail bronchitis. *Proc 37th West Poultry Dis Conf*, 1988, pp 102-104.
  187. **Jacobson ER, et al:** Feather and beak dystrophy and necrosis in cockatoos. *Clinicopathologic evaluations. J Am Vet Med Assoc* 189:999-1005, 1986.
  188. **Jacobson ER, et al:** Epornitic of papovavirus-like virus-associated disease in a psittacine nursery. *J Am Vet Med Assoc* 185:1337-1341, 1984.
  189. **Jacobson ER, et al:** Adenovirus-like infection in white-masked lovebirds (*Agapornis personata*). *J Assoc Avian Vet* 1(2):33, 1989.
  190. **Jacobson ER, et al:** Papilloma-like virus infection in an African Grey parrot. *J Am Vet Med Assoc* 183:1037-1038, 1983.
  191. **Jenkins T:** Creatinine kinase as a diagnostic indicator of splanchic neuropathy. *J Assoc Avian Vet* 5:49, 1991.
  192. **Johnston KM, Riddell C:** Intracellular inclusion bodies in finches. *Can Vet J* 27:432-434, 1986.
  193. **Jones RC, et al:** An enterotropic avian infectious bronchitis. In McFerran (ed): Acute Virus Infections of Poultry. Martinus Nijhoff Publishers, 1986, pp 113-121.
  194. **Kaal:** Venereal disease of parrots. *Proc Intl Avicultural Meeting*, Tenerife, Spain, 1990.
  195. **Kaleta EF, et al:** Newcastle disease in free-flying and pet birds. In Alexander DJ (ed): Newcastle Disease. Boston, Kluwer Academic Publ, 1988, pp 197-246.
  196. **Kaleta EF, et al:** The first isolation of the avian PMV-1 virus responsible for the current panzootic in pigeons. *Avian Pathol* 14:553-557, 1985.
  197. **Kaleta EF, et al:** Newcastle disease in a zoo affecting demoiselle cranes (*Antropoides virgo*), greater flamingoes (*Phoenicopterus ruber*) and a pied imperial pigeon (*Ducula bicolor*). *Avian Pathol* 10:395-401, 1981.
  198. **Kaleta EF, et al:** A new herpesvirus isolated from black storks (*Ciconia nigra*). *Avian Pathol* 9:301-310, 1980.
  199. **Kaleta EF, et al:** Herpesvirus and Newcastle disease viruses in white storks (*Ciconia ciconia*). *Avian Pathol* 12:347-352, 1983.
  200. **Kaleta EF, et al:** Isolation and serological differentiation of a herpesvirus from bobwhite quail (*Colinus virginianus*). *Arch Virology* 66:359-364, 1980.
  201. **Kaleta EF, et al:** Persistent viraemia of a cell-associated herpesvirus in white storks (*Ciconia ciconia*). *Avian Pathol* 15:447-453, 1986.
  203. **Kaleta EF:** Aviäre Paramyxoviren: Typen und Subtypen. Seminar Über Isolierung und Charakterisierung von aviären Paramyxoviren. Gießen, 1989, pp 57-70.
  204. **Kaleta EF:** Detection of antibodies against avian paramyxovirus-1, -2, -3 in sera from pigeons. *Deutsch Tierärztl Wschr* 89:31-32, 1982.
  205. **Kaleta EF:** Hepatosplenitis infectiosa strigum und andere Krankheiten der Greifvogel und Eulen. *Zbl Vet Med Suppl* 25:173-180, 1976.
  206. **Kaleta EF:** Herpesviruses of birds: A review. *Avian Pathol* 19:193-211, 1990.
  207. **Kaleta EF:** Taubenherpesvirus (Plaques groß-klein- Impfstoff). Brief-taube, 1991.
  208. **Karpinski IG, et al:** An outbreak of pox in imported mynahs. *Proc Assoc Avian Vet*, 1986, pp 35-38.
  209. **Karunakaran D, et al:** The bioecology of avian influenza in migratory waterfowl. *Proc 30th West Poultry Dis Conf*, 1981, p 46.
  210. **Kelleher C, et al:** Epizootiology of avian influenza: Simultaneous monitoring of sentinel ducks and turkeys. *Proc 32th West Poultry Dis Conf*, 1983, pp 83-84.
  211. **Kibenge FSB, et al:** Effects of experimental immunosuppression on reovirus-induced tenosynovitis in light-hybrid chickens. *Avian Pathol* 16:73-92, 1987.
  212. **Kiel H:** Pockeninfektion bei Jagdfalken - Klinik, pathomorphologische Ergebnisse, Prophylaxe und Therapie - IV DVG-Tagung Vogelkrt München, 1985, pp 202-206.
  213. **King DJ, et al:** Infectious bronchitis. In Calnek BW, et al (eds): Diseases of Poultry 9th ed. Ames, Iowa State University Press, 1991, pp 471-484.
  214. **King DJ, et al:** Adenovirus isolation and serology from wild bobwhite quail (*Colinus virginianus*). *Avian Dis* 25:678-682, 1981.
  215. **Kirev TI:** Neoplastic response of guinea fowl to osteopetrosis virus strain MAV-2(0). *Avian Pathol* 17:101-112, 1988.
  216. **Kirmse P:** Host specificity and pathogenicity of pox viruses from wild birds. *Bull Wildl Dis Assoc* 5:376-386, 1969.
  217. **Kisary J, et al:** Failure of orally administered attenuated goose parvovirus strain B to induce a humoral immune response in adult geese. *Avian Pathol* 10:91-93, 1981.
  218. **Kisary J:** Parvovirus infections in chickens. In Calnek BW, et al (eds): Diseases of Poultry 9th ed. Ames, Iowa State University Press, 1991, pp 683-684.
  219. **Kitzing D:** Neuere Erkenntnisse über das Falkenpockenvirus. *Prakt Tierärztl* 61:952-954, 1980.
  - 219a. **Klenk HD:** Orthomyxoviridae. In: Francki RIB, et al (eds): Classification and nomenclature of viruses. Springer Verlag Wien-New York pp 261-272, 1991.

220. **Knoll M**: Immunitätsdauer nach Impfung gegen die Paramyxovirose der Tauben mit einer homologen ömulsion-vakzine - Ergebnisse eines Langzeitversuches unter Laborbedingungen. V. DVG-Taugung Vogelkhrth, München, 1986, pp 168-177.
221. **Kocan AA, et al**: Influenza A viruses isolated from migrating ducks in Oklahoma (reservoir of a virus that infects domestic species also). *J Wildl Dis* 16:281-285, 1980.
222. **Kösters J, et al**: Erfahrungen mit der Impfung gegen Paramyxovirus-Infektion bei Taue in der Bundesrepublik Deutschland. Die Brieftaube 108:1165-1168, 1991.
223. **Kraft V, et al**: Nachweis eines Pockenvirus bei Zwergpapageien (*Agapornis personata* und *Agapornis roseicollis*). *Berl Münch Tierärztl Wschr* 84:83-87, 1971.
224. **Krauss H**: Eine verlustreiche Aufzuchtkrankheit bei Gänseküken. *Berl Münch Tierärztl Wschr* 78:372, 1965.
225. **Krautwald ME, et al**: Heterogeneity of Pacheco's disease and its causative agents. *Proc Assoc Avian Vet*, 1988, pp 11-22.
226. **Krautwald ME, et al**: Polyomavirus infection in budgerigars (*Melopsittacus undulatus*): Clinical and aetiological studies. *J Vet Med B* 36:, 1989.
227. **Kronberger H**: Haltung von Vögeln. Krankheiten der Vögel 2. Auflage Verlag Fischer Jena, 1978.
228. **Landowska-Plazewska E, et al**: Ausbruch von Vogelpocken bei Humboldt-Pinguinen im Warschauer Zoo. *Verhber X Intl Symp Erkrankungen Zootiere*, Salzburg, 1968, pp 157-160.
229. **Latimer KS, et al**: A novel DNA virus associated with feather inclusions in BFD. *Vet Pathol* 28:300-304, 1991.
230. **Latimer KS, et al**: An updated review of psittacine beak and feather disease. *J Assoc Avian Vet* 5:211-220, 1991.
231. **Latimer KS, et al**: Cryptosporidiosis in four cockatoos with psittacine beak and feather disease. *J Am Vet Med Assoc* 200:707-710, 1992.
232. **Latimer KS, et al**: Extracutaneous viral inclusions in psittacine beak and feather disease. *J Vet Diagn Invest* 2:204-207, 1990.
233. **Lehn H, et al**: Cloning and characterization of budgerigar fledgling disease virus (BFDV), an avian polyomavirus. *Virology* 151:362-370, 1986.
234. **Leibovitz L**: Duck virus enteritis (duck plague). In Calnek BW, et al (eds): Diseases of Poultry 9th ed. Ames, Iowa State University Press, 1991, pp 609-618.
235. **Leighton FA**: Adenovirus-like agent in the bursa of Fabricius of herring gulls (*Larus argentatus pontoppidan*) from Newfoundland, Canada. *J Wildl Dis* 20:226-230, 1984.
236. **Lester T, et al**: Isolation of a virus from feathers of a cockatoo with feather loss syndrome. *ISR J Vet Med* 42:120-123, 1986.
237. **Ley DH, et al**: Experimental production of enteritis in bobwhite quail (*Colinus virginianus*) with cryptosporidium and reovirus. *Proc 35th West Poultry Dis Conf*, 1986, pp 107-109.
238. **Ley DH, et al**: Histomoniasis and reticuloendotheliosis in a wild turkey. *J Wildl Dis* 25:262-265, 1989.
239. **Ley DH**: Intestinal cryptosporidiosis and reovirus isolation from young pen-raised bobwhite quail with severe diarrhea and high mortality. *Proc 34th West Poultry Dis Conf*, 1985, pp 93-95.
240. **Una P, et al**: Detection of virus in squamous papillomas of wild bird species *Fringilla coelebs*. *J Natl Cancer Inst* 50:567-571, 1973.
241. **Lister SA, et al**: Outbreaks of nephritis in pheasants (*Phasianus colchicus*) with a possible coronavirus aetiology. *Vet Rec* 117:612-613, 1985.
242. **Lister SA, et al**: Paramyxovirus type 1 infection in racing pigeons and associated outbreaks in domestic poultry in the United Kingdom during 1984. *Proc 8th Intl Cong WVPM*, 1985, pp 118.
243. **Logemann K, et al**: Comparative studies for the characterization of avian adenovirus from quail and chickens. DVG VII Tagung Vogelkruhy München, 1990, pp 294-295.
244. **Löfliger H-CH**: Aviäre Onkovirosen. In Heider G, et al: Krankheiten des Wirtschaftsgeflügels, ein Handbuch für Wissenschaft und Praxis. Stuttgart, Gustav Fischer Verlag Jena, 1992, pp 695-770.
245. **Lowenshine L**: Diseases of psittacines differing morphologically from Pacheco's disease but associated with herpesvirus-like particles. *Proc 31st West Poultry Dis Conf*, 1982, pp 141-142.
246. **Lowenshine LJ, et al**: Adenovirus-like particles associated with intranuclear inclusion bodies in the renal tubules of lovebirds (*Agapornis* spp.) and a common murre (*Uria aalgaie*). *Proc 33rd West Poultry Dis Conf*, 1984, pp 105-106.
247. **Lowenshine LJ**: A potpourri of interesting avian cases. *Proc 1st Intl Conf Zool & Avian Med*, 1987, pp 105-107, 1987.
248. **Ludford CG, et al**: Duck infectious anemia virus associated with *Plasmodium lophurae*. *Exp Parasitol* 31:29-38, 1972.
249. **Lukas GN**: Observation on detection of VVND and chlamydia in birds. *Proc 11th West Poultry Dis Conf*, 1982, pp 127-127.
250. **Malkinson M, et al**: Reovirus infection of young muscovy ducks (*Cairina moschata*). *Avian Pathol* 10:433-410, 1981.
251. **Malkinson M, et al**: Serological survey for the prevalence of antibodies to egg drop syndrome 1976 virus in domesticated and wild birds in Israel. *Avian Pathol* 9:421-426, 1980.
252. **Malkinson M**: An outbreak of an acute neoplastic syndrome accompanied by undifferentiated leukemia in a flock of muscovy ducks. *Proc 31st West Poultry Dis Conf*, 1982, p 110.
253. **Mann A, et al**: Neuropathic gastric dilatation in Psittaciformes. *Avian Dis* 31:214-221, 1987.
254. **Mare CJ, et al**: Falcon herpesvirus, the etiologic agent of inclusion body disease of falcons. *Infection & Immunity* 7:118-126, 1973.
255. **Marius V**: Characterization of a reovirus isolated from muscovy ducks. Study of virulence for different species of fowl and waterfowl. Study of immunity afforded by Reovirus vaccine (S1133). WPSA Europ Waterfowl Dis Symp, 1981.
256. **Marshall R**: Papova-like virus in a finch aviary. *Proc Assoc Avian Vet*, 1989, pp 203-207.
257. **Mathey WJ, et al**: Tremors of nestling budgerigars with BFD. *Proc 33rd West Poultry Dis Conf*, 1984, p 102.
258. **Maslin WR, et al**: Effect of a reovirus isolated from broilers with pale bird syndrome on SPF chicks. *Proc 33th West Poultry Dis Conf*, 1984, pp 67-68.
259. **McCracken, et al**: Experimental studies on the aetiology of inclusion body hepatitis. *Avian Pathol* 5:325-339, 1976.
260. **McDonald SE**: Clinical experience with cloacal papillomas. *Proc Assoc Avian Vet*, 1988, pp 27-30.
261. **McDonald SE**: Pacheco's parrot disease. *Assoc Avian Vet Aviculture Seminar*, 1991, pp 81-87.
262. **McFerran JB, et al**: Isolation of adenoviruses and reoviruses from avian species other than domestic fowl. *Avian Dis* 20:519-524, 1976.
263. **McFerran JB, et al**: Studies on a paramyxovirus isolated from a finch. *Arch Ges Virusforsch* 46:281-290, 1974.
264. **McFerran JB, et al**: Avian adenoviruses: A review. *Avian Pathol* 6:189-217, 1977.
265. **McFerran JB, et al**: Isolation of adenoviruses and reoviruses from avian species other than domestic fowl. *Avian Dis* 20:519-524, 1976.
266. **McFerran JB, et al**: Isolation of viruses from clinical outbreaks of inclusion body hepatitis. *Avian Pathol* 5:315-324, 1976.
267. **McFerran JB**: Adenovirus infections. In Calnek BW, et al (eds): Diseases of Poultry 9th ed. Ames, Iowa State University Press, 1991, pp 552-582.
268. **McFerran JB**: Egg drop syndrome. In Calnek BW, et al (ed): Diseases of Poultry 9th ed. Ames, Iowa State University Press, 1991, pp 573-582.
269. **McKeen WD**: Considerations for wild bird control during a Newcastle disease epidemic. *Proc 21th West Poultry Dis Conf*, 1972, pp 52-56.
270. **McNulty MS**: Rotavirus infections. In Calnek BW, et al (eds): Diseases of Poultry 9th ed. Ames, Iowa State University Press, 1991, pp 628-635.
271. **McOrist S, et al**: Psittacine beak and feather dystrophy in wild sulphur-crested cockatoos (*Cacatua galericata*). *J Wildl Dis* 20:120-124, 1984.
272. **McOrist S, et al**: Viral enteritis in cockatoos (*Cacatua* spp.). *Avian Pathol* 20:531-539, 1991.
273. **McOrist S**: Some diseases of free-living Australian birds. ICBP Technical Publication 16:13-68, 1989.
274. **Meister JD**: Untersuchungen zur Diagnose, Differential diagnose, Klinik, Epizootiologie und Immunophylaxe der Paramyxovirus-1-Infektion der Hausstaube (*Columba livia* Gmelin, 1789 variatio domestica). *Vet Diss*, Gießen, 1987.
275. **Meulemans G, et al**: Isolation of orthoreovirus from psittacine birds. *J Comp Pathol* 93:127-134, 1983.
276. **Minamoto N, et al**: Isolation and characterization of rotavirus from feral pigeons in mammalian cell cultures. *Epidemiol Infect* 100:481-492, 1988.
- Minor P**: Picornaviridae. In: Francki RIB, et al (eds): Classification and nomenclature of viruses. Springer Verlag Wien-New York pp 320-322, 1991.
277. **Mohammed MA, et al**: Contagious paralysis of pigeons. *Avian Pathol* 7:637-643, 1978.
278. **Mohan R**: Clinical and laboratory observations of reovirus infection in a cockatoo and a grey-cheek parrot. *Proc Intl Conf Avian Med*, 1984, pp 29-33.
279. **Monreal G**: Adenovirusinfektionen. In Heider, et al: Krankheiten des Wirtschaftsgeflügels, ein Handbuch für Wissenschaft und Praxis. Stuttgart, Gustav Fischer Verlag Jena Bd. 1, 1992, pp 379-414.
280. **Mori F, et al**: Inclusion bodies containing adenovirus-like particles in the kidneys of psittacine birds. *Avian Pathol* 18:197-202, 1989.
281. **Müller H, et al**: A polyoma-like virus associated with acute disease of fledgling budgerigars (*Melopsittacus undulatus*). *Med Microbiol Immunol* 175:1-13, 1986.
- 281a. **Müller H**: Budgerigar fledgling disease virus, (BFDV). V. DVG-Tagung Vogelkhrth., München pp 294-298, 1986.
282. **Müller H**: Strukturelle Eigenschaften des Virus der Nestlingskrankheit der Wellensittiche, eines aviären Polyomavirus mit ungewöhnlichen biologischen Eigenschaften. 2nd Europ Symp Avian Med Sur, 1989, pp 193-197.
283. **Mumme J, et al**: Anthropozoonosen von Menschen auf Tiere übertragbare Krankheiten (3). *Tierärztl Prax* 8:13-20, 1980.
284. **Mustafa-Babjee A, et al**: Acute enteritis in rainbow lorikeets. *Kajian Vet* 5:16-19, 1973.
285. **Mustafa-Babjee A, et al**: A pathogenic paramyxovirus from a budgerigar. *Avian Dis* 18:226-230, 1974.
286. **Myers TL, et al**: Intestinal IgA response and immunity to rotavirus infection in normal and antibody deficient chickens. *Avian Pathol* 19:697-712, 1990.
287. **Nair M, et al**: Studies on broilers' IBV and IB-like virus from Guinea Fowl. WVPA II Intl Symp IB Rauschholzhausen Germany, 1991, pp 302-307.
288. **Nerome K, et al**: Isolation and serological characterization of influenza A virus from birds that were dead on arrival at Tokyo airport. *Arch Virol* 57:261-270, 1978.
289. **Nerome K, et al**: Isolation of a new avian paramyxovirus from budgerigars. *J Gen Virol* 38:293-301, 1978.
290. **Neumann U, et al**: Neoplasms in budgerigar (*Melopsittacus undulatus*): Clinical, pathomorphological and serological findings with special consideration of kidney tumors. *Avian Pathol* 12:353-362, 1983.
291. **Neumann U**: Lymphoproliferative Krankheit der Puten. In Heider G, et al: Krankheiten des Wirtschaftsgeflügels, ein Handbuch für Wissenschaft und Praxis. Stuttgart, Gustav Fischer Verlag Jena, 1992, pp 781-784.
292. **Niagro FD, et al**: Avian polyomavirus. Discordance between neutralizing antibody titers and viral shedding in an aviary. *Proc Assoc Avian Vet*, 1991, pp 22-26.
293. **Niagro FD, et al**: Use of polymerase chain reaction for detection of BFD in suspect birds. *Proc Assoc Avian Vet*, 1990, pp 25-37.
294. **Norton TM, et al**: Acyclovir pharmacokinetics and the efficacy of acyclovir against Pacheco's disease virus in quaker parakeets. *Proc Assoc Avian Vet*, 1989, pp 3-5.
295. **Nuttall PA, et al**: Poxvirus infections in the manx shearwater (*Puffinus puffinus*). *J Wildl Dis* 21:120-124, 1985.
296. **Okoh AE**: Newcastle disease in falcons (as vectors of the disease to poultry in Nigeria). *J Wildl Dis* 15:479-480, 1979.
297. **Olson NC**: A respiratory disease (bronchitis) of quail caused by a virus. *Proc 54th US Lestf San Assoc*, 1950, pp 171-174.
298. **Osterhaus A, et al**: Identification and characterization of a papillomavirus from birds (Fringillidae). *Intervirolog* 8:351-359, 1977.
299. **Ottis K, et al**: Isolation and characterization of ortho- and paramyxovirus from feral birds in Europe. *Zbl Vet Med B* 30:22-35, 1983.
300. **Ozdemir I, et al**: Monoclonal antibodies to avian paramyxovirus type 2. *Avian Pathol* 19:395-400, 1990.
301. **Pacheco G, et al**: Epizootie chez les perroquets du Brésil. Relations avec la psittacose. *CR Soc Biol*, (Paris) 105:109-111, 1930.
302. **Pascucci S, et al**: Characterization of a coronavirus-like agent isolated from coturnix quail. *Proc VIII Intl Congr WVPA*, Jerusalem, 1985, p 52.
303. **Pascucci S, et al**: Transmissible enteritis of guineafowl: Electron microscopic studies and isolation of a Rotavirus strain. *Proc 7th Intl Congr WVPA*, 1981, p 57.
304. **Pascucci S, et al**: CELO virus in guineafowl: Characterization on two isolates. *Proc 5 Intl Kongreß WVPA Vol II*, 1973, pp 1524-1531.
305. **Pass DA, et al**: Granulomatous dermatitis in peach-faced lovebirds. *Aust Vet J* 64:285-287, 1987.
- 305a. **Pass DA**: Inclusion bodies and hepatopathies in psittacines. *Avian Pathology* 16:581-597, 1987.

## CHAPTER 32 VIRUSES

306. **Pass DA, et al:** The pathology of psittacine beak and feather disease. *Aust Vet J* 61:69-74, 1984.
307. **Pass DA, et al:** A papova-like virus infection of splendid parakeets (*Neophema splendida*). *Avian Dis* 31:680-684, 1987.
308. **Pass DA, Perry RA:** Psittacine beak and feather disease. An update. *Aust Vet Pract* 15:55-60, 1985.
309. **Pass DA, Perry RA:** The pathogenesis of psittacine beak and feather disease. *Proc Assoc Avian Vet* 1984, pp 113-119.
310. **Pass DA:** A papova-like virus infection of lovebirds (*Agapornis* sp.). *Aust Vet J* 82:318-319, 1985.
311. **Pass DA:** Inclusion bodies and hepatopathies in psittacines. *Avian Pathol* 16:581-597, 1987.
312. **Payne LN (ed):** Marek's Disease. Boston, Martinus Nijhoff, 1985.
313. **Payne LN, et al:** Leucosis/sarcoma group. In: Calnek BW, et al (eds): Diseases of Poultry 9th ed. Ames, Iowa State University Press, 1991, pp 386-349.
314. **Perelman B, et al:** Pox in ostriches. *Avian Pathol* 17:735-739, 1988.
315. **Perry RA:** Some feather characteristics of acute french molt in fledgling budgerigars (*Melopsittacus undulatus*). *Aust Vet Pract* 13:128, 1983.
316. **Perry RA:** A psittacine combined beak and feather disease syndrome with particular reference to the Australian cockatoos *Cacatua galerita* (Sulphur-crested Cockatoo), *Cacatua leadbeateri* (Major mitchell or Pink Cockatoo), *Cacatua roseicapilla* (Galah or Rose-breasted Cockatoo) and *Cacatua sanguinea* (Little Corella). Univ Sydney. Post-grad Comm Vet Sci. Refresher Course on Avian and Caged Birds Proc No 55, 1981, pp 81-104.
317. **Perry RA, Pass DA:** Psittacine beak and feather disease including French molt in parrots in Australia. *Proc Assoc Avian Vet* 1985, pp 35-38.
- 317a. **Perry RA:** Beak rot in Sulfur Crested Cockatoos. The University of Sydney. The post-graduate committee in veterinary science. Control and therapy article 2:329 (No 329), 1975.
318. **Petrak ML (ed):** Diseases of Caged and Aviary Birds 2nd ed. Philadelphia, Lea & Febiger, 1982.
319. **Pfister R:** Zur Verträglichkeit und Wirksamkeit einiger Adjuvantien in Impfstoffen gegen die Paramyxoviriose der Tauben. *Vet Diss, München*, 1987.
320. **Phalen DN, Wilson DG, Graham DL:** Polymerase chain reaction assay for avian polyomavirus. *J Clin Micro* 29:1080-1037, 1991.
- 320a. **Phalen DN:** Acute pancreatic necrosis in an umbrella cockatoo. *Proc Assoc Avian Vet* pp 203-205, 1988.
321. **Phalen DN, Wilson DG, Graham DL:** Avian polyomavirus biology and its clinical applications. *Proc Europ Conf Avian Med & Surg*, 1993, pp 200-216.
322. **Philpott, MS et al:** Antigenic and phenotypic variants of a virulent avian influenza virus selected during replication in ducks. *J Wildl Dis* 25:507-513, 1989.
323. **Pieper K, et al:** Directions for use: Pacheco's disease vaccine, killed virus. 1st Conf Europ Assoc Avian Vet, 1991, pp 210-211.
324. **Pomeroy BS, et al:** Coronavirus enteritis of turkeys (bluecomb disease). In: Calnek BW, et al (eds): Diseases of Poultry 9th ed. Ames, Iowa State University Press, 1991, pp 621-627.
325. **Potel K:** Geflügelpocken, Variola avium. In: Rohrer H: *Hanbuch der Virusinfektionen bei Tieren*. Vol II. Gustav Fischer Verlag, Jena, 1967, pp 603-613.
- 325a. **Pringle CR:** Paramyxoviridae. In: Francki RB, et al (eds): Classification and nomenclature of viruses. Springer Verlag Wien-New York pp 242-246, 1991.
326. **Ramis AJ, et al:** Inclusion body hepatitis (IBH) in a group of *Eclectus roratus*. *Proc Europ Assoc Avian Vet*, 1991, pp 444-446.
327. **Randall CJ, et al:** Papovavirus-like infection in budgerigars (*Melopsittacus undulatus*). *Avian Pathol* 16:623-633, 1987.
328. **Reece RL, et al:** Inclusion body hepatitis in a tawny frogmouth (*Podargus strigoides*: Caprimulgiformes). *Aust Vet J* 62:426, 1985.
329. **Reece RL, et al:** Inclusion body hepatitis in guinea fowl (*Numida meleagris*). *Aust Vet J* 63:26-27, 1986.
330. **Reed WM:** Characterization of pox viruses isolated from recent outbreaks of avian pox. *Proc West Poul Dis Conf Supplement*, 1991, pp 11-12.
331. **Reed WM:** Pathogenicity and immunologic relationship of quail and mynah pox viruses to fowl and pigeon pox viruses. *Proc 37th West Poul Dis Conf*, 1988, pp 5-8.
332. **Reid HW, et al:** Experimental Louping-ill virus infection of black grouse (*Tetrao tetrix*). *Arch Virology* 78, 1983.
333. **Richter R:** Paramyxovirusinfektion bei Tauben. DVG III Tagung Vogelkrankheiten, München, 1983, pp 86-95.
334. **Richter R:** Untersuchungen zur Steigerung der Immunantwort durch den Paramunitätsinducer PIND Orff beim Geflügel. *Diss med vet*, München, 1983.
335. **Riddell C:** Virus hepatitis in domestic geese in Saskatchewan. *Avian Dis* 28:774-782, 1984.
336. **Rinaldi A, et al:** Atti della Società Italiana della Scienza Veterinaria 22:77-782, 1968.
337. **Ritchie BW, et al:** A review of psittacine beak and feather disease. *J Assoc Avian Vet* 3:143-149, 1989.
338. **Ritchie BW, et al:** Advances in understanding the PBFV virus. *Proc Assoc Avian Vet*, 1990, pp 12-24.
339. **Ritchie BW, et al:** Antibody response to and maternal immunity from an experimental psittacine beak and feather disease vaccine. *Am J Vet Res* 53:1512-1518, 1992.
340. **Ritchie BW, et al:** Hemagglutination by psittacine beak and feather disease virus and use of hemagglutination inhibition for detection of antibodies against the virus. *Am J Vet Res* 52:1810-1815, 1991.
341. **Ritchie, BW, et al:** Production and characterization of monoclonal antibodies to psittacine beak and feather disease virus. *J Vet Diagn Invest* 4:13-18, 1992.
342. **Ritchie BW, et al:** Routes and prevalence of shedding of psittacine beak and feather disease virus. *Am J Vet Res* 52:1804-1809, 1991.
343. **Ritchie BW, et al:** Ultrastructural, protein composition and antigenic comparison of Psittacine Beak and Feather Disease virus purified from four genera of psittacine birds. *J Wildl Dis* 26:196-203, 1990.
344. **Ritchie BW, et al:** Polyomavirus infections in adult psittacine birds. *J Assoc Avian Vet* 5:202-206, 1991.
345. **Ritchie BW, Niagro FD, Lukert PD, et al:** Characterization of a new virus from cockatoos with psittacine beak and feather disease. *Virology* 171:83-88, 1989.
346. **Ritchie BW:** A review of eastern equine encephalomyelitis in pheasants. *Assoc Avian Vet Today* 1:152-154, 1987.
347. **Roizman B, et al:** Herpesviridae, definition, provisional nomenclature and taxonomy. *Intervirology* 16:201-217, 1981.
348. **Romvary J, et al:** The role of wild birds in the spread of influenza viruses. *Acta Microbiol Acad Sci Hung* 27:269-277, 1980.
349. **Rosenberger JK, et al:** Reovirus infections. In: Calnek BW: Diseases of poultry. 9th ed., Wolfe Publishing Ltd pp 639-647, 1991.
350. **Rosenberger JK:** Reovirus interference with Marek's virus vaccination. *Proc 32th West Poul Dis Conf*, 1983, pp 50-51.
351. **Roskopf WJ, et al:** Erythremic myelosis in coureurs, the "hemorrhagic coure syndrome" - a preliminary report. *Proc Intl Conf Avian Med*, 1984, pp 213-228.
352. **Roskopf WJ Jr:** Vaccine therapy for papillomas. *Assoc Avian Vet Today* 1:202, 1987.
353. **Rotz von A, et al:** Letal verlaufende Herpesvirusinfektion bei Gouldsamadinen (*Chloeobia gouldinae* (Gould)). *Schweiz Arch Tierheilk* 126:651-658, 1984.
354. **Sabban MS:** Susceptibility and possible role of doves in transmission of Newcastle disease in Egypt. *Zbl Vet Med* 29:193-198, 1982.
355. **Schaffner T, Herring J, Garber H, Cotler H:** Bursa of Fabricius: Uptake of radioactive particles and radiotoxic sealing of bursal follicles. *Adv Exp Med Bio* 66:33-39, 1976.
356. **Schat KA, et al:** A tumor-like disease in the Japanese quail. *Proc 24th West Poul Dis Conf*, 1975, pp 5-6.
357. **Schat KA, et al:** Intestinal immunity in avian species. *Proc West Poul Dis Conf* pp. 21-22, 1990.
358. **Schemera B et al:** A paramyxovirus of the serotype 3 from African, Australian and Indian finches. *Proc Europ Symp Avian Dis*, Beerse, 1987, pp 89-97.
359. **Schettler CH:** Die Virushepatitis der Gänse. *Vet Hab Schrift*, München, 1973.
360. **Schettler CH:** Virus hepatitis of geese. 3. Properties of the causal agent. *Avian Pathol* 2:179-193, 1973.
361. **Schettler H:** Eine infektiöse Leberentzündung (Hepatitis) der Eulen. *Tierärztl Umsch*, 1969, p 163.
362. **Schmidt RE:** Pathologist's view of PBFV in African greys. *J Assoc Avian Vet* 4:18, 1990.
363. **Schmidt RE, et al:** Morphologic identification of a papovavirus in a Moluccan cockatoo (*Cacatua moluccensis*) with neurologic signs. *Assoc Avian Vet Today* 1:107-108, 1987.
364. **Schmidt J, et al:** Immunologische Probleme der Influenzavirusinfektion. *Arch Exp Vet Med* 32:377-390, 1978.
365. **Schneegans D:** Erfahrungen mit der Paramunisierung Bei Vögeln. *Tierärztl Praxis* 17:293-295, 1989.
366. **Schneegans D:** Nachweise von Paramyxovirus-1 bei Bartgeiern (*Gypaetus barbatus*) DVG VII. Tagung Vogelkrankheiten, München 1990, pp 262-269.
367. **Schneegans D, et al:** Zum aktuellen Vorkommen aviärer Paramyxoviren. *Tierärztl Praxis* 16:159-160, 1988.
368. **Schädel F, et al:** The biology of avian hepatitis B virus. In: *Molecular Biology of Hepatitis B Virus*. Raton, CRC Uniscience, 1990.
369. **Schönbauer M, et al:** Über eine Virusinfektion bei Prachtfinken (Estrildidae). *Kleintierpraxis* 27:149-152, 1982.
370. **Schraishuhm P, et al:** Ergebnisse virologischer Untersuchungen und ca. 1012 Brieftauben. DVG VII Tagung Vogelkrankh. München, 1990, pp 114-119.
371. **Schroder D:** Untersuchungen am Herpesvirus der Hepatosplenitis infectiosa strigum. VII DVG-Tagung Vogelkrankh, München, 1990, pp 298-304.
372. **Scott PC, et al:** Inclusion body hepatitis associated with adenovirus-like particles in a cockatiel (*Psittaciformes: Nymphicus hollandicus*). *Aust Vet J* 63:337-338, 1986.
373. **Several Authors:** Open forum on the use of Pacheco's disease vaccines in psittacines. *J Assoc Avian Vet* 5:10-14, 1991.
374. **Shablovskaia EJ, et al:** Isolation von mit Influenza A/Enfland/42/72 identischen Viren von semisyantrophischen Vogelarten in der Rovnoregion der Ukrainischen SSR. *Vopr Virolog Moska* B14:414-418, 1977.
375. **Shokal M:** Zur Isolierung und Charakterisierung von aviären Paramyxovirus-Stämmen aus ägyptischen und detuschen Haustauben (*Columba livia* Gmel. 1789 var. dom.) unter Verwendung von permanentzellen. *Vet Diss, München*, 1989.
376. **Shaw K:** Papovaviruses. In: Fields BN, et al (eds): *Virology*. Raven Press, New York, 1985, pp 371-391.
377. **Shorridge KF, et al:** Isolation and properties of viruses from poultry in Hong Kong which present a new (sixth) distinct group of avian paramyxoviruses. *J Gen Virol* 50:410-418, 1981.
378. **Siegmann O:** Kompendium der Geflügelkrankheiten 4th ed. Hannover, Verlag M&H Schaper, 1983.
379. **Sileo L, et al:** Hemorrhagic enteritis in captive American kestrels (*Falco sparverius*). *J Wildl Dis* 19:244-247, 1983.
380. **Simpson CF, et al:** Psittacine herpesvirus infection resembling Pacheco's parrot disease. *J Infect Dis* 131:390-396, 1975.
381. **Sironi G, et al:** Papovavirus-like splenohepatic infection in greenfinches (*Carduelis chloris*). *Clinica Veterinaria* 110:79-82, 1987.
382. **Sironi G:** Concurrent papovirus-like and atoxoplasma infections in a gold finch (*Carduelis carduelis*). *Avian Path* 20:725-729, 1991.
383. **Slemmons RD, et al:** Type A-Influenza virus in wild free-flying birds. 3rd Intl Wildl Dis Conf, Munich, 1975.
384. **Smadel JE, et al:** A new virus disease of pigeons: I. Recovery of the virus. *J Exp Med* 81:385-398, 1945.
385. **Smit TH, et al:** Studies on a virus isolated from the brain of a parakeet (*Neophema* sp.). *Avian Pathology* 5:21-30, 1976.
386. **Smith RE:** Psittacine feather and beak disease: A cluster of cases in a cockatoo breeding facility. *Proc Assoc Avian Vet*, 1986, pp 17-20.
387. **Smits CW, et al:** Ortho- and paramyxoviruses in the migratory waterfowl of Michigan (Possible transfer to domestic fowl). *J Wildl Dis* 17:147-151, 1981.
388. **Snoyenbos GH:** Turkey viral hepatitis. In: Calnek BW, et al (eds): Diseases of Poultry 9th ed. Ames, Iowa State University, 1991, pp 699-701.
389. **Spackman D, et al:** Isolation of infectious bronchitis virus from pheasants. *Vet Rec* 113:354-355, 1983.
390. **Speer B:** Proventricular dilatation as a pediatric disease. *J Assoc Avian Vet* 4:15, 1990.
391. **Speer B:** Unusual expression of PBFV. *J Assoc Avian Vet* 4:19, 1990.
392. **Speer BL:** The eclectus parrot, medicine and avicultural aspects. *Proc Assoc Avian Vet*, 1989, pp 239-247.
393. **Sprengel R, et al:** Hepatitis B Viren bei Enten, Gänsen und Graureihern: Epidemiologie, Diagnostik und Pathogenese. VI DVG-Tagung Vogelkrankh, München, 1988, pp 176-187.
394. **Stallknecht DE, et al:** Avian paramyxoviruses from migrating and resident ducks in coastal Louisiana. *J Wildl Dis* 27:123-128, 1991.
395. **Steenis van G:** Survey of various avian species for neutralizing antibody and susceptibility to avian encephalomyelitis virus. *Res Vet Sci* 12:308-311, 1971.
396. **Stehle S:** Krankheiten bei Greifvögeln (Accipitres) und bei Eulen (Stragies) mit Ausnahme der parasitären Erkrankungen. *Vet Diss*, Hannover, 1965.

397. **Stoll R, et al:** Molecular and biological characteristics of avian polyomaviruses: Isolates from different species of birds indicate that avian polyomaviruses form a distinct subgenus within the polyomavirus genus. *J Gen Virol* in press.
398. **Stünzner D, et al:** Isolierung von Influenzaviren aus exotischen und mitteleuropäischen Vogelarten. *Zbl Bakt Hyg I Abt Orig A* 247:8-17, 1980.
399. **Sundberg JP, et al:** Cloacal papillomas in psittacines. *Am J Vet Res* 47:928-932, 1986.
400. **Takase K, et al:** Cytopathic avian rotavirus isolated from duck feces in chicken kidney cell cultures. *Avian Pathol* 15:719-730, 1986.
401. **Tanyi J, et al:** Influenzavirus-A-Infektion. In Heider, et al: *Krankheiten des Wirtschaftsgeflügels, ein Handbuch für Wissenschaft und Praxis*. Stuttgart, Gustav Fischer Verlag Jena, 1992, pp 669-682.
402. **Tanyi J:** Type A Influenza virus infection in guinea fowls. *Acta Vet Acad Sci Hung* 22:125-131, 1972.
403. **Tikasingh ES, et al:** Avian pox in birds from Trinidad. *J Wildl Dis* 18:133-139, 1982.
404. **Todd D, et al:** Comparison of three animal viruses with circular single-stranded DNA genomes. *Arch Virol* 117:129-135, 1991.
406. **Trampel DW, et al:** Parvovirus-like enteropathy in Missouri turkeys. *Avian Dis* 27:49-54, 1983.
407. **Trötschel A:** Pathomorphologie der akuten Form der Nephro-Enteritis der Junggänse. *Vet Diss*, München, 1973.
408. **Tudor DC:** Pigeon Health and Disease. Ames, Iowa State University Press, 1991, pp 47-49.
409. **Tully TN:** Eastern equine encephalomyelitis in emus. *Proc Assoc Avian Vet*, 1992, pp 316-317.
410. **Tumova B, et al:** A further member of the Yucalpa group isolated from the common wren (*Troglodytes troglodytes*). *Acta Virol* 23:504-507, 1979.
411. **Uytenbroek E, et al:** Epidemiology of Adenovirus infections in pigeons. *Proc Europ Assoc Avian Vet*, 1991, 289-292.
412. **VanDertHeyden N:** Psittacine papillomas. *Proc Assoc Avian Vet*, 1988, pp 23-26.
413. **VanDertHeyden N, et al:** Paramyxovirus group 3 infection in cockatiels. *Assoc Avian Vet Today* 1:53-54, 1987.
414. **Vasicek L:** Paramyxovirus 1 in pigeons and its influence on Newcastle disease (ND)-unvaccinated poultry flocks. *Proc 8th Intl Cong WVPA*, 1985, pp 118.
415. **Vindevogel H, et al:** Incidence of rotavirus, adenovirus and herpesvirus in pigeons. *Vet Rec* 109:285-286, 1981.
416. **Vindevogel H, et al:** Reovirus infection in the pigeon. *Ann Rech Vet* 13:149-152, 1982.
417. **Vindevogel H, et al:** Comparaison de trois souches de virus herpétique isolée des psittacides avec le virus herpes du pigeon. *Avian Pathol* 9:385-394, 1980.
418. **Vogel K, et al:** Herpesvirus-1-Infektion der Tauben. In Heider, et al: *Krankheiten des Wirtschaftsgeflügels. Ein Handbuch für Wissenschaft und Praxis*. Stuttgart, Gustav Fischer Verlag, Jena, 1992, pp 439-450.
419. **Waddell G, et al:** Genetic variability of adenoviruses. *Ann N Y Acad Sci* 354:16-42, 1980.
420. **Wadsworth PF, et al:** Some cases of lymphoid leukosis in captive wild birds. *Avian Pathol* 10:499-504, 1981.
421. **Wagner K, et al:** Ein im Hühnerrei vorkommendes Parainfluenzavirus. *Zbl Vet Med B* 13:215-218, 1966.
422. **Wagner K, et al:** Zur Epidemiologie des Parainfluenza-II-Virus der Hühner. *Dtsch tierärztl Wschr* 72:486-488, 1965.
423. **Wainright PO, et al:** Identification of viruses from amazon parrots with a hemorrhagic syndrome and a chronic respiratory disease. *Proc 1st Intl Conf Zool & Avian Med*, 1984, pp 15-19.
424. **Wainwright PO, et al:** Serological evaluation of some psittaciformes for budgerigar fledgling disease virus. *Avian Dis* 31:673-676, 1987.
425. **Wallner-Pendleton E, et al:** An inclusion-body pancreatitis in *Agapornis*. *Proc 32nd West Poul Dis Conf*, 1983, p 99.
426. **Ward FP, et al:** Inclusion body hepatitis in a prairie falcon. *J Wildl Dis* 7:120-124, 1971.
427. **Weingarten M:** Entenpest: Klinik, Diagnose, Bekämpfung. VI. DVG-Tagung Vogelkrht, 1988, pp 197-203. München.
428. **White DO, Fenner F (eds):** *Medical Virology* 3rd ed. Orlando, Academic Press Inc, 1986, pp 381-388.
429. **WHO Expert Committee:** A revision of the system of nomenclature for Influenza viruses: A WHO memorandum. *Bull WHO* 58:585-591, 1980.
430. **Will H, et al:** Hepatitis-B-Virus-Infektion der Enten. In Heider G, et al: *Krankheiten des Wirtschaftsgeflügels*. Stuttgart, Gustav Fischer Verlag Jena, 1992, pp 361-377.
431. **Winterfield RW, et al:** Immunization against psittacine pox. *Avian Dis* 29(3):886-890, 1985.
432. **Winterfield RW, et al:** Quail bronchitis. In Calnek BW, et al (eds): *Poultry Diseases* 9th ed. Ames, Iowa State University Press, 1991, p 564.
433. **Winteroll G, et al:** Schwere durch Herpesvirus verursachte Erkrankung des Respirationsapparates bei Amazonen. *Berl Münch Tierärztl Wschr* 92:277-280, 1979.
434. **Witter RL, et al:** Lymphomas resembling lymphoid leukosis in chickens inoculated with reticuloendotheliosis virus. *Int J Cancer* 23:6763-678, 1979.
435. **Witter RL, et al:** Tolerance, viral shedding and neoplasia in chickens infected with non-defective reticuloendotheliosis virus. *Avian Dis* 25:374-394, 1981.
436. **Witter RL:** Reticuloendotheliosis. In Calnek BW, et al (eds): *Diseases of Poultry* 9th ed. Ames, Iowa State University Press, 1991, pp 439-456.
437. **Woelfling P:** Über die Wirkung verschiedener Desinfektionsmittel und einige geflügelpathogene Virusarten. DVG-Tagung Fachgruppe "Geflügelkrankheiten" Oldenburg, 1976, pp 69-82.
438. **Wolter, HE:** *Die Vogelarten der Erde*. Hamburg and Berlin, Paul Parey, 1975-1982.
439. **Woods L, et al:** Comparison of PBFD virus and pigeon circovirus. In preparation.
440. **Woods L:** Case report: Papova-like virus in a painted finch. *Proc Assoc Avian Vet*, 1989, pp 218-219.
441. **Woolcock PR, et al:** Duck virus hepatitis. In Calnek BW, et al (eds): *Diseases of Poultry* 9th ed. Ames, Iowa State University Press, 1991, pp 597-608.
442. **Wyand DS, et al:** Marble spleen disease in ring-necked pheasants: Histology and ultrastructure. *Avian Dis* 16:319-329, 1972.
443. **Wylie SL, Pass DA:** Experimental reproduction of psittacine beak and feather disease/French molt. *Avian Pathol* 16:269-281, 1987.
444. **Wylie SL, Pass DA:** Investigations of an enteric infection of cockatoos caused by an entero-like agent. *Avst Vet J* 66:321-324, 1989.
445. **York SM, et al:** Pacheco's virus vaccine studies. *Proc 32th West Poul Dis Conf*, 1983, pp 101-103.
446. **Yuasa N, et al:** Isolation and some characteristics of an agent inducing anemia in chicks. *Avian Dis* 23:366-385, 1979.
447. **Zellen GK, et al:** Adenoviral pancreatitis in guineafowl (*Numida meleagris*). *Avian Dis* 33:586-589, 1989.
448. **Zhang C, et al:** Differentiation of avian adenovirus type II strains by restriction endonuclease fingerprinting. *J Am Vet Med Assoc* 50:1466-1470, 1989.
449. **Zsak I, et al:** Characterization of adenovirus isolated from geese. *Avian Pathol* 13:253-264, 1984.
450. **Zwart P, et al:** Sialolithen (weiße Punkte) im Munddach bei Tauben III DVG-Tagung, Vogelkrht München, 1983, pp 39-45.



**S**cientific principles of bacteriology are universal; however, in application, bacteria can adapt to their avian hosts, altering the form and pathogenicity of well known bacterial species. Avian bacteriology is further complicated by the fact that bacteria that are as yet taxonomically undescribed can be isolated from a variety of avian species. Some of these bacterial strains have been erroneously classified as taxons (eg, *Pasteurella haemolytica*, *Alcaligenes faecalis*). In general, bacterial adaption to an avian host minimizes cross-species transmission from birds to mammals. Non-host-adapted transmission usually requires large numbers of organisms, repeated exposures, specific susceptibility or immunosuppression. Some host-adapted strains may form biovars that are specific to one avian species (or a few closely related species) as compared to the dominant species.

Example of Bacterial Taxonomy:

Genus	<i>Salmonella</i>
Species	<i>S. typhimurium</i>
Subspecies	<i>S. typhimurium</i> var <i>copenhagen</i>
Biovar	Pigeon strains, chicken strains

Bacterial infections may be primary or secondary. This differentiation is important for the evaluation of a disease process. After becoming established, many secondary invaders are able to maintain a disease process independent of other infectious agents or predisposing conditions. Laboratory examinations (biochemical or serologic) are rarely of any help in differentiating primary from secondary invaders. The companion bird clinician must determine the importance of bacterial isolation for a specific bird species and a specific disease process. Analogous conclusions drawn from poultry literature may not be valid, and experimental infections are frequently not possible. Some specific points may guide the clinician in interpreting bacterial culture results (Table 33.1).

CHAPTER

33

BACTERIA

Helga Gerlach

**TABLE 33.1** Guides to Interpretation of Bacterial Culture Results<sup>27</sup>

- Isolation of an organism in an almost pure culture (approximately 80% of the colonies present) may indicate that the bacteria is a component in the disease process.
- Isolating large numbers of bacteria in almost pure culture from the heart tissue is suggestive of bacteremia, and the isolated agent should be considered part of the disease process.
- Isolating a bacteria that is part of the autochthonous flora may indicate that it is functioning as an opportunistic (secondary) pathogen.
- If the isolated organism has pathogenicity markers, it is probably involved in the disease process. It is not possible to determine if the bacteria is a primary or secondary pathogen.
- Isolating bacteria from parenchyma with pathologic or histopathologic lesions suggests that the agent contributed to the disease process.
- Isolating a bacterium without identifying other microorganisms (virus, chlamydia, other bacteria, fungi, protozoa) suggests that the agent is a primary pathogen. Finding virus or chlamydia suggests that the bacterium may be a secondary pathogen. Isolation of bacteria from a bird with fungi and protozoa suggests that the bacterium is a primary pathogen.
- Obtaining mixed cultures or identifying individuals within a given flock with different bacterial isolates suggests secondary infections are occurring.
- Isolating small to moderate numbers of bacteria from the liver or kidney can be "normal," because birds have hepatic and renal portal circulations and lack lymph nodes that filter blood before it drains into the liver and kidney. Because lymph follicles are distributed throughout these organs, defense responses actually occur within the parenchyma and not externally, as in mammals. These organs should not be expected to be sterile, but should be expected to contain autochthonous flora. The number of organisms isolated at necropsy depends on the time of death and the method of handling the body (eg, storage, preservation).

Because the isolation of "unusual" bacteria can be expected from avian samples, the clinician can enhance results by providing the laboratory with a thorough anamnesis, exact species of the bird in question, and as far as possible, the names of particular bacteria that may be suspected in the case. This latter point is especially important if special media or environmental conditions are needed for bacterial isolation. In addition, with some organisms, special transport media and shipping methods (eg, on ice) may be necessary to preserve the organism.

Blood cultures are considered a definitive diagnostic tool in humans and some mammals. In these species, samples are, as a rule, taken during a period of fever. A febrile period is difficult to determine in a bird and is generally considered of minimal importance. In birds, organs as well as blood are not necessarily sterile, although the number of bacteria is extremely low. Generally, the isolation of small quantities of

autochthonous flora is considered normal, and only the isolation of primary pathogens is really helpful. Because whole blood has bacteriostatic and bactericidal properties, blood culture samples must be transferred immediately after collection to attenuant containing nutrients and one of the artificial heparinoids, for instance Na-polyanetholsulfate. Commercially available blood culture flasks are also useful.

## Gram-negative Bacteria of Clinical Significance

"Intestinal bacteria" are considered to be those species that can colonize the intestinal tract. As a group, intestinal bacteria can be part of the normal flora or pathogenic organisms that are not routinely found in the GI tract; in some cases, normal flora can become secondary pathogens. When a bacterium leaves the mucosal surface and penetrates the intestinal wall, it then can induce systemic disease, including septicemia and death. The Enterobacteriaceae are considered the most important avian intestinal pathogens, but other groups, such as *Aeromonas*, *Pseudomonas*, *Alcaligenes*, *Bordetella* spp. and related organisms, as well as *Vibrio* and *Campylobacter*, may also colonize the gastrointestinal tract.

### Enterobacteriaceae

The members of the Enterobacteriaceae family typically grow well on commonly used media. Enterobacteriaceae are divided into genera based on specific biochemical and serologic characteristics. Many species are further divided into biotypes and serotypes. In these species, complete identification requires differentiation between the O, K and (in motile species) H antigens. Serologic differentiation between the genera is often difficult since group-specific antigens (lipopolysaccharides) can cross-react.

Enterobacteriaceae are able to propagate in the environment if they are in the proper conditions. Enterobacteriaceae are ubiquitous and considered to be part of the autochthonous intestinal flora in many mammals, including humans and some species of birds (Table 33.2).

TABLE 33.2 Birds in which Enterobacteriaceae are not normal

▪ Psittaciformes (parrots and parakeets)	▪ Gruiformes (cranes)
▪ Fringillidae (finches)	▪ Otididae (bustards)
▪ Ploceidae (weaver finches)	▪ Sphenisciformes (penguins)
▪ Astrildae (waxbills)	▪ Ciconiiformes (storks, ibises)
▪ Accipitriformes (hawks, vultures)	▪ Tetraoninae (grouse)
▪ Falconiformes (falcons)	▪ Musophagiformes (turacos)
▪ Strigiformes (owls)	▪ Trochiliformes (hummingbirds)
	▪ Piciformes (woodpeckers, toucans)

Isolation of Enterobacteriaceae from the respiratory or reproductive tracts is abnormal. This group of bacteria can colonize most avian tissues, where it is frequently considered as a secondary pathogen. In some cases, Enterobacteriaceae can function as primary pathogens. Substantial differences exist in the virulence of the various Enterobacteriaceae and in the host response to infections. The genera *Shigella* and *Edwardsiella* are normally not cultured from birds (the latter rarely from pigeons). The genera *Enterobacter*, *Hafnia*, *Serratia* and *Proteus* are of a low pathogenicity. The isolation of *Enterobacter agglomerans* (a plant pathogen) in avian feces can indicate the consumption of seeds that contain more than  $10^6$  bacteria/g of food. This bacterium is common in decaying plant matter; foods containing the bacterium in high numbers should be considered toxic. *Serratia marcescens* is increasingly found in large parrots with chronic debilitating diseases. Predisposing factors seem to include previous antibiotic treatment and immunosuppression.

### ■ *Escherichia (E.)*

*E. coli* is the most commonly encountered member of this genus; in many avian species it is considered to be a more important pathogen than salmonella (see Table 33.6). This genus contains a number of species that may be motile or nonmotile, encapsulated or nonencapsulated. Classification of the strains of *E. coli* that infect birds has been difficult. The serologic and virulence factors used to classify the *E. coli* strains that infect humans and other mammals do not accurately predict which *E. coli* strains will be pathogenic in birds. Although each serovar of *E. coli* includes both virulent and avirulent strains, there seems to be a slightly higher frequency of virulent strains within the serovars 01, 02 and 078. In experimental transmission studies, all lysine decarboxylase-negative *E. coli* strains have been found to be virulent in birds. Unfortunately, many of the lysine decarboxylase-positive strains are also virulent.

### Pathogenesis

The pathogenesis of *E. coli* infections in birds is poorly defined. Mammalian strains produce large quantities of exotoxins that cause many of the clinical and pathologic changes associated with infection. Except for the presence of enterotoxins, avian *E. coli* strains appear to produce few exotoxins. These enterotoxins cause diarrhea by inducing hypersecretion of fluids into the intestinal lumen. Endotoxins may cause hypersensitivity angitis followed by septicemia and death.

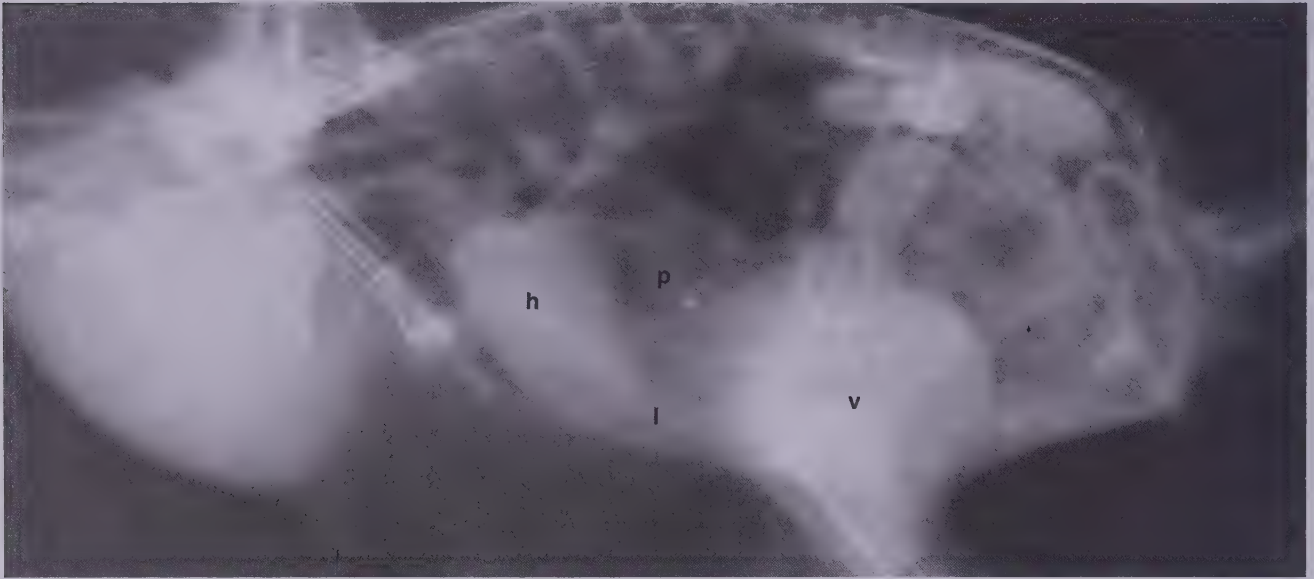
### Clinical Disease and Pathology

The clinical signs associated with primary or secondary infections are thought to be governed by the portal of entry to the avian host.

Colisepticemia is characterized by an acute onset of lethargy, anorexia, ruffled plumage, diarrhea and polyuria. *E. coli* septicemia usually involves the kidneys, although clinical signs of renal involvement may or may not be present. CNS involvement is rare. Ocular lesions occasionally occur and include exudation of fibrin into the anterior eye chamber or uveitis. Serofibrinous arthritis can occur as a sequela in some infected birds. Fibrinous polyserositis, the severity of which depends on the chronicity of the infection, may be noted at necropsy. Catarrhal enteritis is common but nonspecific. The most consistent histologic lesion is serofibrinous inflammation with plasma cell infiltration in the liver and kidneys (Figure 33.1).

Localized enteritis caused by *E. coli* is a result of enterotoxin production, which induces an increased secretion of fluids. The resulting diarrhea causes a substantial loss of electrolytes and proteins and induces dehydration and cachexia. Some strains of *E. coli* are capable of colonizing and destroying the intestinal epithelium. These strains typically induce a pseudomembranous or ulcerative enteritis. Clinically infected birds die peracutely or develop nonspecific signs associated with enteritis. Infections with these strains are usually diagnosed on postmortem examination.

Coligranulomatosis (Hjaerre's disease) is particularly common in Phasianiformes including chickens, turkeys, peafowl, partridges and capercaillie. Muroid (eg, encapsulated) *E. coli* strains, mainly of serovars 08, 09 and 016, are the usual etiologic agents. Coligranulomas are thought to occur when other agents damage the intestinal mucosa and allow a secondary infection with specific *E. coli* serovars. It is currently



**FIG 33.1** A seven-year-old male Amazon parrot was presented for weakness and diarrhea. Abnormal clinical pathology findings included PCV=22, WBC=33,000, SGOT=476. A Gram's stain of the excrement revealed 70% gram-negative rods. Radiographs indicated ileus (gaseous distension of the bowel), a full crop and microhepatia. Dried excrement is visible pericloacally. The dilated bowel loops are displacing the proventriculus (p) ventrally and the ventriculus (v), liver (l) and heart (h) cranially.

thought that galactans found in the *E. coli* capsule stimulate the granulomatous reaction.

Affected birds develop diarrhea, polyuria and chronic weight loss. Granulomatous dermatitis is occasionally noted. Grayish foci of varying sizes in the liver, intestinal subserosa and spleen or kidney are typical findings at necropsy. These granulomas are distinct from those induced by avian tuberculosis because they lack an opening into the intestinal lumen. The center of the foci may be mineralized. Histologic changes are characterized by multinucleated giant cells and a few heterophils around a central necrotic region. Acid-fast staining should be used to rule out mycobacteriosis.

*E. coli* can cause a primary rhinitis but is generally a sequela to infections elsewhere in the body. Air sac lesions can be severe and may extend to the peritoneum, causing a fibrinous polyserositis. Except for in geese, *E. coli* pneumonia is rare. This is due to the special anatomy of the avian lung. When pneumonia occurs, it is most common in young chicks that have inhaled a high number of virulent *E. coli* with contaminated dust. Affected birds are usually dyspneic and cyanotic. In contrast to mammals, pneumonia is not associated with prominent respiratory sounds.

Hens can develop *E. coli* infections characterized by fibrinous salpingitis or oophoritis originating from organisms that ascend from the cloaca or by imprint

metastases from infected air sacs. Infections are usually chronic in nature, with untreated birds eventually dying from salpingoperitonitis. Genital tract infections in males are less common, but when they do occur they usually result in orchitis and permanent sterility.

Secondary colonization of joints and bone marrow can occur following *E. coli* septicemia. These lesions are rare, but when they do occur they are most frequent in nestlings and fledglings. Some of the finch species seem to be particularly susceptible. Bone marrow infections appear to be very painful, and affected birds are usually reluctant to move.

### Diagnosis

Polyserositis and granuloma formation are lesions suggestive of *E. coli* infections. Specific diagnosis requires culturing the organism from infected tissues. Serotyping is of academic importance.

### Treatment

The ability of a selected drug to penetrate target tissues or granulomas must be considered (see Table 33.7). Oral antibiotics may be effective in treating *E. coli* infections limited to the intestinal mucosa, but parenteral antibiotics are necessary for treating most *E. coli* infections. In addition to antibiotics, therapeutic considerations should also include administration of avian lactobacilli in an effort to lower the intestinal

tract pH and help establish a proper autochthonous flora. Mammalian strains of lactobacillus can be effective in changing the intestinal pH but require the administration of large quantities of product over a three- to four-week period. Lactulose may also be helpful in lowering the intestinal pH. Providing a nutritional diet is important in improving gastrointestinal physiology in malnourished birds.

### ■ *Salmonella* (S.)

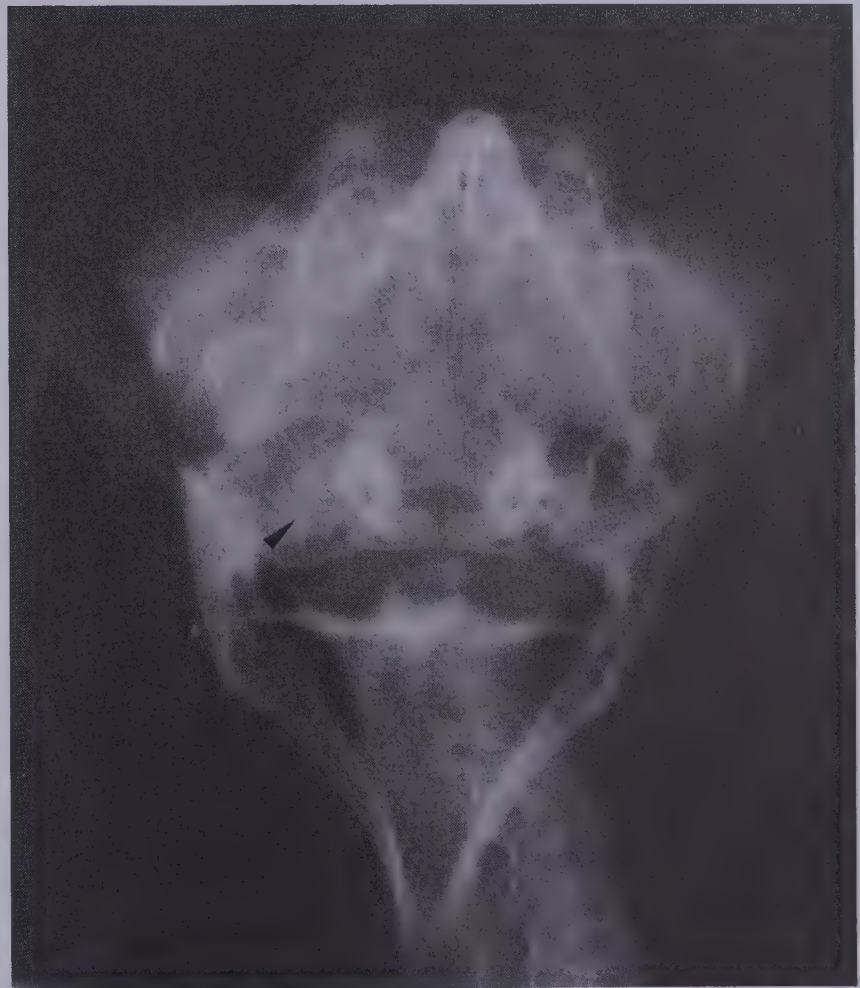
The genus *Salmonella* includes approximately 2000 species divided into five subgenera. Subgenus I is the most important in birds. Subgenus III (*S. arizonae*, *Arizona hinshawii*) has occasionally been reported in birds, particularly those that are in contact with reptiles. Most strains are motile and grow on common media. The subgenera are determined by specific biochemical profiles, and species are differentiated serologically (O, K [Vi] and H antigens). Lysotyping is used for further characterization at the research level. Propagation can occur outside the host if the correct ambient temperatures and proper nutrients are available.

Most vertebrates can be infected with some *Salmonella* spp. However, the host susceptibility and development of carrier states vary widely among species. Free-ranging birds can be subclinical carriers and serve as a reservoir for the aviary. In addition to free-ranging birds, rats, flies and other vermin may also serve as vectors of salmonella. Avian species without ceca or with involuted ceca appear to be more susceptible to salmonella infections than birds with fully functioning ceca. Bacteroides and *Spherophorus* spp. are considered autochthonous cecal flora, and these gram-negative anaerobes may function as natural antagonists for *Salmonella* spp. The incidence of various *S. spp.* seems to vary with geographic location and the types of food consumed, particularly the proteinaceous component. Imported birds (and other animals) may serve as reservoirs for nonindigenous *S.*

spp. that can cause devastating outbreaks. Some salmonella strains are host-adapted (eg, *S. gallinarum-pullorum* to chickens, *S. typhimurium var. copenhagen* [in two biovars] to either pigeons [malonate-negative] or European finches [malonate-positive]).

### Transmission

Salmonella enters the host principally through the oral route. Contaminated dust from feces or feathers may be involved in aerogenic spread in some cases. Egg transmission can occur with fully walled and L-form salmonella. It is most common with adapted strains but is possible with any *S. sp.* Experimental studies indicate that patent infections in embryos occur with fewer than ten bacteria. These infected



**FIG 33.2** An adult Barn Owl from a zoological collection had a three-year history of intermittent depression and anorexia. The bird was presented with severe right-sided head tilt and vertical-to-rotatory nystagmus. The external ear canal was hyperemic, and the tympanic membrane was opaque and edematous. Radiographs indicated a soft tissue density in the right tympanic bullae suggesting an internal ear infection. Auditory evoke potentials indicated lesions in the peripheral and central auditory pathways. *Klebsiella* sp. and *Pseudomonas* sp. were recovered from the infratrochlear area and brainstem at necropsy.

chicks then hatch and spread salmonella by direct contact throughout a nursery. If an embryo has more than ten bacteria, it usually dies before hatching.<sup>47</sup> In freshly hatched chicks, salmonella often serves as the first bacterium to colonize the intestines. This organism becomes host-adapted during the egg incubation period, and the hatched chick can then serve as a subclinical carrier. In some cases, the salmonella infection can eventually induce a septicemia and death. Subclinical carriers allow an infective cycle to occur in the absence of other vectors. Vertical infections may also occur if infected hens feed their young contaminated crop contents.

### Pathogenesis

One of the characteristics of the group Enterobacteriaceae is that they all produce endotoxins. Salmo-

nella is no exception, and some cases of food poisoning are linked to this bacterium. Indirect death through endotoxin contamination of food is rare in birds; most avian salmonella problems are associated with direct infections. Interestingly, both virulent and nonvirulent strains of a given *Salmonella* sp. can exist simultaneously in a host. Virulent strains are those that can penetrate an intact intestinal mucosa, and nonvirulent strains are those that require a mucosal lesion to enter a host. Nonvirulent strains often colonize the gut, resulting in asymptomatic infections and intermittent shedding. Once virulent or nonvirulent strains have passed the mucosal barriers, they induce a septicemia that results in an immune response or colonization in tissues and eventual death of the bird. In some cases, *Salmonella* sp. may cause chronic infections that are characterized by intermittent septicemia and clinical signs. Recurrent infections usually result in progressive organ involvement; the CNS and joints are frequently end-stage sites of infection.

### Incubation

Incubation periods vary with the type of salmonella infection. Presumably, these differences are dependent on the strain of infecting salmonella, the route of infection and the condition of the host. In acute diseases, incubation periods are typically three to five days. With egg transmission the incubation period is shorter, generally considered to be two days. Subclinical carriers can have prolonged incubation periods.

### Clinical Disease and Pathology

Acute diseases are characterized by nonspecific signs including lethargy, anorexia, polydipsia (sometimes followed by polyuria) and diarrhea. In subacute to chronic cases, CNS signs, arthritis (particularly in pigeons), dyspnea and indications of liver, spleen, kidney or heart damage are common. With high-dose infections, conjunctivitis, iridocyclitis and panophthalmia may occur.

Some individual avian species have unique clinical presentations. Outbreaks in lorries (Loriidae) and penguins (particularly Jackass Penguins) are associated with peracute diseases and high flock mortality. African Grey Parrots are also very susceptible, but typically develop a more chronic disease exhibiting phlegmon, granulomatous dermatitis, arthritis and tenovaginitis (Figure 33.3). Respiratory signs with myocardial lesions are common in tangares, quetzals, Red-headed Barbets, terns and House Sparrows. Nonspecific CNS signs are common in

TABLE 33.3 Percentage of Psittaciformes Shedding Gram-negative Bacteria and Yeast

	<i>E. coli</i>	Enterobacter	Klebsiella	Pseudomonas	Yeast
Bare-eyed Cockatoo	44	0	0	13	6
Citron-crested Cockatoo	30	0	0	0	0
Major Mitchell's Cockatoo	27	20	0	0	13
Moluccan Cockatoo	81	13	0	0	13
Sulphur-crested Cockatoo	44	0	0	0	11
Triton Cockatoo	84	8	3	0	0
Red-vented Cockatoo	78	0	0	0	0
Umbrella Cockatoo	56	24	4	0	15
Rose-breasted Cockatoo	16	2	0	0	0
African Grey Parrot	17	0	0	0	0
Eclectus Parrot	10	0	0	0	10
Blue-crowned Amazon Parrot	0	0	0	0	0
Blue-fronted Amazon Parrot	20	0	0	0	0
Yellow-headed Amazon Parrot	12	0	0	0	0
Yellow-naped Amazon Parrot	38	0	0	0	6
Blue and Gold Macaw	23	0	0	8	8
Buffon's Macaw	23	0	0	8	8
Green-winged Macaw	26	3	0	3	3
Military Macaw	20	4	0	0	16
Red-fronted Macaw	7	7	0	0	0
Scarlet Macaw	19	2	0	0	0
Hyacinth Macaw	6	0	0	0	11

Incidence (in percent) of the isolation of gram-negative bacteria and yeast from the cloaca of a group of psittacine birds with no observed clinical abnormalities. Gram-positive bacteria were isolated from 91% of the 506 cloacal samples. It is not unusual to find transient populations of gram-negative bacteria in the cloaca of asymptomatic birds. However, the presence of these bacteria in the gastrointestinal tract can cause problems if a bird is stressed. The isolation of gram-negative bacteria from clinically asymptomatic psittacine birds warrants a close examination of management practices. Adapted from Flammer K: Avian Dis 32: 79-83, 1988.

geese and ducks. Some infected ducks will swim with an inverted keel (keel disease) just prior to death. Subacute salmonellosis in many finches (*Fringillidae*) is characterized by granulomatous ingluvitis that may be confused with candida infections. Granulomatous dermatitis has been reported in several species and is thought to be induced by mosquitoes or other biting insects.

Subgenus III strains are considered less virulent than those of subgenus I; however, the clinical lesions induced by this subgenus are indistinguishable. Ocular lesions appear to be more frequent with subgenus III, and turkeys, ducks, parrots and canaries are particularly susceptible.

Postmortem lesions include dehydration, degeneration or necrosis of skeletal musculature, gastroenteritis (occasionally with ulcers and granulomas), enlargement of the liver and spleen (with or without disseminated small whitish foci), bile congestion and nephropathy. Chronic infections usually cause pericarditis or epicarditis fibrinosa, granuloma formation in the liver, spleen and kidney, and degeneration or inflammation of the ovary or testis. Fibrin filling the cecal lumen is a common finding.

Histopathologic changes are nonspecific with purulent inflammation in the parenchymal organs. Granulomas are common with chronic infections. Purulent leptomeningitis and exudate formation in the subarachnoid spaces are usually noted in birds with CNS signs.

### Diagnosis

A confirmed diagnosis requires isolation and identification of the *Salmonella* species. Serologic evaluation of a flock can be used only if the precise species is known; however, chronically infected subclinical birds are frequently serologically negative. The same is true for birds infected with L-forms. The development of a serologic response requires penetration of the intestinal mucosa, and most subclinical carriers have infections limited to the intestinal lumen.



**FIG 33.3** A three-month-old pigeon was presented with depression, anorexia, diarrhea and reluctance to move. An open ulcer was present on the bird's hock. *Salmonella* sp. was isolated from the bird's feces and the bird responded to treatment with antibiotics (courtesy of Louise Bauck).

### Treatment

Whether or not to treat salmonella infections in companion birds is controversial. The author believes that clinically affected birds and companion birds that are identified as carriers should be treated because of public health hazards. Therapy should include appropriate antibiotics (based on sensitivity) and lactobacillus products. In general, the frequently encountered salmonella strains are sensitive to commonly available antibiotics, but some strains from free-ranging birds (particularly from seagulls) demonstrate varying degrees of antimicrobial resistance. CNS signs and chronic infections tend to be refractory to therapy. Flock management of salmonella should concentrate on preventing egg transmission by identifying and removing subclinically infected breeders. Treating birds that have egg-derived infections is extremely difficult. Host-adapted strains of salmonella seem to cycle in periods of approximately three-month intervals. Cycles of egg transmission can best be broken by collecting eggs for future breeding stock four weeks after treating the parent stock. Newly hatched chicks from these birds should be cultured (fecal swabs) at hatching, and infected birds should be treated immediately.



**FIG 33.4** Aviary hygiene is important in preventing a bird's exposure to many infectious agents including bacteria. Walk-in type enclosures have several disadvantages when compared to drop-through type enclosures. The birds in walk-in enclosures can fly to the floor where pathogens can accumulate in excrement and food waste. Birds are more likely to come in contact with discharge from flies or rodents that have ready access to organic waste on the floor of the enclosure. Additionally, caretakers can act as mechanical vectors for the transmission of pathogens as they walk from one enclosure into the next.

Treatment of L-forms can be attempted with clindamycin (100 mg/kg body weight) or a combination of erythromycin and ampicillin (both components at the full dose).

### Control

Proper hygiene is the best tool for preventing salmonella outbreaks. The effective control of flies, rodents and other vermin is essential (Figure 33.4). Regular cleaning and disinfection of the aviary and nursery, along with proper storage of food, are all important in preventing salmonellosis. Several *Salmonella* spp. vaccines have been evaluated experimentally, but none have proven to be effective.

Companion bird strains of *Salmonella* are not considered important human pathogens in healthy individuals, but can cause problems in infants, geriatric patients or those with immunosuppressive diseases. Humans carrying salmonellosis can infect their companion birds. Such human-to-animal interactions have been shown to occur with African Grey Parrots, Amazon parrots, cockatoos and macaws.

### ■ *Citrobacter* (C.)

The three species of *Citrobacter* (*C. freundii*, *C. amalonaticus* and *C. diversus*) are less commonly encountered than other members of the Enterobacteriaceae. *C. freundii* appears to be the most pathogenic of the group. *C. diversus* is rare in birds. When using serologic assays it is important to know that *C.*

*freundii* antibodies often cross-react with those to *S. typhimurium*.

*Citrobacter* spp. cause serious secondary infections in weaver finches and waxbills. A rapid bacteremia followed by acute death occurs when the organism penetrates the intestinal mucosa. Ostriches, particularly chicks and young birds, also appear to be very susceptible to *Citrobacter* spp. Infected birds of any species may die without any clinical signs, or they can exhibit a brief period of depression and diarrhea prior to death. Postmortem changes indicate septicemia (petechiation of the heart, musculature and parenchyma). Surviving birds frequently become carriers. *C. amalonaticus* is frequently recovered from the intestinal tract of normal Psittaciformes. Intestinal infections would indicate that a disturbance has occurred in the autochthonous flora. A definitive diagnosis requires culturing the organism from affected tissues. The rule-out list is the same as for *Salmonella* spp. Therapeutic decisions should be based on appropriate culture and sensitivity. Neomycin delivered by gavage is often effective in clearing intestinal infections. In flock outbreaks, the same drug administered in the drinking water may be helpful in controlling infections.

There have been no reported cases of citrobacter infections in humans derived from exposure to infected birds.

### ■ *Klebsiella* (K.)

*K. pneumoniae* and *K. oxytoca* are frequently recovered from birds in which they can function as primary pathogens, particularly in weaver finches, or they can be involved as opportunists in immunosuppressed or stressed patients. These organisms are nonmotile Enterobacteriaceae, and most members of the genus are encapsulated. The mucoid capsule provides them with substantial protection from environmental extremes and many disinfectants. Heat and drying are the best methods of killing *Klebsiella* spp.

Specific information on the transmission, pathogenesis and incubation period for *Klebsiella* spp. in birds is not available. The *Klebsiella* capsule provides a barrier to protect the organism from cellular immunity. However, the capsule is also highly antigenic and stimulates a protective humoral immune response. *Klebsiella* spp. bacteremia usually results in the colonization of the kidney, causing renal failure. In chronic infections, the lungs may also be involved. In many bird groups (eg, pigeons, weaver finches,



goldfinches and siskins, geese, birds of prey, Amazons and African Grey Parrots), infections are not detected until late in the disease process when respiratory signs occur. Encephalomyelitis is occasionally noted in terminal cases. While systemic klebsiella infections are most common, local infections involving the sinuses, skin, oral cavity and crop may also occur, particularly in Psittaciformes. The diagnosis is made by isolation and identification of the organism. The rule-out list is the same as with salmonella.

### ■ *Yersinia* (Y.)

The genus *Yersinia* currently consists of eleven species.<sup>1</sup> Unlike other Enterobacteriaceae, which are strictly rod-shaped, *Yersinia* spp. form ovoid-to-coccoid rods that replicate in the environment at extremely low temperatures (+4°C) if provided the proper sources of organic nitrogen. Because the organism can grow effectively at low temperatures, infections are particularly common during the winter months.

*Y. pseudotuberculosis* appears to be the most important avian pathogen. *Y. intermedia*, *Y. frederiksenii* and *Y. kristensenii* are frequently isolated from various avian species, but their pathogenicity remains undetermined.

When grown at 20-28°C, *Y. pseudotuberculosis* is motile; when grown at higher temperatures it is nonmotile. Six serovars have been distinguished. Serovar 1 is most frequently isolated from birds. *Y. pseudotuberculosis* has been recovered in an L-form from free-ranging urban pigeons.

#### Transmission

*Y. pseudotuberculosis* is thought to be indigenous to northern and middle Europe. The occurrence of this bacterium in other parts of the world including Canada, the United States, Africa and Australia is thought to have arisen from the movement of European birds and rodents to other suitable geographic locations. An unknown percentage of the free-ranging birds in Europe are considered asymptomatic carriers.

*Y. pseudotuberculosis* infects a wide range of hosts, including many bird species and various mammals, particularly rodents and including humans. Toucans, toucanets, aracarís, barbets and turacos appear to be extremely susceptible.

#### Clinical Disease and Pathology

*Y. pseudotuberculosis* may be associated with peracute, acute or chronic clinical disease. Peracute death without clinical signs is common in infected Piciformes and Musophagidae. Clinical signs associated with acute disease include lethargy, dehydration, diarrhea and dyspnea. Emaciation, wasting and flaccid paresis or paralysis are common with subacute or chronic cases. Birds with a wasting syndrome appear similar to animals infected with tuberculosis. Infected ducks frequently develop tarsal joint swelling. Canaries may be severely dyspneic prior to death.

Gross changes associated with peracute infections include swelling of the liver and spleen and bloody-to-fibrinous exudate into the body cavity. Submiliary-to-miliary, sharply demarcated grayish foci within the liver, lungs, spleen and kidneys are common with the acute course. Chronic infections are characterized by granuloma formation in organs and the skeletal musculature. Ascites and osteomyelitis may or may not be present. Ulcers in the proventriculus, ventriculus and duodenum may occur in infected canaries. Tarsitis chronica deformans with caseous exudate in the joint cavity is frequently seen in ducks.

Coagulation necrosis and thrombophlebitis are the common histologic changes. In acute and chronic cases, inflammatory cells infiltrate the necrotic areas and eventually induce granulomas.

#### Diagnosis

The histopathologic changes, along with the identification of gram-negative coccoid rods, are suggestive of *Y. spp.* infections. Definitive diagnosis requires isolating the organism from affected tissues. Placing contaminated samples in a cool environment for two weeks may help in recovering *Y. spp.* Isolating avian strains of yersinia appears to be more difficult than isolating mammalian strains. Because there are no demonstrable biochemical or serologic differences, it has been assumed that avian strains are more difficult to grow due to different nutritional requirements. The most consistent isolation results have been obtained by placing fecal or organic material in heart-infusion broth with 5% glucose and storing this material in a refrigerator for two weeks. The material is then inoculated on blood agar plates with 0.2% Tween 80 and 50 ppm tellurite and incubated at 37°C for two days. *Yersinia* causes a reduction of the tellurite, turning the colonies black.<sup>25</sup>

### Treatment

Birds with the peracute to acute forms of yersiniosis usually die before therapy can be instigated. Parenteral drug administration is required if therapy has any chance of being successful. Treating chronic cases is difficult because granulomas prevent antibiotics from reaching the yersinia organisms nestled in the center of necrotic debris. Flock outbreaks can be prevented by treating clinically unaffected animals and applying strict sanitary measures.

### Control

In non-European countries where *Y. pseudotuberculosis* is not endemic, repeated culture of feces during the quarantine period should be used to prevent infected birds from entering the country. In endemic areas, rodents and free-ranging birds can serve as reservoirs, and flock control depends on preventing these animals from contaminating feed supplies and keeping them out of the aviary. Several experimental vaccines for *Y. pseudotuberculosis* have proven to be ineffective. Feeding infected mice to toucans could serve as a source of infection.

*Y. enterocolitica* is principally a human pathogen. Gulls, herons, birds of prey, crows, blackbirds and European robins that inhabit areas contaminated with human sewage are frequently infected. Young children of elementary school age are particularly susceptible to infections.

### *Pseudomonas (Ps.) and Aeromonas (Ae.)*

These two gram-negative rods are taxonomically unrelated but nevertheless have characteristics that make it best from a clinical perspective to discuss them together. Both of these genera contain numerous species, but only *Ps. aeruginosa* and *Ae. hydrophila* are common avian pathogens. Both bacteria are frequently found in aquatic environments and can propagate in cool water (20°C or lower). Both bacteria will grow on common media and induce β-hemolysis on blood plates. These hemolysins are potent toxins and are capable of damaging many cells in addition to erythrocytes. *Ps. aeruginosa* produces a blue-green diffusible pigment and has a sweetish odor. *Ae. hydrophila* causes the typical bad smell of the proteinolytic organisms and may be confused with *E. coli* on Endo- or MacConkey plates. These bacterial genera are further divided into several serovars and biovars. There have been insufficient studies to divide the avian species in a similar fashion.

Both of these bacteria infect many mammals, including humans, as well as most of the birds that have been tested. Free-ranging waterfowl appear to be particularly susceptible, but any free-ranging avian species that contacts contaminated food or water is probably susceptible. Of the commonly maintained zoo birds, penguins are very susceptible.

### Pathogenesis

Some strains of *Pseudomonas* and *Aeromonas* produce a number of extracellular toxins, including hemolysins, elastase, protease and lecithinase, that cause cellular damage resulting in edema, hemorrhage and tissue necrosis. Avian strains of *Ae. hydrophila* that are acetoin-producing (Voges-Proskauer-positive) are considered to be highly toxic.<sup>6</sup> Both species are principally secondary invaders. However, the toxins secreted by these organisms can be life-threatening once colonization of the host occurs. *Ps. aeruginosa* is resistant to many commonly used antibiotics and can cause secondary superinfections in patients being treated for other bacterial infections.

### Clinical Disease and Pathology

Virulent strains of these bacteria can cause a septicemia that induces diarrhea, dehydration and dyspnea followed by acute death. Infected skin lesions are edematous or necrotizing. Localized infections may occur in the upper respiratory tract, causing rhinitis, sinusitis and laryngitis. Hemorrhages and coalescent necrosis in the liver, spleen and kidney are the most common postmortem findings (see Figure 33.2). Catarrhal to hemorrhagic enteritis with edema and fibrinous inflammation of the serosal membranes may also be noted. Histologic changes associated with infections include severe inflammatory reactions involving the venous and arterial walls. Bacteria are often identifiable within the lumina. The formation of thrombi, hemorrhage and necrosis of the infected vessels are the results.

### Diagnosis and Control

The causative agent should be isolated and identified. Aviary outbreaks of pseudomonas are most common when organic material contaminates the water supply, allowing a proliferation of the organisms in the drinking water (Table 33.3). Routine cleaning of food and water containers, along with any external water pipes, is an important control measure. Incubator contamination can be prevented by periodically cleaning the water reservoir. Waterfowl are particularly susceptible to infections when water temperatures are above 20°C, allowing rapid proliferation of

*Ae. hydrophila*. Removing waterfowl from ponds during these periods is a good control measure.

### Alcaligenes (Ac.) and Bordetella (Bo.)

The genera *Alcaligenes* and *Bordetella* are taxonomically related. Both genera are widely spread in the environment. *Alcaligenes* is found mainly in aquatic environments. *Ac. faecalis*, *Bo. avium* and *Bo. bronchiseptica* infect a wide variety of birds in many orders. Psittaciformes and turkeys as well as many finches seem to be particularly susceptible to these bacteria.

There are no details on the pathogenicity of these genera in birds. *Alcaligenes* and *bordetella* are opportunistic pathogens that potentiate viral and other bacterial infections. *Bordetella avium*, a more recently recognized member of the genus, seems to preferentially bind to the ciliated epithelial cells of the upper respiratory tract.

In turkeys, combined infections of *Bo. avium* and the turkey rhinotracheitis virus cause the clinical and pathologic signs of rhinotracheitis. In other avian species, clinical signs are uncommon and, if present at all, are nonspecific. At necropsy, tracheitis, bronchopneumonia and air sacculitis are common findings with subacute to chronic courses of *bordetella*, whereas *alcaligenes* infections are characterized by coalescent liver necrosis in addition to respiratory disease.

#### Diagnosis

A confirmatory diagnosis requires isolation and identification of the causative agent. Serologic flock diagnosis by means of the slide agglutination test or antibody titration by the Gruber-Widal method is possible although no commercial antigens are available.

### Campylobacter (C.)

*Campylobacter* spp. from birds have been classified as: *C. jejuni*, the most frequent, and probably also the most pathogenic; *C. coli*, which is considered to be apathogenic, but is frequently confused with *C. jejuni*; and *C. laridis*, which is isolated from gulls, whose pathogenicity is still not definitely known.<sup>36</sup>

*C. jejuni* has incorrectly been labeled as *Vibrio* (usually *V. metschnikovii*). This error has serious consequences because *Vibrio cholerae*, serotype 01 and

noncholera *Vibrio* can be recovered from healthy birds.

*C. jejuni* may appear in different forms including a short comma, s-shaped, long spiral or coccoid form. The latter is usually an indication of degeneration. Colony formation takes 72 to 96 hours at 37-42°C in a microaerobic environment. Blood agar or selective media are best for isolation. *C. jejuni* is relatively unstable in the environment (surviving less than one week).

There are at least 50 serovars of *C. jejuni*.<sup>42</sup> While the possibility of birds serving as a source of infection for mammals and vice versa has been discussed, this transmission potential has been insufficiently studied.

The host spectrum is large, and includes chickens, turkeys, pheasants, crows, gulls, ducks, geese, pigeons, shorebirds, Pekin Nightingale, Nandu and the Great Bustard. *C. jejuni* has recently been reported in passerine birds, particularly in tropical finches (Estrildidae) and, to a lesser degree, in canaries.<sup>20</sup> Details of occurrence and pathogenicity in many avian species have been reported.<sup>51</sup> Psittaciformes are susceptible, but few documented infections have been reported.

#### Pathogenesis

*C. jejuni* can be isolated from the intestinal tract of clinically affected and asymptomatic birds. Experimental infections generally cause hepatitis. Factors that determine if an infected bird becomes clinically affected have not been established. Clinical disease is common in birds with parasitic infections (coccidia and nematodes), and these agents have been suggested as predisposing factors.

#### Clinical Disease and Pathology

Clinical signs are generally associated with subacute to chronic hepatitis and include lethargy, anorexia, diarrhea (frequently with yellowish stained feces) and emaciation. Transmission takes several weeks through the flock, but spontaneous recovery and relapses do occur. High mortality has been noted in finches, especially among fledglings.<sup>20</sup> Sudden death as a result of liver rupture is possible. Heterophilia and thrombocytophilia are the most consistent changes in the CBC.

At necropsy the liver is enlarged, pale or greenish in color and is congested, with or without hemorrhage. Perivascular infiltrates make the lobules appear more prominent. Coalescing necrotic hepatitis is a

common histologic finding. Catarrhal enteritis (also hemorrhagic enteritis in pheasants, turkeys, Tengmalm's Owl and coot) has been described. In gulls, erosion of the ventriculus has been reported.

### Diagnosis

Diagnosis requires isolation of *C. jejuni* from affected tissues. Phase-contrast microscopy of bile to demonstrate suggestive organisms may provide a tentative diagnosis. Fecal samples can be used for culture in live birds. A transport medium is necessary to ensure survival of the organism.

### Treatment and Control

There are discrepancies between the antibiograms and clinical recovery. Erythromycin or tetracyclines, dehydro- or streptomycin (never in Psittaciformes) or furane derivatives (not in waterfowl) can be tried. Diseases frequently recur despite therapy. Thorough cleaning and disinfecting of the aviary may help prevent reinfection. Dogs can be a reservoir for human infections, but it is not known if they can transmit the organisms to birds. Dogs should not be allowed direct access to birds.

## ■ *Vibrio* (V.)

The genus *Vibrio* comprises numerous species that are not easy to differentiate. *V. cholerae* is of utmost importance as a zoonotic organism. In birds, especially in gulls, *V. cholerae* (serovar 01) is demonstrable in the intestinal tract, although no clinical or pathologic signs have been described. Numerous other *V. spp.* are collectively designated NAG (= non-agglutinable), because they do not agglutinate with human cholera antiserum. NAG strains can be isolated from the feces of many bird species, particularly waterfowl (vibrio is generally found in aquatic habitats).<sup>4</sup> NAG vibrios have not been documented as a cause of clinical disease in any avian species. Because some NAG strains can cause a mild intestinal disease in humans, an analysis of avian strains in the vicinity of human cases might be advisable.

## ■ Spirochaetaceae

*Borrelia* (*Bor.*) *anserina* (syn. *Spirochaeta gallinarum*) is a gram-negative, helical motile organism that stains with Giemsa. A granular form of the organism may occur in ticks and the blood of the birds that have recovered from a disease. The host spectrum includes geese and ducks, turkeys, chickens, pheasants, grouse, partridges, pigeons, crows, magpies, House Sparrows, starlings and African Grey Parrots.

### Transmission

The main vectors for transmission are ticks, in which the organism can be passed transovarially and survive for over a year. Mosquitoes and other biting insects play a minor role in transmission. Transmission from bird to bird by excreta is of minor importance epizootiologically.

### Pathogenesis

Young chicks (one to three weeks of age) are particularly susceptible. Adults may also be infected. *Bor.* is in the peripheral blood from the fourth to the ninth day post-infection and remains in the blood approximately seven days. The organism can then be found in parenchymal organs for another 30 days. Death may occur from embolism due to agglutinating borrelias. A strain-specific immunity develops in survivors. Incubation periods are four to eight days depending on the species of ticks.

### Clinical Disease and Pathology

Acute cases are characterized by a high fever (bacteria generally cause a low body temperature), anorexia, depression (droopy, cyanotic heads), yellowish diarrhea, lethargy, ataxia and paralysis. Morbidity is high, and mortality may range from 10 to 100% depending upon the susceptibility of the host. Spontaneous recovery may occur around the sixth day post-infection. Chronic disease is characterized by anemia, paralysis and dyspnea.

The albumin fraction in the serum decreases to 37% and an increase of the aspartate aminotransferase is accompanied by a decrease of the alkaline phosphatase, the total lipids and the cholesterol.

At necropsy, a mottled, severely enlarged liver is characteristic except in pheasants. In these birds the spleen may be small or normal in size.<sup>58</sup> The liver shows hemorrhages and necrotic foci. Mucoid hemorrhagic enteritis, serofibrinous pericarditis and swollen kidneys may also be seen. Histology displays multiple necrotic foci without inflammatory reactions. *Bor.* can be demonstrated by argentation.

### Diagnosis

Blood smears stained with Giemsa or examined by darkfield microscopy are useful for diagnosis. Culturing *Bor. sp.* is very difficult. Antibodies (agglutination, fluorescence techniques, immunodiffusion) can be demonstrated from the 4th to the 30th day post-infection.

- ***Treponema (T.) spp.***: *Treponema* spp. are helical motile organisms that are much smaller than *Spirochaeta* spp. An unclassified *Treponema* sp. (0.5 µm wide with 13 to 15 flagella)<sup>12</sup> is the cause of a watery, intermittent typhlitis in chickens. The organism is antigenically related to but distinct from *T. hyodysenteriae*. Chickens are the only defined host and lose weight in response to a malabsorption syndrome.<sup>12,22</sup> Histopathology shows an increased number of goblet cells in the cecal mucosa, focal epithelial desquamation and many *Treponema* organisms in the small fissures of the epithelium. The incubation period is one to seven weeks dependent on the infective dose. Culture is possible on spectinomycin blood agar in an anaerobic atmosphere. Fluorescent antibodies designed for *T. hyodysenteriae* can be used to demonstrate the organisms in affected tissue.
- ***Spirochaetaceae Undifferentiated***: A non-classified spirochete from choanal and tracheal mucus of a cockatiel has been described. The organisms were 0.3 to 0.4 X 10 to 15 µm in size and occurred in large numbers on the mucosa. Two other cockatiels have been found to harbor similar organisms in the respiratory passage. Histopathology showed a mild inflammatory reaction in the nasal sinus, but not in the trachea. In the lower parts of the respiratory tract, the organisms could not be demonstrated using argentation. The significance of these findings is unknown. Interference with the ciliary activity of the respiratory mucosa is conceivable.<sup>65</sup>

Spirochetes were demonstrated in a pharyngeal swab of a cockatiel that was depressed and sneezing. The bird had spent ten minutes with another cockatiel that was showing similar clinical signs ten days before being presented for evaluation.

### ■ *Pasteurella (P.)*

The family of Pasteurellaceae currently includes the genera *Pasteurella*, *Actinobacillus* and *Haemophilus*.<sup>49</sup> All three genera can be pathogens in birds.

*Pasteurella* characteristically exhibit bipolar staining in tissue smears or from first culture passages when fixed in methanol and stained with methylene blue. There are presently eleven species within this genus, but others will undoubtedly be added. *P. multocida*, which causes fowl cholera, and *P. gallinarum* are two of the most commonly encountered species. The latter is usually considered a secondary pathogen. Some of the *Pasteurella* organisms isolated from waterfowl, pigeons and Psittaciformes have not been

taxonomically classified. Some isolates designated *P. haemolytica* (gram-negative, polymorphic rods) are improperly classified and do not belong in this genus. The characteristics of these strains resemble those of the genus *Actinobacillus*. Reports on isolation of *P. pneumotropica* from birds are questionable. This species appears to be host-specific and is found in rats or other rodents. Similarly, *P. ureae* is believed to be host-specific for humans.

*Pasteurella* has been associated with disease in Phasianiformes, Anatiformes, Psittaciformes, Columbiformes and Passeriformes. There is variance in species susceptibility. The clinical presentations and pathomorphologic changes are similar to those described for yersiniosis. Propagation outside the host can occur but requires very specific conditions of temperature, relative humidity and pH. Such conditions may occur in large bodies of water, and in these situations *Pasteurella* spp. can survive for long periods. Epornitics are most common in the northern hemisphere from November to December. Outbreaks in tropical climates peak with seasonal highs in ambient temperature and humidity.

- ***P. multocida***: The etiologic agent of fowl cholera, the species is divided into strains based on 16 serologically distinct endotoxins and 4 capsular polysaccharides. Serotypes 1 and 3 and capsule types A and D are most commonly isolated from birds. Three subspecies, *P. multocida (m.) multocida*, *P. m. gallinarum* and *P. m. septica*, have been distinguished based on differences in virulence. The latter is considered to be the most virulent.
- ***P. pneumotropica*** is indigenous in rodents and occasionally causes disease in aviary birds and pigeons. Infected birds develop pneumonia and may exhibit dyspnea shortly before death. Detailed information on the pathogenesis and clinical progression of *P. pneumotropica* in companion birds has not been reported.
- ***P. gallinarum*** appears to have a similar host spectrum as *P. multocida*; however, *P. gallinarum* is thought to be much less pathogenic. If the organism is able to colonize the respiratory mucosa, it can induce conjunctivitis and respiratory signs including coryza, rales and dyspnea. *P. gallinarum* has been isolated from the choanae and nostrils of Psittaciformes with concomitant *Aspergillus* spp. infections in the lungs and air sacs. Aspergillosis is one of the triggering factors that allows this secondary pathogen to overcome host defenses. Postmortem findings associated with *P. gallinarum* include catarrhal to



**FIG 33.5** The hallmark sign of bacterial septicemia is depression. Birds that are bitten or scratched by cats frequently develop *P. multocida* bacteremia. Affected birds may appear normal immediately after the injury occurs, and become rapidly depressed and die 12 to 24 hours later. Any carnivore-related injury in a bird is a critical emergency.

fibrinous inflammation of the upper respiratory tract, pneumonia and air sacculitis.

#### Transmission

*Pasteurella* infections in birds principally occur in the respiratory tract. Asymptomatic carriers harbor the bacteria in the nasal cavities, sinuses and choanae. Transmission can occur through direct contact with contaminated aerosols or through mechanical vectors such as blood-sucking mites. Infected rodents and free-ranging birds are considered important reservoirs. *Pasteurella* is shed almost exclusively from the upper respiratory tract. Shedding in the feces is rare, and egg transmission has not been documented. *P. multocida* is a common inhabitant of the oral cavity of some carnivores, particularly cats, and septicemic infections can occur through bite wounds. Cats should always be considered to be carriers of *P. multocida*, and any bird that has been mouthed by a cat should be treated with antibiotics immediately (Figure 33.5).<sup>40</sup>

#### Pathogenesis

Virulent strains of *P. multocida* cause an acute septicemia and death. Less virulent strains result in bacteremia and colonization of the lungs, liver, kidneys, spleen and heart. Weakly virulent strains generally cause a chronic respiratory disease. The endotoxins

produced by *Pasteurella* damage blood vessels, causing edema, hemorrhage and coagulation necrosis, particularly in the liver. Diseases by less virulent strains usually occur in stressed or immunocompromised hosts.

#### Clinical Disease and Pathology

Acute forms are characterized by cyanosis, dyspnea and diarrhea followed by death. Excess mucus may be present around the nostrils or beak. Birds that survive acute disease often develop respiratory rales, sinusitis, conjunctivitis or swelling of the sinus infraorbitalis. Arthritis and CNS signs have been reported in some chronic cases. Granulomatous dermatitis has been noted in raptors, owls and pigeons.

Postmortem findings with acute disease may be absent or limited to petechiae or ecchymoses of the parenchymal organs. Prolonged cases are characterized by exudative serositis (mainly white, in contrast to yellow with *E. coli*) and the formation of necrotic foci in infected organs. Catarrhal to fibrinous rhinitis, necrotic pneumonia, sinusitis, blepharconjunctivitis and tracheitis are common with chronic courses. Following bacteremia, *Pasteurella* may colonize numerous tissues, resulting in arthritis, osteomyelitis, otitis media and granulomatous dermatitis. Granulomas may also be noted in the liver and spleen. Some strains will colonize the air cells of the cranial bones causing fibrinous exudate. In waterfowl, a diphtheroid enteritis may be observed. Histologic changes are nonspecific.

#### Diagnosis

The isolation of the causative agent is necessary. The occurrence of *Pasteurella* spp. in a flock can be determined through serology using immunodiffusion or indirect hemagglutination tests. Unfortunately, commercial antigens for these tests are not available. Serotyping and differentiation of the subspecies require specialized testing.

#### Treatment

Septicemic birds rarely survive, even when treated intensively. Parenteral administration of broad-spectrum, long-acting sulfonamides can be tried. The combined use of antibiotics and hyperimmune serum has proven to be beneficial. Treating birds with chronic forms is very difficult because of the irreversible damage that occurs to parenchymal organs.

#### Control

Preventing rodents and free-ranging birds from entering the aviary is important in preventing infec-

tions. Vaccines for *P. multocida* are commercially available, but their effectiveness is poor. Failures associated with the vaccine occur because of the numerous different serotypes and the fact that endotoxins are more immunogenic than the bacterial capsule. The production of vaccines from strains that persist in an aviary may provide successful long-term control.

### ■ *Actinobacillus (At.)*

The genus *Actinobacillus* consists of a group of organisms provisionally differentiated into more than 20 biovars, some of which have a rather high host specificity. The taxonomic reclassification of the Pasteurellaceae is intertwined with the genus *Actinobacillus*. Because of these classification revisions, even the actinobacilli that are pathogenic in birds have not been named. The situation has been complicated in recent years because many new strains have been isolated from Psittaciformes, Columbiformes, Anatiformes and Fringillidae. One biovar has been referenced in the literature as *P. haemolytica* syn. *At. salpingitidis*. However, this classification is not valid. The knowledge of the biology and pathogenicity of the members of the genus is limited.

Actinobacilli are polymorphic rods that may exhibit bipolar staining similar to Pasteurellae. Most strains grow only on blood agar plates or media containing serum. Some strains, particularly of *At. salpingitidis*, hemolyze avian and bovine erythrocytes or produce exotoxins that are capable of causing arteritis. Some strains are considered to be primary pathogens, but the majority of this genus is comprised of opportunistic organisms. There are no simple laboratory tests for differentiation between primary and secondary invaders.

There is little information on routes of transmission. It has been proven that egg transmission of some strains occurs in chickens and geese. Incubation periods in the avian host are not known.

### Clinical Disease and Pathology

Many infected birds die acutely. Birds with a more chronic course typically develop joint lesions. Species-specific strains that infect geese morphologically resemble *P. influenzae*. This organism has been referenced as a cause of chronic disease in the gosling,<sup>26</sup> characterized by emaciation, failure to thrive, poor feed conversion and arthritis. Egg transmission may cause reduced hatchability. Asymptomatic infections are thought to occur in adult breeders, with clinical

signs developing in goslings each season. At necropsy, liver necrosis, salpingitis, peritonitis, endocarditis valvularis and fibrinous arthritis are typical lesions. In young geese, polyserositis and arthritis are prominent.

### Diagnosis and Treatment

Isolation and identification of the causative agent is necessary for diagnosis.

*E. coli* and other bacteria, particularly anatipestifer infections in waterfowl, have to be considered as causative agents for the salpingitis, peritonitis and polyserositis.

Tetracyclines and chloramphenicol are indicated for initial therapy. Sensitivities for many strains are difficult to interpret because of oversized inhibition zones. In young geese, antibiotics must be given during the first week of life or lesions become too extensive to be reversed.

### ■ *Haemophilus (H.)*

The haemophilus strains that infect companion birds have not been properly classified. Chickens are considered to be the only definitive host of *H. paragallinarum*, which is the agent of coryza contagiosa gallinarum. Experimentally, Columbiformes and Anatiformes are resistant to infection. Several *Haemophilus* spp., including *H. avium* and *H. paravium*, can be isolated from birds with coryza; however, their involvement in the disease process is questionable. They probably serve as secondary invaders that sustain upper and sometimes lower respiratory tract disease.<sup>11,35</sup>

### Pathogenesis

Details on the pathogenesis of *Haemophilus* spp. strains that infect Psittaciformes and Columbiformes are scarce. *H. paragallinarum* is known to produce a number of cellular toxins, including neuraminidase, nitratase and catalase. Birds do not appear to develop an immune response following infection, and relapses are common.

### Clinical Disease and Pathology

*Haemophilus* infections generally cause a rhinitis that results in a serous-to-mucoid or even fibrinous exudate. Conjunctivitis and sinusitis may also occur. The most common postmortem finding is catarrhal-to-fibrinous rhinitis. Bronchopneumonia and air sacculitis are frequently described but are usually the result of concomitant infections (virus, other bacte-

ria, *Candida* spp.). For those lesions supposedly caused by *Haemophilus* spp. apart from *H. paragallinarum* see Table 33.4.<sup>32,35</sup> Histopathology reveals uncharacteristic lesions.

**TABLE 33.4 Clinical Disease Caused by *Haemophilus* in Avian Species**

Blue Crane	Pneumonia (together with staphylococci) and necrosis of liver tissue
Pigeon	Rhinitis
African Grey Parrot	Pneumonia, air sacculitis
Plum-headed Parakeet	Sinusitis, swelling of the liver together with <i>E. coli</i> or related organisms
Eastern Rosella	Sinusitis, swelling of the liver together with <i>E. coli</i> or related organisms
Budgerigar	Rhinitis (possibly together with <i>Pasteurella</i> or <i>E. coli</i> )
Muscovy Duck	Rhinitis, sinusitis
Andean Goose	Rhinitis, hemorrhage, jejunitis
Turkey	Sinusitis, air sacculitis
Golden Pheasant	Sinusitis, diphtheroid surface lining of the beak cavity
Siamese Fireback	Necrosis of the lung tissue.

## Other Gram-negative Rods

### New Duck Disease (Duck Septicemia)

The etiologic agent of duck septicemia has been suspected to be *Pfeifferella*, *Pasteurella* or *Moraxella anatipestifer*. The causative organism has recently been placed in the genus *Cytophaga*, which is a semi-aerobic, nonmotile rod.<sup>49</sup> The genus contains at least 19 serovars; serovars 1-3 are most common in Europe; serovars 1, 2 and 5 are most common in the United States; serovar 3 is frequently isolated in Australia. This organism is known to infect ducks and geese, free-ranging waterfowl, turkeys, pheasants and Psittaciformes. There is no information on its virulence or ability to survive in the environment.

Experimental disease does not occur following oral administration, and the respiratory tract is thought to be the primary portal of entrance to the host. Egg transmission resulting in high morbidity and mortality of ducklings is a substantial factor for the flock.

The pathogenicity of cytophaga is undetermined. Undoubtedly, there are strain differences in virulence,

and the condition of the host must also play a role. The incubation period in ducks ranges from three to ten days.

### Clinical Disease and Pathology

Infected ducklings (two weeks of age) usually die peracutely. Mortality rates in this age group can reach 75% of exposed young. Acute disease develops in older birds and is characterized by sinusitis, conjunctivitis, coughing and diarrhea, followed in two days by tremors, ataxia and convulsions. Survivors are stunted and fail to grow. Fibrinopurulent polyserositis is the characteristic postmortem finding. Other changes include lung congestion, hepatomegaly, splenomegaly, pericarditis and perihepatitis. Cytophaga-induced spondylitis with compression of the spinal cord was reported in turkeys.<sup>10</sup> Diffuse fibrinous meningitis with lymphocytic infiltration around the meningeal blood vessels was a characteristic histologic lesion. There was exudate formation within the ventricles as well as proliferation of microglia in the subpial and periventricular system.

### Diagnosis

The occurrence of polyserositis is highly suggestive of an infection. Isolation and identification of the causative agent is necessary in all other cases. An ELISA can be used to survey a flock for serologic response.

### Tularemia

Tularemia is caused by *Francisella tularensis*, a motile, short rod, 0.2 X 0.3-0.7  $\mu\text{m}$  in size. Isolates are reported occasionally, mainly from birds that inhabit the northern and subarctic regions of the northern hemisphere, such as the Common Pheasant, Waxwing, Ural Owl, Rough-legged Hawk and Common Raven. Rodents are considered to be the primary reservoir. Nothing is known about the clinical signs. The pathology resembles that of *Pasteurella* or *Yersinia* infections. *Francisella* previously has been classified with these two genera. The organism is considered to be a zoonotic agent.

### *Acinetobacter calcoaceticus* (An.)

This organism forms either cocci (fresh culture) or rods. It grows on commonly used media, even on some selective media for Enterobacteriaceae. The host spectrum is wide, and many avian orders can harbor the organism in the respiratory or intestinal tracts. Egg transmission is possible in many avian species. No reports conclusively describe consistently



occurring lesions in any avian species. Therefore, it is assumed that the organism has a low pathogenicity, and infections indicate a compromised host.

## Gram-positive Bacteria of Clinical Significance

### *Staphylococcus (S.)*

*Staphylococcus* infections can induce sporadic or enzootic disease in many avian species. Clinical manifestations may include acute septicemia or subacute-to-chronic arthritis, osteomyelitis and osteitis. Less common clinical problems include vesicular dermatitis or omphalitis. Staphylococci, particularly *S. aureus*, can function as primary pathogens or may complicate other infections as secondary invaders.

Isolation of the staphylococci is relatively simple using common media and growth conditions. Taxonomy literature<sup>60</sup> currently lists 21 *Staphylococcus* spp., 14 of which can be found in birds and are given here in order of decreasing frequency. *S. xylois* is considered almost apathogenic. *S. sciuri* and *S. lentus* (the latter a former biovar of *S. sciuri*) have some pathogenicity markers. *S. aureus* includes more virulent strains than any other species. These four *Staphylococcus* species are further divided into several biovars. Because some of these biovars are recovered only in a limited number of closely related bird species, they may represent bacterial organisms that have adapted to specific hosts. Other less commonly isolated species include *S. intermedius*, *S. hyicus*, *S. cohnii*, *S. saprophyticus*, *S. haemolyticus*, *S. warneri*, *S. hominis*, *S. epidermidis*, *S. gallinarum* and *S. capitis*. *S. epidermidis* was frequently cited in earlier literature but, using current diagnostic tools, is today rarely found in birds. The isolation of these less common species frequently depends on the internal or external environment of the patient, and limited information is available concerning their pathogenicity.


Staphylococci have several pathogenicity markers including production of the clumping factor, hemolysins, DNase, phosphatase, protein A and leukocidine. The presence of the clumping factor seems to correlate closely with pathogenicity in avian patients. Other pathogenicity markers have not been

studied sufficiently to determine their importance in birds. Staphylococcus protein A, which is found in the bacterial cell wall, is capable of binding to the Fc-fragment of immunoglobulin, thereby inhibiting phagocytosis of the organism. The correlation between protein A production and the virulence of avian *Staphylococcus* strains is poorly documented.

Members of the genus *Staphylococcus* (apart from *S. aureus*) are commonly recovered from many avian species and are considered part of the autochthonous flora. When present in diseased tissue, they are generally considered to be secondary invaders. Because *S. aureus* includes the most virulent strains, the following discussion applies mainly to this species.

### *S. aureus*

Avian strains of virulent *S. aureus* are relatively species-specific and rarely induce disease in mammals. The organism is found in abundant quantities in air and dust. Isolation of the organism can frequently be accomplished from the skin and the mucosa of the respiratory or digestive tract of clinically normal birds (Figure 33.6). *S. aureus*, like other *Staphylococcus* species, is relatively stable in the environment and can remain infectious for long peri-



**FIG 33.6** A five-year-old Amazon parrot was presented with an acute onset of picking at the feet and legs, which caused hyperemia and scab formation. This syndrome, called Amazon foot necrosis, has been reported in *Amazona* spp., and *Staphylococcus* spp. are frequently isolated from the lesions. However, staphylococci are part of the autochthonous flora and are probably not the primary cause of this problem. This affected Amazon parrot belonged to a client who smoked, and when the owner started washing her hands after smoking (presumably to remove nicotine sulfate, a potent toxin), the foot and leg lesions resolved. The client eventually stopped smoking and the bird had no further episodes of Amazon foot necrosis.

ods of time outside the host. Given proper conditions, the organism can propagate in an external environment. Like many bacteria, *Staphylococcus* can also develop resistance to disinfectants following continuous exposure, and frequent changing of disinfectants is required to prevent the development of resistant strains.

Techniques for differentiating between avian and mammalian strains of *S. aureus* remain unsatisfactory. Evaluating the type of lesions caused by experimental subcutaneous infection of *S. aureus* in birds may prove valuable in differentiating between avian and mammalian strains.

### Pathogenesis

The importance of *Staphylococcus* infections in birds is clinically underestimated. Individual strains may cause clinical problems in one bird while being considered normal autochthonous flora in another. Lipoteichoic acid, a major component of the staphylococcal wall, is instrumental in the specific capacity of this organism to bind to host cell receptors, particularly in the respiratory system. Such binding is a precondition for colonization and subsequent infection. However, avirulent strains can also bind to the same receptors and may compete for receptor sites, preventing colonization of virulent strains. This process is called "bacterial interference." Suitable strains of *Staphylococcus* have been used as prophylactic tools, especially in poults. Some of these apathogenic strains also produce bacteriocin, which can inhibit the growth of a variety of bacteria.

Although endogenous infections can be primary, they are frequently secondary to respiratory tract colonization and progress to septicemia. If an infected bird survives the acute septicemic stage of the disease, it will typically develop localized changes. Focal lesions occur as a result of thrombi formation in the arterioles and capillaries, which leads to ischemic necrosis. Clinically, these necrotic areas are frequently localized at the tips of the extremities and in the skin. In addition, infarction can also cause necrotic lesions in internal organs, particularly the liver and kidneys, which are more difficult to discern clinically. The central nervous system (CNS) is another site prone to *Staphylococcus*-induced lesions. Postsepticemic development of arthritis, tenovaginitis, osteitis and osteomyelitis followed by chronic skeletal changes are considered together as one disease process (Figure 33.7). These problems usually occur after a four- to seven-day period of septicemia.

Exogenous infections usually result in localized skin disease, although subsequent septicemia can occur in some cases. Birds, unlike mammals, are generally resistant to wound infection. To become established, exogenous bacteria typically require epithelium damaged by other infectious agents (particularly clostridia or poxvirus), immunosuppression (including immunosuppressive viruses such as retroviruses or reovirus), environmental stressors or prolonged application of an antibiotic.

Localized problems associated with *Staphylococcus* spp. can also result from a delayed hypersensitivity reaction. This type of response is considered to be one of the major factors in treating staphylococcus-related bumblefoot.

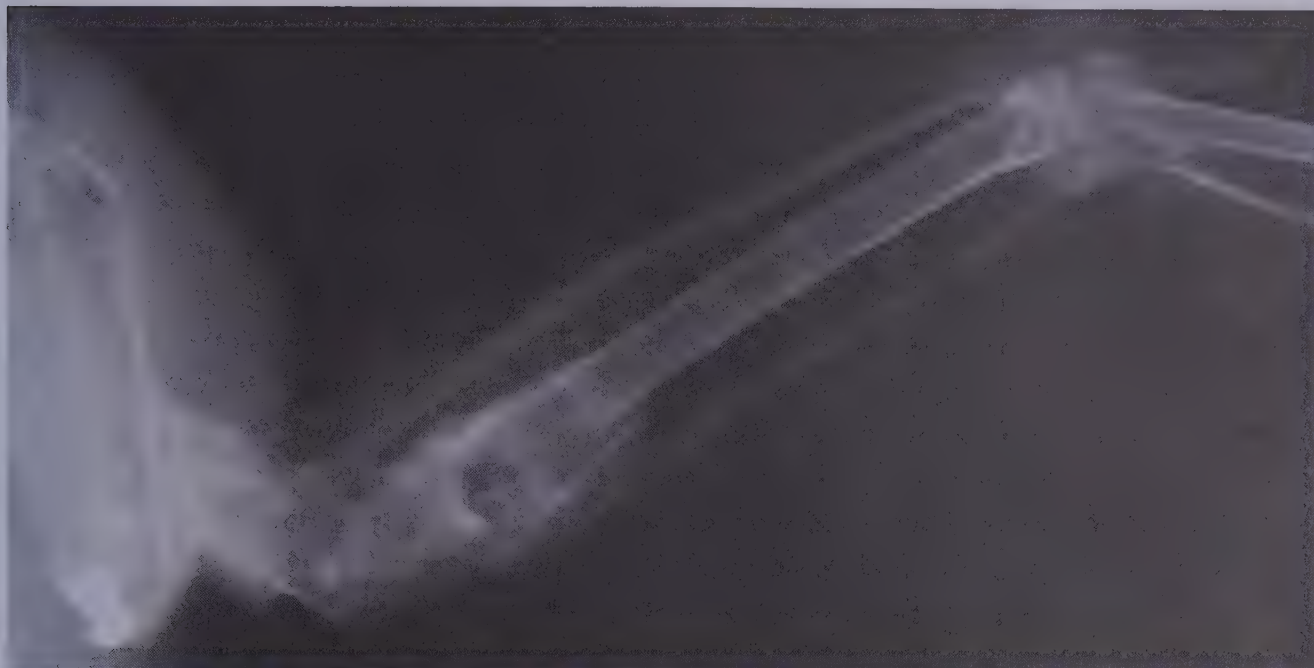### Clinical Disease and Pathology

*Staphylococcus* can induce a wide range of clinical and pathologic lesions, including high embryonic mortality, yolk sac or umbilical inflammation, septicemia, arthritis-synovitis, osteomyelitis, vesicular dermatitis, gangrenous dermatitis and bumblefoot.

Endogenous infections usually cause internal lesions, while exogenous infections frequently result in dermatitis and bumblefoot. Staphylococcal lesions in the umbilical region are typically either dry and brownish or smudgy, reddish and edematous. Clinical problems are most common in newly hatched chicks (up to ten days of age), in which the yolk sac in the body cavity is not absorbed normally, with possible decomposition of its contents.

*Staphylococcus* septicemia may be characterized by nonspecific clinical signs including lethargy, anorexia, a kyphotic posture, ruffled plumage and sudden death. The acute occurrence of necrosis to the distal digits or adnexa of the head and neck is suggestive of a thrombi-inducing infection, which can be a sequela to staphylococcus septicemia. During the initial phases of the ischemic process, the involved digits may be swollen, congested and painful, and many affected birds exhibit lameness. The acute onset of tremors, opisthotonos and torticollis can often be linked to staphylococcus-induced necrosis in the CNS. Gross lesions associated with staphylococcus septicemia include petechiae and ecchymoses of internal organs. Chronic infections may result in endocarditis valvularis. Histologic changes vary with the clinical course of disease but typically consist of a heterophilic and granulomatous response.

Arthritis-synovitis, characterized by the formation of serofibrinous or fibrinous inflammation of the



**FIG 33.7** *Staphylococcus* spp. can cause osteomyelitis either secondary to septicemia or following an injury that allows colonization of the bone. Chronic osteomyelitis, as demonstrated in this radiograph, typically requires surgery to remove necrotic tissue and long-term antibiotic therapy, preferably with clindamycin because of its high affinity to bone and bone marrow.

synovial membranes of tendon sheaths and articular bursae, is frequently noted with staphylococcal infections in gallinaceous species. Any joint may be involved but there appears to be a predilection for colonization of the tarsal and metatarsal joints. Following antibiotic therapy, staphylococcus may be present in its unstable L-form, which is difficult to treat.


In immature birds with active growth plates, *Staphylococcus* frequently localizes in the epiphyseal area with secondary invasion of the bone marrow, resulting in osteomyelitis. Endogenous osteomyelitis is considered to be impossible after consolidation of the growth plate.<sup>46</sup> Infection of the growth plates often leads to chronic skeletal abnormalities. Infections are frequently localized to the proximal epiphyses of the femur, tibiotarsus, tarsometatarsus and fifth to seventh thoracic vertebrae. Vertebral injury may lead to clinical changes described as “kinky back” (Figure 33.8). Swelling and colligation associated with the infection cause deformation of the vertebral spongiosa, which may lead to narrowing of the vertebral foramina and compression of the spinal cord.

*Staphylococcus*-induced vesicular dermatitis is characterized by the formation of vesicles containing yellowish exudate that form brownish to blackish crusts following rupture. Concomitant infection with poxvi-

rus (or other immunosuppressive agents) may be involved in the disease process. Histologic evaluation of biopsy samples is required to confirm an underlying poxvirus.

*Staphylococcus*-induced gangrenous dermatitis is initially recognized by the occurrence of subcutaneous edema and hemorrhage followed by inflammation of the skin. Affected skin is typically blackish and smudgy and feather loss is common. *Clostridium perfringens* or another *Clostridium* sp. is a common secondary invader. Both *Staphylococcus* and *Clostridium* require a triggering factor (often damaged epithelium) to enter the tissue. Gangrenous dermatitis is rare in most bird species.

Advanced bumblefoot is a necrotizing abscess on the plantar surface of the foot. Depending on the location and chronicity of the abscess, infection may or may not extend to neighboring joints, tendon sheaths and bones. The condition is frequently described in raptors but may occur in other avian species. The precise pathogenesis of bumblefoot is undetermined (see Chapter 16). Although staphylococci are frequently isolated from these lesions, they are by no means the only bacteria that can be recovered from diseased tissue. Systemic infections that result in other le-



**FIG 33.8** An eight-week-old African Grey Parrot was presented for an inability to stand or ambulate properly. On physical examination, the bird was BAR, in excellent weight (325 grams) and had a palpable spinal deformity. Radiographs indicated scoliosis. Bacterial infections including *Staphylococcus* spp. can cause spinal deformities. In this bird, the WBC was normal and the etiology of the problem was undetermined. Congenital abnormalities appear to be particularly common in African Grey Parrots and may have been the cause of this scoliosis.

sions or death can occur secondary to bumblefoot caused by virulent strains of *S. aureus*.

### Diagnosis

Staphylococcal colonies, like *Micrococcus* spp., have opaque pigments (from white to yellow). Clumping factor-positive strains are likely to be virulent, and require an aggressive therapy based on antibiotic sensitivities.

Serologic diagnostic techniques using agglutinins, antihemolysins or antitoxins are of little value in diagnosing staphylococcosis. Cross-agglutinins, particularly against *Salmonella gallinarum-pullorum*, frequently result in false-positive reactions.

### ■ *Streptococcus* (*Sc.*) and *Enterococcus* (*Ec.*)

Streptococci and enterococci consist of numerous species that readily grow on most commonly used media. Differentiation between the species is based upon morphologic, biochemical and serologic characteristics. These organisms are ubiquitous (mainly in

dust and air), and some strains can survive for long periods in the environment. They are sensitive to most commonly used disinfectants.

*Sc.* and *Ec.* are considered part of the autochthonous flora of the skin and the mucosal surfaces of the digestive, respiratory and reproductive tracts. *Sc.* and *Ec.* transition from normal flora to disease-inducing agents depends on the functional state of host defense systems. Predisposing factors to disease include immunosuppression, concomitant infections and exposure to a variety of toxins and pathogenicity factors that may be produced by some strains of *Sc.* and *Ec.*

The  $\beta$ -hemolyzing, pyogenic streptococci, frequently found in mammals, are rare in birds. In comparison,  $\alpha$ -hemolyzing streptococci are quite common. It has been suggested that most of the latter species should be included into the newly established genus *Enterococcus*.<sup>45,54</sup> Enterococci are less fastidious than streptococci, and many will grow on selective media used for isolating Enterobacteriaceae. Numerous species

of streptococci and enterococci have been isolated from birds.<sup>15,16,17,29</sup>

References to the pathogenicity of several *Sc. spp.* vary. Variance in the observed behavior of these opportunistic organisms may be a result of the effects induced by concomitant viral or chlamydial infections, the lack of experimental infections and confusion in taxonomy or nomenclature. Irrespective of predisposing factors, many *Sc.* and *Ec.* strains produce compounds that facilitate an infection (M-protein, capsules) or produce extracellular substances that inhibit the host defense system (hemolysin S, streptolysin S, hyaluronic acid, streptokinase, DNase, NADase and esterases) or inhibit other competing bacteria (bacteriocins).


Vertical transmission (including L-forms) can be a cause of early embryonic death and post-hatching developmental problems (Figure 33.9). Infections in hatchlings are usually associated with omphalogenic postnatal septicemia.

### Pathogenesis

The rarely occurring *Sc. spp.* group C can cause a septicemia followed by an embolic-thrombotic systemic disease and death, usually in adult birds. Following infection, hematogenic and intrahepatic spreading results in colonization in almost all organs if the host survives (probably agent- and host-specific). In experimental infections, a persistent bacteremia has been described, the duration of which can range from weeks to months. In addition to the pathogenicity factors already mentioned, *Sc.* group C may also produce reagents that govern the host reactions. Genetic and environmental factors as well as concurrent viral infections or immunosuppressions may predispose mainly adult birds to this rare infection.

Little information is available on the pathogenesis of *Sc. pneumoniae* or *Sc. pleomorphus* lesions in birds. *Sc. bovis* has been described as a pathogen in pigeons<sup>17</sup> and ducks;<sup>52</sup> however, the pathogenesis of these infections is unclear.

Enterococci outside of the digestive tract can cause necrotizing inflammatory lesions in infected organs.



**FIG 33.9** Bacterial infections (*Streptococcus*, *Staphylococcus*, *Enterococcus* and *Salmonella spp.*) of the egg can cause embryonal death, post-hatching developmental problems and yolk sacculitis.

However, the pathogenicity of *Ec. spp.* is generally low. Experimental infections indicate that disease induction requires predisposing immunosuppressive factors. As a rule, natural infections occur by the oral route and are most common in postnatal and growing birds.

*Ec. faecalis* can induce an acute septicemic or a subacute-chronic disease. The acute form predominates in young birds, and survivors often develop endocarditis. Details on pathogenesis are known only in gallinaceous species. *Sc. faecalis* is thought to play a central role in the malabsorption syndrome described in chickens.

Egg transmission of *Ec. faecalis* (also as an L-form) is associated with an acute post-hatching septicemia. The subclinically infected yolk sac is thought to be the source of disease in the hatchling. *Ec. faecalis* is not considered autochthonous flora of canaries and may cause a primary respiratory disease in this species.<sup>18</sup> Subacute-to-chronic tracheitis with dyspnea and rales are considered natural components of the disease. *Ec. cecorum* has not been associated with disease in experimental infections.<sup>14</sup> *Ec. columbae* is mainly found in pigeons and constitutes a component of the autochthonous intestinal flora.

### Clinical Disease

The clinical diseases caused by pyogenic streptococci and other streptococci and enterococci are relatively similar. Clinical presentation can be peracute to chronic, with birds surviving six to eight weeks in the chronic form. Omphalitis in recent hatchlings is typical with egg transmission or infections obtained from the hatchery.

An Amazon parrot with a slight nasal discharge was found to have a *Sc.* group G infection that was causing chronic respiratory disease in the children of the house. Presumably, the bird was infected by the children.

Septicemia may lead to a peracute apoplectiform death or severe depression followed by death in two to three days. Other signs such as diarrhea, dyspnea, paresis, conjunctivitis and sinusitis (Japanese Quail) may develop.

Chronic disease is typified by inflammation of joints, tendon sheaths and adnexa of the head. Fibrinous joint lesions, with or without abscess formation, can occur several months after the initial infection. Birds that survive systemic infections may develop cardiac valve insufficiency secondary to endocarditis. This condition is difficult to diagnose and often presents as chronic dyspnea.

*Sc. pyogenes* has been associated with bacteremia in the Humboldt Penguin, White Pelican, and several Psittaciformes, Anatiformes and Phasianiformes. It has not been clearly defined whether the bacteremia in these cases was a result of true group A streptococci, or whether the inciting strain was *Sc. pyogenes animalis* (classified in group C). Group C *Streptococcus* has been associated with pneumonia secondary to bacteremia in a variety of avian species. In the ostrich, *Sc.* group C cases are characterized by akinesia, anorexia and dysphagia. This organism together with *Corynebacterium pyogenes* can induce diphtheroid lesions in the mucosa of the beak cavity and the crop that can result in similar clinical signs.<sup>32</sup>

*Sc. bovis* infections in pigeons have been associated with clinical changes ranging from peracute death to chronic lameness (myositis) and arthritis.

*Ec.* group D is frequently implicated as a cause of pneumonia in various bird species, particularly Passeriformes, and primarily infects young birds. In canaries, *Ec. faecalis* can cause a tracheitis and chronic respiratory disease that manifests clinically as changes in the voice (more "sparrow-like") or com-

plete voice loss. Tracheal mites (*Sternostoma tracheacolum*) can cause similar clinical signs in this species. Epidemiologically, the infection spreads slowly through the whole flock. Some affected birds develop dyspnea and die, while others may temporarily recover. Relapses are common in recovered birds.

### Pathology

Gross lesions in birds that die acutely with bacteremia include subepicardial and myocardial hemorrhages and serofibrinous polyserositis. The subcutaneous tissues, serosal membranes and pericardium may be congested, and the spleen is frequently hyperplastic. Lung congestion, pneumonia or petechiation of the laryngeal and tracheal mucosa may be noted in some species. The liver may be slightly swollen and exhibit a greenish discoloration. Catarrhal enteritis, skeletal muscle hemorrhages and swollen kidneys may also be observed. Muscle necrosis and purulent myositis are frequently described in pigeons with *Sc. bovis* infections.

Pathologic changes in chronic cases are characterized by arthritis with a light, mucoid exudate and the formation of coagulated or dried exudates in the body cavity. Cauliflower-like or granulomatous atrioventricular inflammation may develop, particularly on the left cardiac valve. Pyogenic streptococci may cause chronic peritonitis, salpingitis and oophoritis.

Histologically, focal necrosis is common in the liver. This lesion is thought to be caused by bacterial endotoxins or the formation of thrombi in the bile ducts. Heterophilic infiltrates are most common in acute lesions. Granuloma formation (without a capsule and consisting of epithelioid cells and multinucleated giant cells), particularly in the spleen and heart, is more common in chronic cases. Purulent meningitis has been described in some cases. Endocarditis and cardiac infarct may occur secondary to embolic-thrombotic incidents. Localized lymph follicles may be described as hyperplastic.

### Diagnosis

In acute cases, samples for culture taken from the liver, heart and brain are most diagnostic. Isolation from the brain indicates that the strain recovered is actively involved in the disease process. A triggering factor might have been necessary to enable the organism to cause septicemia. Special media are necessary for culturing L-forms.



**FIG 33.10** White streaking is evident in the pectoral musculature of an Amazon parrot that was being treated with IM enrofloxacin.

### Treatment and Control

Aggressive treatment with parenterally administered antibiotics is the recommended therapy. Pyogenic streptococci are generally sensitive to penicillins, erythromycin, tylosin, spectinomycin, clindamycin and pleuromutilin. Enterococci have varying antimicrobial sensitivities. Chronic joint and tendon sheath infections are difficult to resolve and may require a combination of surgery, joint lavage and prolonged antibiotic therapy. Joint lavage appears to be more successful in birds than in mammals because iatrogenic secondary infections are less likely. Streptococci in synovial membranes are frequently in their L- or protoplasmic form. Treatment in these cases consists of ampicillin and erythromycin or enrofloxacin (Figure 33.10).

### ■ *Mycobacterium (M.)*

Colony morphology of pathogenic mycobacterium may be smooth or rough and change through successive *in vitro* subcultures. Most strains are nonphotochromogenic and may become yellow with age. Some strains are scotochromogenic and have bright yellow pigments.

All bird species that have been experimentally exposed have been found to be susceptible to *M. avium*. Lesions are typified by large numbers of bacteria in infected tissues. This is in contrast to *M. tuberculosis*, which is typically found in relatively small numbers in infected tissue. *M. avium* is highly resistant to environmental extremes and can survive in the cage or aviary environment for periods ranging from months to years. Shedding from an infected host occurs primarily in the feces and urine, causing contamination of the soil or water supplies within the aviary. Mycobacterium has been found to remain infectious in soil for up to seven years. For disinfection, only compounds tested against mycobacterium are recommended.

- ***M. avium* and *M. intracellulare*:** DNA cleavage techniques (restriction fragment length polymorphism and pulsed-field gel electrophoresis) have shown that *M. avium* consists of three clusters on the subspecies level as follows:<sup>62</sup>

***M. avium* subsp. *avium*:** This subspecies is ubiquitous in the environment and is the agent most commonly associated with avian mycobacteriosis. The organism also has a widely documented mammalian host range including cattle, sheep, goats, pigs, cats, kangaroos and humans. In humans, adults typically develop respiratory infections, children usually develop submandibular adenopathies, and disseminated infections are common in patients with immunosuppressive diseases (eg, AIDS). Strains experimentally caused paratuberculosis in cattle and tuberculosis in fowl (Table 33.5).

***M. avium* subsp. *paratuberculosis*:** This subspecies of *M. avium* requires mycobactin for *in vitro* culture and has not been isolated from the environment. This subspecies is considered to cause paratuberculosis in ruminants and has been implicated as a cause of Crohn's disease in humans.

***M. avium* subsp. *silvaticum*:** Like *M. avium* subsp. *paratuberculosis*, these strains also require mycobactin for primary cultivation and have not been recovered from the environment. Most strains have been

isolated from Wood Pigeons and free-ranging ruminants. The agent causes paratuberculosis in mammals and mycobacteriosis as well as paratuberculosis in birds.

*M. intracellulare* is designated as a distinct species and is considered less pathogenic to birds than *M. avium* (whether justified or not). Morphologic, biochemical and serologic differentiation between *M. avium* and *M. intracellulare* are relatively difficult. These two species are routinely grouped together into the *M. avium-intracellulare* (MAI) complex. MAI complex strains are serologically distinct and have been divided into serovars.<sup>64</sup> *M. avium* is divided into serovars 1 to 11; *M. intracellulare* into three subspecies (subspecies 1: serovar 12 to 17, 19 to 28; subspecies 2: serovar 7; subspecies 3: serovar 18). Serovar 1 is most prevalent and pathogenic in the United States, while serovar 2 is most common in Europe. To date, serovar 3 has mainly been isolated in Europe.

Serovar 8 has been isolated worldwide and is probably the most frequent serovar reported. Birds living in aquatic environments are particularly susceptible to infections, which can be subclinical. Recently, serovars 25 and 27 have been isolated from sick birds. In addition, *M. avium* strains have been recovered that do not belong to serovars 1 to 28. These newly isolated strains vary serologically, have a broad host spectrum and are considered as virulent as serovar 2.<sup>38</sup>

### Transmission

Avian mycobacteriosis primarily involves the alimentary tract. Transmission occurs mainly through contaminated feces, although aerogenic routes of transmission are possible. Arthropods can serve as mechanical vectors of *M. intracellulare* and *M. avium subsp. avium*. Egg transmission can occur but is epornitically unimportant because *M. avium* bacteremia causes an immediate cessation of egg production. Mycobacteria may persist in contaminated soil, litter and, less frequently, feed. Birds of prey can be secondarily infected while consuming infected quarry. The incidence of mycobacteriosis in free-ranging birds is estimated to be less than 1%.<sup>59</sup>

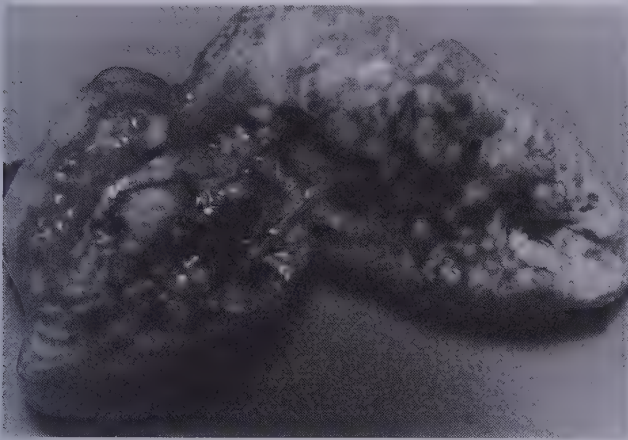
### Pathogenesis

The main portal of entrance in birds is the intestinal tract, which typically results in a visceral infection. Initial colonization occurs in the intestinal wall. Subclinical bacteremia occurs early with subsequent spread to the liver through the portal circulation during the infectious process (relatively low numbers of organisms in the blood). The lack of lymph nodes allows unabated hematogenous spread within the host. The lungs can be secondarily infected during bacteremia. Avian mycobacteria are removed from the endothelium of the vessels by reticuloendothelial cells, mainly in the liver, spleen and bone marrow. Locally, avian mycobacteria induce cellular reactions governed by the cell-mediated immune system. In contrast to this typical *M. avium* infection, Columbigiformes, Anseriformes and some weaver finches of the genus *Textor* develop lesions only within the lungs (Figure 33.11). An acute bacteremia is frequently observed in cranes (Gruiformes), the Hermit Ibis, Columbigiformes and some Passeriformes. Tubercles that form at the site of infection in the intestinal wall commonly remain open to the intestinal lumen. This allows for constant shedding of *M. avium* into the feces (open infection). In birds, three different types of lesions can be recognized although the pathogenesis has not been clarified: 1) classical form with tubercles in many organs; 2) paratuberculous form with typical lesions in the intestinal tract (prone to

TABLE 33.5 Zoonotic Potential of Bacteria From Companion Birds

Bacteria	Zoonotic Potential
Actinobacillus	None reported
Alcaligenes	None reported
Bordetella	None reported
Campylobacter	Undetermined, possible <i>C. lariidis</i> – diarrhea in children
Clostridium	Negligible
<i>E. coli</i>	Possible Prevention – good hygiene
Erysipelothrix	Persistent dermatitis Avoid contact with infected birds
Haemophilus	None reported
Listeria	Conjunctivitis when infected from birds
Klebsiella	Theoretically possible None reported Humans – Friedländer's pneumonia
Megabacterium	Avian-specific
Mycobacterium	Possible Immunosuppressed humans
Pasteurella	Rare human cases
Pseudomonas	Possible Prevention – good hygiene
Salmonella	Negligible (see text)
<i>Staphylococcus aureus</i>	Negligible Avian-adapted strains
Streptococcus/ Enterococcus	Negligible Birds may be infected by humans
<i>Francisella tularensis</i>	Possible/unlikely from birds
Vibrio	Mild enteritis
<i>Yersinia pseudotuberculosis</i>	High potential Transmission documented Humans – difficult to treat





**FIG 33.11** In Psittaciformes, mycobacteriotic lesions are generally not limited to the intestinal tract. In Columbiformes and some other species, atypical granulomas may form in the lungs. *Mycobacterium avium* was recovered from the lungs of this pigeon that was presented for severe emaciation and severe dyspnea. Radiographs indicated soft tissue masses in the lungs. Abnormal clinical pathology lesions included WBC=54,000 and PCV=19.

develop this form of mycobacteriosis are *Amazona*, *Pionus*, *Brotogeris*, *Psittacula* species and the Horned Parakeet); 3) non-tuberculous form, which may be difficult to recognize at necropsy (many Psittaciformes).

### Clinical Disease

In some bird species the clinical course is atypical, and acid-fast rods have been detected more or less accidentally. This is particularly the case with small Passeriformes, especially the Hooded Siskin.<sup>19</sup> Clinical signs associated with mycobacteriosis are highly variable. Adult birds usually develop a chronic wasting disease associated with a good appetite, recurrent diarrhea, polyuria, anemia and dull plumage. Immature individuals frequently develop subclinical conditions. Intermittent switching lameness may occur as a result of painful lesions in the bone marrow. Arthritis, mainly of the carpometacarpal and the elbow joints or tubercle formation of the muscles of the thigh or shank can be seen occasionally. These clinical changes are particularly common in Falconiformes and Accipitriformes. Skin over the affected joint is often thickened and ulcerated. Tubercle formation in the skin is rare, but when it is present, pinpoint to pigeon egg-sized nodules filled with yellow fibrinous material may be noted. Granulomas may be seen within the conjunctival sac, at the angle of the beak, around the external auditory canal and in the oropharynx. Mycobacteriosis should be suspected when tumor-like lesions recur after surgery. Greater Rhea frequently develop granulomas in the upper phar-

ynx. In the Goshawk, loss of balance, convulsions and necrosis of the base of the tongue have been observed.<sup>43</sup> Clinical signs associated with colonization of the lung are rare. However, the peafowl may develop respiratory sounds caused by granuloma formation within the trachea.

### Pathology

The pathology associated with *M. avium* infections varies widely, probably based on the species of bird infected and the serovar of the bacterium. Specific relationships between avian hosts and individual serovars have not been defined. The presence of miliary to greater-than-pea-sized nodules in the wall of the intestinal tract and in the liver, spleen and bone marrow are characteristic of *M. avium* infections. These typical lesions have been described in Falconiformes, Accipitriformes, Strigiformes, Phasianiformes, Charadriiformes, Ciconiiformes, Cuculiformes, Piciformes and Ralliformes. Granuloma formation can occur in any organ but is generally localized to the intestinal tract and reticuloendothelial organs. The nodules are frequently necrotic in the center and in chronic cases may be calcified. In contrast, Columbiformes, Anatiformes, Passeriformes and most of the Psittaciformes do not form typical granulomas. Acid-fast rods are found distributed throughout the parenchyma of infected organs. An infected liver or spleen may be only swollen or may show necrotic foci or even general induration. In pigeons, liver lesions may resemble *Trichomonas* abscesses. In pelicans, greasy tumor-like swellings like those seen in leukemia may be observed. The lungs, particularly of geese, weaver finches (genera *Queleopsis*, *Quelea* and *Euplectes*) and some *Amazona* spp., develop necrotizing or ulcerating lesions. Paratuberculous lesions are characterized by the occurrence of clubbed villi containing acid-fast rods in the intestinal mucosa. Lesions may also occur in glands of Lieberkühn, with characteristic proliferation of their epithelial cells.

Histopathologic identification of foci of single or confluent epithelioid cells in affected organs is suggestive of an *M. avium* infection. Parenchymal lesions generally consist of epithelioid cells or multinucleated giant cells (mostly the foreign body type, only rarely the Langhans type) and occasionally contain lymphocytes and plasma cells. Acid-fast rods in varying quantities can be demonstrated in the affected epithelioid or multinucleated giant cells. Acid-fast rods may also be noted in tissues in the absence of cellular reactions. Some infected birds will have cell-free acid-fast rods in the proventriculus or jejunal villi without an inflammatory response. It has been

postulated that the acid-fast rods may actually be contained within lymphatic vessels in the villi. *M. avium* infections frequently induce depletion of lymphocytes in the spleen (particularly the white pulp) and a proliferation of macrophage or reticular cell types in the same tissue. Depletion of the splenic lymphocytes and lymph follicles may induce an immunosuppression.

### Diagnosis

The demonstration of acid-fast rods in tissues or on cytologic preparations is suggestive of mycobacteriosis. False-negative staining can occur by not obtaining an adequate sample. The demonstration of acid-fast rods in the feces has been suggested as a useful diagnostic tool in subclinical birds. Mucus present in the feces can interfere with test results, and samples should be processed with one of the sputum solvents used in human medicine before staining. The most consistent results can be obtained by centrifuging the feces and then spreading the surface of the pellet on a slide for staining. This test is relatively insensitive and requires the presence of approximately  $10^4$  bacteria/g of feces to be positive. The clinician must differentiate between pathogenic and nonpathogenic strains of mycobacteria, both of which may be present in the feces. In general, nonpathogenic strains are wider and are not granular. Demonstrating acid-fast organisms in the stool is not diagnostic for a mycobacterial-induced disease.

Culture is required to make a distinct diagnosis. Some strains of *M. avium-intracellulare* require mycobactin and will not grow on egg medium. *M. avium* subsp. *paratuberculosis* and subsp. *silvaticum* can be separated by responses to six parameters: subsp. *paratuberculosis* has a mycobactin requirement, grows on egg medium, tolerates cycloserine (50 µg/ml), is stimulated by pyruvate but not by pH 5.5, and has no alkaline phosphatase. The subsp. *silvaticum* has the opposite characteristics.<sup>62</sup>

Unfortunately, most of the mycobacterial strains from Psittaciformes have not been cultured. The future availability of species-specific antibodies will help in delineating infections. Endoscopy (with biopsies) can be used for diagnosis in cases of advanced classical tuberculosis. Radiographs may indicate granulomas in respiratory tissues in some cases. Biopsy is required to differentiate between mycobacterial and fungal granulomas, which radiographically appear similar.

Several indirect tests have been discussed for diagnosing *Mycobacterium*. The tuberculin test (allergic test) and the slide agglutination test (serologic test) have both been used in birds with some success. The tuberculin test is frequently associated with false-negative results, particularly in early and late stages of the disease and is no longer recommended. The slide agglutination test requires fresh plasma or serum and is evaluated against a bank of antigens for the different serovars; there are cross-reactions between the different serovars. Unfortunately, only serovar 2 antigen is commercially available. To estimate the probability of an acute disease process, serotitration (using the Gruber-Widal scheme) is possible. Only titers greater than 1:64 are considered positive. Psittaciformes may exhibit a cyclic reduction in titer and mycobacterial excretion, which may lead to an incorrect suspicion that natural healing or a successful therapy has occurred. An ELISA system has been tested to distinguish between *M. avium* serovars but has been hampered by a high degree of cross-reactivity.

### Treatment and Control

Several treatment modalities have been discussed for birds with *M. avium* infections. However, treating infected birds is not recommended because:

- All *M. avium* isolates that have been tested are totally resistant to the antituberculous drugs routinely used in humans. Recent information revealed that ethambutol, while ineffective, does change the cellular wall of *M. avium* in a manner that allows other tuberculostatics to enter the organism.<sup>21</sup> However, successful therapy is then dependent on pharmacokinetic conditions and requires a combination of drugs to be available at the same time, at the correct concentration and at the correct anatomic location. The pharmacokinetic data necessary to ensure that these parameters are met are not available for a single avian species.
- *M. avium* infections are considered to be "open," allowing infected birds to continuously shed large numbers of organisms into the environment.
- There is potential danger to man, and there is no appropriate method of treatment for infected humans.

Birds that are definitively diagnosed (biopsy of affected tissue with histopathology and culture) with *M. avium* or *M. intracellulare* infection should be euthanatized. Contact birds should be removed from the contaminated area, quarantined for two years and tested every six to 12 weeks to determine if they

are reacting. Birds that remain negative (also not shedding the agent with the feces) and are in good physical condition following the quarantine procedure can be considered free of the disease. There are currently no absolute means of control. The chances of introducing *M. avium*-positive birds to the flock can be reduced by performing serologic or repeated fecal examinations of all new additions during the quarantine period.

The transmission of *M. avium* to humans is possible. However, transmission is probably dependent on inherent resistance, the immune status of the person in question, the frequency of exposure and the number of bacteria per exposure.

- ***M. tuberculosis*:** *M. tuberculosis* lesions in Psittaciformes are possible but are extremely rare. When present, they are generally characterized by the formation of benign localized granulomas of the dermis, frequently around the cere or nares as well as the retroorbital tissue.<sup>63</sup> Birds affected are usually pets with very close human contact and, as such, serve as sentinels for patent tuberculosis in the owners. The affected dermis looks granulomatous and may even ulcerate. The swelling of the retrobulbar tissue causes a protrusion of the eye (exophthalmos). Diagnosis can be made by histology or culture of biopsies. Infected birds should be euthanatized.
- ***M. bovis*:** *M. bovis* was associated with a generalized infection in an Amazon parrot. This animal developed a nontubercular lesion similar to those seen in Psittaciformes infected with *M. avium intracellulare*. The strain in question was sensitive to all common tuberculostatic drugs.

### ■ *Erysipelothrix (E.)*

*Erysipelothrix rhusiopathiae* can induce an acute-to-subacute septicemic disease. Infections are most commonly discussed in ducks and geese but can occasionally occur in other avian species including Psittaciformes.<sup>55,32</sup> The eleven serotypes of *E. rhusiopathiae* are ubiquitous in the environment and can propagate outside the host. Survivability in moist soil and in the water of shallow lakes and ponds, even salt and seawater, is particularly high. Infections in birds occur most frequently in the late fall, winter and early spring (northern hemisphere). Rodents, pigs and raw fish have all been implicated as reservoirs for the bacterium.

### Pathogenesis

*E. rhusiopathiae* infections are most common in waterfowl and fish-eating birds during cold weather when food is scarce and energy requirements are high. Concomitant infections and inadequate hygiene seem to be precipitating factors of natural diseases. Most affected birds die during the bacteremic phase of an infection. Those birds that survive the acute disease frequently have secondary dermatitis and arthritis caused by hypersensitivity reactions.

### Clinical Disease and Pathology

*E. rhusiopathiae* usually causes peracute death. If clinical signs occur, they may include lethargy, weakness, anorexia and hyperemia or bruising of the featherless, nonpigmented skin. Greenish discolored droppings, dyspnea and nasal discharge have been reported in some cases. In the Marabou Stork, infections have been characterized by inflammation and necrosis of the cutaneous adnexa of the neck.

Petechiae in the subcutis, musculature and intestinal mucosa are common gross lesions in diseased birds. The liver and spleen are friable and discolored (red to black). Histologically, these organs are degenerated and necrotic. Chronic *E. rhusiopathiae* cases are rare but have been reported in geese and turkeys. Clinical changes associated with this form of disease include thickened, leather-like skin, serofibrinous arthritis or valvular endocarditis. Histologic changes in these tissues include thrombi and degeneration of vascular walls.

### Diagnosis

Diagnosis is confirmed by isolating *E. rhusiopathiae*. The best samples for isolation (if the tissues are fresh) are liver or spleen. In severely autolytic cases, bone marrow samples may be the most diagnostic. As in most bacterial diseases, cell-mediated immunity is more important in resolving infections than the development of humoral antibodies. Thus, serologic methods of diagnosis are of little value.

*E. rhusiopathiae* adjuvanted bacterins have been used to control flock outbreaks; however, vaccination may sensitize the birds and potentiate chronic disease. Flock control can best be implemented through sound aviary hygiene and rodent control.

### ■ *Listeria (L.)*

*Listeria monocytogenes* causes  $\beta$ -hemolysis on blood agar. The motility of listeria is dependent on the ambient temperature to which it is exposed. *Listeria*

spp. may infect a number of avian species, including Psittaciformes.<sup>32</sup> Canaries appear to be more susceptible to infections than other birds.

*L. monocytogenes* is a ubiquitous organism that is frequently found in areas. The bacteria is environmentally stable and can propagate outside the host.<sup>56</sup>

### Pathogenesis

The role of *L. monocytogenes* as a primary pathogen is controversial; however, there is no question that ingested bacteria can lead to a latent or abortive infection. Acute disease is characterized by bacteremia progressing to death within one to two days. The subacute and chronic forms of the disease involve reactions of the cell-mediated immune system. Intracellular bacteria like *L. monocytogenes* typically induce cell-mediated immunity.

### Clinical Disease and Pathology

Clinical disease is usually associated with sporadic deaths in a collection. Epornitics can develop in canaries and related birds that are maintained in dense populations. Chronic infections can induce lesions in the heart, liver and, rarely, the brain. If clinical signs are noted, they are generally associated with CNS signs and include blindness, torticollis, tremor, stupor and paresis or paralysis (Figure 33.12).<sup>41</sup> Subacute-to-chronic cases usually cause a severe monocythosis (10 to 12 times normal).

The presence of serofibrinous pericarditis and myocardial necrosis is considered suggestive of *Listeria*. There are usually no gross lesions evident in the brain. There may be no lesions in birds that die acutely, or there can be a few petechiae present.

Histologically, infections are characterized by degenerative lesions, without a cellular response, in the heart and liver. Brain tissue is usually normal, even in cases in which CNS signs are present and the organism can be recovered from the cerebrum.

### Diagnosis

A confirmed diagnosis requires the isolation of *L. monocytogenes* from affected tissues. Appropriate transport media are necessary for proper shipment of




FIG 33.12 Encephalitis caused by several bacterial pathogens including *E. coli*, *Listeria*, *Salmonella*, *Staphylococcus* and *Klebsiella* spp. can cause neurologic signs characterized by torticollis, tremor, ataxia, depression, paresis or paralysis.

samples. *Listeria* isolates must be speciated, because *L. ivanovii*, *L. innocua* and *L. seeligeri* are commonly recovered from birds.<sup>8</sup> There is little information on the pathogenicity of these *Listeria* spp. although *L. innocua* is considered apathogenic.<sup>37</sup> Latent infections limit the diagnostic value of serologic tests (slide agglutination).

### ■ Clostridium (Cl.)

The genus *Clostridium* includes a group of ubiquitous bacteria that are considered to be autochthonous flora in raptors and in birds with well developed ceca, including Phasianiformes (gallinaceous birds) and Anseriformes. In birds in which the cecum is small or absent, clostridium is rarely isolated from the intestinal tract and when it is, it is often considered to be transitory.

### Pathogenesis

*Clostridium* spp. produce more potent toxins than any other bacterial genus. The pathogenesis of *Cl.* spp. toxin-induced damage in a bird remains poorly understood except for *Cl. botulinum*. This *Cl.* sp. principally causes an alimentary intoxication. The ability of clostridia to colonize the intestines appears to depend on reduced gastrointestinal motility. Peristaltic abnormalities can occur as a result of enteritis, low levels of dietary fiber, administration of some

medications, or during some viral infections (particularly reovirus). Experimental reproduction of disease by using a culture alone is usually not possible, and clostridial organisms are considered to be opportunistic pathogens. Following colonization, pathogenic clostridia produce exotoxins, which then induce clinical lesions or death.

It is best to discuss clostridial infections by grouping them under clinical signs because a clostridial species can cause differing clinical signs, and various clostridial species can cause similar-appearing diseases.

### Necrotic or Ulcerative Enteritis

Clostridia-induced enteritis can occur in many avian species. Flock outbreaks are most commonly associated with Phasianiformes, especially those within the subfamilies Tetraoninae (grouse) and Odontophorinae (New World quail) or captive and free-ranging lorikeets.<sup>44</sup> Ulcerative gastritis, not enteritis, is the most common form of clostridial infection reported in the ostrich.<sup>60</sup> Clostridial enteritis in game birds (Tetraoninae) is usually associated with *Cl. perfringens* type A. On rare occasions, types B, C or D may be the etiologic agent. *Cl. perfringens* type E is very rare in Phasianiformes. Ulcerative enteritis in the Bobwhite Quail is usually caused by *Cl. colinum* (species *incertae sedis*). This organism is also thought to cause necrotic enteritis in the other Odontophorinae, grouse, chicken, turkey and domesticated pigeon (Köhler, personal communication).

Necrotic enteritis usually occurs in young birds after the second post-hatching week. Adult birds are more resistant. In the acute form of the disease, clinical changes include diarrhea (with or without blood) and polydipsia, followed by death within a few hours. Birds with chronic lesions exhibit retarded growth and weight loss before dying.

Pathologic changes include diffuse or focal hyperemia of the mucosa, which develops into necrotic areas or ulcers. These lesions are most common in the upper jejunum. Lesions start as pinpoint foci and progress to include a necrotic center with a wall and a reddish halo. Ulcers may coalesce and perforate the intestinal wall. Swelling and necrosis of a grayish liver, spleen and kidney are common.

Identification of characteristic lesions and isolation of the organism are confirmatory. If *Cl. perfringens* is the etiologic agent, a diagnosis can be achieved by demonstrating toxins in the serum, intestinal contents and liver homogenates (sterilized by filtration).

The differential diagnosis includes salmonellosis, enterotoxigenic *E. coli* and drug overdoses. Newcastle disease virus can induce ulcers called "boutons" that resemble those induced by *Clostridium*.

### Gangrenous Dermatitis

Gangrenous dermatitis can be caused by *Cl. perfringens* type A, *Cl. septicum*, or *Cl. novyi*. These organisms can directly colonize damaged skin. Microscopic epithelial lesions caused by abrasions, avipoxvirus or staphylococci can become secondarily infected with *Clostridium* spp. The patient's immune status may also play a role in the overall pathogenesis.

The sudden occurrence of regional feather loss with a blue-red or almost black skin discoloration is a characteristic lesion. Affected skin may also be edematous and painful as a result of gas accumulation in the tissue. Sick animals typically develop toxemia and die within 24 hours. With screamers (genus *Chauna*), their corneous-lined bony wing spurs can cause prick-like skin injuries predisposing them to clostridial diseases.

The occurrence of emphysema, edema and hemorrhages (with or without necrosis) in the subcutis, skeletal musculature and myocardium are characteristic necropsy findings. A confirmed diagnosis requires isolation of *Cl. spp.* from affected tissues. *Aeromonas hydrophila*, staphylococci and avipoxvirus can induce pathologic changes similar to those caused by *Cl. spp.* Rapid production and systemic release of toxins usually prevents successful therapy.

### Botulism (syn. Limberneck)

*Cl. botulinum* neurotoxins are typically ingested in contaminated foods. Rarely, clinical disease may result from primary colonization of the alimentary tract. *Cl. botulinum* has been found to produce six thermolabile exotoxins (designated A to F). Types A and C are predominantly involved in inducing pathologic changes (occasionally also type E). High concentrations of clostridium toxins are common in decaying meat and vegetation. Fly larvae (maggots) that feed on decaying material are resistant to the toxins but can serve as a source of intoxication for those species that eat maggots. With a few logical exceptions, most birds are probably susceptible to *Cl. botulinum* toxins. Free-ranging waterfowl are particularly susceptible, and enzootic intoxications are common following periods of drought or flooding. Vultures seem to be resistant to the toxins (by a still

unknown mechanism), and some raptors (that eat carrion) have a reduced susceptibility.

Foods contaminated with *Cl. botulinum* toxins have no particular change in taste or smell and are thus difficult to detect. Toxins enter the body through the intestinal wall, move to the ends of the autonomic and somatic efferent nerves and then ascend into the spinal cord. Once in the spinal cord, toxins selectively and irreversibly bind to the neuromuscular junctions and block the production of acetylcholine. Death is due to respiratory paralysis. Toxins also damage vascular endothelium, resulting in edema and petechiation.

Flaccid paralysis of the skeletal musculature (including the tongue) is the characteristic clinical change. Bulbar paralysis, feather loss and diarrhea may be noted in some birds. Birds with substantial clinical signs usually die, although a few can spontaneously recover. Recovery is more likely with type A rather than type C toxin. Petechial hemorrhage of the cerebellum and focal necrosis and hemorrhage of the central lobe of the cerebrum are indicative of *Cl. botulinum*, but there are no pathognomonic lesions.

Confirming a diagnosis requires using mouse animal models to demonstrate the presence of toxins in serum, filtered liver or kidney from an affected animal. Feed or water (sewage, mud) extracts from a pond also provide diagnostic samples. *Cl. botulinum* toxins are heat-sensitive and degrade at room temperature. Materials to be tested should be preserved by deep-freezing (-20°C).

Intoxication with some algae, eg, red tide (see Chapter 46), may cause clinical signs similar to those caused by *Cl. botulinum*. Affected birds usually have access to muddy, drying bodies of water. *Aeromonas hydrophila* can cause the acute death of large numbers of waterfowl that consume contaminated water. A rapid death, typically in the summer, is characteristic, but some infected birds can develop signs that mimic those of *Cl. sp.* toxin ingestion. *A. hydrophila* and *Cl. botulinum* may both cause epornitics of acute death in connection with contaminated water.

Flock problems can be prevented by reducing contact with decaying foods, removing cadavers, providing toxin-free feed (especially for insect eaters) and regulating the water level and temperature in waterfowl collections (see Chapter 46). A commercial type C antitoxin is available for mink and has proven to be effective in birds. One-half of the dose recommended for mink should be used in birds.

## Tetanus

A few cases of *Cl. tetani* intoxication in birds have been reported in older literature. There have been no cases of tetanus reported in birds using more confirmatory diagnostic tests. Generally, birds are considered to be highly resistant to *Cl. tetani*; cases reported in older literature may have been incorrectly diagnosed.

## Other Gram-positive Rods

*Bacillus* spp., *Corynebacterium* spp., *Streptomyces* spp. and *Lactobacillus* spp. are commonly recovered from avian-derived samples. Because these organisms are frequently isolated from clinically normal birds, they are considered to be components of the autochthonous flora. *Megabacterium* is considered to be a pathogenic organism, although little information is currently available on its involvement in avian disease. *Bacillus* spp. isolated from birds are difficult to differentiate, and most have not been described taxonomically. *Bacillus anthracis* has not been associated with clinical disease in birds, presumably because their high body temperature inhibits the production of the pathogenic toxins. Vultures, and to a lesser extent raptors, are known to be mechanical vectors.

None of the *Corynebacterium* (*Co.*) spp. that have been isolated from birds have been found to be pathogenic. Ostriches have been reported to have concomitant *Co. pyogenes* and *Sc.* group C infections.<sup>32</sup> Antibodies to *Corynebacterium* spp. and *Mycobacterium avium-intracellulare* can cross-react, making differentiation between these organisms difficult.

*Streptomyces* spp. can occasionally be isolated from the avian respiratory system. The pathogenicity of the organism is questionable. Some reports describe nocardia in birds. These cases were described based on bacterial morphology and not on analysis of wall components, which is necessary to confirm nocardia in infected tissues.

*Lactobacillus* spp. can be identified on the mucosa of the intestinal, respiratory and reproductive tracts of many avian species. In birds that do not possess Enterobacteriaceae as a normal component of the gut flora, lactobacillus seems to play an important role in inhibiting colonization of Enterobacteriaceae (although probably not in many species of grouse). Supplementing with lactobacillus has been discussed as a method of inducing a natural competitive inhibition

TABLE 33.6 Survey of Clinically Important Bacteria

Bacteria	Characteristics	Incubation	Transmission	Disinfectants/Stability
Alcaligenes/ Bordetella	Motile 0.3-0.5 x 1-2 $\mu$ m	Turkeys – 5-7 days Others – unknown	Alc. ingestion Shed in feces Egg transmission Bord. respiratory tract, feces Egg transmission	Resistant to drying Environmentally stable (Particularly low temps)
Campylobacter	Gram-negative Motile rod 0.2-0.5 x 1.5-5 $\mu$ m	5 to 15 days	Ingestion Feces	Survives 1 week out of host Most disinfectants effective
Clostridium	Gram-negative Anaerobic Spore-forming rod	Experimental – hrs to 3 days Natural – unknown	Ingestion Wound infection	Resistant in environment Spores – survive years Most disinfectants ineffective Autoclaving/flaming effective
Erysipelothrix	Gram-positive Nonmotile rods 0.2-0.4 x 1-2.5 $\mu$ m	Turkeys, ducks – 1.8 days Other birds – unknown	Ingestion Egg transmission (stork)	Most disinfectants effective
<i>E. coli</i>	Gram-negative 0.5 x 3 $\mu$ m Motile or nonmotile rod	Experimental – 24 to 48 hrs	Ingestion – mainly Aerogenic – dust Egg transmission (normal & L-forms)	Most disinfectants effective
Haemophilus	Gram-negative 0.3-0.6 x 1-3 $\mu$ m Coccioid-to-pleomorphic rods	<i>H. paragallinarum</i> 1-5 days	Respiratory tract Asymptomatic carriers	Survives a few days Most disinfectants effective
Listeria	Gram-positive 0.4 x 0.5-2 $\mu$ m Motile rod	Unknown	Ingestion Common in aquatic environments Reptiles, amphibians, snails natural reservoirs	Most disinfectants effective
Mycobacterium	Gram-positive Acid-fast Granulated short-to-long rods	Weeks to years Exposure and immune system dictate	Feces, urine Aerogenic possible (rare) Arthropods-mechanical vectors	Persists in contaminated soil or litter for years
Pasteurella	Gram-negative Nonmotile Ovoid-to-coccioid rod	Vary with species Cat bite – 6-48 hrs	Upper respiratory tract Fecal shedding rare See text	Not stable to stable depending on conditions Most disinfectants effective
Pseudomonas Aeromonas	Gram-negative 1-3 x 0.3-0.6 $\mu$ m	Specifics unknown Pseud – few hrs Aero – 1-3 days	Ingestion Proliferates in H <sub>2</sub> O Secondary in open wounds	Pseudo: resistant to most disinfectants – steam, boiling H <sub>2</sub> O effective Aero: most disinfectants effective
Salmonella	Gram-negative 0.5 x 3 $\mu$ m Motile, rarely nonmotile rod	Varies with type Acute 3-5 days Egg – 2 days	Ingestion Egg transmission Normal and L-forms	Dried feces stable – 8 months to 2 years Water stable – 3 weeks Most disinfectants effective >60°C kills most strains
Staphylococcus	Gram-positive 0.8 x 1.0 $\mu$ m Nonmotile Spherical coccioid	Unknown Few hrs to few months Latent infections	Vertical, horizontal Normal & L-forms Chronic carriers	Environmentally stable Most disinfectants ineffective
Streptococcus Enterococcus	Gram-positive <2 $\mu$ m Coccioid-to-ovoid pairs or chains	Mammals – days to weeks Birds – unknown	Horizontal, vertical Shed in feces Aerogenic Percutaneous (skin lesion)	Probably no growth in environment Sc spp – short-lived Ec spp – long-lived
Yersinia	0.4 - 0.8 x 0.8 - 1 $\mu$ m Motile or nonmotile Ovoid-to-coccioid rods	Days to 2-3 weeks	Ingestion Carrier birds & rodents Direct contact Fecal contaminated food or water	Most disinfectants effective

TABLE 33.7 Bacterial Control and Therapeutics

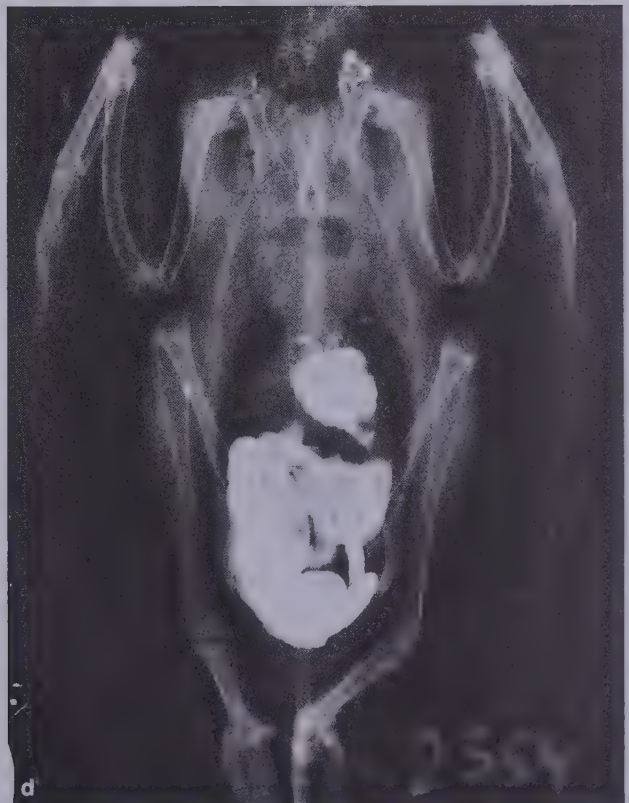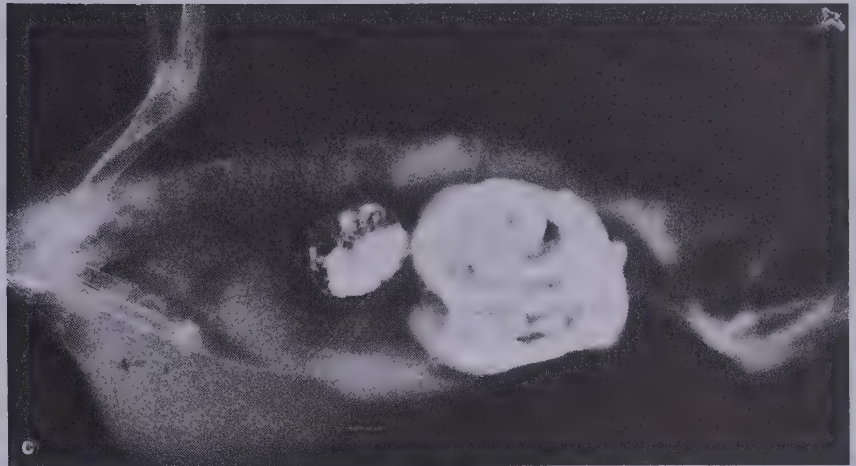
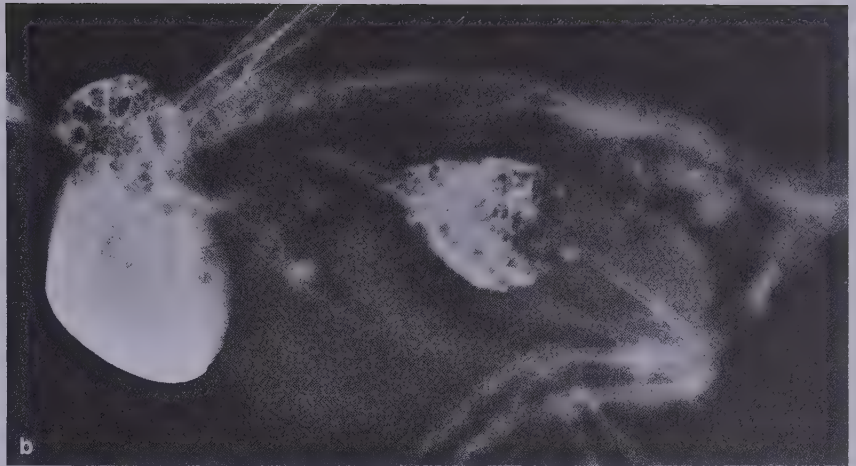
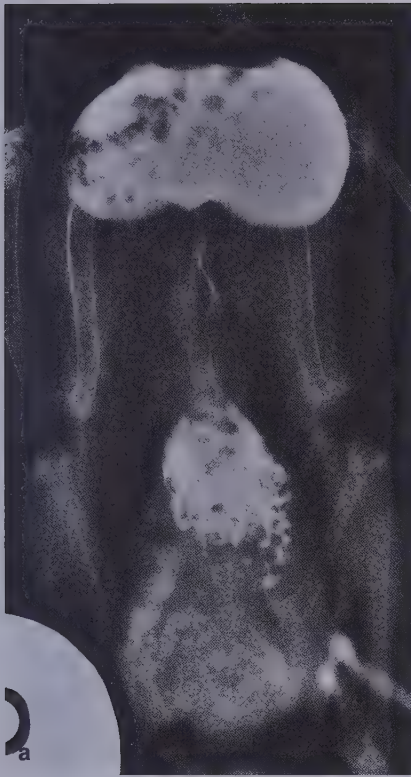Bacteria	Treatment/Control	Bacteria	Treatment/Control
Actinobacillus	Tetracyclines/chloramphenicol See text	Klebsiella	Resistant to many antibiotics Rx based on sensitivity Enrofloxacin initially
Aeromonas	Most antibiotics See text	Listeria	Tetracyclines CNS signs – poor prognosis Hygiene critical
Alcaligenes/Bordetella	Antibiotic resistance common Rx based on sensitivities	Megabacterium	No effective therapy Resistant to all tested antibiotics Control – unknown Acidifying water with HCl
Borrelia	Tylosin/Spectinomycin Control ticks Strain-specific vaccines	Mycobacterium	Not recommended See text
Campylobacter	Erythromycin/tetracyclines Streptomycin, non-psittacines Furane derivatives in non-waterfowl (See text)	Pasteurella	Parenteral antibiotics See text Control – Prevent rodents/free-ranging birds Vaccines – poor efficacy
<i>Clostridium perfringens</i>	Clindamycin/spiramycin Laxatives – Remove unabsorbed toxins Wound irrigation Control – Vaccination (toxoid) Zinc bacitracin (200 ppm) (Bobwhite Quail in food) Prevent skin wounds	Pseudomonas	Resistant to many antibiotics Rx based on sensitivity Enrofloxacin initially Systemic infections usually fatal See text
<i>Clostridium botulinum</i>	Toxoid vaccine, antitoxin Laxatives – remove unabsorbed toxins Guanidine – (15 to 30 mg/kg) May bind neurotoxin Prevent food contamination Activated charcoal See text	Salmonella	See text
Cytophaga	Parenteral antibiotics Treat soon after hatching Bacterins provide sero-specific protection	Staphylococcus	Resistant to many antibiotics Semisynthetic penicillins pending sensitivity Bumblefoot – Debride, antibiotics Heparin – prevents fibrin
Escherichia coli	Rx based on sensitivity See text	Streptococcus Enterococcus	Parenteral antibiotics See text Control – hygiene Stimulates minimal immune response
Erysipelothrix	Parenteral penicillin/doxycycline Surgically remove affected skin Hyperimmune serum See text	Yersinia	See text
Haemophilus	Most antibiotics Sulfonamides – drug of choice Sinusitis – surgical drainage Flushing Topical vitamin A Asymptomatic carriers Detect by culturing sinuses Polyvalent vaccine – poor efficacy		

Treatment of all bacterial infections should be based on specific antibiotic sensitivity. Supportive care in the form of fluids and enteral feeding is frequently necessary. Correcting predisposing factors that cause immunosuppression in the host or allow exposure to an organism are critical control methods. Preventing exposure to rodents, insects and free-ranging birds can reduce bacterial exposure. Hygiene is always important, particularly in neonates, to prevent reinfection.

of gram-negative and other pathogenic bacteria. However, there are strong indications that many groups of birds have specific lactobacilli that can effectively colonize the gut. Strains derived from soured milk do not colonize the avian gut and must be given daily for two to four weeks in order to lower the gastrointestinal tract pH. This drop in pH will favor the colonization of autochthonous microorganisms. Inhibitory expulsion itself takes from four to six weeks, provided no serious triggering factors interfere.<sup>23</sup>

Isolation of megabacteria is difficult, and biochemical descriptions that would allow appropriate taxonomic classification have not been performed. This organism has a unique morphology and is a large (1 x 90 µm) gram-positive rod.<sup>13</sup> Successful culture requires the use of Merck's MRS medium; however, not all megabacterial strains have been found to grow on this medium. The colonies are rough and measure 3 to 4 millimeters in diameter with a dented margin. Development requires 48 hours in a moist chamber. Subcultures are progressively more difficult and the organism may stop growing in successive passages.<sup>28</sup>





**FIG 33.13** A group of budgerigars was presented for occasional melena and chronic weight loss over a prolonged period. Large ( $1 \times 90 \mu\text{m}$ ) gram-positive rods (suggestive of megabacteria) could be detected in the feces. Radiographs in various affected birds indicated **a,b**) proventricular dilatation and **c,d**) filling defects and ulceration in the proventriculus. At necropsy, the filling defects were found to be globules of mucin that had a propensity to accumulate at the isthmus. It should be noted that the presence of a dilated proventriculus is not diagnostic for neuropathic gastric dilatation (courtesy of Nina Ungerechts).

TABLE 33.8 Differential Diagnoses of Bacterial Infections

<b>Arthritis or Synovitis</b> <i>Staphylococcus</i> <i>Actinobacillus</i> sp. <i>E. coli</i> <i>E. rhusiopathiae</i> (ducks and goose) <i>Mycobacterium avium</i> <i>Mycoplasma</i> spp. <i>Pasteurella multocida</i> <i>Salmonella</i> spp.	<b>Enteritis</b> <i>E. coli</i> <i>Aeromonas</i> sp. Most enteric organisms <i>Pseudomonas</i> spp. <i>Salmonella</i> spp. <i>E. rhusiopathiae</i> Chlamydiosis <i>Listeria</i> sp. <i>Pasteurella</i> spp.	Cytophaga (duck septicemia) <i>Pasteurella</i> spp. Haemophilus Chlamydiosis (eg, psittacines, Columbiformes) <i>Salmonella</i> spp.
<b>CNS Signs</b> Listeriosis Chlamydiosis <i>E. coli</i> <i>Klebsiella pneumoniae</i> <i>Listeria monocytogenes</i> <i>Salmonella</i> spp.	<b>Hepatitis</b> Most bacteria that cause septicemia Campylobacter <i>Pasteurella</i> spp. Chlamydiosis <i>Salmonella</i> spp.	<b>Septicemia</b> <i>E. coli</i> Many bacteria <i>Listeria</i> spp. <i>E. rhusiopathiae</i> <i>Pasteurella</i> spp. <i>Salmonella</i> spp. <i>Yersinia pseudotuberculosis</i> <i>Pseudomonas/Aeromonas</i> Most Enterobacteriaceae <i>Staphylococcus</i> (mimics numerous other infectious agents) <i>Streptococcus/Enterococcus</i> Borreliosis (high tick areas)
<b>Dermatitis</b> <i>Pseudomonas/Aeromonas</i> spp. <i>Clostridium</i> spp. <i>Staphylococcus</i> spp.	<b>Pseudomonas enteritis</b> <i>Clostridium</i> spp.	
	<b>Respiratory Disease</b> Algalgenes Enterobacteriaceae <i>Pasteurella</i> spp.	

Morphologically similar strains of megabacterium that were considered normal components of the budgerigar proventricular flora have been described.<sup>53</sup>

Some researchers believe that megabacterium is the causative agent of progressive weight loss ("going light syndrome") in budgerigars. The name "going light syndrome" should provisionally be replaced by megabacteriosis, because weight loss is a clinical sign of a variety of chronic diseases. Experimental infections with pure cultures of megabacterium induce disease only in English standard budgerigars and not in the normal breed.<sup>28</sup> These findings suggest that birds vary in susceptibility to the organism, and other factors are involved in the pathogenesis. Spontaneous recovery was common in experimental cases. The host spectrum includes canaries<sup>34</sup> and related finches, cockatiels, lovebirds, chickens and young (3-week-old) ostriches (Hüchzermeier, unpublished).

Clinically infected birds develop chronic emaciation over a 12- to 18-month period that may or may not

involve intermittent periods of recovery. Severely affected birds may pass digested blood in the feces. Contrast radiography typically indicates a sandglass-like retraction between the proventriculus and ventriculus (Figure 33.13). This finding is considered highly suggestive of megabacteriosis.<sup>31</sup> Megabacterium is shed in the feces and can be detected by gram-stained samples from severely sick birds.

At necropsy, a proventriculitis or proventricular ulcer with or without hemorrhages can be observed. Lesions are most common in the pars intermedia gastris. The organisms lie densely together in the necrotic tissue foci. There is usually little inflammatory cellular reaction associated with the organism, which can be seen readily at low magnification from proventricular scrapings. Impression smears from the liver and spleen may be useful in detecting the bacteria, which can be encapsulated in the tissues. There is no treatment because of resistance to all antibiotics commonly used.

## References and Suggested Reading

- Aleksic S, et al: Mikrobiologie und Epidemiologie der Yersiniosen. *Immun & Infekt* 18:178-185, 1990.
- Backstrand JM, et al: Survival of *Pasteurella multocida* in soil and water in an area where avian cholera is enzootic. *J Wildl Dis* 22:257-259, 1986.
- Bergey's Manual of Systematic Bacteriology: Vol 1. Baltimore, London, Los Angeles, Sydney, William and Wilkins, 1984.
- Biggaard M, et al: Isolation, characterization and public health aspects of *Vibrio cholera* NAG isolated from Danish duck farm. *Avian Pathol* 19:271-276, 1975.
- Böttger EC: Systematik, Differenzierung und Nachweis von bakteriellen Infektionserregern - die Familie Mycobacteriaceae. *Immun Inf* 19:143-152, 1991.
- Braumiller W: Zur Charakterisierung von Hämolytinen aus aviären *Aeromonas-hydrophila*-Stämmen. *Vet Dis, München*, 1991.
- Bredy JP, et al: The effects of six environmental variables on *Pasteurella multocida* populations in water. *J Wildl Dis* 25:232-239, 1989.
- Bühler-Nickel E: Untersuchungen zum Isolierungsverfahren, Vorkommen und zur Differenzierung von Listerien beim Geflügel. DVG-Tagung Fachgruppe Bakteriologie, 1990, pp 74-86.
- Cainek BW, et al (ed): Diseases of Poultry. Wolfe Publishing Ltd, 1991.
- Cooper GL, et al: Spondylitis associated with *Pasteurella anatipestifer* infection in turkeys. Proc 41th West Poultry Dis Conf, 1991, p 54.
- Crosta L, et al: Oral treatment with chlindamycin in racing pigeons. Proc Euro Assoc Avian Vet, 1991, pp 293-296.
- Davelaar FG, et al: Infectious typhlitis in chickens caused by spirochetes. *Avian Pathol* 15:247-258, 1986.
- Davis RW, et al: A preliminary study of thin bird disease. Proc Electron Micro Soc America, 1981, pp 602-603.
- Devriese LA, et al: *Streptococcus cesorum*, a new species isolated from chickens. *Int J Syst Bacteriol* 33:772-776, 1983.
- Devriese LA, et al: Streptococcal infections in pigeons. Proc 2nd Europe Symp Avian Med Surg, 1989, pp 113-117.
- Devriese LA, et al: *Enterococcus columbae*, a species from pigeon intestines. FEMS Microbiology Letters 71:247-252, 1990.
- Devriese LA, et al: *Streptococcus bovis* infections in pigeons. *Avian Pathol* 19:429-434, 1990.
- Devriese LA, et al: Tracheo-bronchitis in canaries: A respiratory condition caused by *Enterococcus faecalis*. *J Assoc Avian Vet* 4:113-116, 1990.
- Dorrestein GM, et al: Diseases of passerines, especially canaries and finches. Proc Assoc Avian Vet, 1983, p 62.
- Dorrestein GM, et al: Campylobacter infections in cage birds: clinical, pathological and bacteriological aspects. Proc Joint Meeting Vet Pathol, Utrecht, 1984.
- Dorbudak, et al: *In vitro* activity of clarithromycin against *M. avium*. 12th Conf Europ Soc Mycobac, Prague, 1991.
- Dwars FG, et al: Incidence of spirochetal infections in cases of intestinal disorder in chickens. *Avian Pathol* 18:591-595, 1989.
- Eichinger E: Lactobacillen zur Bekämpfung von Enterobacteriaceen im Darm von Psittaciformes. DVG VII. Tagung Vogelkrankheiten, München, 1990, pp 231-234.
- Forster F, et al: Mycobacteria in psittaciformes. Proc 1st Intl Conf Zool & Avian Med 39-56, 1987.
- Gerlach H: Diagnose der Pseudotuberkulose bei lebenden Vögeln. DVG-Tagung Krankh. der Vögel, München, 1979, pp 96-101.
- Gerlach H: Infection with the so-called *Haemophilus septicaemia anseris* in geese. Proc VIIth Intl Cong WVPA, 1981, p 80.
- Gerlach H: Bacterial diseases. In Harrison GJ, Harrison LR (eds): Clinical Avian Medicine and Surgery. Philadelphia, London, WB Saunders Co, 1986, p 434.
- Gerlach H: Going light in budgerigars. Proc Assoc Avian Vet, 1986, pp 247-250.
- Grazl-Köhler: Spezielle Pathologie und Therapie der Geflügelkrankheiten. Stuttgart, Ferdinand Enke Verlag, 1968, p 548.
- Grebe HH, et al: Vorkommen von Bakterien der Gattung *Haemophilus* bei verschiedenen Vogelarten. *Zbl Vet Med B* 22:749-757, 1975.
- Grimm F, et al: Die röntgenologische Darstellung von gastrointestinalen Läsionen beim Wellensittich verursacht durch Megabakterien. DVG VII. Tagung Vogelkrankheiten München, 1990, pp 321-325.
- Gylstorff I: In Gylstorff I, Grimm F: Vogelkrankheiten. Stuttgart, Verlag Eugen Ulmer, 1987, p 316.
- Heesemann J: Enteropathogene Yersinien: Pathogenitätsfaktoren und neue diagnostische Methoden. *Immun & Infekt* 18:186-191, 1990.
- Herck van H, et al: A bacterial proventriculitis in canaries (*Serinus canarius*). *Avian Pathol* 13:561-572, 1984.
- Hinz K-H: Über einige bakteriell bedingte Infektionen bei Zierund Wildvögeln. *Collegium veterinarium* 15:9-12, 1984.
- Karmali MA, et al: Taxonomy of the genus *Campylobacter*. In Butzler PJ (Hrsg) (ed): *Campylobacter* infection in man and animal. Boca Raton, CRC Press Inc, 1984, pp 1-20.
- Knorz W, et al: Zur Pathogenität von Listerien. *Immune Infect* 14:76-80, 1986.
- Koppers N, et al: Aviäre Mykobakteriose durch bisher nicht identifizierbare Stämme. *J Vet Med B* 38:3-10, 1991.
- Koppers N, et al: Mykobakteriose bei Waldkrähen (*Geronticus eremita*). *Berl Münch Tierärztl Wschr* 104:57-62, 1991.
- Korbel R: Epizootiologie, Klinik und Therapie der *Pasteurella multocida*-Infektion beim Vogelpatienten nach Katzenbiß. *Tierärztl Prax* 18:365-376, 1990.
- Korbel R: Ocular manifestations of systemic diseases in birds. Proc Europ Assoc Avian Vet, 1991, pp 157-167.
- Lauwers S et al: Campylobacter serotyping and epidemiology. *Lancet* 158-159, 1981.
- Lumeij JJ, et al: Observations on tuberculosis in raptors. In Cooper JE, Greenwood A (eds): Recent Advances in the Study of Raptor Diseases. Keighley, England, Chiron Publications Ltd, 1980, pp 137-139.
- McOrist S, Keece RL: Clostridial enteritis in free-living lorikeets, (*Trichoglossus* spp.). *Avian Pathol* 21:503-507, 1992.
- Mundt JO: Enterococci. In: Bergey's Manual of Systematic Bacteriology Vol 2, Baltimore, London, Los Angeles, Sydney, Williams and Wilkins, 1986.
- Nairn ME: Bacterial osteomyelitis and synovitis of the turkey. *Avian Dis* 17:504-517, 1973.
- Ochsenhirt B: Lokalisation von *Salmonella typhimurium* im Hühnerembryo nach experimenteller Einfeldinfektion. *Diss med vet, München*, 1974.
- Paterson JS, et al: A method for the recovery of *Pasteurella pseudotuberculosis* from faeces. *J Path Bact* 85:241-242, 1963.
- Piechulla K, et al: Phenotypic and genetic relationships of so-called *Moraxella (Pasteurella) anatipestifer* to the Flavobacterium/Cytophaga group. *Vet Microbiol* 11:261-270, 1986.
- Pulverer G, et al: Coagulase-negative staphylococci. *Zbl Bakt Hyg A(264)*:1-28, 1987.
- Riedel B, et al: Untersuchungen über das Vorkommen von Campylobacter im Kot von im menschlichen Wohnbereich gehaltenen Vögeln. *Berl Münch Tierärztl Wschr* 100:52-59, 1987.
- Rinaldi, et al: Episodi di streptococosi dell'anatra. *Atti della Società Italiana della Scienze Veterinarie* 24:665-666, 1970.
- Scanlan CM, et al: Characterization of a gram-positive bacterium from the proventriculus of budgerigars (*Melopsittacus undulatus*). *Avian Dis* 34:779-786, 1990.
- Schleifer KH: Transfer of *Streptococcus faecalis* and *Streptococcus faecium* to the genus *Enterococcus* nom. rev. as *Enterococcus faecalis* comb. nov. and *Enterococcus faecium* comb. nov. *Int J Syst Bacteriol* 43:31-34, 1984.
- Schröder H-D: Beitrag zu den Infektionskrankheiten der Zoo- und Wildvögel. IV. DVG-Tagung Vogelkrhrt, München, 1985, pp 173-174.
- Sinn LC: Listeriosis in birds. Proc Assoc Avian Vet, 1988, pp 189-190.
- Skirrow MB: Campylobacter enteritis: A "new" disease. *Br Med J* 2:9-11, 1977.
- Small PJ: Spirochetosis on a California pheasant ranch: A case report. Proc 33rd West Poultry Dis Conf, 1984, p 31-33.
- Smit EK, et al: Avian tuberculosis in wild birds in the Netherlands. *J Wildlife Dis* 23:485-487, 1987.
- Smit JA, et al: Necrotic enteritis and colitis in rattle birds. Proc 40th West Poultry Dis Conf, 1991, pp 258-260.
- Stoll L: Kälteanreicherung von Yersinia pseudotuberculosis zum Nachweis aus Untersuchungsmaterial. (Vortrag, 1966) ref *Zbl Hyg Bakt I* ref 206:534, 1967.
- Thorel M-F, et al: Numerical taxonomy of mycobactin-dependent mycobacteria, emended description of *Mycobacterium avium*, and description of *Mycobacterium avium* subsp. *avium* subsp. nov., *Mycobacterium avium* subsp. *paratuberculosis* subsp. nov., and *Mycobacterium avium* subsp. *silvaticum* subsp. nov. *Int J Syst Bacteriol* 40:254-260, 1990.
- Woerpel RW, et al: Retro-orbital *Mycobacterium tuberculosis* infection in a yellow-naped Amazon parrot (*Amazona ochrocephala aurohalliata*). Proc Assoc Avian Vet, 1983, pp 71-76.
- Wolinsky E, et al: Proposed numbering scheme for mycobacterial serotypes by agglutination. *Int J Syst Bacteriol* 23:182-183, 1973.
- Woods LW, et al: Summary and review of diagnostic observations of pet/exotic bird cases at the veterinary laboratory services in Petaluma. Proc 36th West Poultry Dis Conf, 1987, pp 124-127.

CHAPTER

# 34

## CHLAMYDIA

■  
Helga Gerlach

**T**he genus *Chlamydia* currently consists of two antigenically related species, *C. trachomatis* and *C. pneumoniae*,<sup>22</sup> which are restricted to humans, and *C. psittaci*, which has a wide host spectrum among birds (most Psittaciformes and at least 130 non-Psittaciformes), mammals (horse, cattle, sheep, roebuck, domesticated cat, guinea pig, dog) and humans.<sup>4</sup> *C. psittaci* can be highly contagious and induces a disease called psittacosis in parrots and ornithosis (by legal definition) in all other animals and man. Because the same agent is involved, the use of the term chlamydiosis to describe infections caused by this organism should be encouraged. Chlamydiosis is a reportable disease in many countries.

*C. psittaci* is an obligate intracellular bacterial parasite that contains DNA and RNA and has a rudimentary cellular wall that does not contain muramic acid or peptidoglycan.<sup>43</sup> This organism is capable of autonomous synthesis of species-specific enzymes, but depends on the host cell for energy (by means of adenosine triphosphate and nicotinamide adenosine diphosphate) and probably some amino acids, particularly tryptophan.<sup>57</sup> These requirements prevent chlamydia from growing on cell-free media.<sup>19,23,27</sup>

### Chlamydia Replication Cycle

Figure 34.1 illustrates steps in the replication cycle of the chlamydial organism.

**Step 1.** The first step in replication is the attachment to and penetration of a target cell (mainly columnar epithelial cells of mucous membranes and mononuclear macrophages) by the infectious-toxic but non-propagating elementary bodies (approximately 0.3  $\mu\text{m}$ ). The process is comparable to receptor-mediated endocytosis.<sup>57</sup> The chlamydia is enveloped in an endocytosomal vesicle where it remains throughout the replication cycle. By remaining in an endosome, the chlamydia is protected from host-derived lysozymes. The development of a phagolysosome (which would destroy the engulfed organism) is inhibited by chlamydial-derived proteins.<sup>24</sup>

**Step 2.** The second phase of replication is the transition of the metabolically inert elementary body into the large (0.5 to 1.5  $\mu\text{m}$ ), fragile, low density, metabolically active reticulate body. This phase of the replication cycle probably begins with the reduction of the disulfide bond that cross links the outer membrane proteins. The developing reticulate bodies possess several surface projections that are assumed to protrude through the endosomal membrane to enable the uptake of nutrients from the host cytoplasm.<sup>57</sup> In other respects, the reticulate bodies resemble bacterial L-forms (which have defective cell walls), because they can persist in spite of circulating antibodies and therapeutics designed to inhibit cellular wall formation.

**Step 3.** The growth and binary fission of the reticulate bodies result in the production of many progeny and micro-colonies containing from 100 to 500 chlamydial organisms per cell. Multiple micro-colonies, also called "inclusions" (Levinthal-Cole-Lillie = LCL bodies) can occur in an infected cell. By the end of the replication cycle, enzymes produced by the intracellular parasite may induce lysis of the host cell (48 hours after the initial infection). These enzymes are susceptible to antibiotics. Endotoxemia may occur in the host cell when lysosomes are destroyed and endosomal enzymes are released into the cytoplasm.

**Step 4.** Maturation of the noninfectious reticulate bodies into infectious elementary bodies involves the restoration of the surface membrane and its associated toxicity. Chlamydia-specific lipopolysaccharide is brought to the host cell surface concomitantly with the growth of chlamydial organisms.<sup>46</sup> This glycolipid is assumed to reduce the fluidity of the plasma mem-

brane, thereby protecting the chlamydial-infected cells from cytotoxic T-cells.<sup>57</sup>

**Step 5.** Newly formed elementary bodies are released, not always by lysis of the host cell.

#### Serovars

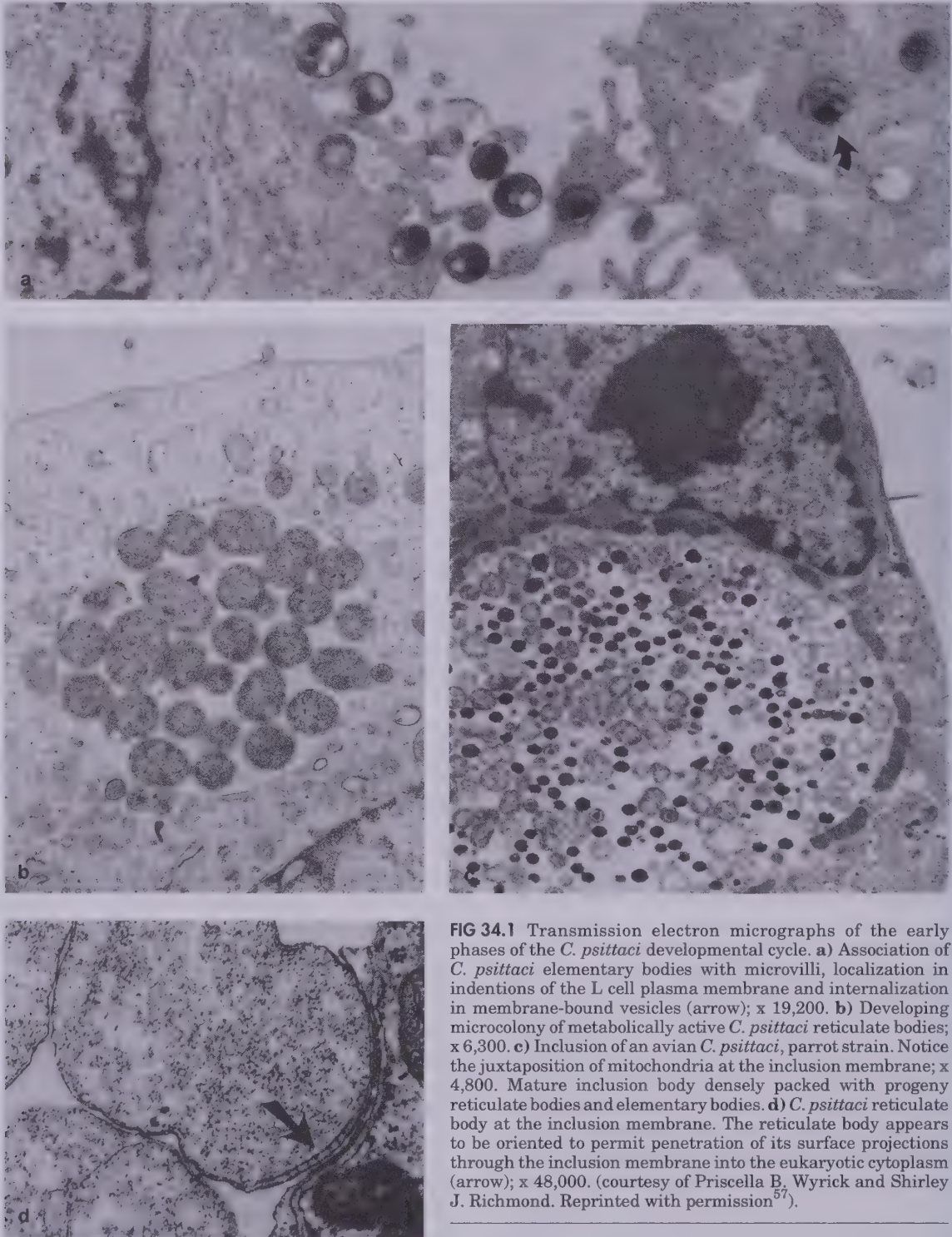
*C. psittaci* strains vary considerably in terms of virulence and antigenicity. In addition, five serovars have been distinguished among the avian strains by using monoclonal antibodies: psittacine, pigeon I, duck, turkey and pigeon II.<sup>54</sup>

Whether or not the parrot serovar and turkey serovar are really of particular importance as zoonotic agents<sup>2</sup> is a matter of controversy. It has been found that the different serovars do not only occur in the named avian species but also in a variety of other host species. Virulent strains replicate more rapidly and enjoy a wider host spectrum. Chlamydia has a genus-specific lipoglycoprotein with an acid polysaccharide as the antigenic determinant (thermostable at 100°C for 30 minutes). Several proteinaceous antigens, including the major outer membrane protein, can show subspecies or even strain-specific variability.<sup>23</sup> Antibodies generated against most of the antigens are not correlated with protective immunity.<sup>23</sup>

#### Pathogenicity

The pathogenicity of chlamydia cannot be fully explained by the direct damage to the host cells. The most important virulence factor is a toxin, which occurs with various degrees of intensity in the different strains and is closely bound to the outer membrane of the elementary bodies. During chlamydial growth in a particular avian host, metabolic and structural changes occur that can alter its pathogenicity and antigenicity. The degree of change is governed by the number of passages in a particular species. The surface of the elementary bodies that are formed during the replication cycle contains heterogeneous "new" antigens, which are assumed to be host-specific.<sup>1</sup> Interspecies transfer (eg, in quarantine stations, breeding farms, multispecies aviaries, pet shops) of chlamydia can change the physicochemical properties and, therefore, the antigenic composition, the toxic components and, in terms of virulence, the host spectrum of the agent.<sup>27</sup> However, the newly acquired characteristics are not truly stable.

The outcome of an infection is dependent on the ratio of elementary bodies to macrophages. Lethal lytic reactions occur in phagocytes infected with high



**FIG 34.1** Transmission electron micrographs of the early phases of the *C. psittaci* developmental cycle. **a**) Association of *C. psittaci* elementary bodies with microvilli, localization in indentions of the L cell plasma membrane and internalization in membrane-bound vesicles (arrow); x 19,200. **b**) Developing microcolony of metabolically active *C. psittaci* reticulate bodies; x 6,300. **c**) Inclusion of an avian *C. psittaci*, parrot strain. Notice the juxtaposition of mitochondria at the inclusion membrane; x 4,800. Mature inclusion body densely packed with progeny reticulate bodies and elementary bodies. **d**) *C. psittaci* reticulate body at the inclusion membrane. The reticulate body appears to be oriented to permit penetration of its surface projections through the inclusion membrane into the eukaryotic cytoplasm (arrow); x 48,000. (courtesy of Priscella B. Wyrick and Shirley J. Richmond. Reprinted with permission<sup>57</sup>).

numbers of virulent chlamydial particles. Low doses of a virulent strain are rapidly inactivated by mononuclear and polymorphonuclear phagocytes. If the macrophage is damaged, the chances of the chlamydial organism to survive are reduced. Low doses of a nonvirulent strain do not stimulate an appropriate lytic reaction, resulting in macrophages that are converted into long-lived epithelioid cells that remain chronically infected (see Chapter 5). The life span of these epithelioid cells should govern the duration of antibiotic treatment. However, nothing is known about the longevity of these transformed cells in birds.<sup>19</sup> It is a high probability that infected macrophages transfer their "inclusions" during mitosis in the bone marrow onto the progeny cells.<sup>57</sup> Life-long carriers may be the result. Incomplete autosterilization and phagocytosis into "new" macrophages favor the selection of strains with low virulence for the species in question. These chronic infections favor shedding of large numbers of chlamydia that might be highly virulent for other avian species.<sup>19</sup>

### Stability of Chlamydia

The infectious elementary bodies, which can be stained as described by Giemsa, Gimenez, Stamp, Macchiavello or Castaneda, can survive outside the host (protected by proteinaceous material) and inside host cells for several weeks (see Color 10). Bacterial-induced destruction of tissues and the presence of feces rapidly inactivate the organism. "Free" elementary bodies are relatively unstable and can be inactivated in the environment within days. Chlamydia is particularly sensitive to heat and one percent formalin if the temperature is above 20°C. Quaternary ammonium compounds and lipid solvents are poor choices for inactivating chlamydia. Infectivity has been shown to be destroyed within minutes by benzalkonium chloride.<sup>23</sup> In Europe, Orbivet™ and hydrogen peroxide have been shown to be effective against chlamydia.

*C. psittaci* is endemic worldwide, where it is distributed liberally among free-ranging birds. As a rule, the organism is well adapted to avian hosts and causes few, if any, clinical signs or pathologic lesions. Clinical disease is precipitated mainly by human-induced conditions and procedures. Systematic testing using modern laboratory methods (various versions of the ELISA) has not been performed on free-ranging birds to determine the incidence or prevalence of infections. However, surveys of imported and domestically bred Psittaciformes as well as free-ranging and captive raptors and owls from Germany indicate

that between 30 and 70% of the birds tested are infected.<sup>12,13</sup>

### Transmission

Elementary bodies present in feather dust and dried feces are primarily dispersed through air circulation. Ingestion of elementary bodies results in infection of the intestinal epithelial cells. Vertical transmission through the egg has been documented in domesticated ducks,<sup>32,47</sup> Black-headed Gulls<sup>32</sup> and budgerigars,<sup>44</sup> and has been suggested in turkeys. Chlamydia can usually be detected in the feces ten days prior to the onset of clinical signs. High numbers of chlamydia can be found regularly or intermittently in the feces (up to 10<sup>5</sup> infectious units per gram of feces), urine, lacrimal fluid, nasal discharge, mucous from the oral and pharyngeal cavities and "crop milk" (pigeons) of infected birds. Insufficient information is available to establish the periods during which birds with clinical disease or carriers can transmit the organism.

Cockatiels are frequent carriers of chlamydia and can shed the agent in the feces for more than one year following an active infection. Infected ducks have been shown to shed chlamydia in the feces for 100 days, and harbor the organism on the nasal mucosa for 170 days. It has been suggested that birds may become subclinical carriers and cease shedding within 30 to 50 days of the initial infection; however, this theory cannot be substantiated using improved methods of chlamydial detection.<sup>13</sup> In any case, carriers may begin to shed the organism following a stressful event. Assumed spontaneous self-elimination of infections within a flock during a four- to five-month period cannot be confirmed. Transmission by hemophagous insects or mites is possible.

Some species like dogs, cats, horses, swine and man develop infections that do not seem to be transmissible to other members of the same species. In contrast, infected birds, cattle, sheep and goats readily transmit chlamydia to other members of the same species. A newly imported Amazon parrot with chlamydiosis was thought to have infected a cat that was restricted to the house (Harrison GJ, unpublished).

### Pathogenesis

There are considerable differences between the susceptibility of various host species to chlamydia. The same strain can cause disease in different avian species, which can be distinguished by the number and

type of affected tissues and replication rate as determined by the period necessary for elementary bodies to appear. Similar differences are described with varying chlamydial strains in the same host species.<sup>33</sup> Young birds are generally more susceptible to infections than adults. Macaws and Amazon parrots appear to be more susceptible than Psittaciformes from South Asia, Australia and related islands (eg, cockatoos, lorries, King Parrots). The African parrots are even less susceptible than the Asian Psittaciformes. These are generalizations with many exceptions, and the condition of a host is probably more important than any species-specific susceptibility (Figure 34.2). *C. psittaci* can cause a totally asymptomatic infection in mature hosts or acute, systemic, often fatal illness in young birds or with nonhost-adapted chlamydial strains. The precondition for such an adaptation is a latent infection of some time period. The virulence and toxicity of host-adapted strains can be most dramatic when they infect a different species.<sup>19,28</sup>

The virulence, antigenicity and biologic properties of chlamydial strains vary. The surface of the elementary bodies contains hepatotoxic and nephrotoxic components that disappear once the organism enters the host cell. The toxins are once again a factor following replication and release of progeny elementary bodies from the host cell. These toxins present on the elementary bodies induce the production of antibodies that neutralize the toxins and destroy infectivity. These toxins have not been isolated and characterized, but they are believed to be related to the few proteinaceous-specific membrane antigens of the intact elementary body. These proteins have low antigenicity.<sup>28</sup>

The outcome of an infection is determined by the mononuclear macrophages. If an elementary body is phagocytized and is not coated with opsonins, the organism can survive and replicate within the macrophage.<sup>31</sup> Lymphokines secreted by activated lymphocytes inhibit the replication of chlamydia found in phagosomes. In order to maintain inhibitory concentrations, the lymphokines must be continuously secreted. During persistent infection, chlamydia remain within a membrane-bound compartment and release infectious progeny and antigens via exocytosis. It is therefore difficult for the host to remove the microorganisms from an infected cell.<sup>5</sup> In addition, exocytosed antigens released from the cells may not be processed in a way that can be recognized by class I-restricted cytotoxic T-lymphocytes. This allows infection, and probably reinfection, to occur and be

maintained in the presence of high levels of humoral antibodies.<sup>57</sup>

These interactions of the host immune system and the intracellular parasite cause the varied incubation times, clinical signs and pathology noted with chlamydial infections.<sup>33</sup> When virulent strains of chlamydia are inhaled, primary propagation occurs within the epithelial cells of the lung and air sacs. Direct spread of the organism from the air sacs to adjacent serosal membranes can lead to polyserositis, including pericarditis.<sup>38</sup>

If chlamydia organisms are ingested, they are believed to initially replicate mainly within the intestinal tract. Given the high number of birds with antibodies to chlamydia, most primary infections must occur without the development of obvious clinical signs. Birds may be fully susceptible following survival of a clinical disease. The amount of antitoxic antibodies seems too low to induce some immunity. It is uncertain if a latent infection prevents another chlamydial strain from entering the host.



**FIG 34.2** A five-year-old African Grey Parrot was presented with a 12-day history of progressive upper respiratory disease, polyuria (biliverdinuria), diarrhea and anorexia. On presentation, the bird had a severe rhinitis, conjunctivitis, severe dyspnea and emaciation (275 g). Clinical pathology findings included WBC=35,000, AST=1800, CPK=550 and LDH=1400. Chlamydia antigen was detected in the feces and on a pharyngeal swab by antigen-capture ELISA. The client had an upper respiratory disease and flu-like symptoms. The bird improved the day after receiving an IV injection of Vibravenos and was switched to oral doxycycline. African Grey Parrots are generally considered resistant to chlamydiosis, but as indicated by this case, under some conditions they can become sick.



### Incubation Period

Incubation periods for chlamydia are difficult to determine because of differences in strain virulence, varying clinical responses of a wide avian host range and the lifelong infections that can occur in some hosts. The minimum incubation period for naturally infected Psittaciformes is 42 days.<sup>42</sup> An incubation period of seven years was suggested for budgerigars.<sup>48,51</sup>

### Clinical Disease and Pathology

The clinical progression of infections varies with the virulence of the infecting strain and the host species. Asymptomatic infections are characteristic in adult birds exposed to moderate numbers of a moderately virulent strain of chlamydia. These infected birds may shed the organism for several months while remaining asymptomatic. Extreme environmental changes or concurrent infections may activate persistent infections, resulting in the occurrence of clinical disease. Epizootologically, outbreaks in offspring from asymptotically infected parents and young birds to which they are exposed are common.

#### Clinical Signs

Young birds exposed to high doses of a virulent strain develop acute systemic infections frequently resulting in death. Clinical signs can include rough plumage, low body temperature, tremor, lethargy, conjunctivitis, dyspnea, rales, coryza (pigeons) and sinusitis (budgerigars). Emaciation, dehydration, yellowish-to-greenish droppings (suggesting liver involvement), or grayish, watery droppings may also be noted (see Color 8). Death ensues within 8 to 14 days. Spontaneous recovery is rare. Survivors may have poorly formed feathers. Table 34.1 lists the typical clinical pathology changes associated with a symptomatic chlamydial infection.

Subacute or protracted diseases are typical for all avian species with a reduced susceptibility or for those infected with a moderately virulent strain. Progressive emaciation, greenish diarrhea, occasional conjunctivitis and high levels of urates in the droppings are common. Clinical signs may be subtle and overlooked. Psittaciformes occasionally develop CNS signs, including paroxysmal or continuous clonic-tonic convulsions, tremors and opisthotonos. Untreated birds die within a few weeks. In the cockatiel and the Houbara Bustard, incapacitating flaccid paresis and paralysis have been described.

TABLE 34.1 Clinical Pathology Findings Associated with Chlamydiosis<sup>41</sup>

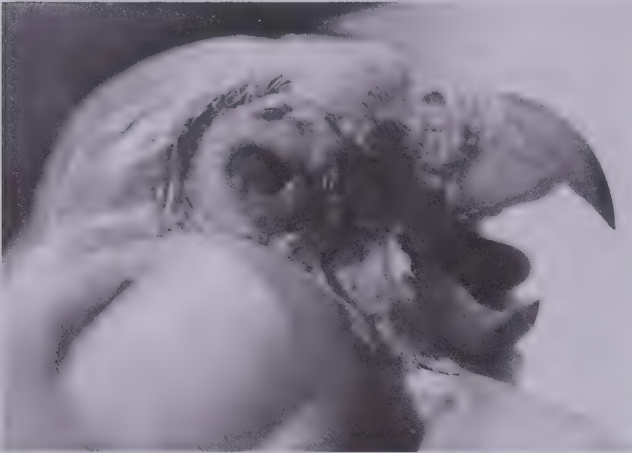Parameter	Change
WBC	Elevated (2 to 3 times normal)
Hct	Decreased (20 to 30%)
Heterophils	Normal
Lymphocytes	Decreased to normal
Monocytes	Normal
Eosinophils	Normal
Basophils	Normal
SGOT	Elevated (> 3 times normal)
CPK	Elevated (> 2 times normal)
LDH	Elevated (> 2 times normal)
AST	Elevated (> 3 times normal)
Total protein	Slight increase
Uric acid	Normal
Bile acids	Elevated (> 2 times normal)

A distinct, sometimes recurrent, keratoconjunctivitis with no other, or only subtle, signs has been described for small Australian parakeets (especially in the genus *Neophema*), pigeons, ducks, and European finches (Figure 34.3). Diseases in *Neophema* spp. are frequently refractory to therapy. Conjunctivitis and nasal discharge are characteristic of chlamydiosis in domestic pigeons. Mortality rates of the ophthalmic form are about 10%, but can reach 100% if untreated.<sup>19,27</sup> Conjunctivitis may be the predominant clinical sign in infected domestic ducks and geese. Mortality, particularly in ducklings, can range between 10 to 80%.<sup>52</sup>

Chlamydiosis in ratites can cause clinical and pathologic lesions of a rather nonspecific type. High mortality has been reported in ostrich chicks infected with *C. psittaci*.<sup>23,45</sup> The chronic course is clinically inconspicuous, although anemia is common and LDH and AST levels may be increased five to ten times. Birds with persistent infections may not be recognized until they infect other animals or their caretakers. The documentation of infections in nestlings from an apparently healthy breeding pair is also suggestive of latently infected adults.

#### Gross Lesions

Gross lesions can vary as widely as the clinical disease. Acute lesions are characterized by hepatomegaly, fibrinous peritonitis, air sacculitis, perihepatitis, pericarditis, bronchopneumonia, enteritis and nephrosis. Miliary necrosis of parenchymal organs is common, probably due to the effects of chlamydial toxins. Splenomegaly is frequently discussed



**FIG 34.3** A two-year-old cockatiel was presented for severe epiphora and conjunctivitis of two days' duration. A conjunctival scraping revealed a mixed population of gram-positive cocci and a few gram-negative rods. Gimenez staining was negative for chlamydia. The patient responded to treatment with tetracycline ophthalmic solution. Chlamydia is frequently implicated in conjunctivitis in cockatiels.

as a common finding in chlamydiosis (Figure 34.4). However, fibrinous air sacculitis is more indicative of chlamydiosis in Psittaciformes and pigeons (see Figure 12.52).

Splenomegaly may not occur with chlamydiosis at all. In sexually active males, chlamydial-induced orchitis or epididymitis results in permanent infertility. Oophoritis is rare.

Subacute to chronic lesions are characterized by anemia caused by a panmyelopathy in the bone marrow and tissue deficiencies of heterophils and macrophages.<sup>19,27</sup> The pathogenesis of the panmyelopathy is undetermined. Chronic cases are characterized by proliferation of connective tissue (up to cirrhosis) in the liver and kidney. Pancreatic necrosis has been described particularly in budgerigars and pigeons.

### Histopathology

Histopathologic findings are mostly nonspecific except for the presence of LCL bodies, which are pathognomonic. LCL bodies can occur in many organs but are especially common in serosal membranes. Typical of more acute disease is the intrasinusoidal proliferation of Kupffer's star cells (pearl string-like appearance) in the liver. Proliferation of monocytes and activation of the RES may occur in parenchymal organs, particularly the spleen, liver and kidney. Epithelioid cell granulomas in the liver and pneumonia with proliferations of epithelial cells in the air capillaries are common with chronic cases.

Swollen epithelial cells may be vacuolated, and immigration of lymphocytes into the damaged tissue can be seen. CNS lesions consist of nonpurulent meningitis. Secondary bacterial, fungal or viral infections may alter lesions and confuse chlamydial changes.<sup>19,20,27</sup>

### Differential Diagnosis

The clinical and pathologic presentation of chlamydiosis is so variable that it can normally be ruled out only with laboratory investigations. The more common rule-outs include infections with herpesvirus, paramyxovirus, influenza A virus and Enterobacteriaceae, particularly salmonellosis. The CNS signs should be differentiated from Newcastle disease and salmonellosis, and the conjunctivitis in ducklings and goslings from influenza A infections and mycoplasmosis.

## Diagnosis of Chlamydiosis

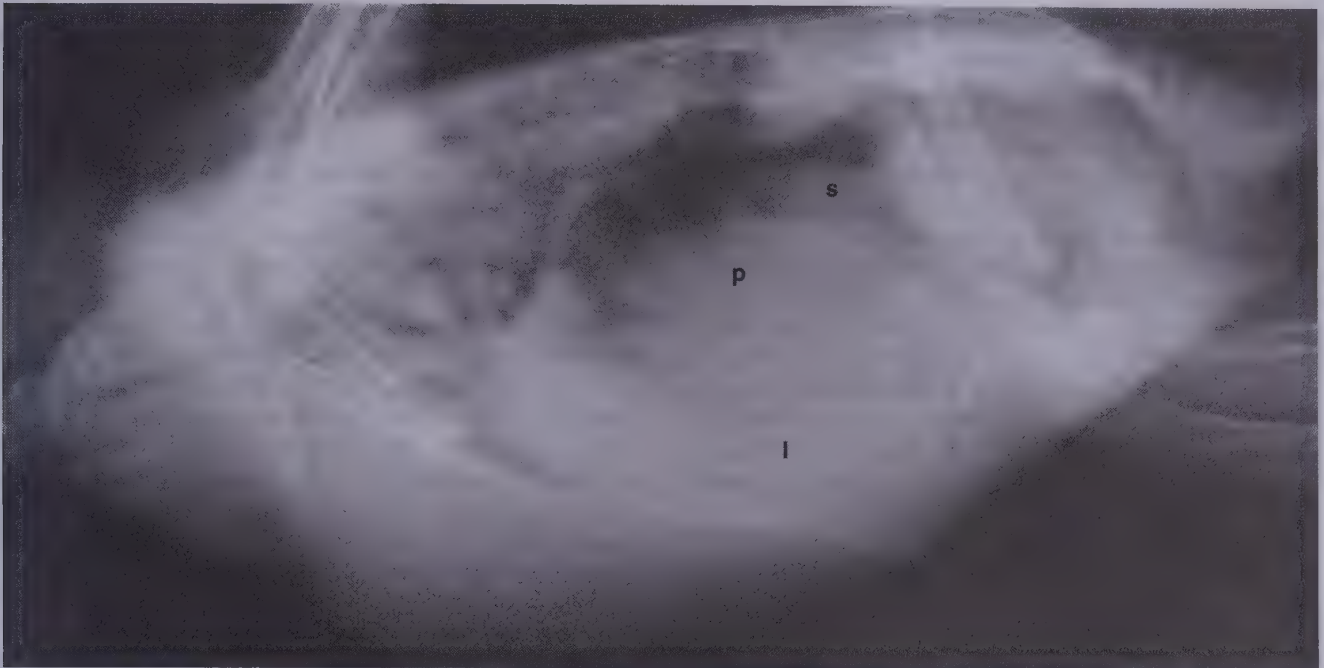
### Diagnostic Methods

#### Cytology

Conjunctival smears of birds with conjunctivitis can be stained for LCL bodies (see Color 10). As a rule, smears contain heterophils, some lymphocytes, some plasma cells and occasionally macrophage-like cells containing intracytoplasmic LCL bodies. Preparations containing numerous cells provide the greatest likelihood of a positive diagnosis. Since LCL bodies are difficult to detect, a positive test is confirmatory while a negative smear does not rule out chlamydiosis. Immunofluorescent methods using commercially available conjugates<sup>a</sup> are more sensitive. Every veterinary hospital should be able to perform cytologic evaluation of imprint slides including postmortem samples of the liver, spleen and air sacs (see Chapter 10). Other diagnostic methods require a specialized laboratory.

#### Culture

Culture of chlamydia is routinely performed in McCoy cell line, Buffalo Green Monkey cells or chicken embryo fibroblasts.<sup>16</sup> Cell culture is sensitive and able to detect small numbers of chlamydia within two to three passages. For isolation, parenchymal organs (liver, spleen, lungs, kidneys,) and feces should be shipped in transport medium (glucose 74.6 g/l,



**FIG 34.4** A mature Amazon parrot was presented with biliverdinuria, diarrhea, dyspnea and anorexia of four days' duration. The bird had been obtained from a "bird farm" about six weeks earlier. Radiographic findings included hepatomegaly (l) and splenomegaly (s). The enlarged liver is displacing the proventriculus (p) and the spleen dorsally. The bird responded to oral doxycycline and improved 12-16 hours after the initial dose.

$K_2HPO_4$  1.237 g/l, L glutamic acid 0.721 g/l, 10% fetal calf serum, vancomycin and streptomycin 100  $\mu$ g/ml, gentamicin and nystatin 50  $\mu$ g/ml).<sup>50</sup> Sucrose albumin phosphate solution (pH 7.2) cooled to 4°C is an effective storage and transport medium for feces. Fecal samples and tissue samples contaminated with feces are cleaned by labor-intensive centrifugation. The first passage takes up to six days, the second and third passages require three days each, so that three passages require approximately two weeks. Culture is the only way to directly demonstrate *Chlamydia psittaci*.

#### Antigen Detection Systems

Highly sensitive and specific ELISA test systems are available for detecting chlamydial antigen or anti-chlamydial antibodies (Table 34.2). An antigen test kit developed for human *C. trachomatis* has been used successfully for *Chlamydia psittaci*, which has the same group-specific antigens. Comparisons between this test kit and cell culture indicated that false-negative results occurred with ELISA when insufficient numbers of chlamydial particles (less than 2.5 ng<sup>3,53</sup> [600 elementary bodies]) were present in the sample. False-negative cell culture results occurred when chlamydial organisms were no longer viable.<sup>14,15,34</sup>

Culture results were poorest with fecal samples that were desiccated, subjected to bacterial deterioration or contaminated with litter or other "foreign" materials. The sensitivity was 84.2 % for ELISA and 80% for cell culture when a cloacal swab shipped in transport medium was used for testing instead of feces.<sup>13</sup> In evaluating 7,000 cloacal swabs for the diagnosis of chlamydiosis, it was determined that the antigen ELISA is sensitive, quick to perform (results in four hours) and can be made noninfectious for laboratory staff by heating at 100°C for 15 minutes. Cloacal

#### CLINICAL APPLICATIONS

- Interspecies transfer of chlamydia (in quarantine stations, breeding farms, multispecies aviaries, pet shops) can change the physicochemical properties, antigenic composition, toxic components and the host spectrum of the organism.
- Surveys indicate that between 30 and 70% of the birds tested have anti-chlamydial antibodies. Clinical disease is precipitated mainly by human-induced conditions and procedures.
- Chlamydia can usually be detected in the feces ten days prior to the onset of clinical signs.
- Carriers may begin to shed the organism following a stressful event.
- Antibody production with an active infection may be poor, and birds that survive infection are fully susceptible to disease.

swabs, not fecal samples, should be used for testing. The former does not require a centrifugation step and probably contains a higher concentration of chlamydial organisms (possibly in cloacal mucosa cells).<sup>12</sup>

Extremely high concentrations of avian *Staphylococcus aureus* (more than  $10^8$ ,<sup>51</sup> or more than  $1.5 \times 10^9$ /ml suspension<sup>3</sup>) can cause false-positive ELISA results.<sup>53</sup> *Actinobacillus salpingitidis*, which is rarely found in feces,<sup>3</sup> and *Acinetobacter calcoaceticum*<sup>53</sup> can also cause false-positive results. *Staphylococcus hyicus*, a non-avian staphylococcus, has also been implicated in false-positive reactions.<sup>53</sup> False-negative results with the antigen ELISA may occur because of the irregularity of antigen shedding in latently or persistently infected birds.<sup>11,34,51</sup> Administration of several antibiotics including chloramphenicol, tylosin, erythromycin and tetracyclines can also interfere with the detection of chlamydia in cell culture.

#### Comparison of Antigen Capture Tests

The reproducibility of some latex agglutination tests has been poor.<sup>3</sup> The latex agglutination test Clearview Chlamydia (CC)<sup>b</sup> used for the diagnosis of *Chlamydia trachomatis* by means of cervical epithelial cells can be easily performed in the veterinary hospital.<sup>3</sup> The CC test was found to be more sensitive (detected 130 elementary bodies/ml) than the IDEA<sup>c</sup> test (required 600 elementary bodies/ml of sample). However, the CC test is unsuitable for use with homogenized organs, fecal material or samples purified by centrifugation. When cloacal samples were collected and transported in tubes provided by the manufacturer, CC and IDEA agreed in 84.6% of the samples. Samples positive only with CC could not be confirmed positive by other methods (one exception). The CC test is more likely to have false positives as a result of bacterial contamination than is the IDEA test. Moderate to high numbers of a mixed bacterial flora, high numbers of *Staphylococcus aureus*, *Pasteurella multocida*, and *Sarcina* sp. can cause false-positive CC results.<sup>3</sup>

The Chlamydiazyme<sup>d</sup> test kit was compared with the IDEA for detection of chlamydial antigen.<sup>39</sup> Chlamydiazyme was found to be less sensitive, but was more likely to have false positives from nonspecific cross reactions (decreased specificity). These findings were confirmed by other testing, and the Chlamydiazyme test system was estimated to detect 312.5 pg (= 4,800 particles). False-positive results occurred with *A. calcoaceticus*, *S. aureus* and *S. hyicus*, *Legionella pneumophila*, *Bartonella bacilliformis*, *Corynebacterium*

*pyogenes*, *Pasteurella multocida* and *Enterococcus faecalis*.

The Surecell<sup>e</sup> ELISA test kit produced by Kodak is easy to use and can be performed in any hospital. Unfortunately, it, like other antigen detection tests that use antibodies, is plagued with false-positive results, probably due to cross-reacting bacteria. A recent study indicated that this test had a specificity of 80% and a sensitivity of 100% (compared to culture). Cross reactions were not found to occur with a variety of bacteria.<sup>37</sup> The minimum quantity of chlamydial material that the producer claims can be detected is 70 per gram. In some cases, birds may have chlamydiosis and are shedding insufficient numbers of organisms to be detected by an antigen capture system. The development and use of *C. psittaci*-specific DNA probes may prove to be the best method to detect birds that are actively shedding the organism.

TABLE 34.2 Antigen Detection Systems for Chlamydia

Diagnostic Test	Number of Elementary Bodies Detected	False positives (specificity)	False negatives (sensitivity)
IDEA <sup>c</sup>	600	+	+
Culture		None	
Clearview Chlamydia <sup>b</sup>	130	+++	+
Chlamydiazyme <sup>d</sup>	4800	+++	+
SureCell <sup>e</sup>	70	+	+

Specificity: Some bacteria will cross-react in antigen detection kits for chlamydia, creating false positives. ++ = some bacteria; +++ = many bacteria. Sensitivity: The sensitivity of any chlamydia antigen test is affected by the number of elementary bodies present. + = high sensitivity; ++ = lower sensitivity. Antigen detection systems are used to document shedding in clinically affected birds.

#### Antibody Tests

Detection of anti-chlamydial antibodies using complement fixation (CF) was proven to be unsuitable because birds produce mainly non-CF antibodies following a chlamydial infection.<sup>26,49</sup> The C1 of guinea pig complement, which is a critical component of the CF test, is incompatible with the serum of many avian species. A test that functions independent of the species in question was necessary for serologic diagnosis of chlamydiosis in the class Aves. An inhibitory ELISA (= BELISA) that recognizes four times more infected birds than CF has been developed.

The relationship between CF and BELISA indicates that high anti-chlamydial antibody titers detected by

CF and BELISA are indicative of a positive reaction; low titers are diagnostic only with BELISA.<sup>34</sup> Ten months following an experimental chlamydial infection, CF antibodies decrease considerably, while BELISA shows a continuous increase. This finding suggests that the composition of the antibodies detected varies<sup>49</sup> and that only those antibodies detected by BELISA are stimulated by the permanent intracellular presence of chlamydia.

A comparison of antigen excretion and antibody status showed that flocks with clinically affected birds had higher antibody titers and excreted chlamydia at a higher rate than non-clinically affected flocks. A small number of birds with an extinction just beneath the cutoff and no demonstrable antibodies gave the reasons for a final correction of the cutoff value. BELISA is suitable for identifying infected birds, whether they excrete the agent or not.<sup>12</sup> A commercially available test kit using the principles of BELISA has been developed (*C. psittaci*-AK-EIA).<sup>f</sup> The antigen and antibody ELISA tests have been compared with cell culture and CF for the detection of chlamydia in thousands of field cases.<sup>8,10,12,13,34</sup> False-negative results may occur with this test kit in fresh infections (no antibody production as yet), following treatment (inhibition of antibody production and no shedding of the agent), pre-test handling of the samples and cross reactions with bacteria.

The high sensitivity of BELISA has shown that *C. psittaci* antibodies are more widely distributed than previously thought. Sustained detection of antibodies by BELISA suggests that chlamydia may cause a life-long persistent infection, which is difficult to eliminate with treatment.<sup>7</sup>

## Treatment of Chlamydiosis

### Therapeutic Agents

Many countries have instigated governmental regulations for treatment and control of chlamydiosis to prevent zoonotic infections. The following therapeutic considerations address only the scientific aspects of treating chlamydiosis, and the reader should be aware of local laws governing therapy. Several antibiotics have *in vitro* activity against chlamydia, but only the tetracyclines and enrofloxacin have been used successfully *in vivo*, the latter only in limited trials.<sup>40</sup>

The tetracyclines alter the replication of chlamydia by inhibiting the synthesis of enzymes, the growth and fission of the reticulate bodies and possibly the reorganization of the elementary bodies. Antimicrobial-induced damage that occurs to the reticulate and elementary bodies may be temporary, with the organism resuming normal replication within 5.5 days of ceasing therapy. The host defense mechanisms must be intact to remove damaged chlamydial elements before they can recover and begin replicating.<sup>17</sup> Providing the immune system with the time necessary to remove these damaged reticulate and elementary bodies is one reason for long-term anti-chlamydia therapy.

Tetracyclines are effective only against actively metabolizing microorganisms, ie, during growth or fission. This drug is not effective in treating latently or persistently infected birds in which the chlamydia is located inertly in macrophages. The hypothesis that chlamydia is eliminated by the natural replacement of infected host cells (if treatment is continued for such prolonged periods) has not been confirmed using currently available diagnostic techniques.

Strains of chlamydia that are resistant to tetracyclines are still rather rare (one strain from ducks > 75 µg tetracycline),<sup>35</sup> but strains with reduced sensitivity continue to be recognized.<sup>18</sup> It has been shown that there is no direct correlation between the blood level of tetracyclines and therapeutic efficacy. Thus, the suggested blood level of >1 µg/ml cannot be assumed to equate with successful treatment. In some situations, subtherapeutic blood levels (<1 µg/ml) may be successful<sup>58</sup> while in other cases, full therapeutic levels do not resolve an infection.<sup>28</sup> These clinical experiences have been supported by laboratory testing.

The *in vitro* MIC for 12 *C. psittaci* strains ranged from 0.01 to 0.08 µg/ml, and 0.2 µg/ml completely inhibited the production of elementary bodies of 62 strains in cell culture. Varying dosages of antibiotics in owls resulted in almost equal plasma concentrations but different time periods of shedding the agent following the discontinuation of the treatment (high dosages shedding 4.5 months, low dosages 9.5 months until the end of the trial).<sup>11</sup> Some chlamydial strains can develop resistance to tetracycline if exposed to sub-therapeutic levels for prolonged periods of time.

In acutely sick birds chlamydial organisms undergoing rapid metabolism, and treatment with tetracyclines leads to immediate cessation of shedding and

a clinical recovery in accordance with the severity of the parenchymatous lesions. In these birds, elimination of *Chlamydia psittaci* is possible; however, under practical conditions, not likely. Nevertheless, treatment reduces the infectious pressure in the environment and, therefore, minimizes the risk of infection for humans and other animals. Birds with severe lesions may die, even if the agent is completely inactivated.

### Chlortetracycline

Chlortetracycline (CTC) for oral application can be administered in soft mixed feed (cooked grain with or without egg [yolk, albumen]), in commercial parrot pellets or on dehulled seeds covered with CTC. The latter is recommended (500 ppm) for budgerigars and small finches. Food containing 5,000 ppm of CTC is normally provided, although there are many avian species, particularly among the Psittaciformes, that reach effective blood levels with CTC concentrations of 2,000 to 2,500 ppm. Birds will generally consume more food when it contains a lower concentration of CTC. Birds that have been shown to do well with food containing lower concentrations of CTC are listed in Table 34.3.

Chlortetracycline is renally excreted and should be used cautiously in patients with kidney damage (see Chapter 17). Birds dislike eating medicated feed or pellets, and therapeutic blood levels are reached only within ten days. Because infected birds will continue to shed, the delayed induction of proper blood levels poses an additional risk for caretakers and for other birds. No other food components can be fed during the treatment period.

### Oxytetracycline

Intramuscular injections of oxytetracycline (OTC) at a dosage level of 100 mg/kg have been suggested. The birds listed in Table 34.3 should be given 75 mg/kg. Oxytetracycline (LA 200) produces a long-lasting blood level at a dose of 75-100 mg/kg body weight. Injections induce effective blood levels within hours, and the shedding of *Chlamydia psittaci* will stop 24 hours post-injection. This treatment regime also allows a bird to remain on its normal diet while being treated (see Chapter 18). OTC has the same side effects as CTC. In addition, severe muscle necrosis may occur at the site of injection.

### Doxycycline

Doxycycline is a preparation that has been developed for intravenous administration in humans. The solvents are different in doxycycline products manufactured in the United States and Europe. Intravenous

**TABLE 34.3** Birds That Respond to Lower Food Concentrations of CTC<sup>27,41</sup>

Large macaws	Eastern Rosella
Genus <i>Agapornis</i>	Pale-headed Rosella
Grey-cheeked Parakeet	Red-fronted Parakeet
Canary-winged Parakeet	Turquoise Parakeet
Red-winged Parrot	Scarlet-crested Parrot
Mulga Parrot	Bourke's Parrot
Western Rosella	Cockatiel

preparations available in the United States cause severe local necrosis of the muscles when given intramuscularly. European preparations may be safely given intramuscularly and induce blood levels of 1 µg/ml that last approximately seven days when administered at a dose of 75 to 100 mg/kg body weight. The quantity of drug to be injected is rather large, and several injection sites should be used.

During long-term treatment, which is still legally stipulated in many countries, the drug is increasingly eliminated from the blood so that injection intervals decrease. Some countries have regulations controlling the injection intervals, although these should vary according to the species. Doxycycline is excreted mainly extrarenally (feces, bile), and the metabolites are microbiologically almost inert. This treatment reduces the destruction of autogenous intestinal flora seen with other tetracyclines. A doxycycline-medicated food was found to provide >1 µg/ml plasma concentration in a group of psittacine birds (Table 34.4).

**TABLE 34.4** Doxycycline-medicated Food Diet<sup>\*41</sup>

29% canned cooked kidney beans
29% canned whole corn
29% cooked white rice
13% dry oatmeal cereal (by weight)
1000 mg doxycycline hyclate (from capsules) per kg of feed

\* Adapted from Flammer K, et al. Proc Assoc Avian Vet, 1991, pp 1-5. Medicated diets have been found to maintain acceptable plasma doxycycline concentrations in Goffin's Cockatoos, African Grey Parrots, Blue-fronted Amazon Parrots and Orange-winged Amazon Parrots.

An antimicrobial that can be added to the drinking water and effectively treat chlamydia in Psittaciformes remains elusive, but enrofloxacin has shown some potential. Birds in the USA with severe, acute chlamydiosis can be initially treated with an IV injection of Vibramycin, followed by oral doxycycline when the bird is stabilized (generally in 24 hours).

A micronized suspension of doxycycline has shown moderate promise in the treatment of chlamydia. In one study involving pigeons, IM administration of

micronized doxycycline (100 mg/kg body weight) three times at weekly intervals maintained a plasma level about 1 µg/ml for 43 days. (More research is planned to increase the doxycycline concentration from today's 66 mg/ml to 132 mg/ml and a prolonged plasma level accordingly.) There was no clinical evidence of pain or histologic lesions suggestive of necrosis associated with the injection site. Exercise would cause a sharp rise in the plasma doxycycline concentrations.<sup>6</sup>

Apart from specific treatment with tetracyclines, symptomatic therapy in acutely sick birds is frequently necessary. Birds should be kept isolated in warm rooms, and intravenous fluids, hepatoprotective therapy and paramunity inducers should be administered according to the clinical signs. Chicks should be fed frequently with small amounts of a liquid formula.

#### Enrofloxacin

Enrofloxacin inhibits the *in vitro* growth of *C. psittaci*, but only a few avian strains have been tested. The MIC of enrofloxacin for *C. psittaci* was found to be 0.125 mg/l; the minimum bactericidal concentration is much higher: 50 to 75 mg/l. Concentrations between 0.5 and 1.0 mg/l evoked irreversible damage to the majority of the chlamydia particles.<sup>40</sup>

Preliminary results indicate that treatment with enrofloxacin-medicated food for three weeks was effective in eliminating chlamydia from parakeets. Seven groups of experimentally infected budgerigars and other psittaciforme birds (Alexander Ring-necked Parakeet, Senegal Parrot, Canary-winged Parakeet) were effectively treated for 14 days with medicated food containing 500 ppm (budgerigars=250 ppm) enrofloxacin. From seven days after the beginning of treatment until four to five weeks after the end of treatment, no chlamydia could be isolated. Complete elimination of chlamydia from a quarantined group of 196 Senegal Parrots was reached only after substituting their normal mixed food with medicated corn containing 1000 ppm enrofloxacin.<sup>40</sup> A minimum blood level of 0.5 mg/l for enrofloxacin for at least 14 days was considered necessary to control chlamydiosis.<sup>36,40</sup>

#### Control

Persistent, probably life-long, infections require new ideas on control. Legal regulations should be reformulated and concentrate on clinically sick and seropositive birds. Seronegative birds should not be treated. During treatment and in clinically healthy

but infected flocks, regular cleaning and disinfecting programs will minimize the chlamydial contamination in the environment and reduce the occurrence of reinfection or transmission. Birds that recover from chlamydiosis are fully susceptible to future infections. Ideally, breeding birds would be seronegative for chlamydia but, given the prevalence of the organism as detected by antibody titers in the companion bird population, it seems unlikely that a seronegative population could be established. Free-ranging birds that may transmit chlamydia should not have access to aviary birds.

Vaccination programs for the control of chlamydiosis remain elusive because chlamydia effectively inhibit the host defense system (see pathogenesis). Subunit vaccines designed to inhibit or block the host membrane receptors could damage normal epithelial cells.<sup>53</sup> Although the group-specific antigen is common to almost all chlamydial strains, it does not elicit a protective response. The antigenic variability among the avian strains is large, so that polyvalent vaccines might be necessary.<sup>7</sup> Because cell-mediated immunity plays an important role in the host defense to chlamydia, vaccines may sensitize the host and initiate excessive host reactions and disease.

#### Zoonotic Potential

*C. psittaci* strains from Psittaciformes, domesticated ducks (in Europe) and turkeys (in USA) appear to cause the most severe disease in humans. It appears that the host animal in which chlamydial passage occurs prior to the human infection influences the pathogenicity of the agent for humans. The only reported case of human chlamydiosis from free-ranging birds involved the Northern Fulmar on the Faroe Islands.<sup>19</sup> Pigeon strains of chlamydia are considered less virulent for humans.

Human infections are characterized by flu-like clinical signs including a high fever, severe headaches, chills, shortness of breath and general debilitation. If untreated, atypical pneumonia or CNS signs mainly caused by meningitis can develop, in addition to liver and kidney lesions due to the presence of toxicity.<sup>52</sup>

In rare cases, neuritis with severe pain is described. Chronic manifestations can be arteritis, cardiovascular insufficiencies and thrombophlebitis including insufficiency of the venal valves. Treatment with doxycycline is recommended for three weeks. A four-fold increase in titer should not be expected to occur in humans being treated with tetracyclines, and diag-

nosis requires culture or detection of antigen in sputum (antigen ELISA). As in birds, the CF test is not sensitive enough for accurate diagnosis in humans. Serologic determinations with the antibody ELISA have shown that humans can also be carriers following treatment, and recrudescence is possible when strong stressors activate the agent.

Chlamydiosis is a reportable disease in the United States because of its potential as a zoonotic agent. Current regulations dictate closing a business or aviary, a forced quarantine period and treatment of all exposed birds with chlortetracycline-medicated

foods. These recommendations do not effectively address the problems associated with treating or controlling chlamydiosis and should be evaluated and modified accordingly.

## References and Suggested Reading

- Allen I, et al: Host modification of chlamydiae: Presence of an egg antigen on the surface of chlamydiae grown in the chick embryo. *J Gen Microbiol* 112:61-66, 1979.
- Andersen AA, et al: Genetic, immunologic, and pathologic characterization of avian chlamydial strains. *J Am Vet Med Assoc* 195:1512-1516, 1989.
- Biendl A: *Chlamydia psittaci* - Diagnostik bei Psittaciformes: Schnelltest zum Antikörpernachweis mittels Latex-Agglutination bzw. zum Antigen nachweis mittels eines kommerziellen Latextestes (Clearview Chlamydia®). *Vet Diss*, München, 1992.
- Brand CJ: Chlamydial infections in free living birds. *J Am Vet Med Assoc* 195:1531-1535, 1988.
- Byrue G, et al: Lymphokine mediated microbistatic mechanisms restrict *Chlamydia psittaci* growth in macrophages. *J Immunol* 128:469-473, 1982.
- Doolen M, et al: Determination of blood levels of a new form of doxycycline after intramuscular injection in the domestic pigeon. *Proc Europ Conf Avian Med & Surg*, 1993, pp 111-115.
- Dorrestein G: Chlamydiosis: A new approach in diagnosis and therapy. *Proc Assoc Avian Vet*, 1989, pp 29-37.
- Eibedenz CU: *Chlamydia psittaci* Diagnostik beim Vogel: Erreger-Nachweis mittels Zellkulturmethoden, Antikörper-Nachweis mittels KBR und ELISA. *Vet Diss*, Giessen, 1991.
- Flammer K: The biology of avian chlamydiosis: Know the enemy! *Proc Assoc Avian Vet Advanced Avian Seminar*, 1992, pp 1-8.
- Fudge AM: Clinical application of the Chlamydia ELISA procedure. VII. DVG Tagung Vogelkrrht, München 1990, pp 290-293.
- Gerbermann H, et al: Excretion of chlamydia and kinetics of the antibodies in owls (*Strigiformes*) treated with doxycycline. VIII. DVG Tagung Vogelkrrht, München, 1992, pp 130-153.
- Gerbermann H, et al: Chlamydiose bei Vögeln. Gegenwärtige Situation und Alternative der Diagnose und Bekämpfung. *Prakt Tierärz* 72:521-528, 1991.
- Gerbermann H, et al: Chlamydiebefunde aus einer größeren Greifvogelhaltung. *J vet med B* 37:739-748, 1990.
- Gerbermann H, et al: Current situation and alternatives for diagnosis and control of psittacosis in the Federal Republic of Germany. *J Am Vet Med Assoc* 195:1542-1547, 1989.
- Gerbermann H, et al: Infections with *Chlamydia psittaci*: Alternatives for diagnosis and control. *Proc Assoc Avian Vet*, 1988, pp 69-78.
- Gerbermann H, et al: Nachweis von *Chlamydia psittaci* in Zellkulturen - eine Alternative zum Mäuseinfektionsversuch für die Routinediagnostik. IV. DVG Tagung Vogelkrrht, München, 1985, pp 92-100.
- Gerbermann H, et al: Der Einfluß des Immunsystems auf die Abwehr einer Psittakoseinfektion. *Prakt Tierärz* 5:458-462, 1982.
- Gerbermann H: Die Wirksamkeit von Doxycyclin gegen *Chlamydia psittaci* bei der Maus. DVG Tagung Vogelkrrht, München, 1979, pp 31-42.
- Gerlach H: Chlamydia. In Harrison GJ, Harrison LR (eds): *Clinical Avian Medicine and Surgery*. Philadelphia, London, Toronto, WB Saunders Co, 1986, 457-463.
- Graham DL: Histopathologic lesions associated with chlamydiosis in psittacine birds. *J Am Vet Med Assoc* 195:1571-1573, 1989.
- Gratzl E, et al: Spezielle Pathologie und Therapie der Geflügelkrankheiten. Ferdinand Enke Verlag Stuttgart, 1968, pp 368.
- Grayston JT, et al: *Chlamydia pneumoniae* sp. nov. for *Chlamydia* sp. strain TWAR. *Internat J System Bact* 39:88-90, 1989.
- Grimes JE, et al: Chlamydiosis (ornithosis). In Calnek BW, et al (eds): *Diseases of Poultry* 9th Edition. Wolfe Publishing, 1991, pp 311-325.
- Grimes JE: Facts, comments, and concerns in understanding the detection of chlamydial infections. *J Assoc Avian Vet* 3(2):76-77, 1989.
- Grimes JE: Latex agglutination: A rapid serologic diagnostic aid for psittacine chlamydiosis. *Proc Assoc Avian Vet*, 1985, pp 215-247.
- Grimes JE: Direct complement fixation and isolation attempts for detecting *Chlamydia psittaci* infections of psittacine birds. *Avian Dis* 29:873-877, 1984.
- Gylstorff I: Chlamydiales. In Gylstorff I, Grimm F: *Vogelkrankheiten*. Verlag Eugen Ulmer Stuttgart, 1987, pp 317-322.
- Gylstorff I, et al: Vergleichende Untersuchungen zur Psittakosebekämpfung auf medikamenteller Basis. II. Mitteilung: Wirksamkeitsprüfung verschiedener Arzneimittel bei unterschiedlichen Applikationsformen bei experimentell infizierten Grünwangamazonen (*Amazona viridigenalis*). *Berl Münch Tierärztl Wschr* 97:91-99, 1984.
- Henning K: Felduntersuchungen zur Frage einer Resistenzbildung von *Chlamydia psittaci* gegen Doxycyclin (*Vibravenos*, Pfizer). IV DVG Tagung Vogelkrrht, München pp 124-131, 1985.
- Hoelzel J: Untersuchungen zur Verbreitung verschiedener Erkrankungen bei Brieftauben und deren Beziehungen zu Alter, Geschlecht, geographischer Herkunft und Jahreszeit sowie die Überprüfung zweier ELISA-Testsysteme auf ihre Verwendbarkeit in der Chlamydiendiagnostik bei Brieftauben. *Vet Diss*, Giessen, 1989.
- Idtse FS: Chlamydia and chlamydial diseases of cattle: A review of the literature. *Vet Med*, 1984, pp 543-550.
- Illner F: Zur Frage der Übertragung des Ornithosevirus durch das Ei. *Mh Vet Med* 17:116-117, 1962.
- Jakoby JR: Verlauf einer experimentellen Infektion mit *Chlamydia psittaci* bei Amazonen. II. DVG Tagung Vogelkrrht, München, 1981, pp 81-88.
- Janecek F: *Chlamydia psittaci* Diagnostik bei Psittaciformes: Vergleichende Untersuchungen zum Antigen nachweis in der Zellkultur und im ELISA sowie zum Antikörper nachweis in der Komplementbindungsreaktion und im Blocking ELISA. *Vet Diss München*, 1989.
- Johnson FWA, et al: Multiantibiotic resistance in *Chlamydia psittaci* from ducks. *Vet Rec* 112:208, 1983.
- Jung C: [Understanding the use and pharmacokinetics of enrofloxacin in budgies with an experimental infection of *Chlamydia psittaci*.] *Vet med Diss*, Giessen, 1992.
- Kingston RS: Evaluation of the Kodak SureCell chlamydia test kit in companion birds. *J Assoc Avian Vet* 6:155-157, 1992.
- Krauss H, Schmeer N: Aviäre Chlamydiose. In Heider, Monreal: *Krankheiten des Wirtschaftsgeflüßels* Bd II. Jena Stuttgart, Verlag Gustav Fischer, 1992, pp 282-283.
- Langhammer PRC: Vergleich von drei Nachweisverfahren für *Chlamydia psittaci* unabhängig vom Vermehrungsstadium in Abstrichen, Organ und Kotproben beim Vogel. *Vet Dis*, Giessen, 1989.
- Lindenstruth H: [Field study of budgies and various parrots using Baytril for prevention and therapy after importation.] *Vet med Diss*, Gießen, 1992.
- Mailison ET: Potential of a voluntary caged pet bird improvement program. *J Am Vet Med Assoc* 195:1535-1537, 1989.
- Meyer KF, et al: In Beaudette FR (ed): *Progress in Psittacosis Research and Control*. New Brunswick NJ, Rutgers University Press, 1958.
- Moulder JW: Chlamydiales. In Krieg NR (ed): *Bergey's Manual of Systematic Bacteriology* Vol 1. Baltimore, Williams & Wilkins, 1984, pp 729-739.
- Olson GH, et al: A review of some causes of death of avian embryos. *Proc Assoc Avian Vet*, 1990, pp 106-111.
- Pericard JM, et al: Infection à *Chlamydia psittaci* sur des Autruches (*Struthio camelus*) de parc zoologique. *Verh. Berichte 33. Intl Symp Erkrankungen Wild und Zootiere*, 1991, pp 229-238.
- Richmond SK, et al: Localization of chlamydial group antigen in McCoy cell monolayers infected with *C. trachomatis* and *C. psittaci*. *Infect Immun* 34:561-570, 1981.
- Rüffle E: Über Funde von Ornithosevirus in Hausenteneiern. *Mh Vet Med* 17:879-881, 1962.
- Schiefer HG, et al: Zellbiologie der Chlamydien. *Lab Med* 6:51-53, 1982.
- Schmeer N: Enzymimmunoassay zum Nachweis von IgG- und IgM-Antikörpern bei Ornithose und Salmonellose der Tauben. III. DVG-Tagung Vogelkrrht, 1983, pp 104-111.
- Spencer WN, et al: Simple transport medium for the isolation of *Chlamydia psittaci* from clinical material. *Vet Rec* 113:535-536, 1983.
- Storz I: Chlamydia and Chlamydia-induced Diseases. Springfield, Charles C Thomas, Publisher, 1971.
- Strauss J: Microbiologic and epidemiologic aspects of duck ornithosis in Czechoslovakia. *Am J Ophthalm* 63:1246-1259, 1967.
- Thiele D: Capture ELISA/ELIFA zum Direkt nachweis von *Chlamydia psittaci* unter Verwendung biotinylierter monoklonaler Antikörper. DVG-Tagung Fachgruppe Bakteriologie, 1990, pp 251-258.
- Vanrompoy D, et al: Serotyping of European avian *Chlamydia psittaci* isolates using serovar specific monoclonal antibodies in an immunofluorescence test. *Proc VII<sup>th</sup> Internat Symp World Assoc Vet Lab Diagnosticians* Lyon, 1992, p 28.
- Valkeri M, et al: An ornithosis related antigen from a coccid bacterium. *Acta path microbiol Scand* 39:117-126, 1956.
- Walter I, et al: *Antibiotica Fibel* 3. Auflage, Georg Thieme Verlag, 1969, p 706.
- Wyryck PB, et al: Biology of chlamydiae. *J Am Vet Med Assoc* 195:1507-1512, 1989.
- Zeh C: Behandlungsversuche bei *Nymphasius des Nymphensittichs* (*Nymphisus hollandicus*). *Vet Diss*, München, 1976.



**F**ungal infections are frequently associated with morbidity and mortality in companion birds. Like bacterial- and viral-induced diseases, the clinical features of a fungal infection may be influenced by stress factors and the age and condition of the patient. Candidiasis is frequently associated with gastrointestinal problems in neonates. Aspergillosis continues to be an important respiratory disease in psittacine species, zoo species and raptors. Improved preventive techniques and therapeutic regimes have enhanced the practitioner's ability to deal with common fungal pathogens.

However, many clinical reports detail the effects of less commonly diagnosed fungal pathogens about which relatively little is known. Current interest in avian pathology has resulted in the identification of disease conditions that were unrecognized in the past. Several of the avian fungal agents have zoonotic implications that must be addressed in the management of the patient.

Reducing stress, maintaining a healthy environment, carefully limiting the use of antibiotics and reducing exposure to fungal organisms are important in preventing these diseases.

---

CHAPTER

---

35

MYCOSES

---

**Louise Bauck**

## Common Fungal Diseases

### Candidiasis

*Candida albicans* is an opportunistic yeast that can cause a variety of problems associated with the avian digestive tract (see Color 19). This agent is frequently implicated in cases of ingluvitis (commonly referred to as “sour crop”).<sup>16</sup> The clinician should be reminded that this terminology is a summation of a clinical sign and not a diagnosis. *Candida* sp. can apparently be a primary cause of crop-related infections or can be a secondary pathogen that takes advantage of an already damaged esophageal mucosa or of a slowed crop-emptying time.

#### Transmission and Predisposing Factors

*Candida albicans* is a common environmental organism and may be a normal inhabitant of the avian digestive tract. The loss of normal bacterial flora (eg, through the use of antibiotics) can cause an increase in the number of candida organisms. Immature animals are thought to develop spontaneous primary candidiasis possibly because of an immature immune system or incompletely developed gastrointestinal (GI) defenses. Neonatal cockatiels are thought to be especially prone to primary candidiasis.<sup>45</sup>

#### Pathogenesis and Incubation

Reduced competition with normal gut flora or a break or weakness in the mucous membranes may precipitate colonization and budding by this opportunistic yeast. The magnitude and outcome of the infection may depend on the age of the bird and status of the immune system. Chronic or systemic infections may result in septate hyphae and reproductive chlamydospores that can be demonstrated by histologic examination. *Candida* sp. infections are characterized by necrosis with minimal inflammation.<sup>5</sup> The exact incubation period is unknown, but birds being treated with antibiotics frequently show increased numbers of yeast several days after initiating antibiotic therapy.


Systemic candidiasis is rare but has been reported in companion birds. In these cases, yeast may be present in the blood, bone marrow and parenchymous organs.<sup>17</sup> Severe stress or immunosuppression may be necessary to potentiate systemic infections.

### Clinical Disease and Pathology

In most young birds, the crop is the principal site of a candida infection. In many cases, the crop may be the only portion of the digestive tract affected. However, several reports also indicate that in some young birds, the proventriculus or ventriculus can be the primary site of yeast replication in the absence of crop lesions.<sup>7,17,20</sup> The characteristic *Candida* lesion is a catarrhal-to-mucoid exudate consisting of raised, white mucosal plaques and whitish-to-clear mucus that may or may not be associated with a foul odor. Chronic cases may develop a “turkish towel” appearance produced by multiple tag-like plaques of mucosa and inflammatory cells (Figure 35.1) (see Color 19).<sup>52</sup>

Clinical signs associated with candida-induced ingluvitis in neonates include regurgitation or vomiting, increased crop-emptying time, depression, anorexia and occasional crop impactions.<sup>42</sup> In older birds, the crop may be distended with mucus, and crop emptying may be hindered by necrotic mucosal debris. *Candida* lesions in the oral cavity are recognized by the appearance of white plaques covered by a tenacious mucus.<sup>31,34</sup> *Candida* has been associated with impacted food, beak abnormalities and tongue necrosis in a variety of adult birds. Yeast infections in ratites have been associated with extensive necrosis of the upper beak.<sup>34</sup>

Although less frequent, candida infections may also be found outside of the GI tract. Yeast infections affecting the cloaca and vent of turkeys and geese have been reported.<sup>4,28</sup> Skin lesions, particularly on the head and neck, have been described in companion birds and pigeons.<sup>39,52</sup> Primary candida infections have also been associated with foot lesions in waterfowl.<sup>12,36</sup> Respiratory infections caused by candida occasionally have been reported in psittacine



**FIG 35.1** Characteristic “turkish towel” appearance of the crop mucosa in a young budgerigar with severe candidiasis.

birds.<sup>19,20</sup> Birds being treated with prolonged antibiotic therapy for upper respiratory tract infections may develop secondary candida infections. Systemic candidiasis in a flock of canaries was associated with central nervous system signs in addition to those routinely noted with gastrointestinal infections.<sup>35</sup> Pericardial lesions attributed to *Candida* spp. were reported in a Sun Conure.<sup>48</sup> Lameness was the principal clinical sign in a Blue-fronted Amazon with candidiasis.<sup>17</sup>

### Diagnosis and Differential Diagnosis

A subjective diagnosis of gastrointestinal candidiasis is often suggested by the history and clinical signs. A Gram's stain of material collected from the site of suspected infection is helpful in confirming a diagnosis (see Color 8). Identifying yeast with a Gram's stain suggests only that the organism is present. Histologic evaluation of biopsy samples is necessary to confirm that the yeast are causing pathologic changes. However, identifying large numbers of budding organisms is suggestive of a prolific population of yeast. Negative cytologic results do not rule out candidiasis, because deep mucosal scrapings are necessary to achieve adequate samples in some cases.<sup>34</sup>

Gram's stains usually provide adequate visualization of yeast but dry smears can also be stained with Diff-Quik<sup>a</sup> and new methylene blue. Lactophenol cotton blue is recommended for wet mounts.<sup>5</sup> The yeast organism, which is often budding, is small (3 to 6  $\mu$ m diameter), and has been compared to the size of an avian red blood cell nucleus.<sup>27</sup> Hyphal forms are considered more diagnostic of a primary yeast infection but are less commonly found in a live patient (see Color 10).

Because candida is frequently a secondary pathogen, the clinician should attempt to determine the predisposing factors that lead to a candida infection. Oral and upper gastrointestinal candidiasis may show signs similar to those of trichomoniasis, hypovitaminosis A, avian poxviruses, bacterial infections, psittacine beak and feather disease, neonatal gastrointestinal viruses, ingested foreign bodies and toxicities. Culturing the organism may be helpful, especially in cases involving beak abnormalities or systemic problems. Sabouraud's<sup>b</sup> or cornmeal agar are the recommended culture media.<sup>5</sup>

### Treatment

Effective candida therapy must include the resolution of predisposing factors such as environmental or nutritional stress, poor hygiene and unnecessary an-

tibiotic therapy. Nystatin is the most frequently used medication for initially treating upper gastrointestinal candidiasis in the avian patient, although some of the azole antifungals are undoubtedly more effective. Nystatin has few side effects and is not absorbed from the gastrointestinal tract following oral administration. It is readily accepted by most birds and can be mixed with a neonate's feeding formula (Table 35.1). Ocular candidiasis is usually responsive to amphotericin B ointment or amphotericin B injected subconjunctivally.

TABLE 35.1 Some Antifungal Agents Used in Companion Species

Amphotericin B <sup>c</sup> (injectable)	1.5 mg/kg IV TID x 3 days 1.0 mg/ml saline intratracheal BID 1 mg/ml saline nebulized for 15 min BID
Flucytosine <sup>d</sup> (capsules)	250 mg/kg PO BID x 21 days
Ketoconazole <sup>e</sup> suspension (tablets)	10-30 mg/kg BID x 21 days
Itraconazole <sup>f</sup> (beads in capsules)	5-10 mg/kg BID in food for 7-21 days
Fluconazole <sup>g</sup> (tablets)	5 mg/kg SID for 7 days
Nystatin <sup>h</sup> (suspension)	100,000 units (1 ml) per 400 gram bird PO BID x 7 days

Ketoconazole is recommended for severe or refractory candidiasis. Although more costly and difficult to administer, it is a very effective systemic antifungal with a high therapeutic index.<sup>5,32,46</sup> Side effects may include vomiting and elevation of liver enzymes.<sup>17</sup> Ketoconazole is normally mixed with a slightly acidic liquid (eg, orange juice, pineapple juice) to facilitate its dilution. *Candida* prefers an alkaline environment and this acidification of the GI tract will have therapeutic value.

Strains of *Candida* spp. resistant to ketoconazole have been reported, and fluconazole has been suggested as a treatment of choice for these strains.<sup>33</sup> Little information is available on the use of this drug in birds; however, reported side effects have been minimal. Itraconazole has also been used to treat candidiasis,<sup>15,20,23</sup> but may offer no real advantage over other azoles. Miconazole has been reported to be effective in treating yeast infections, but few reports exist on its use in companion birds.<sup>54</sup> Azole antifungals may cause depression, anorexia, vomiting and hepatic toxicity.<sup>38</sup>

## Aspergillosis

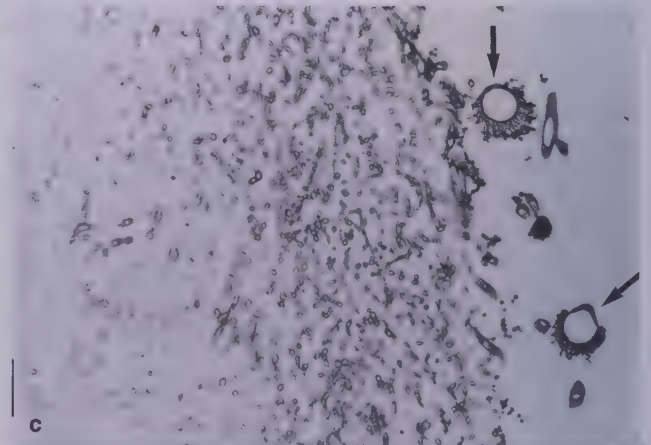
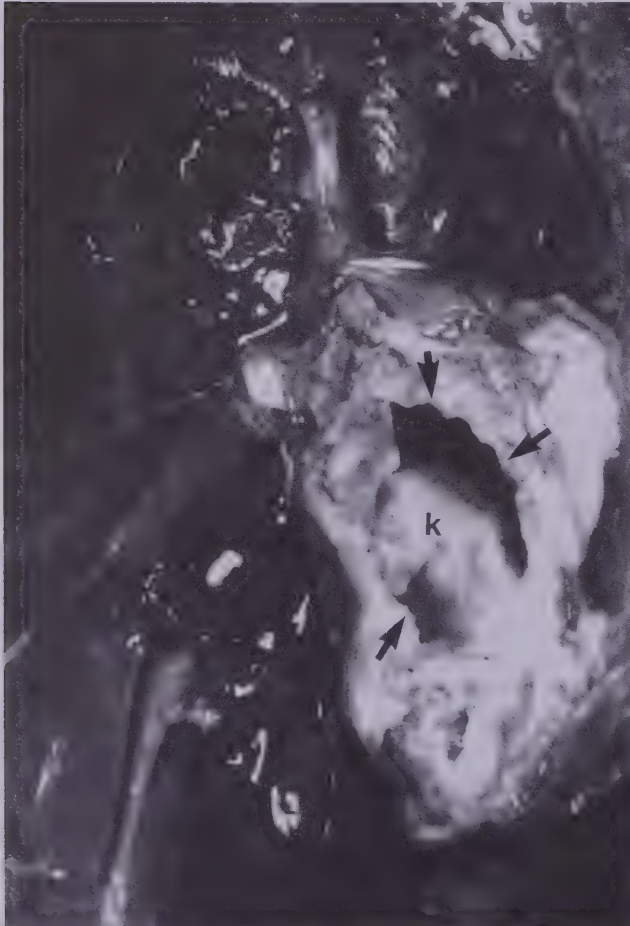
Aspergillosis is a disease of economic importance in the poultry industry (brooder pneumonia), and is a frequent cause of respiratory disease in companion, aviary and free-ranging birds. *Aspergillus fumigatus* is the most common etiologic agent, followed in frequency by *A. flavus* and *A. niger*. Aspergillosis may be chronic and insidious, or it may cause peracute death. Established aspergillosis infections are clinically challenging to resolve.

### Transmission and Predisposing Factors

Penguins, birds of paradise, pheasants, waterfowl (especially diving birds and shorebirds), Goshawks and Gyrfalcons are believed to be especially susceptible to *Aspergillus* spp.<sup>15,37,45</sup> Among companion birds, a high prevalence of aspergillosis has been reported

in African Grey Parrots, Blue-fronted Amazon Parrots and mynah birds.<sup>30,45</sup> Aspergillosis is occasionally described in pigeon flocks with one report listing a prevalence of 2.4%.<sup>37</sup>

Gallinaceous birds (particularly quail) often become infected as chicks following inhalation of spores from contaminated brooders.<sup>16</sup> Hand-raised psittacine birds could be infected in a similar manner. Older gallinaceous birds, and presumably aviary birds as well, can be exposed when maintained on moist contaminated bedding. Moldy straw is a particularly common source of numerous fungal pathogens including *Aspergillus* spp. Waterfowl may be infected by feeding on moldy corn or wheat straw.<sup>29</sup> Zoo birds that are contaminated with oil, or birds maintained in damp, poorly ventilated areas are frequently infected.



**FIG 35.2** A mature Black Palm Cockatoo had a history of progressive rear limb ataxia and weight loss. The bird was presented for necropsy. **a)** Gross findings included a proliferative, white, fuzzy mass that was covering a thickened left abdominal air sac. When the ventral border of the mass was removed, the cranial and middle lobes of the left kidney were also found to be involved. **b)** An impression smear from the interior of the mass stained with new methylene blue revealed numerous branching septate hyphae suggestive of *Aspergillus* spp. **c)** Histopathology indicated thickened air sacs with fungal hyphae and fruiting bodies, which are characteristic of *Aspergillus* spp. growth in an oxygen-rich environment (courtesy of Kenneth Latimer, reprinted with permission<sup>15</sup>).

### Pathogenesis and Incubation


*Aspergillus* is ubiquitous, and infections should always be considered to occur secondarily to an immunosuppressive event. It has been suggested that healthy birds exposed to high concentrations of spores are generally resistant to infections, while immunocompromised hosts exposed to small concentrations of spores are frequently infected. Factors that influence the susceptibility of a bird to aspergillosis include shipping, overcrowding, malnutrition, poor ventilation, very young or old age, antibiotic therapy (particularly tetracyclines), corticosteroid administration, respiratory irritants (eg, disinfectant fumes, cigarette smoke, ammonia) or concomitant disease.<sup>5,16,24</sup>

The type of disease induced by aspergillosis is thought to be dependent on the source and number of spores contacted and the general condition of the bird.<sup>6</sup> Healthy birds can generally withstand exposure to a high concentration of spores.

Aspergillosis infections are generally divided into local and systemic diseases. Lesions frequently originate in one system or area (eg, lower respiratory tract) and later advance into adjacent organs and systems as the disease progresses (Figure 35.2). Acute cases occur when spores germinate in a particularly vital area or when multiple lesions germinate at once.

A single air sac lesion may have a protracted course while a single lesion in the trachea or syrinx may quickly prove fatal (see Color 22). The syrinx or tracheal bifurcation is thought to be a common location for aspergillosis colonization because air turbulence patterns may cause the spores to drop out of the air stream at this point in the respiratory system.<sup>49</sup> Alternatively, the narrowing in the respiratory tract at this point may predispose it to blockage with necrotic debris.

There is a small area of stratified squamous epithelium in the syringeal area of some birds that can be modified by hypovitaminosis A. Tissue hypertrophy and hyperkeratosis may occur, allowing colonization by inhaled aspergillosis spores (Figure 35.3). Nasal aspergillosis also occurs in the avian patient.<sup>25,55</sup> Cutaneous, skeletal and gastrointestinal forms have been reported in rare instances.<sup>11,24,26</sup> An ocular form has been described in gallinaceous birds.<sup>6,16</sup> The incubation period associated with aspergillosis varies with the type of exposure. Experimentally infected ostrich chicks died two to eight days following expo-



**FIG 35.3** A ten-year-old Amazon parrot was presented with a three-week history of progressive dyspnea that had advanced to the point of post-exercise collapse. The bird was anesthetized with isoflurane, and an air sac tube was placed in the abdominal air sac. Tracheoscopy revealed a large proliferative white mass in the syrinx. The bird was breathing through a hole in the center of the mass the size of a 20 ga needle. Attempts to remove the mass were unsuccessful. At necropsy, the bird was normal except for the aspergilloma in the syrinx. The air sacs were clear. The bird was on an all-seed diet, which may have resulted in squamous metaplasia in the syrinx and precipitated an infection.

sure to spores (see Color 22). Air sac infections in mature birds may progress for weeks, or can induce granulomas that are present for months.

### Clinical Disease and Pathology

Clinical signs associated with aspergillus infections of the respiratory tract may include dyspnea, depression and emaciation (Table 35.2).<sup>10</sup> Open-mouthed breathing, pronounced excursions of the keel, tail “bobs” and respiratory distress after exercise are typical. Biliverdinuria is common. Wheezing, squeaking or stertor and a voice change are also sometimes present. Posterior paresis and lameness were the presenting signs in a Black Palm Cockatoo with *Aspergillus* spp. air sacculitis that spread to the kidney and pelvic nerve roots.<sup>18</sup> Signs related to the target organ(s) are seen in the less common forms of aspergillosis. Aspergillosis may be associated with ascites caused by peritonitis or cardiopulmonary im-

pairment, usually secondary to aspergillosis-induced thrombi in the pulmonary vessels.

**TABLE 35.2 Clinical Findings in Companion Birds with Aspergillosis\***

Emaciation	64%
Respiratory distress	26%
Neuromuscular disease	18%
Abnormal droppings	11%
Regurgitation	9%
Vocalization changes	7%
Poor appetite	7%
Nasal discharge	4%
Gout	4%
Hemoptysis	2%

\* Adapted from McMillan MC, et al.<sup>30</sup>

In systemic cases in gallinaceous chicks, lesions are typically found in lungs, air sacs, heart muscle, liver and abdominal viscera.<sup>13</sup> Grossly, lesions in all areas are similar. A cream- to yellow-colored granuloma or plaque is present with or without gray or white “cotton-wool” mycelial masses (see Color 22).

Destruction of adjacent tissue, including bone or beak, may be substantial (Figure 35.4). Nasal aspergillosis typically presents as a dry, granulomatous, destructive swelling within one nostril. Histopathological examination of granulomas generally shows a necrotic foci surrounded by macrophages, heterophils and giant cells, sometimes within a connective tissue capsule (Table 35.3). Tracheal or syringeal aspergillosis lesions usually occur as plugs of creamy white necrotic debris at or near the tracheal bifurcation. Ocular aspergillosis in chicks may be recognized as a white exudate within the conjunctival sac.<sup>6</sup>

**TABLE 35.3 Histopathologic Findings in Birds with Aspergillosis**

Granulomatous pneumonia	66%
Fungal air sacculitis	53%
Bronchopneumonia	37%
Tracheobronchial mycetomas	20%
Acute necrosis with thrombosis	17%
Concurrent infection	40%

\* Adapted from McMillan MC, et al.<sup>30</sup>

### Diagnosis and Differential Diagnosis

History, signalment, physical examination findings and hematologic findings (heterophilia and anemia) may be suggestive of an aspergillosis infection. Fungal culture, hematology, serology, cytology, radiology and endoscopy or exploratory surgery are among the methods used to diagnose infections (Table 35.4). It should be noted that culture of *Aspergillus* spp. in the



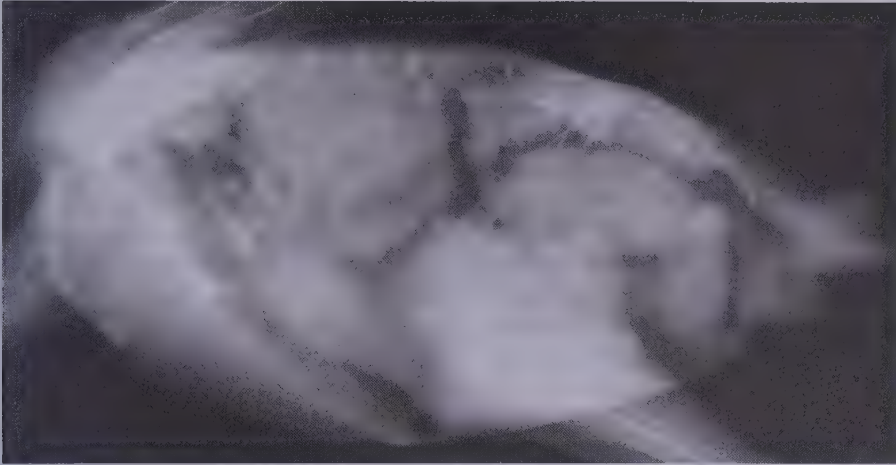
**FIG 35.4** A mature African Grey Parrot was presented with an advanced case of nasal aspergillosis. The nostril and operculum had been damaged by pressure necrosis. The extent of damage to the germinative epithelium is demonstrated by a severe defect in the beak. This photograph was taken several weeks after debridement and treatment of the infected tissues with miconazole (courtesy of Louise Bauck).

absence of lesions is not diagnostic, because the organism is ubiquitous in the environment. Radiographic findings can be negative or may show hyperinflation (enlargement) of the abdominal air sacs, focal densities in lungs or air sacs, reduced coelomic cavity details, loss of definition of air sac walls and asymmetrical opacity of abdominal air sacs (Figure 35.5).<sup>30</sup> Cytology of air sac washes or endoscopic-guided biopsy are useful in diagnosing lower respiratory infections.

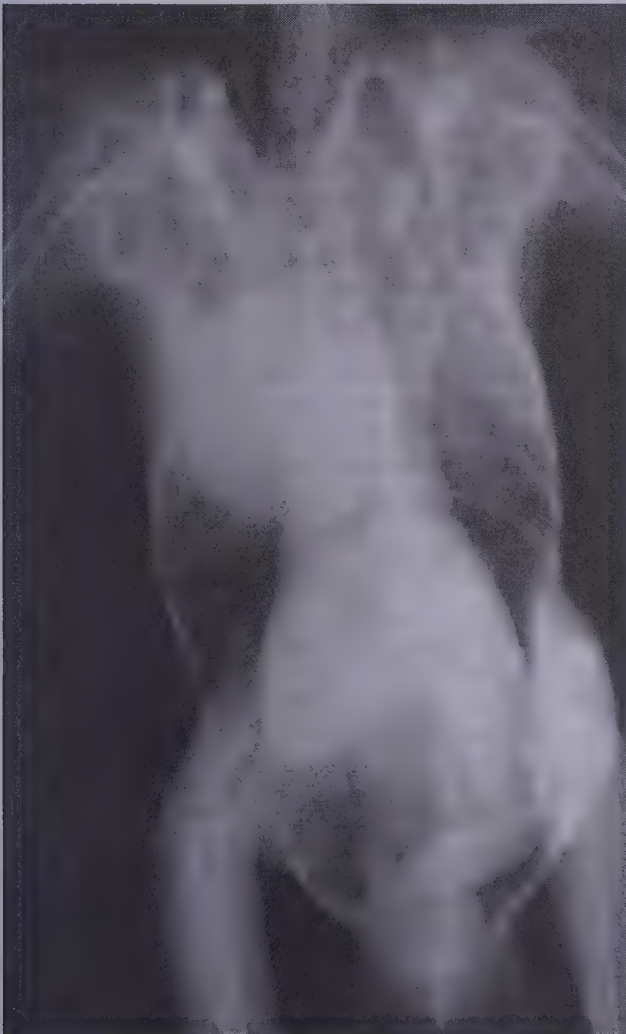For definitive antemortem diagnosis, cytologic samples from granulomas with associated mycelial areas (wet mounts with lactophenol cotton blue, new meth-

**TABLE 35.4 Typical Clinical Pathology Changes with Aspergillosis**

Leukocytosis - heterophilia
Monocytosis
Lymphopenia
Nonregenerative anemia
Hyperproteinemia
Hypergammaglobulinemia



**FIG 35.5** A mature Double Yellow-headed Amazon Parrot was presented with a history of severe dyspnea. Radiographs indicated a large soft tissue mass that was localized to the right lung and cranial thoracic air sac. A slightly oblique, rather than ventrodorsal, radiograph was made to better visualize the thoracic mass. An aspergilloma was diagnosed at necropsy (courtesy of Marjorie McMillan).



ylene blue and culture on Sabouraud dextrose agar or blood agar) may be diagnostic. The presence of branching septate hyphae, sometimes with spores and sporulating areas, is highly suggestive (see Figure 35.2b). Culture may distinguish *Aspergillus* spp. from other fungal organisms such as *Penicillium* spp. and *Mucor* spp. If access to a suggestive lesion is not available, then serology may be helpful. Although not widely available, aspergillosis titers using ELISA systems show promise in diagnosing infections.<sup>3,57</sup> Latex agglutination and complement fixation methods have also been described. Several of these tests are available on a commercial basis for gallina-

ceous birds, and an ELISA test is available in the United States for detecting anti-aspergillus antibodies.<sup>22</sup>

The differential diagnosis for a mature bird with weight loss and severe heterophilia might include chlamydiosis and mycobacteriosis. Neoplastic disease may sometimes cause weight loss and heterophilia. Severe dyspnea can also be caused by increased abdominal pressure (eg, mass, ascites, hepatomegaly), pneumonia and inhaled foreign bodies. Eye lesions, as described in gallinaceous birds, may be caused by hypovitaminosis A.

#### Treatment

Treatment of aspergillosis often depends on the location and extent of the lesion. Resolving advanced cases of aspergillosis is difficult, especially in anatomic areas where surgical removal of affected tissues is not possible. Correction of underlying stress factors is a mandatory component of successful therapy. Surgical debridement of plaques and granulomas should be employed when feasible.<sup>5,29,44</sup> Flushing lesions with amphotericin B or chlorhexidine solutions may be helpful, although caution should be exercised in certain anatomic areas. A severe granulomatous sinusitis occurred in an African Grey Parrot following the use of amphotericin B as a nasal flush.<sup>55</sup>

Intratracheal administration of amphotericin B has been used in treating tracheal and pulmonary asper-

gillosis. The medication is given via the glottis during inspiration and the patient is positioned to distribute the drug to the affected anatomic area.<sup>40,44</sup> Nebulization with antifungals may be helpful in early cases of upper respiratory aspergillosis.<sup>5,48</sup> Topical treatments with amphotericin B or other antifungal creams may be of value in external lesions in combination with systemic therapy (see Figure 35.4).<sup>5,25</sup> Systemic therapy is difficult because amphotericin B must normally be administered intravenously TID for three days. Intraosseous administration should be possible, but has not been documented. Amphotericin B is potentially nephrotoxic.

Flucytosine is also frequently used to treat aspergillosis, especially in combination with amphotericin B (Table 35.5). The advantage to this drug is that it can be administered orally; however, bone marrow toxicity has been reported in some cases. Monitoring for hematologic changes suggestive of bone marrow damage is recommended when this drug is used.

Some of the azole antifungals have good efficacy against aspergillosis in mammals and may be administered orally. Ketoconazole has been used to successfully treat aspergillosis in some avian species. This drug preparation has an advantage over other antifungals in having a wide therapeutic index.<sup>2,26,42,44,47,53</sup>

Current information suggests that itraconazole may have greater efficacy against *Aspergillus* spp. than amphotericin B or any other azole antifungal.<sup>15,20,53,54</sup> Itraconazole is thought to be less toxic than amphotericin B, but its safety in most companion bird species has not been established. Itraconazole has been used in waterfowl, shorebirds, poultry and penguins without serious side effects.<sup>15,54</sup> Anorexia, vomiting and depression have been reported in an African Grey Parrot being treated with itraconazole.<sup>38</sup> Monitoring for anorexia and depression is recommended. Enilconazole also has good efficacy against *Aspergillus* sp., although not as great as itraconazole.<sup>54</sup> Miconazole and parconazole may be less efficacious than other azoles in treating aspergillosis.

**TABLE 35.5 Suggested Concurrent Therapy for Advanced Aspergillosis**

Amphotericin B – IV and/or IT or in the affected air sac – BID for 5 days
Ketoconazole – orally – TID for 10 days
Flucytosine – orally – TID for 20 to 30 days
Kapracidin A – orally – TID for 5 days

Immunization therapy has been suggested to be of value in stimulating host response to *Aspergillus* spp.

although information on the success of this treatment is still limited. Levamisole therapy has been suggested as an immunostimulant, but its efficacy is unknown.<sup>5</sup>

### Control

Prevention of aspergillosis in general is dependent on the reduction of predisposing stress factors. Limiting exposure may be accomplished by reducing contact with organic bedding or nesting material that may be contaminated with mold or spores. Careful cleansing and disinfection of hatching equipment is essential. Feed for companion and aviary birds should always be free of fungal growth in order to limit exposure to fungal pathogens and mycotoxins (see Chapter 37). Vaccination with an autogenous mycotin may be effective in reducing aspergillosis in susceptible species such as captive penguins and waterfowl.<sup>57</sup>

### ■ Cryptococcosis

*Cryptococcus neoformans* is an imperfect, saprophytic yeast that has been reported as a cause of disease in psittacine birds and pigeons.<sup>9,14,43</sup> The transmission and pathogenesis in birds is largely unknown, but it is isolated frequently from the droppings of pigeons. In gallinaceous birds, cryptococcosis has been described as a necrotic granulomatous disease of the intestines, liver, lungs and spleen. In companion birds, a diagnosis of cryptococcosis is usually made at postmortem.

Antemortem diagnosis of cryptococcosis may be challenging. An impression smear of any accessible gelatinous material may reveal the characteristic encapsulated yeast-like organism. A latex agglutination antibody titer may be elevated in an exposed or infected bird.<sup>41</sup>

Central nervous system signs in birds with gelatinous masses should be considered suspicious. A Moluccan Cockatoo with disseminated cryptococcosis was presented for diarrhea and blindness; gelatinous material was present in the long bones, respiratory spaces and abdominal cavity.<sup>14</sup> In another case of cryptococcosis, a Green-winged Macaw was presented for diarrhea and paralysis.<sup>9</sup>

Dyspnea, weight loss and anemia are frequent clinical signs, and heterophilia may or may not be present.<sup>43</sup> The clinician should exercise caution when being exposed to clinical material that may contain *C. neoformans* spores.



The prognosis for disseminated cryptococcosis is poor. Amphotericin B and ketoconazole have been suggested as possible therapies.<sup>43</sup> In humans, amphotericin B, flucytosine and rifampin are sometimes effective. Cryptococcosis is a potentially serious zoonosis and may occur when humans inhale dust from the dried droppings of pigeons, starlings or other avian species.<sup>9,56</sup> Other transmission routes may also be possible. Respiratory signs, encephalitis or meningitis may occur; the outcome is frequently fatal. Treating cryptococcus cases should be carefully considered given the zoonotic potential for this organism.

### ■ Histoplasmosis

Histoplasmosis is similar to cryptococcosis in many ways but is less commonly reported in birds. *Histoplasma capsulatum* is an infectious but not contagious disease of the reticuloendothelial system. *Histoplasma* spp. grow readily in soil and appear as a white-to-brown mold with two types of spores.<sup>6</sup> The organism has been associated with or found in the feces of chickens, blackbirds, pigeons and gulls.<sup>41</sup> This fungus could potentially proliferate in enclosed aviaries with dirt floors. Surveys of aviary soil are needed to determine the incidence of this organism. The transmission and incubation periods are unknown, but in experimental situations, the organism can be recovered from the liver and spleen 7 to 45 days after intravenous inoculation.

Diagnosis of histoplasmosis is based on culture of the organism (mycelial phase may sometimes be recovered on Sabouraud's agar) and histopathology (periodic acid-Schiff, Bauer's and Gridley stains).<sup>6</sup>

*Histoplasma* sp. has zoonotic potential and may cause pneumonitis that progresses to a disseminated disease of the reticuloendothelial system.

## Uncommon Fungal Diseases

Dermatophytosis, mucormycosis, trichosporosis, rhinosporidiosis and penicilliosis have all been documented in avian species. Dermatophyte infections are of some interest to the avian practitioner because of their role in skin and feather abnormalities. While

frequently implicated, fungal infections of the skin in psittacine birds have rarely been documented.

*Trichophyton gallinae* is the principal dermatophyte of gallinaceous species, and is associated with a white crust on the comb and wattles ("fowl favus") (see Color 8). *Trichophyton* sp. has been documented as a cause of dermatologic problems in the duck, pigeon and canary.<sup>5,41,52</sup> Diagnosis of fungal skin infections is usually made with cytologic evaluation of wet mounts or Gram's-stained smears, culture (canine and feline dermatophyte media for in-hospital use may not be suitable) and biopsy (histopathology). Topical treatment with antifungal creams is recommended, with attention to any underlying stress factors. *Trichophyton gallinae* is a zoonotic disease and has been described as a pruritic, scaly lesion of the scalp.<sup>51</sup>

Mucormycosis is a term that includes a variety of fungal pathogens. In birds, disease caused by *Rhizopus* and *Mucor* spp. have been reported. Granulomas of the gut and ventriculus were found in a group of canaries that were being fed sprouted seed; concurrent antibiotic treatment may have been a predisposing factor.<sup>39,53</sup> Infections caused by members of the phycomycetales (zygomycota) can sometimes mimic aspergillosis (eg, tracheal obstruction, mycelial granulomas).

Systemic trichosporosis was reported in a Green-winged Macaw that was presented for weight loss and polyuria. Granulomatous inflammation involving the liver, myocardium and lung was associated with *Trichosporon beigeli*.<sup>50</sup> *Penicillium griseofulvum* is another rare fungal isolate that caused a systemic infection in a group of captive toucanets.<sup>1</sup> Septate, branched mycelia were found in the lungs, air sacs and liver. Conidiophores and conidial chains were present in the air sacs. Nocardiosis (*Nocardia asteroides*) involving the lungs and air sacs of two Pesquet Parrots has been reported.<sup>5</sup>

Rhinosporidiosis seems to be found most frequently in birds living in aquatic habitats. It has been documented in ducks and geese but not in Psittaciformes or Passeriformes. It also occurs in man and the dog, and in most species it can take the form of an erythematous nasal polyp.<sup>10</sup>

A mycetoma caused by *Curvularia geniculata* was reported in a Grand Eclectus Parrot. Mycetomas in man are eruptions of the extremities that usually involve granuloma formation by one of a number of obscure fungal pathogens.

### Products Mentioned in the Text

- a. DiffQuik, Fisher Scientific, Pittsburgh, PA
- b. Sabouraud's agar, Fisher Scientific, Pittsburgh, PA
- c. Fungizone, E.R. Squibb and Sons Inc., Princeton, NJ
- d. Ancobon, Roche Laboratories, Nutley, NJ
- e. Nizoral, Janssen Pharmaceutical Inc., Piscataway, NJ
- f. Itraconazole, Janssen Pharmaceutical Inc., Piscataway, NY
- g. Diflucan, Reorige Division of Pfizer Inc., New York, NY
- h. Mycostatin, E.R. Squibb and Sons Inc., Princeton, NJ

### References and Suggested Reading

1. Aho R, et al: Avian penicilliosis caused by *Penicillium griseofulvum* in a captive toucanet. *J Vet & Med Mycol* 28(5):349-354, 1990.
2. Bouck LB: Treatment of canine nasal aspergillosis with ketoconazole. *Vet Med Sm Anim Clin* 78(11):1713-1715, 1983.
3. Baumgartner R: Clinical diagnosis of aspergillosis with the aid of serology. *Proc Assoc Avian Vet*, 1988, pp 61-67.
4. Beemer AM, Kutin ES, Katz Z: Epidemic venereal disease due to *Candida albicans* in geese in Israel. *Avian Dis* 17(3):636-649, 1973.
5. Campbell TW: Mycotic diseases. In Harrison GJ, Harrison LR (eds): *Clinical Avian Medicine and Surgery*. Philadelphia, WB Saunders Co, 1986, pp 464-472.
6. Chute HL: Fungal diseases. In *Disease of Poultry* (8th ed). Hofstead MS (ed), Iowa State University Press, Ames, 1984, pp 309-320.
7. Clipsham R: Fungal proventriculitis in macaws. *J Assoc Avian Vet* 3(2):68, 1989.
8. Clipsham R: Pediatric management and medicine. *J Assoc Avian Vet* 3(1):10-13, 1989.
9. Clipsham R, Britt JO: Disseminated cryptococcosis in a green-winged macaw. *J Am Vet Med Assoc* 183(11):1303-1304, 1983.
10. Davidson WR, Nettles VF: Rhinosporidiosis in a wood duck. *J Am Vet Med Assoc* 171(9):989-990, 1977.
11. Davidson WR, et al: Feather damage due to mycotic infections in wild turkeys. *J Wildl Dis* 25(4):534-539, 1989.
12. Degryse AD, VanCutsem J, Franssen J: Oral treatment with ketoconazole of plantar candidosis in a mute swan. *J Sm Anim Pract* 26(10):619-624, 1985.
13. Erer H, Sezen IV, Erganis O: Investigations on aspergillosis in chickens. *Selkuk Universitesi Veteriner Fakultesi Dergisi* 2(1):171-179, 1986.
14. Fenwick B, Takeshita K, Wong A: A Moluccan cockatoo with disseminated cryptococcosis. *J Am Vet Med Assoc* 187(11):1210-1212, 1984.
15. Franssen J, VanCutsem J: Fungal infections in birds in captivity (synopsis). *AAV Today* 2(1):15, 1988.
16. Frazer CM, et al (eds): *Diseases of poultry*. Merck Veterinary Manual 7th ed. Rahway, Merck & Co, 1991, p 1562.
17. Goodman G, Widenmeyer JC: Systemic *Candida parapsilosis* in a 20-year-old Blue-fronted Amazon. *Proc Assoc Avian Vet*, 1986, pp 105-119.
18. Greenacre CB, Latimer KS, Ritchie BW: Leg paresis in a black palm cockatoo caused by aspergillosis. *J Zoo & Wildlife Med* 23(1), 1992.
19. Harrison GJ: *Candida* air sacculitis (radiographic self-assessment). *AAV Today* 2(4):202, 1988.
20. Hines RS, Sharkey P, Friday RB: Itraconazole treatment of pulmonary, ocular and uropygial aspergillosis and candidiasis in birds. *Proc Am Assoc Zoo Vet*, 1990, pp 322-326.
21. Hubbard GB, et al: Fungal infection of ventriculi in captive birds. *J Wildl Dis* 21(1):25-28, 1985.
22. Jenkins JR: Aspergillosis. *Proc Assoc Avian Vet*, 1991, pp 328-330.
23. Joyner KL: Pediatric therapeutics. *Proc Assoc Avian Vet*, 1991, pp 188-199.
24. Kaplan W, et al: Fatal aspergillosis in imported parrots. *Mycopathologia* 56(1):25-29, 1975.
25. Kaufman GE: Enilconazole treatment of fungal rhinitis in an African grey parrot. *Proc Am Assoc Zoo Vet/Am Assoc Wildlife Vet*, 1988.
26. Kollias GV: The use of ketoconazole in birds. *Proc Assoc Avian Vet*, 1986, pp 103-104.
27. Lane R: Use of Gram's stain for bacterial screening. *J Assoc Avian Vet* 4(4):214-217, 1990.
28. Marius-Jestin V, et al: Etiology of the venereal disease of the gander. *Recl Med Vet ED Alfort* 163(6,7):645-654, 1987.
29. McDonald SE, Messenger GA: Successful treatment of mycotic tracheitis in a raven. *Proc Assoc Avian Vet*, 1984, pp 155-163.
30. McMillan MC, Petrak ML: Aspergillosis in pet birds: A review of 45 cases. *Proc Assoc Avian Vet*, 1988, pp 35-45.
31. Panigrahy B, et al: Candidiasis in cockatiel nestlings and mucormycosis in a pigeon. *Avian Dis* 23(3):757-760, 1979.
32. Parrott T: Flock treatments. *J Assoc Avian Vet* 5(1):47, 1991.
33. Parrott T: Clinical treatment regimens with fluconazole. *Proc Assoc Avian Vet*, 1991, pp 15-19.
34. Patgiri GP: Systemic mycoses. In Burr EW (ed): *Companion Bird Medicine*. Ames, Iowa State University Press, 1987, pp 102-106.
35. Perez A: Canaries: Systemic candidosis. *Veterinaria Argentina* 2(12):186-189, 1985.
36. Perry RA: Avian dermatology. In Burr EW (ed): *Companion Bird Medicine*. Ames, Iowa State University Press, 1987, pp 40-50.
37. Pokras MA: Captive management of aquatic birds. *AAV Today* 2(1):24-33, 1988.
38. Quesenberry K, et al: Roundtable discussion: clinical therapy. *J Assoc Avian Vet* 5(4):186-191, 1992.
39. Reavill DR, Schmidt RE, Fudge AM: Avian skin and feather disorders: A retrospective study. *Proc Assoc Avian Vet*, 1990, pp 248-253.
40. Redig PT: Mycotic infections of birds of prey. In Fowler ME (ed): *Zoo and Wild Animal Medicine*. Philadelphia, WB Saunders Co, 1978, pp 273-290.
41. Ritchie BW, Dreesen DW: Avian zoonoses: Proven and potential diseases, part II. *Comp Cont Ed* 10(6):688-696, 1988.
42. Ritchie BW: Avian therapeutics. *Proc Assoc Avian Vet*, 1990, pp 415-430.
43. Rosskopf WJ, Woerpel RW: Cryptococcosis in a thick-billed parrot. *Proc Assoc Avian Vet*, 1984, pp 281-288.
44. Rosskopf WJ, et al: Successful treatment of aspergillosis in two psittacine birds. *Proc Assoc Avian Vet*, 1986, pp 119-128.
45. Rosskopf WJ: Therapeutic agents for raptors. *AAV Today* 1(4):146, 1987.
46. Rosskopf WJ, Woerpel RW: Psittacine conditions and syndromes. *Proc Assoc Avian Vet*, 1990, pp 432-459.
47. Sharp NJH, Sullovan M: Use of ketoconazole in the treatment of canine nasal aspergillosis. *J Am Vet Med Assoc* 194(6):782-786, 1989.
48. Smith RE: Avian diseases that antibiotics won't cure. *AAV Today* 1(2):69-70, 1987.
49. Stroud RK, Duncan RM: Occlusion of the syrinx as a manifestation of aspergillosis in Canada geese. *J Am Vet Med Assoc* 181(11):1389-1390, 1982.
50. Taylor M: Systemic trichosporonosis in a green-winged macaw. *Proc Assoc Avian Vet*, 1988, pp 219-220.
51. Torres G, Georg LK: A human case of *Trichophyton gallinae* infection. *AMA Arch of Derm*: 191-197, 1956.
52. Tudor DC: Mycotic infections of feathers as a cause of feather pulling in pigeons and psittacine birds. *Vet Med Sm Anim Clin* 78(2):249-253, 1983.
53. VanCutsem J: Experimental fungal diseases and treatment (synopsis). *AAV Today* 2(1):15, 1988.
54. VanCutsem J, Vangerven F, Janssen PA: The treatment of experimental aspergillosis with enilconazole and itraconazole. *Bull Soc Fr Mycol Med* 18(1):55-60, 1989.
55. Vandermaast H, Dorrestein GM, Westerhof J: A fatal treatment of sinusitis in an African grey parrot. *J Assoc Avian Vet* 4(3):189, 1990.
56. Wolf AM: Systemic mycoses. *J Am Vet Med Assoc* 194(9):1192-1196, 1989.
57. Yearout DR: Prevention and treatment of aspergillosis by vaccination. *Proc Assoc Avian Vet*, 1988, pp 139-143.

**A**vian parasites range from single-celled protozoans that develop either intracellularly or extracellularly to multicellular helminths and arthropods. The effects of an infection can vary from benign to acute deaths. Parasitic life cycles may be direct or complex indirect cycles requiring various arthropod or animal hosts. Some species of parasites can infect nearly every organ system, although individual genera will inhabit specific organs or tissues. For example, mature tapeworms (Cestoda) and spiny-headed worms (Acanthocephala) are restricted to the small intestines. Mature flukes (Trematoda) occur in the intestines, liver, kidney, air sacs, oviducts, blood vessels and on the surface of the eyes. Adult roundworms (Nematoda) parasitize the crop, proventriculus, ventriculus, intestines, ceca, body cavities, brain, surface and periorbital tissues of the eyes, heart and subcutaneous tissues. Mites (Acarina) live in and on the skin, feather shafts and follicles, choanal slit, nasal passages, trachea and air sacs. Immature and mature biting lice and ticks remain on the integument. Single-celled organisms with discrete nuclei (Protozoa) may be found in the lumen of the intestinal tract, extracellularly in the blood or within cells of many tissues.

It should be stressed that identifying a parasite (or parasite egg) does not imply clinical disease. Many parasites coexist with their avian hosts without causing pathologic changes. Long-term symbiotic parasite-host relationships are usually characterized by benign infections compared with parasites that have been recently introduced to a new host. The fact that companion and aviary birds from widely varying geographic regions are combined creates an opportunity for exposure of a naive host to parasitic organisms that may cause few problems in their natural host. Parasites that are apathogenic in endemic avifauna can cause chronic disease or rapid death in unnatural hosts.

---

CHAPTER

36

PARASITES

---

Ellis C. Greiner  
Branson W. Ritchie

With companion and aviary bird species, parasitic infections are most common in birds that are recently imported or that have access to the ground. Some parasites are host-specific, while others can infect a wide range of avian species. Free-ranging birds should be restricted from an aviary to prevent them from serving as sources for parasites. Parasitic problems are best managed by designing facilities that restrict a bird's access to infectious stages of a parasite and by practicing sound hygiene. Birds maintained indoors or in suspended welded wire enclosures are unlikely to have parasites that have an indirect transmission cycle. In contrast, parasitic infections are common in countries where birds are maintained in walk-in type aviaries with access to the ground.

Treatment for parasitic infections should include appropriate anthelmintics (when available) and management changes that will prevent reinfection (Table 36.1). Relatively apathogenic parasites may cause severe clinical disease in birds that are immunosuppressed or stressed or have concomitant infections.

**TABLE 36.1 Suggested Parasite Treatments**

Parasites	Therapy
<i>Haemoproteus</i>	Not recommended in asymptomatic birds
<i>Leucocytozoon</i>	Pyrimethamine, Clopidol (0.0215 to 0.025%) in food as preventative
<i>Plasmodium</i>	Chloroquine phosphate, Primaquine
<i>Giardia</i>	Metronidazole
<i>Histomonas</i>	Iprnidazole, Dimetrodazole
<i>Atoxoplasma</i>	See text
<i>Cryptosporidium</i>	No effective therapy
<i>Sarcocystis</i>	Pyrimethamine, Trimethoprim, Sulfadiazine
Cestodes	Praziquantel
Ascarids	Pyrantel pamoate, Piperazine
<i>Oxyspirura</i>	Ivermectin
<i>Capillaria</i>	Mebendazole, Fenbendazole, Ivermectin (resistant strains occur)
<i>Syngamus</i>	Ivermectin, Physical removal
<i>Knemidokoptes</i>	Topical ivermectin
<i>Sternostoma</i>	Ivermectin, Physical removal
Gapeworms	Thiabendazole, Mebendazole
Trichomonads	Dimetronidazole, Metronidazole
Coccidia	Metronidazole

Life cycles for most avian parasites are poorly understood. Much of the currently available information is based on comparative data from similar taxa in other

hosts. Diagnostic stages of most avian parasites have not been matched to the adults of the same species and thus characterization is usually limited to order or superfamily. Avian parasitology will be enhanced by cooperation among aviculturists, avian veterinarians and parasitologists.

## Diagnosis of Parasites

Parasitic infections in birds may be diagnosed through examining samples from living birds or through necropsy of affected individuals or representatives of flocks.

It is important to determine which parasites are present because: 1) related parasite/host systems may cause clinical signs similar to the ones being observed, providing the clinician with information on potential life cycles; 2) determining which groups of parasite(s) are present will ensure the selection of appropriate antiparasitic agents; and 3) determining a potential source of infection would help in designing a preventive program for individual birds and the flock.

**TABLE 36.2 Common Parasites in Companion Birds**

<b>African Grey Parrots</b>	Tapeworms (common), blood parasites* (occasional)
<b>Australian Parakeets</b>	Proventricular worms (common), nematodes (frequent)
<b>Budgerigars</b>	<i>Trichomonas</i> (common), <i>Giardia</i> (common)
<b>Canaries</b>	Air sac mites
<b>Cockatiels</b>	Ascarids* (common), <i>Giardia</i> (frequent)
<b>Cockatoos</b>	Tapeworms (common), <i>Haemoproteus</i> ,* microfilaria,* liver flukes*
<b>Finches</b>	Air sac mites, tapeworms (common), <i>Trichomonas</i> *
<b>Lorikeets</b>	Coccidia, roundworms* (frequent)
<b>Macaws</b>	<i>Capillaria</i> (frequent, imports), ascarids* (common)
<b>Toucans</b>	<i>Giardia</i> (common), coccidia (frequent)

\* Relatively uncommon in captive-bred birds in the United States

### Diagnosis in the Living Bird

Depending on the parasite, appropriate antemortem diagnostic samples could include feces, blood, tissue

**GREINER'S TENETS FOR FECAL EXAMINATION<sup>44</sup>**

1. Examine an adequate quantity (1 to 2 grams) of fresh feces. Some nematode eggs will larvate if allowed to age, producing atypical eggs or larvae that are difficult to identify. Some parasitic forms (trophozoites of *Giardia* for example) are fragile and will perish if the sample is not examined immediately.
2. Collect feces per cloaca or from nonabsorbent cage lining such as waxed paper or aluminum foil. Using nonabsorbent material to collect feces provides a moist sample of greater volume when compared to scraping a sample off newsprint or paper toweling. Samples collected from corn cob, wood shavings or cat litter should not be considered diagnostic.
3. Conduct the test that specifically demonstrates the parasite that is most likely to be causing the clinical changes. Fluke eggs cannot be demonstrated by flotation. Trophozoites of *Giardia* and *Trichomonas* will be destroyed if placed into saturated salt or sugar flotation solutions. *Giardia* trophozoites die in tap water and are best identified by using warm saline or lactated Ringer's solution as a diluent.
4. Examine each prepared sample completely and systematically. The low power objective (10x) should be used for scanning. The high dry objective can be used to magnify and examine a particular structure. Scan the coverslip beginning at one corner and traversing the length of the coverslip, then move the slide to the next field of view and reverse the field of movement. Repeating this procedure until the entire coverslip has been viewed will provide a systematic examination of the total preparation and reduce the likelihood of missing a parasite. Examine the entire slide and do not stop when eggs of one kind have been identified. Some helminths produce very few eggs that may not be detected unless the entire slide is examined.
5. Standardize procedures so that results are repeatable and comparable. If a diagnostic technique is not standardized, the results are of limited value. Egg counts are of little value because there is no direct correlation between the number of eggs per gram of feces and the number of adult parasites present. Comparing egg counts between treated and untreated birds may provide some information on the effect of an anthelmintic.

biopsies or integument for the detection of intact parasites, eggs or intermediate life forms. Specific diagnostic procedures are dictated by the size and species of bird, clinical signs and the types of parasites that might be contributing to the problems.

Egg characteristics that should be evaluated include shape, size (determined by using a calibrated ocular micrometer), color (colorless, yellowish to brown), texture (smooth, pitted, mammillated), single operculum, bipolar plugs, stage of development (single cell, morula or larvae) and type of larva present in the egg (nematode larva, hexacanth larva, miracidium or acanthor).

The diagnostic stage of most avian helminths is an egg that is detected in the feces by either flotation or sedimentation. The flotation method will remove ex-

traneous debris and concentrate the eggs of nematodes, cestodes and acanthocephala and the cysts and oocysts of protozoa. The most generally used flotation medium is saturated sodium nitrate (568 g sodium nitrate/ 1000 ml water). Sheather's sugar solution (500 g table sugar, 320 ml water and 6.5 g phenol crystals) is most commonly used to detect coccidian oocysts. Saturated zinc sulfate (336 g zinc sulfate/ 1000 ml water) is best for concentrating cysts of *Giardia* and may be better for detecting spiruroid eggs than sodium nitrate.

Flotation can be performed by mixing feces in a volume of flotation medium and passing the mixture through a piece of double-layer gauze or cheesecloth placed on top of a vertical tube. The tube should be filled until a slight positive meniscus is formed. A coverslip is placed on top of the tube and allowed to stand for ten minutes. As an alternative technique, the feces can be placed on a gauze pad on top of a 15 ml centrifuge tube and washed with lactated Ringer's solution. The collected fluid is then centrifuged at 1200 to 1500 rpm for ten minutes and the sediment is mixed in the appropriate flotation medium. The coverslip from either method is then examined microscopically.

**TABLE 36.3 Best Tests for Detecting Avian Parasites**

Parasite	Test
<i>Hexamita</i> , <i>Giardia</i> , <i>Trichomonas</i>	Fresh direct mount with warm LRS (not H <sub>2</sub> O)
Coccidia oocyst	Flotation - Sheather's sugar
<i>Giardia</i> , spiruroid eggs	Flotation - Zinc sulfate
Nematodes, cestodes, acanthocephala	Flotation - Sodium nitrate
Flukes	Sedimentation
<i>Plasmodium</i> , <i>Haemoproteus</i> , <i>Leucocytozoon</i> , <i>Atoxoplasma</i> , <i>Trypanosoma</i> , microfilaria	Blood smear - Wright's stain (see Color 9)
Microfilaria, <i>Trypanosoma</i>	PCV tube, inspect at blood plasma interface using microscope


Fecal sedimentation is used primarily for the detection of fluke eggs that do not float in commonly used media. Feces is mixed in a liquid soap-in-water solution (0.1 to 1%) and allowed to stand for five minutes without centrifugation. The supernatant is gently removed and the tube is refilled with soapy water and allowed to stand for another five minutes. This procedure removes particulate material and concentrates the fluke eggs. It can also be used in place of flotation to detect eggs and cysts but is more time-consuming and may not be as sensitive as a flotation method.

A direct smear is best for detecting motile protozoan trophozoites (*Giardia*, *Trichomonas* or *Hexamita*). Samples are not diagnostic if they are more than 15 minutes old. Feces or tissue swabs are mixed with LRS or normal saline (0.85% sodium chloride), not tap water. The proper density of the preparation is achieved when newsprint can be easily read through the preparation. The microscope light should be adjusted to provide maximum contrast. The morphology of the parasites may be confirmed by fixing feces in polyvinyl alcohol and staining a slide preparation with trichrome.

Blood films are used to detect avian hematozoa, including microfilariae of filarial worms. Commonly identified blood parasites include intracellular stages of *Plasmodium*, *Haemoproteus*, *Leucocytozoon* and "*Atoxoplasma*," and extracellular stages of *Trypanosoma* and microfilariae from various filarial worms. Blood smears may be made on microscope slides or on coverslips. Coverslips have the advantage of being in view when mounted on slides and the sample is protected from being wiped off the slide. Giemsa or Wright's/Giemsa staining procedures provide the best results and long lasting stain quality (see Chapter 9). Alternatively, blood may be collected in a hematocrit tube and centrifuged, and the plasma/cell interface examined.

Arthropods collected for identification should be fixed and stored in 70% ethanol. Larvae of myiasis-causing flies should be killed by placing them briefly in boiling water and then transferring them to 70% ethanol. Mites, ticks, fleas and lice can be placed directly into 70% alcohol. Arthropods may be removed from the skin or feathers with forceps, or those living under crusting skin can be collected by scraping the encrusted area with a dull scalpel and allowing the crusts to fall into a petri dish containing 70% ethanol. A dissecting microscope can be used to demonstrate the mites. Arthropods present in the choanal slit can be collected with a moistened cotton-tipped swab.

Feather mites can be collected by placing the affected feather in 70% ethanol. Quill mites (ones living in the shaft of the feather) may be detected by microscopically examining the transparent portion of plucked primary feathers or coverts. These parasites can be recovered by slitting the shaft lengthwise and placing it in alcohol. Lice can be located by running a finger through the feathers. Bird fleas can be manually removed. However the mouth parts of some fleas, such as *Echidnophaga*, may remain attached to the



**FIG 36.1** Many of the biting and chewing flies that live in and on the feathers of birds (such as this hippoboscidae) are flattened and move quickly, making it difficult to collect them for identification.

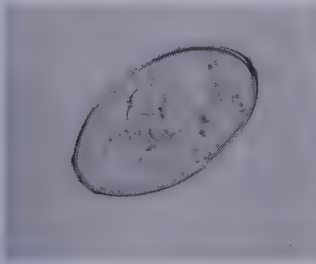bird (see Color 8). Hippoboscid flies are flattened, move rapidly under the feathers and are difficult to catch (Figure 36.1). The use of a pyrethrin-based flea spray, designed for puppies and kittens, is a safe and easy way to collect topical parasites from birds. A minimal dose (one drop under each wing of a cockatiel) is effective.

### Diagnostic Stages Found in Birds

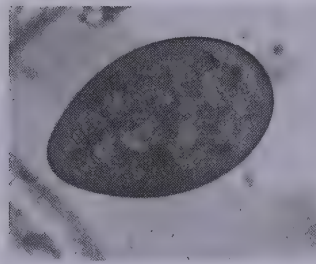
The following information is a review of the few references on the partial or generic identification of parasitic life stages passed by birds. Figures 36.2 to 36.4 illustrate fluke eggs that were detected from sedimentation. Helminth eggs that were recovered by flotation are shown in Figures 36.5 to 36.8. Figures 36.9 to 36.21 are nematodes eggs. Figure 36.22 is the egg of an acanthocephalan and Figure 36.23 is a mite egg. Most mite eggs are large (100  $\mu\text{m}$ ) and often contain a larva with jointed legs. Note all mite eggs seen in fecals do not indicate acariasis as some are normal grain mites being consumed in the bird's food. Figures 36.24 to 36.27 are coccidian oocysts that have been sporulated. They would appear with a granular spherical mass in the center of the oocyst when passed in the feces, and must be sporulated to determine the genus.

### Diagnosis in Dead Birds

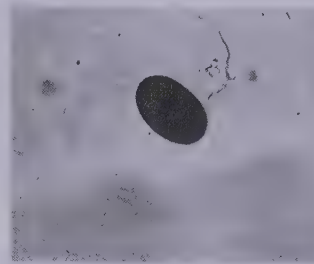
Any bird that dies should be necropsied and tissues should be collected for histopathology. If parasites are identified, they should be collected for classification. Gross and histologic lesions should be correlated with any recovered parasite to determine if the



**FIG 36.2** *Orchipedium* egg from Sandhill Crane, 77 x 45  $\mu\text{m}$ , with prominent operculum.



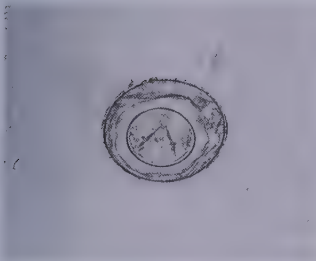
**FIG 36.3** Strigeid egg from Bald Eagle, 95 x 60  $\mu\text{m}$ , with obvious operculum.



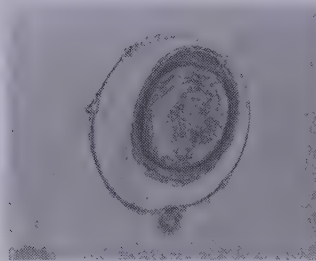
**FIG 36.4** Dicrocoelid egg from macaw, 33 x 22  $\mu\text{m}$ , with inapparent operculum and typical dark brown coloration.



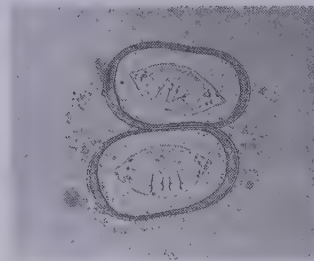
**FIG 36.5** *Raillietina* tapeworm egg packet from an African Grey Parrot, clear halo, 223 x 193  $\mu\text{m}$ , several eggs each with oncosphere bound in a gelatinous mass.



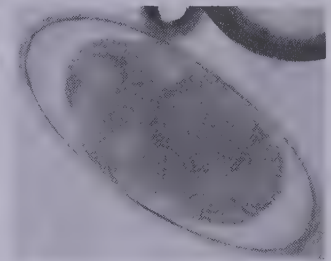
**FIG 36.6** Tapeworm egg from peafowl, 50 x 38  $\mu\text{m}$ , note 2 of 3 pairs of oncosphere hooks in focus.



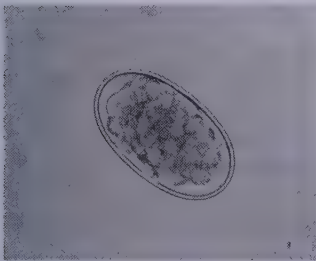
**FIG 36.7** Tapeworm egg from cockatiel, 74 x 68  $\mu\text{m}$ , outer membrane intact and most hooks on oncosphere in focus.



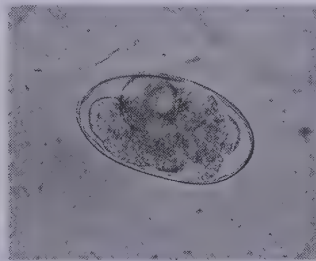
**FIG 36.8** Tapeworm egg (possibly *Pulluterina* sp.) from unidentified parrot, 62 x 26  $\mu\text{m}$ , four of six hooks on oncosphere in focus and rectangular shell with distinctive shape of oncosphere.



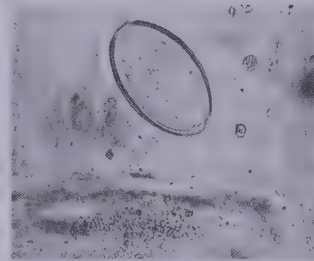
**FIG 36.9** *Deletrocephalus* egg from rhea, 169 x 77  $\mu\text{m}$ , very large.



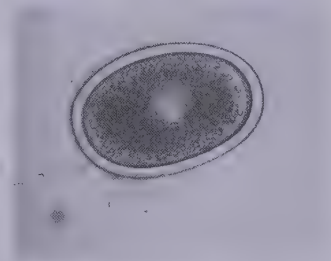
**FIG 36.10** *Codiostomum* egg from ostrich, 60 x 35  $\mu\text{m}$ .



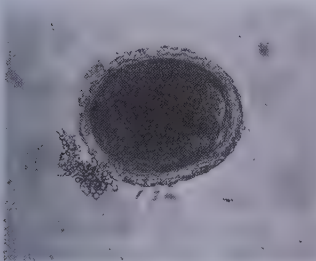
**FIG 36.11** *Trichostrongylus* egg from wild turkey, 67 x 37  $\mu\text{m}$ .



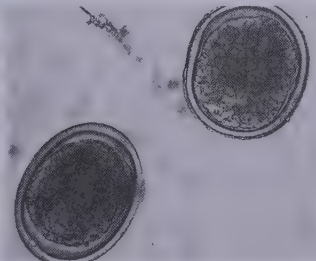
**FIG 36.12** *Syngamus* egg from Barred Owl, 54 x 33  $\mu\text{m}$ , note shape and polar plugs.



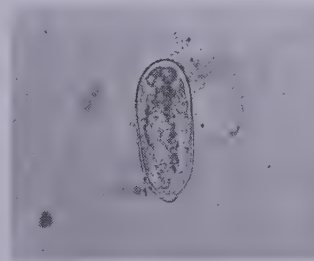**FIG 36.13** *Ascaridia* egg from macaw, 77 x 52  $\mu\text{m}$ , smooth, thick, ellipsoid shell.



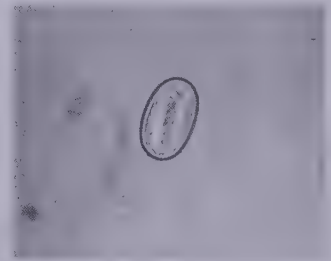
**FIG 36.14** *Porrocaecum* egg from Bald Eagle, 66 x 55  $\mu\text{m}$ , rough-walled, subspherical shape.



**FIG 36.15** *Contraecaecum* egg from pelican, 65 x 50  $\mu\text{m}$ , smooth egg wall and subspherical.

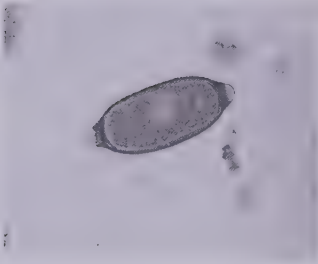


**FIG 36.16** *Habronema*-like egg from macaw, 57 x 22  $\mu\text{m}$ , elongated, larvated.

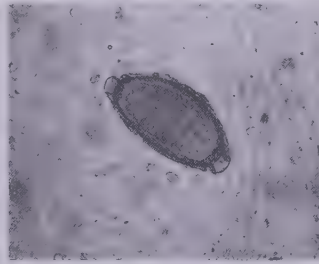


**FIG 36.17** Spiruroid egg from cockatiel, 35 x 22  $\mu\text{m}$ , thick-walled, symmetrical and larvated.

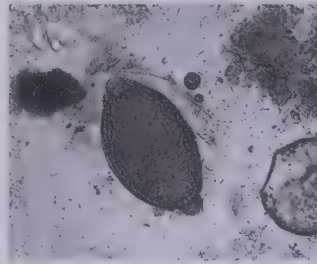
Figures 36.2 through 36.27 courtesy of Ellis Greiner.



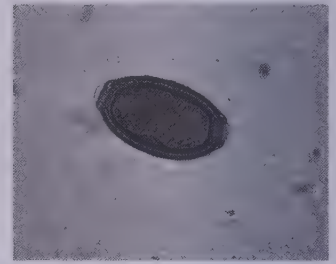
**FIG 36.18** *Capillaria* egg from Bald Eagle, 62 x 29  $\mu\text{m}$ , bipolar plugs and pitted wall.



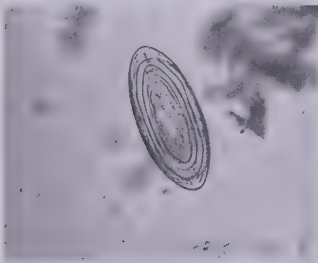
**FIG 36.19** *Capillaria* egg from Barred Owl, 59 x 29  $\mu\text{m}$ .



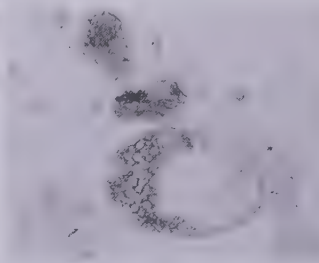
**FIG 36.20** *Capillaria* egg from Great Horned Owl, 64 x 36  $\mu\text{m}$ .



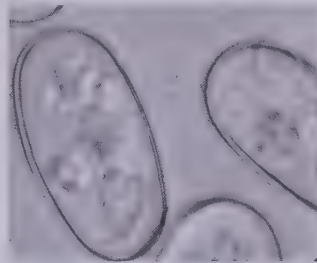**FIG 36.21** *Capillaria* egg from pigeon, 52 x 31  $\mu\text{m}$ .



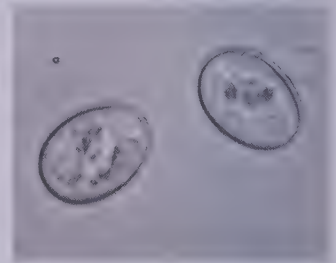**FIG 36.22** *Centrorhynchus* egg (an acanthocephalan), 58 x 23  $\mu\text{m}$ , laminated-appearing egg with central larva (acanthor).



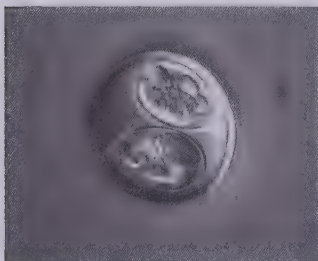
**FIG 36.23** Mite egg from peafowl, 157 x 134  $\mu\text{m}$ .



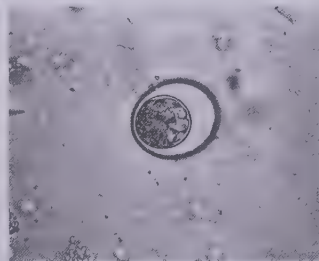
**FIG 36.24** *Eimeria* oocyst from Blue-fronted Amazon, 47 x 25  $\mu\text{m}$ , note the 4 sporocysts each with two sporozoites.



**FIG 36.25** *Eimeria forresteri* oocyst from Toco Toucan, 23 x 18  $\mu\text{m}$ , same sporocysts arrangement as Figure 36.24.



**FIG 36.26** *Isospora* oocyst from House Sparrow, 25 x 25  $\mu\text{m}$ , note 2 sporocysts each with four sporozoites.



**FIG 36.27** *Caryospora* oocyst from Red-shouldered Hawk, 36 x 31  $\mu\text{m}$ , note single sporocyst and eight sporozoites.

organism is contributing to a specific set of clinical changes (Figure 36.28).

It is always a good policy to contact the parasitologist and request special submission instructions. Parasites for classification should be collected from each affected organ, placed in separate containers and fixed as discussed below. The host species, host identification number, location of parasite in the host and date collected should be written in soft pencil on a good quality white paper and included in the vial with the specimens. Other useful information includes whether the bird was imported or captive-raised, its duration in captivity and the number of birds affected.

The complete gastrointestinal tract should be opened lengthwise, section by section. In small birds, each section of bowel may be opened in a series of petri dishes containing water. In large birds, the bowel contents should be washed through #40 and #100 standard sieves. The mucosa should be scraped to free attached helminths, and the residue on the sieve should be back-flushed into a dish and evaluated for the presence of parasites. Detection and recovery of helminths can also be accomplished by placing the gut contents into one-liter flasks and allowing a sediment to form. This procedure is repeated until the water remains clear. Parenchymous organs should be sequentially sliced and evaluated for the presence of helminths. The body cavities, air sacs and orbits of the eyes should be examined grossly for worms. Skin over swellings on the feet or legs should be excised, and the area should be examined for the presence of adult filarial worms. All recoverable parasites should be collected to maximize the information that can be ascertained from the infection.

Nematodes should be placed briefly in full-strength glacial acetic acid or hot 70% ethanol. This process should kill and fix the nematodes in a straight, uncoiled manner. They should then be transferred into glycerin alcohol (9.0 parts 70% ethanol and 1.0 part glycerin) for storage.





**FIG 36.28** An adult African Grey Parrot was presented with a two-week history of progressive diarrhea. The bird was emaciated and dehydrated and had dried excrement around the vent. The bird did not respond to supportive care and died several hours after presentation. Tapeworms (arrows) were identified in the intestinal tract. Note the dark (hemorrhagic) bowel loops.

Cestodes should be relaxed in tap water in a refrigerator for two to four hours and then fixed in AFA (8.5 parts 70% ethanol, 1.0 part full strength formalin and 0.5 part glacial acetic acid). The parasites collected should have an intact scolex (holdfast), which is important in tapeworm identification.

Trematodes should be relaxed by placing them in tap water in the refrigerator for 30 to 60 minutes. Thin-bodied flukes should be placed into AFA. Thick-bodied flukes should be gently held in place between two glass microscope slides while AFA is instilled between the slides. After a few minutes, the top slide is removed.

Acanthocephalans should be gently removed from the gut wall to prevent rupture of the parasite, which will destroy the hydraulic system that extends the proboscis (making identification of the parasite nearly impossible). Acanthocephalans may lose their torpor and detach from the gut wall when the host dies. They may then resemble a yellowish to whitish, short, wrinkled tapeworm. Placing the parasite into tap water overnight in a refrigerator may cause the proboscis to extend, at which point the parasite is fixed in AFA.

A fecal examination should be performed at necropsy so that eggs detected by fecal flotation or sedimentation can be compared to the eggs in the adult worms.

## Clinically Significant Parasites

### Protozoa

The single-celled parasites include the malarial parasites (*Plasmodium* spp.) and their relatives (*Haemoproteus* spp. and *Leucocytozoon* spp.), the coccidians (*Eimeria*, *Isospora*, *Sarcocystis* and *Toxoplasma*), the microsporidians (*Encephalitozoon*) and flagellates in the gastrointestinal tract (*Giardia*, *Trichomonas* and *Hexamita*) and the peripheral circulation (*Trypanosoma*) (Table 36.5).

### Gastrointestinal Flagellates

Protozoans with flagella that reside in the gastrointestinal tract of psittacine birds include *Trichomonas gallinae*, *Hexamita* and *Giardia* spp.

- ***Trichomonas*:** Trichomonads do not require an intermediate host or vector and are transmitted through direct contact or through ingestion of contaminated water or food. Infected adults can transmit the parasite to their chicks during feeding activities. Parental feeding of young is an effective method of parasite transmission. There is no resistant cyst form, and only the motile trophozoite has been described. This extracellular parasite measures 8 to 14  $\mu\text{m}$  in length (may vary in different host species), has four free anterior flagella and possesses an undulating membrane that creates a wave-like appearance along the cell surface. It moves in a jerky manner and the body diameter remains constant as it moves.

Depending on the species, infections may be localized in the mouth, oropharynx, esophagus, crop and trachea, or the pulmonary and hepatic tissues can be invaded. Pathogenic strains cause inflammation and white plaques on the gastrointestinal mucosa or necrosis with an accumulation of cheesy material that might occlude the esophagus and trachea. Overcrowding and poor hygiene may potentiate infections in individual birds as well as increasing the incidence of disease in a flock. Infections in young birds are generally associated with poor growth and high mortality. In adult birds, infections are usually characterized by emaciation, dyspnea or vomiting. A pathogenic strain caused the death of all ages of naive pigeons four to 18 days after infection. Blue-fronted Amazon Parrots, cockatiels and budgerigars are

known to be susceptible.<sup>40,54,79,104</sup> Trichomoniasis is particularly common in pigeons and raptors (frounce) (see Chapter 8). Pathogenic and nonpathogenic strains of *T. gallinae* have been described in pigeons; thus, not all infections may be a threat to the host. Feeding pigeons to captive raptors (especially species that do not normally eat pigeons such as eagles and large hawks) may result in the transmission of *Trichomonas*. Advanced cases with large necrotic masses are difficult to treat and generally have a poor prognosis (see Chapter 19).

- **Giardia:** The *Giardia* sp. recovered from budgerigars appears to be morphologically distinct from those found in other animals and has been identified as *G. psittaci*.<sup>31</sup> Most reports of giardiasis in psittacine birds involve budgerigars, cockatiels, lovebirds and Grey-cheeked Parakeets. Rarely, infections may be detected in Amazon parrots, conures, cockatoos, macaws, toucans, Galliformes and Anseriformes.<sup>15,98,97</sup> *Giardia* has not been reported in finches or canaries.

*Giardia* sp. is commonly found in the feces of asymptomatic adult budgerigars and cockatiels, suggesting an asymptomatic carrier state (see Color 8). In a group of 77 parakeets from several sources, 66% of the birds were found to be shedding *Giardia*.<sup>84</sup> In another study, 70% of cockatiels, 55% of budgerigars, 25% of lovebirds, 5% of Grey-cheeked Parakeets and less than 5% of other psittacine birds were found to be shedding giardia. Asymptomatic birds may intermittently shed the parasite.<sup>84</sup>

Psittacine birds with giardiasis may be asymptomatic, or the birds may exhibit signs of loose, malodorous stools, mucoid diarrhea, debilitation, gram-negative enteritis, anorexia, depression, recurrent yeast infections, eosinophilia and hypoproteinemia. Dry skin and feather picking, particularly in the carpal-metacarpal, flank, axilla and lower leg areas, has been described as a clinical sign of giardiasis in budgerigars and cockatiels (see Chapter 24). Giardiasis can cause poor growth and high mortality in budgerigar and cockatiel neonates. Mortality rates of 20 to 50% have been described in some infected budgerigar flocks.<sup>84</sup>

In mammals, *Giardia* is frequently considered an opportunistic pathogen that requires an immunocompromised host. The role that the immune system plays in preventing a bird from developing giardiasis has not been determined. However, many clinically affected psittacine birds are fed marginal diets, are maintained in overcrowded, hygienically unsound

conditions or are heavily inbred. Birds that recover from an infection are susceptible to re-infection indicating that a long-lasting protective immune response does not occur with infection.

*Giardia* spp. have a motile trophozoite and a cyst stage that can be identified in the feces or from mucosal scrapings collected at necropsy (Figure 36.29). Direct transmission occurs following the ingestion of food contaminated with feces from infected birds. The environmentally stable cysts can serve as a source of infection to other hosts. *Giardia* trophozoites are not stable outside of the host.

Cytologic preparations must be examined within ten minutes of collection or trophozoites may not be recognized. False-negative results are common if the feces is over ten minutes old when it is examined. Trophozoites are flat and move in a smooth rolling manner. If a fecal sample cannot be examined immediately, it should be fixed in polyvinyl alcohol for trichrome staining.

Multiple, fresh, direct fecal smears stained with carbol fuchsin (one minute) or iodine may help in detecting trophozoites (see Color 8). Flotation techniques with zinc sulfate may improve the accuracy of a



**FIG 36.29** Electronmicroscopic view of giardia attached to the mucosal lining of the intestine (courtesy of Kenneth Latimer).

diagnosis. Trophozoites can range from 10 to 20  $\mu\text{m}$  in length and 5 to 15  $\mu\text{m}$  in width, depending on the host or type of fixation. The trophozoites have eight paired flagella (including an anterior and trailing posterior pair), two nuclei and a sucking disc that occupies most of the rounded end. The trophozoites attach to the surface of the villi in the small intestine. The sucking disc may be seen if the light is adjusted to maximize contrast. Cysts are believed to be intermittently shed in the feces, and multiple samples must be examined before considering that a bird is uninfected. The cysts measure 10-14  $\mu\text{m}$  x 8-10  $\mu\text{m}$  and contain four nuclei and fibrillar structures. ELISA tests have been developed to detect *Giardia* spp. in humans, but their efficacy for use in birds has not been evaluated.

Keeping the aviary as clean and dry as possible will reduce the viability and number of cysts available for transmission. Relapses are common after treatment either from endogenous parasites that are not destroyed or from reinfection from exposure to environmental reservoirs. Contaminated water supplies have been discussed as a method of repeated exposure of mammals to *Giardia* and may serve as a source of infection in birds. *Giardia* cysts survive the standard chlorination of water. *Giardia* appear to be limited in host range, and species isolated from birds have not been found to be infectious in mammals.

- **Hexamita:** *Hexamita* sp. has been detected in emaciated Splendid Grass Parakeets and cockatiels and can cause loose stool and weight loss.<sup>51</sup> This genus has a trophozoite with eight flagella and two nuclei as does *Giardia*, but it lacks the sucking disc and is often truncated in appearance. Cysts are probably the infectious form. Generally, *Hexamita* is smaller than *Giardia*, swims in a smooth linear fashion and may be associated with chronic diarrhea. *Hexamita* has been described as a cause of disease in lorries. Demonstration of the parasite is common in asymptomatic pigeon feces and does not appear to cause a problem unless the birds are maintained in poor condition.
- **Histomonas:** Histomoniasis is common in gallinaceous birds. The induced disease is called blackhead and is caused by a flagellated protozoan parasite (*Histomonas meleagridis*) (see Color 20). In some birds, this parasite is considered a major pathogen while in other birds it is considered an incidental finding. When lesions occur, they generally include hepatomegaly (with necrosis) and ascites. Histomonads have also been described in the liver of several non-gallinaceous birds.

Most infections occur following the ingestion of infected embryonated eggs of the cecal worm *Heterakis gallinarum*. The histomonads are released from the larvae and invade the wall of the cecum where they may cause ulceration or small nodules. Parasites in the liver can cause severe hepatocellular necrosis.<sup>30</sup>

### Coccidia

Coccidian parasites include a variety of life styles and means of transmission. Oocysts of most genera are passed unsporulated. They are typically less than 45  $\mu\text{m}$  in length, contain a granular-appearing spherical body (sporoblast) and may be round, ellipsoid or ovoid. There may be a thinning of the wall (the micropyle), and if the micropyle is present, it may have a cap. The wall may be smooth, mammillated or pitted and colorless to dark brown.

Coccidia are common in mynahs, toucans, pigeons, canaries, finches and lorries (Figures 36.24, 36.27). By comparison, infections are rare in captive Amazon parrots. Infections in mynahs and toucans rarely cause clinical changes unless the birds are maintained in crowded, unsanitary conditions. Clinical disease is occasionally seen in canaries and finches. Coccidiosis is a major cause of enteritis in Columbiformes and Galliformes.

- **Eimeria and Isospora:** Two species of *Eimeria* and one of *Isospora* have been described in psittacines (see Figure 36.24). *Eimeria dunsingi* oocysts are ovoid, lack a micropyle and are 26-39 x 22-28  $\mu\text{m}$ . *E. haematodi* has broad ovoid oocysts with a large micropyle and measures 25-40 x 21-35  $\mu\text{m}$ .<sup>108</sup> *Isospora psittaculæ* are round to broadly elliptical and measure 29-33 x 24-29  $\mu\text{m}$  (see Figure 36.26). Sporulated oocysts of *Eimeria* are subdivided into four sporocysts each with two sporozoites, whereas with *Isospora*, the oocysts have two sporocysts each with four sporozoites. *Eimeria* and *Isospora* have direct life cycles. *Isospora canaria* completes its life cycle in the intestines. *E. dunsingi* has been discussed as being pathogenic, but support for this claim is lacking. In general, some cases of coccidiosis are associated with severe clinical disease, while other birds will pass numerous oocysts in the feces and remain asymptomatic.

*Isospora* is most common in Passeriformes, Psittaciformes and Piciformes, and *Eimeria* is most common in Galliformes and Columbiformes. Infected birds may be asymptomatic or develop clinical signs of melena, depression, diarrhea, anorexia and death. Direct transmission occurs through ingestion of fecal-contaminated food or water.

▪ ***Atoxoplasma*:** *Atoxoplasma* spp. may cause disease in canaries and other Passeriformes. Adults are generally asymptomatic carriers that shed oocysts in the feces. Prevalence can be high in young birds during fledging. The *Atoxoplasma* sp. found in House Sparrows was not found to be infectious to canaries, indicating a degree of host specificity.<sup>16,17</sup>

Mortality can approach 80% in juvenile birds between two and nine months of age.<sup>28</sup> Clinical signs are nonspecific including depression, anorexia and diarrhea. Birds less than a year of age are most likely to develop clinical changes.<sup>36,85</sup> Clinical signs may occur in birds that are or are not shedding oocysts in the feces. An enlarged liver and dilated bowel loops can occasionally be observed through the transparent skin (see Color 20). With severe infections, zoite forms of the parasite may be demonstrated in lymphocytes using Romanowsky staining methods (see Color 9).<sup>36</sup>

*Atoxoplasma serini* has an asexual reproductive cycle in the mononuclear cells, and spreads through the blood to parenchymal organs where it infects reticuloendothelial and intestinal epithelial cells. *Atoxoplasma* spp. may be diagnosed by finding 20.1 x 19.2 µm oocysts in the feces or by demonstrating reddish intracytoplasmic inclusion bodies in mononuclear cells (Giemsa stain). Staining a buffy coat may improve the diagnostic sensitivity of blood smears. Transmission is direct through ingestion of contaminated feces. Canaries have been found to shed for eight months following infection.<sup>36</sup> Infected birds can intermittently shed large numbers of oocysts. Coccidial oocysts are environmentally stable and are not killed by most disinfectants.<sup>85</sup>

In a group of infected canaries, atoxoplasmosis could be identified in impression smears of the heart, liver and pancreas using Giemsa stain. Atoxoplasmosis was the cause of death in two young Bali Mynahs. Oocysts were identified in the feces from young and adult birds in the affected group. Gross lesions in the mynahs included pinpoint white foci in the liver, splenomegaly, a swollen pale nodular pancreas and pericardial effusion (see Color 20).<sup>85</sup>

No effective therapy for atoxoplasmosis has been described, but primaquine has been suggested to suppress the tissue form of the parasite, and sulfachlor-pyrazine may decrease oocyst shedding. *Atoxoplasma* infections may persist for over four months, while *Isospora* infections are usually resolved within several weeks.<sup>36</sup>

▪ ***Cryptosporidium*:** *Cryptosporidium* are spheroid-to-ovoid protozoa that infect and may cause disease in the mucosal epithelial cells lining the gastrointestinal, respiratory and urinary tracts of birds.<sup>3,42,67</sup> *Cryptosporidium* develop intracellularly at an extra-cytoplasmic location on the apical surface of epithelial cells. This is in contrast to other coccidia, which replicate in the cytoplasm.<sup>70</sup> *Cryptosporidium* oocysts are the smallest of any coccidia, usually measure 4 to 8 µm in diameter and contain four naked sporozoites.

Cryptosporidiosis has been documented in Galliformes, Anseriformes, Psittaciformes, ostriches, canaries and finches (Table 36.4). Limited data suggest that cryptosporidial infections may be transmitted among closely related species, which should be considered when managing this coccidia in a collection. In the respiratory tract, *Cryptosporidium* may inhibit normal function of the mucociliary elevator, and have been associated with depression, anorexia, rhinitis, conjunctivitis, sinusitis, tracheitis, airsacculitis, coughing, sneezing and dyspnea in gallinaeous birds, ducks, geese and budgerigars. At necropsy, there may be an excessive amount of mucus in the respiratory tree.<sup>42</sup>

TABLE 36.4 Location of Cryptosporidiosis Lesions by Species

	Respiratory Tract	GI Tract	Urinary Tract
Chickens	x	x	x
Ducks	x		
Turkeys	x	x	
Peafowl	x		
Pheasants	x		
Quail	x	x	
Junglefowl	x		x
Geese		x	
Psittaciformes		x	
Finches			x

In the GI tract, *Cryptosporidium* may infect the salivary glands, intestines, colon, cloaca and cloacal bursa, resulting in enteritis (diarrhea) in gallinaeous birds, Amazon parrots, budgerigars, macaws, cockatiels, lovebirds and cockatoos.<sup>10,29,42</sup> Postmortem findings with gastrointestinal cryptosporidiosis may include dilated intestines containing yellowish fluid and blunting fusion and atrophy of intestinal villi.<sup>10</sup> Cryptosporidiosis caused cuboidal metaplasia of glandular epithelium in the proventriculus in a finch that died following an acute onset of diarrhea.<sup>13</sup> Proventricular lesions have also been described in in-

fecting canaries.<sup>107</sup> Cryptosporidial renal disease has been described in gallinaceous birds and finches. The kidneys of both birds were enlarged and pale.<sup>42,68</sup>

In some cases *Cryptosporidium* is considered a primary pathogen; however, in most situations it is considered to cause severe infections only in immunocompromised hosts. Suggestive of the opportunistic nature of *Cryptosporidium* was the detection of the parasite in four cockatoos with PBFV virus. In three birds, the parasite remained localized to the epithelium of the cloacal bursa. In the other bird, *Cryptosporidium* was present throughout the large intestines, small intestines and bursa (see Figure 32.16).<sup>65</sup>

*Cryptosporidium* sp. was identified by Sheather's flotation in 14 of 165 (8.5%) adult ostriches in a quarantine station. The number of parasites varied from a few to several million per gram of feces. There were no clinical signs in any of the birds in which *Cryptosporidium* was identified. *Cryptosporidium* recovered from the ostriches was not infectious to two-day-old chickens inoculated orally. None of the birds in this study had clinical signs of infection, but the possibility exists that *Cryptosporidium* could cause problems in young or immunocompromised birds.<sup>39</sup>

This coccidian parasite can be transmitted through the ingestion or inhalation of sporulated oocysts. The life cycle is direct. *Cryptosporidium* undergoes endogenous sporulation resulting in autoinfection in the parasitized host. As few as 100 oocysts can induce severe enteritis and diarrhea in experimentally infected Bobwhite Quail in the company of reovirus.<sup>50</sup>

*Cryptosporidium* spp. are sporulated when shed in the feces so the frequent cleaning regimes that are used to control other coccidia are ineffective in preventing exposure to cryptosporidial oocysts. *Cryptosporidium* is resistant to many disinfectants. Formal saline (10%), ammonia (5%) and heating to 65°C for 30 minutes have been suggested as effective control measures for *Cryptosporidium*.<sup>105</sup>

The small size of the organism (4 to 6 µm) and low shedding rate make diagnosis of infection difficult. Diagnosis can be improved by centrifuging diluted feces in a high-concentration salt solution or using Sheather's flotation. Fecal smears stained with Giemsa, carbofuchsin or PA Schiff stains may be used to demonstrate oocysts. With modified acid-fast stain, *Cryptosporidium* stains pink against a blue background. *Cryptosporidium* oocysts were identi-

fied in the feces of budgerigars, parrots and macaws using Auramine O.<sup>66</sup>

*Cryptosporidium* spp. that infect birds are different from the species that infect mammals and there is no known zoonotic potential.

- **Toxoplasma:** *Toxoplasma* is a coccidian parasite with an indirect life cycle. Toxoplasmosis, causing fatal infections in most species, has been documented in the Red Lory, Swainson's Lorikeet, Regent Parrot, Superb Parrot and Crimson Rosella.<sup>52,57</sup> *Toxoplasma gondii* is considered a ubiquitous organism with a broad host range, and probably could infect any mammalian or avian host. Oocysts produced and passed in the feces of infected cats would be the only source of infection to psittacine birds. Infections may cause congestion and consolidation of the lungs, hepatomegaly, vasculitis and necrotic foci in the lungs, liver and heart.<sup>57</sup>
- **Sarcocystis:** *Sarcocystis* is a coccidian parasite that undergoes sexual multiplication in the intestine of a definitive host. *Sarcocystis falcatula* appears to be restricted to North America and has been associated with acute deaths in a variety of psittacine species. The pathogenicity of sarcocystosis in psittacine birds appears to depend on the species of bird and the infective dose of the parasite.<sup>18</sup> Severe life-threatening infections are most common in Old World Psittaciformes although neonates of New World species may also die following infection. Adult New World Psittaciformes appear to be relatively resistant (Table 36.5). The susceptibility of Old World Psittaciformes and resistance of New World Psittaciformes may reflect a lack of immunity in the former because the definitive host (and presumably the parasite) are not found in the Old World. Infections appear to be more common in the winter months and males appear to be more susceptible than females. There is no apparent age resistance and a bird over 33 years of age died in one outbreak.<sup>23,24,56,82</sup>

TABLE 36.5 Psittacines Confirmed Susceptible to *Sarcocystis*

African Grey Parrot	Military Macaw
Amazon parrots	Pesquet's Parrot
Blue and Gold Macaw	Port Lincoln Parrot
Budgerigar	Princess Parrot
Cockatiel	Red-capped Parrot
Cockatoo	Red Shining Parrot
Conures (Halfmoon, Patagonian)	Thick-billed Parrot
Eclectus Parrot	White-crowned Pionus
Great-billed Parrot	Tori Parakeet
Green Rosella	
Lories (Red)	

TABLE 36.6 Blood Parasites

Blood Parasite	Location	Some Susceptible Species	Intermediate Host	Clinical Changes
<i>Haemoproteus</i>	Gametocyte in erythrocytes, schizonts in endothelial cells	Anseriformes, Passeriformes, raptors, cockatoos, Columbiformes	Culicoides, louse flies	Rare; anemia (severe infections), reduced stamina in pigeons
<i>Microfilaria</i>	Adults in air sacs, fascial planes, tendon sheaths, pericardial sac	Psittaciformes, raptors	Culicoides, black flies, some lice, mosquitoes	Generally apathogenic, adults (tendinitis in Amazons), Pericarditis in cockatoos, Asphyxiation from occluded capillaries
<i>Trypanosomes</i>	Extracellular in blood	Passeriformes (esp. canaries), Galliformes, Anseriformes, Columbiformes, some Psittaciformes	Louse flies, mosquitoes, black flies	Minimal pathogenicity
<i>Leucocytozoon</i>	Gametocytes in leukocytes or red blood cells	Anseriformes, Galliformes, Passeriformes, Psittaciformes	Black flies, <i>Culicoides</i>	Anemia, dyspnea, death (with some species)
<i>Plasmodium</i>	Gametocytes, trophozoites, schizonts in erythrocytes or its precursors	canaries, penguins, Galliformes, Anseriformes, Columbiformes, Psittaciformes  Passeriformes (carriers)	  Mosquitoes	Anemia, dyspnea, weakness, anorexia, death  Asymptomatic, vomiting, anorexia, depression
<i>Atoxoplasma</i>	Sporozoites in lymphocytes and monocytes; schizonts, oocysts, gametocytes in internal organs	Passeriformes	None	Depression, hepatomegaly, diarrhea
<i>Babesia</i>	Erythrocytes		Ticks	Non-pathogenic

Infections are usually peracute; birds may appear normal and healthy one day and be dead the next. Experimentally infected cockatoos were found to die 10 to 14 days after oral inoculation. If clinical signs occur prior to death, they are characterized by severe dyspnea, yellow-pigmented urates and lethargy. Infected birds have been found to have high LDH and AST enzyme activities.<sup>23,24</sup>

Pulmonary edema with hemorrhage is the most consistent sign in birds that die acutely (see Color 22). Splenomegaly and hepatomegaly also are common (see Color 14). Histopathologic findings include diffuse interstitial and exudative pneumonia, reticuloendothelial cell hyperplasia and schizonts or merozoites in the capillary endothelium. The lung is the tissue of choice for diagnosis where schizonts may be noted.<sup>24,58</sup> Rarely, schizonts may be identified in the brain of birds with CNS signs.<sup>56,59</sup> Generally, psittacine birds die before sarcocysts develop in the muscles.

The two-host replication cycle of *S. falcatula* involves sexual reproduction and sporogony in the intestines of the definitive host (opossum) with passage of infectious sporulated oocysts or sporocysts in the feces. Following ingestion of the sporocysts, asexual repro-

duction with schizogony and sarcocyst formation occur in the intermediate host (psittacine birds).<sup>101</sup> The ingested sporozoites invade intestinal mucosa followed by infection of numerous tissues and schizogony in the reticuloendothelial cells, particularly in the lungs. Asexual reproduction then occurs in the walls of arterioles (first cycle) and capillary and venule walls (second cycle). These replication cycles can cause occlusion of the affected vessels resulting in the fatal lesions characteristic of infections in Old World Psittaciformes.

In a normal infectivity cycle, the intermediate host survives schizogony in the vascular endothelium and mature cysts containing bradyzoites are subsequently formed in striated (skeletal or cardiac) muscles. In Old World Psittaciformes, infections usually cause fatal vascular changes before cysts are formed. Schizogony in the vascular endothelium of experimentally infected budgerigars was found to cause death by occlusion of the vessels secondary to endothelial hypertrophy, schizont formation and endophlebitis.

In adult New World Psittaciformes, the merozoites produced through asexual reproduction are trans-

ported via the circulatory system to striated muscles where they undergo further reproduction in sarcocysts (270 x 37  $\mu\text{m}$ ). Old World psittacines that survive schizogony in the endothelium of the lungs have been found to develop cysts ten weeks post-infection.<sup>18</sup> *Sarcocystis* also infects Passeriformes and Columbiformes, where cockroaches and flies can serve as transport hosts.

Psittacine birds in outdoor facilities throughout the range of the opossum are at risk. Infected opossums can shed sporocysts in the feces for 100 days. Cockroaches can serve as transport hosts by eating infected opossum feces and being consumed by susceptible birds.<sup>24,56,100</sup> Prevention requires fencing to prevent access of opossums to the aviary. Flightless chickens have been suggested as a method of controlling cockroaches within a compound (see Chapter 2).

*Sarcocystis* was responsible for the deaths of 37 Old World Psittaciformes in a zoologic collection over a 15-month period. Lories, cockatoos, Pesquet's Parrot, Port Lincoln Parrot, lorikeets, Princess Parrot and rosellas were included in the affected group. About half of the birds developed clinical signs prior to death, while the other birds died with no premonitory signs. When clinical signs occurred, they included anorexia, diarrhea, weakness, tachypnea, ataxia, posterior paresis, head tilt and dyspnea prior to death. Some birds had clinical signs that lasted several hours while others had clinical signs that progressed over a 52-day period. Characteristic necropsy findings included pulmonary hemorrhage, splenomegaly and hepatomegaly.<sup>56</sup>

In a zoologic collection, five Eclectus Parrots and four Hispaniolan Amazon Parrots were diagnosed with sarcocystosis over a six-month period. Four of the Eclectus and two of the Amazon parrots died. Elevations in CPK, AST and LDH enzyme activities were noted in all the affected birds. Clinical signs included weakness, dyspnea and blood in the oral cavity. Affected birds died one to 36 hours after presentation. Radiographic findings indicated an increased lung field density, hepatomegaly, splenomegaly and renomegaly. Some birds that were only slightly lethargic and had no other clinical signs survived following treatment with 0.5 mg/kg pyrimethanamine PO BID and 30 mg/kg trimethoprim-sulfadiazine IM BID for 30 days. The surviving birds responded to therapy with improved attitude, appetite and decreased serum enzyme activity. Muscle biopsies after treatment revealed multifocal myositis and sarcocysts, indicat-

ing that the birds had survived the schizogony phase of the infection allowing muscle cysts to form.<sup>81</sup>

*Encephalitozoon* sp. is a microsporidian parasite with a broad host range that includes mammals and birds. This parasite has complex spores measuring 1.5 x 1.0  $\mu\text{m}$  and containing a coiled polar filament. The latter will be seen only with the aid of electron microscopy. Lovebirds of the genus *Agapornis* are frequently infected,<sup>93</sup> but an Amazon parrot with a microsporidian infection has also been reported.<sup>69,90</sup> The spores were documented in kidney tubules, lung, liver and the lamina propria of the small intestine.<sup>69,89</sup>

Few birds have been reported with this parasite and all cases were detected at necropsy. One report gave the details of a die-off of 140 lovebirds in Great Britain in which the birds were moved to a different facility, stopped eating and lost condition.

An infected Amazon parrot developed progressive anorexia, weight loss, respiratory disease and diarrhea over a one-month period. Postmortem findings included pale, swollen kidneys and an enlarged, mottled liver. Kidney tubular epithelial cells were filled with tiny spores, as were epithelial cells in the liver and small intestine. Histologic changes were characterized by multifocal nephritis, hepatitis and enteritis.

### Hemoparasites

Haemosporidian parasites have been detected in parrots being imported into England and Japan.<sup>76,86,88</sup> *Haemoproteus* was commonly seen in imported Psittaciformes<sup>12,96</sup> and *Haemoproteus* and *Leucocytozoon* were detected in free-ranging birds in southeast Asia.<sup>71</sup> It is unknown what role, if any, that flies indigenous to North America could play in transmitting the species of *Haemoproteus* or *Leucocytozoon* that occur in birds from other geographic regions. The sexual phase and a form of asexual reproduction occur in biting flies, resulting in the production of sporozoites that localize in the salivary glands and are inoculated into the avian host. Asexual reproduction also occurs in an infected bird.

- ***Haemoproteus*:** Under normal circumstances, species of *Haemoproteus* are considered nonpathogenic and a few species of *Leucocytozoon* and *Plasmodium* are considered pathogenic. If clinical signs occur, they are associated with anemia, splenomegaly, hepatomegaly and pulmonary edema. The lymphoid-macrophage system becomes hyperplastic. High parasitemias of a pathogenic *Haemoproteus* and *Leucocytozoon* can cause clinical problems if a bird is stressed or immunosuppressed. Racing pigeons in-

ected with *H. columbae* are frequently discussed as performing poorly in comparison to uninfected birds.

*Haemoproteus* spp. are the most commonly occurring avian blood parasite; they use *Culicoides* (biting midges or punkies) or louse flies as vectors. In some studies, up to 50% of recently imported cockatoos were found to be positive. In contrast, only 5% of long-term captive cockatoos were found to have *Haemoproteus*.<sup>25</sup> In a survey of 81 African Grey Parrots, 5.7 % had *Haemoproteus*.<sup>96</sup> Most infected birds are subclinical but severe infections in stressed birds may lead to life-threatening anemia. Infections may be potentiated by concurrent disease or stress.

*H. handai* gametocytes completely encircle the red blood cell nucleus.<sup>12</sup> Initial parasite development occurs in endothelial or skeletal muscle cells followed by the production of pigmented gametocytes in RBCs (see Color 9). Some European dieoffs of psittacine birds that were attributed to *Leucocytozoon* were probably caused by *Haemoproteus*. In Roseate Parakeets infected with sporozoites of *H. handai*, large schizonts developed in the skeletal muscles.<sup>73</sup> In another study with *H. meleagridis* in turkeys, it was demonstrated that development of large schizonts occurred following inoculation of sporozoites.<sup>5</sup>

- **Leucocytozoon:** *Leucocytozoon* spp. use Simuliidae (black flies) as vectors. Initial development occurs in the liver and spleen followed by the development of unpigmented gametocytes in white blood cells or RBCs, depending upon the species (see Color 9). Infected host cells are distorted beyond recognition. Although there have been occasional reports of *Leucocytozoon* on blood films taken from psittacine birds, much of the emphasis on this genus in the European literature is based on finding megaloschizonts in muscles of birds that have presumably died as a result of the infection.<sup>41,103</sup> No one has reported blood stages that are more definitive for generic identification, although the birds may have died prior to the development of gametocytes. These deaths probably resulted due to infections of *Haemoproteus*, not *Leucocytozoon*.

*Leucocytozoon* has a seasonal incidence in the wild with parasitemia being highest in the spring. Following infection, high numbers of the parasite may be detected in the blood within four to nine days. The parasite produces an anti-erythrocytic factor, which causes intravascular hemolysis and anemia, the principal clinical sign. *Leucocytozoon* is highly pathogenic in young Anseriformes and Galliformes.<sup>45</sup> Fatal infections have been described in budgerigars. Hepa-

tomegaly, splenomegaly, pulmonary congestion and pericardial effusion are the most characteristic gross findings. Pyrimethamine has been suggested for treatment.

- **Plasmodium:** *Plasmodium* spp. use mosquitoes as vectors. Initial parasite development occurs in the avian reticuloendothelial system followed by the development of pigmented schizonts and gametocytes in the erythrocytes (RBCs) (see Color 9). Schizogony occurs in the erythrocytes, which means that blood-to-blood transfer, without an intermediate host, can result in an infection.

*Plasmodium* spp. have been described in a number of companion and aviary birds. Species of *Plasmodium* are most likely to occur in an avicultural setting because it has the widest host range of all the haemosporidian parasites. Apathogenic strains of *Plasmodium* may cause asymptomatic infections in cockatoos and passerine birds. Some Passeriformes serve as asymptomatic carriers. Some strains of *Plasmodium* are highly pathogenic in canaries, penguins, Galliformes, Anseriformes, Columbiformes and falcons. Clinical signs are most common in recently infected birds and are characterized by anorexia, depression, vomiting and dyspnea for a few hours or days prior to death. In penguins, depression, anemia, vomiting, seizures and high levels of mortality may be noted.<sup>34</sup> Nonpathogenic strains of *Plasmodium* have also been described in many of these same avian orders.

Six species of *Plasmodium* and one of *Haemoproteus* have been reported from Psittacidae.<sup>11</sup> *P. relictum* is a large species that is round as both gametocytes and schizonts (8 to 24 merozoites) and displaces the RBC nucleus toward the pole. *P. nucleophilum* is a small form with elongate, amoeboid gametocytes, which along with small schizonts (4 to 8 merozoites), tightly adhere to the RBC nucleus. *P. vaughani* is another small species with amoeboid gametocytes; the merozoites (4 to 8 per schizont) of schizonts appear to lack cytoplasm, and neither stage clings to the RBC nucleus. *P. dissanaikae* has larger elongate gametocytes that fill the lateral cytoplasm of the RBC and its small schizonts (4 to 12 merozoites) may adhere to the RBC nucleus. *P. circumflexum* has large halteridial gametocytes that usually wrap around the ends of the host cell nucleus and fill most of the RBC cytoplasm. Its schizonts are larger than the RBC nucleus and contain 6 to 30 merozoites, which are arranged in a halter around the RBC nucleus. *P. polare* has variable gametocytes, but they often are



halteridial or at least the length of the RBC. The schizonts are usually in a polar position and are irregular, round or fan-shaped with 8 to 14 merozoites.

- **Trypanosoma:** *Trypanosoma johnbakeri* is an extracellular, flagellated blood parasite that is transmitted by a biting midge and has been demonstrated in Roseate Parakeets, but has not been associated with clinical signs.<sup>74</sup> In one study, trypanosomes were identified in 14% of imported Hyacinth Macaws, and 20% of imported Green-winged Macaws examined.<sup>25</sup>

## Helminths

### Flatworms

Flatworms include digenetic flukes and tapeworms. Flukes found in psittacine birds may reside in the liver (*Platynosomum*, *Lyperosomum*, *Dicrocoelium* and *Brachylecithum*) or in the blood vasculature (a schistosome believed to be *Gigantobilharzia*). Tapeworms live in the small intestine (*Triuterina*, *Biporouterina*, *Cotugnia* and *Raillietina*).

- **Flukes:** Flukes living in the bile ducts are members of the family Dicrocoelidae. All of the cases reported in North America have probably occurred in imported birds (Old World species) that were infected by endemic species in their country of origin. Birds may be infected by eating an arthropod, which serves as a second intermediate host. Liver flukes have rarely been demonstrated in New World Psittaciformes, even though there are a number of genera that occur in North American avifauna. Clinical changes associated with liver fluke infections include hepatomegaly, depression, anorexia, mild anemia, weight loss, diarrhea, hepatic necrosis, elevated liver enzymes and death.<sup>61,64,92</sup> There is a single case reported of a schistosome in a Nanday Conure that died after showing weight loss, anorexia and blood-tinged diarrhea.<sup>48</sup> Histologic evidence of colitis and cloacitis was present along with an epithelial hyperplasia of the lower gut.

Hepatic trematodiasis has been reported in cockatoos. Numerous trematode eggs were seen on direct smears of the feces. Necropsy findings were primarily limited to the liver and were characterized by hepatomegaly, increased firmness, numerous streaks, brown and yellow mottling and fibrosis. In some birds, trematodes were found in dilated bile ducts. Histologic lesions were characterized by hepatic fibrosis and bile duct hyperplasia. Clinical improvement following treatment with fenbendazole and praziquantel was minimal; however, the number of

eggs per gram of feces did decrease dramatically following therapy.<sup>92</sup> Biliary cholestasis and cystic dilatation have also been described in birds with trematodiasis.<sup>77</sup> Schistomiasis can cause heavy motility in free-ranging Anseriformes.<sup>111,112</sup>

- **Tapeworms:** Tapeworms infecting psittacine birds<sup>27,72</sup> can be asymptomatic or the parasite may steal nutrients from the host causing a bird to appear unthrifty and have diarrhea (see Figure 36.28). Infections are most common in finches, African Grey Parrots (15 to 20% of imported birds), cockatoos (10 to 20% of imported birds) and Eclectus Parrots.<sup>22,95</sup> Infections occasionally occur in South American Psittaciformes. Eosinophilia has been discussed as a clinical change associated with tapeworm infections. However, there has been no direct relationship demonstrated between parasitism and eosinophilia in birds. In general, infections are nonpathogenic although large numbers of worms can cause impaction. With severe infections, birds may die following a period of weight loss and diarrhea.

Tapeworms require intermediate hosts, and infections are uncommon in birds that do not have access to the ground. Either proglottids or whole worms may be noted in the feces. Eggs of *Triuterina* and *Biporouterina* are single whereas those of *Raillietina* and *Cotugnia* are passed in clusters encased in a mucilaginous material. Focusing through the individual rounded eggs to see the hooks on the hexacanth larva may be necessary to demonstrate that these are tapeworm eggs. Infections may not be detected during routine fecal exams unless a proglottid present in the feces has ruptured. The eggs contain six hooks on oncosphere and hexacanth larvae.

### Roundworms

Roundworms (nematodes) are more diversified than flatworms and live in the small intestine (*Ascaridia*, *Ascarops* and *Capillaria*), proventriculus and ventriculus (*Microtetrameres*, *Procyrnea* and *Ascarops*),<sup>33,37</sup> the surface of the eye (*Thelazia*, *Oxyspirura*, *Ceratospira* and *Annulospira*) and in subcutaneous regions, body cavity and air sacs (*Eulimdana*, *Pelecitus*, *Cardiofilaria* and *Cyathospira*).

- **Ascarids:** Ascarids are the most common parasite found in birds that are maintained in enclosures with access to ground. Infections are particularly common in budgerigars and cockatiels. Species that infect psittacine birds include *Ascaridia columbae* (shared with pigeons), *A. galli* (shared with gallinaceous birds)<sup>87</sup> and *A. platycerci*,<sup>76</sup> which is restricted thus

far to Psittaciformes. While there are other species described, their validity is questionable.<sup>53,75,76</sup>

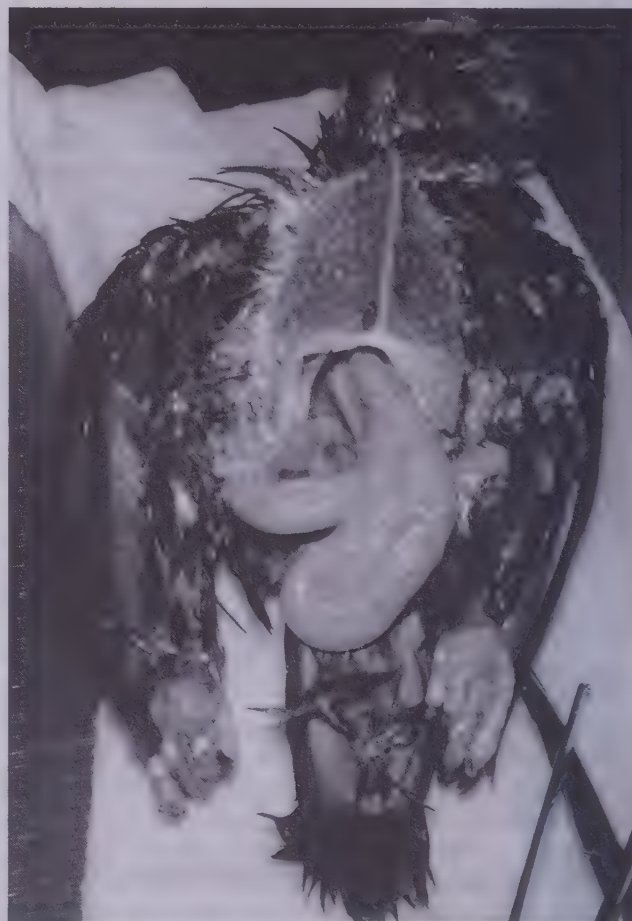
The direct life cycle requires a two- to three-week period for embryonated larva to form within the egg, which is viable for extended periods in moist warm environments. The eggs are resistant to disinfectants but can be controlled with steam or flaming. The ingested larvae infect the intestinal mucosa. Mild infections can cause malabsorption, weight loss, anorexia, growth abnormalities and diarrhea. Heavier parasite loads may cause intussusception, bowel occlusion or death (Figure 36.30).

Providing a dry clean environment will decrease the possibility that eggs will survive to embryonate. Piperazine, pyrantel pamoate and fenbendazole may be effective in resolving infections.

Cerebrospinal nematodiasis caused by larvae from *Baylisascaris procyonis* (raccoon ascarids) has been reported in gallinaceous birds, cockatiels, ratites and several Passeriformes.<sup>4,80</sup> Infective eggs are ingested by the bird; the larvae are digested free from their eggs, where they penetrate the intestinal wall and begin migrating through the tissues. They do not mature and continue to migrate in a form of visceral larval migrans. When they enter the central nervous system, the larvae induce considerable damage leading to ataxia, torticollis, depression and death.<sup>4</sup>

In a group of mixed macaws, seven of ten potentially exposed birds developed ataxia, torticollis and depression after being placed in contact with raccoons. *B. procyonis* larvae were identified in the cerebrospinal tissue of 6 of the birds. The earliest clinical signs developed 35 days after potential exposure to the raccoons. Other birds developed clinical signs over a nine-month period. Some birds developed lesions 7.5 months after being removed from any exposure to the parasite.<sup>22</sup> An ostrich and two emus developed progressive ataxia (two to three weeks) and eventually died. Necropsy findings included multifocal encephalomalacia of the brain stem and cerebellum caused by *Baylisascaris* larvae. Infective eggs were recovered from the ground of the ostrich pen.<sup>62,63</sup>

Because no diagnostic stages of the parasite are released to the environment, and no commercially available serological diagnostic kit is available, this parasite is normally diagnosed histologically at necropsy. The best means of control is to prevent access of free-ranging raccoons to aviaries, and thus prevent contamination of the environment by these thick-walled and long-lived eggs.



**FIG 36.30** A two-year-old Severe Macaw was presented with vomiting, diarrhea and chronic weight loss, even though the bird had a voracious appetite. The bird had lost most of its pectoral muscle mass (weight 230 g), and had a distended abdomen. Radiographs indicated enlarged bowel loops, diffusely filled with linear soft tissue densities. A fecal exam revealed thousands of ascarid eggs. The bird did not respond to supportive care. This bird was maintained in a mixed species outdoor exhibit with access to the ground. Intestinal nematodes are rare in companion birds maintained indoors and in aviary birds maintained in suspended enclosures.

Ascarids in the genus *Heterakis* can infect the ceca of gallinaceous birds, Anseriformes and other birds. Nodular lesions consisting of fibrotic and granuloma-

tous tissue may develop in the submucosa of the ceca, particularly in pheasants (see Color 14). The life cycle is direct following ingestion of embryonated ova. In some species (quail), infections are subclinical, while other affected birds can die from complications associated with the mucosal and submucosal lesions.

- **Capillaria:** Species of *Capillaria* are tiny thread-like nematodes that may infect the gastrointestinal tract of most species of companion and aviary birds.<sup>22,109</sup> Infections appear to be most common in macaws, budgerigars, canaries, pigeons and gallinaceous birds. Severe infections can cause diarrhea (which may contain blood), weight loss, anorexia, vomiting and anemia.<sup>22</sup> Little has been published on these worms as to the species present or their true influence on these birds; the clinical effects are not severe. Species of this genus in other birds are profound pathogens when they reside in the upper digestive tract, particularly in gallinaceous birds. The life cycle of *Capillaria* is direct.

Embryonation requires approximately two weeks, and eggs can remain infectious in the environment for several months. The adults can burrow into the mucosa of the esophagus, crop or intestinal tract causing depression, dysphagia, regurgitation, diarrhea, melena and weight loss. *Capillaria* that infect the crop, esophagus and oral cavity burrow into the mucosa, creating tracts that may fill with blood, producing hyperemic streaks. Frank hemorrhage may occur in the upper intestinal tract in heavily parasitized animals. Diphtheritic lesions may occur in the mouth, pharynx, esophagus and crop of some infected species.

Scrapings of suspect lesions or fecal flotation can be used to detect the characteristic bipolar eggs (see Figure 36.18). Magnification may be necessary to see the adults.

- **Spiruroidea:** The superfamily Spiruroidea represents the most diversified group of nematodes in birds. Little on the biology and pathology of these nematodes is known, but the life cycle probably involves an insect intermediate host. *Ascarops* sp. has been recovered from the intestines of a Greater Sulphur-crested Cockatoo and *A. psittaculai* was described in a Rose-ringed Parakeet.<sup>102,110</sup> *Procyrnea kea* was described from the New Zealand Kea where it lives under the koilin of the ventriculus.<sup>20</sup> *Microtetratmeres nestoris* was found in the proventriculus of the North Island Kaka where it caused hyperplasia

and metaplasia of the duct epithelium, glandular atrophy and limited necrosis and hemorrhage.<sup>21</sup>

Four genera of eyeworms (*Thelazia* and *Ceratospira*) have been reported (see Color 26).<sup>2,19,66,106</sup> The intermediate host is considered to be the fly. Eyelid spasms and mild conjunctival hyperemia were evident in a Senegal Parrot with *Thelazia* even though only three adults were recovered. The worms were removed after they were incapacitated with 0.125% demecarium bromide.<sup>19</sup> In contrast, no pathology was associated with numerous *Ceratospira* infecting a Moluccan Cockatoo. *Thelazia digitata* has been recovered from the eye of several macaws.<sup>2</sup> *Annulospira* has been removed from the eye orbits of a Rose-ringed Parakeet.<sup>60</sup>

*Oxyspirura* sp. is common in the eye of cockatoos where it resides beneath the nictitating membrane or in the conjunctival sac. Severe infections may cause conjunctivitis, chemosis and scratching at the eye. The eyelids may close due to the accumulation of caseous debris. The parasite has an indirect life cycle that involves an arthropod (cockroach) intermediate host. Ivermectin can be used to kill the worms, which are then removed by flushing.

*Streptocara* spp. are pathogenic spiruroids that burrow into the mucosa of the esophagus, crop, proventriculus and ventriculus, principally in Anseriformes. Crustaceans serve as an intermediate host. In severe infections, diaphoretic esophagitis or gastritis associated with ulceration and frank hemorrhage may occur.

*Spiroptera incerta* and *Dispharynx nasuta* have been reported in association with thickening of the proventricular mucosa in a number of Psittaciformes (see Color 19). The adult worms burrow into the proventriculus causing ulcers, inflammation and nodule formation. The proliferative mucosa may prevent the passage of ingesta resulting in chronic vomiting and weight loss (Figure 36.31).

A large-mouthed worm (*Cyathostoma cacatua*) related to gapeworms has been reported from the air sacs of a Sulphur-crested Cockatoo.<sup>14</sup> Lungs from infected birds were consolidated, had extensive necrosis and caseation and contained bacteria and many parasite eggs.

- **Syngamus:** *Syngamus trachea* (gapeworm) has been diagnosed in many species of companion and aviary birds. Infections are rare in companion birds but are common in Galliformes and Anseriformes (Figure 36.32). The red Y-shaped adult parasite can be visu-

alized on the mucosa of the trachea and primary bronchi. Adult birds are generally resistant and most infections occur in young birds. Coughing, open-mouthed breathing, dried blood at the beak commissure, dyspnea and head shaking are common. With severe infections, death can occur secondary to tracheal ulceration, anemia and asphyxiation. The eggs of the parasite can be detected in the feces. The life cycle is direct but earthworms can serve as a transport host. Thiabendazole has been recommended for treatment. Ivermectin can be used to kill the parasites and they can be mechanically removed by repeated transtracheal washes.

- **Filariidea:** The filariid nematodes have indirect life cycles and are transmitted to birds by blood-feeding diptera. A recent key to the genera of adult filarial worms has been published.<sup>7</sup> The diagnostic stage of these worms is the microfilaria and in most cases, the microfilariae have not been matched to the adults. The adults live in the body cavity, chambers of the eyes, heart or air sacs (Figure 36.33). Species of *Pelecitus*, *Chandlerella*, *Cardiofilaria* and *Eulimdana* occur in psittacine birds. Adult *Pelecitus* reside in subcutaneous tissues causing masses, typically on the legs and feet.<sup>1,47</sup> A taxonomic revision of the genus *Pelecitus* has been made.<sup>8</sup> Other filariae have been documented in psittacines, but nothing has been discussed about known or potential pathogenesis.<sup>9,26</sup>


Microfilariae were at one time considered common in the peripheral blood of Passeriformes and Psittaciformes with the incidence in imported cockatoos being particularly high (up to 45%). By comparison, only six percent of imported non-cockatoo psittacine birds were found to have microfilariae in one study.<sup>25</sup> Many cockatoos with microfilariae are also found to be infected with *Haemoproteus*. Microfilariae are easiest to detect by examining the buffy coat on a hematocrit tube. Microfilariae exhibit periodicity and several blood tests may be necessary to demonstrate the parasites.



**FIG 36.31** A mature Umbrella Cockatoo was presented with a history of progressive weight loss of one month's duration. The bird had been vomiting for a week before presentation. Survey radiographs indicated a thickened proventriculus. Contrast medium was instilled into the crop and indicated a thickened proventricular mucosa and slowed gastric emptying time: **a**) at 20 minutes; **b**) at six hours. Note the small heart (suggestive of severe dehydration) and microhepatia. The client chose euthanasia. At necropsy, the proventricular mucosa was ulcerated and inflamed and had numerous nodules. *Spiroptera* eggs were identified in proventricular washings.



**FIG 36.32** *Syngamus* spp. are seen in the trachea of a duck. Note the hemorrhage and accumulation of necrotic debris associated with the parasites (courtesy of Robert Schmidt).



**FIG 36.33** Uncharacterized filariid nematodes (open arrow) were found in the air sacs of a free-ranging Barn Owl that died from a gunshot wound. The air sacs were clear and appeared to be unaffected by the parasites. A loop of bowel (arrow) is also evident.

The adults primarily inhabit the air sacs but may also occur in the joints, subcutaneous tissue and pericardial sac. In most situations, the adults and microfilariae are considered apathogenic; however, filarial worms in the joints and subcutaneous tissues can cause severe problems and should be removed (Figure 36.34).

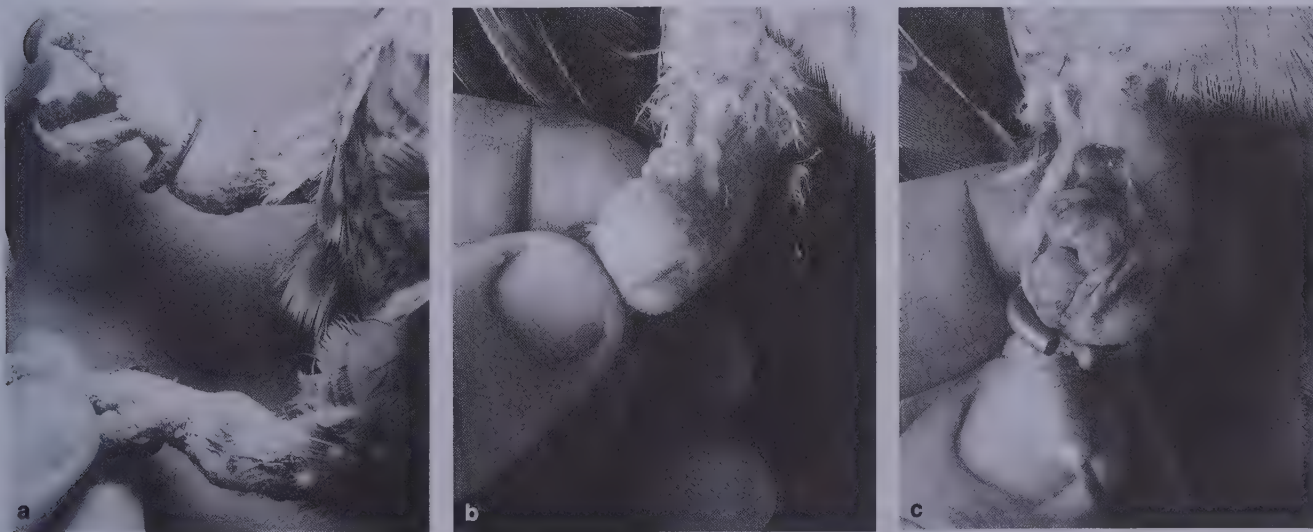Adult filarial worms filling the pericardial sac of a Red-vented Cockatoo caused death.<sup>22</sup> An Umbrella Cockatoo with a one-week history of anorexia, ataxia, diarrhea and increased vocalization was found at necropsy to have microfilariae in the small vessels of the brain, lungs, kidneys, spleen, heart and liver. Adult filariae were identified in the vena cava.<sup>55</sup> Adult filariae were found in the heart of a recently imported Ducorp's Cockatoo with PBF (see Color 14).

### Arthropods

Hematophagous diptera including mosquitoes, black flies and biting midges can feed on psittacine birds and transmit blood parasites. Direct effects of these parasites may include anemia, which is particularly common in neonates during the rainy season in South Florida (see Color 24).

Biting lice known to occur on psittacines include *Neopsittaconirmus*, *Psittaconirmus*, *Eomenopon* and *Pacifimnophon*. Lice may cause pruritus and poor feather condition. The parasites can be observed directly, or the nits (eggs) can be seen attached to the feathers (see Figure 48.21). Most species are host specific and die quickly when they leave a host. Dusting with pyrethrin can control infections. Because many of the parrots and their relatives have not been examined for lice, there are probably many more species that have not been characterized.<sup>90,91</sup>

- **Mites and Fleas:** Numerous mites have been detected on and in psittacine birds. The scaly leg and face mite, *Knemidokoptes pilae*, is the most fre-



**FIG 36.34** a) A Tucamon Amazon Parrot was presented with a history of bilateral, flocculent swellings of the metatarsal area. b) There were no clinical indications of discomfort or dysfunction associated with the masses. A fine-needle aspirate of the swelling revealed microfilaria. c) The masses were incised and numerous adult filariid worms (*Pelecitus* sp.) were removed.

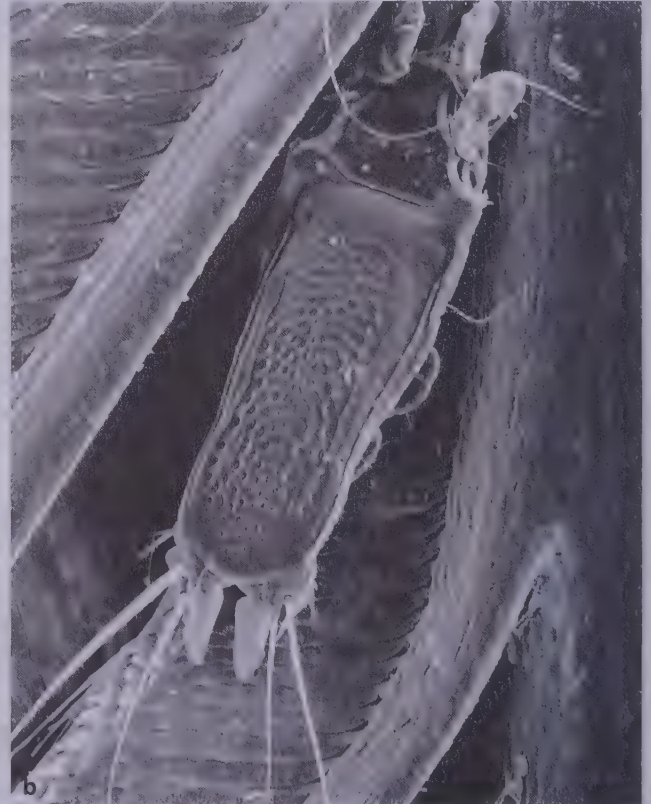quently diagnosed and causes prominent and disfiguring lesions (see Color 24).<sup>98,113</sup> Infections are most common in budgerigars, but they may also occur in other Psittaciformes and Passeriformes. Typically, there is a proliferation of tissue on the beak. Lesions may also occur on the feet, legs and cloaca in some birds (see Color 24). Tunnels in the proliferative tissue create a characteristic honey-combed appearance. The mites can be detected by examining skin scrapings. Using an operating microscope, the adult females can be observed in the tunnels. Histologically there will be shallow burrows in which the adults will be stationed near the entrance.

Young birds are commonly affected, but adults may be infected in some situations. A genetic predisposition to develop *Knemidokoptes* infections has been suggested because only a few birds in a group may be infected. A selective immunosuppression may also be a predisposing factor, but has not been documented. In canaries, *Knemidokoptes* infections on the feet and legs may cause large proliferative masses frequently referred to as "tassel-foot" (see Color 24). *Knemidokoptes* and giardiasis are most commonly seen in inbred birds suggesting a genetic immunosuppres-

sion. Epidermoptid mites may cause hyperkeratosis, hypouricemia and feather loss. Infections are most common around the head and neck and appear to be severely pruritic.

A species of *Knemidokoptes* mite that is morphologically distinct from *K. pilae* and *K. laeris* was recovered from several groups of Red-fronted Parakeets with feather loss. The featherless skin was hyperemic and feather loss was prominent on the head and neck. The mites were identified by microscopic examination of material collected from the thickened calamus. Mites were identified in adult and immature birds but only the adults developed clinical signs.<sup>99</sup> Treatment consisted of two drops of a 1:20 dilution of 1% moxydectin topically on the neck.

*Sternostoma tracheacolum* can infect the trachea of canaries, finches (especially Lady Gouldians), parakeets and cockatiels. The larva, nymph and adult forms of the parasite can be found in the respiratory tract of affected birds, suggesting that the entire life cycle occurs in the infected host. Clinical signs include dyspnea, coughing and sneezing. Nasal discharge and open-mouthed breathing may also be



**FIG 36.35** *Aralichus elongatus* mites on the ventral surface of the feathers of a White-capped Parrot. **a)** Males, females and exuvia. Note the structure of the rachis, barbules and barbs. **b)** Male (courtesy of W. T. Atyeo).

noted. Infections can be mild to severe with resulting death by asphyxiation. These small black mites can be identified by transillumination of the trachea, or the eggs can be identified in the feces or following a transtracheal wash. Young birds may be infected when being fed by infected parents. The incubation period in Gouldian Finches is three weeks but may be months in other species. Mite-free Society Finches can be used to cross-foster Gouldian Finches to produce mite-free flocks.<sup>35</sup>

Numerous feather mites have been described in birds (Figures 36.35 and 36.36). Six species have been described in African Psittaciformes and three to four species have been described in Australian Psittaciformes. Fifteen species of feather mites have been described in New World Psittaciformes. Feather mites have highly specific microhabitats, infecting specific portions of the feathers. In general, feather mites are apathogenic in their host-adapted species, but can cause clinical problems in non-host adapted species, or with heavy infestations when the mites move from the feathers to the skin.

As an example of the highly specialized nature of feather mites, two species that frequently infect budgerigars were studied. *Prolichns* spp. were found to live on the exposed surfaces of the wing and tail feathers, while *Dubininia* spp. lived on the small body feathers.<sup>6</sup>

Myialges (*Metamicrolichus nudus*) were demonstrated in a Grey-cheeked Parakeet with sinusitis, weight loss, pruritic dermatitis and feather loss of the head. The skin was hyperkeratotic (several millimeters thick), and the parasite was demonstrated in pits within the stratum corneum and feather cavity. The females of this parasite generally attach to the exoskeleton of lice or hippoboscid flies for oviposition. The source of infection in this bird was undetermined.<sup>49</sup>

Myialges was diagnosed by finding eggs in a skin scraping taken from an Amazon parrot with a one-week history of scratching around the eyes. The skin around the lores was dry and flaky and the head, cere and lore area appeared to be pruritic. Ivermectin was effective in controlling the infection.<sup>94</sup>



**FIG 36.36** *Rhytidelasma gaud* from an *Aratinga* sp.; **a**) Nymphs. **b**) Cast skins (exuvia). Note the barbicels of the feather (courtesy of W.T. Atyeo).

Nonhost-specific fleas are occasionally noted in companion and aviary birds. If they cause clinical problems (eg, pruritus, anemia, poor feather condition) they can be controlled with a light dusting of pyrethrin powder. The mite protectors sold in most pet supply stores have no effect on common external avian parasites and may cause liver disease. The use of these products is discouraged.

Other mites that have been associated with occasional skin or feather disease in birds include: *Dermanyssus* spp. (red mites), *Ornithonyssus* spp. (fowl mites), *K. laevis* (depluming mite), epidermoptoid mites and quill mites (*Syringophilus* spp., *Dermatoglyphus* spp., *Pterolichus* spp. and *Analges* spp.). *Der-*

*manyssus* feed on blood and may cause anemia, pruritus and poor growth in young birds. They infect the bird only at night and spend the daytime in crevices within the aviary. Under magnification, they can be recognized as rapidly moving dark brown spots. Free-ranging birds can serve as a source of infestation and should not be allowed to nest or roost in the aviary. *Ornithonyssus* can cause problems similar to those seen with *Dermanyssus*. This parasite completes its life cycle on the bird. Dusting with pyrethrin should be effective for controlling the mites. Quill mites may cause damage to developing feathers. The mites can be demonstrated by examining the pulp material within a developing feather.

### References and Suggested Reading

- Allen JL, et al: Subcutaneous filariasis (*Pelecitus* sp.) in a yellow-collared macaw (*Ara auricollis*). *Avian Dis* 29:891-894, 1985.
- Anderson RC, Diaz-Ungria C: Revision preliminar de las especies de *Thelazia* Bosc (Spiruroidea: Thelazidae), parasitas de aves. *Mem Soc Cienc Nat La Salle* 19:37-75, 1959.
- Angus KW: Cryptosporidiosis in man, domestic animals and birds. A review. *J Royal Soc Med* 76:62-70, 1983.
- Armstrong DL, et al: Cerebrospinal nematodiasis in blue and gold macaws and scarlet macaws associated with *Baylisascaris procyonis*. *Proc Assoc Avian Vet*, 1987, pp 489-490.
- Atkinson CT, Forrester DJ, Greiner EC: Pathology of *Haemoproteus meleagridis* (Haemosporina: Haemoproteidae) in experimentally infected domestic turkeys. *J Parasitol* 74:228-239, 1988.
- Atyoo WT, Gand J: Feather mites of the parakeet. *J Parasit* 73:203-206, 1987.
- Bartlett CM, Anderson RC: *Lemdana wernaarti* n. sp. and other filarid nematodes from *Bubo virginianus* and *Asio otus* (Strigiformes) in Ontario, Canada, with a revision of *Lemdana* and a key to avian filarid genera. *Canad J Zool* 65:1100-1109, 1987.
- Bartlett CM, Greiner EC: A revision of *Pelecitus raillet & henry* (Filarioidea, Dirofilarinae) and evidence for the "capture" by mammals of filarioids from birds. *Bull Mus Natn Hist Nat, Paris* 8:47-99, 1910.
- Bartlett CM, Wong PL, Anderson RC: *Eulimdana lari* (Yamaguti 1935) n. comb. (Nematoda: Filarioidea) from *Phalaropus* spp. (Charadriiformes) in Canada and a review of the genus *Eulimdana* Founikoff 1934. *Canad J Zool* 63:666-672, 1985.
- Belton DJ, Powell IB: Cryptosporidiosis in lovebirds (*Agapornis* sp.). *New Zealand Vet J* 35:15, 1987.
- Bennett GF, Whiteaway M, Woodworth-Lynas C: A host-parasite catalogue of the avian hematozoa. *Occas Papers Biol No* 5, 243 pp, 1982.
- Bennett GF, Peirce MA: Avian Haemoproteidae. The haemoproteids of the parrot family Psittacidae. *Can J Zool* 64:771-773, 1986.
- Blagburn BL, et al: *Cryptosporidium* spp. infection in the proventriculus of an Australian diamond firetail finch. *Avian Dis* 34:1027-1030, 1990.
- Bowie JY: *Cyathostoma cacatuae* n. sp. (Nematoda: Syngamidae) from a sulfur-crested cockatoo *Cacatua galerita* (Aves: Psittaciformes), with a key to the species of *Cyathostoma*. *New Zealand J Zool* 12:425-429, 1985.
- Box ED: Observations on *Giardia* of budgerigars. *J Protozool* 28: 491-494, 1981.
- Box ED: *Atoxoplasma* associated with an isosporan oocyst in canaries. *J Protozool* 28:244-246, 1981.
- Box ED: *Isospora* as an extraintestinal parasite of passerine birds. *J Protozool* 28:244-246, 1981.
- Box ED, Smith JH: The intermediate host spectrum in a *Sarcocystis* species of birds. *J Parasit* 68:668-673, 1982.
- Brooks DE, Greiner EC, Walsh MT: Conjunctivitis caused by *Thelazia* sp. in a Senegal parrot. *J Am Vet Med Assoc* 183:1305-1306, 1983.
- Clark WC: *Procyrnea kea* sp. nov. (Habronematidae: Spirurida; Nematoda) from the New Zealand kea (*Nestor notabilis* Gould 1865) (Aves: Psittaciformes). *J Roy Soc New Zealand* 8:323-328, 1978.
- Clark WC, Black, H, Rutherford DM: *Microtetrameres nestoris* n. sp. (Nematoda: Spirurida), a parasite of the North Island Kaka, (*Nestor meridionalis septentrionalis* (Aves: Psittaciformes). *New Zealand J Zool* 6:1-5, 1979.
- Clubb SL: Parasites of cage and aviary birds. *Proc Amer Fed Avi Vet Sem*, 1988, pp 63-68.
- Clubb SL, et al: An acute fatal illness in old world psittacine birds associated with *Sarcocystis falcatula* of oopsums. *Proc Assoc Avian Vet*, 1986, pp 139-149.
- Clubb SL, Frenkel JK: *Sarcocystis falcatula* of oopsums: Transmission by cockroaches with fatal pulmonary disease in psittacine birds. *J Parasitol* 78:116-124, 1992.
- Clubb SL, Cramm D: Blood parasites of psittacine birds. A survey of the prevalence of *Hemoproteus* microfilaria and *Trypanosomes*. *Proc Am Assoc Zoo Vet*, 1981, pp 32-37.
- Dharma DN, et al: Filariasis and microfilariasis in parrots in the eastern islands of Indonesia. *Avian Dis* 29:881-885, 1985.
- Dollfus RP: Miscellaneous helminthologica marocana. XLII. Cestodes d'Oiseaux et de Mammifères. *Bull Mus Natn Histoire Nat* 212:659-684.
- Dorrestine GM, van der Hage MN, Zwart P: Diseases of passerines, especially canaries and finches. *Proc Assoc Avian Vet*, 1985, pp 53-70.
- Doster AR, McHaffey EA, McClearn JR: *Cryptosporidium* in the cloacal coprodeum of red-ored parrots (*Amazona autumnalis*). *Avian Dis* 23:654-661.
- Douglass EM: Histomoniasis in zoo birds. *Vet Med Sm Anim Clin* July:1013-1014, 1981.
- Erlandsen SL, Bemrick WJ: SEM evidence for a new species, *Giardia psittaci*. *J Parasit* 73:623-629, 1987.
- Evans RH, Tangredi B: Cerebrospinal nematodiasis in free-ranging birds. *J Am Vet Med Assoc* 183:1089-1090, 1985.
- Farah MO: Ventricular worm infections in the pigeon. *Br Vet J* 144:596-601, 1988.
- Fix AS, et al: *Plasmodium relictum* as a cause of avian malaria in wild-caught magellanic penguins (*Spheniscus magellanicus*). *J Wildl Dis* 24:610-619, 1988.
- Flammer K: Preliminary experiments for control of internal parasites in Australian finches. *Proc West Poul Dis Conf*, 1982, pp 155-157.
- Flammer K: Clinical aspects of atoxoplasmosis in canaries. *Proc Assoc Avian Vet*, 1987, pp 33-35.
- Flatt RE, Nelson LR: *Tetrameres americana* in laboratory pigeons. *Lab An Care* 19:8453-856, 1969.
- Fudge AM, McEntee L: Avian giardiasis: Syndrome, diagnosis and therapy. *Proc Assoc Avian Vet* 1986, pp 155-164.
- Gajadhar AA: *Cryptosporidium* species in imported ostriches and considerations of possible implications for birds in Canada. *Can Vet J* 34:115-116, 1993.
- Gamer MM, Sturtevant FC: Trichomoniasis in a blue-fronted Amazon parrot (*Amazona aestiva*). *J Assoc Avian Vet* 6:17-20, 1992.
- Glunder G, Hinz KH: Zum Auftreten der Leucocytozoonosis bei (Psittaciden). *Kleintierpraxis* 30 433-437, 1985.
- Goodwin MA: Cryptosporidiosis in birds - a review. *Avian Pathol* 18:365-384, 1989.
- Gothe R, Kreier JP: *Aegyptianella*, *Eperythrozoon* and *Haemobartonella*. In Kreier J (ed): *Parasitic Protozoa*. Academic Press, 1977, pp 254-263.
- Greiner EC: Parasite diagnosis by fecal examination. *J Assoc Avian Vet* 3:69-72, 1989.
- Greiner EC: Leucocytozoonosis in waterfowl and wild galliforme birds. *Bull Soc Vect Ecol* 16:84-93, 1991.
- Greiner EC, Walsh MT: Conjunctivitis caused by *Thelazia* sp. in a Senegal parrot. *J Am Vet Med Assoc* 183:1305-1306, 1983.
- Greve JH, Graham DL, Nye RR: Tenosynovitis caused by *Pelecitus calamiiformis* (Nematoda: Filarioidea) in the legs of a parrot. *Avian Dis* 26: 431-436, 1982.
- Greve JH, Sakla AA, McGehee EH: Bilharziasis in a nanday conure. *J Am Vet Med Assoc* 172:1212-1214, 1978.
- Greve JH, Uphoff CS: Mange caused by *Myialges* in a grey-cheeked parakeet. *J Am Vet Med Assoc* 185:101-102, 1984.
- Guy JS, et al: Experimental reproduction of enteritis in bobwhite quail with *Cryptosporidium* and reovirus. *Avian Dis* 1987.
- Harper FDW: *Hexamita* species present in some avian species in South Wales. *Vet Rec* 128:130, 1991.
- Hartley WJ, Dubey JP: Fatal toxoplasmosis in some native Australian birds. *J Vet Diagn Invest* 3:167-169, 1991.
- Hartwich G, Tschemer V: *Ascaridia platyceri* n. sp., eine neue Spulwurmart aus Papageien. *Angew Parasitol* 20:63-67, 1979.
- Henderson GM, Gulland FMD, CM Hawkey: Haematological findings in budgerigars with megabacterium and trichomonas infections associated with 'going light.' *Vet Rec* 123:492-494, 1988.
- Hillyer EV, Quesenberry KE, Baer KE: Systemic microfiliariasis in an umbrella cockatoo. *Proc Assoc Avian Vet*, 1988, pp 201.
- Hillyer EV, et al: An outbreak of *Sarcocystis* in a collection of psittacines. *J Zoo Wildl Med* 22:434-445, 1991.
- Howerth EW, et al: Fatal toxoplasmosis in a red lory (*Eos bornea*). *Avian Dis* 35: 642- 646, 1991.
- Hunter DB, Taylor M: Lung biopsy as a diagnostic technique in avian medicine. *Proc Assoc Avian Vet*, 1992, pp 207-211.
- Jacobson ER, et al: *Sarcocystis* encephalitis in a cockatiel. *J Am Vet Med Assoc* 185:904-906, 1984.
- Jairajpuri AS, Siddiqi AH: *Annulospira oculata* gen et sp nov (Nema-



- toda: Thelaziidae) from India. *Helminthol* 43:341-342, 1969.
61. **Kazacos KR, et al:** Fatal hepatic trematodiasis in cockatoos due to *Platynosomum proailiensis*. *Avian Dis* 24:788-793, 1980.
  62. **Kazacos KR, Fitzgerald SD, Reed WM:** *Baylisascaris procyonis* as a cause of cerebrosplinal nematodiasis in rufous. *J Zoo Wildl Med* 22:460-465, 1991.
  63. **Kazacos KR, Winterfield RW, Thacker HL:** Etiology and epidemiology of verminous encephalitis in an emu. *Avian Dis* 26:389-391, 1982.
  64. **Kock MD, Duhamel GE:** Hepatic distomatiasis in a sulphur-crested cockatoo. *Am J Vet Med Assoc* 181:1388-1389, 1982.
  65. **Lafimer KS, et al:** Cryptosporidiosis in four cockatoos with psittacine beak and feather disease. *J Am Vet Med Assoc* 200:107-110, 1992.
  66. **Ley DH, et al:** *Cryptosporidium* positive rates in avian necropsy accessions determined by examination of auramine O-stained fecal smears. *Avian Dis* 32:108-113, 1988.
  67. **Ley DH:** Avian cryptosporidiosis - An emerging disease. *Proc Assoc Avian Vet*, 1987, pp 299-303.
  68. **Lindsay DS, Blagburn BL:** Cryptosporidiosis in birds. In: Dubey JP, et al (eds): *Cryptosporidiosis in Man and Animals*. Boca Raton, CRC Press, 1990, pp 133-148.
  69. **Lowenstine LJ, Petrak ML:** Microsporidiosis in two peach-faced lovebirds. In: Montali RJ (ed): *Comparative Pathology of Zoo Animals*, Smithsonian Press, pp 365-368, 1980.
  70. **Marcial MA, Madara JL:** *Cryptosporidium*: Cellular localization, structural analysis of absorptive cell-parasite membrane - membrane interactions in guinea pigs, and suggestion of protozoan transport by M cells. *Gastroenterology* 90:583-594, 1986.
  71. **McClure HE, et al:** Haematozoa in the Birds of Eastern and Southern Asia. Memorial University, St John's, Newfoundland, 296 p, 1978.
  72. **Meggitt FJ:** A new species of tapeworm from a parakeet, *Brotogeris tirica*. *Parasitology* 8:42-55, 1915.
  73. **Miltgen F, et al:** *Parahaemoproteus desseri* n. sp.; gametogonie et schizogonie chez l'hoite naturel: *Psittacula roseata* de Thaïlande, et sporogonie experimentale chez *Culicoides nebulosus*. *Annales Parasitol Hum Comp* 56: 123-130, 1981.
  74. **Miltgen F, Landau I:** *Culicoides nebulosus*, vecteur experimental d'un nouveau trypanosome de Psittaciformes: *Trypanosoma bakeri* n. sp. *Annales Parasitol Hum Comp* 57:423-428, 1982.
  75. **Mines JJ:** *Ascaridia spreuti*, a new species of nematode in Australian parrots. *Internat J Parasitol* 9:371-379, 1979.
  76. **Mines JJ, Green PE:** Experimental *Ascaridia columbae* infections in budgerigars. *Aust Vet J* 60:279-280, 1983.
  77. **Minsky L, Petrak ML:** Diseases of the digestive system. In: Petrak ML (ed): *Diseases of Cage Aviary Birds* 2nd ed. Philadelphia, Lea & Febiger, 1982, pp 432-443.
  78. **Morata K:** Avian haematozoa and microflaria infections in imported psittacine birds. *J Japan Vet Med Assoc* 43:271-274, 1990.
  79. **Murtaug RJ, Jacobs RM:** Trichomoniasis of the crop in a cockatiel. *J Am Vet Med Assoc* 185:441-442, 1984.
  80. **Myers RK, Monroe WE, Greve JH:** Cerebrosplinal nematodiasis in a cockatiel. *J Am Vet Med Assoc* 183:1089-1090, 1983.
  81. **Page CD, et al:** Antemortem diagnosis and treatment of sarcocystosis in two species of psittacines 23:77-78, 1992.
  82. **Page DC, Schmidt RE, Hubbard GB:** *Sarcocystis* myocarditis in a red lory. *J Zoo Wildl Med* 20:461-464, 1989.
  83. **Panigraphy B, et al:** Diseases of pigeons and doves in Texas: Clinical findings and recommendations for control. *J Am Vet Med Assoc* 181:384-386, 1982.
  84. **Panigraphy B, et al:** Zoonotic diseases in psittacine birds: apparent increased occurrence of chlamydiosis (psittacosis), salmonellosis and giardiasis. *J Am Vet Med Assoc* 175:359-361, 1979.
  85. **Parlington CJ, et al:** Atoxoplasmosis in Bali mynahs. *J Zoo Wildl Med* 20:328-335, 1989.
  86. **Peirce MA:** Blood parasites found in imported birds at postmortem examination. *Vet Rec* 84:113-116, 1969.
  87. **Peirce MA, Bevan BJ:** *Ascaridia galli* (Schränk 1788) in psittacine birds. *Vet Rec* 92:261, 1973.
  88. **Peirce MA, Bevan BJ:** Blood parasites of imported psittacine birds. *Vet Rec* 100:282-283, 1977.
  89. **Poonacha KB, Williams PD, Stamper RD:** Encephalitozoonosis in a parrot. *J Am Vet Med Assoc* 186:700-701, 1985.
  90. **Price RD, Clayton DH:** A review of the genus *Psittacornirmus* (Mallophaga: Philopteridae) from South Pacific parrots (Psittaciformes). *Internat J Entomol* 25: 56-70, 1983.
  91. **Price RD, Emerson KC:** The *Neopsittacornirmus* (Mallophaga: Philopteridae) from *Cacatua* (Aves: Psittaciformes). *Pacific Insects* 18:33-36, 1978.
  92. **Quesenberry KE, et al:** Hepatic trematodiasis in five cockatoos. *J Am Vet Med Assoc* 189:1103-1105, 1986.
  93. **Randall CJ, et al:** Microsporidian infection in lovebirds (*Agapornis* spp.). *Avian Pathol* 15:223-231, 1986.
  94. **Remington KH:** *Myialges nudus* in a lalac-crowed Amazon. *Proc Assoc Avian Vet*, 1990, pp 312-313.
  95. **Roskopf WJ, Woerpel RW:** Pet avian conditions and syndromes. *Proc Assoc Avian Vet*, 1989, pp 394-424.
  96. **Roskopf WJ, Woerpel RW, Roskopf GA:** Blood parasites in caged birds. *Vet Med Sm Anim Clin* 1763-1765, 1981.
  97. **Scholtens RG, New JC, Johnson S:** The nature and treatment of giardiasis in parakeets. *J Am Vet Med Assoc* 180: 170-173, 1982.
  98. **Shane SM, Stewart TB, Confer AW:** *Knemidokoptes pilae* infestation in the palm cockatoo. *Avian/Exotic Pract* 2:21-25, 1985.
  99. **Shoshana R:** *Knemidokoptes*: Mites on feathers of the red-fronted parakeet. *Proc Europ Assoc Avian Vet*, 1993, pp 329-331.
  100. **Smith JH, Neill PJG, Box ED:** Pathogenesis of *Sarcocystis falcatula* (Apicomplexa: Sarcocystidae) in the budgerigar (*Melopsittacus undulatus*) III. Pathologic and quantitative parasitologic analysis of extrapulmonary disease. *J Parasitol* 75:270-287, 1989.
  101. **Smith JH, et al:** Pathology of experimental *Sarcocystis falcatula* infections of canaries and pigeons. *J Parasitol* 76:59-68, 1990.
  102. **Sood ML, Kalia R:** Records of two nematode parasites uncommon in birds. *Acta Parasit Polonica* 23:361-365, 1975.
  103. **Spillmann SK, Ehrsam HR, Ossent P:** *Leucocytozoon*-Infektionen bei Sittichen. *Schweiz Arch Tierheilk* 129:215-219, 1987.
  104. **Stabler RM:** *Trichomonas gallinae*: A review. *Exp Parasitol* 3:368-402, 1954.
  105. **Sundermann CA, Lindsay DS, Blagburn BL:** Evaluation of disinfectants for ability to kill avian *Cryptosporidium* oocysts. *Comp Anim Prac* 1:36-39, 1987.
  106. **Theodoropoulos G, Greve JH:** Observations on the morphology of the eye-worm *Ceratospora inglesi* (Nematoda: Thelaziidae) from a moluccan cockatoo. *Proc Helm Soc Wash* 52: 132-133, 1985.
  107. **Tsai SS, et al:** Cryptosporidiosis in domestic birds. *Chinese J Micro Immunol* 16:307-313, 1983.
  108. **Varghese T:** *Eimeria haematodi* sp. n. (Protozoa: Eimeriidae) from the rainbow lorikeet, *Trichoglossus haematodus*, in Papua New Guinea. *J Parasitol* 63:210-211, 1977.
  109. **Wakelin D:** Nematodes of the genus *Capillaria* Zeder 1800 from the collection of the London School of Hygiene and Tropical Medicine. *J Helminthol* 41:257-268, 1967.
  110. **Webster WA, Speckmann G:** The description of a gubernaculum in *Ascarops strongylina* (Rudolphi 1819) (Spiruroidea) and a note on the recovery of this nematode from a bird. *Canad J Zool* 55:310-313, 1977.
  111. **Wilso RB, New JC, Scholtens RG:** Granulomatous encephalitis caused by schistosomiasis in swans. *J Am Vet Med Assoc* 181:1386-13887, 1982.
  112. **Wojcinski ZW, et al:** An outbreak of schistosomiasis in Atlantic brant geese. *J Wildl Dis* 23:248-255, 1987.
  113. **Yunker CE, Ishak KG:** Histopathological observations on the sequence of infection of knemidokoptic mange of budgerigars (*Melopsittacus undulatus*). *J Parasitol* 43:664-669, 1957.

CHAPTER

---

# 37

TOXINS

---

■  
Genevieve Dumonceaux  
Greg J. Harrison

**B**irds are curious pets and frequently investigate unusual textures, containers and locations throughout the home. Many of the items that birds may encounter during these quests can be dangerous. Contact with or consumption of certain plants, cleaners, pesticides and household disinfectants may cause acute or chronic intoxication. Even some types of foods provided to birds can be toxic.

Most compounds considered toxic to mammals should also be considered toxic to birds. Table 37.1 offers a guide for treatment of intoxication from some common household products. Based on their size and physiology, birds are more prone than mammals to intoxication by some compounds, such as volatile chemicals and fumes. Psittaciformes have a propensity to chew on almost anything. All avian clients should “bird-proof” their homes to provide a safe and enjoyable environment for their companion birds.

Birds should be supervised at all times when out of their enclosures. It has been suggested that the consumption of foreign bodies (eg, metal, wood, jewelry), over-consumption of grit and coprophagy may all be mediated by malnutrition (Gerlach H, unpublished). Therefore, birds on a formulated diet would be expected to chew less on plants, perches and toys than birds on a seed-based diet.

TABLE 37.1 Normal Household Compounds That May be Toxic to Birds

Agent	Toxic Components	Clinical Effects	Therapy
Bleaches, pool chemicals	Chlorine	Photophobia, epiphora, coughing, sneezing, hyperventilation, GI irritation or ulceration	Dilution with water or milk orally. Irrigate skin with cool water. GI protectant, demulcent
Cleaning agents, accumulated excrement	Ammonia	Respiratory tract irritation, immune suppression	Fresh air, antibiotics, supportive care
Combustion exhaust (autos, furnaces)	Carbon monoxide	Somnolence, depression, cyanosis, death	Fresh air, oxygen, warmth, support
Denture cleaners	Sodium perborate	Direct irritation, salivation, lacrimation, vomiting, sometimes CNS depression	Irrigate with water, GI protectant, demulcent
Deodorants	Aluminum chloride, aluminum chlorhydrate	Oral irritation and necrosis, hemorrhagic gastroenteritis, incoordination and nephrosis	Careful lavage of crop and proventriculus
Detergents (anionic)	Sulfonated or phosphorylated forms, alkaline product	Dermal irritation, vomiting, diarrhea, GI distension; usually not fatal	Lavage with water
Detergents (cationic)	Quaternary ammonium with alkyl or aryl substituent groups	Vomiting, depression, collapse, coma, may cause corrosive esophageal damage	Oral milk or activated charcoal. Soap for surface areas. Treat seizures and shock as needed
Drain cleaners	Sodium hydroxide, sodium hypochlorite	Caustic to skin and mucous membranes, irritation, inflammation, edema, necrosis, burns in mouth, tongue, pharynx	Flush affected areas with water or milk. Do not use emetics or lavage. Treat for shock and pain
Fireworks	Nitrates, chlorates, mercury, antimony, copper, strontium, barium, phosphorus	Abdominal pain, vomiting, bloody feces, rapid shallow respiration, chlorates may cause methemoglobinemia	Crop or gastric lavage. Use methylene blue or ascorbic acid for methemoglobinemia. Treat for specific metal(s) ingested
Furniture polish	Petroleum, hydrocarbons, mineral spirits	Early CNS depression, disorientation, necrosis, mucosal irritation, aspiration or hydrocarbon pneumonia, hepatorenal damage	Prevent aspiration pneumonia. Avoid gastric lavage or proceed with caution. Monitor and treat for pneumonia
Gasoline, crude oil	Petroleum and petroleum distillates	GI irritation, skin and feather damage, aspiration pneumonia	Wash feathers and skin with mild soap and water. Vegetable or mineral oil gavage. Antibiotics and supportive care
Matches	Potassium chloride	Gastroenteritis, vomiting, chlorates may induce methemoglobinemia with cyanosis and hemolysis	Treat symptomatically. Use methylene blue or ascorbic acid for methemoglobinemia
Paint/varnish removers	Benzene, methanol, toluene, acetone	Dermal irritation, depression, narcosis, pneumonia, hepatorenal damage	See "furniture polish." Rinse contact areas thoroughly with warm water
Pencils	Graphite	GI irritation	Demulcent
Perfumes	Volatile oils	Local irritation of skin and mucous membranes, pneumonitis, hepatorenal damage with albuminuria, hematuria, glycosuria, excitement, ataxia, coma	If ingested, gastric or crop lavage with weak bicarbonate solution. Prevent aspiration. Demulcents. Provide plenty of ventilation
Pine oil disinfectants	Pine oil 5-10%, phenols 2-6%	Gastritis, vomiting, diarrhea, followed by CNS depression, occasional mild seizures, phenols may induce nephrosis	If ingested, gastric lavage with caution to prevent aspiration. Mineral oil. Monitor pulmonary and renal function. Provide fresh air if strong fumes are present
Overheated non-stick cookware, drip pans, heat lamps, irons, ironing board covers	Polytetrafluoroethylene	Sudden death, dyspnea, depression, pulmonary hemorrhage	Fresh air or oxygen, fluids, steroids for pulmonary edema, antibiotics, supportive care
Poor grade peanuts, peanut waste, moldy grains, corn and corn screenings, moldy cheeses, meats	Mycotoxins: aflatoxin, ochratoxin, trichothecenes	Gastrointestinal irritation, dermal irritation, oral necrosis, secondary infections due to immunosuppression	Clean feed, antibiotics for secondary infections. Treatment as indicated for clinical syndromes


table continued on next page

Agent	Toxic Components	Clinical Effects	Therapy
Rodenticides	Anticoagulants	Weakness, dyspnea, hemorrhage, petechiation, anemia	Vitamin K <sub>1</sub> (2.5-5 mg/kg) IM or PO q 24 hr. Minimize stress. Warfarin, treat for 10-14 days. Chlorophacinone, treat for 21-28 days. Brodifacoum, treat for 28-30 days
Rodenticides	Cholecalciferol	Causes hypercalcemia and renal failure, vomiting, diarrhea, depression, anorexia, polyuria, polydipsia	Activated charcoal, fluid therapy. If hypercalcemic, saline diuresis, prednisolone PO 2 mg/kg q 12 hr, furosemide 2-5 mg/kg q 8-12 hr, salmon calcitonin SC 4-6 IU/kg q 2-3 hr until calcium stable (mammalian protocol)
Rubbing alcohol	Ethyl alcohol	Impaired motor coordination, cutaneous hyperemia, vomiting, progress to peripheral vascular collapse, hypothermia	Gastric or crop lavage. Monitor temperature, cardiac and pulmonary function
Shampoo	Laurel sulfates and triethanolamine dodecyl sulfate	Ocular irritation, stimulation of mucous production, ingestion causes diarrhea	Activated charcoal or kaolin orally
Salt, crackers, chips, prepared foods, salt water, sea sand (as grit)	Sodium chloride	Gastrointestinal irritation, dehydration, depression, weakness, PU/PD, death	Rehydration, offer small amounts of water frequently. SC, IV or IO fluids, supportive care
Styptic pencil	Potassium aluminum sulfate	Corrosive due to release of sulfuric acid during hydrolysis of the salt, oral necrosis from chewing on pencils	Oral neutralizer such as magnesium oxide or hydroxide. Do not give bicarbonate orally for acid poisonings

Many of the therapeutic recommendations for the above products have been taken from small animal sources.<sup>39,46,46a,50</sup>

**TABLE 37.2 Some Commonly Encountered Toxins and their Potential Effects in Birds<sup>1</sup>**

Alcohol	Depression, regurgitation	Levamisole	Depression, vomiting, ataxia, mydriasis, paralysis, death (hepatotoxicity)
Aminoglycosides	Renal tubular necrosis	Lincomycin	Death
Arsenic	Pruritus, polyuria, dyspnea, death	Medroxyprogesterone	Lethargy, obesity, polydipsia, fatty liver
Atropine	Gastrointestinal stasis	Mercury	Depression, hematuria, death
Brodifacoum	Death	Metronidazole	Death in finches
Cephaloridine	Blindness	Nicosamide	Death
Chloramphenicol	Death	Nicotine	Depression, dyspnea, coma, death
Chlorine	Epiphora, upper respiratory signs, tachypnea	Nitrates	Anorexia, vomiting, diarrhea, ataxia, convulsions, death
Chocolate	Vomiting, diarrhea, death	Nitrofurazone	Ataxia, convulsions, death
Cigarette smoke	Dermatitis, sinusitis, pneumonitis	Nitrothiazole	Death
Copper	Anemia, weakness, death	Polymyxin B	Lethargy, ataxia, vomiting, death
Coumarin	Fatal hemorrhage	Polytetrafluoroethylene gas	Dyspnea, seizures, death
Cythioate	Death	Praziquantel	Depression, death
Diazinon	Death	Procaine penicillin	Paralysis, death
Dihydrostreptomycin	Paralysis, death	Rotenone	Vomiting, ataxia, convulsions, death
Dimetridazole	Incoordination, ataxia, seizures, death	Selenium sulfide	Death
Fenbendazole	Depression, ataxia, mydriasis	Sodium chloride	Depression, PU/PD, ataxia, convulsions, death
Formaldehyde	Epiphora, upper respiratory signs, death	Ticarcillin	Hepatotoxicity
Gentamicin	Apnea, renal tubular necrosis, death	Vitamin D <sub>3</sub>	Calcification of kidneys and other organs
Ivermectin (propylene glycol formulation)	Weakness, death	Zinc	Depression, vomiting, ataxia, death
Lead arsenate	Depression, CNS signs, death		



**FIG 37.1** Psittacine birds may be exposed to numerous toxins because of their chewing behaviors. In this case, a conure was presented with lead poisoning secondary to the consumption of lead-containing solder used to hold his feeding dish. The case was further complicated by gastrointestinal impaction secondary to the ingestion of pieces of the plastic dish and malnutrition caused by a diet of wild bird seeds. Clinicians should carefully evaluate the environment in birds with clinical signs consistent with toxicity.

Birds are generally more susceptible to inhaled toxins than mammals because of their rapid metabolic rate, small size, highly efficient respiratory system and low body fat content. In comparison, many compounds that cause intoxication following ingestion by mammals are relatively nontoxic in companion birds; however, birds should be restricted from access to compounds known to be toxic in mammals (Figure 37.1).

Products that produce fumes, fogs or mists are not recommended for use in areas where birds are present. Good ventilation should be maintained to prevent the accumulation of harmful gases and fumes. Some toxins may be absorbed directly through the skin causing systemic intoxication, while others cause localized reactions (eg, nicotine dermatitis). Systemic intoxication could occur from birds perching on wood or branches treated with preservatives or pesticides.

A bird's response to a toxin may vary depending on the age, size, health status and plane of nutrition of the patient, as well as on the route, duration and quantity of toxin exposure. A malnourished bird is more likely to develop clinical problems from a toxin exposure than is a bird on an adequate diet. A bird suffering from chronic malnutrition is more likely to develop pansystemic diseases following exposure to toxic agents. Table 37.2 lists some compounds that have been associated with toxicity in birds and their principal clinical changes.

Free-ranging birds, particularly Anseriformes, are commonly poisoned through chronic exposure to a contaminated, abused environment. Toxin-contaminated water, air and food supplies can affect birds through direct contact or through poisoning of components in the food chain. Often the intoxication is subtle, and poisons accumulate over time (eg, lead in waterfowl, organochlorines in birds of prey).

Birds of prey and fish-eating birds are particularly susceptible to contaminants in the food chain because of biologic magnification. It is of interest that the health of free-ranging birds is frequently ignored as a sensitive indicator of human-induced damage to our environment.

In addition to human-related toxins, food and water supplies encountered by free-ranging birds may also be contaminated by biologic organisms that produce their own toxins, including molds (mycotoxins), bacteria (endotoxins) and certain blue-green algae (hepatotoxins).

When submitting samples for toxicologic analysis, it is best to call the laboratory for information on proper sample preparation and shipment. Most laboratories request frozen samples (except whole blood), preferably individually wrapped to prevent cross-contamination. Samples submitted for heavy metal analysis should not be wrapped in foils or contact any metal during shipment. Complete request forms, including the specific analyses to be run and the species involved, improve the speed and accuracy of the results.

Further information on products and chemicals as well as assistance with poisonings is available from the National Animal Poison Control Center, University of Illinois, College of Veterinary Medicine, Urbana, IL 61801, 1-800-548-2423 (credit cards only, \$30 per case) or 1-900-680-0000 (\$20 for the first 5 minutes, plus \$2.95 for each additional minute [\$20 minimum]). This center's experience is limited when dealing with companion birds and they often refer calls to experienced practitioners.

A useful conversion in toxicology analysis is 1 ppm = 100 µg/dl.

## Ingested Toxins

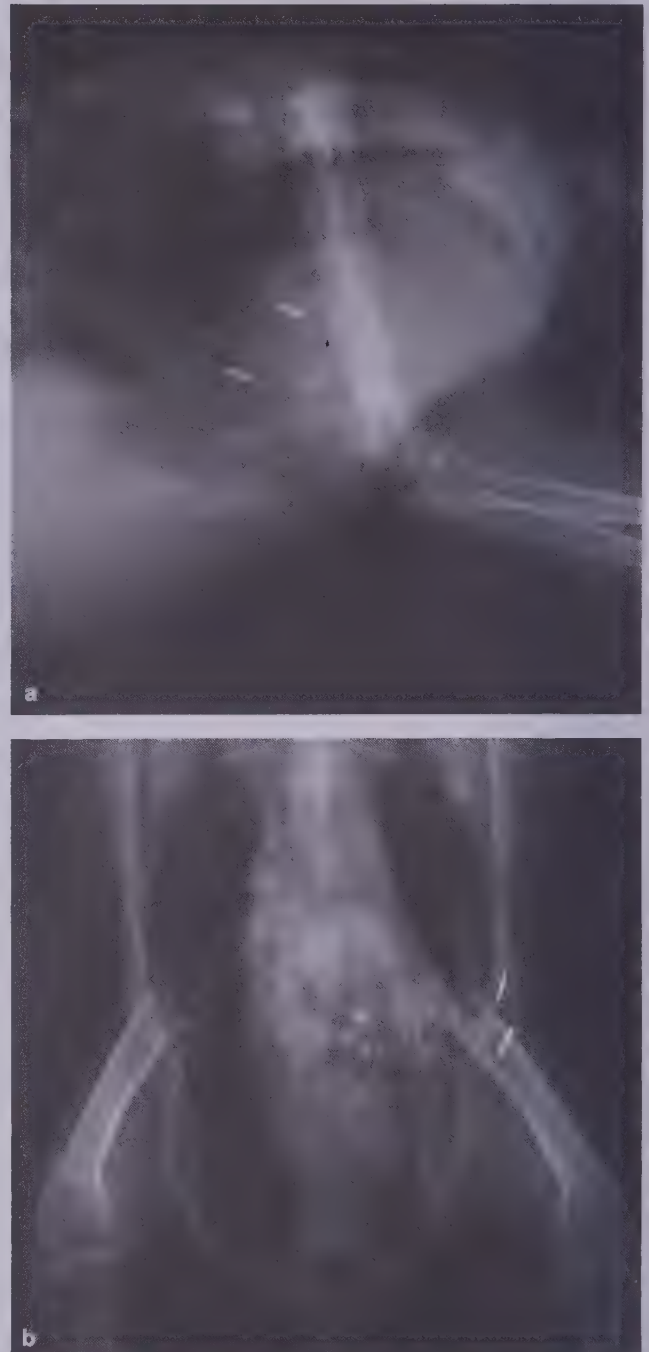
### Lead (Pb)

Lead intoxication is one of the most commonly reported and clinically recognized poisonings of companion and free-ranging birds. Lead is inconspicuously included in numerous products found around the home and the precise cause of lead intoxication is frequently undetermined. Table 37.3 offers some examples of possible household sources of lead. The common lead weights used to balance wheels may be an underestimated source of contamination within a bird's environment. Once ingested, the lead is degraded by acids in the stomach and absorbed into the bloodstream. Raptors can be exposed to lead by ingesting carcasses containing lead shot. Unless paints state that they are "lead free" they may still have toxic levels of lead in the drying agent rather than in the base. Lead exposure may also occur through the inhalation of fumes from lead-containing gasoline (Figure 37.2).

Lead deposited in muscle tissue of birds is generally considered to pose minimal health risks; however, lead shot implanted subcutaneously and intramuscularly in pigeons resulted in decreased levels of delta-aminolevulinic acid dehydratase (ALAD) enzyme activity, indicating the absorption of lead into the bloodstream.<sup>51</sup>

**TABLE 37.3 Potential Sources of Lead**

▪ Weights (curtains, penguin bird toys, fishing and diving, sailing and boating accessories, wheel balances)	▪ Base of light bulbs
▪ Bells with lead clappers	▪ Linoleum
▪ Batteries	▪ Contaminated bone meal and dolomite products
▪ Solder	▪ Leaded gasoline fumes
▪ Lead pellets from shotgun shells	▪ Glazed ceramics (especially imported products)
▪ Air rifle pellets	▪ Costume jewelry
▪ Lead-based paints (varnishes, lacquers)	▪ Contaminated cuttlefish bone
▪ Lead-free paints with leaded drying agents	▪ Plaster
▪ Hardware cloth	▪ Stained glass (decorative glass) – lead seam
▪ Galvanized wire (lead and zinc)	▪ Seeds for planting (coated with lead arsenate)
▪ Champagne and wine bottle foils (some)	▪ Some lubricants (lead naphthalate)



**FIG 37.2** A mature cockatoo was presented with a history of an acute onset of depression, regurgitation and diarrhea. **a)** It is a common but inappropriate practice to obtain only a lateral radiograph when attempting to detect heavy metals in the gastrointestinal tract. **b)** In this case, two metal-density objects that appeared to be in the proventriculus and ventriculus were found to be hemostatic clips that had been used in a previous laparotomy incision.

Lead poisoning and death occurred in an African Grey Parrot that was sprayed with an automobile lubricant<sup>a</sup> to prevent feather picking. The product contained 4.5% lead naphthenate and had previously been used to treat a lovebird that died with a similar clinical progression. Radiographic and clinical pathology data were unremarkable. The bird's only clinical signs were diarrhea, anorexia and depression.<sup>65</sup> Blood lead levels in the bird were 3.9  $\mu\text{mol/l}$  (78  $\mu\text{g/dl}$ ) suggesting lead intoxication. Neither the product label nor information sheet divulged that it contained such a high level of lead.

A simple lead testing kit<sup>b</sup> is available for the detection of lead in environmental samples. A swab supplied with the kit is moistened with a supplied reagent and rubbed against an item to be tested (eg, wire, paint). The tip of the swab turns red if lead is present in the sample. This rapid, in-home test is less reliable than tests performed by commercial laboratories.

### Clinical Signs

Clinically, lead toxicosis may occur as an acute or a chronic problem. Chronic intoxications are most common in Anseriformes and other free-ranging birds. The chronicity of these problems probably occurs because the animals are not evaluated until critically ill from prolonged intoxication. The most commonly reported effect in free-ranging birds is a decrease in population densities. Because companion birds are carefully observed on a daily basis, the non-specific signs of acute lead toxicosis are frequently recognized and birds are presented for medical evaluation.

The presence and severity of clinical signs depends on the amount of lead ingested, the surface area of the particles and the length of time the lead is in the gastrointestinal tract.<sup>19,36</sup> The type and amount of abrasive material in the ventriculus alters the speed of lead digestion and may affect the type of clinical presentation.<sup>36</sup>

Once in the bloodstream, lead causes pansystemic damage, particularly to the gastrointestinal, nervous, renal and hematopoietic systems. Clinical signs of lead intoxication in psittacine birds may include lethargy, depression, anorexia, weakness (wing droop, leg paresis), regurgitation, polyuria, diarrhea, emaciation, ataxia, head tilt, blindness, circling, paresis, paralysis, head tremors, convulsions and death.<sup>19,35,36</sup> Some birds may die with no clinical signs and in others, the only noted abnormalities may be weakness and chronic weight loss.<sup>65</sup> Hemoglobinuria

has been reported as a clinical sign of lead poisoning in Amazon and African Grey Parrots, but it may not occur in all cases.<sup>72</sup> This finding is thought to be secondary to intravascular hemolysis and is frequently misinterpreted as bloody diarrhea.<sup>36</sup> Lead poisoning in waterfowl, cranes and pigeons may cause ileus of the crop, esophagus, proventriculus and ventriculus.<sup>6</sup> In waterfowl and poultry, lead poisoning can cause clinical signs similar to those that occur with botulism. Response to chelation therapy (lead or zinc) or antitoxin (botulism) is suggestive of a diagnosis (see Chapters 28, 33, 46).

### Pathology

In some cases, hematologic parameters may provide an indication of lead intoxication. A hypochromic, regenerative anemia occurs in some affected birds.<sup>36</sup> Basophilic stippling and cytoplasmic vacuolization of red blood cells reported in mammalian lead poisoning cases are not recognized in avian patients.

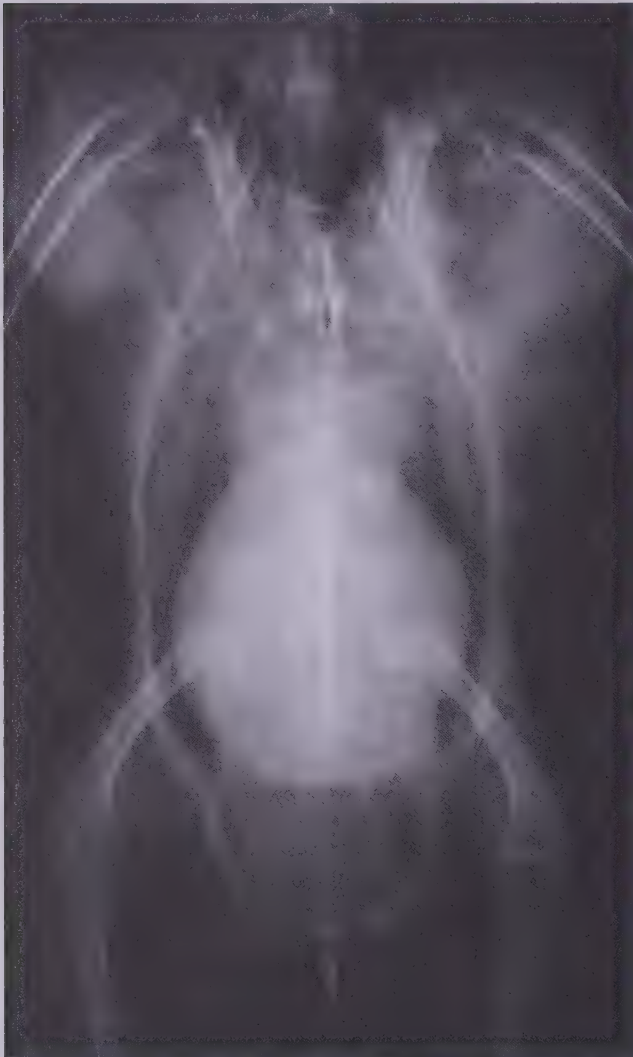
Elevations of LDH, AST and CPK have been reported. Increased LDH and AST are primarily related to liver damage in birds. High CPK activities may be a result of lead-induced neuronal damage.<sup>14</sup>

The functional capacity of the renal system should be carefully evaluated in birds suspected of having lead poisoning. Most commonly used chelating agents have potentially nephrotoxic side effects, and therapy for heavy metal intoxication should be instituted with caution in birds with impaired renal function. There are no reports detailing serious nephrotoxic side effects from the use of chelation therapy in companion birds; however, swans that did not recover from lead poisoning with chelation therapy had markedly elevated uric acid levels, visceral gout and renal nephrosis.<sup>6</sup>

Gross necropsy findings in lead-poisoned swans include weight loss and green liver tissue. Histologic lesions are most severe in birds that survive for several weeks. In these birds, necrohemorrhagic enteritis secondary to *Clostridium perfringens* is common. Other findings include fibrinoid vascular necrosis, renal nephrosis and multifocal myocardial degeneration.<sup>6</sup>

### Radiography

The identification of metallic densities in the gastrointestinal tract of birds with clinical signs of heavy metal intoxication is suggestive. However, the absence of metal densities in the presence of clinical signs does not rule out heavy metal intoxication (Fig-



**FIG 37.3** A two-year-old female Rose-breasted Cockatoo was presented with dyspnea and weight loss (257 g). Abnormal clinical pathology findings included WBC=48,000 (toxic heterophils), LDH=2791, AST=1562, bile acids=291. The bird was negative for chlamydia by ELISA antigen testing of the excrement. Zinc levels were 370  $\mu\text{g}/\text{dl}$ . Radiographs indicated severe hepatomegaly and an auxiliary mass that was determined by cytology to be a lipoma. One week after initiating therapy with CaEDTA, clinicopathologic findings included AST=901, LDH=1500 and bile acids=613.

ure 37.3). In one study involving swans, 25% of lead poisoned birds did not have lead pellets that could be identified by radiographs.<sup>6,19</sup> Some intoxications can occur from absorption of lead that is in a nonradiodense form (eg, paint chips or gas fumes), or a bird can develop clinical signs following the mobilization of lead stored in the bones months after an initial ingestion has occurred.

Metal particles usually are visualized in the ventriculus but may be seen anywhere along the gastrointestinal tract. In chronic cases involving free-ranging birds, eroded pellets have been radiographically documented at necropsy.<sup>19</sup> In some cases, the source of lead may be eliminated from the gastrointestinal tract before clinical signs are recognized.

### Toxicologic Analysis

Several blood tests are available to confirm lead intoxication. They require a small volume of blood, but results require from four days to several weeks. Whole, unclotted blood is the sample of choice for determining lead concentrations because 90% of circulating lead is in red blood cells. Lithium heparin is a suitable anticoagulant. EDTA should not be used because this anticoagulant may interfere with testing.<sup>12,31</sup> Diagnostic blood levels may vary widely between species.

Whole blood lead levels greater than 20  $\mu\text{g}/\text{dl}$  (0.2 ppm; 1.25  $\mu\text{mol}/\text{dl}$ ) are suggestive, and levels greater than 40 to 60  $\mu\text{g}/\text{dl}$  (0.4 to 0.6 ppm; 2.5  $\mu\text{mol}/\text{dl}$ ) are diagnostic of lead intoxication in psittacine birds when accompanied by appropriate clinical signs (Table 37.4).<sup>19,30</sup> Some birds may have clinical signs and respond to therapy with levels as low as 10  $\mu\text{g}/\text{dl}$ . Blood from a normal bird of the same species can be submitted along with that of the ill patient to allow more accurate interpretations of the laboratory results. Higher levels of blood lead have been reported in many avian species with no clinical signs of intoxication.<sup>30</sup>

In cockatiels experimentally exposed to lead, peak blood concentrations ranged from 44 to 129  $\mu\text{g}/\text{dl}$ .<sup>36</sup> In a study involving zinc toxicosis, the cockatiels in the experimental group had a mean blood lead level of 5  $\mu\text{g}/\text{dl}$ .<sup>21</sup> In adult Cuban Whistling Tree Ducks, the blood lead level of one affected bird was 163  $\mu\text{g}/\text{dl}$ ; compared with the normal value of its mate of 32  $\mu\text{g}/\text{dl}$ . An affected Eastern Turkey Vulture in that same report had a blood lead level of 320  $\mu\text{g}/\text{dl}$ .<sup>22</sup> In Mallards and Bald Eagles, values have been reported as high as 500  $\mu\text{g}/\text{dl}$ .<sup>36</sup> A Blue and Gold Macaw with

**TABLE 37.4** Suggested Normal Blood Lead Levels<sup>21</sup>

Swan	6 $\mu\text{g}/\text{dl}$
Mallard	5 – 39 $\mu\text{g}/\text{dl}$
Canada Goose	10 – 37 $\mu\text{g}/\text{dl}$
Pigeon	17 – 81 $\mu\text{g}/\text{dl}$
Cockatiel	5 $\mu\text{g}/\text{dl}$
Most Psittaciformes	<20 $\mu\text{g}/\text{dl}$



lead and zinc poisoning (exposure to galvanized wire) had a reported blood lead level of 50 µg/dl and a blood zinc level of 1500 µg/dl.<sup>40</sup>

With the wide range of lead values reported in blood, this criterion alone may not be sufficient to diagnose clinical lead poisoning.<sup>31</sup> Other reports disagree.<sup>36</sup> With a strong suspicion of lead intoxication, therapy should be initiated while awaiting laboratory results. A rapid response to therapy lends evidence to a diagnosis of lead (or other similar heavy metal) poisoning.<sup>36</sup>

The inhibition ALAD activity has been used as a reliable and sensitive indicator of exposure to lead in ducks.<sup>6,19,36</sup> It also has been recommended as a diagnostic tool in other avian species. In cockatiels, ALAD activities less than 86 units were considered indicative of lead poisoning.<sup>36</sup> In two studies in ducks, lead concentrations of 0.5 ppm in the brain and 200 ppm in the blood were found to correlate with a 75% decrease in ALAD activity in the blood.<sup>7</sup>

Detecting ALAD activity may be of value only in birds with low levels of lead exposure because enzyme activities failed to decrease in humans and pigeons with high exposures to lead.<sup>31</sup> In swans, ALAD activities could not be used as a prognostic indicator for recovery. Additionally, in swans, as the blood levels increased, the ALAD activity was also found to increase rather than decrease.<sup>6</sup> ALAD activity returned to normal in many birds that were treated but subsequently died.<sup>6</sup>

Lead interferes with ALAD activity, which reduces heme synthase activity and causes an increase in protoporphyrin IX concentrations in the blood. Free erythrocytic protoporphyrin (FEPP) and zinc protoporphyrin (ZPP) levels are considered accurate methods of detecting lead intoxication in birds.<sup>31</sup> FEPP levels were found to be suggestive of acute toxicity, while ZPP levels were of more value in documenting chronic lead poisoning. Total protoporphyrin levels were not considered an effective prognostic indicator of recovery.

Blood protoporphyrin levels that exceed 40 ppm are common following lead ingestion. CNS signs occur with levels of 500 ppm. Protoporphyrin levels drop rapidly following chelation therapy. Instrumentation used to measure protoporphyrin levels in humans must be altered by removing the filters to compensate for the low levels of zinc protoporphyrin that occur in avian erythrocytes.<sup>31,55</sup> Diagnostic results may be obtained with one or two microhematocrit tubes of whole blood.<sup>36</sup>

### Treatment

Supportive care for heavy metal poisoning may include chelation therapy (both oral and IM), intravenous lactated Ringer's, 5% dextrose solution, multi-complex B vitamins, iron dextran, antibiotics, assisted alimentation and prophylactic treatment for aspergillosis (waterfowl).<sup>6</sup>

The prognosis for lead intoxication is guarded if chronic exposure has occurred or if the bird has severe CNS signs. In other cases, the response to therapy is dramatic, with most patients responding to chelation therapy within six hours of administration. Many hematuric birds can die in this same time period. Gastrointestinal stasis and impaction of the proventriculus is a complicating factor in waterfowl.<sup>6</sup>

Chelation therapy is designed to remove lead circulating in the bloodstream. Calcium disodium ethylene diamine tetracetate (CaEDTA) or calcium disodium versenate are commonly used chelation agents. The calcium form of EDTA should be used to reduce the chances of drug-induced hypocalcemia.<sup>27</sup>

The recommended dosage of CaEDTA is 10-40 mg/kg twice daily intramuscularly. CaEDTA is poorly absorbed from the gastrointestinal tract and must be used parenterally to remove circulating lead in critically ill patients.<sup>36</sup> Chelation therapy should be used for the least amount of time that is necessary to resolve the intoxication. In general, therapy should not persist for over ten days without a break in drug administration; however, some clinicians have used CaEDTA until there is no radiographic evidence of lead in the gastrointestinal tract (up to 30 days) with no clinically apparent side effects.<sup>28,36,40</sup> CaEDTA may be administered orally at twice the injectable dose two to three times daily in asymptomatic birds to prevent lead from being absorbed.<sup>72</sup> CaEDTA must be used carefully as it may cause gastrointestinal and renal toxicosis.<sup>25,36</sup> If evidence of chelation toxicosis is seen (eg, polydipsia, polyuria, proteinuria, hematuria), CaEDTA should be discontinued for a period of five to seven days. Therapy can then resume if the patient is stable.

D-penicillamine (PA) is an effective lead chelator that can be used orally (55 mg/kg twice daily). It has been suggested that PA may increase the gastrointestinal absorption of lead;<sup>30</sup> however, more recent reports suggest that PA is a superior chelating agent to CaEDTA and does not increase absorption.<sup>37</sup> Combining CaEDTA and PA for several days until a bird is asymptomatic followed by the use of PA for three to

TABLE 37.5 Chelating Agents for Heavy Metal Toxicities

CaEDTA	Beryllium, copper, cerium, iron, zinc, lead
BAL (dimercaprol)	Arsenic, gold, mercury, copper, iron, nickel, thorium, zinc, lead
D-Penicillamine	Copper, mercury, lead, zinc

six weeks may prove to be the best therapeutic regime for lead poisoning. Birds should be monitored for clinical signs of copper depletion including lethargy, anemia and weight loss.

Dimercaprol (British Anti-Lewisite - BAL) is the best agent for removing lead from the CNS; however, this agent is rarely used because of its low therapeutic index and the positive response of most birds to PA or CaEDTA. The recommended treatment regime is 2.5 mg/kg IM every four hours for two days, then twice daily for up to ten days or until clinical signs resolve (Table 37.5).<sup>27</sup>

Lead-induced seizures can be controlled with diazepam at 0.5-1 mg/kg intramuscularly two to three times daily as needed.<sup>36</sup> The primary therapy for any heavy metal intoxication is to remove the source of the toxin from the body. Both surgical and nonsurgical approaches may be useful, depending on the circumstances of an individual case.

Emollient cathartics (mineral oil or peanut butter) can be administered to aid in the passage of small particles of heavy metal out of the gastrointestinal tract. Other substances that have been used to aid in the passage of heavy metal particles include barium sulfate, psyllium and corn oil. The comparative effectiveness of these agents has not been determined. The use of sodium sulfate (Glauber's salts) has also been recommended for the removal of lead.<sup>16</sup> Additionally, this agent can be mixed with activated charcoal and used following the ingestion of unknown toxins for its cathartic and absorptive effects. Sulfate will bind free lead in the gastrointestinal tract forming an insoluble lead sulfate that cannot be absorbed (mode of action similar to oral Ca EDTA and PA). Treated birds will generally develop diarrhea, and patients must be carefully monitored to prevent dehydration and severe electrolyte imbalances.<sup>16</sup> The sodium sulfate is given as a slurry for up to two doses (in large birds) or until lead is gone from the gut. Aluminum sulfate is very irritating to the kidneys and is not recommended. Magnesium sulfate is not recommended as the released magnesium is depressing.<sup>16</sup>

An experimental chelating agent, dimercapto succinic acid (DMSA) has been found to improve survival

from lead poisoning by 35 to 50% when used in conjunction with CaEDTA in swans.<sup>1,6,35</sup> This drug is experimental and requires a special FDA permit. The experimental dose is 25 to 35 mg/kg BID orally for five days per week for three to five weeks.

The administration of three to five appropriately sized pieces of grit may help in the removal of metal particles from the ventriculus by reducing their size<sup>27</sup> and facilitating passage, particularly when used in conjunction with psyllium (hemicellulose).<sup>40</sup>

Activated charcoal is recommended to bind small lead particles in the gastrointestinal tract and make them unavailable for absorption. The small animal dose for activated charcoal is 2 to 8 g/kg body weight.<sup>46</sup> This should be gavaged as a slurry with water according to manufacturer's instructions. Activated charcoal will be inactivated if administered with mineral oil. Activated charcoal may be administered one to two hours before administration of a cathartic. This allows sufficient time for free heavy metals to be bound to the charcoal before the system is purged.

Endoscopic removal of heavy metal particles using appropriate forceps<sup>30</sup> or gastric lavage can be attempted in stable patients that are of sufficient size to tolerate this procedure.<sup>6</sup> This technique is particularly effective when metal fragments in the ventriculus are too large to pass through the lower gastrointestinal tract in a reasonable period of time. Lead particles were removed from the gastrointestinal tract of swans by fasting eight to twelve hours followed by the insertion of a 110 cm tube into the ventriculus. The birds were tilted head down at a 45° angle and warm water was pumped into the ventriculus using a gastric lavage syringe.<sup>6</sup> The contents were filtered through a towel to evaluate the number of particles removed. Radiographs of the head, neck and abdomen were used post-lavage to determine the presence and location of any remaining lead particles.<sup>6</sup> Occasionally, a proventriculotomy may be necessary if other attempts to remove metal particles fail (see Chapter 41).<sup>56,72</sup>

### ■ Zinc (Zn)

Zinc is another frequently encountered heavy metal that causes toxicity when ingested by birds. Zinc toxicosis should be included in the differential list when heavy metal intoxication is suspected. Galvanized wire and the clips used to construct enclosures are common sources of zinc. The clinical syndrome

described in birds that ingest zinc from a wire enclosure is frequently referred to as “new wire disease.”<sup>40</sup> The brighter and shinier the wire, the higher the zinc level.<sup>21</sup> The occurrence of “new wire disease” can be reduced (but not eliminated) by scrubbing the wire with a brush and mild acidic solution (vinegar).<sup>50</sup> Galvanized wire may also contain lead.<sup>40</sup> Some galvanized coatings contain 99.9% zinc while others are 98% zinc and 1% lead. The white rust associated with the galvanized coating is also toxic.<sup>21</sup> Galvanized containers and dishes are other sources of zinc contamination.<sup>27</sup> Pennies minted in the USA since 1982 contain from 96% to 98% zinc that is coated with copper.<sup>1,29,30,40</sup> Monopoly™ game pieces are made of 98% zinc.<sup>1</sup>

A duck from a zoological collection developed an acute onset of weakness and depression and died during examination. On necropsy, the ventriculus contained five tightly stacked, well eroded pennies. Some were minted after 1982. Pennies thrown into the duck's pond by park visitors were the source of intoxication.<sup>30</sup>

Common signs reported in zinc-intoxicated birds include polyuria, polydipsia, gastrointestinal problems, weight loss, weakness, anemia, cyanosis, hyperglycemia and seizures.<sup>28,30,50,68</sup> Systemic effects are related to hypoproteinemia-induced damage in the kidneys, gastrointestinal system and pancreas.<sup>52</sup> There are two cases of zinc depressing fertility, one in a male Mallard<sup>16</sup> and one in a female Black Bustard.<sup>30</sup>

Cockatiels fed the zinc coating from galvanized wire, or white rust from the same wire, developed clinical signs that included lethargy, weight loss, greenish diarrhea, ataxia, recumbency and death. This was the most common presentation in acute cases. A more chronic clinical course was characterized by intermittent lethargy, dysphagia and depression. Gross necropsy findings were limited to ileus. Histopathologic changes included focal mononuclear degeneration in the liver, kidney and pancreas.<sup>21</sup>

Serum concentrations of zinc can be used to confirm a diagnosis. Samples must be properly collected and stored to avoid extraneous contamination. Only glass or all-plastic syringes and tubes should be used for samples intended for zinc analysis. Rubber stoppers on serum tubes and the grommets on most plastic syringes can be a source of zinc contamination.<sup>37</sup> Serum tubes with royal blue-colored stoppers are free of zinc and are best for sample handling. A serum


sample collected from a clinically normal bird of the same species and handled identically will assist with interpreting results. In general, blood zinc levels of greater than 200 µg/dl (2 ppm) are considered diagnostic for zinc toxicosis.<sup>40</sup> In a group of normal cockatiels, the mean blood zinc level was found to be 163 µg/dl (1.63 ppm). The pancreas proved to be the best tissue for postmortem zinc level determination. Before exposure, the mean pancreatic zinc levels were 26.11 µg/g dry weight. The level in zinc-intoxicated birds ranged from 312.4 µg/g to 2418 µg/g.

Calcium EDTA is recommended as an effective chelating agent.<sup>30,42,54</sup> D-penicillamine is also useful. Radiographically and clinically, zinc toxicosis cannot be differentiated from lead intoxication. Fortunately, the therapy is the same for poisonings caused by either of these heavy metals. The primary treatment involves removal of the foreign body. If a bird has ingested galvanized wire, this zinc-coated ferrous metal can be removed using a powerful neodymium-ferro-barium alloy magnet attached to a small diameter catheter with a removable, flexible steel grid wire (see Figure 19.13).<sup>32</sup>

Fluoroscopy-guided removal is ideal; however, particles can also be removed by repeatedly passing the apparatus into the ventriculus until no further metal particles are removed. The success of the removal process can be determined with radiographs (Figure 37.4).<sup>32</sup> Often, zinc foreign bodies can be removed with bulk cathartics (sodium sulfate), activated charcoal or mineral oil as described for lead. Gastroscopic removal using blunt-jawed forceps has been described.<sup>32,40</sup> Surgical removal may be necessary if the object cannot be removed with other methods. It may be necessary to monitor packed cell volumes periodically if the bird is anemic.

### Copper (Cu)

Factors that have been shown to affect the toxicity of copper in mammals include dietary zinc and molybdenum concentrations.<sup>46</sup> There are wide differences in how various animal species maintain copper homeostasis in the body, and birds appear to tolerate higher levels of copper than many mammals. Some reports have suggested that water contaminated with antifouling paints can be a source of copper intoxication in waterfowl.<sup>39</sup> Other sources of copper include copper wire, chronic over-supplementation in the diet, pennies minted before 1982 or any copper-coated objects small enough to be ingested. In a warm climate, copper sulfate used to control algae on a



**FIG 37.4** An adult Amazon parrot as presented with an acute onset of depression and regurgitation three days after a lead sinker was placed in the bird's enclosure as a toy. The metal in the crop, esophagus and proventriculus was removed either by endoscopy or gastric lavage. The bird was given oral D-penicillamine and a bulk laxative (psyllium). Response to therapy was excellent.

pond accumulated over time and caused the intoxication and death of swans.

Clinical abnormalities associated with copper intoxication have rarely been reported in birds. There have been reports of Mute Swans tolerating liver copper residues of up to 1000 mg/kg.<sup>13</sup> A Mute Swan with inanition, anemia and generalized weakness showed signs of toxicity with liver copper levels in excess of 3000 mg/kg and over 50 mg/kg copper in the kidneys.<sup>13</sup> Evidence of intravascular hemolysis (which is described in mammals) has not been documented in waterfowl.<sup>13,39</sup> Postmortem findings following copper intoxication include anemia and coal-black discoloration of the liver (see Color 20).<sup>39</sup>

D-penicillamine increases the renal excretion of copper and is the chelating agent of choice for copper toxicosis in mammals. In mammals, a dose of 52 mg/kg/day for six days has been recommended.<sup>48</sup> High-quality nutritional support is necessary to prevent chelation and removal of other vital minerals. Supportive care with fluids, warmth and minimal stress may aid in recovery. In severely anemic birds, blood transfusions may be necessary. In advanced cases the prognosis is poor.

#### Mercury (Hg)

Mercury poisoning is becoming an environmental concern as levels in water continue to rise. Fish

accumulate mercury, which is then further concentrated in fish-eating birds. An Amazon parrot that consumed the back of a mirror died following a period of profuse hematuria.<sup>34</sup> BAL (and presumably DMSA) and D-penicillamine chelate mercury.

#### Arsenic (Ar)

Polyuria, polydipsia, feather picking, pruritus, weight loss, dyspnea (air sacculitis), egg binding, poor feathering and death occurred in a group of aviary birds, presumably secondary to the consumption of arsenic-contaminated mineral block. Necropsy findings included cystic ovaries and adrenal gland enlargement. Clinical changes started when a new group of mineral blocks was used in the aviary. These blocks were found to contain 0.5% arsenic, and all clinical problems in the birds resolved when the mineral blocks were removed.<sup>67</sup>

#### Oil

Crude oil is extremely toxic, and quantities of 0.3  $\mu$ l placed on the outside of eggs caused death in 50% of embryos; the embryos that survived had malformations of the eye, brain and beak. Generalized edema, hepatic necrosis, cardiomegaly and splenomegaly were noted also.<sup>45</sup>



**FIG 37.5** The pelletized fertilizers found on the surface of the soil in many house plants are more of a threat to companion birds than the houseplant itself. These encapsulated products contain high levels of nitrates that can be rapidly fatal (courtesy of Genevieve Dumonceaux).

### Selenium

A dog shampoo containing selenium sulfide caused the death of a budgerigar.<sup>19</sup>

### Nitrates

Nitrates are common components of fertilizers and may cause polydipsia, dyspnea, cyanosis and death following ingestion. The pelletized form of nitrate-containing fertilizers are particularly hazardous because they resemble seeds and may be readily consumed by birds (Figure 37.5).<sup>19</sup>

### Plants

Clients are frequently concerned when a bird consumes a houseplant; however, plant intoxications are rare (Table 37.6). Free-flying companion birds frequently encounter and consume a variety of plants found in the home, few of which are at all toxic, some of which are thought to be toxic and some of which are of unknown toxicity. Determining the amount of plant ingested is always difficult, because birds seem to enjoy shredding leaves more than ingesting them. There have been few documented cases of plant poisonings in birds, and their rapid gastrointestinal transit time is thought to play a role in the low incidence of intoxication.

The ability of parrots to consume plants and fruits that are deleterious to other animals may have allowed these birds to reach their current widespread

**TABLE 37.6** Poisonous Plant Cases Documented in Birds

Avocado	Psittaciformes (C,E)
Black Locust	Budgerigars (E)
Clematis	Budgerigars (E)
Diffenbachia	Canaries (E)
Foxglove	Canaries (E)
Lily of the Valley	Pigeons (C,E)
Lupine	Canaries (E)
Crown Vetch	Budgerigars, cockatiels, lovebirds (C)
Oleander	Budgerigars, canaries (E)
Parsley	Ostriches (C), ducks (E)
Philodendron	Budgerigars (E)
Poinsettia	Budgerigars (E)
Rhododendron	Budgerigars (E)
Virginia Creeper	Budgerigars (E)
Yew	Pheasants (C), canaries (E)

C = clinical report; E = experimental

The state of an animal's health should be expected to have an impact on its response to ingested plants. The experimental doses used to demonstrate that some of these plants were toxic are not likely to occur in natural settings.

distribution in the wild.<sup>42</sup> It has been proposed that parrots can consume toxic plants because they carefully remove the outer covering, which frequently contains the highest concentration of toxins. Alternatively, it has been suggested that the consumption of clay by free-ranging birds may serve to absorb some toxic materials and prevent them from passing through the gastrointestinal mucosa. However, many birds consume potentially toxic plants and only macaws have been observed consuming clay. It is more likely that the ingested plant material is eliminated before dangerous levels of the toxic component can be systemically absorbed.<sup>12</sup> The Cedar Waxwing and the House Finch can safely consume fruit from the pepper tree (*Capsicum annuum*) that is toxic to mammals.<sup>43</sup>

In one study, yew, oleander, Virginia creeper, black locust, clematis and avocado<sup>59</sup> were described as toxic to budgerigars when administered by gavage. Many other plants that were tested had no harmful effects under the same testing conditions. In another study, oleander, lily of the valley, rhododendron, poinsettia and philodendron were not found to be major health hazards for budgerigars.<sup>12</sup>

In a similar study involving canaries, oleander, lupine, foxglove, yew leaves and diffenbachia were considered to be highly toxic. Nine other plants that have traditionally been considered toxic (parsley, hoyo [wax plant], rhododendron, black locust, wis-

teria, clematis, cherry, pyracantha [fire thorn] and privet) caused no, or only transient, clinical problems. Most canaries that died did so within minutes to hours following the ingestion of the plants.<sup>2</sup>

Split-leaf philodendrons have been used in some aviaries in Florida for years with no signs of toxicity. However, in one case, two Amazon parrots that destroyed a large split-leaf philodendron had a two-hour course of lethargy and vomiting followed by complete, unsupported recovery.

Cherries, plums and peaches (*Prunus* spp.) have pits containing seeds that produce cyanogenic glycosides; however, there are no reports of cyanide poisoning in birds following the ingestion of these fruits. It has been suggested that cyanide poisoning may be more common in ruminants because of a rapid enzymatic degradation of the glycoside to free cyanide. Alternatively, detoxification may be more effective in simple-stomached animals.<sup>12</sup>

Avocados (*Persea* spp.) have recently been suggested as toxic for companion birds. At one time it was believed that only the pit was a danger; however, some studies suggest that all parts of the avocado, including the fruit, are toxic to birds.<sup>5,18</sup> The toxin in the avocado has not been described.<sup>5</sup> There are several varieties of avocados commercially available (eg, Guatemalan, Mexican, Nabal and Fuerte), which appear to differ in their toxic capacity. In one study involving rabbits, the Guatemalan and Nabal varieties caused death from pulmonary congestion within 24 hours after ingestion.<sup>5</sup> The Mexican variety was nontoxic.<sup>5</sup>

Signs of avocado toxicity (Guatemalan and Fuerte varieties) in budgerigars and canaries include cessation of perching, anorexia, fluffed feathers, increased respiratory rate, outstretched wings and death. At necropsy, intoxicated birds are in good overall condition, and the crop and ventriculus may be full of ingesta, indicating the acute nature of the toxicity. Subcutaneous edema of the pectoral region has been reported in some affected birds, and others will have pectoral muscles that bulge slightly above the sternum with mild pale streaks running parallel to the muscle fibers. Histologic lesions have been limited to generalized congestion, especially in the lungs.<sup>18</sup>

To the authors' knowledge, a specific treatment regimen for avocado intoxication in birds has not been established. Based on clinical signs and postmortem findings, activated charcoal and general supportive measures such as oxygen, warmth and perhaps a



**FIG 37.6** Crown Vetch ingestion has been associated with tremors, opisthotonos, seizures and death in budgerigars, cockatiels and lovebirds (courtesy of Michael Lutz).

mild diuretic may be indicated. Birds have been reported to die as soon as 9 to 15 hours after consuming avocado. Some birds died within 10 to 15 minutes after developing signs of respiratory distress without prior clinical signs.<sup>18</sup>

Budgerigars, cockatiels and lovebirds developed tremors, opisthotonus and seizures twelve hours after consuming crown vetch (Figure 37.6). Eighty percent of the birds with clinical signs died despite treatment. Deaths in the flocks reached 10% until the plant was removed, and no further losses were reported.<sup>33</sup> The inciting toxin was not confirmed, but may be a cyanide.

Oak toxicosis (coast live oak - *Quercus agrifolia*) was confirmed in a cassowary that consumed the leaves. Clinical changes included anorexia, ataxia, diarrhea, severe polydipsia and death. Necropsy revealed diffuse serosal hyperemia, ulcers and hemorrhage in the small intestine. Liver tissue and gastric contents tested for tannins showed levels of 178 and 340 ppm respectively, which supported the diagnosis of oak toxicosis.<sup>23</sup>

Rape seed has been suggested as a hepatotoxin; however, canary breeders routinely feed soaked rape seed to breeding canaries and their offspring without a problem. Parsley has been shown to cause photosensitization and skin lesions in ostriches and experimentally in ducks.<sup>44</sup>

### ■ Mycotoxins

Mycotoxins are chemical metabolites produced by various species of fungi that grow on grains and foodstuffs. Each fungus has its own light, temperature and moisture requirements.<sup>74</sup> Some of these fungi grow on crops in the field during periods of high moisture content (*Fusarium* spp.). Others grow on foods during storage, when moisture contents are relatively low (*Aspergillus* spp.). Aflatoxin production can be decreased by storing food in a low-oxygen, high-CO<sub>2</sub> environment. In areas of the southern United States, where the preferred conditions for aflatoxin production are common (25-30°C, humidity 85%), refrigeration of food is often necessary to prevent aflatoxin production.

The conditions that induce a fungus to produce toxins may be different than those needed for fungal growth; therefore, the fungus can grow without toxin production. Likewise, the toxin can be present after the fungus has stopped reproducing. Clinically, this means that the presence of a fungus on a foodstuff does not necessarily indicate that a toxin is present, nor does its absence mean that food or grain is free of mycotoxins.

The amount of toxin present can vary within any given batch of grain or feed. Depending on the storage methods and size of the stored sample, one area may have no detectable mycotoxin, while another may have a very large concentration (known as a "hot spot"). Attempts to determine if mycotoxins are present using ultraviolet light are of little value, because both false-positive and false-negative results are common.

Toxins can enter an avian host through surface-to-skin contact. The effects of mycotoxin exposure can vary based on the type of toxin and on the species, nutritional state and physiologic status of the patient. A stressed bird or one on a poor diet is more likely to be poisoned by a lower dose of mycotoxin than is a healthy, well-fed bird. Ducklings have been shown to be much more sensitive to aflatoxin than chicks, indicating species variance in sensitivity.<sup>41</sup>

There are no specific antidotes for mycotoxicoses. It is easier to prevent exposure to mycotoxins than to attempt treatment following their ingestion. All foods and seeds available to birds should be clean and fresh. Foods that are dusty, damaged by insects or have molds present should not be offered to birds. Particular caution should be exercised with poor quality corn and peanuts, as these are common sources of toxin-producing molds. Some high-quality formulated diets are certified free of mycotoxins. Treatment involves providing clean food free of molds, supportive care, broad-spectrum antibiotics and specific therapies for clinical signs.

There are four main mycotoxins of concern to birds: aflatoxin B<sub>1</sub>, ochratoxin A, deoxynivalenol (vomitoxin) and the trichothecenes, especially T<sub>2</sub> toxin. These are all potent mycotoxins that affect different body organs or systems. The molds producing these toxins can grow on various foods, including grains, peanuts and peanut products, breads, meats, cheeses and cereal grains. Whole kernel peanuts of apparently good quality can harbor high concentrations of aflatoxins.<sup>74</sup> Brazil nuts are banned in Austria because a mycotoxin-free nut was not available (Hochleithner M, unpublished). Diagnosis is based on clinical signs, postmortem and histopathologic findings, and detecting high quantities of the toxin in the gastrointestinal contents or the food. However, it is difficult to establish a diagnosis of mycotoxicosis in birds. Clinical and histologic changes usually mimic other diseases or may be due to secondary infections. Often, by the time signs are apparent, the toxin-contaminated food source has already been consumed and is not available for evaluation.

Aflatoxin B<sub>1</sub> is a known hepatotoxin. It is produced by *Aspergillus* spp. and may cause depression, poor growth, anorexia and other signs related to liver disease. Postmortem changes include an enlarged, pale liver (probably the result of fatty infiltration), an enlarged spleen, an enlarged pancreas, atrophy of the cloacal bursa and less-than-normal body fat deposits (see Color 20).<sup>61</sup>

Aflatoxins inhibit protein and nucleic acid synthesis. Microscopic examination shows hepatic cell degeneration and bile duct hyperplasia. The kidneys may have swollen proximal convoluted tubules.<sup>41</sup> Anticoagulant activity is altered, and a bird with a prolonged whole blood clotting time and prothrombin time may be suffering from aflatoxicosis. Gastrointestinal hemorrhage is also common. Immunosuppression through a reduction in alpha and beta

globulins has also been linked to aflatoxin exposure. Serum electrophoresis to detect this IgG pattern may be useful in diagnosing aflatoxicosis.

The trichothecenes, including T<sub>2</sub> toxin, are produced by *Fusarium* spp., which commonly grow on crops in the field. This toxin has corrosive effects on the mucous membranes of the oropharynx, and occasionally the gastrointestinal tract, causing necrotic lesions of the hard palate and other oral areas. Lesions can appear within 48 hours of ingestion.<sup>58</sup> Trichothecene intoxication in Sandhill Cranes caused signs including flaccid paralysis of the wing and neck, depression and flying with the head and neck perpendicular (in those birds that could fly). These birds were exposed to waste peanuts that contained high levels of trichothecenes.<sup>71</sup> Peanut farmers are encouraged to plow ground containing waste peanuts to prevent their consumption by free-ranging birds, particularly Sandhill Cranes.

Trichothecene T<sub>2</sub> toxin may also cause contact dermatitis (from contaminated litter), poor growth and feathering, constrictive lesions of the digits (dry gangrene) and occasionally neurologic disorders.<sup>71,73</sup> In one study, a high incidence of T<sub>2</sub> toxin was reported in grains heavily damaged by insects.<sup>4</sup>

Histopathology of affected birds may reveal congestion and hyperemia of the gastrointestinal tract, hemorrhagic myositis, hepatic and renal swelling and congestion.<sup>71</sup> In chronic cases, evidence of secondary infections may be noted.

Ochratoxin is produced by species of *Aspergillus* and *Penicillium* fungi. The toxin has an immunosuppressive effect and has been associated with air sacculitis, nephrotoxicity, CNS signs, hepatotoxicity and bone marrow suppression. It has been shown to cause depression of the immunoglobulin-containing cells in the lymphoid organs.<sup>9</sup> Clinical changes are commonly related to secondary infections that take advantage of a depressed immune system.



**FIG 37.7** Birds should not be allowed to consume high-salt foods, chocolate in any form or alcoholic beverages (courtesy of Genevieve Dumonceaux).

### ■ Ethylene Glycol

Free-ranging birds may consume ethylene glycol. In gallinaceous birds, consumption of antifreeze has been associated with lethargy, ataxia and polyuria. Characteristic calcium oxalate crystals form in the kidneys.<sup>28</sup>

### ■ Harmful Foods

Clients frequently share favorite foods with their companion birds; however, some of these treats can be life-threatening through a single or chronic exposure. Chocolate is contraindicated as a treat for any pet, including birds. Consumption of small quantities of chocolate can result in hyperactivity, vomiting, diarrhea, cardiac arrhythmias, seizures, dark-colored feces and death. The progression of these effects can be rapid when large concentrations of the active ingredients (theophylline and caffeine) are ingested. A rule of thumb for chocolate toxicity is that the less sugar that is present, the more of the toxic active ingredients there are in the product. It is best to avoid feeding any type of chocolate to birds (Figure 37.7). Treatment for chocolate toxicosis includes the administration of gastrointestinal protectants and cathartics.

Excessive consumption of sodium chloride can cause polydipsia, polyuria, depression, neurologic excite-



ment, tremors, opisthotonos, ataxia and death. Necropsy changes are generally limited to cerebral edema and hemorrhage.<sup>28</sup>

Consumption of alcoholic beverages can lead to severe ataxia and death. Additionally, birds may become intoxicated if compounds containing high levels of ethanol (STA) are used to clean open wounds.

## Iatrogenic Intoxications

Properly administered medications can be life-saving; however, many drugs have a low therapeutic index, and the safest of drugs may be toxic in excess quantities. Pre-existing systemic disease, nutritional status, state of hydration, drug interactions, carrier agents and species-specific idiosyncracies of a particular therapeutic agent should all be considered before initiating drug therapy (see Chapter 18). The most common cause of iatrogenic drug toxicosis is a failure to base the dose on an accurate weight. A dosing table<sup>d</sup> that can be used to quickly and accurately determine drug dosages is commercially available.

There are only a few therapeutic agents approved for use in birds; however, many drugs approved for other species can be beneficial in the treatment of sick and injured avian patients. Administering drugs at the proper dose, at an appropriate time interval, through a recommended route of administration and with consideration for patient-specific contraindications will minimize the potential for iatrogenic intoxications.

Some drugs given parenterally at the appropriate dosage (especially IM) can cause various degrees of local tissue damage (see Figure 17.4). Many of these reactions can be attributed to the carrier in the formulation. Injectable products that contain propylene glycol (PG) or oil as a carrier may cause an abscess or toxic reaction. Oral consumption of propylene glycol has not been reported to cause acute signs of toxicity, but the long-term effects of PG used as a food preservative have not been studied in birds. In cats, ingestion of PG can cause anemia. Ethoxyquin is another food preservative that may have unreported toxic side effects. This compound was originally used

as a herbicide, and there have been some discussions that it may cause reproductive abnormalities in dogs.

### Anthelmintics

Ivermectin in a PG base may cause toxic reactions when administered IM to budgerigars. Oral or topical administration is safer and equally efficacious. Ivermectin that is diluted in PG and allowed to stand should be mixed thoroughly before administration. Oral administration of a product that was not shaken caused seizures in several canaries and budgerigars. High-dose steroids reversed the clinical signs in these cases. Ivermectin persists in the environment and is excreted unchanged in the urine. Low concentrations that accumulate in water are extremely toxic to crustaceans, and whales may be particularly sensitive to this drug.

Dimetridazole was shown to have a low therapeutic index when added to the drinking water of cockatiel chicks. In nestlings (one to eight days old), the recommended concentration of 0.1% dimetridazole in the drinking water caused signs of toxicity including weakness, depressed growth rates, tremors and death. Older nestlings (over eight days old) showed no signs of toxicity at 0.1% concentrations.

At 0.5% dimetridazole, older birds developed signs of ataxia, weakness, inactivity, tremors, extensor rigidity of the legs and necks, and death. Consistent necropsy findings included multiple hemorrhages, pale livers and enlarged, pale kidneys. Treatment of adult cockatiels at the recommended dose appears to be safe. Dimetridazole should not be used in the drinking water during the breeding season when males may consume excess quantities of the drug and feed it to nestlings, causing toxicosis and death.<sup>60</sup>

Vetisulid and some other sulfa-containing antibiotics have been reported to cause hypersensitivity reactions leading to a hemorrhagic syndrome in gallinaeous birds.<sup>17</sup> They may also interfere with renal tubular excretion and are contraindicated in dehydrated or uricemic patients.<sup>10</sup> These antimicrobial agents should be limited in use to sensitive bacteria and the treatment of coccidiosis.<sup>17</sup>

Levamisole hydrochloride (oral) and levamisole phosphate (injectable) have been used to treat intestinal parasites in birds. Side effects associated with these agents in Psittaciformes and Galliformes include regurgitation, ataxia, recumbency, catatonia, dyspnea and death. Effects are immediate, and sur-

viving birds are clinically normal within one hour after administration. The dosage range used to study toxic effects in birds was 22-100 mg/kg. A dose rate of 22 mg/kg was considered effective for some parasites and was well tolerated by many genera of aviary birds.<sup>66</sup> Regurgitation is the most common side effect associated with oral levamisole administration, and food and water should be withheld for several hours prior to dosing.

The parasiticides praziquantel and fenbendazole have been reported to cause problems in finches and pigeons ranging from feather malformations to vomiting and death.

### Antibiotics

Aminoglycosides have a narrow therapeutic index and are nephrotoxic. Gentamicin causes severe renal tubular necrosis and is the most frequently discussed member of the group. Systemic, topical and ophthalmic canine products can cause nephritis and are generally contraindicated in all companion birds. Amikacin is a safer alternative when an aminoglycoside is indicated. Renal function should be monitored during treatment. Administration of aminoglycosides into the leg is generally avoided due to the renal portal system of birds. It is speculated that drug administration in the leg muscles may cause excessive renal concentrations of the aminoglycoside, increasing the potential for nephrotoxicosis. If an intoxication is suspected, the antibiotic should be discontinued and diuresis with physiologic saline should be initiated immediately.

Tetracyclines, cephalosporins (especially cephaloridine) and amphotericin B<sup>50</sup> may also cause nephrotoxicosis in patients with impaired renal function.

Procaine penicillins have been associated with some toxic reactions in birds (see Chapter 18). A South American Black-collared Hawk experienced vomiting and acute collapse following an intramuscular injection;<sup>50</sup> however, this class of antibiotics is still considered effective and indicated in many bacterial infections. Vomiting may be noted following the IM or oral administration of doxycycline.

The popularity of enrofloxacin has been increasing in avian medicine because of its broad spectrum of activity and its good tissue penetration. Abnormalities in articular cartilage have been reported in squabs dosed at 800 ppm. Only one chick was affected at a dose of 200 ppm. Enrofloxacin was not shown to

cause clinically recognizable joint abnormalities in a group of psittacine birds from a large aviary.<sup>3,26</sup>

Chloramphenicol, penicillin, tetracycline, oxytetracycline and sulfa drugs may cause deformities in embryos and should not be used in hens near or during the breeding season.<sup>45</sup>

### Antifungals

Antifungal agents can have serious side effects, particularly with prolonged use. Amphotericin B has been associated with acidosis, azotemia, vomiting, seizures, hypokalemia, hepatic dysfunction, anemia, anaphylaxis and nephrotoxicosis.<sup>50</sup> Flucytosine may cause bone marrow depression, anemia, thrombocytopenia and leukopenia. Decreased renal function may precipitate gastrointestinal signs and elevate liver enzymes.<sup>48</sup> Amphotericin B used as a sinus flush caused a severe granulomatous reaction in an African Grey Parrot resulting in death.<sup>66</sup> The toxic side effects of these drugs should be considered when treating a bird for a fungal infection, and these agents should be used only when specifically indicated.

### Hypervitaminosis

Increased awareness of the nutritional needs of birds and the availability of formulated diets and numerous dietary supplements have created problems associated with the consumption of toxic levels of some nutrients. Of particular concern are vitamins A, D<sub>3</sub> (cholecalciferol) and calcium. Many formulated diets contain excess quantities of these nutrients, and further supplementation of these diets with vitamin and mineral products can result in life-threatening toxicities.

Hypervitaminosis A can cause osteodystrophy characterized by thickening of the proliferative-maturation zone, metaphyseal sclerosis, hyperosteoidosis and decreased numbers of osteoclasts. Parathyroid gland hyperplasia can also occur (see Color 14).<sup>63</sup> Hypervitaminosis D<sub>3</sub> can cause mineralization of parenchymal organs including the liver, kidneys, stomach, intestines, heart and blood vessels.<sup>64</sup> High levels of vitamin D<sub>3</sub> cause an increase in serum calcium levels, which may affect cardiac conduction and smooth muscle contractions.<sup>8</sup> Renal calcification in macaws and African Grey Parrots suggests that they may be particularly sensitive to hypervitaminosis D and excess calcium consumption.<sup>64</sup> Excessive calcium

can lead to skeletal abnormalities, especially in developing chicks (see Chapter 3).

A thorough dietary history must be included in the general history of any patient presented for evaluation. Vitamin injections are often used in debilitated birds. If the patient has been on a formulated diet or over-supplemented previously, parenteral administration of a multivitamin preparation may cause or exacerbate a vitamin intoxication problem.

The formulation of the injectable supplement used is important. Injacom 100 is the injectable vitamin supplement recommended for use in birds. It is water-soluble and contains 100,000 IU vitamin A and 10,000 IU vitamin D<sub>3</sub> per milliliter. Regular Injacom is an oil-based product containing five times as much vitamin A and 7.5 times as much Vitamin D<sub>3</sub>, which increases the potential for toxicosis when administered to birds.

## Airborne Toxins

The avian respiratory system is more efficient than that of mammals. The disadvantage to this efficient system is that it readily extracts harmful gases and particles from inhaled air, increasing a bird's sensitivity to inspired toxins. Administering 100% oxygen to birds for more than 12 hours was found to be fatal with death occurring in four to eight days; exposed birds appeared stressed and uncomfortable as early as three days post-exposure.<sup>62</sup>

### Polytetrafluoroethylene Gas

Polytetrafluoroethylene (PTFE) gas, released when various non-stick surfaces such as Teflon® overheat or burn, is a common respiratory toxin in birds. Potential sources of PTFE gas exposure include non-stick cookware, drip pans, irons, ironing board covers, the heating elements of some reverse-cycle heat pumps and heat lamps. As these surfaces are heated to above 530°F (280°C), they undergo pyrolysis and PTFE is degraded releasing irritant particles and acidic gases.<sup>69,70</sup>

The lungs are the target organ for PTFE poisoning in birds. Clinical signs are usually limited to sudden death, but depending on the degree of exposure may

include somnolence, dyspnea, wheezing, incoordination, weakness, respiratory distress and terminal convulsions.<sup>69,70</sup> Death usually occurs too rapidly for treatment to be initiated.

Hemorrhage and congestion of the lungs are the usual postmortem findings (see Color 22).<sup>69,70</sup> These lesions are thought to be caused by exposure of the respiratory epithelium to inhaled acidic gases.<sup>70</sup> Occasionally, PTFE particles may be recognized histologically in some lung sections.

With minimal exposure, birds may respond to immediate transfer to fresh air, coupled with the administration of intratracheal and systemic steroids, broad-spectrum antibiotics, fluids and a warm environment to prevent shock, pulmonary edema and bronchopneumonia.


### Tobacco Products

Birds should never be allowed to consume tobacco products. Ingestion of small quantities of nicotine can cause hyperexcitability, vomiting, diarrhea, seizures and rapid death. Treatment is supportive and symptomatic.

Passive inhalation of cigarette, cigar and pipe smoke can cause chronic ocular, dermatologic and respiratory disease in companion birds (see Chapter 22). Birds that live in homes with smokers will often present with clinical signs including coughing, sneezing, sinusitis and conjunctivitis due to continuous irritation of the respiratory system. The clinical signs may resolve without treatment if no secondary infectious agents are involved, the clients stop smoking or the bird is placed in a location where there is no smoke. Secondary bacterial invasion of the damaged respiratory epithelium is common and requires therapy; however, therapy for these infections will be of little value if the bird is continuously exposed to smoke.

In order to keep pet birds healthy, they should be maintained in well-ventilated, smoke-free environments (Ritchie, BW unpublished). Exposure to secondary smoke from marijuana can cause severe depression and regurgitation and should be strictly avoided.

Nicotine sulfate has been shown to cause severe skeletal malformation, reduced body weight, torticollis, edema, muscular dystrophy and malformation of the beak, heart and kidneys.<sup>45</sup> Pododermatitis has been observed in some birds handled by people who smoke routinely. Repeated exposure to the nicotine



**FIG 37.8** An adult Amazon parrot was presented with a ten-day history of progressive picking at the feet with scab formation. The bird was fed a formulated diet supplemented with some fresh vegetables. The feet were hyperemic and the feathers were dull and appeared tattered, particularly at the ends. The bird had mild epiphora and a serous nasal discharge. Both adult clients were heavy smokers. The bird's ocular, respiratory and foot problems resolved when the clients stopped smoking in the house and washed their hands before handling the bird.

residues on the hands of smokers is thought to cause this local irritation (Figure 37.8). Macaws may suffer a similar dermatitis on the bare cheek patches following repeated contact with a smoker's hands. Many birds with severe feather picking problems will resume normal preening behavior when removed from exposure to cigarette smoke (Ritchie, BW unpublished).

### Disinfectants

Disinfecting agents used to clean enclosures and food dishes should be used cautiously in aviaries and where companion birds are housed. Hatchlings and nestlings are especially prone to respiratory problems associated with chronic exposure to disinfectants or their fumes. A standard drain opener that contains sodium hypochlorite produced fumes that killed a Goffin's Cockatoo, African Grey Parrot and a cockatiel within minutes after a Clorox solution was also poured into the sink.

Irritation and dermatitis may occur following contact with many concentrated cleaning solutions (phenols, chlorhexidine and chlorine). All enclosures, nest boxes or aviary tools that are placed in disinfectants should be thoroughly rinsed with clean water before they are in contact with a bird.<sup>11</sup>

Direct contact between the bird and cleaning solutions should be avoided. If contact occurs, the area should be rinsed copiously with sterile saline. Appli-

cation of antibiotic creams and bandaging may be necessary in some cases. When ingestion of cleaning products or disinfectants occurs, the manufacturer's recommendations for therapy should be followed. If recommendations are not available, then birds ingesting non-caustic materials should be treated with a mild laxative to speed passage of the solution out of the body. Gentle gavage or flushing is indicated if a corrosive material has been ingested to prevent perforation of the esophagus or crop.<sup>11</sup> Corrosive materials require immediate dilution with water. Eyes or skin areas exposed to corrosives must be rinsed with clean water for at least twenty minutes. Systemic poisoning must be treated symptomatically, as there are no antidotes for disinfectant intoxications.

Ammonia and bleach are frequently used in household cleaning, and fumes from these products are commonly encountered by companion birds. Ammonia can be absorbed into the circulation by inhalation. In some species, increased blood ammonia concentrations have been shown to reduce lymphocyte function and alter their mitogenic activity resulting in a decreased cellular and humoral immune response. One study showed that blood ammonia concentration in excess of 1 mg/dl was an indication of toxicity. Even subtoxic concentrations (<1 mg/dl) in birds can predispose them to infectious diseases (see Figure 5.3).<sup>24</sup>

Ammonia and chlorine vapors can also irritate the epithelial linings of the eyes, conjunctiva, nares and respiratory tract. The resulting inflammation and damage can predispose these surfaces to secondary bacterial and fungal infections. Severe inflammation from exposure to strong concentrations of ammonia may impair respiration. Treatment consists of oxygen therapy, steroids to reduce inflammation and broad-spectrum antibiotics to combat secondary bacterial infections.

### Miscellaneous Aerosols

Common household aerosol products such as perfumes, deodorants and cleaning agents may cause respiratory problems in birds. These problems arise from direct irritation of the respiratory tract by the fluorocarbons and particulates in these aerosols. The most common effect is inflammation and edema of the respiratory tract leading to dyspnea. In severe cases, death may occur shortly after a large or direct exposure. It is the authors' recommendation that aerosol sprays not be used in areas where companion birds may be directly exposed, and definitely not

sprayed directly on the bird. Formaldehyde fumes have been associated with epiphora, dyspnea and death in canaries (see Figure 5.3).<sup>19</sup> An ozone generator caused the deaths of some birds in a pet shop. A cockatoo that was in the same room where a suede protector was used developed dyspnea within two hours, and died five hours after being exposed to the fumes from this product.

Leaks in natural gas lines may cause subtle respiratory signs in birds, even when no odors are detected by the clients. With more serious leaks, sudden death can occur. When birds are presented with respiratory problems or weakness of unknown etiology, careful questioning concerning the home environment may help determine if a leaking gas line could be a contributing factor. Kerosene fumes may also be toxic to birds, and combustible space heaters should not be used in homes containing companion birds.

Carbon monoxide (CO) is an odorless, colorless, tasteless gas produced by combustion engines and some furnaces. Birds maintained in poorly ventilated, heated areas, or transported in poorly ventilated vehicles (especially in car trunks) are at high risk of CO poisoning. Carbon monoxide competes with oxygen for hemoglobin binding sites in the blood. The affinity of hemoglobin for CO is about 250 times greater than its affinity for oxygen in mammals. Binding of CO to hemoglobin decreases the ability of oxygen to dissociate from hemoglobin, resulting in hypoxia. Carbon monoxide poisoning can occur when birds are placed in a confined area where the gas cannot escape.

Birds suffering from CO poisoning may die acutely and have bright red, apparently well oxygenated blood and pink- or red-colored tissues. Other signs of CO poisoning include depression, somnolence and dyspnea.

If CO poisoning is suspected, fresh air should be provided immediately, and emergency care should include the administration of 90 to 95% oxygen in a cool, dark, stress-free environment. Oxygen toxicosis can occur if a bird is exposed to O<sub>2</sub> levels of 90% to 100% for prolonged periods.<sup>62</sup>

Pulmonary silicosis caused chronic dyspnea and death in a Blue and Gold Macaw. The bird was exposed to the silicone through peat moss used as nesting material. In humans, a silicone/sulfur ratio of over 0.3 is considered indicative of silicosis. The ratio in this Blue and Gold Macaw was 9.07.<sup>49</sup>

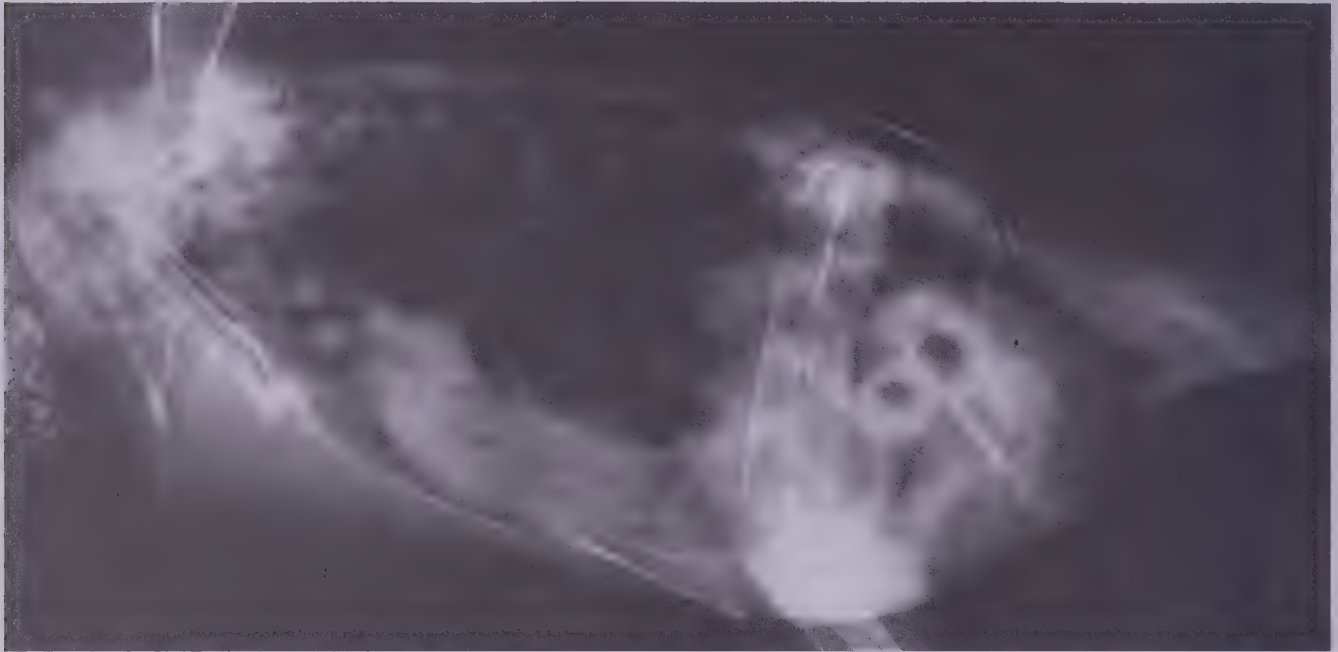Grossly, this bird's lungs appeared necrotic, and unencapsulated pyogranulomatous nodules that contained deposits of pale, amphophilic, refractory crystalline material that displayed birefringence when exposed to polarized light were seen histologically. Similar toxicities have been described in a rhea, ostrich, turaco, swan, owl, crane, duck, kiwi and Ring-neck Pheasant.<sup>49</sup>

## Insecticides

Exposure to high concentrations of pesticides can lead to nonspecific signs of poisoning including gastrointestinal problems, tremors, weakness, dyspnea, seizures or sudden death. Chronic low-grade exposure to pesticides may induce more subtle clinical signs that are more difficult to attribute to a toxin exposure. These exposures may cause immunosuppression and increased susceptibility to disease, decreased reproductive activity or generalized unthriftiness (Figure 37.9).

The most commonly used household insecticides contain pyrethrins, carbamates and organophosphates. While pyrethrins and carbamates are occasionally used as pesticides in association with birds, these agents are nonetheless toxic, especially following inhalation or contact with high concentrations. Pesticides may be absorbed through the skin following secondary contact with treated surfaces. Additionally, many insecticides contain carriers that can be irritating to the skin and respiratory tract mucosa.<sup>11</sup> Ingestion of foods contaminated with common agriculture pesticides could be a source of intoxication in birds. All grain products, fruits and vegetables that are not certified organic have levels of pesticides that have been determined to be acceptable ("safe" is a relative term) for human consumption. The effects of constant exposure of birds to these toxins has not been determined.

If absolutely necessary, dusting powders containing pyrethrins or carbamates (eg, 5% Sevin) can be used with some margin of safety on birds.<sup>11</sup> These compounds are not absorbed through the skin and are more likely to penetrate the feathers than sprays; however, excessive preening (ingestion) or inhalation of the dusts can lead to systemic intoxication that is dose-related.



**FIG 37.9** A Scarlet Macaw that was housed ten feet from a cyclic (every 30 minutes) pyrethrin mister was presented for regurgitation and severe weight loss (590 g). Radiographs indicated ileus, microcardia and microhepatia. Note the gastric distension of an empty cranial gastrointestinal tract and a full crop. The bird did not respond to supportive care. A perforating proventricular ulcer and liver cirrhosis were demonstrated at necropsy (see Color 19).

Clients can minimize a bird's exposure to insecticides by providing clean water and residue-free foods. If fresh fruits and vegetables are provided, they should be thoroughly rinsed in clean water to remove any insecticides used by the grower. Care must be exercised when pesticides and other volatile chemicals are used in and near a bird's area. Any materials used for perches should be thoroughly scrubbed and rinsed before being placed into the bird's enclosure.

Most potential contaminants are difficult to detect, and it is best to err on the side of caution. The effects of modern petro-chemicals on companion birds can only be postulated using the statistics that suggest their impact on the declining migratory bird populations in North and South America.

### ■ Organochlorines

The use of some organochlorines (DDT and DDE) have been banned in the United States and other countries, yet reports of poisoning in native species persist.<sup>49</sup> Migratory birds may be exposed in other countries that still use DDT produced in the United States. Poisoned birds may develop signs of convulsions, blindness (pupils may or may not respond to light), ataxia, anemia and hypoproteinemia. Gas

chromatography can be used to determine tissue concentrations of these compounds.<sup>47</sup>

### ■ Organophosphates

Clinical signs of organophosphate toxicity are caused by inhibition of acetylcholinesterase. Organophosphate poisoning in raptors appears clinically different than is typically described for mammals. Raptors are frequently contaminated by consuming poisoned starlings or grackles.<sup>47</sup> Clinical signs include ataxia, spastic nictitans, a detached attitude, inability to fly and occasionally convulsions. If present, convulsions are characterized by rigid paralysis, tightly clinched talons, rapid respiration, alivation, twitching of muscles and anascaria.

Scoliosis, lordosis (shortening or contortion of the axial skeleton) and severe edema were described in embryos exposed to parathion. Diazinon caused incomplete ossification and stunting. Carbaryl, methomyl and permethrin were considered relatively non-toxic to embryos.<sup>45</sup>

Dichlorvos (DDVP, Vapona) is a commonly used organophosphate that is impregnated in insect repellent strips. It is best for birds not to be exposed to any inhaled toxins; however, if a dichlorvos insecticide

must be used, it should be placed in a well ventilated room of appropriate size. Direct oral exposure should be avoided. Smaller species (eg, canaries, finches) are more sensitive to the pesticide vapors than budgerigars and larger psittacine birds.<sup>11</sup> In addition, higher ambient temperatures increase the risk of intoxication.<sup>11</sup> Other sources of avian exposure to organophosphates include flea collars, contaminated fruit limbs and frequently treated baseboards. There have been reports of birds being poisoned by consuming food that was stored in containers in which dichlorvos strips had been placed to control insects. A mite protector (para-chlorometazymol) placed in a container of finch seeds was thought to have caused the death of a finch. Seven of 15 canaries and finches died when moth balls were enclosed in a container that held their seed mix.<sup>23</sup> The toxic ingredients in these products are naphthalene and para-dichlorobenzene, respectively.

Pyrethrins have perhaps the lowest degree of toxicity in birds and warm-blooded mammals. They are often combined with the synergist piperonal butoxide to enhance insecticidal activity.<sup>11</sup>

### General Considerations

Birds suffering insecticide intoxication can manifest symptoms similar to those observed in mammals including sudden anorexia, incoordination, weakness, ataxia, muscle tremors, diarrhea, convulsions, respiratory difficulty and bradycardia.<sup>23,34,53</sup> Sudden death is usually due to respiratory failure from a single high-dose exposure.<sup>38</sup> Other less obvious signs of exposure include reductions in hatchability and egg production. These clinical changes are more common in breeding populations chronically exposed to pesticides.<sup>40</sup> While taking a history, clients should always be questioned about their use of insecticides in and around (outside open windows) the home.

A tentative diagnosis of insecticide poisoning is usually possible with a history of recent exposure and appropriate clinical signs. Whole blood acetylcholinesterase activity can be used to confirm a diagnosis of organophosphate intoxication. This test is frequently available in human pediatric laboratories. A sample from an unexposed bird should be included to serve as a control. In quail dusted with carbaryl, plasma cholinesterase activities were depressed up to 27% within six hours.<sup>20</sup>

There are usually no gross postmortem changes associated with insecticide poisoning, although in some

cases lung edema and hemorrhage may occur. A definitive postmortem diagnosis can be made by tissue analysis of the liver, kidneys, body fat and gastrointestinal contents for insecticide residues. Brain cholinesterase activity can be used to determine if the bird's death was due to an organophosphate intoxication; clinical analysis of tissues may not always be reliable due to the rapid metabolism of these insecticides.<sup>38</sup> Any tissues to be analyzed for insecticide residues or acetylcholinesterase activity should be submitted frozen in separate containers.

Treatment for organophosphate toxicosis includes supportive care (supplemental heat, fluids and diazepam to control seizures). Atropine is indicated for cholinergic signs (0.2 to 0.5 mg/kg one-fourth dose IV or IM every three to four hours).<sup>49,53</sup> Pralidoxime hydrochloride (2-PAM) is antidotal for organophosphate intoxications. 2-PAM was administered to King Pigeons with good results at 10 mg/kg IM.<sup>53</sup> The recommended range for mammals is 10 to 100 mg/kg. Steroids may be beneficial for the treatment of pulmonary edema or shock. For maximum effectiveness, antidotal therapy must be initiated within 24 hours of exposure. Organophosphates irreversibly bind to acetylcholinesterase. The more binding that is allowed to occur, the less effective the antidote will be.

### Carbamates

Carbamates' mode of action, induced clinical signs and methods of diagnosis and treatment are the same as for organophosphates, although 2-PAM is contraindicated. Over 2,000,000 bird deaths are estimated to occur annually in the United States as a result of the granular carbamate, carbofuran.<sup>47</sup>

### Rodenticides

Most rodenticides are of the anticoagulant variety. The first-generation products (warfarin) are less toxic and require longer periods of exposure than the newer generation products (brodifacoum). Clinical signs of toxicity include depression, anorexia, petechiation, epistaxis and subcutaneous hemorrhage. The antidote is vitamin K<sub>1</sub>. Some rodenticides contain cholecalciferol or bromethalin and are potentially more difficult to treat than the anticoagulant types. Rodenticide poisoning has been reported in quail and aviary birds when the poison is carried into the bird's food or water by contaminated rodents. Secondary poisonings of raptors from consumption of poisoned rodents (brodifacoum - Talon) have also been reported.<sup>19</sup>

### Products Mentioned in Text

- a. Bardahl Super Spray, Bardahl, Durdrecht, The Netherlands
- b. Leadcheck kits or swabs, Hybrivet Systems, Inc., Framingham, MA
- c. Edlich Gastric Lavage Kit, Monoject, Sherwood Medical, St. Louis, MO
- d. Formulator, © Wingers Publishing, Inc, Lake Worth, FL

### References and Suggested Reading

1. Allison N, et al: When pets ingest zinc: How likely is toxicosis? *Vet Med* 77:779, 1989.
2. Arai M, et al: Evaluation of selected plants for their toxic effects in canaries. *J Am Vet Med Assoc* 200(9):1329-1331, 1992.
3. Bond M, et al: Enrofloxacin in neonates. *J Assoc Avian Vets*, in press 1993.
4. Bohm J, Hochleithner: Mycotoxicosis in pet birds: Selected cases. *Proc Europ Assoc Avian Vet*, 1991, p 255-257.
5. Craigmill AL, et al: Toxicity of avocado *Persea americana* (Guatemalan var) leaves: Review and preliminary report. *Vet Hum Toxicol* 26(5):381-383, 1984.
6. Degernes LA, et al: Lead poisoning in trumpeter swans. *Proc Assoc Avian Vet*, 1989, p 144-155.
7. Dieter MP: Delta-aminolevulinic acid dehydratase enzyme activity in blood, brain and liver of lead-dosed ducks. *Environ Res* 19:127-135, 1979.
8. Dorman DC, Beasley VR: Diagnosis of and therapy for cholecalciferol toxicosis. *In* Kirk RW, Bonagura JD (eds): *Current Veterinary Therapy X, Small Animal Practice*. Philadelphia, WB Saunders Co, 1989, pp 148-152.
- 8a. Dorman DC: Anticoagulant, cholecalciferol and bromethalin-based rodenticides. *In* Beasley (ed): *Clinics North Am Sm Anim Pract* 20:339-352, 1990.
9. Dwiwedi P, Burns RB: Ochratoxins in chickens. *Vet Rec* 114(12):295, 1984.
10. Feldman BF, Kruckenberg SM: Clinical toxicities of domestic and wild caged birds. *In* Oehme FW (ed): *Vet Clin No Am Sm Anim Pract* 5(4):653-673, 1975.
11. Fowler ME: Disinfectant and insecticide usage around birds and reptiles. *In* Kirk RW (ed): *Current Veterinary Therapy VIII, Small Animal Practice*. Philadelphia, WB Saunders Co, 1983, pp 606-611.
12. Fowler ME: Plant poisonings in pet birds and reptiles. *In* Kirk RW (ed): *Current Veterinary Therapy IX*, 1986, pp 737-743.
13. Frank A, Borg K: Heavy metals in tissues of the mute swan (*Cygnus olor*). *Acta Vet Scand* 20:447-465, 1979.
14. Fudge AM: Clinical findings in an Amazon parrot with suspected lead toxicosis. *Cal Vet* 36(5):23-25, 1982.
15. Gussaway WC, et al: Zinc toxicity in the mallard duck. *J Wildl Mgt* 36(4):1107-1117, 1972.
16. Gayley F: Personal communication. U Calif Toxicology Laboratory, 1992.
17. Gerlach H: Drug hypersensitivity. *J Assoc Av Vet* 4(3):156, 1990.
18. Hargis AM, et al: Avocado (*Persea americana*) intoxication in caged birds. *J Am Vet Med Assoc* 194(1):64-66, 1989.
19. Harrison GJ: Toxicology. *In* Harrison GJ, Harrison LR (eds): *Clinical Avian Medicine and Surgery*. Philadelphia, WB Saunders Co, 1986, pp 491-499.
20. Hill EF: Cholinesterase activity in Japanese quail dusted with carbaryl. *Lab Anim Sci* 29:349-352, 1979.
21. Howard BR: Health risks of housing small psittacines in galvanized wire mesh cages. *J Am Vet Med Assoc* 200(11):1667-1674, 1992.
22. Janssen DL, et al: Lead toxicosis in three captive avian species. *Proc Am Assoc Zoo Vet*, 1979, pp 40-42.
23. Klein PN, Galey FD: The challenge of toxicology investigation in birds. *Proc Assoc Avian Vet*, 1989, pp 139-143.
24. Klucinski W, Targowski SP: Ammonia toxicity for mammalian and avian lymphocytes from blood. *Immunopharm* 8(1):47-52, 1984.
25. Kowalczyk DF: Lead poisoning. *In* Kirk RW (ed): *Current Veterinary Therapy IX, Small Animal Practice*. Philadelphia, WB Saunders Co, 1986, pp 145-150.
26. Krautwald ME, et al: Further experiences with the use of baytril in pet birds. *Proc Assoc Avian Vet*, 1990, pp 226-236.
27. LaBonde J: Avian toxicology. *Vet Clin No Am Sm Anim Pract* 21(6):1329-1342, Nov. 1991.
28. LaBonde J: Pet avian toxicology. *Proc Assoc Avian Vet*, 1988, pp 159-174.
29. Latimer KS, et al: Zinc-induced hemolytic anemia caused by ingestion of pennies by a pup. *J Am Vet Med Assoc* 195(1):77-80, 1989.
30. Lloyd M: Heavy metal ingestion: Medical management and gastric foreign body removal. *J Assoc Avian Vet* 6(1):25-29, 1992.
31. Lumeij JT: Clinicopathologic aspects of lead poisoning of birds: A review. *The Vet Quarterly* Vol 7(2):133-138, 1985.
32. Lumeij JT, et al: A new instrument for removing gastric foreign bodies in birds. *Proc Europ Conf Avian Med, The Netherlands*, 1993, pp 91-98.
33. Lutz ME: Crown vetch intoxication. *J Assoc Avian Vet* 5:2:73, 1991.
34. Lyman R: Neurologic disorders. *In* Harrison GJ, Harrison LR (eds): *Clinical Avian Medicine and Surgery*. Philadelphia, WB Saunders Co, 1986, pp 486-490.
35. Mautino M: Avian lead toxicosis. *Proc Assoc Avian Vet*, 1990, pp 245-247, 1990.
36. McDonald SE: Lead poisoning in psittacine birds. *In* Kirk RW (ed): *Current Veterinary Therapy IX, Small Animal Practice*. Philadelphia, WB Saunders Co, 1988, pp 713-718.
- 36a. McDonald SE: Summary of medications for use in psittacine birds. *J Assoc Avian Vet* 3:120-127, 1989.
37. Minnick PD, et al: Altered serum electrolyte concentrations due to laboratory usage of vacutainer tubes. *Vet Hum Toxicol* 24(6):413-414, 1982.
38. Mohan R: Dursban toxicosis in a pet bird breeding operation. *Proc Assoc Avian Vet*, 1990, pp 112-114.
39. Molnar JJ: Copper storage in the liver of the wild mute swan (*Cygnus olor*). *Arch Pathol Lab Med* 107:629-632, 1983.
40. Morris P: Lead and zinc toxicosis in a blue and gold macaw (*Ara ararauna*) caused by ingestion of hardware cloth. *Assoc Avian Vet Newsletter* 6(3):75, 1985.
41. Muller RD, et al: The response of chicks, ducklings, goslings, pheasants and poults to graded levels of aflatoxins. *Poultry Sci* 49(5):1346-1350, 1970.
42. Munn C: The real macaws. *Animal Kingdom*. Bronx, NY Zool Soc Mag 91(5):26, 1988.
43. Navarro JL, et al: Capsaicin effects on consumption of food by cedar waxwings and house finches. *Wilson Bull* 104(3):549-551, 1992.
44. Perelmann B, Nuttin ES: Parsley-induced photosensitivity in ostriches and ducks. *Avian Pathol* 17:183-192, 1988.
45. Olsen GH, et al: A review of some causes of death of avian embryos. *Proc Assoc Avian Vet*, 1990, pp 106-111.
46. Osweiler GD, et al: *Clinical and Diagnostic Veterinary Toxicology* 3rd ed. Dubuque, Kendall/Hunt Publishing Co, 1976.
- 46a. Osweiler GD: Household and commercial products. *In* Kirk RW (ed), *Current Veterinary Therapy IX*. WB Saunders Co, Philadelphia, 1986, 193-195.
47. Porter SL, Snead SE: Pesticide poisoning in birds of prey. *J Assoc Avian Vet* 4(2):84-85, 1990.
48. Quesenberry KE: Avian antimicrobial therapeutics. *In* Jacobson ER, Kollias GV (eds): *Exotic Animals*. New York, Churchill Livingstone, 1988, pp 177-207.
49. Rae MA, et al: Pulmonary silicosis in a blue and gold macaw (*Ara ararauna*). *Proc Assoc Avian Vet*, 1991, pp 260-262.
50. Reece RL, et al: Zinc toxicity (new wire disease) in aviary birds. *Austr Vet J* 63(6):199, 1986.
51. Repper R, et al: The effects of implanted lead shot and various metal on certain parameters in pigeons. *Deutsche Veterinärmedizinische Gesellschaft e.v. München*, 1986, pp 34-37.
52. Ritchie BW: Emergency care of avian patients. *Vet Med Report* 2:230-245, 1990.
53. Ritchie BW: Treatment of organophosphate toxicosis in *Columba livia*. *Assoc Avian Vet Today* 1(1):23, 1987.
54. Robinson PT, Richter AG: A preliminary report on the toxicity and efficacy of levamisole phosphate in zoo birds. *J Zoo Anim Med* 8(1):23-25, 1977.
55. Roscoe DE, Nielsen SW: A simple, quantitative test for erythrocytic protoporphyrin in lead-poisoned ducks. *J Wildl Dis* 15:127-136, 1979.
56. Roskopf WJ, Woerpel RW: Removal of a lead pellet by gizzardotomy (ventriculotomy) in a green-winged macaw. *Vet Med Sm An Clin*, 1982, pp 969-974.
57. Ruff MD, et al: Characterization of the toxicity of the mycotoxins aflatoxin, ochratoxin and T-2 toxin in game birds. I. Chukar partridge. *Avian Dis* 34(3):717-720, 1990.
58. Schlosberg AS, et al: Muscovy ducklings, a particularly sensitive avian bioassay for T-2 toxin and diacetoxyscirpenol. *Avian Dis* 30(4):820-824, 1986.
59. Shropshire, et al: Evaluation of selected plants for acute toxicosis in budgerigars. *J Am Vet Med Assoc* 200(7):936-939, 1992.
60. Smith JM, et al: Emtryl toxicity in cockatiels. *Proc 34th West Poult Dis Conf*, 1985, pp 98-100.
61. Smith JW, Hamilton PB: Aflatoxicosis in the broiler chicken. *Poult Sci* 49(1):207-215, 1970.
62. Stauber E: Effects of increased concentration of inspired oxygen. *Proc Europ Assoc Avian Vet*, 1991, pp 105-114.
63. Tang K, et al: Vitamin A toxicity: Comparative changes in bone of the broiler and leghorn chicks. *Avian Dis* 29(2):416-429, 1985.
64. Takeshita K, et al: Hypervitaminosis D in baby macaws. *Proc Assoc Avian Vet*, 1986, pp 341-345.
65. van der Horst H, et al: Poisoning with lead naphthenate after ingestion of aerosol lubricant in an African grey parrot. *Proc Europ Conf Avian Med & Surg, The Netherlands*, 1993, p 396-404.
66. van der Mast H, et al: A fatal treatment of sinusitis in an African grey. *J Assoc Avian Vet* 4(3):3, 189, 1990.
67. Vaughn S: Arsenic poisoning in a cockatiel aviary. *Proc Europ Assoc Avian Vet*, 1991, pp 258-263.
68. Van Sant F: Zinc toxicosis in a hyacinth macaw. *Proc Assoc Avian Vet*, 1991, pp 255-259.
69. Wells RE: Fatal toxicosis in pet birds caused by an overheated cooking pan lined with polytetrafluoroethylene. *J Am Vet Med Assoc* 182(11):1248-1250, 1989.
70. Wells RE, et al: Acute toxicosis of budgerigars (*Melopsittacus undulatus*) caused by pyrolysis products from heated polytetrafluoroethylene. *Clinical study*. *Am J Vet Res* 43(7):1238-1242, 1982.
71. Windingstad RM, et al: Fusarium mycotoxins from peanuts suspected as a cause of sandhill crane mortality. *J Wildl Dis* 25(1):38-46, 1989.
72. Woerpel RW, Roskopf WJ: Heavy-metal intoxication in caged birds: parts I, II. *Comp Cont Ed Pract* 4(10):191-196, 1982.
73. Robb J, Kirkpatrick KS, Marshall DB, Norval M: Association of toxin-producing fungi with disease in broilers. *Vet Rec* 111:389-390, 1982.
74. Heathcote JG, Hibbert JR: *Aflatoxins: Chemical and biological aspects*. Amsterdam, Elsevier Scientific Publishing, 1978.



**T**he mycoplasmatales constitutes one order within the class Mollicutes that replicates mainly by binary fission. Strains that produce mycelia-like forms may propagate by dissociation of these "mycelia." Morphologically, colonies and single organisms can exist in multiple forms (coccoid, rods, ring-forms), depending on the physical properties of the media in which they are growing. In most cases, morphology is unsuitable for species differentiation. In contrast to bacteria, mycoplasmatales have no cell wall and are bound by a three-layer membrane. Thus, they are resistant to antibiotics that inhibit cell wall development (eg, penicillins, cephalosporins, bacitracin) and sulfonamides. Mycoplasmatales are fastidious and must obtain most of the nutrient requirements from the growth media because of their relatively small genome. They grow on agar media in small, fried egg-shaped colonies, which in many instances, can be recognized only under the microscope. Generally, specialized laboratories are necessary for isolation and identification. The lack of a cell wall makes the organism sensitive to inactivation outside the host (it survives only hours on dry surfaces, two to four days in water); therefore, transport media are necessary for shipping infected tissues intended for isolation attempts. Mycoplasmatales that are free in the environment are susceptible to all commonly used disinfectants. Organisms within host excretions are protected from contact with the disinfectant. Secretions and excretions must be removed before disinfecting procedures are effective.

The mycoplasmatales consist of three genera, which can be distinguished roughly by the following properties:

*Mycoplasma* need cholesterol for growth (production of the cellular membrane).

*Acholeplasma* do not need cholesterol for growth, but many strains can be inhibited by the thallium acetate that is commonly used for inhibiting gram-negative bacteria in media used for the isolation of mycoplasma.

*Ureaplasma* were formerly called T-strains because of their tiny colony sizes. They require urea for their energy metabolism and also cholesterol for growth.

---

CHAPTER

38

MYCOPLASMA AND  
RICKETTSIA

---

■  
Helga Gerlach

Many isolates from companion and aviary birds have not yet been fully identified and have no valid name. In addition, the pathogenicity and epizootiology of these strains have not been defined to date.

Mycoplasmatales are distributed worldwide in connection with the poultry industry. There is little information on the prevalence of mycoplasmatales in captive or free-ranging Psittaciformes or other groups of birds. Isolations have been rare, and the importance of the majority of the strains is unknown. With intensified aviculture, increased farm sizes and population densities on these farms, more problems with mycoplasmatales can be expected.

## Mycoplasmatales

The host spectrum of the mycoplasmatales is rather narrow (see Table 38.1), with the exception of *Mycoplasma cloacale* and the genus *Acholeplasma*. Reports suggesting isolates of well known species from unusual hosts should be met with skepticism. The various mycoplasmatales have similar biochemical properties and serologically cross-react with other species of the order, creating a high number of false-positive results (low specificity). The reason for these cross reactions is that the lack of a cell wall diminishes the antigenicity, which is probably governed by enzymes within the microorganisms. Because these enzymes are phylogenetically old and highly conserved, they do not vary much between genera. Physical methods such as electrophoresis (combined with blot methods) are more reliable than serologic methods for differentiating between species or strains.<sup>28</sup>

### Transmission

Mycoplasmatales are relatively low in infectivity. Close contact between individuals is necessary for transmission, and infections are most common in dense populations (Figure 38.1). The respiratory and genital tracts are the primary portals of entrance. The organism is spread by respiratory excretions and by the gonads of both sexes as well as hematologically through the body. Infected air sacs can lead to contact transmission of the ovary (and developing follicle). Transovarian transmission is epornitically important, although in clinically healthy breeders, the egg



**FIG 38.1** High density, confined, indoor breeding operations increase the exposure of individual birds to a mixture of microorganisms that may include *Mycoplasma* spp. Damage to the respiratory tract caused by increased dust, dry-heated air and respiratory viral infections predispose birds to mycoplasma infections. Most infectious diseases are less of a problem in birds maintained in low density outdoor breeding facilities (reprinted with permission *J Assoc Avian Vet*).

transmission rate is low (between 0.1 and 1.0 %); however, there are some exceptions. The egg transmission rate of *M. meleagridis* in turkeys can be as high as 25%. This species causes predominantly a venereal disease. Infected breeders may be asymptomatic. Close contact is the primary mode of transmission in neonates. Offspring feeding on contaminated crop regurgitations (eg, crop milk in pigeons) may also become infected.

### Pathogenesis

Primary pathogenic strains, ie, strains that can damage epithelial cells and cause disease without additional factors, have to be distinguished from secondary pathogenic strains that need predamaged epithelium, and from strains that are assumed to be apathogenic. Mycoplasmatales preferably colonize the mucosa of the respiratory and the genital tracts. Strains capable of inducing systemic infections can be found in the brain and joints. Infections start with the adsorption of the organism to the surface of host cells (including erythrocytes with hemagglutinating strains). Multiplication takes place on the cell surface, and both the membrane integrity as well as the function of the host cell can be altered. Because the agent may be hidden in the recesses of the host cell membrane, it can remain rather inaccessible by therapeutics and the host defense mechanisms. As a consequence, only negligible amounts of humoral antibodies, if any, are produced. *M. gallisepticum* (and

TABLE 38.1 Avian Host Spectrum of Mycoplasmatales<sup>13,17</sup>

Species	Host Spectrum	Signs of Disease
<i>M. gallisepticum</i>	Chicken, turkey, guineafowl, peafowl, pheasants, partridge, rock partridge, Red-legged Partridge, Japanese Quail, Bobwhite Quail, House Sparrow, domestic duck and goose, <sup>5</sup> Canada Goose <sup>5</sup>	Rhinitis, sinusitis, tracheitis, air sacculitis, pneumonia, arthritis, encephalitis, ophthalmitis
<i>M. gallinarum</i>	Chicken, pheasant, Chinese Bamboo Partridge, House Sparrow, Demoiselle Crane, Domestic Goose, Bewick's Swan	Mild respiratory signs in geese also infected with parvovirus
<i>M. pullorum</i>	Chicken, Turkey, Pheasant, Partridge	Asymptomatic
<i>M. gallinaceum</i>	Chicken, Turkey, Pheasant, Hoopoe	Asymptomatic: complicated with PMV1
<i>M. iners</i>	Chicken, Turkey, Domestic Goose, <sup>2</sup> Golden Pheasant <sup>31</sup>	Asymptomatic
<i>M. gallopavonis</i>	Turkey, (Chicken?)	Mild respiratory signs only in turkeys
<i>M. meleagridis</i>	Turkey	Sinusitis, air sacculitis, infection of the genital tract
<i>M. iowae</i>	Chicken, Turkey, Yellow-crowned Amazon Parrot	Mild air sacculitis, in turkeys venereal transmission and reduced hatchability
<i>M. columbinasale</i>	Pigeon	Rhinitis, pharyngitis
<i>M. columborale</i>	Pigeon (Chicken ?)	Rhinitis, pharyngitis
<i>M. columbinum</i>	Pigeon	Asymptomatic
<i>M. synoviae</i>	Chicken, Turkey, <sup>23</sup> Guinea fowl, Red-legged Partridge, Japanese Quail, <sup>2</sup> House Sparrow, <sup>31</sup> Tree Sparrow, <sup>31</sup> Domestic Duck and Goose	Sinusitis, synovitis, air sacculitis, hepatitis, splenomegaly
<i>M. anatis</i>	Domestic Duck, Greater Scaup, Common Teal and other Teals, <sup>31</sup> Domestic Goose, <sup>2</sup> Coot, <sup>31</sup> Common Shoveler <sup>31</sup>	Rhinitis, sinusitis, air sacculitis only if triggered by influenza virus
<i>M. glycyphilum</i>	Chicken	
<i>M. lipofaciens</i>	Chicken	
<i>M. cloacale</i>	Turkey, <sup>2</sup> Domestic Duck and Goose, <sup>2</sup> Tufted Duck, European Pochard, Muscovy Duck, Skylark, Starling, Cockatiel, Lesser Spotted Woodpecker <sup>4</sup>	
<i>M. anseris</i>	Domestic Goose	Together with <i>M. cloacale</i> lesions in geese
<i>M. spp. n.n.</i> (7 different types)	Domestic Duck	Mild respiratory signs
<i>M. sp. n.n.</i>	Budgerigar	Air sacculitis
<i>A. laidlawii</i> B (var. <i>inocuum</i> )	Chicken, Pigeon, Greater Adjutant Stork, Night Heron	Asymptomatic
<i>A. laidlawii</i> A	Domestic Duck and Goose	Air sacculitis, conjunctivitis, cloacitis
<i>A. axanthum</i>	Domestic Goose Domestic Duck	Embryonal death, peritonitis, salpingitis, air sacculitis Conjunctivitis, cloacitis
<i>A. equifetale</i>	Chicken	
<i>A. spp. n.n.</i> (2 different types)	Pigeon	Rhinitis, pharyngitis
<i>U. gallorale</i>	Chicken, Red Junglefowl	Air sacculitis, pneumonia
<i>U. spp. n.n.</i>	Turkey, Jungle Bush Quail	Respiratory signs
Unidentified (3 different types)	Severe Macaw, Cockatoo spp., Cockatiel, Canary	Chronic conjunctivitis, rhinitis, sneezing, sinusitis, dyspnea, arthritis
Several types ?	Saker Falcon, Peregrine Falcon, Prairie Falcon, Rough-legged Buzzard, Common Buzzard, Griffon Vulture, <sup>31</sup> Common Kestrel	Synovitis, air sacculitis, catarrhal tracheitis, serofibrinous pneumonia, sitting on paralyzed hocks,
One type	Phasianinae	See text
Several types ?	Black-headed Gull, Brown-eared Bulbul, Phasianinae, White-fronted Goose	Asymptomatic

probably other strains of avian mycoplasmatales) has a special organelle for attaching to the host cell.

Depending on the virulence of the strain in question, cellular damage may be caused at the site of colonization. The host reacts with a serofibrinous inflammation and activation of the cell-mediated defense system. The excessive response of the latter (which is genetically determined) governs the type and magnitude of pathologic changes.

Many mycoplasmatales cause transformation of the host lymphoblasts (mainly T-cells) by excreting a mutagenic substance. Affected cells function improperly and there is a severe proliferation of immature lymphocytes in local lymph follicles with invasion of the lymphoid cells into the infected area. These altered lymph follicles can appear similar to those described for lymphoma. Other pathogenicity factors are cytotoxins (exotoxins, H<sub>2</sub>O<sub>2</sub>) and polysaccharides. Triggering factors for mycoplasmatales are immature epithelial membranes, environmentally induced dyspnea (heat, dry air) and damage to the respiratory epithelium (excess NH<sub>3</sub>, paramyxovirus, reovirus, adenovirus, infectious bronchitis virus and *E. coli*). The involvement of several different factors in a flock outbreak creates a high variability in clinical and pathologic changes.

#### Incubation Period

Incubation periods for *M. gallisepticum* are 6-21 days in chickens and 7-10 days in turkeys.<sup>43</sup> In other avian species and with other mycoplasmatales, long latency periods, egg transmission and the involvement of environmental factors make the determination of an incubation period difficult.

### Clinical Disease and Pathology

#### Red Junglefowl

*U. gallorale* has been isolated from the pharynx of this species. Although the strain is serologically identical with isolates from the chicken, experimental infections did not cause disease in chickens.

#### Phasianinae

The Common Pheasant and its subspecies, *Crossoptilon* spp., the Golden Pheasant and probably other pheasants are susceptible. The main host is the Common Pheasant, which is typically maintained in large flocks. The strains of mycoplasma that are infectious to pheasants have been incompletely studied and documentations in the literature provide conflicting information.<sup>13</sup> The author's experience suggests that

the Phasianinae have host-adapted strains, one that is apathogenic and another that experimentally reproduces typically defined signs of the disease. Clinical signs are most common in large groups of chicks at the age of two to eight weeks. Adults are rarely affected. A seasonal peak can be observed between June and August. The disease spreads slowly and not all aviaries are always affected. Morbidity is high. Mortality depends on secondary factors and can range from 30 to 90%. Blinking the eyes and scratching at the eyelids are the first clinical signs. Deterioration of the general condition, photophobia and swelling of the eyelids are followed by exudation, blepharoconjunctivitis and sometimes keratitis; approximately 25% of the corneal surface is affected. Death can be caused by cachexia as a result of blindness. Voluminous expansion of the infraorbital sinus, which contains only a small amount of exudate, may be observed. Birds are frequently dyspneic, particularly when agitated. At postmortem, the air sacs may be mildly inflamed or grossly normal.<sup>13</sup>

#### Japanese Quail

Experimental infections indicate that Japanese Quail are less susceptible to *M. gallisepticum* than are chickens. Isolation of the organism is possible from the trachea, lung and brain for weeks post-infection. The course is subclinical. Infections derived from contact with infected chickens or egg transmission have been documented.

#### Bobwhite Quail

This species is raised in large numbers in the southern parts of the United States. Dyspnea and anorexia have been observed. An isolate assumed to be *M. gallisepticum* from Bobwhite Quail caused typical lesions in turkey poults. However, a strain of *M. gallisepticum* experimentally given to Bobwhite Quail chicks did not result in lesions, and no antibodies were produced.

### CLINICAL APPLICATIONS

- Mycoplasmatales are most important in dense populations of birds where direct transmission can easily occur. Control can be enhanced through sound hygiene.
- Mycoplasma are resistant to antibiotics that inhibit cell wall development (eg, penicillins, cephalosporins, bacitracin and sulfonamides).
- Mycoplasmatales that are free in the environment are susceptible to all commonly used disinfectants. Organisms within host excretions are protected from contact with the disinfectant. Secretions and excretions must be removed before disinfecting procedures are effective.
- With intensified aviculture, increased farm sizes and population densities on these farms, more problems with mycoplasmatales are to be expected.

### Partridge

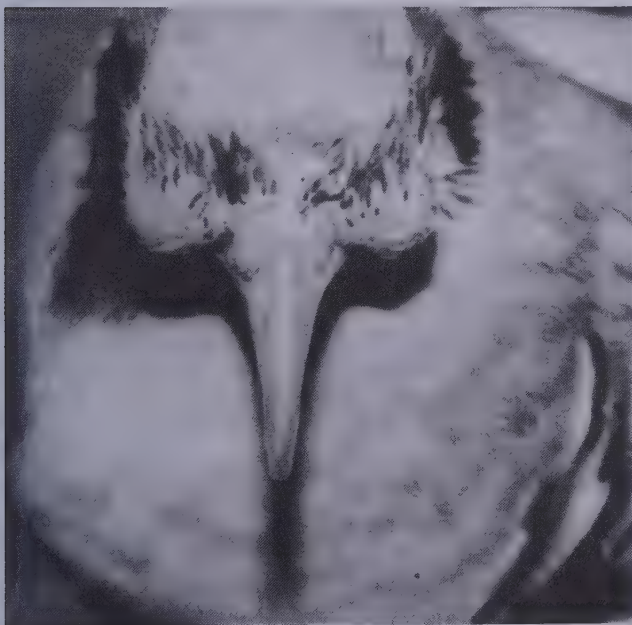
It is assumed that the same strains as in Phasianinae cause disease in the partridge, although this has not been proven. Affected birds develop infections that are similar to those seen in pheasants, but there is no defined seasonal peak. Birds up to 11 weeks of age show a swelling of the infraorbital sinuses which, in contrast to pheasants, are filled with a fibrinous, cheesy exudate (Figure 38.2). Free-ranging Red-legged Partridge usually develop clinical disease in August to December. Isolates are assumed to be identical to strains removed from pheasants and other partridges.

### Rock Partridge

Disease has been described only in chicks and not in the respective breeding flock. Emaciation and swollen sinuses are the main clinical signs. Isolates assumed to be *M. gallisepticum* were experimentally apathogenic for chickens and turkeys.

### Peafowl

Affected birds are lethargic, shake their heads to remove sticky nasal exudates, have swollen infraorbital sinuses and make gurgling respiratory sounds. Latent infections are thought to occur.



**FIG 38.2** A young partridge was presented with a five-day history of progressive ocular irritation, photophobia, dyspnea and periocular swelling. Large, bilateral, periocular masses were noted on physical examination. Large quantities of necrotic debris were surgically removed from both intraorbital sinuses. *Mycoplasma* sp. was isolated from culture samples taken from the sinus cavities. The bird responded to postsurgical therapy with tylosin (courtesy of Helga Gerlach).

### Guineafowl

An outbreak of infectious synovitis caused by *M. synoviae* in guineafowl could not be distinguished clinically or pathologically from the lesions that occur in chickens and turkeys.<sup>26</sup> In contrast to chickens and turkeys, affected guineafowl (including experimentally infected birds) developed severe amyloidosis and did not develop sinusitis.<sup>29</sup> Strains isolated from guineafowl are more virulent for guineafowl than for chickens.

### Domestic Duck

A variety of *Mycoplasma* and *Acholeplasma* strains can be isolated from domestic ducks. In the few isolates that have been evaluated experimentally, pathogenicity is limited to mild respiratory lesions, conjunctivitis and cloacitis. *M. anatis* may cause enzootic rhinitis, sinusitis, conjunctivitis and lacrimation in association with concomitant influenza virus A infections. Morbidity may be as high as 50-80%, but mortality remains below 5%. As a rule, affected ducks recover spontaneously without therapy. Experimentally, the clinical disease can be produced using *M. anatis* and influenza virus A,<sup>32</sup> although both infectious agents alone have been proven to be apathogenic. The role of *M. cloacale* as the cause of a cloacitis in ducks has not been fully studied. Most of the *Mycoplasma* and *Acholeplasma* strains described are capable of causing increased embryonic mortality.

### Domestic Goose

Geese suffering from cloacitis and necrosis of the phallus were found to be infected with mixed cultures of *M. spp.* (mostly *M. cloacale*, but also *M. anseris* and strain 1220). Phallus lesions are characterized by serofibrinous inflammation of the mucous membrane of the lymph sinus, the glandular part of the phallus, and occasionally the cloaca and the peritoneum. Necrosis of the affected phallus can be severe if secondary pathogens are present. Mortality is less than 1%. *M. spp.* can be isolated from the phallic lymph secretion as well as the spleen, testes, air sacs, peritoneum and liver. The incidence of affected ganders in some flocks can be as high as 40-100%. High numbers of infertile eggs and a high incidence of embryonic death are common in affected flocks.<sup>36,40</sup>

*A. axanthum* may cause embryonic mortality (up to 60%) around the 13th day of incubation. The organism can be isolated from the respiratory tract and feces of breeding birds showing embryonic mortality. Infected adults develop fibrinous peritonitis, salpingitis and air sacculitis. Goslings from infected flocks and experimentally infected neonates can suffer from

mild to severe air sacculitis (depending on the virulence of the strain in question).<sup>37</sup> The pathogenicity of *A. axanthum* can be potentiated by concomitant infection with parvovirus, even if antibody titers are high enough to prevent the parvovirus from causing clinical disease.<sup>22</sup>

### Domestic Pigeon

At least six different species of mycoplasmatales have been isolated from domestic pigeons.<sup>13,15</sup> All of them apparently are incapable of causing primary disease. Following natural or experimental infection with all except *M. columbinum* and *A. laidlawii* (which have not been tested), the agents can be isolated from various organs including brain, eye and joints of asymptomatic birds. The frequent colonization of the pharyngeal mucosa is epizootiologically important because pigeons feed their offspring crop milk. During the act of regurgitation the crop milk passes over the infected mucosa and may be contaminated. Although egg transmission has been proven, this means of transmission might play the most important role.

Clinical signs of rhinitis, sinusitis, tracheitis and conjunctivitis are generally chronic in nature and vary with secondary factors such as concomitant infections with *Salmonella* spp. or *Chlamydia psittaci*. Under these conditions, mycoplasmatales can be isolated from the lower third of the trachea, air sacs and occasionally lung, and birds frequently have persistent respiratory sounds and serofibrinous inflammation of these organs. The association between the colonization of the meninges and synovial structures by mycoplasmatales and the frequency of arthritis and meningoencephalitis caused by salmonellosis has not been determined. Further evidence for the apathogenicity of uncomplicated mycoplasmatal infections in pigeons is the fact that humoral antibodies only occasionally develop following natural or experimental infections. In contrast to some older reports, experimental infection of chickens with pigeon mycoplasma strains does not lead to clinical disease. *M. gallisepticum* does not affect pigeons. *M. columborale* was recovered from a pigeon flock with respiratory signs that responded to treatment with tylosin. Experimentally infected three-week-old chicks developed mild to severe air sacculitis, but were clinically asymptomatic. There is no report of natural infection in chickens with *M. columborale*.<sup>25</sup>

### Other Pigeons

In addition to domestic pigeons, infections with mycoplasmatales have also been described in the Wood

Pigeon,<sup>20</sup> Collared Dove<sup>14</sup> and Crowned Pigeon.<sup>13</sup> The isolation of *M. columbinum* and *M. columborale* has also been recovered from healthy "feral pigeons."<sup>21</sup>

### Saker Falcon

*Mycoplasma* was isolated from the trachea of a Saker Falcon with insufflation of the soft tissues around the eye and between the rami mandibulares following each expiration. Similar respiratory signs occurred in two contact birds.<sup>10</sup> A definitive connection between the clinical signs and the *M.* isolate was not established. *Mycoplasma*-induced synovitis has also been described in this species.<sup>19</sup>

### Peregrine Falcon

A *Mycoplasma* sp. was isolated from the trachea of two Peregrine Falcons with anorexia, vomiting, respiratory sounds and tachypnea (60-70 beats per minute).<sup>10</sup> The animals responded to treatment with tylosin.

### Budgerigar

A *Mycoplasma* sp. was isolated from a budgerigar with air sacculitis.<sup>1</sup> The serum of five contact birds revealed humoral antibodies against the homologous strain with titers between 1:160 and 1:640. Antibodies were not detected against *M. gallisepticum* and *M. meleagridis*. The budgerigar strain propagated in the embryonated chicken egg and showed no embryonal pathogenicity. Budgerigars experimentally infected with *M. gallisepticum*<sup>6</sup> and *M. synoviae*<sup>3</sup> developed clinical signs. Budgerigars are not considered to be a natural host of *M. gallisepticum* and *M. synoviae*.

### Cockatiel

It has been assumed that conjunctivitis in cockatiels can be caused by mycoplasmatales, (see Color 26) as wet sneezes and sinusitis are common in those birds. Although mycoplasmatales can be isolated from some of these cases, their importance in the disease process has not been determined. From the clinical course and response to treatment it can be concluded that chlamydiosis and infections with polyomavirus are the main pathogens in these conditions.<sup>9,12</sup> Many cockatiels in Florida with symptoms of mycoplasmosis respond to tylosin (as an eyewash) or lincocin-spectinomycin (Harrison GJ, unpublished).

### Severe Macaw

An ornithic of mycoplasma was described in Severe Macaws with clinical and pathologic lesions in the respiratory tract. Although mycoplasmas were iso-

lated, no causal relationship between the agent and the disease could be established.<sup>11</sup>

### Yellow-crowned Amazon

A flock of Yellow-crowned Amazon Parrots experienced high mortality (200 of 1100 birds) with an upper respiratory tract disease. Lesions were complicated by the presence of many bacteria and also some fungi. A mycoplasma strain (assumed to be *M. gallisepticum*) was isolated and used for experimental infections in budgerigars and chickens. Mild air sac lesions were induced in budgerigars, but the strain was apathogenic for chickens. The serologic evidence for *M. gallisepticum* was questionable.<sup>3</sup>

### Cockatoo

An unidentified strain of mycoplasma was isolated from a group of cockatoos with severe air sacculitis.<sup>12</sup>

### Canary

An unidentified strain of mycoplasma was recovered from a flock of canaries with a high incidence of wheezing and "tail-bobbing." The affected flock had suffered from canarypox.

## Pathology

At necropsy, lesions caused by various mycoplasmales in respective hosts vary in degree but not in presentation. Serous to serofibrinous conjunctivitis, rhinitis, sinusitis, tracheitis, air sacculitis and focal bronchopneumonia have all been described.<sup>18</sup> The nasal cavity and the infraorbital sinus frequently display a unilateral, seromucoid (later fibrinous) exudate that also fills the choanal fissure. In ducks and turkeys, the exudate is often semigelatinous, fibrinous or caseous, and leads to distension of the infraorbital sinus. The mucous membranes are swollen and may show petechiation. The tenacious exudate can be mixed with fibrinous debris.

Histopathologically, the disease is initially characterized by severe distension of the mucous glands, the swollen cells of which have particularly large nuclei. Subsequent proliferation of epithelial cells leads to multilayered, glandular epithelium, pressure on the glands themselves and mucoid degeneration. The superficial mucosal epithelia lose their cilia, proliferate to 10-15 cellular layers and finally show vacuolization and karyorrhexis. In contrast to various viral diseases, desquamation and necrosis of the epithelium are mild.

From the second week after infection, an infiltration of the lamina propria with lymphocytes and histiocytes is seen. Round-to-oval, up to 400  $\mu\text{m}$  in diameter nodules that consist mainly of lymphocytes appear in the submucosa. The proliferation of the lymph follicles persists in the lower part of the trachea and the syrinx from the 2nd to the 12th week after infection. This is generally a longer course of reactions than are noted with other infections of the respiratory tract. As healing occurs, there is a proliferation of connective tissue in the submucosa. The histopathomorphologic changes vary depending on the presence of secondary bacterial or viral infections. Secondary fungal infections are rather rare.

Lesions of the air sacs start with edema between the inner and outer epithelial layers. The cellular reaction consists initially of subepithelial infiltrates of heterophils. The capillaries are engorged. Progression is marked by increased edema and growing numbers of heterophils followed by lymphocytes, macrophages and plasma cells. The normally flat epithelium becomes cubic, loses its cilia and is finally desquamated. Inflammatory exudate, mainly in the form of fibrin, appears on both sides of the air sac membrane. The host responds with proliferation of the endodermal epithelial layer and necrotic foci of epithelial cells and proliferation of fibrocytes and mononuclear cells (80% can be lymphocytes). A granulomatous reaction characterized by the formation of multinucleated giant cells occurs by the third week post-infection. Lymph follicles and diffuse mononuclear infiltrations govern the pathologic picture. Pneumonia is a rare complication in avian mycoplasmosis, and in most instances is caused by secondary infections with *E. coli*.

Mycoplasma colonization of the mucosa of the urogenital tract can cause pathologic lesions, although colonization of the phallus may be inconspicuous. Histologically, lesions are mainly seen in the part of the mucosa where the majority of the glands are situated (species-specific differences). Submucosal proliferation of lymph follicles and disseminated infiltration of lymphocytes into the tissue are the main lesions. In ganders, the phallus is enlarged and covered with fibrinous exudate; and may finally become necrotic if secondary infections occur. Synovial membrane lesions have been rarely reported in companion and aviary birds.<sup>23</sup>

### Differential Diagnosis

The rule-out list includes many viral, bacterial and fungal diseases. In Psittaciformes, pigeons, ducks and geese, chlamydiosis is the main rule-out. The genital tract can be infected by other microorganisms as well. Embryopathologic lesions and embryonal death are suggestive. With mycoplasmatales, infected embryos generally die late in incubation. Embryos that die after pipping frequently have air sacculitis of the left thoracic air sac group (exceptions are geese that have air sacculitis bilaterally). After hatching, chronic lymphofollicular proliferation can be so severe that lymphoma must be considered in the rule-out list.

### Diagnosis

A tentative diagnosis can be made by histopathologic examination. Isolation of the agent is necessary for identification and biologic assays. Because of the fastidious nature of this organism and the difficulties in identifying the agent, specialized laboratories are necessary to isolate *Mycoplasma*. In addition, the mycoplasmatales need to be differentiated from bacterial L-forms. Swabs from the upper respiratory tract, or the phallus in males, can be taken from live birds. Endoscopic biopsies of affected air sacs are useful diagnostic aids. Samples from air sacs, salpinx, lungs and spleen should be collected for post-mortem evaluation. Transport media are necessary for shipping samples. They should contain heart infusion broth, mycoplasma broth or another similar medium with penicillin (2000 IU/ml). Because the organisms are primarily to be protected from drying during transport and are not supposed to grow, the pH is not of particular importance (however, it should be around 7 or slightly above). Penicillin does not affect acholeplasma, but thallium-acetate does; therefore, mycoplasma broth that contains thallium-acetate should not be used for material from geese.

Indirect diagnosis of mycoplasmatales by serology is hampered by false-positive (cross-reactions) and false-negative tests. The presence of a mycoplasmatales on a mucosal surface usually does not stimulate production of humoral antibodies. Antigen-recognizing cells become active only after the mucosa has been penetrated. The most frequently used tests are: serum slide agglutination (SSA), HI test (for the hemagglutinating species), growth- or metabolic-inhibition test, immunodiffusion test, immunofluorescence test, ELISA, and recently the polymerase chain reaction.

### Treatment

Clinical infections can be treated with tylosin, spiramycin and erythromycin or spectinomycin in combination with clindamycin or pleuromutilin. The efficacy of tetracyclines against avian mycoplasmatales has yet to be proven. However, in Psittaciformes, the tetracyclines are recommended because of the clinical similarities between mycoplasmosis and chlamydiosis. The pigeon strains are highly resistant to erythromycin and, to a lesser extent, tylosin. Only pleuromutilin was able to inhibit 57 of 65 strains recovered from pigeons.<sup>15</sup> The LD<sub>50</sub> for pleuromutilin in pigeons is 440 mg/kg, considerably less than for chickens and turkeys. This drug must be carefully used when treating pigeons that are feeding offspring or if used in the water during hot weather.

Spiramycin given parenterally to Ploceidae, Estrildae and even canaries may lead to sudden death from unknown causes. The same dose given via drinking water is well tolerated. Spiramycin is one of the macrolid antibiotics and is given at a dose of 100 mg/kg body weight IM, or 100-200 mg/kg body weight orally. Since the primary patent has expired, several manufacturers produce it. Enrofloxacin has been used to treat mycoplasmosis in poultry. There have been no reports of success in treating mycoplasmosis with enrofloxacin in other birds. Treatment is designed to allow clinically affected birds to recover. The organism is difficult to eliminate.

### Control

Recovery from mycoplasmosis results in the production of a low antibody level and a persistent infection. *In vitro*, mycoplasmatales can propagate in the presence of homologous antibodies, indicating that humoral antibodies are not correlated with immunity. The disease is governed by the excessive reactions of the cell-mediated immune system. Therefore, vaccinations might sensitize a bird to the organism and cause a severe reaction to a field exposure. Theoretically, vaccines that prevent mycoplasmatales from attaching to the mucus cells might give protection.



## Rickettsia

Little information is available on rickettsial infections in birds. Rickettsia form a group of microorganisms, the taxonomy of which has still not been fully determined. They are obligatory cellular parasites, and can be differentiated from chlamydia by the absence of a developmental cycle and the capacity to synthesize energy-rich compounds (ATP). Rickettsia are small rods or coccoids with an average size of 0.3 to 0.5  $\mu\text{m}$  in diameter and 0.8 to 2.0  $\mu\text{m}$  in length. They may also be pleomorphic, and are generally nonmotile. Multiplication takes place by binary fission. The organism parasitizes reticuloendothelial cells, vascular endothelial cells or erythrocytes. Infections may occur in arthropods, which can serve as vectors or as primary hosts. The mutualistic forms in insects are considered to be essential for development and reproduction of the host.<sup>47</sup> Rickettsia may cause disease in humans, many vertebrates and insects. The organisms can be cultured in embryonated chicken eggs or metazoan cells. The chlamydial staining procedures may be used, although some changes are made particularly in fixation.

The rickettsia have historically been divided into three families:<sup>47</sup> Rickettsiaceae, Bartonellaceae and Anaplasmataceae. The latter two families are no longer considered to be Rickettsia and are "phylogenically unaffiliated bacteria" (Gothe, unpublished).

### Rocky Mountain Spotted Fever (RMSF)

RMSF is a mammalian disease caused by *Rickettsia rickettsii*. Prior to the availability of antibiotics (tetracyclines), infections were characterized by high mortality rates. The pathogenicity (for many other rickettsia as well) involves a toxin-like action that damages endothelial cells, inducing increased capillary permeability, plasma flow into the tissue, hemoconcentration and eventual circulatory collapse. Cytotoxicity is thought to be the mechanism by which rickettsia gain access to the cytoplasm of the host cells.<sup>41</sup>

RMSF is transmitted by ticks (mainly *Dermacentor* spp.) and rodents. Dogs and opossum are thought to be reservoirs. Birds, including chickens, several Columbiformes, pheasants, Falconiformes and the

Magpie, are susceptible to experimental infection and may also serve as reservoirs. Pigeons may be particularly important reservoirs.<sup>24</sup> Clinical abnormalities have not been described in infected birds.

### Q-Fever

Q-fever, caused by *Coxiella burnetti*, is an aerosol-borne disease in humans with worldwide distribution. Direct and indirect transmission (arthropods) can occur in humans and other host species. This agent differs considerably from other members of the Rickettsiaceae. The cells are smaller (0.2 to 0.4  $\mu\text{m}$  by 0.4 to 1.0  $\mu\text{m}$ ) and replicate in vacuoles of the host cells. In contrast to chlamydia, *C. burnetti* infections result in the formation of phagolysosomes. Two different phase variations are distinguished. Phase I is more virulent, presumably because of the high amount of lipopolysaccharides, and occurs naturally. Phase II appears following repeated passages in the yolk sac of embryonated chickens. The occurrence of plasmids has been established. The replication cycle includes production of endospore-like bodies, which are probably the cause of the high tenacity of *C. burnetti*. This organism is resistant to chemical disinfectants and high temperatures that might kill other rickettsia. Metabolic activity in these endospore-like bodies is extremely low outside the host. Survival, which can be several years in the feces of ticks, is augmented by dryness. Chlorine-containing preparations are recommended for disinfection. The effects of phenol and formaldehyde products are debatable.<sup>35</sup>

The host spectrum of *C. burnetti* is wide, and includes arthropods (particularly ticks), birds and mammals. An infectious cycle in free-ranging animals, arthropods, birds and mammals is differentiated from an infectious cycle in domesticated animals (sheep, goats, cattle, dogs). Cross transmission, including in man, is possible from both cycles.<sup>35</sup>

Avian susceptibility to *C. burnetti* seems to be high, and this organism has been demonstrated in at least 49 avian species.<sup>8,30,39</sup> The type of feeding behavior, breeding areas and seasonal migrations are the main factors for the spread of the organism. Carrion-eating birds may be infected by ingesting the infected placenta of ruminants from endemic areas. The feeding location of granivores and insectivores is more important than their food preferences. Birds that live in close contact with humans (synanthrops) are exposed more frequently to *C. burnetti* than birds that avoid civilization (exanthrops). The susceptibility to infec-

tion in domesticated birds is variable.<sup>8,38,39</sup> Chickens are apparently most susceptible and may shed the agent in the feces for 7 to 40 days post-infection. Vertical transmission via the egg may also occur. Domesticated pigeons are next in susceptibility. Domesticated turkeys, ducks and geese are rarely infected. All the free-ranging urban pigeons that were examined (125) in the Netherlands showed CF titers of  $\leq 1:20$  against *C. burnetti*.<sup>7</sup> In experimentally infected domesticated pigeons, the agent could be isolated from the spleen and lung 58 days post-infection.<sup>34</sup> No clinical disease has been observed in any susceptible avian species.

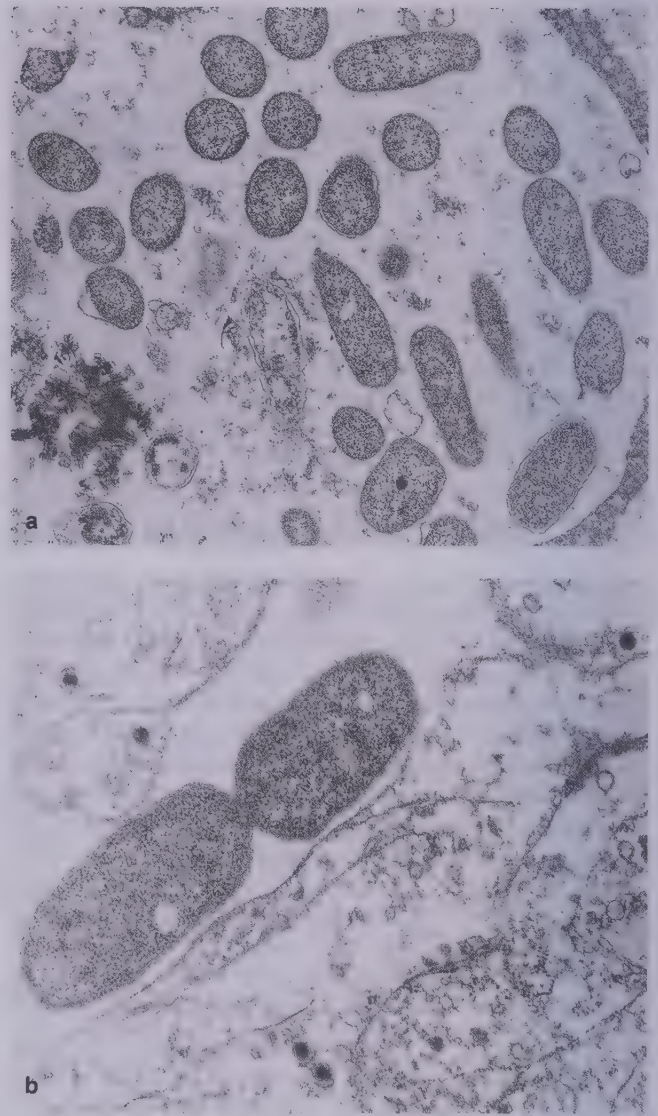
*C. burnetti* can be identified in tissues using various staining methods (Giemsa, Macchiavello, Castañeda) as for chlamydia. The organism replicates in embryonated chicken eggs and various cell cultures. Antibodies can be demonstrated using the CF test or the ELISA. Not all exposed domestic pigeons have been found to produce CF antibodies.<sup>34</sup> Antibody production is not related to immunity.

Therapy with tetracyclines is effective for the clinical disease, but elimination of the organism is not possible. Treatment for infected birds is not encouraged because of the high immunosuppressive side effect of the tetracyclines.

### ■ *Aegyptianella* (Ae.)

*Ae. pullorum* is the causative agent of anemia and hepatitis in chickens and other birds. It is an erythrocytic parasite that produces endocyttoplasmic inclusions, which stain using the Giemsa or Pappenheim procedures. The inclusions measure 0.3 by 4.0  $\mu\text{m}$ , and each can contain up to 26 initial bodies (reproducing form up to 0.8  $\mu\text{m}$  in diameter). In many instances, the inclusions are polymorphic (round, oval, ring- or horseshoe-shaped) and are separated from the plasma by a single-layered membrane. Infection of the cell starts with an endocytosis-like process followed by vesiculation in the erythrocyte. Exocytosis is one way in which the organism is released from the infected host cell. However, the host erythrocytes are usually damaged by the parasite, leading to lysis and release of the parasite into the plasma. Arthropods, mainly ticks of the genus *Argas*,<sup>16</sup> are essential for transmission.

The organism is most common in tropical and subtropical regions including the Mediterranean. The host spectrum is probably incomplete but certainly includes chickens, quail, Columbiformes, Strigidae,



**FIG 38.3** a) A group of Gouldian Finches died following an onset of clinical signs that included depression, dyspnea and coughing. Electron microscopy of tracheal epithelial cells revealed intracytoplasmic inclusion bodies with organisms morphologically suggestive of rickettsia. Magnification: x 22,250. b) Same cell type with rickettsia in binary fission; magnification: x 52,500; (courtesy E. Göbel).

Falconidae, Accipitridae, crows, canaries, ostriches, ducks, geese and some Psittaciformes such as *Agapornis* spp.<sup>16,17,33</sup>

Clinical signs in young birds are characterized by an acute onset of anemia, anorexia, weakness, weight loss, greenish diarrhea and death.<sup>33</sup> Chronic infections in older birds are characterized by icterus, which may not be clinically recognizable. The post-

mortem examination reveals anemia as well as a considerable enlargement of the liver and spleen.

Small inclusion bodies were demonstrated in the majority of the mature erythrocytes in two domestically raised Eclectus Parrot neonates (six weeks old) with heterophilia (toxic heterophils) and anemia. These intracellular parasites resembled those identified as *Aegyptianella* in several imported African Grey Parrots. Following a long-term course of doxycycline therapy, the parasites were no longer identifiable in the erythrocytes. The parents that produced these neonates were also positive for *aegyptianella* and responded to long-term doxycycline therapy.<sup>33</sup>

In gallinaceous birds, the age and condition of the host govern the pathogenesis and outcome of the infection. Up to 60% of the erythrocytes may be infected in one-day-old chicks, while by one year of age less than 1% of the erythrocytes may be infected.<sup>16</sup> Mortality is higher in chicks less than two days of age.

The rule-out list includes internal bleeding, chlamydiosis and chronic diseases of various etiology. For diagnosis, a blood smear stained according to Giemsa or Pappenheim shows the parasites in the erythrocytes. Tetracyclines are effective for treatment. Tick control is mandatory to prevent reinfection and epizootics.

### Unclassified

There are indications that diseases caused by rickettsia other than *aegyptianella* may occur. Tracheal epithelial cells in Gouldian Finches with severe respiratory disease were filled with cytoplasmic "inclusions." Many of the affected birds died. Electron microscopy of the epithelial cells revealed particles that were morphologically compatible with rickettsia (Figure 38.3). Treatment with tetracyclines was successful. Isolation was not possible because the material had been prepared for histopathology.<sup>27</sup>

### References and Suggested Reading

- Adler HE: Isolation of a pleuropneumonia-like organism from the air sac of a parakeet. *J Am Vet Med Assoc* 130:408-409, 1957.
- Bencina D, et al: Mycoplasma species isolated from six avian species. *Avian Pathol* 16:653-664, 1987.
- Bozeman LH, et al: Mycoplasma challenge studies in budgerigars (*Melopsittacus undulatus*) and chickens. *Avian Pathol* 13:426-434, 1984.
- Bradbury JM, et al: Isolation of *Mycoplasma cloacale* from a number of different avian hosts in Great Britain and France. *Avian Pathol* 16:183-186, 1987.
- Buntz B, et al: Isolation of *Mycoplasma gallisepticum* from geese. *Avian Pathol* 15:615-617, 1986.
- Butcher GD, et al: Reductions of clinical signs in budgerigars experimentally infected with *Mycoplasma gallisepticum*. *J Assoc Avian Vet* 4:227-230, 1990.
- Dorrestein GM, et al: Some observations on the health status of free-living urban pigeons (*Columba livia*). VII DVG-Tagung Vogelkrhrt, München, 1990, pp 77-87.
- Enright JB, et al: Q-fever antibodies in birds. *J Wildlife Dis* 7:14-21, 1971.
- Fudge AM: Common medical conditions seen in the cockatiel *Nymphicus hollandicus*. *Conf Europ Com Assoc Avian Vet*, Vienna, 1991, pp 351-356.
- Furr PM, et al: Isolation of mycoplasmas from three falcons (*Falco* spp.). *Vet Rec* 100:72-73, 1977.
- Gaskin JM, et al: A mycoplasma-associated epornitic in severe macaws (*Ara severa severa*). *Proc Am Assoc Zoo Vets*, pp 59-61, 1979.
- Gaskin JM: Mycoplasmosis in caged birds. *Proc 1st Intl Conf Zoological & Avian Med*, 1987, pp 57-60.
- Gerlach H: Infektionen durch Mollicutes bei Vögeln. In Gylstorff I: Infektionen durch Mycoplasmatiales. Infektionskrankheiten und ihre Erreger. Band 21 VEB Verlag Gustav Fischer, Jena, 1985, pp 448-491.
- Gerlach H: Über das Vorkommen von Mycoplasmen bei Tauben. *Berl Münch Tierärztl Wschr* 90:140-143, 1977.
- Gerlach H: Untersuchungen über Mollicutes bei Tauben. *Habil.-Schrift Tierärztliche Fakultät München*, 1978.
- Gothé R, et al: Genus II. *Aegyptianella* (Carpano, 1929). In Bergey's Manual of Systematic Bacteriology vol 2. Baltimore, London, Los Angeles, Sydney, Williams and Wilkins, 1986, pp 722-723.
- Gylstorff I: Rickettsiales. In Gylstorff I, Grimm F: Vogelkrankheiten. Stuttgart, Verlag Eugen Ulmer, 1987, p 317.
- Gylstorff I: Entzündung der Nase und Nebenhöhlen. In Joest: Handbuch der speziellen pathologischen Anatomie der Haustiere. Band 7, 3. Auflage Berlin und Hamburg/Verlag Paul Parey.
- Gylstorff I: Mollicutes. In Gylstorff I, Grimm F: Vogelkrankheiten. Stuttgart, Verlag Eugen Ulmer, 1987, pp 323-325.
- Jordan FTW, et al: The recovery of *Mycoplasma* from the avian oesophagus. *Vet Rec* 102:403-404, 1978.
- Jordan FTW, et al: The isolation of *Mycoplasma columbinum* and *M. columborale* from feral pigeons. *Vet Rec* 109:450, 1981.
- Kisary J, et al: Mycoplasma infection in geese II. Studies on pathogenicity of mycoplasmas in goslings and geese and chicken embryos. *Avian Pathol* 5:15-20, 1976.
- Kleven SH, et al: *Mycoplasma synoviae* infection. In Calnek BW, et al (eds): Diseases of Poultry 9th ed. Wolfe Publishing, 1991, pp 223-231.
- Lundgren DL, et al: Infectious diseases of wild animals in Utah. VI. Experimental infection of birds with *Rickettsia rickettsii*. *J Bact* 91:963, 1966.
- Macowan KJ, et al: *Mycoplasma columborale* in a respiratory condition and experimental airsacculitis of chickens. *Vet Rec* 109:562, 1981.
- Maestrini N, et al: Amiloidosi nella gallina faraona. *Veterinaria* 24:378-380, 1967.
- Merkus: Dr. med vet., Landesuntersuchungsamt, Krefeld Germany
- Müllegger P-H: Die Differenzierung aviärer Mycoplasmen mit Hilfe der Disk-Elektrophorese. *Zbl Bakt Hyg I Abt Orig A* 226:119-136, 1974.
- Pascucci S, et al: *Mycoplasma synoviae* in the Guinea-Fowl. *Avian Pathol* 5:291-297, 1976.
- Pospisil R, et al: Q-Fieber in der Ostlowakei (CSSR). 2. Internat. Arbeitskoll. Naturherde von Infektionskrankheiten in Zentraleuropa. Graz, 1976.
- Poveda JB, et al: An epizootiological study of avian mycoplasmas in southern Spain. *Avian Pathol* 19:627-633, 1990.
- Roberts DH: The isolation of an influenza A virus and a mycoplasma associated with duck sinusitis. *Vet Rec* 76:470-473, 1964.
- Roskopf WJ, et al: Aegyptianella-like parasites seen in eclectus parrots in southern California. *Proc Assoc Avian Vet*, 1992, pp 129-133.
- Schmatz H-D, et al: Zum Verhalten des Q-Fieber-Erregers, *Coxiella burnetii*, in Vögeln. 2. Mitteilung: Experimentelle Infektion von Tauben. *Dtsch Tierärztl Wschr* 84:60-63, 1977.
- Selbitz H-J: Lehrbuch der veterinärmedizinischen Bakteriologie. Gustav Fischer Verlag Jena, Stuttgart pp. 257-268, 1992.
- Stipkovits L, et al: Mycoplasma infection of geese. I. Incidence of *Mycoplasma* and *Acholeplasma* in geese. *Avian Pathol* 4: 35-43, 1975.
- Stipkovits L, et al: Occurrence of mycoplasmas in geese affected with inflammation of the cloaca and phallus. *Avian Pathol* 15:289-299, 1986.
- Syrucsek L, et al: Q-fever in domestic and wild birds. *Bull Wild Hlth Org* 15:329-337, 1956.
- Thiel N, et al: Übersichtsreferat: Zum Verhalten des Q-Fiebererregers, *Coxiella burnetii*, in Vögeln. 1. Mitteilung: Natürliche Infektionen bei Vögeln. *Dtsch Tierärztl Wschr* 84:63-68, 1977.
- Varga ZS, et al: Biochemical and serological study of two *Mycoplasma* strains isolated from geese. *Arch exper Vet med Leipzig* 43:733-736, 1989.
- Weiss E, et al: Order I Rickettsiales (Gieszczykiewicz, 1939). In: Bergey's Manual of Systematic Bacteriology Vol 2. Baltimore, London, Los Angeles, Sydney, Williams and Wilkins, 1986, pp 687-722.
- Yamamoto R: *Mycoplasma meleagridis* infection. In Calnek BW, et al (eds): Diseases of Poultry 9th ed. Wolfe Publishing, 1991, pp 212-223.
- Yoder H Jr: *Mycoplasma gallisepticum* infection. In Calnek BW, et al (eds): Diseases of Poultry 9th ed. Wolfe Publishing, 1991, pp 198-212.

## ■ C H A P T E R S

### 39 ANESTHESIOLOGY

Leslie C. Sinn

### 40 SURGICAL CONSIDERATIONS

R. Avery Bennett

### 41 SOFT TISSUE SURGERY

R. Avery Bennett  
Greg J. Harrison

### 42 ORTHOPEDIC SURGICAL TECHNIQUES

Howard D. Martin  
Branson W. Ritchie

VI

---

---

## SECTION SIX

# SURGERY

---

---

VI



CHAPTER

# 39

## ANESTHESIOLOGY

Leslie C. Sinn

**W**ith the refractory attitudes of many birds toward even mild restraint, sedatives and local anesthetics are of little use in most avian species. General anesthesia, however, with appropriate agents, can enable clinicians to safely and rapidly perform fluid administration, emergency procedures, blood collection and radiography, or to perform prolonged invasive surgical procedures in avian patients.


Historically, avian anesthesia has been a problem fraught with continuous debate. Many clinicians have had their preferred drug “cocktails,” and there were many conflicting views with regard to dosage ranges and choice of anesthetic regime. Anesthesia machines have been altered in an attempt to meet the specialized needs of avian patients, and numerous modified endotracheal tubes, non-rebreathing bags and delivery systems have been implemented. Sophisticated monitoring systems and equipment designed for or found to be suitable for avian patients are now commercially available.

As in other animal species, general anesthesia in birds can be accomplished with either injectable or inhalant anesthetic agents. The goal of anesthetizing a patient is to select the safest drug that allows the minimum amount of physiologic changes. (The reader is referred to Section Seven for use of anesthetics in non-psittacine species.) Injectable anesthetics are far inferior to gas anesthetics for use in avian patients, and for private avian practice, isoflurane is the only recommended anesthetic. This is particularly true given that the vast majority of patients are anything but healthy and are less tolerant of the physiologic compromises induced by most injectable and other inhalant anesthetics.

The basic principles of risk assessment and patient support used for mammalian anesthesia are also applicable to the avian patient. Ability to assess the condition of avian patients has improved, as has the ability to provide physiologic support during the anesthetic episode.

## Anesthetic Agents and Equipment

The ideal avian anesthetic agent is one that creates minimal stress in administration, has a high therapeutic index, provides for rapid induction and recovery, induces minimal physiologic changes, provides adequate restraint for the desired procedure and can be safely used in critical cases. Contraindications for anesthetizing an avian patient should include severe obesity, fatty liver, liver or kidney failure, dehydration, shock, anemia, dyspnea and fluid in the crop. Unfortunately, patients presented with many of these problems are those that require anesthesia for proper resolution of the case. The choice of anesthetic agent must be based on the patient's status and the working conditions that the clinician faces (eg, field vs. hospital anesthesia). In all situations, the anesthetic of choice is isoflurane.<sup>a,b</sup> There are some indications for the use of injectables in the field, and recent work with reversal agents may make the use of injectables more appealing to some avian practitioners.



**FIG 39.1** An isoflurane anesthesia circuit for use in birds that will fit into a small tool box is commercially available. **a)** The components of the system are shown separated and **b)** connected to form a functional circuit (courtesy of Exotic Animal Medical Products).

ners. However, an isoflurane anesthetic unit designed for field use will fit into a small tool box (10" x 12" x 20"); the only other necessary equipment is an oxygen source (Figure 39.1).

When compared to injectable anesthetics, inhalation agents have numerous advantages. They can be titrated to effect, have a more consistent therapeutic index and provide for rapid induction and smooth, rapid recoveries. Additionally, the anesthetic episode can be maintained for variable durations as dictated by the procedure and, particularly with isoflurane, effects can be instantly reversed.

### Physiologic Effects of Inhalant Anesthesia

In administering avian inhalant anesthetics, there are several important differences between the mammalian and avian respiratory system that should be addressed. The paramount difference is that the avian lung does not have alveoli. Instead, the air capillaries function as the anatomic location of gas exchange.<sup>28</sup> Avian species also lack a diaphragm, and inspiration is totally dependent on the correlative movement of the coracoids, ribs and sternum. The total lung capacity of avian species is much less than that of an equivalent-sized mammal; however, due to the air sac system, the total respiratory volume is substantially greater. There is also a high gas exchange surface-to-volume ratio that accounts for more efficient gas exchange. This efficiency accounts for the rapid equilibration of inspired components with arterial blood and for the rapid induction, rapid changes in depth of anesthesia and speed of recovery when inhalant anesthetics are used in birds. Recovery from isoflurane is primarily a function of the excretion of the gas by the lungs. Full recovery with agents such as methoxyflurane that are highly metabolized depends on the biotransformation of the agent by the liver. Birds are very sensitive to CO<sub>2</sub> concentrations, and if the blood is depleted of CO<sub>2</sub>, the patient will become acutely apneic. The minimum level of CO<sub>2</sub> in the blood that is necessary to stimulate respiration in birds has been suggested to be 25 torrs.<sup>6</sup>

Because of the anatomy and structure of the avian respiratory system, even healthy birds may not be properly oxygenated when anesthetized and placed in dorsal recumbency.<sup>6</sup> It may be impossible for some species that have a large pectoral muscle mass (eg, Galliformes and Anseriformes) to adequately ventilate. Because of their unique respiratory anatomy, intubation and the use of gentle intermittent positive

pressure ventilation (IPPV) (20 to 40 per minute at 15 mm H<sub>2</sub>O) is strongly recommended in anesthetized patients.<sup>28</sup>

### Isoflurane

Isoflurane is rapidly replacing halothane and methoxyflurane as the gas anesthetic of choice for small animal patients. This surge in popularity is based on isoflurane's rapid induction time, rapid and smooth recoveries, rapid change in anesthetic level, high margin of safety for both the patient and hospital staff, reduced arrhythmogenic properties, reduced cardiovascular depression and reduced respiratory depression. The drug can also be safely used to obtain diagnostic information from high-risk and critically ill birds. Recovery from even long surgical procedures requires only minutes.

Isoflurane can have a dose-related depressant effect on the respiratory and cardiovascular system. Fortunately, there is a substantial interval between respiratory and cardiac arrest.<sup>1,9,11,27</sup> The hypotensive effects of isoflurane have been shown to be severe in cranes. The effect was dose-dependent and was potentiated by spontaneous respiration when compared to assisted ventilation (IPPV).<sup>19</sup> Isoflurane is only 0.3% metabolized compared to 15% for halothane and 50% for methoxyflurane; thus, isoflurane does not produce the hepatic damage induced by halothane and methoxyflurane. However, it has been evaluated in the field for only 12 years, and precautions should still be used with this anesthetic gas. The low metabolism rate also means that when the gas is expired by the lungs, few residues or toxic metabolites remain to further hinder the patient's recovery. Isoflurane has a blood solubility of 1.4 compared to 13 for methoxyflurane and 2.4 for halothane. Because the solubility is so low, the agent is not dissolved in the blood, and the speed of induction and recovery are extremely rapid. Minimum alveolar concentration (MAC) has been found to be approximately 1.3 (cranes and ducks).<sup>18,19</sup> This would indicate that higher settings for isoflurane delivery might predispose the patient to apnea, cardiac arrhythmias and cardiac arrest.

### Methoxyflurane

Methoxyflurane is 50% metabolized, has a high degree of organ toxicity and produces prolonged effects on physiologic parameters. This gas is highly soluble in blood, which accounts for its relatively long periods of induction and recovery (may take hours). This solubility prevents the rapid change in anesthetic depth, which makes the anesthetized bird easier to

maintain. However, the quantity of gas dissolved in the blood also prolongs the time required to lighten a bird in critical situations. Methoxyflurane is known to induce major hepatic and renal dysfunction in chronically exposed hospital personnel, and scavenging systems should be used to remove waste gas from the hospital setting. Because of methoxyflurane's low volatility, techniques have been described for administering the gas in open anesthetic systems. This is an extremely dangerous method of providing anesthesia in birds, and if an adequate oxygen supply is not assured, it will result in rapid death of the patient.

### Halothane

Halothane is a relatively nonirritating gas that requires a precision vaporizer for proper delivery. The blood:gas coefficient for mammals is 2.3, which, when combined with the rapid arterial gas exchange that occurs in the avian respiratory system, accounts for a rapid induction and recovery. Induction is usually achieved within two to five minutes at a two to three percent level; recovery time depends on the length of the procedure but generally varies from 5 to 20 minutes. Halothane will induce a rapid decrease in the heart rate that returns to normal shortly after ceasing anesthetic administration. Maintenance is usually achieved between 1 to 1.5%, which decreases as the length of the procedure increases, and decreases with the degree of induced hypothermia. Halothane is only 15% metabolized. Disadvantages of halothane in the avian patient are that 1) apnea and cardiac arrest often occur at the same time, and 2) the gas does sensitize the heart to catecholamines, which may induce arrhythmias, particularly with longer surgical procedures. The agent can cause liver disease in chronically exposed hospital personnel, and scavenging systems should be used to remove waste gas from the hospital setting. Recoveries with halothane are more prolonged than with isoflurane.

## CLINICAL APPLICATIONS

Isoflurane is an ideal anesthetic in birds because of its:

- High therapeutic index
- Rapid induction and recovery
- Minimal physiologic changes
- Adequate restraint for many procedures
- Safety in critical patients
- Reduced toxicity



### Oxygen

The oxygen flow should be high enough to ensure that a precision vaporizer is accurate in its delivery of the anesthetic gas. For most precision vaporizers, the minimum flow rate is 500 ml/min. Some vaporizers function adequately at low settings but the manufacturer's recommendations should always be followed. If a semi-open system is used, the oxygen flow should be three times the respiratory minute volume, which for a 450 g bird is about 275 ml/min. As a general guideline, this ratio can be used to determine the respiratory minute volume of any avian species. For most psittacine birds, the oxygen flow rate during induction is 1 l/min and maintenance is 0.5 to 1 l/min depending on the size of the patient.

### Nitrous Oxide

Nitrous oxide ( $N_2O$ ) has successfully been used in birds in combination with isoflurane anesthesia.  $N_2O$  is not potent enough to induce anesthesia on its own; however, it does allow for the reduction in the percentage of isoflurane necessary for anesthetic maintenance. Because cardiovascular and respiratory depression caused by isoflurane are dose-dependent,  $N_2O$  is an important addition to the anesthetic regime.  $N_2O$  does have the characteristic of diffusing into closed gas spaces faster than nitrogen (room air) can diffuse out. This means that  $N_2O$  is contraindicated in situations where dead gas spaces are present. Because the avian respiratory system including the air sacs freely intercommunicate, the use of  $N_2O$  is not contraindicated. Some species differences do exist. For instance, diving birds have naturally occurring subcutaneous air pockets, and the use of  $N_2O$  in these birds may lead to subcutaneous emphysema.<sup>3</sup>

### Pre-anesthetics

The routine use of atropine as a pre-anesthetic has been avoided in avian patients because it thickens respiratory secretions, slows gastrointestinal motility and increases the heart rate. The thickening of respiratory secretions could contribute to a life-threatening occlusion in patients intubated with small-diameter endotracheal tubes. Additional elevation of the heart rate is not desirable in patients that already have a rapid rate. Glycopyrrolate does not have as marked effect on the heart, but it too causes thickening of respiratory secretions. Consequently, these drugs are used only as specific therapy for bradycardia. Further studies on the use of these drugs in birds are needed.

### Injectable Anesthetics

Injectable anesthetics in birds have the same disadvantages that are recognized in mammalian species. There is a tremendous variability in therapeutic dosages and physiologic effects, both at the species and individual patient levels. Likewise, many injectable anesthetics do not provide an adequate plane of anesthesia without reaching tissue levels that threaten the life of the patient. There is minimal ability to titrate injectable agents to effect, so levels of anesthesia may be insufficient to perform a procedure or may be so deep that the patient is in danger. With most commonly used injectable agents, the anesthetic level cannot be rapidly decreased, and the recovery is prolonged because the drug must be totally removed by metabolic pathways. Increased recovery times create excessive stress, increase the period of hypothermia and prolong the deviation from a physiologically normal state. With any anesthetic episode, a major goal should be to minimize the time between induction and recovery, and injectable anesthetics do not effectively meet this criteria. Unfortunately, when using parenteral anesthetics, the period of recovery may be far longer than the duration of useful anesthesia.

The most commonly reported injectable anesthetics used in birds are combinations of ketamine and xylazine and, less frequently, ketamine and diazepam. Etorphine, methoxymol, propafol, midazolam, tiletamine/zolezepam and barbiturates have all been used in birds.<sup>4,7,12,15</sup> Initial data are promising for some of these drugs, but in many cases actual clinical trials are not available. In general, phenobarbital, methohexital, thiobarbiturates and barbital should not be used in companion birds. They have a low margin of safety, produce prolonged violent recoveries, must be given IV to prevent perivascular damage and at best provide radically variable levels of anesthesia.

Ketamine, a cyclohexamine, produces a cataleptic state that inhibits movement, but does not provide adequate analgesia for major surgical procedures. This drug has a highly variable effect in different avian species. It is metabolized by the kidneys and is therefore contraindicated in patients with renal insufficiency. Dose ranges for various species are reported from 5 to 75 mg/kg. The drug is most commonly administered IM, and the first signs of incoordination occur within three to five minutes. The typical duration of anesthesia is 10 to 30 minutes, and recovery may take from 30 minutes to several hours, which is completely dose-dependent.

Ketamine anesthesia is typified by cardiac and respiratory depression, increased blood pressure, reduced body temperature, slow violent recoveries and prolonged physiologic changes.

Ketamine is rarely used alone. Because of the muscle rigidity produced by this drug and the inadequacy of the analgesia achieved, ketamine is most often used in combination with either xylazine or diazepam.<sup>12,20</sup> The ratio for both ketamine/diazepam or ketamine/xylazine combination is 10:1 on a mg/kg basis. Either combination provides for more rapid induction, smoother maintenance and less violent recovery than when ketamine is used alone.

Xylazine produces good muscle relaxation and transient analgesia. It can cause bradycardia and heart blocks.<sup>20</sup>

Diazepam is an excellent sedative and provides some muscle relaxation.<sup>20</sup> Ketamine/diazepam combinations can be useful when mild restraint is required.

The dosages for the drugs to be administered in combination are calculated based on a ketamine dosage of 5 to 30 mg/kg IM (or 2.5 mg to 5.0 mg IV) mixed with xylazine 1.0 mg to 4.0 mg IM (or 0.25 to 0.50 mg IV). Alternatively, diazepam (0.5 mg to 2.0 mg/kg IM or IV) may be substituted for the xylazine.<sup>2,4,5,8,12,28</sup> The two drugs chosen are mixed together and administered either intramuscularly or intravenously. Reduced doses are necessary in seriously ill, pediatric and geriatric patients and for intravenous administration. Ratites require only 3 mg/kg of ketamine. Because these drugs have a narrow therapeutic index and the species and individual dose responses vary widely, clinicians are advised to start at the lower end of the dosage range. The intravenous route is preferred, as the dose can be titrated to effect.<sup>12</sup> Both xylazine and diazepam can be mixed in the same syringe with ketamine. Care must be taken, especially with smaller doses, to eliminate all air pockets from the syringe and to thoroughly mix the two drugs. Recovery from intravenous administration of these injectable anesthetic combinations may take 15-45 minutes, while recovery from intramuscular administration, especially if additional dosages have been necessary, may take hours. Recovery may be violent. Yohimbine has been shown to be an effective reversal agent for ketamine/xylazine anesthesia in raptors. A dosage of 0.1 mg/kg yohimbine was effective in reversing anesthesia caused by the administration of intravenous ketamine (4.4 mg/kg)/xylazine (2.2 mg/kg).<sup>5</sup> Tolazoline (15 mg/kg IV) has been

used to successfully reverse ketamine/xylazine anesthesia in turkey vultures.<sup>2</sup> The use of these reversal agents may make the use of ketamine/xylazine safer and more practical for birds.


Etorphine has been successfully used in large birds such as ostriches and cassowaries. A dosage of 0.02 to 0.03 mg/kg IM is utilized for restraint. This can then be reversed with 0.04 to 0.06 mg/kg IV of diprenorphine.<sup>15</sup>

Midazolam (same group as diazepam) (15 mg/kg IM) was successfully used to reduce the percentage of isoflurane necessary for general anesthesia in racing pigeons. It was then effectively reversed with the drug flumazenil (0.1 mg/kg IM).<sup>29</sup>

## Gas Anesthetic Equipment and Delivery

### Anesthetic Machines and Vaporizers

Most of the available models of anesthetic machines are adequate for an avian practice. What is required is an out-of-circuit, precision vaporizer for the administration of isoflurane. The vapor pressure of isoflurane (261 mm Hg) is so close to halothane (243 mm Hg) that the same type precision vaporizer can be used for both agents (Figure 39.2). However, once converted to isoflurane, a machine should no longer be used for halothane. A vaporizer can be purchased that is manufactured specifically for use with isoflurane, or a halothane vaporizer can be cleaned with ether and re-calibrated for use with isoflurane. A vaporizer cannot be used for halothane and isoflurane at the same time. Switching back and forth



**FIG 39.2** The vapor pressure of isoflurane and halothane are similar so isoflurane can be delivered through a halothane vaporizer; however, once a vaporizer has been converted to isoflurane use, it should not be used with halothane.



**FIG 39.3** Tank systems should not be used for inducing anesthesia in birds.

between these agents will destroy the vaporizer. Calibration of the vaporizer is necessary after a conversion has occurred from halothane to isoflurane. Once isoflurane is in use, the vaporizer should be cleaned and re-calibrated on a yearly basis.

### Breathing Systems

Gas anesthesia can be achieved through either an open, semi-open or semi-closed system. Open systems rely on the animal's being placed in contact with an absorbent material soaked in the anesthetic liquid. There are descriptions of methoxyflurane being administered in a drip cone system. With the highly volatile anesthetics like halothane and isoflurane, very high concentrations of the gas will rapidly occur in the inspired air, causing acute anesthetic overdose and death. Tank systems used to induce anesthesia in small mammals should not be used in birds. These chambers prevent monitoring of the patient, create a potential for beak, head, neck or spinal trauma and release high concentrations of gas into the environment when the top is opened (Figure 39.3).

Semi-open systems rely on an Ayres T-piece, Y-piece, Norman elbow or Kuhn circuit that prevents the rebreathing of expired gases. Because of the rela-

tively low resistance to air flow present in these systems, they are ideal for avian patients.

Semi-closed systems rely on the complete rebreathing of expired gases. The resistance inherent in the circuit makes them impractical for birds.

A non-rebreathing anesthetic system is recommended for patients under seven to eight kilograms (most birds). This reduces dead space and decreases the effort that the patient must exert in order to breathe. This is especially important in birds, because both expiration and inspiration involve active use of the trunk muscles. Either an Ayer's T-piece or Bain's circuit can be effectively used with most birds. Some clinicians prefer the Bain's circuit because in theory, the patient's expired gases warm the in-flowing gases and reduce the loss of body heat. This can be critical in birds because their small size predisposes them to hypothermia, and respiration is one of the major routes through which body heat is lost. In patients over seven to eight kilograms, conventional human pediatric supplies are adaptable, easy to obtain and easy to maintain. In larger avian patients (eg, ostriches), standard small animal anesthetic equipment and supplies are applicable.

A standard 0.5 liter reservoir bag can be used in some larger avian patients, but better control and monitoring of respiration can be achieved with a smaller volume bag specifically designed for birds. These can be handmade from plastic bags, or an inexpensive, disposable avian anesthesia bag is commercially available (Figure 39.4).<sup>c</sup>



**FIG 39.4** Anesthesia bags (50 ml, 100 ml and 250 ml) are commercially available for use in birds. These inexpensive bags account for the reduced tidal volumes of birds, allow for precise IPPV and are disposable, which prevents nosocomial infections. The bags can be adapted to any Ayres T-piece-type semi-open anesthetic delivery system (courtesy of Exotic Animal Medical Products).

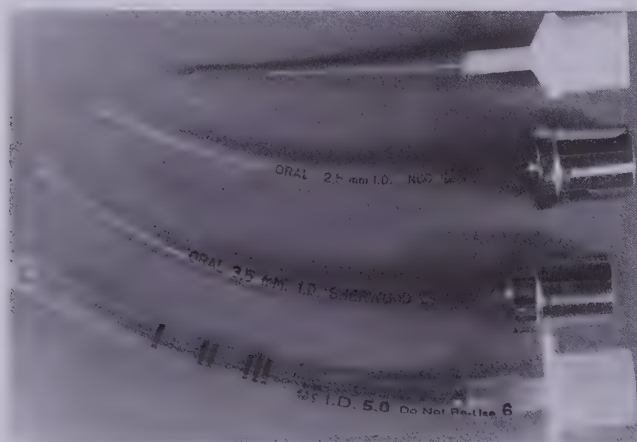
An appropriate scavenging system is the best protection for operating room personnel from secondary gas exposure. Once the scavenging system is in place, gas exposure can be reduced by quickly intubating patients, minimizing the time the patient is wearing a mask and keeping flow rates as low as possible to prevent gas from escaping via the pop-off valve. End valves placed in the reservoir bag can be vented directly into the scavenging system.

### Endotracheal Tubes

Non-cuffed infant, Magill or Cole (smallest size = 2 mm) endotracheal tubes can be used in medium- to large-sized birds (Figure 39.5). Cuffless tubes are used because birds have complete tracheal rings that cannot expand if excessive amounts of air are introduced into a cuffed tube. Alternatively, some clinicians choose to make their own endotracheal tubes out of red rubber feeding tubes. The end of the tube is snipped off and small holes are cut in the surface of the tube to allow for air exchange. The tip of the tube should be blunted by heating it with a flame and pressing it on a hard surface. These tubes are less costly than purchased tubes and have the added bonus of being disposable. In any situation, a tube with the maximum internal diameter that will fit in a bird's trachea should be used.

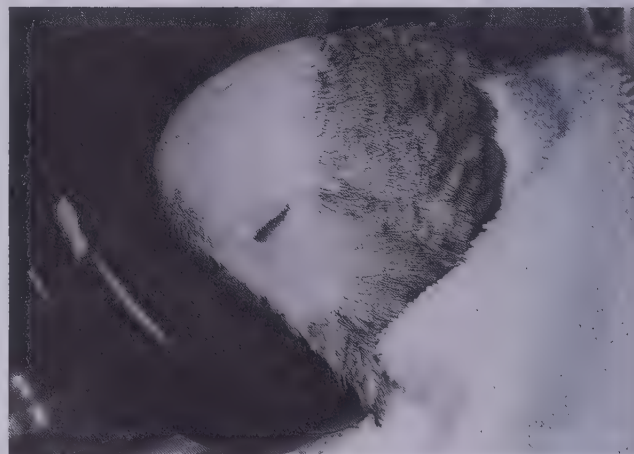
### Face Masks

The delivery of inhalant gases from a precision vaporizer can best be achieved by manually restraining the patient and placing the nostrils and mouth in a face mask connected to an Ayres T-piece anesthetic circuit. Common canine or feline anesthetic masks, while not ideal, can be used for induction. Most small



**FIG 39.5** Non-cuffed, 2 mm endotracheal tubes are commercially available. These are generally small enough for use in birds over 150 g. In smaller birds, a red rubber feeding catheter with several holes cut in the end can be used as an endotracheal tube.


animal masks fit avian patients poorly, resulting in dilution of the anesthetic gas with room air. With these leaks, higher gas and oxygen settings are necessary in order to compensate for leakage (Figure 39.6). To avoid nosocomial infections, a disposable plastic drinking cup, with soft paper products placed between the cup and the patient's neck to prevent gas leaks, can be used as a face mask (Figure 39.7). In birds less than 150 g, an effective mask can be made by covering the end of a 12 cc syringe case with a section of latex glove. The syringe case can then be slipped over an Ayres T-piece with a 50 ml anesthesia nonrebreathing bag (Figure 39.8).



**FIG 39.6** A small animal face mask can be used to induce gas anesthesia in medium and large companion birds.



**FIG 39.7** Using a disposable plastic cup as an induction mask prevents the transmission of respiratory pathogens (eg, chlamydial, viral, fungal) between patients. If small animal face masks are used, they must be cleaned and sterilized between avian patients.



**FIG 39.8** A 12 cc syringe case can be cut to fit over an Ayres T-piece and covered with a latex glove to be used as a disposable face mask in small avian patients.

### Care of Equipment

The proper use and maintenance of anesthetic equipment is an often overlooked area.

With the large number of infectious bacterial, fungal and viral agents encountered in avian patients, any equipment used during anesthesia, including tubing and endotracheal tubes, should be thoroughly disinfected to reduce the chance of nosocomial infections. Equipment should not be used for other companion animals and then used for birds without sterilization. While the face mask and Ayres T-piece can be easily disinfected in cold sterilization solutions, anesthetic bags are much more difficult to disinfect.

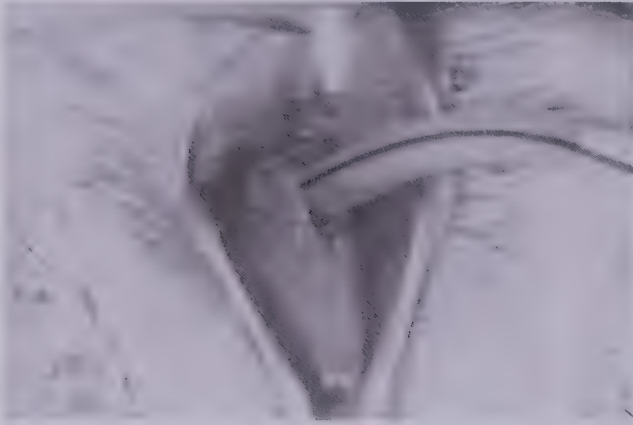
Tubing, reservoir bags, face masks and endotracheal tubes should be thoroughly cleaned with soap and water, then rinsed with clear water. They should then be disinfected using a chemical disinfectant and rinsed again with clear water. Finally, they should be allowed to air-dry in a clean, dust-free location. Alternatively, they may be sterilized using ethylene oxide or, with some endotracheal tubes, a heat autoclave. Because this cleaning regime must be used with every anesthetic episode, a large reserve of equipment is necessary to handle a sizable avian patient case load. Many clinicians feel it is more economical to use disposable anesthetic supplies than to use technician time for cleaning equipment. Disposables, however, are more expensive and they contribute to the medical waste problem.

### Delivery of Inhalant Anesthetics

Two methods of anesthetic induction with isoflurane have been discussed. One method is to place the bird in a face mask and slowly increase the gas to a level of 2.5 to 3%. However, the editors believe that the rapid induction achieved by using a 5% setting initially, followed by a decrease to maintenance levels of 1 to 2% is a better method. The amount of isoflurane delivered will vary with the patient, the individual anesthetic machine and the delivery system. Some macaws, owls and Galliformes appear to be particularly sensitive to gas anesthesia and may become apneic even with the use of isoflurane. Maintenance levels of anesthesia may be as low as 0.25% in sensitive individuals.

After induction, any patient that will be anesthetized for more than ten minutes should be intubated with an appropriately sized endotracheal tube (Figure 39.9). The amount of dead space should be minimized by ensuring an adequate gas flow and by using tracheal tubes of the proper length. The appropriate endotracheal tube length can be determined by measuring the distance from the thoracic inlet to the tip of the beak. The laryngeal structure of birds is highly mobile and can be manipulated from below the mandible to improve access for intubation.

Following intubation, the endotracheal tube can be connected directly to the semi-open system. If there is a possibility of regurgitation, the tongue and glottis should be pulled cranially, and the esophagus



**FIG 39.9** In some birds (like this owl), it is easy to visualize the glottis for intubation. In others (many psittacine birds), it is more difficult to visualize the glottis. Intubation can be simplified by placing a finger in the intermandibular space and gently lifting the glottis into view.

should be packed with moistened cotton to prevent aspiration.

#### Air Sac Administration

For surgery of the head, trachea or syrinx, anesthesia can be delivered by placing a short endotracheal or red rubber tube into the clavicular or caudal thoracic air sacs.<sup>25,26</sup> The placement procedure is rapid and may be indicated as an emergency tactic when an animal is presented with respiratory arrest or when severe dyspnea has been induced by foreign body aspiration. To place an air sac tube, the animal is positioned with the leg extended to the rear as for a surgical sexing procedure. A small skin incision is made over the sternal notch, and hemostats are used to produce an entrance through the body wall and into the left abdominal air sac (see Chapter 13). A shortened endotracheal tube can then be inserted into the air sacs and the Ayres T-piece connected directly to the tracheal tube.

A study in pigeons and common buzzards indicated that isoflurane could be safely administered through the air sacs to maintain a surgical plane of anesthesia for 60 minutes. These birds were monitored for changes in temperature, pulse rate, oxygen saturation, blood pressure and  $\text{paCO}_2$  levels (Table 39.1). In this study a persistent period of apnea was noted when the air sac tube was perfused with oxygen. It was suggested that the loss of  $\text{CO}_2$  present in the lungs and air sacs decreased the stimuli to the respiratory centers and induced the apnea. No assisted respiration techniques were used during the 60-minute period of apnea.<sup>16</sup>

At the end of the 60-minute study, the birds were flushed with oxygen to remove residual isoflurane and their  $\text{paCO}_2$  levels dropped to 19. This hypocapnia was followed in four minutes by the return of spontaneous respiration, which was associated with an increase of  $\text{paCO}_2$  levels (40 in the pigeons, 31.7 in the buzzards). Arrhythmias were common in the pigeons starting around 50 minutes after induction. The part that hypothermia played in inducing arrhythmias could not be determined. The mean recovery time to standing was 10 to 12 minutes. A metabolic alkalosis occurred throughout the anesthetic episode that was attributed to the decrease in  $\text{paCO}_2$ .<sup>16</sup>

**TABLE 39.1** Mean Effects of Air Sac Anesthesia with Isoflurane<sup>16</sup>

	Pigeon	Buzzard
Temperature ( $^{\circ}\text{C}$ )	37.3 (41.5)	38.7 (41)
ApH	7.62 (7.36)	7.67 (7.51)
$\text{paO}_2$	426 mm Hg	360 mm Hg
$\text{paCO}_2$	19.2	19.1
Pulse rate	93.1 (172)	232 (301)
Blood pressure	64.6 mm Hg (106)	119.7 mm Hg
$\text{O}_2$ saturation (pulse oximeter)	98.1%	99%


Normal is listed in parenthesis. ApH = arterial pH,  $\text{paO}_2$  = partial pressure of oxygen,  $\text{paCO}_2$  = partial pressure of carbon dioxide.

## Management of the Anesthetic Patient

### ■ Patient Evaluation

Isoflurane can be used for two distinct purposes in the avian practice. One is for long-term general anesthesia needed to perform difficult diagnostic procedures and surgeries. The other is as an anesthetic to provide short-term restraint and to facilitate the ease of performing fluid administration, blood collection, radiography, endoscopy or bandage changes (Figure 39.10).

The goal of a preanesthetic evaluation is to detect and correct any underlying pathology prior to inducing anesthesia. In some cases, several days or weeks of supportive care may be needed in order to ade-



**FIG 39.10** Isoflurane is generally safe to use for short procedures (eg, radiography, endoscopy, blood collection) in patients with only a history and a physical examination. If a bird will be anesthetized for more than ten minutes, a complete database should be obtained to assess the stability of the patient.

quately stabilize a compromised patient before anesthesia can be safely administered. In other cases, eliminating abnormalities may not be possible, and consequently, adjustments must be made in inducing and monitoring anesthesia to ensure a successful outcome.

The minimum database is designed to help the anesthetist develop a list of risk factors associated with general anesthesia in a given patient and to develop evaluation methods or supportive care techniques that decrease the anesthetic risk. The patient evaluation associated with the use of isoflurane for short-duration procedures (five to ten minutes) is generally limited to a thorough history and physical examination. The theory in using isoflurane for short-term procedures with a limited database is that this drug has a wide therapeutic index and has consistently been shown to be relatively safe even in severely compromised patients.

If a bird is going to undergo anesthesia for more than ten minutes, then in addition to the history and physical examination, a minimum database ideally should include a fecal parasite check, Gram's stain of feces and choana, PCV, TP, WBC with differential, a platelet estimate, estimated clotting time, bile acids, AST, LDH and UA. Additional tests may be indicated depending on the initial assessment and the type of procedure requiring anesthesia.

### Risk Classification

Successful risk classification depends on conservative evaluation of the minimum database. Practically, risk assessment allows one to estimate the duration of safe anesthesia, the intensity of monitoring required and the supportive care and technical assistance needed to ensure patient safety. It also provides the clinician with a prognostic perspective to be discussed with the owner (see Table 39.2).

It can be successfully argued that few avian patients requiring anesthesia are Class I. Most patients are Class IV and V. With careful supportive care, a clinician can reduce the anesthetic risk factors of many Class IV and V patients to those of Class II or III patients.

A commonly encountered complication of anesthesia in birds is liver dysfunction. Hepatopathies may be suspected when performing the initial physical examination and confirmed with findings of lowered protein levels, elevated or depressed bile acids and tissue enzyme values, and radiographic findings of hepatomegaly, or conversely, a loss of liver mass. Liver dysfunction may reduce a patient's ability to metabolize anesthetic agents and may also be associated with coagulopathy. The use in these patients of any anesthetic drug that is dependent on the liver for metabolism is contraindicated (most injectables, halothane, methoxyflurane). Supportive care designed to improve liver function may be necessary before anesthesia. If anesthesia cannot be postponed to allow

**TABLE 39.2** Risk Classification of Potential Anesthesia Patients

<b>Class I</b> (minimal risk)	Young, healthy patient undergoing an elective procedure.
<b>Class II</b> (some risk)	Young, healthy patient undergoing a non-elective procedure, or a healthy patient undergoing an elective procedure.
<b>Class III</b> (risky)	Patient with an ongoing health problem undergoing a procedure for this or another problem.
<b>Class IV</b> (very risky)	Patient with a major health problem (unstable in nature) undergoing a procedure.
<b>Class V</b> (moribund)	Last ditch effort to save bird's life.

sufficient stabilization, then anesthetic agents that are minimally metabolized by the liver (eg, isoflurane) and vitamin K injections to help promote clotting are suggested.

Obesity is common in companion birds. Excess fat deposits interfere with the patient's ability to ventilate. Respiratory effort is further compromised when a bird is anesthetized and placed in abnormal body positions for surgery. With elective procedures, dietary changes and treatment for underlying metabolic disorders are indicated before general anesthesia is performed.

Surgery is frequently required for egg-related peritonitis, especially in small species (eg, cockatiels, lovebirds, budgerigars). These patients should be carefully stabilized prior to anesthesia. This stabilization process may take weeks and in some cases render surgical intervention unnecessary. An abdominal tap and diuretic therapy are indicated prior to anesthesia to reduce the volume of fluid in the abdomen and to improve the patient's ability to breathe.

These patients should be maintained in an upright position to prevent abdominal fluid and debris from entering the lungs through rents in the air sacs. The surgery table should be tilted so that the patient's head is slanted up.

In non-elective procedures on obese patients or those with an abdominal fluid accumulation, proper intubation is mandatory to ensure a patent airway. Gentle IPPV will help maintain adequate oxygenation. Keep in mind when providing IPPV that the avian lungs inflate minimally, and pressure placed on a breathing bag should be less than 15 mm H<sub>2</sub>O to prevent rupture of the air capillaries.

## ■ Preanesthetic Stabilization and Preparation

### Nutritional Therapy

For elective procedures, inadequate diets should be corrected three to four weeks before surgery. For specific nutritional requirements and nutritional support of surgical patients, see Chapters 3, 15 and 40.

### Fluid Therapy

Fluid therapy is an important aspect of supportive care that should be provided to avian patients. Many sick birds presented for evaluation have been off food and water for at least a day, often longer. With their high metabolic rate, birds rapidly become dehydrated. Correcting dehydration will dramatically im-

prove the patient's ability to physiologically cope with anesthesia.

It has been suggested that all birds suffering from trauma and disease can be assumed to be at least ten percent dehydrated, and that the following formula should be used to calculate their fluid requirements: normal body weight (grams) x 0.1 (10%) = fluid deficit in ml. The dose for maintenance fluid is estimated at 50 ml/kg/day.<sup>24</sup>

Calculated fluid requirements can be administered in severely dehydrated patients by an intravenous or intraosseous route (see Chapter 15) (Figure 39.11).<sup>17,30</sup> Fluids administered by oral or subcutaneous routes are not as effective in restoring or maintaining circulating volume.



**FIG 39.11** Placing an intraosseous cannula in the tibiotarsal bone is an excellent way to provide fluids to a patient during surgery. In comparison to catheters in peripheral vessels, intraosseous cannulas are much easier to maintain. Intraosseous cannulas placed in the tibiotarsus can also be used in critically ill patients for intermittent fluid, blood or drug administration.



Lactated Ringer's solution is the fluid of choice. This balanced electrolyte solution protects renal function better than sugar solutions.<sup>23</sup> Five percent dextrose is not a satisfactory replacement solution because the dextrose is metabolized, leaving free water.<sup>23</sup> Fluids administered to anesthetized birds should be heated (96°F) to prevent hypothermia.

Fluids must be carefully administered to birds to prevent volume overload. The maximum acute fluid load that can be tolerated by healthy patients is 90 ml/kg/hr.<sup>14</sup> In a cockatiel this would be a maximum of 9 mls in an hour or 0.15 mls per minute. Most avian patients, however, are unstable and cannot tolerate such a high rate and volume of fluid administration.

Electrolyte levels and acid-base balance should always be of concern in the anesthetic candidate. Some newer analyzers use small volumes (10 µl) of serum, providing clinicians access to actual values to use in assessing the status of their patients. If no means of determining the bicarbonate deficit is available and the patient is dehydrated or critically ill, the administration of 1 mEq/kg of bicarbonate at 15 to 30 minute intervals to a maximum of 4 mEq is suggested.<sup>24</sup>

### Fasting

Recommendations concerning fasting of birds prior to anesthesia have varied from no fasting to an overnight fast.<sup>12,13</sup> Practically speaking, the patient should be kept off food long enough for the upper gastrointestinal system to become empty. This process takes overnight in large birds and four to six hours in smaller birds. One should palpate the crop and postpone surgery if it is not empty. In an emergency, a patient with food in the crop should be held upright during the induction procedure, with a finger blocking the esophagus just below the mandible. Once the animal is anesthetized, the crop can be emptied by placing a finger covered with cotton or gauze over the choanal slit to prevent food entering the nasal cavity, turning the bird upside down and manually emptying the crop and esophagus. The esophagus can then be packed with gauze, and the head and neck positioned on an upward slant to minimize the chances of passive regurgitation. The trachea should be intubated using an appropriately sized tube.

### Patient Monitoring

The goal in any anesthetic episode is to maintain the lowest possible level of anesthesia to achieve necessary restraint. Anesthetic planes in birds are difficult

to observe from outward signs, and depth should be monitored by combining information obtained from heart rate monitored by either an ECG or doppler, respiratory rate and effort, toe pinch, palpebral and corneal reflexes and wing tone. The rates will vary depending on the species (Table 39.3). A doppler can be placed on either the cranial tibial or medial metatarsal arteries.

**TABLE 39.3 Heart Rates and Respiratory Rates in Birds Anesthetized with Isoflurane**

	Beats Per Minute	Breaths per Minute
Budgerigar	600-750	55-75
Cockatiel	450-604	30-40
Pigeon	93.1±5.4 <sup>16</sup>	15-25
Parrot	120-780	10-20
Ostriches <sup>4</sup>	60-72	2-20

Anatomic locations to evaluate the reflex response to pain or touch in avian patients include palpebra, cornea, cloaca, proptagium, cere, interphalangeal area, pupils (response to light) and pectoral muscles.<sup>16</sup>

In a light plane of anesthesia, the patient has a palpebral, corneal and pedal reflex but has lost voluntary motion. The ideal anesthetic level, as described in one study,<sup>16</sup> was when the bird's eyelids were completely closed and mydriatic, the pupillary light reflex (pupillary response to light) was delayed and the nictitating membrane moved slowly over the entire cornea. The muscles were relaxed and all pain reflexes were absent. The loss of a corneal reflex (no reflex closure of the lid after touching the peripheral cornea with a dry swab) was considered to indicate deep anesthesia.<sup>16</sup>

The respiratory rate should be slow and deep. If a patient becomes too deep, all reflexes will be lost and the respiratory rate will be slow and irregular. Wing flutter is often an early indicator that an animal is

### CLINICAL APPLICATIONS

Anesthetic planes may be monitored by:

- Rate and depth of respiration
- ECG
- Heart rate — doppler
- Toe pinch
- Palpebral reflex
- Temperature
- Wing flutter
- Lid closure
- Pupillary dilation
- Pupillary reflex
- Corneal reflex


becoming light. An excellent plane of anesthesia for most procedures can be accomplished by reaching a depth of anesthesia where wing tone has just disappeared. If injectable agents have been used, the traditional planes of anesthesia may not be present, making evaluation of the patient more challenging.

### Body Temperature

Physiologically, birds are actually less efficient homotherms than mammals and as a result undergo more rapid changes in body temperature during anesthesia. Loss of heat during surgical anesthesia is a very important factor in anesthetic survival and in the rate of return to a physiologic normal state following anesthesia. Besides a loss of physiologic responses to reduced core temperature, hypothermia is also induced during surgery by removal of large areas of feathers to expose surgical sites, by the constant flow of cool anesthetic gases through the respiratory tract, by the liberal use of alcohol, by body contact with a cold conductive surface and by the length of the procedure. Even with supplemental heat, it is not unusual to have rapid reductions in core temperature during anesthesia. Any degree of hypothermia compromises the patient's ability to recover from anesthesia. While supplemental heat will not prevent the drop in core temperature seen with anesthesia, it does tend to reduce the speed of heat loss.

All patients undergoing long surgical procedures should be placed on water circulating heating pads. Keep in mind that these devices need at least a 20-minute warmup period before they reach the preset temperature. The clinician may choose to minimize the amount of alcohol used in the surgical scrub and instead use chlorhexidine or povidone iodine to minimize heat loss through evaporation. Body temperature loss may also be minimized through the use of heat lamps, heated lavage solutions, heated IV fluids or hot towels wrapped around non-rebreathing tubes. Hypothermia occurs in birds despite their being placed on water circulating pads.

Body temperature (normal=105 to 107°F<sup>28</sup>) can be constantly monitored during anesthesia to properly evaluate the degree of heat loss. A patient under anesthesia will experience a time-related reduction in body temperature (maybe as much as 10°F), which can predispose to cardiac arrhythmias and increased recovery times. If severe hypothermia (loss of greater than 10°F) occurs, the patient may not recover at all. Traditional thermometers can be used to record this data, but they require cloacal insertion and take



**FIG 39.12** A doppler probe placed on the medial metatarsal artery can be used to monitor the heart rate during anesthesia.

three to five minutes to give an accurate reading. Electronic thermometers also require cloacal insertion and take two to three minutes to give a reading. A more practical option is a tympanic scanner,<sup>d</sup> which gives a reading in five to six seconds. The monitors are easy to use by applying the probe to the outer surface of the ear. Tympanic temperatures are consistently slightly higher than cloacal temperatures.<sup>21</sup>

### Heart Monitoring

Heart rate in avian patients can be monitored in several ways. Palpation at the point of maximum intensity is possible in some patients (see Table 39.3). Peripheral pulses can be used but are often difficult to detect in smaller patients. Auscultation via a stethoscope is possible, although the chest may be difficult to reach once the patient is draped for surgery. Esophageal stethoscopes equipped with pediatric tubing can be used for auscultation of the heart in avian patients the size of Amazon parrots and larger. This monitoring system allows direct auscultation of the heart without having to go near the surgical field. If correctly positioned, the esophageal stethoscope can also be used for monitoring respiration. Dopplers can be used, but are extremely positional in nature and difficult to maintain in birds (Figure 39.12). Some oximetry units provide pulse rates up to 250 bpm; these units are easy to use and are not positional like the doppler. In a group of cockatiels maintained in a surgical plane of anesthesia, the heart rate remained above 450 bpm.<sup>12</sup> In one study with pigeons and common buzzards, the pulse rates determined by the oximeter were consistent with those determined through a direct arterial line.<sup>16</sup> In an emergency situation, a heart rate can be quickly obtained by placing the doppler probe on the globe of the eye. An ECG is an excellent way to monitor the depth of avian anesthesia. As a bird gets deeper, the

T-waves become smaller and may totally disappear. As the depth further increases, the R-wave will increase in magnitude and the S-wave is reduced.

### Respiratory Rate

Respiratory rates during anesthesia should be slow and regular (see Table 39.3). Hyperventilation or rapid jerky motions are indications of ensuing problems. An increase in the respiratory rate may indicate that a bird is entering a lighter plane of anesthesia, that the bird is having difficulty breathing (occluded tracheal tube) or that the bird has an elevated  $\text{paCO}_2$ . Because surgical patients are draped, it is often difficult to observe respiratory effort. Direct visualization of chest movement as an indication of respiration can be facilitated by using clear sterile surgical drapes.<sup>9</sup> An anesthetic bag<sup>c</sup> designed to deal with the lower tidal volumes of birds will also make it easier to monitor respiration.

When using halothane or methoxyflurane, apnea and cardiac arrest may develop at the same time without prior warning. With isoflurane, apnea usually proceeds cardiac arrest by several minutes. Halothane typically induces a rapid decrease in heart rate that returns to normal shortly after ceasing gas administration.

Apnea monitors do work in birds; however, less expensive units may not be sensitive enough to detect the respirations of smaller patients. The monitoring device that attaches to the endotracheal tube is heavy, and precautions must be taken to keep the weight of the monitor from kinking small diameter tubes. These units also require that the patient be intubated. A unit intended for use in birds should be evaluated on avian patients prior to purchase.

### Blood Pressure

Blood pressure can be monitored directly or indirectly and should remain above 100 mm Hg. Except in a research situation, it is unlikely that most practitioners are going to opt for direct blood pressure monitoring due to the cost and invasiveness of the procedure. Although indirect monitors that use pediatric cuffs are available and offer some promise for use in avian patients, they are less reliable for

smaller patients. Appropriate responses to patients with decreased blood pressure values include reduction of anesthetic levels, administration of IV fluids, correction of hypothermia and evaluation and correction of blood loss.

### Blood Gases

Arterial blood gases can be assessed directly by running arterial samples on a blood gas machine. This is not practical for most practitioners and it may involve taking multiple blood samples, a procedure that smaller patients cannot tolerate. Indirect assessment of blood oxygenation can be done via an oximeter. An oximeter records the percentage of circulating oxygenated blood via a noninvasive probe.<sup>10</sup> The unit works by spectrometrically measuring the difference in absorbance between reduced hemoglobin and oxyhemoglobin. Oximeters are not as sensitive at direct determination of arterial blood gases, and oximeter readings at 98% saturation are common in birds that are actually 100% saturated.<sup>16</sup> The author has found that the oximeter probe can be attached to the wing web, toe, tongue or the area over the tibiotarsal bone. The tibiotarsal area seems to give the most consistent and reliable readings. The probe is small and requires only one wire so it is easily used during surgery. Additionally, many oximeters are actually pulse oximeters that produce an audible beep, allowing the anesthetist to monitor heart rate as well as oxygen saturation levels. Ideally, oxygen saturation levels should be above 90%. A reading below 80% should be considered life-threatening. Most birds will maintain an oxygen saturation between 80 to 85% when self-ventilating. Use of IPPV to increase oxygen saturation is, therefore, valuable. Normal blood gas values of  $\text{paCO}_2=19$ ,  $\text{paO}_2=400$  and  $\text{ApH}=7.4$  have been reported.<sup>20</sup>

## Anesthetic Emergencies

With careful assessment of patients, conscientious supportive care and thorough monitoring, many anesthetic-related emergencies can be prevented.

### Respiratory Arrest

If respiratory arrest occurs, the anesthetic system should be disconnected from the bird and the chest should be lightly pressed and released to induce air intake, or fresh air can be gently delivered into the tracheal tube. If the patient is not intubated, an air sac tube should be placed or the animal should be immediately intubated. The practitioner must keep mind that air sac intubation may result in apnea while the  $\text{paO}_2$  is increasing and the  $\text{paCO}_2$  is decreasing.

## CLINICAL APPLICATIONS

### Emergency Steps for Respiratory Arrest

- Disconnect bird from anesthetic
- Press on sternum 40 to 50 cycles/min
- Intubate or apply air sac tube
- IPPV through tube

If respiratory arrest occurs in response to injectable anesthetics, the reversal agent should be administered intravenously. The administration of doxapram HCl on the tongue may help stimulate respiration. The pulse rate should be carefully monitored and resuscitation should continue until the bird is breathing unassisted. Birds that show respiratory arrest should be rescheduled for the procedure; a second or third episode of apnea in these cases is often followed by cardiac arrest.

### Cardiac Arrest

Cardiac arrest represents a poor prognosis. Resuscitation efforts are often unsuccessful. If success is to be achieved and cardiac arrest truly does exist, the clinician should be aggressive and utilize open heart massage. The rate should be 60 or more compressions per minute and they should be accompanied by coordinated artificial ventilation. These efforts should be continued for up to five minutes. Although rare, some birds may recover following cardiac arrest.

### Hemorrhage

If hemorrhage occurs during surgery, a significant portion of that loss can be replaced via fluid therapy using isotonic solutions. If hemorrhage is severe, a transfusion will be necessary (see Chapter 15).

### Postanesthetic Monitoring and Recovery

Anesthetic recovery should occur in a pre-heated environment, preferably a pediatric or avian incubator. The

safest approach to post-anesthetic monitoring of a patient is to leave all of the monitoring devices in place until the patient absolutely will not tolerate them. Patients should be recovered where they can be easily observed. Birds should not be left unattended until they are perching without difficulty.

Recovery from injectable anesthetics will be much more prolonged and if ketamine has been used, potentially traumatic. Anesthetic recovery is best accomplished by wrapping the bird in a towel to prevent wing-flapping and self-inflicted trauma. The lights should be dimmed and the noise level kept to a minimum to prevent violent reactions. The patient should be rolled over every few minutes, and the pharynx should be monitored for the accumulation of mucus or vomit. In severely depressed birds, IPPV can be continued until the patient is no longer willing to tolerate the tracheal tube. Recovery from even long anesthetic episodes with isoflurane generally requires less than five minutes. The administration of a reversal agent is indicated when appropriate.

#### Products Mentioned in the Text

- a. AErrane, Anaquest, Madison, WI
- b. IsoFlo, Solvay Animal Health, Mendota Heights, MN
- c. Avithesia, Exotic Animal Medical Products, Watkinsville, GA
- d. Tympanic Scanner, Exergin Corp, Newnan, MA
- e. Steri-drapes, 3M, St. Paul, MN

### References and Suggested Reading

1. Aguilar R, et al: Electrocardiographic changes in bald eagles (*Haliaeetus leuccephalus*) subjected to isoflurane anesthesia. Proc 8th Annual Vet Midwest Anes Conf, 1992.
2. Allen JL, Oosterhuis JE: Effect of tola-zoline on xylazine/ketamine-induced anesthesia in turkey vultures. J Am Vet Med Assoc 189(9):1011-1016, 1986.
3. Bendnarski RM, et al: Isoflurane-nitrous oxide-oxygen anesthesia in an Andean condor. J Am Vet Med Assoc 187(11):1209-1210, 1985.
4. Bruning DF, Dolensek EP: Ratite (Struthioniformes, Casuariiformes, Rheiformes, Tinamiformes and Apterygiformes). In Fowler ME (ed): Zoo and Wild Animal Medicine 2nd ed. Philadelphia, WB Saunders Co, 1986, pp 277-291.
5. Degernes LA, et al: Ketamine/xylazine anesthesia in red-tailed hawks with antagonism by yohimbine. J Wildl Dis 24(2): 322-326, 1988.
6. Fedde MR: Avian respiratory physiology. Proc 8th Annual Vet Midwest Anes Conf, 1992.
7. Fitzgerald G, Cooper JE: Preliminary studies on the use of propofol in the domestic pigeon (*Columba livia*). Res Vet Sci 49(3):334-338, 1990.
8. Flammer K: Update on avian anesthesia. In Kirk RW (ed): Current Ther-  
apy X. Philadelphia, WB Saunders Co, 1989, pp 776-780.
9. Goelz MF, et al: Effects of halothane and isoflurane on mean arterial blood pressure, heart rate and respiratory rate in adult Pekin ducks. Am J Vet Res 51(3):458-460, 1990.
10. Green SA: Monitoring oxygenation and ventilation in practice-pulse oximetry and capnography. Proc ACVCS Vet Symp, 1991, pp 559-561.
11. Greenless KJ, et al: Effect of halothane, isoflurane and pentobarbital anesthesia on myocardial irritability in chickens. Am J Vet Res 51(5):757-758, 1990.
12. Harrison GJ: Evaluation and support of the surgical patient; Anesthesiology. In Harrison GJ, Harrison LR (eds): Clinical Avian Medicine and Surgery. Philadelphia, WB Saunders Co, 1986, pp 543-559.
13. Harrison GJ: Pre-anesthetic fasting recommended. J Assoc Avian Vet 5(3):126, 1991.
14. Hubbell JAE: The case against routine fluid administration. Vet Clin No Amer Sm Anim Anes, 1992, pp 448-450.
15. Jacobson ER, et al: Ventriculostomy for removal of multiple foreign bodies in an ostrich. J Am Vet Med Assoc 189(9):1117-1119, 1986.
16. Korbel R, et al: Aerosacral perfusion with isoflurane - an anesthetic procedure for head surgery in birds. Proc Europ Assoc Avian Vet, 1993, pp 9-37.
17. Lamberski N, Daniel G: Fluid dynamics of introsseous fluid administration in birds. J Zoo Wildl Med 23:47-54, 1991.
18. Ludders JW, et al: Minimal anesthetic concentration and cardiopulmonary dose response of isoflurane in ducks. Vet Surg 19(4):304-307, 1990.
19. Ludders JW, et al: Isoflurane anesthesia in sandhill cranes (*Grus canadensis*): Minimal anesthetic concentration and cardiopulmonary dose-response during spontaneous and controlled breathing. Anesth Analg 68(4):511-516, 1989.
20. Mandstager RE, Raffae MR: Chemical restraint techniques in dogs and cats. In Kirk RW (ed): Current Veterinary Therapy X, Philadelphia, WB Saunders Co, 1989, pp 63-70.
21. Paster M: Use of tympanic temperature scanner. J Assoc Avian Vet 4(3):154, 1990.
22. Petrak M (ed): Diseases of Cage and Aviary Birds. Philadelphia, Lea & Febiger, 1982, p 401.
23. Raffae MR: The case for routine fluid administration. Vet Clin No Amer Sm Anim Anes 22(2):447-448, 1992.
24. Redig PT: Fluid therapy and acid base balance in the critically ill avian patient. Proc Intl Conf Avian Med, 1984, pp 59-73.
25. Rode JA, et al: Ventilation through an air sac cannula during tracheal obstruction in ducks. J Assoc Avian Vet 4(2):98-102, 1990.
26. Rosskopf WJ, Woerpel RW: Abdominal air sac breathing tube placement in psittacine birds and raptors: Its use as an emergency airway in cases of tracheal obstruction. Proc Assoc Avian Vet, 1990, pp 215-217.
27. Seaman G, et al: Effects of inspired oxygen on ventilation in birds anesthetized with isoflurane. Proc 8th Annual Midwest Anes Conf, 1992.
28. Sedgwick CJ: Anesthesia of caged birds. In Kirk RW (ed): Current Veterinary Therapy VII, Philadelphia, WB Saunders Co, 1980, pp 653-656.
29. Smith J, Muir WW: Cardiopulmonary effects of midazolam and flumazenil in racing pigeons. Proc 8th Annual Midwest Anes Conf, 1992.
30. Ritchie BW, et al: A technique of introsseous cannulation for intravenous therapy in birds. Comp Cont Ed 12:55-58, 1990.

**M**any avian patients are small and delicate, increasing the risks associated with surgery. Seemingly minor hemorrhage can be life-threatening in patients with such a small blood volume. Their high metabolic rate, small body size, and high ratio of body surface area to body volume predispose them to intraoperative hypoglycemia and hypothermia, the risks of which increase as the duration of anesthesia and surgery increases. These factors make it crucial that the avian surgeon not only have the procedure well thought out, but also have any necessary equipment ready and accessible. Exactness, precision, advanced preparation and minimal anesthesia time are the keys to success in avian surgery.

Avian blood vessels are relatively thin-walled, tend to course in a more superficial manner and are less protected by surrounding tissues than in mammals. Because there is less perivascular tissue in birds, vessels are prone to move within the tissues and retract from the surgeon's view. Even after radiocoagulation, vessels may relax and begin to leak blood after they retract into the tissues. The avian surgeon must frequently re-evaluate vessels for recurrence of hemorrhage and should be meticulous with hemostasis to prevent surgically induced hypovolemia. With the aid of magnification, small blood vessels can be identified, isolated and coagulated, minimizing the risk of recurrent hemorrhage.

Surgery is frequently a life-prolonging procedure when applied correctly to a properly conditioned avian patient; however, birds with severe nutritional and metabolic abnormalities do not have the capacity for long-term recovery from many anesthetic and surgical episodes. The most common cause of problems associated with elective surgeries is inadequate presurgical evaluation of the patient, which prevents proper post-surgical recovery. Although some surgical procedures must be performed on an emergency basis without the benefit of a complete medical evaluation and preconditioning, in many situations there is adequate time to accumulate clinical data. In some cases, surgery should be delayed in the patient's best interest.

---

CHAPTER

---

# 40

## SURGICAL CONSIDERATIONS

---

■  
R. Avery Bennett

## Patient Evaluation

When possible, a clinical database acquired prior to surgery should include a complete history, physical examination and laboratory data. A minimum database for any preoperative evaluation should include hematocrit, total serum solids and WBC. If possible, a complete blood chemistry profile, whole body radiographs, electrocardiogram and cultures, if indicated, should be obtained. A blood glucose is useful in Anseriformes and raptors.

Patients with blood glucose of <200 mg/dl should receive 5% dextrose IV intraoperatively. Patients with total serum solids of <2 mg/dl are usually severely debilitated and are poor candidates for surgical recovery. A hematocrit >60% is indicative of dehydration, and fluid therapy should be instituted. If the hematocrit is <20%, surgery should be delayed or a whole blood transfusion should be administered. Blood transfusions are best made from donors of the same species; however, heterologous transfusions appear to be safe and efficacious.<sup>7,26</sup> A serum uric acid of >30 mg/dl indicates dehydration (prerenal) or renal disease. Surgery should always be postponed until a patient is adequately hydrated. The hematocrit and total serum solids can be used to determine whether primary renal disease is a factor.

Serum cholesterol, AST and LDH activities may be helpful in evaluating the preoperative condition of a patient. Of 54 birds used to evaluate various anesthetic agents, three deaths occurred, two of which had preanesthetic serum parameters: AST=>650 IU/l, LDH=>600 IU/L and cholesterol=>700 mg/dl. Many of the birds that survived had high AST and LDH activities but not in combination with a high serum cholesterol level.<sup>17</sup>

Respiratory recovery time is determined by the time it takes a bird to return to a prestressed respiratory rate following two minutes of handling. A return to normal respiratory rate within three to five minutes indicates respiratory stability adequate for most anesthetic and surgical procedures. Periods longer than five minutes indicate severe respiratory compromise.

The bird's nitrogen balance should be addressed, especially in birds that have been anorectic for several

days. In a properly hydrated bird, an increase in body weight is a good indicator of a positive nitrogen balance.

Birds have relatively little glycogen stored in the liver. A decrease in blood glucose and insulin combined with an increase in glucagon stimulate hepatic glycogenolysis. Liver glycogen stores may decrease as much as 90% during a 24- to 36-hour fast and potentially quicker in smaller birds.<sup>21</sup> Vomiting and regurgitation may occur if the patient is not fasted, and can result in aspiration pneumonia (see Chapter 39). A short fast of five to eight hours will help decrease the probability of aspiration pneumonia and will have minimal effects on blood glucose.<sup>20</sup> In emergency situations when the digestive tract is full, it should be partially emptied before the bird is placed in dorsal recumbency (see Chapter 39).

When significant hemorrhage is anticipated, intraoperative IV fluid therapy should be provided. A patient may be suspected to have a clotting disorder if perifollicular bleeding occurs during surgical preparation. When a mature feather is removed, there should be virtually no hemorrhage around the follicle.

### Nutritional Support

Little is known about the nutritional requirements of the various species of companion and aviary birds. Even less is known about how stress, such as surgery, increases the nutritional and caloric requirements of avian patients. In contrast to starvation, stress may cause an initial hypometabolic state followed by hypermetabolism,<sup>32</sup> which increases the body's need for protein. Protein is necessary for tissue repair, antibody production and blood cell production, all of which are necessary for postsurgical recovery. Carbohydrates (not fats) are nitrogen-sparing energy sources that best correct a stress-related negative nitrogen balance.<sup>32</sup> The postoperative surgical patient must have a positive nitrogen balance to facilitate tissue repair, and a source of nonprotein energy to meet increased caloric requirements.

The basal metabolic rate (BMR) of inactive animals may be determined using the formula  $BMR \text{ kcal/kg/24 hr} = K(BW_{\text{kg}})^{0.75}$  (see Chapter 15). Additional energy is required for growth, reproduction, disease and tissue repair and is defined as productive energy (the amount of energy a bird mobilizes above the requirements for existence).<sup>41</sup> Stresses such as severe trauma, head injury and sepsis increase the patient's energy requirements 1.5 to 3.0 times the minimum energy requirement.<sup>13,32</sup> Birds have a higher

requirement for protein,<sup>13,32</sup> and their amino acid requirements are different from those of mammals.

Liquid diets that can be used to provide assisted alimentation to pre- or postsurgical patients are commercially available.<sup>13,14,32</sup> Hyperosmolar diets should be diluted (1:1) with water. Only 25% of the calculated requirements should be provided initially in order to prevent diarrhea. Over a period of two to three days, the concentration and volume of formula are gradually increased as the intestines adapt to the hyperosmolar solution.<sup>40</sup>

The patient's water requirements must also be met. When using hyperosmolar diets, water may be pulled into the intestine, which contributes to dehydration. Water requirements vary with species, diet, size, age and environmental temperature (see Chapter 15).<sup>32</sup>

## ■ Patient Preparation

### Feather Control

In preparing the skin for surgery, feathers surrounding the proposed surgical site should be gently plucked for a distance of two to three centimeters. The contour and covert feathers of the body grow in pterygiae or tracts, which are separated by featherless areas (apteria). These feathers may be easily and safely removed individually if plucked in the same direction as their growth. The large flight feathers (remiges and retrices) are attached to the periosteum of the underlying bone and have highly developed feather muscles and ligaments. Removing these feathers is painful and is best accomplished while the patient is anesthetized. When flight feathers must be removed, they should be removed individually by holding the feather at its base and pulling in the direction of feather growth. To avoid injury to the skin, muscles and periosteal attachments, the other hand is used to carefully secure the tissues at the base of the feather while it is being removed (see Figure 15.12).<sup>28</sup>

Small feathers should be pulled in groups of three or four in a direction opposite their growth.<sup>1,18,28</sup> If the skin has been damaged or torn, the feathers in this area can be cut to avoid further damage to the skin.<sup>10</sup> Cut feathers are replaced only during the normal molt cycle.

Excess feather removal will reduce a bird's insulating ability, increase metabolic demand during the recovery period (energy used to regrow the feathers)<sup>28</sup> and, if primary or secondary feathers are removed, the

bird will not be able to fly until they regrow. The removal of primary and secondary feathers should be avoided because it is easy to damage the follicle, resulting in the growth of malformed replacement feathers. Flight feathers are molted one at a time and require the structural support of the adjacent feathers for proper growth. Because the skin of birds is very fragile and tears easily, removal of feathers is a delicate procedure, and attempting to remove too many feathers too quickly may result in bruising and tearing of the skin. Feathers in adjacent pterygiae can be retracted using a stockinette, masking tape or water-soluble gel.<sup>1,18,28</sup> Water-soluble gels will prevent clear plastic drapes from properly adhering to the skin and should not be used in this situation.

### Creating a Sterile Field

Standard aseptic technique<sup>30,39</sup> must be adhered to when performing surgery on avian patients. Poor technique may have devastating consequences. Skin preparation solutions are used to decrease the number of bacteria present on the skin surface to minimize the risk of bacterial contamination of the surgery site. They should accomplish this objective without damaging the skin and predisposing the patient to dermatitis.<sup>27</sup>

Concentrations of chlorhexidine diacetate (0.05%)<sup>a</sup> and povidone iodine (1.0%)<sup>b</sup> are effective for skin preparation. Although studies have shown these concentrations to be cytotoxic *in vitro*, they do not have a significant clinical effect on wound healing. Chlorhexidine gluconate (4%)<sup>c</sup> is equally effective when rinsed with saline or alcohol. A saline rinse has been found to leave sufficient residual chlorhexidine gluconate bound to the skin to be effective. This is beneficial in avian patients where the use of alcohol predisposes to hypothermia. When povidone iodine (1%) was used as a skin preparation, approximately

## CLINICAL APPLICATIONS


Clinical pathology parameters for which postponement of surgery may be necessary include:

- PCV: <20% - delay surgery or provide blood transfusion  
>60% = dehydration; give fluid therapy
- Total solids: <2 mg/dl = severe debilitation
- Blood glucose (raptors, Anseriformes): <200 mg/dl - give 2.5-5% dextrose
- Uric acid: >30 mg/dl = dehydration (prerenal) or renal disease
- AST: >650 IU/dl
- LDH: >600 IU/dl
- Cholesterol: >700 mg/dl

50% of the treated dogs developed erythema, edema, papules, wheals and “weeping” of serum from the skin surface.<sup>27</sup> Chlorhexidine is generally preferred over povidone iodine solution as a patient preparation<sup>27</sup> because it has a broader spectrum of antimicrobial activity, longer residual antimicrobial activity, is efficacious in the presence of blood and organic matter and is nontoxic and hypoallergenic. However, in clinical settings, the type of scrub solution used has not been found to affect the rate of wound infections.<sup>34</sup>

It is challenging to create a sterile field of the wing because of the large flight feathers, which should not be removed unless absolutely necessary. The primary and secondary flight feathers can be wrapped together with masking tape. The surgeon can then cover the entire wing with a sterile stockinette or self-adherent bandage material<sup>d</sup> creating a sterile field (Figure 40.1).<sup>28</sup>

Patient drapes are currently available in a variety of sizes, shapes and materials. With avian patients clear drapes are recommended, as they allow the surgeon and anesthetist to visually monitor the patient during the procedure. Clear plastic drapes are commercially available<sup>e</sup> with or without povidone iodine impregnation. These drapes have an adhesive that will stick to dry avian skin and create a sterile field, but must be removed with care to prevent damaging the tissue. These drapes conform closely to the patient's body, are lightweight, disposable and inexpensive, and allow the anesthetist to monitor respiratory movements. As an alternative, a clear



**FIG 40.1** Feather removal in preparation for surgery should be sufficient to allow the establishment of a sterile field but not so severe that the bird is predisposed to hypothermia. In this case, the feathers from the mid-diaphysial humerus to the carpus were removed to prepare the bird for the placement of an external fixator to repair a fractured ulna. The primary feathers were clipped and wrapped in a self-adherent bandage material to facilitate the creation of a sterile field without removal of the primary feathers.

plastic drape can be made from plastic kitchen wrap. The border of the plastic should be edged with masking tape, making it easy to find the edges and open the drape. These drapes can be folded with a sheet of plastic but must be gas sterilized and are not adhesive.

In most cases, the plastic drape is small and does not allow the surgeon to create a sterile field incorporating the entire surgery table and instrument stand. In order create such a field, the clear plastic drape is placed over the patient and a large drape sheet with a central fenestration large enough to allow the draped patient to be exposed, is placed over the entire field. This will prevent accidental contamination of the arms and elbows by touching them to an undraped table.

Perioperative antibiotic therapy involves the use of antibiotics such that there are therapeutic tissue levels of the agent present at the time of exposure to bacteria. With most antibiotics, parenteral administration one to two hours preoperatively, and maintaining therapeutic doses for 8 to 16 hours postoperatively, will accomplish this goal. Unless there is infection or significant contamination, use of antibiotics beyond this period is not indicated and has been shown not to decrease the incidence of surgical wound infections.

## Wound Healing

Wound healing has been thoroughly studied in mammals, and five phases have been described: the inflammatory stage, the fibroblastic phase, the epithelialization phase, the contraction phase and the remodeling phase.<sup>29,31</sup> The cellular and vascular events of the inflammatory phase have been studied in chickens.<sup>2,8,10,24,25</sup> The inflammatory response in birds is similar to that classically described in mammals with early vasoconstriction to initiate hemostasis, followed by vasodilation within 30 minutes.<sup>25,31</sup> Bradykinin, histamine, 5-hydroxytryptamine and other chemical mediators initiate the acute inflammatory phase of wound healing in birds.<sup>2</sup> During the first two to six hours, large numbers of heterophils, basophils and monocytes migrate into the wound margins.<sup>8,25</sup> Phagocytosis of cellular debris and bacteria begins during this phase. After 12 hours there is a shift in the cellular response from one of primarily polymorphonuclear leukocytes initially to one of primarily mononuclear cells such as lymphocytes, plasma cells, macrophages and monocytes.<sup>25</sup> During the next 36 hours, macrophages and multinucleated giant cells begin to phagocytize those leukocytes that



have been involved in the early phagocytosis of tissue debris and bacteria. Fibroblasts begin to appear at the wound margins and proliferate over the next few days.

As soon as necrotic tissue, blood clots and other debris are removed by phagocytic cells, fibroblasts move into the damaged tissue. In the inflammatory phase, the exudate contains fibrinogen, which is converted to fibrin by the release of tissue enzymes. This acts as a hemostatic barrier and a scaffolding for other repair elements such as the incoming fibroblasts. New capillaries enter immediately behind the migrating fibroblasts. They contain plasminogen activator that is necessary for the breakdown of the fibrin. Collagen is synthesized during this fibroblastic phase beginning on the third or fourth day in birds<sup>8</sup> and on the fourth or fifth day in mammals.<sup>31</sup> The collagen bundles are initially small, but gradually enlarge to form dense collagen networks that bind the edges of the wound together. The fibroblastic phase of healing lasts two to four weeks. As the content of collagen increases, the number of fibroblasts decreases, and the capillaries begin to regress. Eventually, the rate of collagen production roughly equals the rate of collagen destruction.<sup>31</sup>

The epithelialization phase is characterized by the migration of epithelial cells from the wound margin. The epidermal basal cells are normally adhered to each other. These adhesions break down, allowing the cells to be mobilized. The cells enlarge and migrate down and across the wound. These cells do not begin to proliferate until the entire wound surface has been covered by a single layer of epithelial cells. Eventually, the normal epithelial thickness is restored.

The contraction phase is described as “the process by which the size of a full-thickness open wound is diminished and is characterized by the centripetal movement of the whole thickness of surrounding skin.”<sup>29</sup> Several mechanisms have been theorized to be responsible for this action.<sup>31</sup>

The remodeling phase is described in terms of early wound strength and late wound strength.<sup>31</sup> There is no appreciable gain in wound strength during the first four to six days of healing. However, the fibrin clot, epithelialization and ingrowth of new capillaries occur early and provide some support to the wound. After the early fibroblastic phase, wound strength increases to an early maximum at 14 to 16 days, paralleling the rise in collagen content of the

wound.<sup>31</sup> Late wound strength occurs as a result of collagen maturation. The collagen content stabilizes after the third week. Wound strength may continue to increase for a period of years following the stabilization of the collagen content resulting from the intramolecular and intermolecular cross linking of collagen fibers.

Freshly created (within eight hours), uncomplicated wounds should be treated by primary closure with anticipated first intention healing;<sup>5</sup> however, this is not appropriate for the treatment of open, contaminated wounds.

## Instrumentation

Instuments for avian surgery should be appropriate to the patient's size. In many cases, ophthalmic instruments are suitable and should be included in the standard avian surgery pack. Iris scissors (curved and straight), forceps with fine teeth, micro Halstead mosquito forceps, jeweler's forceps (curved and straight), iris hooks, eyelid retractors for abdominal retractors, retinal forceps, adventitia scissors, spring handled scissors and Castroviejo needle holders are particularly useful (Figure 40.2). Because avian tissues are delicate, the use of toothed forceps is seldom appropriate. Debaquey-type forceps are relatively atraumatic and serve well in avian surgery. Penrose drains or other sterile rubber materials may be used to wrap around structures for elevation or retraction, and eyelid retractors work well as wound retractors (Figure 40.3). A sterile gavage or feeding tube can be used for irrigation or for flushing out hollow viscera (such as the proventriculus during proventriculotomy). Various sizes of bone curettes are useful to retrieve foreign bodies from the ventriculus or proventriculus. A tuberculin syringe with an attached 25 ga needle can be fashioned into a tissue hook by bending the tip of the needle 45 to 90° under the operating microscope.

A mini-Frazier suction tip is well suited for avian surgery because of its small, delicate size. This type of suction tip also has a small hole at the finger rest, which the surgeon may use to adjust the amount of suction created at the tip. Red rubber urinary catheters and infant feeding tubes are available in varying sizes and may be cut off and adapted for use as a




FIG 40.2 Ophthalmic instrumentation is best suited for use in birds.

suction tip. Care must be taken with this type of tip and a powerful suction unit in order not to damage viscera inadvertently suctioned against the tip. The strength of suction can be controlled on most suction units and should be adjusted so that fluids can be evacuated without damaging tissues. A Poole-type suction tip can be fashioned from a catheter by cutting multiple fenestrations along the terminal two to three centimeters of the catheter. By having many fenestrations, the suction force is distributed among the inlets, decreasing the force at any one hole. Additionally, if some of the holes are occluded by tissue, the remaining inlets continue to evacuate the celomic cavity.

A one- to three-millimeter rigid endoscope is helpful for visualizing areas that the surgeon may not be able to access with the operating microscope (eg, lumen of hollow viscera). Abdominal retractors appropriate for small avian patients should maintain retraction but not have blades that extend deep into the body cavity. Mini-Balfour retractors are useful in large patients such as macaws and cockatoos, Alm retractors are appropriate for medium-sized patients like Amazons and conures, and Heiss retractors work well in small avian patients including cockatiels and budgerigars.

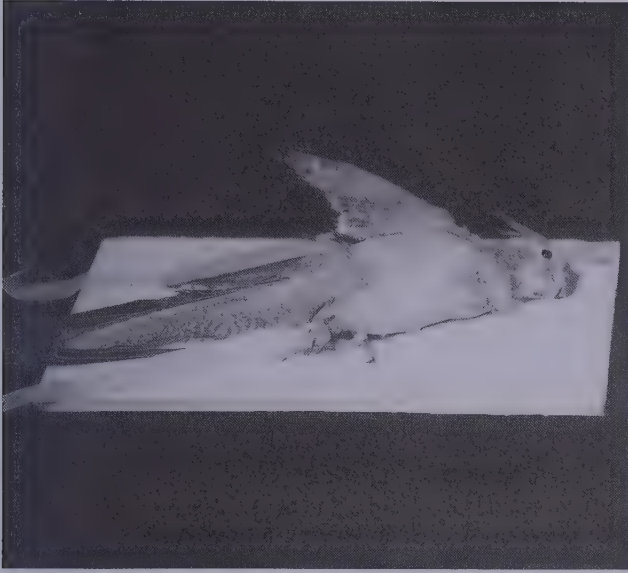In many situations, the placement of ligatures in deep surgical sites is unachievable or results in unacceptable tissue damage due to the relative inaccessibility and delicate nature of avian tissues. Hemostatic clips<sup>h,i</sup> are best for controlling bleeding in these



FIG 40.3 Various types of lid retractors are ideal for use in maintaining access to the abdomen of birds. In this photograph, a lid retractor is being used to maintain an opening in the left abdominal wall. The seventh rib (r) has been isolated and cut ventrally to facilitate its removal for better access to the proventriculus. Several rents can be seen in the relatively clear caudal abdominal air sac (arrow) just to the left of the rib. The proventriculus (p) and ventriculus (v) can be seen deep to the surgical site.

cases. Multiple-sized clips should be available to address varied-sized patients and different surgical needs. The major expense is encountered in purchasing the applier, as the clips themselves are relatively inexpensive. The appliers are available either straight or with a 45° bend. The bent-tipped applier is useful for deep clip placement; however, the bent-tipped instruments are about twice the size of the equivalent straight-tipped applier, making them more cumbersome to use. Generally, the small and medium clips are used most frequently.

Number 15 and No. 11 scalpel blades are most appropriate for avian surgery. Small gauze pads (2 x 2) and sterile cotton-tipped applicators should also be available (see Figure 40.2). Surgical spears<sup>j</sup> are small, wedge-shaped, highly absorbent, synthetic sponges attached to a stick. The point of the spear provides critical control when working under magnification.



**FIG 40.4** Surgical boards made of sterilizable materials are helpful to facilitate the movement of patients undergoing microsurgical procedures. An anesthetized cockatiel hen has been taped to a surgical board in preparation for a hysterectomy.

Absorbable gelatin sponges<sup>k</sup> are valuable for controlling hemorrhage, as is oxidized regenerated cellulose.<sup>l</sup>

With avian patients it is best to place the patient on a restraint board, which is then placed on the operating table. This allows the surgical assistant to move the patient intraoperatively to achieve proper visualization of structures. This is especially important when using the operating microscope as it is much easier to move the patient than to move and refocus the microscope (Figure 40.4). Such boards are commercially available<sup>m</sup> or can be easily constructed from a plastic container lid, a piece of styrofoam or a section of cardboard. Any material that is used should be disposable or sterilizable. Tape restraints are preferred over velcro restraints because they are disposable and minimize the risk of disease transmission.


An ideal monitor for the surgical patient would be easy to apply, unaffected by the surgical environment, economically priced and provide data on the patient's heart rate, respiration, body temperature and hemoglobin oxygen saturation. The high heart rate and small tidal volume of small avian patients are not easily detected by traditional monitors. Pulse oximeters have become standard in human anesthesia but may be unable to detect the high pulse rate of some smaller patients. Sensitive respiratory monitors that have a thermistor that extends to the end of an endotracheal tube<sup>n</sup> are effective in intubated pa-

tients but do not function properly if the patient is maintained using a face mask (see Chapter 39). Remote thermometers are available at a reasonable price.<sup>o</sup> The best monitor for surgical anesthesia is still a well trained and experienced surgical technician.

### ■ Radiosurgery (Electrosurgery)

Radiosurgery employs high frequency (two to four mHz), alternating current to generate energy waves, which create vibration and molecular heat inside individual cells, causing water to vaporize and the cells to rupture while the active electrode remains cool (Figure 40.5).<sup>15,16,19,33,38</sup> Most electrosurgical units generate wave forms in the frequency range of radio waves, making the term *radiosurgery* applicable. The frequency can be varied to achieve either cutting of tissues or coagulation of vessels. Coagulation occurs when the current density is sufficient to dehydrate cells and coagulate their organic contents.<sup>16,19,33,38</sup>

When set for monopolar operation, a radiosurgery unit employs two electrodes (an active electrode and an indifferent electrode or ground plate), which concentrate the current density at the tip of the smaller (active) electrode. Monopolar radiosurgical techniques are acceptable for gross tissue manipulations in avian patients weighing more than two kilograms. These are analogous to a broadcast antenna (active electrode) and a receiving antenna (indifferent electrode) for radio transmission. The ground (indifferent electrode) should be large and placed as close as possible to the surgical area, and the contact with the patient should be improved using an electrode paste. It is important to keep the active electrode clean and free of char and debris. A dirty electrode will drag



**FIG 40.5** Radiosurgery units are indispensable in avian practice. Versatile units are available that also have numerous applications in mammalian surgery (courtesy of Ellman Intl. Mfg. Inc.).

through the tissue, inhibiting the cutting action and increasing tissue coagulation, which can delay healing and predispose the wound to dehiscence.<sup>15,16,19</sup> Many types of active electrode tips are commercially available. Ball-type electrodes create a lot of tissue destruction and are used for fulguration and coagulation of large vessels. Loop electrodes are used to contour tissues, obtain organ biopsies and remove large masses in a piecemeal fashion. Skin incisions and incisions into other fine tissues are best accomplished with fine wire electrodes.

### Bipolar Forceps

Bipolar radiosurgical forceps are superior to monopolar forceps in patients weighing less than two kilograms and when manipulating tissues in the realm of microsurgery. With bipolar forceps a ground plate is not needed as one of the tips serves as the active electrode and the other as the indifferent electrode (Figure 40.6). Compared with the fine-needle or wire monopolar electrodes, the tips of the bipolar forceps are broader, allowing the current to be dispersed just enough to accomplish the tissue welding that is critical for hemostasis. The current passes from one tip (active electrode), through the contacted tissue and to the other electrode (indifferent) without passing through the entire patient. In avian patients, bipolar forceps induce less reflex hemorrhage and provide improved tissue control. With the two electrodes in such close proximity, the transmitted wave currents are different from those generated with the monopolar


lar system, resulting in precise control of energy application.

Some commercially available bipolar ophthalmic forceps are slightly wider than is ideal for avian surgery. These forceps can be made more appropriate for avian surgery by using a fine sharpening stone to reduce the width of the tips. It is best to make the active electrode tip slightly narrower than the indifferent tip. Forceps with the active electrode slightly bent are commercially available and are best for avian surgery.<sup>p</sup> The energy passes through the tissue between these tips in a manner not attainable with unmodified, straight-tipped bipolar forceps. A lower energy setting can be used with these forceps. With the Surgitron,<sup>q</sup> the fully filtered wave pattern of the *cutting* settings are used most commonly. The unit is set at 1 for vessel coagulation, 2 for muscle transection, and 3 for incision of dry skin. For vessels that are difficult to coagulate, the *cutting/coagulation* settings may occasionally be indicated. The *coagulation* setting is used primarily for tissue fulguration (such as the destruction of cloacal papillomas).

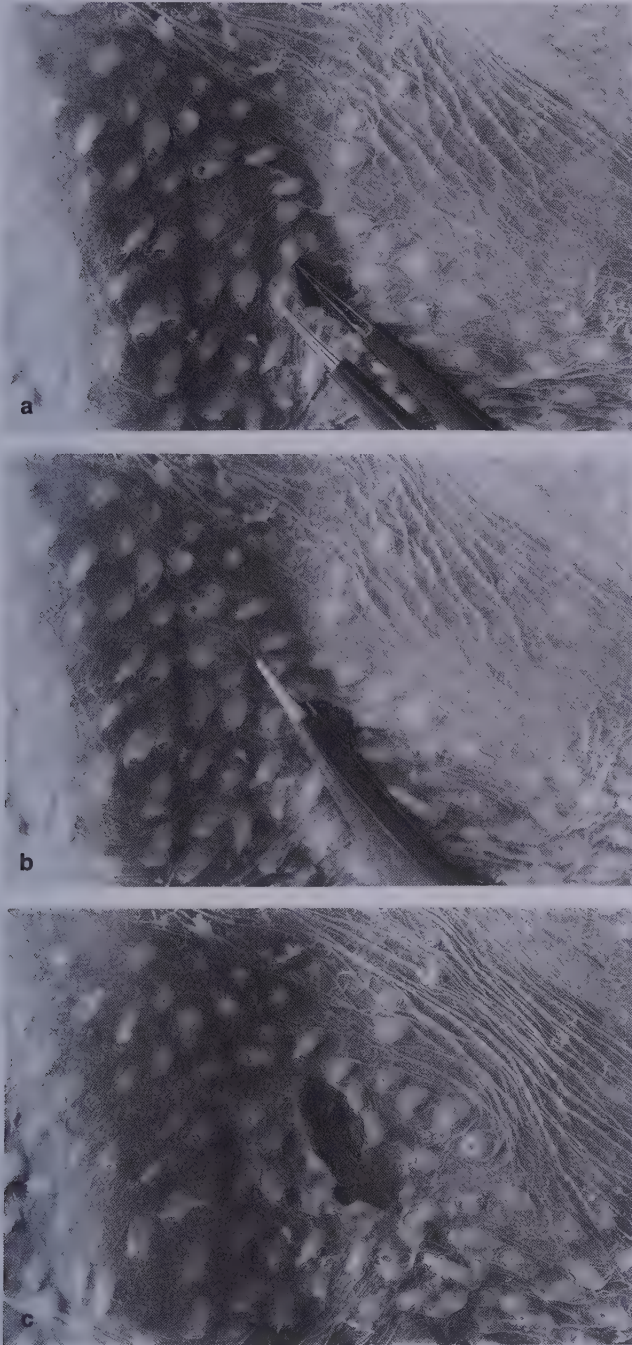
### Incision Techniques

The Harrison modified bipolar forceps<sup>p</sup> may be used to make primary skin incisions, coagulate cutaneous vessels prior to blade incision and coagulate individual vessels. These forceps may also be used with or without current for tissue dissection. Skin incisions should be planned in a manner to minimize the effect on feathers and feather tracts and to avoid the major blood supply to feathers. The skin is tented with thumb forceps and grasped with the bipolar forceps at the location of the proposed incision (Figure 40.7).

The current is activated (using a foot switch) precisely as the grasp on the tissue is relaxed slightly, and with a smooth, rapid motion, the forceps are pulled off the tissue.<sup>15,16</sup> When correctly applied, a fine, white blanching of the tissues occurs with a barely discernible separation of the skin that can be seen under magnification. This will create a small incision in the tissue that may then be parted to allow introduction of the indifferent electrode of the bipolar forceps (non-bent tip). The electrode is inserted subcutaneously to the extent of the proposed incision. The electrodes of the bipolar forceps are lightly apposed, the current is activated and the forceps withdrawn. This creates a skin incision with minimal damage. If properly performed, the skin should remain a normal color except immediately adjacent to the incision (which should be white), and there should be no hemorrhage.<sup>15</sup>



**FIG 40.6** Several styles of bipolar forceps are available. The top one has been specifically designed for avian microsurgical application. These tips are thinner than normal bipolar tips and the active electrode has a 45° bend to facilitate cutting of avian tissues (courtesy of Ellman Intl. Mfg. Inc.).



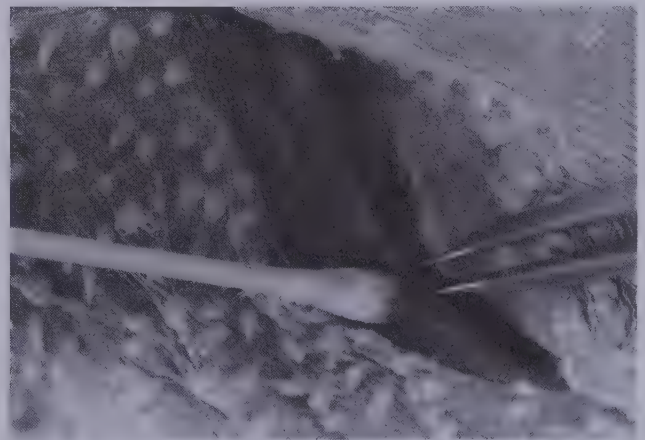
**FIG 40.7** a) When possible, the site for a skin incision is chosen by selecting an area that does not pass directly through a feather follicle. A small nick incision is made with a scalpel or by raising the skin slightly with a pair of forceps and grasping the tissue with the bipolar forceps. b) The indifferent electrode of the bipolar forceps is then inserted under the skin, the tips are gently apposed and the forceps are pulled out of the nick incision in a straight line. c) The length of the bloodless incision line can be increased as needed. Note that the skin is incised between, not through, the feather follicles.

When thicker tissue is to be transected, small bites of tissue are grasped with the bipolar forceps, the current is activated and the forceps are withdrawn through the tissue, creating a small nick. This process is repeated until the tissue is completely transected, stroke by stroke.

### Coagulation Techniques

If hemorrhage is encountered, a sterile cotton-tipped applicator is used to dry the area for radiocoagulation, which cannot be achieved in a wet field. The swab is rolled toward the source of blood flow with gentle pressure to serve as a tourniquet (Figure 40.8). The pressure is relaxed slightly to identify the source of hemorrhage. Once the vessel is identified, the slightly broader, flat indifferent electrode is placed under the vessel, and the bent-tipped, active electrode is loosely apposed to occlude the vessel. The current is activated as the forceps are relaxed, sealing the vessel. At high current or coagulation settings, the vessel frequently retracts within the tissue due to vasospasm. This results in temporary hemostasis only. As the vessel relaxes, the hemorrhage recurs.

When using monopolar radiosurgery, the power settings vary with the type and size of the electrode, the area of electrode surface in contact with tissue, the nature of the tissue, the operation performed (cut or coagulation) and the depth of the incision desired. Higher settings are necessary with tough tissues, deep incisions and large electrodes. Healing after radioincision is by first intention. When used correctly for creating an incision, the current should be activated *before* touching tissue, and the electrode should glide effortlessly, producing only a slight color



**FIG 40.8** A cotton swab is used to roll toward a bleeding vessel and, with gentle pressure, to occlude the vessel, stop the bleeding and allow the identification and coagulation of the severed vessel.

change in the tissue. When used for coagulation, the electrode should be activated *after* contacting the tissue and should produce a white spot at the site of energy transfer. Current applied repeatedly to the same area will cause excessive heating and damage to underlying tissues.

A radio current may pass through any portion of the exposed metal portion of the electrode. When the current is activated, it is important to be certain that only the tissue to be cut or coagulated is in contact with the metal portion of the electrode tip. This is especially important when attempting to coagulate vessels in the abdominal cavity through a small incision in a small bird. If the electrode inadvertently touches other structures (abdominal wall, parenchymous organs), the current will pass from the electrode through the first tissue it touches and exit at the ground plate, potentially without even contacting the intended tissue. Most bipolar forceps are insulated such that only the tips are exposed. This reduces the likelihood of errors causing unwanted damage to adjacent structures.

The fine-tipped monopolar electrode requires a higher setting when used on avian tissues than when used on thicker mammalian skin. When a vessel is encountered at these high settings, the electrode has a tendency to cut rather than coagulate the vessel, resulting in hemorrhage. A second effort must then be made to locate the vessel and coagulate it separately, creating the potential to induce more damage to the vessel and surrounding tissues. In mammals, the tissues surrounding vessels will heat slightly with the application of radiocurrent, which helps seal any transected vessels.

The application of a bipolar radiosurgical unit to avian practice and to veterinary practice in general is limited only by the time that the clinician spends in practicing with this equipment. Each radiosurgical unit requires precise adjustments that must be performed by the surgeon who will be using the instrument. Time invested in practicing with a radiosurgical unit will be well worth the improvement in clinical results.

### ■ Magnification

The hands and fingers are able to accomplish tasks of intricate detail, and vision is generally the limiting factor in surgical procedures. Therefore, some form of magnification is recommended for avian surgery<sup>33</sup> and is an integral part of an avian specialty practice.

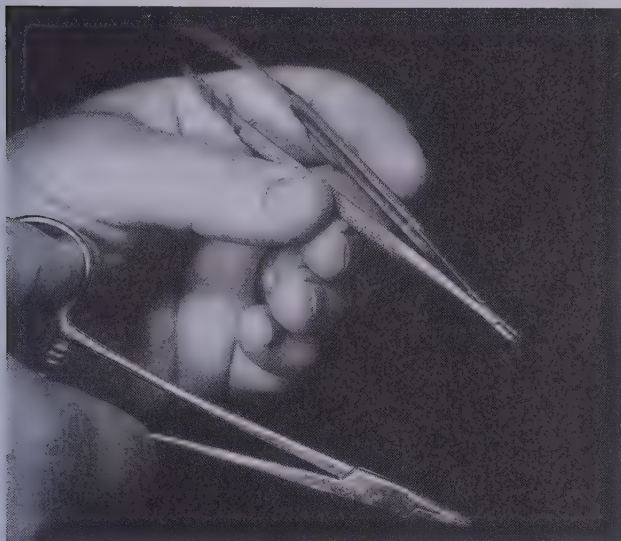
### Operating Microscope

In patients weighing less than a kilogram, an operating microscope and microsurgical instrumentation are mandatory and would be considered advantageous in larger birds. Using microsurgical techniques, severed nerves and vessels, which if left unrepaired would result in a dysfunctional post-fracture limb, can be anastomosed. Binocular magnification loupes of 2.5x to 8x are adequate for many procedures. Head sets with higher magnification usually create disorientation because of the constant micro-movements of the head. Attaching a fiberoptic lamp to the loupe facilitates vision. With the use of magnification, individual vessels are more easily identified for coagulation, minimizing the degree of hemorrhage associated with a procedure.<sup>1,19,33</sup> Because minor hand tremors are magnified, it is recommended that microsurgeons abstain from the use of alcohol, caffeine, other stimulants and heavy exercise prior to surgery.<sup>16</sup> The major disadvantage of performing surgery under an operating microscope is that it generally requires more time to complete a procedure than when a magnification loupe is used.

The operating microscope should have a lens objective of approximately 150 mm with 12.5 mm ocular lenses.<sup>12</sup> An electronic zoom is advantageous. A fiberoptic ring light can be attached to the lens for improved illumination of the surgical field. This type of ring light can be connected to most standard endoscope light sources. Bright white light is critical for visualization during microsurgery. Microscopes are expensive, but used and reconditioned models are becoming more readily available.

### Microsurgical Instruments

There are four requirements for microsurgical instruments: they should be long, be counterbalanced, have round handles and have miniaturized tips (Figure 40.9).<sup>16</sup> It is important that only the tips of microsurgical instruments are miniaturized. The handles should be of normal length to help provide stability to the tips and diminish the effect of hand tremors. The handles should be long enough to rest comfortably in the hand between the thumb and index finger. The instrument should be held like a fine writing instrument and be manipulated with minimal pressure. Gripping the instrument will fatigue the hand and fingers, causing motion at the tips. Microsurgical instruments have a counterbalance and are contoured to rest in the groove between the thumb and index finger. They should lie in the hand and not fall out when the grip is released (Figure 40.10). The handles should be round (except for scissors) to facili-



**FIG 40.9** A microsurgical needle holder with long, rounded, counter-balanced handles and miniaturized tips is compared to a standard needle holder.

tate a rolling action that results in smooth, precise, flowing movements at the tip. This rolling motion is especially important for delicate cutting, suturing and knot-tying. It is important to note that totally miniaturized instruments (older generation of ophthalmic instruments) are not appropriate for microsurgery. These instruments have short shanks and handles, and their use under the operating microscope results in loss of balance and control leading to fast, jerky movements.



The microsurgical pack should include micro-scissors, micro-needle holders and a variety of micro-for-

ceps. Needle holders should not have a clasp or box lock, as the motion that occurs when the lock is set and released is enough to cause the needle to tear tissues. Inexpensive forceps can be fashioned by placing vulcanized silicone on the handles of jewelry forceps. Layers of liquid plastic (dispensed from a hot glue gun) may be applied to the handles to achieve the necessary round shape. An ophthalmic Castroviejo needle holder can be modified for microsurgery by grinding the tip narrower, removing the box lock and making the handle round.<sup>12,16</sup>

For microvascular work, specialized clips are used to maintain the severed ends of the vessel in approximation. A colored background is placed under the vessel to improve contrast and make identification of the vessel easier. These backgrounds are commercially available<sup>7</sup> or can be made from pieces of balloon appropriately sterilized. Vessel dilators are also necessary. A vascular irrigation system can be made using a 27 or 30 ga needle, the tip of which has been cut off and polished smooth so it will not damage the vascular intima. A motorized rotary tool and the operating microscope are used to modify the needle. Heparinized irrigation solution in a hand syringe with the modified needle attached is used to clear the vessel of clots and debris.<sup>12,16</sup> Suture material for small avian patients usually is of 6-0 to 10-0 size, while for microvascular work, 10-0 nylon suture on a 75 micron needle is routinely used.<sup>12</sup>

### Developing Microsurgical Skills

The avian surgeon should take advantage of every opportunity to gain experience. Human plastic surgeons and microvascular surgeons are valuable resources. Continuing education courses and opportu-



**FIG 40.10** a) The handles of microsurgical instruments should be of sufficient length to allow them to rest comfortably in the groove between the thumb and index finger. b) Miniaturized instruments are difficult to manipulate and cause increased fatigue of the hands during use.

nities to practice on cadaver specimens are also valuable. Prior to practicing on tissues, it is helpful to gain experience manipulating objects under magnification by picking up and moving small objects (eg, canary seeds) with the microsurgical instruments. A slit can be placed in a latex glove to practice suture placement and knot tying. Initially, the clinician must develop new eye-hand coordination, and it is important to develop dexterity with both hands under the operating microscope. Microsurgery is tedious, time-consuming work, and it is imperative that the surgeon be comfortable. Prior to the onset of the procedure, the height of the table and chair should be adjusted for the surgeon's maximum comfort. Motion from the shoulders and arms should be minimized by resting the mid-antebrium along the edge of the table to serve as a fulcrum. The fourth and fifth fingers should also rest on the table to provide a second fulcrum and additional stability. The hands should be relaxed, and any motion should originate from the wrists and fingers, resulting in smooth, accurate paint brush-type movements. Breathing patterns should be natural. Breath-holding results in tremors at the instrument tips.<sup>16</sup>

### ■ Suture Materials

The goals of incision repair are to limit the adverse effects of the repair technique and to restrict the loss of tissue function. In routine avian surgery, suture sizes of 3-0 to 6-0 are most commonly used.<sup>18</sup> For small patients and microsurgery, sutures of 10-0 may be necessary. Companion birds may have a rather formidable beak that could easily remove the toughest materials; however, they generally do not traumatize suture lines.<sup>1</sup> This characteristic allows the use of continuous patterns in the skin of many avian patients. Topical medications, splints and bandages are not well tolerated by companion birds.

Many factors should be considered when selecting an appropriate suture material for a given procedure. The tissue characteristics, the presence of contamination or infection and the characteristics of the suture material influence the selection. The ability of suture material to potentiate infection is roughly proportionate to the inflammatory reaction caused by the suture.<sup>36</sup> The inflammatory response and reaction to various suture materials differ between birds and mammals. A number of factors influence the amount of inflammation a suture material induces including the surface area of material exposed to the tissue, the tissue in which the material is used (ie, fascia does not react to silk while intestines and

skin react strongly), the method of placement (tight sutures strangulate tissue), the length of time the material has been present (some sutures stimulate a reaction shortly after placement but become inactive within a few months) and the chemical properties of the material.<sup>36,37</sup>

Suture is a foreign material in a surgical wound and may potentiate infection. Bacteria may be protected from the body's defenses within the suture material. By reducing the amount of material implanted (the fewest number of sutures and the smallest diameter possible to accomplish the task) and minimizing surgical tissue trauma, the risk of suture-related infection may be diminished.<sup>36,37</sup> Braided sutures should not be used in contaminated or infected wounds as they delay the clearance of bacteria, prolonging and promoting inflammation.<sup>36</sup> Bacteria are better able to bind to braided materials than monofilament suture made of the same material. Where there is contamination or infection, a monofilament, nonreactive material such as nylon is indicated, as it will not allow bacterial wicking and will retain its tensile strength long enough for resolution of the infection and completion of tissue healing. In a study of the ability of bacteria to adhere to suture material it was found that monofilament, nonabsorbable materials have the least capacity for adherence while polyglycolic acid and polyglactin 910 have the most.<sup>36</sup>

Sutures that act as a wick to allow transport of serum and bacteria are called capillary sutures.<sup>37</sup> They may potentiate the spread of infection from a contaminated or infected tissue into a sterile area.<sup>36</sup> Multifilament sutures are also more likely to cause the formation of suture sinus tracts and granulomas than monofilament materials. The advantage of braided sutures is that they generally have better handling characteristics.

The extent of tissue damage during suture placement also influences the reaction and the risk of infection. Sutures should be placed with a minimum amount of both intrinsic (tension on tissue within the loop of suture material) and extrinsic (tension on surrounding tissues) tension. Knots must be securely tied, yet the surgeon must attempt to use the least amount of suture material to decrease the foreign body reaction. It is important to use the fewest throws to create a secure knot, which will fail by suture breakage and not by knot failure. For chromic catgut, polyglactin 910, polyglycolic acid and polypropylene, three throws are required and four are required for polydioxanone and nylon.<sup>35</sup> When starting and finishing a



continuous pattern, a different number of throws is required to create a secure knot. To start a continuous pattern with polyglycolic acid, polyglactin 910 and polypropylene three throws are required. Four are required for chromic catgut and five for polydioxanone. When ending a continuous pattern, it takes five throws for polypropylene, chromic catgut and polyglycolic acid, six for nylon and polyglactin 910, and seven for polydioxanone to create a secure knot.

After considering suture characteristics, tissue interaction and the processes of wound healing, the final factor in suture selection is personal preference. The technique of suture placement and tissue handling remains more important for uncomplicated wound healing than the selection of suture material.<sup>37</sup> The placement of sutures in a manner that allows accurate tissue apposition appears to be more critical in avian patients than in mammals. Tension and the resultant tearing of tissue in birds dictates the use of more sutures per centimeter, less intrinsic tension (within the suture loop) and atraumatic insertion. Most avian tissues have low tensile strength. It is important to use the smallest swaged-on atraumatic needle that is available for a particular suture. Many visceral organs are very delicate and require that the surgeon develop specialized handling techniques.

#### Evaluation of Suture Materials in Birds

The tissue reaction to five suture materials (polyglactin 910, polydioxanone suture, monofilament nylon, medium chromic catgut and monofilament stainless steel) in pigeons was evaluated at 3, 7, 15, 30, 60, 90 and 120 days following implantation in the body wall.<sup>4</sup> In mammals, it is known that chromic catgut is absorbed by the action of proteolytic enzymes released from monocytes. The pigeons in this study developed a marked granulocytic inflammatory response the the catgut that diminished during the period of evaluation; however, the material was still present at the end of the study indicating prolonged absorption of the material. Polyglactin 910 is considered nonreactive in mammals. It is absorbed by the process of hydrolysis and does not require enzyme degradation. In this study, polyglactin 910 caused the most intense inflammatory reaction but it was absorbed the most quickly (completely gone by day 60). Polydioxanone is a monofilament material, which, like polyglactin 910, is absorbed by hydrolysis. It is considered nonreactive in mammals and is usually completely absorbed by 180 days after implantation. This material behaved similarly in the pigeons studied. It caused minimal tissue reaction and absorption was underway at the close of the study.

Nylon and stainless steel cause minimal tissue reaction but are nonabsorbable. In the pigeons, they caused minimal tissue reaction but, because they are stiff and potentially more mechanically irritating to surrounding tissues, they were more often associated with hematoma, seroma and caseogranuloma formation. Based on the findings reported in this study, chromic catgut should be avoided in avian surgery. Slowly absorbed monofilament, synthetic materials absorbed by hydrolysis rather than proteolysis are most appropriate when wound healing is expected to be prolonged. Rapidly absorbed, braided, synthetic materials absorbed by hydrolysis are best used when the benefit of rapid absorption outweighs the disadvantage of a pronounced inflammatory reaction.

*(The editors have experienced some adverse reactions with Polyglactin 910 in psittacine birds; therefore they personally use nylon for subcutaneous sutures and stainless steel wire for skin.)*

#### Tissue Adhesives

Tissue adhesives of cyanoacrylate have many applications in avian medicine and surgery. The cyanoacrylate monomer is a liquid that polymerizes in the presence of the small amount of water present in tissues. The time required for the liquid to become solid and bond tissues depends on the amount of water (more water present will delay curing) and the thickness of the acrylic applied (thicker will delay curing). Medical grade adhesives<sup>8</sup> are biologically inert and cause minimal tissue reaction. Some prefer to use the less expensive commercial grade of glue (eg, SuperGlue); however, these contain substances that are toxic to tissues<sup>6,19</sup> and are not recommended for medical use.

These materials hold tissues in approximation to allow healing to progress; however, cells cannot penetrate the adhesive. It is important not to allow the adhesive to run between the tissues to be apposed as the presence of the acrylic will delay healing by creating a physical barrier. In some cases, especially with water birds, the acrylic may be applied in a thin layer over the apposed incision to create a seal yet allow epithelial cells to migrate under the acrylic during the healing process. These adhesives may also be used to secure IV catheters in place, to attach the limbs or digits of tiny patients to splints for orthopedic problems and various other purposes. Caution should be exercised when using these materials in the presence of anesthetic gases with which they are synergistic and may cause ocular irritation and vomiting in avian patients.<sup>19</sup>

## Postoperative Care

The patient should be placed in an incubator at 85°F with supplemental oxygen during recovery from surgery. It is best to continue maintaining the postsurgical patient in a small, controlled environment during the convalescent period (see Chapter 39). The patient's activity level should be kept to a minimum to allow proper tissue healing. A square, box-type enclosure is preferred and in most circumstances perches should be removed or lowered to decrease the likelihood of falling. Food and water should be placed where they are easily accessed by the patient. Toys and extraneous objects within the enclosure should be removed.

Postoperative antibiotic therapy should be instituted when there is a specific indication, such as with open, contaminated wounds or where there has been intraoperative contamination of the surgical field. IM perioperative antibiotic therapy is recommended for general prophylaxis in these cases.

In general, avian patients do not traumatize their surgical incisions, and they poorly tolerate bandages and other devices. Elizabethan collars or neck braces should be reserved for the most desperate cases. If an Elizabethan collar is considered necessary, the patient's neck should first be wrapped so the collar will be held in position against the mandible. Using this technique, a smaller, looser collar may be utilized.<sup>22</sup> In some patients, the center core of cardboard from a roll of bathroom tissue may be padded and used as a neck brace alone or in conjunction with an Elizabethan collar. The first day, the Elizabethan collar should open rostrally in the traditional manner. This will allow the patient time to become accustomed to the collar, and it will not damage the wings while the patient is struggling to escape the device. The second day, the collar should be reversed such that the cone opens caudally. This will allow the patient more ready access to food and water. The patient should be kept in a plain box with nothing to trap and hold the collar. Food and water should be placed on a pedestal for easy access. The patient's weight should be closely monitored to assure that an adequate amount of food and water is being consumed. The collar should be

regularly evaluated for evidence of pressure or esophageal obstruction.

### Analgesics

Historically, it has been considered that birds have a remarkable capacity to deal with pain, although the assessment of what animals perceive as pain is difficult. Research in the area of avian pain perception has been minimal. Companion birds have a well developed sense of touch and react by loud vocalization and withdrawal when potentially painful stimuli are applied. Clients expect that analgesia will be provided for their pet, and it is the responsibility of the entire staff to relieve a patient's postoperative pain and suffering.

Some research has been conducted with respect to pain in pigeons and poultry. One study was conducted in budgerigars<sup>3</sup> to evaluate the effect of high doses of butorphanol tartrate and flunixin meglumine<sup>a</sup> on heart rate, motor control and respiratory rate.

Butorphanol is an opioid analgesic with both agonist and antagonist properties, resulting in a "ceiling effect" such that above a maximum effective dose, neither beneficial nor deleterious effects are noted. The action and potency of opiates and opioids is related to the specific receptor sites to which a given agent binds.<sup>3</sup>

There are three major types of opiate receptors. Mu receptors mediate analgesia and euphoria. They are also responsible for physical dependency, sedation and respiratory suppression. Kappa receptors also are involved in analgesia and, to a lesser degree, with sedation and respiratory depression. Sigma receptor stimulation results in cardiac and respiratory stimulation, anxiety and hallucinations.

Butorphanol exerts its effects at mu and kappa receptors. Doses of 3 to 4 mg/kg of butorphanol given to budgerigars had no statistically significant effect on heart rate or respiratory rate;<sup>3</sup> however, some treated birds lost motor control. This effect was considered minor and all birds remained alert. Return to normal motor coordination occurred within two to four hours post-administration. No gastrointestinal effects were observed with this agent. This study did not evaluate the minimum and maximum effective doses. It would be advisable to start with a standard dose of 0.2 to 0.4 mg/kg of butorphanol, recognizing that doses up to ten times this dose are safe in birds.

Buprenorphine hydrochloride<sup>v</sup> is another opioid with agonist/antagonist activity that appears to be effective in controlling pain in avian patients. A dose of

0.01 to 0.05 mg/kg IM appears to provide adequate postoperative analgesia.<sup>23</sup>

Flunixin meglumine is a nonsteroidal anti-inflammatory agent that is a potent analgesic for certain types of pain; however, surgical pain is rarely responsive to this class of analgesic, and it is more appropriate for use in the treatment of inflammatory conditions. It has been recommended for use as an analgesic in companion birds at 1 to 10 mg/kg SID IM or IV.<sup>9,23</sup> Flunixin at 10 mg/kg had no effect on respiratory or heart rates in budgerigars.<sup>3</sup> Additionally, motor function remained normal following IM administration of flunixin. Regurgitation or vomiting occurred within two to five minutes after administration in five of six patients. Tenesmus was also observed several minutes after administration of flunixin. Aspirin has been recommended at a dose of one 5 gr tablet dissolved in 250 ml drinking water. These nonsteroidal agents have the potential to cause serious gastrointestinal side effects and may prolong clotting time. They should be used with caution until their benefits and limitations are better understood.

#### Products Mentioned in the Text

- a. Nolvasan Solution, Fort Dodge Laboratories, Inc, Fort Dodge, IA
- b. Betadine Solution, The Purdue Frederick Co, Norwalk, CT
- c. Hibiclens, Stuart Pharmaceuticals Division of ICI America, Inc, Wilmington, DE
- d. Vetrap, 3M Company, St. Paul, MN
- e. Incise, Johnson & Johnson Co, Inc., New Brunswick, NJ
- f. Safe & Warm, Safe & Warm, Inc., Boulder City, NV
- g. Heiss blunt retractors, small Alm retractors - Fine Science Tools, Foster City, CA
- h. Ligaclip, Pitman Moore, Mundelein, IL
- i. Hemoclip, Weck, Solvay Animal Health, Inc, Mendota Heights, MN
- j. Weck-Cell Surgical Spears, Solvay Animal Health, Inc., Mendota Heights, MN
- k. Gelfoam, Upjohn Co., Kalamazoo, MI
- l. Surgicel, Johnson & Johnson Co, Inc., New Brunswick, NJ
- m. Miami Vise, Henry Schein, NY
- n. The Beeper, Spencer Instrumentation, Irvine, CA
- o. Model Bat-12, Sorsortek, Santa Clara, CA
- p. Harrison Modified Bipolar Forceps, Ellman Intl. Mfg, Hewlett, NY
- q. Surgitron, Ellman Intl. Manufacturing, Hewlett, NY
- r. Visual Background, Ethicon, Somerville, NJ
- s. TissuGlu, Ellman Intl. Mfg, Hewlett, NY
- t. Torbugesic, Fort Dodge Laboratories, Fort Dodge, IA
- u. Banamine, Schering Corp, Kenilworth, NJ
- v. Buprenex, Rickitt & Colman, Hull, England

#### References and Suggested Reading

1. **Altman RB:** General principles of avian surgery. *Comp Cont Ed Prac Vet* 3:177-183, 1985.
2. **Awadhiya RP, et al:** Studies on acute inflammation in the chicken using mesentery as a test system. *Res Vet Sci* 29:172-180, 1980.
3. **Bauck L:** Analgesics in avian medicine. *Proc Assoc Avian Vet*, 1990, pp 239-244.
4. **Bennett RA, Yeager M, Trapp A, et al:** Tissue reaction to five suture materials in pigeons (*Columba livia*). *Proc Assoc Avian Vet*, 1992, pp 212-218.
5. **Bojrab MJ:** A Handbook on Veterinary Wound Management. Boston, Kendall Co, 1981.
6. **Boothe HW:** Suture materials and tissue adhesive. *In Slatter DH* (ed): *Textbook of Small Animal Surgery*. Philadelphia, WB Saunders Co, 1985, pp 334-343.
7. **Bos JH, et al:** Treatment of anemic birds with iron dextran therapy: Homologous and heterologous blood transfusions. *Proc Assoc Avian Vet*, 1990, pp 221-225.
8. **Carlson HC, Allen JR:** The acute inflammatory reaction in chicken skin: Blood cellular response. *Avian Dis* 13:817-833, 1969.
9. **Clubb SL:** Therapeutics. *In Harrison GJ, Harrison LR* (eds): *Clinical Avian Medicine and Surgery*. Philadelphia, WB Saunders Co, 1986, pp 327-355.
10. **Degernes LA:** Soft tissue wound management in avian patients. *Proc Assoc Avian Vet*, 1990, pp 182-190.
11. **Degernes LA, et al:** Preliminary report on the use of total parenteral nutrition in birds. *Proc Assoc Avian Vet*, 1992, pp 19-20.
12. **Doyle JE:** Introduction to microsurgery. *In Harrison GJ, Harrison LR* (eds): *Clinical Avian Medicine and Surgery*. Philadelphia, WB Saunders Co, 1986, pp 568-576.
13. **Fowler ME:** Nutrition in injured and diseased birds: *Proc Avian Pediatric Seminar*, 1990, pp 115-121.
14. **Goring RL, et al:** Needle catheter duodenostomy: A technique for duodenal alimentation of birds. *J Am Vet Med Assoc* 189:1017-1019, 1986.
15. **Greene JA:** Electrosurgery. *In Bojrab MJ* (ed): *Current Techniques in Small Animal Surgery* 3rd ed. Philadelphia, Lea & Febiger, 1990, pp 40-41.
16. **Harrison GJ:** New aspects of avian surgery. *Vet Clin No Am Sm Anim Pract* 14:363-380, 1984.
17. **Harrison GJ:** Evaluation and support of the surgical patient. *In Harrison GJ, Harrison LR* (eds): *Clinical Avian Medicine and Surgery*. Philadelphia, WB Saunders Co, 1986, pp 543-549.
18. **Harrison GJ:** Selected surgical procedures. *In Harrison GJ, Harrison LR* (eds): *Clinical Avian Medicine and Surgery*. Philadelphia, WB Saunders Co, 1986, pp 577-595.
19. **Harrison GJ:** Surgical instrumentation and special techniques. *In Harrison GJ and Harrison LR* (eds): *Clinical Avian Medicine and Surgery*. Philadelphia, WB Saunders Co, 1986, pp 560-567.
20. **Harrison GJ:** Preanesthetic fasting recommended. *J Assoc Avian Vet* 5(3):126, 1991.
21. **Hazelwood RL:** Carbohydrate metabolism. *In Sturkie PD* (ed): *Avian Physiology* 4th ed. New York, Springer-Verlag, 1986, pp 303-325.
22. **Janczek F:** Pipe foam collar. *J Assoc Avian Vet* 5(4):191, 1991.
23. **Jenkins JR:** Postoperative care. *Sem Avian Exotic Pet Med* 2(2):97-102, 1993.
24. **Jain NK, et al:** Studies on acute inflammation in the chicken using turpentine-induced pleuroperitonitis as a test system. *Vet Rec* 110:421-422, 1982.
25. **Jortner BS, Adams WR:** Turpentine-induced inflammation in the chicken. A light- and electron-microscope study, with emphasis on the macrophage, epithelioid cell, and multinucleate giant cell reaction. *Avian Dis* 15:533-550, 1971.
26. **Martin HD:** Resection of a false aneurysm in a cockatiel (*Nymphicus hollandicus*). *J Assoc Avian Vet* 5(3):142-146, 1991.
27. **Osuna DJ, DeYoung DJ, Walker RL:** Comparison of three skin preparation techniques in the dog. Part 1: Experimental trial. *Vet Surg* 19:14-19, 1990.
28. **Paul-Murphy J:** Feather plucking in preparation for surgery. *J Assoc Avian Vet* 1:17, 1989.
29. **Peacock EE, Van Winkel W:** Wound Repair. Philadelphia, WB Saunders Co.
30. **Powers DL:** Preparation of the surgical patient. *In Slatter DH* (ed): *Textbook of Small Animal Surgery*. Philadelphia, WB Saunders Co, 1985, pp 279-284.
31. **Probst CW, Bright RM:** Wound healing. *In Slatter DH* (ed): *Textbook of Small Animal Surgery*. Philadelphia, WB Saunders Co, 1985, pp 28-37.
32. **Quesenberry KE, et al:** Nutritional support of the avian patient. *Proc Assoc Avian Vet*, 1989, pp 11-19.
33. **Ritchie BW, Doyle JE, Harrison GJ:** Micro Techniques for the Surgical Management of Avian Diseases. *Res Inst Avian Med, Nut & Repro*, Lake Worth, 1990, pp 13-18.
34. **Romatowski J:** Prevention and control of surgical wound infection. *J Am Vet Med Assoc* 194:107-114, 1989.
35. **Rosin E, Robinson GM:** Knot security of suture materials. *Vet Surg* 18:269-273, 1989.
36. **Smeak DD, Wendelburg KL:** Choosing suture materials for use in contaminated or infected wounds. *Comp Cont Ed Pract Vet* 11:467-475, 1989.
37. **Smeak DD:** Selection and use of currently available suture materials. *In Bojrab MJ* (ed): *Current Techniques in Small Animal Surgery* 3rd ed. Philadelphia, Lea & Febiger, 1990, pp 34-39.
38. **Toombs JP, Crowe, DT Jr:** Operative techniques. *In Slatter DH* (ed): *Textbook of Small Animal Surgery*. Philadelphia, WB Saunders Co, 1985, pp 310-333.
39. **Wagner SD:** Preparation of the surgical team. *In Slatter DH* (ed): *Textbook of Small Animal Surgery*. Philadelphia, WB Saunders Co, 1985, pp 269-278.
40. **Wheeler SL, McGuire BH:** Enteral nutritional support. *In Kirk RW* (ed): *Current Veterinary Therapy X*. Philadelphia, WB Saunders Co, 1989, pp 30-36.
41. **Whitow GC:** Energy metabolism. *In Sturkie PD* (ed): *Avian Physiology* 4th ed. New York, Springer-Verlag, 1986, pp 253-268.

CHAPTER

---

# 41

## SOFT TISSUE SURGERY

---

■  
R. Avery Bennett  
Greg J. Harrison

**S**oft tissue surgical techniques that can be performed in birds have increased substantially over the last decade because of the widespread use of isoflurane anesthesia, the introduction of microsurgical techniques to the avian practice, improvement in microsurgical instrumentation, improvements in bipolar radiosurgical instrumentation and the growing expertise of avian surgeons. Board certified surgeons are becoming attracted to the field for the purpose of developing and refining avian procedures. Procedures that were once considered impossible are now performed on a routine basis.

The most substantial limitation to soft tissue surgery of the abdomen is the small size (<100 grams) of many avian patients. Some of these problems can be overcome with the use of magnification, but others are a result of having limited surgical access to an area, and are difficult to overcome. Surgery of the thoracic area, even in large companion birds, presents a similar problem, in that the organs of interest are covered by the sternum and heavy musculature. Continued improvements in the endoscopic surgical equipment available in human medicine will undoubtedly improve the surgeon's ability to perform surgery in difficult-to-reach areas of the avian body.

The avian surgeon should practice surgical techniques on cadavers prior to performing the procedures on clinical patients. The delicate avian tissues tear in the presence of slight autolysis; therefore, the use of fresh specimens will give the surgeon an appreciation of avian tissue characteristics and allow the surgeon to explore the capabilities of surgical instrumentation.

When necropsies are necessary, the clinician should approach this procedure from the perspective of a surgeon rather than of a pathologist, by dissecting and reviewing anatomy from a regional approach rather than by performing the necropsy strictly from the traditional ventrodorsal approach.

## Surgery of the Skin

The skin and subcutaneous tissues of birds differ from those of mammals. Birds have relatively thin, dry epidermis, and the dermis is attached to the underlying muscle fascia with little subcutaneous tissue.<sup>19,33</sup> In feathered areas, the skin is generally only ten cells thick. Compared to mammals, the skin is only loosely attached to underlying structures, except in the distal extremities where it is firmly adherent to underlying bone.

### Passerine Leg Scales

Passerine leg scale syndrome is characterized by the development of abnormally large scales of the legs and feet, possibly as a result of mite infection or malnutrition (see Chapter 43). These scales can coalesce and act as a constricting band. They also predispose the bird to bacterial pododermatitis (usually *Staphylococcus* spp). If present, the shiny, convex carapace of the female *Knemidocoptes* mite can usually be visualized, with the aid of the operating microscope, inside the burrows they create. In most instances, lesions resolve after treatment with ivermectin or correction of nutritional deficiencies. In severe cases, it may be necessary to surgically debride the proliferative scales to prevent vascular compromise. A 22 or 25 ga needle with the point bent to a 90° angle can be used to lift the scales and scabs, which can then be grasped with the micro-forceps. Skin softeners may also be beneficial.

### Toe Necrosis (Constricted Toe Syndrome)

Avascular necrosis of digits may occur secondary to circumferential constriction caused by fibers, scabs or necrotic tissue (see Color 24). These constrictions cause edema and if untreated, sloughing of the digit distal to the constriction.<sup>4</sup> This condition is generally not life-threatening, and amputation should be considered only after less aggressive therapies have failed. Removal of the offending tissue or fibers and supportive care are frequently successful. Avascular necrosis of the digits has been described in passerine birds and Amazon parrots. Scabs should be debrided or incised to prevent vascular compromise, and hydroactive dressings should be applied to the affected

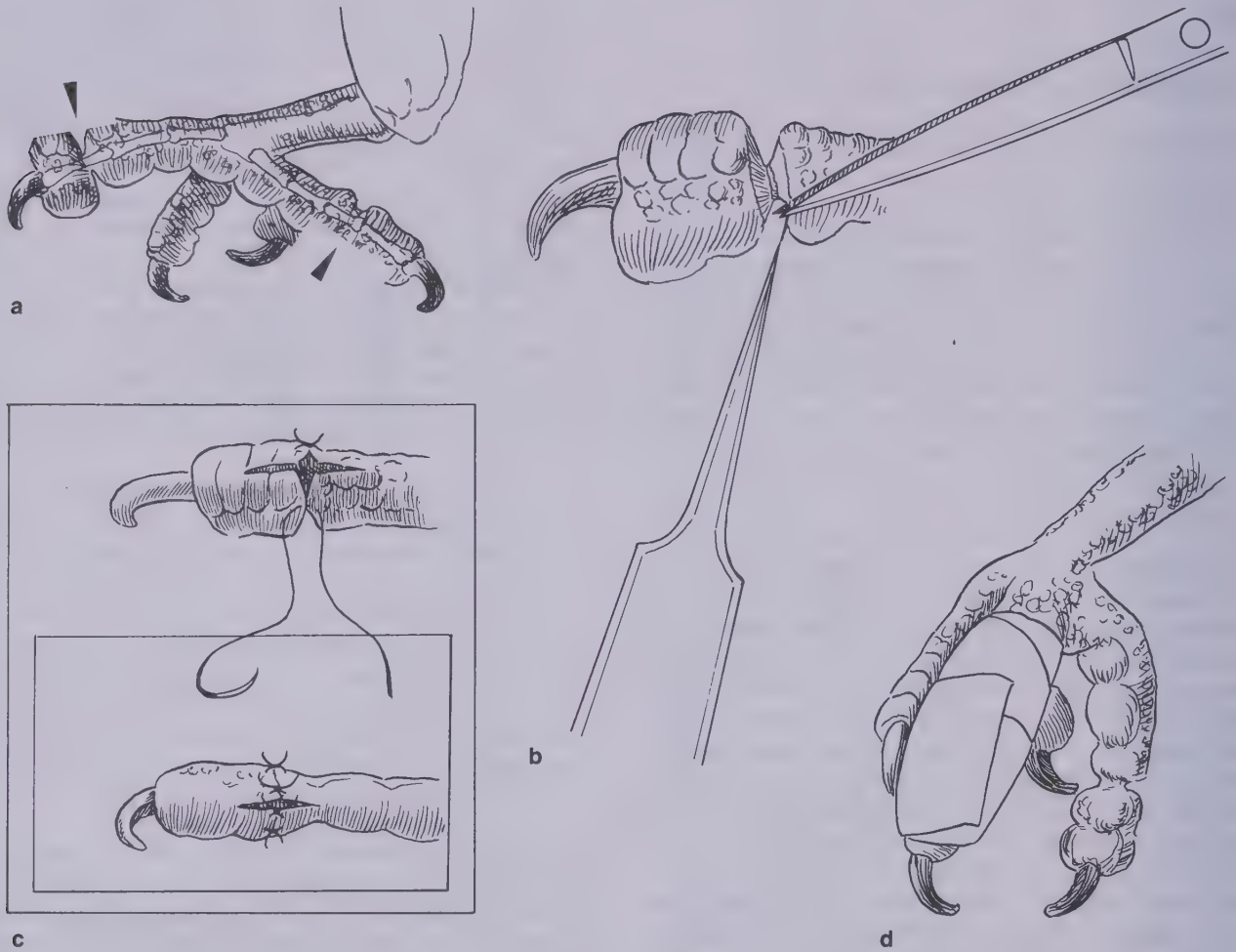
digits to prevent the formation of additional scabs. Complete healing may require weeks to months.

In small birds (eg, Passeriformes), constricting fibers may be visualized using the operating microscope (see Figure 43.4). A bent 25 ga needle is helpful for removing constricting fibers. The tip can be used to elevate the fiber, which can then be cut by gently rolling the needle such that the beveled edge severs the fiber. Microsurgical forceps may be used to untangle the fibers. Even severely swollen digits with exposed tendons may heal without incident once the fibers are removed. A hydroactive dressing should be placed on any wounds created by the fibers to prevent desiccation and the formation of a constricting scab.

Neonates (especially macaws and Eclectus Parrots) may develop constrictive toe lesions that can result in avascular necrosis of the digit (see Color 30). Proposed etiologies for these include low humidity, egg-related strictures or ergot-like intoxication.<sup>25</sup> Increasing the environmental humidity or providing hot moist compresses and massage may be effective in resolving lesions in the early stages.<sup>25</sup> More advanced lesions require surgical intervention. The circumferential indentation is treated using magnification to remove the constricting tissue (Figure 41.1).

A tourniquet fashioned from a rubber band held tightly with a mosquito hemostat may be used to control hemorrhage for short periods until the injury is properly treated. Hemostatic agents including radiocoagulation should be avoided. The blood supply to the digits is minimal, and anything that interferes with proper blood flow may predispose the digit to postoperative necrosis.

A circumferential anastomosis of the skin is then performed by placing one or two sutures in the subcutaneous tissues to provide skin apposition without tension. Skin sutures should be placed shallow below the epidermis and be sufficiently tight to appose the skin edges without disrupting the blood supply. Sutures placed too deeply will cause the skin edges to evert, exposing subcutaneous tissue and delaying healing. When the skin edges are apposed, a two to three millimeter release incision should be made at the site of the anastomosis on both the lateral and medial aspects of the digit. These incisions allow swelling without constriction. A hydroactive dressing is applied to prevent scab formation, which could result in reformation of the constriction.



**FIG 41.1** a) Constriction of the digits (arrows) is common in some macaw and Eclectus Parrot neonates. b) The lesion is repaired by using an operating microscope to remove the circumferential scab and create a fresh tissue margin. c) The wound edges are then apposed with shallowly placed sutures, and longitudinal incisions are made through the constriction on the medial and lateral sides of the digit to compensate for swelling and growth. d) The wound is covered with a hydroactive dressing to keep it clean and prevent dehydration.

**Feather Cysts**

Feather cysts are generally the result of trauma to the feather shaft, feather follicle or, as in the case of “soft-feathered” canaries, the result of abnormally developed feathers (see Color 24).

Feather cysts may occur within any feather follicle, but those on the wing and tail are the most challenging to the surgeon. In canaries, feather cysts are most common in Norwich, Gloucester and their cross-breeds. These birds have been genetically selected to produce an extra downy type of feather (soft feathering) that may predispose them to this syndrome (see Color 24).<sup>3</sup> In other birds, malformed and cystic feather development have been associated with trauma, malnutrition and viral, bacterial or parasitic infections. If damage is sustained to one side of the

follicle, feather growth becomes asymmetrical and the feather may grow in a curled fashion inside the follicle, resulting in a feather cyst.

Feather cysts on the wing that are treated by lancing and curettage frequently recur. Fulguration with a radiosurgical unit has been reported to be successful in some cases; however, the depth of destruction is difficult to control, resulting in damage to adjacent follicles. These damaged follicles can then develop feather cysts. Use of laser for follicle excision does not appear to improve the long-term clinical results.

Blade excision appears to be the treatment of choice. A tourniquet can be applied to aid in hemostasis. The entire follicle, including any bony attachments, should be excised. Adjacent follicles and their blood supply should be carefully avoided. In the postop-

erative period, the wing should be bandaged to prevent movement at the site of follicle excision while healing occurs by second intention. As adjacent feathers begin to regrow, debris should be gently removed by flushing with warm sterile saline several times daily.

With a single cyst or a large feather, the follicle may be saved by marsupializing the lining of the cyst with the skin surrounding the follicle. An incision is made centered on the cyst, parallel to the direction of feather growth. Hemorrhage is controlled with 6-0 ligatures, not with radiocautery. The lining of the cyst is cultured and the debris is removed. Redundant tissue is excised and the follicle is thoroughly lavaged with sterile saline. The margin of the cyst is then sutured to the skin using a simple continuous pattern of fine suture. New feather growth must be closely monitored.

Feather cysts of the tail may be severe and disfiguring, requiring amputation of the pygostyle. Blunt dissection to the coccygeal vertebrae allows disarticulation at the sacrococcygeal junction without entering the cloaca. Soft tissues are closed routinely.

Feather cysts on the body are easily removed using elliptical or fusiform excision followed by primary skin closure.<sup>3</sup> Treatment of individual feathers is generally unrewarding in cases where an entire feather tract is involved. A technique for radical excision of an entire pteryla of affected feathers in canaries has been described.<sup>3</sup> A fusiform incision is made from the flank to the thoracic inlet around the affected pteryla. The main vascular supply to the tract is located centrally at the cranial third of the pteryla. Large cysts may be supplied by relatively large individual vessels that should be coagulated or ligated. Despite the significant-sized defect, skin apposition is easily accomplished using a monofilament suture in a simple continuous pattern (braided material may damage the skin). Removal of one or more pterylae from the body wall does not seriously affect the cosmetic appearance of the bird.

### CLINICAL APPLICATIONS

- Feather cysts are particularly common in line-breed canaries.
- Feather cysts may occur secondary to any factor that damages the follicular epithelium.
- For feather cysts on the wing, blade excision appears to be the treatment of choice.
- Feather cysts of the tail may require amputation of the pygostyle.
- Feather cysts on the body are removed using elliptical or fusiform excision followed by primary skin closure.

### Xanthomas of the Wing Tip

Xanthomatosis is characterized by the deposition of a rubber-like proteinaceous material within the skin and is frequently associated with inflammation of underlying tissues (see Color 25). Xanthomas at the wing tip may cause the wing to droop, resulting in trauma to the mass. Probucola (25 mg/day for an Amazon parrot) and dietary management should be used in combination with surgical excision of the mass. Medical management is ineffective alone but may help prevent recurrence. Serum cholesterol levels should be closely monitored because they are usually elevated in birds with xanthomatosis and should be medically reduced to a normal level prior to surgery. The diet should be low in protein (13%) and fat (5.5%).

A monopolar, wire electrode functions well for removal of xanthomatous masses. The wound is left to heal by second intention. The wound may be protected with tissue adhesive or a hydroactive dressing, which should be changed every three to five days. Complete healing often requires several weeks. If subcutaneous tissues are involved (especially bone), the affected wing may require amputation.

### Excision of the Uropygial Gland

Impaction of the uropygial gland may respond to medical management using hot, moist compresses and gentle expression of the contents. In some cases, the gland may rupture, causing inflammation and scar tissue formation in the surrounding tissues. Chronic debilitation and death may follow.<sup>31</sup> Excision of the gland should be considered in cases where impaction recurs, the gland has ruptured, a tumor is present or chronic infection of the gland is not responsive to medical management.

A fusiform incision is made along the dorsal midline to incorporate the papillae of the gland. The skin is reflected with the aid of blunt dissection and radiocautery of damaged vessels. The gland is bilobed, and each lobe receives its blood supply from a vessel that branches at the cranial, middle and caudal portions of the gland. The gland may extend deeply to the synsacrum and caudally to the insertion point of the tail feathers. The vessels are identified and coagulated or ligated. Bipolar coagulation should be used to minimize damage to the follicles of the rectrices. Dissection is continued, beginning at the cranial extent of the gland proceeding circumferentially until its removal is possible. The deep fascia is closed

with monofilament absorbable material in a continuous or interrupted pattern, depending upon the amount of tension present. Subcutaneous and skin closures are routine.

Extensive dissection and debridement are necessary if the gland has ruptured. An additional caudal incision perpendicular to the dorsal midline incision may be necessary.<sup>31</sup> In these cases, extensive tissue trauma increases the likelihood of postoperative dehiscence and damage to the follicles of the rectrices.<sup>31</sup> Dehiscence usually occurs at the junction of the two perpendicular incisions. If possible, it is preferable to remove a diseased uropygial gland prior to its rupture.

## Surgery of the Eye

### Lateral Canthoplasty for Inferior Ectropion

Idiopathic paralysis of the inferior eyelid occurs with some degree of frequency in cockatiels and occasionally in Umbrella Cockatoos (see Color 26). Clinical signs generally include exposure keratitis with secondary epiphora and corneal ulceration. Symptomatic treatment involves the use of ophthalmic ointment to lubricate and protect the cornea. A lateral canthoplasty will create a smaller aperture, reducing the risk of exposure keratitis and associated conditions (Figure 41.2). Postoperatively the eye is medicated with an antibiotic ophthalmic ointment TID to QID, and the eye is cleaned as needed with an appropriate eye wash solution.

### Conjunctival Masses

Masses involving the palpebral conjunctiva occur with some frequency in cockatiels. These may be the result of tissue edema, cyst formation or discrete masses. They are usually easy to remove with radio-surgical bipolar forceps. These masses may be secondary to chlamydiosis, mycoplasmosis, eyelid paralysis or oropharyngeal abscessation from hypovitaminosis A (see Chapters 22, 26).

### Indolent Corneal Ulcers

Successful treatment of indolent corneal ulcers in birds appears to require debridement of the entire superficial layer of the cornea. Under the operating

microscope, a cotton-tipped applicator moistened with 10% acetylcysteine<sup>b</sup> is used to gently debride the edge of the ulcer toward the limbus. Once the affected epithelium has been debrided, it should be excised using a #11 scalpel blade or a corneal knife. Standard ulcer treatment is instituted postoperatively. The corneal surface will re-epithelialize from the limbus.

### Lens Removal

Trauma (blunt or penetrating) and senile lenticular degeneration have been speculated as causes for cataract formation in birds.<sup>7,27</sup> In canaries, cataracts are inherited, and surgical removal has been recommended.<sup>50</sup> The avian eye is large, conforms closely to the orbit and has limited mobility.<sup>52</sup> Scleral ossicles help support the eye and prevent collapse during surgery.

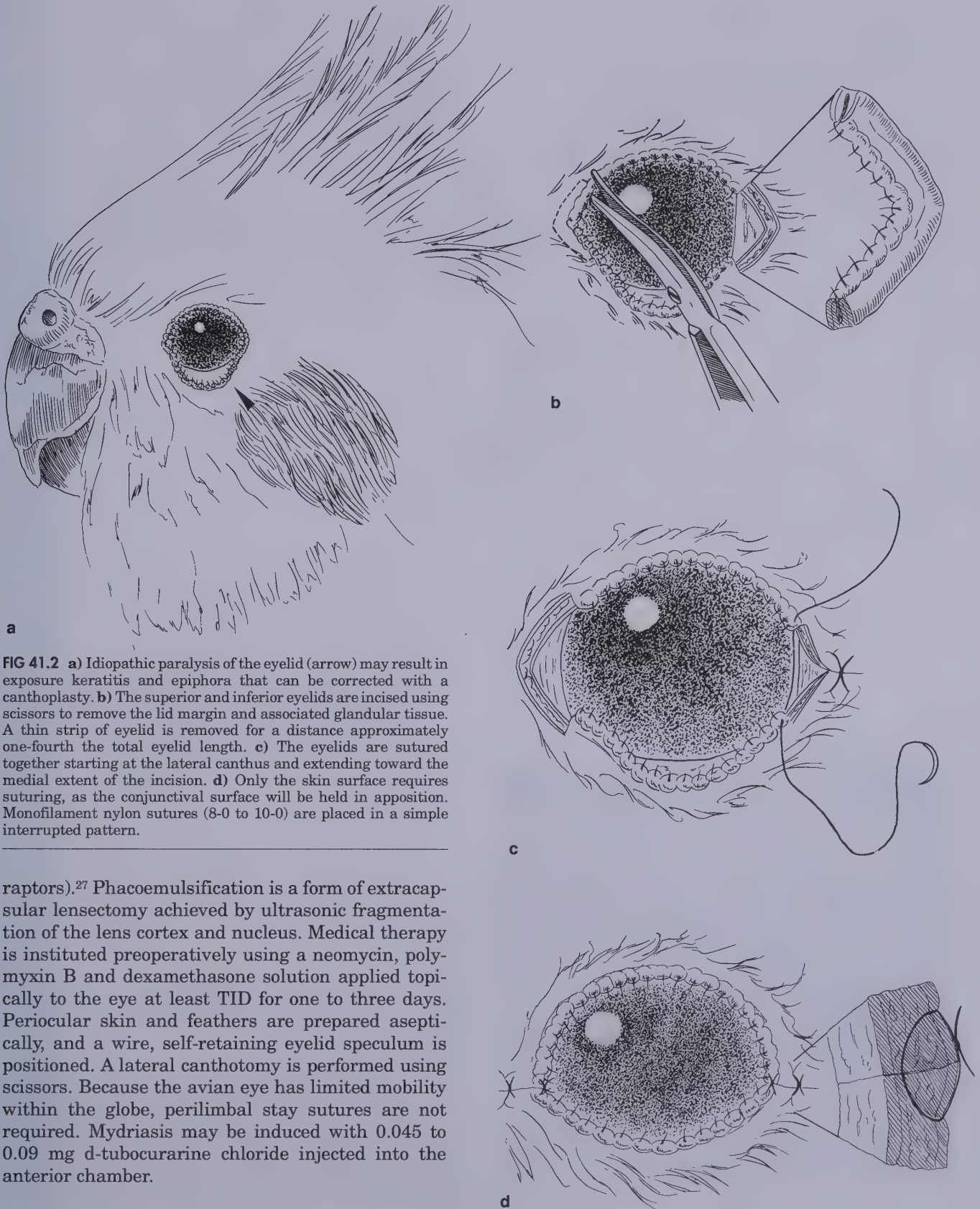
In a study of older macaws, immature cataracts were present in at least one eye of most birds over the age of 35.<sup>7</sup> In many cases, the cataracts remained immature for several years without completely obstructing vision. The change from an incomplete, immature cataract progressed rapidly to a complete, mature cataract seemingly skipping a complete, immature stage. Those birds with rapidly developing cataracts frequently became blind due to phacolytic uveitis. Lens removal was performed on 13 eyes in 8 birds because of visual impairment or uveitis.<sup>7</sup>

For lens removal in these macaws, no attempt was made to dilate the pupil preoperatively. The macaw cornea is approximately seven millimeters in diameter, which is too small for phacoemulsification instrumentation, and the cataracts were removed using standard surgical technique (Figure 41.3). In the immediate postoperative period, the eyes were treated with a topical steroid-antibiotic ointment,<sup>c</sup> followed by weekly subconjunctival injections of triamcinolone<sup>d</sup> for up to a total treatment period of four weeks. Hemorrhage, synechiae of the iris and sloughing of the corneal epithelium were reported complications; however, postoperative inflammation was minimal in most cases.

Ten of the 13 eyes were visual after surgery. One bird had bilateral posterior synechiae and pigment migration that obstructed vision. A third eye remained blind because of a pre-existing intraocular inflammation that caused a change in consistency of the lens material and retention of the lens protein.<sup>7</sup>

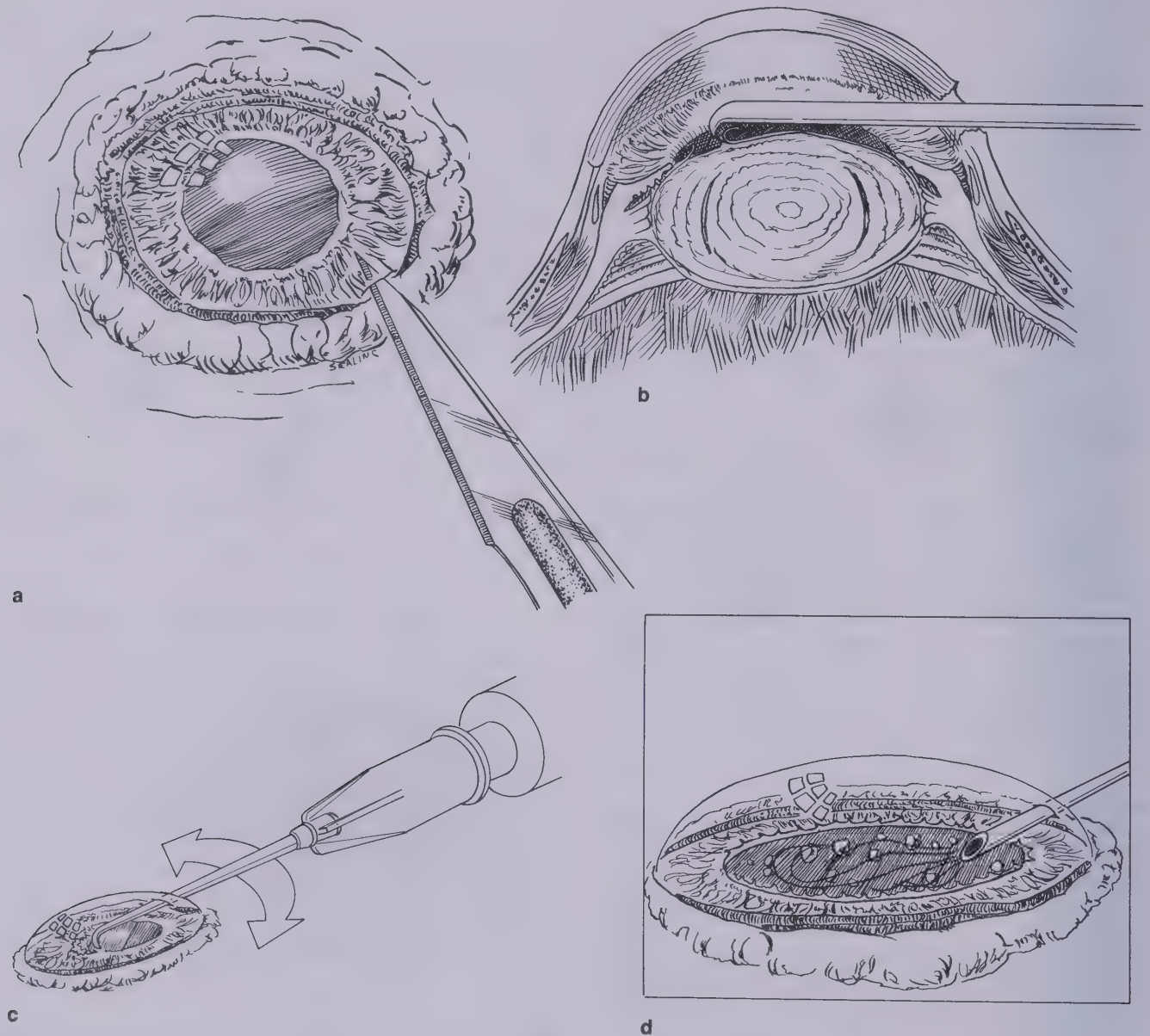
Ultrasonic phacoemulsification may be successful in removing the lens of birds with large eyes (such as





**FIG 41.2** **a**) Idiopathic paralysis of the eyelid (arrow) may result in exposure keratitis and epiphora that can be corrected with a canthoplasty. **b**) The superior and inferior eyelids are incised using scissors to remove the lid margin and associated glandular tissue. A thin strip of eyelid is removed for a distance approximately one-fourth the total eyelid length. **c**) The eyelids are sutured together starting at the lateral canthus and extending toward the medial extent of the incision. **d**) Only the skin surface requires suturing, as the conjunctival surface will be held in apposition. Monofilament nylon sutures (8-0 to 10-0) are placed in a simple interrupted pattern.

raptors).<sup>27</sup> Phacoemulsification is a form of extracapsular lensectomy achieved by ultrasonic fragmentation of the lens cortex and nucleus. Medical therapy is instituted preoperatively using a neomycin, polymyxin B and dexamethasone solution applied topically to the eye at least TID for one to three days. Periocular skin and feathers are prepared aseptically, and a wire, self-retaining eyelid speculum is positioned. A lateral canthotomy is performed using scissors. Because the avian eye has limited mobility within the globe, perilimbal stay sutures are not required. Mydriasis may be induced with 0.045 to 0.09 mg d-tubocurarine chloride injected into the anterior chamber.



**FIG 41.3** Cataract removal can be performed using phacoemulsification in most raptorial birds with large eyes. For most companion birds with small eyes, standard surgical techniques are used. **a**) Under the operating microscope, a small corneal incision is made. **b**) A 26 ga one-inch needle with the tip bent is inserted into the anterior chamber and used to tear the anterior lens capsule. **c**) A needle is then inserted into the lens through the anterior capsule to break down the lens and **d**) it is flushed out of the anterior chamber with lactated Ringer's solution. The corneal incision is closed with one or two simple interrupted sutures.

The phacoemulsification tip requires a 3 mm incision at the limbus or perilimbus at approximately the 10 and 3 o'clock positions. A #11 scalpel blade or a von Graefe cataract knife is used to make these incisions. Prior to making the second incision, a 22 ga needle connected to an IV set (containing lactated Ringer's solution supplemented with aqueous sodium bicarbonate without preservative to a final concentration of 25 mEq/l) is inserted through the first incision. The

depth of the anterior chamber is maintained using a continuous infusion of this solution while the second incision is made.

A cystotome or 27 ga needle with a bent tip is inserted through the second incision and used to create a tear in the anterior lens capsule at its periphery. The anterior capsule is not removed in order to help contain the fragments of lens material. After the capsulotomy is created, the needle is removed and

the phacoemulsification tip is inserted through the second incision, through the capsulotomy incision and under the anterior capsule. The tip is hollow with a 0.75 mm internal diameter and is used to aspirate materials or vibrate at 40,000 cycles/second. It is preferable for the lens to be removed without the use of ultrasonic waves. The posterior lens capsule is left intact. Once the entire lens is removed, the anterior capsule is removed by grasping it with Colibri forceps or the cystotome and tearing it from its attachments. The incisions are closed with 8-0 polyglactin 910 in a simple interrupted pattern. The first incision is closed while the infusion needle is maintained. Some fluid is lost during closure of the second incision but the depth of the anterior chamber is reestablished within a few minutes. The lateral canthotomy is closed using 5-0 polyglactin 910 in a simple interrupted pattern. At present, lens replacement devices are not commercially available in a size appropriate for avian patients.

Postoperatively, topical neomycin-polymyxin B-dexamethasone is applied at least TID for approximately 14 days and exercise is restricted for several weeks. Minimal evidence of uveitis has been noted in the postoperative period.<sup>27,38</sup> Corneal edema generally occurs only at the corneal incision sites. Optimum results are achieved when minimal surgical trauma occurs. The corneal endothelium must not be disturbed by touching the inner corneal surface with instruments or by directing the flow of the irrigation solution toward the cornea.

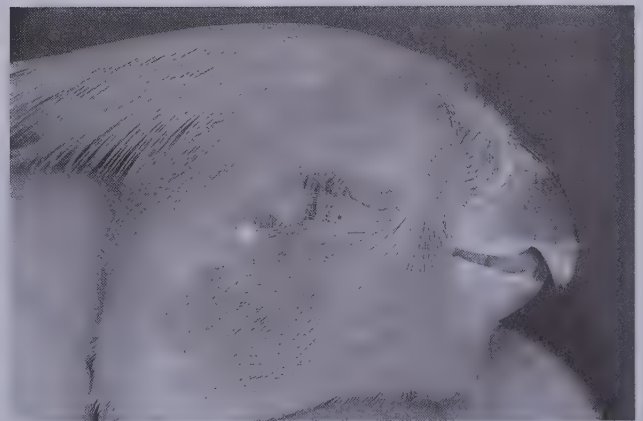
The ciliary processes fuse to the lens capsule in the region of the annular pad (see Chapter 26). The posterior capsule is adhered to the anterior vitreous. Care must be taken to avoid shearing the fused ciliary processes and producing hemorrhage. Posterior capsule opacification may occur as a sequela to extracapsular lensectomy, possibly due to retained lens cortex or iris pigment migration from synechiae.

### ■ Enucleation

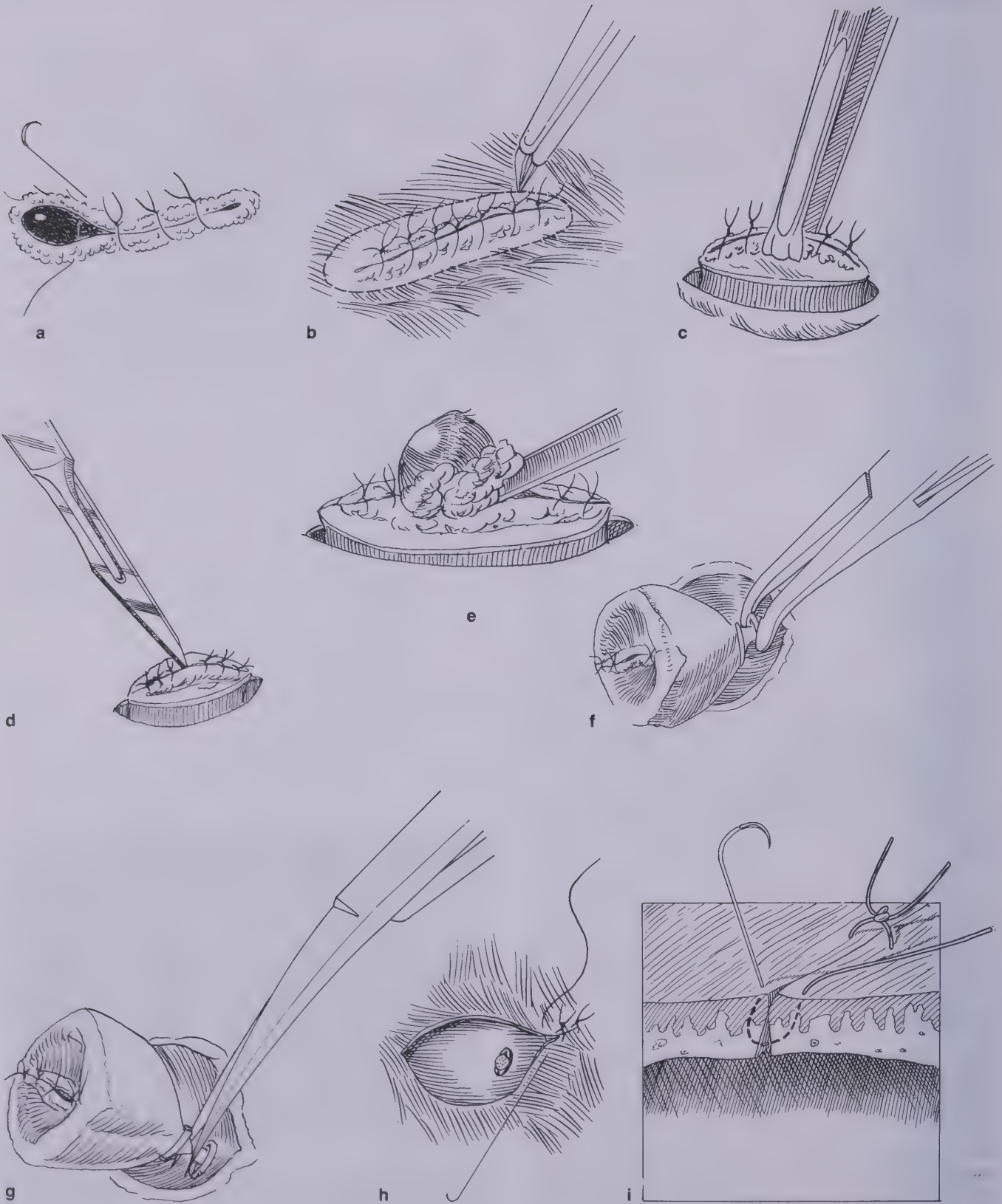
Enucleation is indicated for treatment of conditions that cannot be managed by other methods, such as neoplasia, overwhelming infection and severe trauma (Figure 41.4). The technique is similar to that described for mammals, except that birds have a very short optic nerve, and excessive traction on the globe can result in pressure trauma to the brain. Visualization of the muscles and blood vessels is enhanced by collapsing the globe at the start of the procedure. After the cornea is incised, the lens and vitreous are expressed through

the incision. The lid margins must be excised to eliminate glandular tissue and provide a cut edge for the blepharoplasty. It is also important to remove all conjunctival tissues and any secretory tissue.

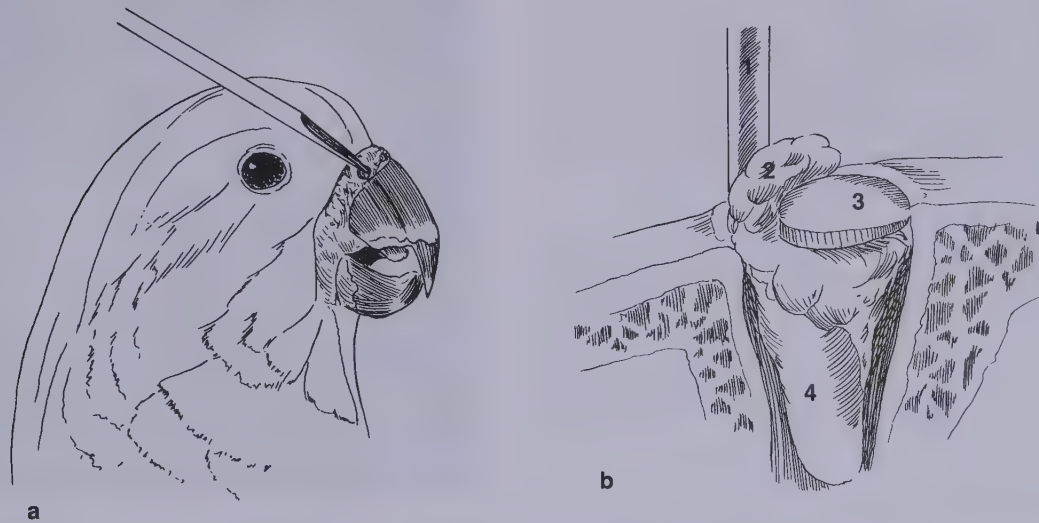
One enucleation technique involves suturing the eyelids together to improve the precision of the incision of the skin, which needs to be made a few millimeters from the lid margin circumferentially (Figure 41.5). The dissection is continued subcutaneously around the globe such that the palpebral conjunctiva will be excised with the globe. Hemorrhage is controlled with the bipolar radiosurgical forceps. Once all attachments have been transected except for the optic nerve and associated vessels, hemostatic clips are placed on this neurovascular bundle. Two clips should be applied to assure hemostasis. Curved applicators facilitate placement of the clips caudal to the globe and minimize traction on the optic nerve. The optic nerve is severed and the globe is removed. Any remaining hemorrhage is controlled using radiosurgery. An ocular prosthesis may be used to prevent the sunken appearance characteristic of avian enucleation. The skin margins are sutured together routinely. Drains or bandages are not indicated in most cases.



**FIG 41.4** A mature female cockatiel was presented several days after a traumatic injury that resulted in rupture of the globe. The eye was necrotic, and multiple gram-negative bacteria were detected by cytologic examination of periocular discharge. The eye was not salvageable and was removed. Enucleation is a cosmetic solution to ocular neoplasia and severe unresponsive ocular infections.



**FIG 41.5** A technique for enucleation in birds: **a)** The eyelids are sutured together. **b,c)** The lid margins are incised circumferentially so that the palpebral conjunctiva are excised with the globe. **d,e)** The globe is collapsed and eviscerated. **f)** Two hemostatic clips are placed around the neurovascular bundle at the base of the globe. **g)** The optic nerve is then cut between the clips. **h,i)** The skin margins are closed.



**FIG 41.6** a) A feathered wooden applicator stick can be used to gently break apart and remove rhinoliths. b) These masses start as an accumulation of debris frequently located caudal to the operculum. 1) probe 2) rhinolith 3) operculum 4) conchae.

## Surgery of the Respiratory System

### Rhinoliths

Rhinoliths may occur secondary to chronic malnutrition and rhinitis (Figure 41.6). These masses, formed of desiccated secretions and debris, cause a physical obstruction to respiration, which may result in respiratory distress and disfiguring atrophy of the nares (Figure 41.7). Clinical signs include sneezing, upper

respiratory sounds and inflation of the infraorbital air sac during expiration. Rhinoliths are difficult to diagnose, and identification requires probing under magnification and a strong light source. Once the technique for visualizing these concretions has been mastered, their occurrence will seem quite common.

Removal of rhinoliths requires magnification. Nasal tissues are friable and bleed easily when traumatized, which also predisposes the mucosa to infection. A wooden applicator stick broken to create a long bevel works well to begin the gentle removal of the mass (Figure 41.6). The beveled applicator stick is used to elevate the concretion from the margin of the naris followed by slow, precise, gentle probing with pressure to separate the mass from the wall of the



**FIG 41.7** a) A conure was presented with a three-week history of progressive dyspnea and inflation of the sides of the face on expiration. The right nostril was partially occluded with dried crusty material, and the area around the nostril was hyperemic; the left nostril shown in this view is relatively normal. b) The necrotic material was removed and the nostrils were flushed daily with sterile saline. c) Rhinoliths that are allowed to persist can cause disfiguring atrophic rhinitis-type lesions.

nasal cavity. Once the margins of the mass are clearly identified, a slightly thicker metal spatula may be used to finish the dissection. The lith usually breaks during manipulation and is retrieved in fragments. Fragments may fall caudally into the nasal cavity and must be flushed from their resting place behind the turbinates.

Once the rhinolith is removed, the lining of the nasal cavity should be swabbed and evaluated cytologically and by culture for mycotic and bacterial pathogens. The nares should be flushed with dilute chlorhexidine, and any fungal or bacterial component should be treated systemically with appropriate antimicrobial medications.


### ■ Infraorbital Sinusitis

Infraorbital sinusitis in birds may lead to secondary lacrimal and conjunctival infections, chronic rhinorrhea and other upper respiratory problems. Effective treatment requires a definitive diagnosis. Frequently, nutritional problems such as hypovitaminosis A predispose a bird to secondary infections with bacteria, yeast and fungi. A sinus flush technique can be used to obtain samples for cytology and cultures (see Chapters 10 and 22).

If untreated, mild infraorbital sinusitis may progress to abscessation that requires surgical exploration and curettage (see Color 22). Clinical signs may include sneezing, rhinorrhea, swollen eye, other ocular diseases, periorbital swelling and conjunctivitis. In some cases, purulent material can be visualized below the conjunctiva of the eyelid or the globe itself (Figure 41.8).

The infraorbital sinus is initially opened in the same location described for sinus flushing (see Chapter 10). This area is highly vascular, and laser, if available, is best for providing hemostasis. Bipolar radio-surgical units on higher coagulation settings may also be effective. Pressure may be applied to the area with a cotton-tipped applicator to allow visualization of the vessels. The sinus must be thoroughly and deeply explored, as purulent debris may be located within the nasal cavity, the recesses of the beak and even between the sinus and the nasal cavity caudal to the turbinates. It may be necessary to remove affected portions of the periorbital bone.

Supraorbital sinus trephination may be used to gain access to the dorsal and caudal-most areas of the sinus that cannot be accessed using nasal flushes and



**FIG 41.8** If left untreated, infraorbital sinusitis can progress to abscessation with necrosis and discharge from the side of the face as noted in this a) Sulphur-crested Cockatoo and b) Green-winged Macaw.

sinus injections.<sup>46</sup> The purpose of sinus trephination is to create an opening in the sinus through which irrigation and antimicrobial solutions may be instilled over a long period of time. Its major disadvantage is the risk of ocular injury. The site for trephina-

tion varies with the species, and the anatomy should be carefully studied prior to attempting this procedure.

To create an opening in the supraorbital sinus, the skin is incised exposing the frontal bone. Holes are made in the bone with a sterile rotary tool about one-half to two-fifths the distance between the rostral-most plane of the eye and the naris. The hole is angled toward the midline. Cortical bone is removed until the cancellous bone above the supraorbital sinus is visualized. Drilling proceeds into the supraorbital sinus and may then be widened to an appropriate diameter. Samples for cytology and culture are obtained, and the sinus is flushed with irrigation solution. The passage of irrigation solution through the choana and into the oral cavity confirms that the hole is properly placed. The periorbital tissue will bulge when fluids are introduced, and these tissues should not be over-distended. If indicated, this procedure may be performed bilaterally in some Passeriformes, whereas a single trephination site is sufficient in Psittaciformes in which the infraorbital sinuses communicate (see Chapter 22).

The trephination sites may be irrigated as often as indicated with appropriate antimicrobial solutions. The incisions heal rapidly and may need to be opened periodically. When therapy is no longer indicated, the trephination sites heal with minimal scarring.

### ■ Hyperinflation of the Cervicocephalic Air Sac

This condition is thought to occur secondary to trauma, but the location of leakage of air into the subcutaneous space is generally not identifiable. Generalized subcutaneous emphysema usually occurs in small birds, while in larger species the emphysema is generally confined to the dorsum of the neck (see Figure 22.11). A procedure for surgically implanting a cutaneous stent at the poll of the head to allow the air to escape (in a location where the bird cannot remove the device) has been described.<sup>12</sup> A Teflon stent,<sup>h</sup> with a 5 mm outer rim that allows the skin to be placed under its edge to prevent the dermis from closing over the opening, is used for the procedure.

A skin incision is made just large enough for the insertion of the stent. Sutures are pre-placed through the four pairs of holes in the flange of the stent such that the suture enters one hole from the external side, doubles back and passes through the other hole from the internal side. Once all four sutures are placed, the stent is implanted. A 22 ga needle is inserted through the skin at the proper location for

one tail of suture material to be inserted through the needle to be exteriorized through the skin. This procedure is repeated so that each of the four sutures passes through the skin, one hole of the stent, doubles back, passes through the other hole of the stent and exits the skin. The four sutures should be placed one on each of the four sides of the incision. The sutures can then be tied. The main postoperative problem is a transient occlusion of the stent with dried tissue fluids, which is easily resolved using a swab or needle.

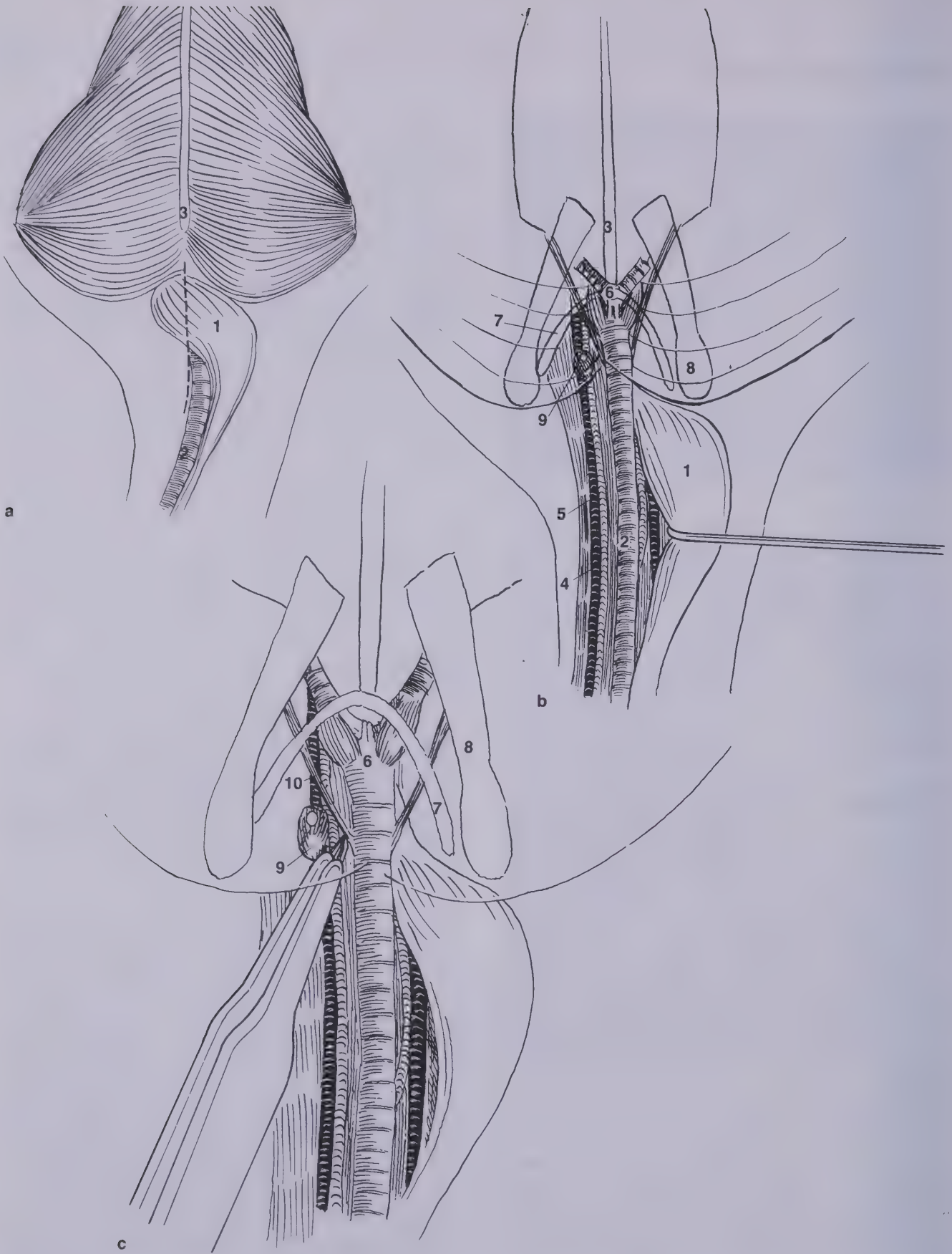
This syndrome has also been treated in an Amazon parrot using a one-way valve connecting the cervicocephalic air sac to the clavicular air sac. The approach is through the left lateral thoracic inlet, and the tube is inserted into the hyperinflated air sac. It is then directed caudally along the esophagus, through the thoracic inlet and into the cranial aspect of the clavicular air sac. The tube is sutured to the longus coli muscles to prevent migration. No attempt is made to suture the air sac around the tube. Skin closure is routine.

## ■ Thoracic Surgery

### Tracheal/Syringeal Obstruction

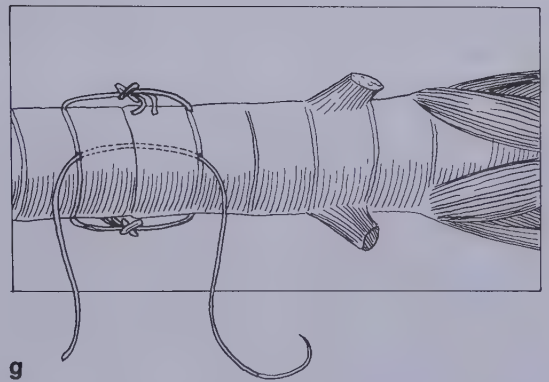
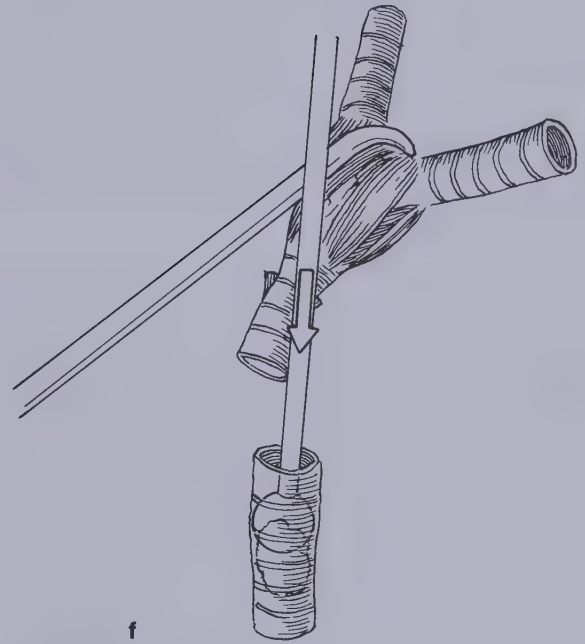
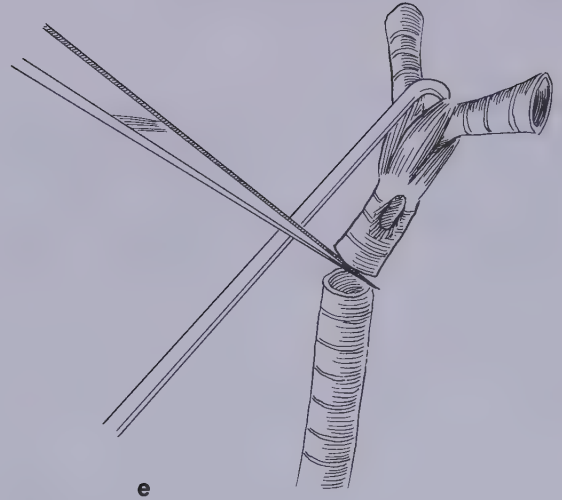
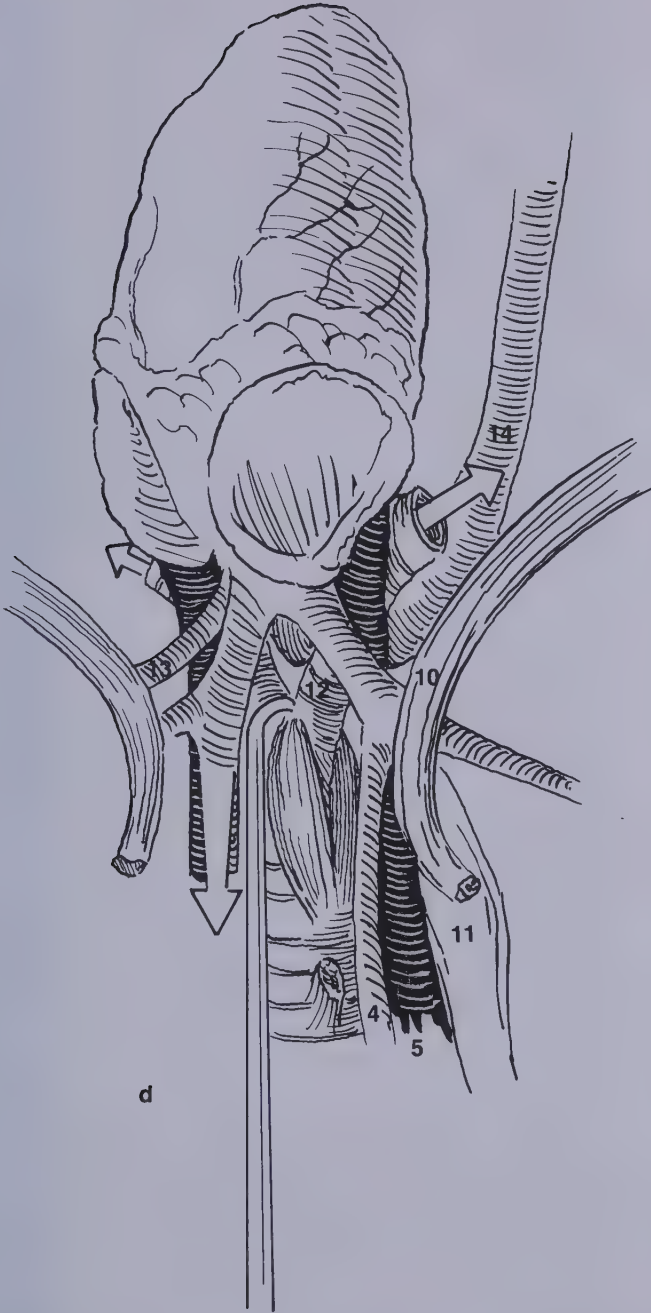
Seed or other foreign body aspiration,<sup>9,19</sup> fungal granulomas resulting from aspergillosis or candidiasis<sup>36</sup> or concretions of epithelial cells and mucus may occlude the trachea or syrinx resulting in respiratory distress. Some birds present with no premonitory signs, while others have a history of voice change and a more gradual onset of dyspnea.

Therapy depends upon the size of the patient and the configuration of the trachea. The trachea of some birds such as swans and cranes is coiled and encased within the sternum, making retrieval of distal tracheal foreign bodies extremely difficult (see Figure 12.17).<sup>19</sup> Care must be taken not to push the foreign body into the sternal portion of the trachea. In a Sarus Crane, a 22 ga spinal needle was passed transversely through the trachea to prevent a kernel of corn from migrating farther down the trachea while it was being surgically removed.<sup>19</sup> The avian trachea is composed of complete tracheal rings, which are generally cartilaginous, although calcified rings have been reported in adult Amazon parrots and adult cranes.<sup>19</sup> Annular ligaments connect adjacent rings.<sup>40</sup> In some species, the pessulus (a midline laryngeal cartilage) may be present, providing an additional challenge to foreign body retrieval.<sup>19</sup>



**FIG 41.9** If all other techniques for removal fail, some foreign bodies and granulomatous plaques can be removed from the trachea and syrinx using a tracheotomy. **a)** An incision is made over the crop on the ventral midline. **b)** The crop is retracted laterally to the right. **c)** The tracheal muscles are transected using bipolar radiosurgery. (continued on next page)





**d)** A spay hook is used to gently pull the syrinx into the thoracic inlet. **e)** The trachea is transected. **f)** A blunt probang or suction device can be used to remove debris. **g)** Closure is completed by apposing the tracheal rings. 1) crop 2) trachea 3) sternum 4) internal carotid artery 5) jugular vein 6) syrinx 7) clavicle 8) coracoid 9) thyroid 10) sternotracheal muscle 11) esophagus 12) primary bronchi 13) pulmonary artery and 14) aorta; lateral arrows show primary bronchi to lungs.

Establishment of a patent airway is crucial. Placement of an air sac cannula will allow the patient to ventilate through an alternate airway until the obstruction can be removed. It may be beneficial to place the bird in an oxygen-enriched environment prior to manipulating the patient for placement of the air sac cannula.

In small birds (cockatiels and smaller), the tracheal diameter (approximately 1.5 mm for cockatiels) precludes use of an endoscope to retrieve a foreign body or granuloma. If the obstruction is the result of a granuloma or inspissated cells and mucus, a suction tube (urinary catheter) slightly smaller than the diameter of the trachea may be utilized to remove material from the trachea and syrinx (see Chapter 22).<sup>30</sup> By maintaining anesthesia with an air sac cannula, the trachea may be occluded with the suction tube without compromising respiration. If squamous metaplasia secondary to hypovitaminosis A is suspected, dietary modification and vitamin A supplementation should be instituted.

In medium to large birds, a rigid or flexible endoscope can be used to evaluate the cause of an obstruction and potentially aid in its removal. In some cases, the endoscope may allow visualization of the object, but the tracheal diameter may be too small to use a wire basket or grasping forceps to remove the object.<sup>19</sup> In these cases, the endoscope can be used to brush off plaques or physically alter lesions sufficiently to open the airway, and the loosened plaques can be removed with a suction tube. Cytologic evaluation of samples obtained from the suction tube, or the end of the endoscope, may be used to determine the identity of an etiologic agent. Following this procedure, the patient should be treated using nebulization, intratracheal medications and systemic therapies as indicated (see Chapter 22).

In some cases, tracheal foreign bodies may be retrieved using grasping forceps, a Foley catheter<sup>i</sup> or a Fogarty catheter<sup>28</sup> with the aid of an endoscope. The size of the patient's tracheal diameter will determine which catheter is most appropriate. The catheter is passed beyond the foreign body and the balloon is inflated sufficiently to occlude the airway but not to prevent it from being withdrawn. With the balloon inflated, the catheter is withdrawn, resulting in removal of the foreign body.<sup>19,28</sup>

As a last ditch effort in medium- to large-sized birds (parrots, raptors, doves, pheasants and peafowl), the thoracic inlet may be approached surgically for re-

moval of tracheal or syringeal foreign bodies (Figure 41.9). The patient is positioned in dorsal recumbency on a surgical restraint board. A tube should be placed in the esophagus to allow for its easy identification to prevent iatrogenic trauma. The skin is incised from the right clavicular/sternal junction to the clavicular/coracoid junction just cranial to the crop. The skin is elevated from the crop, and the right lateral aspect of the crop is gently dissected from surrounding tissues. Major blood vessels are easily avoided using blunt dissection. Once the crop is freed from its clavicular attachments, it should be reflected to the right. The trachea is identified by its complete cartilage rings. The sternotracheal muscles are identified traversing obliquely to their caudolateral attachments, and both sets of sternotracheal muscles are transected. A large blood vessel between the muscle bellies should be coagulated prior to transection of the muscles. A small canine vaginal speculum may aid in visualization.

At this point, the use of the operating microscope becomes essential. The restraint board should be elevated at the cranial end such that the operating microscope can be used to visualize the structures deep in the thoracic inlet. It may take some time and patience to achieve proper positioning and focus, but this technique allows the surgeon to visualize critical structures while having both hands free for manipulations.

The interclavicular air sac is bluntly dissected to expose the syrinx. A blunt hook is looped over the syrinx, which is gently pulled into view. In Amazon parrots, small macaws and smaller birds, this procedure may result in avulsion of the bronchi from the lung. For these patients, a left lateral approach to the syrinx is recommended as a last desperate attempt.

A transverse tracheotomy (50% of diameter) can also be created on the ventral surface to allow retrieval of the foreign material. Foreign bodies have been removed through longitudinal tracheal incisions;<sup>35,36,44</sup> however, these incisions provide limited visibility and access due to the inward twisting of the cut rings, and are more prone to iatrogenic trauma during manipulation, are more difficult to close than a transverse tracheotomy and are more prone to stricture formation.<sup>15,46</sup> Unless absolutely mandatory, the trachea should not be completely transected in order to maintain its alignment, reduce tension on the closure and prevent complete disruption of the blood supply.<sup>19</sup> Stay sutures placed around the tracheal rings adjacent to the tracheotomy allow atraumatic manipulation of the trachea. Foreign materials located

cranial to the tracheotomy site can be pushed out of the trachea with a sterile probang. Those located caudal to the tracheotomy site can be removed by suction. If the trachea completely separates during manipulations, anastomosis may be performed. The incision should be closed with a small-sized, monofilament, absorbable suture material encompassing at least one tracheal ring on each side of the tracheotomy incision.<sup>19</sup> A simple interrupted pattern is best performed by pre-placing the encircling sutures. Knots should be placed external to the tracheal lumen. Intraluminal granuloma formation at the sutures is common. Soft tissue, skin and subcutaneous closure are routine.

A lateral thoracic approach to the trachea can be used in very small birds where there is no other means to approach and evaluate the syringeal area. Practice and microsurgical techniques are essential for this procedure. The patient is positioned in right lateral recumbency. An incision is made over the second and third ribs. These ribs are exposed using blunt dissection, and they are transected at both ends to allow their complete removal. This will expose the cranial portion of the lung. Using a moistened cotton-tipped applicator, the cranial extent of the lung is gently dissected and reflected from its attachments. The jugular vein, pulmonary artery and branches of the subclavian artery may be identified and should be avoided. Dissecting between these vessels allows visualization of the syrinx, which is incised (2 to 3 mm) using bipolar radiosurgical forceps at its junction with the left primary bronchus. A foreign body may then be removed using a combination of tracheal endoscopy, visualization and suction through the syringeal incision.

The syringeal incision is allowed to close by second intention. The ribs are not replaced. The lung is repositioned in its normal location. Soft tissues are apposed and the remainder of the closure is routine. This is a difficult procedure that should be used only as a life-saving technique when all other methods for foreign body removal have failed.

#### Devocalization

The authors and editors consider devocalization a cruel and unethical practice; therefore, a procedure will not be described. Birds with vocalization patterns that are unacceptable to a client should be placed in new homes.

#### Pneumonectomy

Removal of lung tissue may be indicated in the treatment of abscesses or granulomas. In some instances,

a surgical lung biopsy may be required instead of an endoscope-guided biopsy for diagnosis of a respiratory disease.<sup>20</sup>

In birds, there is no distinct pleural space, and the visceral and parietal pleura are in close approximation. The pulmonary parenchyma is contoured to the dorsal aspect of the ribs and the intercostal spaces. This makes the lungs easy to approach surgically. Compared with mammalian lungs, those of birds are more vascular and the intrinsic clotting mechanism appears to be less efficient.

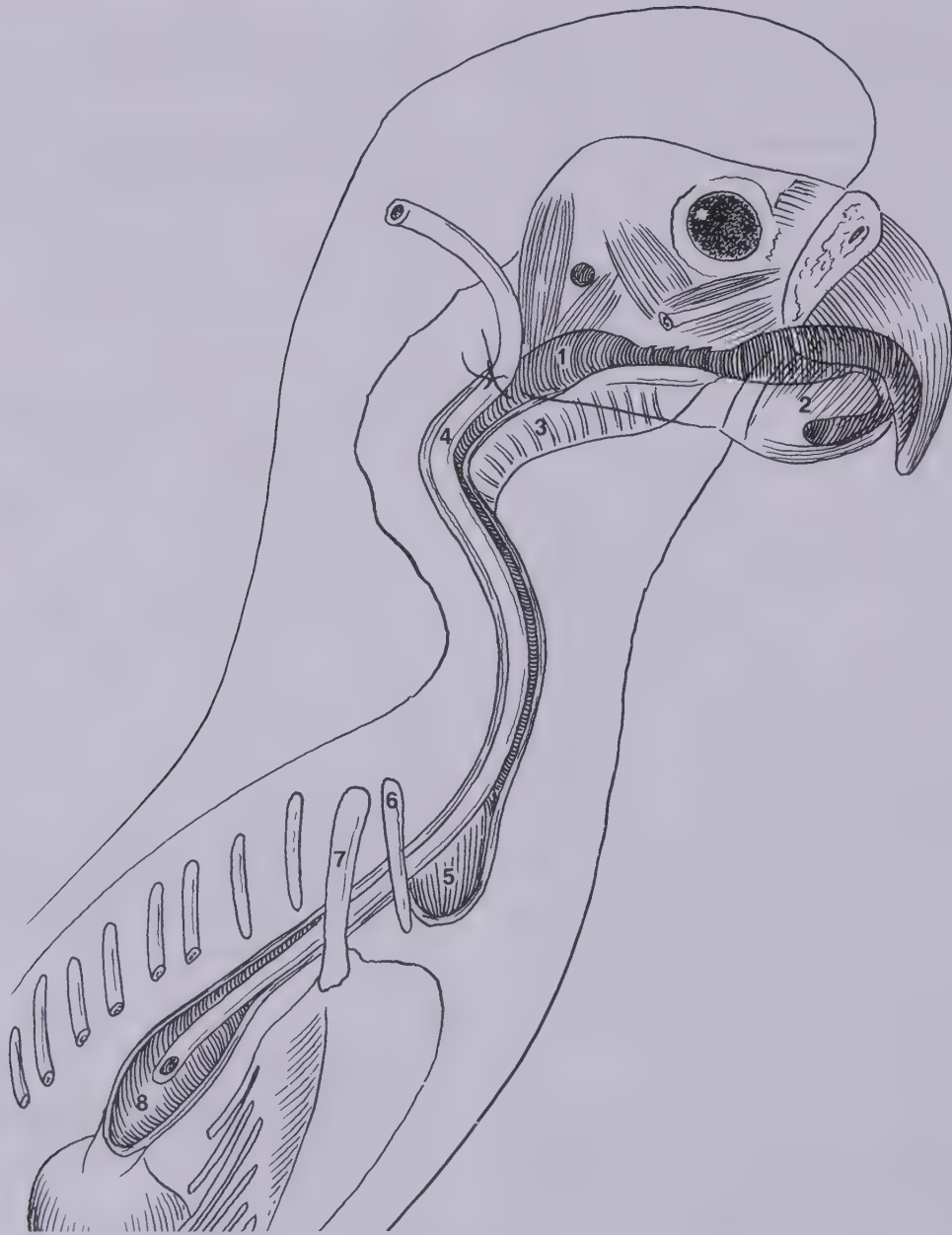
The lungs can be approached through the caudal thoracic air sac or the intercostal space by removing one or more ribs as described for the lateral approach to the syrinx. The affected lung tissue is elevated from the ribs and surrounding structures using a moistened cotton-tipped applicator or a spatula. The affected area is isolated using vascular clips, and the tissue to be removed is incised such that the clips remain with the viable portion of lung. No studies have been conducted to determine the amount of lung that may be removed or the physiologic effects of partial pneumonectomy; however, clinically, partial pneumonectomy patients appear to function normally.<sup>20</sup>

Closure is accomplished using wire suture to oppose the intact ribs on each side of the thoracotomy site. For a caudal thoracotomy, the pubis may be utilized to aid in closure of the gap created by the removal of ribs.

## Surgery of the Gastrointestinal System

### Pharyngostomy Feeding Tube

Pharyngostomy feeding tubes are indicated when it is necessary to aliment the patient while bypassing the oral cavity, esophagus or crop. The technique is simple and straightforward. The right side of the neck at the caudal extent of the lower mandible is prepared for surgery. A small incision is made through the skin, and the esophagus is identified. A moistened cotton-tipped applicator is inserted per os into the esophagus to aid in identification and to prevent the incision from penetrating the opposite side of the esophagus. A small (1 to 2 mm) stab incision is made into the esophagus to allow passage



**FIG 41.10** A pharyngostomy tube can be used to supply food to the proventriculus and bypass the oral cavity, esophagus and crop. 1) pharynx 2) tongue 3) trachea 4) tube in esophagus 5) crop 6) clavicle 7) coracoid and 8) proventriculus.

of a feeding tube. The tube is advanced into the crop or lower esophageal sphincter and sutured in place (Figure 41.10). A bandage is used to protect the site and to direct the tube to the dorsal cervical area away from the patient's field of vision. When it is no longer needed, the tube is removed, and the esophagus and skin defects are allowed to heal by second intention.

### ■ Oropharyngeal Abscesses

Oropharyngeal abscesses in birds frequently occur secondary to hypovitaminosis A (see Color 13). Abscessation occurs following squamous metaplasia and the development of a bacterial infection. These may be located at the base of the tongue, the intermandibular space, the choana, the pharynx or the larynx (see Color 8). These abscesses are often highly

vascular necessitating careful dissection and hemostasis for removal.

Surgical management of an oral abscess involves pretreatment with antibiotics and vitamin A (if indicated). A fine-needle aspirate may be used for culture and sensitivity. In cases of hypovitaminosis A, parenteral vitamin A administration will help encapsulate the abscess and reduce inflammation and vascularization. In some cases, beta carotene therapy has resulted in complete resolution of the abscess without the need for surgical intervention.

Abscesses that are lanced and curetted frequently recur because minute fragments of material may be located within the tissue surrounding the abscess. The abscess will reform when the mucosa heals over the trapped necrotic debris. Removing the tissue surrounding the abscess is preferable. In some locations, such as with intermandibular abscesses, the abscess and its capsule may be removed intact. Dissection is meticulous and time-consuming, and accurate hemostasis is imperative.

Choanal abscesses must be lanced to remove necrotic material followed by surgical removal of the abscess. Laser or radiosurgery are best for controlling hemorrhage in this highly vascular area. Invasive abscesses may erode the palatine artery and result in severe hemorrhage.

### ■ Oropharyngeal Papillomas

Oral papillomas are uncommon except in some macaw species. These masses can be removed using cryosurgery, radiosurgery or chemical cautery (silver nitrate). Papillomatous growths that extend into the crop and proventriculus are currently considered untreatable, and are eventually fatal.

### ■ Esophageal Perforation

Esophageal perforation may occur from using a rigid feeding tube for supportive alimentation in a struggling bird, in enthusiastic, violently bobbing neonates or from feeding overheated formula (see Color 30). As the tube penetrates the esophagus, food or medication may be deposited in the subcutaneous tissues (Figure 41.11). Additional material may accumulate during subsequent feedings. Edema, sepsis and toxemia occur in response to the foreign material. Emergency and supportive care should be instituted. A proventricular feeding tube should be placed to bypass the damaged esophageal tissue. Fasciot-

omy, copious irrigation, debridement, topical antiseptics and systemic antimicrobials are indicated. Surgical debridement and closure may be possible in three to five days when the affected tissues begin to granulate and appear healthy. Extensive fasciotomy and copious irrigation are probably the most important portions of the initial treatment.

### ■ Esophageal Strictures

A case of esophageal stricture of undetermined etiology in a Hyacinth Macaw was successfully treated by bougienage.<sup>56</sup> The stricture was located in the thoracic esophagus and was believed to be obstructing the flow of ingesta to the proventriculus. Initially a 5 Fr rubber feeding tube was the largest bougie that could be inserted. Three sessions of bougienage separated by a few months produced an increase in lumen size to accommodate an 11 Fr bougie. Attempts to pass larger tubes produced an intense vagal response. Following this treatment, the patient was able to eat solid food. No steroids were administered; however, the owner instituted therapy involving nonsteroidal anti-inflammatory medications (ibuprofen and naprosyn).

### ■ Crop Fistula Repair

The primary function of the crop is storage of food. When the crop is full of food, it is often prominent and pendulous, making it more susceptible to trauma.<sup>16</sup> Penetrating wounds can result in the formation of a fistula in the crop. Such wounds are often the result of animal bites, improperly assisted feeding technique, foreign body ingestion, trauma and consumption of excessively hot food items.<sup>16</sup> A permanent fistula may form because food will pass continuously from the crop through the defect in the crop and skin and out into the environment (see Color 30).

Crop fistulae occur most commonly in neonates being hand-fed. The crop of neonates is more fragile and susceptible to injury than the adult ingluvies.<sup>16</sup> One source of injury to the neonatal crop is penetration resulting from improper or careless gavage tube-feeding. This allows food to escape from the esophagus or crop and collect under the skin, creating an abscess and potential toxemia. Early diagnosis and treatment are essential for optimum recovery.<sup>1,16,25</sup> Crop burns may also occur if a hair dryer is used to dry a wet bird.<sup>1</sup> Crop burns most frequently occur when food is warmed in a microwave oven and not thoroughly mixed.<sup>1,4,25</sup> Microwave ovens do not heat



**FIG 41.11 a)** A 15-week-old Blue and Gold Macaw chick that was still being tube-fed was presented with a soft, mobile swelling of the right lateral neck area and thoracic inlet. The bird was depressed, regurgitating and losing weight. **b)** An esophageal tear that was allowing food to collect subcutaneously was located in the mid-neck area. The skin tissues overlying the accumulated food were excised, and the subcutaneous tissues were flushed with copious amounts of warm LRS. Penrose drains were placed to facilitate flushing of the subcutaneous tissues.



food uniformly and generate areas where the food is excessively hot.

Crop burns may be small or very extensive. Immediate treatment consists of removing the hot food and replacing it with cool water.<sup>25</sup> The patient should be placed on antifungal medication and a systemic antibiotic. Small frequent feedings should be used to minimize the stretching force placed on the crop. Small burns may not be noticed immediately and may develop fistulae. Birds with crop burns may present in the acute phase when it is difficult to determine the extent of the injury, or in the chronic stage when a well developed fistula is present.

Chronic crop fistulae are generally easier to deal with than acute crop burns (Figure 41.12). Because a fistula has developed, the serosa of the ingluvies and the skin have healed together as one tissue. These must be separated using scissors to circumferentially excise the edge of the fistula. Using meticulous dissection, the tissue plane between the ingluvies and the skin is identified and separated. The skin is normally adherent to the crop, being attached by two layers of striated muscle that form a sling-like support for the diverticulum of the crop.<sup>1,37</sup> Once the two tissues are separated, closure is as described for ingluviotomy. It is important to repair the crop as a

separate structure from the skin to minimize the chance of dehiscence, which is more likely to occur if the two are closed as one tissue. Placement of a tube from the mouth through the crop into the distal esophagus or into the proventriculus will aid in identifying the crop lumen.

In some cases, the crop may develop a defect while the skin remains intact,<sup>16</sup> causing an accumulation of food in the subcutaneous space that may be misdiagnosed as crop stasis (Figure 41.11). The affected skin should be opened, the subcutaneous tissues debrided, the crop and esophagus closed and the skin defect managed as an open wound. The wound should be evaluated periodically and debrided of any food material or necrotic tissue accumulates. Once the subcutaneous tissues are healthy, the skin defect may be closed or it may be left to heal by second intention.

Cases of acute crop burn are significantly more challenging than chronic crop injuries. Severe cases of crop burn may be fatal as a result of metabolic changes, sepsis and absorption of toxins from necrotic tissues. Initial treatment should be supportive and should include shock therapy, broad spectrum antibiotic therapy and antifungal medication. In cases of severe burns with significant edema, fasciotomy may be beneficial.<sup>13</sup> The affected area should be

liberally opened, copiously irrigated and left to heal by second intention or a delayed closure performed at a later date. In less severe cases, clinical signs may simply be consistent with a “sick bird:” lethargy, anorexia and fluffed appearance.<sup>16</sup>

The feeding regimen will need to be changed in order to bypass the damaged tissues. This can be accomplished using a needle catheter intestinal feeding tube<sup>11</sup> or by tube-feeding directly into the proventriculus. It is important to instruct the owner on proper methods for tube-feeding, and it must be stressed that the proventriculus cannot hold the same volume of food as the ingluvies; therefore, feedings will be more frequent and of smaller volume.

In most cases, it will be three to five days before the delineation between healthy and devitalized tissues becomes apparent,<sup>1</sup> and it may take as long as 7 to 14 days.<sup>45</sup> Prior to this, it will be difficult to determine what tissue should be removed and what is viable and should remain. Burned tissue becomes pale and edematous and then becomes dry, dark and leathery. Eventually, the devitalized tissue will separate from viable tissue and the edges of the crop and skin will heal together, forming a fistula (see Color 30).

Any tissue that is obviously necrotic should be debrided to reduce the body’s burden of necrotic tissue. If a skin and crop defect result from this debridement, this defect can be used to intubate the proventriculus for nutritional support and also to cleanse and apply topical antiseptics to reduce the chances of developing fungal or bacterial infections.

The definitive correction should be postponed until approximately five days after the injury when the demarcation between healthy and devitalized tissue is apparent.<sup>1</sup> It is often beneficial to endoscopically examine the crop prior to planning the surgery. A small catheter can be used to inject air and dilate the crop, and an endoscope can be used to detect avascular, darkened areas. It is important to evaluate the entire crop, because devitalized mucosa may occur away from the primary burn. The aboral extent of the crop at the thoracic inlet is a location where devitalized areas are often missed.

At surgery, all necrotic tissue must be removed and the tubular structure of the esophagus and ingluvies reestablished. In some cases this may be very challenging, as major portions of crop may be devitalized. If possible, the length of the crop should be maintained even if only a thin strip of esophageal tissue remains. Esophageal strictures are more likely to

occur if a resection and anastomosis have been performed than if a thin strip of normal esophagus is preserved and allowed to granulate over a stent. If enough viable tissue remains, it may be sutured around a pharyngostomy feeding tube, through which the patient can receive alimentation while the crop is healing. The crop will stretch in time, but the patient must be fed frequently small volumes of soft or liquid diets until the capacity of the ingluvies increases.<sup>1</sup> Where indicated, a Penrose drain may be placed to provide postoperative local drainage and may also be used for wound irrigation.<sup>16</sup>

In cases where there is extensive tissue loss, the defect may be allowed to heal by second intention while maintaining the patient with a pharyngostomy feeding tube. If the defect is so large that wound contraction cannot occur, a dermoplasty may be performed once there is a healthy bed of granulation tissue. A rotating skin flap will generally provide tissue to cover the defect.

### ■ Inguvotomy

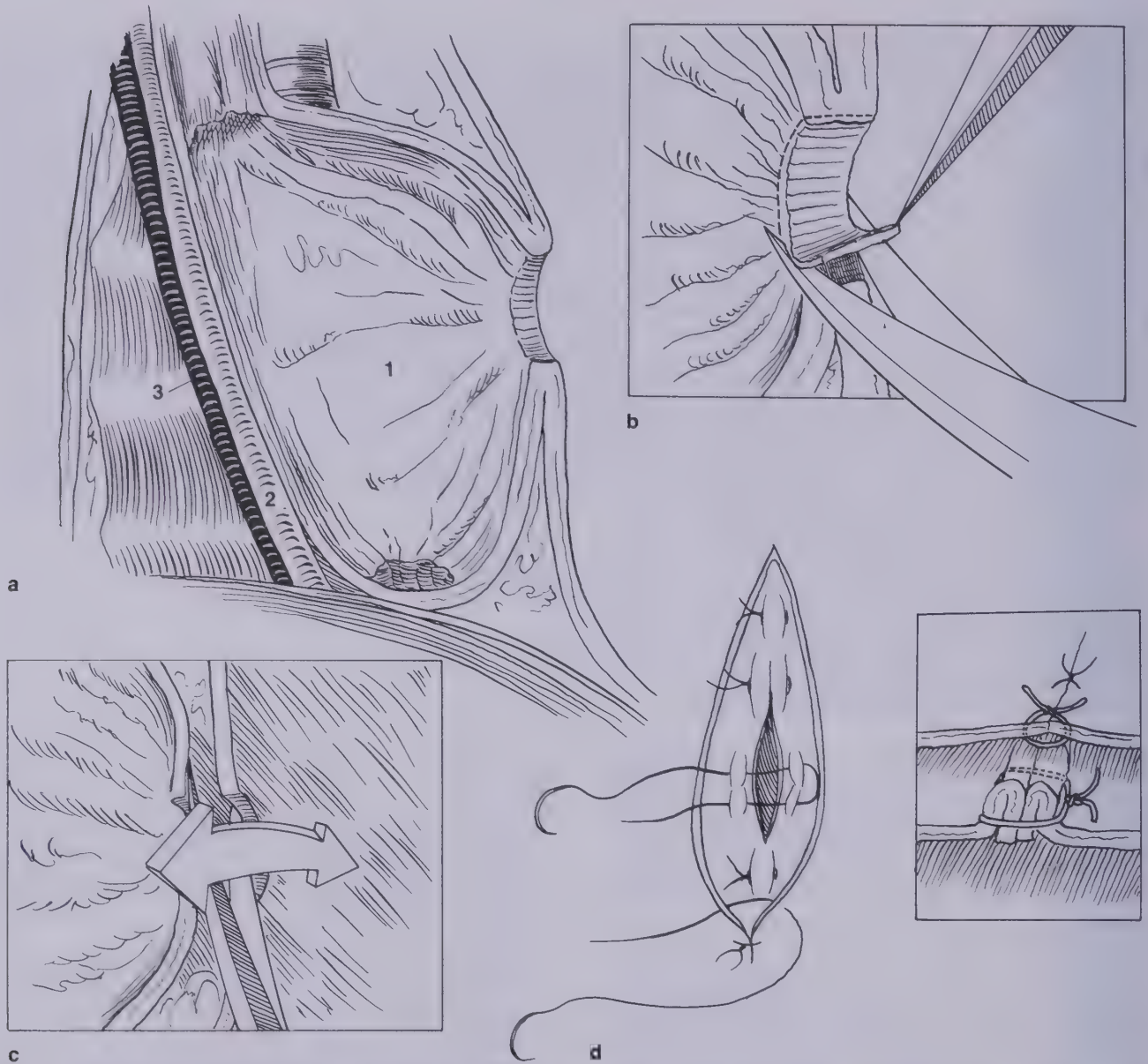
Neonates are susceptible to ingestion of foreign objects such as substrate materials, especially if they are underfed. Feeding tubes, small toys and unhulled seed may also be ingested.<sup>4</sup> These objects may interfere with the passage of food and may irritate the lining of the ingluvies.<sup>4</sup> Palpation of a persistent lump in the crop, food retention, delayed crop emptying and regurgitation are clinical signs associated with crop foreign bodies.

Small objects may be retrieved from the crop using a flexible endoscope and a biopsy instrument. Many foreign bodies including feeding tubes can be pal-

## CLINICAL APPLICATIONS

### How to Repair a Crop Fistula (Figure 41.12)

- Intubate the patient and pack the esophagus with moistened gauze to prevent flush solution from entering the pharyngeal area.
- Remove any necrotic tissue and thoroughly clean the underlying bed of granulation tissue with a dilute chlorhexidine solution.
- Once the tissue defect is thoroughly cleaned, debride the edges of the fistula to remove granulation tissue and completely separate the crop from overlying skin.
- Separate the skin and crop further by careful blunt dissection with strabismus scissors.
- Perform the closure in two layers. The crop is initially closed with an inverting suture pattern making certain that the incision line extends past the defect on both ends. The skin can be closed in a simple interrupted pattern.

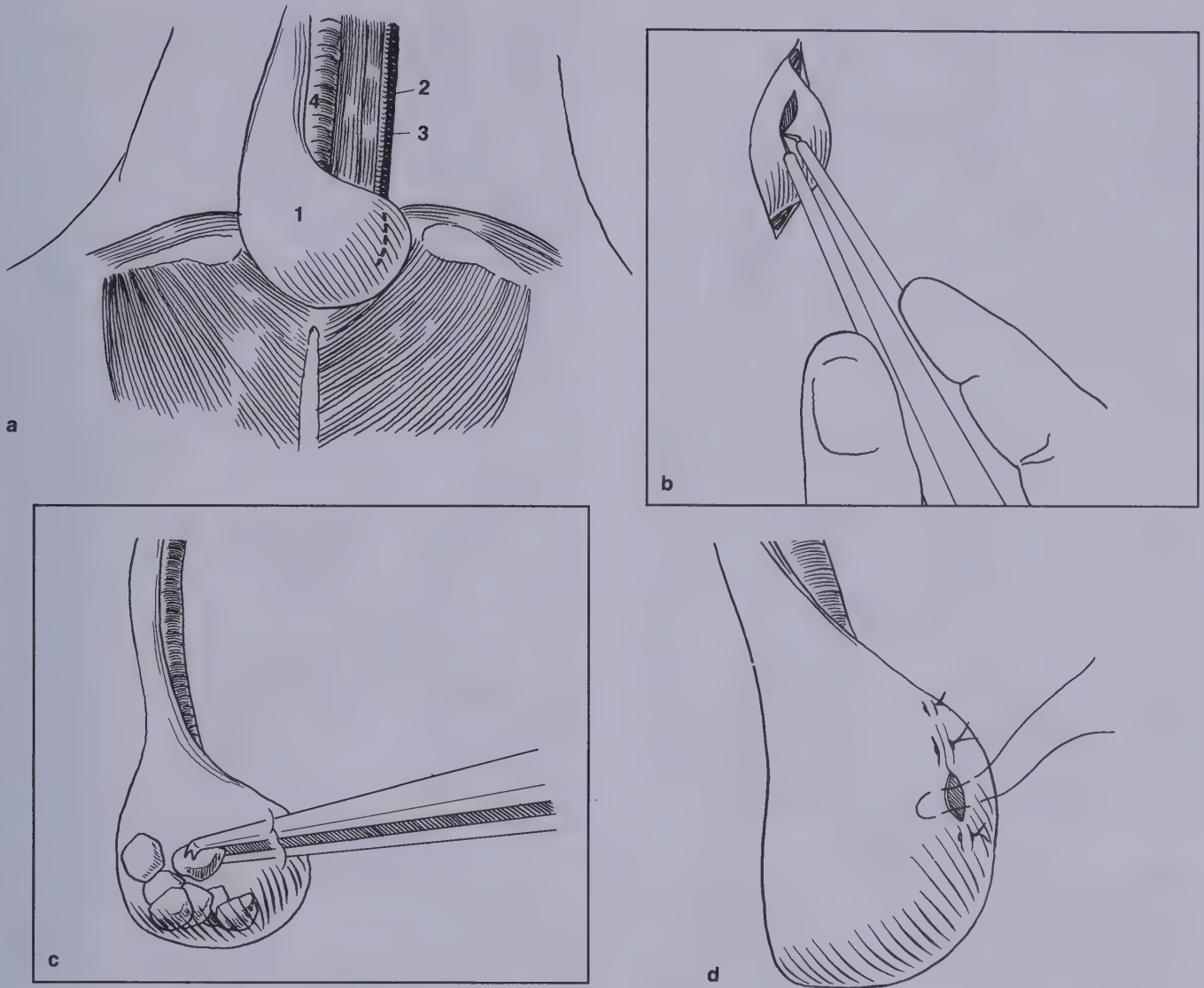


**FIG 41.12** Crop burns frequently result in the formation of fistulas that must be surgically repaired. The surgical closure of a burn should be delayed as long as possible to allow the body to differentiate between healthy and devitalized tissue. **a)** Fistula in the crop. **b)** The wall of the fistula is debrided and **c)** the skin and crop are separated by blunt dissection. **d)** The crop is sutured with an inverting suture pattern and the skin is closed with a simple interrupted pattern. 1) crop 2) internal carotid artery and 3) jugular vein.

pated and removed using a hemostat. Instilling a dilute water-soluble lubricant into the crop may help prevent iatrogenic injury to the crop and esophageal wall.<sup>25</sup> If the object is to be digitally manipulated out the pharynx, traction on the head can be used to stretch the neck, allowing the object to be pushed into the pharynx. This is not as easy as it sounds, and care must be taken to prevent iatrogenic injury to the crop, esophagus and mouth.<sup>4</sup>

Indications for ingluviotomy include foreign body removal,<sup>1,29</sup> placement of a feeding tube and gaining endoscopic access to the proventriculus and ventriculus.<sup>55</sup> To perform an ingluviotomy (Figure 41.13), the patient is positioned in dorsal recumbency with the head elevated and the esophagus occluded with moist cotton to prevent fluids from refluxing into the oral cavity. An incision is made through the skin, only over the cranial edge of the left lateral sac of the crop. The skin incision can be made using a radiosurgical





**FIG 41.13** Inguviotomy may be indicated to remove foreign bodies or to gain endoscopic access to the proventriculus and ventriculus. **a)** A skin incision is made over the left lateral portion of the distended crop. **b)** A sharp incision is made into the crop. Specific bleeding can be controlled with radiosurgery, but the incision in the crop should not be made using this unit. **c)** Foreign materials can be removed with forceps or by flushing with dilute chlorhexidine. **d)** The crop and skin are closed in separate layers. 1) crop 2) internal carotid artery 3) jugular vein and 4) trachea.

unit. This area of the crop is less subject to stress as the crop fills and is out of the path of a feeding tube. Because of the ability of the ingluvies to stretch, the incision should be made only about half the size necessary to accomplish the procedure; however, having adequate exposure is more important than having a small incision, and retrieval of large foreign bodies through small ingluviotomy incisions should not be attempted. The crop generally heals without complication. The crop incision should be made with a blade in an avascular area. Radiosurgery should be used to seal only specific vessels. Use of the radiosur-

gical forceps will result in unnecessary tissue trauma. The opening can be enlarged as needed. The incision is closed using an inverting technique with an absorbable material swaged on an atraumatic needle. Two-layer inverting patterns are frequently recommended;<sup>4</sup> however, one layer of simple continuous appositional sutures over-sewn with an inverting pattern is effective and is less compromising on the size of the crop lumen. The crop may be inflated with saline or air to check for leakage prior to skin closure. Foreign bodies can be removed manually or impacted material can be removed by flushing.

## ■ Celiotomy

Surgical approaches to the abdomen involve invasion of the air sac, allowing anesthetic gas to escape through the celiotomy site. This effect can be minimized by packing the borders of the incision with saline-moistened gauze sponges. Additionally, an air sac cannula may be introduced into the abdominal air sac on the side contralateral to the surgical incision. This will allow anesthetic gas to enter an intact air sac, pass through the lung and out the trachea. Using this technique, anesthetic gas does not escape from the surgery site, and waste gas can be scavenged from the trachea. For any celiotomy, the patient should be positioned with the cranial part of the body elevated 30 to 40° to prevent irrigation fluids from flowing cranial and entering the lungs following incision of the air sacs. Similarly, patients with ascites should have the fluid removed from the coelomic cavity prior to opening the air sacs. Moistened cotton may be placed in the caudal pharynx to occlude the esophagus and prevent proventricular reflux from entering the oral cavity and causing aspiration pneumonia. The celiotomy approaches used for access to the avian abdomen include left lateral, ventral and transverse. Skin incisions can be made in varying arrangements and combinations depending on the surgical procedure and the degree of abdominal exposure that is required (Figure 41.14).

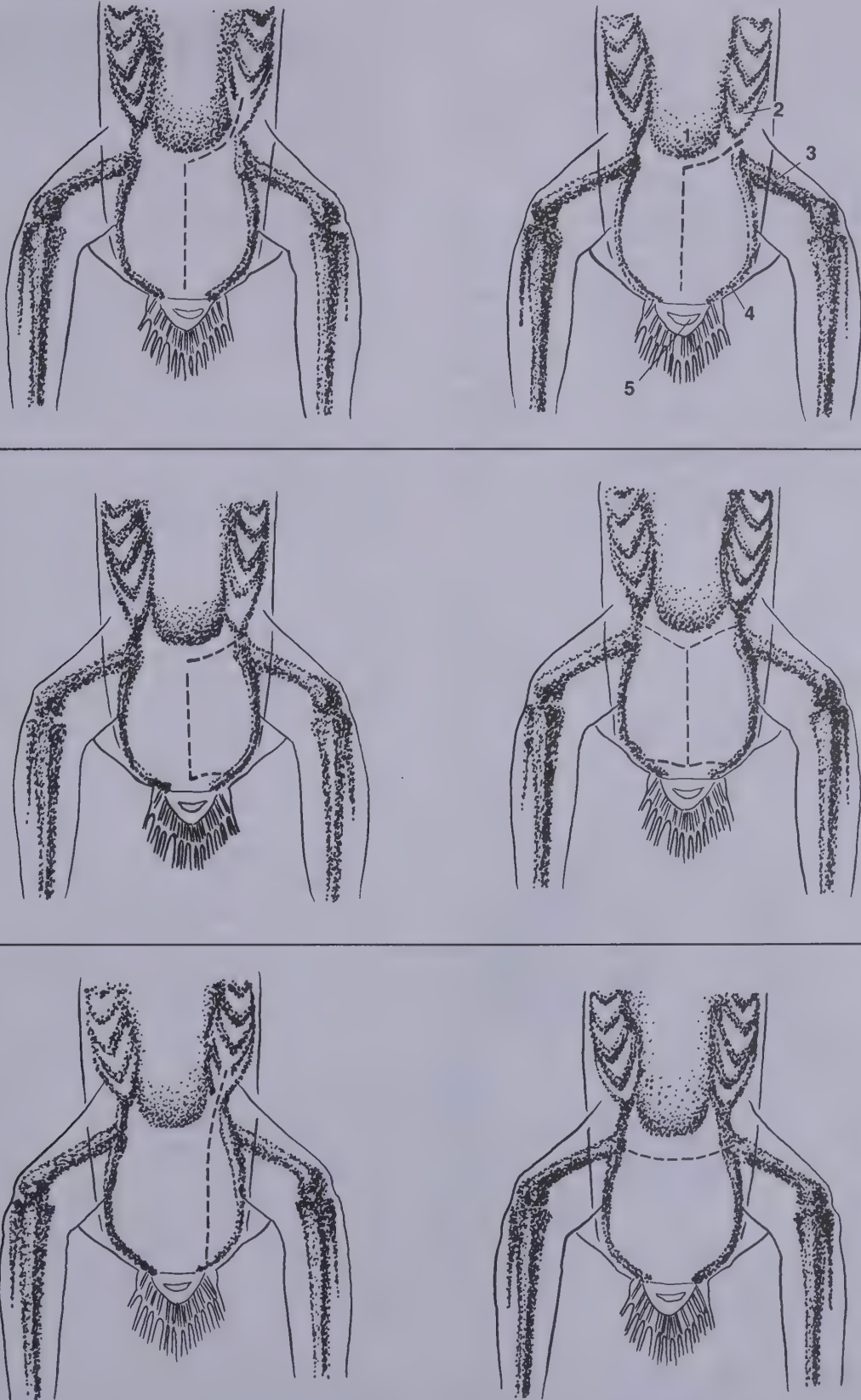
### Left Lateral Celiotomy

A left lateral celiotomy provides the best exposure of the proventriculus, the ventriculus, the female reproductive tract and the left kidney (Figure 41.15).<sup>16,24</sup> With the patient in right lateral recumbency, the caudodorsal border of the sternum can be palpated. The pelvic bones, including the cranial extent of the pubis, should be identified. The left leg should be retracted as far caudally as possible, creating a fold of skin (knee web) in the flank extending from the stifle to the lateral margin of the sternum. In small patients, lung tissue can be visualized per cutaneously through the intercostal spaces between the fifth, sixth and seventh ribs. In larger birds, the latissimus dorsi and iliobtibialis cranialis muscles obscure visualization of the lung. The skin incision will extend from the cranial extent of the pubis to just dorsal to the uncinat process of the fifth or sixth rib. The incision is started in the knee web and continued ventral and caudal following the boundaries of the postventer and postlateral regions, passing through the groove of the groin web caudally to the region of the pubic bone. Care should be taken to incise only the skin, which is easily accomplished using the

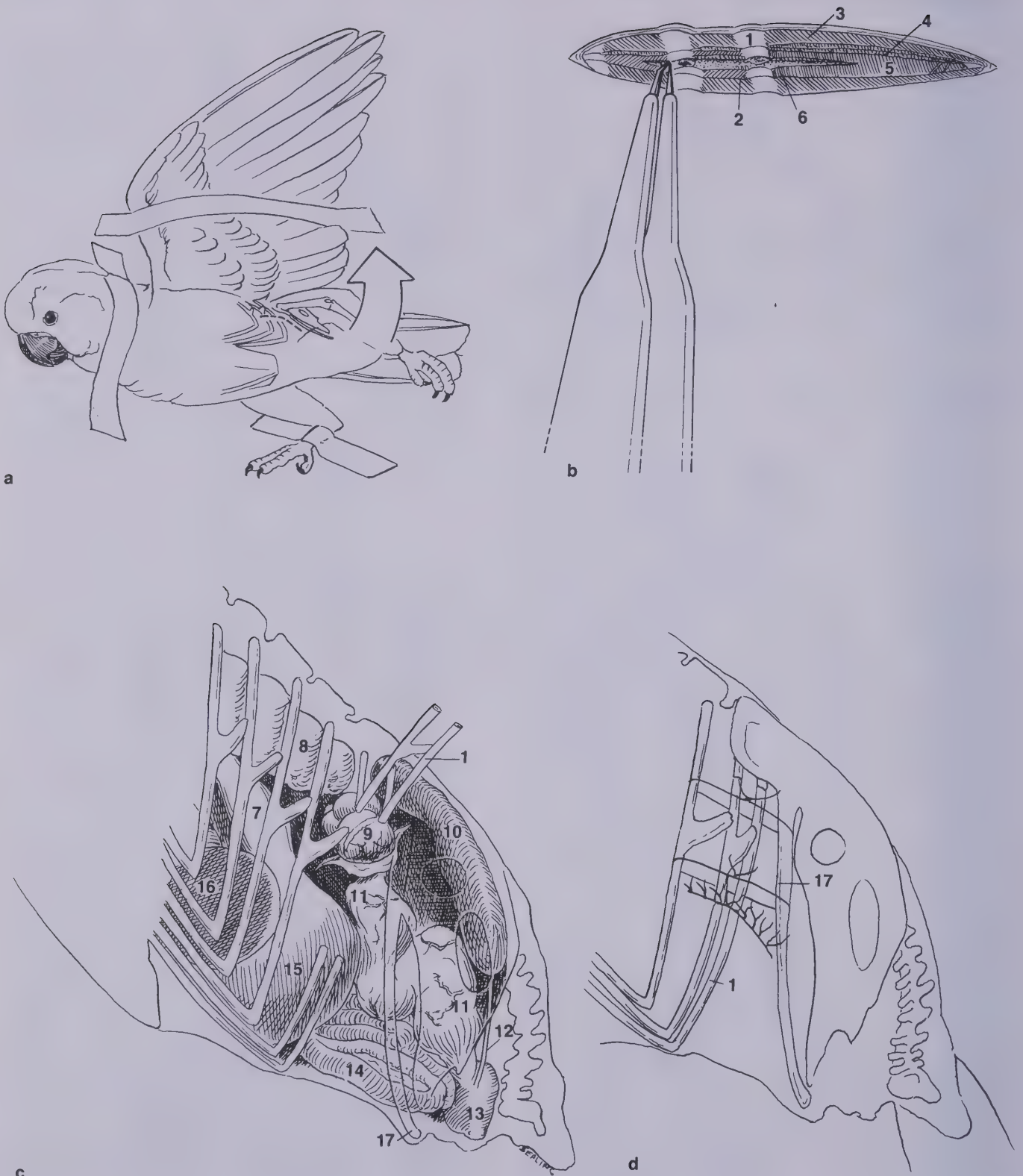
modified bipolar radiosurgical forceps. Once the skin is incised, the left leg may be further retracted caudally and somewhat dorsally to expose the abdominal wall. A branch of the superficial medial femoral artery and vein should be identified passing over the lumbar fossa toward the pubis. These vessels should be sealed or ligated prior to incising the musculature. The radiosurgical body wall incision is initiated in the external abdominal oblique muscle, just caudal to the last rib. The incision is extended caudally through the internal abdominal oblique and transversus abdominis muscles to the cranial extent of the pubis.

The intercostal vessels coursing along the cranial border of the last two or three ribs should be ligated or coagulated. In small birds, these vessels may be sealed by inserting the indifferent electrode inside the thoracic wall, lightly opposing the electrodes, withdrawing the electrodes until the cranial aspect of the rib is encountered, then activating the electrodes. In larger birds, it is best to cut the rib, clamp the vessel cranial to the rib to achieve hemostasis, then identify the vessel visually and apply a hemostatic clip. In larger birds, the caudal-most two or three ribs will need to be transected at their dorsal and ventral extents and removed to achieve adequate visualization of the viscera. In small birds, excision of the ribs may not be required. They may be fractured and retracted dorsally to provide proper exposure. This method is preferred, because closure of the incision is easier. Once the incision is made through the musculature, the shiny surface of the caudal thoracic or the abdominal air sac is visualized. In some patients, the lung extends caudally as far as the seventh rib. Care must be taken to prevent lacerating the lung, which can be gently elevated using a moistened cotton-tipped applicator if necessary.

A Heiss, Alm or mini-Balfour retractor should be positioned to maintain retraction of the body wall. Entering the air sac, the surgeon can visualize the lung parenchyma and the hilus of the caudal thoracic air sac entering the lung at its craniodorsal extent. Dorsally, the liver lobes become thin at their margins, and the wall of the proventriculus can be observed. If the abdominal air sac is entered instead of the caudal thoracic air sac, the lung is not visible, but will lie dorsolateral to the incision rather than cranial as observed when entering through the caudal thoracic air sac. Medially, the proventriculus can be seen suspended by the air sacs and suspensory ligaments. Often the intestines are the first structures encountered. They can be gently retracted using a cotton-



**FIG 41.14** Several different celiotomy incisions can be used to gain access to the abdomen of birds. 1) sternum 2) eighth rib 3) femur 4) pubis and 5) vent.



**FIG 41.15** a) To perform a left lateral celiotomy, the bird is placed in right lateral recumbency, the leg is retracted caudally and a skin incision is made as shown. b) The intercostal vein and artery on the edge of the ribs are coagulated using bipolar radiosurgery. c) This approach provides the best access to the proventriculus, ventriculus, female reproductive tract and left kidney. d) Closure of the skin and muscles can be facilitated by placing sutures between the rib and the pubis to reduce pressure on the incision line. 1) eighth rib 2) intercostal artery, vein and nerve 3) external oblique muscle 4) internal oblique muscle 5) transversus abdominis muscle 6) air sac 7) proventriculus 8) lung 9) ovary 10) kidney 11) oviduct 12) ureter 13) cloaca 14) intestine 15) ventriculus 16) liver and 17) pubis.

tipped applicator. The intestines are fragile and should not be manipulated with toothed forceps, which will create severe bruising and potential perforation. Once the intestines are retracted caudally, the kidney may be identified at the dorsomedial aspect of the coelom. The ovary or left testicle should be encountered at the cranial division of the kidney. The adrenal gland is located between the gonad and the cranial division of the kidney, but may be obscured if the gonad is large. Obesity and hepatomegaly result in topographical changes in the abdominal anatomy, emphasizing the need to practice on a variety of cadavers with a variety of conditions prior to performing a celiotomy in a clinical patient.

If the seventh and eighth ribs have been removed, closure will require the placement of tension sutures from the abdominal musculature to the sixth rib. Sutures passed around the pubic bone may be necessary when closing large incisions.

#### Ventral Midline Celiotomy

A ventral midline celiotomy is used primarily for surgery of the small intestines, liver biopsy, egg-related peritonitis, abdominal masses, egg binding and repair of a cloacal prolapse. This approach provides access to both sides of the coelomic cavity.

The skin is incised in the midpostventer region from the sternum to the interpubic space (see Figure 41.14). The linea alba is usually broad and easily identified. It must be incised carefully because the duodenum crosses from left to right just inside the body wall. It is best to initiate the incision between the pubic bones over the cloaca. Once a two millimeter incision is initiated, it may be extended cranial to the level of the sternum. If exposure is limited, the incision may be extended to one or both sides approximately two millimeters from the sternal border creating a muscular flap. Further exposure is achieved by extending the incision along one or both sides of the pubic bones in a similar fashion. This approach provides the best exposure to mid-abdominal masses, uterine masses and generalized abdominal disease (peritonitis). The size of the incision should be sufficient to allow a procedure to be performed, but as small as possible to minimize tissue damage and air sac disruption, and to make it easier to maintain anesthesia. If it is necessary to approach a large area of the abdomen, it is often best to open and close each area before proceeding on to another area.

Closure of the body wall is accomplished using simple interrupted or simple continuous, monofilament, synthetic, absorbable suture material. Skin closure is routine.

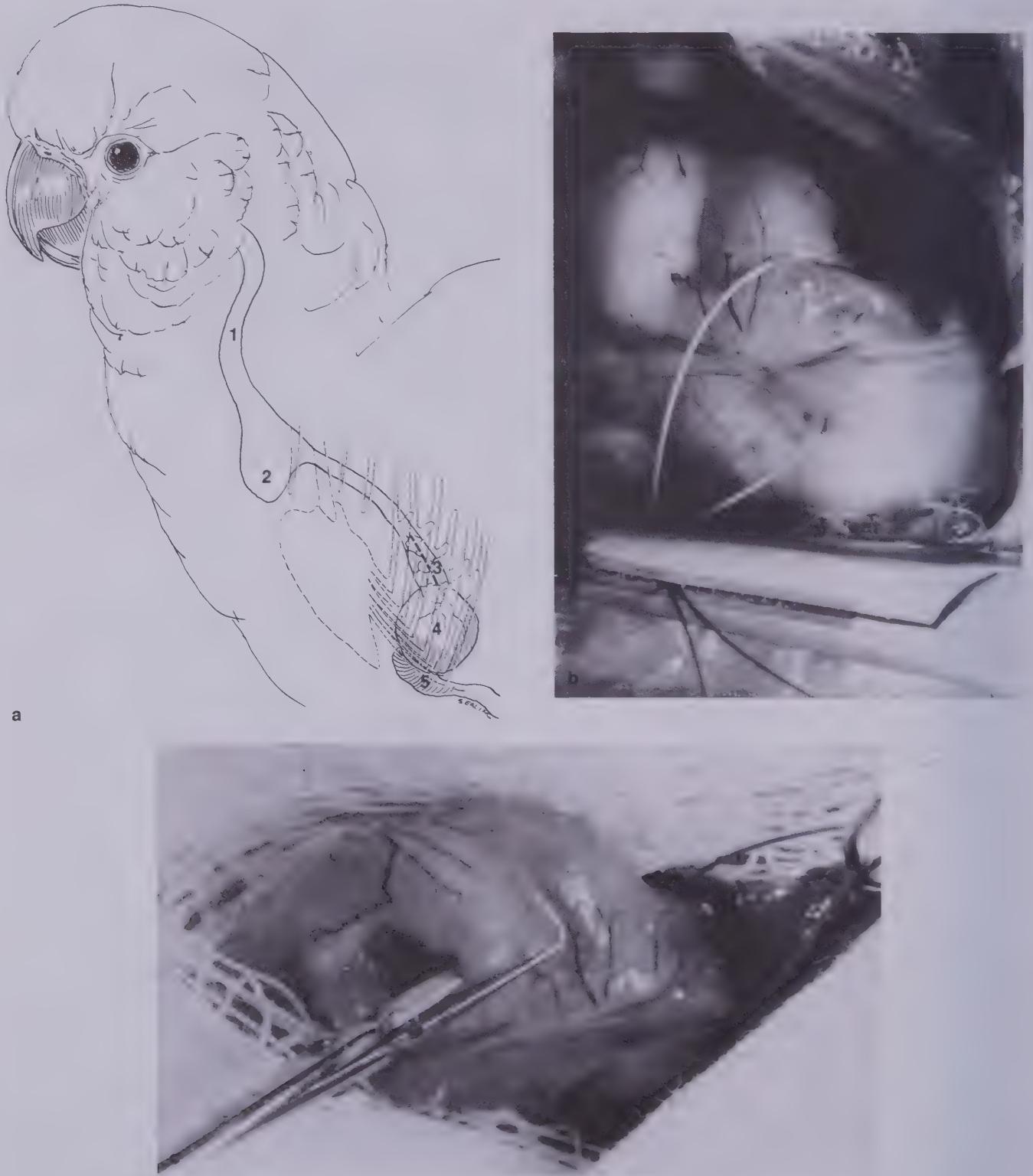
#### Transverse Celiotomy

Transverse celiotomy provides exposure to a large area of the abdomen.<sup>1,24,51,53</sup> The bird is positioned in dorsal recumbency and the postventer region is prepared. A transverse skin incision is made midway between the sternum and the vent (see Figure 41.14).<sup>1</sup> The abdominal wall is lifted and incised with care to avoid lacerating the underlying intestines. The ventriculus and duodenum are the first organs encountered, but may be reflected to expose the cranial aspect of the cloaca, the middle and caudal lobes of the kidneys and the lower reproductive tract of hens. The abdominal wall and skin are sutured separately using 4-0 to 6-0 synthetic, monofilament, absorbable material in a continuous or interrupted pattern.

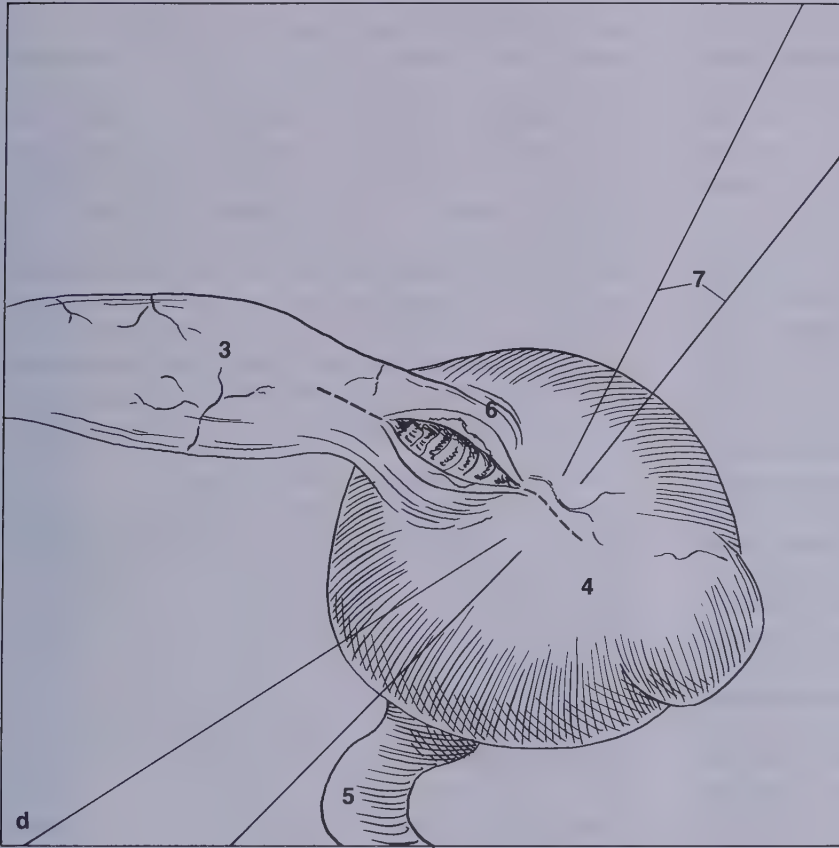
#### Proventriculotomy and Ventriculotomy

The stomach of birds is divided into an orad, glandular portion (the proventriculus) and the aborad muscular ventriculus (gizzard). The isthmus or intermediate zone separates these two structures, and the pylorus controls the emptying of ingesta from the ventriculus into the duodenum. In carnivorous birds, the crop is underdeveloped so the bird relies on the stomach for digestion and as a storage organ. These birds often have a large, thin-walled stomach with a poorly developed isthmus and little distinction between the proventriculus and ventriculus. The proventriculus tears easily when excessive tension is applied. The ventriculus is composed of dense muscle and fascia and holds sutures well, but is more difficult to seal with suture and cannot be inverted.

Proventriculotomy is most often indicated for the removal of foreign objects or toxic materials (such as lead or zinc-containing coins) from the proventriculus or ventriculus that cannot be retrieved using rigid or flexible endoscopes.<sup>10</sup> A definitive diagnosis of neuropathic gastric dilatation requires a ventricular biopsy, although there are some discussions that biopsies of the crop may provide similar information. In an Umbrella Cockatoo that had ingested sticks, the proventriculus was determined to be distended based on radiographs.<sup>21</sup> The tentative diagnosis of neuropathic gastric dilatation could not be confirmed by biopsy of the ventriculus. Several pieces of glitter and 72 small green sticks were surgically removed. Although techniques for ventriculotomy have been de-



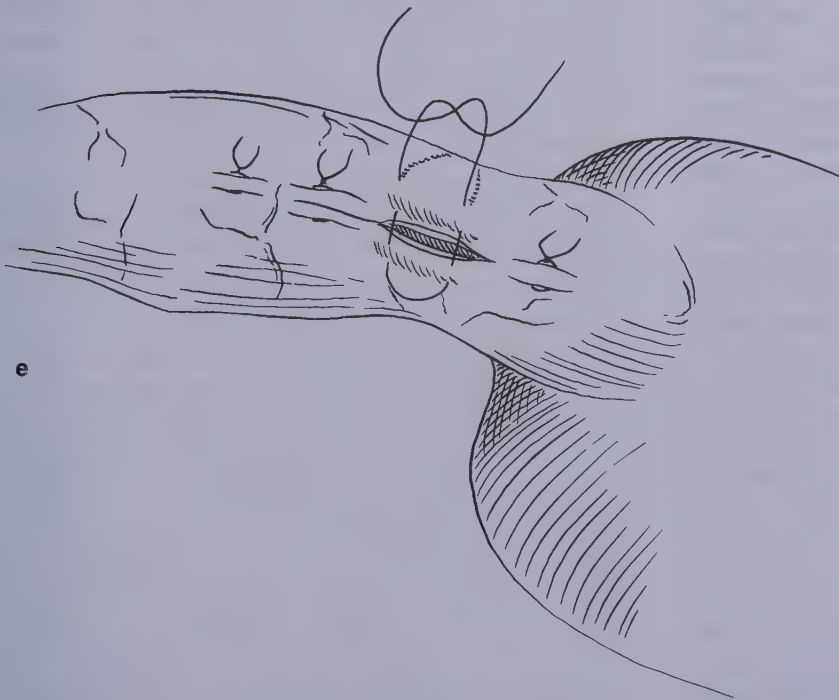
**FIG 41.16** a) A proventriculotomy is indicated in patients with foreign bodies that cannot be removed by lavage or endoscopy. The proventriculus is approached through a left celiotomy incision site as shown. b) Stay sutures can be placed in the ventriculus (not the proventriculus) to improve control over the position of the organ. c) The incision into the proventriculus should be made with a blade and extended into an avascular area with scissors. Note that stay sutures are used to exteriorize the proventriculus, and the abdomen has been isolated with moistened gauze pads. (*continued next page*)



scribed they are generally avoided because of the vascularity and slow healing characteristic of this organ.<sup>1,5,6,10,22</sup>

A left lateral celiotomy approach will provide exposure of the ventriculus and proventriculus (Figure 41.16). The ventral suspensory structures are bluntly dissected to allow the proventriculus to be retracted caudally. The proventriculus in some birds is quite fragile and toothed forceps should be avoided. Stay sutures may be placed in the ventriculus to aid with exteriorization and manipulation of the proventriculus. Stay sutures should not be placed in the proventriculus. The coelomic cavity should be packed off with moist gauze sponges to prevent contamination of the abdominal cavity with gastric contents.

The isthmus or intermediate zone is identified as a constriction between the ventriculus and the proventriculus. The vessels on the surface of the proventriculus are easily identified and avoided. The proventriculotomy incision is initiated at the isthmus and extends road into the body of the proventriculus. Hemorrhage from the cut edge of the proventriculus may be controlled using radiocoagulation. Thumb forceps may be used to gently clamp the cut edge to occlude the vessel, allowing it to be identified and appropriately coagulated. Proventricular contents should be removed using suction. Small spoons or curettes may be used to remove solid contents. A combination of irrigation and suction is useful to completely evacuate the proventriculus and ventriculus. A small diameter flexible endoscope may be used per os, or through the proventriculotomy to assure that all foreign objects have been removed.



**d)** Radiosurgical forceps should be used only for controlling hemorrhage and not for making incisions into viscera. **e)** Closure is routine, using an inverting suture pattern. 1) esophagus 2) crop 3) proventriculus 4) ventriculus 5) duodenum 6) isthmus 7) stay sutures.

The proventriculotomy is closed using a simple continuous appositional pattern of a fine, synthetic, monofila-

ment, absorbable material over-sewn with a continuous or interrupted inverting pattern such as a Cushing or Lembert pattern. The inverting pattern should extend beyond the actual incision to ensure an adequate seal. The closure may be evaluated for leakage using an orogastric tube to insufflate the proventriculus with air or sterile saline.

Food and water should be offered in the immediate postoperative period. The wound strength immediately following suture placement is stronger than during the debridement phase of wound healing, which occurs three to five days postoperatively. Unless one intends to withhold food until wound strength begins to increase again (the phase of fibroplasia), fasting for one to two days postoperatively is not indicated. Incisional leakage of gastric contents occurs with some frequency in birds.<sup>95</sup> The lack of an omentum may be partially responsible for this complication. Meticulous attention to proper closure is vital to prevent leakage. A small, atraumatic needle should be used with a continuous suture pattern to provide the best seal. If the proventricular wall appears thin and friable, the potential for postoperative incisional leakage may warrant placement of a duodenal feeding tube. This will allow enteral alimentation of the patient while bypassing the gastric incision.

The ventriculus is best approached through a proventriculotomy incision. The incision in the isthmus is extended aborad toward the ventriculus. The opening into the ventriculus can be gently dilated to allow the introduction of instruments appropriate for removal of ventricular contents. Some surgeons suggest that a ventriculotomy (transverse abdominal approach) is easier than a proventriculotomy (left lateral approach). The lighter-colored, elliptical area of the ventriculus, where the muscle is thin and the fibers can be seen to course in a different direction from the remainder of the ventriculus, is the location where the incision is made (see Anatomy Overlay).<sup>1</sup> The incision is made transversely across the muscle fibers into the lumen. At closure, sutures must be placed close together to prevent leakage, because a serosal seal cannot be created by using an inverting suture pattern.

### Intestinal Surgery

Surgery on the intestines may be necessary to repair an accidental enterotomy created during a ventral midline celiotomy or to debride necrotic bowel secondary to constrictions caused by adhesions (see Color 14). These cases generally carry a poor-to-grave prog-

nosis. A midline, flap or transverse celiotomy may be appropriate, depending on the location of the lesion. In most circumstances, microsurgical technique is indicated due to the extremely thin nature of the avian intestine. The blood supply to the small intestine is via the celiac artery (to the duodenum) and the cranial mesenteric artery (jejunum and ileum). The technique used to anastomose the bowel requires microsurgical manipulation of 6-0 to 10-0 monofilament suture on a one-fourth circle atraumatic needle. Typically, six to eight sutures are used for an end-to-end anastomosis in a simple interrupted appositional pattern. Side-to-side anastomosis may prove to be more appropriate in birds and is easier to perform.

### Intestinal Feeding Tubes

Enteral feeding tubes may be indicated for a variety of conditions in which a diseased portion of the alimentary tract must be bypassed to provide nutritional supplementation to anorectic and debilitated patients. A variety of medical and surgical conditions including crop infections, impaction, injury or inflammation, esophageal perforation or laceration, proventricular dilatation, beak disorders, pharyngeal disorders and any condition resulting in hypophagia or anorexia places a nutritional demand on the patient that may not be met by oral alimentation. Proper attention to the patient's nitrogen balance can make the difference between success and failure of therapy (see Chapters 15 and 40).

A technique for placement of a duodenostomy tube has been described in domestic pigeons.<sup>11</sup> Four of the five catheterized birds had minor weight loss after 14 days of total nutritional support through the enterostomy tube (4% to 10%). Within seven days of tube removal, all the birds had regained their normal weight.

The catheter is placed through a ventral midline incision. The ascending duodenum is easily identified by its close association with the pancreas (see Anatomy Overlay). A "through-the-needle" catheter (indwelling jugular catheter) is used with the needle passing first through the left abdominal wall, then into the descending loop of duodenum. The catheter diameter should be less than one-third the diameter of the intestine.<sup>11</sup> The catheter is advanced through the descending and ascending loops of duodenum (4 to 6 cm), and the needle is withdrawn from the intestine and body wall. One or two sutures are placed between the left body wall and the duodenum at the entry site of the catheter to secure the intestine to the body wall and allow a seal to form (monofila-



ment 5-0 prolene). The midline celiotomy is closed routinely.

The catheter is secured to the outside left abdominal wall using a "finger trap" technique. The needle is protected within its "snapguard," and the snapguard is bent to conform to the contour of the bird's body. The snapguard is then sutured to the skin to secure it in place. The catheter is brought caudal to the leg and under the wing. The excess is coiled and the catheter is secured to the lateral and dorsal body wall using two sutures. The catheter is flushed with saline to assure patency, and an injection cap is placed to create a sealed system for alimentation.

Once the caloric need is calculated (see Chapter 40), the amount of liquid diet required is calculated based on the caloric density of the diet (usually 1 ml = 1 kcal). A variety of liquid diets is commercially available and their compositions have been described (see Chapter 15).<sup>41</sup> The amount should be divided into equal volumes and injected four to six times daily at a rate of approximately 1 ml/15 seconds to allow the intestine to accommodate the volume. The catheter should be flushed with water or LRS (1 to 2 ml) before and after injection of the diet to prevent plugging.

The catheter should be maintained a minimum of five days to allow a seal to form between the intestine and the body wall.<sup>41</sup> If the catheter is dislodged prematurely, leakage of intestinal contents may occur. Once the catheter is no longer needed, the finger trap suture is cut, the catheter removed and the defect left to heal by second intention.

Hypertonic diets may cause osmotic diarrhea. Daily weight and biochemistry changes can be used to alter the volume and content of the liquid diet. Patients that have a tendency to disturb the catheter should be fitted with a neck brace.<sup>k</sup>

### ■ Cloacal Prolapse

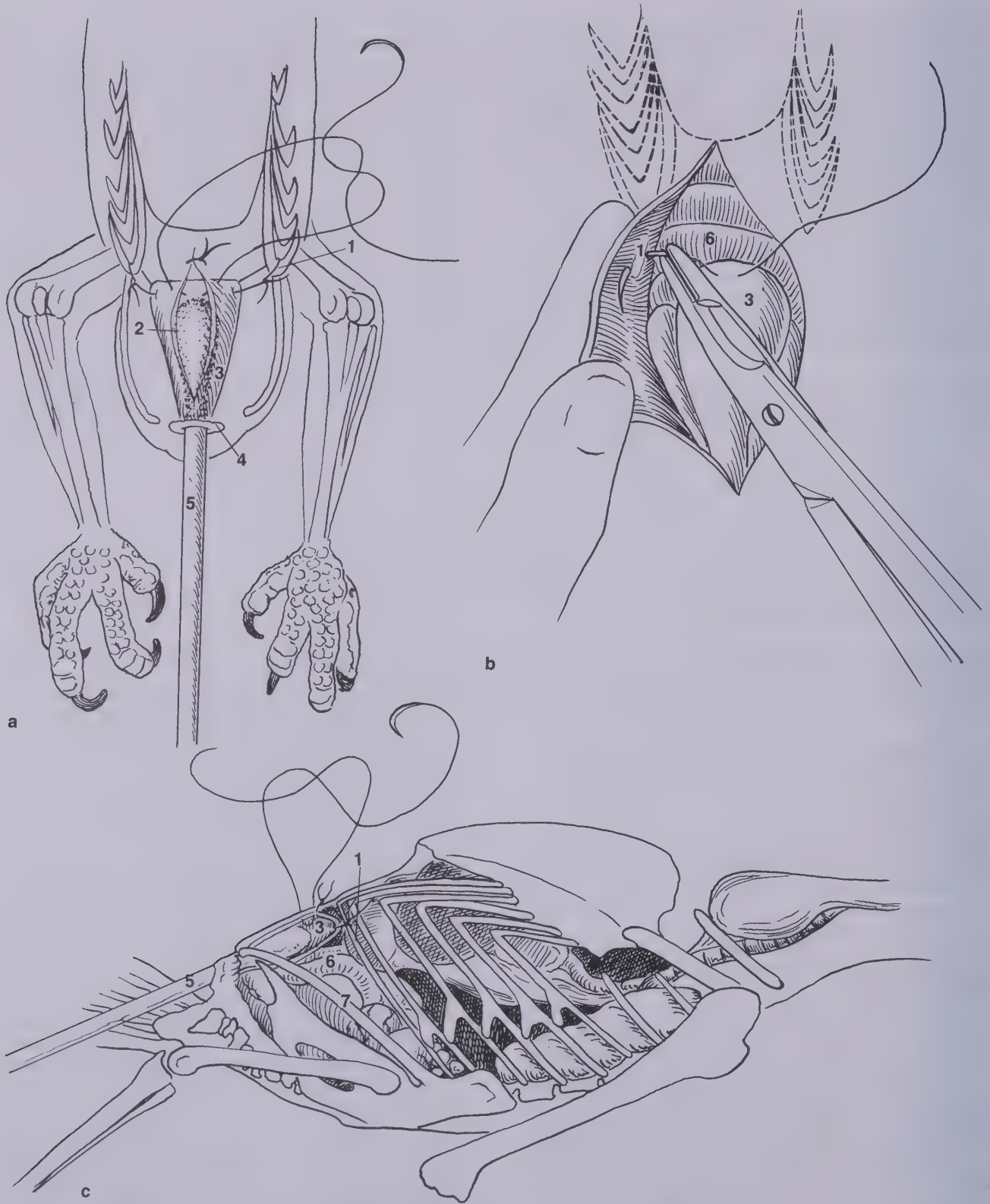
Cloacopexy is indicated to correct problems with chronic cloacal prolapsing. This condition appears to be most common in Old World psittacine birds, especially cockatoos, and is associated with reduced sphincter tone. Chronic gram-negative enteritis may be an initiating factor,<sup>2</sup> underscoring the need for cloacal cultures as part of the patient evaluation process. The attachments of the cloaca are damaged, allowing the entire structure to prolapse, which may cause occlusion of the ureters and colon. Minor prolapses may respond to placement of a mattress su-

ture on either side of the cloaca; however, when the entire organ prolapses, this method of treatment is ineffective. If mattress sutures are used, they must allow for the passage of droppings. An alternative method involves the placement of two sutures transversely across the vent. These must be placed close enough together to prevent recurrence of the prolapse, but far enough apart to allow the normal passage of droppings. These sutures may be left in place from a few days to several weeks depending on the clinical situation. Purse-string sutures are contraindicated due to frequent postsurgical cloacal atony secondary to nerve damage.

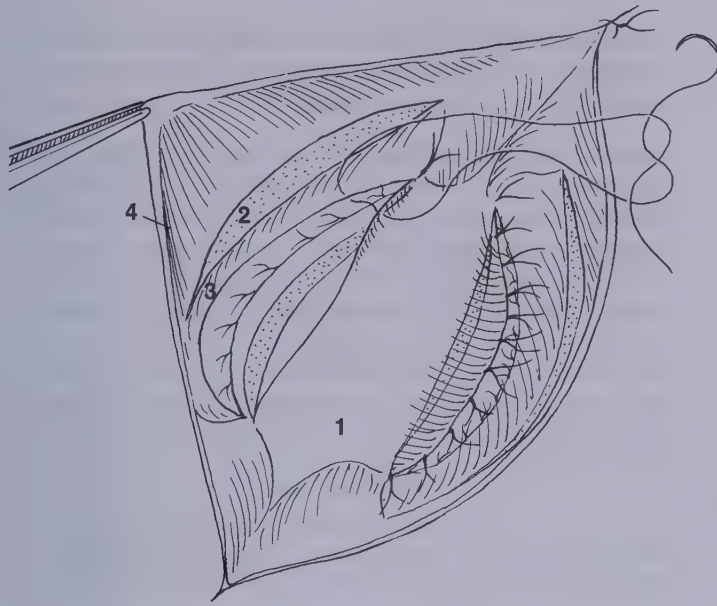
A percutaneous cloacopexy may be performed as a temporary or definitive treatment for cloacal prolapse.<sup>33</sup> The prolapse is reduced using a moistened cotton-tipped applicator. The applicator is maintained within the cloaca to help identify its limits, and two or three sutures are placed percutaneously through the skin, body wall and urodeum. The sutures should be removed in two to four weeks. This procedure carries the risk of inadvertently entrapping or perforating the ureters, rectum, duodenum and pancreas.

In some cases, prolapse is due to atony of the vent sphincter. This condition may be treated by surgically narrowing the vent opening. One-half to three-fourths of the margin of the circumference of the vent is incised to provide a cut surface for healing. Simple interrupted sutures are placed from one side of the vent to the other in order to partially close the opening. This will decrease the size of the vent opening permanently, preventing prolapse of the cloaca.

A rib cloacopexy is an effective treatment for severe cloacal prolapse.<sup>47</sup> A ventral midline celiotomy is performed and the cloaca is identified (Figure 41.17). This approach provides exposure to the entire cloaca and its associated structures. It may be necessary to use a moistened cotton-tipped applicator or the finger of a gloved assistant to reduce the prolapse and define its limits intraoperatively. Fat on the ventral surface of the cloaca should be excised. This appears to be crucial for a successful surgery.<sup>48</sup> The ribs are pushed caudally using the thumb, and the surgical incision is elevated with the index finger, bringing the ribs into view to facilitate suture placement. A suture is placed around the last rib on each side of the bird and passed through the full thickness of the ventral aspect of the cranio-lateral extent of the urodeum. The suture should be tied with enough tension to slightly invert the vent. Large sections of



**FIG 41.17** A rib cloacopexy is indicated to permanently correct chronic cloacal prolapse. **a)** The cloaca is pushed cranially with a moistened cotton-tipped applicator and sutures are placed between the cranio-lateral border of the cloaca and the eighth rib. **b)** Pushing the eighth rib caudally with a finger will help in the placement of sutures. **c)** Lateral view of the cloacopexy procedure showing the placement of the suture between the cloaca and the eighth rib, and the suturing of the cloaca to the abdominal wall during closure. 1) eighth rib 2) skin incision 3) cloaca 4) vent 5) swab 6) intestines and 7) pubis.

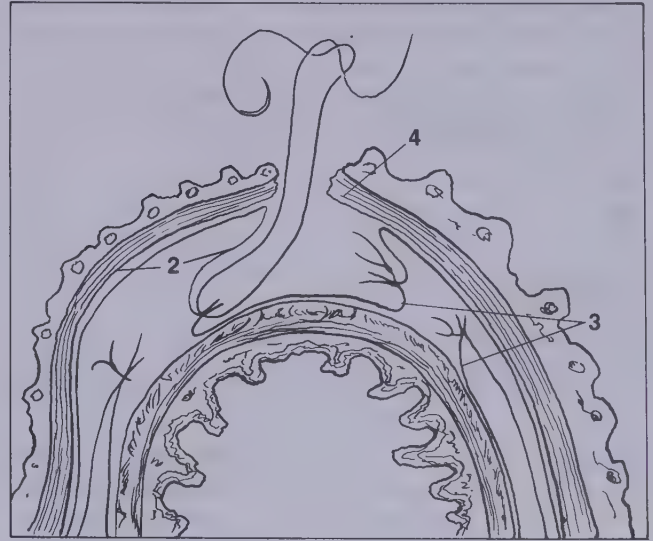


**FIG 41.18** An alternative cloacopexy technique is to make a ventral midline incision and place three or four sutures that appose the subserosal surfaces of the cloaca and internal body wall. 1) cloacal wall 2) pleuro-peritoneum 3) seromuscular layer of the cloaca and 4) body wall.

tissue must be used for suture placement, and it appears to be important to penetrate the cloacal lumen. Several other sutures are then placed between the body wall and the wall of the cloaca. The cloaca may be sutured to the caudal border of the sternum instead of the ribs, if the rib sutures place excessive inverting tension on the cloaca. This procedure may not be effective in birds with a thin-walled cloaca.

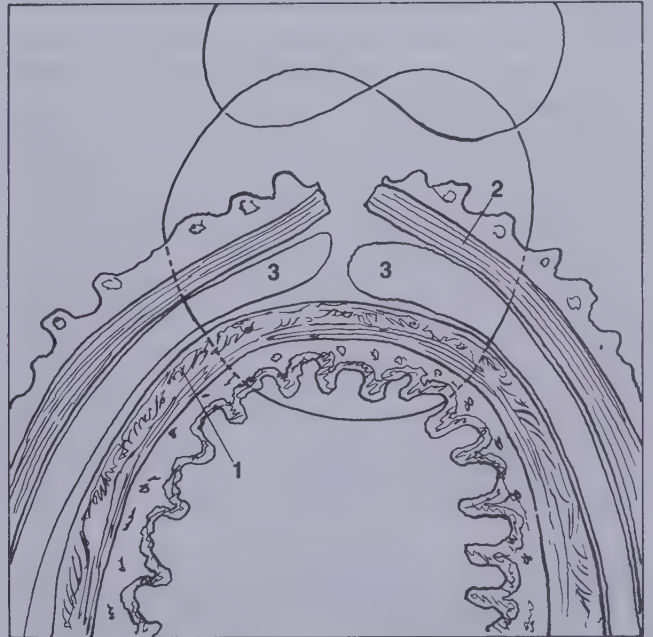
Another method for performing a cloacopexy has been described.<sup>23</sup> A 2 to 5 mm incision is made in the serosal surface of the coprodeum parallel to its length and 5 to 10 mm from the midline (Figure 41.18). A corresponding paramedian incision is made in the peritoneal surface of the body wall at a point that will maintain the cloaca in a position that will result in slight inversion of the vent. Three or four sutures are placed between each side of the two incisions such that the serosal surfaces are sutured and the subserosal surfaces of the two structures are apposed. This procedure is repeated on the contralateral paramedian side.

Alternatively, a routine ventral midline incision may be made, the cloaca reduced and the associated fat excised. The abdomen is closed incorporating the cloaca. The suture passes through one side of the body wall, through the full thickness of the cloaca and through the other side of the body wall in a



simple interrupted pattern (Figure 41.19). Skin is closed over this layer.

A transverse abdominal cloacopexy may provide more even distribution of tension than a ventral midline approach.<sup>2</sup> The transverse incision is made



**FIG 41.19** A simple cloacopexy technique that involves full-thickness suturing of the cloaca into a ventral midline incision may be effective in resolving mild cases of cloacal prolapse. 1) cloacal wall 2) body wall and 3) peritoneal cavity.

through the skin and abdominal musculature in the postventer region. The cloaca is incised to the level of the submucosa, and the seromuscular layer is then sutured to the incision in the abdominal wall. The abdomen and skin are closed routinely.

## Surgery of the Reproductive Tract

Surgery on the female reproductive tract is most often indicated in cases of egg binding, ectopic ovulation, soft-shelled eggs, congenital atresia of the oviduct, damage to the uterus, salpingitis, neoplasia, abnormal egg production, biopsy and culture of the oviduct and egg-related peritonitis.<sup>8,14,24,42,48,57</sup> Generally, only the left side of the female reproductive tract is functional. The right oviduct may become cystic in older fowl,<sup>43</sup> and this condition has been reported in a budgerigar (see Color 29).<sup>18</sup> A left lateral flap or ventral midline celiotomy approach may be used, depending upon which portion of the reproductive tract is to be evaluated.

### Egg Binding

Egg binding occurs commonly in companion birds and has been associated with a genetic predisposition, improper nutrition, atony of the uterus, oversized eggs, inexperience of the hen, tumors of the reproductive tract and extraluminal compression of the reproductive tract by abdominal masses.<sup>14,18,34,48,53</sup> In one case of egg binding, a cystic right oviduct was compressing the left reproductive tract, preventing normal migration of the egg.<sup>18</sup> Both oviducts were successfully removed, relieving the dystocia. In an Isle of Pines Amazon Parrot, an oviduct defect allowed deposition of uncalcified eggs into the abdominal cavity. Five eggs were successfully removed from the coelom. A hysterectomy was performed after two more eggs were deposited into the abdomen and surgically removed the following year.<sup>57</sup>

Egg binding in birds is most commonly the result of malnutrition. If the egg remains in the uterus (shell gland), it will continue to deposit shell material onto the egg, further lowering systemic calcium levels. Any bird presenting for egg binding should be evaluated for hypocalcemia prior to planning surgery, and

any abnormalities should be addressed. Medical management including ovocentesis should be attempted prior to considering surgical intervention.

Prolapse of oviduct or uterine tissue occurs with some degree of frequency in egg-bound birds, especially budgerigars and cockatiels.<sup>47,48</sup> It may occur following egg binding or from straining. The tissue may have been expelled through the vaginal opening into the cloaca and potentially externalized through the vent. As the tissue protrudes through the cloaca, it undergoes axial torsion, making it difficult to identify the lumen. Exposed uterine tissue becomes dry and necrotic within 30 to 60 minutes.

### Ovocentesis

If medical management of egg binding fails, ovocentesis and collapsing the egg may be successful. Under general anesthesia, the opening of the vagina into the cloaca is identified. A blunt probe is used to dilate the opening. Once the egg is visualized, a needle can be inserted into the egg to aspirate its contents. Following ovocentesis, the egg can be collapsed and the shell fragments removed (see Chapter 29). The vagina and uterus should be flushed repeatedly to verify that all egg material has been evacuated. It is prudent to reconstruct the egg to be certain that all shell fragments have been retrieved. Alternatively, a radiograph may be valuable to rule out the presence of another egg or remaining fragments.

If the lumen is not identifiable, the prolapsed tissue may be incised to deliver the egg. Once the egg is removed, the layers of uterine wall should be sutured with a fine (6-0 to 10-0) monofilament, absorbable material on an atraumatic needle in a simple appositional or inverting pattern. If the patient's condition permits, necrotic tissues should be excised and viable tissues reconstructed. With critical patients, the damaged tissue should be replaced into the cloaca after removal of the egg, and debridement should be postponed until the patient's condition improves. If an egg or shell fragments remain in the oviduct, a celiotomy is indicated.

If the egg is near or within the pelvic canal, it may be delivered using an episiotomy-type incision.<sup>33</sup> The incision is made on the ventral midline through the cloacal sphincter extending cranial through the urodeum. If necessary, the incision may extend into the uterus. After the egg is removed, the uterus and cloaca are closed with a simple interrupted or simple continuous pattern of a slowly absorbable material. Closure of the body wall and skin are routine. This is

a radical procedure and is indicated only in critical cases in which the hen is likely to die or the egg is of major importance for species propagational purposes.

In cases where the egg is lodged farther cranial in the oviduct, it may be best to perform a midline celiotomy, and hysterotomy may be the best technique for removing the egg. The hysterotomy incision should be closed with a simple appositional continuous or inverting pattern of a fine monofilament synthetic absorbable material. Postoperatively, hormone therapy or photoperiod regulation should be used to prevent subsequent laying until the hysterotomy has healed. If hysterectomy is indicated, a left lateral approach is preferred to gain access to the entire oviduct.

### ■ Salpingohysterectomy

This procedure involves removal of both the uterus (shell gland) and the oviduct; therefore, the term salpingohysterectomy is most appropriate. Although hysterectomy is the term commonly used to refer to this procedure, the ovary is not removed. Salpingohysterectomy is indicated to terminate pathologic egg laying, alleviate egg binding, remove an infected or ruptured oviduct and to treat a prolapsed oviduct and recurring egg-related peritonitis.

Salpingohysterectomy carries a significant degree of risk and is generally not recommended as a preventive measure. Although cockatiels continue to have copulatory, nesting, territorial and egg-laying behavior following salpingohysterectomy, there is no evidence that problems related to the deposition of yolks into the abdomen occur.<sup>14,34</sup> Presumably, a hormonal feedback loop from the uterus to the ovary prevents follicular development and release of ova.<sup>15,33,48</sup> In a retrospective study of 30 birds on which salpingohysterectomy was performed, five were evaluated laparoscopically several months postoperatively.<sup>34</sup> Follicular development was noted; however, no large follicles were observed. Continued yolk release with subsequent yolk-related peritonitis was reported in a California Quail and a duck following routine salpingohysterectomy.<sup>48</sup>

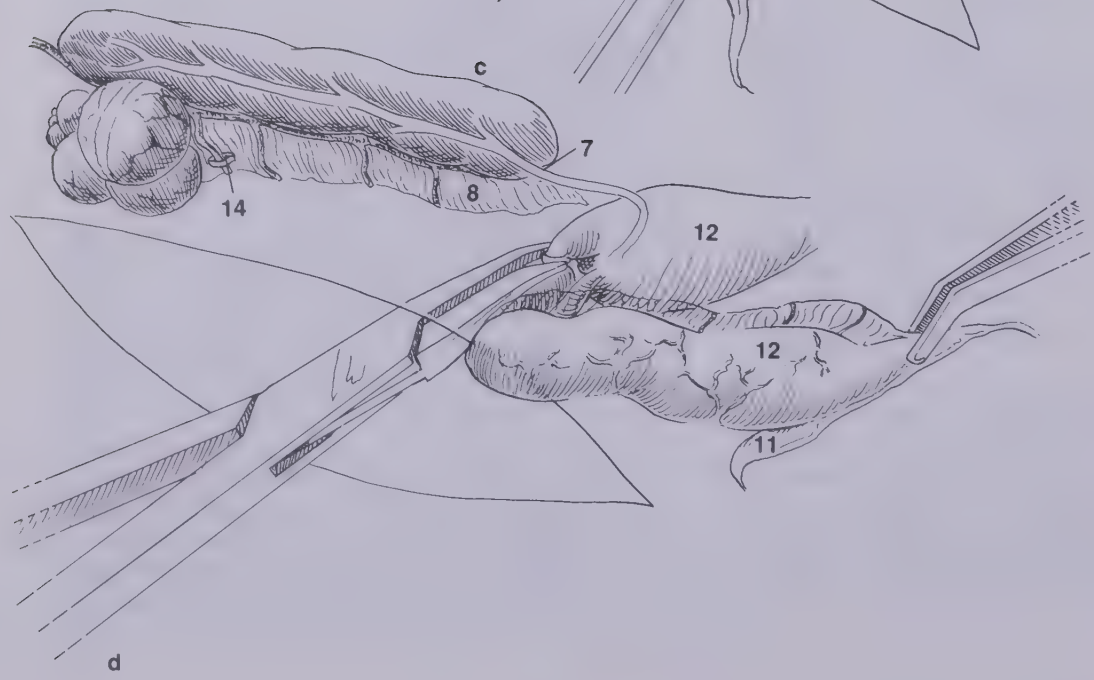
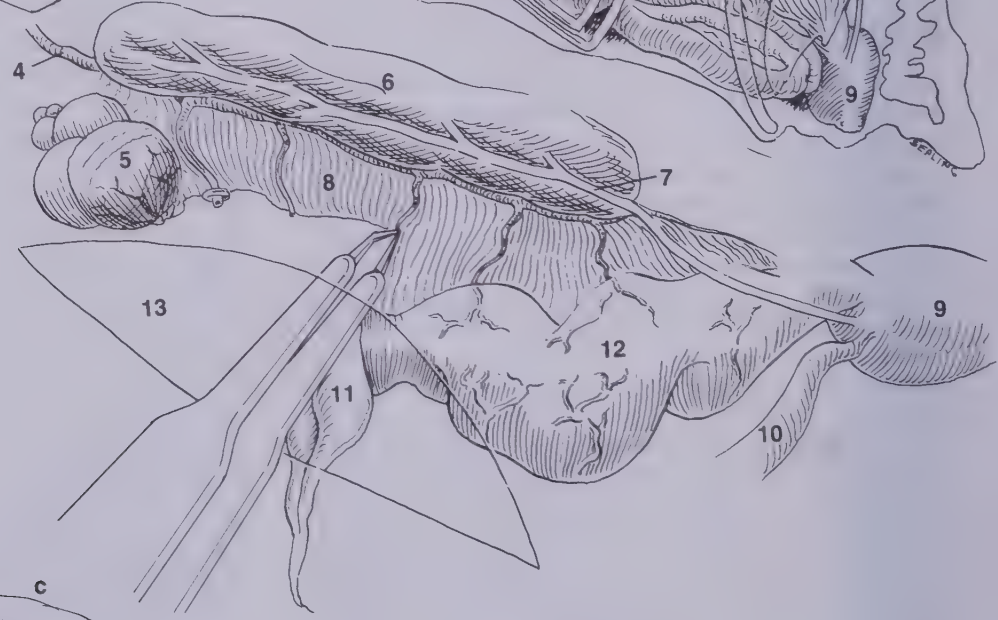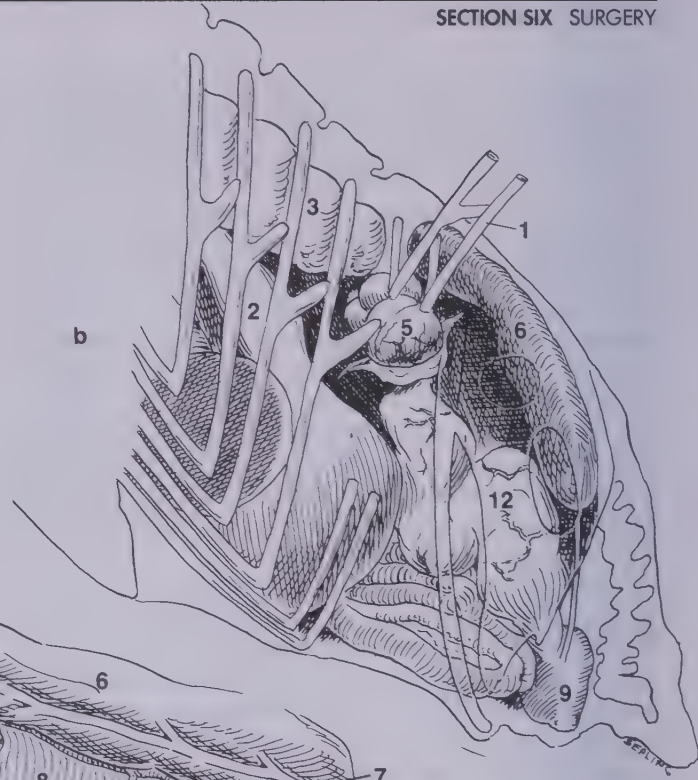

The size of the oviduct and uterus varies with the reproductive and physiologic status of the patient. The reproductive tract of a cockatiel that is not in breeding condition is narrow (2 to 3 mm). A bird in poor condition may also have a small, inactive ovary. A young bird in good condition with exposure to a

male may have a well developed ovary with large follicles and a large reproductive tract.

Salpingohysterectomy may be accomplished through a left lateral celiotomy (Figure 41.20). The ovary may be visualized following lateral and ventral retraction of the proventriculus. The oviduct and uterus lie convoluted along the dorsal aspect of the body cavity. The oviduct is identified and elevated away from the large caudal vena cava. Minor damage to this vessel will result in life-threatening hemorrhage. The ventral ligament causes the convolutions in the uterus and oviduct. The ligament courses caudally and collects as a muscular cord at the vagina. There are no vessels in this ligament, and it should be dissected to allow the oviduct and uterus to be stretched into a linear configuration.

The fibria of the infundibulum lie caudal to the ovary and may be elevated to expose the dorsal attachments. At the base of the infundibulum and coursing caudally along the uterus, the dorsal ligament suspends the uterus and a branch of the ovarian artery. A small blood vessel can be identified coursing from the ovary through the infundibulum. This vessel should be coagulated or a hemostatic clip should be applied to control hemorrhage. If it is inadvertently transected or broken, it will retract under the ovary in a virtually unretrievable location. A small piece of absorbent gelatin sponge<sup>8</sup> may be packed against the ovary to achieve hemostasis. The remainder of this suspensory structure may then be dissected with the bipolar radiosurgical forceps.

Once the infundibulum is free, the oviduct is retracted ventrally and caudally, exposing the dorsal suspensory ligament. Several small blood vessels, branches of the ovarian artery, can be seen in this structure perpendicular to the oviduct and uterus. These should be identified and coagulated. Each vascular stump should be inspected for residual hemorrhage before closure. As this dissection is continued caudally toward the cloaca, the ureter can be identified as a white tubular structure extending from the kidney to the cloaca. This structure should be avoided. As the dissection approaches the cloaca, the uterus courses along with the terminal colon and enters the cloaca (see Anatomy Overlay). The uterus should be ligated at its junction with the vagina by placing one or two hemostatic clips a short distance from the cloaca. In cases where the vaginal tissue has been damaged, the clips may be applied at the cloaca, being careful not to entrap the ureter. The clips should be secure with the entire width of the uterus



within the clips to prevent leakage. If the clips become dislodged or do not completely occlude the uterus, feces and urates may reflux into the abdomen.

### ■ Egg-related Peritonitis

Egg-related peritonitis occurs most commonly in cockatiels, budgerigars, lovebirds, ducks, gallinaceous birds and macaws (see Color 29).<sup>48</sup> Diagnosis is made by clinical signs, hematology, radiography, abdominocentesis and laparotomy. A severe inflammatory response is typical of the hemogram.

Mild cases may respond to antibiotic therapy and supportive care (see Chapter 29). Surgical intervention is usually necessary to resolve severe cases.<sup>33,48</sup> In some cases, surgery should be postponed and the patient treated medically until the condition stabilizes. A ventral midline celiotomy is preferred because fluids are easily drained out the incision rather than down into the air sacs, and potentially into the lungs. Once the celiotomy is performed, the intestines should be retracted using moistened cotton-tipped applicators or other suitable atraumatic instruments. Any yolk or tissue debris should be removed. The cavity should be copiously irrigated prior to closure. Implantation of Penrose drains may be indicated in some cases, but do not generally provide adequate coelomic drainage. This condition warrants a guarded-to-poor prognosis. Birds that recover frequently have abdominal adhesions, distention and muscular dysfunction.

### ■ Removal of the Gonads

Carbon dioxide laser destruction of gonadal tissue has been attempted; however, the procedure is very time-consuming and costly, and controlling damage to surrounding tissues, especially the adrenals, is very difficult. Removal of the gonads with laser in companion birds is often followed by severe hemorrhage either intraoperatively or postoperatively.

Alternatively, the vascular supply to the ovary may be destroyed using vascular clips, but this is a diffi-

cult procedure, performed without being able to visualize vital structures. Microsurgical equipment is essential. Clients should be informed that this procedure is extremely difficult and the possibility of complications is higher. The patient should be treated medically to reduce the size of the ovary and improve visualization. Through a left lateral celiotomy, the ovary is identified. A hemostatic clip is applied dorsal to (under) the ovary to occlude all ovarian vessels. In small birds, one clip applied from a caudal to cranial direction is adequate. Two clips, one from a cranial direction and the other from a caudal direction, may be required for large birds. Angled appliers should be used to place the clips under the ovary parallel to the spine, which reduces the possibility of inadvertently entrapping the aorta or peripheral nerves.

### ■ Orchidectomy

Neutering a male is theoretically easier than neutering a female because the testicles are not as adherent to deeper structures as the ovary, making clip application easier and safer. However, orchidectomy must be performed bilaterally, making a ventral approach more applicable than a left lateral approach. The placement of vascular clips is similar to that described for the ovary. Orchidectomy in companion birds is extremely difficult and many birds do not survive the surgery.

A technique for orchidectomy in ostriches has been described.<sup>49</sup> The procedure is indicated to control aggressive behavior in birds that present a danger to keepers, handlers, the public or other birds. The surgical approach is through the costal notch and lumbar fossa on each side. The skin and body wall are incised adequately to allow introduction of a gloved hand. The testicle on the corresponding side is palpated, grasped and twisted until it is torn from any attachments. It is recommended that the procedure be performed at the onset of breeding season when the testicles have begun to increase in size so they can be easily located. If performed during the breeding season, excessive hemorrhage may result from avulsion of the hypertrophied testicular vascular supply. Body wall, subcutaneous tissue and skin are closed routinely. The procedure can be accomplished through a single, lateral celiotomy incision if the surgeon has hands small enough to reach through to the contralateral testicle. Minor postoperative subcutaneous emphysema and occasional incisional dehiscence are the only reported complications.

**FIG 41.20** (opposite) **a**) A salpingohysterectomy is performed through a left lateral celiotomy incision and is indicated to terminate pathologic egg laying and to prevent egg-related peritonitis secondary to a diseased oviduct. **b**) Regional anatomy for salpingohysterectomy. **c, d**) Hemostatic clips are shown passing through a left lateral celiotomy incision to provide a more realistic impression of the visibility through the incision site. 1) eighth rib 2) proventriculus 3) lung 4) aorta 5) ovary 6) kidney 7) ureter 8) suspensory ligament of oviduct 9) cloaca 10) rectum 11) infundibulum 12) oviduct 13) celiotomy incision and 14) hemclip.

## Miscellaneous Surgical Procedures

### Abdominal Hernias

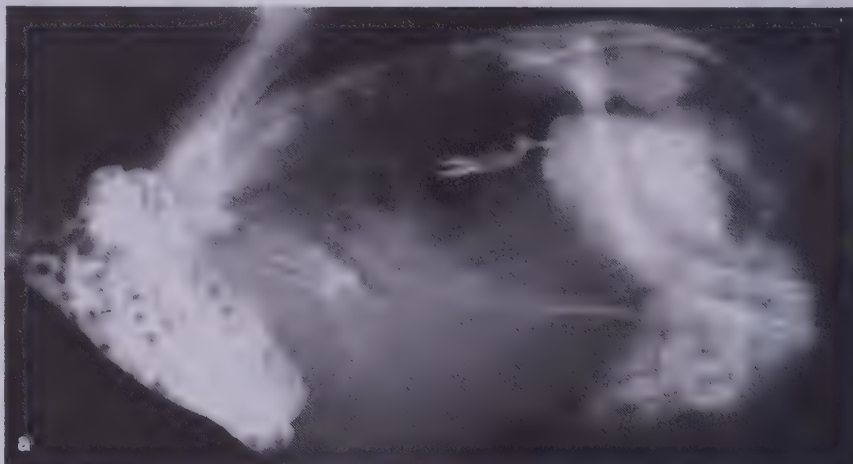
Abdominal hernias in birds may be congenital or acquired. They are characterized by a separation of the aponeurosis of the abdominal musculature at the ventral midline. This gives the bird a pot-bellied appearance with the abdominal viscera visible directly beneath the skin (Figure 41.21). Abdominal hernias frequently develop in female budgerigars and cockatiels, which may be related to a hormone imbalance causing a weakening of the abdominal muscles.<sup>40,48</sup> It has been suggested that altered calcium metabolism in chronic egg-laying hens may contribute to muscular atony and over-distention in the caudal abdomen near the cloaca.<sup>32</sup>

In most cases, the hernia is of little clinical consequence. The defect in the body wall is large with little risk of organ entrapment. As a result, herniorrhaphy may carry more risk than the potential benefit. Because of the extensive system of air sacs (on which birds rely heavily for respiration), efforts to close the body wall defects frequently result in respiratory compromise. In birds with chronic or large hernias, the resulting respiratory compromise can be life-threatening. As closure proceeds caudad, the abdominal viscera are forced cranial. This results in compression of the thoracic and abdominal air sacs. In these cases, a mesh implant should be considered. If the hernia is small or acute, primary closure may be successful.

Herniorrhaphy is necessary if secondary clinical problems such as cloacal urolithiasis or egg binding occur. A fusiform section of skin and urodeum was excised and the body wall closed to repair a hernia containing urate concretions in a cockatiel. The hernia recurred, but a second surgery was not attempted, and the owner was instructed to manually express urates out of the cloaca as needed.<sup>32</sup>

### Abdominal Masses

Surgical excision may be considered for treatment of neoplastic diseases of birds.<sup>3,54</sup> Removal of abdominal tumors is rarely successful. Their removal requires meticulous attention to detail, strict hemostasis with blood transfusions and a prolonged anesthesia time, predisposing the patient to hypothermia and severe metabolic compromise. Carbon dioxide laser surgery shows the greatest promise for removal of neoplasms.



**FIG 41.21** a) An adult African Grey Parrot hen was referred for surgical removal of an egg that was thought to be causing a distended abdomen. On physical examination, a sizable abdominal swelling that was soft and contained palpable tubular structures was identified. Contrast radiography indicated that the hen had an abdominal hernia. b) The hernia was repaired using a surgical mesh to add strength to the damaged abdominal wall.



### ■ Lipomas

Lipomas are frequently the expression of obesity. Central necrosis and ulceration may occur. Some lipomas are covered by xanthomatous skin. Efforts should be made to reduce the size of the mass medically before attempting surgical extirpation. Diet and exercise are effective over a period of several months. Lipomas are generally well encapsulated and shell out easily.

### ■ Leg Amputation

When a leg must be amputated, it is best performed at mid-femur. If the stump is too long, the bird may continue to use it for ambulation, causing trauma and granuloma formation to the stump. A mid-femoral amputation allows adequate soft tissue coverage of the end of the bone and prevents the patient from traumatizing the surgical site. Because the majority of the femur is contained within the skin of the body wall, a mid-femoral amputation is also cosmetic. Most companion birds with one leg are able to function normally. Psittacine birds compensate particularly well because they use their beak as an aid to ambulation. Pododermatitis of the contralateral foot, as occurs commonly in raptor amputees, is rarely a problem in companion birds on a formulated diet.

The skin incision should be made along the knee web to conform to the contour of the abdomen. A semicircular incision is created both medially and laterally at about the level of the stifle. This will allow adequate skin for tension-free closure. The muscles should be transected at the stifle. Use of the radioscissors will aid in hemostasis. The muscles are elevated from the femur to the mid-diaphyseal region using a periosteal elevator. The ischiatic nerve should be injected with lidocaine or bupivacaine prior to transection for temporary postoperative analgesia. The femur may be cut with a bone cutter, an osteotome, a gigli wire, a sagittal saw or other suitable instruments appropriate for the patient's size. Following the osteotomy, the muscles are sutured over the end of the bone to provide padding. Subcutaneous tissues and skin are closed routinely.

### ■ Toe Amputation

Indications for toe amputation include avascular necrosis, trauma and infection. Hemostasis is aided by the use of a tourniquet. Hemostatic agents should be avoided. The heavily keratinized scale surfaces may be gently debrided exposing the more supple epider-

mis below. This improves tissue handling for suture placement. The site of amputation should be at the joint proximal to the affected area. The skin should be incised distal to the joint to provide adequate skin for closure (Figure 41.22). A hydroactive dressing will promote healing and prevent contamination (see Chapter 16).

### ■ Wing Amputation

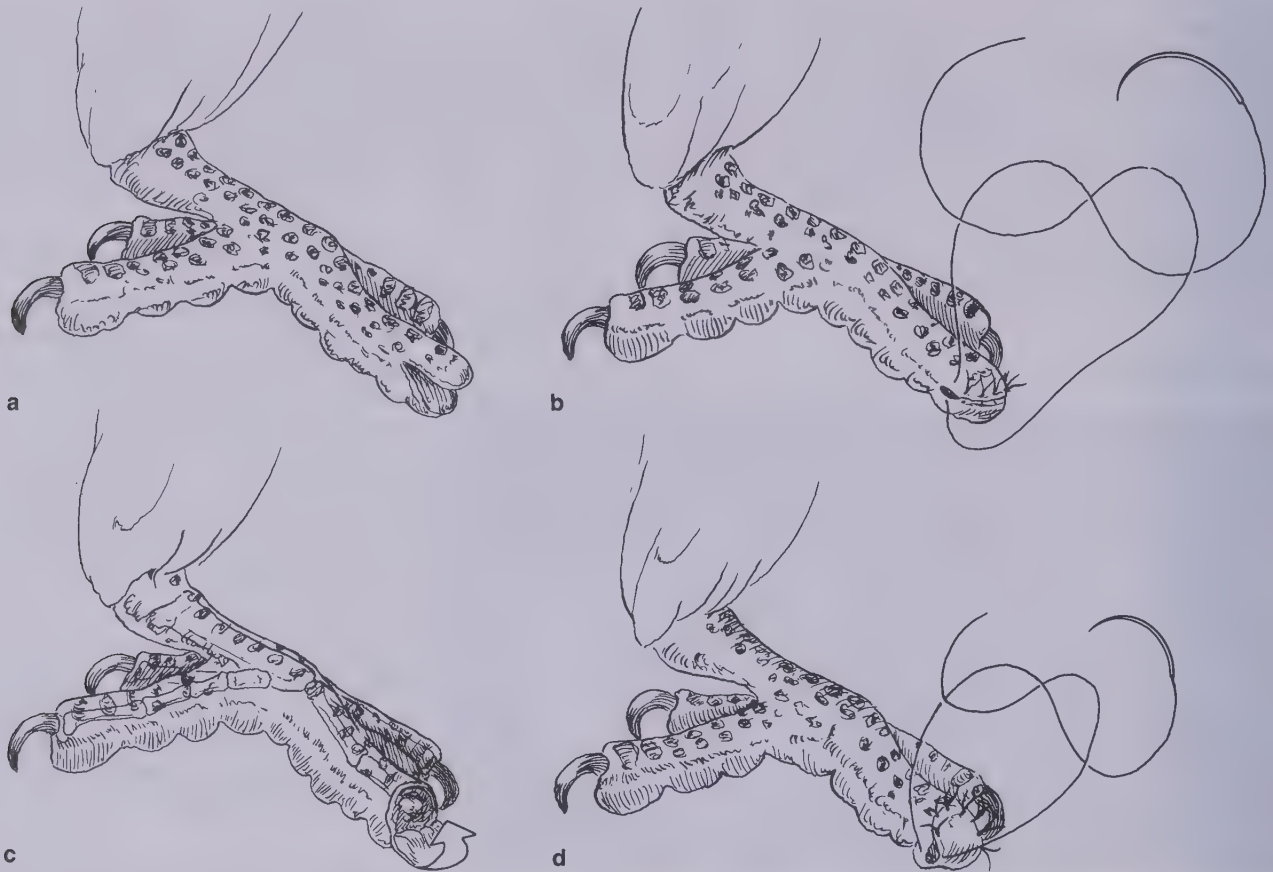Amputation of the humerus at the junction of the middle and proximal thirds of the bone provides adequate soft tissue coverage and creates a stump short enough to prevent self trauma. The skin incision should be made at the distal humerus, just proximal to the elbow. If additional skin is needed for closure, the patagium may be utilized. The muscles are transected at their musculotendinous junctions near the elbow. The radial and medianoulnar nerves should be injected with lidocaine or bupivacaine for short-term postoperative analgesia prior to their transection. Brachial musculature is mobilized by blunt dissection to remove attachments from the humerus. The humerus should be transected at the proximal third, to provide sufficient muscle distally to be sutured over the stump. Subcutaneous and skin closure are routine.

In situations where use of the wing for balance is important, it may be beneficial to amputate as distally as possible.<sup>19,39</sup> This function is especially important when working with birds to be used in breeding programs and as surrogate parents. It may be difficult to obtain adequate soft tissues for stump coverage with distal amputations.

### ■ Vascular Access Devices

In avian patients, intravenous catheters are viable only for short-term therapies. Avian veins are relatively small, thin-walled and fragile, with a propensity for hematoma formation following venipuncture. The intraosseous placement of a needle provides access to the vascular space for administration of fluids and therapeutics for up to 72 hours. Vascular access devices provide a route for long-term administration of therapeutics into the vascular system.<sup>8,17</sup> They have been used for long-term administration of amphotericin B in a Cassin's Auklet<sup>17</sup> and Magellanic Penguins and for total parenteral nutrition in pigeons.<sup>8</sup>

Vascular access devices are subcutaneously implanted devices with a reservoir that is accessed through surgically prepared skin using a non-coring



**FIG 41.22** Two techniques may be used for toe amputation: **a,b**) The skin may be incised, creating a semicircular flap on both the dorsal and the plantar surfaces of the digit. This skin pattern will provide adequate tissue for closure over the distal end of the bone. **c,d**) Alternatively, the plantar skin may be incised to create a flap of plantar skin that will cover the end of the bone. The plantar skin is somewhat stronger than the dorsal skin, providing additional protection over the end of the bone. Because the metaphysis and epiphysis of the phalanges are larger than the diaphysis, it may be beneficial to remove the exposed joint surface with rongeurs prior to skin closure. The skin is sutured as described for the repair of toe necrosis (see Figure 41.1).

needle (Huber point needle). Risk of sepsis and thrombosis is minimized because the catheter is not exposed to the environment. These have been maintained in humans for years and in birds for up to 12 weeks.<sup>17</sup> Vascular access devices have a number of synonyms, some of which are proprietary names, such as portacath, infusaport, dome, vascular access port and subcutaneous port.

The material, construction, surface finish and tip configuration influence the thrombogenicity of the catheter. Silicone and hydromer-coated polyurethane are considered the least thrombogenic materials currently in use. The catheter can be implanted into a vein, artery or other hollow organ and connected to the reservoir.

The right jugular vein is the preferred site for implantation. The patient is positioned in left lateral

recumbency, and the area over the right jugular vein is prepared for surgery. In many avian patients, there is no need to remove feathers because there is an apterium in this location. The skin is moved dorsally and an incision is made over the jugular vein. When the skin is released, the incision site will be ventral to the jugular vein and not over the reservoir. The jugular vein is identified and isolated for a distance of approximately 15 mm. Dissection must proceed cautiously as the vein is very fragile. Two ligatures are placed around the vein, one at the cranial extent and the other at the caudal extent of the isolated area. The caudal suture is elevated to occlude blood flow. The jugular vein will distend and the cranial suture is then tied off permanently occluding jugular flow. This does not seem to affect cerebral hemodynamics.

At this point, a small segment of the jugular vein remains distended. Using fine iris scissors and magnification, a transverse venotomy is created in the distended portion of the vein. This incision will not transect the vein but will allow the catheter to be inserted. After the blood from the distended segment is cleared, the end of the catheter is inserted into the venotomy site. The tension on the caudal ligature will have to be loosened to allow the catheter to pass, but enough tension should be maintained to prevent reflux hemorrhage. The venotomy may be widened using fine forceps or a vascular introducer. The catheter is advanced to the right atrium and secured in place by suturing above and below the retention ring at the venotomy site to prevent the catheter from advancing or backing out.

A Huber needle attached to a three-way stopcock and a saline-filled syringe is used to test the ease of injection and withdrawal of a sample. The position of the catheter tip should be evaluated using contrast radiography. Some catheters are radiopaque. With those that are radiolucent, the position can be evaluated by injecting a vascular contrast medium.

A subcutaneous pocket is created dorsal to the jugular vein large enough to accommodate the reservoir, which is placed into the pocket and sutured in place to the fascia of the neck musculature. A 2 to 4 cm loop of catheter is left to allow for neck movements. Subcutaneous and skin closure are routine. During recovery, feathers over the reservoir should be removed and the skin aseptically prepared. The device should then be filled with heparin at 100 IU/ml. Only non-coring needles should be used with these devices. With a minimal amount of practice, these devices can be implanted in 10 to 15 minutes.

The skin area above the port must be aseptically prepared before each use. Chlorhexidine has been shown to be three to four times more effective at preventing bacterial colonization of the catheter than povidone iodine.<sup>17</sup> The individual administering the therapy should wear sterile gloves and use sterile equipment. The non-coring needle is inserted into the reservoir until it hits the base plate and the injection can then be made.

These devices can be maintained for extended periods of time but require some maintenance.<sup>17</sup> Catheters were maintained in chickens for 12 weeks using a 1000 IU/ml heparin lock and weekly flushing. In geese, the catheters were flushed every four days with 1.0 ml physiologic saline and locked with 0.25

ml heparin at 100 IU/ml. When catheters are used daily or several times daily, there is no need for heparin locks, which eliminates the potential for heparinizing the patient. However, there is a higher potential for thrombus formation with small gauge catheters, and a heparin lock may still be necessary.<sup>17</sup>

Removal of the device requires a surgical approach to the vein and the reservoir. The sutures holding the reservoir are removed as is the suture holding the catheter in the vein. A ligature is pre-placed around the vein and the catheter is removed. The ligature is tightened to prevent reflux of blood. Closure of the skin and subcutaneous tissues is routine.

### ■ Perinatal Surgery

Many aviculturists do not seek veterinary assistance with embryonal and neonatal matters, attempting to manage problems themselves. Rarely are these attempts successful. Neonatal tissues are challenging to suture. Compared with adult tissues, they have a high moisture content, making them very friable, with reduced tensile strength. With practice and management, fine suture (8-0 to 10-0) and an atraumatic needle can be used for closure of the umbilicus. However, hemostatic clips are more appropriate for application to the umbilicus than suture ligatures. Featherless neonates are highly prone to developing hypothermia. Anesthesia and surgery time should be less than 15 minutes, and the operating room temperature should be elevated to 75 to 85°F.<sup>1</sup> Body temperature should be carefully monitored throughout the procedure, and supplemental glucose should be provided through an intraosseous cannula as necessary.

Because of their small blood volume, perinatal patients are more likely to require transfusion if major blood loss occurs or if the hematocrit is below 20 to 25%. Respiratory movements may be difficult to observe in perinatal patients, making the use of clear drapes and small non-rebreathing bags essential. The crop of altricial avian neonatal patients is usually full, increasing the risk of regurgitation and aspiration. The patient may be fasted until the crop volume has diminished or the contents may be removed by aspiration. Elevating the head and packing the thoracic esophagus with moist cotton will also help prevent reflux of crop contents.

#### Yolk Sac Removal

The yolk sac is a diverticulum from the small intestine attached by the yolk stalk and accompanying

vasculature. It is normally internalized prior to hatching. Yolk is absorbed during incubation through the endodermal cells of the yolk sac and, at least in chickens, nutrients are absorbed through a duct that connects the yolk stalk to the intestines. Yolk provides nourishment, minerals, fat-soluble vitamins and maternal antibodies to the developing embryo and the neonatal bird. After the yolk has been completely absorbed, the remnant of the yolk sac becomes the vitelline or Meckel's diverticulum.

A procedure for removal of unabsorbed yolk sacs has been successful in decreasing mortality in affected chicks (see Chapter 48). Candidates for surgery demonstrate one or more of the following clinical signs: abdominal distention, exercise intolerance or dyspnea, weight loss and anorexia, failure to grow or inability to stand or walk. Abdominal palpation and radiography support the diagnosis of unabsorbed yolk sac. Radiographically, the yolk mass displaces the viscera cranially into the thoracic space, compromising the caudal

air sacs. This results in exercise intolerance and dyspnea. Yolk sac removal is most effective if performed before the chick becomes dyspneic. Percutaneous aspiration of the yolk should not be attempted as the yolk sac is very thin and will leak yolk into the coelomic cavity resulting in peritonitis. Injecting antibiotics directly into the yolk sac carries the same risk. Systemic antibiotics are not effective alone.<sup>26</sup>

#### Products Mentioned in the Text

- a. Lorelco, Merrell Dow Pharmaceuticals Inc., Cincinnati, OH
- b. Mucomyst, Mead Johnson, Evansville, IN
- c. Maxitrol ophthalmic ointment, Alcon Laboratories, Fort Worth, TX
- d. Vetalog, Solvay Animal Health, Mendota Heights, MN
- e. Jardon Eye Prosthetics Inc., Southfield, MI
- f. Moto-tool, Dremel, Racine, WI
- g. Gelfoam, Upjohn Co, Kalamazoo, MI
- h. McAllister Technical Services, Coueur d'Alene, ID
- i. Bard Urological Division, CR Bard, Murray Hill, NJ
- j. Norfolk Medical Products, Access Technologies, Skokie, IL
- k. Avian Restraint Collar, Vet Specialty Prod., Boca Raton, FL

#### References and Suggested Reading

1. **Alman RB**: Avian neonatal and pediatric surgery. *Sem Avian Exotic Pet Med* 1(1):34-39, 1992.
2. **Avgeris S, Rigg D**: Cloacopy in a sulphur-crested cockatoo. *J Am Anim Hosp Assoc* 24:407-410, 1988.
3. **Bauk L**: Radical surgery for the treatment of feather cysts in the canary. *AAV Today* 1(5):200-201, 1987.
4. **Bond MW**: Avian pediatrics. *Proc Assoc Avian Vet*, 1991, pp 153-160.
5. **Bush M, Kennedy S**: Ventriculostomy for removal of foreign bodies from saurus cranes. *J Am Vet Med Assoc* 173:1107-1110, 1978.
6. **Calle PP, Ensley PK**: What is your diagnosis? *J Am Vet Med Assoc* 189:1230-1231, 1986.
7. **Clubb SL, Karpinski L**: Aging in macaws. *Proc Assoc Avian Vet*, 1992, pp 83-86.
8. **Degernes LA, et al**: Preliminary report on the use of total parenteral nutrition in birds. *Proc Assoc Avian Vet*, 1992, pp 19-20.
9. **Doster GL**: Aspirated corn kernels cause death of cannon-netted wild turkeys. *J Wildl Manag* 38:578, 1974.
10. **Gasthuys F, DeMeurichy W**: Successful ventriculostomy for removal of foreign bodies in a kiwi (*Apteryx australis mantelli*). *J Zoo Anim Med* 18(4):166-167, 1987.
11. **Goring RL, et al**: Needle catheter duodenostomy: A technique for duodenal alimentation of birds. *J Am Vet Med Assoc* 189:1017-1019, 1986.
12. **Harris JM**: Teflon dermal stent for the correction of subcutaneous emphysema. *Proc Assoc Avian Vet*, 1991, pp 20-21.
13. **Harrison GJ**: Initial treatment of severe crop wounds. *J Assoc Avian Vet* 5(3):126, 1991.
14. **Harrison GJ**: Reproductive medicine. In *Harrison GJ, Harrison LR (eds): Clinical Avian Medicine and Surgery*. Philadelphia, WB Saunders Co, 1986, pp 625-626.
15. **Harrison GJ**: Selected surgical procedures. In *Harrison GJ, Harrison LR (eds): Clinical Avian Medicine and Surgery*. Philadelphia, WB Saunders Co, 1986, pp 577-595.
16. **Harrison GJ**: Surgical repair of crop injuries. *AAV Today* 1(2):63, 1987.
17. **Harvey-Clark C**: Clinical and research use of implantable vascular access ports in avian species. *Proc Assoc Avian Vet*, 1990, pp 191-209.
18. **Hochleithner M, Lechner C**: Egg binding in a budgerigar (*Melopsittacus undulatus*) caused by a cyst of the right oviduct. *AAV Today* 2(3):136-138, 1988.
19. **Howard PE, et al**: Surgical removal of a tracheal foreign body from a whooping crane (*Grus americana*). *J Zoo Wildl Med* 22(3):359-363, 1991.
20. **Hunter RB, Taylor M**: Lung biopsy as a diagnostic technique in avian medicine. *Proc Assoc Avian Vet*, 1992, pp 207-211.
21. **Ingram I**: Proventricular foreign body mimicking proventricular dilatation in an umbrella cockatoo. *Proc Assoc Avian Vet*, 1990, pp 314-315.
22. **Jacobson ER, et al**: Ventriculostomy for removal of multiple foreign bodies in an ostrich. *J Am Vet Med Assoc* 189(9):1117-1119, 1986.
23. **Jenkins JR**: Avian soft tissue surgery: Part I. *Proc American College of Veterinary Surgeons*, 1992, pp 631-633.
24. **Jenkins JR**: Avian soft tissue surgery: Part II. *Proc American College of Veterinary Surgeons*, 1992, pp 634-636.
25. **Joyner KL**: Pediatric therapies. *Proc Assoc Avian Vet*, 1991, pp 188-198.
26. **Kenny D, Cambre RC**: Indications and technique for the surgical removal of the avian yolk sac. *J Zoo Wildl Med* 23(1):55-61, 1992.
27. **Kern TJ, et al**: Lens extraction by phacoemulsification in two raptors. *J Am Vet Med Assoc* 185(11):1403-1406, 1984.
28. **Kosloske AM**: The Fogarty balloon technique for removal of foreign bodies from the tracheobronchial tree. *Surg Gyn Obs* 55:72-73, 1982.
29. **Lloyd M**: Heavy metal ingestion: Medical management and gastrointestinal foreign body removal. *J Assoc Avian Vet* 6(1):25-29, 1992.
30. **Lumeij JT**: A new instrument for removing gastric foreign bodies in birds. *Proc Europ Assoc Avian Vet*, Utrecht, 1993, pp 91-98.
31. **McCoy DM, Campbell TW**: Excision of impacted and ruptured uropygial glands in three Gentoo penguins. *Proc Am Assoc Zoo Vet*, 1991, pp 259-260.
32. **Martin HD**: Abdominal hernia with formation of a urate concretion in a cockatiel. *J Am Vet Med Assoc* 189(10):1332-1333, 1986.
33. **Martin HD**: Avian reproductive emergencies: Surgical management. *Vet Med Rep* 2(3):250-253, 1990.
34. **McCluggage D**: Hysterectomy: A review of selected cases. *Proc Assoc Avian Vet*, 1992, pp 201-206.
35. **McCluggage D**: Proventriculotomy: A study of selected cases. *Proc Assoc Avian Vet*, 1992, pp 195-198.
36. **McDonald SE**: Successful treatment of mycotic tracheitis in a raven. *Proc Assoc Avian Vet*, 1984, pp 154-163.
37. **McLelland J**: A Color Atlas of Avian Anatomy. Philadelphia, WB Saunders Co, 1991.
38. **Moore CP, et al**: Extracapsular extraction of senile cataract in an Andean condor. *J Am Vet Med Assoc* 187(11):1211-1212, 1985.
39. **Mullen JL, et al**: Amputation of the wing in a whooping crane. *J Am Vet Med Assoc* 185(11):1402-1403, 1984.
40. **Nickel R, et al**: Respiratory system. In *Anatomy of the Domestic Birds*, New York, Springer-Verlag, 1977, pp 62-69.
41. **Quesenberry KE, et al**: Nutritional support of the avian patient. *Proc Assoc Avian Vet*, 1989, pp 11-19.
42. **Reece RL**: Reproductive diseases. In *Burr EW (ed): Companion Bird Medicine*. Ames, Iowa State University Press, 1987, pp 89-100.
43. **Ringer RK**: Selected physiology for the avian practitioner. In *Harrison GJ, Harrison LR (eds): Clinical Avian Medicine and Surgery*. Philadelphia, WB Saunders Co, 1986, pp 78-80.
44. **Roskopf WJ**: Surgery of the avian respiratory system. *Proc 12th Annual Vet Surg Forum*, 1984, pp 47-56.
45. **Roskopf WJ, et al**: Pet avian emergency care. *Proc Assoc Avian Vet*, 1991, pp 349.
46. **Roskopf WJ, et al**: Sinus trephination of the supraorbital sinuses in psittacine birds: An aid in the treatment of chronic sinus infections. *Proc Assoc Avian Vet*, 1986, pp 295-301.
47. **Roskopf WJ, Woerpel RW**: Cloacal conditions in pet birds with a cloacopy update. *Proc Assoc Avian Vet*, 1989, pp 156-163.
48. **Roskopf WJ, Woerpel RW**: Pet avian obstetrics. *Proc 1st Int Conf Zoo & Avian Med*, 1987, pp 213-231.
49. **Sikarski JG**: Ostrich castration for behavioral control. *Proc 1st Int Conf Zoo & Avian Med*, 1987, pp 416.
50. **Slatter DM, et al**: Hereditary cataracts in canaries. *J Am Vet Med Assoc* 183:872-874, 1983.
51. **Smith RE**: Hysterectomy to relieve reproductive disorders in birds. *Avian Exotic Pract* 2:40-43, 1985.
52. **Steinbach MJ, et al**: Torsional eye movements in the owl. *Vision Res* 14:745-746, 1974.
53. **Swartout MS, Wyman M**: Pancreatic carcinoma in a cockatiel. *J Am Vet Med Assoc* 191(4):451-452, 1987.
54. **Turrel JM, et al**: Diagnosis and treatment of tumors of companion birds. *AAV Today* 1(3):109-116, 1987.
55. **Van Zant F**: Resolution of a cloacal adhesion in a blue-fronted Amazon. *Proc Assoc Avian Vet*, 1992, pp 162-164.
56. **Van Zant F**: Resolution of an esophageal stricture in a hyacinth macaw. *Proc Assoc Avian Vet*, 1992, pp 177-179.
57. **Wissman MA**: Unusual c-section and hysterectomy in the Isle of Pines Amazon. *Proc Assoc Avian Vet*, 1991, pp 265-266.

**N**umerous approaches have been used to repair fractures and luxations in avian species. Typically, these techniques have been adapted from those used for small mammals and humans. Regardless of the specific techniques employed in fracture repair, it is important to:

- Treat contaminated and infected wounds.
- Preserve soft tissue structures.
- Appose, align and control rotation of fractures and reduce luxations.
- Rigidly immobilize the fracture site.
- Maintain range of motion in all joints affected by the fracture or fixation technique.
- Return the affected limb to “normal function” as soon as possible.

The presence of a fracture certainly suggests major trauma, and a thorough physical examination should be performed to determine other injuries.

Subcutaneous emphysema may be noted in birds with ruptured air sacs or with fractures of the humerus, thoracic girdle or some ribs (the pneumatic bones). The emphysema will generally resolve within a few days. In many cases, birds may require several days of stabilization with fluids, steroids, antibiotics or supportive alimentation before anesthesia and surgery can be safely performed (see Chapter 40).

CHAPTER

---

**42**

**ORTHOPEDIC  
SURGICAL  
TECHNIQUES**

---

**Howard Martin  
Branson W. Ritchie**

It is common for subtle injuries to occur that are difficult to detect by physical examination. Survey radiographs of affected skeletal areas as well as the abdomen and thorax are needed to assess any bony or soft tissue changes that may have occurred during a traumatic episode. Recommendations for other evaluation procedures are similar to those described in soft tissue surgery (see Chapter 41).

Fracture stabilization techniques used in free-ranging birds must be designed to increase the likelihood that a rehabilitated bird can be released. Repair of a wing fracture, particularly near a joint, must be nearly perfect with no ankylosis and minimal soft tissue damage to ensure return to full flight. For these avian patients, maintenance and protection of soft tissues is the single most important aspect of successful surgery. The degree and type of soft tissue damage may be more critical in determining the potential for postsurgical return to function than specific osseous injuries. Native avifauna with injuries that will prevent their release must be repaired to a functional level that allows them to adapt to a zoo, breeding program or educational facility. Injured native birds that cannot be repaired to sufficiently achieve one of these goals may require euthanasia.

Birds that are maintained in aviary situations or in breeding facilities must have adequate postoperative use of a fractured limb to allow them to function effectively in their respective environments. Most companion birds can tolerate a substantial loss of function of the wings and still function normally. Leg injuries that alter weight-bearing in one or both feet can predispose a bird to bumblefoot or arthritis. Some birds will tolerate postoperative surgical hardware while others will not.

## Therapeutic Strategies

The fracture should be classified as to anatomy, shape, whether it is open or closed and its chronicity. The type of fracture will frequently dictate the type of specific therapy and stabilization procedures that are used. Patient preparation for surgery, preparing the surgical site and draping are discussed in Chapter 40.

**TABLE 42.1** Types of Fixation

- **External coaptation** - Sling, splint, bandage
- **Internal fixation** - IM pins, cerclage wires, bone plates
- **External fixation** - pins passed through bone from skin surface and connected to stabilizing bars

**TABLE 42.2** Principles of Fracture Stabilization<sup>31,30,38,39</sup>

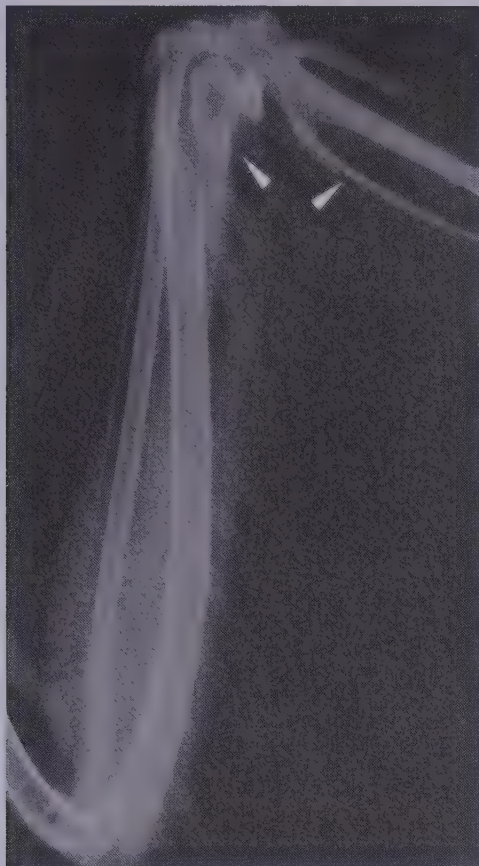- Minimal soft tissue damage
- Maintenance of length, rotation, angular orientation
- Anatomic alignment
- Rigid stabilization
- Minimal disturbance of callus formation
- Neutralization of forces:
  - Rotation, bending (transverse fractures)
  - Shear, rotation, bending (oblique or spinal fractures)
  - Compression, shear, rotation, bending (comminuted fractures)

### Developing a Surgical Plan

The method of fixation selected should suit the patient's injury, natural behavior, activity levels and future needs (Tables 42.1, 42.2). A thorough understanding of the location of major nerves, arteries and veins ensures that the surgeon can properly perform any necessary stabilization procedure. Bipolar radiosurgery is necessary to control blood loss and allow thorough visualization of a relatively small surgical field (see Chapter 40).

Avian bones have a high calcium content, and a thin, brittle nature.<sup>31,35</sup> In addition, portions of the medullary canal of the humerus in many birds are connected to the air sacs (pneumatic), which reduce the weight of the bone and are believed to contribute to the respiratory cycle during flight (see Anatomy Overlays). It is best to cover the medullary canal of the proximal fragment of a humeral fracture before irrigating the surgical site. Fluids or necrotic debris that are flushed into the pneumatic bones may cause asphyxiation, air sacculitis or pneumonia.

The distal legs and wings of birds have relatively little soft tissue (ie, tendons, ligaments, skin and muscles). Bone in these areas are, therefore, particularly susceptible to impact-related injuries (see Anatomy Overlays). Aggressive tissue manipulation can cause increased damage of already compromised blood supply and soft tissues, which increases the healing time and likelihood of unsuccessful function post-repair.



**FIG 42.1** Primary and secondary remiges (arrows) are attached to the periosteum of the metacarpal bones and ulna, respectively. Periosteal stripping and damage to the primary and secondary feather follicles should be avoided during a surgical procedure (courtesy of Laurel Degernes).

Gentle manipulation and frequent irrigation of soft tissues and bones with sterile saline will help maintain the integrity of vascular and neural structures and speed return to normal function. If exposure of a fracture site requires the transection of a muscle, it is best to do so near the muscle's origin or insertion in order to minimize trauma and hemorrhage and to facilitate reattachment. Periosteal stripping and damage of soft tissue attachments to the bone should be avoided, particularly in the wings, where the primary and secondary feathers are attached to the periosteum (Figure 42.1).

### Open Versus Closed Reduction

Thin skin, scarce soft tissues and sharp bone fragments frequently result in open fractures in birds. Even if bones are not protruding from the skin at the time of presentation, the presence of any wound associated with the fracture would indicate previous

violation of the skin barrier. If any skin wound is present, the fracture should be considered open.

Closed reduction involves the manipulation of the fracture through application of traction and counter-traction to stretch the soft tissues and appose and align the bone fragments. It is difficult to achieve adequate alignment and reduction of fractures with closed reduction techniques without causing significant soft tissue trauma, except in those fractures that are minimally displaced.

The advantages of open reduction include reduced soft tissue trauma (as traction is applied directly to the bones), visualization of the fracture site (and therefore the ability to attain optimal reduction as well as cleansing of the fracture site) and removal from the fracture site of interposed soft tissues, contaminated or infected debris and necrotic or devitalized bone.<sup>11</sup>

### Prognosis

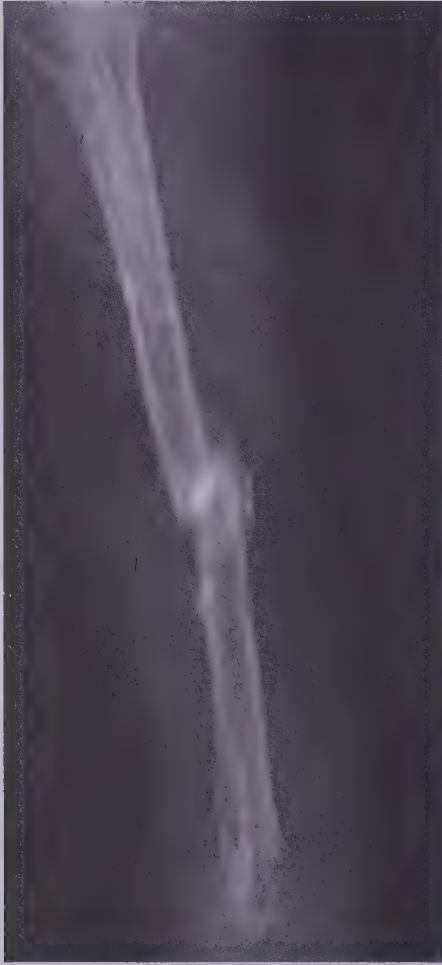
Companion and aviary birds rarely require full mobility following fracture repair, and the post-fracture prognosis for return to function with these birds is generally excellent. By comparison, free-ranging birds (particularly raptors), which can be viewed as finely tuned athletes, must have near perfect wing function in order to survive in the wild. A slight rotation in the wing (particularly in the distal wing) can alter flight. The ulna and radius normally slide by each other longitudinally. If trauma causes the ulna and radius to fuse (preventing this sliding motion), a bird will be unable to properly supinate or pronate the carpus and may not be able to fly.<sup>21,41</sup>

Fractures near a joint usually result in ankylosis, which prevents normal limb function. Open comminuted fractures are more likely to be infected, resulting in secondary osteomyelitis.<sup>21</sup> A 20 to 30% decrease in leg function may be acceptable in birds released to the wild as long as the dysfunction does not dramatically affect the flexion or extension of the foot or the prehension of food.

### Postoperative Care

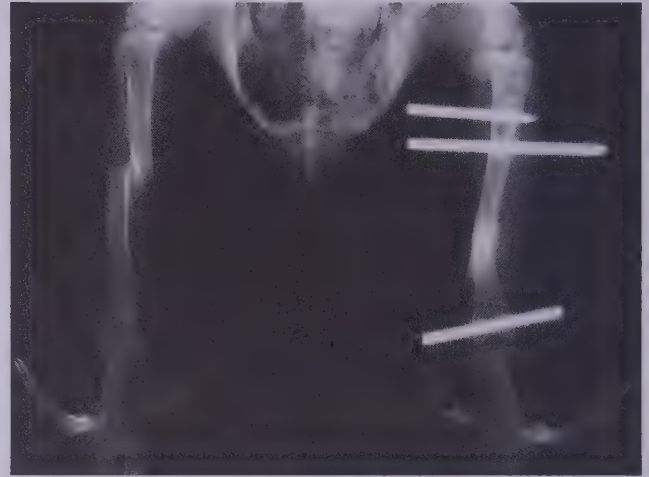
Postoperative radiographs should be taken at two- to four-week intervals to assess bone healing. The radiographic changes associated with bone healing can appear similar to those that occur with osteomyelitis including periosteal reaction, sclerosis and increased radiodensities in the medullary canal (Figure 42.2).

To improve vascular supply to damaged tissue and to speed the bone healing process, active and passive



**FIG 42.2** A minimally displaced mid-diaphyseal tibiotarsal fracture in a Green-winged Macaw was stabilized with a cast. Radiographs three weeks after the fracture occurred show a loss of detail at the fracture ends and a smooth, well defined periosteal response characteristic of a normal healing process. This lateral radiograph indicates slight malalignment and over-riding of the fragments (courtesy of Marjorie McMillan).

rehabilitative techniques should be instigated as soon as possible after an orthopedic surgery. The physical therapy program should be based on the bird's injury, behavior and required degree of post-surgical function. Initial physical therapy may involve only a bird's daily activities of perching and prehending food. Physical therapy should evolve to include a variety of regimented exercises designed to maintain or increase cardiovascular endurance, to maintain or increase range of motion of joints and to maintain or increase muscular flexibility tone and fitness.<sup>10</sup> The physical therapy program is dictated by the exact nature of the injury and species of injured bird.



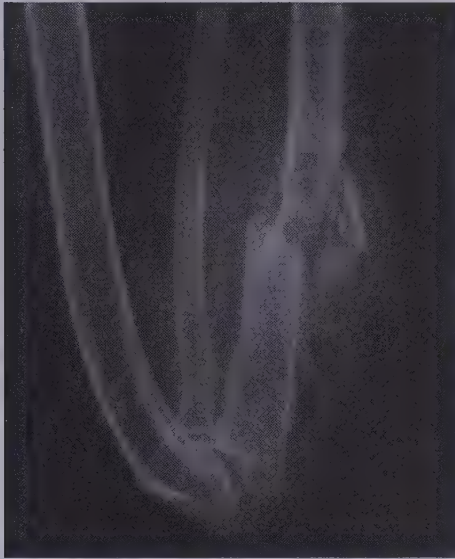**FIG 42.3** Radiographic findings suggest that primary bone healing occurs in birds if a fracture is properly aligned and rigidly stabilized. An adult Amazon parrot was presented with a history of having fractured the right tibiotarsus three months before presentation. This fracture was repaired with a Robert Jones bandage. Three weeks before presentation, the bird had fractured the left tibiotarsus and the limb was cast. The bird had not improved during the three-week period, and the case was referred for evaluation. The severely displaced right tibiotarsal fracture was stable and a substantial periosteal callus was evident radiographically. At presentation, the left tibiotarsus was displaced (bone ends were not touching) and there was excessive soft tissue swelling. The fracture site was approached medially, and a large amount of fibrous connective tissue was removed to allow the bone ends to be reduced. The fracture was stabilized using positive profile threaded pins connected with methylmethacrylate. The bird was placed in a light Robert Jones-type bandage and was using the leg several hours after surgery. Radiographs taken four weeks postsurgery indicated a bony union with minimal callus formation.

### ■ Bone Healing

Controlled studies evaluating the healing process of avian bone are scarce. In general, it is assumed that the rate of fracture repair is dependent on the displacement of the bone fragments, the amount of damage to the blood supply, whether an infectious agent is present and the amount of motion at the fracture site.<sup>14</sup> In mammals, primary bone healing (bone growth through the Haversian system with minimal callus formation) occurs with rigid fixation and does not occur if there is a gap or motion at the fracture site. In these cases, secondary bone healing characterized by maximum callus formation occurs (Table 42.3). In birds where fractures were repaired with bone plates (maximum stabilization), callus formation was found to be minimal, suggesting that primary bone healing had occurred (Figure 42.3).<sup>19</sup>

Callus formation appears to be similar in birds and mammals.<sup>19,58</sup> Endosteal callus provides rapid stabilization in bones that are properly aligned. Periosteal





**FIG 42.4** In comminuted fractures, bone fragments that maintain a blood supply heal rapidly. Devitalized, uninfected fragments should be left at the fracture site to provide additional support for callus formation (courtesy of Laurel Degernes).

callus formation is minimal if the bones are rigidly fixed. The blood supply to the bones is believed to arise from periosteal (originating from soft tissues and muscles), medullary (originating from nutrient artery), metaphyseal and epiphyseal vessels.<sup>57</sup>

Stable, properly aligned fractures appear to heal more rapidly in birds than in mammals.<sup>6,7,30,31,45</sup> It has been suggested, but not confirmed, that pneumatic bones heal slower than medullary bones.<sup>31</sup> Clinical stability of a fracture (two to three weeks) may precede radiographic evidence that the bone is healed (three to six weeks).<sup>7,31,45</sup> The healing of unstabilized humeral fractures in pigeons was characterized by increased radiolucency in the medullary canal and endosteal and periosteal calluses that were present histologically by nine weeks. Poorly aligned fractures changed little between four and twelve weeks,<sup>31</sup> while properly stabilized bones remodeled rapidly during that time period.

Minor forces that cause undetectable levels of movement can damage the growth of small capillary beds and impede fracture stabilization. Fracture stabilization is most likely to fail in comminuted fractures that have the greatest number of forces that must be neutralized.<sup>30</sup> In these fractures, bone fragments that maintain a blood supply should heal as rapidly as the intact distal and proximal fragments. Devitalized, uninfected fragments should be left in place to provide structural support for callus formation (Figure 42.4).<sup>33</sup>

**TABLE 42.3 Secondary Bone Healing**

**Induction and Inflammation**

- Fibroblasts proliferate
- Osteogenic cells migrate from periosteum and endosteum and proliferate at fracture site

**Callus Formation**

- Collagen and mucopolysaccharide produced
- Calcium deposited in callus
- Soft callus becomes bone (endochondral ossification)

**Remodeling**

- Accelerated deposition and resorption of bone
- Change in shape of bone
- Function and strength restored

**Osteomyelitis**

Avian heterophils lack the proteinase necessary to liquify necrotic tissue, and birds tend to form granulomas that wall off infectious agents and necrotic material. Consequently, osteomyelitis is characterized by caseous, dry, non-draining lesions that are frequently restricted to the site of infection and rarely induce secondary systemic infections.<sup>33</sup> With mild infections, it is common for the host defense mechanism to wall off the necrotic debris and form callus around the infected tissue. However, these granulomatous osteomyelitis lesions can serve as a nidus for infection that can cause a fatal septicemia if a bird becomes immunosuppressed.

Large quantities of necrotic debris may prevent bone healing and should be surgically removed if successful fracture stabilization is expected to occur.<sup>33,46</sup> Debridement and flushing should be used to remove necrotic tissue and debris from all open fractures to reduce the chances of postoperative osteomyelitis. Samples for culture and sensitivity should be collected from the fracture site at the time of surgery. The use of intraoperative, broad-spectrum antibiotics with good tissue penetration (trimethoprim-sulfa, cephalosporins, chloramphenicol, tetracyclines) should be considered in these cases.

Placement of stabilizing hardware at or near an open fracture site should be avoided to decrease the likelihood of osteomyelitis and improve the speed of bone healing. External fixators are recommended in these cases. It has been suggested that fractures in pneumatic bones would be predisposed to osteomyelitis from contaminated air entering the fracture site. There is no evidence to support this theory.<sup>7,31</sup>

**Malunions**

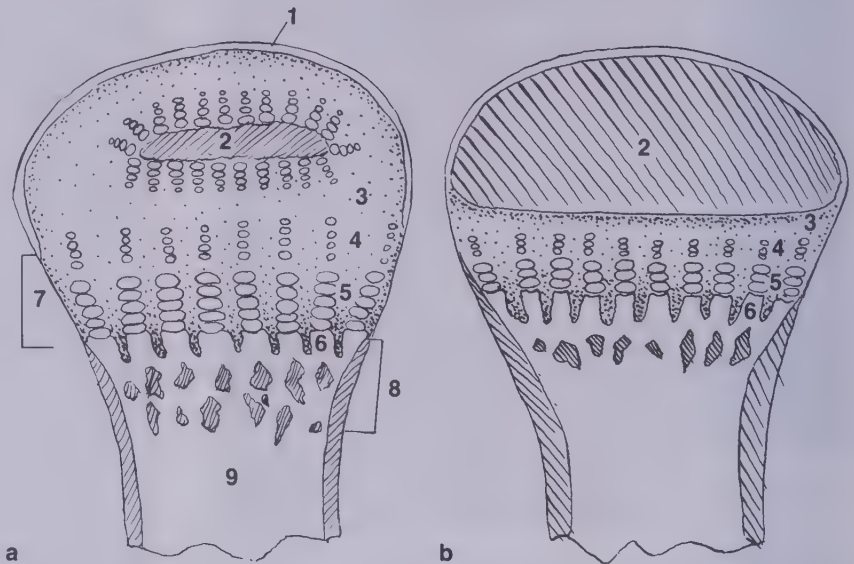
Viable and nonviable malunions can occur in birds (Table 42.4). Malunions occur when the ends of fractured bones heal but not to each other. Stabilization

requires removing necrotic debris, freshening the bone ends and compressing and rigidly stabilizing the fracture site.<sup>41</sup> Electrical current stimulation was used to repair a non-union fracture (six months' duration) in the radius and ulna of a Rough-legged Hawk. A direct-current stimulator<sup>a</sup> was implanted and delivered 0.83 volts at 20 uA to the fracture site. Callus formation was evident radiographically at 21 days post-implantation and the fracture was healed by 80 days post-implantation.<sup>27</sup>

### Ossification<sup>13</sup>

The maturation process of the long bones of birds is different from that of mammals. In the majority of raptors, ossification of the limb bones occurs within 60 days of hatching and bones appear to mature thereafter. The diaphysis, or shaft, is that portion of a long bone between the ends (Figure 42.5). The metaphysis is the wider part of the extremities of the shaft, adjacent to the epiphyseal disc (physis). The epiphysis is the end of a long bone and is formed from a secondary center of ossification. The physis, or growth plate, is that segment of tubular bone concerned with growth. It is divided into four distinct zones:<sup>11</sup>

- **Zone of resting cartilage:** Small chondrocytes are dispersed in an irregular pattern.
- **Zone of cell proliferation:** Chondrocytes are somewhat larger and tend to form columns; this is the area of chondrocyte proliferation and mitotic figures are usually present.
- **Zone of cell maturation:** Cells are larger still and arranged in columns. As the cells enlarge and mature, they accumulate glycogen and begin producing phosphatase, which initiates calcification.
- **Zone of calcification and ossification:** With maturity, the columns of chondrocytes die and disintegrate, leaving spaces between partitions within the cartilage. Capillaries invade the spaces and osteoblastic activity takes place on the surface of the partitions. Longitudinally oriented bony trabeculae develop, which give a jagged appearance to this zone on histologic and radiographic preparations.



**FIG 42.5** a) Mammalian long bone ossification during early development and b) after the epiphysis has reached maximum size. 1) articular cartilage 2) secondary center of ossification 3) zone of resting cartilage 4) zone of cell proliferation 5) zone of maturation 6) zone of calcification and ossification 7) physis 8) metaphysis and 9) diaphysis (modified with permission from Fowler<sup>13</sup>).

**TABLE 42.4** Types of Malunions<sup>3</sup>

**Viable** – Sufficient blood supply

**Hypertrophic**

- Abundant callus and blood vessels
- Fractures filled with fibrocartilage
- Caused by inadequate fixation or premature loading

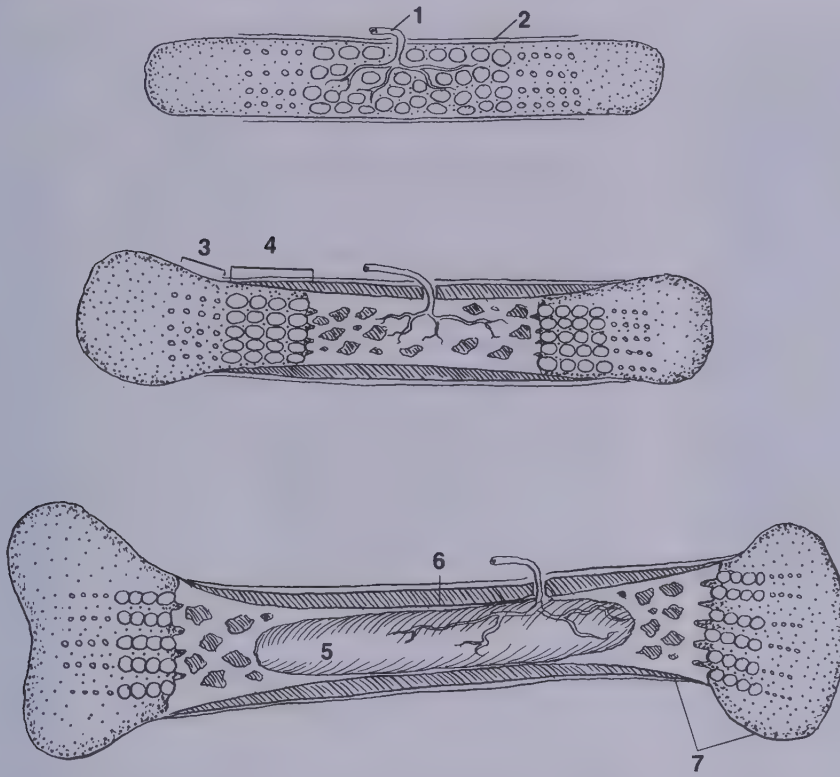
**Oligotrophic**

- No evidence of callus
- Biologically, fracture can heal
- Hypervascularized fragments
- Rounded, decalcified fragment ends

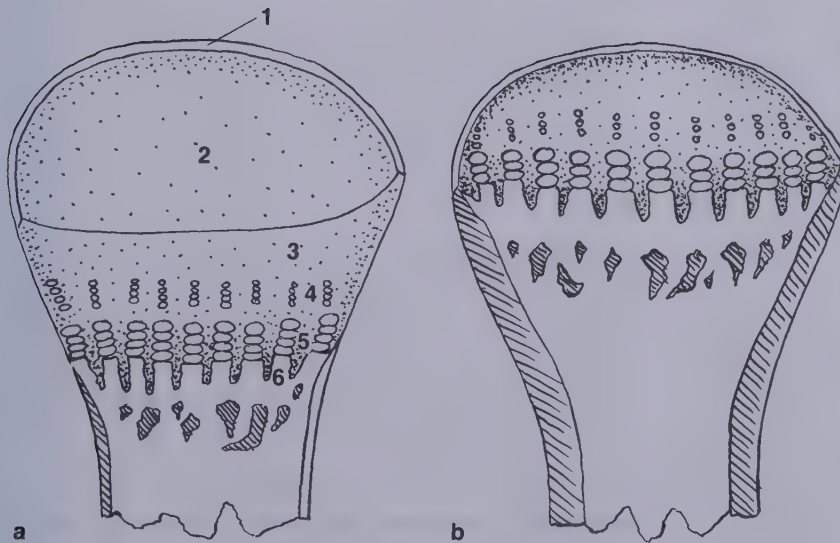
**Nonviable** – Insufficient blood supply

In mammals, most long bones have one or more epiphyseal or secondary centers of ossification. Their formation is similar to endochondral ossification with proliferation occurring in all directions until a predetermined size is reached. The epiphyseal center is covered distally by hyaline articular cartilage and proximally by an epiphyseal plate or physis until the animal reaches maturity.

The tibiotarsus of birds appears to follow a classic mammalian ossification pattern. The ends of the bones grow rapidly and establish secondary centers of ossification (epiphyses). The growth in length takes place at the epiphyseal layer, and when growth ceases, the layer of cartilage ossifies. The avian hu-



**FIG 42.6** Ossification of avian long bones from day 9 to day 13. 1) nutrient artery 2) periosteum and initial bone plate 3) zone of proliferation 4) zone of maturation 5) marrow cavity 6) cortex and 7) physis (modified with permission from Fowler<sup>13</sup>).



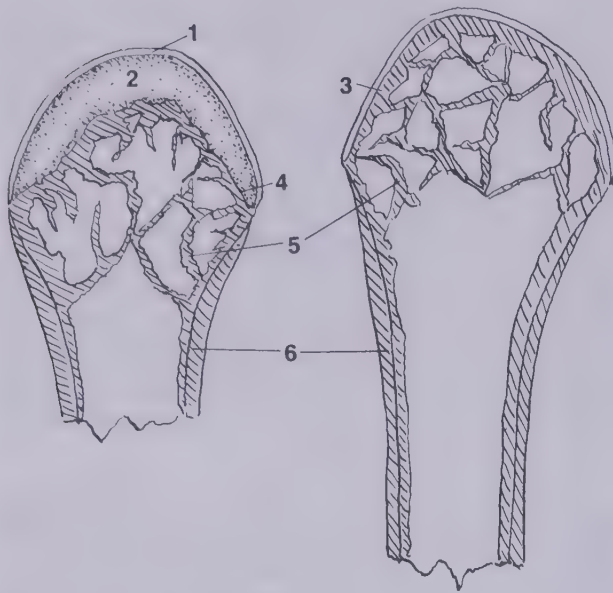
**FIG 42.7** a) In contrast to mammals, the epiphyseal center of the avian long bone remains cartilaginous (day-old chick). b) After the maximum bone size is reached (in this case a 155-day-old chick), the epiphyseal cartilage undergoes endochondral ossification. 1) articular cartilage 2) epiphyseal cartilage 3) zone of resting cartilage 4) zone of proliferation 5) zone of maturation and 6) zone of calcification and ossification (modified with permission from Fowler<sup>13</sup>).

merus, radius, ulna and femur appear to have different patterns of ossification.

The basic progression of ossification in long bones has been described in chickens (Figure 42.6). In the femur of a 9-day-old embryo, a sheath of bone has begun to form beneath the perichondrium of the original hyaline cartilage. At 13 days, the central diaphyseal cartilage has been replaced by bone, and the marrow cavity has formed. Endochondral ossification progresses toward both extremities.

In the day-old chick, the diaphysis has elongated by replacement of the cartilage model at the metaphysis. There is also a cartilage model analogous for the mammalian epiphyseal center of ossification (Figure 42.7), but the epiphyseal cartilage does not undergo endochondral ossification in the femur of chickens as it does in mammals. Instead, it persists as a wide basophilic hyaline zone covered by a narrow strip of eosinophilic articular cartilage. Elongation of the cartilage model is accomplished by interstitial growth of chondrocytes.<sup>11</sup>

At a predetermined time (may be controlled by age, species, nutrition), the growth cartilage becomes exhausted. The invading marrow tissue then enters the epiphyseal cartilage (Figure 42.8). Individual chondrocytes undergo hypertrophy allowing final endochondral ossification of the epiphyseal cartilage. By 190 days, ossification is essentially complete. At each end of the bone, a dense terminal bone plate is covered by an articular hyaline cartilage. It is possible for slight elongation of a long bone to take place by cartilage proliferation and ossification at the junction of the bone and articular cartilage. This is typical of the long bones of the humerus, radius, ulna and femur.

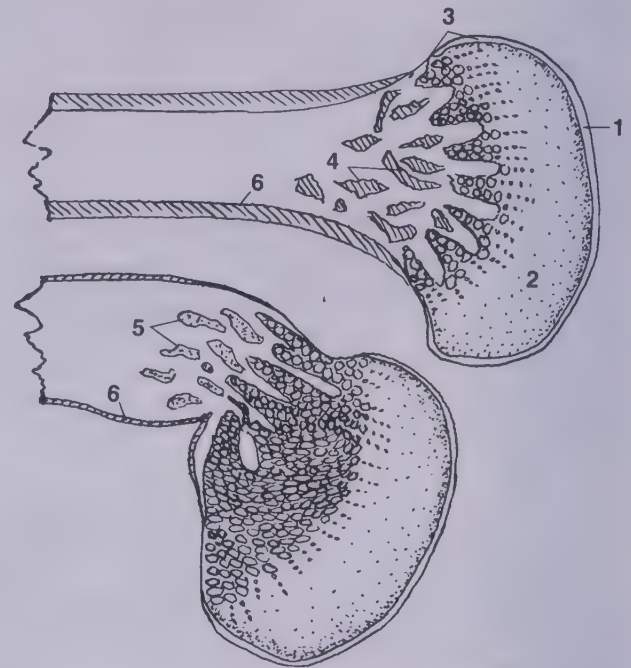


**FIG 42.8** Progression toward mature bone in a 190-day-old chick. 1) articular cartilage 2) epiphyseal cartilage 3) dense layer of bone beneath articular cartilage 4) physis 5) bone trabecula and 6) cortex (modified with permission from Fowler<sup>13</sup>).

The ossification of the tibiotarsal and tarsometatarsal bones is different. The epiphyseal center of ossification of the proximal end of the tibiotarsus becomes visible radiographically at 35 days in the chicken. The fibular and tibial tarsal bones, which make up the hock of mature mammals, fuse in avian embryos to the tibial cartilaginous model and appear as two epiphyseal centers in the seven-day-old chick. Likewise, the epiphyseal center at the proximal end of the tarsometatarsus corresponds to the distal row of tarsal bones in mammals. The carpals, metacarpals and phalanges of the wing ossify from a diaphyseal center in the same manner as long bones of the wing.

### Metabolic Bone Disease

Metabolic bone disease in the tibiotarsus and tarsometatarsus (bones with epiphyseal centers of ossification) appears similar to that described in mammals. If growth of the long bone continues by interstitial cartilaginous growth in the zone of proliferation without a sufficient supply of calcium and phosphorus, calcification of the intracellular substance between the mature cells ceases. Without calcification, the chondrocytes continue to live, causing thickening of the whole growth zone (Figure 42.9). Osteoblastic activity continues with the production of unmineralized osteoid tissue in the metaphysis. The stimulus for osteoid production is intensified because



**FIG 42.9** Comparison of normal avian ossification and ossification in a bone affected with metabolic bone disease. 1) articular cartilage 2) epiphyseal cartilage 3) physis 4) bone spicules 5) osteoid spicules 6) folding fracture and 7) cortex (modified with permission from Fowler<sup>13</sup>).

of the relative structural weakness of the unmineralized growth zone. This excessive osteoid production occurs subperiosteally, resulting in knobby growth centers. The radiographic changes are characterized by rickets, increased width of the physis, increased trabeculation in the metaphysis, lipping of the metaphysis and swollen distal extremities.<sup>40</sup>

The femur and wing bones lack epiphyseal centers of ossification. However, histologically, the same pattern of abnormal development takes place in the growth zone of a femur or wing bone in a bird with metabolic bone disease. The epiphyseal cartilage in birds corresponds to the epiphyseal ossification center in mammals.<sup>13</sup>

### Bone Grafts

Bone grafts promote fracture healing through osteogenesis (production of new bone), osteoinduction (recruitment of mesenchymal cells that differentiate into chondroblasts and osteoblasts) and osteoconduction (osteoblast ingrowth from the host into the graft providing structural and mechanical support). In general, cancellous bone is better than cortical bone


for grafting because the former has a larger surface area and a large number of viable cells for stimulating new bone production.

Autogenous medullary bone (collected from the tibiotarsus), corticocancellous bone (collected from the sternum or ribs) and cortical bone (devitalized fragments from the fracture site) have been shown to augment bone healing in birds.<sup>33,35,41</sup> Cortical allografts (same species, different individual) and xenografts (different species) were not found to stimulate nor inhibit bone healing when applied in an overlay fashion to humeral fractures in pigeons. There was less callus formation in the fractures supported by a graft but these birds also had a significantly higher occurrence of dehiscence, sequestration and foreign body reactions than birds with no grafts.<sup>28</sup> These findings suggest that the positive effects of cortical bone grafts in birds are limited to added fracture stabilization.

## Fracture Repair Techniques

It is best to have a command of a variety of fracture fixation techniques and to be ready with alternative plans at the time of surgery (see Table 42.1). Reassessment of the injury intraoperatively may necessitate a change in the surgical procedure. Each avian fracture is unique and may require a variety of maneuvers, techniques and instruments to achieve optimal reduction and immobilization.

Many closed fractures may heal without any type of coaptation or fixation. However, with unsupported long bone fractures, excessive callus formation, malalignment of the bone ends and shortening of the limb (overridden fractures) will dramatically reduce normal function. Non-displaced fractures of the pelvic girdle, coracoid, clavicle and scapula will generally heal with minimal support.<sup>21,39,46</sup> Displaced fractures of the coracoid must be surgically repaired or the fracture will usually result in an inability to fly.<sup>46</sup> Fractures of the radius or ulna, in which the other bone is intact, can generally be repaired with external coaptation and forced rest (Figure 42.10).<sup>38</sup>



**FIG 42.10** Minimally displaced fractures of the radius or ulna in which the other bone is intact can generally be repaired with a figure-of-eight wing-body wrap and forced rest; **a)** before and **b)** after coaptation (courtesy of Laurel Degernes).

### External Coaptation: Bandages and Splints

External coaptation is an inexpensive and rapid method of providing increased comfort to a patient (decreased movement of bone ends) and minimal stabilization of a fracture. Bandages and splints should be made of the lightest weight materials with the minimal amount of padding needed to compensate for swelling of damaged soft tissue. External coaptation is acceptable as a primary stabilization technique only when a limited post-fracture range of motion is satisfactory, a patient is too small to facilitate surgical repair, a fracture is minimally displaced or anesthesia and surgery would jeopardize the patient's life (eg, liver failure, kidney failure, heart disease, head trauma).

Fracture disease (malalignment of bone ends, muscle atrophy, joint ankylosis, shortened bone length and tendon contraction) is common in fractures repaired by external coaptation (Figure 42.11). In general, external coaptation should be considered an emergency method of stabilizing fractures until surgery can be performed or for providing additional support for fractures repaired by other methods.

Some companion birds may not require full return to flight; in these patients, some wing fractures can be effectively managed with external coaptation. Bandages or splints can be used to repair fractures of the distal legs and feet if the fracture can be properly



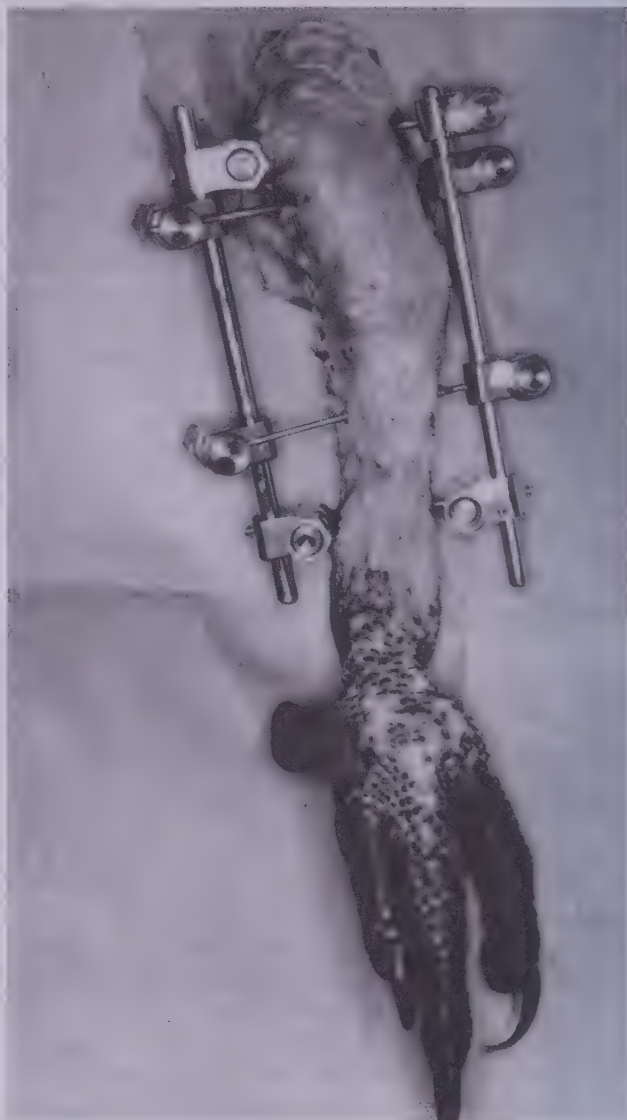**FIG 42.11** VD radiograph of a falcon with post-traumatic degenerative joint disease of the elbow. Improper fracture repair techniques are frequent causes of fracture disease in birds.

aligned and if any decrease in bone length does not alter the weight-bearing capacity of either limb and predispose the patient to arthritis or pododermatitis (see Chapter 16). Additionally, if leg function is altered, the companion bird may not be able to ambulate or adequatelyprehend food.

### External Fixators

Bony injuries in the avian patient tend to heal in a reasonable manner and are amenable to a variety of fixation methods. In contrast, maintenance of soft tissues and joint mobility, the most vital components of return of full function for birds, may be hindered by many of the techniques used for immobilization of fractures and luxations. External fixators are generally considered the best stabilization technique for immobilizing fractures in birds that require a full return to function.

Numerous types of external fixation devices have been described for use in birds (Table 42.5). A variety of Kirschner wires and Steinman pins may be passed into the bones, and a variety of connecting bars and acrylic cements can be used for stabilizing the pins.<sup>6,16,25,26,37,45</sup> These devices are inexpensive, lightweight, easy to remove and are well tolerated by many avian species. An external fixator can be easily removed from a calm patient without anesthesia. When properly used, external fixators provide rigid stabilization and preserve joint and periarticular structure, while neutralizing rotational, bending and shear forces.<sup>14,21,24,25,26,35,46</sup> The approach to the surgical site can be minimal and, therefore, decreases soft tissue damage and reduces post-fixation dysfunction of the limb.<sup>16,18,19</sup> In many cases, external fixators



**FIG 42.12** An external fixator is an ideal way to repair many fractures in birds. Either KE connectors, various cements or casting materials can be used to connect the stabilizing pins. In this case, a valgus deformity of the tibiotarsus was corrected with a dome osteotomy and stabilized with a Type II external fixator. The connecting bars should be as close to the skin edge as possible.

allow a bird to use a repaired limb within several days of surgery (Figure 42.12).

External fixators can be applied in conjunction with IM pins to further neutralize rotation and increase stability.<sup>43</sup>

Type II (through-and-through) fixators are more stable and stronger than Type I fixators, which tend to loosen rapidly (Table 42.5).<sup>6</sup> The use of positive-profile threaded pins in a Type I fixator configuration is

particularly useful in repairing fractures of the proximal humerus and femur, where interference with the body wall makes it difficult or impossible to place a Type II fixator (Figure 42.13).

External fixators are ideal for corrective osteotomies and open, comminuted fractures. In the latter situation, the fixator can be placed so that an infected wound can remain open for several days for flushing and evaluation.

### Application of an External Fixator

External fixator pins should be placed by making a small incision in the skin, and should not be placed through a primary incision site or open wound. This placement technique will decrease the likelihood that the pins will promote an infection at the surgical site. Pins should be inserted so that they avoid large muscle masses (minimizes loosening) and should be passed through pre-drilled holes to decrease wobble (improperly increases the size of the hole) and increase pin purchase on the cortices. It is best to place from three to four pins on each side of a fracture to decrease the stresses on any one pin. A minimum of two pins must be placed in each bone segment to ensure that the fixator will provide adequate fixation without rotation.

TABLE 42.5 Fixator Types Listed in Increasing Strength

<b>Type I</b>	Half-pin splint - Pins penetrate one skin surface and both cortices. Connecting bars only on one side of the limb.
<b>Type II</b>	Full pin splint - Pins pass through both skin surfaces and both cortices. Connecting bars on both side of the limb in one plane.
<b>Type III</b>	Type I and Type II splints placed at a 90° angle to each other. Fixators are connected to each other. Creates a three-dimensional frame.

Positive-profile threaded pins inserted through pre-drilled holes have been found to maintain solid bone-to-pin interfaces for prolonged periods (up to three months) in some birds (Aron DN, unpublished). By comparison, other types of threaded or unthreaded pins are frequently loose in the cortex within three to six weeks of insertion. The diameter of positive-profile threaded pins is not reduced by the threading process and these pins are less likely to fail from the stress-riser effect than other types of threaded pins.<sup>2,18</sup> Placing unthreaded pins at an angle (35 to 55°) perpendicular to the bone will decrease the chance that the fixator will slip from side to side, but

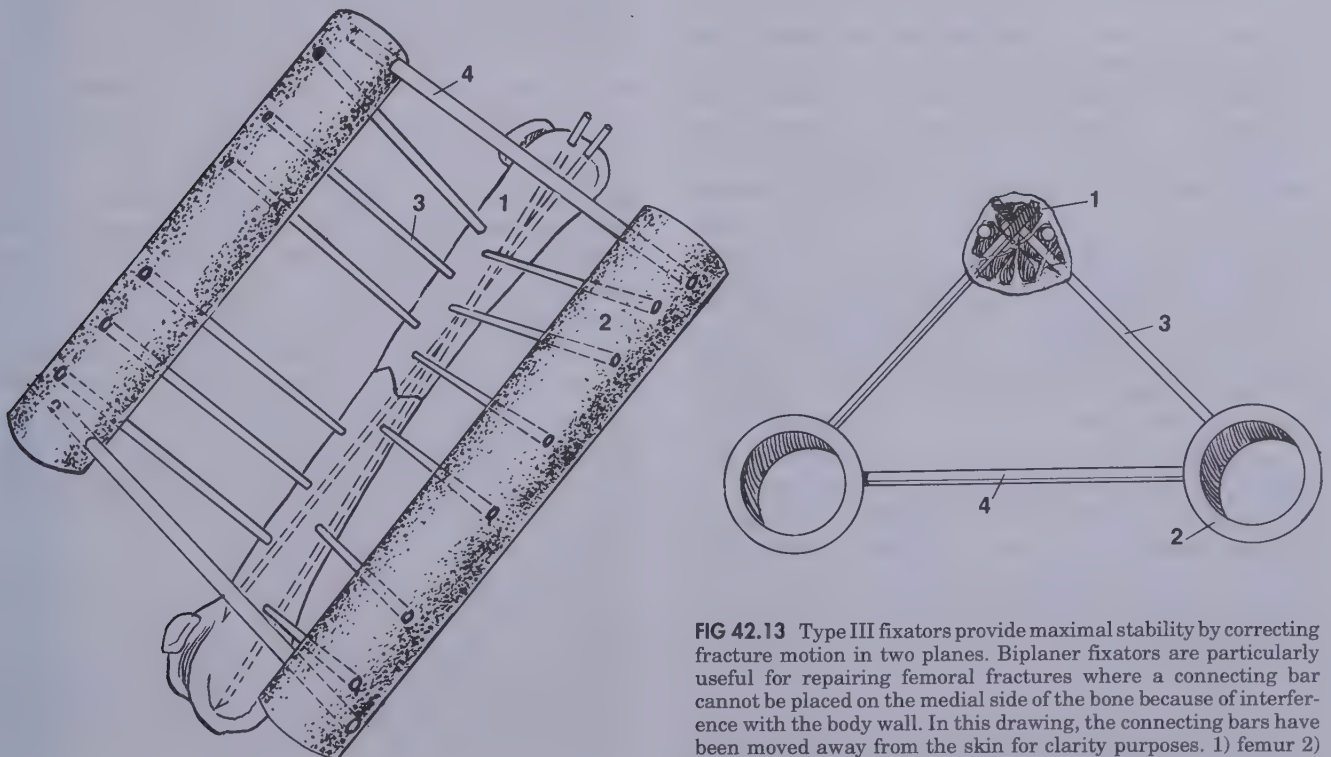


FIG 42.13 Type III fixators provide maximal stability by correcting fracture motion in two planes. Biplaner fixators are particularly useful for repairing femoral fractures where a connecting bar cannot be placed on the medial side of the bone because of interference with the body wall. In this drawing, the connecting bars have been moved away from the skin for clarity purposes. 1) femur 2) connecting bars 3) stabilizing bars and 4) cross bar.

would not be expected to be as effective as positive-profile threaded pins.

The connecting bar for the fixator pins should be placed as close as possible to the skin (taking into account anticipated swelling) to increase the strength of the apparatus. Standard Kirschner-Ehmer (KE) fixator hardware can be used to stabilize fractures in medium- or large-bodied birds. Their primary limitations are their size and weight.

It is extremely difficult to properly align a group of stabilizing pins that are passed free-hand. If they are not properly aligned, the pins cannot be attached to the connecting bars by KE fixator hardware. The easiest way to apply a KE fixator is to place the most proximal and distal stabilizing pins through the bone. The connecting bar is equipped with the desired number of clamps (minimum of four), and the first and last clamps are connected to the already inserted proximal and distal pins. The interior clamps are then used as a drill guide for placement of the remaining stabilizing pins.

In addition to KE clamps, stabilization pins can be connected with polymethylmethacrylate,<sup>b</sup> cast material<sup>c</sup> and dental acrylic.<sup>26,29,36,38,45</sup> In comparison to KE clamps, these materials are inexpensive, lightweight and are malleable so that pins that are not in perfect alignment can be easily connected. The tips of the stabilizing pins can be carefully bent parallel to the long axis of the bone to increase their holding strength in the connecting material. During the bending process, the pin should be stabilized to ensure that no forces are applied to the fracture site, the bone pin interface or associated joints.

Polymethylmethacrylate (PMM) can be attached to the stabilizing pins by mixing the material until it is the consistency of dough and then molding it around the stabilizing pins. The material can also be used by passing the stabilizing pins through a hole in a clear plastic tube (eg, clear straw). The plastic tubes used for a mold should be thin-walled to ensure that the methylmethacrylate column is of adequate diameter (approximately equal to that of the bone). When the pins are properly positioned (fracture site reduced and in proper alignment), the PMM is placed in a syringe and injected into the straw while it is still liquid. The fracture is held in place until the PMM hardens (generally ten minutes).

A soft metal connecting bar with numerous holes has recently become available.<sup>d</sup> The stabilizing pins are passed through the holes in the connecting bar, which

is then crimped to firmly secure the pins. These connecting bars are light-weight and inexpensive.<sup>16</sup>

In birds that weigh less than 200 g, hypodermic needles can be used as stabilizing pins and these can be attached with cyanoacrylate glue (SuperGlue) to other needles or tooth picks that function as temporary connecting rods. An index card can be fashioned into a V-shaped trough and placed over the pins. Five-minute epoxy cement is then poured into the trough to firmly bind the stabilization pins and connecting bars.

## Intramedullary Fixation

### Intramedullary Pins

Generally, intramedullary pins neutralize bending forces and provide adequate fracture alignment, but they do not protect the fracture from rotational or shear forces.<sup>6,21,33,46</sup> Minimal rotational deformities in the wing bones can inhibit flight by altering the dynamics of the wing aerofoil.<sup>9,19,46</sup> Techniques that use IM pins in combination with external coaptation have been frequently discussed in the literature; however, the combination of these two fixation techniques should be avoided to prevent ankylosis of the associated joints.<sup>6,8,14,16,19</sup> Because of the relatively thin cortices of birds, the use of threaded IM pins has been suggested to provide better bone purchase than non-threaded pins.<sup>36,37,42</sup> However, IM pins are primarily used to counter bending force which would not be influenced by the degree of purchase in the cortex.<sup>21</sup>

*Editors' note: Intramedullary pins have several disadvantages when compared to external fixators. They have the inherent potential to cause articular and periarticular damage resulting in ankylosis of the joints. Even properly placed pins that exit near a joint can cause sufficient tendon or ligament damage, resulting in a partially dysfunctional limb. Unless an IM pin can be placed so that it does not exit through or near a joint, it is best not to use this method of internal fixation in birds that require full post-fixation use of a limb. Even pins that do not exit near a joint can still injure the vasculature and significantly alter the growth pattern of the bone.<sup>13</sup>*

*Retrograde placement of pins through the distal humerus, normograde placement from the lateral or medial epicondyle of the humerus, placement through the distal ulna or retrograde placement from the elbow can cause severe periarticular fibrosis and wing dysfunction.<sup>17,46</sup>*



The use of IM pins, with or without interfragmentary wires, is effective for stabilizing some fractures in companion birds when clients are not concerned with postsurgical return of flight. When IM pins are used, they should be of sufficient size to fill about one-half to two-thirds of the medullary canal.<sup>12,36-38</sup> In mammals, current theories suggest that the pin should occupy approximately 60% of the medullary canal; however, in birds, excessively large pins can interfere with endosteal blood supply, which may cause avascular necrosis or iatrogenic fractures.<sup>6,8,14</sup> In order to compensate for these problems, stack-pinning, cross-pinning or Rush-type pinning with multiple, small-diameter pins has been recommended for use in birds. However, placement of the pins with any of these techniques induces excess cortical damage.

Cerclage, hemicerclage and interfragmentary wires can be used as an adjunct to internal or external coaptation to neutralize rotational and shear forces. They are most useful for adding stability to long oblique and spiral fractures and for holding fragments of bone in apposition during the application of other fixation devices.<sup>41</sup>

Long bone fractures fixed with intramedullary pins alone are often immobilized with bandages or splints for 10 to 21 days. A significant loss in post-surgical range of motion should be expected when bandages are used in combination with intramedullary pinning.<sup>3</sup>

#### Intramedullary Polymer Pins

Several techniques have been described for the insertion of high-density polymer rods, polypropylene welding rods or polymethylmethacrylate into the medullary canal.<sup>17,24-26</sup> Plastic and acrylic rods have been successfully used in combination with external fixators for additional stability. The polymer rods are lighter than IM pins, inexpensive, biologically inert, provide for stable fracture repair and do not require removal when the fracture is healed.<sup>4,21,24</sup>

In one study, fractures of the wing repaired with IM polymer rods allowed rapid post-fixation exercise (seven to ten days) and most birds were able to fly 14 to 21 days postsurgery.<sup>24</sup> However, because the rods must be inserted using a shuttle technique (technically difficult), the length of the pin is limited to the longest fracture segment and the pin may not be passed into the shorter fragment segment to a sufficient depth to provide adequate stability.<sup>24-26</sup> Additionally, these techniques dictate that a foreign material remain in the medullary canal, which is likely

to alter the biomechanical response of a portion of the wing to stresses induced by flight.<sup>24</sup>

#### Intramedullary PMM

Polymethylmethacrylate has been used in the intramedullary canal of birds to aid in fracture stabilization. This material comes as a liquid monomer and a powdered polymer that, when mixed together, undergoes polymerization that is exothermic (100°C).<sup>16,19</sup> The high temperatures associated with polymerization do cause bone necrosis, and application of cool water has been suggested as a method of dissipating heat.<sup>18,35</sup> The material generally hardens in ten minutes. This method of fracture fixation does have the advantage of being fast and inexpensive, providing rapid stability and allowing almost immediate return to function without joint insult.

The inhibition of endosteal callus formation, endosteal blood supply (that is theorized to occur) and the intramedullary bone necrosis (that is known to occur) have not been shown to interfere with the clinical outcome of fracture healing.<sup>18,19,21,35</sup> The most significant interference with healing occurred when polymethylmethacrylate was allowed to pass between the bone ends and inhibit callus formation. If the humerus or femur are overfilled with PMM, the material may enter the connecting air sacs.

Methylmethacrylate should not be used in open wounds where infectious agents are likely. If the methylmethacrylate is contaminated with bacteria, the material can serve as a chronic source of infection.<sup>18,19</sup> The necrosis that occurs during the polymerization process and the damage to the endosteal blood supply would theoretically predispose an affected limb to osteomyelitis.<sup>35</sup> In humans, heat-stable antibiotics (cephalothin, potassium penicillin) have been added to the polymer to provide up to five years of bacteriostatic activity.<sup>35,44</sup> The effects of long-term exposure of birds to these antibiotics have not been investigated.

Given the uncertainties about the long-term effects of IM PMM (particularly in the wing bones of free-flighted birds), this technique should be used with caution. Techniques have also been reported using polymer rods in conjunction with IM PMM.<sup>10,22,23</sup> The advantages and disadvantages of these techniques are similar to those described with either technique alone.

## Bone Plates

Bone plates have been infrequently discussed for use in birds because of their thin cortices (undetermined whether a real or perceived concern) and their relative lack of soft tissue.<sup>6,14,24,41,46</sup> In addition, traditional bone plating equipment is expensive and the technique requires specialized training and prolonged anesthesia times.

The availability of small, lightweight bone plates has made these devices more worthy of consideration for repairing some avian fractures. Small finger plates designed for humans, cuttable metal plates<sup>e</sup> and acrylic plates are available in sizes useful for fractures of long bones in birds of 350 g or more.<sup>5,15,19</sup>

Bone plates have been successfully used to achieve what clinically and radiographically appear as primary bone healing in larger birds (ratites).<sup>20,41</sup> When they are used, bone plates have the advantage over other fixation techniques of providing rigid fixation with minimum callus formation and joint involvement.<sup>18,19,33,35</sup> Another advantage of plates is that they are completely internal and therefore are well tolerated by birds.

The stress junction at the end of the plate is susceptible to fracture. In raptors, plates used for the repair of closed fractures resulted in long healing times and rehabilitation periods, but produced excellent reduction and alignment of the fractures and a high level of return to full function.<sup>9</sup>

Some avian fractures are not conducive to being repaired with bone plates. Plates can serve as a nidus for infection and are not recommended for use in open fractures. Plates usually require a relatively long healing and rehabilitation time because of the “shielding effects” the plate induces with respect to underlying bone. After a plate is removed, the underlying bone may fracture (usually through the screw holes) if normal use is resumed immediately. Therefore, gradual physical therapy programs should be instituted. Movement should be limited for the first seven to ten days following removal of the plate, and then the bird should be allowed to gradually return to normal function. Plates

### CLINICAL APPLICATION

- The long-term effect of infusing polymethylmethacrylate into the medullary canal of birds has not been determined. The presence of any foreign material in the medullary canal of a bone would be expected to change its response to applied forces (particularly those involved with flight).

can conduct cold and lead to deep bone pain as well as frostbite of surrounding tissues and should generally be removed in birds that will be released to the wild. Plates can remain in place if the bird is not exposed to freezing temperatures or the plate does not cause any specific problems.

## Doyle Technique

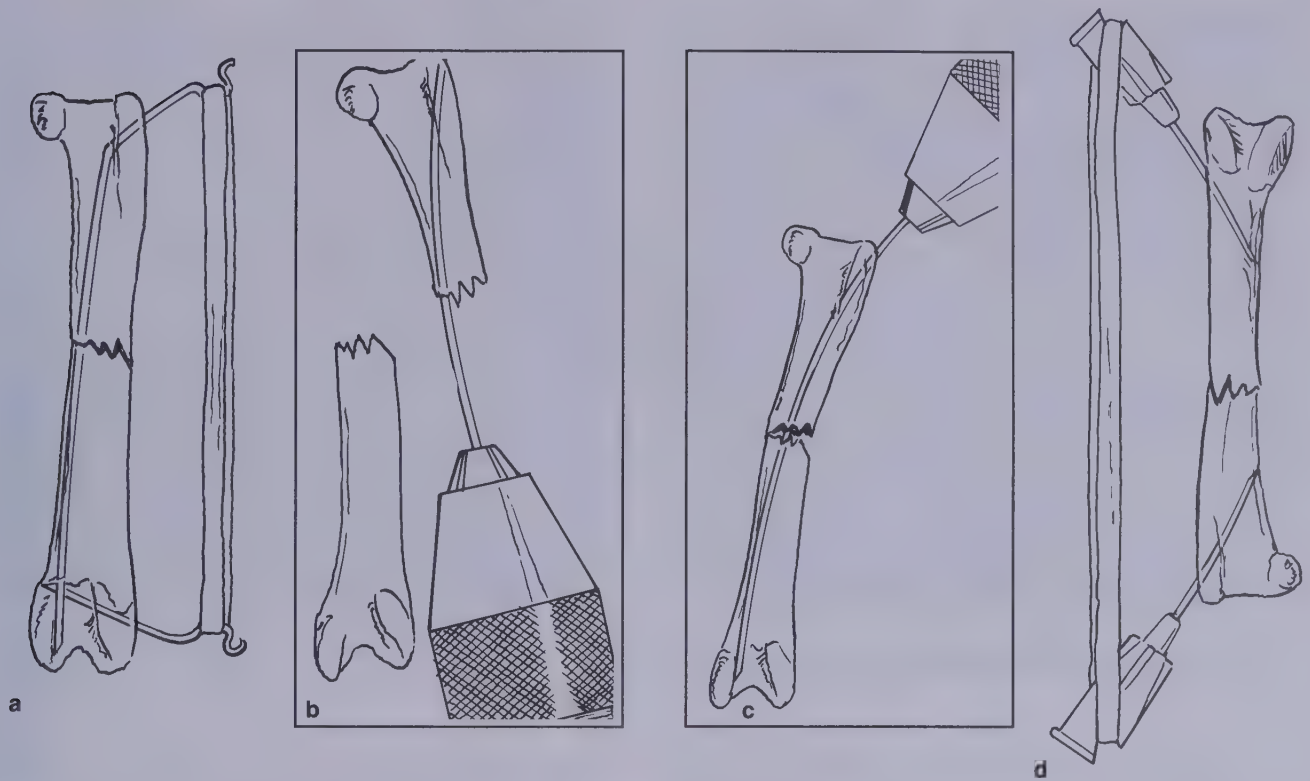
A fracture fixation method has been developed (Doyle JE, unpublished) that combines intramedullary pinning concepts with those of external fixation (Figure 42.14). In both the distal and proximal fracture segments, a pin is placed through one cortex and angled to bounce off the opposite cortex and remain in the medullary canal (Figure 42.15). Hooks are fashioned on the external end of each pin, and the fracture site is then compressed and stabilized by stretching a dental impact type rubber band<sup>f</sup> over the hooks of each pin. The technique requires that the smallest fracture segment be of sufficient size for the safe placement of a stabilizing pin. Kirschner wires (0.028, 0.035, 0.045 or 0.062 cm) are adequate for most avian fractures. In small birds, various-sized catheter needles or hypodermic needles can be used in place of the K wires.

This technique compensates for several problems that typically occur with intramedullary pinning techniques:

- The pins placed in the medullary canal do not damage periarticular tissue.
- Smaller pins can be used in order to prevent trabecular damage and excessive fixator weight.
- Maximum compression of the fracture site is achieved.



**FIG 42.14** Use of the Doyle technique to repair a diaphyseal tarsometatarsal fracture in a cockatoo.



**FIG 42.15** a) Doyle technique to repair long bone fractures. This technique allows for the use of intramedullary pins while reducing the degree of perivascular and trabecular damage and providing the maximum compression of the fracture site. Note that the longest pin does not penetrate the cortex of the bone, and that the shortest pin is placed into the cortex. b,c) A battery- or air-driven drill is used to place the pins. A dental rubber band attaches the cupped ends of the pins. d) In small birds, side cutters are used to notch the hubs of hypodermic needles, which are used in place of intramedullary pins.<sup>14a</sup>

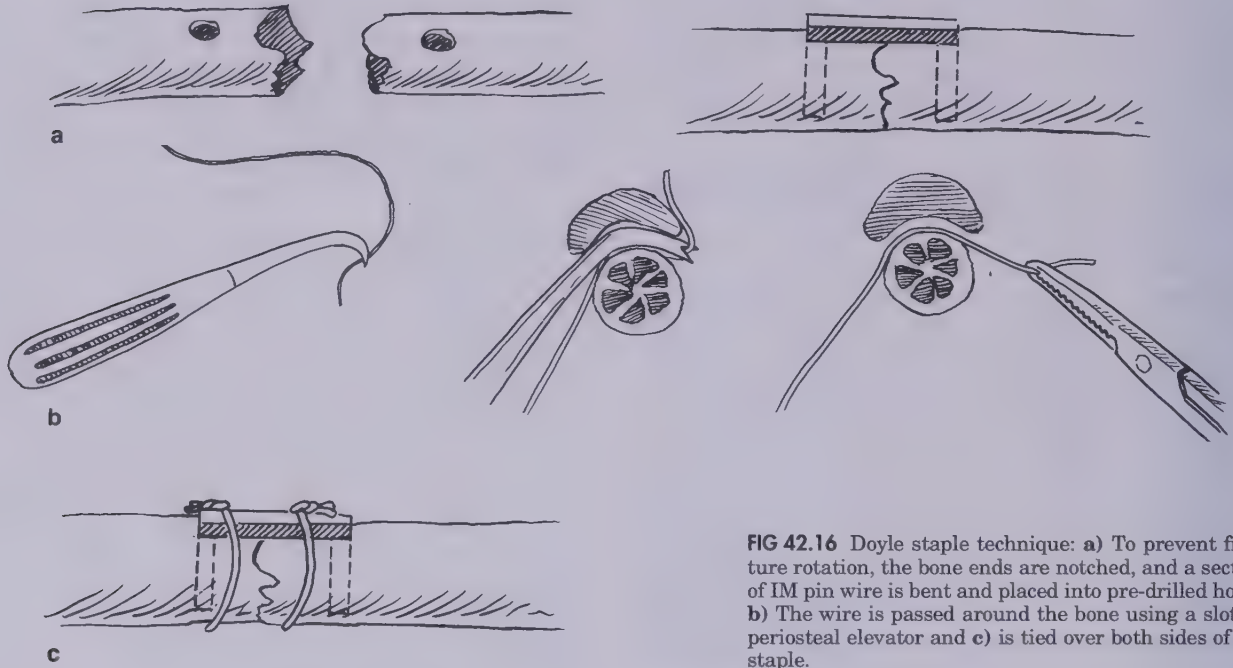
- The joint is not involved in the repair process.
- The bird will have less of a problem with fixation-induced fracture disease.

As with any pin that is placed through the cortex, the stabilizing pins used in this technique should be inserted through pre-drilled, appropriately sized holes (smaller than the pin size). The pin is inserted as far away from the fracture as possible without compromising the periarticular tissues. Once the pin has entered the cortex, the angle is changed so that the pin bounces off the opposite cortex and can be threaded into the medullary canal, past the fracture site and as deep as possible into the smaller fracture segment (the long pin should not penetrate through the cortex in the smaller segment) (Figure 42.15).

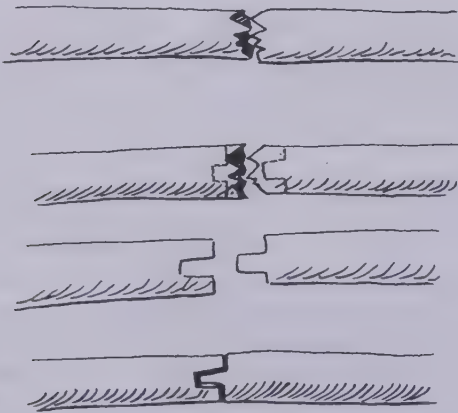
The exterior portion of the pin is bent in two places using locking pliers. A right angle bend is placed in the pin as it exits the skin so that the pin is relatively perpendicular to the bone. A semicircle (hook) is fashioned in the end of the pin about 1 cm from the skin. A

second pin is placed in the smaller fracture segment. This pin is inserted at a 45° angle to the long axis of the bone and parallel to the initial pin. This pin should penetrate but not exit the opposite cortex. A rubber band is placed around the hooks to compress the fracture. Postoperatively, several opened gauze pads are placed between the skin and the rubber band to prevent irritation. The affected appendage is placed in an appropriate bandage (leg: Robert Jones; wing: figure-of-eight body wrap). The rubber bands can generally be removed within 10 to 21 days, and the pins between 21 and 40 days after surgery.


Fractures that are minimally displaced and have recently occurred can be repaired in a closed fashion. Fractures that are several days old or that are displaced must be repaired in an open fashion, and any tissue debris or fibrous connective tissue should be removed from the bone ends. Either cerclage wires or fracture transverse staples can be used to minimize over-riding or rotation in oblique and comminuted fractures (Figure 42.16). Transverse fractures

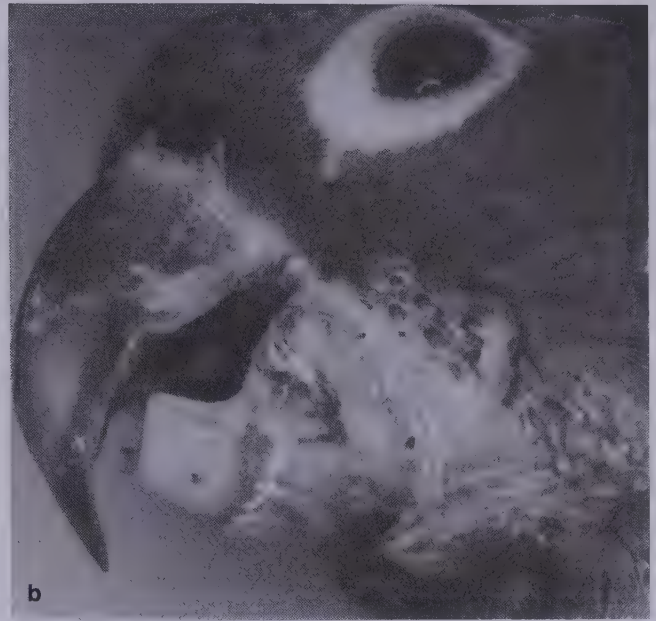
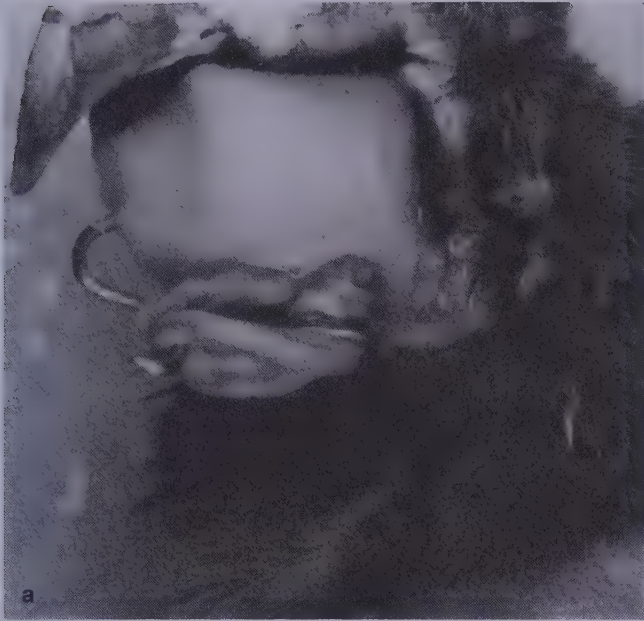


**FIG 42.16** Doyle staple technique: **a)** To prevent fracture rotation, the bone ends are notched, and a section of IM pin wire is bent and placed into pre-drilled holes. **b)** The wire is passed around the bone using a slotted periosteal elevator and **c)** is tied over both sides of the staple.



**FIG 42.17** Doyle technique for slotting the end of fractures to reduce rotation. The bone ends are most easily notched using a sagittal saw. For additional stability, a section of the bone end can be removed (arrow) and placed in a slot created in the end of both fracture segments.





**FIG 42.18** a) A bite wound to the mandible in a conure resulted in rhamphothecal damage. A Doyle apparatus was applied to stabilize the fracture. The defect in the beak was covered with calcium hydroxide and a hydroactive dressing before being sealed with cyanoacrylate. b) The pins and cyanoacrylate were removed in four weeks and the mandible and beak were healed.

are most likely to rotate. This rotation can be reduced by notching the ends of the bone fragments with a sagittal saw and then applying a Doyle compression apparatus (Figure 42.17).

The Doyle technique can be used in combination with cleaning, calcium hydroxide and acrylics to repair the beak and fractures of the mandible. Pins are placed into the fracture segments and connected with rubber bands. The fracture site and beak defect are covered with calcium hydroxide paste to prevent dental acrylic from entering the defect and causing a malunion. The fracture is then covered with dental acrylic or a hydroactive dressing. The defect and fracture will generally require six weeks to heal (Figure 42.18).

## Surgical Approaches

During a surgical procedure, every attempt should be made to identify and follow the natural separations between muscles and along fascial planes. In most instances, surgical approaches can be planned to avoid muscles completely, which will reduce the degree of surgically induced soft tissue damage. Inci-

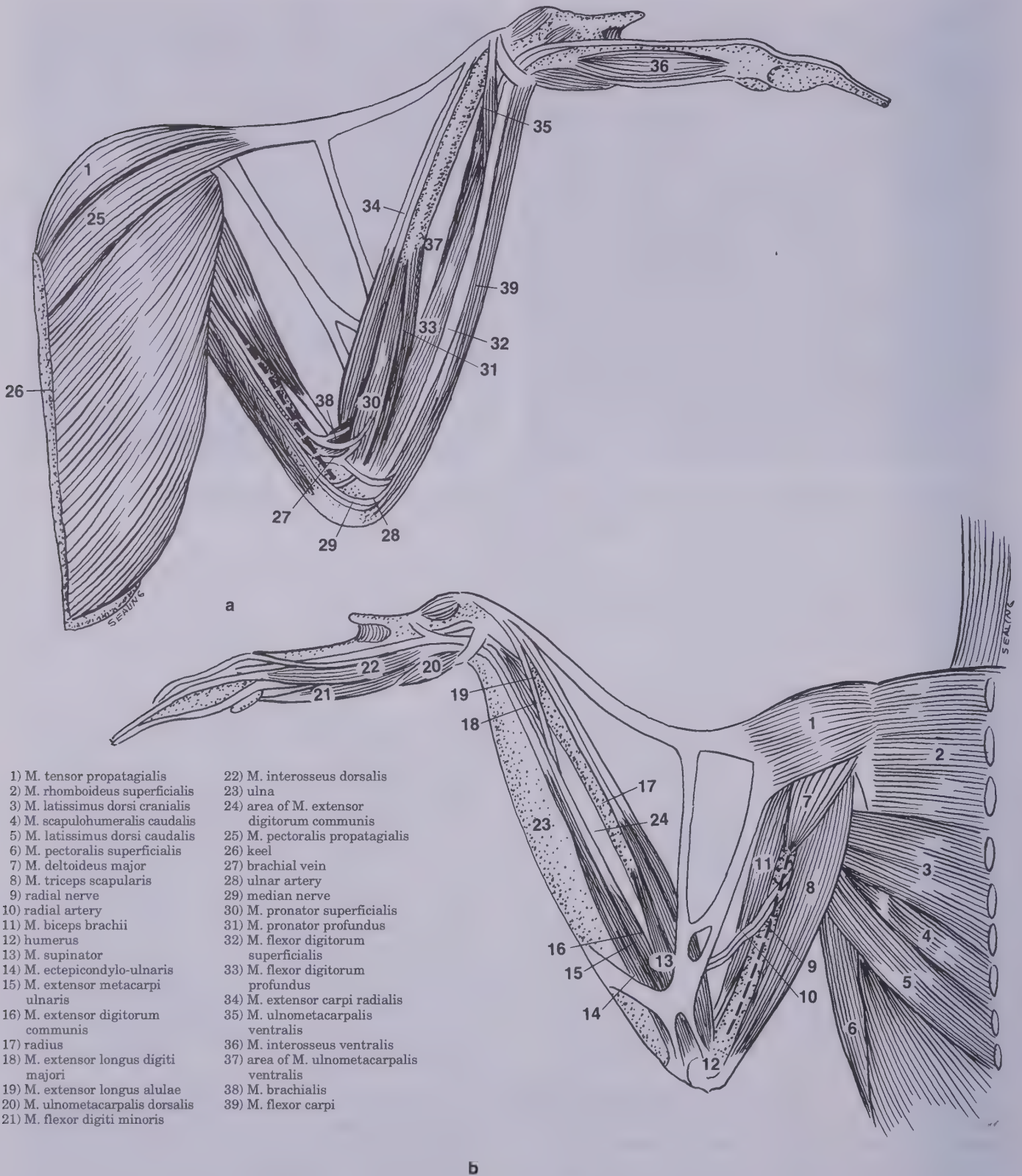
sion or bruising of the proptagium should always be avoided.

### The Wing

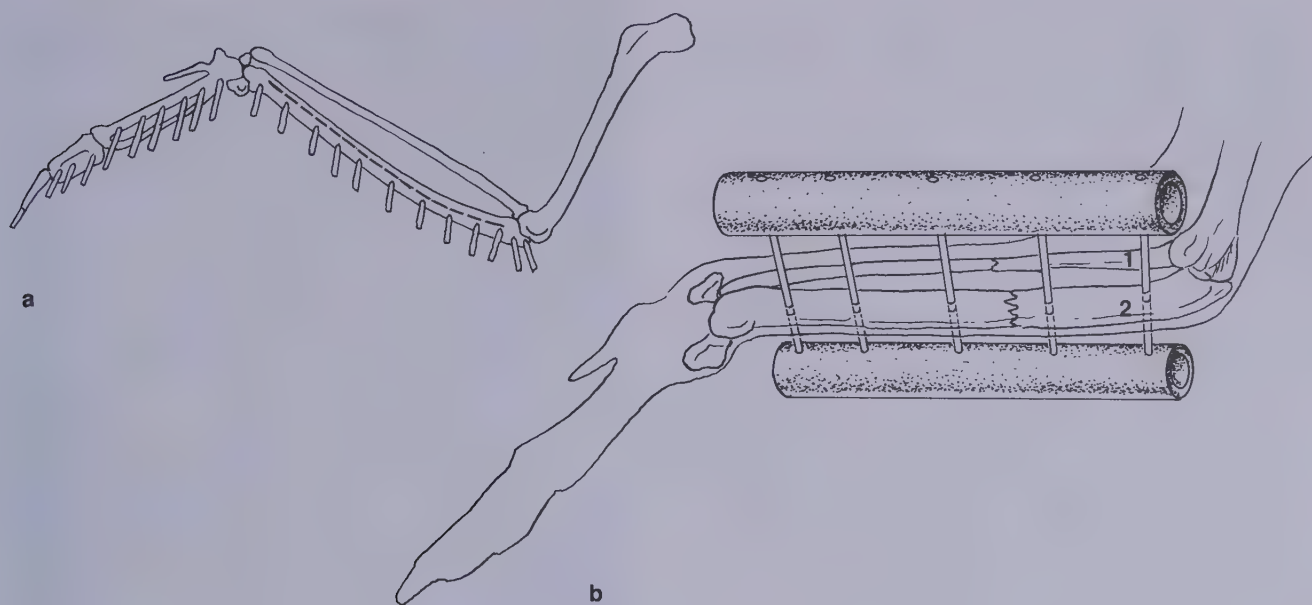
#### The Carpometacarpus

Figure 42.19 illustrates the anatomy of the wing. Repair of metacarpal fractures is meticulous. If the single artery and vein located between the third and fourth metacarpal bones are damaged, avascular necrosis to the distal portion of the wing can occur.<sup>41</sup> The most direct approach to fractures of the carpometacarpus is the dorsal approach. The bone can be visualized immediately beneath a dorsal skin incision. A ventral approach requires that soft tissues, tendons and blood vessels be separated in order to approach the main, or primary, metacarpal bone. Minimally displaced closed fractures of the carpometacarpus may be repaired with a figure-of-eight bandage (see Chapter 16). The clinical drawback to bandages is the loss in range of motion of the carpal joint while the fracture is healing.

Fractures of the carpometacarpus are ideally suited for small, lightweight external fixators that allow freedom of movement in the carpal joint. These are usually applied using small K wires or hypodermic needles and then attached by a connecting bar composed of plastic tubing filled with methylmethacryl-



**FIG 42.19** Overview of surgically important anatomic features of the left wing. Dotted lines represent surgical approaches to the humerus. **a)** Ventrodorsal view and **b)** Dorsoventral view.



**FIG 42.20** Dorsal approach to the radius and ulna. **a)** An incision (dotted line) is made in the dorsocranial aspect of the ulna just cranial to the insertion point of the secondary feathers. **b)** A type II fixator is preferable for stabilization of the ulna. The ventral connecting bar should be padded to reduce damage to the body wall. The dorsal connecting bar has been elevated away from the skin margin for clarity purposes. 1) radius and 2) ulna.

ate cement. IM pins may be added to help with alignment; these are usually placed through the fracture site and normograded distally and then retrograded back to the proximal fragment. Passing IM pins normograde from the carpus reduces the damage to the carpal joint.<sup>41</sup>

In larger birds, small plates may also be used; however, wound closure may be difficult due to the lack of subcutaneous tissues.

### The Radius and Ulna

Occasionally, birds are presented with fractures of the radius alone. Given the larger size of the ulna, radial fractures are often anatomically stabilized and splinted by the larger ulna. Bandages or simple enclosure rest may result in adequate fixation of minimally displaced radial fractures. If displaced, IM pins introduced through the fracture site and normograded out toward the carpus (avoiding the joint) and then retrograded back through the proximal fragment may be useful in reducing the fracture. External fixators may be used alone or in combination with IM pins. External fixators are easily applied to ulnar fractures.

Traumatic injuries frequently cause fracture of both the ulna and radius. For minimally displaced mid-shaft fractures, bandaging or external coaptation

(figure-of-eight to immobilize the elbow and carpus) may be adequate. However, given the resulting decrease in range of motion of the elbow and carpal joints, it is preferable to repair these fractures with external fixators. Concomitant use of intramedullary or shuttle pins to provide alignment and increased stability is helpful. Plates may also be used on fractures that are closed.

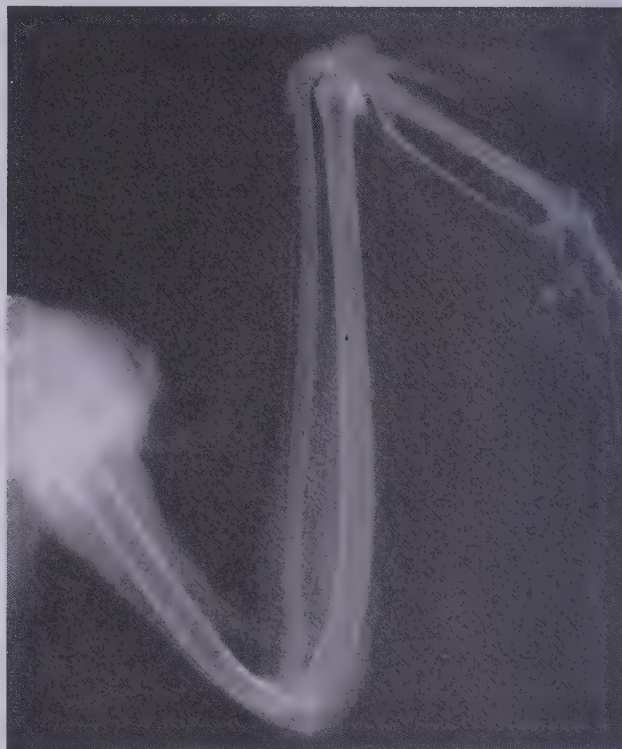The dorsal approach to the radius and ulna is preferred. An incision is made on the dorsocranial aspect of the ulna just cranial to the insertion point of the secondary feathers (Figure 42.20). In some cases in which both bones are broken, repair of the ulna alone is sufficient. However, with severely displaced fractures, the surgeon may need to stabilize the radius to allow proper healing. The same incision may be useful for stabilizing both bones depending on the location of the radial fracture. The intraosseous space between the radius and ulna houses the radial nerve and the radial artery, both of which should be avoided. The ulna can be easily identified and exteriorized for debridement and repair through the dorsal incision. If intramedullary pins are used, they are introduced through the fracture site and retrograded out the olecranon (avoiding the elbow) and then normograded into the distal fragment.

To approach the radius separately, an incision is made over the dorsal aspect of the radius between the extensor metacarpi radialis muscle anteriorly and the extensor digitorum communis over the intraosseous space. IM pins placed in the radius can be retrograded out through the distal radius and then normograded back into the proximal fragment. Badly displaced radial and ulnar fractures can usually be repaired by applying an external fixator or shuttle pin in the ulna, and placing a simple intramedullary shuttle pin in the radius. Plates can be used to repair ulnar fractures.

### The Humerus

Humeral fractures usually require open fixation because contraction of the pectoralis and biceps brachii muscles pulls the distal bone fragment proximally, creating a displaced fracture (Figure 42.21). A dorsal approach is recommended for most fractures of the humerus (Figure 42.22). This procedure avoids transection of the brachial vein and artery over the medial aspect of the bone, as well as the medianoulnar nerve. However, the surgeon must cautiously incise dorsally over the midsection of the humerus to avoid the radial nerve. Once the incision is made through the skin, the radial nerve should be immediately identified and retracted. The humerus is exposed immediately beneath the skin. Proximally, the muscles of the biceps and deltoids will overlie the humerus. For a ventral approach, the surgeon makes an incision over the craniomedial aspect of the humerus, taking care to avoid the medianoulnar nerve and the brachial artery and vein. The easily separable muscles of the biceps, the pectorals and the triceps converge proximally (see Figure 42.19).

A variety of methods may be used to repair fractures of the humerus. The choice of fixation technique is based on the nature of the fracture, the type of patient and the surgeon's experience. External fixators in combination with shuttle pins or intramedullary pins are preferred for free-ranging birds. Type II external fixators should be carefully applied to prevent pins and connecting bars from inducing soft tissue trauma medially on the trunk of the animal. Threaded pins in a Type I or biplanar Type I external fixator will reduce the chances of fixation-induced injuries to the animal. Stabilizing splints and bandages must immobilize the shoulder joint as well as the elbow and, therefore, must be wrapped around the body of the bird. Some birds may be highly intolerant of this type of bandaging.



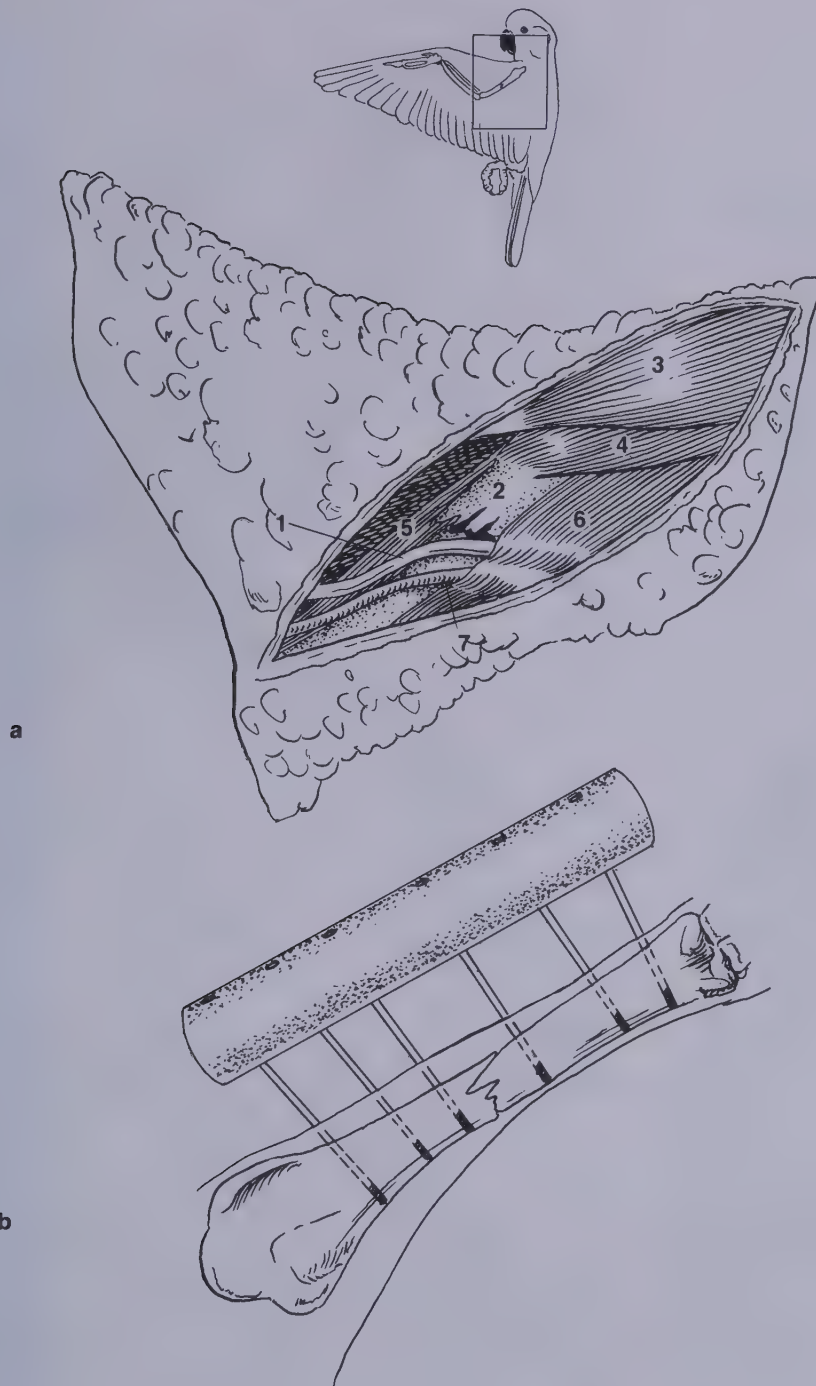
**FIG 42.21** Contraction of the pectoralis and biceps brachii muscles usually pulls the distal fragment of a humeral fracture proximally. The resulting displacement of the bone necessitates open reduction and repair (courtesy of Laurel Degernes).

### The Coracoid

Birds can fracture the coracoid by flying into large, solid objects such as walls, windows or cars. Minimally displaced fractures may be stabilized successfully by bandaging the wing to the body. Surgical correction is necessary if the fracture is markedly displaced. A skin incision is made along the caudal edge of the furcula starting laterally and then continuing medially along the lateral edge of the keel for the first one-fifth or one-sixth of the length of the keel bone (Figure 42.23).

The superficial pectoral muscle is encountered, and an incision is made through the superficial pectoral muscle along the caudal edge of the furcula. This muscle can then be elevated from the keel bone medially. Radiosurgery is necessary to control hemorrhage from the clavicular artery, which supplies part of the pectoral muscle. This vessel is usually encountered at the caudal midpoint of the furcula. An incision or blunt dissection is used to penetrate the deep pectoral muscle. The coracoid is located immediately beneath the deep pectoral muscle and runs from the point of the shoulder at approximately a 45° angle to





**FIG 42.22** Dorsal approach to the left humerus. **a)** The skin over the dorsal humerus should be carefully incised to avoid cutting the 1) radial nerve. The 2) humerus is visible immediately beneath the incision. Exposure to the proximal humerus is prevented by the 3) *M. tensor propatagialis* and the 4) *M. deltoideus*. The 5) *M. biceps brachii* is seen on the cranial edge of the humerus and the 6) *M. triceps scapularis* is located caudally. The 7) radial artery runs caudal to the nerve. **b)** A Type I external fixator in conjunction with positive-profile threaded pins can be used for stabilization of humeral fractures. The connecting bar has been raised from the skin edge for clarity purposes.

the cranial aspect of the sternum. Trauma associated with a fractured coracoid can be significant, resulting in massive soft tissue damage and hematoma formation. Because of the location of the coracoid, the surgeon works in a small, deep hole, and radiosurgery as well as irrigation are mandatory to keep the surgical field clean.

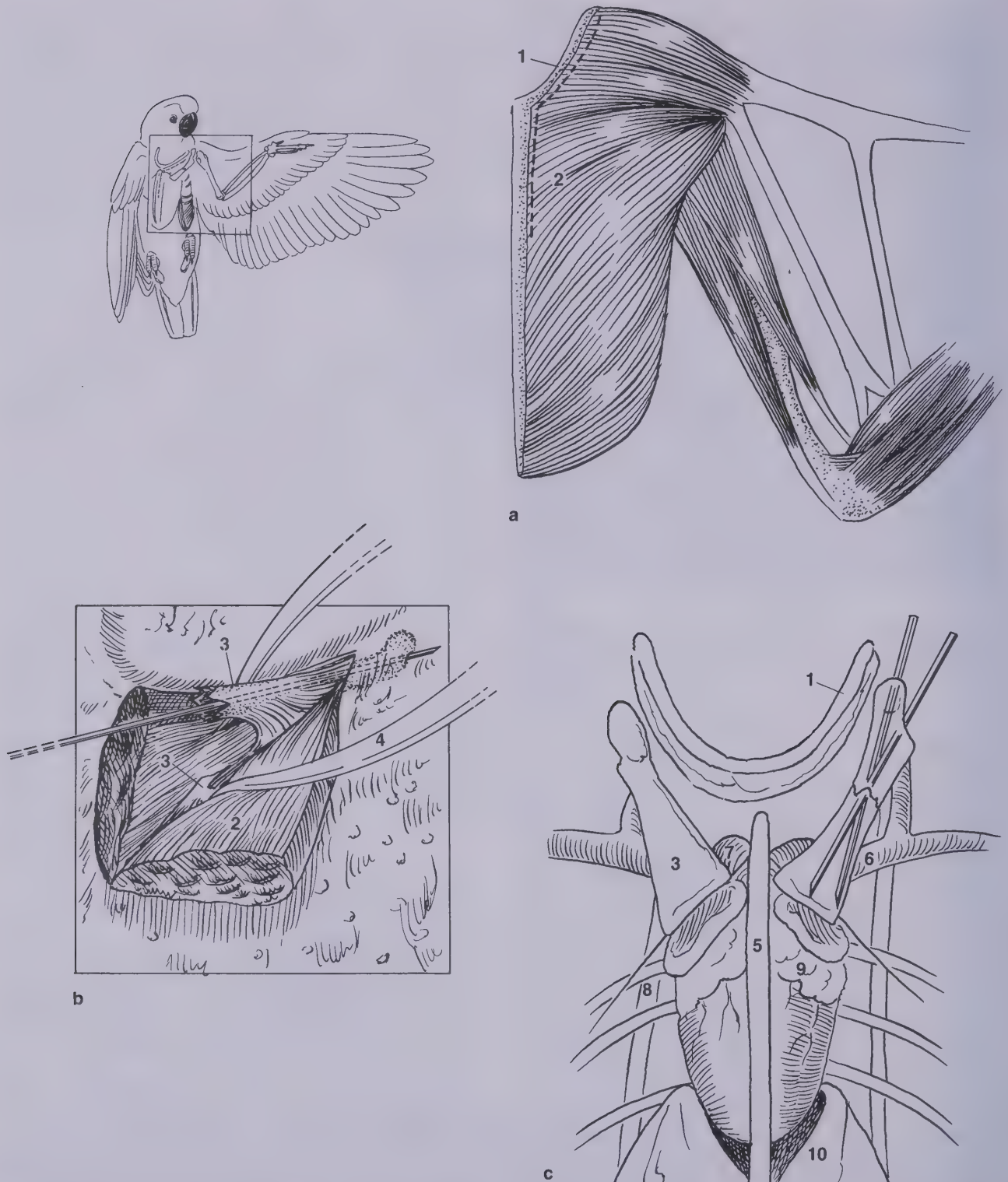
The proximal fragment of the coracoid should be grasped and rotated into the incision. Following cleaning and debridement, multiple small intramedullary pins are introduced at the fracture site and exteriorized through the point of the shoulder. The distal fragment is rotated up into view and cleaned, and the fracture is aligned. Intramedullary pins must be carefully normograded back into the distal fragment. If the pins are advanced too far caudally and penetrate the sternum, the pins may perforate the pericardium and the heart. This problem can be prevented by carefully measuring the length of the distal fragment and using this distance to advance the pins. Muscle bellies are re-apposed using a simple continuous pattern and absorbable suture material. The superficial pectoral muscle may also be secured to the furcula. The wing should be wrapped to the body for five to ten days following surgery.

### The Leg

Fractures of the tibiotarsus, tarsometatarsus and phalanges are best repaired using external fixation techniques (Figure 42.24).

### The Tarsometatarsus

The approach to the tarsometatarsus is simple because of the lack of soft tissues in this area. A lateral dorsal or medial dorsal approach may be used. A straight dorsal approach is generally not used because of the scutes overlying this area and the extensor tendons beneath. The sur-



**FIG 42.23** Surgical approach to the coracoid. **a)** A skin incision is made along the caudal edge of the 1) clavicle starting laterally and continuing medially along the lateral edge of the keel. **b)** The 2) pectoralis muscle is incised along the caudal edge of the clavicle and the 3) coracoid can be identified beneath the deep pectoral muscle coursing at a 45° angle to the cranial aspect of the sternum. **c)** Multiple, small intramedullary pins are passed retrograde out the cranial part of the shoulder. The pins are then carefully passed normagrade back into the distal fragment taking care not to have the pins pass through the caudal end of the coracoid and into the heart. 4) retractors 5) keel 6) left brachiocephalic trunk 7) aorta 8) scapula 9) heart and 10) liver.

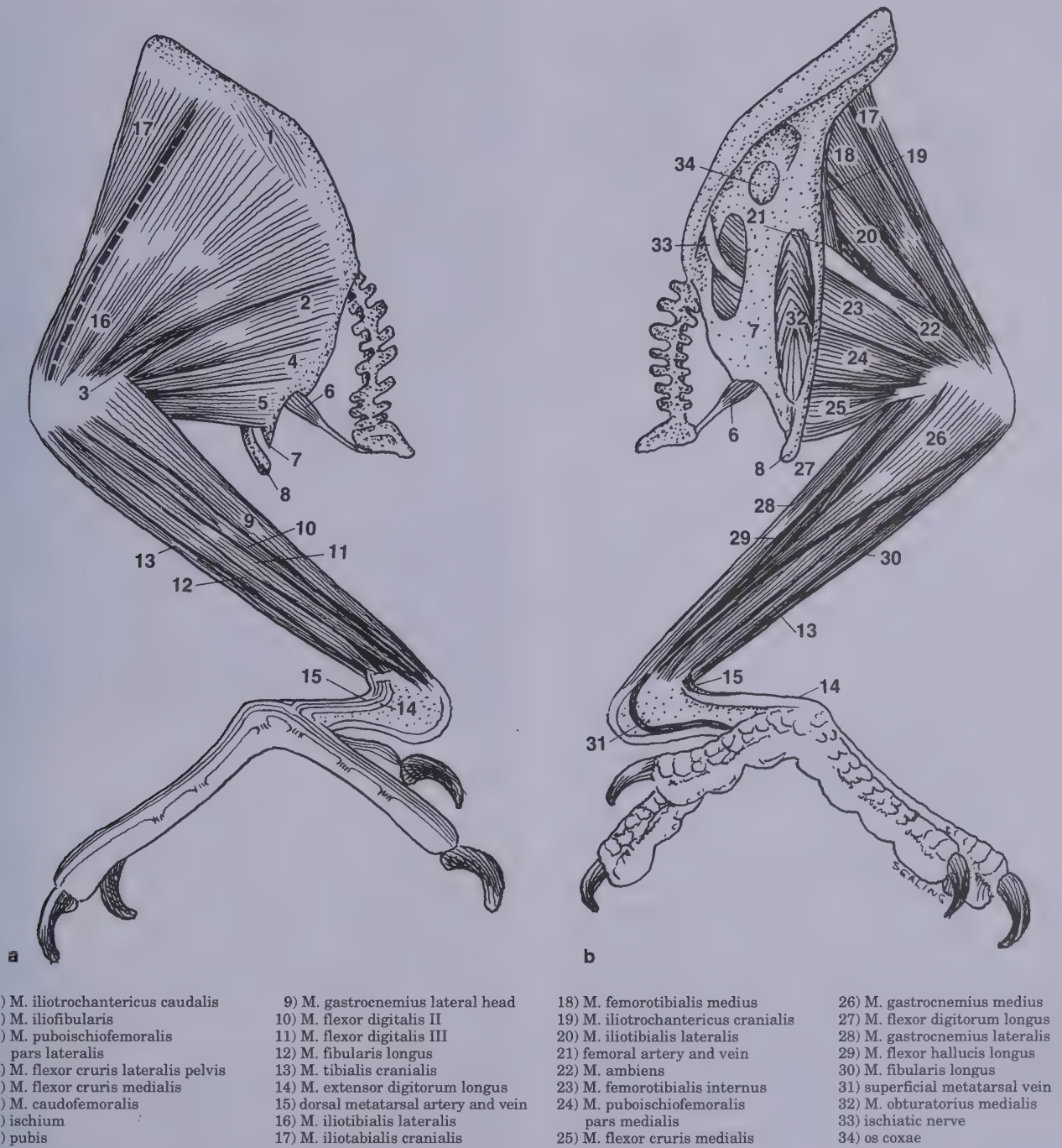
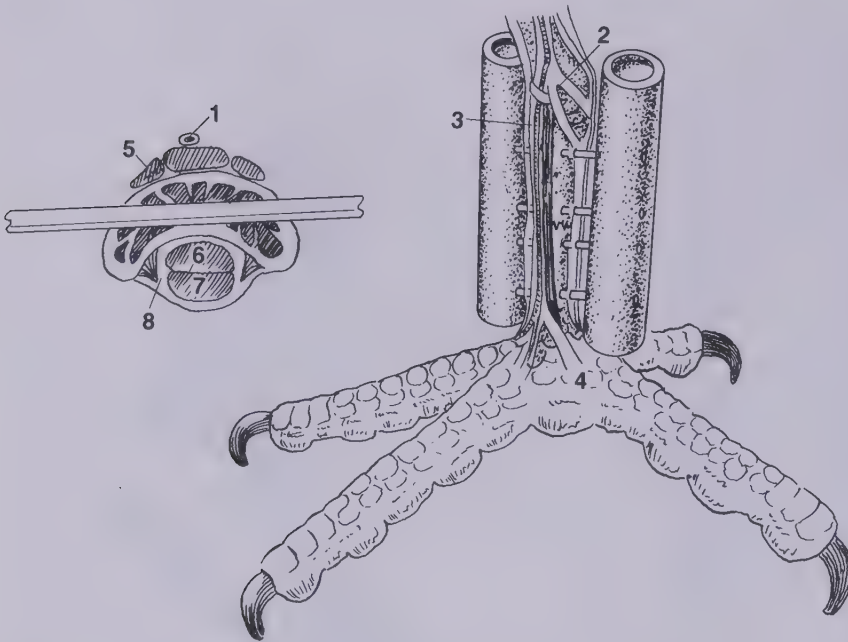


FIG 42.24 Overview of important surgical anatomy of the leg. a) Lateral view and b) Medial view.

geon should be aware of the concave nature of the caudal aspect of the tarsometatarsus (Figure 42.25). A groove, which houses the flexor tendons of the foot as well as the dorsal metatarsal artery, runs dorso-medially along with the vein and should be avoided when approaching the tarsometatarsus.

Any number of fixation methods may be utilized for fractures in this area (Figure 42.26). However, external fixators are ideally suited, and Type II configurations are easy to apply and provide excellent stability. If IM pins must be used, they are generally introduced through the fracture and exteriorized in a



**FIG 42.25** Type II external fixators are ideal for repairing tarsometatarsal fractures. The clinician should be aware of the concave nature of the tarsometatarsal bone. 1) dorsal metatarsal artery 2) *M. fibularis longus* 3) *M. extensor digitorum longus* 4) *M. extensor brevis digiti IV* 5) *M. extensor hallucis longus* 6) *M. flexor digiti II, III, IV*, 7) *M. flexor digiti II, IV* and 8) *M. gastrocnemius*.

retrograde fashion laterally or medially to the joint, then normograded back into the distal fragment. Small plates may also be used; however, there are scant soft tissues or skin in this area that can be used to cover the plate.

### The Tibiotarsus

A skin incision over the craniomedial aspect of the tibiotarsus provides access to the distal two-thirds of the underlying bone (Figure 42.27). The medial belly of the gastrocnemius muscle may have to be retracted from the cranial tibial muscle and fibularis longus craniolaterally to achieve access to some fractures. The cranial tibial artery, which runs over the mid to distal tibiotarsus in a craniolateral position, should be avoided when making this approach.

External fixators are ideally suited and easy to apply in this area. IM pins may be introduced from the tibial crest and normograded down through the proximal and then into the distal fragments. This positioning prevents the pin from penetrating the stifle. Plates may be used in midshaft closed fractures. External fixation can be used to repair metaphyseal fractures by placing stabilizing pins on both sides of the affected joint.

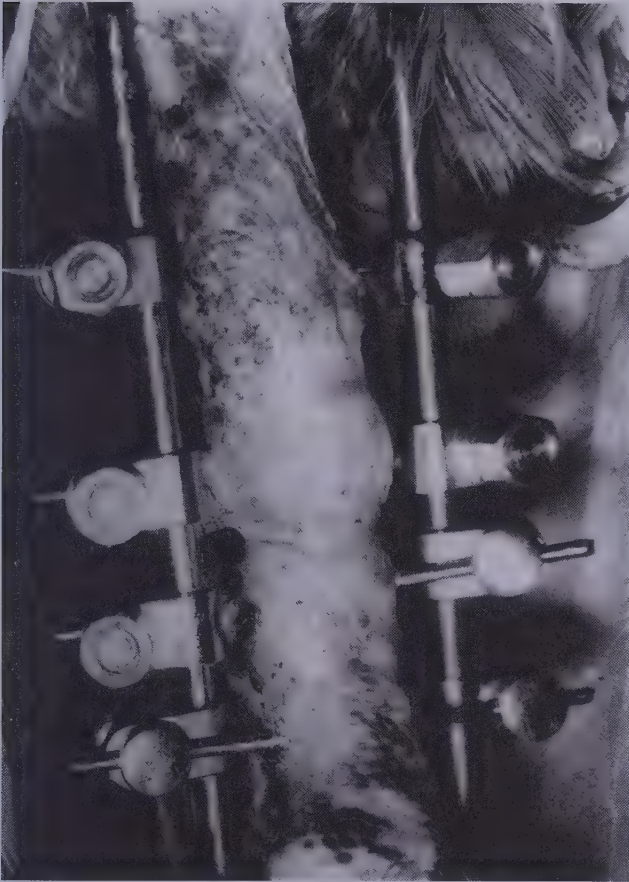### The Femur

The lateral approach to the femur is initiated by making a craniolateral skin incision (Figure 42.28). The greater trochanter proximally and the stifle joint distally can be used as landmarks. The cranial and caudal bellies of the iliotibialis muscle are separated using blunt and sharp dissection. The iliofibularis muscle is located caudally. With this approach, the femorotibialis medialis muscle will be located craniolateral and ventral to the pubo-ischio-femoralis muscle will be located caudally. Distally, a branch of the lateral genicular artery may require attention when working around the epicondyles and condyles.

Branches of the femoral artery may be encountered in the cranial proximal region of the femur. However, the femur is generally easy to approach except in those species that have a well developed femorotibialis medialis muscle that originates on the lateral aspect of the femur (eg, Anseriformes). In these species, the muscle is transected and elevated cranially and caudally to expose the femur.

A variety of fixation methods may be used for femoral fractures. Plates provide excellent stabilization especially in closed fractures. Type I or biplanar external fixators may be used alone or in combination with intramedullary pins. IM pins are passed through the fracture site and retrograded out through the greater trochanter laterally and then normograded back through the distal fragments. Shuttle pins are also ideally suited for this area.

Some surgeons have described a medial approach to the femur (Figure 42.29).<sup>3,16</sup> With this procedure, care must be taken to avoid the ischiatic nerve, artery and vein, which lie caudomedially. The bone is approached by separating the pubo-ischio-femoralis muscle medially. IM pins can be successfully used to repair proximal and metaphyseal fractures of the femur.<sup>21,41</sup> Retrograde insertion through the trochanteric fossa and normograde insertion from the same anatomic area can be accomplished.



**FIG 42.26** Type II external fixators are ideal for repairing tibiotarsal or tarsometatarsal fractures. A recently imported Military Macaw was presented with an open comminuted fracture of the distal tibiotarsus. The fracture was reduced through an open approach and stabilized using an external fixator. Two pins were placed in the large proximal fracture segment, one pin was placed in the small distal fracture segment and a pin was placed in the metatarsal bone, with the joint in a normal flexed position to ensure stability of the fracture. The bird was using the limb within 24 hours after surgery and healing was uneventful. The medial side of the KE apparatus was removed in three weeks, and the entire KE apparatus was removed six weeks after surgery.

### ■ Dome Osteotomy

Several techniques have been described for correcting angular limb deformities including transverse, oblique, wedge and dome osteotomies. Dome osteotomies have been successfully used to correct angular limb deformities in Psittaciformes, Falconiformes and Strigiformes, and offer several advantages over other osteotomy techniques. These include ease of planning and implantation, maintenance of maximum bone length and maximum bone-to-bone contact to facilitate healing. In addition, the dome osteotomy technique allows three-dimensional correction of the deformity while ensuring bone-to-

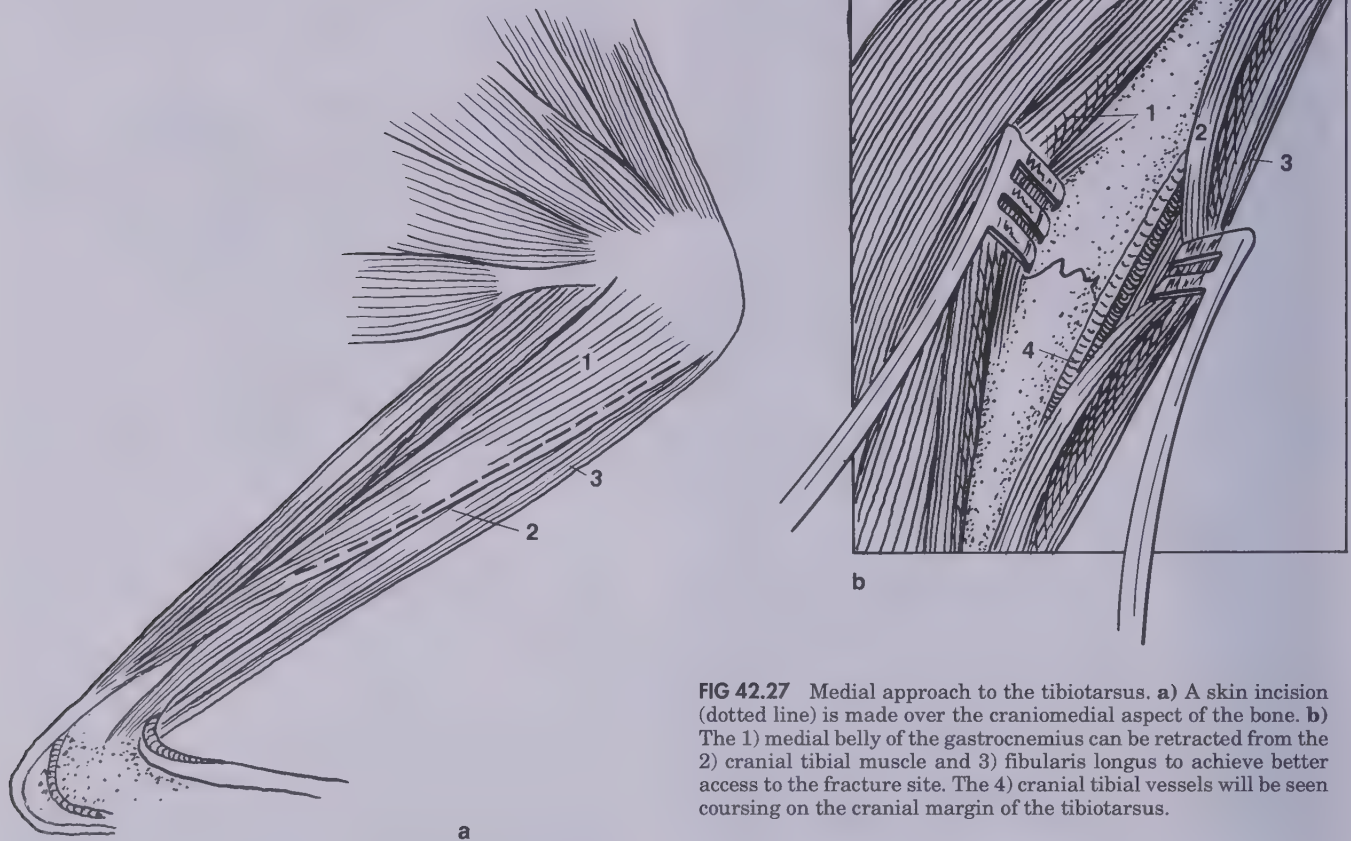
bone contact in all three planes. This technique can also be used to successfully repair fractures that have healed, producing an incorrect bone angle.

The procedure is planned from a tracing of a radiograph of the affected limb. The radiographic view that indicates the most severe angular deformity should be used for planning the procedure. Lines are drawn sagittally through the center of the distal and proximal ends of the bone. The point where the two lines intersect is the location for the dome osteotomy. The osteotomy is performed by using a drill to make a series of small holes in a half-circle fashion at the osteotomy site. The holes are then connected using a high-speed air drill and a side cutting bit. The distal bone segment can then be rotated freely in the proximal segment to allow proper bone alignment.<sup>42</sup> Appropriate fixation, generally an external fixator, is then used to stabilize the fracture during healing. Radiographic findings in birds suggest that when properly applied, a dome osteotomy site will undergo primary bone healing with minimal to no callus formation (Figure 42.30).

### ■ Repair of Luxations

Luxations have been infrequently reported in birds. Those that have been reported usually involve coxofemoral luxations secondary to a companion bird getting a leg trapped in enclosure accessories or as a consequence of struggling during restraint. Luxations of the elbow are probably the most common luxation in free-ranging raptors and are the result of trauma to the distal wing while in flight. Repair requires reduction of the luxation and stabilization of the joint. The sooner the luxation is detected, the better the chances for reduction without secondary joint damage.

Femoral head luxations are generally craniodorsal to the acetabulum. Open reduction may be successful in repairing acute cases. A femoral head osteotomy has been recommended for repair of chronic luxations of the hip. Coxofemoral luxations may be approached laterally or medially for stabilization. Spica-type splints are recommended, as well as supporting sutures, which are placed from the greater trochanter to the ilium and to the ischium. These sutures, usually of nonabsorbable materials, support the reduced hip in its normal location and are recommended in those avian species with a gliding hinge-type coxofemoral joint (noncursorial species such as most psittacine birds and raptors). It is important to remember that some cursorial species of birds (eg,



**FIG 42.27** Medial approach to the tibiotarsus. **a)** A skin incision (dotted line) is made over the craniomedial aspect of the bone. **b)** The 1) medial belly of the gastrocnemius can be retracted from the 2) cranial tibial muscle and 3) fibularis longus to achieve better access to the fracture site. The 4) cranial tibial vessels will be seen coursing on the cranial margin of the tibiotarsus.

ratites), have a ball and socket-type coxofemoral joint and these sutures would not be appropriate.

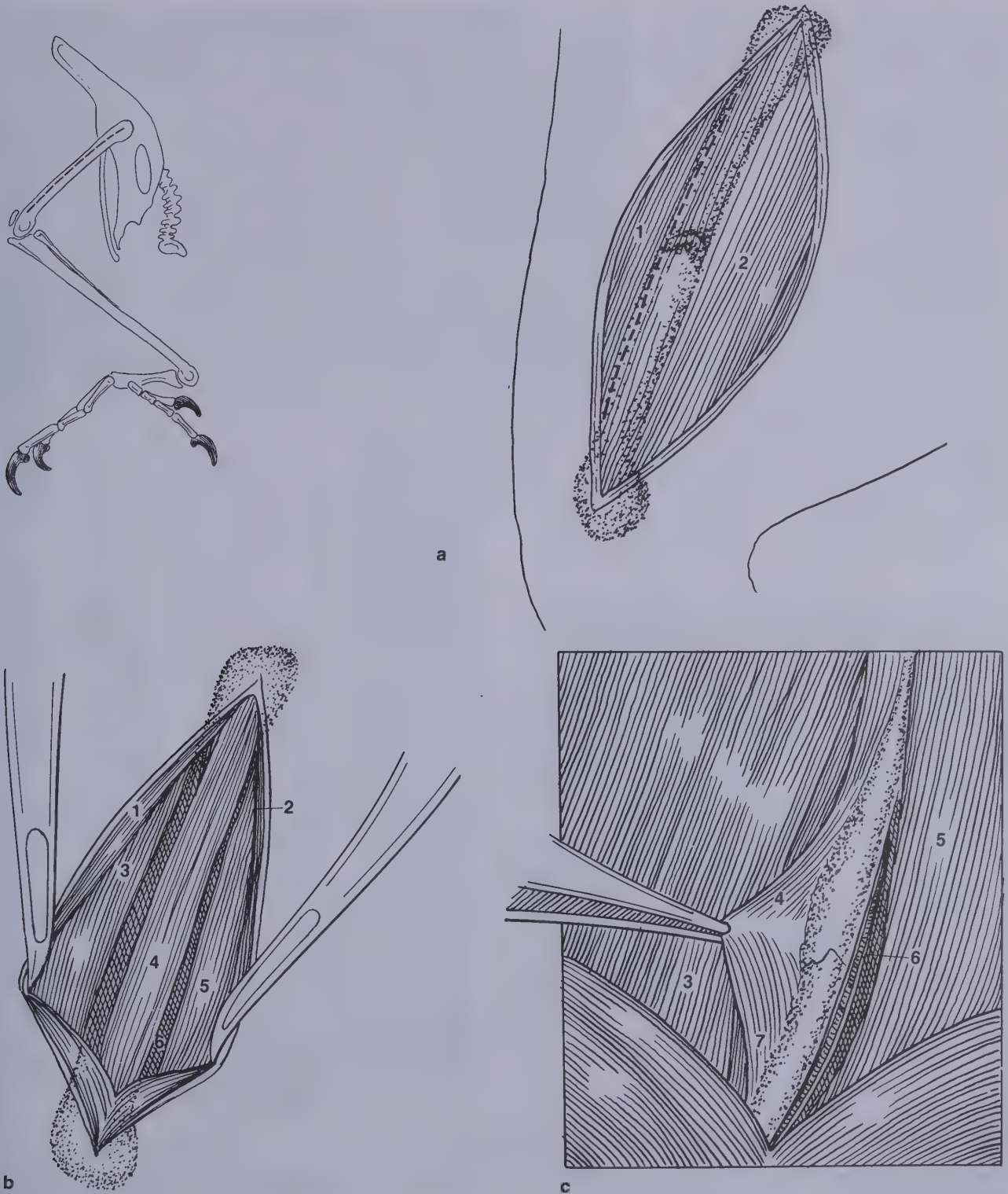
Elbow luxations in raptors usually result in a straight caudal or dorsocaudal displacement of the ulna. If treated early, closed reduction of these luxations can be made and then supported with external fixators or bandages. In one report, five of nine raptors with elbow luxations were successfully returned to the wild following closed reduction and support with external fixators or bandages for seven to ten days.

Luxations of the shoulder have also been reported in raptors. These are usually accompanied by an avulsion fracture of the ventral tubercle of the proximal humerus. These can be stabilized by application of a figure-of-eight bandage to immobilize the wing to the body for 10 to 14 days. A surgical approach may be warranted to reduce and reattach the ventral tubercle with wires or lag screws. It is important to note that luxations do not necessarily suggest a hopeless prognosis for return to complete function, particularly if addressed soon after the injury occurs.

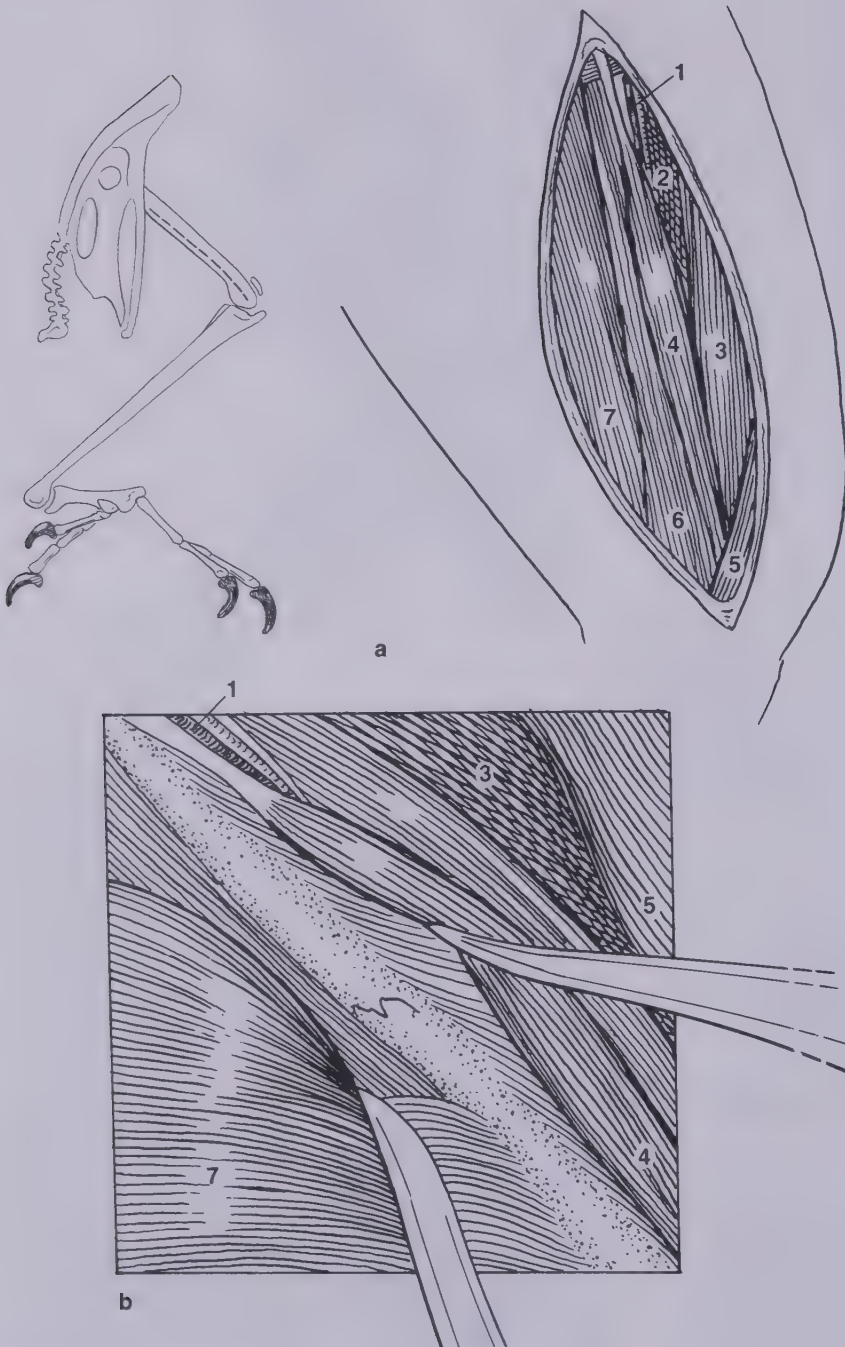
The collateral ligaments of the knee may be damaged following many traumatic events. A positive drawer sign is characteristic. Techniques used to repair collateral ligament damage in mammals can also be used for birds.

### Repair of the Beak

A healthy beak is critical to the everyday survival of a bird, and minor injuries to this tissue can be serious depending upon the degree of associated soft tissue damage. Initially, therapy for any beak injury should be provided to control hemorrhage, maintain nutritional support and prevent secondary infection. Several approaches may be used to correct these injuries, and the therapeutic plan is chosen based upon the size of the patient and the nature of the fracture. Birds with beak injuries that result in defects can also readily adapt to soft diets. Prosthetic beak devices require continuous replacement as the beak grows, and must be carefully monitored to prevent bacterial or fungal infections.



**FIG 42.28** Lateral approach to the femur. **a)** A skin incision is made from the greater trochanter to the stifle joint as needed. The 1) cranial and 2) caudal bellies of the iliotibialis muscles are separated, using blunt dissection. **b)** The 3) M. iliobtibialis cranialis, 4) M. femorotibialis externus, 5) M. iliofibularis and 6) M. pubo-ischio-femoralis will be in view. **c)** The 7) M. femorotibialis medialis is seen on the cranial edge of the femur.



**FIG 42.29** Medial approach to the femur. 1) femoral artery, vein and nerve 2) M. femorotibialis medius 3) M. ilirotibialis 4) M. ambiens 5) ilirotibialis cranialis 6) M. femorofibialis internus and 7) M. pubo-ischio-femorales medialis.

### Fractures

Mandibular fractures are the most common injury and should be addressed in two stages: repair of the bone,

and repair and realignment of the keratinized beak. Fractures through the beak will not heal side-to-side. Forces encountered by the beak must be neutralized or they will be transferred to the underlying bone and interfere with healing (Figure 42.31).

Depending upon patient size and the location of the fracture, pins, wires, cements, screws and plates may be useful in repairing mandibular fractures. For most smaller birds, hypodermic needles and cerclage wires are useful. The primary goals are realignment and stabilization of the fracture site. Pins and hypodermic needles may be inserted into the body of the mandible, antegraded across the fracture site from the rostral point of the beak, and stabilized with cerclage wires (plus or minus cements) (Figure 42.32).

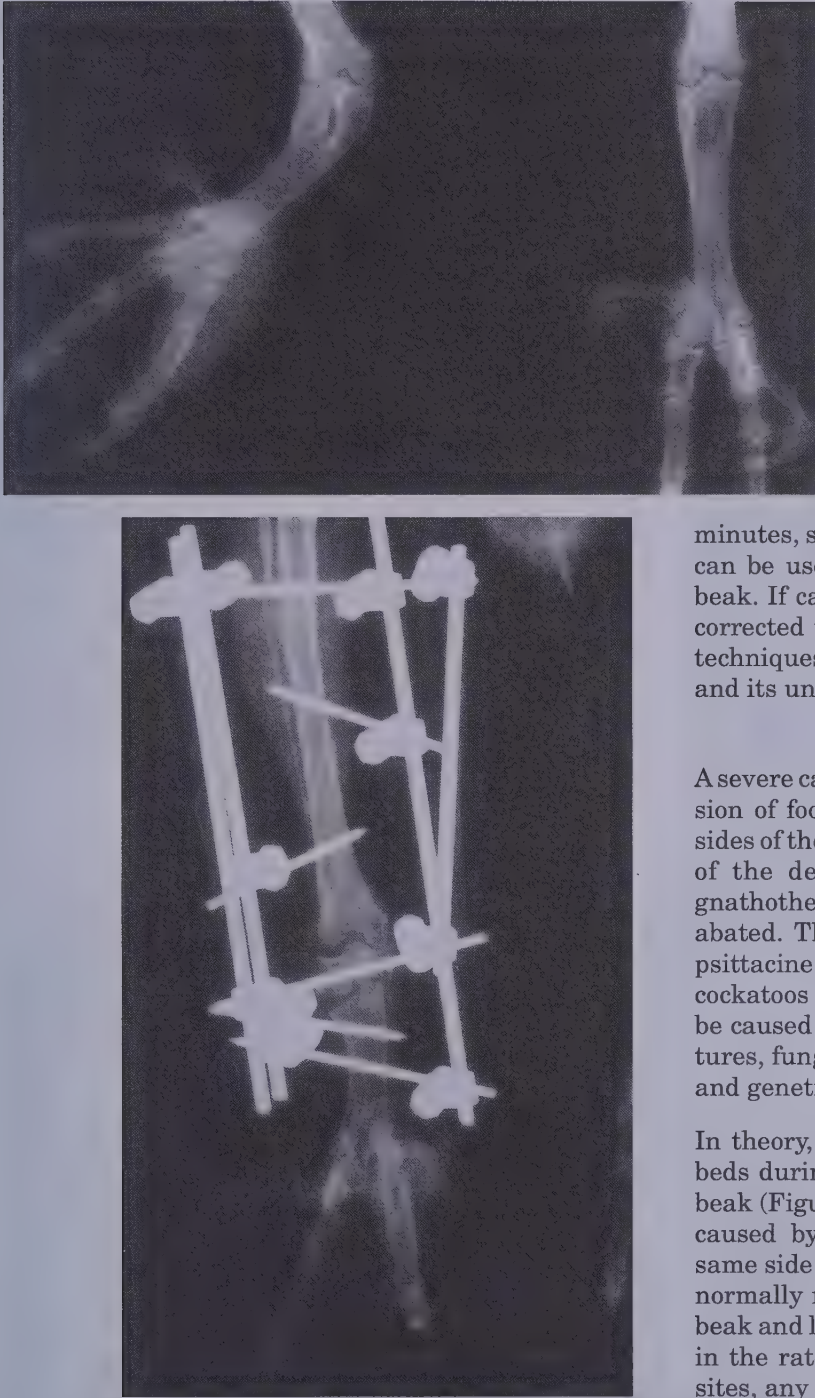
Once the fracture is repaired, soft tissue injuries must be treated. If the injury is of a degloving type, every attempt should be made to reappose the displaced skin. Tissue glues are useful for facilitating this repair. If glues are not applicable, the fracture site should be dressed with a self-adherent wet/dry type dressing.<sup>8</sup>

Fractures of the upper beak are generally more difficult to manage due to the presence of small bones and the kinetic nature of the maxilla. These fractures frequently involve the quadrate and jugal bones, which are thin structures that are difficult to immobilize. The use of small hypodermic needles is usually necessary to facilitate repair, but their effectiveness is limited. Healed fractures often result in beak abnormalities such as lateral deviation of the maxillary beak.

### Beak Deformities

Beak defects that require repair may occur secondary to trauma, nutritional deficiencies or congenital abnormalities. The beak is constantly growing and any prosthesis that is applied will migrate and loosen over time. The beak





**FIG 42.30** A free-ranging Great-horned Owl neonate was presented with a valgus deformity of the right tarsometatarsus. Note the soft tissue swelling on the medial side of the foot induced by improper ambulation. A dome-shaped cut was made in the metatarsus at the point of maximum deformity. The angle of the limb was so severe that even though a dome-shaped cut was made, it appears on radiographs as an oblique osteotomy site. The osteotomy site was stabilized with a Type III external fixator. The bird had full postsurgical use of the foot and was released.

is similar in structure to a hoof, with sheets of protein overlying a substantial vascular supply and bone. The keratin layers of the bone can regenerate only if the underlying vascular bed is viable. If the vascular tissue is destroyed, a permanent defect will be present in the beak.

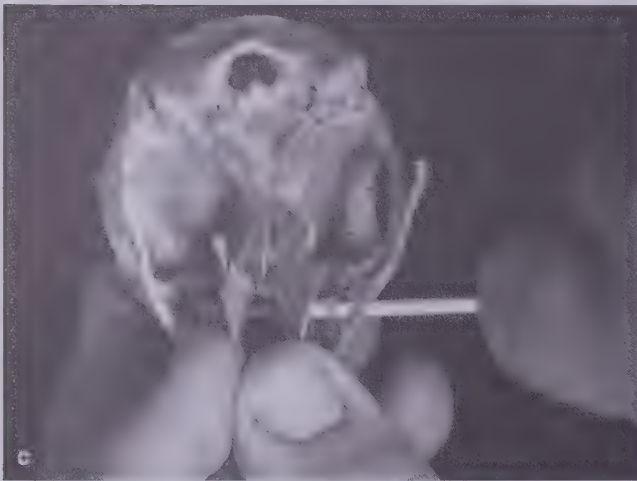Two common defects in psittacine neonates are scissors beak (lateral deviation of the upper beak) and mandibular prognathism. The etiology of these problems is only speculative. If mandibular prognathism is recognized early, it can be corrected by applying gentle outward pressure to the beak for ten minutes, six to eight times daily. The same technique can be used to correct some early cases of scissors beak. If cases are allowed to progress, they must be corrected using various beak prostheses or surgical techniques to redirect the forces applied to the beak and its underlying bones.

#### Scissors Beak

A severe case of scissors beak can prevent the prehension of food and will cause abnormal wear on both sides of the gnathotheca. The gnathotheca on the side of the deviation will wear excessively, and the gnathotheca on the contralateral side will grow unabated. This problem may occur in most species of psittacine birds but appears to be most common in cockatoos and macaws. In poultry, scissors beak can be caused by inappropriate egg incubation temperatures, fungal toxins, vitamin D<sub>3</sub> toxicosis, teratogens and genetic defects.<sup>1</sup>

In theory, any slight injury to the cere or germinal beds during early development could cause scissors beak (Figure 42.33). The theory that scissors beak is caused by constantly feeding a neonate from the same side of the mouth has been disproven.<sup>1</sup> Keratin normally migrates rostrally along the surface of the beak and laterally from the vascular bed. Any change in the rate of keratin migration between these two sites, any change in the premaxilla that changes the orientation of the tip, or a malformation of the frontal bone could cause the beak to deviate laterally.

Correction procedures are designed to change the forces that direct the anterior growth of the rhinotheca (Figure 42.34). Redirected growth is achieved by applying a prosthesis to the lower beak on the affected side or by placing pins in the calvarium and



**FIG 42.31** a) An adult Blue and Gold Macaw was presented with a malaligned beak after attempting to bite a large wooden dowel. Radiographs indicated a dislocated palatine bone dorsal and rostral to the vomer bone. b,c) The dislocation was repaired by placing a pin through the frontal sinus over the maxilla and pushing caudally. The dislocation was stabilized for healing by placing wire sutures around the suborbital arch and the jugal bone ventral to the globe. The bird returned to normal function.

using rubber bands to apply pressure to the tip of the beak (similar to orthodontic techniques used in humans).

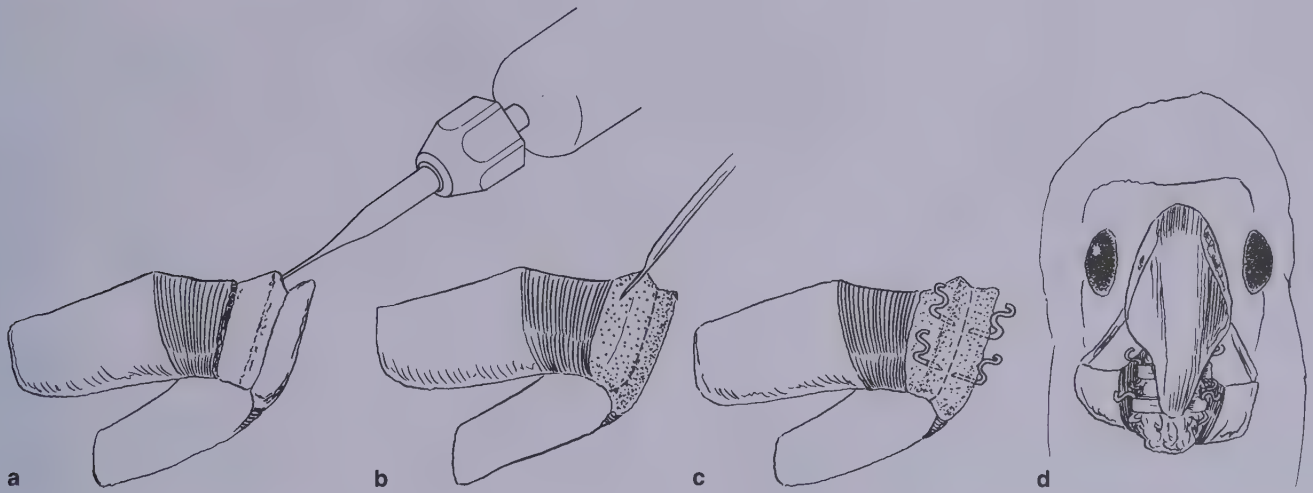
Scissors beak is easiest to repair in a young bird because the bones and beak are actively remodeling. The prosthetic device must be sufficiently anchored to the lower beak to prevent normal beak occlusion from dislocating the prosthesis. The keratin of the gnathotheca on the affected side is grooved with a Dremel tool. The grooves should be deep enough to increase the surface area for prosthetic attachment but should not be so deep as to induce hemorrhage.

The scored gnathotheca is cleaned and disinfected, and a light coat of cyanomethacrylate is applied to the area and allowed to dry. Stainless steel or nylon dental screen mesh is molded to the gnathotheca. The mesh should be extended to create a ramp that redirects the beak tip to the midline with each bite. The ramp is covered with cyanoacrylate and

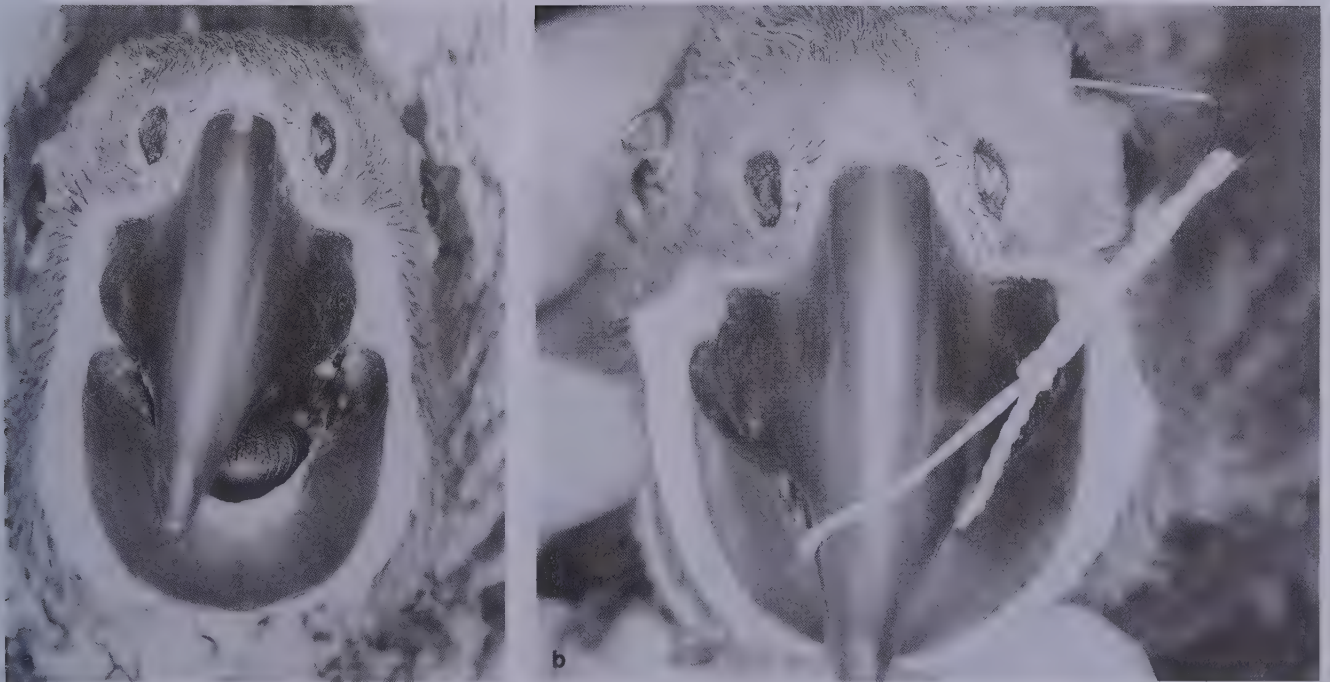
smoothed with a Dremel tool. When the defect is corrected, the implant is removed.

### Braggnathism

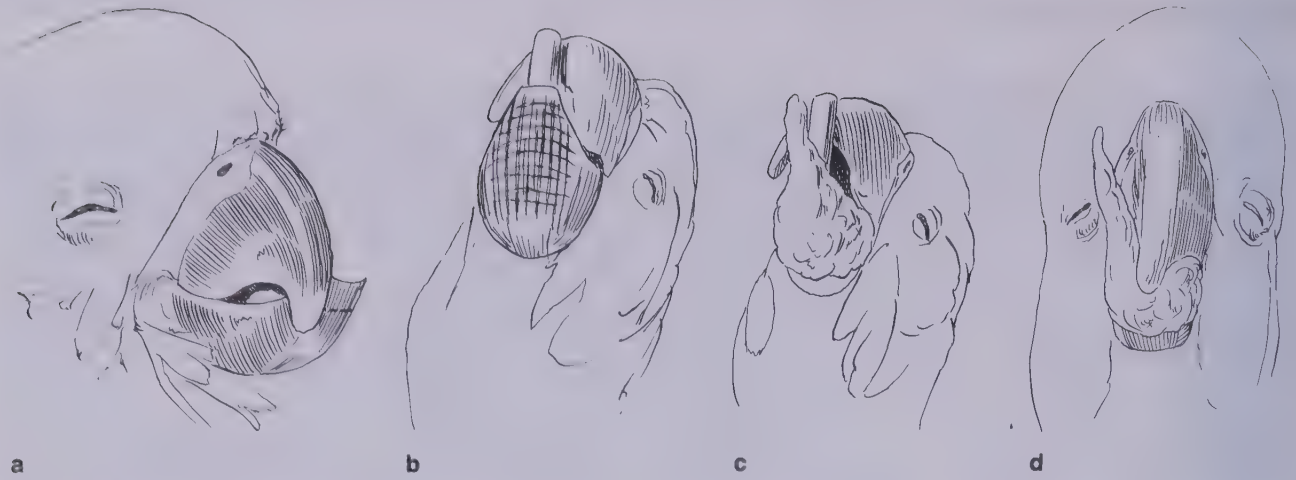
Braggnathism can be repaired by placing a KE wire into the frontal bone just caudal to the maxilla joint and caudal to the nares (Figure 42.35). A caudally directed hook is bent into the external portion of the pin. A second pin is placed in the maxilla midway down the beak at the point at which the internal rotation of the maxilla is most severe. Acrylic is applied to the area, incorporating the pins to supply extra support. A rubber band placed between the two pins will pull the beak tip into proper apposition. When the rhinotheca is properly positioned on the outer surface of the gnathotheca, the rubber band can be removed. The pins can remain in place for several more days until it is apparent that the bragg-nathism will not recur. When it is apparent that the problem is permanently corrected, the acrylic and pins can be removed.



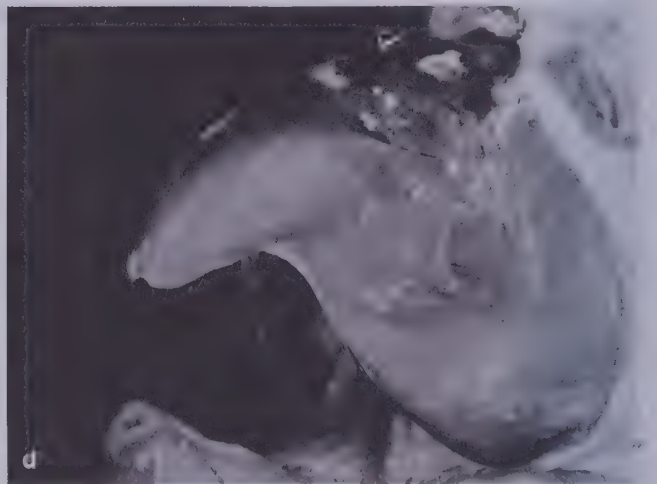
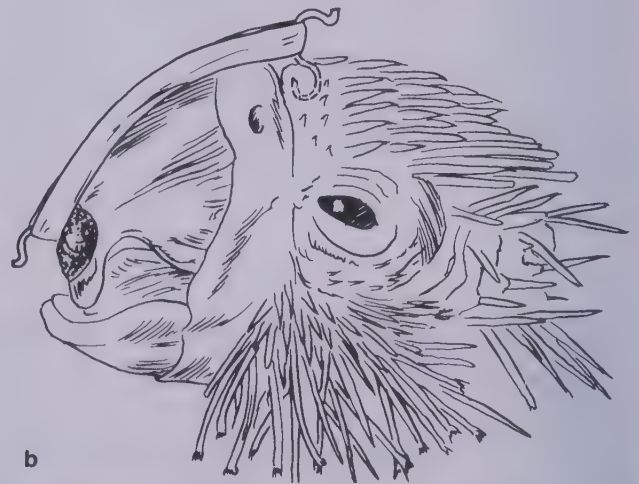
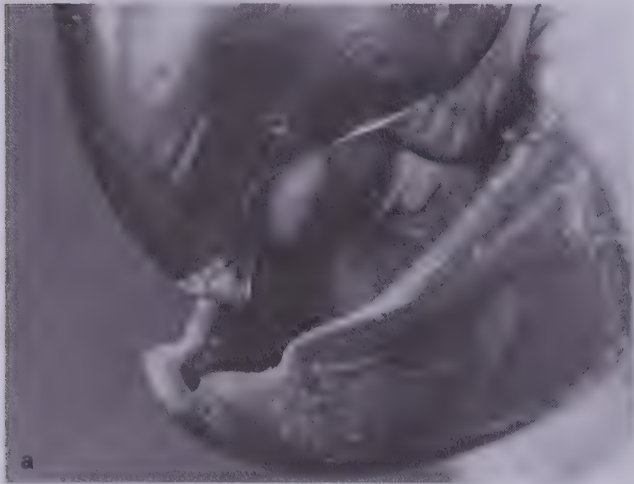**FIG 42.32** Doyle technique for repair of a mandibular symphyseal fracture. **a)** The gnathotheca is scarified with a dental burr. **b)** The scarified area is coated with calcium hydroxide. **c)** Pins are placed through the mandible and hooks are fashioned in their ends. **d)** Rubber bands are placed around the hooks and the hardware is coated with methylmethacrylate.



**FIG 42.33** **a)** Scissors beak in a Hyacinth Macaw chick. **b)** The defect was corrected by placing a KE wire through the frontal bone and using a rubber band to place correcting pressure on the beak tip. The upper beak was properly aligned within seven days of applying the apparatus.



**FIG 42.34** a) Scissors beak can be corrected by using pins placed through the frontal bone or by using a prosthetic device attached to the gnathotheca. b) The gnathotheca is scarified with a dental burr and cleaned and covered with a light coat of dental acrylic. c) Nylon dental mesh is covered with dental acrylic to create a ramp that pushes the tip of the beak into proper alignment. d) The prosthesis after being shaped with a Dremel tool.



**FIG 42.35** a) Brachnathism in a cockatoo neonate before repair. b,c) Repair of brachnathism using a principle (modified Doyle technique) similar to those used in human orthodontics. A KE wire is passed through the frontal bone and hooks are fashioned in both ends. A second pin is placed into the maxilla midway down the beak. The pin in the maxilla is supported with dental acrylic. The tip of the beak is pulled into proper apposition using a rubber band. d) Patient after correction of brachnathism.

### Products Mentioned in the Text

- a. Osteostim, Englewood, CO or Surgical Simplex-P, Howmedica Inc, Rutherford, NJ
- b. Non-sterile hoof repair material, Technont, Jorgensen Labs, Loveland, CO
- c. Hexcelite, Hexcel Medical Co, Dublin, CA
- d. Manuflex, Trade-Coop, Budapest, Hungary
- e. American Society of Internal Fixation cuttable plates, Synthes, Paoli, PA
- f. A-508 Associated Rubber Bands, Boise Cascade Co, Chicago, IL
- g. DuoDerm, Convatec (Squibb), Princeton, NJ

### References and Suggested Reading

1. **Clipsham R:** Surgical correction of beaks: A practical lab. *Proc Assoc of Avian Vet*, 1990, pp 325-333.
2. **Bennett RA, Egger EL, Histan M, et al:** Comparison of the strength and holding power of 4 pin designs for use with half-pin (type I) external skeletal fixation. *Vet Surg* 16:207-211, 1987.
3. **Black J:** Biomaterials for internal fixation. In Heppenstall, RB (ed): *Fracture Treatment and Healing*. Philadelphia, WB Saunders Co, 1980, pp 145-146.
4. **Bennett RA, Kuzma AB:** Fracture management in birds. *J Zoo Wild Med*, 1991.
5. **Bruse SJ, Dee J, Prieur WB:** Internal fixation with a veterinary cuttable plate in small animals. *Vet Comp Orthop Trauma* 1:40-46, 1989.
6. **Bush M:** External fixation of avian fractures. *J Am Vet Med Assoc* 171:943-946, 1977.
7. **Bush M, Montali RJ, Novak GR, et al:** The healing of avian fractures: A histologic xeroradiographic study. *J Am Anim Hosp Assoc* 12:768-773, 1976.
8. **Chaffee VM:** Sequela into intramedullary fixation of the humerus in an osprey. *Vet Med Sm Anim Clin* 68:892-894, 1973.
9. **Coles BH:** *Avian Medicine and Surgery*. London, Blackwell Scientific Publications, 1985, pp 123-164.
10. **Degernes LA, Lind PJ, Olsen DE, et al:** Evaluating avian fractures for use of methylmethacrylate orthopedic technique. *J Assoc Avian Vet* 3(2):64-67, 1989.
11. **Dellman, HD, Brown EM:** *Textbook of Veterinary Histology*. Lea and Febiger, Philadelphia, 1976.
12. **Elkins AD, Blass CE:** Management of avian fractures. Part 2: Pins and wires. *Vet Med Small Animal Clin* 77:825-828, 1982.
13. **Fowler ME:** Ossification of long bones in raptors. In Cooper JE, Greenwood A: *Recent Advances in the Study of Raptor Diseases*. *Proc Intl Symp Dis Birds of Prey*, London, 1980, pp 75-82.
14. **Gandal CP:** Anesthetic and surgical techniques. In Petrak ML (ed): *Diseases of Cage and Aviary Birds* 2nd ed. Philadelphia, Lea & Febiger, 1982, pp 304-328.
- 14a. **Harrison GJ:** Anesthesia and common surgical procedures. *Proc Assoc Avian Vet*, 1990, pp 460-488.
15. **Howard PE:** The use of bone plates in the repair of avian fractures. *J Am Anim Hosp Assoc* 26:613-622, 1990.
16. **Kuzma AB:** Avian orthopedics: An update and review of new techniques. *Proc Am Assoc Zoo Vet*, 1990, pp 159-162.
17. **Kuzma AB, Hunter B:** Avian fracture repair using intramedullary bone cement and plate fixation. *Proc Assoc Avian Vet*, 1989, pp 177-181.
18. **Kuzma AB, Hunter B:** Osteotomy and derotation of the humerus in a turkey vulture using intramedullary polymethylmethacrylate and bone plate fixation. *Can Vet J* 30:900-901, 1989.
19. **Kuzma AB, Hunter B:** A new technique for avian fracture repair using intramedullary polymethylmethacrylate and bone plate fixation. *J Am Anim Hosp Assoc* 27:239-248, 1991.
20. **Leeds EB:** Tibial fracture repair in a double-waddled cassowary. *J Vet Orthop* 1:21-27, 1979.
21. **Levitt L:** Avian orthopedics. *Compend Cont Ed Pract Vet* 11:899-929, 1989.
22. **Lind PJ, Degernes LA, Olson DE, et al:** Bone cement/polypropylene rod orthopedic technique. *J Assoc Avian Vet* 3(4):203-205, 1989.
23. **Lind PJ, Gushwa DA, VanEk J:** Fracture repair in two owls using polypropylene rods and acrylic bone cement. *Assoc Avian Vet Today* 2(3):128-132, 1988.
24. **MacCoy DM:** High density polymer rods as an intramedullary fixation device in birds. *J Am Anim Hosp Assoc* 19:767-772, 1983.
25. **MacCoy DM:** Techniques of fracture treatment and their indications: External and internal fixation. 13th *Ann Vet Surg Forum*, 1985, pp 97-109.
26. **MacCoy DM:** Techniques of fracture treatment and their indications: External and internal fixation. *Proc Assoc Avian Vet*, 1987, pp 549-562.
27. **MacCoy DM, Collier MA:** Treatment of nonunion of the ulna in a rough-legged hawk with constant direct electric current: A case report. *J Am Anim Hosp Assoc* 19:761-766, 1983.
28. **MacCoy DM, Haschek WM:** Healing of transverse humeral fractures in pigeons treated with ethylene oxide-sterilized, dry-stored, on-lay cortical xenografts and allografts. *Am J Vet Res* 49:106-111, 1988.
29. **MacCoy DM, Redig PT:** Surgical approaches to and repair of wing fractures. *Proc 1st Intl Conf Zool Avian Med*, 1987, pp 564-577.
30. **Milton JL:** Principles of fracture treatment and bone healing. 13th *Ann Vet Surg Forum*, 1985, pp 91-96.
31. **Montali RJ, Bush M:** Avian fracture repair, radiographic and histologic correlation. *Proc Am Assoc Zoo Vet*, 1975, pp 150-154.
32. **Morris PJ, Weigel JP:** Mandibular fracture repair in a marabou stork (*Leptoptilus crumeniferus*) with a methacrylate prosthesis. *Proc Assoc Avian Vet*, 1985, pp 303-305.
33. **Newton CD, Zeitlin S:** Avian fracture healing. *J Am Vet Med Assoc* 170:620-625, 1977.
34. **Paul-Murphy J:** Psittacine skull radiography. *Proc Assoc Avian Vet*, 1986, pp 81-86.
35. **Pumey DL, Borman ER, Lohse CL:** Methylmethacrylate fixation of avian humerus fractures: A radiographic, histologic study. *J Am Anim Hosp Assoc* 19:773-782, 1983.
36. **Redig PT:** A clinical review of orthopedic techniques used in the rehabilitation of raptors. *Proc Student Am Vet Med Assoc Symp*, 1986, pp 8-21.
37. **Redig PT:** A clinical review of orthopedic techniques used in the rehabilitation of raptors. In Fowler ME (ed): *Zoo and Wild Animal Medicine* 2nd ed. Philadelphia, WB Saunders Co, 1986, pp 388-401.
38. **Redig PT:** Basic orthopedic surgical techniques. In Harrison GJ, Harrison LR (eds): *Clinical Avian Medicine and Surgery*. Philadelphia, WB Saunders Co, 1986, pp 596-598.
39. **Redig PT, Roush JC:** Orthopedic and soft tissue surgery in raptorial species. In Fowler ME (ed): *Zoo and Wild Animal Medicine*. Philadelphia, WB Saunders Co, 1986, pp 246-253.
40. **Ritivo M:** Bone and Joint X-ray Diagnosis. Lea and Febiger, Philadelphia 1955.
41. **Roush JC:** Avian orthopedics. In Kirk RW (ed): *Current Veterinary Therapy VII*. Philadelphia, WB Saunders Co, 1980, pp 662-673.
42. **Rowley J, Pshyk BW:** Repair of a fractured humerus in a red-tailed hawk. *Vet Med Small Anim Clin* 76:1180-1181, 1981.
43. **Sikes RL, Olds RB:** Dome osteotomy for the correction of long bone malunions: Case reports and discussion of surgical technique. *J Am Anim Hosp Assoc* 22:221-226, 1986.
44. **Wahlig H, Dingeldein E:** Antibiotics and bone cements. Experimental and long term observations. *Acta Orthop Scand* 51:49-56, 1980.
45. **Williams RJ, Holland M, Milton JL, et al:** A comparative study of treatment methods for long bone fractures. *Comp Anim Pract* 1(4):48-55, 1987.
46. **Withrow SJ:** General principles of fracture repair in raptors. *Comp Cont Ed Pract Vet* 4:116-121, 1982.

## ■ C H A P T E R S

- 43** PASSERIFORMES  
Patricia Macwhirter
- 44** COLUMBIFORMES  
Curt Vogel  
Helga Gerlach  
Mait Löffler
- 45** GALLIFORMES  
Christian Schales  
Kerstin Schales
- 46** ANSERIFORMES  
John H. Olsen
- 47** RAMPHASTIDAE  
Hans Cornelissen  
Branson W. Ritchie
- 48** RATITES  
James S. Stewart

**VII**

---

---

### SECTION SEVEN

# COMPARATIVE MEDICINE AND MANAGEMENT

---

---

**VII**



CHAPTER

# 43

## PASSERIFORMES

Patricia Macwhirter

**P**asseriformes (perching and songbirds) is the largest order of birds. It contains nearly 60 percent of all bird species ranging in size from the tiny Weebill (80 mm in length) to the Superb Lyrebird (130 cm long, including a 72 cm tail). Canaries, finches, starlings and mynahs are examples of passerine birds that are common in captivity. Passerines are widely distributed throughout the world, and all passerines share a common anisodactyl foot structure with three unwebbed toes pointed cranially and one caudally. The altricial young are usually naked when hatched and are reared in a nest.

The order is believed to have originated in Gondwana, the ancient southern continent. Convergent evolution makes differentiating species based on morphologic grounds difficult, and in the past, the anatomy of the syrinx has been a primary means of classification. Recent DNA hybridization and protein electrophoresis studies are modifying traditional views. One group of passerines is now believed to have evolved and radiated in eastern Gondwana, proto-Australasia (these include such species as bowerbirds, lyrebirds, birds of paradise, honeyeaters, Australian grass finches and fairy wrens). Another group, the suboscines or primitive songbirds are believed to be of western Gondwanan origin (current-day South America). These include such primitive South American species as contingas, manikins, antbirds and gnateaters. More advanced songbirds like Fringillidae finches, sparrows, warblers, starlings, thrushes and sunbirds may also have evolved via western Gondwana and migrated from this area to become widely distributed.<sup>10</sup>

While Passeriformes are widespread in the northern hemisphere, there are very few endemic families and many of the species are migratory.<sup>56</sup>



## Anatomy and Physiology

Passeriformes have become adapted to a wide variety of ecological niches. The anatomic and physiologic differences expressed within the order reflect these specific evolutionary patterns (Table 43.1).

### Digestive System

The basal metabolic rate (BMR) of passerine birds is generally about 65% greater than that of non-passerines, and their body temperature is about two degrees Centigrade higher (around 42°C). While some desert passerines such as the Zebra Finch have been known to survive months without drinking water, most small passerine birds drink from 250 to 300 ml/kg body weight of water each day and may eat up to 30% of their body weight daily. These figures are higher than those for most non-passerines, which tend to be larger birds.

Most passerine species have a narrow, triangular tongue compared with the thick blunt tongue of parrots. The tongue is rarely involved in clinical problems. The tongue of passerines may become hyperkeratotic at the tip and extend rostrally through the beak. The syndrome appears to cause few clinical problems, but the hyperkeratotic tissue can be slowly trimmed back with a pair of strabismus scissors, taking care not to cut healthy mucosa. Other parts of the digestive tract differ depending on the species' feeding patterns. A ventriculus is present in granivorous and insectivorous species such as finches, but not in species such as honeyeaters that consume nectar and soft foods. If present, cecae are generally small and vestigial.

Inexperienced Passeriformes breeders may present chicks for evaluation of a "sore" or "swelling" on the neck. This clinical sign is usually determined to be the crop distended with seeds and visible beneath thin, featherless skin.

There is no production of crop milk in passerines as there is in pigeons, but some finches will regurgitate crop contents to feed their young. Pathogens can be transmitted from parent to offspring during this process, particularly with foster-raised chicks that probably did not receive yolk-derived antibodies against microorganisms from their foster parents'

digestive system. For example, although *Cochlosoma* sp. may cause inapparent infections in adult Bengalese (Society) Finches, significant mortality may occur in juvenile Gouldian Finches being fostered by Bengalese parents.<sup>15</sup>

Nestling Estrilid finches (eg, Gouldian and Zebra Finches) normally have characteristic luminous mouth markings. Mucosal patterns are species-specific and help to guide parents to their own chicks within the recesses of dark nests.

The spleen in most passerines is oblong, not spherical, as it is in Psittaciformes.

### Respiratory System

In most Passeriformes, unlike in Psittaciformes, the right and left nasal sinuses do not communicate. In passerine birds, separate samples for rhinal disease (bacterial, viral, chlamydial) cytology examination should be taken from each sinus if a bilateral nasal discharge occurs (Figure 43.1).<sup>9</sup>

Singing ability is highly developed in many passerine species and is related to the complexity of the syringeal anatomy. Some species have the capacity to sing duets with themselves by alternately using op-



**FIG 43.1** Passeriformes, like this canary, have right and left paranasal sinuses that do not communicate as they do in Psittaciformes. If bilateral oculonasal discharge suggestive of sinusitis is occurring, it is wise to collect samples from both the right and left sinuses for culture and cytologic evaluation. Conjunctivitis in this canary was responsive to tylosin therapy (courtesy of Michael Murray).

TABLE 43.1 Distinguishing Features of Selected Passerine Birds

Family	General Composition	Approx. Number of Species	Characteristics
Emberizidae	New World finches, cardinals, buntings, Cuban finch	550	Cup-shaped open nest, female incubates, diverse group, 9 primary feathers
Estrildidae	African, Asian and Australian finches, waxbills, nunias, parrot finches	125	Palatal markings in young, monogamous, dome-shaped nest with side entrance, 10 primary feathers
Fringillidae	True finches, canaries, goldfinch, chaffinch	125	Cup-shaped open nest, female incubates, 9 primary feathers, 12 long tail feathers
Passeridae	Sparrows, finches	32	Bulky domed nest of dried grass, breed in colonies, seed-eating, finch-like birds
Ploceidae	Weavers, whydahs, queleas	145	Dome-shaped, covered, woven nest, do not sing, some species parasitic
Sturnidae	Starlings, mynahs	108	Dark, iridescent, or brightly colored, colonial, nest in holes, long straight bills, mimicry ability



FIG 43.2 A hand-raised European starling can develop an extensive vocabulary and have a voice quality that is similar to its relative, the mynah bird (courtesy of Mark Spreyer).

posite bronchi. Roller canaries are specifically bred and trained for their singing ability.

The ability to mimic the human voice is well developed in some passerines, notably mynahs, starlings and corvids (Figure 43.2). Among Australian passerines, lyrebirds are legendary in their ability to mimic the calls of other bird species, and rain forest gullies will re-echo with an apparent chorus of calls that can

be traced to a single individual bird. The American mockingbird has similar abilities and may mimic the sounds of companion Psittaciformes.

Like psittacine birds but unlike ratites and penguins, passerine birds have a highly developed neopulmonic and paleopulmonic parabronchi. This allows for highly efficient oxygen exchange. In most passerines, the cranial thoracic air sacs are fused to the single median clavicular sac, making a total of seven air sacs as opposed to the nine air sacs of psittacine species.

### Reproductive System

In general, only the left ovary and oviduct develop in normal female passerines. Occasionally a nonfunctional right ovary will develop in female sparrows. Both testicles develop in males and during the breeding season these may reach enormous proportions in relation to the size of the bird. These physiologically enlarged testicles should not be mistaken for pathologic conditions.

### Role of Light in Reproduction

Temperate-evolved species (including canaries) are usually dependent on daylight intervals for reproductive performance. Increased daylight hours trigger the release of luteinizing hormone (LH) in responsive individuals. The precise light interval varies among species but the physiologic control mechanism appears to be similar. Light stimulates photoreceptors in the brain, probably in the hypothalamus, where there is a circadian rhythm of photosensitivity. If

light coincides with the period of sensitivity, luteinizing hormone releasing factor (LHRF) is released and gonadotrophin secretion is increased. If light coincides with the insensitive phase of the rhythm there is no response. Gonadotrophin release in turn, triggers the release of sex hormones.

There must be a rest period following a long light exposure to allow the photoreceptive system to reac-

tivate and once again be responsive to increasing day length. Stimulation of the reproductive cycle is best accomplished by a progressive increase (four-week period) of exposure to light. In general, the maximum effect of increasing day length will occur when a passerine individual is exposed to 10-14 hours of light. In males, the release of testosterone may occur in less than 24 hours following exposure to appropriately increased daylight hours. This in turn can result in rapid development of secondary sexual characteristics and breeding display (territorial calling, testicular and cloacal enlargement, courtship behavior).

Courtship behavior is the culmination phase of the reproductive cycle. Response of females to increased photoperiod is less dramatic, and it may require the presence of a male in breeding condition to trigger appropriate nesting and egg laying responses.<sup>60</sup> By gradually increasing the light exposure, a more natural reproductive cycling occurs, and a male is less likely to brutalize a slowly responsive hen. This also accounts for the common aviculture practice of separating males and females during the non-breeding season.

Many aviculturists use a “breeder” cage with a removable partition that allows the male to feed the female through an opening. At various intervals, the partition separating the two sexes is removed, and if the female “accepts” the male, they are left together. The nest is put in the male’s side of the cage along with a source of nest material, which he collects in the nest as part of the courtship activity. An experienced canary breeder can remove the partition at precisely the right time for the female to accept the male.

This photoresponsive mechanism is very sensitive, and some species of birds indigenous to high latitudes commence breeding at almost the same week from one year to the next. The fact that many Psittaciformes hens produce eggs within a one- to two-day period on an annual basis suggests a similar, well defined control system of the reproductive cycle. This is obviously an advantage where suitable conditions for raising chicks are restricted to a very limited season. In indoor breeding aviaries, it is important to mimic appropriate daylight patterns in order to stimulate breeding. Appropriate daylight-hour patterns will vary from species to species. In canaries, 14 hours of light is commonly recommended to induce reproductive behavior in a responsive bird. Longer light periods may cause a shorter breeding period

and early molting. Molting causes an immediate cessation of breeding activity.

After a period of long daylight hours, birds become refractory to photostimulation, and plasma concentrations of both LH and FSH begin to fall. In male White-crowned Sparrows, for example, this occurs after 50 days of long daylight hour exposure. Following the molt and period of decreasing daylight hours (fall), the breeding season starts again with the increasing daylight hours in the late winter and early spring. Following the molt and several months of reconditioning, the process starts over (in the United States, this occurs in December with January breeding).

### Testosterone-induced Singing

Male canaries will usually sing best in the spring in response to the endogenous testosterone “surge.” If a bird becomes ill, it may stop singing and may not recommence vocalizations until the following spring, even though the initial illness has resolved. In contrast, some canaries (even some females) sing year round and birds that stop singing because of illness re-commence singing as soon as their general condition improves. Injectable testosterone has been suggested as a method of inducing singing in birds that have stopped after a period of illness. This is a practice that should be discouraged because the testosterone has a negative feedback that causes shrinking of the testes and reduced fertility.

## Avicultural Considerations

### Husbandry

Dietary and husbandry requirements for passerines are diverse. There are primarily seed-eating species such as the canary and Bengalese Finches that have been domesticated for centuries, are easy to care for and breed well in captivity. Many varieties of these domesticated species bear little resemblance to their free-ranging ancestors. Java Finches, Zebra Finches and Gouldian Finches have somewhat shorter histories of domestication but are also bred intensively in captivity, and many mutations have occurred.

Many Passeriformes are critically endangered because of habitat destruction and human interference. By developing a better understanding of these spe-

TABLE 43.2 Breeding Characteristics of Selected Passerine Birds

	Eggs Per Clutch	Incubation (days)	Fledging
Australian Grass Finches	4-8	12-17	21-25
Birds of paradise	1-2	17-21	17-30
Bowerbirds	1-2	19-24	18-21
Bulbuls	2-5	12-14	14-18
Canaries and Frigillid finches	3-5	12-14	11-17
Cardinals	2-5	11-14	9-15
Crows and jays	2-8	16-22	20-45
Java Finch	4-8	14-14	26-28
Sparrows and weavers	2-5	13-14	21-24
Starlings and mynahs	2-7	11-18	18-30

cies and pressuring local, national and international leaders to preserve all remaining natural habitat, the aviculturist and avian veterinarian can have a dramatic impact on the health of the planet.

Table 43.2 lists the breeding characteristics of selected passerine species.

### Housing

Aviaries for Passeriformes should provide adequate protection from the elements, with tropical species requiring the greatest degree of protection. In mild climates, hardy species of Passeriformes do well in carefully planned, planted aviaries that provide adequate protection as well as visually attractive sur-

roundings (Figure 43.3). Indoor, temperature-controlled rooms may be necessary to raise finches in harsher climates or when artificial lighting control is necessary to increase production.

Planted aviaries are popular for passerines because these birds cause less damage to vegetation than psittacines and the vegetation provides observers a more natural view of a bird's behavior. Care must be taken to ensure that the plant species are nontoxic.

Some passerine birds require special materials for nesting or to stimulate display behavior. Care must be taken that the type of objects provided for these birds are safe. Any contact with fine synthetic fibers should be avoided because these may become entangled around the birds' feet, toes or other body areas and cause damage, loss of limb or death. Burlap (hessian) cut into small squares, torn strips of facial tissue or coconut fiber make suitable, safe nesting materials (Figure 43.4) (see Color 24).

Male Satin Bowerbirds will build intricate display nests that they decorate with blue objects if suitable materials are provided. At one time in Australia, blue plastic rings were used to seal milk bottle tops, and free-ranging bowerbirds would selectively collect these rings from rubbish dumps and elsewhere to decorate their bowers. The rings would occasionally slip over the bowerbird's neck with fatal results. Manufacturers changed the color of the rings from blue to white or red, ending the strangulation deaths.

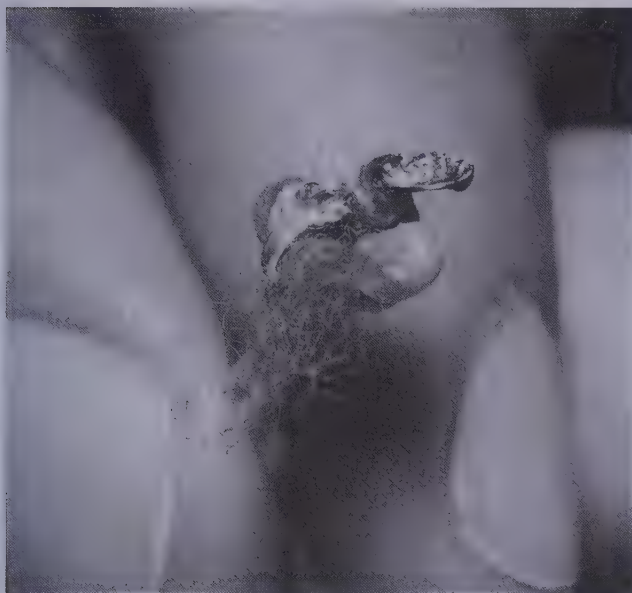### Disease Control

Disease control in planted aviaries can be challenging because of the difficulties involved in controlling microorganisms and in medicating individual birds. Because it is difficult to eliminate infectious agents once they are introduced into a planted aviary, it is critical that any new birds be quarantined, tested and treated for parasites and infectious diseases prior to introduction.

Free-ranging birds should be excluded from aviaries to prevent the transmission of microorganisms. Sparrows, for example, may transmit poxvirus, *Plasmodium*, feather lice, mites and *Haemoproteus* to canaries.



FIG 43.3 Depending on the climatic conditions and the durability of the species, many Passeriformes can be maintained in attractive, planted outdoor aviaries.

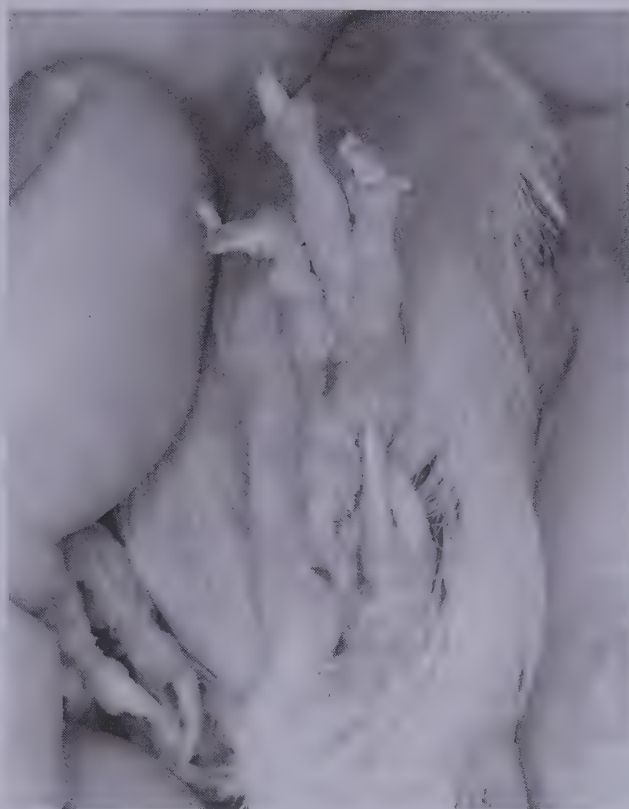


**FIG 43.4** Only natural substitutes (burlap, coconut fiber) should be used for nesting material in Passeriformes. Synthetic fibers (particularly yarn) may wrap around a digit, leg or wing causing avascular necrosis distal to the constriction. In some cases, the fibers are grossly visible, while in others, magnification is necessary to see and remove the constricting fibers. A 26 or 30 ga needle makes an excellent cutting tool for removing small fibers under magnification (courtesy of Michael Murray).

### Nutrition

Passeriformes may be granivorous, nectivorous, fructivorous, insectivorous, omnivorous or carnivorous. Some species adapt readily to commercially available diets, while others may require live food and are thus difficult to maintain in captivity. Some free-ranging species have specific dietary preferences (Gouldian Finches prefer sorghum) but may adapt to diets provided in captivity. Even finches that are considered omnivorous or carnivorous can be successfully raised on properly balanced vegetable-based diets (Figure 43.5).

Recommended dietary levels of vitamins and minerals developed for poultry are used as a base in small passerines. Finches may consume up to 30% of their body weight daily in food compared with 10% for larger parrots. If dietary supplementation is based on a percentage of particular ingredients in the diet, finches may be consuming greater amounts on a per gram body weight basis than larger species. Overdosage of vitamins and minerals may occur, resulting in infertility, renal calcification, gout and general poor condition; thus, only diets specifically formulated for finches should be used.



**FIG 43.5** A mature canary was presented with a four-month history of progressive lameness. The bird was maintained on an all-seed diet in a small enclosure and had no exposure to water for bathing or sunlight. Note the generalized edema, hyperkeratosis, dry brittle nails and poor feather quality suggestive of chronic malnutrition.

Feather color is dietary-dependent in species with carotenoid pigmentation. Red factor and new color canaries have genotypes that require exogenous sources of carotenoids or related compounds to enable full development of yellow, orange and red pigments in feathers. Foods for these birds contain carotenoids and xanthophylls to enable proper color development. Reduced or absent carotenoids during feather formation produces pale or whitish feathers while excess carotenoids will cause a deepening of yellow and red pigments.<sup>8</sup> Commercial diets that contain algae (spirulina) should have sufficient levels of naturally occurring carotenoids to maintain proper feather coloration. In the United States, "colored" foods generally contain carotene-soaked stale bakery products and should be avoided in favor of more natural sources of carotenoids.

Free-ranging Green Finches may be bronze or reddish if they are exposed to excessive carotenoids. Their natural color will return when they are placed

on a more natural diet. Cardinals may fade in color when fruits, berries or greens that contain canthaxanthin are scarce.

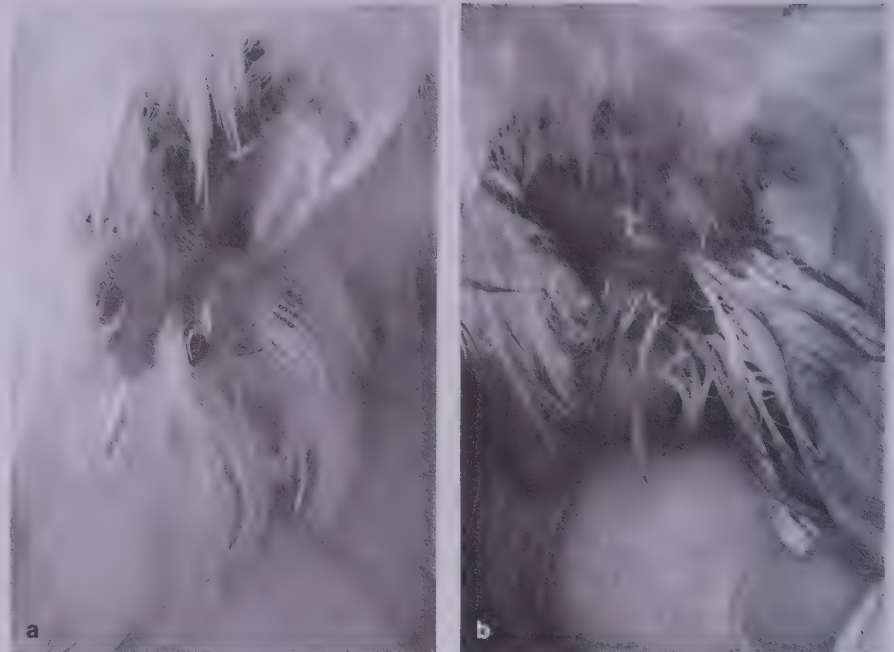
Vitamin A lacks color even though it is related to carotenoid pigments. Birds that have yellow feathers (honeyeaters) may become pale in captivity in spite of being given access to grated carrot and other sources of vitamin A precursors, due to the nutrient's being bound to undigestible cellulose. Consideration should be given to the bird's natural diet. Pollen, for example, may be a source of utilizable carotenoids such as apocarotenol, a pigment associated with golden-orange shades.

### Seasonal Feeding Practices

In passerines indigenous to tropical or arid regions, seasonal changes related to daylight hours are less important to the reproductive cycle than the periodic availability of food and water. Most successful breeders of these species mimic natural conditions by lowering the caloric, protein and fat content of diets and maximizing the birds' physical condition by allowing free flight in open aviaries during the non-breeding season. At the beginning of the breeding season, the birds are "flushed," or encouraged to come into a breeding condition by increasing the plane of nutrition. Misting some species with water (to mimic rainfall) and providing green, fresh foods and foliage may stimulate breeding, particularly those species from desert environments such as the Australian grass finches. Birds must not become chilled during the misting process. Depending on the species, birds may be transferred in pairs to smaller breeding enclosures or left in flights to colony breed.

### Sexing Passerines

In some passerines, there are obvious or subtle morphologic differences between the genders. Males are generally brightly colored or elaborately marked, particularly during the breeding season. Differences in singing, courtship or nesting behavior may also provide clues as to gender. Males usually have a melodious song and are more active during courtship



**FIG 43.6** In many male Passeriformes, the seminal glomerulus swells and pushes the cloaca caudally during the breeding season. The cloacal promontory is **a)** present in the male and **b)** absent in the female, which has a flatter vent.

with dancing, hopping and assuming of various unusual postures in addition to building the nest. The females usually have more of a chirp or single-note call and are more passive in the courtship role.

In males of many species, the caudal end of the ductus deferens forms a mass of convolutions called the seminal glomerulus. During the culmination phase of the breeding cycle, the seminal glomerula pushes the cloacal wall into a prominent projection, the cloacal promontory. This can be observed by blowing the feathers on the bird's vent cranially (Figure 43.6). Hens do not develop this projection and have a flatter vent. In the non-breeding season and with immature birds, these differences are less obvious.

Laparoscopy can be used to determine gender in monomorphic passerine birds, but the small size of many species may increase the risk of this procedure. Newer methods of gender determination using DNA technology are proving useful and will probably be used more extensively in the future. The cost of these procedures tends to limit their application to more expensive species.

### Vasectomy in Finches

Estrilid finches may be vasectomized by making a 3 mm bilateral incision 5 mm lateral to the cloaca. The skin and muscle layers are incised and adipose tissue

is displaced to reveal the seminal glomus. A portion of each seminal glomus is removed. The incisions are closed with single sutures and the bird placed on antibiotics postoperatively. The procedure generally takes less than 15 minutes.<sup>5</sup>

### ■ Combating Aggression

While passerine species may be small, some are quite territorial and others have well developed pecking orders. Head trauma, feather picking, other injuries or death may occur in individuals that have been attacked by a companion (Figure 43.7). Self-mutilation, poor body condition and increased susceptibility to disease can be indirect results of such aggression in birds that are psychologically stressed because of their low social position. Aggression is more likely to occur if the birds are overcrowded in small, open enclosures where less dominant birds have few opportunities to escape from dominant birds. Aggression-related injuries can be particularly pronounced if new birds are introduced into collections where a social order has already been established.<sup>3</sup>


Appropriate measures to prevent combat aggression will vary depending on individual circumstances. Suggestive control measures include:

- prevent overcrowding; the fewer birds, the better
- keep stocking densities low
- clip the wings or remove particularly aggressive individuals
- provide extra vegetation or visual barriers (burlap sheets) to provide less dominant birds with an escape area
- provide multiple perches, feeding locations and nesting sites
- maintain subdued lighting in indoor areas
- simultaneously introduce all birds into a new environment.

Parents that become aggressive toward their chicks are preparing to lay a second clutch of eggs and the chicks should be removed.

Sick or injured birds should be housed separately from other birds to prevent them from being injured by their healthier companions.

Successfully establishing aviaries containing psittacine, passerine and other bird species requires a working knowledge of individual behavioral characteristics and interspecies tolerance. Parrots from the



**FIG 43.7** A Zebra Finch female was presented after having been involved in an episode of territorial aggression in an overcrowded enclosure. The bird had bilateral rear limb paresis with some deep pain. The finch responded to therapy that included corticosteroids and being placed in a dark, cool (72°F) environment.

genera *Neophema* (Bourke's or Scarlet-chested Parrots) or *Polytelis* (Princess Parrots) are usually sedate and will mix well with finches. In contrast, rosellas (except for the Western Rosella) or *Psephotus* parrots (Hooded or Blue Bonnet Parrots) are usually aggressive and will kill other birds that are in their space.

### ■ Cross-fostering Techniques

Species with long histories of domestication, such as Bengalese (Society) Finches, will usually breed freely in captivity without the use of specialized techniques. Members of this species are sometimes used as foster parents to incubate and raise other finches. Similarly, Border Canaries may be used as foster parents for other canary varieties. Cross-fostering is practiced to increase the production of a particular pair of birds. Many species will breed and lay but may require certain foods to raise the young. Many birds will immediately re-lay when eggs are pulled to foster, thereby increasing production.

One of the inherent problems in cross-fostering is that it does not enable selection for good parenting ability in the offspring. The problems that gave rise to the need for fostering in the first place are often perpetuated into future generations. Some organisms such as *Campylobacter* spp. and *Cochlosoma* spp. may cause inapparent infections in foster parent birds but be transmitted to cross-fostered juveniles where disease may result. By comparison, using foster parents may prevent some infectious diseases that are transmitted from infected parent to offspring. For example, colonies of Gouldian Finches that are air sac mite-free have been established by

using Society Finches, which are not susceptible to air sac mites, as foster parents.

Cross-fostering has also been used as a technique to enhance breeding populations of endangered species. The Helmeted Honeyeater, state bird of Victoria, Australia, is endangered. In an effort to save this bird, eggs are collected from free-ranging Helmeted Honeyeaters and are incubated in captivity by the closely related Yellow-tufted Honeyeater. This induces the free-ranging Helmeted Honeyeaters to produce a second clutch of eggs and increase the annual production of chicks from a single pair. Similar techniques have been used to save other endangered passerines such as the Black Robin (fostered under Chatham Island Robins). However, preservation and rehabilitation of suitable natural habitats must also be a priority if captive breeding and subsequent release to the wild is to be effective.

### Imprinting

One of the major disadvantages of fostered birds is that they imprint on the foster parents and may be less likely to breed with their own species. Experimental work in Bengalese and Zebra Finches has shown that development of sexual orientation and adult song patterns occur during a defined period in early juvenile life. Male finches reared by foster parents of a different species or color variety preferentially choose females of the foster species as they sexually mature. If only male members of the foster species were available, the cross-fostered males formed homosexual pairs with these birds rather than heterosexual pairs with birds of their own variety. The critical sensitive period for sexual orientation from imprinting lasts from about the 15th to the 40th days of life. Acquisition of adult song follows a similar pattern: birds raised by foster parents learn the song of the foster parent, even if this song was audible only some weeks prior to the young bird's beginning to sing.<sup>35</sup> For species-specific imprinting to occur, a finch should be exposed to its own species from the 15th to 40th days of life.

Parallels of the imprinting behavior that occur in finches have been defined in humans and other animal species. For example, adult humans retain accents acquired during childhood even when they move to new locations. By comparison, children will quickly change an original accent and acquire the one characteristic to a new location. As an example in other birds, Whooping Cranes in the United States that were foster-raised by Sandhill Cranes did not learn appropriate Whooping Crane courtship behav-

ior, yet were rejected by Sandhill Cranes during the breeding season.

Finches are an inexpensive experimental animal and are being used as a model to study neurophysiologic controls of imprinting.

### Breeding Parasitic Species of Passerines

Some finch enthusiasts relish the challenge of breeding parasitic species (birds that lay their eggs in the nests of other species) such as Paradise Whydahs (parasitize various species of the *Pytilia* family) and Broad-tailed Whydahs (parasitize Aurora Finches). Whydahs are generally bred in large planted aviaries where the parasitized finch species has first been firmly established and is breeding freely. The parallels between the appearance and behavior of the whydah chicks and the finch chicks that they mimic are striking even though the adults of the two species are very different.

If male and female whydahs do not originate from the same geographic area, they may not enter breeding condition simultaneously, preventing successful reproduction. The male whydah develops a long, flowing tail during the breeding season.

## Special Considerations in Managing Passerine Patients

Passeriformes are increasingly presented for veterinary evaluation as aviculturists recognize that successful medical and surgical treatment can be performed, even in tiny patients. However, owner financial constraints and difficulties in collecting samples from small birds may limit diagnostic and treatment options. Veterinary care in these species is frequently directed toward appropriate preventive husbandry measures and approaching medical problems from a flock perspective. As importation of wild-caught Passeriformes (eg, African finches) ceases, the cost of acquiring pairs warrants further financial investment in their care.



### Restraint and Handling

A “lights out/perches out” approach to capture is often useful for small active birds. Birds will generally not move in a dark room and can easily be removed from an enclosure with minimal stress. Once out of the enclosure, the bird can be restrained by placing the head between two fingers so that the body rests in the palm of the hand, or it can be restrained by holding the head gently between the thumb and first finger. The latter can be difficult to execute (Figure 43.8).

### Blood Collection Techniques

The right jugular vein is generally the best site for collecting blood or giving intravenous fluids. It is surprisingly large even in very small birds. A nail clip, medial metatarsal vein or cutaneous ulnar vein are alternative blood collection sites but they frequently provide insufficient sample volumes. A skin prick technique from these sites or from the external thoracic vein (which courses on either side of the rib cage just behind the shoulder) can be used. The blood is collected directly from the skin into a micro-collection tube.<sup>71</sup>

The lymphocyte is the predominant white cell in most passerine species, and lymphocytes rather than heterophils tend to increase in stress-related conditions.

### Treatment Techniques

#### Therapeutics

Although the right jugular vein can be used for administering intravenous fluids, intraosseous catheterization using a 26 ga needle is a practical means of fluid administration in a finch.

Hemorrhage may be a problem following intramuscular injections into the pectoral muscles in small birds. To minimize risk, the injection site should be located in the caudal third of the chest muscles, and a fine gauge needle should be used (25 ga or less). Aspiration should be performed prior to injecting any drug to ensure that a blood vessel has not been cannulated. After the needle has been removed the site should be observed for hemorrhage, and pressure should be applied digitally if bleeding does occur.

Drug dosing in small patients must be based on an exact weight (as determined by a gram scale) and should be delivered with precise microliter or insulin syringes to avoid overdose. There is little room for a dosing error in a small bird.



**FIG 43.8** Passeriformes can be restrained by **a**) placing the head between the second and third fingers and letting the body rest in the palm of the hand, or **b**) by holding the head between the thumb and first finger. Note the clean, dry nostril and perinasal area, relatively smooth beak, dry sleek feathers and clear bright eye suggestive of a healthy Gouldian Finch.

### Fiber Removal

It is common to see canaries and finches with fine fibers (cotton or synthetics) wrapped around their feet or legs. Swellings associated with the feet and legs should be examined using magnification to determine if fibers are involved. Individual digits or the whole foot may be lost from untreated or chronic vascular constriction (see Figure 43.4) (see Color 24).

If there are only a few fibers, it may be possible to remove them using magnification and gentle teasing with fine scissors, a needle and forceps under magnification. If numerous fibers are present, it is best to cut through all the fibers down to the skin, keeping the incision parallel to the long axis of the leg or digit. The incision should be made on the lateral side of the appendage or wherever the fibers are least imbedded. Pulling on deeply imbedded fibers can cause them to further constrict vascular structures. Once all the fibers have been severed, they may be removed with reduced risk of iatrogenic damage.

### Splinting


In small birds, lower limb fractures can often be repaired with a sandwich adhesive or masking tape splint (see Figure 16.3). The limb should be positioned in moderate flexion to enable the bird to move and to prevent bending that may occur if the leg is splinted straight. Several layers of tape may be needed. This type of splint is also used to provide support to weakened or damaged bones following the removal of tight leg bands.

## Diseases

Table 43.3 lists the most common diseases of captive Passeriformes that are likely to be seen by avian practitioners.

### Mutations and Genetic Diseases

Some passerines, such as Gouldian Finches, new color canaries and Zebra Finches, are bred for their color mutations. Other varieties (eg, Norwich, Gloucester and Yorkshire canaries) are bred for morphologic characteristics. Some of these mutations may be associated with genetic disease (Figure 43.9).



**FIG 43.9** Linebreeding and inbreeding to achieve color or morphologic mutations produce a weaker bird with greater potential for genetic abnormalities. This color mutation Gouldian Finch will have a reduced life-span in comparison to its wild-type conspecifics.



**FIG 43.10** Feather cyst formation is believed to be hereditary although infectious agents have not been ruled out as an etiology. Severe localized feather cysts, like this one in a canary, generally require surgery to remove the cyst and all affected feather follicles. Less aggressive therapy generally results in recurrence of cyst formation with subsequent molts (courtesy of Michael Murray).

### Feather Cysts (Hypopteronosis Cystica)

Heavily feathered canaries, particularly those with "double buff" soft feathers, may develop feather cysts. Norwich, Crested, Crest-bred and dimorphic new

color canaries are most frequently affected with this condition but it may occur in other varieties as well. The condition is believed to be hereditary but the mode of inheritance is not simple, and other factors apart from genetics may play a role in the development of the condition. The possibility of a vertically transmitted virus infection causing folliculitis with secondary cyst formation has been suggested.

Feather cysts may occur as isolated or multiple lumps. Often they affect the wings, back or chest. They may be bilaterally symmetrical or occur randomly on the body (Figure 43.10). Badly affected birds have irregularly directed feathers all over their bodies (see Color 24). The cysts may involve one or more feather follicles, and occasionally whole feather tracts are affected. The texture of the material within the cyst will vary depending on the stage of molt. Actively growing feather cysts will have vascular walls and contain blood and gelatinous material. Mature cysts will contain drier keratinous material, and the cyst wall may be more expansive, thickened and reduced in vascularity (see Color 24).

Medical treatment for feather cysts is generally unrewarding. Some canary breeders believe that iodine given at 0.1 ml to 50 ml drinking water will hasten the maturation of feather cysts and allow some to desiccate and slough naturally. Controlled trials to verify this mode of therapy have not been performed, and some feather cysts will heal without treatment. Once mature, the material can be expressed from small cysts but the problem will recur with the subsequent molt.


Surgical options for feather cysts include excision of individual cysts, removal of complete feather tracts or lancing and curetting individual cysts (Figure 43.11). Excision will remove the affected follicle and may be useful for solitary cysts, particularly those

**TABLE 43.3 Common Clinical Presentations and Diagnoses in Companion Passerines**

Clinical Presentation	Common Diagnoses
<b>Canaries</b>	
Open-mouthed breathing, moist rales	Air sac mites, upper respiratory tract infections (bacteria, mycoplasma), inhalant toxins, lymphoproliferative disease
Masses on head	Pox, caseated sinus abscesses, mycoplasma
Masses on wings and body	Feather cysts
Masses on legs and feet	Pox, insect bites, swelling from strangulating fibers, Knemidokoptes mites
Digit necrosis	Strangulating fibers, Staphylococcus infections
Scale on legs, swollen feet	Knemidokoptes mites, genetic, nutritional, associated with aging in some birds
Diarrhea in nestlings	Bacterial infections, Isospora, atoxoplasmosis
Black spot (enlarged, dark liver visible through skin)	Atoxoplasmosis, bacteremias, Plasmodium
Deaths in adults (both sexes)	Bacterial septicemias (especially colibacillosis and yersiniosis)
Abdominal enlargement	Egg binding, leukosis
Deaths in breeding hens	Egg peritonitis (often due to <i>E. coli</i> )
Feather loss from head	Feather mites, male baldness, aggression, malnutrition
Torticollis	Paramyxovirus, listeriosis, cerebral vascular accident
<b>Finches</b>	
Open-mouthed breathing, moist rales	Air sac mites (Gouldian Finches), upper respiratory tract infections
Masses on legs and feet	Knemidokoptes (esp. European Goldfinches), swelling from strangulating fibers, insect bites
Scale on legs	Knemidokoptes (may also be genetic/nutritional in some birds)
Diarrhea in nestlings	Bacterial infections, coccidiosis, atoxoplasmosis, polyomavirus (in Gouldians), Cochlosoma (in Gouldians cross-fostered on Bengalese)
Voluminous white droppings	Campylobacteriosis, pancreatic insufficiency
Seed in droppings	Cochlosoma infections, vitamin E or selenium deficiency, enteritis, lack of grit
Deaths in adults (both sexes)	Bacterial septicemias (especially colibacillosis and yersiniosis); tapeworms or gizzard worms (in insectivorous finches); mycobacteriosis (esp. siskins); avian malaria (parrot finches)
Feather loss from head	Feather mites, aggression from enclosure mates
<b>Mynahs (and other Sturnidae)</b>	
Ascites, dyspnea	Iron storage disease, hepatic cirrhosis or neoplasia, congestive heart failure
Seizures	Epilepsy
Nasal discharge, sinus swelling, rales	Bacterial upper respiratory tract infections, malnutrition
Chronic weight loss, dyspnea	Aspergillosis, mycobacteriosis

located on the body. This therapy is not practical if there are numerous cysts and will not prevent new cysts from developing at remote sites. In birds with numerous cysts it may be more practical to remove a complete feather tract<sup>2</sup> (see Color 24).

The author's preference for treating feather cysts is to place hemostats at the base of the cyst and remove



**FIG 43.11** Surgically removed feather cyst from a canary (courtesy of John Cooper).

all tissue to the base of the hemostats with a radiosurgical unit. With this technique, the contents of the cyst are removed along with the skin that forms the wall of the cyst but the cyst is not totally excised. The hemostats are removed, and any remaining keratinous material is curetted from the base of the cyst. The small remaining part of the interior lining is cauterized with the radiosurgical unit. An elastic adhesive bandage is used to control minor bleeding. The advantages to this technique are that it is quick, economical and can be performed without anesthesia. Stitches are generally not required. The cosmetic effect is preferred to what occurs when cysts are simply lanced, and damage to surrounding tissue is less than with total excision. If the base of the cyst has been adequately cauterized, there is generally no recurrence at that site.

Birds with feather cysts should not be used for breeding. Unfortunately, cysts may not develop in a bird until after it is reproductively active.

#### Crested Canaries

Crested varieties of Norwich or Glouster canaries are occasionally kept for show or pets. Depending on the variety, birds with crests are referred to as "coronas" or "crested" while those of the same conformation but without crests are referred to as "consorts" or "crest-bred." The desirable crested phenotype is heterozygous for the autosomal crested gene. Birds that are homozygous for the crested gene die. Crested canaries are produced by breeding crested birds (coronas) with non-crested (consorts or crest-bred) canaries. This mating will result in 50% crested birds (Cc) and 50% non-crested birds (CC). If crested birds are mated to crested birds, normal Mendelian genetics will result in 25% non-crested, 50% crested and 25% dead chicks.

#### Dominant White Lethal Factor

Canaries that are homozygous for the dominant white gene die, while heterozygous individuals are white. Two dominant white birds should not be mated or all the chicks will die. If white birds are mated with other color varieties, 50% of the chicks will be heterozygote-dominant white and 50% of the chicks will be other colors.

#### Straw Feathers

Canaries and Zebra Finches occasionally show retention of the feather sheath and incomplete development of the barbs and barbules. The disease may affect first-molt fledglings or adult birds in a symmetrical fashion; it is believed to be genetically determined (see Color 24).<sup>18,58</sup>

#### Cataracts

Cataracts are occasionally seen in canaries, particularly in Norwich and Yorkshires. Affected birds will often be found on the bottom of the cage or aviary, possibly avoiding flight after a previously misjudged landing. Histologically, there may be disorganization of lens cortex, fragmentation of fibers, globule formation and lens resorption. Cataracts are reported to be caused by a recessive gene in Yorkshire and Norwich canaries. They may be removed surgically.<sup>36,67</sup>

### Viral Diseases

#### Poxvirus

- Clinical Presentation:** The clinical appearance of poxvirus in passerine birds varies with the virulence of the strain, the mode of transmission and susceptibility of the host. Canaries and House Sparrows are particularly susceptible and may show the cutaneous, septicemic or diphtheroid forms of the disease (Figure 43.12). The cutaneous form of poxvirus has also been reported in a variety of free-ranging Passeriformes, eg, starlings, juncos, silvereyes and Australian magpies.<sup>26,57</sup> Poxvirus infections are usually self-limiting in free-ranging birds.

Poxvirus may be transmitted from free-ranging starlings to other members of the Sturnidae family. In one instance, all of a group of Rothschild's Mynahs exposed to infected starlings died. In Greater Hill Mynahs, poxvirus has been associated with low mortalities, but chronic eye, wattle and oral lesions occur. These include proliferative lymphocytic conjunctivitis, keratitis, chronic corneal ulcers, lid depigmentation, cataracts, eyelid distortion and scar tissue with feather loss on the head.<sup>37</sup>



**FIG 43.12** Poxvirus infections are common in canaries that are maintained outdoors in areas with high densities of mosquitoes. Depending on the species of bird and virulence of the virus, either cutaneous, diphtheritic or septicemic forms of the disease may occur. Cutaneous lesions are common on **a**) the face or **b**) feet and legs (courtesy of Michael Murray).

Mortalities of up to 100% have occurred in some outbreaks of canary pox. Acutely affected birds may show lethargy, ruffled feathers, open-mouthed breathing and death in two to three days. In less acute cases, birds may show conjunctivitis, blepharitis and lacrimation before the appearance of characteristic proliferative lesions around the eyes and mouth. Death may result if these lesions cause pharyngeal obstruction. On necropsy, birds dying acutely may show cloudy air sacs and pneumonia with proliferative necrotizing bronchitis, while those dying later in the course of the disease are more likely to show proliferative skin lesions and typical intracytoplasmic inclusions in the epidermis and respiratory epithelium. The skin lesions should be differentiated from mosquito bite abscesses, which result in discrete lumps that contain caseous material when

lanced.<sup>18,40</sup> An uncomplicated pox lesion is a contained fibrous reaction without a necrotic, expressible center.

A much milder form of cutaneous canary pox is also seen in southeastern Australia and California. Periodically more virulent strains erupt and high mortalities occur, particularly in birds kept in outdoor aviaries in areas with dense mosquito populations.

While birds affected with poxvirus will typically show intracytoplasmic Bollinger bodies, intranuclear inclusions have been demonstrated in the junco. Concurrent infections with other viruses have also been noted. Retrovirus-like particles have been found in the brains of some poxvirus-infected canaries.<sup>11</sup> Adenomatous tumors in the lungs have occurred as a sequel to poxvirus infections.

Serologic cross-reactions between strains of poxvirus in Passeriformes have not been demonstrated, but some strains will affect more than one passerine species. For example, in one outbreak, canaries and House Sparrows were the only species to show clinical signs of poxvirus or mortality even though ten species of passerine birds were present in the aviary (see Chapter 32).

- **Treatment and Control:** There is no specific treatment for poxvirus. Antibiotics may be useful to control secondary infections, and vitamin A or its natural precursor may aid in the healing process. Scarifying individual pox lesions may result in spontaneous remission. Topical application of astringent solutions such as mercurochrome or alcohol may be useful. Adenine arabinoside ointment<sup>a</sup> has also been recommended. Mild baby shampoo may be gently applied to any lesions around the eyes to remove scabs. Immune stimulants such as PEP-E<sup>b</sup> and echinacea may be of possible value.

Avian poxviruses can be transmitted by mosquitoes, mites or by contact through damaged epithelial surfaces. Bird rooms should be mosquito-proofed and treated with insecticides to eliminate vectors, and affected birds should be isolated until fully recovered. Recovered birds generally have lasting immunity to the disease but may become carriers and shed the virus. A modified live virus canary pox vaccine<sup>c</sup> is available in some countries.<sup>15,18</sup>

### Herpesvirus

Herpesviruses have been isolated from Estrildid finches, Ploceid finches (weavers and whydahs) and canaries, but in most cases they have not been asso-

ciated with disease. Outbreaks of conjunctivitis in Gouldian Finches associated with herpesvirus-like particles have been reported in Europe.<sup>64</sup>

### Cytomegalovirus

An epidemic of conjunctivitis with respiratory distress and a 70% mortality rate was reported in Australian grass finches maintained in Europe. Basophilic intranuclear inclusions were seen in karyomegalic epithelial cells of conjunctiva, esophagus and trachea. Cytomegalovirus-like particles were identified by electron microscopy.<sup>12</sup>

### Polyomavirus

Polyomavirus-like infections have been associated with several clinical presentations in passerine birds. Sporadic deaths have occurred in adult finches of various species, particularly in birds that have been stressed by transport or other factors. Ventricular mycosis has been reported as occurring concurrently with polyomavirus in many of these birds.<sup>40</sup>

In color mutation Gouldian Finches, polyomavirus-like infections have been reported to cause acute mortality in two- to three-day-old babies, and poor growth, dirty feathering and late fledging in older nestlings. Many affected birds had an abnormal lower mandible that was long and tubular (Figure 43.13). Nonspecific illness and mortality occurred in slightly older birds. Concurrent *Candida* infections were common.<sup>46</sup>

In a separate report, deaths in fledgling and immature Gouldian Finches occurred without any concurrent feathering or beak defects. The most consistent gross lesion was a swollen, pale liver.<sup>22</sup> Currently there is no effective treatment for polyomavirus. Controversy exists as to whether it is best to depopulate, rest breeding stock or to continue to breed with the expectation that birds will develop immunity (see Chapter 32).

While polyomavirus-like intranuclear inclusion bodies have been described in finches in North America, Europe and Australia, the virus has not yet been cultured from passerine species. Gross lesions that have been associated with polyomavirus infections in finches include perirenal hemorrhage, serosal or subserosal intestinal hemorrhage, splenomegaly, and swollen or mottled liver. Histologically, amphophilic intranuclear inclusion bodies are typically seen in the kidneys, heart, spleen, gastrointestinal tract or liver. Cellular necrosis may occur in the bone marrow, gastrointestinal tract, spleen or hepatocytes.



**FIG 43.13** Long, tubular lower beaks have been reported in Gouldian Finches with polyomavirus-like infections.

Diagnosis is based on the histologic presence of large, clear-to-amphophilic, intranuclear inclusion bodies in one or more organs. Fluorescence should occur using polyclonal antibody FITC-labelled conjugate specific for polyomavirus antigen. Electron microscopy should reveal polyomavirus-like particles.<sup>75</sup>

### Papillomavirus

Avian papillomavirus has been demonstrated in association with papillomas on the legs of wild European chaffinches. Three hundred and thirty birds out of approximately 25,000 birds examined were affected. The virus was purified and its physicochemical properties characterized.<sup>42,51</sup>

Viral papillomatosis has also been described in canaries from Argentina. The disease occurred seasonally during late summer and autumn over a three-year period, and the outbreaks were controlled using hygienic measures and an autogenous vaccine.<sup>45</sup>

### Paramyxovirus

Passerines are known to harbor paramyxoviruses of groups 1,2 and 3.<sup>26</sup>

- **Group 1 (Newcastle Disease Virus):** Many weaver finches are susceptible and show conjunctivitis, pseudomembrane formation in the larynx and death. Neurologic signs are rare. Canaries rarely develop clinical signs, and infected birds should be considered asymptomatic carriers. Because species susceptibility varies, mortality patterns in an aviary may be sporadic and an infectious agent may not be considered as the cause.

- **Group 2:** Free-ranging passerines, particularly weaver finches in North Africa, are considered to be carriers of this virus. Many infected birds are asymptomatic but others may die following a period of emaciation and pneumonia.
- **Group 3:** This virus has been isolated from a variety of passerines including canaries, Gouldian Finches and weaver finches. It is generally associated with an overall poor condition and central nervous system signs (tremor, paralysis or torticollis).

### Leukosis

Sporadic deaths associated with enlarged pale livers and spleens and histopathologic lesions suggestive of leukosis have been reported in canaries in Europe, Australia and North America. A viral etiology has been proposed but has not been confirmed.<sup>1,15,18</sup> Treatment with prednisolone may slow the progression of the disease.

### Chlamydia Infections

Passeriformes are less susceptible to chlamydiosis than Psittaciformes. Chlamydia has been isolated from the droppings of clinically normal finches in households in which clinical cases of chlamydiosis occurred in psittacine species. Active disease outbreaks are intermittent, and infection rates of less than ten percent of the at-risk population are typical.<sup>16</sup> Chlamydiosis should be suspected in passerines with recurrent respiratory disease especially if they are exposed to psittacine birds.

### Mycoplasma

*Mycoplasma* spp. have been isolated from canaries with wheezing, respiratory signs including tail-bobbing and conjunctivitis. Many cases of conjunctivitis and upper respiratory disease in canaries are responsive to tylosin. However, there has been no conclusive experimental work proving that mycoplasma is associated with this syndrome<sup>25</sup> (see Figure 43.1).

Tetracyclines are believed to be effective against many mycoplasma isolates as well as chlamydia. Both of these infectious agents are difficult to identify in a live bird, and a therapeutic trial with tetracyclines may be appropriate if they are suspected of being part of a disease complex. Tylosin or tiamulin are other drugs that may be considered if mycoplasma disease is suspected.

### Bacterial Infections

Some investigators believe that bacteria and other microorganisms should seldom be found in stained fecal smears from normal canaries and finches. Others believe that low levels of gram-positive rods or cocci are considered normal. There is generally no bacterial growth on routine aerobic microbiological cultures taken from passerine birds.<sup>15,21</sup>

The general principles for treating and controlling bacterial infections in passerines are similar to those discussed in psittacines (see Chapters 17, 33). Passerines are frequently maintained in planted aviaries and medicating individuals can be extremely impractical. If a decision is made to use water-based medication, frequently used drugs include trimethoprim and sulfamethoxazole, amoxicillin, chloramphenicol, tetracyclines and enrofloxacin. Some passerines are particularly sensitive to certain antimicrobial agents (dimetridazole, furacin) and care should be exercised when administering any medication to a finch or canary (see Chapter 18).

### Gram-positive Flora

- ***Staphylococcus* spp.** are normal inhabitants of the gastrointestinal tract and the skin but occasionally virulent strains may cause disease in susceptible hosts (see Chapter 33). Staphylococcal infections are commonly associated with the occurrence of thrombi in arterioles. This lesion can be particularly dangerous in small birds because collateral circulation is more limited than with larger birds. Digit necrosis, gangrenous dermatitis and pododermatitis are likely outcomes. Other clinical syndromes that have been associated with staphylococcus infections in passerines include high embryonic mortality, omphalitis, septicemia and arthritis.<sup>27</sup>

Streptococcal infections have also been associated with embryonic mortality, omphalitis, septicemia and arthritis in passerines, although, like staphylococcus, these bacteria are often part of the normal autochthonous flora.

- ***Enterococcus faecalis*** (formerly *Streptococcus faecalis*) has been associated with chronic tracheitis, pneumonia and air sac infections in canaries. Experimental infections are possible following subcutaneous or intrathoracic air sac injections but not by simple aerosol administration. Clinically affected birds have harsh respiratory sounds, voice changes and dyspnea. These changes are similar to those caused by the tracheal mite *Sternostoma tracheacolum*. Concurrent infections are possible.<sup>13</sup>

- ***Mycobacterium avium***: Passerines are susceptible to *Mycobacterium avium* and may show nonspecific signs similar to those seen in other avian species: chronic wasting, diarrhea, polyuria, anemia, dull plumage and leukocytosis. Classic tubercles rarely develop, and gross necropsy findings usually reveal minimal changes. Two histopathologic conditions have been noted: small focal granulomas may be found in the lungs or high numbers of acid-fast bacteria may be noted in the lamina propria of the intestine.<sup>27,47,61</sup>

Red-hooded Siskins may be particularly susceptible to tuberculosis. Treatment of companion birds for *Mycobacterium* spp. is not recommended because of the public health concerns.

- ***Erysipelothrix rhusiopathiae*** may cause disease in passerines as it does in other avian species but infections are not common.
- ***Listeria monocytogenes*** is a ubiquitous organism that may be transmitted by the oral route. Canaries are particularly susceptible to listeriosis and flock outbreaks may occur. Clinical signs include torticollis, tremors, stupor, paresis or paralysis. A marked monocytosis may occur. Tetracyclines may be useful therapy in the early stages of the disease but treatment is usually ineffective in birds with CNS signs.<sup>21</sup>
- ***Clostridium perfringens*** was isolated from a canary that died after eating contaminated food. Other reports of clostridial infections in Passeriformes are scarce but there is no reason to believe that birds of this order would not be susceptible.<sup>31</sup>
- ***Megabacterium***: A large, rod-shaped, gram-positive bacteria that was difficult to culture and was associated with a proliferative, inflammatory reaction in the proventriculus of canaries was described in Europe. In affected birds, the proventriculus had an increased pH and altered synthesis of mucopolysaccharides. The koilin lining of the ventriculus was thinner in affected canaries than in a control group, possibly as a result of the increased pH in the proventriculus. The organism identified in these birds appeared to be very similar, if not identical, to the organism defined as "megabacterium" in psittacine birds (see Color 14).<sup>69</sup>

#### Enterobacteriaceae and Other Gram-negative Bacteria

Enterobacteriaceae are generally considered secondary pathogens. The predisposing factors that allowed organisms to colonize the bird should be iden-

tified and corrected. Oral neomycin or spectinomycin may be useful for infections localized to the gastrointestinal tract.

- ***Escherichia coli*** has been associated with a variety of disease problems in passerine birds including diarrhea, septicemia and ascending oviduct infections. Ascending oviduct infections are usually rare; however, *E. coli*-induced egg-related peritonitis and metritis have been associated with high mortality in some canary flocks in southeastern Australia. Juveniles and cock birds on the same premises were not affected. Mortalities stopped when the birds were placed on appropriate antibiotics (as indicated by sensitivity testing). Interestingly, bacteria isolated from Australian birds are frequently sensitive to a wider range of antibiotics than are commonly reported with similar organisms in the United States.<sup>44</sup>
- ***Salmonella typhimurium var copenhagen*** is commonly isolated from finches in Europe that develop a characteristic granulomatous ingluvitis, which can be confused with crop candidiasis or capillariasis. Histologic lesions are nonspecific and include intestinal inflammation and focal necrosis in the heart, lung, liver, spleen and kidney. Granulomas may occur in chronic cases. *Salmonella* spp. have also been isolated from cases of osteomyelitis and subcutaneous granulomas in canaries.<sup>54,62</sup>
- ***Citrobacter* sp.** is commonly found as a secondary invader in weaver finches and waxbills. It has also been associated with acute septicemia and death.<sup>21</sup>
- ***Yersinia pseudotuberculosis*** is a common cause of peracute mortality in finch and canary aviaries as well as causing general ill health, diarrhea and dyspnea. The organism is believed to have originated in Europe with worldwide dissemination occurring through rodents on ships. Yersiniosis is a widespread problem in Australian aviaries where rodent control is poor. Infections occasionally occur in free-ranging birds. Enteritis and pinpoint or large abscesses throughout the liver and spleen are characteristic gross findings. Affected birds are often too sick to respond to therapy but treatment of exposed birds with antibiotics based on sensitivity testing will usually stop an outbreak. Decontaminating the aviary and rodent-proofing food and water supplies should accompany any antibiotic therapy.<sup>27,44</sup>
- ***Klebsiella, Pasteurella and Haemophilus* spp.** are occasionally isolated from Passeriformes. *Pasteurella* is often associated with fatal septicemias following cat bite wounds. Even if injuries seem mi-



nor, birds that have been bitten or scratched by cats should receive antibiotics immediately.

- *Campylobacter fetus* var. *jejuni* has been associated with pale, voluminous droppings (“popcorn poohs”) in canaries and finches of a variety of species (particularly Gouldian Finches). European investigators have suggested that adding animal protein, minerals and vitamins (soft food) to the diet may strengthen the bird’s immune system and protect against repeated infections. Antibiotics (particularly erythromycin and tetracyclines) may also be useful.<sup>70</sup>
- *Pseudomonas* sp. infections may originate from the consumption of contaminated drinking water, misting bottles or inappropriately prepared soaked seed. The organism may cause foul-smelling diarrhea or mucopurulent pneumonia and air sacculitis. Treatment should be based on sensitivity testing, as the bacteria is often resistant to routinely used antibiotics. Steps should be taken to identify and remove environmental sources of contamination.
- *Aeromonas* sp. has been isolated from European rooks and House Sparrows.<sup>29</sup>

## Fungal Infections

### *Candida albicans*

Identifying candida in fecal swabs from passerines should be evaluated with caution. Many passerine species are fed bread products that are made with yeast. Yeast blastospores may pass through the gastrointestinal tract unchanged and appear in large numbers in the feces. These organisms do not reflect disease. Small numbers of candida blastospores may also be present as a part of autochthonous flora.

*Candida albicans* is occasionally associated with upper gastrointestinal tract infections in passerines, particularly in immunosuppressed or hand-fed neonates. Vomiting, anorexia, weight loss and diarrhea are characteristic findings. The lining of the crop may be thickened and covered with whitish “turkish towel” coating (see Color 14). Yeast blastospores or hyphae may be identified on Gram’s stain of material from a crop wash. Systemic candidiasis has also been reported in canaries.<sup>17</sup> Nystatin or ketoconazole may be useful in infections confined to the gastrointestinal tract (see Chapter 15).

### *Aspergillus* spp.

Aspergillosis may cause weight loss, respiratory distress, anorexia, vomiting or diarrhea in infected pas-

serines. Immunosuppression, usually from malnutrition, along with contaminated environmental conditions are primary factors in the development of the disease. Captured free-ranging birds are often stressed, suffering from poor nutrition and kept in unclean surroundings with decaying organic material. It is not surprising that aspergillosis occurs under these conditions. Aspergillosis is also a common postmortem finding in sporadic deaths in free-ranging passerine birds. A granulomatous form of this disease occurs in which nodules varying in color from yellow to white may be seen in the liver, lungs, kidneys, muscles and subcutaneous tissues. Most Passeriformes should be considered susceptible.<sup>57</sup>

Aspergillosis was a major cause of mortality in hatchling Helmeted Honeyeaters. Mortality was controlled by nebulizing the birds with amphotericin B.

Captive mynahs are reported to be particularly susceptible to aspergillosis, possibly because of their moist, messy droppings and the tendency for these birds to be maintained in small enclosures<sup>39,63</sup> (see Chapter 35).

### *Cryptococcus neoformans* var. *neoformans*

Respiratory or systemic cryptococcosis has been rarely diagnosed in passerine birds, even though the organism has been isolated from seed and droppings of canaries. It has been suggested that the fungus might persist from year to year on the wood of poorly cleaned enclosures. The organism has been associated with deaths in munia finches<sup>53</sup> (see Chapter 35).

### Zygomycosis (Mucormycosis)

Multiple fungal granulomas have been identified in the lung, liver or brain in canaries and Gouldian Finches fed damp, germinated seeds (sprouts). Histologically, fungal hyphae are frequently associated with blood vessel walls.

### Superficial Mycoses

Dermatomycoses are occasionally reported in passerines and generally cause alopecia (especially of the head and neck) or hyperkeratosis. *Microsporum gallinae* and *Trichophyton* spp. are the most common etiologic agents, but other saprophytic fungi may also be involved. Whole body dermatomycosis has occasionally been seen in free-ranging Red Wattle birds (a type of honeyeater) presented at the author’s practice. In one case, the client also developed dermatomycosis. Treatment with ketoconazole and griseofulvin provided some improvement but did not eliminate the infection. Topical baths with chlor-

hexidine and tamed iodine washes were irritating but they did lead to some improvement. One bird died when the owner attempted home treatment by applying a propylene glycol-based product over extensive areas of the bird's body.

## ■ Protozoa

### Cochlosoma

*Cochlosoma* spp. are flagellates that inhabit the gastrointestinal tract of some finches. Bengalese Finches may be inapparent carriers of this organism; when they are used to foster species of Australian finches (such as Gouldians), they may pass the organism on to juveniles, causing high mortality in nestlings. Typical clinical signs include debility, dehydration and passing whole seeds in the droppings. At necropsy the intestine may be filled with a yellow suspension or whole undigested seeds. Most affected birds are six to twelve weeks of age.

The organism may be identified by direct wet preparation of fresh warm droppings or at necropsy using intestinal contents. *Cochlosoma* has six anterior flagella with a helicoidal, anterior ventral sucker.<sup>38</sup>

Treatment with ronidazole at 400 mg/kg in egg food and 400 mg/liter of drinking water for five days has been suggested. After a two-day rest period, the treatment is repeated. Dimetridazole may also be used at no more than 100 mg of active ingredient per liter of water for five days. Water containers should be disinfected and rinsed clean (the organism is sensitive to most common disinfectants) and the aviary should be kept clean and dry.<sup>15</sup>

### Trichomonas

*Trichomonas* spp. infections are occasionally seen in finches, particularly those housed near infected budgerigars. Clinical symptoms include gagging, neck stretching, regurgitation, respiratory distress, nasal discharge, green diarrhea and emaciation. Diagnosis is made by identifying the flagellate on a wet smear prepared from a crop wash. At necropsy, caseous material may be seen lining the crop and esophagus, and flagellates may be identified from this material provided that it is fresh.

### Giardia

*Giardia* sp. has also been reported to be associated occasionally with gastrointestinal tract infections in finches. Treatment is the same as for cochlosomiasis.

## ■ Coccidiosis

Coccidia infections in passerine birds may be asymptomatic or associated with diarrheal syndromes (sometimes with blood in the droppings), emaciation, general ill health and systemic disease. Systemic protozoal disease is occasionally diagnosed in avian species, but it is difficult to classify the causative organism based solely on histologic appearance. Fresh tissues for transmission studies, blood for serology and hematology and feces for parasitologic evaluation should be saved from patients where protozoal disease is suspected.

Coccidia in the Eimeriidae family have a single host. Development of the endogenous stages occurs within host cells to produce a resistant oocyst. Sporulation of oocysts usually takes place outside the host and oocysts of different genera have a characteristic number of sporocysts, each with one or more sporozoites<sup>68</sup> (see Chapter 36).

Eimeriidae genera affecting passerines include:

- *Eimeria* (oocysts with four sporocysts each containing two sporozoites)
- *Isospora* (oocysts with two sporocysts each with four sporozoites)
- *Dorisiella* (oocysts with two sporocysts each with eight sporozoites)
- *Wenyonella* (oocysts with four sporocysts each with four sporozoites)
- *Sarcocystis* (oocysts with four sporozoites)
- *Toxoplasma* and *Cryptosporidium* (same as *Isospora*, but sporocysts are usually found individually instead of inside membrane-like oocyst wall)

When examining fresh fecal material, it is often not possible to classify coccidial oocysts because sporulation may take several days to occur (see Chapter 36).

Atoxoplasmatidae are single-host coccidia with merogony in the blood and intestinal cells, gametogony in the intestinal cells of the same individual and sporulation outside the host. This family contains a single genus, *Atoxoplasma*. Early work suggested that *Atoxoplasma* spp. could be transmitted between different bird species, particularly between House Sparrows and canaries, by an arthropod transport host (particularly the red mite *Dermanyssus gallinae*). More recent investigations have shown that these findings were incorrect, and that the parasite is transmitted directly via oocysts in the feces and that it is host-specific.<sup>21,38,43,68</sup>

### Coccidia in Canaries

Oocysts from *Atoxoplasma* or *Isoospora* spp. may be found in the feces of infected canaries. *Isoospora* is less pathogenic and completes its life cycle within the intestines while *atoxoplasma* develops asexually in mononuclear blood cells and spreads hematogenously to other organs including the liver, spleen and lungs.

Canaries with atoxoplasmosis may be defined as having "black spot," referring to the enlarged, dark liver that is visible beneath the skin. Diarrhea, nonspecific illness and death sometimes occur. The organism can be diagnosed by identifying sporozoites on Giemsa-stained impression smears of the spleen, liver or buffy coat. The sporozoites are found in the cytoplasm of lymphoid-macrophage cells and appear as oval structures containing pink-staining chromatin. Indentation of the host nucleus often occurs (see Chapter 36). Table 43.4 is useful for differentiating between these two species.<sup>20</sup>

Sulpha drugs or amprolium are usually effective for *Isoospora* sp. but *Atoxoplasma* sp. is resistant to treatment. Maintaining clean surroundings to reduce the birds' exposure to the infective oocysts may help control infections, but will probably not eradicate the organism from an aviary.

### Coccidia in Other Passerine Species

Morphologically similar *Isoospora* species of coccidia have been identified in over 50 species of passerine species throughout the world. This species has been named *Isoospora lacazei* although it represents more than a single species. Many other morphologically distinct species of *Isoospora* have also been identified. Life cycles are believed to be similar to *Isoospora canaria*.<sup>68</sup>

*Eimeria* spp. generally follow the same pattern as *Isoospora* and complete their life cycle in the intestinal tract. One species, *Eimeria grallinida*, has been described in a wild-ranging Australian Magpie-Lark in which the parasite was found in the liver. The affected bird had been found in a moribund state and died shortly thereafter. On necropsy, the bird showed marked hepatic enlargement with small white foci. Various stages of the life cycle including schizogony, gametogony and oocysts were found in the bile ducts. Sporulated oocysts were consistent morphologically with *Eimeria* sp.<sup>60</sup>

Coccidia of the genus *Dorisiella* have been identified in a number of passerine species including munias,

TABLE 43.4 Characteristics of *A. serini* and *I. canaria*

Characteristic	<i>A. serini</i>	<i>I. canaria</i>
Oocyst length	20.1 (13-23) $\mu\text{m}$	24.6 (17-30) $\mu\text{m}$
Oocyst width	19.2 (13-23) $\mu\text{m}$	21.8 (17-30) $\mu\text{m}$
Length:width	1.05	1.13
Prepatent period	9-10 days	4-5 days
Patency	10 ->95 d	5-18 d post-infection
Duration of infection	4 months	2-3 weeks

avadavats, hawfinches and a Fohkein Grey-headed Crow Tit. Pathogenicity appears to be minimal. *Wenyonella* sp. has been recovered from Pied Wagtails in India.<sup>68</sup>

### Sarcocystis

Sarcocysts are common in the skeletal muscles of passerines from many geographic regions. North American cowbirds, grackles and other Passeriformes have been shown to be the intermediate hosts of *Sarcocystis falcatula*, for which opossums are the definitive host. In Australia, sarcocysts are incidental findings at necropsy and a definitive life cycle has not been determined. Cysts can sometimes be observed through the skin.<sup>33,38</sup>

### Toxoplasmosis

*Toxoplasma gondii* is occasionally identified in passerines and in isolated cases may cause death. In one outbreak, all 23 mynahs in a shipment died with visceral toxoplasmosis. It was postulated that the birds had been exposed to the organism at some time prior to shipment and that the stress of transportation had reactivated latent infections.<sup>14</sup>

Cats and other members of the Felidae family are definitive hosts for *Toxoplasma gondii*, and birds must ingest oocysts from cat droppings or visceral cysts from other animals in order to be infected. Feral cats in Australia have damaged native bird populations from direct killing and by spreading *Toxoplasma* sp. In one Tasmanian study, over 30% of free-ranging ravens were found to carry the organism. Carnivorous marsupials, many of which are threatened or endangered, are extremely susceptible to toxoplasmosis. If a free-ranging bird infected with toxoplasmosis is eaten by one of these species, the marsupial is likely to die. Birds infected with toxoplasmosis may be asymptomatic or show neurologic symptoms, ophthalmitis or sudden death. Such birds are easy targets for free-ranging carnivores. To avoid fecal contamination and the risk of toxoplasmosis, cats should be prevented from entering bird food storage areas.

### Cryptosporidiosis

*Cryptosporidium* sp. has been associated with acute onset, severe diarrhea and death in a Diamond Fire-tail Finch. At necropsy the bird showed focal cuboidal metaplasia of glandular epithelial cells of the proventriculus and amyloid deposits at the base of the glands, as well as renal amyloidosis.<sup>6</sup> Proventricular cryptosporidiosis has also been identified in canaries with concomitant salmonellosis. Renal cryptosporidiosis has been diagnosed in a Black-throated Finch.<sup>24</sup>

*Cryptosporidium* sp. has a direct life cycle but oocysts have not been identified in the droppings of clinically affected passerines. The true clinical significance of the organism is not known, as it is often associated with other disease entities.

### Blood Parasites

Blood parasites may be detected on routine screening of apparently healthy passerines, but they are occasionally implicated as the primary cause of disease or death. Life stages of the coccidian parasite *Atoxoplasma* sp. may also be seen in monocytes and lymphocytes. The occurrence of blood parasites varies from time to time and region to region. There is some evidence that the incidence of blood parasites in birds has decreased in some areas as a result of decreased numbers of invertebrate vectors.<sup>4</sup>

Passerine families reported to be most commonly infected with hematozoa in one European study included Paridae (tits, 8% affected), Sylviidae (warblers, 14% affected) and Turidae (thrushes, 10% affected). The most commonly encountered parasites included *Haemoproteus* sp. (4%), *Leucocytozoon* sp. (1.8%), *Trypanosoma* (0.9%), *Plasmodium* (0.8%), *Atoxoplasma* (0.2%) and microfilaria (0.1%). *Haemoproteus* sp. is also the most common blood parasite encountered in birds in North America and Australia.<sup>4,43</sup>

Other blood parasites that are occasionally seen in passerines include the small tick-borne erythrocytic parasites *Aegyptianella* and *Nuttallia* spp.

### Plasmodium

*Plasmodium* spp., the cause of avian malaria, are mosquito-borne protozoa of the family Plasmodiidae that occur worldwide. Sporogony occurs in the invertebrate host, schizogony occurs in erythrocytes and pigment is formed from the host cell hemoglobin. Each of the avian plasmodia has a limited host range but they do not appear to be particularly host-specific. *Plasmodium* spp. have been described in free-

ranging wild tits, Fringillid finches, Old World warblers, thrushes, starlings, sparrows and in Australian magpies.<sup>4,43</sup>

The parasite has been associated with significant mortalities in Blue-faced Parrot Finches in the Taronga Zoo in Sydney. Free-ranging house sparrows are believed to have been asymptomatic carriers of the organism. No other species of captive birds at the zoo were affected. The parrot finches showed signs of lethargy, anorexia, labored respiration and death. A darkened, enlarged liver could be observed as a "black spot" through the skin and muscle of the abdominal wall. Treatment with chloroquine or pyrimethamine was successful in some cases but the birds did not have any lasting immunity and were susceptible to repeated infections. Controlling mosquito vectors is necessary to prevent infections. Avian malaria has also been reported to cause deaths in canaries and other species.<sup>23,71</sup>

### Haemoproteus

Like *Plasmodium* sp., *Haemoproteus* spp. are found worldwide and are capable of infecting a variety of birds. Each species appears to have a limited host range but they are not particularly host-specific and generally cause only mild or inapparent clinical symptoms. Diagnosis is based on identification of typical pigment containing gamonts in erythrocytes. For most species of *Haemoproteus* the intermediate hosts are hippoboscid flies, biting midges (*Culicoides* spp.) or tabanids.

Passerine species in which *Haemoproteus* spp. have been reported are numerous and include mynahs, Fringillid finches, swallows, fly catchers, tits, sparrows, weaver finches, warblers and thrushes. In one outbreak, canaries were believed to have been infected following exposure to free-ranging house sparrows.<sup>38,43,57</sup>

Schizonts have a predilection for development in skeletal and cardiac muscle, lung and spleen. One form of schizont is sausage-shaped and often branches during development within capillary endothelium. Megalochizonts may develop in the absence of circulating gamonts and reach sizes of up to 200  $\mu$ m. Extensive myopathy and myonecrosis may be associated with intramuscular megalochizonts (eg, commonly seen in free-ranging infected Pied Currawong around Sydney, Australia). These birds show multiple, yellow streaks in pectoral and other muscles, and most are presented thin, weak and unable to fly.<sup>57</sup> Treatment with antimalarial drugs

(chloroquine at 250 mg/120 ml drinking water for one to two weeks) may be useful. Orange juice may be added to the drinking water to make the drug more palatable.<sup>71</sup>

### **Leucocytozoon**

*Leucocytozoon* spp. occur worldwide except for South America (where appropriate simuliid vectors are absent). These parasites may infect either erythrocytes or leukocytes. Parasitized cells are so distorted by the organism that it may be difficult to determine their origin. Pigment is not produced by leucocytozoon and schizonts do not appear in peripheral blood. Megaloshizonts can be found in brain, liver, lung, kidney, intestinal tissue and lymphoid tissue.

Most leucocytozoon infections are subclinical, although vague signs of illness and death were reported in infected Crested Oropendolas from a zoo in Florida. These birds hemorrhaged from protozoal cysts within hepatic and renal tissue. It was thought that the leucocytozoon may have been transmitted from free-flying black flies infected by feeding on local leucocytozoon-infected crows. The oropendolas, which had been trapped in South America, may have been particularly susceptible because of lack of previous exposure to the parasite.<sup>52</sup>

Leucocytozoon-like megaloschizonts have also been described in association with acute and fatal hepatocellular necrosis in canaries in Texas. Outbreaks of the disease were controlled with dimetridazole.<sup>55</sup>

Some other passerine species that have been reported to harbor *Leucocytozoon* spp. include Fringillid finches, swallows, tits, warblers, thrushes, starlings, blackbirds, canaries and lyrebirds.<sup>38,43,57</sup>

### **Trypanosoma**

Trypanosomes are found worldwide but their incidence is low and they may only be found during summer months in temperate climates. Vectors are thought to include hippoboscids flies (*Ornithomyia avicularia*), red mites (*Dermanyssus gallinae*), simuliids and mosquitoes. Evidence suggests that the parasites may be transmitted by contamination rather than inoculative routes. Diagnosis is by finding the parasites on stained blood smears.<sup>38</sup> High prevalence levels of this parasite (8.3%) have been reported along the coast of the Baltic Sea in Europe.<sup>72</sup> Treatment is not warranted.

Trypanosomes have been identified in over 14 passerine families, including Fringillid finches and canaries, swallows, tits and pipits.<sup>38,43</sup>

### **Avian Piroplasmosis**

Piroplasmosis is an important tick-borne infection that has been identified in many species of birds in the Mediterranean, Asia and Africa but it has not yet been found in Australia. *Aegyptianella* sp. is a rickettsial organism that appears as a small, signet ring-shaped structure in the cytoplasm of infected erythrocytes. Clinical signs of infection may include anemia, fever, lethargy and occasionally jaundice. Some passerine species in which piroplasmosis has been identified include crows, rooks, larks, sparrows and buntings.<sup>38</sup> Treatment with doxycycline or antimalarial drugs may be useful.

### **Filarial Worms**

Microfilaria and adult filarial nematodes (*Serratospiculum amaculata* and *Diplotrriaena* sp.) have been reported at a low prevalence in a variety of species of passerines such as lyrebirds, Estrilid finches, honeyeaters, thrushes, grackles, sparrows and corvids. Most infections have not been associated with any disease and the parasites have been found incidentally in blood smears (microfilaria) or at necropsy (adults). *Splendidofilaria passerina* may be pathogenic in sparrows. Treatment is not generally warranted but levamisole may be useful.<sup>38,43,57</sup>

## **Internal Parasites**

### **Acanthocephalans**

Both adult and intermediate stages of acanthocephalan parasites may be found in free-ranging passerines. Adult worms are generally susceptible to benzimidazole anthelmintics. Genera affecting passerines include *Polymorphous*, *Plagiorhynchus*, *Prosthorhynchus* and *Centrorhynchus*.

The Superb Lyrebird, the largest passerine species, is a ground-dwelling inhabitant of rain forests in southeastern Australia. The acanthocephalan parasite *Plagiorhynchus menurae* has been identified in lyrebirds showing weakness, emaciation and respiratory distress. Duodenal necrosis has been demonstrated at necropsy. Invertebrates are postulated to be the intermediate hosts.<sup>48,50</sup>

Small cysts, 2 to 3 mm long and shaped like rice grains, may sometimes be found in the subcutaneous tissues of the neck and thorax in a wide variety of Australian passerine birds. These cysts are intermediate stages of the acanthocephalan *Oncicola pomatostomi*, the adult stages of which are found in the intestines of dingos and feral cats. The initial host is postulated to be scavenging insects.<sup>50</sup>

### Cestodes

Because tapeworms require arthropods as intermediate hosts, they are predominately a problem in soft-bill and insectivorous finches. They are normally not seen in canaries or exclusively seed-eating birds (such as Gouldian Finches), except in situations where parent birds feed insects to their offspring or the insects are accidentally consumed with the seeds.

Many different tapeworms have been described in passerines but in most cases, infectivity levels are low, and the parasites cause no clinical disease. Emaciation, diarrhea, general debilitation and death may occur in birds that are stressed and are continuously exposed to infected intermediate hosts. Proglottids or hexacanth larvae may be noted on gross or microscopic examination of droppings, but these are passed only intermittently. Certain finch species, eg, parrot finches and Diamond Firetails, are particularly prone to developing intestinal obstructions from heavy *Choanotaenia* sp. infections. These high levels of infectivity are common in densely planted aviaries with compost heaps or other sources of infected intermediate hosts.

Tapeworms can be avoided by limiting access to intermediate hosts and by using insect-proof screening. Other sources of protein (such as commercially available formulated diets, insectivore mixes, egg food or grated cheese) may replace live invertebrates as food items. However, some birds may not accept these alternative foods and may die or be left susceptible to disease because of poor nutrition. Others will be reluctant to breed without live food or may desert their nestlings.

Effective anthelmintics for passerines include praziquantel and oxfendazole. In cases where it is not appropriate to prevent access to intermediate hosts, a regular deworming program will lower the infection rate.<sup>18</sup>

### Trematodes

These parasites have complicated life cycles that typically involve snails as initial intermediate hosts and other invertebrates as secondary intermediate hosts. It is unlikely that appropriate conditions for completion of the life cycle will be found, except possibly in planted aviaries.

Trematodes are seen occasionally in wild-caught passerines.<sup>38,50</sup> *Collyriculum* sp. may be found encysted in the skin of birds. *C. faba* forms 4 to 6 mm cysts on passerine birds such as sparrows and starlings, as

well as gallinaceous birds. These cysts have been reported to cause death in wood thrushes by obstructing the cloaca.

Schistosomes are trematodes that live in blood vessels. *Gigantobilharzia huronensis* is a blood fluke that has been reported in North American goldfinches and cardinals. It has also been experimentally transmitted to canaries.

*Prosthogonimus* sp. are trematodes affecting the intestinal tract, cloaca, bursa or oviduct. These parasites have been found worldwide in passerine species such as sparrows, corvids, starlings and thornbills.<sup>38</sup> They are not particularly pathogenic, and if clinical signs occur they are generally nonspecific. Dragonflies and snails are intermediate hosts. Praziquantel may be useful in treating trematodes.

### Nematodes

- **Ascaridia:** Two main types of roundworms affect passerines: *Ascaridia* spp., which have direct life cycles, and *Porrocecum* spp., which have indirect life cycles with invertebrates such as earthworms as the intermediate host. Both types of roundworms may be associated with weight loss, diarrhea, general debility and sometimes neurologic symptoms. *Ascaridia* spp. are uncommon in passerines.

*Porrocecum* spp. have been found in a variety of free-ranging passerines, for example pipits, quail-thrush, thrush, blackbirds, Australian magpies, currawongs and corvids. Fibrous tumors, believed to have been induced by larval *Porrocecum* spp. have been described in blackbirds on the peritoneal surface of the intestine.<sup>38,50</sup> Fenbendazole, piperazine and levamisole are useful in treating ascarid infections.

- **Capillaria:** *Capillaria* spp. are cosmopolitan in their distribution and affect a range of passerine species. The life cycle is direct or may involve earthworms as paratenic hosts. Susceptibility does not depend on dietary preferences, and the parasite has been found to cause disease in a variety of seed-eaters (such as canaries), insectivorous and omnivorous species (such as weavers, whydahs, jays and mynahs) and honeyeaters.

Birds with low numbers of capillaria may be subclinical. Higher parasite loads may lead to weight loss, diarrhea, general ill health and death. These worms may localize to a variety of sites along the gastrointestinal tract. They may be associated with white or cream plaques in the buccal cavity or pharynx and swelling and lumen distension of the crop, proven-

trculus, intestine or bowel. Typical bi-polar plugs may be found by directly swabbing lesions or by fecal flotation.

Capillaria are often more difficult to treat than ascarids. Aviary hygiene and removal of earthworms are important control measures. Levamisole, fenbendazole and oxfendazole may be effective in some cases.

- **Spiruroid:** *Acuaria skrjabini* has been associated with significant mortalities in Australian aviaries housing both native and imported finches. This ventricular and proventricular worm parasite does not affect psittacine birds. The parasite lives under the koilin lining of the ventriculus, and characteristic embryonated eggs are passed in the feces. Attempts to identify intermediate hosts in this species have been unsuccessful, but other species of *Acuaria* are believed to be transmitted by arthropod vectors. The parasite is resistant to treatment with many common anthelmintics, but oxfendazole may be effective.

*Acuaria* spp. have been reported in a variety of free-ranging passerines in Australia, eg, bushlarks, trillers, thrush, flycatchers, whistlers, shrike-thrush, honeyeaters, Australian magpies, currawongs and corvids.<sup>50</sup>

Other spiruroid worms that occur worldwide and may be found in the proventriculus or ventriculus of passerine species include *Dispharnyx nasuata* (which has been described in the House Sparrow, starling, catbird and gallinaceous birds) and *Spiroptera incerta*. These worms have been reported to cause swelling of the proventricular mucosa and may inhibit the passage of food.<sup>74</sup>

- **Eye Nematodes:** *Oxyuris masoni* has been reported in mynahs, sparrows and other passerines. The parasite is found behind the nictitating membrane or in the conjunctival sac or the nasolacrimal duct. The intermediate host is the cockroach. Worms should be mechanically removed and any inflammation treated symptomatically. Ivermectin is effective.<sup>36</sup>
- **Respiratory Nematodes:** *Syngamus trachea* (gape-worm) affects a range of passerine species as well as birds from other orders. Corvids, starlings and blackbirds are particularly susceptible. Earthworms may act as transport hosts. Levamisole, ivermectin and fenbendazole are effective in treating this parasite, but caution should be exercised when treating birds with heavy infections. Tracheal obstruction may oc-

cur when the parasites are killed. Mechanical removal of worms and treatment with low doses of anthelmintics over several days is an effective therapeutic plan.

### Arthropod Parasites

- **Respiratory Mites:** Respiratory acariasis ("air sac mite infection") caused by *Sternostoma tracheacolum* is a common cause of dyspnea, open-mouthed breathing and wheezing respiration in canaries and Gouldian Finches. "Air sac mites" is a misnomer given that these parasites are frequently found in the trachea, particularly near the syrinx. Occasionally, the mites may be visualized by wetting the feathers of the bird's neck with alcohol and transilluminating the trachea with a bright source of light. If mites are present, they may be visible as tiny, dark, moving, pinhead-sized spots. Failure to see the mites does not rule out their occurrence because the mites may be present lower in the respiratory tract.

There are several options for treating this mite. Ivermectin may be used orally or topically. A dichlorvos pest strip may be placed (according to manufacturer's directions) near but out of reach of the birds. Birds may also be sprayed with pyrethrin synergized with piperonyl-butoxide insecticide spray.

Other species of passerines apart from canaries and Gouldian Finches may harbor *S. tracheacolum*, but they are less frequently affected and less likely to show severe clinical symptoms. Other species of *Sternostoma* mites have been recorded in passerines including *S. sialiphilus* in Eastern Bluebirds, *S. spatulatum* in Olive-backed Thrush and *S. cryptohyncheum* in sparrows. A nasal rhynonyssid mite *Speleognathus sturni*, which occasionally causes nasal discharge, has been recorded in starlings.

*Cytodites nudus* is another mite that has been associated with respiratory disease in free-ranging passerines. It is much less common than *Sternostoma* sp. and may be found in the abdominal cavity as well as the respiratory system. Heavy infections have been associated with granulomatous pneumonia, peritonitis and obstruction of the respiratory passages.<sup>38</sup> Treatment is as described for other air sac mites.

### External Parasites

#### Skin and Feather Mites

- **Scaly Mites:** *Knemidokoptes pilae* (and several other less common species) tend to cause hyperkeratotic lesions on the feet in passerines. This is in contrast

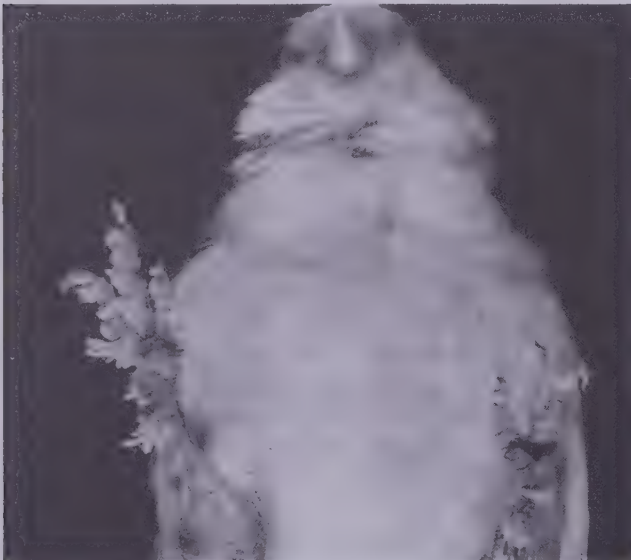
to infections in psittacine birds, which are primarily associated with beak lesions. Hyperkeratosis caused by scaly mite needs to be differentiated from generalized hyperkeratosis of the feet and legs that occurs with malnutrition and age in some canaries and other passerines (see Color 24). Scaly mite lesions start as crusts on the plantar surface of the foot and gradually get thicker. Flexion of the joints of the digits causes the thickening keratin to split and gradually enlarge, making it difficult for the bird to perch. Scaly mite lesions in passerines are sometimes referred to as “tassel foot” because of this characteristic appearance (Figure 43.14). European goldfinches and canaries are particularly susceptible to *Knemidokoptes* spp. but the condition has been reported in a wide range of Passeriformes (Figure 43.15).

*Knemidokoptes* spp. may be treated with topical ivermectin. A single dose may be effective in mild cases. A repeat dose three weeks later may be needed in more severe cases.

- **Feather Mites:** *Dermanyssus* sp. (red mites) and *Ornithonyssus* sp. (fowl mites) are not host-specific and may be found on a variety of Passeriformes including canaries, starlings and mynahs. These mites commonly cause irritation and anemia. Deaths have been reported with heavy infections in small birds. Non-pathogenic feather mites of a variety of genera (*Analgas*, *Megninia* and *Rivoltasia*) may also occur. Lightly dusting birds with pyrethrin or carbaryl pow-

ders may be effective. Placing the powder in a salt shaker and “lightly salting” is sufficient.

- **Quill mites** are not particularly species-specific and may attack both passerine and non-passerine species. *Dermoglyphus*, *Syringophilus*, *Picobia* and *Harpyhynchus* are genera that have been reported on Passeriformes. *Harpyhynchus* sp. has been associated with extensive dermatitis as well as cysts and skin tumors on hawfinches and a Lanceolate Warbler. Hanging a dichlorvos pest strip near birds affected with quill mites has eliminated the parasite in some cases. Treating the bird with ivermectin should be effective.
- **Epidermoptie Mites**, which may be carried mechanically by hippoboscid flies, cause a depluming dermatitis followed by scale formation (Figure 43.16). *Myialges* sp. (from a Blue Tit and Pekin Robin),



**FIG 43.14** A mature female canary was presented with a three-week history of anorexia and lying on the bottom of the enclosure. The proliferative hyperkeratotic lesions on this canary's foot are characteristic for a *Knemidokoptes* sp. infection (“tassel foot”) (courtesy of Terry Campbell).



**FIG 43.15** A group of several hundred robins died following the ingestion of pesticide-contaminated worms. Several of the birds had hyperkeratotic lesions on the feet and legs. These were confirmed to be caused by *Knemidokoptes* sp. by demonstrating the mite on skin scrapings.




*Epidermotes bilobatus* (from canaries) and *Microlichus avus* (from canaries, House Sparrows and mynahs) have been described in Passeriformes. Epidermoptic mites may be easily identified on microscopic examination of skin scrapings. Trombidiform mites of the genus *Neochelytiella* have also been reported to cause depilating mange in canaries and Pekin Robins. Treatment options are like those described for quill mites.<sup>38</sup>

### Lice

Lice are more common on Passeriformes than they are on Psittaciformes. Some of the genera of biting lice (*Amblycera*) that occur on passerines include *Colpocephalum*, *Menacanthus*, *Machaerilaemus*, *Mysidea* and *Rininus*. These lice are not specialized for life on particular feathers and are able to move quickly. Chewing lice (*Ischnocera*) are often specifically adapted to a particular part of the bird's body and are generally more sluggish than biting lice. Some genera that affect passerines include *Bruelia* (on canaries and House Sparrows), *Sturnidoecus* (on starlings and other passerines), *Degeeriella* and *Philoapterus*. Signs of the presence of lice include restlessness and biting, excessive preening and damage to plumage. Some cases of baldness in canaries are caused by lice.

Lice undergo a complete life cycle on the bird, and a weekly dusting with pyrethrin is an effective method of control.



**FIG 43.16** A number of external parasites including quill mites, epidermoptic mites and lice can cause skin irritation, pruritus and plumage damage.

## Metabolic Diseases

### Iron Storage Disease and Related Entities

Various Passeriformes species including Indian Hill Mynahs, Rothschild's Mynahs, quetzals, Birds of Paradise, Green Cat Birds and tanagers have been reported to be susceptible to excessive accumulation of iron in the liver.<sup>28,30,59</sup> In a group of 11 mynah birds that varied from five to ten years in age, clinical signs associated with hepatomegaly and ascites included a three-day to three-month history of listlessness, regurgitation, dyspnea, weight loss, diarrhea, coughing, wheezing and syncope. Most of the birds died within several days of presentation.<sup>59</sup>

Radiographs may reveal hepatic enlargement and ascites in affected birds. Liver enzymes are typically elevated while total serum protein is low. Diagnosis using biopsy is discussed in Chapters 13 and 20.

At necropsy birds may show an enlarged, congested liver which may be tan in color (see Color 20). Histologically the distinction is made between hemosiderosis, where there is no visible tissue alteration but an increased amount of hemosiderin, and hemochromatosis, where there are pathologic changes in the hemosiderin-containing tissues. Hepatic pathology may include congestion, focal necrosis, accumulation of inflammatory cells and fibrosis. Iron-processing cells are absent from the spleen and the spleen does not contain iron pigments.<sup>28,30,34</sup>

Neoplasia including lymphosarcoma, hepatocellular carcinoma and erythroblastosis has been associated with iron storage disease. The neoplastic cells do not contain iron.

Iron storage disease is believed to be associated with high dietary iron levels in avian species with problems in processing iron. Susceptible species should be kept on low-iron diets such as fresh fruit and commercially available formulated rations that are low in iron (less than 60 parts per million) (see Chapter 20).

### Amyloidosis

Amyloidosis is common in Gouldian Finches and is occasionally seen in other Passeriformes species.<sup>39</sup> Affected birds may be found dead, have a chronic nonspecific history of illness or suffer from concurrent infections (polyomavirus, cryptosporidio-

sis). Social stress may play a role in the development of the disease. The liver and kidneys may appear normal at necropsy even though they may be severely affected histologically. More often they will appear pale and yellowish. A hereditary predisposition is suspected.<sup>18,46</sup>

### Hepatic Lipidosis

Fatty livers are occasionally seen in Estrilid finches (Zebra Finches, parrot finches and Star Finches) and may be associated with inadequate exercise and high-energy diets such as soft foods and mealworms. The liver is swollen, yellow or tan in color and may float in formalin.<sup>18</sup> The use of some formulated diets may help resolve or prevent hepatic lipidosis.

### ■ Toxicosis

Canaries and finches are particularly susceptible to inhalant toxins because they breathe more air per gram of body weight than larger birds, and they have a highly efficient gas exchange system (see Chapter 22). Carbon monoxide exposure from any source (car exhaust, gas furnace leaks, kerosene stoves) can be rapidly fatal. There may be minimal changes at necropsy or the lungs and blood may appear bright red. Carbon dioxide poisoning may occur in crowded, poorly ventilated shipping boxes. Passerines, like psittacines, are very susceptible to the gases released from overheated polytetrafluoroethylene<sup>65</sup> (see Chapter 37).

Certain varieties of avocado may be toxic to some Passeriformes. Postmortem findings in intoxicated birds include hydropericardium and subcutaneous edema in the pectoral area.<sup>32</sup> Deaths have occurred in American Goldfinches after consuming green almonds, presumably from cyanide released by hydrolysis of amygdalin, a cyanogenic glycoside.

Ethanol toxicity has been reported in free-ranging passerines (especially Cedar Waxwings) following the ingestion of hawthorn pomes or other fruits that have frozen and then thawed allowing yeast fermentation of sugars to produce ethanol. Birds are lethargic, ataxic or may be in a stupor ("drunk"). Many intoxicated birds die from accidents that occur while they are "flying under the influence." Diagnosis is based on analyzing crop contents for ethanol concentrations.<sup>19</sup>

Heavy metal toxicities caused by the consumption of wire are uncommon in passerines because they have limited capacity to damage metal objects. Lead or zinc toxicosis has occasionally been seen when galvanized wire has been used in the construction or repair of enclosures. Heavy metal particles may be identified on radiographs, but most affected birds die quickly. Removing the source of heavy metals and administration of chelation therapy are recommended. The occurrence of "new wire disease" can be reduced by scrubbing galvanized wire with a dilute acetic acid solution and allowing it to weather before it is used for enclosure construction; however, even wire that is washed may still be toxic (see Chapter 37).

### ■ Neoplastic Diseases

Passeriformes have one of the lowest incidence of tumors of any order of birds or mammals. Neoplasms that have been regularly reported include leukosis in canaries, adenomas associated with poxvirus, papillomas in finches and neoplasia associated with iron storage disease.

#### ■ Products Mentioned in the Text

- a. Vira-A, Parke Davis, Morris Plains, NJ
- b. PEP-E, Phylomed, Plantation, FL
- c. Biomune, Inc, Lenexa, KS

## References and Suggested Reading

- Bauk L: Lymphosarcoma/avian leukosis in pet birds: Case reports. *Proc Assoc Avian Vet*, 1986, pp 241-245.
- Bauk L: Radical surgery for the treatment of feather cysts in the canary. *J Assoc Avian Vet* 1(5):200-201, 1987.
- Bauk L: Diseases of the finch as seen in a commercial import station. *Proc Assoc Avian Vet*, 1989, p 196-201.
- Bennett GF, et al: Blood parasites of some birds from the Lorraine Region, France. *J Wildl Dis* 18:81-88, 1982.
- Birkhead TR, Pellatt JE: Vasectomy in small passerine birds. *Vet Rec* 125:646, 1989.
- Blagburn BL, et al: *Cryptosporidium* sp. infection in the proventriculus of an Australian diamond firetail finch (*Staganopleura bella*: Passeriformes, Estrilidae) *Avian Dis* 34:1027-1039, 1990.
- Box ED: Recovery of *Sarcocystis* sporocysts from feces after oral administration. *Proc Helminth Soc Washington* 50:2, 1983.
- Buckley PA: Plumage and pigmentation. In Petrak ML (ed): *Diseases of Cage and Aviary Birds* 2nd ed, 1982, pp 59-74.
- Campbell TW: Infraorbital sinus aspiration. *Assoc Avian Vet Newsletter* 4:38, 1983.
- Christadis I, Schodde R: Relationships of Australo-Papuan songbirds: Protein evidence. *Ibis* 133:277-285, 1991.
- Davis AJ, et al: Morphology of cytoplasmic neuronal inclusions in canaries with poxvirus infection. *Proc 37th West Poult Dis Conf*, 1983, pp 108-109.
- Desmidt M, et al: Cytomegalovirus-like conjunctivitis in Australian finches. *J Assoc Avian Vet* 5(3):132-136, 1991.
- Devriese LA, et al: Tracheitis due to *Enterococcus faecalis* infection in canaries. *J Assoc Avian Vet* 4(2):113-116, 1990.
- Dhillon AS, et al: Toxoplasmosis in mynahs. *Avian Dis* 26(2):445-449, 1982.
- Dorrestein GM, et al: Disease of passerines, especially canaries and finches. *Proc Assoc Avian Vet*, 1985, pp 53-70.
- Dustin LR: Clinical conditions in a pet canary practice. *J Assoc Avian Vet* 4(2):80-82, 1990.
- Fain-Binda JC, et al: Canaries: Systemic candidosis. *Veterinaria Argentina* 2:186-189, 1985.
- Filippich LJ: Diseases of finches. *Proc 178 Post Grad Comm Vet Sci, Univ Sydney*, 1991, pp 357-381.
- Fitzgerald, et al: Suspected ethanol toxicosis in two wild cedar waxwings. *Avian Dis* 34:488-490, 1990.
- Flammer K: Clinical aspects of toxoplasmosis in canaries. *Proc Assoc Avian Vet*, 1987, pp 33-35.
- Flammer K: Bacterial diseases of caged birds. *Proc 178 Post Grad Comm Vet Sci, Univ Sydney*, 1991, pp 149-154.
- Forshaw D, et al: Infection with a virus resembling papovavirus in gouldian finches (*Erythrura gouldiae*). *Aust Vet J* 65:26-28, 1988.
- Fowler A: Avian malaria in sparrows at Taronga Zoo. *Proc Wildl Dis Assoc (Aust Branch), Warrumbungles National Park, (supplementary pages)* 1992.
- Gardiner CH, lmes GD: *Cryptosporidium* sp. in the kidney of a black-throated finch. *J Am Vet Med Assoc* 185(11):1401-1402, 1984.
- Gaskin, JM: Mycoplasmosis of caged birds. *Proc Assoc Avian Vet*, 1987, pp 57-60.
- Gerlach H: Virus diseases in pet birds. *Vet Clin No Am* 14(2):299-315, 1984.
- Gerlach H: Bacterial diseases. In Harrison GJ, Harrison LR (eds): *Clinical Avian Medicine and Surgery*. Philadelphia, WB Saunders Co, 1986.
- Gerlach H: The so-called iron storage disease in mynahs. *Proc 1st Intl Conf Zool & Avian Med, Hawaii*, 1987, pp 79-86.
- Glander G, Siegmund O: Occurrence of *Aeromonas hydrophila* in wild birds. *Avian Pathol* 18:685-695, 1989.
- Gasselini SJ, Kramer LW: Pathophysiology of excessive iron storage in mynah birds. *J Am Vet Med Assoc* 183(11):1238-1240, 1983.
- Greenham LW, et al: *Clostridium perfringens* in pelleted food. *Vet Rec* 120:23, 557, 1987.
- Hargis AM, et al: Avocado (*Persea americana*) intoxication in caged birds. *J Am Vet Med Assoc* 194(1):64-66, 1989.
- Harrigan K: Bird parasitism. *Post Grad Comm Vet Sci, Univ Sydney*, 1981, pp 337-396.
- Hill JE, et al: Hepathology and lymphosarcoma in a mynah bird with excessive iron storage. *Avian Dis* 30(3):634-636, 1986.
- Immelmann K: The influence of early experience upon the development of social behaviour in estrildine finches. *Proc XVth Intl Ornith Cong*, 1972, pp 316-338.
- Karpinski LG: Ophthalmology. In Harrison GJ, Harrison LR (eds): *Clinical Avian Medicine and Surgery*. Philadelphia, WB Saunders, 1986, pp 278-281.
- Karpinski LG, Clubb S: An outbreak of avian pox in imported mynahs. *Proc Assoc Avian Vet*, 1986, pp 35-37.
- Keymer: Parasitic diseases. In Petrak ML (eds): *Diseases of Cage and Aviary Birds* 2nd ed. Philadelphia, Lea & Febiger, 1982, pp 535-598.
- Janovski MD: Disseminated aspergillosis in a mynah bird. *J Am Vet Med Assoc* 149:944-949.
- Johnson BJ, Castro AE: Canary pox causing high mortality in an aviary. *J Am Vet Med Assoc* 189(10):1345-1347, 1986.
- Johnson KM, Riddell C: Intracellular inclusion bodies in finches. *Can Vet J* 27:432-434, 1986.
- Lina PH, et al: Detection of virus in squamous papillomas of the wild bird species *Fringilla coelebs* (chaffinch). *J Natl Cancer Inst* 50:567-571, 1973.
- Mackerras MJ, Mackerras IM: Haematocytosis in Australian birds. *Aust J Zool* 8(2):226-265, 1960.
- Macwhirter PJ: Avian practice in Australia. *Proc Assoc Avian Vet*, 1989, pp 46-56.
- Maich R, et al: Viral papillomatosis in canaries. *Pet's Ciecia* 4:(23)352-357, 5107 AGua de Oro, Cordoba, Argentina, 1988.
- Marshall R: Papova-like virus in a finch aviary. *Proc Assoc Avian Vet*, 1989, pp 203-207.
- McOrist S: Mortality in the canary in Australia. *AAV Newsletter* 5(4):97, 1984.
- McOrist S, Scott PC: Parasitic enteritis in superb lyrebirds (*Menura novae-hollandiae*). *J Wildl Dis* 25(3):420-421, 1989.
- Mitchell G, et al: Mucormycosis in canaries (*Serinus canarius*) fed damp germinated seed. *Vet Pathol* 23:625-627, 1986.
- Mawson PM, et al: A checklist of helminths from Australian birds. *Rec S Aust Mus* 19(15):219-325, 1986.
- Osterhaus AD, et al: Identification and characterization of papillomavirus from birds (Fringillidae). *Intervirology* 8:351-359, 1977.
- Page DC, et al: Leucocytozoosis in crested oropendolas (*Psarocolius decumanus*). *J Assoc Avian Vet* 1(4):155-157, 1987.
- Pal M: *Cryptococcus neoformans var neoformans* and *munia* birds. *Mycoses* 32:250-252, 1989.
- Panigrahy B, Gilmore WC: Systemic salmonellosis in an African gray parrot and salmonella osteomyelitis in canaries. *J Am Vet Med Assoc* 183:699-700, 1983.
- Panigrahy B, et al: Hemorrhagic disease in canaries (*Serinus canarius*). *Avian Dis* 28:536-541, 1984.
- Perrins CM: *Intl Coun Preser Birds, The Illustrated Encyclopaedia of Birds*, Headline, 1990.
- Perry RA: Rehabilitation of Birds. *Proc 104 Post Grad Comm Vet Sci, Univ Sydney, Australian Wildlife*, 1988, pp 115-209.
- Perry RA: Skin, beak, claw and feather disorders. In Macwhirter P (ed): *Everybird, a Guide to Bird Health*. 1987, pp 98-121.
- Randall MG, et al: Hepatopathy associated with excessive iron storage in mynah birds. *J Am Vet Med Assoc* 179:1214-1217, 1981.
- Reece RL: Hepatic coccidiosis (*Eimeria* sp) in a wild magpie-lark (*Grallina cyanoleuca*). *Avian Pathol* 18:357-362.
- Reece RL, et al: Some unusual diseases of birds in Victoria, Australia. *Vet Rec* 130:178-185, 1992.
- Reinhard GR, et al: Subcutaneous salmonella granulomas in canaries. *Lab An Sci* 38:505, 1988.
- Roskopf WJ, et al: Pet avian conditions and syndromes. *Proc Assoc Avian Vet*, 1986, pp 377-400.
- Rotz A, et al: A fatal herpesvirus infection in gouldian finches (*Choebia gouldiae*). *Schweizer Archiv fur Tierheilkunde* 126:651-658, 1984.
- Sakas P: Call for information on polytetrafluoroethylene toxicity. *Assoc Avian Vet Newsletter* 6(4):102, 1985.
- Scanes CG: Pituitary gland. In Sturkie PD (ed): *Avian Physiology* 4th ed. New York, Springer-Verlag, 1986.
- Slatter DH, et al: Hereditary cataracts in canaries. *J Am Vet Med Assoc* 183(8):872-874, 1983.
- Todd KS, Hammond DM: Coccidia of Anseriformes, Galliformes and Passeriformes. In Davis JW (ed): *Infectious and Parasitic Diseases of Wild Birds*. Ames, Iowa State University Press, 1971, pp 185-233.
- van der Hage M: A bacterial proventriculitis in canaries (*Serinus canarius*). *Avian Pathol* 13(3):561-572, 1984.
- van der Hage M: Finches with disturbance of the digestive tract. *J Assoc Avian Vet* 4(2):83, 1990.
- Vogelnest I: *Avian Clinical Pathology*. 1. Hematology and Biochemistry. *Post Grad Comm Vet Sci, Proc 178, Avian Medicine*, 1991, pp 243-313.
- Val'kyunas GA: Some characteristics of infections with blood protozoa in passerine birds. *Lietuvos-TSR-Mokslu-Akademijos-Darbai.-C-Serjaj.-Biologijos-Mokslai* 3:88-96, 1987.
- Van Ripper C: Discovery of *Atoplasma* in Hawaii. *J Parasitol* 73(5):1071-1073, 1987.
- Wehr EE: Nematodes. In Davis JW (ed): *Infectious and Parasitic Diseases of Wild Birds*. Ames, Iowa State University Press, 1971, pp 185-233.
- Woods LW: Papova-like virus in a painted finch. *Proc Assoc Avian Vet*, 1989, pp 218-219.
- Worell A: Phlebotomy for treatment of hemochromatosis in two sulfur-breasted toucans. *Proc Assoc Avian Vet*, 1991, pp 9-14.

CHAPTER

---

# 44

## COLUMBIFORMES

---

■  
Curt Vogel  
Helga Gerlach  
Mait Löffler

**C**olumbiformes are among the most ancient domesticated animals in the world. They were initially used as utility birds (meat, fertilizer and feather products), were later used for sport and as carriers of information, and more recently, as laboratory animals. The history of the domesticated pigeon starts in the early Stone Age, approximately 10,000 to 2,000 years B.C.<sup>17</sup> Pigeons can be termed cosmopolitan birds because, with the exception of the northern and southern polar regions, they occur on all continents and in all the countries of the world. More than half the species are native to Asia and Australia; the second highest number of species is found in the tropics of the Americas.<sup>36</sup>

Of special interest and importance is the Rock Pigeon, from which a whole variety of domestic breeds and color variations have been developed via mutations and recombinations throughout the millennia. Worldwide, millions of pigeon fanciers breed or keep more than 800 varieties of the domesticated pigeon, although the number of breeders of wild-type or nondomesticated pigeons and doves is still rather small.<sup>16</sup> Pigeon breeding is considered a hobby and, as such, provides pleasure and an interesting combination of genetics, behavior, physiology and endocrinology.

## Zoologic Taxonomy

The order Columbiformes consists of 8 families, 67 genera and 296 living as well as 11 extinct species (including 3 species of the genus *Dodo*). The Passenger Pigeon, which populated the North American continent, became extinct in the last century. Other dove and pigeon species, particularly populations on small islands, are in danger of extinction.<sup>1,36</sup>

### Domesticated Pigeons

#### Distinctive Pigeon Groups

The species Rock Pigeon is divided into 14 subspecies and is the original genetic stock for domesticated

pigeons and for domesticated pigeons that have returned to the wild. These are called city or street pigeons or incorrectly, feral pigeons, and are considered a special variety. The number of these city or street pigeons worldwide is estimated at approximately 500 million. The so-called Field Pigeon, a direct progeny of the Rock Pigeon, became accustomed to humans during the sixth and fifth millennium B.C.<sup>21</sup>

There are at least 800 varieties of the domesticated pigeon globally. These can be systematically differentiated from the Rock Pigeon by body morphology, size and weight; deviations of the skeleton, musculature beak and cere; coloration and design of the plumage (in particular feather structure) and feather morphology; and breed-specific behavior.<sup>33</sup> Nine groups of domesticated pigeons have been distinguished (Table 44.1).<sup>33</sup>

#### Families of Columbiformes<sup>36</sup>

<b>Caloenadidae</b>	The Nicobar Pigeon is a large 38 to 40 cm bird that develops a mane (long, thin body contour feathers around the neck) and a short white tail. The color of the plumage is mainly a dark, coppery-shimmering green, which shows blue and black at the head and the upper breast. Nicobar Pigeons have a strong beak with small wart-like protuberances at the base. The beak is used to burrow into soil to forage for seeds and fruits. This species needs frost-free shelters for the winter.
<b>Gouridae</b>	The Blue-crowned Pigeon is a large 76 cm bird that may weigh more than 1 kg. A large, light-blue crest is characteristic. There are several subspecies, which show differences in coloration and in size. The beak of the male has a prominent hook, while that of the female is straight.
<b>Otidiphabidae</b>	The Pheasant Pigeon is a 38 to 40 cm pigeon with a relatively large tail. The bird's gait and colorful plumage are similar to those of pheasants. This tropical bird requires a warm environment.
<b>Columbidae</b>	These are true pigeons with 47 genera and 173 species. This is the largest group of pigeons and contains the best flyers. They may consume small seeds or large grains, depending on their body size, which ranges from 12.5 to 40 cm.
<b>Duculidae</b>	"Fruit-eating" pigeons range from 20 to 47 cm in size, live exclusively in trees, and appear awkward when ambulating on the ground.
<b>Treronidae</b>	Green Pigeons are 25 to 40 cm birds that are indigenous to high altitudes (2,500 m) where they inhabit trees in light woods and are occasionally found on the ground.
<b>Didunculidae</b>	Tooth-billed Pigeon

**TABLE 44.1** Nine Distinguishing Characteristics of Groups of Domesticated Pigeons

- Colored pigeons, eg, German toys (These birds are selectively bred for coloration and plumage morphology.)
- Medium-sized varieties (with a body mass of up to 500 to 700 g)
- Heavy-sized varieties (with a body length of up to 55 cm, a wing spread of up to 105 cm, and body weight of over 700 g)
- Trumpeters (with their characteristic vocal expressions)
- Frillbacks, Fantails, Jacobins and Monks, Owls, Dewlaps and Swifts (each with a particular feather structure and design)
- Tumblers (These birds are considered flight sports breeds and represent the largest group with several hundred varieties worldwide.)
- Wattled Pigeons (They have a characteristic bulged, distended or wart-like cere, as well as more or less prominently developed naked or wart-like rings around the eyes.)
- Pouters (including the ringbeaters) with a singularly developed round, egg-shaped, pear-shaped or sac-like crop area, which varies according to the breed.
- Hen Pigeons (with their fowl-like body morphology and body posture.)

#### Pigeon Fanciers

There are several groups of pigeon fanciers whose interests and objectives differ.<sup>33</sup> In decreasing number of enthusiasts, these groups include: 1) the racing pigeon fanciers; 2) breeders of fancy pigeons for exhibition; 3) tumbler pigeons (high flyers, sustained flyers, flying tipplers, purzelers and rollers); 4) producers of meat pigeons (may be raised for individual consumption or as part of a large breeding facility) and breeders of wild pigeon and dove species.

Forty-two countries belong to the International Racing Pigeon Association (Fédération Colombophile International - FCI). There are almost 590,000 members and more than 20 million leg band registrations annually. With average flocks of approximately 50 birds, the FCI members would possess about 30 million pigeons.<sup>33</sup> In Europe alone, there are approximately 205,000 pigeon breeders who raise birds for exhibition and maintain approximately 6.6 million birds.<sup>33</sup>

## Unique Characteristics of Columbiformes

Despite the many families, genera and species, which vary in size, weight, plumage and coloring, pigeons have some uniform features.<sup>21,33</sup>

The size of Columbiformes ranges from that of sparrows to that of chickens. They can move effectively on the ground and in the air. The birds have a droplet-shaped rump and an oval front. Their streamlined morphology and their closed plumage, which covers almost the whole body, reduces air resistance during flight and allows the air to pass around the aerodynamic body almost free of turbulence.<sup>1</sup> They have a relatively short neck, small head, small tail and four (in some species, five) short toes.

Columbiformes produce varied vocalizations including cooing, howling, buzzing, tittering or whistling sounds. A chirp-whistling noise is produced mainly by nestlings.<sup>1</sup> Pigeons may live 20 to 30 years.

### Selected Anatomy and Physiology

#### Integument

A particular feature on the beak of the Columbiformes is the cere (ceroma).<sup>16a,21,30</sup>

The plumage of the pigeon does not have the powder down (plumae) found in many other avian groups. The powder found in pigeons is produced by modified semiplumes as well as downs (semiplumae), which can be generally called pulviplumes. Pulviplumes are distinguished from the small body contour feathers by their finer pennaceous barbs, which consist only of the upper part of the vane, while the lower part

shows plumulaceous barbs that unfurl more slowly. Semiplumae are found in several genera of pigeons and doves, particularly on the sides of the body.

The powder is derived from cells that surround the differentiating cells of the barbules of a growing feather. They are not a fragment of the sheath or the feather itself. Powder is shed only while the feathers are emerging from their sheaths. Pulviplumes are characterized by a slow exsheathing process, decreased thickness of the rachis and increased reduction of the barbules, resulting in larger quantities of powder. The number of pulviplumes and the amount of powder produced vary significantly with the species.

The feather powder is composed entirely of keratin. The keratin particles inhibit abrasion of the feathers, provide the plumage its silky gray gleam and keep the ends smooth and pliable. The feather powder protects the pigeon from being waterlogged in the rain and from losing body heat in the cold. Powder enables the flight sport breeds to fly more quickly and with greater endurance. There also seems to be a correlation between high powder production and the reduction of the uropygial gland in some species and breeds.<sup>16a</sup>

The most highly modified powder feathers, the fat quills, are found in only some breeds of domesticated pigeons (ie, German toys such as the Nuremberg Swallows and the South German Shield Pigeons). Instead of powder, these feathers contain homogeneous, yellow, organic fat. The fat is distributed throughout the plumage during preening, creating the "silky" appearance.<sup>16a</sup>

Frequent exposure to feather powder has been associated with allergic alveolitis (pigeon breeder's lung) in some susceptible, genetically predisposed humans. The same pathogenesis has been determined for the feather powder coryza.<sup>1a,32</sup> Recent investigators working on a causative relationship between exposure to feather dust and human lung cancer misinterpreted the results, because of the failure to recognize that avian feather dust is not only created by companion birds but also by geese, ducks and chicken feathers in numerous pillows and quilts.

The uropygial gland is absent or poorly developed in many species and in some breeds of the domesticated pigeon.<sup>21</sup> The secretions contain the precursor of vitamin D. Most Columbiformes enjoy getting wet in the rain and bathing in shallow water. Other anatomic characteristics are the absence of a gall bladder and the presence of a highly rudimentary ceca.<sup>1,21,30</sup>

### Vascular Plexus

The Columbiformes have an anatomic characteristic called the plexus arteriosus et venosus intracutaneous seu subcutaneous collaris. This plexus of anastomosing vessels extends from the cranium to the crop and base of the neck (Figure 44.1). It is divided dorsally into left and right portions, where it is separated by a 1 mm-wide gap in the median plane. The plexus is thicker (more vessels) in the male than in the female. The venous part of the plexus is composed of manifold twirled and tangled vessels that can be distended or narrowed. In scanning electron microscope pictures, the engorged blood vessels appear to be arranged like roofing tiles.

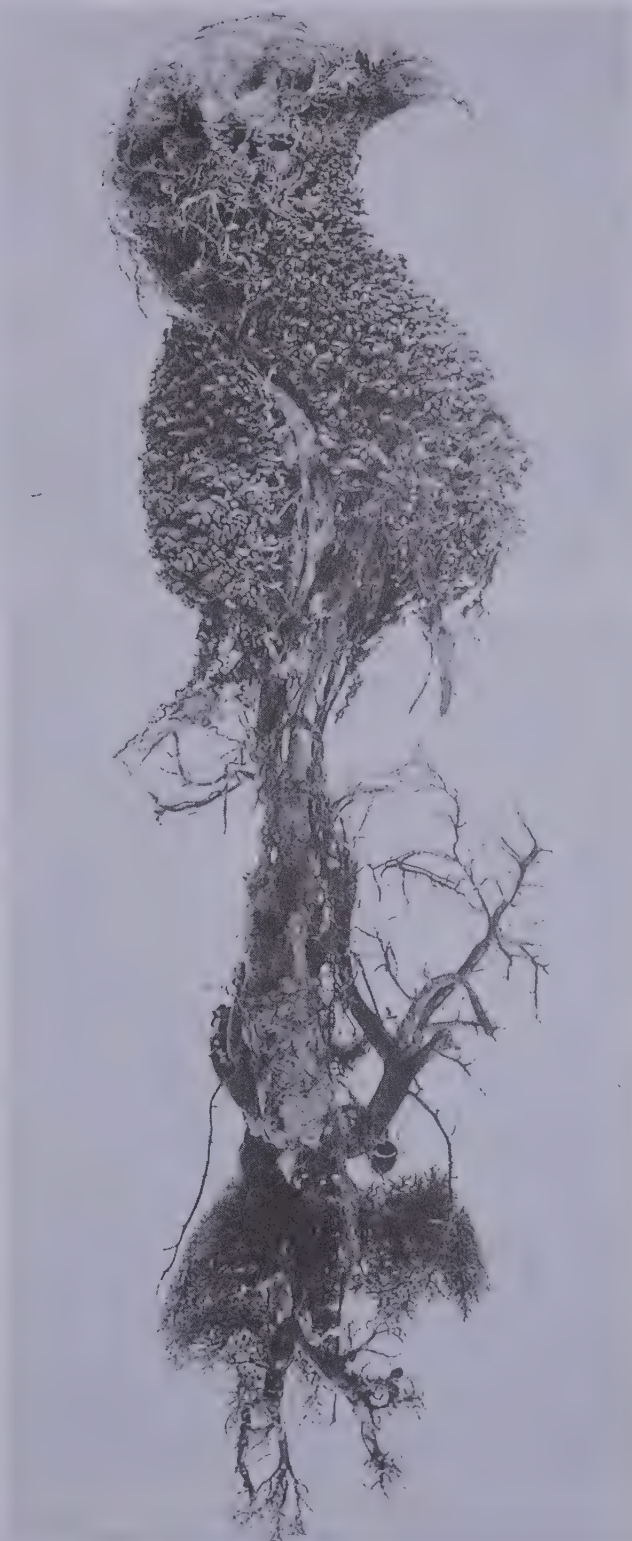
The plexus is used for sexual and territorial display and regulates circulation and body temperature in both genders.<sup>6</sup> The plexus engorges at high ambient temperatures to prevent hyperthermia through the dissipation of excess body heat through the skin. In flight, the head, underside of the wings, breast, legs and toes radiate heat. At temperatures over 25°C, surplus heat is also dissipated by hyperventilation. Injections in or damage of this plexus, especially during display and in hot weather, can cause fatal hemorrhage.

### Gastrointestinal Motility

Gastrointestinal transit times vary with the species and amount and type of food but generally include crop (3 to 17 hours), ventriculus (5 to 19 hours) and intestine (9 to 14 hours).<sup>1</sup> The length of the intestinal tract varies depending on the species, composition of diet and amount and frequency of food consumed. Length ranges from approximately 35 cm in pygmy doves to 70 to 120 cm in domesticated pigeon varieties. Thus, the intestines are 2.5 to 3.5 times longer than the body. Fasted pigeons will defecate between 2.5 and 3.5 hours after consuming food. The majority of excrement (up to 80%) is produced within 24 hours, and the rest is excreted over three to four days.<sup>1</sup>

### Physiologic Parameters

The body temperature of the Rock Pigeon and the descendant domesticated pigeon breeds and varieties is not as uniform as in mammals (eg, Wood Pigeon = 41.8°C, African Collared Dove = 41.0°C, Mourning Dove = 42.6°C).<sup>11</sup> The internal temperature varies with the state of excitement, vigor of flight and ambient temperature. The cloacal temperature averages 39.8 to 43.3°C. The diurnal body temperature varies by approximately 2°C.<sup>1,31</sup> During flight, the metabolic rate is increased to 10 to 12 times the basal



**FIG 44.1** Latex cast of the vasculature of a male pigeon demonstrating the plexus arteriosus et venosus intracutaneous seu subcutaneous collaris. Note the extensive network of anastomosing vessels. This plexus is involved in territorial displays and thermoregulation (courtesy of D. Brückner<sup>6</sup>).

level and the body temperature increases by about 1.5 to 3°C.

In Rock Pigeons and domesticated pigeons, there is a thermo-neutral zone between 25 to 30°C where the regulation of the body temperature between 39.8 to 43.3°C is almost independent of changes in the ambient temperature. These pigeons can withstand extremes in ambient temperature of 42°C to minus 40°C. Resting pigeons begin to shiver at an ambient temperature of approximately 20°C, independent of whether or not they have adapted to the cold.

The heart rate of Rock and domesticated pigeons ranges from 180 to 250 beats per minute; the respiratory rate is 20 to 35 breaths per minute.<sup>30</sup> During sustained flight, the heart rate may reach 5.2 to 6.2 beats per second with a high of 9.4 beats per second at the time of take off.<sup>1</sup>

The blood volume of pigeons is approximately 0.01 ml/kg body weight.<sup>30</sup> The prothrombin time, which is a sensitive indicator of hepatopathies, is 15.1 seconds (range of 11.5 to 18.7) for undiluted pigeon plasma. Pigeons generally have a lymphocytic blood differential. Hematologic and clinical chemistry values are listed in the Appendix.<sup>11,17</sup> Electrocardiographic data are provided in Chapter 27.<sup>19,35</sup>

In contrast to most avian species (except hummingbirds and some finches), pigeons and doves drink water by placing the beak up to the nares in water and sucking it up like a vacuum pump. The drinking cycle consists of combined mechanisms of the beak tip, tongue, palate, laryngeal mound and the pressure differences that occur in the anterior and posterior oropharynx while drinking.<sup>37</sup> With each drinking cycle, domesticated pigeons ingest approximately 0.6 ml of water.

## Behavior

Although considered the international symbol for peace, pigeons and doves are by no means docile creatures.<sup>1</sup> Columbiformes are rather aggressive, particularly during the reproductive cycle, and have no behavioral inhibitions against killing members of their own species or their offspring. In free-ranging birds, one of the combatants can usually escape, which is not always possible in captivity. This behavioral trait should be considered when designing flight enclosures and constructing lofts. Birds should always have a place that they can use to escape from

an aggressive male. Many pigeon and dove species can also be aggressive toward other avian species.

## Homing Abilities of Racing Pigeons

Only racing pigeons have an innate homing ability that has been enhanced through selective breeding and continuous training.<sup>34</sup> Their capacity to return home is based on special senses that enable them to determine the direction of home as soon as they are released. Their methods of navigation detect each divergence from the correct course immediately.<sup>27</sup>


Three distinct parts of the orientation system have been defined in pigeons and migratory birds: the inborn magnetic compass, the acquired sun compass and the star compass (not in homing pigeons).<sup>1,13,15,26,27,28,33,34</sup> The magnetic compass and the sun compass function independently, but they function together to monitor a bird's progress.<sup>13,28</sup> Probably a computer-like mechanism has stored a variety of data, which can be used for reaching the "home loft" target as well as finding the navigational data to get there. Four to five training flights can provide the necessary data.

Other important senses enable a bird to find its way home.<sup>1,15</sup> Homing pigeons can perceive infra-acoustic waves of below 0.06 Hz; they recognize ultraviolet light as well as the plane of polarized light; they sense small changes in air pressure of less than 1 microbar and altitude variations of only 10 m or less; they can detect small variations in the earth's magnetic field; they react to the slightest deviations in the earth's gravitational field.

According to recent findings, racing pigeons obviously do not rely on any one single sense to find their way home, but are assumed to use a combination of orientation factors.<sup>15,33,34</sup> Pigeons can see the sun even when it is invisible to human eyes. Pigeons react to polarized light and probably use this to indirectly determine the sun's position. They are particularly sensitive to the ultraviolet light spectrum and can detect polarized ultraviolet light even through heavy clouds.<sup>15</sup> On the other hand, it is known that homing pigeons are not able to navigate correctly under inversion layer air conditions.

Racing pigeons have iron oxide (magnetic particles) both in the cranium and in the neck musculature that may enable them to gauge the earth's magnetic field by means of special detectors that can recognize the density of the magnetic field.<sup>15</sup> It has been speculated but not proven that olfactory navigation is also of importance for racing pigeons.<sup>1,8,13,15,18,26,28,33,34</sup>



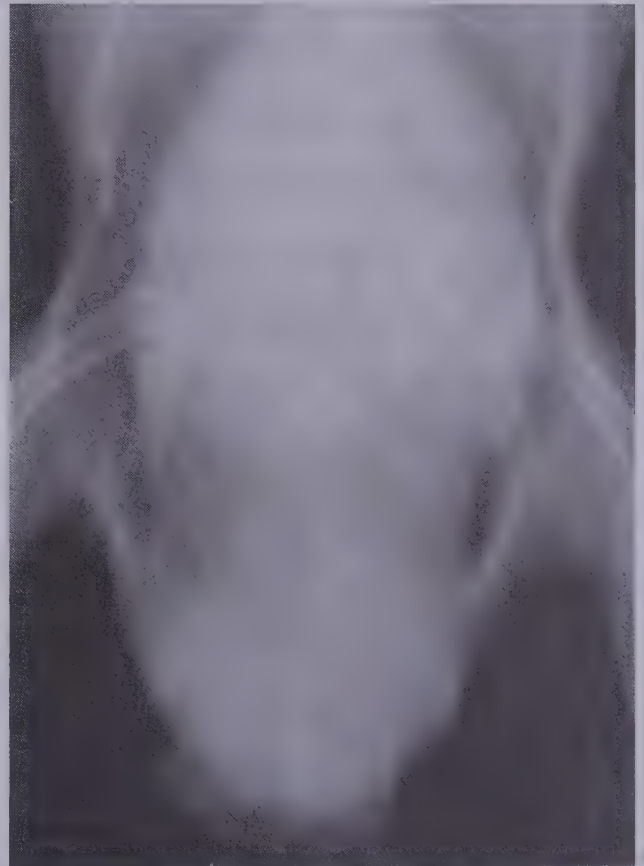


## Husbandry

### Nutrition

With the exception of fruit-eating pigeons (Duculidae) and green pigeons (Treronidae), the natural feed of other families (including the Columba) consists of the seeds of cultivated plants such as cereals, peas, beans, lentils and oil-fruit.<sup>33</sup> Many doves, free-ranging pigeons and domesticated pigeons feed on other cultivated plants, the seeds of weeds, green parts of many plants, berries and other fruits and animals (insects, snails, earthworms). In addition, they pick up small stones, grit and earth particles, which are necessary for grinding the seeds and other grains (Figure 44.2).<sup>1,33</sup> Domesticated pigeons have been observed to perform as many as 35,000 pick actions a day as a response to visual stimuli.<sup>1</sup>

Diets for pigeons should be rich in concentrated nutrients but should not contain high amounts of water or fiber. Effective formulated diets are readily available for domesticated pigeons<sup>33</sup> (nutritional requirements are listed in Tables 44.2-44.5). Commercially available mixed seeds used for many pigeon and dove species can be enriched by adding brewer's yeast, vegetables and vitamin preparations.<sup>33</sup> Pigeons that are allowed free flight will find additional foodstuffs and are usually well nourished.



**FIG 44.2** An adult dove was presented for evaluation of progressive tenesmus of several days' duration. Physical examination indicated a firm mass in the caudal abdomen. Radiographs indicated that the cloaca was impacted with a granular material. A large amount of straw, grit and excrement was removed from the cloaca (courtesy of Marjorie McMillan).

TABLE 44.2 Suggested Mineral Mixture for Pigeons (%)

Components	Breeding Pairs	Squabs
CaCl <sub>2</sub>	84.79	61.32
Ca <sub>2</sub> PO <sub>4</sub>	9.21	31.58
NaCl containing iodine	4.80	4.80
FeSO <sub>4</sub>	0.75	1.50
MnSO <sub>4</sub>	0.15	0.30
CuSO <sub>4</sub>	0.10	0.10
ZnSO <sub>4</sub>	0.20	0.40

TABLE 44.3 Vitamin Requirements for Pigeons

Requirements			
Vitamins (Unit)	Per kg BW*	Per Adult Pigeon**	Per kg Feed
A (IU)	200	100	7,500
D <sub>3</sub> (IU)	20	10	750
E (mg)	2	1	15
K <sub>3</sub> (mg)	0.2	0.1	3
B <sub>1</sub> (mg)	0.3	0.15	3.5
B <sub>2</sub> (mg)	0.3	0.15	3.5
B <sub>6</sub> (mg)	0.3	0.15	3.5
B <sub>12</sub> (μg)	1	0.5	15
Biotin (μg)	6	3	300
Choline (mg)	70	35	1000
Folic acid (mg)	0.05	0.025	1
Nicotinic acid (niacin) (mg)	3	1.5	35
Pantothenic acid (mg)	0.70	0.35	15

\*Body weight

\*\*Body weight approximately 500 g for a racing pigeon

The nutritional requirements and quantity of food consumed vary, based on species, body mass, season, climatic conditions (temperature, relative humidity), type of husbandry (free-flying or restricted to pens), stage of reproduction (egg or sperm production, incubation, raising squabs), stage of growth or molting, amount of exercise, type of feed (seeds, formulated diet) and method of feeding.<sup>33</sup>

The daily feed consumption of pigeons and doves is approximately 1/5 to 1/20 of their body weight. The feed intake of squabs ranges from 10 to 100% of their body weight, depending on their age. The daily amount of drinking water varies between 5 and 8% of the body weight.<sup>1</sup>

The feed quality is of the utmost importance. Grains, seeds or formulated diets should be stored in a dry, clean, pest-free location. Fungi, particular mycotoxins, feed mites and toxic seeds from weeds should be avoided.<sup>33</sup>

TABLE 44.4 Recommended Diet for Pigeons\*

Component	Quantity per kg feed
Crude protein	30 - 150 g
Crude fat	20 - 35 g
Crude fiber	50 g
Metabolizable energy	12 ME
Methionine	3.5 g
Methionine and cystine	6.5 g
Lysine	8 g
Calcium	10 g
Phosphorus	6 g
Sodium	1.5 g
Zinc	50 mg
Iodine	1 mg
Copper	2 mg
Manganese	50 mg
Vitamin A	7,500 IU
Vitamin D <sub>3</sub>	750 IU
Vitamin E	15 mg
Vitamin K <sub>3</sub>	3 mg
Vitamin B <sub>1</sub>	3.5 mg
Vitamin B <sub>2</sub>	3.5 mg
Vitamin B <sub>6</sub>	3.5 mg
Vitamine B <sub>12</sub>	15 μg
Biotin	300 mg
Choline	1000 mg
Folic acid	1 mg
Niacin	15 mg
Pantothenic acid	15 mg

\* Recommendations during breeding, racing and main molting period

TABLE 44.5 Composition of Homemade Pigeon Stones

Components	Percentage
Clay	40
Vitamin/mineral mix (see Table 44.2)	30
CaCO <sub>3</sub> granules	20
Grit or gravel (2-3 mm in diameter)	10

## Housing

When constructing lofts, it is necessary to consider particular requirements for individual pigeon varieties and the number of birds to be housed.<sup>21-23</sup> Breeds maintained for their flying ability must have the opportunity to fly freely in order to maintain a proper level of health.

Optimal environmental conditions increase the productivity, performance and health of Columbiformes of all species and varieties. The housing (lofts, dove-

cots, aviaries, pens and flypens) criteria for pigeons are listed in Table 44.6. Pigeons must be protected from raptors, cats, dogs, foxes, opossums, raccoons, skunks, martens, weasels and rats.<sup>21</sup>

Pigeon lofts or dovecots should be partitioned so that several pens are provided.<sup>21-23</sup> There should be an entrance room that can be used for storing the necessary equipment, tools and feed, as well as one or more pens for breeding pairs.

For tumblers and other flight sport breeds, room should be provided for the bird's flight training (the exact specifications can be requested from local breeder associations for those breeds). Each loft should have compartments for newly weaned birds. Excrement should be removed on a routine basis or the birds should be placed on gratings (steel bar, metal lattice or rip-wire frames) so that the feces can drop through the grate.

Many countries require that domestic pigeons be kept indoors during certain times of the year. In the northern geographical regions, this period extends from April and May, when the cultural grains are sprouting in the fields.

### Preventive Medicine

For pigeons to be at the peak of health and performance, it is necessary to provide them an optimal environment. Practicing sound preventative medicine techniques is far superior to treating disease. Birds involved in racing may be exposed to infectious agents in the race basket and then bring these pathogens back to the flock. This necessitates an ongoing disease surveillance and management program. Pathogens are best recognized and treated before the breeding and racing season.

### CLINICAL APPLICATIONS

Pigeon lofts should be equipped with:<sup>16,17,33</sup>

- Appropriate nests (single coops, double coops or batteries). The latter can be equipped for automatic fecal removal by means of a conveyor belt.
- Hoppers, aisle feed troughs or cafeteria feeders and small dishes for feeding mineral.
- Drinking vessels such as bottle fountains or float-valve fountains that work automatically.
- Baths.
- Multipurpose pens.

TABLE 44.6 Design Criteria for Pigeon Lofts

Floor area/kg body weight	0.25-0.5 m <sup>2</sup>
Air space/kg body mass	0.25-0.5 m <sup>3</sup>
Hourly air exchange/kg body weight	270-320 ml
Maximum content of dust	10 mg/m <sup>3</sup> air
Maximum content of toxic gases:	
CO <sub>2</sub>	2000 ppm
NH <sub>3</sub>	20 ppm
H <sub>2</sub> S	10 ppm
Room temperature	5-28°C

Each bird in the loft should be visually examined daily to determine its overall state of health. Pigeons that appear abnormal should be isolated, observed and evaluated by an experienced avian veterinarian. Birds that cannot be treated are euthanatized immediately and submitted for a complete veterinary and laboratory examination.

Good hygiene demands that excrement and discarded food be removed from the loft and flypens daily. Drinking containers, hoppers, cafeteria troughs and gutters should be thoroughly cleaned at least three times per week or better, daily.

Lofts should be designed with well drained concrete floors to facilitate proper cleaning and disinfection. The concrete floor can be covered with clean litter, sand, gravel or grasses planted in removable flat boxes. If natural soil is used as a floor, excrement should be removed regularly. The upper layer should be removed and replaced with sand or gravel once a year. Flypen floors covered with grass should be cut regularly and the clippings discarded. The lawn should be chalked with unslaked lime, and holes in the surface should be reseeded.

Recently purchased birds must be placed into quarantine before being added to the flock. This includes birds with veterinary certificates stating that they are free of the most important pathogenic agents. There are many pathogenic organisms, particularly viruses, chlamydia and salmonella, which are not regularly excreted and are not always recognizable by antibodies. Therefore, sentinel birds, preferably very young birds, are placed together with the new ones in the quarantine room. If the sentinel and quarantined birds remain healthy for eight weeks, they can be introduced to the flock.

Any free-ranging pigeons that appear in the loft should be isolated immediately, provided food and water and then released. Birds that do not leave should either be treated according to legal regula-

tions or, if these do not exist, euthanatized or placed into quarantine.

Substandard environmental conditions increase the possibility of microbial enrichment and impair the bird's defense mechanisms.

Factors that may increase a pigeon's susceptibility to disease include:<sup>21,22,33</sup>

- Aviaries, lofts and flypens that are overcrowded, too small, dark, insufficiently ventilated, have accumulated toxic gases and dust, and are not kept clean.
- Equipment and supplies that are not kept clean.
- Feeding birds from impractical hoppers or cafeteria troughs.
- Drinking vessels that are difficult to clean and disinfect and hold stale, dirty water or none at all.
- Litter contaminated with too much feces may be either moist (fungal spores) or dry (dust).
- Squabs weaned too early or fed insufficient quality or quantity of food.
- Failure to separate the weaned squabs from the parents.
- Nutritional deficiencies and food contamination with mycotoxins or feces from insects and rodents.
- Overexertion of birds during the flight and race season and exhibition periods.
- Transport baskets and carriers that are dirty and poorly ventilated.
- Immunosuppression caused by viral, bacterial, fungal, parasitic, toxic or metabolic diseases as well as corticosteroids, some antibiotics, coccidiostats and chemotherapeutic agents (see Chapter 5).
- Corticosteroids should be considered highly immunosuppressive (not only in pigeons).

### Special Management Considerations

#### During the Racing Season

During the racing season (May to September in the northern hemisphere), active racing pigeons should have a veterinary certificate indicating that they are clinically free of salmonella, helminths and other contagious agents. The veterinary certificate should be based on clinical examinations and laboratory testing. Many organizations in Europe request that pigeons be vaccinated against paramyxovirus-1-pigeon.

Young birds should be properly conditioned before they are entered in races. This is accomplished by

gradually increasing the flight distance without causing the birds to overexert themselves. Racing pigeons that return from strenuous flights should be provided energy-rich foods and a mixture of electrolytes, glucose and amino acids. Many racing pigeon fanciers feed their own preparations, which are usually kept secret. Racing pigeons that return very late to the loft or appear weak without any obvious reason should be isolated and may be reintroduced to the flock only after successfully passing through quarantine. Birds involved in races should be considered exposed to infectious agents.

The transport baskets and boxes should always be cleaned and disinfected following each transportation. It is imperative that these containers be kept extremely clean to prevent the transmission of infections. Shipping boxes for racing pigeons should offer adequate space for each bird. Only birds that are in excellent condition should be flown. Racing pigeons should be transported to their release destination as quickly as possible. Birds being shipped long distances should be provided food and water and should have at least a three hours' rest before being released.

#### Prior to the Breeding Season

Fecal samples should be collected from pigeons in all lofts, compartments or flypens and evaluated for bacteria (salmonella) and parasites (coccidia, helminthic eggs) prior to the breeding season (January and February in the northern hemisphere). Groups in which salmonella, protozoa or helminths are identified should be treated. Between treatments, the loft, flypens and all equipment should be cleaned and disinfected as dictated by the respective agent.

Vaccination with avian paramyxovirus-1-pigeon is recommended, and in appropriate regions, vaccination with pigeon poxvirus should also be considered. The latter is usually administered in the late summer but should be available on all appropriate occasions. There is still no efficacious vaccine for *Salmonella typhimurium* var. *cop*. A vaccine against pigeon herpesvirus is available commercially in Hungary, but the effectiveness of this vaccine remains undetermined.

#### During the Breeding Season

Approximately two weeks before the first clutch of eggs hatches, all breeding pigeons should be treated with carnidazole, dimetridazole, metridazole or ronidazole to control trichomoniasis. One tablet of carnidazole might be an effective treatment. The tablet should be administered into an empty crop to reduce

the chances of regurgitation. For large flocks, a second prophylactic treatment for trichomonas is recommended from mid-April to the beginning of May. A breeding pair with massive trichomonas should be retreated two weeks before the subsequent clutch hatches. Trichomoniasis should be considered a secondary disease, and the initiating factors that allow an infection to occur should be identified (see Chapter 36).

During the warm season, it is especially important to observe pigeons and their environment for ectoparasites, in particular the red mites, northern feather mites, pigeon ticks, bed bugs, pigeon bugs, pigeon flies and chicken and pigeon fleas. Many of these parasites are found on the birds only at night. If necessary, the animals and their environment should be treated with carbaryl powder or pyrethrin.

Squabs should be placed together in compartments immediately after separation from their parents. If necessary, the weaned squabs should be tested for bacteria (particularly salmonella) and parasites as well as for antibodies against paramyxovirus-1-pigeon. If necessary, the youngsters should be vaccinated.

In the northern hemisphere, all young racing pigeons should be vaccinated for pigeon pox around the end of July. The breeding pairs should be separated from each other at the end of the breeding season.

#### During the Non-breeding Season

Pigeons that will be involved in exhibition should be removed from the nesting area at the beginning of September to induce an undisturbed molt. During the main molt period, pigeons should be provided food that is high in energy, essential amino acids, minerals, trace elements and vitamins.

Until the middle of October, pigeons for exhibition are separated by gender and are allowed to fly free in segregated groups. Most exhibitors require a veterinary certificate indicating that the birds are free of salmonella and parasites; some also require vaccination again for paramyxovirus-1-pigeon.

A complete physical examination should be performed on each breeding pair and their offspring. Any bird that does not meet breeding target or that is determined to be abnormal should be removed from the flock.

## Reproduction

All Columbiformes are monogamous. They differ substantially from gallinaceous birds in reproductive characteristics. In contrast to chickens, female pigeons must at least be able to see a sexual partner for egg production to occur. If a male is not present, another female or a mirror image may stimulate ovulation.

Most of the Columbiformes construct a nest consisting of twigs or similar material in trees, shrubs or other hiding places. Some particular genera are cavity or ground breeders. The Nicobar Pigeon will nest in colonies. The design of enclosures for breeding pigeons should provide a dry, warm, draft-free area.

Pigeons generally are sexually mature by four to six months of age and will select a mate for the breeding season. Pigeons generally breed from spring to late summer when they stop oviposition and enter the main molt that lasts several months. Breeding may start again in late winter. In temperate areas, pigeons may produce offspring year round.

The females of large species lay a single egg; medium-sized species, two and small species occasionally three. Domestic female pigeons lay two eggs, the first at about 5:00 p.m. on one day, and the second approximately 40 hours later (ie, at 2:00 p.m. two days later).<sup>1</sup> Incubation periods and weaning ages are listed in Table 44.7. The hen and cock share incubation duties and two eggs hatch after 17 to 19 days of incubation. The female incubates from the late afternoon until morning, and the male sits on the nest for the rest of the day. The offspring are fed by both parents.<sup>4,5,12,23,24</sup> Information on all stages of embryonal development is still incomplete.<sup>25</sup>

#### Production of Crop Milk

For two weeks before the squabs hatch, the mucosa of the crop in the hen and the cock proliferates, producing increasingly large amounts of exfoliated crop epithelial cells known as "crop milk." Columbiformes feed their offspring exclusively "crop milk" for the first days of life and as a supplemental food until they are 16 days of age.

Crop milk is a holocrine secretion of the epithelium of the crop and consists of 75% water, 12.5% protein, 2.5% non-protein, 8.5% lipids and 1.5% minerals. In addition, it contains all essential amino acids, fatty acids, gammaglobulins (IgA), vitamins, minerals and trace minerals. Carbohydrates are present only in small amounts, if at all.<sup>1</sup> Recent research has shown that crop milk is essential for squabs and cannot be replaced by other material, at least not during the first six days of life. Artificial incubation of pigeon eggs is simple; successful hand-feeding remains difficult.

Crop milk is formed in pigeons under the influence of prolactin. The changes in the epithelium of the crop that allow the production of crop milk can be demonstrated microscopically starting on the sixth day of brooding.<sup>1</sup> In the domestic pigeon, the proliferation of the crop epithelium is macroscopically distinguishable by the twelfth day of brooding. The crop wall is thickened ten to twenty times (1.5 to 3 mm) its normal thickness (0.15 mm) and may appear hyperemic.

The offspring of pigeons and doves are considered to be particularly fast-growing vertebrates. Their body mass doubles within 34 hours following hatch, and their growth curve is steep.<sup>31</sup> Both genders of domesticated pigeons reach sexual maturity as early as 120 days of age. The thyroid gland governs molting patterns in the squab, which start around the 50th day of age, and are completed by the sixth or seventh month when the bird is fully grown.<sup>1</sup>

### Gender Determination

Only a few of the Columbiformes, eg, the Namaqua Dove, Plain-breasted Ground Dove, Emerald Dove, Luzon Bleeding-heart Dove and the Galapagos Dove, are sexually dimorphic. In these species, the males are noticeably larger than the females.


With most other Columbiformes, including the domesticated pigeons, there are few differences between the secondary sexual signs in the male and female. The sexes cannot always be distinguished with certainty by body size or morphology, the shape of the head, cere or neck, or by differences in specific behavior. Evaluation of differences in the structure of the cloacal lips according to the Japanese method<sup>21</sup> for gender determination has been shown to be ineffective in practice. Endoscopy might be necessary for definitive determination of gender (see Chapter 13).<sup>19</sup>

Gender can be determined in most Columbiformes using a modified nose speculum to examine the in-

TABLE 44.7 Incubation Period and Fledging Age for Pigeons (in days)

Common name	Incubation Period	Fledging Age
Nicobar Pigeon	28-30	90
Blue-crowned Pigeon	28-30	28
Domestic Pigeon	17-18	21-28
Stock Dove	17	28
Wood Pigeon	16	20-25
Band-tailed Pigeon	15-18	28
Turtle Dove	15-17	14-16
Zebra Dove	12	11-12
Peaceful Dove	13	11-12
Diamond Dove	12-13	11-12
Picui Ground Dove	14	12-14
Plain-breasted Ground Dove	12	14-18
Emerald Dove	12	12-13
Common Bronze-wing	12-14	16-20
Crested Pigeon	14	12
Plumed Pigeon	17	14-17
Squatter Pigeon	17	14-17
Cinnamon Dove	15	12-21
Grey-fronted Dove	17	14-17
Ruddy Quail Dove	10-12	8-11
Luzon Bleeding Heart	15-17	12-14
Pintailed Green Pigeon	16	13-15
Nepal Thick-billed Green Pigeon	14	12
Lilac-capped Fruit Dove	18	9-12
Seychelle Blue Pigeon	28	14-16
Banded Imperial Pigeon	18	14-16

side of the cloaca.<sup>21</sup> The lateral part of the speculum is ground off and smoothed so that the ends are only 17 to 25 mm long and 3 to 5 mm wide. To perform this procedure, the bird is held in a vertical restraint position with the head upside down and the feet toward the examiner. The speculum is inserted carefully about 1 cm into the cloaca (depending on the size of the bird), then opened and slowly advanced dorsally and cranially. The cloacal lips widen and some of the internal cloacal structures become visible. The female is identified by visualization of the orifice of the oviduct on the left side, while the male has bilateral papillae where the vas deferens open into the cloaca. This method of gender determination is reliable for adult birds, but less so for younger pigeons. Injection of either testosterone or follicular hormones has been suggested in juveniles to improve the success of cloacal gender determination. However, considering the accuracy and safety of endoscopy, the use of therapeutic agents that could alter a bird's natural development is not encouraged.



**FIG 44.3** A pigeon was presented with conjunctivitis and a mass in the lower eyelid. Cytology of a fine-needle biopsy indicated that the mass was characterized by epithelioid cells packed with acid-fast rods, suggestive of *Mycobacterium* spp. (courtesy of Helga Gerlach).

## Artificial Insemination

### Managing the Male

The best males to use for semen donors are mature birds that are with hens eight days before, or up to four days after, egg laying. Two people are required for collecting the semen. One person restrains the bird upside down with the tail toward the examiner. The other person holds a Pasteur pipette in one hand, and the tail is lifted up and held between the thumb and index finger of the same hand. The opening of the cloaca is literally pressed together to push the spermatozoa out of the papilla of the ductus deferens.

This pressure also causes blood plasma to pass from the capillaries under the cloacal epithelium. This blood plasma collects in the median part of the cloaca and combines with the spermatozoa to produce 0.1 to 0.2 ml of semen.

### Managing the Female

The most suitable females for artificial insemination are those that have been sexually stimulated by a sterile male.<sup>2,33</sup> Males are sterilized by transecting the ductus deferens, which are visible as meandering whitish cords between connective tissue folds of the peritoneum (cave ureters) (see Color 13). The cranial end of the transected vas deferens should be permanently closed with an ethicon clip to prevent the spermatozoa from being released into the abdominal cavity. Spermatozoa are still produced following sterilization and may initially occlude the seminal duct

and vas deferens. The accumulated spermatozoa will eventually be phagocytized by leukocytes.


The collected semen is used to directly inseminate the female. The oviductal mucosa contains glands that store sperm and keep it viable for several days. Insemination is best performed around 8:00 p.m. four days before the first egg of a clutch would be laid. This method maximizes the chance that any eggs produced will be fertilized. Insemination is achieved by restraining the hen in the same manner as described for semen collection. An assistant opens the proctodeum with a short vaginal speculum. The orifice of the oviduct is identified on the left side of the urodeum, and should not be confused with the opening of the cloacal bursa or the entrance to the coprodeum.

The salpingeal orifice is relatively large in older hens but is difficult to visualize in young hens before the first egg has been laid. Two small papillae that represent the vestiges of the Wolffian duct can also be identified. These structures disappear shortly before the first egg is laid. Insemination is most successful if performed with undiluted ejaculate immediately or shortly after collection. The pipette is positioned relatively deep into the distal section of the salpinx and the semen is released, while simultaneously and slowly withdrawing the pipette. If properly performed, semen should not reflux into the cloaca.

## Clinical Examination

The clinical examination might involve a single pigeon or the entire flock. The physical appearance of a healthy pigeon, examination procedures for the loft and examination procedures for the individual pigeon are similar to those described for Psittaciformes (see Chapters 2, 8). A bird's feathers should be carefully protected during the examination procedure. Damage to the feathers of a racing or exhibition bird can substantially affect their performance.

It is necessary to determine the breeds and color varieties, because some groups of pigeons are more susceptible to certain diseases. For example, the German toy pigeons, many pouters, trumpeters, frill-backs, fantails, jacobins, owls, tumblers, certain homers, strassers, kings and runts are very suscepti-




**FIG 44.4** The basic method of restraint in Columbiformes is the horizontal hold. **a)** The bird's feet are stretched caudally and are held between the index and middle fingers. At the same time, the thumb and the other fingers fix the end of the wings and the base of the tail. The restrained pigeon lies flat in the inside of one hand. The other hand is free for examining the bird. **b)** Large pigeons may require both hands for proper restraint, and in this instance a second person is needed to facilitate the physical examination (courtesy of R. Korbel).

ble to salmonella and viral infections. Restraint techniques for Columbiformes are described in Figures 44.4 to 44.7.

### Therapeutic Methods

The subcutaneous connective tissue of the caudal third of the neck is most suitable for subcutaneous injections. The skin near the base of the neck should be gently lifted to create a fold, and the needle should be directed strictly dorsomedian with a relatively flat cranial orientation.<sup>39</sup> The animal is restrained in the horizontal hold. The exact location of the needle is checked by injecting a small fraction of the drug and watching for a bubble of fluid in the tissue. The plexus arteriosus et venosus intracutaneous collaris

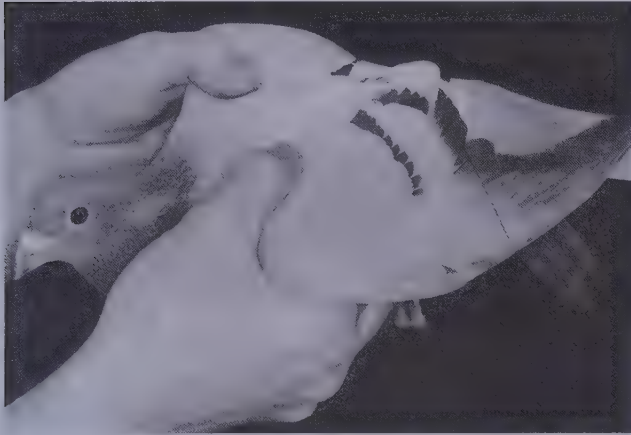


**FIG 44.5** With a vertical restraint technique, the bird is held upright with the thumb, index and middle fingers placed at the end of the wings and the remaining fingers restraining the feet and base of the tail (courtesy of R. Korbel).

must be avoided. Injection into this area can cause fatal hemorrhage. Infusing large volumes of fluid or injecting caudally can damage the clavicular air sac, the jugular vein and the vagus nerve. Large volumes of fluid can be administered into the subcutaneous connective tissue on the side of the thoracic wall and behind the wings.<sup>39</sup>

Pigeon poxvirus vaccines can be administered by feather follicle or wing web method. A feather follicle vaccine is applied by removing approximately ten feathers on the lateral thigh and rubbing the vaccine into the follicles using a brush provided by the manufacturer (Figure 44.8).<sup>31,32,39</sup> This method should not be used for emergency vaccination because field virus can infect the traumatized skin. The wing web method employs a puncture through the propatagium with a special needle provided by the manufacturer. Both methods should be used only as recommended by the manufacturer.<sup>10,39</sup>





**FIG 44.6** The wings are best examined using horizontal restraint. Another method for restraint when examining the wings is to hold both wings with the head facing the examiner. The thumb is on the upper surface of the wings, the other fingers on the lower side, and both wings can be palpated simultaneously. For examining the legs, the pigeon is held against the body of the person who is restraining it, and the hands press gently down on the body while the hind limbs are examined and compared between the thumb and index finger (courtesy of R. Korbel).



**FIG 44.7** To examine the crop and neck region, the animal is restrained in one hand using the horizontal hold. The other hand is used to palpate the regions in question and to open the beak. This can be done by fixing the upper beak between the thumb and middle finger while carefully pressing down the lower beak with the index finger. It is easier, particularly with larger pigeons, if an assistant restrains the bird while it is being examined (courtesy of R. Korbel).

The iliobtibialis muscle of the thigh is a good site for intramuscular injections in some pigeons or doves. The bird is restrained inside the palm of one hand, the head and the leg to be injected are fixed between the middle and index fingers, and the other leg is held between the ring and little fingers. The injection is administered at the middle of the femur, and the needle runs distally. The pectoralis muscle is used for IM injections in larger Columbiformes that require a higher injection volume.<sup>39</sup> The injection site is approximately parallel to the cranial third of the mediana sterni, close to the carina with a cranio-dorsal needle angle of approximately 70°. The needle must be advanced approximately 5 to 7 mm into the muscle, not too flat or too far laterally. Although the injection volume depends on the body size, it should generally be restricted to less than 0.5 ml. The smallest possible needle gauges that are compatible with the viscosity of the therapeutic agent should be used to prevent hemorrhage.

For intravenous injections, the ulnar vein or medial metatarsal veins can be used (Figure 44.9). Post-venipuncture hemorrhage can be reduced by using the thumb to tighten the propatagium at its insertion, directing the needle as far proximally as possible and releasing the propatagium before withdrawing the needle. This reliably prevents bleeding without the need to apply continuous compression.<sup>39</sup>

## ■ Anesthesia

### General Anesthesia

Isoflurane is the anesthetic of choice for use in pigeons (see Chapter 39).<sup>11,14</sup>

Several protocols for injectable anesthetics have been suggested including the IM administration of ketamine hydrochloride (20 to 40 mg/kg body weight) in combination with diazepam (0.5 to 1.5 mg/kg body weight) or xylazine (2 to 5 mg/kg body weight).<sup>14,11</sup> The use of methomidate (10 to 20 mg/kg body weight intramuscularly) has also been reported in pigeons. However, the use of injectable anesthetics in pigeons is fraught with problems that include widely variable responses and levels of safety among patients.<sup>9</sup>

If injectable anesthesia must be used, it is best to use 25 mg/kg body weight ketamine hydrochloride together with 12.5 mg/kg body weight clamazolam IM.<sup>9</sup> Combined ketamine/clamazolam injection anesthesia has been shown to have minimal adverse effects on the physiologic regulation systems of the pigeon. An excitation phase will occur during the induction



**FIG 44.8** Application of a feather follicle pox vaccine in a pigeon. The feathers from the medial area of the thigh have been removed, and the vaccine is applied to the follicles with a brush according to the manufacturer's recommendations (courtesy of Curt Vogel).



**FIG 44.9** The ulnar vein can be used for blood collection or IV injections, but tends to hemorrhage more than the medial metatarsal vein. Using the thumb to tighten the propatagium before inserting a needle may help reduce post-cannulation bleeding (courtesy of Curt Vogel).

and recovery phases with this combination, but in general it appears to provide satisfactory restraint for about 25 minutes. There are no known anesthetic recovery problems. The recovery phase can be shortened to 10 to 20 minutes by administering benzodiazepine antagonists IV.

ples or cadavers, the agent becomes invisible. Therefore, sending samples to a diagnostic laboratory is of no benefit.

In pouters, so-called sour crop (ingluveitis) is a common problem. Sour crops have to be emptied and

### Local Anesthesia

Columbiformes are sensitive to many local anesthetic agents and may develop adverse drug reactions or die following the administration of 0.5 ml/kg of 2% procaine or lidocaine hydrochloride. Local anesthesia can be achieved with 1% procaine or 2% lidocaine hydrochloride with the addition of adrenalin 1:20,000. The addition of adrenalin increases safety, decreases absorption and prolongs anesthetic duration.<sup>29</sup> Local anesthesia is achieved within two to ten minutes of application.

## Diseases

The primary disease problems are due to infectious agents. The corresponding clinical and pathologic features, as well as some suggestions for control and therapy, are mentioned in the pertinent chapters. Table 44.8 provides a checklist of infectious diseases. Noninfectious ailments are also discussed in other chapters.

Two special problems with pigeons should be mentioned here.

Pigeons frequently have trichomoniasis (canker) of the oropharynx and the crop as well as occasional systemic infections, which cause lesions in the liver, base of the heart and lungs. Native preparations (swab from the crop) for demonstrating trichomonas are taken for direct microscopic examination. One-half to one hour after collection of the sample, the agent will no longer be recognizable. With cooling down of sam-

TABLE 44.8 Check List of Infectious Agents in Pigeons

VIRUS	ECTOPARASITES	INSECTS
Pigeonpox Herpesvirus – Inclusion body hepatitis in pigeons (syn. Infectious esophagitis) – Contagious paralysis (syn. pigeon herpes encephalomyelitis) Avian adenovirus Avian parvovirus Avian reovirus Eastern and western equine encephalomyelitis Venezuelan equine encephalomyelitis Rubivirus St. Louis encephalitis West-Nil-Virus Avian paramyxovirus, serotype 1 Newcastle disease, serotype 1 pigeon, serotype 7 Avian influenza virus A Avian retrovirus – Type C retrovirus group (Avian leukosis-related viruses) including avian sarcoma and leukemia viruses – Avian reticuloendotheliosis virus	Argas spp. – ( <i>A. reflexus</i> = Pigeon tick) Ixodes spp. <i>Dermanyssus gallinae</i> – Roost mite syn. chicken mite <i>Ornithonyssus</i> – Northern fowl mite <i>Syringophilus columbae</i> – Quill mite <i>Sarcopterus nidulans</i> <i>Cytodites nudus</i> – Air sac mite <i>Laminosioptes cysticola</i> – Forms nodules within the subcutis <i>Neonyssus</i> spp. – In nasal and sinus cavities <i>Speleognathus striatus</i> – As above <i>Cheyletiella heteropalpa</i> – Feather mite <i>Falculifer</i> spp. – Feather mite <i>Megninia</i> spp. – Feather mite <i>Analges bifidus</i> – Feather mite <i>Hemialges anacentros</i> – Feather mite <i>Knemidocoptes mutans</i> – Scaly-leg mite <i>Neoknemidocoptes laevis</i> – Depluming scabies	<i>Columbicola columbae</i> – Slender pigeon louse <i>Campanyulotes bidentatus</i> – Golden feather louse <i>Colocera</i> spp. – Little feather louse <i>Hohorstiella</i> spp. – Large body louse <i>Neocolpocephalum</i> spp. – Narrow body louse <i>Bonomiella columbae</i> <i>Physconelloides</i> spp. <i>Cimex</i> spp. – Bedbugs <i>Haematosiphon inodora</i> – Adobe bug <i>Oeciacus vicarius</i> <i>Triatoma</i> spp. – Assassin bug <i>Ceratophyllus</i> spp. – Fleas <i>Echidnophaga gallinacea</i> – Stick-tight flea <i>Tenebrio molitor</i> – Yellow mealworm <i>Dermestes lardarius</i> – Larder beetle <i>Neocrophorus vestigator</i> <i>Silpha</i> spp. – Carrion or Sexton beetle <i>Pseudolynchia canariensis</i> – Pigeon louse fly <i>Ornithomyia</i> spp. – Louse fly <i>Orthofiersia</i> spp. – Louse fly <i>Stribometapa podostyla</i> – Louse fly <i>Lynchia</i> spp. – Louse fly <i>Microlynychia pusilla</i> – Louse fly
<b>CHLAMYDIA</b>		
<i>Chlamydia psittaci</i>		
<b>MOLLECUTES</b>		
<i>Mycoplasma</i> spp. <i>Achloplasma</i> spp.		
<b>RICKETTSIA</b>		
<i>Coxiella burnetii</i> <i>Aegyptianella pullorum</i>		
<b>BACTERIA</b>		
<i>Staphylococcus</i> spp. <i>Streptococcus</i> spp. <i>Mycobacterium avium-intracellulare</i> <i>Erysipelothrix rhusiopathiae</i> <i>Listeria</i> spp. <i>Clostridium</i> spp. <i>Enterobacteriaceae</i> <i>Pseudomonas aeruginosa</i> <i>Aeromonas hydrophila</i> <i>Alcaligenes faecalis</i> <i>Bordetella</i> spp. <i>Campylobacter</i> spp. <i>Vibrio</i> spp. <i>Borrelia anserina</i> <i>Pasteurella</i> spp. <i>Actinobacillus</i> spp. <i>Haemophilus</i> spp. <i>Cytophaga anatispestifer</i> (syn. Pfeifferella, Moraxella, Pasteurella) <i>Acinetobacter calcoaceticus</i>	<b>FLUKES (Trematodes)</b>	
	<i>Echinoparyphium</i> spp. <i>Echinostoma</i> spp. <i>Hypoderaeum conoideum</i> <i>Cotylurus comutus</i> <i>Ribeiroia ondatrae</i> <i>Apatemon gracilis</i> <i>Brachylaema</i> spp. <i>Harmostomum</i> spp. <i>Postharmostomum</i> spp. <i>Cryptocotyle concavum</i> <i>Amphimerus elongatus</i> <i>Tanaisia bragai</i>	
	<b>ROUNDWORMS (Nematodes)</b>	
	<i>Ascaridia columbae</i> and other <i>A.</i> spp. – Common or large roundworm <i>Ornithostrongylus quadriradiatus</i> <i>Trichostrongylus tenuis</i> <i>Tetrameres</i> spp. <i>Dispharynx nasuta</i> – Spiral stomach worm <i>Pelucitus</i> spp. – Filaria in the subcutis of the neck <i>Capillaria</i> spp. – Thread worms <i>Syngamus trachea</i> – Red worm syn. forked worm	<b>TAPEWORMS (Cestodes)</b>
		<i>Aporina delatondi</i> <i>Choanotaenia infundibulum</i> <i>Hymenolepis</i> spp. <i>Raillietina</i> spp. <i>Cotugnia</i> spp. <i>Diphyllobothrium mansonii</i> (only larvae)
		<b>PROTOZOA</b>
		<i>Eimeria</i> spp. <i>Toxoplasma gondii</i> <i>Sarcosporidia</i> spp. <i>Haemoproteus</i> spp. <i>Plasmodium</i> spp. <i>Leucocytozoon</i> spp. <i>Trypanosoma hanna</i> <i>Spironucleus columbae</i> <i>Trichomonas gallinae</i>
<b>FUNGI</b>		
<i>Microsporium</i> spp. <i>Candida albicans</i> <i>Cryptococcus neoformans</i> <i>Histoplasma capsulatum</i> <i>Aspergillus</i> spp.		



**FIG 44.10** Mild conjunctivitis is characteristic of chlamydiosis in adult Columbiformes.

rinsed with saline at body temperature, possibly with some added antibiotic. Pouters must be fed in small portions to avoid overloading the crop. This is particularly important after transport, when the animals start eating again.



**FIG 44.11** Poxvirus infections can cause high morbidity in some flocks. Squabs are particularly susceptible to the virus and may develop the cutaneous or diphtheroid forms of the disease. This squab had characteristic papules on the beak and oral mucosa.



**FIG 44.12** Torticollis caused by paramyxovirus-1-pigeon in a fancy (helmet) pigeon (courtesy of Louise Bauck).

## References and Suggested Reading

1. **Abs M:** Physiology and behaviour of the pigeon. London, New York, Academic Press, 1983, pp 1-360.
- 1a. **Bauer X:** Die Taubenzüchterlunge. Die Brieftaube 108:1161-1163, 1991.
2. **Berens von Rautenfeld D:** Mitteilungen zur künstlichen Besamung bei Tauben. Praktischer Tierarzt 63:917-922, 1982.
3. **Beuing R:** Paarungsverfahren in der Taubenzucht. Bibertal, Verlag für Tierzucht und Angewandte Genetik, 1979, pp 1-138.
4. **Blount M:** The early development of the pigeon's egg, with especial reference to the supernumerary sperm nuclei, the periblast, and the germ wall. Biol Bull 13:231-250, 1907.
5. **Blount M:** The early development of the pigeon's egg, with especial reference to polyspermy and the origin of the periblast nuclei. J Morphol 20:1-64, 1909.
6. **Brückner D:** Blutgefäßverlauf im Kopf- und Halsbereich der Taube. Gießen, vet med Diss, 1987, pp 1-143.
7. **Dorrestein GM:** Studies on pharmacokinetics of some antibacterial agents in homing pigeons (*Columba livia*). Utrecht, The Netherlands, vet med Diss, 1986, pp 1-224.
8. **Galler SR:** Animal Orientation and Navigation. Washington DC, National Aeronautics and Space Administration, 1972.
9. **Ganter M:** Untersuchungen zur Narkose mit Ketamin-HCl, Xylazin, Diazepam, Clomazepam und Pentobarbital-Na bei Tauben. Hannover, Tierärztliche Hochschule, vet med Diss, 1986, pp 1-260.
10. **Grund S:** Pockenerkrankungen bei Brieftauben - Diagnostik und Impfung. Die Brieftaube 108(28):1151-1153, 1991.
11. **Gylstorff J, Grimm F:** Vogelkrankheiten. Stuttgart, Verlag Eugen Ulmer, 1987, pp 1-609.
12. **Harper EH:** The fertilization and early development of the pigeon's egg. Amer J Anat 3:349-386, 1904.
13. **Keeton WT:** Advances in the Study of Behavior Vol 5. London, New York, Academic Press, 1974, pp 47-132.
14. **Krautwald ME, et al:** Atlas of Radiographic Anatomy and Diagnosis of Cage Birds. Berlin, Hamburg, Verlag Paul Parey, 1992, pp 1-211.
15. **Kreithen ML:** In Schmidt-Koenig K, Keeton WT (ed): Animal Migration, Navigation and Homing. Proc in Life Sciences, Berlin, Heidelberg, New York, Springer Verlag, 1978.
16. **Lipp HP:** Brieftauben in der Armee, ein Anachronismus? In "Krieg im Äther", Folge XIX, Lausanne, Switzerland, 1980, pp 1-24.
- 16a. **Lucas AM, et al:** Avian anatomy, Integument I & II. US Department of Agriculture, Agricultural Handbook pp 335-338; 386-387, 1972.
17. **Lumelij JT:** A contribution to clinical investigative methods for birds, with special reference to the racing pigeon *Columba livia domestica*. Utrecht, The Netherlands, vet med Diss, 1987, pp 1-186.
18. **Mikulicz-Radecki von N:** Studien über die Musterung und Färbung von Wild- und Haustauben. Zoologisches Jahrbuch, Abteilung für allgemeine Zoologie und Physiologie 62:211-354, 1950.
19. **Miller WJ, Wagner FH:** Sexing mature Columbiformes by cloacal characters. Auk 72:279-285, 1955.
20. **Nwosu CC:** Untersuchungen zur Durcberechnung der Monogamie der Taube (*Columba livia*) durch spezielle Paarungs- und Haltungstechniken. Gießen, Universität, tierzüchterische Diss, 1975, pp 1-114.
21. **Levi WM:** The Pigeon. Sumter, SC, Levi Publ Co. 1957, 1963, pp 1-667.
22. **Levi WM:** Encyclopedia of pigeon breeds. Jersey City, TFH Publications, 1965, pp 1-790.
23. **Patterson JT:** On gastrulation and the origin of the primitive streak in the pigeon's egg. Biol Bull 13:251-271, 1907.
24. **Patterson JT:** Gastrulation in the pigeon's egg: A morphological and experimental study. J Morphol 20:65-125, 1909.
25. **Romanoff AL:** The Avian Embryo. New York, Macmillan, 1960.
26. **Schmidt-Koenig K:** Avian Orientation and Navigation. London, New York, Academic Press, 1979.
27. **Schmidt-Koenig K:** Das Rätsel des Vogelzuges. Hamburg, Hoffmann und Campe, 1980, pp 1-252.
28. **Schmidt-Koenig K, Keeton NT (ed):** Animal Migration, Navigation and Homing. Series: Proc in Life Sciences. Berlin, Heidelberg, New York, Springer Verlag, 1978.
29. **Schott E:** Untersuchungen zur Anwendung der Lokalanästhesie bei Tauben (*Columba livia* Gmelin 1789) mit Procain und Lidocain. München, Universität, vet med Diss, 1987, pp 1-109.
30. **Sturkie PD (ed):** Avian Physiology. New York, Heidelberg, Berlin, 1976, pp 1-400.
31. **Tudor DC:** Pigeon Health and Disease. Ames, Iowa State University Press, 1991, pp 1-244.
32. **Vogel C, et al:** Taubenkrankheiten, D-8355 Hengersberg, Schober Verlags-GmbH, 1983, pp 1-488.
33. **Vogel C, et al:** Tauben. Berlin, Deutscher Landwirtschaftsverlag, 1992, pp 1-539.
34. **Wallraff HG:** Das Navigations system der Vogel. München, Wien, Oldenbourg Verlag, 1974, pp 1-156.
35. **Warzecha M:** Vektorkardiographische Untersuchungen an jungen und adulten Brieftauben. Berlin, Freie Universität, vet med Diss, 1989, pp 1-153.
36. **Wolters HE:** Die Vogelarten der Erde. Hamburg, Berlin, Paul Parey Verlag, 1982.
37. **Zweers GA:** The feeding system of the pigeon (*Columba livia* L.). Advances in Anat. Embryol and Cell Biol 73:1-107, 1982.
38. **Zweers GA, van Pelt HC, Beckers A:** Morphology and mechanisms of the larynx of the pigeon (*Columba livia* L.): A drill chuck system (Aves). Zoolmorphol 99:37-69, 1981.
39. **Korbel R:** Praxis der Injektions- und Blutentnahmetechniken an Vogelpatienten. Tierärztliche Praxis 18:601-611, 1990.
40. **Korbel R:** Zwangsmaßnahmen beim Vogelpatienten. Theoretische Grundlagen und praktische Durchführung, Teil 1,2. Tierärztliche Praxis 20:59-64, 164-170, 1992.

CHAPTER

# 45

## GALLIFORMES

Christian Schales  
Kerstin Schales

**M**embers of the order Galliformes occur on every continent except Antarctica. The Red Junglefowl, Common Turkey and Helmeted Guineafowl have been domesticated for centuries and are of considerable economic importance. Some varieties reach monstrous proportions and some members of the order, like the Japanese Quail and various pheasants, are approaching a level of complete domestication.

Many Galliformes are commonly maintained as game birds, some of which are stable in captivity, easy to breed and inexpensive. Other species are from niches with specific environmental requirements and need specialized diets, humidity or temperature to survive.

In this chapter, “domestic fowl” means *Gallus gallus, forma domestica* (domestic form of the Red Junglefowl); “domestic turkey” is *Meleagris gallopavo, forma domestica* (domestic form of the Common Turkey) and “domestic guinea fowl” is *Numida meleagris, forma domestica* (domestic form of the Helmeted Guineafowl) (Table 45.1).

Maintaining, breeding, treating or dealing with gallinaceous birds may be regulated by laws that govern the protection of animals, property rights, exchange of goods, liability, epornitics, food for human consumption, hunting and (international) transport of animals.

Several gallinaceous birds have anatomic or physiologic peculiarities that should be discussed.<sup>7</sup> In the circulatory system, for example, most gallinaceous birds have right and left internal carotid arteries; however, the megapodes have only the right internal carotid artery.<sup>28</sup> The respiratory rates, heart rates and rectal temperatures of some gallinaceous birds are listed in Table 45.2

## Anatomy and Physiology


### Integument

Many gallinaceous species develop a durable, vascularized thickening of the corium in the ventral thoracic region called a brooding spot. The feathers in this region are temporarily lost, and body heat is transferred directly from the brooding bird to the eggs.<sup>34</sup>

The preen gland in the domestic fowl consists of two bilateral symmetric lobes, each with one secretory duct opening into the uropygial teat. Some breeds of domestic fowl have two uropygial teats. Tail-less breeds of the domestic fowl and the argus pheasants have no preen gland. A brush-like feather tuft that absorbs secretions from the gland is present on the uropygial teat (see Figure 24.7).<sup>34</sup> This feather tuft is absent in the megapodes.<sup>28</sup>

Some gallinaceous birds have unique skin appendages. Junglefowl possess marked unpaired carneous combs consisting of a wide intermediate layer, which is formed of a fibrillar network filled with mucus-like substances that impart elastic stability to the comb. The intermediate layer is covered by the strongly vascularized corium and the epidermis. Feathers are present on the comb bonnet in some domestic fowl breeds. The paired wattles of the throat are similar in structure to the comb (Figure 45.1). Like the comb, the size of the wattles is influenced by hormones, and both are better developed in cocks than in hens. Paired cheek or ear lobes are located ventral to the auditory canal and are red or white if subepithelial capillary sinusoids are absent.<sup>34</sup>

The structure of the skin appendages on the head and neck of turkeys varies from those described in junglefowl. These appendages have no elastic intermediate layer but do have superficial, muscular and vascular layers. The dewlaps of turkeys are smooth, can increase and decrease in size and can change color. Turkeys have a single snood on the forehead that can increase or decrease in length. Numerous red caruncles are located on the poorly feathered blue skin of the head. A beard consisting of tough dark bristles is present at the border between the neck and chest. Turkey hens have smaller skin appendages than cocks, and a beard is found occasionally in older hens<sup>34</sup> probably as a result of hormonal changes.



**FIG 45.1** Fly bite dermatitis in the comb of a Rhode Island Red Rooster.

In New World quail, the edge of the lower bill is serrated or slightly toothed. An osseous process, which can be large in some species or subspecies, exists near the junction of the upper bill and cranium of Helmeted Guineafowl and some cracids.<sup>28</sup> This helmet consists of a cone of spongy bone covered by the corium and a keratinized epidermis. The wattles of the Helmeted Guineafowl are white to light-blue and, like the helmet, are larger in cocks than in hens.<sup>34</sup> Some other phasianids, some megapodes and some cracids also possess ornamental appendages of the head and the neck. In some species, these appendages are visible only during mating displays. Some breeds of the domestic fowl, some megapodes, some francolins, some tragopans and some pheasants have completely featherless heads and necks or featherless areas of the head or neck. Unfeathered areas of skin are frequently colored.<sup>28</sup> Many grouse species have red-colored supra-ocular combs. These unfeathered regions become swollen during the mating season.<sup>5,17</sup>

TABLE 45.1 Families and Subfamilies of Gallinaceous Birds<sup>41</sup>

Family Subfamilies	No. of Genera	No. of Species
Cracidae (cracids)	10	43
Megapodiidae (megapodes)	7	12
Phasianidae (phasianids)	70	203
Numidinae (guineafowl)	4	6
Pavoninae (peafowl)	2	3
Meleagridinae (turkeys)	1	2
Argusianinae (peacock pheasants and argus pheasants)	3	8
Phasianinae (pheasants)	8	21
Lophophorinae (monals)	1	3
Pucasiinae (Koklass)	1	1
Ithagininae (Blood Pheasant)	1	1
Gallinae (junglefowl)	1	4
Tragopaninae (tragopans)	1	5
Galloperdicinae (spurfowl)	1	3
Ptilopachinae (Stone Partridge)	1	1
Perdicinae (partridges, snowcocks, francolins, Old World quail)	27	98
Odontophorinae (New World quail)	9	31
Tetraoninae (grouse)	9	16

The cocks of many gallinaceous birds have spurs, which are osseous eminences originating from the tarsometatarsus and are covered by keratinized epidermis (see Figure 12.34). If spurs occur in hens, they are generally smaller than in cocks and often have no osseous component.<sup>34</sup> The cocks' spurs are frequently sharp and can easily injure rivals, females, clients or veterinarians. Cracids and grouse do not have spurs.<sup>5</sup> In the Common Pheasant, annual rings are formed in the epidermis at the base of the spurs and can be used to determine the minimum age of the bird.<sup>20</sup>

### Adaptations to Low Temperatures

The feet and toes of grouse are feathered. In ptarmigans, even the plantar surface of the foot is covered with fur-like feathers. Long nails and keratinous pins on both sides of the digits facilitate locomotion on snow. Dense plumage and a thick layer of subcutaneous fatty tissue help protect against the cold. Hair-like feathers cover the nostrils. In ptarmigans, shivering for the active production of body heat starts only below  $-12^{\circ}\text{C}$ .<sup>5,17,28</sup>

### Plumage

The chicks of all gallinaceous birds are nidifugous and hatch with a downy plumage.<sup>33</sup> The contour feathers of the plumage are formed of the deck feathers (tectrices), the flight feathers (remiges) and the tail feathers (rectrices). The number of rectrices varies among different species: the domestic fowl has 7 pairs; the Bulwer's Wattled Pheasant has 12 to 16 pairs. Ornamental feathers can originate from different portions of the plumage including tail coverts (peafowl), rectrices (many pheasants) and chin feathers (capercaillies). Birds that are indigenous to open terrain often have a patterned plumage that serves as camouflage.<sup>28,34</sup> Some species like the Golden Pheasant show polychromatism of the plumage.<sup>28,33</sup>

The eyes of many gallinaceous birds are hidden by dark periorbital feathers. Attempting to escape from predators by running or flying in open terrain is poor defense; thus, most ground-dwelling gallinaceous birds remain immobile when predators approach and flee only as a last ditch effort to escape.

Gallinaceous birds generally have well developed afterfeathers (hypopennae). Peafowl do not have afterfeathers. In some cracids, the vanes of the first primaries are curved and narrow, which, when a bird flies, produce a unique sound that is used to mark its territory.<sup>28</sup>

Most gallinaceous birds molt once a year, generally after the breeding season. Gallinaceous birds retain their ability to fly during a molt. The secondaries are molted in a divergent pattern from an inner starting point. The rectrices are molted randomly.<sup>33</sup> The Willow Ptarmigan lives in a subarctic-type habitat and molts three times a year in order to adapt to color changes in the environment, with the winter plumage being mainly white. Some grouse (capercaillies and ptarmigans) even molt the horny sheath (rhamphotheca) of the bill (in small pieces) after the breeding season. Ptarmigans also replace their nails.<sup>17</sup>

Some birds (notably grouse, pigeons) undergo a stress-induced physiologic response when attacked by predators that results in release of the feathers (the shock or fright molt). The predator or handler is left with a collection of feathers and the bird escapes.<sup>14</sup>

Gallinaceous birds normally fly at a low level, have a high frequency wing flap and tire quite rapidly. Their flight is often limited to gliding for short distances. Some species lead a nomadic life. Birds that dwell in high mountainous regions in the summer usually move to lower altitudes in the winter. The only true



migratory gallinaceous birds are the Common Quail and the Japanese Quail. Some gallinaceous birds move by running, which is assisted by quick flapping of the wings. A normal cruising speed for the Common Pheasant would be 20.5 mph (= 33 km/h) while the Common Turkey cruises through the forest at 15 mph (= 24 km/h). The nidifugous chicks of the gallinaceous birds are able to fly shortly after hatching. The chicks of the phasianids first attempt to fly at the age of ten to sixteen days, and the cracid chicks start to fly three to four days after hatching. Megapode chicks, which are not tended by their parents, are able to fly short distances just after hatching.<sup>28</sup>

### Locomotor System

The furcula (wishbone) of the domestic fowl is V-shaped and has a ventral process (see Figure 12.32). In the Crested and Plumed Guinea fowl, an indentation exists at the junction of the two clavicles. This indentation holds the U-shaped loop of the elongated trachea. The medial notch of the sternum extends far cranially, and the lateral and medial notches are connected by fibrous membranes. In this region, the liver is not protected by the sternum, and injections, abdominocentesis or handling procedures must be carefully performed.<sup>35</sup>

The ground-dwelling phasianids generally have a long femur, tibiotarsus and tarsometatarsus to facilitate ambulation, while the tree-dwelling cracids have shorter tarsometatarsi. The legs of all gallinaceous birds are well muscled.<sup>35</sup> Cracids are active climbers, and other gallinaceous birds need strong feet and legs to scratch the ground in search of food. The toes of cracids and megapodes are on the same plane, whereas the first toe of the phasianids originates more proximally than the other digits. The first digit of the gallinaceous birds is oriented mediocaudally and the three other digits are directed cranially.<sup>28</sup> Some breeds of the domestic fowl have five digits (Houdans, Faverolles, Dorkins, Chinese Silk Fowl), with the additional digit being located medial to the first.<sup>33</sup>

### Respiratory System

Desert-dwelling gallinaceous birds such as sand partridges, possess well developed salt glands situated in an osseous indentation above the eyes. This extra-renal excretory organ for salt empties through a duct into the nasal cavity.<sup>36</sup>

TABLE 45.2 Respiratory Rate, Heart Rate and Rectal Temperatures of Selected Gallinaceous Birds<sup>37,36</sup>

Species	Respiratory Rate (per min)	Heart Rate (per min)	Temperature (°C)
Domestic Fowl	12-37	220-360	41.2
Domestic Turkey	28-49	93-163	40.7
Pheasant	12-37	—	—
Bobwhite Quail	—	—	44.0
Common Quail	40-85	249-494	42.2


The cocks or both genders of some gallinaceous birds have elongated tracheas. The additional length produces a U-shaped or circular loop in the trachea that lies between the skin and the muscle layer in the ventral thoracic or cranial abdominal region. In Helmeted Curassows, the loop extends to the cloaca, and in some other cracids, it extends to the caudal end of the sternum. Crested and Plumed Guinea fowl and the Common Capercaillie also have an elongated trachea. Although the function of the loop is not fully understood, it may be involved in generating deep sounds.<sup>28</sup>

The tracheobronchial syrinx of gallinaceous birds is a simple structure. The neopulmo, which is the phylogenetically younger portion of the lung, is well developed in Galliformes. A phylogenetic increase in the size of the neopulmo is accompanied by a decrease in the size of the caudal thoracic air sacs. The Common Turkey has a well developed neopulmo and has no caudal thoracic air sacs. Four clavicular air sacs are recognized in gallinaceous embryos. In the Common Turkey, only two of the four clavicular air sacs merge with the unpaired cervical air sac, and two clavicular air sacs remain distinct. In other birds, all the embryonic clavicular air sacs merge into one. With these adaptations, the Common Turkey has only seven air sacs, while most gallinaceous birds have nine air sacs: the unpaired clavicular air sac, and the paired cervical, cranial thoracic, caudal thoracic and abdominal air sacs.<sup>36</sup>

### Alimentary Tract

Most gallinaceous birds have a pointed bill (rostrum) that is used to pick up food.<sup>37</sup> In grouse, the bill is stronger and is used for cutting tough vegetable matter.<sup>5,17</sup> In gallinaceous birds, the cere is usually limited to the base of the upper bill; however, in cracids, two-thirds of the bill is covered by the cere.<sup>28</sup>

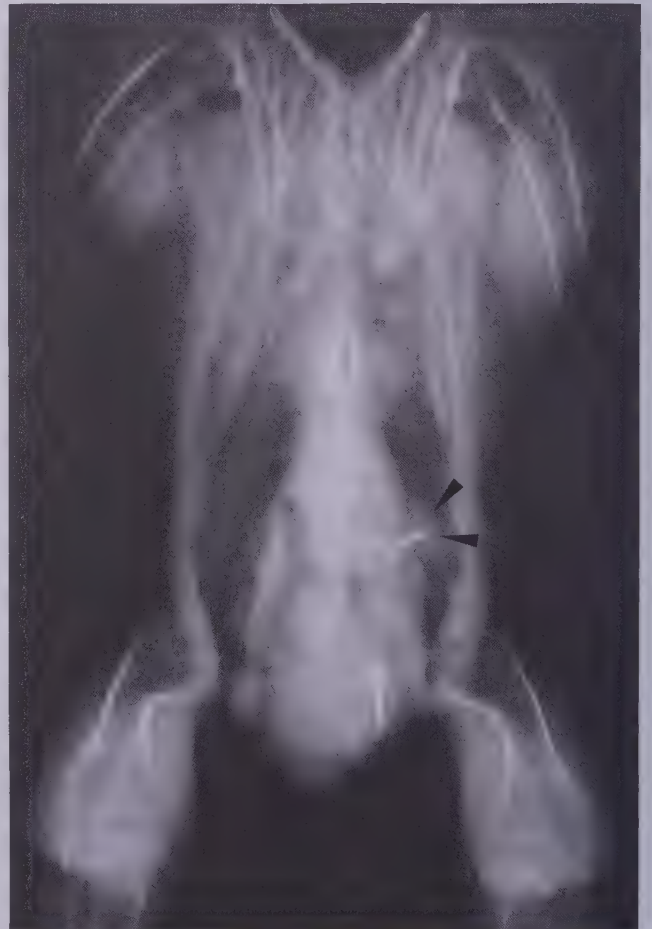The tongue of gallinaceous birds is shaped like an acute triangle, is stabilized by a bone and has no



intrinsic musculature. Most gallinaceous birds have a crop.<sup>37</sup> This esophageal diverticulum is missing in small cracids and snowcocks, and in its place is a slight bulge in the diameter of the esophagus or only an increased stretchability of the esophagus.<sup>28</sup> The Sage Grouse and some other North American grouse use a diverticulum in the middle part of the esophagus for territorial display and not for the storage of food. During display, the “inflatable esophageal air sacs” are inflated to expose featherless, brightly colored skin. The organ may also play a part in amplifying the voice.<sup>5,17</sup>

The ventriculus and its associated musculature is well developed in most gallinaceous birds (Figure 45.2). Grouse and snowcocks, which eat extremely rough food, possess the most heavily muscled ventriculus. The Sage Grouse, which feeds on soft food, has a thin-walled ventriculus.<sup>5,17,28</sup>

The secretory ducts of the liver and the pancreas open into the duodenum. Gallinaceous birds have a



**FIG 45.2** Most gallinaceous birds have a well developed ventriculus with its associated musculature. Note the density of the thick ventriculus (open arrows) containing a partially digested screw and grit. In this case, a peafowl hen was presented for weight loss and regurgitation of several days' duration. An ingested wire had penetrated the proventricular mucosa. The formation of a granuloma (arrows) at the end of the foreign body had prevented the wire from penetrating through the proventriculus. A proventriculotomy was used to remove the wire.

gall bladder and two bile ducts. In the domestic fowl, the pancreas extends to the apex of the duodenal loop and generally has three secretory ducts. The largest pancreas is found in gallinaceous birds that feed on grain.<sup>37</sup>

All gallinaceous birds have well developed ceca. Fluid and small food particles are transported into the cecal lumen by peristaltic movements of the small intestine and antiperistaltic movements of the rectum. The contents of the ceca are dark-colored and have a sticky consistency.<sup>10</sup> The size of the ceca will increase or decrease depending on the amount of crude fiber in the diet.<sup>15,27</sup> In some species, bacterial digestion of cellulose occurs in the ceca,<sup>12</sup> and species like grouse and snowcocks that feed on foods with high amounts of crude fiber have particularly well developed ceca.<sup>28</sup>

The cecal flora probably plays an important role in the synthesis of vitamins and the metabolism of nitrogen.<sup>9</sup> Uric acid that enters the cloaca is transported into the ceca by antiperistaltic movements of the rectum and is used for the synthesis of bacterial amino acids.<sup>6</sup> The ceca are usually emptied once a day, typically in the morning.<sup>28</sup>

### Urinary and Reproductive System

The testicles are generally yellowish or white, but can be pigmented in some species like the Common Capercaillie or in some breeds of the domestic fowl. The testicles enlarge during the breeding season. Fertile semen is not produced between breeding seasons. The ductus deferens and, in some species, an enlarged area of the caudal ductus deferens, serve as reservoirs for the storage of semen. Gallinaceous cocks have a non-erectile phallus.<sup>38</sup>

## Husbandry

Most gallinaceous birds are best maintained in combination indoor and outdoor aviaries and can live to 6 to 20 years depending on the species (Table 45.3) In general, the available space should be as large as possible. In some countries the minimum areas are stipulated by law.

**TABLE 45.3** Longevity of Selected Gallinaceous Birds<sup>28,39</sup>

Bird	Years
Peafowl	Approx. 20
Bobwhite Quail	Approx. 6
Grouse	8-10
Common Pheasant	10-18
Cracids	20 and more

A pair of pheasants can be maintained and bred in an aviary with a floor space 4 by 6 meters with an additional 4 square meter shelter. A Common Pheasant cock with 5 to 6 hens needs 30 to 40 square meters. An aviary for peafowl should be at least 3 meters wide, 3 meters deep and 3 meters high. These species are best maintained in open-air enclosures or big gardens. One pair of Bobwhite or California Quail needs a minimum of 1.5 m x 1.5 m floor space.<sup>28</sup> For grouse, small aviaries measuring 4 meters in depth and 8 meters in width are recommended, because these birds may injure themselves if they fly into netting at the high speeds attained in larger flights.<sup>5</sup>

Many Galliformes prefer to roost in elevated positions, making the height of an aviary important. Shelters should be provided to protect birds from sun, wind and rain. Tropical or subtropical species maintained in cold climates require an indoor aviary or, if kept outdoors in winter, a heated shelter. The mesh size of netting should be small enough to prevent a bird from placing its head through the mesh. It should also prevent the smallest predators from entering the aviary. Some gallinaceous birds, especially the Common Pheasant, fly straight up when panicked. For this species, the top netting in an enclosure should be loose to provide some give and reduce the chances of head and neck injuries. An opaque barrier can be placed at the back of the aviary, extending up to one-half of the height, to provide extra visual security for the birds.<sup>28</sup>

Ground-dwellers like some quail, some partridges and some francolins do not need elevated perches. Perches should be placed far enough from walls or wire netting to prevent the tail or wing feathers from contacting these surfaces. Peafowl, Reeve's Pheasant, argus pheasants and Phoenix Fowl require especially high perches, three to four meters above the ground, to accommodate their long tail feathers. Sharp corners should be avoided in designing the aviary. Curved corners or dense bushes planted in the corners reduce the possibility of trauma.<sup>1,28</sup>

Shrubs also help to landscape an aviary and provide shelter for the birds; however, the aviary should not

be overplanted. Too many plants will make an aviary difficult to clean. Natural turfs are attractive, but are not recommended when keeping birds that are highly susceptible to infectious diseases. An aviary with a concrete floor that is covered with an exchangeable layer of sand meets the needs of sensitive species (like grouse or the Cheer Pheasant) and is better than natural soil. Plants may be grown in containers that are removed when the aviary needs cleaning.

Snowcocks need large rocks for perching and shaping their bills. Some species like monals, eared pheasants and the Cheer Pheasant use their upper bill to search the soil for roots and insects. If these birds are maintained on artificial substrate, natural abrasion of the bill will not occur and manual trimming will be necessary. Gallinaceous birds do not bathe in water. Most gallinaceous birds like to take dust or sand baths. The placement of abrasive materials on the plumage may function to lightly abraid and polish the edges of the feathers, and may help reduce the number of external parasites as long as the sand itself is not contaminated. Insect powders should be used only if they are known to be nontoxic for the species concerned and only if the birds in fact have parasites. In the winter, Willow Ptarmigan bathe in the snow.<sup>28</sup>

Various bird species should generally not be mixed in one aviary because of possible interspecific aggression and the potential transmission of infectious agents. If species are combined, it is best to mix birds that do not compete for the same food or biotope. Ground-dwelling gallinaceous birds can be combined with bush- or tree-living species like thrushes, babblers, starlings, bulbuls and doves (with the exception of the Ground Pigeon); however, mixing of species is not recommended. Predatory species, including birds that feed on eggs, should not be combined with gallinaceous birds.

Silver Pheasant, eared pheasants, Golden Pheasant, Lady Amherst's Pheasant, Elliot's Pheasant, Swinhoe's Pheasant and Indian peafowl can be maintained in open-air enclosures that are fenced but not covered. Birds in open-air enclosures must have sufficient hedges, bushes or trees for cover. Higher trees should be available for roosting. Fruit trees or oaks (some are poisonous) provide a food source as well as cover. The flight capacity of a bird should be reduced by clipping the wings before introducing it to new surroundings.

Losses to predators can occur in open-topped facilities, particularly with respect to chicks. Rare species should not be maintained in an open-topped enclosure. A breeder who uses open-topped enclosures should expect that the loss of a bird to a predator is the responsibility of the breeder and not the fault of the predator. Some gallinaceous birds are noisy, especially the Indian peafowl and guinea fowl during the breeding season, and should be maintained in secluded areas to avoid complaints from neighbors.

## Nutrition

Many diseases and problems in captive Galliformes are directly or indirectly related to malnutrition. Breeders of gallinaceous birds should be aware of the natural foods consumed by any species maintained in captivity. Conclusive data on the nutritional demands (with respect to maximal egg or meat production and not for longevity and appearance) is available only for the domestic fowl, domestic turkey and the Japanese Quail. Some information is available for the domestic guinea fowl, and less has been determined for the Common Pheasant. All nutritional guidelines for other gallinaceous birds are based on experience.

Generally, the protein requirement increases at the beginning of the mating season because of egg and semen production. After the breeding season, the amount of protein in the feed should be gradually reduced. With any change in the diet, the new feed should be mixed slowly into the daily diet until the conversion is complete.

### "Easy" Birds

Many gallinaceous birds are omnivorous. The nutritional requirements of Common Pheasant, Golden Pheasant, Lady Amherst's Pheasant, Silver Pheasant, peafowl, guinea fowl, turkeys, partridges and New World quail are relatively easy to provide. Commercial diets for domestic fowl, domestic turkey, Common Pheasant and Japanese Quail are available in many countries. Pellets designed for turkeys can be used in species without special requirements. Adding fresh green plants to the diet provides the birds with nutritional diversity. Grass or corn silage can also be offered in small quantities. During the breed-

ing season, the diet should contain 20 to 25% crude protein. Outside the breeding season, a maintenance diet containing less than 20% crude protein is best. Commercial diets for domestic turkey are usually better suited for pheasants than diets developed for domestic fowl. Feeding is best accomplished by providing small portions of the diet several times a day in the non-breeding season and offering food *ad libitum* during the breeding season.<sup>28,31</sup>

Most New World quail are primarily seed-eaters and are easy to feed. Forest-adapted species may be largely insectivorous and have higher and more specific protein requirements in comparison to other gallinaceous birds.<sup>28</sup> Cracids are mainly, but not exclusively, vegetarians. They can be sustained on pellets containing 21% crude protein supplemented with fruits but no grains. During the breeding season, they are fed soybean paste, chopped hard-cooked eggs, chopped meat or mealworms (larvae of the meal beetle).<sup>25</sup> Megapodes can be fed a commercial poultry diet.<sup>28</sup>

#### Birds with a High Protein Requirement

Some gallinaceous birds like peacock pheasants, argus pheasants and the Roulroul (Crested Wood Partridge) do best with high-protein diets. In addition to high-protein turkey or pheasant diets, adult peacock pheasants should be fed mealworms, chopped meat, fruits and a small quantity of grain. Green plants are rarely consumed by these species. The Roulroul is fed a commercial soft feed for insectivorous birds mixed with live insects, chopped hard-cooked eggs and chopped meat. The primarily meat diet of these birds results in an odoriferous feces.<sup>28</sup>

#### ■ "Difficult" Birds

Some gallinaceous birds consume almost exclusively vegetable material. The Koklass, the Blood Pheasant, snowcocks, tragopans and grouse are examples. Feeding these species with game bird pellets or, even worse, with commercial diets for domestic fowl and turkeys, results in obesity, reduced fertility and imbalances in the intestinal microflora. These species should be maintained only where natural-type foods are available year round. These gallinaceous birds should be fed large amounts of fresh vegetables. Pellets should be provided only in small quantities, if at all. Koklass naturally feed on ferns, grasses, leaves, mosses, buds and berries. In captivity they should be provided soft green plants, fruits and berries and no grains. In the summer, grasses and lucerne can be provided. Spinach, romaine lettuce and fresh, frozen

vegetables can be substituted in the winter months. Free-ranging Blood Pheasants feed on mosses, lichen, ferns, grass tips and conifer needle-buds. They browse constantly in planted aviaries. Snowcocks eat mostly grasses and leguminous plants. Their chicks feed on these plants immediately after hatching.

Tragopans consume oak trees, bamboo sprouts, grasses, mosses, oaknuts, berries and a few insects. In captivity, tragopans can be fed lucerne, grasses, cucumbers, apples and different kinds of berries.<sup>28</sup> In the spring, summer and autumn, grouse feed on a variety of plants. In the winter, most grouse species are restricted to consuming one or a few plant species. During the winter season, the Spruce Grouse, capercaillies and other grouse species feed almost exclusively on conifer needles, the Black Grouse on birch buds, and ptarmigans on buds from different deciduous trees (birch, alder, willow).

Captive grouse should receive natural foods or at least large amounts of leaves, grass and berries supplemented with a limited quantity of pellets and grain. Capercaillies and ptarmigans require a diet high in crude fiber.<sup>5,17</sup> Even with strict attention to the diet, the bacterial fecal flora in capercaillies in captivity is similar to the fecal flora of the domestic fowl, and differs substantially from the fecal flora of free-ranging capercaillies.<sup>30</sup> The tannin and essential oil content of natural food plants may support the growth of autochthonous intestinal flora in free-ranging grouse.<sup>29</sup> In the Sage Grouse, leaves and sprouts of the North American Big Sagebrush are the sole winter food and the main portion of food in the summer.<sup>5,17</sup>

Some commercial poultry diets contain coccidiostatic agents. Halofuginone is toxic for the Common Pheasant, guineafowl and the Common Partridge. Monensin is toxic for guineafowl.<sup>14</sup> Commercial diets for the Common Turkey contain antflagellates. The presence of antimicrobial agents can be life-threatening in species that depend on a functional cecal flora and fauna (eg, grouse) for proper digestion. In general, the effects of coccidiostats and other medical feed supplements on gallinaceous birds have not been sufficiently studied. It is safer to provide food without these potentially toxic supplements.

All gallinaceous birds should have access to grit. The grit container should be emptied and refilled regularly because birds select only stones that are suitable for their body mass. Pellets or complete rations have an adequate supply of calcium and should not

be supplemented with lime or crushed shell. Fresh, clean water must be available at all times for all species.

### Chicks

During their first few weeks of life, free-ranging gallinaceous chicks feed mainly on live invertebrates like insects, larvae of insects, worms and snails in order to obtain the protein levels needed to sustain rapid growth. Starting at five to six weeks of age, the protein requirements begin to decrease, and the intake of carbohydrates increases to meet energy requirements. By six months of age, most young gallinaceous birds have reached a mass equivalent to that of adults. The quantity of carbohydrates in the diet must then be reduced to prevent obesity.

Feed should be provided to newly hatched chicks on a large flat plate on which they can move around and practice picking. By five to seven days of age, food can be offered in larger containers. The change from the plate to larger containers should occur by offering feed in both containers at the same time. Small chicks may drown in large water containers. Placing stones or glass marbles in the container will reduce losses.

Chicks of unpretentious species (Common Pheasant, peafowl, guineafowl) are initially fed a starter diet like turkey starter (28% crude protein) and are transferred to a lower protein diet (18% to 20% crude protein) from the eighth to eighteenth week of age.<sup>31</sup>

Chicks of the vegetarian species are difficult to feed. It is best to provide these birds with foods that are similar to those eaten by their free-ranging conspecifics. A diet composed of turkey starter mixed with mealworms, ant cocoons, chopped hard-cooked eggs, diced romaine lettuce, spinach, dandelion and other green plants is a viable substitute. In several species (some grouse), chicks obtain food by picking at the ground and by cutting off parts of plants with the bill. In these species, it is important that chicks be provided intact plants that are placed in the ground or tied in bundles to facilitate natural food-gathering behavior.<sup>5</sup> Chicks that are to be released into the wild must be introduced to their natural foods to prevent starvation. Perhaps chicks are imprinted with food shapes and colors, or at the least, they learn what foods to consume from the hen.

The chicks of some gallinaceous birds will not pick downwards in the first days of life. This is because

peacock pheasants, Crested Argus, Great Argus and some other gallinaceous hens feed their chicks for several days after hatching. Argus pheasant chicks can be enticed to pick by offering live food (mealworms). Monal chicks fed mealworms will pick at their siblings' toes.<sup>28</sup>

## Reproduction

Some gallinaceous birds breed readily in captivity while others rarely reproduce. Breeding failures are an indication that the birds are not happy or healthy, and that the natural conditions of the bird are not being sufficiently simulated. Some pheasant and quail species are approaching a level of domestication that is advantageous for both the captive animal and the breeder. Comparatively, "semi-domesticated" animals are of no value if offspring are to be released to the wild with the intent of reintroducing genetic diversity into dwindling populations. Genetic selection and breeding to achieve color variants increase the expression of genetic abnormalities, semilethal factors and susceptibility to disease. The clutch size and incubation times for commonly maintained gallinaceous birds are listed in Table 45.4. Parameters for artificial incubation are listed in Table 45.5.

### General Considerations

Gallinaceous birds to be used for breeding purposes should be introduced to each other before the breeding season in surroundings that are novel to all the candidates concerned. The female should be introduced to the enclosure a few hours prior to the male. In some species, it is possible to keep several males together if there are no females present. If females are present, only one male should be housed in an aviary or in one compartment. In monogamous species, only a single pair should be housed together.

Males of some species are very aggressive, and during the breeding season may attack other males, other bird species or even the keeper. Pursuit by the male and mock escape by the female is normal behavior in some species like eared pheasants and francolins. If there is insufficient space for the hen to escape, she may be injured or killed by the cock. Debeaking or restricting the flight capabilities of the male can prevent injuries to the hen, but are inferior

TABLE 45.4 Clutch Sizes and Incubation Times of Gallinaceous Birds<sup>28</sup>

	Species	Clutch Sizes	Incubation Time (days)
<b>Megapodiidae</b>			
	<i>Alectura lathami</i>	25-30	46-54
<b>Cracidae</b>			
	<i>Ortalis</i> spp.	3	26-28
	<i>Penelope</i> spp.	2-3	27-29
	<i>Aburria</i> spp.	2-3	unknown
	<i>Chamaepetes</i> spp.	unknown	unknown
	<i>Penelopina</i> sp.	2	unknown
	<i>Oreophasis</i> sp.	2	unknown
	<i>Nothocrax</i> sp.	2	28
	<i>Mitu</i> spp.	2	29-30
	<i>Pauxi</i> spp.	2	30
	<i>Crax</i> spp.	2	29
<b>Phasianidae</b>			
<b>Numidinae</b>	<i>Guttera</i> spp.	8-10	unknown
	<i>Numida</i> spp.	8-12	27
	<i>Acryllium</i> sp.	10-14	23-24
	<i>Agelastes</i> spp.	12	unknown
<b>Pavoninae</b>	<i>Afropavo</i> sp.	3-4	26-27
	<i>Pavo</i> spp.	3-5	28-30
<b>Meleagridinae</b>	<i>Meleagris</i> spp.	8-15	28
<b>Argusianinae</b>	<i>Polyplectron</i> spp.	2	18-23
	<i>Rheinardia</i> sp.	2	25
	<i>Argus</i> sp.	2	24-25
<b>Phasianinae</b>	<i>Chrysolophus</i> spp.	5-12	22-23
	<i>Phasianus</i> sp.	8-12	22-24
	<i>Graphephasianus</i> sp.	6-12	24
	<i>Symaticus</i> sp.	7-15	24-25
	<i>Calophasis</i> spp.	6-8	25-28
	<i>Lophura</i> spp.	5-15	22-25
	<i>Crossoptilon</i> spp.	4-14	24-28
	<i>Catreus</i> sp.	9-14	26
<b>Lophophorinae</b>	<i>Lophophorus</i> spp.	4-5	27
<b>Pucrasiiinae</b>	<i>Pucrasia</i> sp.	5-7	20-21
<b>Ithagininae</b>	<i>Ithaginis</i> sp.	5-12	27
<b>Gallinae</b>	<i>Gallus</i> spp.	5-8	19-21
<b>Tragoponinae</b>	<i>Tragopan</i> spp.	4-10	28-31
<b>Galloperdicinae</b>	<i>Galloperdix</i> spp.	2-5	23
<b>Ptilopachinae</b>	<i>Ptilopachus</i> sp.	4-6	unknown
<b>Phasianidae</b>			
<b>Percicinae</b>	<i>Lerwa</i> spp.	5-7	unknown
	<i>Tetraogallus</i> spp.	5-8	28
	<i>Tetraophasis</i> spp.	4	unknown
	<i>Tropicoperdix</i> spp.	unknown	unknown
	<i>Arborophila</i> spp.	3-5	20-21
	<i>Perdix</i> spp.	8-20	24-25
	<i>Alectoris</i> spp.	8-14	24-26
	<i>Bambusicola</i> spp.	4-6	18-20
	<i>Francolinus</i> spp.	4-8	19-21
	<i>Pternistis</i> spp.	3-9	18-20
	<i>Scleroptila</i> spp.	3-6	22
	<i>Dendroperdix</i> spp.	4-9	19
	<i>Peliperdix</i> spp.	2-6	unknown
	<i>Ortygornis</i> sp.	4-8	18-19
	<i>Perdicula</i> spp.	4-8	22
	<i>Cryptoplectron</i> spp.	4-7	16-18
	<i>Ammoperdix</i> spp.	8-14	22-24
	<i>Synoicus</i> sp.	4-12	20-22
	<i>Coturnix</i> spp.	7-14	16-20
	<i>Margaroperdix</i> sp.	5	unknown
	<i>Caloperdix</i> sp.	8-10	18-20
	<i>Melanoperdix</i> sp.	5	unknown
	<i>Rollulus</i> sp.	4	18-20
	<i>Haematortyx</i> sp.	8-9	unknown
	<i>Rhizothera</i> sp.	5	unknown
<b>Odontophorinae</b>	<i>Colinus</i> spp.	7-28	22-23
	<i>Callipepla</i> spp.	9-17	22-23
	<i>Oreortyx</i> sp.	6-15	24-25
	<i>Philortyx</i> sp.	8-12	22-23
	<i>Dendrortyx</i> spp.	4-7	28-30
	<i>Odontophorus</i> spp.	4-5	26-27
	<i>Dactylortyx</i> sp.	5	unknown
	<i>Cyrtonyx</i> spp.	6-16	24-25
<b>Tetraoninae</b>	<i>Tympanuchus</i> spp.	5-17	24-25
	<i>Bonasa</i> sp.	11	24
	<i>Tetrastes</i> spp.	7-11	23-25
	<i>Centrocercus</i> sp.	7-13	25-27
	<i>Dendragapus</i> sp.	7-10	24-25
	<i>Falcipecten</i> spp.	4-10	21-22
	<i>Lagopus</i> spp.	6-9	20-23
	<i>Lyrurus</i> spp.	7-10	26-27
	<i>Tetrao</i> spp.	5-12	26

TABLE 45.5 Parameters for Artificial Incubation of Some Gallinaceous Birds<sup>26,28</sup>

Species	Incubation Chamber		Hatching Chamber	
	Temp. (°C)	Humidity (%)	Temp. (°C)	Humidity (%)
Common Pheasant	37.5	60	37.0	85
California Quail	38.5-39	50-60	-	80
Common Capercaillie	37.5	60-70	36.5-37	80-90
Black Grouse	37.4	55-60	-	85-90
Ruffed Grouse	37.5	60-65	-	70-75
Chukar Partridge	37.5	65	37.0	85

procedures to providing adequate space for a pair of birds to behave normally. Densely planted aviaries that provide a hen with areas to hide may still have inherent problems. Fiberglass panels leaned against the wall or concrete tubes provide similar protection and are easy to clean.<sup>28</sup>

For species in which there are substantial differences in body size between the genders, aviaries can be designed to allow the hens to visit the cock when she wishes. Small holes, just big enough for the hen, are used to connect adjacent enclosures. This allows the hen to enter the cock's enclosure, while preventing the cock from entering the hen's area. This is an effective method for breeding birds like the Common Capercaillie.<sup>5</sup> In some species, the hen chooses the most attractive of several cocks and if only one cock is available, breeding may not occur if the hen does not like the cock. In some species, the visual or acoustic presence of other males is necessary to stimulate display and mating behavior.

Most gallinaceous birds incubate eggs on the ground and should be provided with flat trays containing moss, foliage or hay for nesting material. Tragopans, the Congo Peafowl, the Bronze-tailed Peacock Pheasant, the Crested Argus Pheasant, the Mikado Pheasant, the Salvadori's Pheasant and the cracids nest in trees. A box placed approximately 150 cm from the ground and filled with hay and foliage can be used as an artificial nest. A slanted limb should be provided for easy access to the nest. Nests of ground- and tree-nesting birds should be inconspicuous to provide the pair with visual security but should be placed such that the birds can easily look out.<sup>28</sup>

Most gallinaceous birds are nondeterminant layers, and if the first clutch of eggs is removed, the hen will lay a second and sometimes a third clutch. Hatching is genetically determined and should not be assisted. Because gallinaceous chicks are nidifuguous, the family can stay together only if all the chicks hatch at the same time. Synchronization of the hatch dates can occur by two mechanisms: 1) The hen does not incubate the clutch until the last egg has been laid, allowing the eggs to cool (which slows the process of embryogenesis); or 2) The chicks in a clutch synchronize hatching through audible signals. This latter process occurs in species like the Japanese Quail. When sounds are heard from other eggs, the chicks increase the speed of hatching. When no sounds are heard from other eggs, the most developed chicks reduce their speed of hatching. Most gallinaceous chicks are independent by three months of age. The exception is the megapode chick, which is independent immediately after hatching.<sup>28</sup>

#### Foster Breeding

The hens of some gallinaceous birds are unreliable brooders in captivity. Cracid, Common Pheasant and nearly all species of New World quail hens are unamenable brooders in captivity.<sup>28</sup> These hens can be encouraged to produce two or three clutches per year instead of one by using foster parents or an incubator for hatching eggs. Chinese Silk Fowl and Bantams make excellent foster parents. Domestic turkey hens can be used to incubate the eggs of larger gallinaceous birds. Small and fragile eggs should be placed under Golden Pheasant hens, which are cautious brooders and excellent care-providers. During the last week of incubation, the eggs of tropical birds being raised in dry climates should be moistened with a clean mister once a day. After hatching, the hen and chicks can be placed in a small enclosure that is movable, and can be placed on fresh grassy areas on a daily basis. Chicks are prone to chilling the first few days post-hatching and must have supplemental body heat from the attending hen.<sup>28</sup>

The disadvantages of foster parenting are:

- crushing of small fragile eggs by heavy or clumsy adults;
- premature cessation of brooding if the natural incubation period of the foster hen is shorter than the fostered eggs;
- trauma or death of the chicks if the hen recognizes them to be strange (this is a particular problem when behavioral incompatibilities exist between the hen and chicks);



- transmission of infectious agents between hen and chicks.

Infanticide and disease transmission can be reduced by placing the eggs in an incubator for the last third of the incubation period (this method is often used for grouse). Generally, chicks that are to be released into the wild should be reared by a hen of the same species.<sup>5,17</sup>

For many pheasants, the percentage of carbon dioxide in the incubator must be increased up to approximately 1%, verified with a gas detector, during the last two days of incubation. This is achieved by reducing the intake of fresh air. Chicks should be taken out of the incubator immediately after hatching.

### ■ Specific Reproductive Characteristics

#### Megapodes

Megapode eggs differ from those of other gallinaeous birds, owing to the uncommon brooding biology of these birds. The eggs are not incubated by the parents but by solar heat, fermentation heat or geothermal energy. One egg can reach a size of up to 17% of the hen's body mass. The eggs are thin-shelled and contain a large yolk that is rich in lipids. Cocks or both sexes begin constructing an induction mound out of foliage and earth when the air temperature and atmospheric humidity reach a certain level. The hens lay their eggs every two to three days in previously prepared holes, which are quickly covered after oviposition. Eggs are deposited in a mound with the pointed pole downwards, and they are not turned during incubation. They do not have a fixed air chamber or chalaza.

The birds may determine the temperature of the mound, and perhaps other parameters, with the bill or tongue. The mean temperature in the incubation mound is around 34°C. The incubation mound is cooled when needed by scratching holes. This allows carbon dioxide to escape and oxygen to enter. The incubation period varies from 45 to 90 days, depending on the temperature in the mound. Brush Turkey chicks leave the mound 24 to 30 hours after hatching.<sup>28</sup> Normally, megapode chicks do not come into contact with their parents, who function only to care for the incubation mound. The chicks join their brothers and sisters who have hatched at around the same time. Megapodes are sexually mature by one year of age.<sup>28</sup>

The Australian Brush Turkey is easy to maintain and breed in captivity, and is the most common captive representative of the megapodes. This species is monogamous. In one breeding season, an Australian Brush Turkey hen lays about 25 to 30 eggs.

#### Cracids

Cracids are Central and South American species that are considered monogamous. The breeding season lasts from March until July. Most nests are well hidden in a fork or branch of a tree, but some species are ground-nesters. Only the hen incubates the eggs. A clutch consists of two to three eggs, which are rough-shelled with wide pores and a uniform white color. Newly hatched chicks are immediately able to climb trees. The family stays together until the next breeding season. Sexual maturity occurs by two years of age.<sup>28</sup>

#### Turkeys

The Common Turkey is polygamous. Behavior of free-ranging birds is dramatically different from that of domesticated breeds. The brain volume of domesticated turkeys is 35% smaller than that of their wild-type conspecifics. The nest is formed of a flat depression in the soil and may be padded with leaves, grass or twigs. The chicks are able to fly at two weeks of age. Several hens, together with their offspring, typically associate in a flock in winter. The young birds leave their mother before the next breeding season. Young turkeys of both species are sexually mature at two years of age.<sup>28</sup>

#### New World Quail

New World quail are monogamous. Both parents participate in building the nest and brooding the chicks. Young birds are sexually mature by one year of age, in some species even earlier. Outside the breeding season, the gregarious New World quail live together in large family groups (coveys). At the beginning of the breeding season, the older cocks become very aggressive toward young cocks. Captive Bobwhite Quail have become polygamous and it is possible to keep one cock with two hens, indicating the effects of domestication.<sup>18,28</sup>

#### Grouse

Some grouse species like ptarmigan, Ruffed Grouse, Hazelhen, Spruce Grouse and Blue Grouse are monogamous. In these species, cocks should not be allowed to see or hear other cocks. Hazelhen males may attack the female if a rival can be heard but not seen. Other grouse species are polygamous. In these species, the hen chooses one cock from a group of display-

ing males. One cock may be chosen to mate with several hens. Hens in captivity breed best when allowed to choose between two or more cocks. The cocks, which are housed in different compartments of an aviary, may see and hear each other if there are enough hiding places for the hens. In most grouse only the hen provides chick care. The chicks of different species can be distinguished by the varying color patterns on the head and back plumage. Most grouse are sexually mature at one year of age. Crossbreeding between different genera and species occurs in free-ranging birds. Similarities in the appearance and display behavior of hens seem to induce cocks to cross-breed. Hens will choose cocks of another species if a representative of their own species is not available.<sup>5,17,28</sup>

### Peafowl

The Congo Peafowl is monogamous. The nest is always built in a tree. Both parents care for the chicks. The Indian and the Green Peafowl are polygamous. In captivity, it is possible to keep one cock with four to five hens. The hens care for the clutch and the chicks, which mature slowly. Hens reach sexual maturity in the second year and cocks in the third year of life. The Green Peafowl is more aggressive than the Indian Peafowl, but has a more pleasant call.<sup>28</sup>

### Pheasant

Most pheasant species are polygamous. One Common Pheasant cock can be kept with five to six hens. The hens make poor care-providers in captivity. They tend to be indiscriminant in the placement of eggs and will not incubate the eggs. Young Common Pheasants are sexually mature at one year of age. Free-ranging Golden Pheasants are monogamous, but in captivity one cock can be kept with three to four hens. The hens are exceptional care-providers and de-

TABLE 45.6 Gender Determination of Selected Species of Gallinaceous Birds Without Marked Sexual Dimorphism<sup>28</sup>

Genus	Plumage Identical	Plumage Similar	Differences
<b>Megapodiidae:</b>			
<i>Alectura</i>	*		Cocks have neck appendages
<b>Cracidae:</b>			
<i>Ortalis</i>	*		Voice of cock is deeper
<i>Penelope</i>	*		In some species iris colors differ
<i>Nothocrax</i>	*		In cocks the tracheal loop is palpable
<i>Pauxi</i>	*		In hens, plumage is sometimes a red phase
<b>Phasianidae:</b>			
<b>Numidinae:</b>			
(all genera)	*		Cock's call has 3 syllables; hen's call has 2 syllables
<b>Argusianinae:</b>			
<i>Polyplectron</i>		*	Hen's plumage is dull; cocks have spurs
<b>Phasianinae:</b>			
<i>Crossoptilon</i>	*		In general, cocks have spurs
<i>Catreus</i>		*	Cocks have long, sharp spurs
<b>Ptilopachinae:</b>			
<i>Ptilopachus</i>		*	
<b>Perdicinae:</b>			
<i>Tetraoallus</i>	*	**	In some species, cocks have short spurs.
<i>Arborophila</i>	*	**	In some species, cocks have short spurs.
<i>Bambusicola</i>	*	**	
<i>Frankolinus</i>	*		
<i>Pternistis</i>	*		In some species, cocks have spurs.
<i>Scleroptila</i>	*		Cocks have spurs.
<i>Ortyornis</i>	*		Cocks have spurs.
<i>Coturnix</i>		*	
<b>Odontophorinae:</b>			
<i>Odontophorus</i>	*	**	
<b>Tetraoninae:</b>			
<i>Tympanuchus</i>		*	
<i>Bonasa</i>		*	
<i>Tetrastes</i>		*	
<i>Lagopus</i>	*		(only in winter)

\*\* Some species of the genus are identically colored and some are similar.

feed their chicks. Young Golden Pheasant hens are sexually mature within one year, cocks within two years. Lady Amherst's Pheasant cocks and hens can be aggressive during the breeding season. Only a few of the birds found in captivity are purebred. Both male and female argus pheasants, peacock pheasants and the Copper Pheasant establish and defend their own territories. Males should be introduced to females only for a short time during the breeding season to prevent aggressive behavior and traumatic injuries from both genders.<sup>28</sup>

### Junglefowl and Domestic Fowl

Junglefowl can be either monogamous or polygamous. The hens can breed year-round, but the main breeding season is from February to May in the northern hemisphere. A Red Junglefowl cock can be maintained with three to four hens. The young birds are independent at an age of four months, and sexually mature after the first year. Many domestic fowl breeds have lost their brooding behavior, and eggs must be artificially incubated.<sup>28</sup>

### Gender Determination

Many gallinaceous birds show a marked sexual dimorphism. The size (height and width), the body mass (weight), the color of the plumage, the shape of certain feathers, the presence of spurs and the length and color of the tail feathers assist in gender determination between adults of some species (Table 45.6). In some breeds of domestic fowl, fertile cocks may have plumage that resembles that of hens.

Gender can be determined by highly skilled individuals by examining the cloaca in one-day-old chicks or adults. The cloacal examination in newly hatched chicks of small bird species must be done carefully (see Chapter 46). Holding a chick too tightly can cause asphyxiation. Restraint of a chick for gender determination should start by gently pressing on the abdomen from both sides distal to the keel bone to stimulate defecation. The procedure is then similar to that described for Anseriformes (see Chapter 46).

Behavioral clues like dominance and certain mating rituals may suggest a gender, but are not always indicative. Under certain conditions the hens of some gallinaceous birds behave like, and can have plumage like, the males.<sup>19</sup> Only endoscopic examination of the gonads provides definitive determination of gender in species with similar morphologic characteristics (see Chapter 13).

### Artificial Insemination

Artificial insemination is of economic importance in the domestic turkey and domestic guineafowl. Domestic turkey cocks, like domestic fowl cocks, are fertile year-round, except during periods of extreme heat or during the molt period. Domestic guineafowl cocks are not fertile all year, and artificial insemination is used to induce year-round production.

The semen is collected by massaging the caudal region of the back or the abdomen, followed by stimulation of the cloaca. Fecal contamination of the semen may occur. It is best to collect the semen directly from the spermatic duct with a syringe and a blunted hypodermic needle. The semen may be diluted with Ringer's or Tyrode's solutions by up to a factor of three.

Avian semen has a short half-life and must be used as quickly as possible. The semen is introduced with a syringe and a blunted hypodermic needle into the hen's oviduct. It is best to inseminate the hen just after she has laid an egg. This ensures that the oviduct is open, providing the semen with unrestricted access to the infundibulum.<sup>14,39</sup>

### CLINICAL APPLICATIONS

In rare and endangered species, the production of offspring by artificial insemination might be useful in several situations:

- The semen of one cock can be used to inseminate numerous hens; however, spread of genetic defects is increased, while the genetic diversity is decreased.
- In many species, the captive production of offspring is still difficult. Cocks may not mate with the hen, or if they do, insemination may not occur. (As an example, Brown-eared Pheasants will rarely produce fertile eggs in captivity. It has been assumed that the cocks were not producing fertile semen. Artificial insemination has proven that the semen is usually fertile, suggesting that breeding problems are primarily behavioral.)<sup>40</sup>
- Different aviculturists can exchange semen from their cocks; however, this procedure can result in the spread of venereal diseases, like leukosis.
- Semen can be used from cocks that are genetically and organically healthy but have been handicapped by an injury and are no longer able to mate.

TABLE 45.7 Checklist of Infectious Diseases in Gallinaceous Birds

<b>Viruses (see Chapter 32)</b>	<i>Clostridium</i> spp. Ulcerative and necrotic enteritis ( <i>Cl. colinum</i> and <i>Cl. perfringens</i> ) Botulism (toxin of <i>Cl. botulinum</i> )	<b>Parasites (see Chapter 36)</b>
Poxviridae Avian pox	<i>Escherichia coli</i> Colibacillosis Coligranulomatosis	Protozoal Parasites: <i>Trypanosoma avium</i> <i>Spiroucleus meleagridis</i> <i>Histomonas meleagridis</i> (blackhead disease) <i>Trichomonas</i> spp. <i>Chilomastix gallinarum</i> <i>Entamoeba</i> spp. <i>Endolimax</i> spp. <i>Eimeria</i> spp. <i>Toxoplasma gondii</i> <i>Sarcocystis</i> spp. <i>Cryptosporidium</i> spp. <i>Haemoproteus</i> spp. <i>Leucocytozoon</i> spp. <i>Plasmodium</i> spp.
Herpesviridae Infectious laryngotracheitis Marek's disease	<i>Salmonella</i> spp. Salmonellosis	Metazoal Parasites
Adenoviridae Quail bronchitis Inclusion body hepatitis Egg drop syndrome = (infectious salpingitis) Marble spleen disease Hemorrhagic enteritis of turkeys Chicken splenomegaly Adenovirus infection of the Blue Grouse	<i>Klebsiella</i> spp. Klebsiella infection <i>Yersinia pseudotuberculosis</i> Pseudotuberculosis <i>Pseudomonas</i> spp. Pseudomonas infection <i>Aeromonas hydrophila</i> Aeromonas infection	Trematodes <i>Prosthogonimus</i> sp.
Parvoviridae Parvovirus infection of chickens Parvovirus-like infection of turkeys	<i>Bordetella avium</i> Bordetellosis (turkey coryza)	Cestodes <i>Davainea proglottina</i> <i>Raillietina</i> spp. <i>Amoebotaenia cuneata</i> <i>Choanotaenia infundibulum</i> <i>Hymenolepis</i> spp. <i>Metroliasthes lucida</i> <i>Fimbricaria fasciolaris</i>
Circodnaviridae Infectious anemia	<i>Campylobacter</i> spp. Avian hepatitis	Nematodes (in digestive tract) <i>Capillaria</i> spp. <i>Trichostrongylus tenuis</i> <i>Heterakis</i> spp. <i>Ascaridia</i> spp. <i>Ganglyonema ingluvicola</i> <i>Cheilospirura</i> spp. <i>Dispharynx nasuta</i> <i>Tetrameres</i> spp. <i>Subulura</i> spp.
Reoviridae Viral arthritis Other reovirus infections Rotavirus infections	<i>Borrelia anserina</i> Spirochetosis	Nematodes (in respiratory tract) <i>Syngamus trachea</i>
Birnaviridae Infectious bursal disease	<i>Treponema</i> spp. Infectious typhlitis in chickens	Nematodes (in the eye) <i>Oxyspirura</i> spp.
Togaviridae Eastern and western encephalitis Avian serositis Louping-ill Israel turkey meningoencephalitis	<i>Pasteurella</i> spp. Fowl cholera <i>Actinobacillus salpingitidis</i> Actinobacillosis <i>Haemophilus</i> spp. Haemophilus infection <i>Francisella tularensis</i> Tularemia	Nematodes (in other locations) <i>Aproctella stoddardi</i> <i>Singhilaria hayesi</i>
Coronaviridae Coronaviral enteritis of turkeys (bluecomb disease) Infectious bronchitis	<b>Mycoplasma (see Chapter 38)</b> <i>Mycoplasma</i> spp. <i>Ureaplasma</i> spp.	Acanthocephalans <i>Mediorhynchus papillosus</i>
Rhabdoviridae Rabies	<b>Chlamydia (see Chapter 34)</b> <i>Chlamydia psittaci</i> Chlamydiosis	Arthropods External parasites like lice, fleas, flies, mosquitoes, midges, and ticks occur in most gallinaceous birds. Mites occur above all in intensively reared gallinaceous birds, predacious bugs in some gallinaceous birds.
Paramyxoviridae Newcastle disease PMV-2-infection (Yucaipa) PMV-3-infection (Wisconsin) Turkey rhinotracheitis Swollen head syndrome	<b>Rickettsia (see Chapter 38)</b> <i>Coxiella burnetii</i> Query (Q) fever <i>Aegyptianella pullorum</i> Aegyptianellosis	
Orthomyxoviridae Avian influenza, fowl plague	<b>Mycoses (see Chapter 35)</b> <i>Aspergillus</i> spp. Aspergillosis <i>Candida albicans</i> Candidiasis <i>Dactylaria gallopavo</i> Dactylariosis <i>Trichophyton</i> spp. Favus	
Retroviridae Leukosis Reticuloendotheliosis Lymphoproliferative disease of turkeys	<b>Mycotoxicoses (see Chapter 37)</b> Toxins of <i>Aspergillus</i> spp., <i>Penicillium</i> spp., <i>Fusarium</i> spp. and others	
Picornaviridae Avian encephalomyelitis Turkey viral hepatitis Infectious nephritis		
<b>Bacteria (see Chapter 33)</b>		
<i>Staphylococcus</i> spp. Staphylococcosis		
<i>Streptococcus</i> spp. Streptococcosis		
<i>Mycobacterium avium</i> Tuberculosis		
<i>Erysipelothrix rhusiopathiae</i> Erysipelas		
<i>Listeria monocytogenes</i> Listeriosis		

## Restraint

Cocks with spurs can injure handlers, especially when they become increasingly aggressive during the mating season. The beak can also serve as a weapon. Although serious injuries are rare, the face and the eyes of handlers should always be protected from a bird's beak, even in small species. The legs of a gallinaceous bird should be the initial focus for restraint.

Catching gallinaceous birds in an aviary can be done gently with a hooked, long stick. The birds should never be restrained by the feathers alone. The whole body must be secured to prevent a shock molt. Shock molt is most common in tail feathers, but other feathers can be involved. Birds can be nearly "bald" after several failed restraint attempts. In larger species, the base of the wing is fixed with one hand and the legs are controlled with the other hand (see Chapter 44). The abdomen should be supported from below. If assistance is not available, a large bird can be restrained by placing it under one arm and pressing it gently against one's body.<sup>11</sup> Birds can usually be calmed by placing a loose-fitting, lightweight cotton sock over the head to reduce vision.

## Disease Considerations<sup>3,8,14,39</sup>

Gallinaceous birds are susceptible to a wide variety of viral, bacterial, mycoplasmal, parasitic, chlamydial, rickettsial and fungal agents (Table 45.7). Information on these diseases may be found in the appropriate chapters.

### Nutritional Diseases

Vitamin C deficiency does not occur in most birds; however, it has been reported in Willow Ptarmigan chicks, and may occur in other grouse chicks.<sup>16</sup> Though the chicks are able to produce endogenous vitamin C (as all gallinaceous birds probably can), the internal production is not sufficient in the first weeks of life, and has to be augmented by the intake of vitamin C from natural food plants (eg, blueberries).

Clinical signs of vitamin C deficiency are abnormal behavior, enteritis, ruffled plumage, weakness of the wings and legs, bone fractures, retarded growth and death before the age of four weeks. Characteristic necropsy findings include weight loss, pale and edematous skeletal muscles, petechial hemorrhage in the muscles and mild subcutaneous edema. Fractures in the diaphysis of the humerus, radius, ulna, femur and tibiotarsus with massive callus formation and lateral twisting of the tibia may also occur. Feeding the chicks natural food stuffs will prevent vitamin C deficiency.

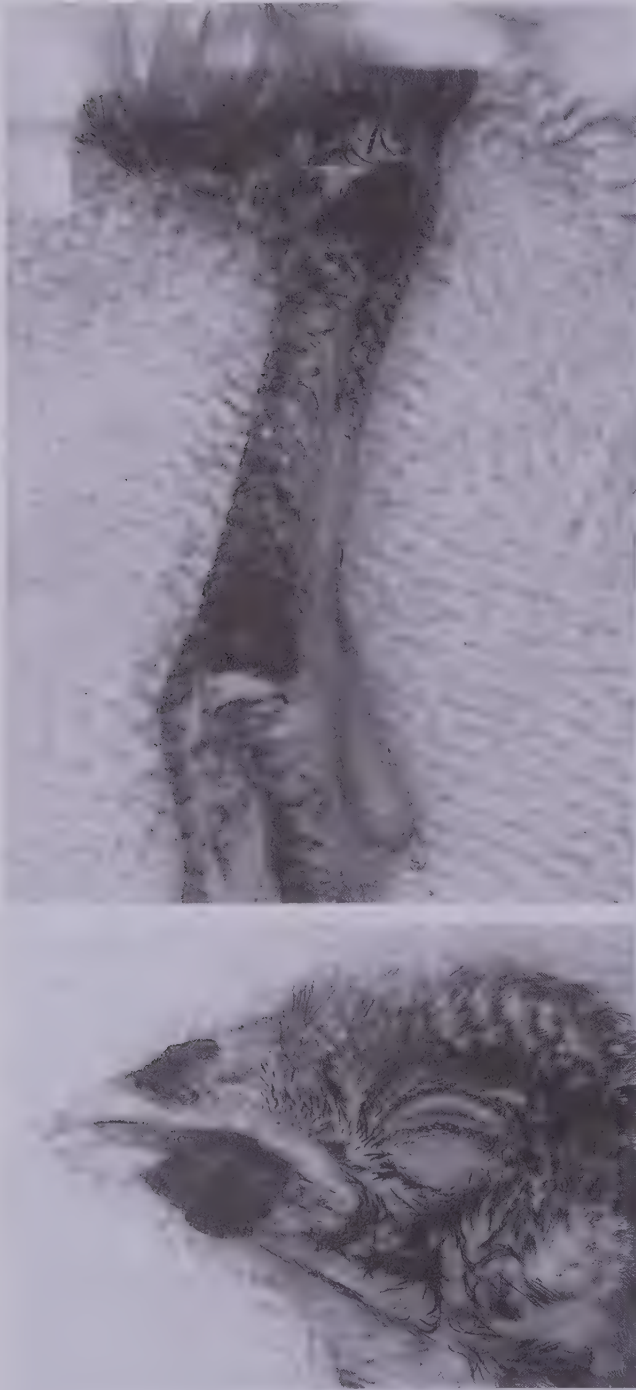
### Integument Concerns

Amputation of the comb or the wattles may be indicated following extensive injury, infection or frostbite. Adequate hemostasis is necessary to prevent fatal hemorrhage. Occasional trimming of the keratinous tip of the bill is necessary if the horny layer grows too fast, or is insufficient abrasive materials are available to facilitate normal wear. The excessive horn is pared off prudently with a sharp knife without cutting into the viable parts of the bill.

Cannibalism may occur in some Galliformes and is characterized by vent-picking, feather-pulling, toe-picking, head-picking and egg-eating. Overcrowding, incorrect feeding, an inappropriate daylight cycle, poor housing conditions (eg, high proportion of toxic gases in the air), genetic predisposition and other factors may all promote cannibalism.

Amputating the comb and wattles and "debeaking" have been used to control cannibalism; however, these control methods should be viewed as cruel and unacceptable procedures. These procedures are painful, cause permanent loss of tissue, may heal improperly or become infected and cause a change in social ranking. The bill is not only important for the uptake of food, but also has sensory functions, and is necessary for preening. Damage to the beak should be considered a substantial handicap. In most cases, cannibalism can be successfully prevented by correcting deficiencies in the birds' environment; however, once feather picking is initiated, some birds never stop. In these cases, affected birds should be separated from the remainder of the flock.


Trimming of the flight feathers in one wing can be used to prevent birds from escaping from open aviaries, or to reduce the mobility of an aggressive cock during the breeding period. Usually all but the outermost two primaries and the innermost three secondaries



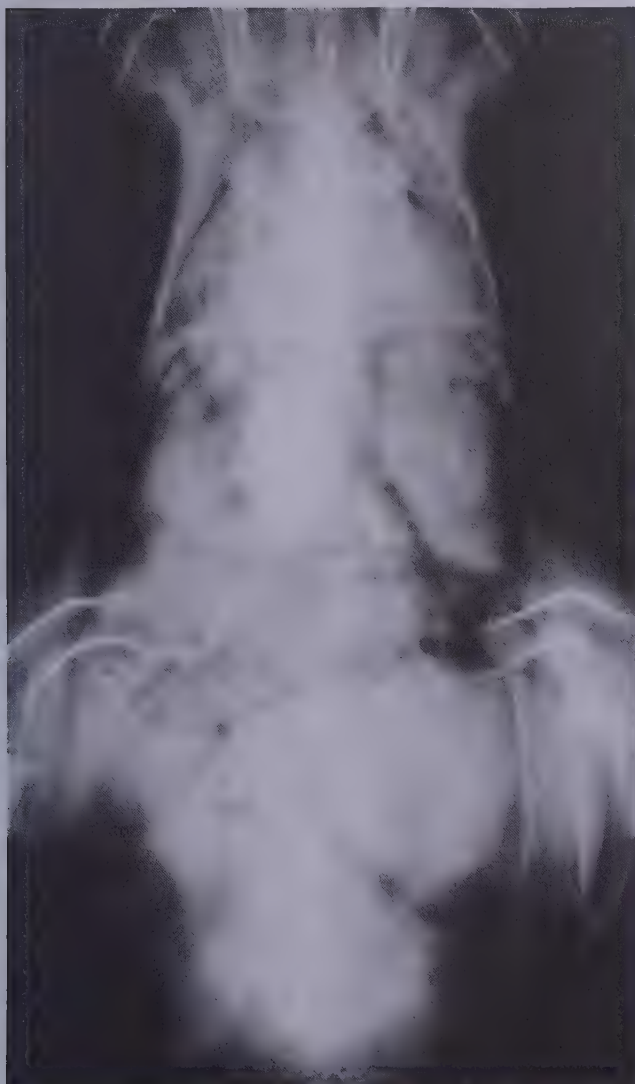**FIG 45.3** Poxvirus lesions on the legs and beak of a gallinaceous bird. The client had placed black shoe polish on the lesions, which is a commonly discussed lay treatment of poxvirus. The shoe polish will delay healing and may cause secondary infections.



**FIG 45.4** Necrotic tracheitis in gallinaceous birds is frequently caused by laryngotracheitis virus. Infected birds may develop sneezing and coughing and have audible tracheal rales. Gross necropsy findings frequently include diphtheritic tracheitis with the accumulation of necrotic debris (arrows) that may cause asphyxiation (courtesy of SW Jack).



**FIG 45.5** An adult Brown-eared Pheasant hen was presented for severe dyspnea and anorexia, which had initially been noted two days earlier when the hen produced a soft-shelled egg. Radiographs indicated gastrointestinal impaction with cranial displacement of the heart (arrows) and intestinal tract (open arrow). At necropsy, fibrous exudate and ingesta were covering the abdominal viscera. The ceca were impacted and had thickened walls. Histopathology indicated *E. coli* peritonitis with severe *Heterakis* sp. typhlitis.



daries are transected, creating an effective and cosmetic wing trim (see Chapter 1). With one wing trimmed, the bird is unbalanced and cannot gain speed during flight. Because the feathers will be replaced during the next molt, trimming must be repeated annually in adults. Under certain circumstances, it may be necessary to trim both wings. Other methods, like pinioning or cutting the short tendon of the extensor carpi radialis, make birds permanently unable to fly. The client should be made aware of the consequences of these procedures.

#### ■ *Heterakis* sp.

*Heterakis isolonche* infections have been described in a number of free-ranging and captive Galliformes. This parasite causes typhlitis with clinical signs of infection including diarrhea, weight loss and depression. Mortality rates in captive pheasants may reach 50%. The parasite invades the wall of the cecum and causes lymphocytic infiltration and granuloma formation. In pheasants, the nodules merge, leading to substantial thickening of the cecal wall. The ceca may dilate and increase in size (volume) by up to ten times (Figure 45.5).

## References and Suggested Reading

1. **Amand WB:** Husbandry of galliformes. In Fowler ME (ed): *Zoo and Wild Animal Medicine*. Philadelphia, WB Saunders Co, 1978, pp 295-296.
2. **Amand WB:** Surgical problems. In Fowler ME (ed): *Zoo and Wild Animal Medicine*. Philadelphia, WB Saunders Co, 1978, pp 304-306.
3. **Amand WB:** Disease description. In Fowler ME (ed): *Zoo and Wild Animal Medicine*. Philadelphia, WB Saunders Co, 1978, pp 309-319.
4. **Amand WB:** Clinical pathology. In Fowler ME (ed): *Zoo and Wild Animal Medicine*. Philadelphia, WB Saunders Co, 1978, pp 320-322.
5. **Aschenbrenner H:** Rauhfusshühner. Hannover, Verlag M & H Schaper, 1985.
6. **Barnes EM, Impey CS:** The occurrence and properties of uric acid decomposing anaerobic bacteria in the avian caecum. *J Appl Bact* 37:393-409, 1974.
7. **Baumel JJ, et al:** *Nomina Anatomica Avium*. London, Academic Press, 1979.
8. **Calnek BW, et al (eds):** *Diseases of Poultry*. Wolfe Publishing Ltd, 1991.
9. **Coates ME, et al:** Intestinal synthesis of vitamins of the B complex in chicks. *Brit J Nutr* 22:493-500, 1968.
10. **Fenna L, Boag DA:** Filling and emptying of the galliform caecum. *Can J Zool* 52:537-540, 1974.
11. **Franchetti DR, Klide AM:** Restraint and anesthesia. In Fowler ME (ed): *Zoo and Wild Animal Medicine*. Philadelphia, WB Saunders Co, 1978, pp 303-304.
12. **Gasaway WC:** Cellulose digestion and metabolism by captive rock ptarmigan. *Comp Biochem Physiol* 54 A:179-182, 1976.
13. **Gylstorff I:** Blut, Blutbildung und Blutkreislauf. In Mehner A, Hartfiel W (eds): *Handbuch der Geflügelphysiologie*. Gustav Fischer Verlag Jena, 1983, pp 280-393.
14. **Gylstorff I, Grimm F:** Vogelkrankheiten. Stuttgart, Verlag Eugen Ulmer, 1987.
15. **Hanssen I:** Micromorphological studies on the small intestine and caeca in wild and captive willow grouse (*Lagopus lagopus lagopus*). *Acta Vet Scand* 20:351-364, 1979.
16. **Hanssen I, et al:** Vitamin C deficiency in growing willow ptarmigan (*Lagopus l. lagopus*). *J Nutr* 109:2260-2278, 1979.
17. **Johnsgard PA:** *The Grouse of the World*. Croom Helm, University of Nebraska Press, 1983.
18. **Johnsgard PA:** *The Quails, Partridges, and Francolins of the World*. Oxford, Oxford University Press, 1988.
19. **Kaal TF:** Geschlechtsmerkmale bei Vögeln. Hannover, Verlag M & H Schaper, 1982.
20. **Keller H:** Hornringe am Sporn der Hühnervögel zur Altersbestimmung. *Lebensmitteltierarzt* 5:11, 1954.
21. **Kösters J, Korbel R:** Zur Frage des Schnabelkürzens beim Geflügel. *Tierärztl Umschau* 43(11):689-694, 1988.
22. **Korbel R:** Praxis der Injektions- und Blutentnahmetechniken am Vogelpatienten. *Tierärztl Prax* 18:601-611, 1990.
23. **Korbel R:** Zwangsmassnahmen beim Vogelpatienten. Teil 1, Teil 2, *Tierärztl Prax* 20:59-64, 164-170, 1992.
24. **Korbel R, Kösters J:** Einige von Tierhaltern geforderte oder durchgeführte Operationen an gesunden Vögeln unter tierschutzrechtlichen Aspekten. *Tierärztl Prax* 17:380-381, 1989.
25. **Lopez JE:** The cracidae. *Avic Mag* 85:210-215, 1979.
26. **Michigan State University:** *Managing gamebirds*. Extension Bulletin E 692. Resource Development Series 44. Michigan State University, 1974.
27. **Pendergast BA, Boag DA:** Seasonal changes in the internal anatomy of spruce grouse in Alberta. *The Auk* 90:307-317, 1973.
28. **Raethel HS:** *Hühnervögel der Welt*. Melsungen, Neumann-Neudamm, 1988.
29. **Schales C:** Untersuchungen über die antibakterielle Wirkung ätherischer Öle und hydrophiler Inhaltsstoffe aus Koniferennadeln auf Bakterien aus dem Kot von in Gefangenschaft gehaltenen Auerhühnern (*Tetrao urogallus* L, 1758) *in vitro*. Diss med vet, München, 1992.
30. **Schales K:** Untersuchungen über die aerobe Flora und *Clostridium perfringens* im Kot von freilebenden und in Gefangenschaft gehaltenen Auerhühnern (*Tetrao urogallus* L, 1758). Diss med vet, München, 1992.
31. **Snyder RL:** Feeding and nutrition. In Fowler ME (ed): *Zoo and Wild Animal Medicine*. Philadelphia, WB Saunders Co, 1978, pp 296-302.
32. **Sturky PD:** Body fluids: Blood. In Sturky PD (ed): *Avian Physiology*. New York, Springer Verlag, 1986, pp 102-121.
33. **Spearman RIC, Hardy JA:** Integument. In King AS, McLelland J (eds): *Form and Function in Birds*. Vol 3. London, Academic Press, 1985, pp 1-56.
34. **Vollmerhaus B, Sinowatz F:** Haut und Hautgebilde. In Nickel R, et al: *Lehrbuch der Anatomie der Haustiere*. Band V. Anatomie der Vögel. Berlin, Verlag Paul Parey, 1992, pp 16-49.
35. **Vollmerhaus B:** Spezielle Anatomie des Bewegungsapparats. In Nickel R, et al: *Lehrbuch der Anatomie der Haustiere*. Band V. Anatomie der Vögel. Berlin, Verlag Paul Parey, 1992, pp 54-154.
36. **Vollmerhaus B, Sinowatz F:** Atmungsapparat. In Nickel R, et al: *Lehrbuch der Anatomie der Haustiere*. Band V. Anatomie der Vögel. Berlin, Verlag Paul Parey, 1992, pp 159-175.
37. **Vollmerhaus B, Sinowatz F:** Verdauungsapparat. In Nickel R, et al: *Lehrbuch der Anatomie der Haustiere*. Band V. Anatomie der Vögel. Berlin, Verlag Paul Parey, 1992, pp 176-221.
38. **Waibel H, Sinowatz F:** Harn- und Geschlechtsapparat. In Nickel R, et al: *Lehrbuch der Anatomie der Haustiere*. Band V. Anatomie der Vögel. Berlin, Verlag Paul Parey, 1992, pp 224-264.
39. **Wallach JD, Boerer WJ:** Game birds, waterfowl and ratites. In *Diseases of Exotic Animals II. Medical and Surgical Management*. Philadelphia, WB Saunders Co, 1983, pp 830-889.
40. **Wiese DR, Fuller MK:** Artificial insemination in the brown-eared pheasant. *World pheasant assoc J* III, 1977-1978, pp 90-95.
41. **Wolters HE:** Ordnung Phasianiformes. In *Die Vogelarten der Erde*. Hamburg, Paul Parey, 1975-1982, pp 100-109.
42. **World Pheasant Association (WPA):** *Census 1982*.



**A**vian practitioners with a general understanding of Anseriformes are needed to care for valuable private waterfowl breeding facilities as well as backyard waterfowl. Waterfowl have generally been treated on a flock rather than an individual basis; however, a flock approach to rare birds, pets or small collections is usually not accepted by the client. Waterfowl aviaries are frequently plagued by problems associated with overstocking, poor management practices, and pathogen-contaminated ground or water.<sup>37,51,39,108</sup>

Veterinarians who plan to treat free-ranging or captive Anseriformes in the United States should be aware of pertinent federal and state laws. The Migratory Bird Treaty Act involves the US, Mexico, Canada and Japan, and provides federal protection for all free-ranging birds in the US except for resident exotic species such as the English sparrow, starling, feral pigeon and resident game birds such as pheasant, grouse and quail. It is unlawful for anyone to kill, capture, collect, process, buy, sell, trade, ship, import or export any migratory birds, eggs, nests or part thereof without first obtaining an appropriate federal permit. These regulations do not necessarily apply to waterfowl species not indigenous to North America. Most states also have their own regulations.

The state requirements for interstate shipment of Anseriformes vary. Some states require testing for *Salmonella* sp., avian influenza, exotic Newcastle disease virus and duck plague virus before an import permit is issued. The state veterinarian's office in the destination state should be contacted to determine specific requirements.

CHAPTER

46

ANSERIFORMES

John H. Olsen

## Biology

### Family and Subfamily Characteristics

Anseriformes have nostrils that connect with one another and a lower mandible with a long process at the angle. The sternum has two indentations or foramina at the rear. Two pairs of muscles are located between the sternum and the trachea. The neck is extended in flight. There are 10 to 11 primaries, the fifth secondary is absent and there are 12 to 24 tail feathers. Down feathers are numerous in the fully developed plumage. The unspotted eggs are light in color. The young are nidifugous, have a dense, downy plumage and are tended for a long time by one or both parents (except in parasitic species that lay eggs in the nests of other birds). The flamingos and the Ciconiiformes (herons, bitterns) are the nearest relatives of the Anseriformes (Figure 46.1).<sup>37</sup>

The Anhimidae are goose-sized birds of fowl-like appearance, with thick, long legs and unwebbed feet. They weigh two to three kilograms.<sup>37</sup> The bill is game bird-like with a downward hook and has none of the filtering fringes (lamellae) common in ducks. Flight feathers are molted gradually so that, like the Magpie Goose, but unlike most waterfowl, they do not pass through an annual flightless period.<sup>39</sup>

The family Anatidae has three subfamilies. Subfamily Anseranatinae contains the Magpie Goose. This bird differs from the rest of the family. The feet are slightly webbed with an unusually long hind toe adapted for semiterrestrial life. The trachea is elongated in adults of both sexes, and in adult males may reach 150 cm long. The trachea is not convoluted inside the sternum as it is in some

swans (Figure 46.2); in contrast, the trachea penetrates the area between the breast muscles and the skin in a manner comparable to that in certain species of Cracidae. The elongated trachea probably functions as an effective resonator producing low-frequency sounds.<sup>51</sup>

Breeding birds often form trios consisting of a male and two females that lay their eggs in a single nest. All the birds share incubation responsibility. Magpie Geese are the only waterfowl species to provide food

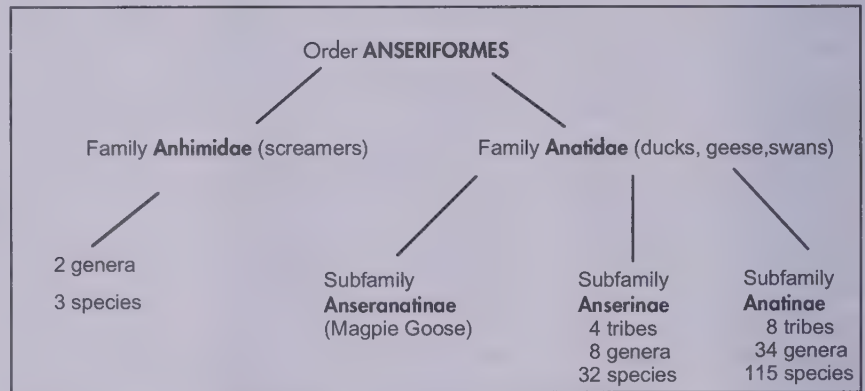


FIG 46.1 The order Anseriformes.

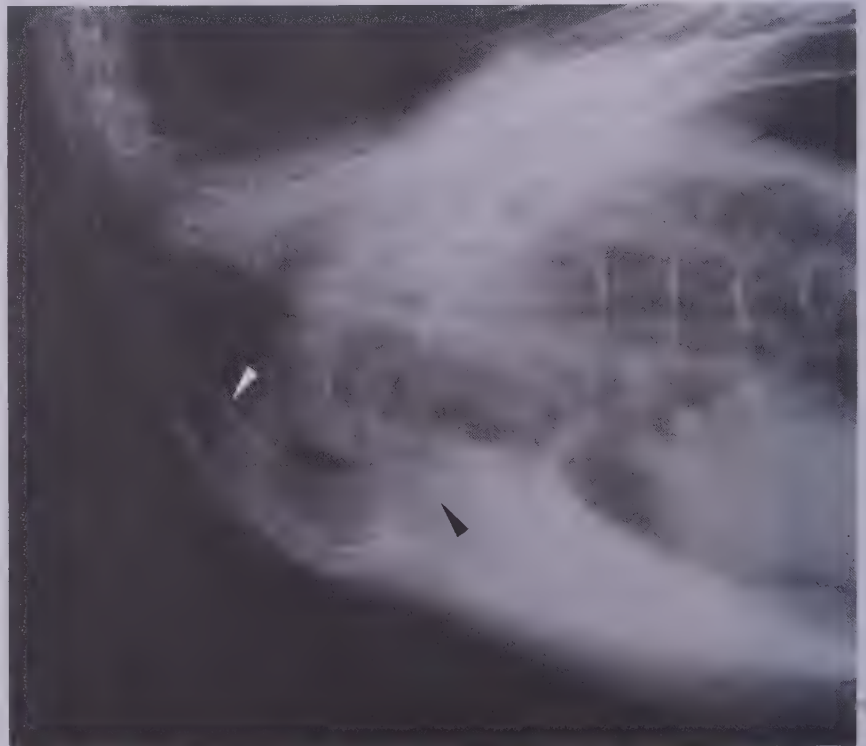


FIG 46.2 The structure of the trachea and syrinx varies among Anseriformes. A syringeal bulla may be present on the left side of the syrinx in male ducks (see Figure 12.16). In this goose, the trachea can be seen to be more elongated (arrows) than in companion birds, and the sternum is broad and less convex than in many avian species.

to their young. The adults deposit proper foodstuffs in front of their downy chicks.<sup>51</sup>

The subfamily Anserinae includes Whistling Ducks, swans, true geese, Cape Barren Geese and Freckled Ducks. These species undergo a complete annual molt following the breeding season. The flight feathers are shed almost simultaneously so the birds are unable to fly for a period of about three to six weeks. The front toes are fully webbed except in two semiterrestrial species of geese. In all species, the plumage is monomorphic and all species lack iridescent coloration, even on the wings.<sup>51</sup>

Subfamily Anatinae includes Sheldgeese, Shelducks and all the typical ducks. Most of the members of this subfamily molt the body feathers twice each year. Consequently, the breeding (nuptial) and non-breeding (winter or eclipse) plumage are distinct. In some species the breeding plumage of the male closely resembles that of the female, but more often, the genders have dimorphic plumage. There is frequently a gender difference in calls as a result of a difference in the structure of the syrinx and sometimes the trachea. The front surface of the lower tarsus has a linearly arranged (scutellated) scale pattern not seen in the other subfamilies. Iridescent coloration is frequently present in the plumage, particularly among males. The male of sexually dimorphic species is typically larger, more brilliantly patterned and more aggressive. The plumage of juveniles and the non-breeding males generally resembles that of the adult female. The patterns of the downy young are often quite contrasting and distinctive, and usually include spotting and striping on the head and back. Males of this subfamily do not assist in incubation but, depending on the tribe, participate in brooding the chicks.<sup>51</sup>

### ■ Diversity of Anseriformes

Waterfowl species range in size from the diminutive Pygmy Goose (300 g) to the Trumpeter Swan (13.6 kg), which has a wing spread approaching 2.5 m (Table 46.1). Normal body weight can vary tremendously with the season.

Although Anseriformes generally surface feed, they may also graze or feed by diving. Some species are omnivorous while others are strictly herbivorous. For example, the Ruddy Shelduck has been observed eating carrion, whereas the algae-eating Pink-eared Duck of Australia has a highly specialized bill for filter feeding.<sup>108</sup>

A few species are widely distributed, such as the Northern Pintail, which is found over nearly the entire northern hemisphere. The Madagascar White-eye, on the other hand, occurs on only a few island lakes. Ducks are usually sexually dimorphic (exceptions: Pekin, Muscovy, American Black and Mexican). Swans and geese are usually sexually monomorphic (exceptions: Magellan and Kelp geese).<sup>56</sup>

Most waterfowl are excellent swimmers, with webbed front toes and short legs. The short femurs, long tibiotarsal bones and extremely short tarsometatarsus bones are adapted for powerful swimming and account for the poor ambulatory abilities and characteristic waddling gait when Anseriformes attempt to walk. The normal speed of swimming for waterfowl is about two to three miles per hour.<sup>108</sup> Most diving ducks stay within 10 to 20 feet of the surface. The Oldsquaw and King Eider are reported to dive at least 180 feet.<sup>108</sup>

Waterfowl are thickly feathered and have compact waterproof plumage and a dense coat of insulating down. A Whistling Swan may have 25,000 feathers, a Green Wing Teal, about 11,500. They have a highly developed uropygial (oil) gland. Frequent preening and oiling is imperative to keep feathers in prime condition so that chilling and sinking do not occur. Waterfowl are generally powerful fliers that cruise with their necks and legs extended. The wing beat of swans is approximately 160 per minute, while some ducks may exceed 300 wing beats per minute. The Canvasback Duck, one of the fastest waterfowl, has been clocked at 70 mph in flight, but normally cruises at 25 to 35 mph. During migration, waterfowl often cruise at 1000- to 3000-foot elevations, but may go as high as 20,000 feet or more.<sup>108</sup>

Ducks have anatomic variations in the syrinx that should not be misinterpreted as pathologic lesions. In most ducks, only the male has a left-sided enlargement of the syrinx (syringeal bulla) (see Figure 12.16). This structure may be responsible for courtship vocalizations. Vocalizations are also used as communication for defense, warning, recognition and flocking signals.<sup>84,108</sup> A syringeal bulla is not present in geese and swans. In swans the trachea is elongated and in the Trumpeter Swan it extends into the sternum, turns on itself and reenters the syrinx (see Figure 12.17).

Many waterfowl species roost on shore where they typically sleep while standing on one leg with the head turned back and the bill inserted into the scapu-

TABLE 46.1 Anseriformes: Body Weight, Eggs/Nest and Incubation Data<sup>8,41,108</sup>

Common Name	Body Weight (grams)		Average Eggs/Nest	Average Incubation in Days
	Male	Female		
<b>SUBFAMILY ANSERANATINAE</b>				
<b>Tribe Anseranatini</b>				
Maggie Goose	2766	2071	8-9	28*
<b>SUBFAMILY ANSERINAE</b>				
<b>Tribe Dendrocygnini</b>				
Spotted Whistling Ducks	800	800	11	30-31*
Eyton's (Plumed) Whistling Duck	788	792	8-14	28-30*
East Indian Wandering Whistling Duck			6-8	28-30*
Fulvous Whistling Duck	675	690	8-16	24-26*
Cuban (Black-billed) Whistling Duck	1150	1150	8-12	30*
Javan (Lesser) Whistling Duck	450-600	450-600	8-10	27-28*
White-faced Whistling Duck	686	662	6-12	26-28*
Northern Black-bellied (Red-billed) Whistling Duck	816	839	12-16	28-31*
<b>Tribe Anserini (Swans and True Geese)</b>				
Coscoroba Swan	4600	3800	4-7	35
Black Swan	6270	5100	4-10	35-40*
Mute Swan	12200	8900	4-8	35-40
Black-necked Swan	5400	4000	4-8	36
Whistling Swan	7100	6200	3-5	30-32
Whooper Swan	10800	8100	4-6	31-40
Swan Goose	3500	2850-3450	5-8	28
Western (Yellow-billed) Bean Goose	3198	2843	4-6	27-29*
Pink-footed Goose	2620	2352	3-5	26-27
European White-fronted Goose	2290	2042	5-6	27-28
Lesser White-fronted Goose	1440-2300	1300-2100	3-8	25
Western Greylag Goose	3531	3105	5-6	24-30
Bar-Headed Goose	2000-3000	2000-3000	4-6	27
Lesser Snow (Blue) Goose	2744	2517	4-5	22-23
Ross's Goose	1315	1224	3-5	20-22
Emperor Goose	2812	2766	4-6	24-25
Nene (Hawaiian) Goose	2212	1923	3-5	29
Atlantic Canada Goose	3809	3310	4-6	28
Barnacle Goose	1672	1499	4-6	24-25
Russian (Dark-bellied) Brant	1410	1410	3-5	22-26
Red-breasted Goose	1315-1625	1150	3-7	23-25
<b>SUB-FAMILY ANATINAE</b>				
<b>Tribe Tadornini (Shelducks and Sheldgeese)</b>				
Crested Shelduck	Unknown	Unknown	Unknown	Unknown
Ruddy Shelduck	1200-1640	950-1500	8-12	27-29
Cape Shelduck	1785	1417	6-13	30
Australian Shelduck	1559	1291	10-14	30-32
New Zealand (Paradise) Shelduck		1260-1340	5-11	30
European (Common) Shelduck	980-1450	801-1250	7-12	28-30
Moluccan (Black-backed) Radjah Shelduck	750	839	6-12	30*
Egyptian Goose	1900-2550	1500-1800	6-12	30
Orinoco Goose		1250	6-8	30
Abyssinian Blue-Winged Goose		1520	4-9	30-34
Andean Goose	2730-3640	Same	5-10	30
Lesser (Upland) Magellan Goose	2834	2721-3200	5-8	30

\*Both parents incubate, others, female only.

Common Name	Body Weight (grams)		Average Eggs/Nest	Average Incubation in Days
	Male	Female		
Patagonian (Lesser) Kelp Goose	2607	2607	3-7	30
Ashy-Headed Goose	2267	2200	4-6	30
Ruddy-Headed Goose	2000	2000	5-8	30
Cape Barren (Cereopsis) Goose	5290	3770	3-6	35
Flying Steamer Duck	3073	2616	5-9	30-40
Magellanic Flightless Steamer Duck	6039	4111	5-8	30-40
Falkland Flightless Steamer Duck	4303-4420	3400	5-8	28-40
Patagonian Crested Duck	1070-1180	900	5-8	30
<b>Tribe Anatini (Dabbling Ducks)</b>				
Blue (Mountain) Duck	887	750	4-8	31-32
Salvadori's Duck	462	469	3-4	28*
South African Black Duck		952-1077	4-8	28
European (Eurasian) Wigeon	720	640	7-11	23-25
American (Baldpate) Wigeon	770	680	7-9	24-25
Chiloe Wigeon	939	828	5-8	26
Falcated Duck	713	585	6-9	24-25
Gadwall (Gray Duck)	990	850	8-12	26
Baikal Teal	437	431	6-9	25
European Green-winged Teal	329	319	8-10	21-23
Chilean Speckled Teal	429	394	5-8	24
Cape Teal	419	380	7-8	25-26
Madagascar (Bernier's) Teal			2-4; 8-10	Unknown
East Indian Grey Teal	507	474	4-14	24-25
Chestnut Teal	595	539	9-10	28
New Zealand Brown Teal	665	600	5-7	27-30
Northern Mallard	1261	1084	8-12	23-29
Hawaiian Duck (Koloa)	670	573	6-13	26-28
Laysan Teal		450	4-8	26
North American Black Duck	1330	1160	6-12	26-28
Meller's Duck			8-10	27-29
South African Yellow-billed Duck	954-844	817-677	4-10	27
Indian Spotbill	1230-1500	790-1360	7-9	28
New Zealand Grey Duck	765-1275	623-1275	5-13	28
Philippine Duck	906	779	8-14	25-26
Bronze-winged (Spectacled) Duck	1130	990	4-6	30
Northern Pintail	850	759	8-10	21-26
Chilean (Brown) Pintail	776	705	4-10	26
Lesser (Northern White-cheeked)	474-533	505-633	6-10	25
Red-billed Pintail	617	566	5-12	25-27
Northern Silver (Versicolor) Teal	422	373	7-10	25-26
Hottentot Teal	224-253	224-253	6-8	24-27
Garganey	240-542	220-445	8-11	22-23
Prairie Blue-winged Teal	360	332	10-12	21-24
Northern Cinnamon Teal	408	362	6-14	24-25
Argentine Red Shoveler	608	523	5-8	25
Cape (South African) Shoveler	688	597	5-12	26-28
Australian Shoveler	667	665	9-12	24-28
Northern (Common) Shoveler	410-1100	420-763	7-14	23-28
Pink-eared (Zebra) Duck	404	344	3-11	27
Marbled Teal	240-600	250-550	10-11	25
Freckled (Monkey) Duck	969	842	5-10	26-28

table continued on next page

Common Name	Body Weight (grams)		Average Eggs/Nest	Average Incubation in Days
	Male	Female		
Ringed Teal	190-360	197-310	6-12	26-28
Pink-headed Duck	935	840	5-10	Unknown
Chilean Torrent Duck	440	315-340	3-4	43-44
<b>Tribe Somaterinii (Eiders)</b>				
European Eider	2253	2127	3-6	25-30
King Eider	1830	1750	3-6	22-24
Spectacled (Fischer's) Eider	1630	1630	4-6	24
Steller's Eider	860	860	7-8	22-24
<b>Tribe Aythyini (Pochards)</b>				
Red-Crested Pochard	1135	967	6-12	26-28
South American (Southern) Pochard	600-977	533-1000		
Rosy-Billed (Rosybill) Pochard	1181	1154	8-12	25-28
Canvasback	1252	1154	8-10	24-25
European (Eurasian) Pochard	998	947	6-9	23-29
Redhead	1080	1030	7-8	24
Ring-necked Duck	790	690	8-12	26-27
Australian White-eye (Hardhead)	902	838	9-12	25
Baer's Pochard (Siberian White-eye)	880	680	6-9	27
Ferruginous White-eye	583	520	7-11	25-27
Madagascar White-eye			5-6	26-28
Tufted Duck	1116	1050	6-14	23-25
New Zealand Scaup (Black Teal)	695	610	5-8	27-30
European Greater Scaup	1250	900-1200	8-10	24-28
Lesser Scaup	850	800	8-10	23-25
<b>Tribe Cairinini (Perching Ducks)</b>				
Lesser Brazilian Teal	380-480	350-390	6-8	25
Maned Goose (Australian Wood Duck)	815	800	8-11	28
Mandarin Duck	440-550	440-550	9-12	28-30
North American Wood Duck (Carolina Duck)	680	539	10-15	28-30
African Pygmy Goose	285	260	6-12	23-26
Indian Pygmy Goose (Cotton Teal)	403	380		
Green Pygmy Goose	310	304	8-12	22-24
Hartlaub's Duck	800-940	800-940	9	32
White-Winged Wood Duck	2495-3855	1925-3050	6-13	33-35
Muscovy Duck	2000-4000	1100-1500	8-15	35
Old World Comb Duck	1300-2610	870-2325	8-12	30
(Gambian) Spur-winged Goose	5400-6800	4000-5400	6-15	30-32
<b>Tribe Merginina (Sea Ducks)</b>				
Labrador Duck	864	482		
Atlantic Harlequin Duck	680	540	4-8	28-29
Oldsquaw (Long-tailed) Duck	800	650	6-7	24-26
European Black Scoter	1108	1006	6-9	27-28
Surf Scoter	1000	900	5-7	27-28
European White-winged (Velvet) Scoter	1727	1492-1658	9-10	26-27
Bufflehead	450	330	8-9	30
Barrow's Goldeneye	1110	800	9-11	32
European Goldeneye	990-1158	710-799	9-11	27-32
Smew	540-935	515-650	6-9	28
Hooded Merganser	680	540	9-11	32-33
Brazilian Merganser				

Common Name	Body Weight (grams)		Average Eggs/Nest	Average Incubation in Days
	Male	Female		
Common Red-breasted Merganser	1133-1209	907-959	9-10	32
Auckland Islands Merganser				
Chinese (Scaley-sided) Merganser			8-12	
Eurasian Goosander	1670	1535	9-10	32-35
<b>Tribe Oxyurini (Stiff-tailed Ducks)</b>				
Black-headed Duck	513	565	2	20-25
Masked Duck	406	339	4-6	28
North American Ruddy Duck	550	500	6-9	23-24
White-headed Duck	737	593	6-8	23
Maccoa Duck	450-700	450-700	4-8	24-27
Argentine Ruddy (Blue-billed) Duck	610	560	3-5	23-28
Australian Blue-billed Duck	812	852	5-6	26-28
Musk Duck	2398	1551	1-3	Unknown
African White-backed Duck	650-790	625-765	5-7	29-33

lar feathers. Other species seldom come ashore, preferring to sleep on the water.<sup>108</sup>

Young Anseriformes easily imprint on humans or other species of birds. Pair formation may be difficult in imprinted birds. Homosexual and interspecific pairs are common under captive conditions. Some geese (*Cereopsis* and Egyptian) may be very aggressive and should not be maintained where they can injure animals or children. Imprinted geese and swans of all species can be dangerous to children.

### ■ Physiology

Pulse and respiration rates differ so widely in normal Anseriformes that they have limited value as indicators of disease. In the domestic Pekin Duck the heart rate (HR) varies from 180 to 230 bpm and the respiration rate (RR) from 30 to 95 bpm. Daytime body temperature (BT) is 41°C.<sup>44</sup> In the goose, RR is 13 to 40 bpm and BT is 40.5°C.<sup>111</sup> The values in Table 46.2 illustrate some consistency within these species.

The heart rate slows dramatically when a bird dives and there is an increased use of oxygen in the blood. Heat loss occurs through panting or through the webs of the feet. Anseriformes will try to prevent heat loss through the feet by squatting down on them in cold weather.<sup>44</sup>

Anseriformes from tropical countries (eg, Whistling Ducks) are prone to frostbite and subsequent gangrene of the toes. These species should be housed indoors during freezing conditions. Otherwise, wa-

terfowl are remarkably tolerant of adverse climatic conditions, especially if open water is available for swimming. They can be maintained successfully in most regions of the world.<sup>44</sup>

The growth rate in Anseriformes is usually faster than that of gallinaceous birds. Species from extreme latitudes grow faster than those from low latitudes. Growth rate and egg production appear to be related to day length during the breeding period.<sup>56</sup>

Anseriformes are often long-lived. In captivity, ducks often live 10 to 12 years, and geese and swans commonly live for 25 years or more.<sup>44</sup> Mortality rates in free-ranging birds are high. Smaller duck species survive two to three or possibly up to six breeding seasons. In the first year of life 60 to 70% of the annual hatch die, and 90 to 95% die before three years of age. Some free-ranging ducks are known to survive 16 years and geese, 18 years (Table 46.3).<sup>108,111</sup>

Evaluating blood parameters is a useful diagnostic tool in Anseriformes. Limited data are available on many species, but there is considerable data on Mallard Ducks. Selected serum constituents and hematologic parameters were analyzed<sup>a</sup> from Mallard Ducks of both sexes during several stages of reproduction: pre-egg laying, egg laying, incubating, molting and post-reproductive (see Appendix).<sup>22,23</sup> Similar assays were also conducted on ducklings, 5 to 58 days of age. These findings indicated that clinical chemistry values must be evaluated with respect to sex, age and reproductive status of the birds. Lactate dehydrogenase (LDH), cholinesterase (CHE), alanine aminotransferase (ALT), aspartate aminotrans-

**TABLE 46.2** Compilation of Normal Parameters in Pekin and Muscovy Ducks

Parameter	Pekin Duck <sup>35,67,90</sup>	Muscovy Duck <sup>55</sup>
Cloacal Temperature (°C)	40.5 - 41.6	39.1 - 41.1
Heart Rate (bpm)	150 - 250	
Respiratory Rate (bpm)	13 - 23	
Mean Arterial Blood Pressure (mmHg)	111 - 142.5	
PaO <sub>2</sub> (mmHg)	73 - 109.1	80 - 83
PaCO <sub>2</sub> (mmHg)	28.9 - 43	32 - 39
HCO <sub>3</sub> (mEq/l)	19.6 - 24.8	
Blood pH	7.36 - 7.48	7.48 - 7.53
Tidal volume (ml)	40 - 58	
Minute ventilation (l/min)	0.67 - 0.97	

ferase (AST), creatinine (CRN) and direct bilirubin (BIDI) were the only parameters that did not vary with the reproductive status of the bird. All assays except albumin (ALB), glucose (GLU), calcium (CA) and magnesium (MG) showed age-related changes (see Appendix).<sup>23</sup>

For nonreproductive birds, GLU was the only assay where values differed between males and females. Hens and drakes in pre-egg laying condition had significantly different concentrations of ALB, gamma-glutamyl transferase (GGT), CA, phosphorus (PHOS) and MG. Laying hens differed from drakes in the ALB, amylase (AMY), GGT, CA, PHOS, MG, uric acid (UA) and total bilirubin (BITO) assays. Incubating birds had sex-related differences in ALB, AMY and PHOS concentrations. In molting birds, only AMY differed between the genders.

Egg-laying activity significantly influenced serum enzyme activity and chemistry concentrations, causing increased values in 12 of the 17 assays. Egg-laying hens had a ten-fold increase in GGT during the reproductive periods. AMY doubled during egg laying while other constituents increased by a statistically significant, although lesser, amount. Values of 12 of the assays in samples from the drakes also differed by reproductive condition. GGT activity in molting males was twice their nonreproductive values (see Appendix).<sup>23</sup>

Differential white blood cell counts were also recorded in these test birds. Gender or reproductive state of the adult birds did not significantly change (P) the cell ratio. Non-laying and laying birds had a similar number of thrombocytes, which were significantly greater than thrombocyte counts of incubating, molting or post-reproductive birds. Young birds

**TABLE 46.3** Longevity of Selected Waterfowl<sup>87,39,51,52,108</sup>

Species	Years
Whistling Duck	15
Redhead	16.5
Common Goldeneye	17
Canvasback	19
European Pochard	20
Common Mallard	20
Northern Green-winged Teal	20
Egyptian Goose	25
Greylag Goose	26
Magpie Goose	26
Trumpeter Swan	32.5
Canada Goose	33

had a decrease of the percent lymphocytes from 50 to greater than 60 days of age and a concomitant, compensating increase in percent heterophils. Thrombocyte numbers increased from 5 days of age to a peak at 18 days of age, after which they did not vary significantly.<sup>22</sup>

## Husbandry Practices

### Hospitalization

Anseriformes are relatively easy to restrain. Their primary defenses include scratching with sharp toenails, pinching with their bills, striking with their wings or poking at eyes. A dry, warm enclosure with good footing is suitable for brief hospitalization. When confined, waterfowl sometimes stress, so a quiet, dimly lighted enclosure may be preferable. If longer hospitalization is necessary, an enclosure with an accessible pool and padded flooring<sup>b</sup> is necessary to prevent leg and foot problems. Hard surfaces (concrete) may damage the plantar foot surfaces, eventually promoting bumblefoot. Chain-link enclosures should be protected with burlap or other similar materials to prevent birds from abrading their wings, heads or eyes.

### Housing

Waterfowl are commonly kept as pairs in small, planted, open pens with a small pool or stream, or in large, open, mixed-species groups with a large pond. Most Anseriformes should have an area for swimming to maintain long-term overall health. Open enclosures allow various free-ranging birds to com-



pete for feed and nesting sites and potentially to introduce infectious diseases (Figure 46.3). Pests and predators (rats, snakes, otters, raccoons, bobcats, opossums, hawks, owls and eagles) may also complicate waterfowl maintenance in large open exhibits. Burying the fence line will discourage some predators from digging under the fence, and electric fencing will discourage terrestrial predators. Some aviculturists use small aviary mesh to cover pens to reduce access by free-ranging birds, pests and predators.

Covered enclosures allow birds to be full-flighted (most are typically pinioned or wing-clipped to prevent escape from open enclosures). Wing clipping is accomplished by cutting the flight feathers from one wing with a pair of scissors or shears. This procedure impedes flight until the next molt. The feathers should be trimmed at the level of the rachis, not at the level of the hollow calamus. This will reduce the chances of water entering the feather shaft, resulting in algae growth and folliculitis. Pinioning is the amputation of the distal portion of the wing, permanently handicapping a bird's flight abilities.

Large ponds should have islands to provide nesting areas and privacy for the birds. Some birds will nest on small floating platforms. Grazing species, such as geese, require more land area than do diving ducks. Small ducks can be maintained in small planted pens with an elevated cement water container that holds three to five gallons.

A high water flow rate or filtration is important for maintaining clean water and reducing the incidence of disease. Cold water is better for ponds than warm water. Generally, a depth of two feet is adequate for most Anseriformes, although swans and some diving ducks require three to four feet of water.<sup>108</sup> Many waterfowl species require standing water to breed. Anseriformes typically dig or nibble at the pond bank. Lining the banks with concrete blocks, stone or other solid materials will help maintain pond continuity.<sup>44</sup>

The nasal secretions of some marine and semi-marine waterfowl are believed to inhibit the growth of mycotic spores. If these species are maintained in fresh water, the salt glands producing these secre-



**FIG 46.3** While aesthetically pleasing, open enclosures create management problems with respect to free-ranging birds, rodents and predators. A portion of the pond should be protected from the sun, which was accomplished in this enclosure using shade cloth. The pool has gently sloping sides and can be easily drained for cleaning (1994 Busch Gardens Tampa. All rights reserved.).

tions may atrophy, affecting the bird's ability to resist infections.<sup>44</sup> These birds may die from hypernatremia if they are returned to salt water.

Multiple-species aviaries are frequently constructed with pens arranged in rows and a common stream flowing from pen to pen. This arrangement creates disease control and maintenance problems. Preferably, each enclosure should have an individual pool draining into a common drainage ditch that does not contain animals (Figure 46.4).

Planted aviaries provide nesting materials, shade and privacy for sensitive species. Large, destructive waterfowl, such as swans and geese, require hardy plants. Safe plants that are partially bird-proof include juniper, palm, pine, bird of paradise, coral tree, cycad and natal plum. Geese and other grazing birds do well on golf course fairway grasses (eg, hybrid bermuda) (Figure 46.5). In warm climates, Korean grass (*Zosia* or *Zoysia*) provides a relatively durable, lush ground cover that birds tend not to consume.<sup>108</sup>

Housing is not usually necessary for Anseriformes if they have access to open water. Some very sensitive tropical species may require protection during the winter. Water circulation systems should be used to keep ponds from freezing in the winter. If housing units are necessary, they should contain soft flooring or mats to prevent calluses and abrasions that are common with unprotected concrete floors.



**FIG 46.4** Facilities that are designed with individual enclosures, but a common pool, increase the risk of disease transmission. Preferably, each enclosure should have its own pool that can be drained into a common ditch outside the enclosure (1994 Busch Gardens Tampa. All rights reserved.).



**FIG 46.5** Geese and swans should be provided ample areas for grazing (1994 Busch Gardens Tampa. All rights reserved.).


### ■ Nutrition

Considerable nutritional information is available for commercially produced waterfowl; however, very little information is available for nondomesticated species. Because of a lack of extensive research, nutritional recommendations for nondomesticated Anseriformes are often based on observation and opinion.

The types of food consumed, and thus their nutritional components, vary widely between surface-feeding ducks and divers. High protein (28%) gamebird rations are frequently recommended for feeding ducklings; however, it has been found that a ration of 19% protein supplemented with scratch grains on a free-choice basis produced better growth and feed efficiency than higher protein diets (Table 46.4). Diets with 8% animal protein (19% total protein) promoted the best growth. Redhead, Pintail and Canvasback chicks grew best when fed a starting diet containing 2,970 kcal/kg and 19% protein until three weeks of age.<sup>43</sup> After three weeks of age, this pelleted diet was offered free choice with a mixture of cracked corn, wheat and oats or barley (the grain mixture used should depend upon the grains that free-ranging ducks are likely to consume).<sup>97</sup> Amino acid quality of the diet was maintained by the inclusion of 8% fish meal. This diet produced similar results with both dabbling and diving ducks, even though their natural feeding habits differ widely. This did not include species such as the sea ducks and mergansers that feed exclusively on fish.

Rations designed for feeding commercial ducks are not generally recommended for the long-term maintenance of other waterfowl. These diets are designed to produce a carcass to be processed for food and usually contain growth additives and compounds to stimulate feather loss. The fat content in dog foods is much higher than waterfowl can tolerate, particularly when mixed grains are

fed as part of the diet. Most ducks have a tendency to deposit excessive fat in the abdomen and around the heart and ventriculus, and overweight birds frequently die from fatty liver degeneration (see Color 20). Adequate levels of choline chloride have been found to help protect Anseriformes from fatty infiltration of the liver.<sup>45,81</sup>



**FIG 46.6** A 1.5-year-old female duck was presented with a three-week history of anorexia, ataxia and inability to fly. Abnormal clinical pathology findings included WBC=24,000, LDH=479, PCV=36.5. The bird was offered free-choice grit and, for an undetermined reason, engorged on grit, causing an impaction. The bird was given corn oil by gavage tube to facilitate passage of the grit.

Many experienced Anseriforme breeders are convinced that all waterfowl need a high-protein diet, and one pelleted ration is fed to all species. This is an inaccurate and dangerous assumption. Many geese are grazers, and most lush grasses seldom exceed 17% protein. Feeding high-protein diets to these birds can cause terminal renal failure. In addition, excessive water consumption is necessary to remove the extra protein, and a relatively short period of water deprivation can be fatal.<sup>45,81</sup> High-protein diets may also cause developmental abnormalities in the wings and legs.

Diets designed for the long-term health and breeding of Anseriformes are listed in Table 46.4. Chicken, broiler and commercial duck diets are not acceptable for commonly maintained Anseriformes. A turkey ration (20% protein) can be used as an adequate diet for recently hatched ducklings. This should be supplemented with scratch grains when birds are two to three weeks of age. After the birds mature, they can be fed a maintenance diet of 10% turkey grower pellets and 90% mixed grains until laying season begins. If grains are fed to ducklings, their diet should be supplemented with a hard, insoluble granite grit. Various-sized particles should be sprinkled on top of the feed when the ducklings are eating well (about three days of age). Later it can be provided in a separate dish. Some breeders add four percent grit to their pellets (Figure 46.6).<sup>45,81</sup>

#### Feeding Habits of Free-ranging Ducks

The fall and winter diets of non-breeding, free-ranging waterfowl depend largely on the kinds of foods available in each particular locality. Gadwalls wintering in Louisiana were found to consume 95.3% vegetable foods and only 4.2% animal matter. White-faced Tree Ducks of Senegal were found to consume primarily seeds, rice, grass, water lilies and tubers. Studies with free-ranging Mallard Ducks have shown that, when given a choice, these birds consumed those foods that were most readily available in volume. When a choice was given between barley, soft wheat, or two varieties of hard wheat, the ducks preferred the barley.

Post-breeding feeding studies of Redhead Ducks at Long Island Sound showed that plant material accounted for over 90% of the total food intake in both males and females. Muskgrass and fennel leaf pond weed were the most important foods. In the breeding season, the females appeared to prefer the tubers and root stalks of this pond weed.

In New South Wales, Black Ducks were found to eat a varied diet including seeds of grasses, swamp plants, legume plants, water snails, water beetles (adults and larvae), water spiders and ostracods, as well as terrestrial invertebrates. In one study, Canvasback hens were found to enter the breeding season with heavy fat reserves and appeared to consume decreased quantities of food throughout the laying

period. Redhead hens were found to forage continuously on the most abundant foods in the marsh. During the laying and incubation periods, the Canvasback hens lost about 68% and the redhead hens, about 76% of their lipid stores.

Female free-ranging ducks seem to instinctively consume more animal materials during the laying period than they do during other times of the year. In male and non-laying female Mallard Ducks, it was found that animal foods represented about 38% of the total food intake. In comparison, animal foods represented about 72% of the diet of laying females. It is possible that ducks increase animal food consumption during breeding for reasons other than an instinctive desire for additional protein.

Studies in chickens have shown that they consume food to satisfy an inner craving for energy. They will increase their consumption of low-energy diets in order to grow and perform normally, but will not increase their consumption of low-protein diets, even when these diets are too low in protein to support normal body requirements. Breeding hens also appear to have an inner instinct that calls for extra consumption of calcium during egg production. When offered graded levels of calcium during the egg-laying period, hens will increase the total food intake when the calcium content of the diet is low. The increase in consumption of animal materials during the breeding season may relate to calcium needs rather than protein.<sup>97</sup>

Free-ranging ducks and geese consume large quantities of energy-rich foods to establish the fat reserves necessary for migration. The same diet fed to captive birds will predispose them to obesity and fat metabolism problems when they are provided excessive quantities of food.

TABLE 46.4 Diet for Wild Ducklings

	WILD DUCK STARTER RATION	WILD DUCK GROWER RATION
Ingredient	Pounds per Ton	
Corn meal, No. 2 yellow	933.0	753.0
Oats, heavy, pulverized	200.0	400.0
Wheat standard middlings	300.0	300.0
Soybean oil meal, 50% protein, low fiber	250.0	280.0
Fish meal, 60% protein	160.0	100.0
Fish solubles, dried basis	10.0	10.0
Dried brewer's yeast, 40% protein	20.0	20.0
Whey, dried product, 55% lactose	20.0	20.0
Alfalfa meal, dehydrated, 17% protein (100,000 A/lb)	60.0	80.0
Dicalcium phosphate	10.0	10.0
Calcium carbonate, ground	30.0	20.0
Salt, iodized	5.0	5.0
Manganese sulfate, feed grade	0.5	0.5
Copper sulfate	0.5	0.5
Zinc carbonate	0.25	0.25
DL-methionine (hydroxylanalog)	1.0	1.0
Santoquin		0.25
Vitamin, Unit of Measure	Amount per Ton	
Stabilized vitamin A, USP units	10,000,000	12,000,000
Vitamin D <sub>3</sub> ICU	1,500,000	1,500,000
Vitamin E, IU	5,000	5,000
Riboflavin, grams	3	4
Choline chloride, grams	112	250
Niacin, grams	40	40
Calcium pantothenate, pure D-isomer, grams	6	10
Vitamin K (menadione sodium bisulfite), grams	4	4
Vitamin B <sub>12</sub> , milligrams	6	6
Calculated Analysis (%)		
Protein	20.0	19.0
Fat	6.5	5.0
Fiber	4.0	4.5
Calcium	1.2	1.0
Phosphorus	0.7	0.7

Starter ration to be fed for first three weeks with insoluble grit available at all times. Grower ration to be fed from 21 days of age to maturity with scratch grains free choice. Grit to be available at all times. This diet plus scratch grain free choice can be used as a maintenance ration and for nonlaying breeders (adapted from Hyde<sup>95</sup>).

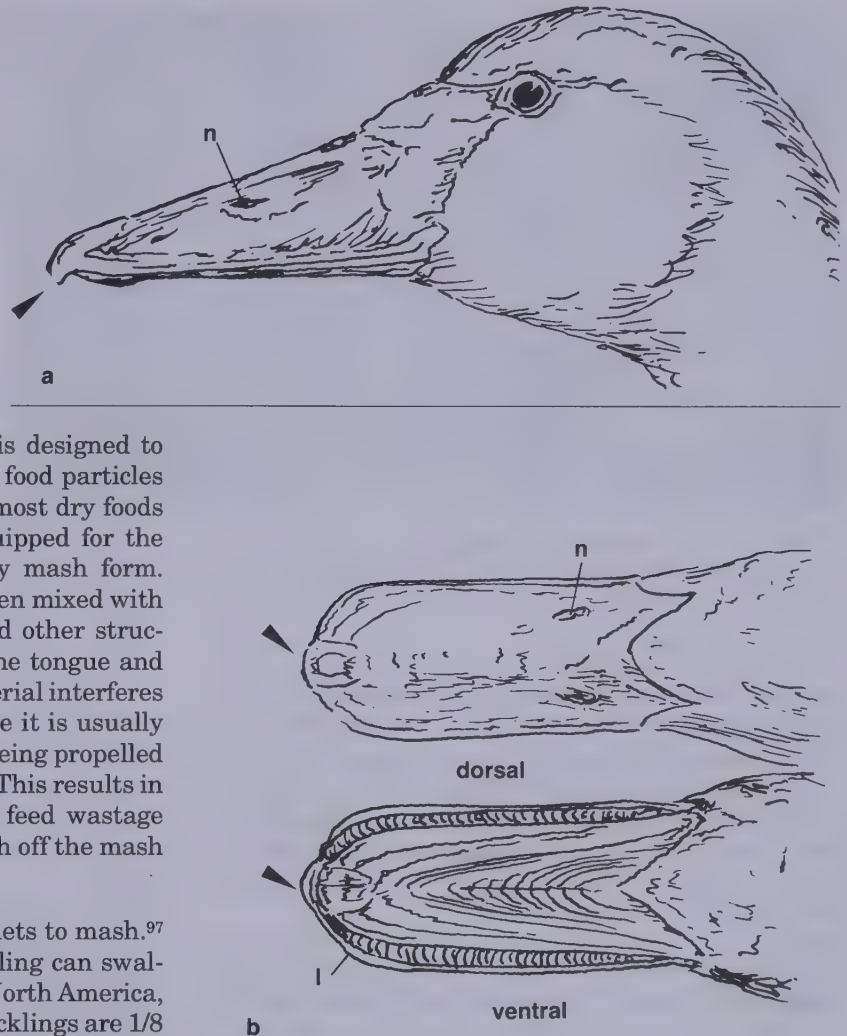
Geese appeared to have a better ability to utilize dietary fiber than ducks.<sup>97</sup> Captive geese did best when provided alfalfa hay in addition to a pelleted ration. Geese do well when fed the same diets recom-

mended for ducks (Table 46.4). A duck starter diet should be provided for four weeks, followed by the duck grower/finisher diet until maturity. Scratch grains should be added to the grower/finisher diet, approximately 50:50, after eight weeks of age.<sup>97</sup>

A duck's ability to gather food from flooded or muddy areas is assisted by cutaneous mechanoreceptors on the bill and tongue, which allow them to quickly differentiate edible from non-edible matter. Taste buds may also assist in this process.<sup>97</sup> A duck's bill is designed to allow efficient straining of submerged food particles (Figure 46.7) as well as the intake of most dry foods of appropriate size. They are not equipped for the consumption of mixed feeds in a dry mash form. Mashings tend to form a sticky paste when mixed with saliva and adhere to the lamellae and other structures bordering the outer margin of the tongue and upper and lower bill. The adhered material interferes with food passing to the tongue, where it is usually rotated and coated with saliva before being propelled back to the esophagus and swallowed. This results in a reduced food intake and increased feed wastage because the duck tries to shake or wash off the mash sticking to its mouth parts.<sup>97</sup>

When given a choice, ducks prefer pellets to mash.<sup>97</sup> The maximum diameter pellet a duckling can swallow easily dictates acceptable size. In North America, the two most common sizes used for ducklings are 1/8 inch (3.18 mm) and 5/32 inch (3.97 mm), with the latter being the maximum size for newly hatched Pekin ducklings. Starter pellets should not exceed a length of 5/16 inch (7.94 mm). Pekin ducklings can eat pellets 3/16 inch (4.76 mm) in diameter and about 1/2 inch (12.7 mm) in length by two weeks of age.<sup>97</sup>

Feeding containers for ducks should be several inches deep and at least one foot square to facilitate their normal forward "shoveling" prehension motion for food collection.<sup>97</sup> Anseriformes should always have access to fresh, uncontaminated water. The daily water requirement of ducks (by weight) is approximately four to five times the weight of the daily feed intake. Water and food containers should be positioned near each other. Poultry water units and nipple drinkers can be used for waterfowl (Figure 46.8).



**FIG 46.7** The bill of a duck is designed to gather food from flooded and muddy areas and has highly developed cutaneous mechanoreceptors. **a**) The nares (n) are located in the mid-portion of the upper beak. **b**) The epidermis is thickened at the tip of the upper beak (ducks, geese and swans) and lower beak (ducks) to form a "nail" (arrows). These nails are designed to grasp small slippery objects and have well-developed nerve endings (Herbst's corpuscles). The lamellae (l) vary in form among species and serve either to cut or to filter food (modified from Lucas and Stettenheim, 1972).

### Energy Requirements

Metabolizable energy levels commonly used for poultry are similar to those required by ducks. The Pekin Duck has been shown to thrive with pelleted diets varying from 2200-3300 kcal ME/kg of diet, provided the proper ratio of energy to protein and necessary nutrients is maintained.<sup>97</sup>



**FIG 46.8** Waterfowl should always have access to clean, fresh water of sufficient depth. The food should be kept in a flat, large container to facilitate the scooping motion of the head and neck (1994 Busch Gardens, Tampa. All rights reserved.).

### Protein Requirements

Varying reports on the protein requirement of ducks may be a result of these animals' exceptional capacity for compensatory growth. Diets formulated using milo, corn, barley, wheat or other cereal grains mixed with fish meal, soybean meal, bone meal and meat have been shown to contain adequate amounts of essential amino acids except for methionine, and possibly cystine and lysine.<sup>97</sup>

### Nutrient Requirements of Laying Ducks

Theoretical ME requirements of laying Pekin Ducks: The energy requirement for maintenance of a moderately active Pekin Duck at an environmental temperature of 21°C is about 472 kcal/day.<sup>98</sup> A duck egg contains 185 kcal energy/100 g egg.<sup>109</sup> A large Pekin Duck has an egg that weighs about 90 grams. The energy put into the egg is  $0.9 \times 185 = 167$  kcal. The efficiency of converting feed energy into duck egg energy is about 73.6%.<sup>24</sup> To produce a 90 g duck egg, the feed energy needed is approximately 167 divided by 0.736 = 227 kcal. For 100% egg production, the total ME requirement of the Pekin Duck is approximately  $472 + 227 = 699$  kcal/day. A Pekin Duck would need to consume 252 g (0.55 lb) of a diet containing 2,772 kcal/kg to obtain this amount of ME.<sup>97</sup>

Theoretical protein requirements of laying Pekin Ducks: A duck egg contains 12.81% protein.<sup>109</sup> A 90 g egg contains  $0.1281 \times 90$  or approximately 11.5 g of protein. The protein maintenance requirement of the Pekin Duck has been calculated to be approximately 10 g/day.<sup>98</sup> To produce an egg, assuming the duck is

55% efficient in conversion of feed protein to egg and tissue proteins, a duck must eat  $11.5/0.55 = 20.9$  g of feed protein. When this is added to the 10 g of feed protein required for body maintenance, the total feed protein needed per day is 30.9 g. When a duck consumes the 252 g of feed needed to provide its energy requirements, the feed should have 12.5% protein, balanced in all amino acids needed for maintenance and egg production. Protein requirements for feather replacement is not included in this calculation. A diet for breeding ducks with 16% protein provides a reasonable quantity of the essential amino acids.<sup>97</sup>

### Vitamins

Recommended vitamin levels for practical commercial duck rations are in Table 46.5.<sup>97</sup>

- **Vitamin A:** Vitamin A is important in maximizing the efficiency of feed utilization. It has also been shown that young ducklings do not utilize the provitamin A found in alfalfa meal as well as they utilize preformed vitamin A.<sup>97</sup> This is caused by a reduced digestion of plant matter in the undeveloped cecum. The vitamin A content of the livers of ducklings remains high up to 14 days of age as a result of the vitamin A fed to the hen. After 14 days of age, the ducklings acquire vitamin A from their food.

Hypovitaminosis A is associated with poor growth, muscular weakness, retardation of endochondral bone growth and ataxia, paralysis and death. Chronic hypovitaminosis A in ducks has not been verified but has been suggested as a precipitating factor in the high incidence of bumblefoot described in *Anseriformes* (see Color 8).<sup>97</sup>

- **Vitamin D<sub>3</sub>:** Deficiencies of calcium or phosphorus result in rickets. Vitamin D<sub>3</sub> deficiency may occur in birds on proper diets if an animal lacks the enzymes needed to convert dietary vitamin to the metabolically active metabolite, 1,25-dihydroxycholecalciferol.<sup>97</sup>
- **Vitamin E:** Hypovitaminosis E has not been associated with encephalomalacia in ducks. The muscular dystrophy caused by hypovitaminosis E in ducklings is not prevented by dietary cystine as it is in gallinaeous chicks.<sup>97</sup> Prevention of vitamin E-related muscular dystrophy in ducks is mostly associated with

their requirement for dietary selenium. With low-selenium diets, 27 mg vitamin E/kg is needed to prevent myopathies. Vitamin E-deficient diets may cause neurocalcinosis in the heart, ventriculus and intestinal muscles, while skeletal muscles may have typical hyaline degeneration. Ducklings on deficient diets often will die by three weeks of age. Muscular dystrophy is prevented with diets containing 1.2 mg vitamin E/kg of food when selenium is added at a level of 0.1 ppm.<sup>46,47</sup>

- **Thiamine (Vitamin B<sub>1</sub>):** Ducklings begin to lose weight four days after being placed on thiamine-deficient diets. “Star-gazing” is a characteristic clinical sign. If deficiencies occur, thiamine should be added to the drinking water at 100 µg/l.<sup>97</sup>
- **Riboflavin (Vitamin B<sub>2</sub>):** Riboflavin deficiencies in ducklings cause poor growth and high mortality. The “curled toe” syndrome common in riboflavin-deficient chicks has not been reported in ducklings (see Color 48). Deficiencies in breeding ducks cause late embryonic mortality.<sup>97</sup>
- **Niacin (Nicotinic Acid):** Ducklings have a relatively high requirement for niacin, which is required for growth and prevents severe leg weaknesses. Ducks have high levels of picolinic acid carboxylase, an enzyme that converts tryptophan to carbon dioxide and water instead of allowing it to be converted to niacin. Ducklings receiving a diet deficient in niacin showed a 100% incidence of bowed legs. Severity of the leg deformities increased, and growth was depressed when 2% cod liver oil was added to the diet. The growth rate was returned to normal when 5% brewer’s yeast was added to the diet. Bowed legs were completely prevented when 7.5% brewer’s yeast was added. Niacin has been shown to be poorly available from natural feedstuffs, and supplementation with pure niacin may be necessary.<sup>97</sup>
- **Biotin:** The dermatitis associated with biotin deficiency in chickens has not been described in ducks. A poor growth rate appears to be the only sign of deficiency.
- **Folic Acid:** Deficiencies result in severe anemia as well as reduced growth and poor feathering.
- **Choline:** Unlike young mammals, ducklings, chicks and poults are unable to synthesize choline until later in life. Choline deficiency in Pekin ducklings causes perosis and fatty liver degeneration. Ducklings on choline-deficient diets grow poorly, have weak legs, develop perosis and may die. Most diets for ducklings

TABLE 46.5 Vitamin Requirements for Pekin Ducks

Vitamin	A	B	C
Vitamin A, IU	8000	5000	10,000
Vitamin D <sub>3</sub> , IU	1000	500	1000
Vitamin E, IU	25	20	40
Vitamin K, IU	2	1	2
Thiamine, mg	2.0	2.0	2.0
Riboflavin, mg	4.5	4.5	4.5
Niacin, mg	70.0	70.0	50.0
Pantothenic acid, mg	12.0	11.0	15.0
Pyridoxine, mg	3.0	3.0	3.0
Folacin, mg	0.5	0.25	0.5
Biotin, mg	0.15	0.1	0.15
Vitamin B <sub>12</sub> , mg	0.01	0.005	0.01
Choline, mg	1300.0	1000.0**	1000.0**

\* Must be increased to 8 mg/kg if sulfaquinoxaline or other vitamin K antagonist is present in the diet.

\*\* growing ducks may be able to synthesize choline

Adapted from Scott.<sup>97</sup>

**A** = Recommended vitamin allowances for **starting** ducks

**B** = Recommended vitamin allowances for **growing-finishing** ducks

**C** = Recommended vitamin allowances for **breeding** ducks

contain adequate levels of choline. After eight weeks of age, it is recommended that choline supplementation be added to diets so that maximum choline biosynthesis will occur before the onset of egg production.<sup>97</sup>

- **Vitamin B<sub>12</sub>:** Ducks appear to have minimal requirements for dietary B<sub>12</sub> and newly hatched ducklings have sufficient levels of this vitamin derived from the hen.<sup>97</sup>
- **Ascorbic Acid (Vitamin C):** Ducks readily synthesize vitamin C; however, birds receiving supplemental vitamin C have superior erythrocyte and hemoglobin values as well as greater bacteriocidal and lysozyme activity than unsupplemented ducks.

### Mineral Requirements

Only eight of the thirteen minerals required by animals have been studied in ducks. Of the other five, all (potassium, iron, copper, molybdenum) except iodine are found in adequate amounts in most commercial feedstuffs.<sup>97</sup> Recommended allowances for minerals in starting ducks, growing Pekin Ducks and breeding Pekin Ducks are found in Table 46.6.

- **Calcium:** Calcium levels for ducklings are recommended at 0.6 to 0.8%. Levels up to 1 or 1.5% may cause progressive-to-severe decreases in weight gain. Ducklings receiving a diet with 0.17% will develop

rickets. For laying Tsaiya Ducks, the calcium allowance is 3%. For Pekin Ducks, it is 2.75% and for Khaki Campbell Ducks, 3.25%.<sup>97</sup>

- **Phosphorus:** Adequate levels for maximum growth and percentage of bone ash is 0.6% total phosphorus, of which 0.35% is available. When phosphorus was increased to 1%, there was neither a beneficial nor negative effect on weight gain or bone ash.<sup>97</sup>
- **Sodium:** Ducklings are considerably more susceptible to low sodium levels than gallinaceous chicks. All ducklings receiving a diet without sodium chloride or sodium bicarbonate died by the 19th day on this diet. In order to maximize weight gain, sodium chloride was supplemented to 0.3% (0.135% total sodium). Mortality was prevented, but inferior growth rates occurred when sodium bicarbonate was added to the diet. Chloride at a level of 0.072% provided by the basal diet was not adequate for normal growth. Supplementation with potassium chloride (KCl) to bring chloride level to 0.122% produced normal weight gains. There is a range from 0.4 to 0.8% total dietary salt (0.15 to 0.32% sodium) that is tolerated. When more than 1% salt is added, weight gain is significantly depressed. The sodium requirement of ducks is suggested to be 0.15% throughout all stages of life.<sup>97</sup>

## Reproduction

### Breeding Factors

Most ducks become sexually mature at about one year of age. A few exceptions, such as the Bufflehead and Scaup, require longer. Geese often take two years to mature, while swans may take five years to reach sexual maturity.<sup>44</sup> Waterfowl maintained in captivity are prone to hybridize, and related species should not be housed together.

A bird's behavior may change drastically during the breeding season, and aggressive species such as Cape Barren Geese, Sheldgeese, swans and Bronze-winged Ducks must be carefully monitored. Mixed aviaries must be large enough to allow birds involved in territorial aggression to escape.<sup>108</sup>

Male Anseriformes have an erectile phallus covered with keratinized papillae. This anatomic feature allows the gender of ducks or geese to be accurately

TABLE 46.6 Mineral Requirements for Pekin Ducks

Mineral	A	B	C
Calcium, %	0.7	0.6	2.75
Available phosphorus, %	0.5	0.4	0.4
Sodium, %	0.18	0.18	0.18
Chloride, %	0.18	0.14	0.14
Magnesium, ppm	500.0	500.0	500.0
Manganese, ppm	55.0	45.0	35.0
Zinc, ppm	60.0	60.0	60.0
Selenium, ppm	0.2	0.2	0.2

Adapted from Scott.<sup>97</sup>

**A** = Mineral allowance for **starting** Pekin Ducks

**B** = Mineral allowance for **growing** Pekin Ducks

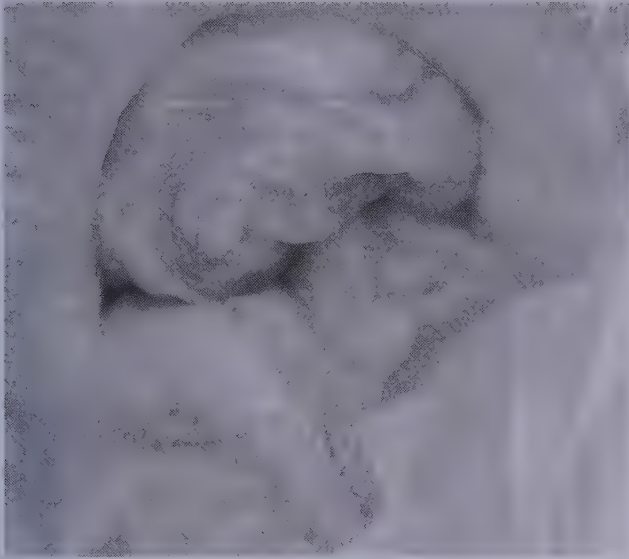
**C** = Mineral allowance for **breeding** Pekin Ducks

determined at a very early age (Figure 46.9). Exposure and identification of structures is easier in mature breeding birds. The cloaca is manually everted to visualize the phallus by holding the bird vertically with its head down and abdomen toward the examiner. Gentle, firm pressure with the thumbs on each side of the cloaca will tend to evert the phallus. It may take some time to overcome the resistance of the cloacal sphincter but continued downward and outward pressure of the thumbs will help achieve exposure. Two small labia-like structures are found in the female. The phallus can be palpated in its retractile state and needs to be everted only for confirmation; the female requires little effort as a palpable mass cannot be detected.<sup>44</sup>

Male ducks frequently leave after the eggs are laid and the pair may or may not re-mate the following season. Swans and geese form a lasting pair bond that is broken only by the death of one of the birds. The surviving bird may have difficulty forming another pair bond, or may not breed again.<sup>44</sup>

Waterfowl nest in a variety of ways. Some prefer cavities, some thick vegetation and others, open areas. Waterfowl generally lay their eggs in the early morning. Smaller species usually lay one egg a day, while larger species lay an egg every other day. Information on average number of eggs per clutch, incubation time and incubation responsibility can be found in Table 46.1. Once incubation begins, the hen is reluctant to leave the nest, except for brief periods in the early morning or late afternoon to feed, drink and bathe.<sup>108</sup> During incubation, it is not uncommon for some free-ranging migratory waterfowl to lose up to 40% of their peak weight.





**FIG 46.9** The phallus of a male Anseriformes can be visualized or palpated in the ventral wall of the cloaca and is covered with keratinized papillae.

Because incubation of the clutch usually begins at the same time, most eggs in a clutch will hatch within a day or two of each other.<sup>108</sup> Once an egg pips, there is usually an interval of 16 to 24 hours before hatching is complete.

In some species, both parents protect the young (swans and geese), while in other species only the hen cares for the brood. There are also parasitic species (such as the Redhead) in which no parental care occurs, and the hen lays her eggs in the host nest.<sup>44</sup>

Anseriformes have nidifugous young that are covered in down and can eat, swim and dive almost from hatching. The young begin to forage within a day or so of hatching. Normal chicks have sufficient fat and yolk stores to survive for several days without eating. Some of the smaller species will fledge and can fly at about 40 days of age. Larger birds may take two to three months to fledge. An exception is the Ross's Goose chick that may fledge by four weeks of age.<sup>108</sup>

Preservation of semen and artificial insemination have been successful in free-ranging as well as captive waterfowl. Successful cryogenic preservation of semen has been reported for the Aleutian Canada Goose. Semen was diluted with Beltsville poultry semen extender, adjusted to  $270 \pm 30$  mOs and  $7.5 \pm 0.4$  pH. DMSO was added to seven percent concentration. With frozen-thawed semen, 19 of 31 eggs were fertile. About half of the live spermatozoa from the fresh semen (87.3 to 92.9% live sperm) survived the

freeze-thaw process.<sup>33</sup> Information on naturally occurring and artificial breeding programs for various waterfowl can be found in a variety of sources.<sup>37,39,51,108</sup>

## Embryo and Neonatal Management and Pathology

### Incubation

Artificial incubation and brooding of waterfowl is a common practice. A pair of birds may be stimulated to produce another clutch of eggs by removing the first clutch. In some aviaries, eggs and babies are susceptible to predators or environmental injury, and artificial incubation is necessary to ensure survival. Small enclosures may alter normal behavior so that a pair will not properly incubate or brood.

Typically, an incubator temperature of 99.3°F and 85% humidity is appropriate for most waterfowl. Improper egg storage, egg contamination, low humidity, air flow problems and inadequate turning of the eggs can all cause reduced hatchability (see Chapter 29).

Nutrition, infectious diseases and genetics can also reduce hatchability and survivability. Genetic factors have not been adequately explored as a cause of poor hatchability in birds. Inbreeding in domestic birds correlates with a significant increase in infant mortality, which may reach 100% after three to four generations of breeding.<sup>25</sup>

In a study at the New York Zoological Park, attempts to determine the cause of early embryonic death in birds were inconclusive due to rapid degeneration of the embryo at high incubation temperatures.<sup>20</sup> A study at the Regent's Park Zoo from 1973 to 1975 on 442 birds was unable to document bacterial infections as a cause of poor hatchability.<sup>96</sup>

### Brooder Room Management

The requirements of Anseriforme chicks are the same whether they are reared by their parents, a surrogate hen or artificially. Ducklings seem to thrive best if they are provided a thermal gradient and allowed to choose their own temperature. The temperature on the heated side of the enclosure should be about 95 to 99°F initially and then gradually decreased to about 70°F over a three-week period. It is important that chicks never become chilled. Although they may appear to recover when warmed, many affected chicks develop gastrointestinal problems or liver or kidney failure and die several days later. The chicks are the best guide to determine if a proper temperature is available. If chicks are huddled under the heat, they are too cold; if they are panting, appear stressed and

are staying away from the heat, then they are too hot (Figure 46.10).<sup>81</sup>

Housing enclosures for ducklings should be easy to clean and sanitize. With any brooding method, it is important to maintain a clean, dry, warm enclosure with an easily available supply of clean food and water. Drafts should be avoided. Many chicks seem suicidal, and pebbles or marbles must be added to the water container to prevent drowning. Chicks have been known to get stuck between the food container and a wall, and they may also jump out of the brooder and become chilled.<sup>81</sup>

An effective brooder room has a sloping concrete floor with a drain in one corner. The room has a control system that allows heating, cooling and adequate ventilation. A metal rack is attached to the wall to suspend individual containers off the floor for easy cleaning. Individual brooder boxes can be removed for intensive cleaning and disinfecting. Each box is 19 inches wide by 36 inches long. The back is 16 inches deep and the front is 10 inches deep. The bottom is made of one-fourth inch by one-half inch vinylized wire<sup>c</sup> and the removable top is made of one-fourth inch by one-fourth inch hardware cloth in a wood frame that is hinged in the middle for access to both the front and back of the brooder. Enclosures for older birds have higher walls and lack a sloping top. A small stainless steel pool is inserted into the front bottom of the enclosure (Figure 46.11). This pool has a sloping bottom so the birds can get in and out easily, and a maximum depth of three to four inches. Shallow pools, three-fourths inch deep, are used initially to acclimate young ducklings to the water.<sup>81</sup>

A 150-watt infrared heat lamp is placed over each box on an extendable cord so that the heat can vary from directly over the enclosure to 32 inches above the enclosure (Figure 46.12). Room temperature is maintained at 76 to 82°F while the box temperatures are increased by the lights. A poultry water bottle is used in each box with pebbles in the troughs so that young birds do not drown. The water bottle and food pan are positioned away from the wall at the opposite end of the heat source.


For younger birds, it is advisable to use a vinyl turf-type mat<sup>b</sup> or towel under the heat source to make the flooring more comfortable as well as to retain heat. Hay, straw, shavings, newspaper or other absorbent materials used for bedding may be consumed by some ducklings and cause impactions. The room should have a treatment area with a counter, scale



**FIG 46.10** Behavior of a neonate is the best indication of a proper temperature gradient. These chicks are standing together for security but are not huddled, which would indicate chilling. Note that the back half of the brood box is heated (Figure 46.12) and the front half is unheated, creating a natural thermogradient (1994 Busch Gardens Tampa. All rights reserved.).

and record keeping materials. Daily records are maintained on each group of birds. A double sink is effective for cleaning pans and a hose is used for cleaning the wall-mounted brooder boxes. Various disinfectants can be used. Water bottles may be changed several times a day as needed, and enclosures are cleaned once a day.<sup>81</sup> Further information on brooder room set-ups may be found in Brown<sup>3</sup> and Hyde.<sup>45</sup>

The ducklings are ready for outside pens at two to four weeks of age. It is preferable to use an intermediate facility to acclimate the ducklings to the difference between the very controlled environment of the brooder room and the limited control of outside pens. Providing birds free choice to indoor or outdoor environment is optimal. Outside enclosures approximately eight feet square with concrete floors and a gently sloping pool covering about half of the floor space are ideal. The slope of the pools should be



**FIG 46.11** As waterfowl mature, they should be provided a shallow pool with gently sloping edges. Neonates are best raised in groups of similarly sized individuals. This lone neonate was provided a stuffed toy for company (1994 Busch Gardens Tampa. All rights reserved.).

gradual, and vinyl mats should be placed on the edge of the pool and on some of the dry areas to prevent leg and foot problems. A heat lamp should be available for each pen. All pools should have overflows and good drainage for easy cleaning. Once acclimatized to the outdoors, the birds can be moved to larger growing pens. They can then be moved to other areas such as breeding pens or large mixed species aviaries.

### Neonatal Problems


The majority of losses during the first two weeks of life are associated with the poorly understood diagnosis of starveout. Starveout is a term coined by poultry pathologists to describe a condition of turkey poults wherein birds never start to eat; they starve after their yolk stores are depleted. Characteristically, deaths occur in waterfowl at 7 to 14 days of age; the birds have an empty, contracted gastrointestinal tract, a small yellow liver, a distended gall bladder and no fat stores. It has been shown that many species, especially in captive situations, require specific stimuli and encouragement to begin self-feeding,<sup>64</sup> and a lack of these stimuli may contribute to the problem.

Young waterfowl generally do not require food for the first 24 to 48 hours while the yolk sac is being absorbed. Scoters, Harlequins, Oldsquaw duck-

lings and other specialized species may be particularly difficult to get started eating and must be fed by hand and pampered for considerable lengths of time. Mallard ducklings may be used to stimulate feeding in reluctant eaters. It is easier to raise a brood of young rather than a single bird.

Simulating the natural conditions that a free-ranging hatchling would encounter may stimulate feeding behavior. Newly hatched Mandarin Ducks and Wood Ducks tend to calm down in the brooder and begin to eat after they have been tossed in the air and allowed to drop to the ground. As strange as this may seem, it works because these species are cavity nesters and young often fall 60 feet or more to the ground when they leave the nest.<sup>108</sup> Wood Duck chicks feed best if a cotton floor mop is hung in the brooder.

Ducklings may become wet and chilled in a brooder or when moved to an outdoor area and exposed to heavy rains. Their undeveloped feathers lack the natural oils and proper structure to repel water. Weaker ducklings that are not competing effectively with other chicks for food may become hypoglycemic, weak and chilled. A hair dryer can be used to dry the feathers and warm the body. Once the birds are dry, tube feeding with 0.25 to 3 cc of a prepared formula<sup>d</sup> provides a quick energy source. Steroids, subcutaneous fluids and antibiotics may prevent secondary problems. Large doses of rapidly metabolized ster-



**FIG 46.12** An ideal brooder room designed for Anseriformes and Galliformes. Tile floors and walls are easy to clean, and the brooder boxes can be removed for cleaning and disinfecting. Heat lamps are placed on retractable extension cords to allow changes in the amount of heat provided to an individual brood box. (1994 Busch Gardens Tampa. All rights reserved.).

oids (prednisolone sodium succinate 2 mg/60 g chick) should be repeated every 15 minutes (some chicks may require four or five doses) until the chick is warm and stabilized (Harrison G, unpublished).

Gastrointestinal disorders seem to be particularly common in neonatal birds. A high energy requirement and the need to establish a resident flora in what is a sterile environment at hatching probably account for many of these problems. Impaction of the crop and ventriculus, and less commonly the colon, may be the only lesions seen at necropsy. A precise etiology is rarely identified although inappropriate or excessive food intake is often implicated. Impactions lead to putrefaction of the gastrointestinal contents causing inflammation of the gastrointestinal mucosa and frequently systemic intoxication.<sup>64</sup>

- **Yolk Sac Disorders** can be divided into three overlapping syndromes. The first is retention of the yolk sac. At necropsy, affected birds have a moderate-to-large unabsorbed yolk sac in the abdominal cavity that is recognized clinically as a distended abdomen. No other abnormalities are noted. In domestic fowl, the yolk sac is completely absorbed by ten days of age. Similar data are not available for most aviary species, but, in general, persistence of the yolk past two weeks of age is abnormal and detrimental. Causes for non-absorption are unknown, as are the events that lead from retention to death of the bird. Neonates depend on the yolk sac for the first two to three days of life and if the yolk is not absorbed, the birds will be malnourished. Maternal immunoglobulins, specifically IgG, are absorbed with the yolk. Improper absorption of the yolk could result in the same immunosuppression seen in mammals that do not ingest colostrum.<sup>64</sup>

Temperature and humidity during incubation affect yolk sac development. High humidity or low temperature may cause a failure to retract the yolk sac into the abdomen prior to hatching. Low humidity during incubation has been associated with infection of the yolk sac. Infected yolk appears as a thick brownish or yellow coagulated mass compared to normal yolk, which is a greenish-yellow liquid (see Color 48). Compared to other birds, precocial birds such as waterfowl have a large yolk sac. One study showed that yolk sacs in precocial species ranged from 12 to 25% of the body weight. The majority of the yolk sac should be absorbed within a week.

The yolk sac should be surgically removed if clinical signs, palpation and radiography indicate nonabsorption. Surgery usually is successful if performed

before a bird becomes dyspneic. Clinical signs suggesting that surgery is necessary include swollen abdomen, dyspnea, exercise intolerance, inability to stand or walk, inappetence, weight loss or failure to grow. For surgery, birds are anesthetized with isoflurane and placed in dorsal recumbency with the legs pulled caudally. Feathers on the abdomen are plucked from flank to flank and from the keel to the cloaca, and the skin is surgically prepped (see Figure 48.13). Birds should be given 0.016 ml/g body weight of a 50:50 mixture of 5% dextrose in lactated Ringer's solution and 0.9% sodium chloride to compensate for any blood loss during surgery. Birds should be given broad-spectrum antibiotics postoperatively pending results of a yolk sac culture. Some chicks will require tube-feeding for several days before they will resume feeding, whereas others will begin to eat and gain weight one to two days postoperatively.<sup>58</sup>

A second syndrome, rupture of the yolk sac, can occur as a sequela to yolk sac retention or yolk sacculitis (the third yolk sac-related syndrome). Rupture can also occur following traumatic events in two- to three-day-old birds with normal yolk sacs. Death results from yolk-related peritonitis and shock. Yolk sacculitis and omphalitis can occur separately or concurrently in a bird and are most frequently associated with gram-negative organisms, especially *Salmonella* sp. and *E. coli* (see Color 48). Omphalitis is characterized by edema and inflammation of the abdominal wall surrounding the umbilicus. Yolk sacculitis is characterized by enlargement, hyperemia and petechiation of the wall and greenish discoloration and coagulation of the yolk sac. In most cases, omphalitis and yolk sacculitis arise from contamination of the umbilicus. Incubator and brooder sanitation are crucial for prevention of yolk sacculitis.<sup>64</sup>

- **Miscellaneous Microbial Infections:** Bacterial infections in neonates usually cause a multisystemic, fatal septicemia. Bacteriemia occurs so quickly that the entry point for the bacteria cannot be determined. The gross and microscopic lesions of septicemia are often subtle: splenomegaly, hyperemia and petechiation of the lung and gastrointestinal serosa, and congestion or focal necrosis of the liver. *Salmonella*, *E. coli*, *Pseudomonas*, *Streptococcus* and *Erysipelas* spp. are usually implicated. The incidence of bacterial septicemia can be reduced through sound brooder hygiene and by identifying and controlling infections in subclinical parents. *Salmonella* sp. have been implicated in necrotizing colitis in Anseriforme neonates. Infections may be localized or occur as part of a systemic infection including yolk sacculitis and air

sacculitis.<sup>64</sup> Aspergillosis is uncommon in healthy birds; however, neonates with immature defense mechanisms that are compromised by malnutrition or environmental stress are more susceptible to inhaled spores (see Color 23).

### Nutritional Diseases

▪ **Angel Wing:** This condition is also referred to as healed-over, slipped, crooked, rotating, tilt, sword, spear, reversed, airplane and dropped wing. Angel wing is apparently caused by the weight of the growing flight feathers placing excess stress on the weak muscles of the carpal joint. Gravity encourages the developing wing to hang and finally to twist outward. If untreated, the wing may remain in that position and the ligaments and bones will be permanently deformed (Figure 46.13). Simply taping the wing on itself (not to the body) in a normal position for three to five days is usually sufficient to correct the problem. Manganese deficiency and hypovitaminosis D<sub>3</sub> have been suggested as etiologies. Genetic factors, environmental influences or management practices have also been implicated.<sup>56,111</sup>

Angel wing has been suggested to be a problem associated with captivity; however, it has been described also in free-flying populations of *Cereopsis* in South Australia, Canada Geese in Sweden, Mute Swans in Switzerland and semi-wild Mallard Ducks in England. Most affected birds have slow natural growth rates and are from temperate or tropical areas.<sup>57</sup> Interesting differences in the susceptibility of different waterfowl species to angel wing are being recognized.

Several fast-growing species originating from the Arctic have not yet shown slipped wing. These include the Greater Snow Goose, which can grow to nearly 14 times its hatching weight by three weeks of age, and the Barnacle Goose that can grow to thirteen times. The Swan Goose and Hawaiian Goose, in similar conditions of light, heat, food and water, increase their weight by only a factor of eight. Similar slow growth rates occur for most low-latitude ducks, geese and swans.

Differences in food intake are also apparent among Anseriformes from different geographic regions. For instance, *Cereopsis* goslings spend a large part of each 24 hours sitting or sleeping. Snow Geese, on the other hand, are restless even in the dark and will feed steadily if given the chance, with frequent pauses for brief periods of sleep. The result of these differences is that the Arctic species fledge much faster than temperate or tropical species. In nature, this quick



**FIG 46.13** Angel wing is characterized by droop and outward twist of the wing. In this Black Swan cygnet, the carpus is ventrally displaced (arrows) (1994 Busch Gardens Tampa. All rights reserved.).

maturation is vital so that the birds are ready for migration before winter storms occur.<sup>57</sup>

These findings would suggest that angel wing is associated with overfeeding tropical and temperate species, causing an excessively rapid growth. Deformities are more common in the heavier members of a brood and are more frequent in males, which grow more rapidly. Angel wing is also more common during warmer weather when young birds are able to use more dietary energy for growth and less to maintain body temperatures. Angel wing seems to occur more commonly in birds fed ad libitum and provided inadequate areas for exercise. In one flock, four out of six New Zealand Gray ducklings developed angel wing, apparently after the accidental feeding of turkey starter diet (28% protein) instead of chick diet (18.5% protein).<sup>57</sup>

Excessive energy, excessive protein or a deficiency of vitamin E have all been suggested as dietary factors in the occurrence of angel wing. Clearly, a balanced diet formulated for tropical and temperate waterfowl species is required. A study with Mallard, Pintail and Redhead ducklings (slow growth-rate species) indicated that the protein requirement during the first three weeks of life is below 19%. Optimum growth curves occurred when the animal protein content of the diet was 8%.

Factors that may reduce the incidence of angel wing include exercise (swimming, diving) and plenty of grass and other green foods. Birds originating from low latitudes should not be fed high-energy, high-protein foods. It is clear that waterfowl chicks from different species must be treated differently. Birds originating north of the Arctic Circle should be provided constant light, plenty of water and a constant supply of food that is relatively high in protein. Those originating from equatorial regions should be provided 11 hours of darkness per 24 hours; these birds can consume comparatively less food of a lower quality.<sup>57</sup>

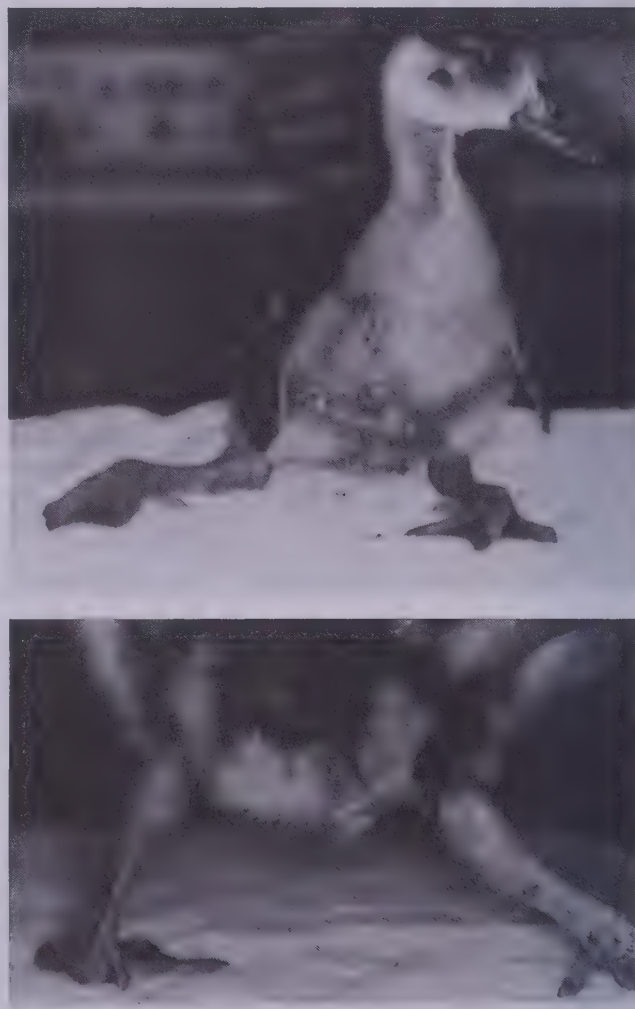- **Perosis:** Also known as slipped tendon, perosis is characterized by enlargement of the hock, bending deformities of the mediotarsal and tarsal metatarsal bones and medial luxation of the Achilles tendon, which prevents the bird from bearing weight on the affected limb (Figure 46.14). One suggested etiology is a manganese deficiency caused by excessive calcium supplementation (calcium binds manganese). If the problem occurs before two weeks of age, it is likely that the hen's diet is deficient in manganese. Ducklings and goslings fed a manganese-deficient diet will develop perosis in two to ten weeks.<sup>111</sup> Angel wing and perosis may have a similar etiology.

A leg undergoes rapid pathologic changes once it begins to deviate (see Color 8). Bandaging or splinting the leg is usually unsuccessful. Trochlear grooving or transplantation of the insertion of the Achilles tendon laterally have been attempted. Open reduction and stabilization of the luxated tendon are successful in some cases. An incision is made through the skin and over the posterolateral aspect of the joint midway between the displaced tendon and lateral condyle of the tibiotarsal bone (Figure 46.15). The tendon is dissected free of its trochlear and medial adhesions and reduced to its normal position in the trochlear groove. The tendon sheath is sutured to the lateral periosteum and retinaculum with simple interrupted 3-0 absorbable suture. The skin incision is closed with simple interrupted 4-0 nonabsorbable suture. A tongue depressor can be used as a splint for a week. The patient should be using its leg normally by the second postoperative week.<sup>118</sup>

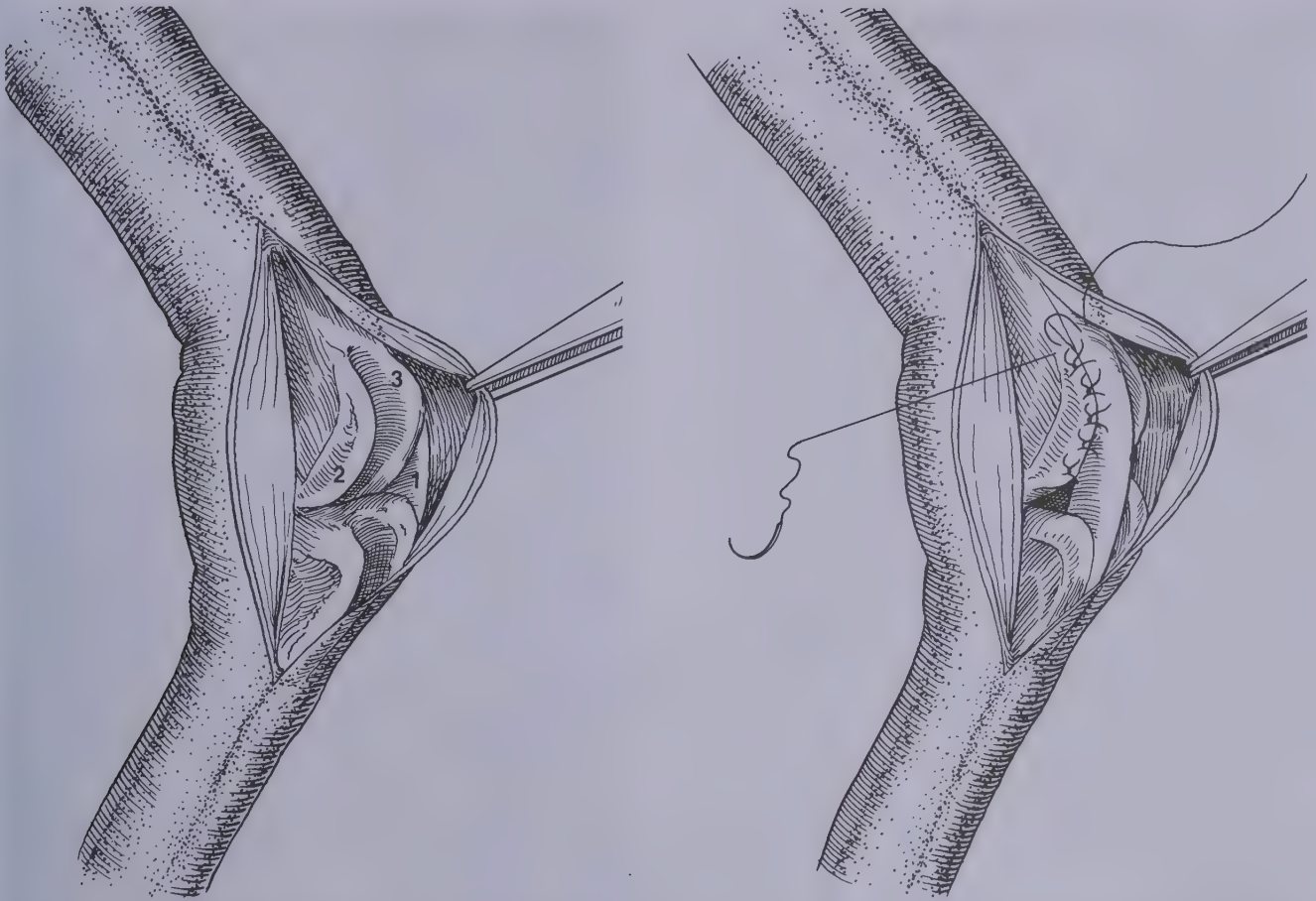
- **Nutritional Secondary Hyperparathyroidism:** Ducklings whose diets are poor in calcium or contain excessive phosphorus may develop fibrous osteodystrophy or osteomalacia. The birds may appear reluctant to move. Abscesses or blisters of the keel often develop in birds that are non-ambulatory. Soft bones

and enlarged parathyroids are common postmortem findings (see Color 14).<sup>45</sup>

- **Rickets:** Rickets results from a lack of vitamin D. The first clinical signs are lameness, retarded growth and bent or twisted breast bones. Providing a proper diet will reverse the symptoms in two to four weeks unless advanced changes have occurred.<sup>45</sup>



**FIG 46.14** Cranial and caudal view of a duckling showing the clinical appearance of a medially luxated Achilles tendon of the right hock joint. Manganese deficiencies (possibly exacerbated by over-supplementation of calcium) have been suggested as a cause (courtesy of John Olsen).



**FIG 46.15** An incision is made through the skin and over the caudolateral aspect of the joint midway between the 1) displaced tendon and 2) lateral condyle of the tibiotarsal bone. The tendon is dissected free of its trochlear and medial adhesions and reduced to its normal position in the 3) trochlear groove. The tendon sheath (right) is sutured to the lateral periosteum and retinaculum with simple interrupted 3-0 absorbable suture. The skin incision is closed with simple interrupted 4-0 nonabsorbable suture. A tongue depressor can be used as a splint for a week. The patient should be using its leg normally by the second post operative week (modified from Wolfe<sup>118</sup>).

## Restraint, Handling and Anesthesia

### Capture and Handling

Various nets can be used to catch waterfowl in the confines of an aviary. In some cases, a group of birds can be herded to a corner of the enclosure and captured together or individually. On large ponds, a boat or several people wading in the water may be needed to capture waterfowl. A bright spotlight can be used at night to “freeze” a bird, allowing it to be quietly approached.

Heavy-bodied species should not be carried by using the wings or feet alone, although smaller species can be restrained by their wings. Smaller ducks can also be held by grasping the back and wings and using the thumb and fingers to restrain the feet (Figure 46.16). For larger birds, the base of both wings should be grasped with one hand while the other hand and arm supports the body. These birds should be carried under one arm, with their head facing to the back. The arm is wrapped around the wings and a hand is used to support the body and control the legs (Figure 46.17). A wrap using Velcro adhesive straps or a pillowcase-type bag with a hole in the end for the head and neck can be used for restraining waterfowl during certain examinations, blood collection and radiographic procedures.

### Field Immobilization and Capture

Occasionally, a practitioner may be asked to catch waterfowl from a pond. Attempts to capture these free-ranging birds can be frustrating. Capture nets, mist nets, spring-loaded nets, funnel nets and rocket or cannon nets are useful but are not typically available to private practitioners.<sup>6e</sup>

Several agents have been used to immobilize free-ranging ducks or geese, with sodium amobarbital being the most frequently used. In test studies, an oral dose of 100 mg/kg was found to produce muscle incoordination approximately 20 minutes after ingestion. The test ducks never reached a plane of anesthesia but were immobilized sufficiently to allow easy capture. For field immobilization, one cup of hen scratch was mixed with 900 mg of dissolved amobarbital and allowed to dry in shallow pans (50 pounds of scratch will dry in about four hours with the aid of fans). Animals should not be approached for 60 minutes after feeding to ensure that they are adequately immobilized and will not fly to another location and die. Recovery may take up to eight hours.<sup>36</sup>


The drug has a low therapeutic index and should be used only in a field setting when restraint is critical and all other methods of capture have failed. There must be a fast method of retrieving birds from the water before they drown. Some birds may consume excessive concentrations of the drug and die. There was an eight percent mortality rate in one study of ducks. Half of these losses may have been prevented with post-capture gastrolavage or tubing with fresh water to dilute and accelerate passage of the drug.<sup>36</sup>

Another study evaluated seven agents as possible immobilizing drugs for field use on ducks. The only compound to satisfy the study criteria was tribromoethanol. Alpha-chloralose, methoxymol, metomidate, pentobarbital sodium, secobarbital sodium and thiopental sodium were all inferior to tribromoethanol. At the median effective dosage (ED<sub>50</sub>) for immobilization (100 mg/kg of body weight), the duration of induction

was 2.4 minutes, immobilization was 8.7 minutes, and recovery was 1.3 hours. The median lethal dosage (LD<sub>50</sub>) was 400 mg/kg of body weight. None of these drugs was given in feed in field situations.<sup>6</sup> The study refers to other work indicating that a drug-to-bait ratio of three grams tribromoethanol per cup of whole corn was effective.<sup>10</sup>

### Anesthesia

Waterfowl, like other birds, have a highly variable regional response to pain. The most sensitive areas are the beak, head, feet and feather follicles. Removing one or two feathers may elicit a more violent reaction than suturing a cutaneous wound or cutting skin. It is frequently possible to handle viscera without evoking any sign of pain from a conscious bird.



**FIG 46.16** Restraint technique used for small waterfowl. This technique should not be used for larger Anseriformes. Some small duck species can be restrained (bottom) by folding the legs caudally and holding the wings and legs in one hand (1994 Busch Gardens Tampa. All rights reserved.).





**FIG 46.17** Larger waterfowl should be restrained by holding the legs against the bird's body and tucking the bird, with head facing backward, under the arm of the handler (1994 Busch Gardens Tampa. All rights reserved.).

Local anesthesia is often sufficient for performing superficial procedures. Lidocaine hydrochloride (2%) is one of the safest local anesthetics for waterfowl; however, general depression can occur with high doses.<sup>4</sup> Reasonable amounts relative to weight are usually safe and effective. Using 1 ml of 2% procaine in ducks and 3 ml in swans was found to provide good local anesthesia with few problems.

Isoflurane anesthesia is convenient for performing minor procedures, positioning for radiographs or major surgery. Mask induction and maintenance for short procedures (< 15 minutes), or mask induction followed by intubation for longer procedures are common. The neck must be extended in intubated, long-necked birds to prevent the trachea from folding over

the end of the tube, causing partial or complete airway obstruction. Halothane and methoxyflurane have also been used in waterfowl but are inferior to isoflurane. Many waterfowl species have profuse salivary secretions under anesthesia and may benefit from the use of an antisialogogue such as glycopyrrolate.<sup>42</sup>

Induction times for gas anesthetics in waterfowl are frequently prolonged when compared to psittacines, probably due to the substantial subcutaneous fat deposits in the former. Recovery periods are also prolonged.<sup>54</sup> Breathing amplitude (an indicator of tidal volume) has been shown to decrease by 40 to 50% and the frequency of respiration increases 20 to 50% when birds are in dorsal recumbency. This causes a 10 to 60% decrease in minute ventilation, probably due to visceral compression of the air sacs.<sup>90</sup> Positive pressure ventilation can be used to decrease these effects. A peak positive pressure of 15 to 20 cm of water is adequate.<sup>54</sup>

With both isoflurane and halothane, waterfowl tend to change planes of anesthesia rapidly and unexpectedly. Cardiac monitoring of anesthetized waterfowl can be done with a doppler flow probe placed under the tongue, against the carotid artery or on the ventral surface of the elbow on the recurrent ulnar artery. An esophageal stethoscope or ECG can also be used. A rectal or esophageal thermometer is useful to monitor body temperature. Time of recovery from anesthesia is directly proportional to the amount of heat loss. The lower the body temperature, the longer the anesthetic recovery period.<sup>54</sup>

In one study evaluating isoflurane and halothane, 2.2 to 2.7 kg Pekin Ducks were masked with a concentration of 3.5% anesthetic gas with an oxygen flow of 3 l/min. They were intubated with 5 mm cuffed endotracheal tubes (uncuffed tubes are preferred in birds) and maintained with 2 to 3% isoflurane or 2 to 2.5% halothane. When anesthesia was discontinued, ducks received oxygen for two minutes prior to breathing room air. The ducks showed no distress from the mask or vapors.<sup>35</sup>

Palpable reflexes were lost during induction with both agents. Isoflurane induction was significantly shorter than halothane induction. Slow to absent pedal and wing reflex characterized a surgical plane of anesthesia. Both anesthetics had a smooth recovery pattern of similar length. Respiration was regular and deep with halothane and isoflurane. Both anesthetics significantly depressed respiratory rate,

TABLE 46.7 Gas Anesthetic Parameters in Pekin Ducks

	Induction Time	Respiratory Rate - (bpm)	Heart Rate - (bpm)	Blood Pressure - (mmHg)
Baseline	—	15 - 23	173 - 207	114 - 142
Halothane	5 - 9 minutes	4 - 6	230 - 388	96 - 128
Isoflurane	3 - 5 minutes	7 - 11	176 - 310	107 - 131

Values at 30 minutes post-induction  
Adapted from Goetz.<sup>35</sup>

increased heart rate (HR) and decreased blood pressure (Table 46.7).<sup>35</sup>

Cardiac rhythm was not affected by isoflurane. With halothane, four of eight ducks showed abnormal rhythms. Three ducks developed abnormal ECGs with ventricular bigeminy and multifocal ventricular rhythms (perhaps due to increased  $\text{paco}_2$ ). One duck developed ventricular fibrillation and died. Mean arterial blood pressure decreased with both anesthetics.<sup>35</sup>

Isoflurane is superior to halothane because induction and recovery times are shorter, there is less preoperative stress and less postoperative hypoglycemia and hypothermia. Isoflurane also causes fewer cardiac arrhythmias and is less of a cardiopulmonary depressant. The editors believe that injectable anesthetics are a poor choice in Anseriformes and should be avoided (see Chapter 39).

## Diseases

The most prominent problems in a group of Anseriformes presented over a six-year period to the Canadian Disease Research Institute were improper management, nephritis and reproductive disorders.<sup>103</sup> At the National Zoological Park, 1,500 Anseriformes that died during a ten-year period were found to have many diseases similar to those described in free-ranging Anseriformes. Diseases identified included botulism, erysipelas, tuberculosis, pasteurellosis (avian cholera), salmonellosis, other bacterial septemicias, aspergillosis, candidiasis, amyloidosis, gout, hematozoan infections, schistosomiasis, echinuriasis and others (Table 46.8).<sup>73,74</sup> Several diagnostic facilities may be helpful in resolving problems associated with Anseriformes.

## Non-infectious Diseases

### Bumblefoot

Bumblefoot (pododermatitis) occurs frequently in captive waterfowl, especially swans. It is believed to be caused by rough, hard surfaces such as concrete pools or pens that cause trauma to the bottom of the birds' feet (see Chapter 16). Large, lumpy protuberances or eroded or scabbed lesions can develop (see Color 46). A bird may naturally recover from mild lesions if it is placed in a pen with adequate pool space and easy access in and out of the pool (Figure 46.18).

Treatment of bumblefoot is difficult and often unrewarding. If a bird is not lame, it may be best to forego treatment that frequently increases the severity of the problem. Suggested therapies that include surgical debulking of the lesion and medical management frequently fail. The bird must be maintained on soft footing during the recovery period.<sup>b</sup> One common treatment is a topically applied combination of dimethylsulfoxide (DMSO) (30 ml), dexamethasone (2 mg) and chloromycetin succinate (200 mg) (or other appropriate antibiotics based on sensitivity). This is applied to the lesion every eight hours. Recovery may take three to six weeks.<sup>104</sup> Another treatment includes daily cleaning of the lesion with iodine scrub followed by the application of camphor spirits (drying agent) and benzoin (toughens the tissues).<sup>91</sup> Supplemental vitamin A and an improved diet may also be helpful (see Chapter 16).

### U.S. Diagnostic Facilities for Resolving Problems in Anseriformes

The federal diagnostic facility is the U.S. Fish and Wildlife Service, National Wildlife Health Center, Madison, Wisconsin. Several states have active wildlife disease programs located at: Fairbanks, Alaska; Sacramento, California; Fort Collins, Colorado; Rose Lake, Michigan; Hampton, New Jersey; Delmar, New York; Fargo, North Dakota; Madison, Wisconsin; and Laramie, Wyoming.<sup>28</sup>

There are three regional wildlife disease programs affiliated with universities. These include the Southeastern Cooperative Wildlife Disease Study, University of Georgia, Athens; Northeastern Center for Wildlife Disease, University of Connecticut, Storrs; and Colorado Wild Animal Disease Center, Colorado State University, Fort Collins. The University of Florida-Gainesville and Virginia Polytechnic Institute and State University-Blacksburg also have active wildlife disease programs. Cornell University has the Duck Research Laboratory located at Box 217, Eastport, New York 11941, telephone (516) 325-0600. The primary focus of the Duck Research Laboratory is on production duck management, nutrition and disease, but it also has involvement with wild fowl. The staff has considerable expertise and diagnostic capability available. The U.S. Department of Agriculture, Veterinary Services Laboratory, Ames, Iowa can also accept diagnostic specimens that have been submitted through appropriate channels.

### Oil-contaminated Birds

Anseriformes are often affected by oil spills. The oil destroys the insulating and waterproofing properties of the plumage. Oil may also be associated with reproductive disorders; alteration of neural, endocrine and osmoregulatory functions; toxic changes in the gastrointestinal tract, pancreas and liver; aspiration pneumonia; renal damage; and Heinz-body anemia. Mortality of birds affected by oil spills often exceeds 80% but can be reduced to 15% with proper treatment (see Chapter 15).<sup>16,65</sup>

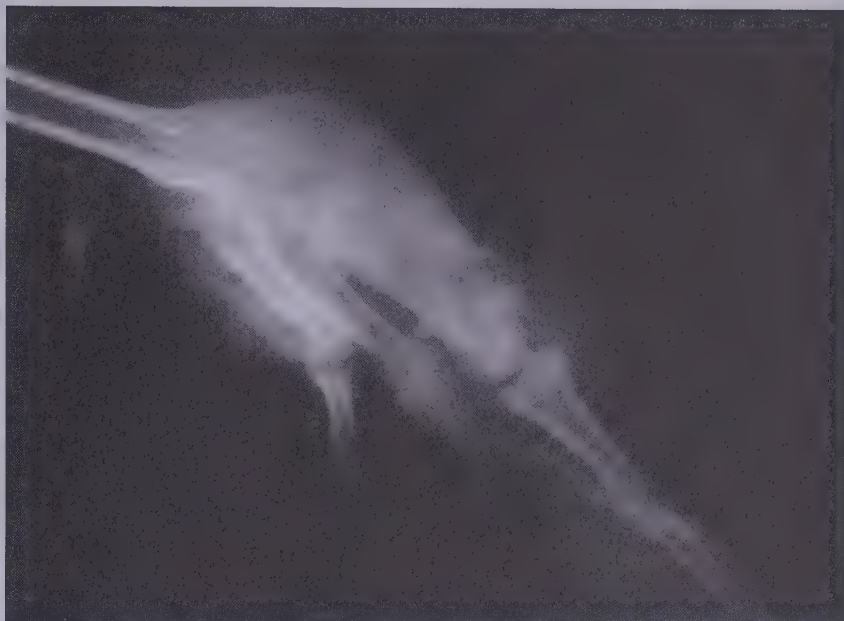### Amyloidosis

Amyloidosis is a common finding in captive and domestic waterfowl, but is rarely diagnosed in free-ranging birds. Gross lesions include pallor and enlargement of the liver, spleen or adrenal glands. Less commonly affected organs include the pancreas, kidney, intestine, lung and heart. Affected organs are firm and usually yellow-brown in color. Histologically (with hematoxylin-eosin stain), amyloid is amorphous, eosinophilic, acellular material that separates, compresses and displaces normal cells. With Congo red stain, amyloid is orange-red and slightly fibrillar, and under ultraviolet light it fluoresces when treated with thioflavine S or T.<sup>116</sup>

The pathogenesis of amyloidosis appears to be complex and is poorly understood.<sup>18</sup> Amyloidosis is found in association with a number of chronic primary diseases and can be induced by some types of immunization. Amyloidosis in domestic ducks has been associated with crowding and social stress.<sup>116</sup> Although there is no treatment for amyloidosis, maintenance of environments with minimal stress and low exposure to infectious diseases should decrease its occurrence.<sup>73</sup>

### Capture Myopathy

Capture myopathy has been reported in Lesser Snow Geese and Ross's Geese that were captured with rocket nets and restrained for several hours. Some birds (18 hours post-capture) were stiff and unable to fly but could walk. Others were unwilling to walk and appeared depressed. The only gross necropsy lesions were pallor of the skeletal muscles and pulmonary and hepatic congestion. Histologically, there was lysis and fragmentation of skeletal muscle fibers. The



**FIG 46.18** Severe foot infections can progress to osteomyelitis. In this case, osteomyelitis secondary to bumblefoot was resolved, but resulted in ankylosis of the tarsometatarsal phalangeal joint.

prevalence and importance of this condition in captured free-ranging waterfowl are unknown, but a small number of restrained birds are stiff and reluctant or unable to fly when released (see Chapter 48).

### Botulism

Botulism (limberneck, western duck sickness, duck disease, alkali poisoning) occurs from the ingestion of toxins produced by the bacterium *Clostridium botulinum*. It is a paralytic, often fatal disease. Waterfowl die-offs are usually caused by type C toxin. *C. botulinum* is commonly found in wetlands (especially those overlying limestone and alkaline water). It is resistant to heat and drying and remains viable for years in a spore form. The vegetative form produces the toxin and requires dead organic matter and an anaerobic environment. The presence of carcasses of invertebrates and vertebrates, rotting vegetation, poor water quality and high temperatures promote growth of *C. botulinum*. High temperature and vertebrate carcasses also promote maggot infestations. Birds that eat maggots may consume the toxin at the same time.<sup>28</sup>

The botulism toxin affects peripheral nerves and results in paralysis of voluntary muscles and an inability to sustain flight. Once paralysis of leg muscles has occurred, ducks may attempt to swim using their wings. By comparison, birds with lead poison-

ing retain their ability to walk and run. As the disease progresses, paralysis of the neck muscles results in an inability to hold the head erect. Death from drowning is common. Many affected waterfowl (75 to 90%) can be saved by being provided fluids, a cool environment and antitoxin.<sup>28</sup> Removing toxins and maggots from the stomach by gavage may increase the recovery rate.

Disease prevention requires control of fluctuating water levels during hot summer months and a prompt removal of animal protein to decrease the source of toxin production and maggot infestations. A single waterfowl carcass can produce several thousand toxic maggots. A duck can become intoxicated by eating only two to four maggots. Carcasses should be buried or burned. The toxin is quite stable in the environment. Botulism outbreaks have occurred worldwide. U.S. outbreaks usually occur west of the Mississippi River. In the United States and Canada, most outbreaks occur from July to September, although cases are seen in south Florida on a year round basis.<sup>28</sup> A commercial type C toxoid is available for mink and has proven to be effective in birds. One-half of the dose recommended for mink should be used in birds (Harrison GJ, unpublished).

**Lead Poisoning**

Lead poisoning is a common problem in waterfowl because of the ingestion of lead shot. Less common causes are ingestion of lead fishing sinkers, mine wastes, paint pigments, bullets and other lead objects. Lead shot has been banned in many states for hunting, but is still used in skeet shooting.<sup>82</sup> Within the United States, annual waterfowl losses from lead poisoning are between 1.6 to 2.4 million birds. Lead poisoning in Trumpeter Swans occurred when drought conditions caused water levels to drop, allowing birds to reach previously unattainable shot.<sup>15</sup>

Clinical signs of lead intoxication include weight loss, weakness and depression, bright green diarrhea, anorexia and variable neurologic disorders such as leg paresis, wing droop and abnormal head tremors.<sup>15</sup> Blood (2 to 5 ml) should be collected in lead-free tubes containing sodium citrate. Treatment includes use of chelating agents such as Ca+ disodium EDTA, DMSA, PA and DTPA (see Chapter 37).<sup>28</sup>

Gastric lavage and endoscopy can be used to remove lead shot from the ventriculus. Birds are fasted for 8 to 12 hours, masked down with isoflurane and intubated. A flexible polyvinyl chloride tube (1.5 cm in diameter) is lubricated and passed (approximately

**TABLE 46.8 Typical Disease Prevalence in Captive Anseriformes**

Type	Condition*	Number Affected
<b>Viral</b>	Duck Virus Enteritis	30
<b>Bacterial</b>	Pasteurellosis	2
	Tuberculosis	33
	Erysipelas	3
	Salmonellosis	1
<b>Fungal</b>	Aspergillosis	99
	Candidiasis	62
<b>Parasitism</b>	Haemoproteus	1
	Capillariasis	6
	Echinuriasis	1
	Amidostomiasis	2
	Tetrameriasis	4
	Cestodiasis, intestinal	16
	Schistosomiasis, intestinal	19
	Trematodiasis	6
	<b>Toxicity</b>	Botulism
Talon		6
<b>Noninfectious</b>	Amyloidosis	122
	Gout	52
	Bumblefoot	3
	Predator	106
	Foreign Body, GI	3
	Vandalism	5

Important pathologic conditions in 1528 captive Anseriformes necropsied at the National Zoological Park, 1975 - 1984. Adapted from Montali.<sup>73</sup>

\*An individual bird may have had more than one condition.

110 cm in a Trumpeter Swan) to the cranial aspect of the ventriculus. The bird is tilted, head down, at a 45° angle on the table. Large quantities of warm water are pumped into the ventriculus using a 140 ml gastric lavage syringe. Water pressure and gravity will force most of the food, grit and lead pellets out of the intestinal tract. Radiographs can be used to confirm that the lead pellets have been removed. A colonoscope can be used to visualize and remove remaining lead particles (see Chapter 37).<sup>15</sup>

**Zinc Poisoning**

Zinc toxicity has been reported in captive Anseriformes following the ingestion of pennies minted after 1983 (containing 98% zinc) or metal fence clips (96% zinc). Clinical signs include weight loss, depression, anorexia and posterior paresis. Normal serum levels of zinc are 1.84 to 4.65 µg/g; normal liver levels are 34.9 µg/g. Abnormal levels seen in an affected group of ducks were 12.6 to 16.6 µg/g (serum) and 242 to 548 µg/g (liver). Pathologic findings include necrotizing ventriculitis and degenerative pancreatic lesions re-

sulting in acinar atrophy and ductular proliferation. Exposure to a penny for two months in the ventriculus is sufficient to cause toxicity.<sup>121</sup> Treatment consists of endoscopic removal of the foreign bodies and chelation therapy (see Chapter 37).

### Mycotoxicity

Mycotoxins are toxic metabolites produced by molds. Mold-contaminated foods are frequently unpalatable and avoided by free-ranging waterfowl, while captive birds may be forced to consume the moldy food. Diagnosis in field cases is difficult, because some toxins have subtle or nonspecific effects. Clinical changes may be delayed and animals may have changed food by the time symptoms occur, making it difficult to find the source of the toxin. Moldy food may contain more than one toxin, and analytical procedures for identification of toxins are not readily available. Aflatoxicosis, fusariotoxicosis and ergotism have been described in free-ranging waterfowl.

Aflatoxin poisoning is caused by the metabolic by-product of *Aspergillus flavis*, which can be found in feed (especially peanut products and corn). Aflatoxin has been associated with liver cirrhosis in older ducks. Nodular hypoplasia or hepatoma may occur in chronic cases. Young ducks exposed to aflatoxin die at one to two weeks of age, showing signs of inappetence, depressed growth, cyanosis of the feet and legs (caused by subcutaneous hemorrhages), ataxia, convulsions and opisthotonos.<sup>111</sup> Gross lesions include a slightly enlarged, putty-colored liver, pale and slightly swollen kidneys, and petechiae on the kidneys and pancreas. In birds over three weeks of age, the liver is firm and slightly shrunken and has a reticulated pattern; ascites and hydropericardium and petechiation may also be noted. The LD<sub>50</sub> for day-old ducklings is approximately 0.3 to 0.4 mg/kg.<sup>111, 116</sup>

Immunosuppression with chronic aflatoxicosis may be a problem with waterfowl as it is with some other species. The significance of aflatoxicosis in free-ranging waterfowl is unknown. The disease has occurred among Mallards consuming waste peanuts in the southern United States. Birds recover quickly from short-term sublethal exposure to aflatoxin once the source of toxin is removed from the diet.<sup>116</sup>

Fusariotoxicosis is caused by *Fusarium* spp., which are common saprophytes and parasites on plants. Their presence on cereal grains is important because of the variety of toxins they produce, including zearalenone (F<sub>2</sub>) and tricothecene toxins (including

T<sub>2</sub>). Zearalenone was found to interfere with sperm production in ganders but not with egg production in geese (it causes hyperestrogenism in domestic mammals). Clinical signs of T<sub>2</sub> intoxication include vomiting, thirst and depression. Geese force-fed 60 to 90 grams of contaminated grain developed head and leg tremors and died within 19 hours. Gross lesions were restricted to mucosal necrosis in the esophagus, proventriculus and ventriculus.<sup>116</sup>

Ergotism is caused by toxic alkaloids formed by the fungus *Claviceps purpurea*, which parasitizes and forms sclerotia in place of the seed in certain cereal grains. Heavy mortality was seen in two- to four-month-old Muscovy Ducks fed wheat containing 1.7% ergot sclerotia. The birds died 48 hours after developing lethargy and diarrhea. Older birds were not affected. Necrosis and gangrene of the extremities, which occur in mammals, have not been reported in waterfowl. Ergotism is unlikely in free-ranging waterfowl that have a choice of food.<sup>116</sup>

### Algal Toxins

Algae blooms usually occur in eutrophic waters in warm, sunny weather. The algae must accumulate in shallow water so that the liberated toxin will not be diluted. Algae often concentrate on the downwind shore of lakes. Some of the common genera of blue-green algae implicated in animal intoxication include *Nodularia*, *Rivularia*, *Aphanizomenom*, *Oscillaria*, *Anabaena*, *Microcystis*, *Collosphaerium*, *Nostoc* and *Gloeotrichia*. An *Anabaena* bloom on Storm Lake in Iowa was associated with the deaths of 5,000 to 7,000 Franklin's Gulls, 560 ducks, 400 coots and 200 pheasants. Death occurred two to ten minutes after ingestion of a minimal lethal dose. The very fast death factor of this *Anabaena* was found to be a depolarizing neuromuscular blocking agent that was rapidly absorbed following ingestion.

Clinical signs may be peracute prostration and death, restlessness, blinking of the eyes, repeated swallowing, salivation and regurgitation. There is no specific treatment, but oral administration of charcoal and mineral oil has been suggested. Access to clean water and food should be provided. There are no specific histologic lesions and there are no tests to detect these toxins. Diagnosis is subjective and is based on identifying toxic algae in an affected bird's environment and ruling out other etiologies of similar clinical signs.<sup>116</sup> Control in the wild is not practical. Algae blooms may be controlled in ponds with copper sulfate, or by increasing water flow to remove nutri-

ents and dilute the algae; however, copper sulfate can also be toxic.

### Marine Dinoflagellates

Waterfowl may be poisoned by mollusks living in areas affected by "red tides." Several thousand Lesser Scaup died in Florida as a result of "red tide" caused by *Gymnodinium breve*. *Gonyaulax catenella* and *G. tamarensis* are other dinoflagellates that can be a problem. Clinical signs include weakness, reluctance to fly, dehydration, nasal and oral discharge, lacrimation, edema of the nictitating membrane, bilateral mydriasis, chalky yellow diarrhea, tachypnea, tachycardia and depressed blood pressure.<sup>44</sup> No specific gross or histologic lesions have been described. Recovery occurred rapidly when affected birds were placed in fresh water.<sup>116</sup>

### Plant Toxicities

Some plants may be toxic to waterfowl. A seven-week-old goose was treated for sudden onset of ataxia, progressive paresis, recumbency and prolific salivation. Its pen mate died with similar clinical signs. Microscopic lesions included occasional hemosiderin-containing macrophages in the proximal lamina propria of the small intestine. Multifocal loss of cardiac muscle striation was consistent with oleander toxicity. Oleander leaves were found in the proventriculus and ventriculus.<sup>60</sup>

### Chemicals

Fertilizers or pesticides should not be used around birds or where runoff may enter animal enclosures. In one case, several ducks died with evidence of coagulopathy while others in the same enclosure were bleeding and had prolonged prothrombin times. The poisoning was attributed to the ingestion of insects that had consumed brodifacoum (Talon). Diagnosis was confirmed by finding 43 ppm brodifacoum in the liver.<sup>73</sup>

### Tumors

Spontaneously occurring tumors are infrequently described in waterfowl. The tumors that do occur are histologically similar to those seen in mammals. At the Philadelphia Zoo, between 1901 and 1963, there were only 19 primary neoplasias in the 19,000 birds examined. The largest number of spontaneous tumors was reported in 1949 when 148 hepatomas were found in 1,113 ducks. The youngest ducklings died when they were 143 days old, 14.5% died between three months to one year of age, 23.7% died between 1 and 1.5 years of age and 3.5% died between 1.5 and 2 years of age. Periportal inflammation and degen-

eration, bile duct proliferation, regeneration and nodular hyperplasia of liver cells with adenomatous formation were common.

This report of spontaneously occurring hepatomas is important today in view of tumors resulting from the feeding of Brazilian ground nut meal. Young ducks are most susceptible to aflatoxin toxicity (see Color 20). Hepatic tumors developed in 5 of 37 one-week-old Khaki Campbell ducklings when fed aflatoxin. Similar lesions developed in 11 ducks that were fed a ration containing 0.5% Brazilian ground nut meal for 14 months.<sup>87</sup>

### Egg-related Peritonitis

Egg-related peritonitis is life-threatening and requires intense and aggressive care.<sup>117</sup> It is not uncommon to find old remnants of egg adhered to the abdominal wall or viscera of waterfowl hens at necropsy. These findings are incidental and are usually not related to the cause of death. It is assumed these are eggs that were laid intra-abdominally and were partially reabsorbed (see Chapter 29).

## Infectious Diseases

A compilation of data on a variety of bacterial, fungal, parasitic and viral diseases seen in waterfowl can be found in Table 46.9. The reader is also referred to the appropriate etiology chapters elsewhere in this book. Few investigations have been performed on the pharmacokinetics of antibiotics and other therapeutics in free-ranging and captive waterfowl. Antibiotics and other therapeutics used in other aspects of avian medicine can often be used in waterfowl at similar dosages.

### Aspergillosis

Aspergillosis is commonly seen at necropsy in Anseriformes. Diagnosis and treatment can be difficult (see Chapter 35 and Color 22).<sup>48,80,86,120</sup>

### Parasites

Schistosomes in the genera *Trichobilharzia* and *Dendritobilharzia* were considered the cause of high mortality rates (90%) in a group of geese. The principal pathologic changes included thrombosis of the caudal mesenteric vein, fibrinohemorrhagic colitis and hepatomegaly. This parasite is frequently found in waterfowl but is rarely associated with disease. Weight loss and lameness were the principal clinical findings. Parasites were identified in the lumen of the thrombosed vessels. In general, lesions associated with schistosomes are secondary to reactions to the

**TABLE 46.9 Bacterial, Fungal, Viral and Parasitic Diseases of Anseriformes\***

DISEASE/AGENT	HOST RANGE	TRANSMISSION	CLINICAL SIGNS	TREATMENT/CONTROL
Aspergillosis <i>Aspergillus fumigatus</i> <sup>8,28,44,93,111,116</sup>	All species varying susceptibility	Airborne spores; moldy litter or feed	Respiratory signs; chronic debility	Prevent exposure; surgical excision of affected tissue.
Avian cholera <i>Pasturella multocida</i> <sup>8,14,28,50,93,111,116</sup>	Most species highly susceptible; epidemics in wild waterfowl and aviaries, mortality up to 50%	In excrement and respiratory secretions; recovered birds are carriers	Peracute death; acute form - anorexia, dyspnea, diarrhea, mucoid oral discharge; chronic form - dyspnea, diarrhea	Isolate affected birds; burn/bury corpses; autogenous bacterin every three months <sup>9</sup> ; A, B, E, F, H*
Avian diphtheria, contagious epithelioma, avian pox, Poxvirus <sup>8,28,111,116</sup>	Undefined, most Anseriformes; seen in Greenwing Teal, Canada and Hawaiian Geese, Mute and Tundra Swans, Mallard Duck	Mosquitoes, direct contact, skin wounds	Wart-like growths on unfeathered skin, dysphagia, dyspnea if lesions in pharynx	Self-limiting, course long; supportive care; control vectors; efficacy/safety fowl pox vaccine undetermined
Avian encephalomyelitis, epidemic tremors Picornavirus <sup>8,111</sup>	All species; affects chicks 1-2 weeks old	Egg transmission possible	CNS signs in chicks, decreased egg production	No treatment, vaccinate
Avian influenza, fowl plague Orthomyxovirus <sup>8,44,93,111</sup>	Ducks and other anseriformes; rare; not reported in wild waterfowl	Inhalation, direct contact, excrement	Sinusitis - mild to severe, mucopurulent or caseous	Reduce stress and crowding, supportive care
Chlamydiosis, ornithosis <i>Chlamydia psittaci</i> <sup>8,28,44,93,111</sup>	All species, young mainly; 20-70% mortality in ducklings possible	Excrement; inhalation; asymptomatic carriers	Conjunctivitis, rhinitis, sinusitis, diarrhea, weakness	Chlortetracycline 0.044% in feed 3-6 weeks; doxycycline
Colibacillosis <i>Escherichia coli</i> <sup>8,44,93,111</sup>	All species; common	Excrement; ingestion	Septicemia, death, diarrhea, decreased hatchability, omphalitis, salpingitis, bumblefoot	Sanitation, antibiotics based on sensitivity; A, B, G*
Duck plague, duck viral enteritis Herpesvirus <sup>8,11,28,50,93,111,116</sup>	Ducks, geese, swans; susceptibility varies; sporadic outbreaks, see in spring; mortality up to 100%	Excrement - ingestion or inhalation, free-ranging waterfowl carriers	Peracute death, hematocchezia, depression, photophobia, epiphora	No therapy, live-virus vaccine, <sup>9</sup> prevent access to carriers and outside water
Duck virus hepatitis Picornavirus <sup>8,92,93,111,116</sup>	Seen in domestics; not reported in free-living waterfowl; ducklings 2-6 weeks old ≤ 90% mortality	Excrement; ingestion or parenteral	Peracute death within hours; sluggishness, paddling of feet, CNS signs	Hyperimmune serum, vaccinate breeders MLV vaccine before laying; vaccinate day old chicks <sup>9</sup>
Eastern and western encephalomyelitis virus, Alpha Virus/Togavirus <sup>8,111,116</sup>	All species; clinical disease rare; not reported in free-living waterfowl	Insect vectors	Asymptomatic or CNS signs; morbidity and mortality highest in chicks	None; vaccine for horses used in ratites and pheasants
Erysipelas <i>Erysipelothrix insidiosus</i> <sup>8,44,93,111</sup>	All, 30% mortality in ducklings	Wound infection or ingestion	Depression, diarrhea, inappetence	D; <sup>a</sup> Bacterin for turkeys may be effective by SC or aerosol (ducklings)
Goose gonorrhoea, Neisseria-like organism <sup>106,116</sup>	Geese, captive birds only	Direct cloacal contact; egg transmission	Cloacitis, inflamed/ulcerated phallus; 10% ganders die	Reference 106
Goose virus hepatitis, goose influenza, goose plague Parvovirus <sup>8,93,111,116</sup>	Common in Europe; not seen in US; domestic goslings < 30 days of age; mortality ≤ 80%	Highly contagious	Coryza, diarrhea, ataxia; survivors stunted, loss feathers neck and back	Hyperimmune serum; attenuated virus vaccine in Hungary
Leukosis/sarcoma virus <sup>8</sup>	All species; rare		Tumors of the parenchymous organs	
Necrotizing enteritis agent unknown, possible flagellate, enteric bacteria, <i>Clostridium</i> sp. <sup>116</sup>	Seen in free-living waterfowl, captive geese, mallards; common in breeder ducks, mortality ≤ 40%	Stress predisposes	Depression, subcutaneous and pulmonary hemorrhages, mucoid necrotic enteritis	Neomycin sulfate 0.02% in food for 2-3 weeks; reduce stress
New duck disease, infectious serositis <i>Cytophaga</i> sp. <sup>8,14,44,93,111,116</sup>	Ducks, geese, swans; sporadic outbreaks in wild; more common domestic flocks; ducklings = acute; older birds = chronic	Probably egg-transmitted	Lethargy, ocular discharge, diarrhea, ataxia, torticollis, often on back paddling legs, acute death	Reduce crowding; bacterin at 2-3 weeks of age; live vaccine experimental <sup>9</sup> ; A, C, D, H*
Newcastle disease Paramyxovirus NDV (serotype group 1) <sup>111</sup>	All species; uncommon; few reports clinical disease	Fecal spread likely	Respiratory, conjunctivitis, gastrointestinal, CNS signs	Vaccination for poultry may effective if legal; depopulate
Pseudotuberculosis <i>Yersinia</i> sp. <sup>8,44,111</sup>	All species; not uncommon at end of severe winter	Contaminated food supply (rodents and wild birds)	Non-specific clinical signs	
Reticuloendotheliosis Retroviruses <sup>116</sup>	Unknown; rare; high mortality in 2 week old domestic ducks	Unknown	Tumors of RE cells and organs	
Salmonellosis <i>Salmonella</i> spp. <sup>8,28,44,93,111,116</sup>	All; rare in free-ranging; common in captivity, domestic ducklings disease < 2 weeks of age	Excrement; ingestion; carried by rodents, insects, water, wild birds	Depression, sudden death; acute septicemia, enteritis	Sanitation; remove carriers; antibiotics may reduce disease but not stop carriers; B, F, I*
Tuberculosis, <i>Mycobacterium</i> avian, spp. <sup>8,44,111,116</sup>	All; rare in free-ranging; common in captivity	Excrement	Emaciation, diarrhea, debility; often dead, no symptoms	Depopulate infected birds, flame environment; potential treat rare birds

table continued on next page

\* see Chapters 18, 32, 33, 35 and 36 for further information; treatments: A — sulfaquinoxaline 0.025-0.05% in feed, or penicillin-streptomycin 50,000 U/kg IM; B — sulfadimethoxine-ormetoprim 0.02-0.08% in feed; C — sulfamethazine 0.2-0.25% in drinking water or feed; D — penicillin 50,000 U/kg IM; E — tetracycline IM; F — chlorotetracycline 300-400 g/ton feed; G — lincomycin-spectinomycin IM; H — novobiocin 350 g/ton feed; I — furazolidone 0.022-0.044% in feed.

DISEASE/AGENT	HOST RANGE/TRANSMISSION	CLINICAL SIGNS	DIAGNOSIS	TREATMENT/CONTROL
Acuaria <i>Echinuria uncinata australis</i> <sup>5</sup>	Unknown. Daphnia is intermediate host	Proventricular ulceration, anorexia, weight loss, anemia, death		Increase water flow to decrease daphnia; J, L, M, N, O*
Air sac mites <i>Cytodites nudus</i> <sup>111</sup>	Anseriformes are aberrant hosts		Seen in respiratory passages and air sacs	Difficult
<i>Avioeserpens taiwana</i> <sup>44</sup>	Ducks in Taiwan, Indochina and North America; cyclops is intermediate host	Parasite-induced masses, submandibular, thigh, shoulder		Remove masses
Capillariasis <i>Capillaria contorta</i> <sup>8,44,111</sup>	All; rare	Occasionally, anorexia, dysphagia, diarrhea, necrotizing enteritis	Fecal flotation; barrel-shaped eggs, bipolar plugs; parasites in esophagus, crop, small intestine	J, K, L, N, O*
Cecal worms <i>Heterakis</i> sp. <sup>8,44,111</sup>	All; rare	Common at postmortem; rarely clinical signs	Fecal flotation; ellipsoidal, thick shelled eggs, 60x40µ	
Coccidiosis <i>Eimeria</i> sp., <i>Tyzzeria</i> sp., <i>Wenyonella</i> sp. <sup>8,22,93,111</sup>	All; common; mortality ≤ 10% in ducklings; direct transmission	Enteritis, emaciation, anemia, death, renal disease in geese	Fecal flotation; intestinal lesions with merozoites	Amprolium; B, C, Q*
Conjunctival worms <i>Oxyspirura mansonii</i> <sup>111</sup>	All; rare	Conjunctivitis, blepharitis, epiphora	Direct visualization; slender, thread-like worms	Manual removal, dilute ivermectin topically
Gape worms of geese <i>Cyathostoma bronchalis</i> <sup>31,44,111</sup>	Geese; mortality highest in goslings. Carrier adults	Depression, anemia, coughing, blood-tinged tracheal mucus	Parasite or eggs in tracheal mucus or feces; worms in bronchi and trachea	L, O, P*
Gizzard worms (several nematode species) <sup>8,28,111</sup>	Ducks, geese, swans; mortality highest in young; direct life cycle	Unthriftiness, ventricular dysfunction	Eggs in feces; hairlike worms under horny gizzard lining	K, L, N, O*
Heartworms <i>Sarcoca eurycerca</i> <sup>111</sup>	Whistling Swan, White-faced Goose; rare	Depression, death, myocardial necrosis	Microfilaria in blood smear; 2-3 adults/host	Unknown
Leeches <i>Hirudinea</i> sp., <i>Theromyzon</i> <sup>12,21</sup>	Many species; occasional	Anemia, conjunctivitis, asphyxiation, bloody nasal discharge		Drain and disinfect pond
Lice - shaftlice, wetfeather <i>Holomenopen leucocytozoon</i>	Unknown	Moist-appearing feathers; louse feeds on quill; severe irritation		Malathion powder
Lice - chewing <i>Mallophaga</i> spp. <sup>8,44,111</sup>	All; common; life cycle 2-3 weeks	Mainly nonpathogenic; feed on feather debris may cause local irritation	Adults or eggs on feathers	5% carbaryl powder
Ocular trematodes <i>Philophthalmus gralli</i> <sup>111</sup>	Ducks, geese	Conjunctivitis, epiphora	Direct visualization 5 x 1.2 mm	Manual removal
Sarcocystis <i>Sarcocystis ridleyi</i> <sup>9</sup>	Ducks, especially dabblers; more common in adults	Asymptomatic	Small white rice grain masses in muscles	Nonpathogenic
Schistosomiasis <i>Dendritobilhargia pulverulenta</i> <sup>115</sup>	Diving ducks, geese	In arteries, not veins; multisystemic signs; granulomatous encephalitis	Flukes in aorta and cranial branches	
Simulian black fly <sup>111</sup>	Many species	Anemia, toxicity; transmit leucocytozoon and microfilaria		4% malathion inside buildings
Spirurids <i>Streptocara</i> spp. <sup>105</sup>	Ducks; common	Proliferative gastritis, vomiting, weight loss	Parasites in gizzard or under mucus lining gizzard and proventriculus	Unknown
Tapeworms <sup>8,23,111</sup>	All; not uncommon; invertebrate or fish = intermediate host	Asymptomatic; catarrhal enteritis, diarrhea, emaciation	Fecal flotation; onchosphere proglottids in feces	R*
Tetrameres <sup>44</sup>	Rare; grasshopper or anthropod is intermediate host	Poor growth; proventricular dystrophy; anemia	Parasite in mucus glands proventriculus	J, K*
Toxoplasmosis <i>Toxoplasma gondii</i> <sup>111</sup>	Geese	Anorexia, anemia, emaciation, diarrhea, CNS signs	Complement fixation; Sabin-Fellman Dye test	C, D*
Trematodes/flukes (numerous species) <sup>8,23,111</sup>	Ducks, geese; not uncommon; mollusk is intermediate host	Unthriftiness, enteritis or hepatitis depending on location	Fluke eggs in feces	Difficult; O*

\* see Chapters 18, 32, 33, 35 and 36 for further information; treatments: A — sulfaquinoxaline 0.025-0.05% in feed, or penicillin-streptomycin 50,000 U/kg IM; B — sulfadimethoxine-ormetoprim 0.02-0.08% in feed; C — sulfamethazine 0.2-0.25% in drinking water or feed; D — penicillin 50,000 U/kg IM; E — tetracycline IM; F — chlorotetracycline 300-400 g/ton feed; G — lincomycin-spectinomycin IM; H — novobiocin 350 g/ton feed; I — furazolidone 0.022-0.044% in feed; J — pipazine 200-1000 mg/kg PO, 6-10 g/gal drinking water for four days; K — pipazine 45-200 mg/kg PO single dose or 6-10 g in 4 liters of drinking water; L — mebendazole 5-15 mg/kg PO for two days; M — thibendazole 100 mg/kg PO; N — thibendazole 200-500 mg/kg PO; O — levamisole 25-50 mg/kg PO; P — ivermectin 1% (200 µg/kg SC); Q — furazolidone in the feed at 0.033% for 14-21 days; R — niclosamide (toxic to geese) 250 mg/kg PO, droncit, Bunamadine PO.



eggs. Lesions associated with adult schistosomes have been reported in the liver, intestines and lung, and reactions to eggs have been reported to cause encephalitis. The high mortality in this group of birds was believed to have been potentiated by placing a group of birds that normally spend the summer in an Arctic marine environment into a fresh water pond.

### Proventricular Dilatation

A syndrome similar to that described with neuropathic gastric dilatation in Psittaciformes was documented in two free-ranging Canada Geese. The birds were found in an emaciated state. Postmortem findings included pectoral muscle atrophy and a dilated, thin-walled proventriculus. Nonsuppurative encephalitis with lymphoplasmacytic perivascular cuffing was the principal histologic lesion (see Chapter 32).

## Common Surgical Procedures

Most surgical techniques used in psittacines can be applied to waterfowl. Anseriformes normally have a high concentration of subcutaneous and intra-abdominal fat, making the delineation of anatomic structures (particularly vessels) difficult. The transection of large vessels coursing through the fat is common. Blood that may be present on feathers following a surgical procedure should be carefully removed from goslings, ducklings or cygnets to prevent the parents from traumatizing the area through excessive grooming.<sup>44</sup> Most waterfowl can be easily managed in a hospital situation although some do better when their mate or a companion is with them. Birds that are stressed do well in a quiet, darkened enclosure.

### Pinioning

There are various surgical means of deflighting birds including patagiectomy,<sup>68,89</sup> joint ankylosis,<sup>111</sup> tendonectomy<sup>71,94</sup> and pinioning.<sup>44,68,71,89,94,111,114</sup> The most common procedure is pinioning. When waterfowl are one to four days of age, they can be quickly and easily pinioned without anesthesia. This procedure causes very little hemorrhage or stress to young chicks. Early pinioning obviates the need for a more complicated procedure at a later date. The nail clippers,

scissors or other cutting device (suture scissors and wire cutting scissors work well) are used for the procedure. The chick is held upside down, preferably with one wing outstretched, and the alula (second digit) is held out from the carpus (Figure 46.19). The third and fourth metacarpals are then cut as close to the alular and carpus as possible. This will remove all of the primary flight feathers. Although no further treatment is usually necessary, bleeding can be controlled with silver nitrate, Monsel's solution or radio-surgery. The stump can be sprayed with an antibiotic powder.

In older birds, pinioning can be performed at the level of the carpus, but is usually performed at the proximal end of metacarpals III and IV. The procedure can be performed using a local anesthetic in a bird that is manually restrained or the bird may be anesthetized with isoflurane (Figure 46.20). Feathers are removed from the carpus to midway on metacarpals III and IV. A tourniquet is placed on the wing at the level of the humerus. The skin is prepped with povidone iodine and alcohol. A ligature of absorbable suture of approximately 2-0 size is placed around the proximal end of metacarpal IV, incorporating as much interosseous tissue as possible. A similar ligature is placed around metacarpal III, also incorporating as much interosseous tissue as possible. These sutures are designed to ligate the interosseous metacarpal artery, which passes between these bones. A figure-of-eight suture placed around and between the metacarpal bones has been suggested, but in the author's opinion it is inferior to the described technique.

The skin is then incised between mid-shaft and the proximal one-third of metacarpals III and IV. Muscle and fascia are cut deep to the bone. The skin and muscle are bluntly dissected and pushed proximally using a gauze pad to expose the metacarpal bones. The bone should be exposed as close to the base of the alula as possible. Metacarpal bones III and IV are cut as proximal as possible with a bone saw. Rongeur's or nail trimmers tend to splinter the bone. Vessels are ligated if necessary. The skin and muscle are pulled back over the bone end and excess tissue is removed. Muscle and fascia should be sutured over the bone to help pad the ends. Two or three overlapping horizontal mattress sutures are generally sufficient for closure, and the end of the incision can be sealed with tissue adhesive. Skin should be sutured loosely over the bone ends to prevent pressure necrosis.

Although bandaging is not usually required, a pressure wrap may be placed over the stump for several



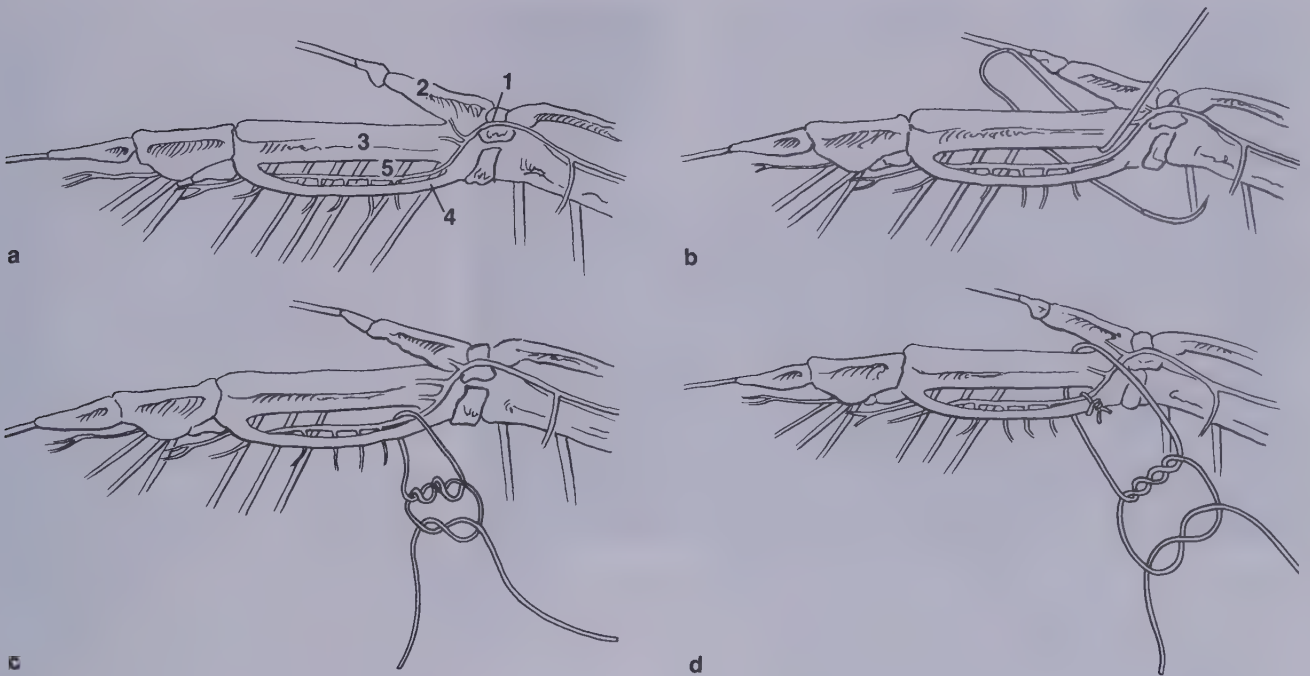
**FIG 46.19** Pinioning is easiest in two- to three-day-old birds. A pair of sterile scissors (top) is used to remove metacarpals III and IV, while leaving the alula intact. Bleeding is minimal (bottom) and can be controlled with a silver nitrate stick, if necessary (1994 Busch Gardens Tampa. All rights reserved.).

days to control mild hemorrhage and protect the incision. Birds should be restricted from the pool for three to seven days to prevent water and bacteria from contaminating the incision. If tissue glue is used to seal the skin, the wound may be sufficiently protected to allow immediate release to water.<sup>111</sup> The comparison of a pinioned and non-pinioned wing is shown in Figure 46.21. A modification of this procedure utilizes elastic castration bands at the base of the metacarpal and excision of bone and tissue distal with a double action bone cutter.<sup>66</sup> However, several weeks may be necessary for the stump to necrose, slough and heal. The editors do not recommend this procedure, for humane reasons.

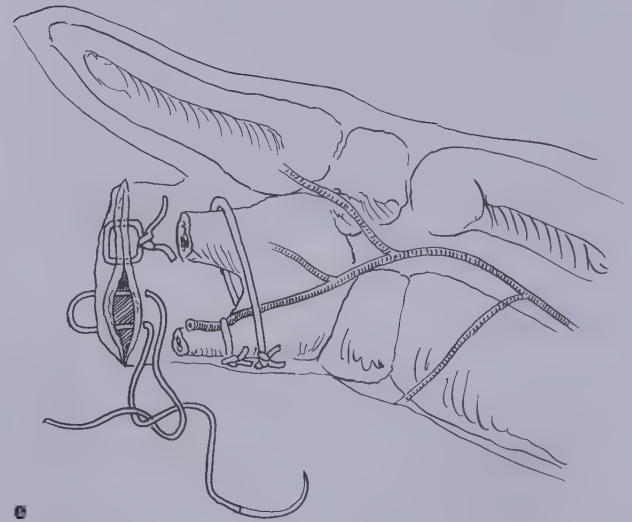
### ■ Tendonectomy

Pinioning results in an aesthetically altered bird, particularly if the wings are extended during preening or courtship behavior. Some bird keepers believe that a pinioned male will have difficulties in maintaining the necessary balance to properly mount and mate with a hen. Suggested alternatives to pinioning include removal of the extensor carpi radialis tendon (tendonectomy) or a wedge resection of the propatagium (patagiectomy). Both techniques are cosmetically and functionally unacceptable. In addition, scar tissue may form that allows the carpus to be sufficiently extended to sustain flight. This is more likely to occur in large-winged birds on windy days when the birds are able to run, jump and glide for variable distances.

Another form of tendonectomy involves removing the insertion point of the superficial pectoralis muscle. This will result in a bird that cannot fly but is cosmetically normal (Figure 46.22). To perform this procedure, the bird is anesthetized with isoflurane and placed in lateral recumbency. The feathers are removed from the ventral side of the humerus directly over the pectoral crest, distal to the level of the scapulohumeral joint. The area is aseptically prepared and the skin is incised with a bipolar radiosurgical unit in a curvilinear manner beginning just distal to the pectoral crest. The incision ends at a point proximal to the scapulohumeral joint. In most birds, the pectoral crest can be visualized through the skin. The dorsomedial aspect of the pectoral crest is the insertion point for the supracoracoideus muscle, which originates deep to the pectoralis and is the primary muscle responsible for elevation of the wing. The wing is then extended fully over the bird's back and should approach the mid-line of the body. This



**FIG 46.20** Pinioning renders a bird incapable of flight. **a)** Regional anatomy of the carpus: 1) ventral metacarpal artery 2) alula 3) metacarpal III 4) metacarpal IV and interosseous space. **b,c)** Feathers are removed from the carpus and a circumferential incision is made at the midpoint of the metacarpal bones. The skin and muscle are bluntly dissected and pushed proximally using a gauze pad to expose the metacarpal bones. A ligature of absorbable suture is placed around the proximal end of metacarpal IX to ligate the ventral metacarpal artery. **d)** A similar ligature is placed around metacarpal III, also incorporating as much interosseous tissue as possible. The metacarpal bones are excised with bone cutters. **e)** Horizontal mattress sutures are used to close a skin flap over the bone ends. Sufficient skin should be used to cover the bone to prevent pressure necrosis (modified from Fletcher KC, Miller BW, *Vet Med Small Anim Clin*, December 1980).



places maximum tension on the tendon of insertion of the superficial pectoralis muscle.

The muscle and tendon are separated from the pectoral crest starting at the ventral edge. A distinct popping sound is audible when the final strands of muscle and tendon are separated from the crest. All of the fibrous connective tissues (tendon and periosteum) are radiosurgically removed and the site is fulgurated. The complete radiosurgical destruction of the area of insertion of the superficial pectoralis will prevent the muscle from partially reattaching, which could allow flight. Tissue fragments are debrided from the humerus by scraping with a scalpel blade. The wound should be flushed with sterile LRS. The insertion of the supracoracoideus muscle on the dorso-medial aspect of the pectoral crest should be

avoided. This muscle elevates the wing and must be intact to provide the bird with proper balance.

A second branch of the pectoralis muscle, the tensor propatagialis, crosses the shoulder cranial to the superficial pectoralis muscle. The tensor propatagialis is easily identified by grasping and pulling on the leading edge of the wing (propatagial membrane). A 2 or 3 cm section of the tensor propatagialis is removed. The incision should be carefully examined to ensure that the transection is complete. The skin is closed in a continuous or simple interrupted suture pattern. This procedure prevents a bird from flying,



**FIG 46.21** A pinioned bird. Note that the alula (arrows) remains to cover and protect the transected end of metacarpals III and IV (1994 Busch Gardens Tampa. All rights reserved.).

but allows normal flexion and extension of the wing. The wing can be moved in a relatively normal fashion for breeding or display, but there is no strength to the down stroke of the wing or control to the leading edge of the wing and thus, no lift. Aesthetically, the bird is normal. The procedure has been successful in deflating Anseriformes, Ciconiiformes, Pelecaniformes, Galliformes, Gruiformes, Charadriiformes and Columbiformes (see Figure 46.22) (Fletcher K, unpublished).

### Beak Repair

Beak injuries that result in an inability to eat, drink and preen will occur in waterfowl. Various attempts at applying prosthetic bills have been described.<sup>7,30,117</sup> One report described the placement of a fully threaded 0.045 Kirschner wire into each tomial margin of the maxilla. The pins were threaded until the tapping end was palpated exiting the caudal aspect of the maxilla at the rectus. The distal tips of the Kirschner wire were bent approximately 90° medially, slightly shorter than the planned rostral prosthetic edge. Prior to surgery, a two-piece template (dorsal and ventral halves) of the upper bill from a Canada Goose model was formed using fast, self-curing dental repair acrylic<sup>f</sup> at a 1.5:1 ratio of powder to liquid. The templates were then waxed to help prevent adherence to the prosthesis.

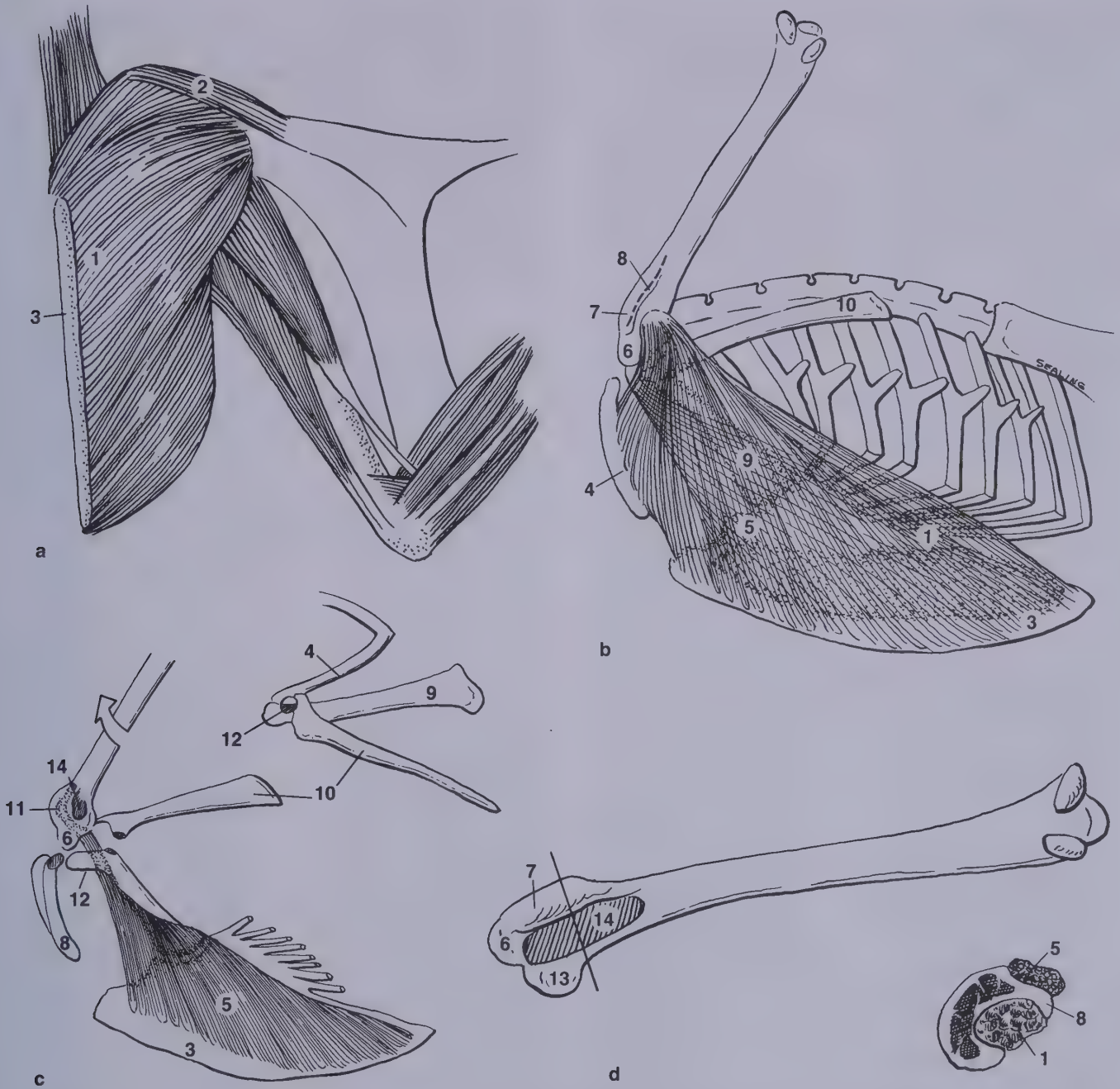
The nares and the oral cavity were plugged with cotton to prevent possible influx of dental acrylic. The

dorsal half of the template was fitted into position over the maxillary stump and the Kirschner wires. The mold was manually held in position while dental acrylic was poured onto it using a 3 ml syringe. The ventral half of the template was positioned over the semi-solid acrylic and pushed down in apposition with the dorsal half of the template. Holding the mold in position, the acrylic was allowed to harden (approximately ten minutes) and the mold was removed.

Additional acrylic was applied with a fine brush to strengthen thin areas of the prosthesis and to feather out the caudal edges of the prosthesis, both on the dorsal surface and the ventral surface where the prosthetic overlapped the bill. This feathering was carried caudally approximately 6 mm with care being taken to exclude external nasal openings. At this point, a high-speed hand-held drill with a fine grinding stone was used to do final shaping and smoothing. A grinding disk was used to create lamellae on the prosthesis. Postoperative care was uneventful, and the bird immediately started to utilize the new bill and was able to eat, drink and preen normally. This bird was monitored for six months, and there were no signs of loosening or instability of the prosthesis.<sup>117</sup> This procedure would be considered a temporary repair and would need replacement in 6 to 12 months (see Chapter 42).

### Air Sac Cannulation

Installation of an air sac cannula as emergency care for airway obstruction is described in Chapter 15. In Psittaciformes, this procedure is usually performed in the abdominal air sac. Successful cannulation of the clavicular air sac has been reported in Pekin Ducks.<sup>90</sup> The clavicular air sac is located just under the skin in the area of the thoracic inlet and can be visualized with minimal dissection (see Anatomy Overlay). Chest tubing (6.5 cm long) of the same internal diameter as the endotracheal tube was placed 2 cm into the air sac and fixed in place with a purse-string skin suture. The study showed that the heart rate, mean arterial blood pressure, PaO<sub>2</sub>, and PaCO<sub>2</sub> of cannulated birds remained unchanged from control values. There were significant increases in tidal and minute volume.<sup>90</sup>



**FIG 46.22** Superficial pectoralis tendonectomy for cosmetic deflighting: **a)** The insertion point of the 1) superficial pectoralis muscle and the 2) tensor propatagialis can be excised. **b)** A curvilinear incision (dotted line) is made from a point distal to the pectoral crest extending to a point proximal to the scapulohumeral joint. The wing is then extended fully over the bird's back and should approach the mid-line of the body. This places maximum tension on the tendon of insertion of the superficial pectoralis muscle. **c)** The superficial pectoralis muscle is removed at its insertion on the humerus. The insertion of the supracoracoideus muscle on the dorsomedial aspect of the pectoral crest must be avoided. A two- to three-cm section of the tensor propatagialis is removed. **d)** Anatomy of the head of the proximal humerus including a cross section showing the relationship of the superficial pectoralis and supracoracoideus muscles to the pectoral crest. 3) sternum 4) clavicle 5) supracoracoideus muscle 6) head of the humerus 7) dorsal tubercle 8) pectoral crest 9) coracoid 10) scapula 11) attachment of supracoracoideus muscle 12) triosseal canal 13) ventral tubercle and 14) insertion of the superficial pectoralis muscle.

## Castration and Caponizing

Ganders may become very aggressive during the breeding season. As an alternative to removing an aggressive bird, some clients will choose to have the animal castrated to prevent inter-male fighting, reduce aggression toward people and prevent additional offspring. The procedure is performed on an anesthetized bird placed in lateral recumbency. The wings are extended and taped above the body. Geese are very muscular, so full caudal extension of the up leg is necessary to expose the surgery site. The area of the last two ribs cranial to the femur is plucked and prepped for surgery.

The lungs extend almost to the last intercostal space, so care is necessary when making a one-half-inch vertical incision between the last two ribs. Retractors are necessary to keep the ribs separated. Blunt dissection through the air sac reveals the testicle. Two curved hemostats are clamped between the testicle and body wall and left in place for two minutes. The outer hemostat is then pulled up and away from the other hemostat, tearing the testicle free. Minimal

bleeding can be expected. Alternatively, two hemostatic clips may be applied between the testicle and the body wall, taking care not to occlude the aorta or vena cava. The ribs are closed in a simple interrupted pattern with an absorbable suture material. The skin is then closed. The opposite testicle is removed in a similar manner. Several affected birds have been reported to maintain their original personality, but their bellicose nature associated with previous breeding seasons did not develop.<sup>83</sup> This procedure can be most safely performed in young birds.

### Products Mentioned in Text

- a. Chemistry assays from Gilford Impact 400 Autoanalyzer, Ciba Corning Diagnostics, Oberlin, OH
- b. Nomad Mat #262105, 3-M, distributed by Zellerbach (USA); EnKamat #7210106, Flatback Erosion Control Systems, Tuscaloosa, AL
- c. Valentine, Hinsdale, IL 323-7070.
- d. Emerald I, Lafeber, Odell, IL
- e. Nichols Net & Twine Company, Inc., Granite City, IL
- f. Lang's Jet Acrylics, Lang Dental Manufacturing Company, Chicago, IL

## References and Suggested Reading

1. **Boever WJ, Wright W:** Use of ketamine for restraint in anesthesia of birds. *Vet Med Sm Anim Clin* 70:86-88, 1975.
2. **Borzio F:** Ketamine hydrochloride as an anesthetic for wildfowl. *Vet Med Sm Anim Clin*: 1364-1367, Dec 1973.
3. **Brown AF:** The Incubation Book. Surrey, England, Spur Publications, 1979.
4. **Brownell JR, Sadler WW:** An evaluation of selected anesthetics and surgical anesthetics for chickens. *Avian Dis* 13(7): 1967.
5. **Clark WC:** *Echinuria australis* n.sp. and *E. uncinata* (Nematoda: Spirurida) parasites of ducks in New Zealand. *NZ J Zool* 6:7, 1979.
6. **Cline DR, Greenwood RJ:** Effect of certain anesthetic agents on mallard ducks. *J Am Vet Med Assoc* 161(6):624-633, 1972.
7. **Cliphsham R:** Surgical beak restoration and correction. *Proc Assoc Avian Vet*, 1989, pp 164-176.
8. **Coles BH:** Avian Medicine and Surgery. Boston, Blackwell Scientific Publications, 1985.
9. **Costango GR:** Sarcocystis in American black ducks wintering in New Jersey. *J Wildl Dis* 26(3):387-389, 1990.
10. **Crider ED, McDaniel JC:** Oral drugs used to capture waterfowl. *Proc SE Assoc Game & Fish Comm* 22:1-18, 1968.
11. **Dardiri AH:** Duck viral enteritis (duck plague) characteristics and immune response of the host. *Am J Vet Res* 36(4):535-538, 1975.
12. **Davies R, Wilkialis J:** A preliminary investigation on the effects of parasitism of domestic ducklings by *Theromyzon rube*. *Can J Zool* 59:1196, 1981.
13. **Davis JW, et al:** Infectious and Parasitic Disease of Wild Birds. Ames, Iowa State University Press, 1978.
14. **Dean WF, Price JI, Leibovitz L:** Effects of medicaments on bacterial infections on ducklings. *Poult Sci* 53(2):549-558, 1973.
15. **Degernes LA, et al:** Lead poisoning in trumpeter swans. *Proc Assoc Avian Vet*, 1989, pp 144-155.
16. **Dein, FJ, Frank LS:** Rehabilitation of oil-contaminated birds. In Kirk, RW (ed): *Current Veterinary Therapy IX*. Philadelphia, WB Saunders Co, 1986, pp 719-723.
17. **Dein FJ:** Laboratory Manual of Avian Hematology. New York, Association of Avian Veterinarians, 1984.
18. **DiBarthola SP, Benson MD:** The Pathogenesis of Reactive Septic Amyloidosis. *J Vet Intl Med* 3:31-41, 1989.
19. **Dieterich RA:** Alaskan Wildlife Diseases. Fairbanks, Institute of Arctic Biology, 1981.
20. **Dolensek EP, et al:** Hatching problems in exotic birds. *Proc Am Assoc Zool Vet*, 1979, pp 63-64.
21. **Elliot JM, Talbott, DA:** Leech parasitism of waterfowl. *Wildfowl* 33:164, 1982.
22. **Fairbrother A, O'Loughlin D:** Differential white blood cell values of the mallard (*Anas platyrhynchos*) across different ages and reproductive states. *J Wildl Dis* 26(1):78-82, 1990.
23. **Fairbrother A:** Changes in mallard (*Anas platyrhynchos*) serum chemistry due to age, sex, and reproductive condition. *J Wildl Dis* 26(1):67-77, 1990.
24. **Farrell DJ:** Energy expenditure of laying ducks; Confined and herded. In *Duck Production Science and World Practice* (D.J. Farrell and Stapleton, Eds.) University of New England, Armidale, NSW, Australia 1985.
25. **Fisher HI:** *Auk* 75:391-399, October 1958.
26. **Fite RW:** Diagnosis and control of leucocytotoxosis in captive waterfowl. *Proc Assoc Avian Vet*, 1984, pp 193-198.
27. **Franson JC:** Enzyme activities on plasma, liver and kidneys of black ducks and mallards. *J Wildl Dis* 18:481, 1982.
28. **Friend M:** General Field Procedures and Diseases of Migratory Birds, Vol 1. Fieldguide to wildlife diseases, Washington DC, US Department of the Interior Fish & Wildlife Service, 1987.
29. **Fritz JC, Archer W, Barker D:** Vitamin D requirements of ducklings. *Poult Sci* 20(15):1-154, 1941.
30. **Frye FL:** Prosthesis enhance quality of life. *Veterinary Medicine July*:931-935, 1984.
31. **Gassman-Duvall R:** An acute *Cyathostoma bronchialis* outbreak in the Hawaiian goose and other parasites found. *Proc First Intl Conf Zool & Avian Med*, 1987, pp 61-68.
32. **Gee CG, Carpenter JW, Hensler GL:** Species differences in hematological values of captive cranes, geese, raptors and quails. *J Wildl Mgt* 45:463, 1981.
33. **Gee GF, Sexton TJ:** Cyogenic preservation of semen from the Aleutian Canada goose (*Branta canadensis leucopereia*). *Zoo Biol* 9(5):361-372, 1990.
34. **Gieffner G et al:** On the occurrence of leeches (Hirudinea) in waterfowl. *Proc Intl Symp Erkrankungen der Zoonund Wildtiere*, Sofia Bulgaria, 1988, pp 333-335.
35. **Goetz MF, Hahn AW, Kelley ST:** Effects of halothane and isoflurane on mean arterial blood pressure, heart rate, and respiratory rate in adult Pekin ducks. *Am J Vet Res* 51(3) March, 1990.
36. **Gordon B:** The use of sodium amobarbital for waterfowl capture. *J Zoo Am Med* 8:34-35, 1977.
37. **Gryznecki's Animal Life Encyclopedia. Anseriformes:** screamers, ducks and geese, chapter 11. New York, Nosstrand Reinhold, 1972, p 253.
38. **Haigh JC:** Levamisole in waterfowl: Trials on effect and toxicity. *J Zoo Anim Med* 10:103-105, 1979.
39. **Harrison CJO (Consult ed):** Birds, Their Life, Their Ways, Their World. USA, The Readers Digest Association, Inc, 1979, pp 206-211.
40. **Harvey-Clark C:** Clinical and research use of implantable ocular access ports in avian species. *Proc Assoc Avian Vet*, 1990, pp 191-209.
41. **Hayes MB (ed):** Rehabilitation Guidebook for Birds and Mammals. Brunner Nature Center, Ohio, 1984.
42. **Heard DJ:** Overview of avian anesthesia. *Assoc Avian Vet Today* 2(2):92-96, 1988.
43. **Holm ER, Scott ML:** Studies on the Nutrition of Wild Waterfowl. NY Fish & Game J 1:171-187, 1954.
44. **Humphreys PN:** Introduction and identification, restraint and handling, parasitic diseases. In *Fowler ME (ed): Zoo and Wild Animal Medicine 2nd ed.* Philadelphia, WB Saunders Co, 1986, pp 334-335, 341-342, 353-357.
45. **Hyde DO:** Raising Wild Ducks in Captivity. New York, EP Dalton and Company, 1974.
46. **Jager FC:** Effect of dietary linoleic acid and selenium on the requirement of vitamin E in ducklings. *Nutri and Metab* 14:210-227, 1972.
47. **Jager FC:** Linoleic acid intake and vitamin E requirements in rats and ducklings. *Ann NY Acad Sci* 203:199-211, 1972.
48. **Jenkins JR:** Aspergillosis. *Proc Assoc Avian Vet*, 1991, pp 328-330.
49. **Jensen WI:** Perosis in Canada geese (*Branta canadensis*). *Wildl Dis Assoc* 4:95-99, 1968.
50. **Jessup DA:** Infectious diseases, avian cholera, botulism. In *Fowler ME (ed): Zoo and Wild Animal Medicine 2nd ed.* Philadelphia, WB Saunders Co, 1986, pp 342-352.

51. **Johngard PA:** Ducks, Geese, and Swans of the World. Univ of Nebraska Press, 1978, pp xvii-xxiii.
52. **Johngard PA:** Waterfowl: Their Biologies and Natural History. Lincoln University of Nebraska Press, 1968.
53. **Jordan R:** Parrot Incubation Procedures. Ontario, Canada, Silvio Mattacchione & Company, 1989.
54. **Kaufman E, Pokras M, Sedgwick C:** Anesthesia in waterfowl. *Assoc Avian Vet Today* 2(2):98, 1988.
55. **Kawashiro T, Sheid P:** Arterial blood bases in undisturbed resting birds: Measurements in chicken and duck. *Respir Physiol* 337-342, 1975.
56. **Kear J:** Feeding and nutrition. In *Fowler ME (ed): Zoo and Wild Animal Medicine 2nd ed.* Philadelphia, WB Saunders Co, 1986, pp 335-341.
57. **Kear J:** Notes on the nutrition of young waterfowl, with special reference to slipped wing in Duplaix-Hall N (ed): *Intl Zoo Yearbook*, Vol 13, London, The Zoological Society of London, 1973, pp 97-100.
58. **Kenny D, Cambre, RC:** Indications and techniques for the surgical removal of the avian yolk sac. *J Zoo Wildl Med* 23(1):55-61, 1992.
59. **Klea JA:** Artificial incubation: Problems and solutions. *Proc Jean Delacour/IPCBS Symposium on Breeding Birds in Captivity*, 1983, pp 223-238.
60. **Klein PN:** The challenge of toxicological investigation in birds. *Proc Assoc Avian Vet*, 1989, pp 139-143.
61. **Kocan RM, Pitts SM:** Blood valves of the canvasback duck by age, sex and season. *J Wildl Dis* 12:341, 1976.
62. **Kocan RM:** Some physiologic blood values of wild diving ducks. *J Wildl Dis* 8:115, 1972.
63. **Kock RA et al:** Acuariasis in waterfowl at Whipsnade Zoo. *Proc Intl Symp Erkrankungen der Zootiere*, Cardiff, 1987, pp 65-73.
64. **Langenberg J, Montali RJ:** Avian neonatal pathology. *Proc Am Assoc Zoo Vet*, 1983, pp 172-175.
65. **Lauer, DM, Frank J, Dein FJ:** Rehabilitation of ruddy ducks contaminated with oil. *J Am Vet Med Assoc* 181(11):1398-1399, 1982.
66. **Lewandowski AH, Sikarskie JG:** Pinioning: a quick and simple technique. *Proc 1st Intl Conf Zool & Avian Med*, 1987, pp 414-415.
67. **Ludders JW et al:** Effects of ketamine, xylazine, and a combination of ketamine and xylazine in Pekin ducks. *Am J Vet Res* 50(2):245-249, 1989.
68. **Mangili G:** Unilateral patagiotomy: A new method of preventing flight in captive birds. *Intl Zoo Year Book*, London Zool Soc 11:252-254, 1971.
69. **Mautino M:** Avian lead intoxication. *Proc Assoc Avian Vet*, 1990, pp 245-247.
70. **McLelland J:** A Color Atlas of Avian Anatomy. Philadelphia, WB Saunders Co, 1991.
71. **Miller JC:** The importance of immobilizing wing after tenectomy and tenotomy. *Vet Med Sm Anim Clin* 68:35, 1973.
72. **Miller RE, et al:** *Leucocytozoon simondi* infection in European and American eiders. *J Am Vet Med Assoc* 183(11):1241-1244, 1983.
73. **Montali RJ:** Comparisons of diseases of waterfowl in captive and free-living species. *Sonderdruck aus Verhandlungsbericht des 29. Internationalen Symposiums uber die Erkrankungen der Zootiere*. Cardiff, 1987, pp 7-12.
74. **Montali RJ:** Disease of waterfowl: Comparisons in captive and free-living species. *Proc Am Assoc Zoo Vet*, 1989, pp 2-6.
75. **Mori JG, George JC:** Seasonal changes in serum levels of certain metabolites, uric acid and calcium in the migratory Canada goose (*Branta canadensis interior*). *Comp Biochem Physiol* 59B:263, 1978.
76. **Morishita TY:** Establishing a differential diagnosis for backyard poultry flocks. *Proc Assoc Avian Vet*, 1990, pp 136-146.
77. **Motzok I, Branion HD:** The vitamin D requirements of growing ducks. *Poult Sci* 27:482-485, 1948.
78. **Mulley RC:** Haematology of the wood duck *Chenonetta jubata*. *J Wildl Dis* 16:271, 1980.
79. **Mulley RC:** Haematology and blood chemistry of the black duck *Anas superciliosa*. *J Wildl Dis* 15:437, 1979.
80. **Napolitano RL, Dolensek EP, Russo EA:** Serodiagnosis of aspergillosis in avian species. *Proc Am Assoc Zoo Vet*, 1978, pp 265-267.
81. **Olsen JH:** Management and disorders of young waterfowl. The Role of Veterinary Medicine in Aviculture, AFA Veterinary Seminar, Orlando, 1984, pp 36-49.
82. **Peek JM:** Chlordiazepoxide and pentobarbital as tranquilizers for cow birds and coturnix quail. *J Am Vet Med Assoc* 149:950-952, 1966.
83. **Phalen DN:** Castrating the gander. *Assoc Avian Vet Today* 1(4):173-174, 1987.
84. **Pokras MA, Blackman R:** Understanding the syringeable bulla. *Assoc Avian Vet Today* 2(3):134-135, 1988.
85. **Redig P:** An overview of avian anesthesia. *Proc Assoc Avian Vet*, 1982, pp 127-139.
86. **Redig, PT:** Treatment of bumblefoot and the management of aspergillosis and various other problems commonly seen in raptors. *Proc 1st Intl Conf Zool & Avian Med*, 1987, pp 309-321.
87. **Rigdon RH:** Tumors in the duck (Family Anatidae): A review. *J Natl Cancer Trust File* 49(2):467-476, 1972.
88. **Robinson PT, Buzikowski RB:** Pinioning young birds with hemostatic clips. *Vet Med Sm Anim Clin* 70:1415-1417, 1975.
89. **Robinson PT:** Unilateral patagiotomy: A technique for deflighting large birds. *Vet Med Sm Anim Clin* 70:143-145, 1975.
90. **Rode JA, Bartholow S, Ludders JW:** Ventilation through air sac cannula during tracheal obstruction in ducks. *J Assoc Avian Vet* 4(2):98-102, 1990.
91. **Rowley J, Brown RD, White SE:** Bumblefoot in raptors. *Avian/Exotic Prac* 2(1):5-7, 1985.
92. **Sandhu T:** Duck virus hepatitis, goose virus hepatitis, *Pasteurella anapesti* infection. In *Fowler ME (ed): Zoo and Wild Animal Medicine 2nd ed.* Philadelphia, WB Saunders Co, 1986, pp 346-349.
93. **Sandu TS:** Important diseases of ducks. In *Farrell DJ, Stapleton P (ed): Duck Production Science and World Practice*. Univ New England, pp 111-134.
94. **Schroder CR, Koch K:** Preventing flight in birds by tenotomy. *J Am Vet Med Assoc* 97:169-170, 1940.
95. **Schwartz LH:** Poultry surgery. In *Hofstad M, et al (eds): Diseases of Poultry 5th ed.* Ames, The Iowa State University Press, 1965, pp 1149-1161.
96. **Scientific Report of the Zoological Society of London.** *Journal of Zoology*: 306-307, 1975-1977.
97. **Scott ML, Dean WF:** Nutrition and Management of Ducks. Ithaca, ML Scott of Ithaca, 1991.
98. **Scott ML:** Nutrition of Humans and Selected Animal Species. Somerset NJ, John Wiley & Sons, 1986.
99. **Shave H:** Clinical pathology. In *Fowler ME (ed): Zoo and Wild Animal Medicine 2nd ed.* Philadelphia, WB Saunders Co, 1986, pp 357-362.
100. **Shave HJ, Howard V:** A hematologic survey of captive waterfowl. *J Wildl Dis* 12:195, 1976.
101. **Soifer FK:** Anthelmintics for exotic & zoo animals. *Proc Am Assoc Zoo Vet*, 1970, pp 123-124.
102. **Soothill E, Whitehead P:** *Wildfowl of the World*. London, Blandford Press, 1988.
103. **Speckmann G:** Necropsy findings in various avian species other than domestic chickens and turkeys. *J Zoo Anim Med* 7(4):27-30, 1976.
104. **Stefanatos J:** A new treatment for bumblefoot in birds. *J Zoo Anim Med* 5(2):25, 1974.
105. **Steiner MC, Starkhouse L:** Parasitic ulcerative ventriculitis in mallards (*Anas platyrhynchos*). *J Wildl Dis* 23(4):680-682, 1987.
106. **Szep I, Pataky M, Nagy G:** Infectious Inflammatory Disease of Cloaca and Penis in Geese (Goose Gonorrhoea). I. Epizootiological, Clinical, Pathological Observations & Control. *Acta Vet Acad SEI HUNG*, 1974.
107. **Tarsname S:** Waterfowl: A Guide to Management and Propagation. Tarsname Productions, Montana, 1985.
108. **Todd FS:** Waterfowl: Ducks, Geese and Swans of the World. Sea World Press, San Diego, 1979.
109. **USDA Agriculture Handbook** No. 8-1 1976. Dairy and Egg Products; No. 8-5, 1979 Poultry Products. U.S. Government Printing Office, Washington, DC.
110. **Valverde A, Honeyman VI, Dyson DH, Valliant AE:** Determination of a sedative dose in influence of midazolam on cardiopulmonary function in Canada geese. *Am J Vet Res* 51(7):1071-1074, 1990.
111. **Wallach JD, Boever WJ:** Gamebirds, waterfowl, and ratites. In *Diseases of Exotic Animals: Medical and Surgical Management*, Philadelphia, WB Saunders Co, 1983, pp 831-888.
112. **Wilgas HS:** Reserpine for tranquilizing geese. *Second Conf Use of Reserpine in Poultry Production*. The Institute of Agriculture, St. Paul, MN, 1960, p 54-56.
113. **Williams JJ, Traines DO:** A hematological study of snow, blue and Canada geese. *J Wildl Dis* 7:258, 1971.
114. **Williamson WM, Russell WC:** Prevention of flight in older captive birds. *J Am Vet Med Assoc* 159(5):596-598, 1971.
115. **Wilson RB, New JC, Scholtens RG:** Granulomatous encephalitis caused by schistosomiasis in swans. *J Am Vet Med Assoc* 181(11):1386-1387, 1982.
116. **Wobeser GA:** Diseases of Wild Waterfowl, New York, 1981.
117. **Wolf L:** Prosthetic bill technique in a Canada goose. *Proc Assoc Avian Vet*, 1985, pp 177-179.
118. **Wolfe DA:** Surgical correction of paresis in a 3-week-old mallard duck. *Vet Med Sm Anim Clin* :1567-1570, 1978.
119. **Yanoff SR:** Egg yolk peritonitis in a duck. *Proc Am Assoc Zoo Vet*, 1983, pp 214-215.
120. **Yearout DR:** Prevention and treatment of aspergillosis by vaccination: A new protocol. *Proc Assoc Avian Vet*, 1988, pp 139-144.
121. **Zdzirski JM, et al:** Zinc toxicity in downy ducks. *J Zoo Anim Med*, in press.

CHAPTER

---

# 47

## RAMPHASTIDAE

---

Hans Cornelissen  
Branson W. Ritchie

**T**he family Ramphastidae, included in the order Piciformes, consists of six genera divided into 43 species or subspecies (Table 47.1).<sup>15</sup>

These birds are indigenous to South America, ranging from southern Mexico to northern Argentina.<sup>15</sup> Of the 43 species of toucans, toucanets and aracarís, only a few are frequently seen in captivity, including the Toco, Keel-billed, Red-billed and Channel-billed Toucans, and the Green Aracari (rare). These birds have been maintained in captivity since the Spanish Conquistadors first landed in the Americas, but active breeding programs have occurred only during the past 30 years. The average longevity in captivity is 20 years.

The *Ramphastos* spp. most commonly encountered as companion birds are the Toco and Keel-billed Toucans. If hand-raised, these birds are tame, easily handled and highly inquisitive. These large, active birds require plenty of space for exercise and produce a voluminous, moist excrement, which may account for the low numbers of these birds that are maintained as pets.



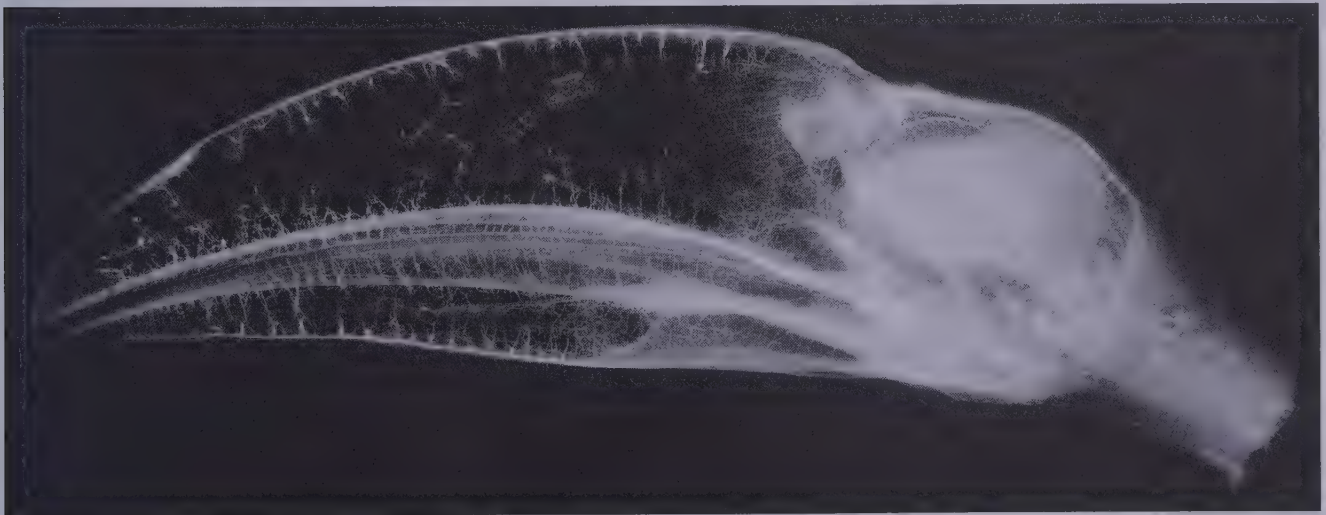
## Anatomy

Toucans have a large, lightweight, highly vascular bill composed of spongy bone (Figure 47.1). Several branches of the fifth cranial nerve innervate the bill (Figure 47.2), which is extremely sensitive. Toucans have a long keratinous tongue with lateral horn fringes. These birds have no crop and have an intestinal tract that is shorter and wider than that found in Psittaciformes of similar size. There is no cecum. The gall bladder is elongated. Nestlings have a keratinous thickening on the caudal side of the intertarsal joints (heel pad), which falls off shortly after they leave the nest.<sup>31</sup> Ramphastids have a zygodactyl foot. The trachea deviates ventrally at the level of the thoracic inlet and should not be misinterpreted as pathology radiographically (Figure 47.3). A detailed description of the biomechanics of the skull and beak is available in the literature.<sup>18,19</sup>

### Gender Determination

Sexual dimorphism occurs in some Ramphastidae, while others are monomorphic and gender must be determined by endoscopy (Table 47.2).<sup>35</sup> Spot-billed Toucans have individually distinct beak patterns that can be photographed and used for identification.

In general, male Ramphastids have a larger beak than females. To determine the beak's length, the lower margin of the upper mandible is measured from the edge of the facial skin outward toward the tip. In Toco Toucans, the beak of the male is generally greater than 16 cm in length, while in the female the measurement is less than 15.5 cm.<sup>35</sup>



**FIG 47.1** Radiograph of the head of a Channel-billed Toucan showing the massive bill composed of spongy bone. Note the large scleral ossicles that support the eyes (courtesy of Hans Cornelissen).

**TABLE 47.1** The Family Ramphastidae


Genera	Characteristics
<i>Ramphastos</i>	Large, black toucans
<i>Andigena</i>	Mountain-ranging toucans
<i>Aulacorhynchus</i>	Green mountain toucanets
<i>Selenider</i>	Lowland toucanets
<i>Ballonius</i>	Lowland toucanets
<i>Pteroglossus</i>	Aracaris

**TABLE 47.2** Gender Dimorphism

Genera	Male	Female
<i>Selenidera</i> sp.	Black head feathers	Brown head feathers
<i>S. culik</i>	Black neck and underparts	Chestnut neck, grey underparts
<i>Pteroglossus viridis</i>	Black head feathers	Brown head feathers
<i>P. inscriptus</i>	Black head feathers	Brown head feathers

## Behavior

Toucans can be loud and aggressive, particularly if untamed. Tame birds that are not given sufficient attention may also become very aggressive toward their keepers. Ramphastids are best restrained by initially removing them from the enclosure with a net or large towel. The bird can then be controlled by holding the beak in one hand and using a towel loosely wrapped around the body to control the wings and feet. Toucans should never be handled by the head and neck alone, as is commonly done with psittacine birds.



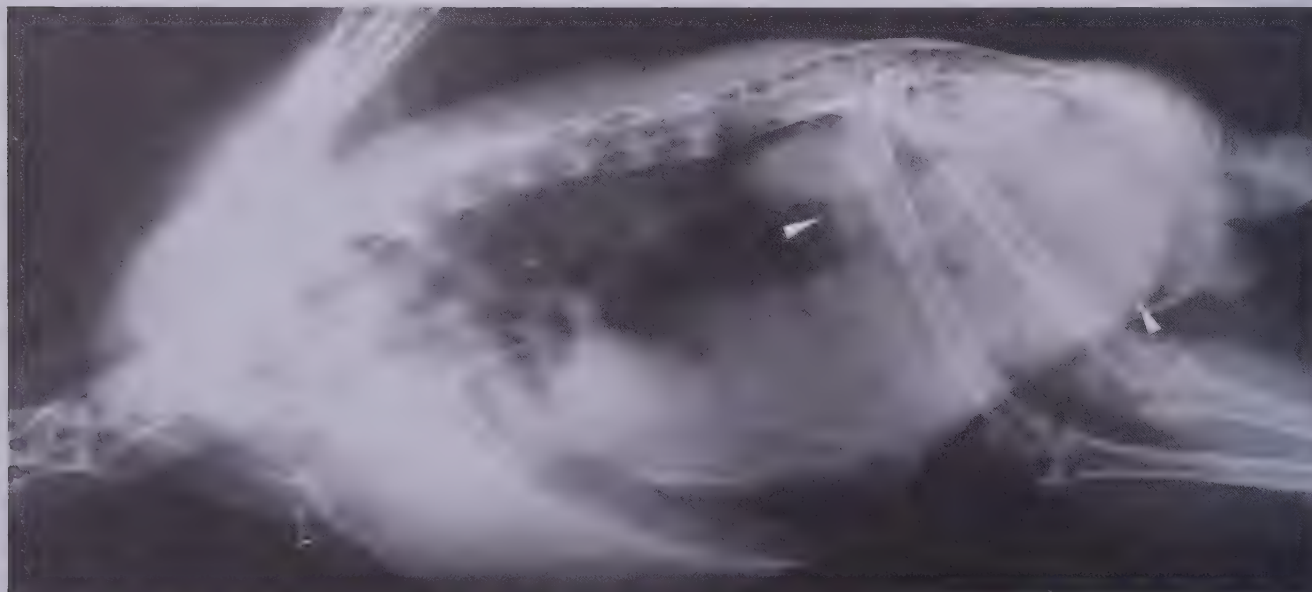
**FIG 47.2** Cross-section of the bill of a Channel-billed Toucan showing the extensive nerve supply to the extremely sensitive bill (courtesy of Hans Cornelissen).

The active, curious nature of these birds often leads them to pick up and consume nonedible foreign bodies found in the enclosure (eg, rocks, pieces of wood, screws, string, coins). Resulting impactions can cause perforation or stasis of the gastrointestinal tract, which may lead to death. These birds are capable of being extremely destructive and can injure their beaks when biting on solid objects.

Ramphastids are known to sunbathe. This activity involves spreading the wings with their back to the sun. The mouth is usually open. However, these birds are extremely sensitive to heat prostration and must have access to shade at all times. When sleeping, these birds frequently place their bills into the feathers on the back and raise their tails to form a roof over the back and beak.

Toucans are active, inquisitive birds that are best housed as pairs in large flights with numerous, variably-sized perches. These birds are carnivorous, and if housed in mixed-species aviaries may consume smaller aviary inhabitants. If these birds must be mixed with other birds in the same flight, there should be sufficient room and adequate hiding places to ensure the safety of all inhabitants. Emerald Toucanets are particularly aggressive and should always be housed alone. Most male toucans are aggressively territorial and should not be housed with other males.

The aracarids are the most secretive of the Ramphastidae and require a nest box for security and privacy. This group can thrive if raised in species-specific



**FIG 47.3** A three-year-old Toco Toucan was presented with a progressive posterior paresis of four months' duration. Clinical pathology findings were unremarkable. Radiographs indicated enlarged kidneys. Necropsy findings included renal tubular necrosis and multifocal nonsuppurative neuritis. Note the normal ventral deviation of the trachea (open arrow) in the thoracic inlet. The normal bowel loops (arrows) of toucans appear distended when compared to those of similarly sized Psittaciformes.

colonies where the young from one clutch may assist the parents in caring for subsequent chicks.<sup>35</sup>

### ■ Husbandry

Free-ranging Ramphastids eat a variety of fruits, insects, spiders, bird eggs and small vertebrates.<sup>35</sup> They grasp the food with the tip of the bill, toss it into the air, catch the food in the open bill and swallow. Large food items are compressed with a foot and segmented into smaller pieces with the bill. An adequate maintenance diet for toucans would consist of fresh fruits (eg, melons, papaya, berries, tomatoes) supplemented with a low-iron, formulated diet.<sup>a-d</sup> Paprika may be added to the diet to maintain the bright coloration of the beak. During the breeding season, the diet should be supplemented with crickets (up to 800 per day when a pair is raising chicks), small mice and crushed hard-boiled eggs.<sup>34</sup> Fresh water for drinking and bathing should always be available. Toucans like to bathe and should be provided with large, easy-to-clean water containers.

The diet recommended for toucans is low in iron, which may reduce the chances of iron storage disease. The recommended level of iron for poultry is 40 to 60 ppm and the suggested diets for toucans approximate these levels. Many dog foods contain high levels of iron (up to 1500 ppm) and these high-iron foods should be avoided in a diet designed for Ramphastids. Grapes and raisins are also high in iron and should be avoided. Vitamin C enhances the absorption of iron, and citrus fruits should be offered on a limited basis.

The floor of a toucan enclosure should be well drained and easy to clean.<sup>4</sup> The large amount of moist foods that these birds consume results in the production of voluminous, malodorous excrement. These birds may normally pass some undigested food. Birds that are losing weight and consistently excreting undigested food should be evaluated.

### ■ Reproductive Characteristics

Toucans are best bred in large, planted flight enclosures with plenty of privacy. The walls of the enclosure should be covered with a cloth or plastic barrier to protect young chicks from collision injuries while they are learning to fly or, more appropriately, stop.

Toucans are cavity nesters. The larger species make an entrance hole in decayed portions of large trees. The smaller species take over the nests of woodpeck-

ers and remodel them for their own use. Most birds will readily accept natural palm logs as nesting cavities. Some toucans can be adapted to plywood boxes six feet long and one foot square with a concave bottom. The front can be covered with bark to simulate a natural nest. The nests of free-ranging birds can be found from a few inches to several feet below the entrance hole.

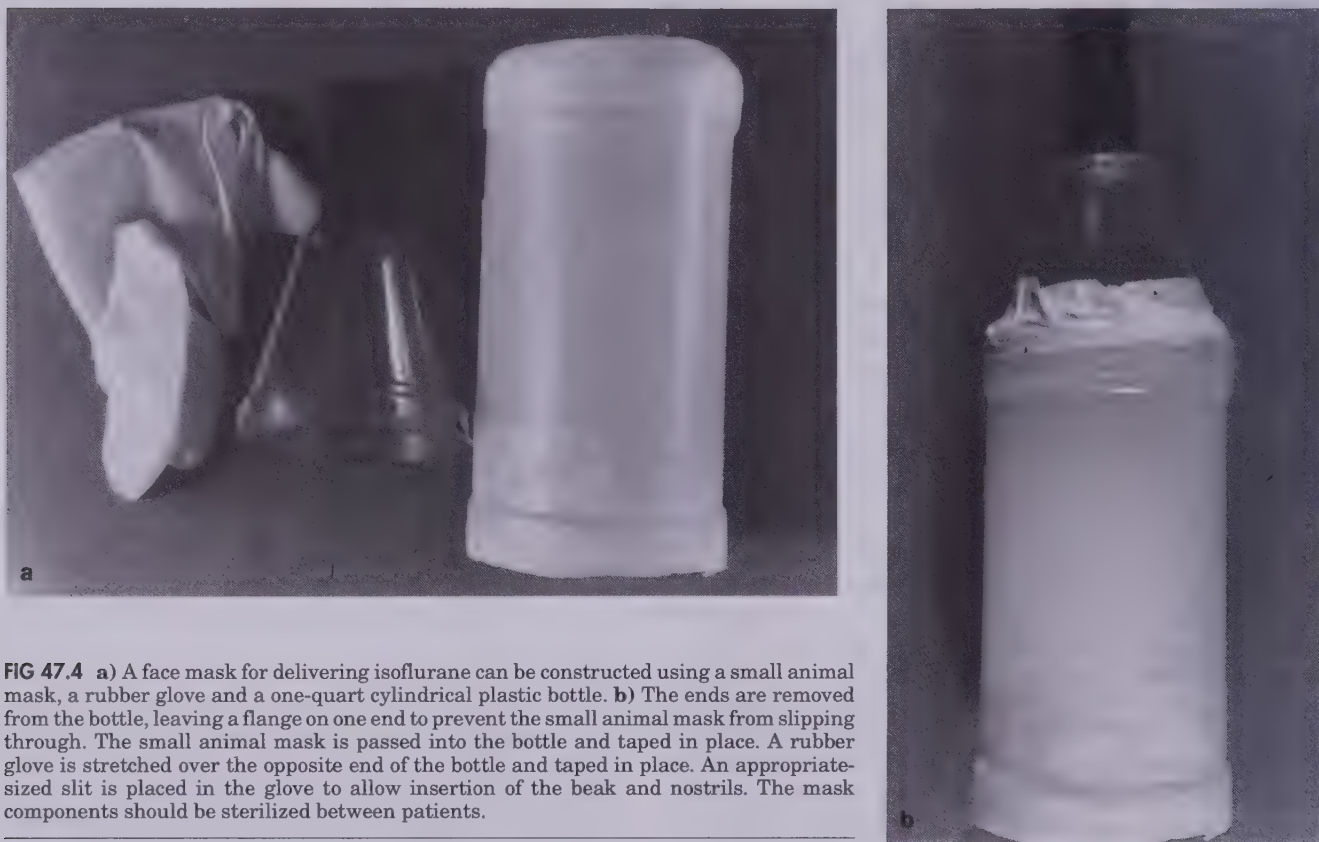
Courtship behavior is characterized by the males feeding the females, and both adults share incubation and rearing responsibilities. Sexual maturity generally occurs by three years of age.

Toco Toucans usually lay three to four eggs per clutch with an 18-day incubation period. Red-breasted Toucans usually have two to three eggs with a 16- to 17-day incubation period. Some of the toucans will use nesting material while others will empty the nesting cavity and lay the eggs directly on the bottom of the container.<sup>3a</sup> Frequently, the addition of nesting material will stimulate a pair to clean out the nest box and induce breeding.

Toucan chicks may leave the nest within 45 days of hatch and are generally weaned from two to four months of age.<sup>22</sup> Cannibalism of young chicks by the parents is common if the diet is not supplemented with crickets, mice or mealworms.

Toucan chicks have been successfully hand-raised from the egg. Initially, the diet consisted of small diced pieces of grape, banana, and pinkie mice soaked in water and offered by forceps. By three days of age, soaked monkey biscuit was added to the diet. The neonates were fed every two hours for the first twelve hours and then every three hours for 16 days, when the feeding frequency was reduced to four times per day. The eyes were open at three to four weeks of age. It is important to remember that these birds do not have a crop and should be fed smaller quantities and more frequently than psittacine neonates. Weaning may occur from two to four months of age.<sup>3a</sup> A neonate should be expected to gain weight daily and any weight loss is an indication of a problem. The weight should double each week.

Toucans can be anesthetized using isoflurane delivered through a modified face mask (Figure 47.4). Blood collection techniques are similar to those described for other avian species. Normal blood parameters are listed in the Appendix.<sup>33,34</sup>



**FIG 47.4** a) A face mask for delivering isoflurane can be constructed using a small animal mask, a rubber glove and a one-quart cylindrical plastic bottle. b) The ends are removed from the bottle, leaving a flange on one end to prevent the small animal mask from slipping through. The small animal mask is passed into the bottle and taped in place. A rubber glove is stretched over the opposite end of the bottle and taped in place. An appropriately sized slit is placed in the glove to allow insertion of the beak and nostrils. The mask components should be sterilized between patients.

## Diseases

### Liver Disease

Toucans are frequently diagnosed with iron storage disease, liver cirrhosis and chronic acute hepatitis (Figure 47.5). They are among the species of birds most susceptible to iron storage disease.<sup>14,21,30,33,34,35</sup> Primary iron storage disease is generally considered to be of hereditary origin, while secondary disease occurs from exposure to toxic levels of iron, anemia or other factors (see Color 20).<sup>23</sup> It remains unclear whether hemochromatosis in toucans is caused by hereditary factors, excess dietary iron or a defect in iron metabolism. There does seem to be some species predisposition, with Toco Toucans being particularly susceptible.

Studies have shown that birds of paradise absorb 90% of their dietary iron intake, while humans absorb only 10% of their dietary iron.<sup>10</sup> Studies on the efficiency of dietary iron absorption in toucans have

not been performed. Based on the frequency of iron storage disease in a presumably genetically diverse group of birds, it is likely that an efficient iron absorption process plays some role in the development of iron storage disease.

Toucans with hemochromatosis may die acutely with no premonitory signs or can develop clinical signs, including emaciation, dyspnea and abdominal enlargement (ascites). Affected birds typically have an enlarged, yellow liver with ascites (see Color 20). Histologically, iron deposits are most frequently identified in hepatocytes and Kupffer cells, but may also be demonstrated in the spleen, renal tubular epithelium, lung, pancreas and intestines.<sup>35</sup> Definitive diagnosis requires the confirmation, with a Prussian blue stain, of excess iron in affected tissues or toxicologic analysis of liver tissue.<sup>39</sup>

Previously, an antemortem diagnosis of iron storage disease was made by measuring total serum iron, the total iron binding capacity (TIBC) and by taking a liver biopsy for histologic evaluation.<sup>33,35</sup> More recently, the same author surveyed 24 clinically normal birds and found bile acids, serum chemistries and hematology values within the normal reference in-

tervals. Liver biopsies from these birds showed histologic evidence of hemochromatosis, and toxic levels of iron were above the reported normal of 100-300 ppm.<sup>37</sup>

A low iron diet (< 150 mg/kg) and weekly phlebotomies to remove a blood volume equivalent to one percent of body weight have been suggested as methods to prevent hemochromatosis in Ramphastids with high serum iron levels.<sup>34</sup> Iron chelating agents have also been suggested as a method of treatment.<sup>33,35</sup>

Toucans do not frequently breed in captivity.<sup>2,4,17,22</sup> Because the liver is critical in the formation of yolk, it is possible that the frequency of hepatic-related problems in toucans directly affects their ability to reproduce.



**FIG 47.5** Ascites secondary to iron storage disease, liver cirrhosis and chronic active hepatitis is one of the most common clinical presentations in toucans. In this case, a toucanet from a breeding aviary was found dead in its enclosure. The bird had a severely distended abdomen. Fluid collected by abdominocentesis at necropsy was characterized as a transudate and there was no bacterial growth. The liver was enlarged and pale-orange. The histologic diagnosis was hemochromatosis.

### Infectious Diseases

The normal aerobic and microaerophilic microflora of clinically normal toucans include *Escherichia coli*, *Staphylococcus* spp. and *Streptococcus* serotype D. These organisms were detected in the cloaca of 90% of 53 asymptomatic toucans representing five different species.<sup>6</sup> *Klebsiella pneumonia* was recovered from 50% of the clinically normal Red-billed and Plated-billed Mountain Toucans examined in one study. Birds from aviaries with good hygiene had fewer gram-negative bacteria than birds from less well maintained facilities. However, the fact that pathogenic gram-negative bacteria were commonly recovered from normal birds suggests that toucans are able to withstand colonization of the gastrointestinal tract by these bacteria better than are psittacine birds. Because gram-negative pathogens are frequently recovered from clinically normal Ramphastids, antimicrobial therapy should be considered only in patients with high concentrations of these bacteria, especially when they are demonstrating clinical signs of disease.

Avian pseudotuberculosis (*Yersinia pseudotuberculosis*) has been documented as a cause of acute death following a brief period of lethargy in toucans.<sup>3,4,7,8,16</sup> Infections are most frequently associated with a rapid bacteremia and peracute death. Postmortem findings include pneumonia, hepatomegaly and

splenomegaly. The enlarged liver and spleen are generally covered with numerous raised, white-to-yellow-orange foci (see Color 20).<sup>7</sup> Chronic debilitating infections have also been defined with *Y. pseudotuberculosis*. In these cases, bacteremia results in formation of granulomas in numerous parenchymatous organs.

It has been suggested that *Y. pseudotuberculosis* may cause dark-green or black discoloration of the orange portion of a toucan's bill, but the involvement of this bacteria in causing these lesions has not been confirmed.<sup>35</sup> In one study, *Y. pseudotuberculosis* was not isolated from the cloacal contents of 53 clinically normal toucans representing five species.<sup>6</sup> Small rodents, such as mice and rats, which normally are part of the toucan diet, are known to carry *Y. pseudotuberculosis* and may serve as a reservoir for infection.<sup>11</sup> The aviary should be rodent-proof, and only laboratory-raised mice and rats should be offered as food items.

An experimental *Y. pseudotuberculosis* vaccine appears to be clinically effective in reducing the prevalence of infections. All newly arriving toucans, tucacos and hornbills in a bird facility that normally experienced loss from *Y. pseudotuberculosis* were vaccinated with the experimental vaccine. A reduction in the morbidity and mortality in this group was evident.



**FIG 47.6** Toco Toucan with a chronic dermatitis. Cytology of skin scrapings from the wounds indicated a mixture of bacteria and fungi.

A pet male Toco Toucan that was housed indoors died following a one-day history of anorexia. The bird had acute nephrosis, and *Aeromonas hydrophilia* was recovered from the heart and liver. The source of bacterial infection was undetermined.<sup>27</sup> A three-year-old female Toco Toucan was diagnosed with *Mycobacterium* sp. Clinical abnormalities were limited to lethargy, poor feather formation and an enlarged abdomen. Necropsy findings included a swollen and congested liver, spleen and kidney. The intestinal wall was thickened, and the lumen was dilated and filled with fluid. In most species, mycobacterium infections tend to induce localized infections that result in the formation of discrete granulomas. In contrast, mycobacterium infections in psittacine birds and toucans are usually diffuse.<sup>32</sup>

#### Mycotic Diseases

A group of Toco Toucan neonates was diagnosed with corneal ulcers caused by *Candida* sp. Some of the affected birds had secondary bacterial infections. A combination of IV and topical amphotericin B as well as topical gentamicin ophthalmic solution resolved the ulcers. Scar formation was common (Figure 47.6).<sup>20</sup>

Acute deaths caused by *Penicillium griseofulum* were reported in a group of toucanets. Affected birds had a pale-green mold that was visible in the trachea, abdominal air sacs and lungs.<sup>1</sup>

Ergotism was suspected in a group of Keel-billed Toucan neonates being fed a kitten chow diet. Constrictive lesions occurred to multiple digits in the neonates. The most severely affected chick died. Changing the diet and initiating antifungal therapy prevented any further problems in the other neonates.

#### Viral Diseases

Newcastle disease virus was isolated from 3 of 48 toucans tested in a quarantine station.<sup>28</sup> A herpesvirus was recovered from a mature female toucan that died following a brief episode of depression and inappetence. Severe necrotizing hepatitis with intranuclear inclusion bodies in the spleen and liver were the principal histologic lesions. The toucan had been exposed to several macaws that died from herpesvirus five days before clinical signs developed in the toucan. The herpesvirus isolated from the toucan did not react with Pacheco's disease virus-specific antibodies, suggesting that the isolate from the toucan was a serologically distinct herpesvirus. The bird was also diagnosed with chlamydiosis using the direct fluorescent antibody test of impression smears from the liver and spleen.<sup>5</sup>

#### Parasites

Three species of *Plasmodium* (*P. huffi*, *P. nucleophilum tucani* and *P. rouxi*) have been documented in toucans. High levels of *P. huffi* usually result in death. The other species have been associated with mild to subclinical infections in Swanson's Toucans, Sulphur-crested Toucans, Collared Aracaris, White-throated Toucans and Plate-billed Mountain Toucans.<sup>24,25</sup>

Fluke eggs and numerous giardia were found in the feces of a Red-bellied Toucan with loose droppings that contained undigested food. Metronidazole resolved the giardia infection in four days but had no effect on the flukes. Treatment with praziquantel (10 mg/kg) IM daily for three days followed by the same dose orally daily for 11 days was effective in stopping the passage of fluke eggs.<sup>12</sup>

Giardia is frequently identified in fecal samples collected from asymptomatic toucans. Currently, no clinical disease has been associated with these infections. However, toucans could serve as a reservoir for

this parasite and expose other avian species housed in the same facility. Ascarids, coccidia and capillaria are other parasites frequently encountered in toucans. These infections are treated in a manner similar to those described for psittacine birds (see Chapter 36).<sup>35</sup>

Subclinical infections with ventricular nematodes have been documented in toucans that were housed in enclosures once occupied by finches (the nematodes' natural host).<sup>35</sup> A subclinical infection with a diurnal microfilaria of an undetermined genera was documented in a Swanson's Toucan.<sup>24</sup>

### Metabolic Diseases

Idiopathic diabetes mellitus is frequently diagnosed in toucans. Weight loss, glucosuria (1 mg/dl), hyperglycemia (700 mg/dl often occur), polyuria and polydipsia are frequent clinical findings. The frequency with which this disease occurs suggests that the etiology is related to management or diet rather than genetic defects. Pancreatic islet cell tumors and hypothyroidism have also been suggested as causes for diabetes mellitus in toucans.<sup>35</sup>

Protamine zinc insulin (0.1 to 0.5 units BID) has been suggested as a possible treatment.<sup>35</sup> However, maintaining proper blood glucose in toucans with insulin is difficult. Long-term therapy is generally associated with pancreatic atrophy, which causes pancreatic exocrine insufficiency, eventually leading to death. Toucans also develop rapid tolerance to insulin, making proper administration difficult. In a study involving three normal adult Toco Toucans, it was determined that glucagon suppression did not occur following glucose challenge, suggesting that toucans metabolize glucose differently than do other birds.<sup>26</sup>

A toucan being fed a fruit and dog food kibble diet was found to have diabetes mellitus with a blood glucose level of 1587 mg/dl. Changing the diet to a 100% formulated diet<sup>4</sup> supplemented with prozyme reduced the blood glucose level to 365 mg/dl, suggesting this bird's diabetes was dietary related.<sup>26</sup>

### Products Mentioned in the Text

- Bird of Paradise Diet, Ziegler Bros. Inc., Gardners, PA (iron content 77 ppm)
- Harrison's Bird Diets, Pawnee City, NE (iron content 65 ppm)
- Science Diet, Hill Pet Nutrition Inc., Topeka, KS (iron content 100 ppm)
- Kaytee Softbill Diet, Green Bay, WI (iron content 80 ppm)

### References and Suggested Reading

- Aho R, Westerling, et al: Avian penicilliosis caused by *Penicillium griseofulvum* in a captive toucanet. *J Med & Vet Mycol* 28(5):349-354, 1990.
- Berry RJ, Coffey B: Breeding the sulphur-breasted toucan (*Ramphastos s. sulfuratus*) at the Houston Zoo. *Intl Zoo Yearbook* 16:108-110, 1976.
- Borst GH, et al: *Yersinia pseudotuberculosis* in birds. *Tijdschrift voor Diergeneeskunde* 102(2):81-85, 1977.
- Branch S: Breeding and handrearing toucans. *Assoc Avian Vet Today* 1(4):171, 1987.
- Büngener W: Tukane und Arasaris. *Die Gefiederte Welt* 113(3):73-76, 1989.
- Charlton BR, et al: Herpes viral hepatitis in a toucan. *Avian Dis* 34(3):787-790, 1990.
- Cornelissen JMM, et al: Cloacal microflora of healthy hornbills, toucans and aracaris. *Proc 1st Conf Europ Assoc Avian Vet*, 1991, pp 453-460.
- Dhillon AS, Shafar D: *Yersinia pseudotuberculosis* infection in two toucan toucans and a turaco. *Proc 1st Intl Conf Zool & Avian Med*, 1987, pp 37-38.
- Dhillon AS, Schaberg DM: Pseudotuberculosis in toucans. *Proc 73rd Ann Meet Poultry Sci Assoc. Poulit Sci* 63(suppl 1):90, 1984.
- Douglass EM: Diabetes mellitus in a toucan. *Med Vet Pract* 62(4):293-295.
- Frankenhuis MT, et al: Iron storage in livers of birds of paradise. *Proc 2nd Eur Symp Avian Med & Surg*, 1989, pp 92-95.
- Gerlach H: Bacterial diseases. In Harrison GJ, Harrison LR (eds): *Clinical Avian Medicine and Surgery*. Philadelphia, WB Saunders Co, 1986, pp 434-453.
- Giddings RF: Treatment of flukes in a toucan. *J Am Vet Med Assoc* 193(12):1555-1556, 1988.
- Gould J: A monograph of the Ramphastidae or family of toucans, London, 1837.
- Griner LA: Order Piciformes. In Griner LA (ed): *Pathology of Zoo Animals*. San Diego, Zoological Society of San Diego, 1983, pp 246-250.
- Haffer J: Avian Speciation in Tropical America. 1974, pp 179-312.
- Gutknecht P: Pseudo-tuberculose chez des toucans a bec carene (*Ramphastos sulfuratus*). *Proc Diseases of Zoo Animals XIVth Intl Symp*, Wrocław, 1972, pp 85-88.
- Hofner J: Hybrid Ramphastos toucans in captivity. *J Ornithol*, 119(2):233-234, 1978.
- Höfling E, Gase JP: Biomécanique du crâne et du bec chez Ramphastos (Ramphastidae, Aves). I. Descriptions des éléments anatomiques. *Gegenbaurs morph Jahrbuch* 130(1):125-147, 1984.
- Höfling E, Gase JP: Biomécanique du crâne et du bec chez Ramphastos (Ramphastidae, Aves). II. Analyse des conditions du mouvement du bec. *Gegenbaurs morph Jahrbuch* 130(2):235-262, 1984.
- Karpinski LG, Clubb SL: Further investigations into the ocular problems of caged birds. *Proc Assoc Avian Vet*, 1985 pp 101-108.
- Kincaid AL, Stoskopf MK: Passerine iron overload syndrome. *Zoo Biology* 6:79-88, 1987.
- Longo J: Breeding the toucan. *Proc Assoc Avian Vet*, 1989, pp 248-249.
- Lowenstine, LJ: Nutritional disorders of birds. In Fowler ME (ed): *Zoo and Wild Animal Medicine* 2nd ed. Philadelphia, WB Saunders Co, 1986, pp 204-205.
- Manwell RD, Sessler GJ: Malaria parasites of toucans. *J Protozool* 18(4):570-574, 1971.
- Manwell RD, Rossi GS: Blood protozoa of imported birds. *J Protozool* 22(1):124-127, 1975.
- Murphy J: Diabetes in toucans. *Proc Assoc Avian Vet*, 1992 pp 165-170.
- Panigraphy B, et al: Unusual disease conditions in pet and aviary birds. *J Am Vet Med Assoc* 178(4):394-395, 1981.
- Pearson GL, McCann MK: The role of indigenous wild, semidomestic, and exotic birds in the epizootiology of velogenic viscerotropic Newcastle disease in Southern California. *J Am Vet Med Assoc* 167(7):610-614, 1975.
- Phalen DN, et al: The avian urinary system: Form, function, diseases. *Proc Assoc Avian Vet* pp 44-57, 1990.
- Spalding M, et al: Hepatic encephalopathy associated with hemochromatosis in a toucan. *J Am Vet Med Assoc* 189(9):1122-1123, 1986.
- Stresemann J: *Handbuch der Zoologie*, 7de band, 2 teil, Sauroptadia: Aves, Walter de Gruyter und Co, Berlin und Leipzig, 1934.
- Van Der Heyden N: Avian tuberculosis: diagnosis and attempted treatment. *Proc Assoc Avian Vet*, pp 203-213, 1986.
- Worell A: Phlebotomy for the treatment of hemochromatosis in two sulfur-breasted toucans. *Proc Assoc Avian Vet*, 1991, pp 9-14.
- Worell A: Serum iron levels in Ramphastids. *Proc Assoc Avian Vet*, 1991, pp 120-130.
- Worell A: Management and medicine of toucans. *Proc Assoc Avian Vet*, 1988, pp 253-261.
- Zscheile D, Boeters E: Prothetische Versorgung eines Tukanschnabels. *Zoologische Garten* 50(5):353-357, 1980.
- Worell A: Further investigation in Ramphastids concerning hemochromatosis. *Proc Assoc Avian Vet*, 1993, pp 98-107.

CHAPTER

# 48

RATITES

James Stewart

**R**atites are a group of large, ground-dwelling birds that share the common characteristic of flightlessness. The term ratite is derived from the Latin *ratitus*, meaning raft, and refers to the shape of the sternum that lacks a keel. There is no scientific classification "ratite," but the term is used to collectively describe the ostrich (from Africa), rhea (from South America), emu (from Australia), cassowary (from Australia and the New Guinea archipelago) and the kiwi (from New Zealand).<sup>1</sup> Once considered to be a single category of related primitive birds, the ratites are now considered to be derived from unrelated groups of flighted birds that have adapted to a highly specialized terrestrial lifestyle.

In the 1980's, it was estimated that between 90,000 to 120,000 ostriches existed on approximately 400 farms as part of a multi-crop rotation system in South Africa. During the same time period, a fledgling industry arose in the United States and by the end of the decade, it was estimated that there were close to 10,000 ostriches and about 3,000 emus in the US.<sup>55</sup>

This growing interest in breeding ostriches and emus has occurred due to the birds' potential as producers of meat, feathers and skin. Ostrich skin is characterized by prominent feather follicles and is a high status product of the leather industry. Ostriches yield a red meat that has the flavor and texture of beef, yet has the cholesterol and nutritional value of poultry. Ostrich feathers, still used for dusters, are also used in the manufacture of fashion and theatrical attire.



## Characteristics

### Ostrich

The ostrich is the largest living bird, reaching over 200 kg in weight and 2.7 m in height. The ostrich that was first described (nominate race) was put in the family Struthionidae and the genus *Struthio*. The bird's dome-backed profile, desert living conditions and odd-shaped feet are reminiscent of the camel, thus the species name, *camelus*. Four subspecies are currently recognized; their range is through the northern, eastern and southern savannahs of the African continent. The Syrian ostrich of the Arabian peninsula became extinct in 1941.

*Struthio camelus camelus* (North African ostrich) ranges from Morocco to Ethiopia and Uganda. A male *S. c. camelus* has a red coloration of the skin of the neck and thighs and a bald crown of the head. The hens of all races are indistinguishable. The eggs can be differentiated among subspecies, and those of the nominate species are characterized by fine stellate pores.

*S. c. massaicus* (East African or Masai ostrich) inhabits Kenya and Tanzania. The male has a red neck and thigh and the crown of the head is feathered.

*S. c. molybdophanes* (Somali ostrich) is found in Ethiopia and Somalia. The male has a blue-gray neck and thighs and the crown of the head is bald.

*S. c. australis* (South African ostrich) ranges throughout southern Africa. The neck and thighs of the male are gray and the head is feathered.<sup>5</sup> The large pores in the shells of this subspecies leave the egg with a pitted appearance.

A hybridized ostrich that is a combination of *S. c. australis*, *S. c. massaicus* and *S. c. syriacus* is referred to as a "domestic" or "African black" ostrich. The careful breeding of this bird since the 1870's has resulted in a smaller, calmer bird that has higher quality feathers than its free-ranging relatives.<sup>55</sup>

Ostriches can run up to 40 mph for several miles and can kick forward with powerful and accurate blows. Ostriches have large eyes with substantial visual acuity, and large ear canals with a keen sense of hearing. These birds have been known to breed for up

to 42 years, and may live over 80 years. The male has black and white plumage at maturity, while the females and juveniles have dull brown plumage.

### Rhea

Rheas are frequently referred to as South American ostriches, but are related only in superficial appearance. Weighing 25 kg and standing 1.5 m in height, the rhea is the largest bird of the western hemisphere. Two distinct species are recognized. The Common Rhea ranges throughout the central continent, and as many as five subspecies have been described. Darwin's Rhea, including three subspecies, is a smaller bird residing in the eastern foothills of the Andes. Free-ranging rheas eat grass, leaves and insects.

### Cassowary

Cassowaries are stout, heavy-bodied birds reaching 85 kg in weight and 1.5 m in height. They are distinguished by a large bony casque on the forehead that is used to deflect brush as they dart through their dense rain forest habitat. Three species are found on New Guinea; one also ranges in northern Australia. Cassowaries are solitary, the males are highly aggressive and these birds adapt poorly to most captive settings.

### Emu

Emus are closely related to cassowaries and share the same type of feather. The shaft and aftershaft are equally well developed, giving each feather the appearance of being doubled. The single existing species is found throughout Australia, while the Tasmanian and Kangaroo Island emu became extinct only in the past century. Adult emus may weigh 55 kg and stand 1.7 m in height. Emus may live 30 years and have strong eyesight and hearing. Like ostriches, emus are good swimmers. Free-ranging emus consume grasses, herbs, fruits and insects.

### Other Ratites

Included among the ratites is the kiwi, and frequently the tinamous. Both groups are specialized ground-dwelling birds that bear little resemblance and no relationship to the larger species. This chapter will focus primarily on the ostrich as the model ratite, with only occasional comment on the emu, rhea and cassowary.

## Clinical Anatomy and Physiology

Despite their impressive size, ratites are, nonetheless, birds, and their anatomy and physiology are fundamentally similar to a psittacine model. The deviations from this model, including their size, are all adaptations to a terrestrial lifestyle. The similarities and differences are clinically relevant and should be familiar to the ratite veterinarian.<sup>2,11,19</sup>


### Integument

The skin of ratites is thick along the legs and body, but relatively thin along the neck where it is subject to tears (Figure 48.1). The ostrich, emu and rhea have sternal callosities. In addition, the ostrich has a callosity distal to the pubic bone and another distal to the hock joint; both anatomic areas contact the ground in a recumbent bird. Apterias are present along the lateral body wall and provide convenient access sites for surgery and diagnostic procedures such as ultrasound. In contrast to other birds, the feathers of the ostrich function to shade the body, rather than insulate it, and an ostrich will erect the feathers when hot and flatten them when cold. Ostriches have no feathers on the thigh, while in other ratites feathers extend to the tarsometatarsus. Ostrich, emu and rhea feathers lack barbicels, making their feathers less water-resistant than those of other birds (Color 48.14).

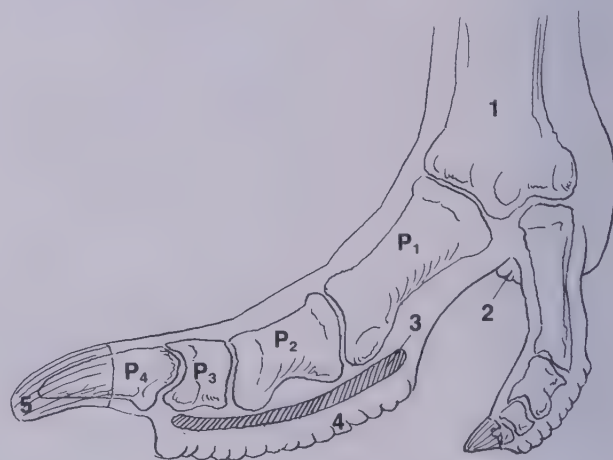
### Musculoskeletal System

The rhea, emu and cassowary have three toes (digits 2, 3 and 4), each with four phalanges. The ostrich is the most specialized runner and has only two toes (digits 3 and 4); the metatarsal-phalangeal joint is suspended so that the standing weight is born entirely by the digits (Figure 48.2). The pubic bones of the ostrich form a solid ventral symphysis to support the weight of the abdomen (Figure 48.3).

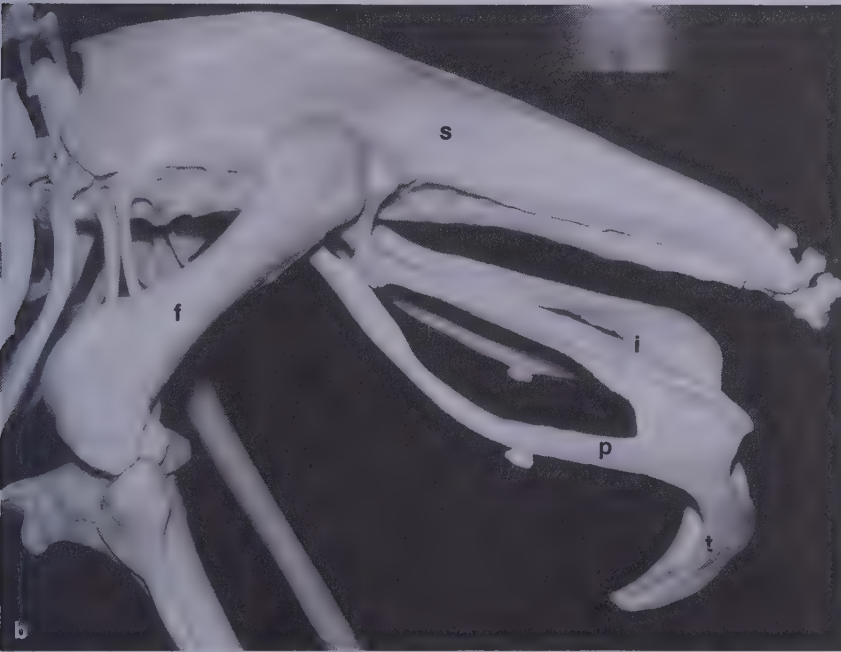
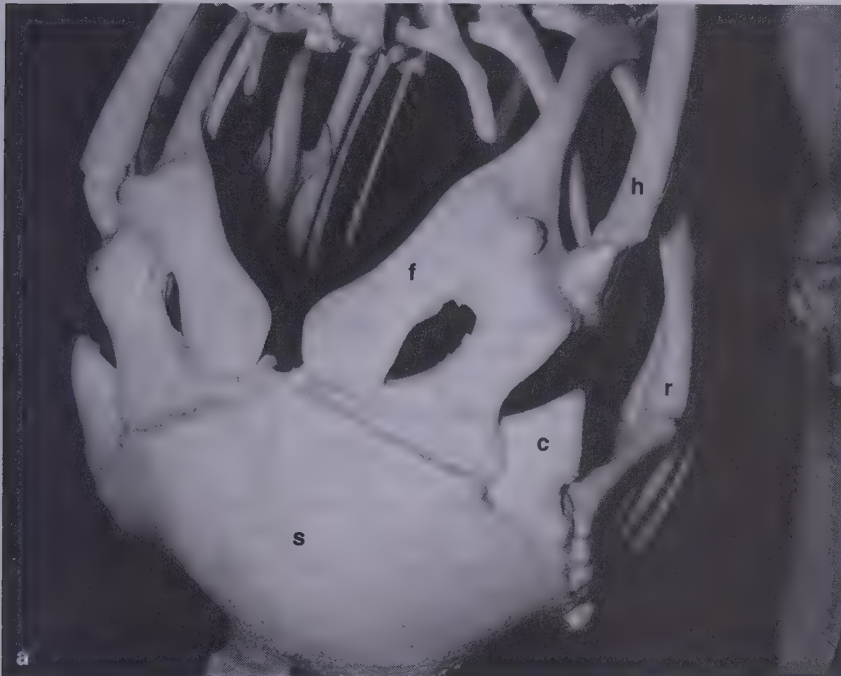
Corresponding with flightlessness, the pectoral musculature is greatly reduced and the sternum lacks a keel. Because there is no need for flight, the thoracic girdle is modified, and the fused scapula, coracoid and clavicle are attached to the cranial sternum (Figure 48.3). The patella is absent in ratites. In the



**FIG 48.1** Ratite skin is thin and easily torn by sharp projections on fences and transporting vehicles. The trachea and jugular vein are visible through the tear in the skin (courtesy of James Stewart).



**FIG 48.2** The ratite foot is composed of two toes. 1) tarsometatarsus 2) metatarsal phalangeal pad 3) digital cushion 4) phalangeal pad 5) toenail (modified with permission from Murray Fowler<sup>19</sup>).



**FIG 48.3** **a** The sternum (s) of ratites lacks a keel, and the coracoid and scapula are fused to form the scapulocoracoid (f). Other structures of interest include the first rib (r), cartilaginous extension of the sternum (c) and the humerus (h). **b** The pubic bones (p) of the ostrich are fused to form a solid ventral symphysis that supports the weight of the bird. Other structures include the femur (f), synsacrum (s), ischium (i) and pubic symphysis (t) (courtesy of Murray Fowler,<sup>19</sup> reprinted with permission).

ostrich there may be a small bone in the tendon of insertion of the muscle on the cnemial crest of the tibiotarsus. The crest is projected craniodorsally pro-

viding extra leverage for quick, sure forward movement of the leg when the bird is running, swimming or kicking. In the ostrich and emu, one of the tarsal bones remains unfused to the contiguous bones, which should not be misinterpreted as the knee radiographically.<sup>19</sup>

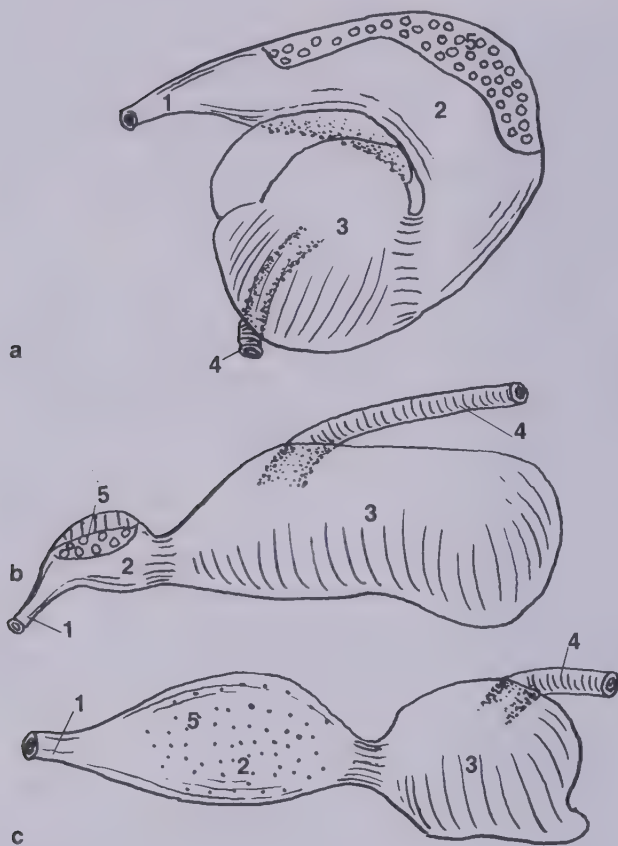
The ventral midline area of the abdominal wall consists only of the aponeuroses of the abdominal muscles. A surgical incision made along the midline penetrates the skin, subcutaneous fat (minimal) and a dense fibrous abdominal tunic. The next layer is retroperitoneal fat, which may be two to eight centimeters thick, especially in the emu. When a laparotomy is performed, the bulk of this adipose tissue should be peeled away prior to closing the body wall (Color 48.26).<sup>19,20</sup>

### Respiratory System

Unlike other birds, the sternum is fixed and bears the weight of the resting ratite. Respiration occurs by lateral excursions of the chest wall, which must be considered during anesthesia and recovery. The normal respiratory rate in adult ostriches is 6 to 12 bpm, which may increase to 40 to 60 bpm during periods of stress, exercise or with high temperatures.<sup>19</sup> The syrinx is poorly developed in these relatively avocal birds. The lungs and air sacs are similar to those of other avian species, but the air sac capacity is greatly reduced. The distinct visceral outlines created by the air sacs in the radiographs of psittacines are not present in ratites. The femur is the only pneumatized long bone in ratites.

Emus have a longitudinal cleft in the trachea 10 to 15 cm cranial to the thoracic inlet that opens into a resonance chamber for vocalization (Color 48.16). This area is particularly well developed in the female. In the chick, a thin membrane covers the cleft. Air di-

rection



**FIG 48.4** Anatomic arrangement of the 2) proventriculus and 3) ventriculus in the a) ostrich, b) rhea and c) emu. 1) esophagus 4) duodenum and 5) glandular area of the proventriculus (modified with permission from Murray Fowler<sup>19</sup>).

rected into the pouch causes a drumming sound in the female and a growling sound in the male. The skin of the neck enlarges laterally when the pouch is inflated.

The presence of this expandable pouch may complicate inhalation anesthesia in mature emus. If positive pressure ventilation is used to inflate the air sacs and ventilate the lungs, air may be directed into and thus inflate the pouch. Inflation of the pouch can be prevented by wrapping the lower neck with a self-adhesive bandage, taking care not to place excessive pressure on the major vessels of the neck. Ostriches may inflate the neck by gulping air into the esophagus.<sup>19</sup>

### Digestive System

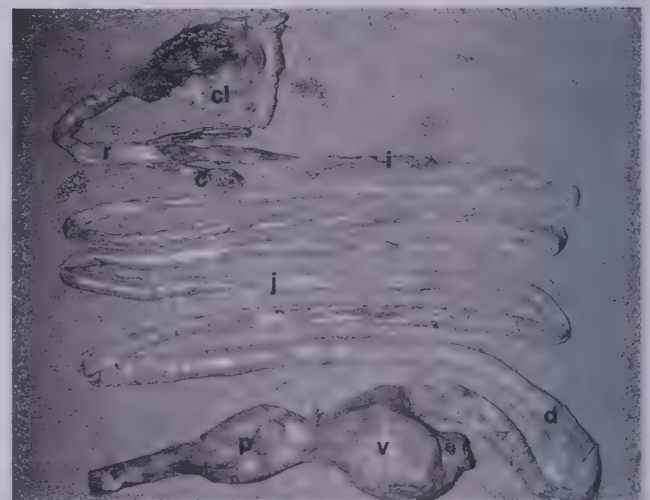
The digestive system of ratites reflects the ecological niche of these large grazing ungulates. Ratites have

no crop, and the large proventriculus serves the feed storage function. Material deposited into the esophagus during tube-feeding is routinely regurgitated, creating a risk for aspiration. Consequently, gavage feeding requires that a tube extend into the proventriculus.

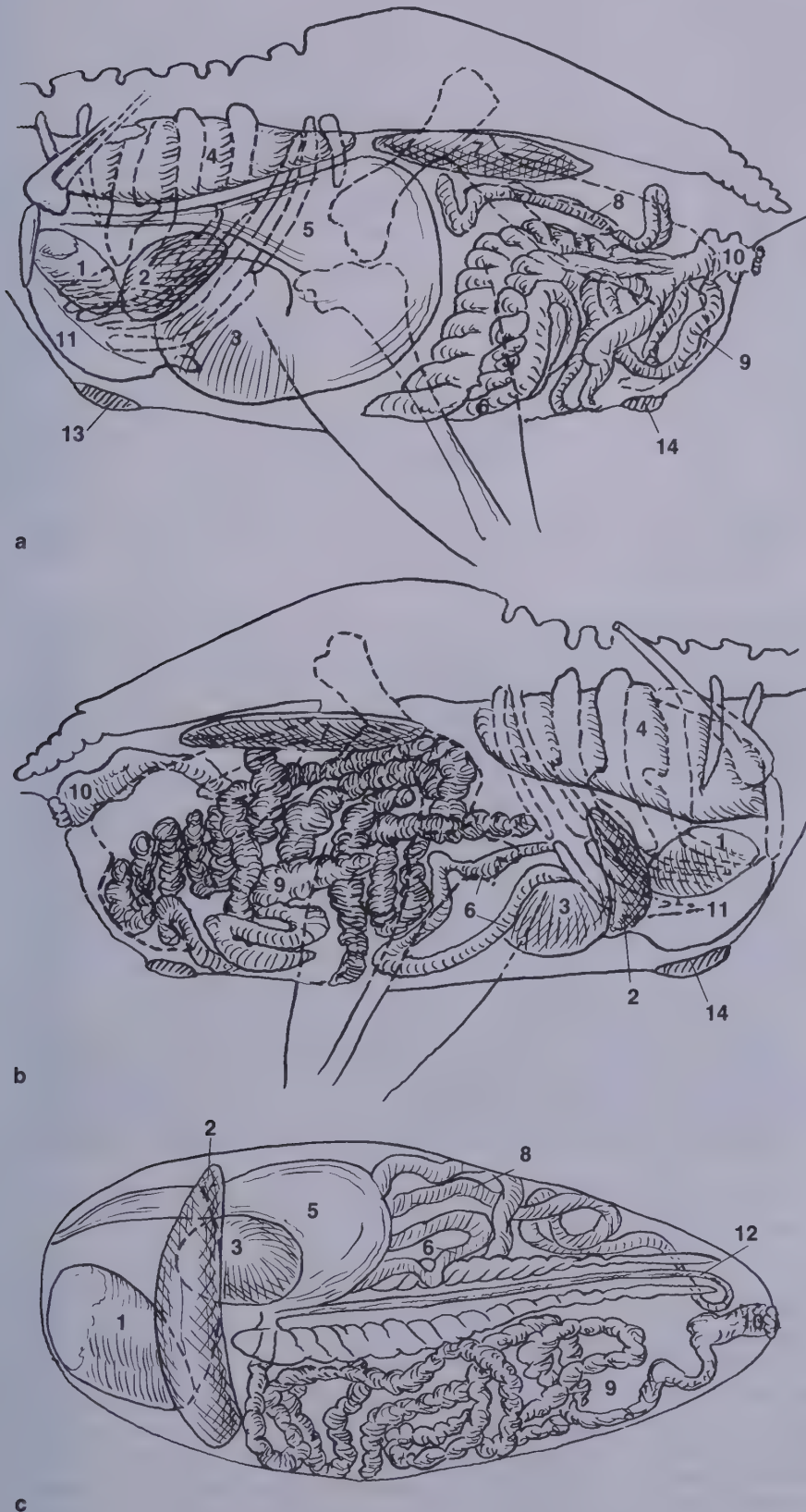
The proventriculus of the ostrich is a large, dilated, thin-walled structure that is easy to access surgically because it extends caudal to the ventriculus (Figure 48.4). In most avian species, the entire inner surface of the proventriculus secretes digestive enzymes. In contrast, the secretory region of the ostrich proventriculus is restricted to an area of glandular tissue on the greater curvature. The distal extremity of the ostrich proventriculus passes dorsal to the ventriculus and empties into this organ through a large opening on its caudal aspect. Ventricular foreign bodies can be easily removed through an incision made into the proventriculus.<sup>19,20</sup>

The ostrich ventriculus is a thick-walled structure similar to that in seed-eating birds. The ventriculus is situated slightly to the left of the midline at the caudal border of the sternum. Though the proventriculus and ventriculus can normally contain small stones, gastric impaction from the consumption of foreign bodies is a common problem in ratites, particularly in juvenile birds (Color 48.30).

Rheas have a small proventriculus and an elongated ventriculus. The stomach is slightly to the left of midline, dorsal to the sternal notch and more caudal to the sternum than is found with ostriches. In emus



**FIG 48.5** Digestive tract of an emu. Proventriculus (p), ventriculus (v), duodenum (d), jejunum (j), ileum (i), ceca (c), rectum (r) and cloaca (cl) (courtesy of Murray Fowler, reprinted with permission<sup>19</sup>).



and cassowaries, the proventriculus is large and spindle-shaped, and the ventriculus is slightly larger and less heavily muscled than the proventriculus (Figure 48.4). Cassowaries have no koilin membrane.

The opening from the ventriculus to the duodenum is on the right side in all ratites.<sup>19,20</sup> Intestinal length and morphology are highly variable. The small intestine is most important in the emu, in which it occupies most of the abdomen caudal to the ventriculus.

The caecae are paired in ratites (Figure 48.5). In the ostrich and rhea, the elongated, well developed caeca, visible immediately after entering the midline abdominal wall, course diagonally from right to left in a caudal direction. The lumen of the caeca appears sacculated as a result of spiral folds that increase the surface area in the organ and facilitate the fermentive digestion of fiber (Color 48.27). The caecae of the emu and cassowary are short.

The large intestine of the ostrich is voluminous and occupies the caudal right abdomen (Figure 48.6). The long, large intestine is considered necessary to digest high-fiber food items. The large intestine of the emu is short (10 to 15 cm). The gastrointestinal transit time is slow in ostrich and rheas (36 hours) and much faster in emus (5 to 6 hours). Interestingly, emus produce a large portion of their energy through fermentation even though they have poorly developed caeca, a short colon and a rapid gastrointestinal transit time.<sup>26</sup> These differences in gastrointestinal morphol-

**FIG 48.6** Thoracoabdominal anatomy of an ostrich: **a**) left lateral view **b**) right lateral view and **c**) ventrodorsal view. 1) heart 2) liver 3) ventriculus 4) lung 5) proventriculus 6) duodenum 7) kidney 8) jejunum 9) rectum 10) cloaca 11) sternum 12) ileum 13) sternal callosity and 14) pelvic callosity (modified with permission from Murray Fowler<sup>19</sup>).

ogy and function would suggest that free-ranging ostriches and emus ingest different feeds and may require different diets in captivity; however, these differences are rarely considered when formulating diets for these birds.

In the ostrich, the urodeum and coprodeum are separated by a muscular sphincter, making the ostrich the only bird that can urinate independent of defecation. The coprodeum is a large sac that may be covered by a dark tough membrane similar to koilin. The cloacal bursa begins to involute by 18 months of age in ostriches and rheas and is complete by two to three years in the male rhea, and three to four years in the female rhea (Figure 48.7).<sup>60</sup>

The liver is cranial to the ventriculus and caudal to the transverse membrane (avian equivalent of a diaphragm). There is no gallbladder in the ostrich, but this organ is present in the emu and rhea.<sup>19,20</sup>

### Reproductive System

All female ratites have a single left ovary and oviduct similar in form and function to other birds. All of the follicles ("eggs") that the female will have are present at birth. As a hen reaches sexual maturity, the follicles begin to develop, so the ovary has many visible follicles of different sizes at any one time (see Color 29).

The male ratite has two intra-abdominal testicles that are located near the kidney. During the breeding season, the testicles increase 200 to 300 percent in size (Figure 48.8). The cock does not produce sperm during the non-breeding season.<sup>19</sup> Testicles are tan in all ratites except emus, in which they are black. Male ratites have a phallus that serves to transport semen from the ejaculatory ducts in the cloaca of the male to the cloaca of the female. The phallus is shaped differently in ostrich, emu and rhea; however, the function is the same, and the phallus contains a dorsal groove through which

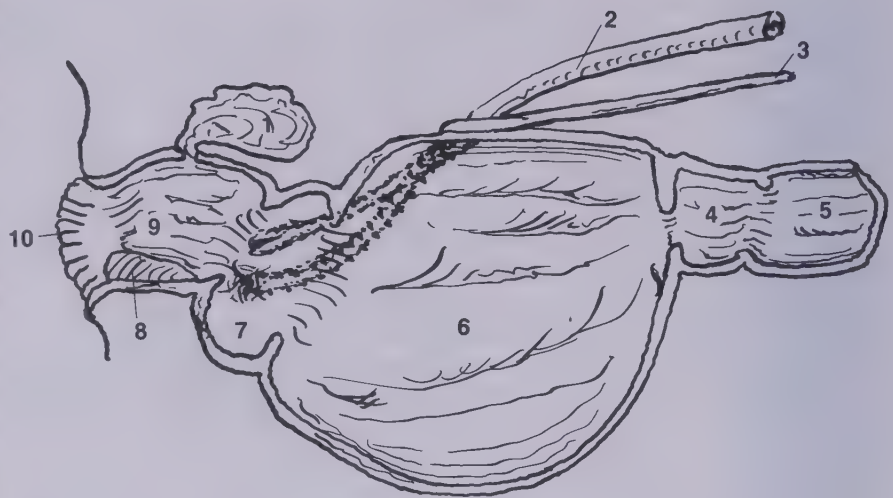


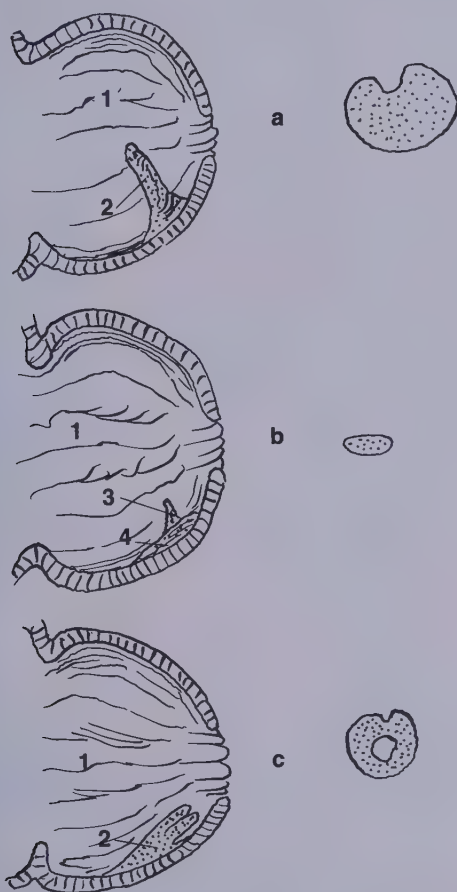
FIG 48.7 Right lateral view of the cloaca of an ostrich. 1) bursa 2) ureter 3) genital tract 4) rectal pouch 5) rectum 6) coprodeum 7) urodeum 8) genital eminence 9) proctodeum and 10) vent (modified with permission from Murray Fowler<sup>19</sup>).



FIG 48.8 Testicle size and location in a mature rhea. Cranial division of the left kidney (k), left testicle (t) and left adrenal gland (a) (courtesy of Murray Fowler, reprinted with permission<sup>19</sup>).

the semen travels (Figure 48.9).<sup>19</sup> The avian phallus serves no function within the urinary system and does not contain a urethra.<sup>19</sup>

Ratites of both genders possess a genital prominence that extends from the ventral aspect of the cloaca. This prominence may be visualized or palpated to determine the gender of any aged individual.<sup>25</sup> Gender determination is easiest in chicks between one



**FIG 48.9** Left lateral view of the cloaca of juvenile ratites. The cross sectional view of the reproductive organ is also provided. **a)** male ostrich, **b)** female ostrich and **c)** male rhea or emu. 1) proctodeum 2) phallus 3) clitoris and 4) genital eminence (modified with permission from Murray Fowler<sup>13</sup>).

and three months of age. A lubricated gloved finger is used to expose the cranio-ventral aspect of the cloaca.

The male ostrich chick has a phallus that is conical in cross section, contains a palpable core of fibroelastic tissue and is characterized by the presence of a seminal groove. By comparison, the clitoris in the hen is laterally compressed, soft and lacks the seminal groove. The clitoris of the adult female remains approximately one to two centimeters in length (Figure 48.10). By six months of age the phallus of the male is approximately three to five centimeters in length and is readily detected on the ventral wall of the cloaca by palpation. The phallus of the adult male ostrich is “J”-shaped and when everted curves to the left (Figure 48.11). The phallus of the emu and rhea are considerably smaller, and the males are usually distinguished from females by the spiral conformation of the phallus.

### Anatomic Considerations for Sample Collection and Supportive Care

Blood samples can be collected by routine venipuncture techniques used in most other avian species. Venipuncture can be performed using the jugular, brachial and medial metatarsal veins. The right jugular vein is larger than the left as in other avian species and is a convenient site for venipuncture or placement of intravenous catheters (Figure 48.12). The brachial vein is inaccessible in the reduced wings of the cassowary and emu, but is well developed in the large wings of the ostrich and can be easily accessed. The medial metatarsal vein is readily accessible in sedated or immobilized adult ratites and in unsedated chicks. The medial metatarsal vein generally is not used in standing adults due to the potential for being kicked.<sup>4</sup> Reference hematologic and biochemical values for the ostrich, emu and cassowary are listed in the Appendix.<sup>36,37,41,58</sup>

Intravenous catheters can be placed in any of the vessels used for venipuncture. The medial metatarsal vein is a common preference for intravenous catheterization of chicks (Figure 48.13). Catheterization of the brachial vein (18 ga) is preferred in adults. A 14 ga catheter can be placed in the jugular vein of an adult ostrich. Catheters should be secured in place using tissue adhesive followed by a light bandage.<sup>4</sup>

Samples for cytology and for culture and sensitivity can be collected from the oviduct of adult hens (see Chapter 29). Abdominocentesis can be performed on birds with clinical signs suggestive of intestinal torsions, penetrating foreign objects, egg yolk peritonitis or retained eggs. A teat cannula is the safest device for use for abdominocentesis in ratites (see Chapter 10).

Oral medications are relatively simple to administer by orogastric tube to chicks or tractable adults. Occasional feedings can be provided by placing an equine stomach tube directly into the proventriculus; however, to perform gastric lavage or supply sustained enteral nutrition, an equine stomach tube is passed through an esophagostomy incision and is sutured into place. The tube is most easily placed by introducing it orally into the esophagus, making an incision over the cranial end of the tube and retracting it back through the incision. Blended canine maintenance kibble administered TID has been suggested as an effective enteral nutrition product.<sup>22</sup>

Parenteral medications are often administered to ratites. Subcutaneous administration of medications

## ■ Ratites

Unless otherwise noted, color photographs in this section are courtesy of Brett Hopkins.

### Color 48.1

**a)** A normal, healthy, well developed ostrich egg shell. Note that the shell is clean, has an even surface and is free of debris. **b)** An extremely thin egg shell from an ostrich shows abnormal deposition of calcium (blebs) and contamination of the shell with sand and debris.

### Color 48.2

Two ostrich embryos died at about 40 days of incubation. The chick on the left is severely edematous, which in other avian species can be caused by excessive humidity during incubation. The chick on the right has a closed umbilicus with one-third of the yolk sac remaining externalized.

### Color 48.3

Two ten- to fifteen-day-old ostrich chicks. The chick on the left has a distended abdomen caused by the retention of an infected yolk sac. The bird on the right has a small, tucked abdomen secondary to starvation.

### Color 48.4

Two ostrich embryos that died late in the incubation period are stunted (40% smaller than normal), have abnormal feathering and curled feet. These findings are characteristic of a riboflavin deficiency in other avian species.

### Color 48.5

**a)** Star-gazing in a one-day-old ostrich chick is suggestive of thiamine deficiency. Note also the edematous limb. **b)** The same chick is shown two days after parenteral administration of thiamine.

### Color 48.6

A bulging, inflamed umbilicus is suggestive of an active yolk sac infection. These birds are best managed by surgically removing the infected yolk sac before an irreversible septicemia develops (courtesy of R. Korbel).

### Color 48.7

The skin has been removed from the abdomen of a three-day-old emu chick to better visualize the infected yolk sac. *E. coli* was recovered from the yolk.

### Color 48.8

**a)** A three-week-old ostrich chick that died following a five-day period of anorexia and progressive weight loss. Volvulus of the small intestines was caused by rotation of the yolk sac. Note the congestion of the yolk sac and distal portion of the small intestines (arrow). The kidneys (k), proventriculus (p) and ventriculus (v) are pale. **b)** A pendulous yolk sac (arrow) caused volvulus of the small intestines in a three-week-old ostrich chick.

### Color 48.9

Infection of the pipping muscle may occur following the insertion of a non-sterile microchip.



48.1a


b



48.2



48.3



48.4



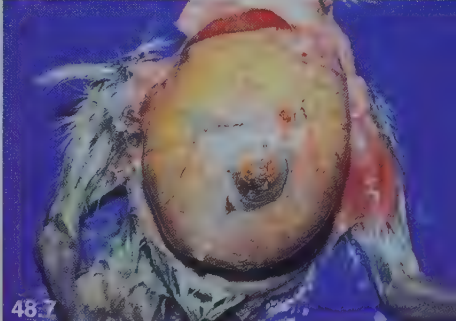
48.5a



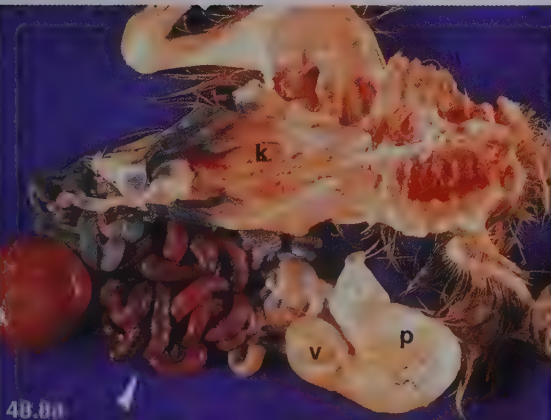
b



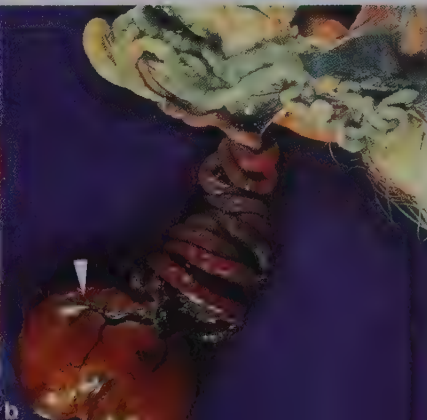
48.6



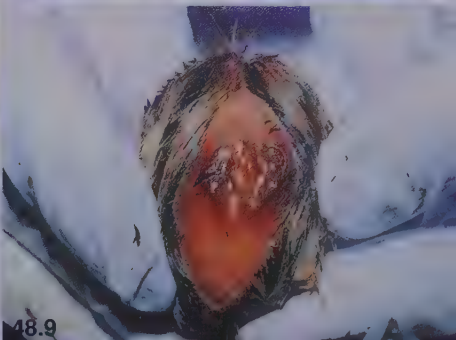48.7



48.8a



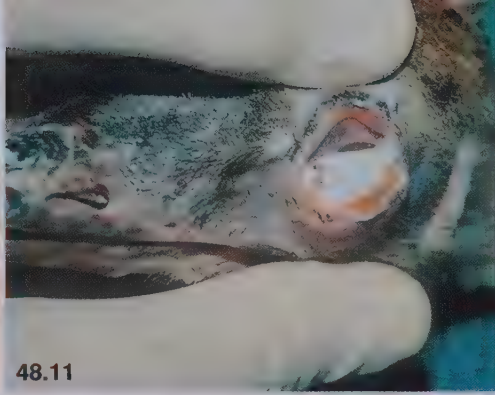b



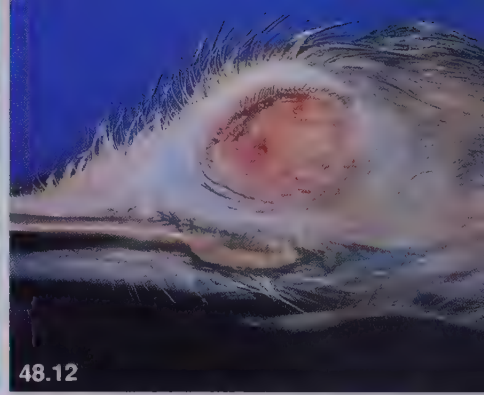
48.9



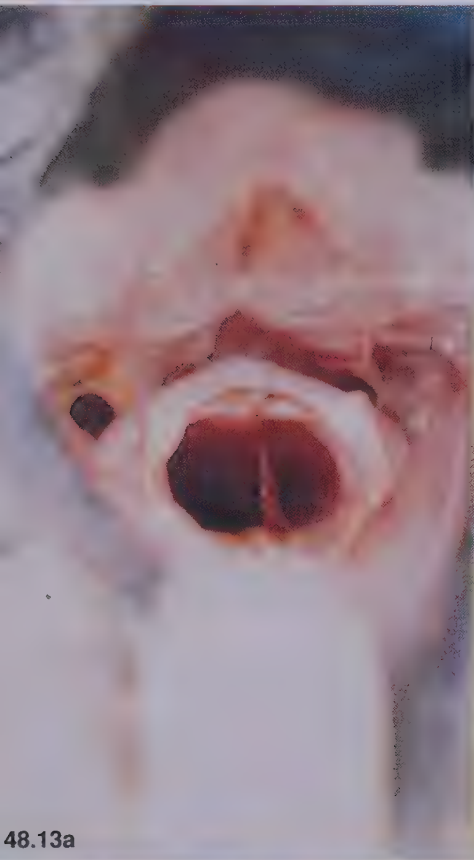48.10



48.11



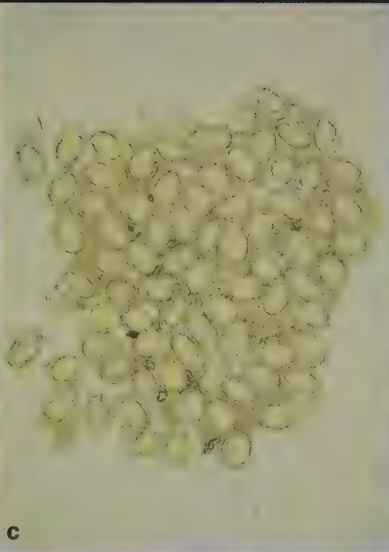
48.12



48.13a



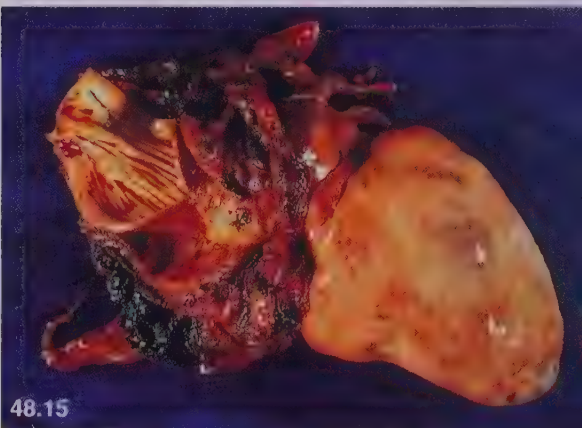
b



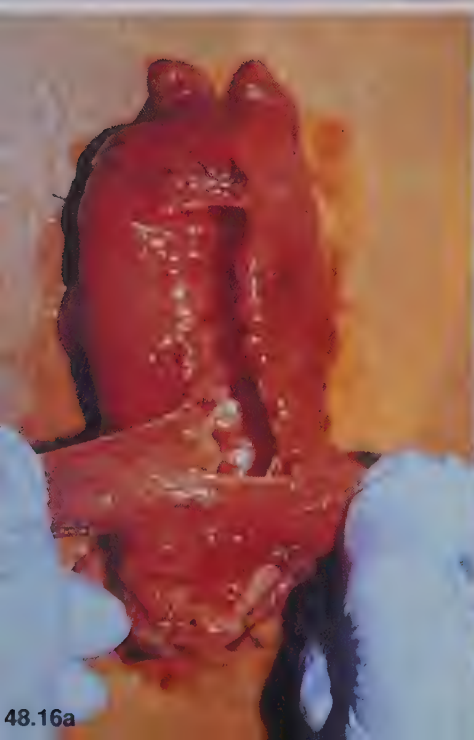c



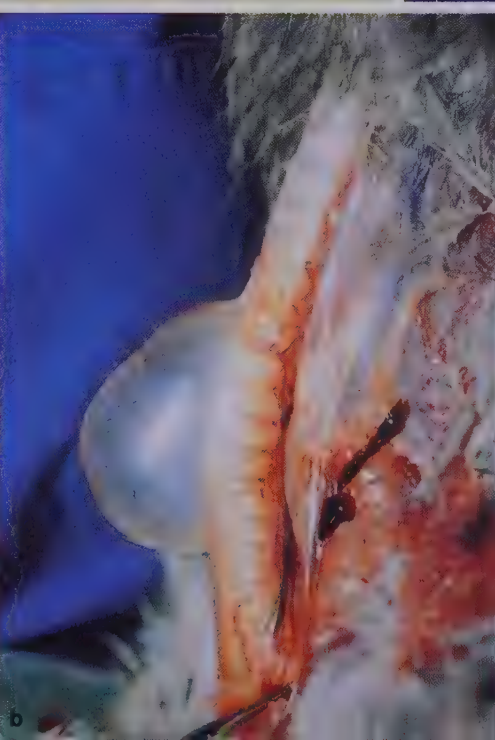48.14



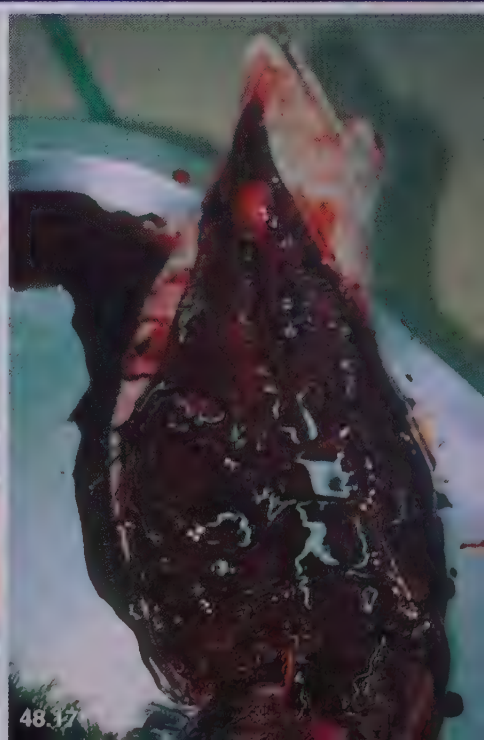
48.15



48.16a



b



48.17

## Ratites

### Color 48.10

Cataract in a yearling ostrich (courtesy of James Stewart).

### Color 48.11

Severe *Pseudomonas* sp. keratitis in a two-month-old ostrich. A fibrino-necrotic plaque is visible over the cornea.

### Color 48.12

Uric acid deposits in the eyelid of a rhea that died from renal failure. Accumulations of uric acid were also noted on the tongue, thoracic and cervical vertebrae, heart, ventriculus, liver, intestines and kidneys.

### Color 48.13

**a)** Rostrocaudal view of the oral cavity of an emu demonstrating hemorrhagic mucus in the trachea. This bird was infected with the tracheal worm *Syngamus trachea*. **b)** Female tracheal worm removed from an emu. **c)** Tracheal worm infections can be diagnosed by demonstrating the eggs in mucus collected from the trachea or pharyngeal area.

### Color 48.14

Difference in quality between the feather of an African black ostrich (above) and a wild-type ostrich is shown (courtesy of James Stewart).

### Color 48.15


Aortic rupture of unknown etiology in a six-month-old female ostrich that died acutely. The site where the aneurysm formed between the intima and media of the base of the heart is clearly visible. A copper deficiency has been discussed as a possible cause of this lesion.

### Color 48.16

**a)** Tracheal diverticulum in a six-month-old emu. **b)** The diverticulum has been inflated. This structure is particularly well developed in adult female emus.

### Color 48.17

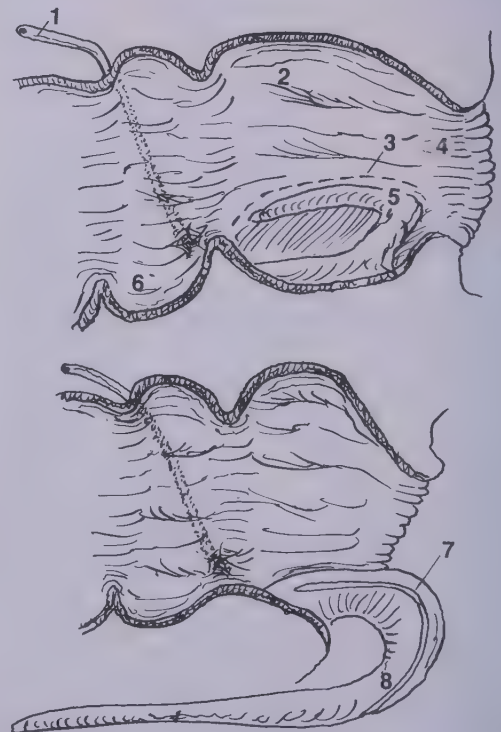
A three-year-old male ostrich bled to death when the client ruptured the carotid artery while using a shepherd's hook to control the bird.



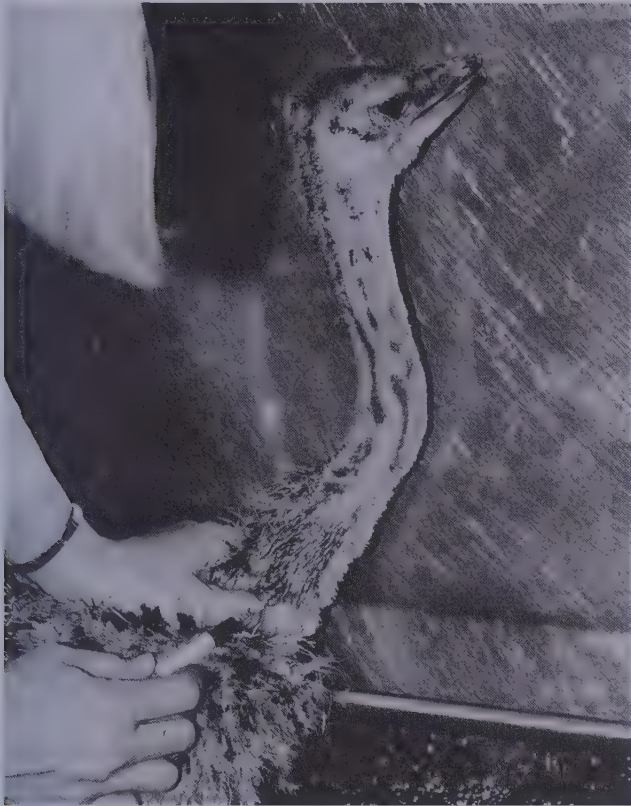**FIG 48.10** a) Erect phallus of a three-month-old ostrich male. The phallus is firm, conical in shape, curves to the left and has a prominent seminal groove. b) The erect clitoris of a three-month-old ostrich hen. The clitoris is soft, small and laterally compressed (courtesy of James Stewart).

is difficult because the skin adheres to the underlying tissues. Subcutaneous medications can be given in the knee web cranial to the thigh.<sup>4</sup>

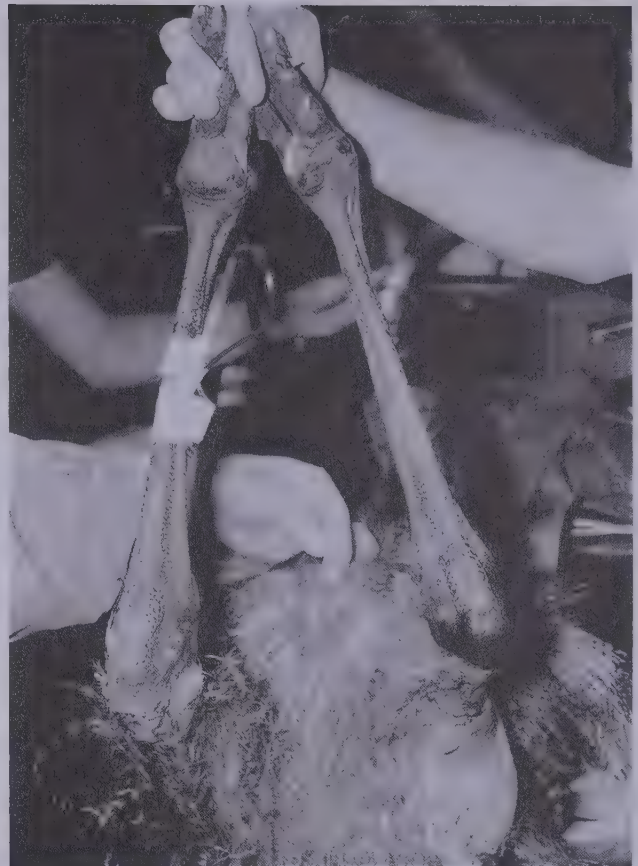The pectoral musculature of ratites is greatly reduced, and the large thigh muscles are frequently selected as a site for intramuscular injections. It has been suggested that this site may be inappropriate for the administration of nephrotoxic or renally excreted drugs because of the renal portal system. However, in one study involving the clearance of aminoglycoside, there was no difference in plasma levels when the drug was given in the posterior or anterior portions of the body.<sup>30</sup> This finding suggests that the renal portal system may not be of importance when considering drug administration in ratites. The epaxial musculature along either side of the spine serves as an alternative site to the thigh muscles for IM injections.



**FIG 48.11** Left lateral view of the cloaca and phallus of a mature male ostrich: 1) vas deferens 2) proctodeum 3) crypt on the floor of the proctodeum 4) vent 5) retracted phallus 6) urodeum 7) dorsal sulcus and 8) erect phallus (modified with permission from Murray Fowler<sup>19</sup>).



**FIG 48.12** The right jugular vein is easily accessible for venipuncture (courtesy of James Stewart).



**FIG 48.13** The medial metatarsal vein is the preferred site for catheterization in ratite chicks (courtesy of Louise Bauck).

## Adult Bird Management

### Identification

It is suggested that all ratites be permanently identified. The importance of properly identifying birds is dramatically illustrated by a case in which an ostrich was identified on a health certificate as an “African black” and was insured for twenty thousand dollars. The bird died, and at necropsy the veterinarian identified the bird as a “blue-necked” ostrich, and the animal was cremated. The insurance company declared that the dead bird was not insured.

The implantation of a microchip provides one fail-safe method of identification. Sterilized microchips can be implanted immediately after hatching in the left side of the pipping muscle approximately two to three centimeters below the ear (Color 48.9). These chips help in the recovery of stolen birds, satisfy most

insurance company requirements for identification and provide unmistakable identification for record keeping purposes.

### Nutrition

Numerous pelleted rations are commercially available for ratites. Most of these are locally produced and are highly variable in content and quality. Information on the specific nutritional requirements of ratites is lacking. In South Africa, range-raised ostriches are fed on alfalfa pastures supplemented with maize. Captive ratites seem to maintain a good state of health and reproduction when fed a diet that contains 16 to 20% protein, 10% fat and 10% fiber. Diets with 18% protein produced the best weight gains in one small nutritional study that compared only the effects of varying levels of protein.<sup>23</sup> The calcium to phosphorus ratio should be about two to one.

Several commercial ratite foods are available with 18 to 23% protein and greater than 10% fiber. The feed-

ing of higher protein diets (27%) to young birds would be expected to induce an accelerated rate of growth and may predispose them to leg deformities. Nutritional deficiencies are unlikely in birds that are fed a pelleted ration supplemented with good quality grazing areas.<sup>31</sup>

The adequacy of the breeder diet is reflected in the eggs produced. Generally speaking, hens deficient in carbohydrates, proteins and fats produce fewer, smaller eggs. Vitamin and trace mineral deficiencies can result in nutrient-deficient eggs. The effects may be graded with the level of the deficiency. Characteristic lesions may be noted at various stages of incubation or several days post-hatch. Gastrointestinal or other systemic disease may affect nutritional uptake and metabolism, resulting in nutrient-deficient eggs.

Hypovitaminosis A has been described in rhea chicks with clinical signs of epiphora, oral abscesses and decreased growth. A goose-stepping gait was thought to have been corrected with supplemental vitamin B<sub>6</sub>.<sup>16</sup>

Thiamine deficiencies are thought to cause star-gazing (Color 48.5), and riboflavin deficiencies may be a cause of curled toe deformities in ratite embryos (Color 48.4) (Hopkins B, unpublished). Pantothenic acid and biotin have been associated with curling of the feathers and hyperkeratosis of the skin, particularly around the mouth, beak, feet and neck (Color 48.25).<sup>44</sup>

In a group of ostrich chicks fed crushed corn, hypovitaminosis E was suspected to have been the cause of muscle degeneration, which was characterized by paresis, poor weight gains and high AST (up to 1600 U/l) and CPK (up to 69,600 U/l) activities.<sup>4</sup> Vitamin E and selenium deficiencies also may occur in birds fed locally produced foods from regions with low levels of selenium in the soil.

Manganese deficiencies have been associated with slipped tendons in gallinaceous birds, but a deficiency of this mineral has not been associated with porosis in ratite chicks. Angular limb deformities are probably multifactorial, with decreased exercise, genetics and diets of high fat and protein all being involved.<sup>44</sup>

### ■ Restraint and Transportation

Ratites are large fractious birds that can easily injure themselves or attendants. Clients and veterinarians

should be aware of the dangers associated with handling ratites and should be well versed in restraint techniques. Male ostriches are particularly aggressive during the breeding season and must be handled with caution. Any handling procedure is best performed in an area with solid walls in which the lights can be dimmed. Many basic procedures can be performed in these confined areas without the need for excessive physical restraint.

The natural defense of ratites is the kick, enhanced by the well developed toenails. Ostriches kick straight forward at chest level to the bird, followed by a downward sweep of the foot. Emus and cassowaries may kick either forward or backward and may incorporate wide lateral swings into the range of motion. All ratites jump with great agility, and when restrained, cassowaries roll onto their backs with their legs flailing.

When physical restraint is necessary, it is best to make slow, methodical movements. Working with untrained birds is an exercise in patience. It is important when handling chicks to use gentle restraint because rough handling can cause fractures, tendon damage and severe bruising. Whenever possible, larger chicks are usually herded rather than carried, but they may also be guided by placing one hand across the sternum and the other below the pelvis.

Most adult ostriches will become tractable when the head is covered with a dark, tight-fitting cloth hood, such as a sweatshirt sleeve (Figure 48.14). The sleeve is placed over the arm, the bird is grasped by the beak and the sleeve is then inverted over the head of the ostrich. The natural curiosity of a captive ostrich is usually sufficient to tempt the bird close enough to the handler to grasp the beak. A long smooth shepherd's hook can also be used to grasp the ostrich around the neck and lower the head, but the handler must be prudent of potential injuries to himself or the bird (Color 48.17).

Ostriches may also be restrained without a hood if one person holds the head and neck horizontal to the ground while a second person provides upward and forward pressure to the pelvis. Grasping ostriches by the wings is a common cause of fractures and paralysis. Emus can be crowded into a corner and restrained by standing straddled over the bird's hips while holding the bird across the sternum with the hands (Figure 48.15).



**FIG 48.14** A sweatshirt sleeve or similar cloth tube can be placed over the head of a ratite to keep it quiet and to facilitate examination or recovery from anesthesia (courtesy of James Stewart).

### Mechanical Restraint

Enclosures designed with catch pens, alley systems and stanchions facilitate the restraint of ratites. Facilities designed for cattle and horses usually include fencing inappropriate for use with ostriches. One side of the standard horse trailer is suitable to accomplish most procedures on an adult ostrich. A stanchion is used in the commercial feather industry to restrain ostriches for the clipping and plucking of feathers and is excellent for veterinary procedures. The stanchion consists of two thigh-high side-bars in the formation of a "V," with a strap to be placed over the shoulders and a bar to be positioned behind the legs and below the pelvis, thus restricting the bird's motion in all directions.

### Chemical Restraint

Anesthetic protocols for the different ratite species are basically similar when adjusted to body size.<sup>31,54</sup> The author's preference for smaller birds (under 20 kg) is face mask induction with four per cent isoflurane, followed by intubation and maintenance at two to three percent levels. The success of any anesthetic



**FIG 48.15** Emus can be restrained by straddling the hips of the bird and wrapping the hands around the sternum (courtesy of James Stewart).

episode can be improved by performing the procedure in a small, quiet, dark room. Injectable agents are adequate for short procedures such as wound repair or casting in large birds. The author's agent of choice is tiletamine-zolazepam administered intravenously at 2-8 mg/kg depending upon the desired duration of anesthesia. Induction time is less than 15 seconds, and cardiac and respiratory functions are well maintained. The duration of anesthesia for a single dose is approximately 20 to 40 minutes, and supplemental doses may be administered as needed.

Alternatively, ketamine hydrochloride may be administered IV at 2-5 mg/kg when used in conjunction with either xylazine at 0.2-0.3 mg/kg or diazepam at 0.2-0.3 mg/kg. Ketamine alone gives unacceptable results. A smoother recovery from injectable agents may be facilitated by the administration of aza-



**FIG 48.16** Isoflurane is the anesthetic of choice for use in ratites. Anesthetized birds can be intubated with standard, cuffed endotracheal tubes that are available for small animals (courtesy of Tom Tully).

paerone IM at 1 to 2 mg/kg following induction, or the administration of diazepam IV at 0.2 to 0.3 mg/kg during recovery. In one study of ostriches, induction with tiletamine/zolazepam at a dose of 4.4 mg/kg IM was found to provide the best induction and recovery.<sup>12</sup>

For surgical anesthesia, large ratites are generally induced with low doses of tiletamine-zolazepam by intravenous administration and maintained on either 2 to 4% halothane or 2 to 4% isoflurane. Mature ostriches can be intubated using 14 to 18 mm cuffed endotracheal tubes (Figure 48.16). Intermittent positive pressure ventilation can be performed with a peak pressure of 15 to 20 cm of H<sub>2</sub>O. The tidal volume of ratites is considered to be 10 to 15 ml/kg. Birds may become apneic immediately after or commonly at 15 to 20 minutes into anesthesia. These birds should be provided IPPV at 6 to 30 breaths per minute until paCO<sub>2</sub> levels have stabilized.

Bradycardia, apnea, hypercapnia, hypocapnia and movement are complications of anesthesia in ratites. Glycopyrrolate (0.011 mg/kg) was effective in reversing bradycardia (<30 bpm) in one bird. Heart rates in young ostriches at rest are normally 100 to 150 bpm and in the adults, 80 bpm.<sup>24</sup> The respiratory rate in a group of anesthetized ostriches was 25 to 40 bpm and the heart rate was 65 to 70 bpm. Mean blood pressure varied from 165 to 220 mm HG. In another group of anesthetized ostriches, the mean blood pressure was 60 to 137 mm Hg.<sup>39</sup>

Ratites can easily injure themselves during the ataxic phase of anesthetic recovery, particularly following injectable agents. Extubation should occur in recovery when the bird is swallowing. Large, shaded areas, padded with mats or straw and clear of objects or walls within reach of the flailing legs can be used for recovery. Alternatively, a bird may be packed in a crate that is heavily padded with straw to restrict extension and flailing of the legs. Because ratites respire with lateral excursions of the chest, the sternal position for recovery is preferred. Small ratites can be recovered by wrapping them in a towel and using manual restraint. Adults should remain hooded with minimal disturbances. When the bird sits sternally with the head held upright, the hood should then be removed.

### Transportation

When considering the transportation of ratites, it should be remembered that these birds are bipedal and have difficulty balancing when provided unstable footing. Excessively large trailers with slippery surfaces have been a leading cause of injury and mortality. Chicks and juveniles may be transported by land or air most safely if confined to small individual crates. Specifications for air shipment of ratites are outlined in the International Air Transportation Association live animal regulations and container requirements. The individual compartment of a standard horse trailer is well suited for the routine transport of one adult ostrich. The compartment should be modified to have solid smooth walls to the floor, and adequate traction can be provided by covering the floor with wet wood shavings or sand. Hauling birds at night tends to keep them calm and reduces the possibility of overheating. Food and water should be offered two to three times per day, but should be removed from the compartment while traveling.

### Ostrich Management

#### Housing

Adult ostriches are maintained in outdoor paddocks.<sup>53</sup> They are tolerant of extremes in weather conditions, faring well even in snow. Birds in southern climates can be maintained outdoors in the win-





**FIG 48.17** Wire (smooth or barbed) should never be used for fencing ratites. This breeding bird became entangled in the wire and died (courtesy of James Stewart).

ter with adequate protection from the wind, but birds in northern areas may require completely enclosed areas to survive long periods of sub-zero temperatures. Ostriches are gregarious in nature, with one male breeding several hens; however, they do have preferences, and incompatible pairs are common when birds are not allowed to select their mates. The breeding group in intensive operations consists of one male and one to three females. Semi-intensive farms utilize large paddocks containing many birds with an excess of hens. Visually separating breeding groups and allowing a hen to select a male may improve reproductive success. Housing trios adjacent to each other may cause males to spend time soliciting attention from females in adjacent enclosures, while neglecting the hens in his pen.

Breeding paddocks in intensive systems are typically one-quarter to one-half acre in size. A paddock with

5,000 square feet would be considered minimum for a pair of adult ostriches. Fencing should be approximately two meters tall, clearly visible to a running bird and designed so that the feet or neck cannot become entangled within the fence. The bottom of the fence can be raised 40 cm from the ground to prevent the bird's legs and feet from becoming entangled.

Stranded wire fence (barbed or smooth) should never be used for ratites (Figure 48.17). Wood corrals, 2 x 4" field fencing, chain-link fence or pipe fencing are all effective. Electric fencing may be necessary to prevent terrestrial predators from entering the compound.

Birds should have a supply of fresh water and dry food at all times. Placing the food and water station in the fence line with a flap to allow access without entering the paddock is the easiest way to maintain ostriches. Ratites readily adapt to the use of automatic water supplies and bin-type feeders. These devices reduce labor and minimize disturbances in the breeding group.

### Breeding Behavior


In general, ostriches reach puberty around two years of age, but are not at full reproductive maturity until four years of age.

Ostriches are long-day breeders, are photoperiod dependent and primarily breed in the summer (Table 48.1). Free-ranging ostrich cocks do not produce sperm in the non-breeding season. With increasing day length, testosterone production increases and secondary sexual characteristics such as reddening of the beak and legs, vocalization and territorial displays (kanteling) begin (Figure 48.18). Sperm production, which is controlled by follicle stimulating hormone, starts at the same time.

### CLINICAL APPLICATIONS

Specific factors that might affect the onset of maturity in ostriches include:

- The "breed" - The smaller African black ostrich matures earlier than the larger North African subspecies ("red-necked").
- The season of hatch - Birds that hatch during a period of increasing day length mature faster than those that hatch during a period of decreasing day length. Throughout its lifetime, a bird hatched early in the year will produce better than a bird hatched late in the year.
- The plane of nutrition
- The environment - The specific effect of temperature on reproductive activity is unknown; however, extremes in temperature may stop production or reduce egg fertility.<sup>27</sup>



**FIG 48.18** Courtship behavior in ostriches. The male (left) drops to his hocks, fans his wings and slaps his head on his back (kanteling). The female (right) is on the ground with the neck extended in a receptive position (courtesy of James Stewart).

The cock displays to the hen during breeding season by dropping to his hocks, fanning his wings and striking the back of his head on either side of his back. In captivity, males frequently display and make a booming noise to any visitor that approaches the enclosure. The hen flutters her wings, drops her head and makes a snapping motion with her beak. She will drop to the ground with her head extended. The male mounts from the left placing his right foot on the hen's back (Figure 48.18). He drops to his hocks and intromission occurs. During copulation, the male will strike his back with his head. When ejaculation occurs, the male makes a guttural sound.<sup>27</sup>

In the United States, the breeding season varies from north to south. Birds in the northern US have a laying season from May to September, while birds in the southern US may produce all year. The nest consists of a shallow depression in the ground that is formed and protected by the male. Ostriches and rheas usually lay eggs in the afternoon or evening while emus generally lay at night. If left to parental care, the eggs are incubated by the male at night and the female during the day. In free-ranging groups, the dominant hen will incubate the eggs during the day. The dominant hen recognizes her eggs, and if the nest is overcrowded (20 to 25 eggs), the hen will remove the eggs laid by rival females. Nondominant hens may lay in several nests and be bred by several males. Both adults brood the chicks.<sup>27</sup>

Ostrich hens are indeterminate layers and if the eggs are removed, a hen may lay an egg every other day throughout the breeding season. Free-ranging hens

may have a normal clutch size of 15 to 25 eggs. Forty is the average for hens in captivity; however, some birds may produce 70 to 100 eggs per year.

Both sexes may have periods of reproductive quiescence within the breeding season, each lasting three or four weeks. During this time the female stops laying and the male "goes out of color" (ie, the bright red coloration of the face and tarsal scutes fades).

Breeding males may become territorial and aggressive, and stressful social interactions within and between breeding groups can decrease reproductive behavior and egg fertility. These problems can best be prevented by having visual barriers between breeding groups. Fertility in the male may decrease with prolonged breeding periods, and separating the breeding adults for several weeks may improve egg fertility.<sup>31</sup>

## Emu

### Breeding Behavior

Emus are managed in a manner similar to ostriches, but with proportionately smaller facilities. During

**TABLE 48.1** Factors Affecting Ostrich Reproduction<sup>27</sup>

<b>Behavior:</b>	Most of the breeding birds available in the US are from free-ranging stock and have not been genetically selected to adapt to captive conditions. Some individual birds adapt well to enclosed spaces and varying terrain while others do not.
<b>Genetics:</b>	Highly productive hens are more likely to produce daughters that also are extremely productive.
<b>Environment:</b>	Severe weather fluctuations, looming predators and objects overhead have been shown to decrease productivity.
<b>Age:</b>	Ostriches sexually mature two to three years after hatch, and production improves as the bird ages. The most productive age for ostriches has not been established.
<b>Nutrition:</b>	Obesity is one of the biggest causes of decreased production in birds. Although nutritional deficiencies can decrease productivity, nutritional excesses are just as detrimental (Color 48.26).
<b>Season:</b>	Production is best in the early and middle portion of the breeding season.

breeding, the female sits on the ground with her cloaca everted. The male drops to his hocks behind her and intromission occurs. The male pecks the hen's back and makes guttural noises during ejaculation. Breeding occurs most often in the morning and evening hours.<sup>27</sup> Adults are typically maintained as pairs, but colony breeding is effective. Eggs are laid in grass or straw and are partially hidden. The male conducts the incubation and chick-raising. The male may not leave the nest during the entire incubation period, leading to a substantial degree of weight loss.

Emus are short-day breeders, with a breeding season that lasts from October to March in the United States. Free-ranging emus are gregarious during the non-breeding season, but these birds tend to form pairs or trios during the breeding season. Free-ranging birds may begin egg laying at two to three years of age. Captive females may require one to two extra years to reach sexual maturity.

## Rhea

### Breeding Behavior

The male rhea performs the courtship displays, builds the nest, incubates the eggs and rears the young. The male attracts the apparently disinterested females with wing-spreading and head-swaying displays. Several females will lay eggs near a nest established by the male. The male collects these eggs for about one week and then initiates incubation of all the eggs at one time so that the hatch is synchronized.<sup>27</sup>

## Medical Disorders and Therapies

Among the ratites, ostrich diseases are best documented because of the development of a breeder industry (Table 48.2). When viewed from the perspective of disease, ostriches are little more than giant chickens. Most medical disorders of ratites have models within the commercial poultry industry. The important differences lie with the susceptibilities and relative prevalence of these diseases. Many of the infectious diseases are also shared by psittacines, waterfowl and other common companion and aviary birds. Sound management dictates that ratites should not be reared in close proximity to other types of birds.

TABLE 48.2 Infectious Diseases Reported in Ratites

	Ostrich	Rhea	Emu	Cass-owary
<b>Viral</b>				
Coronavirus	x			
Alphavirus			x	
Avipoxvirus	x	x	x	x
Influenzavirus type A	x			
Paramyxovirus type 1	x	x	x	x
<b>Bacterial</b>				
<i>Bacillus anthracis</i>	x			
<i>Bordetella avium</i>	x	x		
<i>Clostridium botulinum</i>	x			
<i>Campylobacter jejuni</i>	x	x		
<i>E. coli</i>	x	x	x	x
<i>Edwardsiella tarda</i>	x			
<i>Pasteurella multocida</i>	x			
<i>Haemophilus paragallinarum</i>	x	x		
<i>Clostridium perfringens type C</i>	x	x	x	
<i>Clostridium colinum</i>	x			
<i>Salmonella</i> spp.	x	x	x	x
<i>Treponema</i> sp.		x		
<b>Mycobacterial</b>				
<i>Mycobacterium avium</i>	x	x	x	
<b>Mycoplasma</b>				
<i>Mycoplasma</i> sp.	x			
<i>Mycoplasma synoviae</i>	x			
<i>Mycoplasma gallisepticum</i>	x			
<i>Mycoplasma meleagridis</i>	x			
<b>Chlamydial</b>				
<i>Chlamydia psittaci</i>	x		x	
<b>Mycotic</b>				
<i>Aspergillus fumigatus</i>	x	x	x	
<i>Aspergillus flavus</i>	x		x	
<i>Aspergillus niger</i>	x			
<i>Candida albicans</i>	x	x	x	
<i>Rhizopus oryzae</i>	x			

Due to the lack of research targeted at accurate identification of organisms that affect ratites, the list provided in Table 48.2 will certainly prove to be incomplete. There are many disease syndromes that epidemiologically suggest an infectious etiology for which a specific pathogen has not been described. Waste management, sanitation and human movement patterns within the flock are essential in preventing the transmission of infectious agents from paddock to paddock or from farm to farm. Ratite clinicians must be acutely aware of the role they can play in the transmission of disease through improper

hygienic practices. New birds should be quarantined in an area separated from the remainder of the group for at least one month. During this period, the birds should receive a thorough physical examination and should be treated for parasites.

### Reproductive Abnormalities

On the average, 50% of the ratite eggs produced annually in the United States are infertile. This represents a considerable economic loss given current market values for fertile eggs. Fertilization of the egg must occur during the first 15 minutes after ovulation while the egg is in the infundibulum.<sup>27</sup> Ratite hens are subject to all the reproductive disorders seen in other birds including oviduct infections, egg retention, uterine prolapse, internal ovulation and egg-related peritonitis. The anatomy, physiology and pathogenesis of disease are comparable to the psittacine model (see Chapter 29). In contrast to the smaller avian species, ratites may be afflicted with severe reproductive disorders for months or even years, but remain otherwise healthy and exhibit no outward signs of disease. Excessive ventrodorsal movement of the cloaca when a hen is jogging may be an early sign of egg-related problems.

A diagnosis of reproductive tract disease is based upon the reproductive history, physical examination (including cloacal palpation and eversion of the phallus), and diagnostic tests including hematology and serum biochemistry, oviduct cultures, abdominocentesis, radiology and ultrasonography.

Prolapse of the phallus has been described in male ostriches. A partial prolapse may occur in reproductively active males with no adverse effects. The precise etiology is unknown, but debilitation toward the end of the breeding season and extreme weather fluctuations have been suggested as causes. Frostbite or necrotizing dermatitis are frequent sequela to a prolapse. Full prolapse requires replacement of the phallus into the cloaca, with or without a purse-string suture, and administration of nonsteroidal anti-inflammatory agents. If the phallus is traumatized, daily washes with a disinfectant solution and administration of systemic antibiotics may be indicated. The prognosis is good if the damage is not too extreme.

Intersex appears to be common in the ostrich. The black pigment of the male's feathers is due to a lack of estrogen. A mature black bird that sexes cloacally as a hen will not reproduce and may have inactive

ovaries, testes or both. Many young hens may be very dark brown or even have a few black feathers, but become gray with maturity.

Prolapse of the vagina can occur without egg laying and may be seen in hens less than one year of age. These prolapses are thought to be caused by unseasonably cold temperatures. Replacement and application of a retention suture are usually corrective.<sup>27</sup>

Peritoneal hernias occur in the caudal abdominal cavity, allowing the intestines and uterus to prolapse into the pericloacal region. Affected hens appear to have a large pericloacal swelling. Ultrasound is diagnostic. Surgical repair is required.

*E. coli*, *Pseudomonas* spp., *Acinetobacter* spp. and other gram-negative bacteria are common causes of oviduct infections in ostriches. Affected hens generally present with a history of erratic egg production, cessation of egg production or malformed or odoriferous eggs. On physical examination, the temperature and respiration are variable. The hen may have a discharge below the cloaca and may have a peculiar odor. Affected hens often have white blood counts ranging from 20,000 to 100,000 (pronounced heterophilia in acute cases or lymphocytosis in chronic cases); however, the severity of the infection varies with the etiologic agent. In mild cases, only the uterus or shell gland (metritis) may be affected, and in these hens clinical signs range from the formation of abnormal shells to the cessation of breeding.

Salpingitis or peritonitis may also occur with chronic infections or those that occur secondary to septicemia.<sup>27</sup> Therapy for metritis should include appropriate antimicrobial therapy, multiple vitamin and calcium injections. Surgical (laparotomy) or nonsurgical (vaginal) flushing of the oviduct can be used to remove accumulated debris.

*Mycoplasma* spp. and paramyxovirus have been isolated from the reproductive tracts of ratites but their clinical importance is unknown.<sup>27</sup> Papillomas have been described in the reproductive tract of both cocks and hens.

Egg binding may occur in ratite hens and is thought to be caused by genetic factors, malnutrition, cold weather or lack of exercise. Many affected hens are asymptomatic, while others may present with a history of tenesmus or with a vaginal prolapse. An impacted egg may be palpable in the caudal abdomen. Radiology or ultrasound may be required for diagnosis. Medical treatment consists of increasing the

bird's ambient temperature along with the injection of multivitamins, calcium and oxytocin (prostaglandin may be superior, see Chapter 29). Ovocentesis procedures that have been described for correcting egg binding in other avian species are dangerous in the ostrich because of the likelihood of fractured egg shell damaging the oviduct. Impacted eggs should be removed surgically.

None of the methods traditionally used to artificially collect semen from birds is effective in ostriches because of their physical size, demeanor and lack of sexual imprinting response. Ostrich semen has been collected by means of forced massage and voluntary response; however, the semen collected is usually contaminated with urine, making assessment of concentration, volume and pH unreliable.<sup>27</sup>

Emu semen can be easily collected by voluntary ejaculation because the birds do sexually imprint on humans. Emu ejaculation volume averages 1.2 milliliters with 4.4 billion sperm per milliliter. Average pH is 7.32. Beltsville chicken semen extender in a 1:1 dilution has been found to be an appropriate diluent in some birds.<sup>27</sup>

### Gastrointestinal Abnormalities

Ingestion of foreign bodies is a common problem in ratites. These birds are likely to swallow anything that fits into their mouths, and their keen eyesight and curiosity all but ensure that they will find many unusual items in their pen. Stones, sand, hardware and long-stemmed grasses are common offenders (Figure 48.19). The consumption of materials that induce impactions may be caused by primary enteric disease, inadequate feed availability, nutritional inadequacies and movement to a new environment with a different substrate. Ingestion of foreign bodies can be reduced by making certain that pastures and paddocks are covered with grass and do not contain abundant or clearly visible rocks or sand (Color 48.30). Decreasing stress by slowly introducing birds to a new area also may reduce the consumption of foreign bodies.

Impactions may be acute or chronic, primary or secondary. The most common clinical presentation includes lethargy accompanied by small, firm, fecal balls and a distended abdomen. Occasionally, affected birds may appear lame or be unwilling to rise due to weakness or pain. A cloacal prolapse may occur in chicks with proventricular impaction. Eighty-five percent of impactions occur in birds under six or



**FIG 48.19** Sand impaction of the proventriculus (p) and ventriculus (v) in an ostrich chick. Note that the proventriculus in ostriches extends caudal to the ventriculus. Also visible are the liver (l) and yolk sac (y) (courtesy of James Stewart).

seven months of age, with 10 to 12% occurring in birds six to twelve months of age and 3 to 5% occurring in adults.<sup>61</sup>

Ingested foreign objects initially settle in the well developed proventriculus and obstruct the flow of ingesta or act as valves by blocking outflow into the ventriculus. In chronic cases, the blockage may also involve the ventriculus. Ventricular ulcers often develop from the trauma of constant grinding against an immobile mass.<sup>22</sup> Chronic and severe distension of the proventriculus may cause a permanent loss of muscle tone. These irreparable changes can be prevented through the early diagnosis and surgical correction of gastric impactions.

An impacted proventriculus can frequently be palpated on the left side of the abdomen by identifying the caudal and dorsal extremities of this organ. Impactions with rocks or sand can best be detected by

palpating caudal to the sternum. Impactions caused by grasses and leaves may be more difficult to palpate.<sup>22</sup> Radiography can be used to document the presence of foreign bodies and an enlarged stomach. Ultrasound and gastroscopy may be other effective diagnostic techniques.

Psyllium administered by stomach tube may be effective in resolving mild cases of gastric distension, but true impactions can be resolved only by surgical removal of the foreign material. The proventriculus of the ostrich lies caudal and to the left of the ventriculus, and the surgical procedure is a slight variation of that used in psittacines (see Chapter 41). The proventriculus may be approached via either a midline or left paramedian incision that extends caudally from the caudal margin of the ventriculus.<sup>28,52</sup> A 15 cm skin incision is made caudal to the end of the sternum just to the left of midline, and the peritoneum is incised to expose the proventriculus. Allis tissue forceps or stay sutures can be used to manipulate the proventriculus. The proventriculus is temporarily sutured to the abdominal wall to minimize contamination of the coelomic cavity with ingesta. The proventriculus is then incised and the contents are removed. Closure is in two layers with a simple continuous primary suture pattern.

Recovery from proventriculotomy is usually uneventful when the impaction is detected early. Chronic impactions may be accompanied by gastric atony, ulcers and candidiasis that require additional therapy. Birds can be offered alfalfa pellets and corn as soon as they are fully recovered from anesthesia.<sup>28</sup>

Many ingested objects will penetrate the wall of the ventriculus or proventriculus causing peritonitis (Color 48.29). The diagnostic procedures are the same as those used for gastric impaction. A proventriculotomy to remove the foreign body and surgical removal of necrotic peritoneum is indicated. Other common digestive disorders include cloacal prolapse and intussusception. Cloacal prolapse may be associated with diarrhea, or more frequently, with tenesmus due to constipation. Treatment of the prolapse is similar to methods used in other birds, but the initiating cause must be addressed to prevent recurrence (see Chapter 41). Intussusception is caused by hypermotility and gastrointestinal tract irritation and is often the result of an abrupt dietary change, especially when the new diet is higher in fiber.

Any number of ingested toxins can cause enteritis. Cantharidin, for example, is a toxin produced by the Three-striped Beetle, which swarms to feed on Mesquite trees and alfalfa hay. Mortality levels of 25% were reported in a group of emus that consumed these beetles that were attracted to a barn light.<sup>61</sup>

Torsion of the large bowel occurs sporadically. The etiology is unknown, but it is speculated that an abrupt change in feed may be an inciting factor. Clinically, these birds are dehydrated, depressed and produce a scant diarrhea. Diagnosis is confirmed through an exploratory laparotomy. Intestinal anastomosis may be effective in resolving mild cases that do not involve an extensive amount of the gastrointestinal tract.<sup>61</sup>

Porphyryns, a breakdown product of chlorophyll, are sometimes seen in the urates, giving them a red or orange coloration. Clients often mistake this substance for blood. This porphyruria is routinely noted following the ingestion of fresh green vegetation, and becomes more prominent during colder weather when water intake reduction makes the urine more concentrated.

## Fractures

Leg fractures are common in ratites, and successful repair is difficult in these large, fractious, easily stressed, bipedal birds that must be able to ambulate postoperatively.<sup>18,35</sup> Femoral and proximal tibiotarsal fractures in ostriches frequently result in internal exsanguination. Tarsometatarsal fractures are usually open and infected. Prolonged recumbency results in muscle necrosis and tendon contraction.

The long-term use of slings is unsuccessful with ostriches, but emus tolerate them well. Tibiotarsal fractures in small birds under 15 kg are best repaired with a through-and-through, six-pin, modified external fixation device (see Chapter 42). Plates may be used in larger birds if bone quality is normal (Figure 48.20). Fractures of the phalanges, fractures of the distal metaphysis of the tarsometatarsus and luxations of the metatarsal-phalangeal or interphalangeal joints can be stabilized with fiberglass casts, to which most ratites readily adapt.

Wing fractures in ostriches frequently occur secondary to improper restraint. These may be resolved by placing the wing in a normal anatomic position and taping it to the body for six weeks; however, intramedullary pinning usually produces more satisfactory



**FIG 48.20** A bone plate was used to stabilize a dome osteotomy site in an emu with a valgus deformity of the tibiotarsal bone. Fractures of the leg are relatively easy to repair surgically, but are rarely successful long-term because of problems in managing these large, fractious, bipedal patients (courtesy of Louise Bauck).

results. The author prefers a closed reduction and fixation technique. A small diameter pin may enter the distal caudal surface of the humeral shaft and be advanced through the fracture site into the proximal fragment. Alternatively, the pin may enter the proximal fragment at the fracture site, be advanced proximally out the deltoid crest and then retrograded into the distal fragment. The wing is then taped to the body for a period of six weeks to provide rotational stability to the fracture site.

### ■ Ruptured Aorta

Ostriches are prone to spontaneous rupture of the aorta (Color 48.15). These are most often located at the aortic arch, but ruptures in the caudal aorta have also been described. Surprisingly, this condition is

seen with some frequency but the cause is unknown. Copper deficiencies have been implicated in other species. Overweight yearlings that are subjected to physical stress are most commonly affected.

### ■ Degenerative Myopathy

A large percentage of the young ostriches, rheas and emus submitted for necropsy have evidence of degenerative myopathy, with the majority of affected birds being less than six months of age.<sup>47</sup> It should be noted that myocyte degeneration appears the same histologically, regardless of the cause. In birds, several etiologies for degenerative myopathy have been reported, including capture myopathy, selenium or vitamin E deficiency, furazolidone and ionophore toxicity.<sup>33</sup> Clinical signs of degenerative myopathy that have been described in ratites include depression, reluctance to rise or move, and a rapid progression to death (two to five days). White foci and streaks in the myocardium and muscles of the hind limbs and myocyte degeneration with infiltration of macrophages and early calcification may be noted in birds that die several days after transport.<sup>47</sup>

Furazolidone is a nitrofurantoin antibiotic commonly used in the poultry industry. This compound is premixed in some chick starter feeds. Young turkey poults appear particularly susceptible to intoxication. Ionophore coccidiostats, such as monensin, lasalocid and salinomycin, are frequently added to chick starter feeds. These compounds may be contributing factors in the development of degenerative myopathy, and ratite producers should avoid the use of turkey or chick starter feeds that contain furazolidone and ionophores.

In the southern United States, pastures may contain the shrubs or trees of coffee senna (*Cassia occidentalis* or *Cassia obtusifolia*). In ruminants, ingestion of these beans may cause diarrhea, weakness, gait abnormalities, recumbency and muscular lesions consistent with degenerative myopathy. *Cassia* spp. intoxication has not been reported in ratites, but exposure to this toxic plant should be considered in cases of acute myocyte degeneration.<sup>47</sup>

Some authors believe that capture myopathy, which has been described in ratites with some frequency, is simply the acute manifestation of a chronic subclinical deficiency of selenium or vitamin E.<sup>13</sup> Degenerative myopathy appears to be primarily a disease of young ratites and higher levels of vitamin E may be required for growth. Two rheas with limb abnormali-

ties had a mean plasma vitamin E level of 1.34 mcg/ml, compared with a level of 11.5 mcg/ml in apparently healthy rheas.<sup>13</sup> The mean serum levels of vitamin E in 23 ostriches was 2.1 mcg/ml, and in 23 emus was found to be 2.39 mcg/ml.<sup>32</sup> Circulating vitamin E levels in five rheas with no suspected deficiency ranged from 9.0 to 14.5 mcg/ml (mean of 11.60 mcg/ml).<sup>13</sup> Additional work is required to determine whether there is an age-related difference in serum vitamin E levels.

Normal liver selenium levels are not available for ratites but levels below 0.25 ppm are considered deficient in poultry, and levels below 0.35 ppm are considered marginally deficient. Adequate liver selenium levels in poultry range from 0.35 to 1.00 ppm wet weight.<sup>46</sup> Liver selenium levels ranged from 0.176 ppm to 0.986 ppm and liver vitamin E levels ranged from 0.69 mcg/gm to 9.10 mcg/gm in a group of ratite neonates with clinical or histologic lesions suggestive of degenerative myopathy.<sup>47</sup>

Additional investigations to determine the normal serum and organ levels of selenium and vitamin E and their correlation with degenerative myopathy, diet and health are necessary. Studies in horses with degenerative myopathy suggest that skeletal muscle and adipose tissue may be a better sample for determining vitamin E levels than liver.<sup>47</sup>

### Therapy and Prevention

Treatment with vitamin E followed by immediate correction of the diet is the recommended therapy and is generally effective in early cases.<sup>62</sup> One author has suggested the parenteral administration of 3.0 mg of vitamin E and 0.06 mg of selenium/kg of body weight at two days of age, then weekly thereafter for a total of three injections.<sup>43</sup>

It is probably safer to supplement a bird with vitamin E rather than selenium. The latter has a low therapeutic index and can readily reach a toxic level. A chick with clinical signs suggestive of degenerative myopathy that was treated with this regime died despite therapy and had histologic lesions suggestive of the syndrome. Liver selenium levels in this bird were 3.738 ppm. The toxic liver selenium level in poultry is considered 4.00 ppm wet weight.<sup>46</sup>

A safer treatment regimen may be to use injectable vitamin E at a dose of 5.0 mg/kg IM every other day until clinical signs resolve. Adding oral formulations of vitamin E to the drinking water or the feed (100 IU/kg of feed) can be used for maintenance therapy. This treatment regime was successful in stopping

morbidity and mortality in a flock of emu chicks experiencing degenerative myopathy.<sup>47</sup>

### Neoplasms

Neoplasias have been reported in all ratites with none of particular prevalence. Lymphoid tumors have been described in ratites, and their similarity to tumors caused by leukosis virus in poultry warrants further investigation.

Lymphoma was diagnosed in a three-year-old female red-necked ostrich with a history of weight loss, mild bilateral conjunctivitis and a bright green mucoid diarrhea. On palpation, the liver was enlarged with rounded edges, and a bilobed mass was detected in the thoracic inlet. Abdominocentesis revealed a small amount of straw-colored, cloudy fluid with changes suggestive of chronic active hepatitis. Ultrasonography of the abdomen revealed an enlarged oviduct and multiple nodules within the liver. Abnormal clinical pathology results included a marked leukocytosis (160,000), lymphocytosis (95%), hyperproteinemia (6.9 g/dl), anemia (26%), hypoglycemia (102 g/dl), hypergammaglobulinemia and elevated AST (450 U/l) and CPK (6286 U/l) activities.<sup>59</sup>

### Viral Disease

There has been little definitive work completed on viral diseases in ratites; consequently, specific diagnostic tests as well as vaccines are currently unavailable. The transmission of viruses from paddock to paddock or from farm to farm should be prevented through good sanitation practices and by not allowing visitors on the farm. Optimum nutrition, environmental conditions and reduced stress will ensure that a bird has an adequate immune system to resist disease.

Newcastle disease was the only disease of viral etiology reported in the ostrich prior to 1987. Recent international interest in ostrich production, particularly in the United States and Israel, has prompted further viral investigations. Numerous viruses have been detected in ratites by virus isolation or electron microscopy, but the clinical relevance of most of these findings is uncertain. Newcastle disease virus,<sup>49</sup> coronavirus, reovirus, influenza virus and togavirus have been associated with specific diseases.<sup>21</sup>

Coronaviral particles were reported in the small intestines of an 18-day-old ostrich chick that died following a one-week history of anorexia, lethargy, weak-



ness and diarrhea. Lesions included dilation of the proventriculus, nutritional osteodystrophy and degenerative myopathy.<sup>21</sup>

Avian influenza was associated with high levels of mortality among ostriches in South Africa. Clinical signs in affected birds included respiratory signs, conjunctivitis, green discoloration of the urine and death. Although ostriches up to 14 months of age have been shown to be affected, morbidity is greatest in chicks under six months of age. Mortality may reach 80% in hatchlings and is complicated by secondary bacterial and nutritional problems. Characteristic postmortem findings include fibrinous air sacculitis, mucoid sinusitis, multifocal hepatic necrosis, splenomegaly and nephritis.

Fowlpox infections are well documented in ostriches.<sup>45</sup> This disease presents primarily as the dry form, although diphtheritic lesions may also occur. Vesicles that turn to encrustations form along the eyelids, ear openings, beak, neck and legs. Morbidity may be high but mortality is low. A commercial fowlpox vaccine administered at 10 to 14 days of age appears to provide some protection.

Eastern equine encephalomyelitis virus has been associated with high mortality (14 of 23 birds in one outbreak) among flocks of emus in the southeastern United States.<sup>57</sup> Clinical signs include profuse hemorrhagic diarrhea, depression, ataxia and death. Terminally, affected birds may become recumbent and develop hemorrhagic hyperemesis. Paired serum samples can be used to document an increase in antibodies indicating an active infection. Some infected birds will respond to supportive care.<sup>57</sup>

An inactivated equine vaccine is apparently effective in preventing the disease in emus. The initial vaccination is given at three months of age followed by boosters at six-month intervals. Written consent from the client and clearance from the insurance carrier should be obtained before the extra-label use of this vaccine is initiated.<sup>57</sup>

### ■ Bacterial Disease

Bacterial infections in ratites are similar to those described in other birds and may be associated with conjunctivitis, sinusitis, pneumonia and air sacculitis, gastroenteritis, omphalitis and septicemia. Young chicks are most susceptible, and the diagnostic techniques and treatments are comparable to those of other avian species. Although the normal intestinal

flora for ratites has not been established, the birds are terrestrial; thus, ample gram-negative bacteria would be expected in the healthiest of individuals.

Common pathogens include *Pseudomonas*, *Klebsiella*, *Proteus*, *Salmonella* and *Campylobacter* spp. (see Color 24). *E. coli* can be a pathogen, but it is also a normal component of the ratite intestinal flora, and is frequently misrepresented as the cause of mortality in ostrich chicks (Color 48.21). Clostridial enteritis is a common disorder in ratites of all ages and is often associated with the excessive consumption of wet soil (Colors 48.18, 48.19). Botulism, clinically characterized by paralysis and death, has historically been a significant industry problem in adult ostriches in South Africa.

Tuberculosis is a common finding in adult ostriches. Affected birds develop a chronic wasting syndrome with visceral tubercles that can be detected by exploratory laparotomy. *Salmonella* outbreaks have been described in three- to six-week-old birds presented with acute weight loss, lethargy and bilaterally symmetrical distal limb edema. The total serum protein in affected chicks was less than 1 g/dl. Diarrhea was present in chronic cases but did not occur in peracute infections that resulted in rapid death.<sup>61</sup> *Staphylococcus* sp. is frequently associated with omphalitis and septic arthritis.

Ostriches are the only birds susceptible to anthrax, and the symptoms and diagnostic methods are identical to those for mammalian hoof-stock. Commercial anthrax vaccines are safe and effective in ostriches, following standard recommendations for hoof-stock. The client and insurance company should provide written consent before the extra-label use of this vaccine.

### ■ Mycotic Disease

In South Africa, aspergillosis causes the condemnation of up to ten per cent of inspected ostrich carcasses. Granulomatous nodules are most frequently distributed through the parenchyma of the lung, and only occasionally in the air sacs (see Chapter 22). Infections in older birds are enhanced by the inhalation of dust from dry feeds and soil. Outbreaks in chicks are associated with prolonged antibiotic therapy or inadequate hatcher and brooder hygiene.

If they occur, clinical signs include dyspnea, outstretched wings, exercise intolerance, anorexia and weight loss. Heterophilia is a common clinicopa-

## Ratites

### Color 48.18

Glandular portion of the proventriculus in a twenty-three-month-old ostrich with a *Clostridium perfringens* gastroenteritis. Note the congestion and hemorrhage in the mucosa of the proventriculus.

### Color 48.19

**a)** Normal (left) and diseased leg from a six-month-old emu with *Clostridium shovaei* (black leg). **b)** Note the cavitation, hemorrhage and necrosis of the muscle.

### Color 48.20

Stifle and tibia of a 20- to 22-month-old ostrich with severe hypoproteinemia. The white discoloration of the skin is caused by subcutaneous edema.

### Color 48.21

*E. coli* infection in the stifle joint of a three-week-old ostrich chick. Note the white, coagulated exudate in the synovium of the joint. The infection can be seen extending into the muscle planes.

### Color 48.22

Exuberant granulation tissue on the proximal metatarsus of an ostrich that was chronically lame and spent most of its time in sternal recumbency.

### Color 48.23

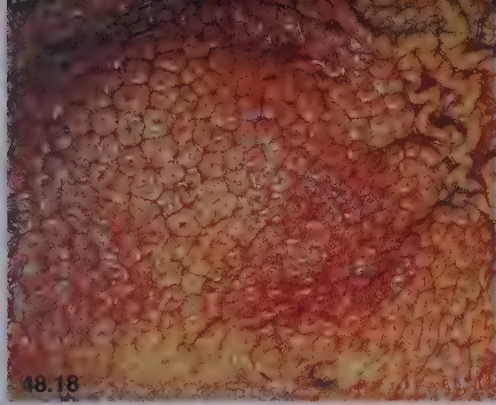Rotational deformity of the left tibiotarsal bone in a two-week-old emu. The distal tibiotarsus has rotated 180 degrees causing the plantar surface of the left foot to be oriented cranially. The rotation occurred over a six-day period.

### Color 48.24

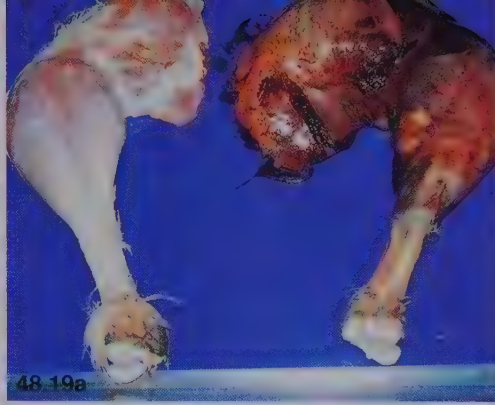Three-month-old ostrich with a rotated toe. The affected digit was also infected with a mixture of gram-negative bacteria. Note the proliferation of the synovial membrane and ulceration of the junction of P1 and P2. These changes are characteristic of chronic bacterial synovitis and arthritis.

### Color 48.25

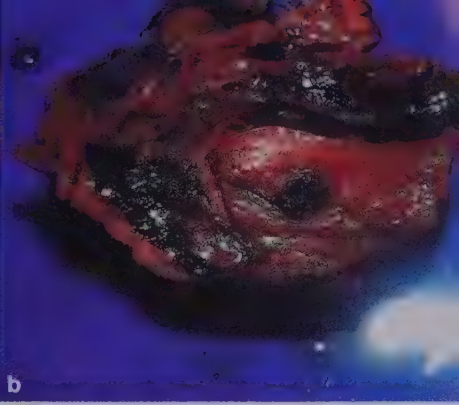
Hyperkeratic lesions of the skin that are suggestive of pantothenic acid and biotin deficiencies are common in two- to six-month-old ostriches. **a)** Hyperkeratosis of the eyelids and cracking of the lower beak. **b)** Bilateral cracking of the skin at the commissures of the beak. **c)** Severe hyperkeratosis and cracking of the plantar foot surfaces. **d)** Hyperkeratosis of the skin on the distal third of the neck.




48.18



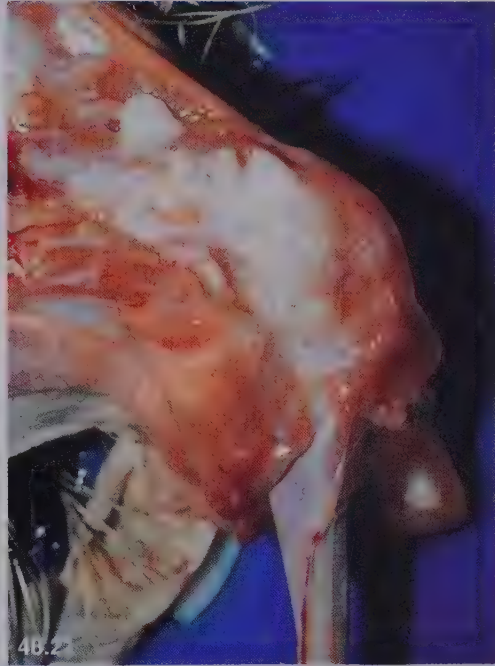48.19a



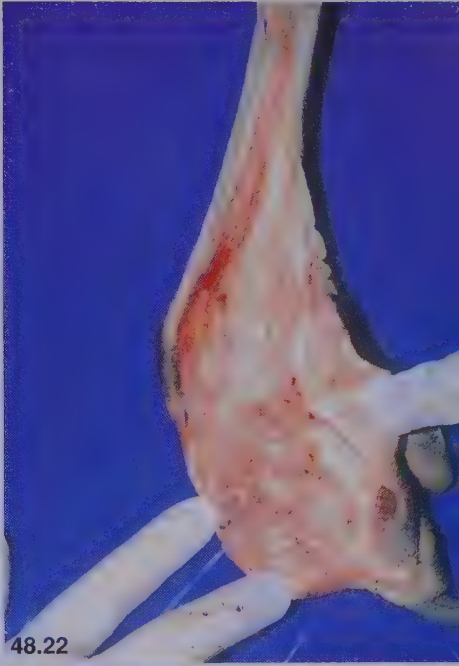
b




48.20



48.21



48.22



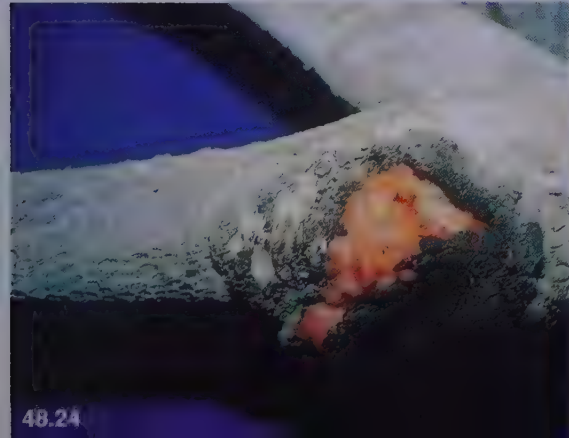48.23



a




b



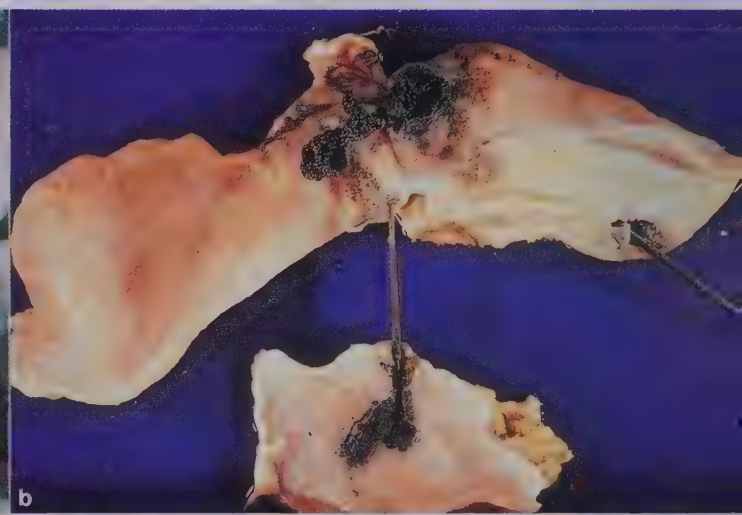
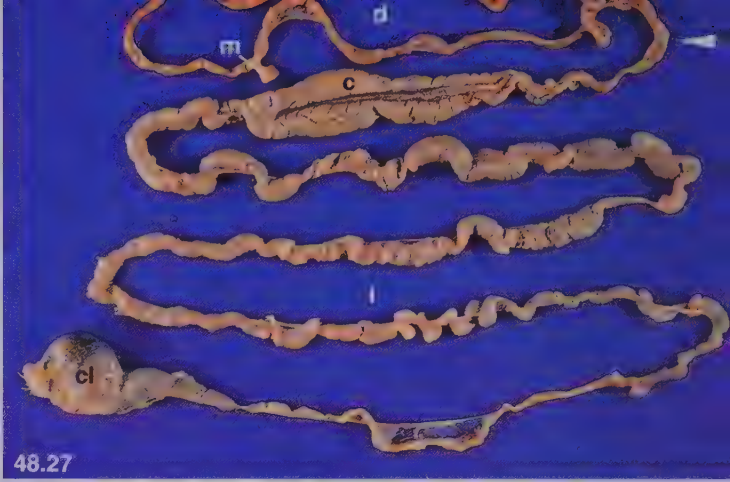
48.24



48.25c



b



## Ratites

### Color 48.26

Massive fat accumulation is shown in the coelomic cavity of an adult ostrich that was being fed an excess quantity of grain. The ostrich died from heart and liver failure secondary to obesity.

### Color 48.27

In this intestinal tract of a four-week-old ostrich, note that the large intestine is much longer than the small intestine and is divided into a thin-walled, smooth section caudally. The cloaca is distended with urine. duodenum (d), pancreas (arrow), Merckel's diverticulum (m), cecum (c), large intestines (i), cloaca (cl).

### Color 48.28

**a)** A nail penetrated through the ventricular wall of a rhea. **b)** Hardware disease in a six-month-old ostrich that ingested two nails. One nail has penetrated the proven-

tricus, mesentery and lodged near the acetabulum. This bird died of inanition.

### Color 48.29

Large consolidated hematoma (arrow) was caused by the passage of a nail through the proventriculus. The mesentery has effectively contained the nail within the lumen of the hematoma. This was an incidental finding at necropsy. ventriculus (v) and large intestines (i).

### Color 48.30

Rock impaction in the ventriculus of an eight-month-old ostrich that had been recently moved to a new paddock.

### Color 48.31

Necropsy exposure of an ostrich. The incision demonstrates an approach to the proventriculus (p). Note the fascial membrane that separates the proventriculus from the intestines.

thologic finding. Clinical changes usually indicate an advanced disease and recovery is unlikely. Endoscopy can be used to document air sac lesions and to perform biopsies or obtain cultures from diseased tissues. Serologic tests for *Aspergillus* sp. may prove to be useful in ratites but have not been adequately investigated.<sup>61</sup>

Flock management should be carefully evaluated to prevent other cases. Appropriate antibiotics to treat secondary bacterial pathogens and aerosolized and oral antifungals are suggested therapies, but are rarely effective. Aspergillosis is best prevented by reducing a bird's access to organic debris, reducing stress, minimizing the use of antibiotics and providing adequate ventilation.

Candidiasis of the proventriculus, esophagus and mouth may occur in ostrich chicks. Infections are most common in birds maintained in damp environments or secondary to proventricular impaction or the long-term use of antibiotics. Chlorhexidine, ketoconazole or nystatin have been discussed as effective therapies. Candidiasis may be prevented with good hygiene and a dry environment.

### ■ Mycoplasma and Chlamydia

*Mycoplasma* spp. infections in ostriches are an enigma. Serologic tests designed for poultry occasionally yield positive results, but the interpretation of these results is speculative. Mycoplasma have been identified on culture as well, but there is no firm evidence to implicate these microbes as the cause of clinical disease in ratites. Ostriches in the United States are gradually falling under stricter guidelines for interstate transport including screening for mycoplasma, and the need for an accurate diagnostic test is imminent.

A pigeon-like isolate of chlamydia has been diagnosed in rheas and ostriches.<sup>25a</sup> Birds raised on an open range may be at risk. Treatment of chlamydial infections in ratites with chlortetracycline (CTC) at the rate of 400 g per ton of feed for 45 days may be expected to be effective (see Chapter 34).

### ■ Parasites

Ratites are susceptible to a number of parasitic infections. The most important parasites are listed in Table 48.3.

#### Protozoa

Intestinal protozoa including *Cryptosporidium*, *Toxoplasma*, *Histomonas*, *Giardia* and *Trichomonas* spp. have been discussed as causes of severe and transient diarrhea in ratites (see Chapter 36). It is unclear the extent to which these organisms cause disease in ratites, but they should be treated when identified. Coccidiosis is a common finding in emu chicks, but is not confirmed as a clinically important problem in ostriches. Asymptomatic leukocytozoon infections are common in ostriches in Africa.

#### Cestodes

The tapeworm *Houlttuynia struthionis* is abundant on South African ostrich farms and has been seen sporadically in the United States. Chicks are particularly susceptible, becoming unthrifty with high mortality rates. Adults are unaffected. A diagnosis is made by identification of parasite segments passed in the feces. The intermediate host is unknown, but infestations can be controlled with regular use of fenbendazole at 15 mg/kg orally.<sup>17</sup>

#### Nematodes

The wireworm *Libyostrongylus douglassi* is an economically important parasite of ostriches. The adult worms and third and fourth stage larvae reside in the glandular crypts of the proventriculus. The resultant inflammation obstructs gastric secretions and inhibits digestion. Food decays within the stomach, and the disorder is referred to as "vrotmaag" or rotten stomach. Eggs may survive in dried feces for over a year, and the infective third stage larvae develop to maturity in 29 days. Diagnosis is made by identification of the trichostrongyloid-type egg in the feces. The eggs can be confused with those of the harmless cecal worm, *Codiostomum struthionis*. Levamisole hydrochloride dosed at 30 mg/kg is routinely administered monthly to chicks and four times per year to adults. Fenbendazole (15 mg/kg)<sup>17</sup> and ivermectin (0.2 mg/kg) are also considered to be effective.

Tracheal worms *Syngamus trachea* have been associated with hemorrhagic tracheitis in emus (Color 48.13). The ostrich guinea worm, *Dicheilonema spicularum*, is a large filarial worm found in the subperitoneal connective tissue. Females may exceed 2.1 m in length and 2.5 cm in diameter. They are frequently found in free-ranging ostriches where they induce no clinically detectable problems.

Filariid nematodes *Chandlerella quisquali* were removed from the spinal cord and lateral ventricles of the brain of emus with clinical signs that included

TABLE 48.3 Protozoa, Helminths and Arthropods Reported in Ratites

	Ostrich	Rhea	Emu	Cassowary
<b>Protozoa</b>	<i>Aegyptianella pullorum</i> , <i>Blastocystis</i> sp., <i>Cryptosporidium</i> sp., <i>Giardia</i> sp., <i>Isospora struthionis</i> , <i>Histomonas meleagridis</i> , <i>Leukocytozoon struthionis</i> , <i>Plasmodium struthionis</i> , <i>Toxoplasma gondii</i> , <i>Trichomonas</i> sp.	<i>Histomonas meleagridis</i> , <i>Toxoplasma gondii</i>	<i>Eimeria</i> sp., <i>Giardia</i> sp., <i>Trichomonas</i> sp.	<i>Toxoplasma gondii</i>
<b>Trematodes</b>	<i>Philophthalmus gralli</i>			
<b>Cestodes</b>	<i>Houttuynia struthionis</i>	<i>Chapmania tauricollis</i> , <i>Houttuynia struthionis</i>	<i>Davainea australis</i>	<i>Davainea casuarii</i> , <i>Davainea infrequens</i>
<b>Nematodes</b>	<i>Baylisascaris procyonis</i> , <i>Codiostomum struthionis</i> , <i>Dicheilonema spicularum</i> , <i>Libyostrongylus douglasi</i> , <i>Paronchocerca struthionis</i> , <i>Struthiofilaria megaloccephala</i>	<i>Ascaridia orthocerca</i> , <i>Deletocephalus dimidiatus</i> , <i>D. cesarpintoi</i> , <i>Dicheilonema rhea</i> , <i>Habronema incerta</i> , <i>Odontospirura zschokkei</i> , <i>Paradeletocephalus minor</i>	<i>Baylisascaris</i> sp., <i>Chandlerella quisicali</i> , <i>Dromastrongylus bicuspis</i> , <i>Syngamus trachea</i>	
<b>Gnats</b>	<i>Simulium</i> spp.			
<b>Fleas</b>	<i>Ctenocephalides felis</i>			
<b>Louse flies</b>	<i>Struthiobosca struthionis</i>			
<b>Lice</b>	<i>Struthiolipeurus struthionis</i>	<i>Struthiolipeurus andinus</i> , <i>S. nandu</i> , <i>S. renschi</i> , <i>S. stresemanni</i>		
<b>Ticks</b>	<i>Amblyomma gemma</i> , <i>A. hebraeum</i> , <i>A. lepidum</i> , <i>A. variegatum</i> , <i>Argus persicus</i> , <i>Haemaphysalis punctata</i> , <i>Hyalomma albiparmatum</i> , <i>H. dromedarii</i> , <i>H. impeltatum</i> , <i>H. luscitanicum</i> , <i>H. marginatum</i> , <i>H. truncatum</i> , <i>Otobius megnini</i> , <i>Rhipicephalus deltooides</i> , <i>R. guilhoni</i> , <i>R. sanguineus</i> , <i>R. turanicus</i>	<i>Amblyomma parvitarsum</i> , <i>Ixodes brunneus</i>		<i>Amblyomma papuanum</i>
<b>Mites</b>	<i>Gabucinia bicaudata</i> , <i>G. sculpturata</i> , <i>Paralges pachynemis</i>	<i>Gabucinia bicaudata</i> , <i>Paralges pachynemis</i>		

torticollis, ataxia and abnormal gait followed by recumbency and death.<sup>3</sup> Only two- to five-month-old emus were affected, with adult and yearling emus apparently resistant. The cause of apparent resistance in these older birds is unclear. It is possible that older birds were immune to the parasite or that the neural tissues were less severely damaged. Emu chicks that were affected by the parasite were repeatedly tested for circulating microfilaria, but all birds were negative during a three-month period of sampling. Several birds with mild neurologic signs were followed for a six-month period and never developed a microfilaremia.


Grackles are the normal host for *C. quisicali*, which is transmitted by *Culicoides* sp. Following a migration of unknown duration, the larvae enter the brain and spinal cord and migrate toward the lateral ventricles of the brain where the adults mature and produce microfilaria. When the microfilaria are ingested by gnats, the life cycle of the nematode is completed.

Infected Great-tailed Grackles and *Culicoides* sp. were collected from farms with affected emus.

Prevention of this cerebrospinal nematode may be possible by control of the vector, elimination of the environmental conditions conducive to transmission of the parasite and prevention of larval migration. Treatment would be expected to be ineffective once the larvae enter the CNS because anthelmintics normally do not pass the blood-brain barrier. Several emu farms use anthelmintics in an attempt to arrest larval migration, but it is unclear if this preventative is effective. Although this parasite has not been reported in the ostrich, it should be considered a threat until proven otherwise.<sup>3</sup> *Baylisascaris* sp. has also been shown to cause neurologic signs in ratites (see Chapter 36).

### Arthropods

Ostriches are subject to infestation by a variety of external parasites, both host-specific and indiscriminate. The ostrich louse, *Struthiolipeurus struthionis*, is commonly found on ostriches worldwide. These



**FIG 48.21** Nits of the ostrich feather louse (*Struthiolipeums struthionis*) can be seen along both sides of the rachis (courtesy of James Stewart).

chewing lice feed on skin scale and feathers and by removing the barbules, make the feather coat appear thin and tattered. Infestation is easily diagnosed by identification of the nits glued to the barbs along the shaft of feathers, particularly under the wing (Figure 48.21). The ostrich louse fly, *Struthiobosca struthionis*, is a minor annoyance to African birds but may also bite the human caretakers. Quill mites may be found within the feather shaft or along the external groove of the shaft.

Ticks from a variety of mammalian, avian and reptile hosts have been reported to infest ostriches. They may cause blemishes on the skin that reduce its commercial value. More importantly, many of these tick species are potential vectors of livestock diseases. The discovery of ticks on imported ostriches released from private quarantine in 1989 caused the United States Department of Agriculture to impose an immediate ban on the importation of ratites.<sup>40</sup> Following considerable study and public debate, the importation of ratites was reapproved in 1992 with modified quarantine restrictions and guidelines.

External parasites may be treated with monthly applications of five percent carbaryl or two to four

percent malathion in either powder or liquid form. Benzene hexachloride is highly toxic to ostriches and should be avoided. Quill mites are responsive to monthly treatments with ivermectin at standard doses.<sup>29</sup>

### ■ Respiratory Problems

Upper respiratory tract infections may be caused by bacteria, mycoplasma, fungi (*Aspergillus* spp.) or possibly viruses (see Color 22). Clinical signs are characterized by ocular or nasal discharge, and birds may be dyspneic and appear unkempt. Treatment is based on the etiology. Affected birds should be isolated immediately and flockmates should be carefully observed. Adequate ventilation and reduced airborne debris are necessary to prevent the spread of infections in the flock. Air sacculitis and pneumonia are most commonly caused by bacteria or *Aspergillus* spp.<sup>61</sup> A sunken sinus syndrome has been described in emus secondary to sinusitis (see Figure 26.8).

### ■ Ocular Problems<sup>53,54</sup>

Cataracts are frequently seen in ostriches. They are more common in older birds, but may occur also in chicks only a few months of age (Color 48.10). Unilateral cataracts are of little clinical importance. Bilateral cataracts must be removed, and surgery has been successful.

Lacerations, abrasions or ulcerations to the eye may cause epiphora or blepharospasms. Foreign bodies may or may not be found. The discharge in these cases is usually clear and often is present in only one eye. Diagnosis is made via physical examination and fluorescein-staining of the eye. Standard ocular therapies used in other birds are effective in ratites (see Chapter 26). Subpalpebral flukes may cause chronic epiphora in birds raised in moist areas.

Eye infections generally cause the production of a purulent discharge and will usually be bilateral (Color 48.11). Cytology and cultures are necessary to determine the etiologic agent. Ocular discharges are common with upper respiratory infections. A blocked nasolacrimal duct is recognized clinically by epiphora and swelling within the lower lid. The lacrimal duct can be cannulated and flushed to determine if a blockage has occurred and to correct the problem.<sup>66</sup>





**FIG 48.22** Feather picking in ratites may be caused by malnutrition or overcrowded, small or barren enclosures (courtesy of James Stewart).

### ■ Feather Loss (With or Without Skin Involvement)

Bacterial folliculitis has been described in ratites and is most commonly caused by *Staphylococcus* spp. The ingestion of parsley was associated with a photosensitization reaction in an ostrich (see Chapter 37). Poxvirus may cause crusty proliferative lesions on the head, periocular area and legs. Lice or mites can damage the skin and feathers of ratites. Adult lice and their eggs can be visualized along the shaft of the feather (Figure 48.21). Five percent Sevin dust is an effective treatment.

Feather picking can be caused by overcrowding, excessive exposure to light at night and a lack of available food. Feather picking is common in adult ostriches maintained in small, barren paddocks and may be a reflection of malnutrition or environmental stresses (Figure 48.22). Large deplumed areas of skin are subject to sunburn. These birds will usually respond to an enriched environment, especially green pasture. In one case, a large, reflective, chrome plate (mirror) was used to distract a male and prevent him from feather picking a hen.

### ■ Neural Diseases

Toxins that can cause neurologic lesions in ratites may include plants, oil, grease and insecticides. Endotoxins produced by bacteria can lead to severe ataxia. Infectious causes of neurologic problems include viruses, bacteria, fungi or parasites. Paramyxovirus, EEE virus and Newcastle disease virus

have all been associated with neurologic signs in ratites. Overheating may cause ataxia or seizures. The normal body temperature of ratites is approximately 103°F. Birds, particularly chicks, that are panting with extended wings are overheated. Treatment should include cold water baths. Hypoglycemia can cause ataxia and tremors in anorectic neonates. Oral or IV dextrose as well as tube feeding with high-carbohydrate diets three to four times daily is usually curative.<sup>62</sup>

## Hatchery Management

### ■ The Egg

The general principles of egg management for ratites are no different than those for other avian species.<sup>52,56</sup> Hatchability exceeding 90% of fertile eggs should be expected with well managed commercial ostrich operations. The maintenance of accurate records, including the analysis of unhatched eggs, is an absolute necessity for the elucidation of incubation and hatchery problems.

There is an optimum size for all eggs. Unusually small eggs lose excessive moisture during incubation and produce small dehydrated chicks that rarely survive. Conversely, large eggs produce weak, edematous chicks that frequently fail to hatch (Color 48.2).

The shell of an egg balances two opposing functions: the egg shell must allow the free exchange of oxygen, carbon dioxide and water vapor, yet inhibit the penetration of infectious agents. Thick shells and shells with low porosity inhibit gas and water vapor exchange, while thin, highly porous or defective shells may lose excessive water vapor and readily allow bacterial penetration (Color 48.1). Shell quality is influenced by nutrition, disease and genetics, as well as by the conditions of the nest site and the egg handling methods.<sup>27</sup> Porosity of the shell is a heritable trait, and each hen will have unique eggs.<sup>27</sup> Strict sanitation is essential to maintain hatchability.

The physical health of the hen can also affect egg quality. Pathogens colonizing the reproductive tract may result in a thin or absent shell, or may be a source of infection for eggs that appear otherwise normal. Eggs with rough-textured surfaces, ridges, a lack of a mucin coat or soft shells may indicate metri-

tis. Soft shells may also occur as a result of dietary deficiencies. Yolkless eggs may be caused by metritis, deposition of yolk into the peritoneal cavity or abnormalities of the ovary. Double yolks are postulated to occur with abnormal egg passage through the oviduct.

The physical characteristics of an egg have a strong genetic basis. Commercial poultry have been selected to produce a nearly uniform egg that results in uniform incubation and hatching characteristics. Ostrich breeding stock from free-ranging lineage will retain their full natural variability in egg quality and specific incubation requirements.

Ratites lay their eggs on the ground, creating a potential for egg contamination by infectious agents. Management practices require that a clean nest such as sand or straw be available for egg laying and that eggs to be artificially incubated are collected and disinfected promptly. Ostriches typically lay in the evening hours, while emus frequently lay shortly after dark. Eggs should be gently collected from the nest and transported by hand to the preparation area. Excessive jarring of the egg contents or damage to the shell can be fatal to the developing embryo.

Cold storage of eggs allows the use of efficient batch incubation and brooding systems and is a routine practice on large farms. Disinfected eggs are maintained up to seven days between 12.8°C (55.0°F) and 18.3°C (65.0°F) and near 75% relative humidity. Egg-turning is not necessary for storage periods of less than one week. Ideally, eggs are stored directly in the incubation trays and the entire tray may then be loaded into the incubator racks.

Egg washing is a controversial issue in ratite production. It is better to provide the breeding pair with a clean, dry area in which to lay eggs rather than attempting to clean or disinfect dirty moist eggs. Wet washing of eggs involves the use of warm dilute solutions of commercial quaternary ammonia or phenolic disinfectants, chlorhexidine or sodium hypochlorite. Dry washing is performed by using a soft

bristle brush to remove gross organic debris and misting the egg with a disinfectant. The dried mucinous cuticle of ratite eggs is particularly well developed and serves as a significant barrier to bacterial penetration. It has been suggested that the wet washing of clean eggs removes this cuticle and increases the incidence of infection over that of a dry cleaning method.

**Incubation**

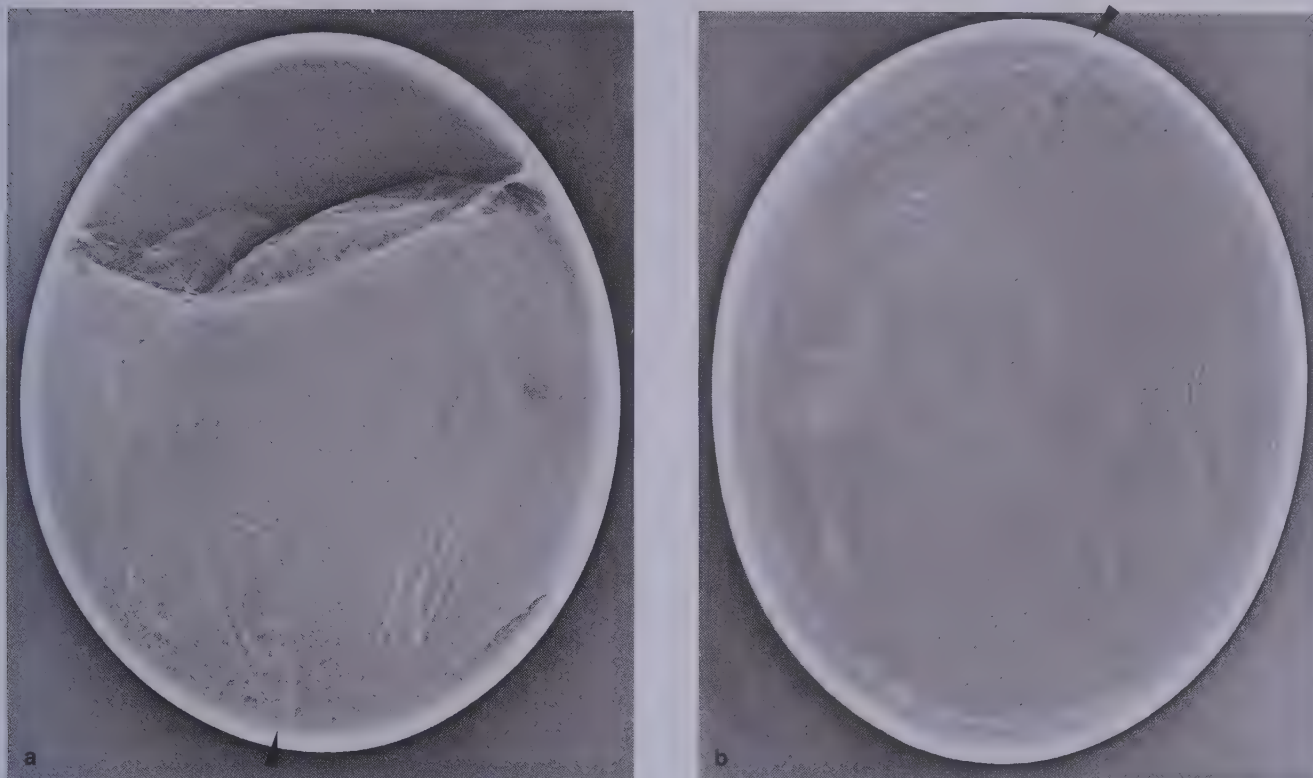
The incubation temperatures and humidities required for ratite eggs are lower than those used for other avian species (Table 48.4).<sup>52,56</sup> The incubators currently available for ratite production vary in quality. Many of them are inadequate in several aspects, and faulty incubators are a common cause of hatchery problems. Incubators should generate a uniform temperature throughout the cabinet and maintain the temperature within narrow limits, preferably one- or two-tenths of a degree. Late-term embryos are particularly sensitive to decreasing temperatures, and it is imperative that backup electrical power be available for incubation equipment so that eggs are not chilled if a power outage occurs.

Ventilation is the amount of fresh air brought into the incubator. Circulation is the amount of air movement within the incubator. The minimum ventilation requirement for the incubation of ostrich eggs is calculated at 50 cubic feet of fresh air per hour per 100 eggs. Inadequate ventilation causes an accumulation of carbon dioxide and severely reduces hatchability. Ventilation also controls the humidity in most incubators. Circulation functions to maintain uniformity of temperature, humidity and gas levels throughout the incubator cabinet. Rapid air circulation is critical with the large ratite eggs to effectively dissipate the high temperature and humidity that develops at the egg surface.

Ratite eggs should be incubated in the vertical position with the air cell end upward. Embryonic malposition 2 (head at opposite end from air cell, see

**TABLE 48.4 Breeding and Hatchery Parameters for Ratites**

Species	Eggs/year	Egg wt. (g)	Temperature	Humidity (%)	Period (days)
Ostrich	40-60	1300-1700	36.0-36.4°C (96.8-97.5°F)	20-40	41-43
Rhea	40-60	400-700	36.0-37.2°C (96.8-99.0°F)	55-70	36-41
Emu	20-40	500-700	36.0-36.7°C (96.8-98.0°F)	25-40	50-57
Cassowary	3-10	500-700	36.0-36.7°C (96.8-98.0°F)	55-70	47-53



**FIG 48.23** Xeroradiographs of ostrich eggs. **a)** Notice the dead embryo skeleton positioned with its head and the tip of its beak (arrow) oriented opposite the air cell end of the egg. The embryo died late in development. The air cell at the top of the egg has not been penetrated. **b)** Notice the dead embryo skeleton in a normal position after penetration of the air cell with the tip of the beak (arrow). The embryo did not pip the shell, and the air cell has been displaced by the embryo (courtesy of David Ley, reprinted with permission<sup>38</sup>).

Chapter 29) is especially common in ostrich eggs incubated in the horizontal position and results in poor hatchability. The incidence of malposition 2 increases from 3% among eggs incubated vertically to 16 to 20% among eggs incubated horizontally (Figure 48.23).

Eggs are rotated during incubation in order to stir the liquid layers of nutrients and waste products around the developing embryo. Inadequate turning increases both embryonic and post-hatch mortality. Following poultry protocol, the egg rotation angle should be 45° from vertical, shifting a minimum of six times per day.

Incubator humidity settings vary with the type of incubator as well as the size and shell characteristics of the eggs. Humidity is generally set at 20 to 40% to achieve the desired evaporative water loss during the course of incubation (13 to 14% for ostrich eggs and 10 to 11% for emu eggs). Egg monitoring during the course of incubation should include determination of weight loss and candling for embryonic development. The weight loss of eggs is fairly linear throughout

incubation, and weighing an egg weekly can be used to monitor an embryo's development and guide adjustments in humidity.

It is important to determine when mortality occurred in a dead embryo. Losing ten per cent of fertile eggs during incubation is considered normal, with peaks of loss at 3 to 4 days (organogenesis) and 40 days (respiration change) of incubation. Embryonic death at other times may be caused by incorrect incubation parameters, nutritional deficiencies in the egg, infectious agents, genetic abnormalities, improper egg storage or toxins. If candling indicates that an egg is not developing after ten days of incubation, the egg should be opened to determine if the egg was infertile if early embryonic death occurred (see Chapter 29). The embryonic disc floats up and can be examined for any development. This is best done early in the incubation cycle rather than at day 43, because embryos that die early in incubation decompose rapidly.<sup>27</sup>

Fluctuating incubation temperatures result in unthrifty chicks. High temperatures result in an early hatch, small dry chicks, increased embryonic mortal-

ity and malformations (Color 48.2). Low temperatures result in soft, large, weak chicks with a delayed hatch. Excessive humidity (inadequate moisture loss from the egg) may cause a delayed hatch, small air cells, wet edematous chicks and mild degeneration of the leg muscles (Color 48.4). Humidity that is too low (excess moisture loss from the egg) results in large air cells, increased malpositions due to sticky chicks (dry albumen), albumen plugs in the non-air cell end of the egg and weak, dehydrated chicks with poor survivability.

### ■ Hatching

Ratite eggs are transferred to a hatcher with the same temperature and humidity settings as the incubator three to five days prior to the anticipated date of hatch. Hatching should be a gradual process that gives the chick time to switch from chorioallantoic to pulmonary respiration. The yolk sac with the blood from the chorioallantois is absorbed, and the navel closes during the last 24 hours of incubation.

The social facilitation of pipping and hatching is strongly developed in ratite chicks, and light, sound and motion help stimulate a hatch. Daily candling of ostrich and rhea eggs allows for careful monitoring of the chicks' progress, and assisted hatches are a common management procedure. The pigmented shells of cassowary and emu eggs prohibit effective candling, and various techniques of percussion and auscultation have been used to evaluate embryo development in these species. Many clients are anxious to help a chick out of the shell and begin to assist with the hatching process prematurely. This procedure results in chicks with a high incidence of yolk sac infections (see Chapter 29).



## Chick Management

Ratite chicks are precocial, hatching with a full coat of natal feathers, open eyes and the ability to stand within hours.<sup>63</sup> They should be removed from the hatcher at one to two days of age and placed in brooder pens with other neonates that do not vary more than three weeks in age. Eating and drinking are behaviors that must be learned from older birds, and dehydration or starvation are common in chicks that are housed alone. Bin feeders and automatic

water units designed for poultry and gamebirds can be effectively used in recently hatched young. Numerous commercial starter and grower rations are available for ratites. Chicks should be expected to lose weight for three to five days following hatch and then to begin a steady increase in weight gain.

Young chicks should have access to supplemental heat that can be provided by infrared lamps, heated floors or space heaters. Chicks should be maintained at decreasing temperatures with age (90°F one to two weeks, 85°F to 12 weeks).<sup>61</sup> Indoor flooring should be inedible, provide good traction and be easily cleaned. Brushed concrete, with or without perforated plastic or rubber matting, is commonly used. In order to prevent gastric impactions, hay or wood chips should not be used. Adequate ventilation is essential in the brooding area. The general consideration for air circulation is 0.012 cubic feet per minute/per pound of bird for each degree F. For example, if the temperature is 70° and ten birds weighing 50 lbs each are in the space (500 lbs total), then the air exchange requirement is 0.012 x 500 x 70 or 420 cubic feet per minute.<sup>61</sup>

As soon after hatching as ambient temperatures permit, chicks should be moved to outdoor grazing areas with fencing that is low to the ground and with holes no larger than 2.5 cm. Chicks should be considered cold-intolerant and provided supplemental heat in cold weather until they are six months of age. Chicks should be housed with birds of similar age to prevent injuries. Young chicks require constant attention to keep them tame and to quickly detect any developmental problems.

To reduce the chances of foreign body ingestion, chicks should be carefully monitored during their initial introduction to a pasture. Using a grassy area that has been well groomed (cut to three inches) and placing chicks with slightly older birds to serve as feeding models are the best techniques to introduce chicks to pasture. Initial introduction periods should be 10 to 15 minutes in length with daily doubling of the time in the paddocks.

### ■ Chick Problems

“Wet” is the term applied to chicks that have not lost sufficient weight during incubation and are consequently edematous at hatching (Color 48.2). These birds may or may not be capable of an unassisted hatch. Diuretics have been suggested to reduce the edema but they are rarely necessary. Most birds will

lose the excess water several days after hatch.<sup>61</sup> This condition can be caused by several factors including: 1) Large ostrich eggs (greater than 1700 to 1800 g) that do not have sufficient surface area to allow adequate water loss; 2) Poor egg shell quality, such as low pore density or excessive thickness; 3) High incubation humidity. Relative humidity in the incubator should be 20 to 25% as a starting point. Adjustments must be made to achieve a 13 to 15% egg weight loss throughout incubation.

### “Sticky” Chicks

This condition occurs when the inner shell membrane is excessively dry, causing the chick to stick to the membrane. Assisted hatching is mandatory in these chicks or they will not survive. To correct this problem, the humidity in the hatcher must be increased (perhaps as high as 80 to 90% relative humidity) to a point that allows the membrane and its underlying chorioallantois to remain pliable and easy for the chick to tear. This problem can occur if the humidity in the incubator is too low.<sup>61</sup>

### External Yolk Sac

If the umbilicus does not close properly, the yolk will protrude from the abdomen to varying degrees (Color 48.2). High incubation temperatures (early hatch), poor gas exchange (may occur with high altitude or high humidity) and egg infections are thought to be the principal causes of improperly absorbed yolk sacs. The cause can best be determined by carefully evaluating the incubation and hatching parameters and culturing affected embryos. In mild cases, the yolk can be placed in the abdomen, the umbilicus covered with antibiotic ointment and gauze, and the abdomen wrapped with self-adherent bandage. Systemic antibiotic therapy should be initiated immediately. If a large quantity of the yolk sac is externalized or the umbilicus has sealed (Color 48.2), the yolk sac should be surgically removed. The prognosis for chicks with externalized yolk sac is poor.<sup>61</sup>

### Retained Yolk Sac

Chicks that fail to absorb the yolk sac are generally weak, depressed and may peck erratically at the air with or without their eyes closed. A distended abdomen in a depressed chick less than two weeks old is a characteristic finding (Figure 48.24). Additionally, they may display a characteristic “S”-curve in the neck and feign eating without ingesting any food. These birds will continue to lose weight beyond the normal weight loss seen the first four to five days after hatch.

Retained yolk sacs are thought to be caused by improper incubation parameters, malnourished hens or infected eggs (Color 48.7). Improper incubation temperature as well as inappropriate gas exchange (poor circulation or ventilation) between the embryo and the air surrounding the shell can cause retention of the yolk sac. Ventilation defects are thought to have their most profound effects late in the incubation process and may be most common when an incubator is filled to near capacity, which causes an accumulation of CO<sub>2</sub> if the ventilation is inadequate. Incubation problems are suspected if infectious agents cannot be cultured from the yolk sac of affected chicks.

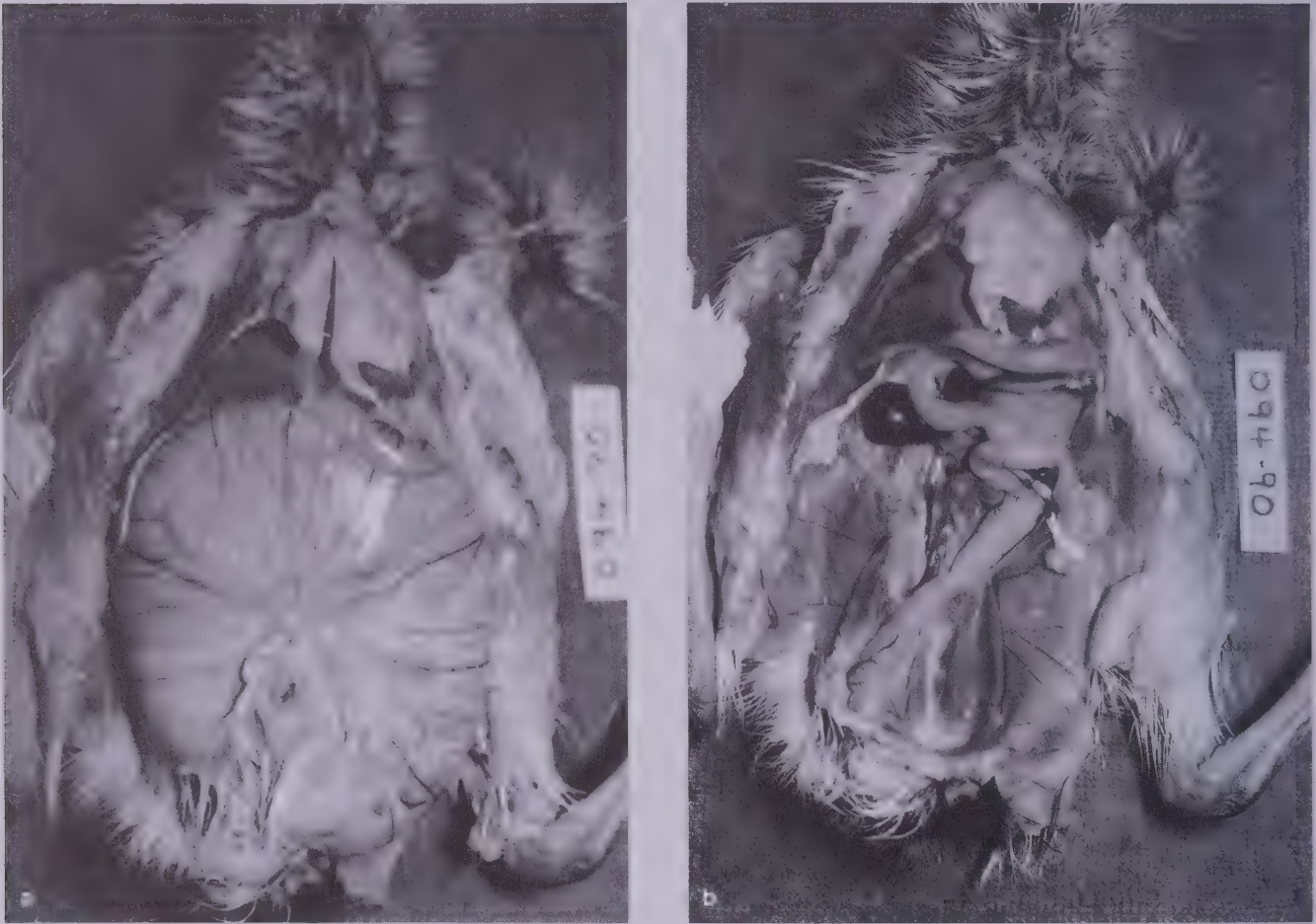Inflammation of the umbilicus shortly after hatching can be an early warning sign of an impending yolk sac infection (Color 48.6). Affected chicks have subnormal weight gains over a two- to three-week period and intermittently appear depressed or chilled. These chicks may absorb a portion of their yolk sac and may not have a severely distended abdomen until late in the disease process. Applying an antibiotic ointment to the umbilicus of recently hatched chicks may help prevent infections.

Retained or infected yolk sacs may represent 15 to 40% of a chick’s total body weight and should be surgically removed in conjunction with the administration of broad-spectrum antibiotics. *E. coli* is frequently cultured from retained yolk sacs (Color 48.7). To remove the yolk sac, the chick is placed in dorsal recumbency and the abdomen is prepared for surgery. The skin is incised circumferentially around the umbilicus and the incision is extended transversely at the three and nine o’clock positions to the lateral distance required to allow easy removal of the intact yolk sac. The body wall is then incised in a corresponding pattern being careful to not damage the underlying yolk sac. The yolk sac is exteriorized by placing gentle traction on the umbilical stump. The

## CLINICAL APPLICATIONS

### Management Tips for Chicks<sup>61</sup>

- Feed pellets with 19 to 21% protein content supplemented with fresh grazing as soon as possible.
- Weigh chicks daily for the first two to three weeks after hatching. Weight gain is a good indicator of a healthy chick, and weight loss often precedes clinical signs of disease.
- The single most important requirement for growing ratites is ample exercise.
- Exposure of chicks to infectious agents can be reduced by restricting access of all visitors, utilizing sound hygiene procedures and caring for neonates in a youngest to oldest pattern.



**FIG 48.24** a) Retained egg yolk in a six-day-old cassowary chick that developed dyspnea and an inability to walk. b) The yolk sac has been removed showing cranial displacement of the abdominal viscera (courtesy of Richard Cambre, reprinted with permission *J Zoo Wildl Med* 23:1992).

yolk stalk is clamped, clipped or ligated just distal to the intestine to allow the stalk to be transected and the yolk sac to be removed. The body wall is closed with a monofilament, absorbable material in a simple continuous pattern. Broad-spectrum antibiotic therapy is indicated pending culture results. Trimethoprim-based antibiotics can be administered until the results of yolk sac culture and sensitivities are available. Some chicks begin to eat and gain weight within a day or two of surgery while others require nutritional support by tube-feeding for several days before they resume normal growth.<sup>10</sup>


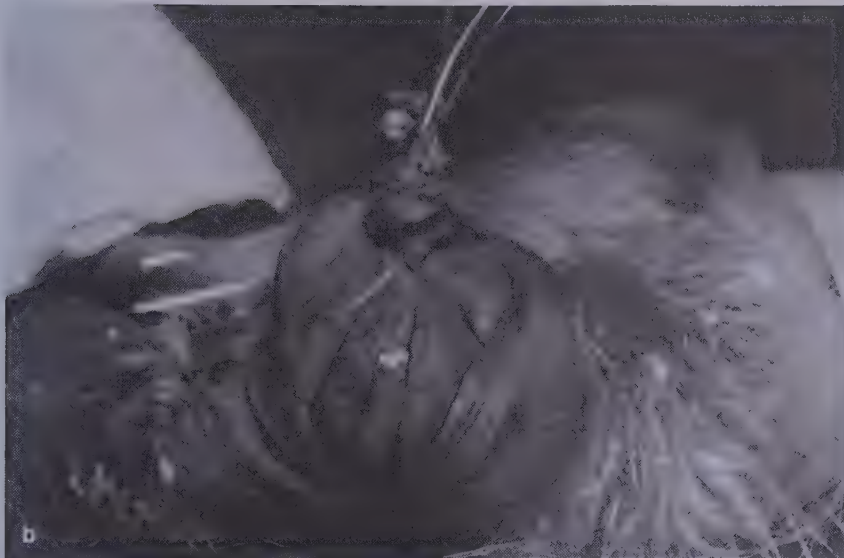
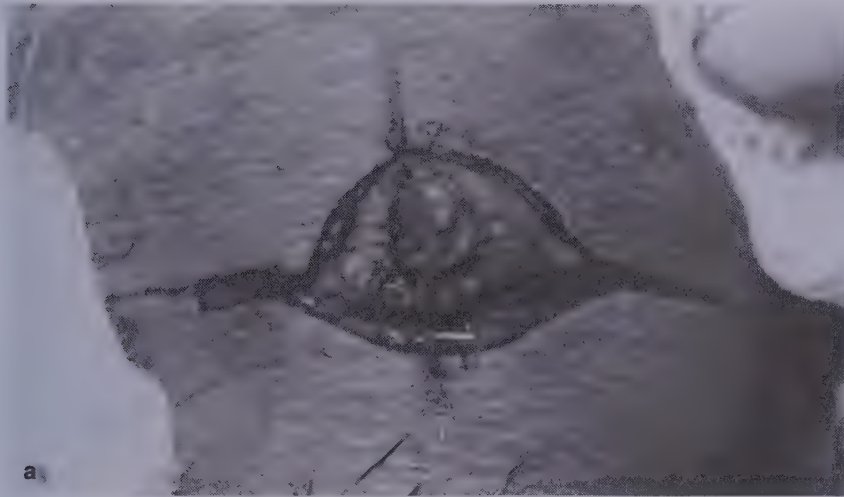
#### Congenital Disorders

Congenital anomalies described in ostrich chicks include albinism, leucism, melanism, pied, prognathism, crossed beak, choanal atresia, microphthalmia, blindness, meningocele, crooked neck, hernia, schistomus reflexus, polydactyly, third leg,

micromelia and hermaphroditism. Congenital defects in chicks may be attributable to genetics, the effects of nutritional deficiencies or teratogens in the laying hen, or may be caused by inadequate egg handling and incubation procedures. The incidence of these problems is usually sporadic and the specific etiology obscure.

#### Cloacal Prolapse

Prolapse of the cloaca may occur in neonates. This condition is most common in birds less than four weeks of age and has been associated with distension of the abdomen (ie, excessive water-drinking on hot days, proventricular impactions, retention of the yolk sac) and tenesmus. Mild cases can be resolved by simply replacing the cloaca through the vent. More severe cases require retention sutures for one to three days (see Chapter 41).



### Stress

Stress is an extremely important consideration in ostrich management and is generally under-rated or ignored. It is the most frequent primary cause of chick mortality. Ostriches are highly social animals that do not readily adapt to change. Young chicks require a stable social group that might include a parental figure in the form of a natural parent, older counselor chick or a human substitute. Complete social isolation of young chicks is tantamount to death.

Management systems in which chicks are transferred through a series of pens are disturbing to the birds. Relocating or mixing chicks from different groups may alter the social structure causing some chicks to be harassed or rejected by dominant birds. These abandoned chicks may exhibit neurotic pacing, inadequate or inappropriate ingestion behavior, intermittent diarrhea and stunting. Chicks shielded from constant human activity become flighty, adjust poorly to captivity and may mature to become substandard producers. Environmental and social stability, combined with the taming of young chicks through continuous human presence, are among the most important components of a successful ostrich management program. Gradually introducing chicks to a new area or situation will help maintain the group stability and reduce stress.

**FIG 48.25** a) To remove a retained yolk sac, a circumferential incision is made around the umbilicus extending laterally at the three and nine o'clock positions. b) The yolk is exteriorized by placing gentle traction on the umbilical stump. c) The exteriorized yolk sac showing the vascular and yolk sac connection to the small intestines. These structures are ligated close to the small intestines (courtesy of Richard Cambre, reprinted with permission *J Zoo Wildl Med* 23:1992).

### Musculoskeletal Disorders of Chicks

Rolled toe in ostrich chicks is a problem frequently seen in backyard operations the first few day after hatching (Color 48.22). The distal portion of the main toe is rotated off of the centerline (Figure 48.25).

In poultry, riboflavin deficiencies cause damage of the peripheral nerve trunks and paralysis resulting in curling of the toes and leg weakness; however, in ostriches, rolled toe syndrome seems to be caused by genetic abnormalities, incubation problems or inappropriate substrates during the first week of life while the phalanges are mineralizing. Brooder pens with soft surfaces or wire mesh allow the toe to flex and roll medially. A firm flat surface such as packed dirt or concrete induces proper toe formation.

Rolled toe deformities may be corrected with a variety of simple splints, but become more difficult to resolve as the chick matures. A splint can be applied by wrapping tape around the toe in a direction opposite to the deflection (Figure 48.26). A tongue depressor can be incorporated into the plantar surface of the toe on the final wrap to provide extra stability. Correction of this problem in older chicks requires surgical intervention.

Rotational and angular deformities of the legs are a common problem in the rearing of all ratite chicks and should be viewed primarily as a management problem (Figure 48.27). This condition occurs when one or both legs rotate laterally at the distal tibiotarsus causing the toe to point laterally (Color 48.23). Chicks from a particular breeding pair may have a high incidence of deformities under conditions in which other chicks are raised satisfactorily, implicating genetics as a contributing factor. Chicks raised on slick and slippery surfaces have severe leg deformities. Classical rickets is often seen, with elongated metaphyses of the long bones and ricketic rosaries along the ribs. These chicks respond favorably to adjusted dietary levels of calcium, phosphorus and vitamin D<sub>3</sub>. Leg problems associated with inadequate or imbalanced levels of these compounds are exacerbated by high levels of dietary protein.

Leg deformities are more common in birds that are pushed to grow too fast (high-protein, high-fat diets) combined with reduced exercise, and are maintained in areas with poor footing (sand, straw, Astroturf). An injury of the growth plate (nutritional, traumatic) will result in a rapid bending or twisting of the bone due to the rapid growth rates. In long-legged altricial species, bone growth in the tarsometatarsus may be

six millimeters/day. In precocial young, the growth rate may be two millimeters/day.<sup>34</sup>

An excessive growth rate induced by high-energy diets may cause an unacceptable level of stress on the cartilage in the developing bones, causing deviations in the growth patterns. Weight gains should be linear, and several days of excess weight gain may induce bone deformities.<sup>6</sup> Chicks are best raised on moderate protein diets (20%) in large pastures with plenty of room for exercise. Empirical observation suggests that the incidence of leg deformities is reduced with increased exercise. Bone strength responds to usage, and it is hypothesized that exercise increases circulation to the developing bone and enhances the mineralization process.


Leg deformities in poultry are associated with deficiencies in manganese, zinc, choline, biotin, folic acid, niacin and pyridoxine, and the involvement of these nutrients in certain leg deformities of ratites is likely. Infectious disease, gastric impaction and dehydration often inhibit the appropriate absorption and utilization of feeds and induce secondary skeletal deformities.

Treatment of afflicted individuals can be attempted with a variety of external splints and slings or by derotational osteotomy and fracture repair, but the prognosis is exceptionally poor. Re-rotation following surgery commonly occurs. Proper positioning with external bracing coupled with an immediate decrease in protein content of the feed may be helpful in arresting the process. It is best to apply bracing at night during roost time and to release the chick with the flockmates during the day. It is stressful for chicks to be alone and, with a rotational problem especially, they need extensive exercise. In commercial ratite production, such techniques are economically unfeasible and individuals with marked deformities should be condemned.

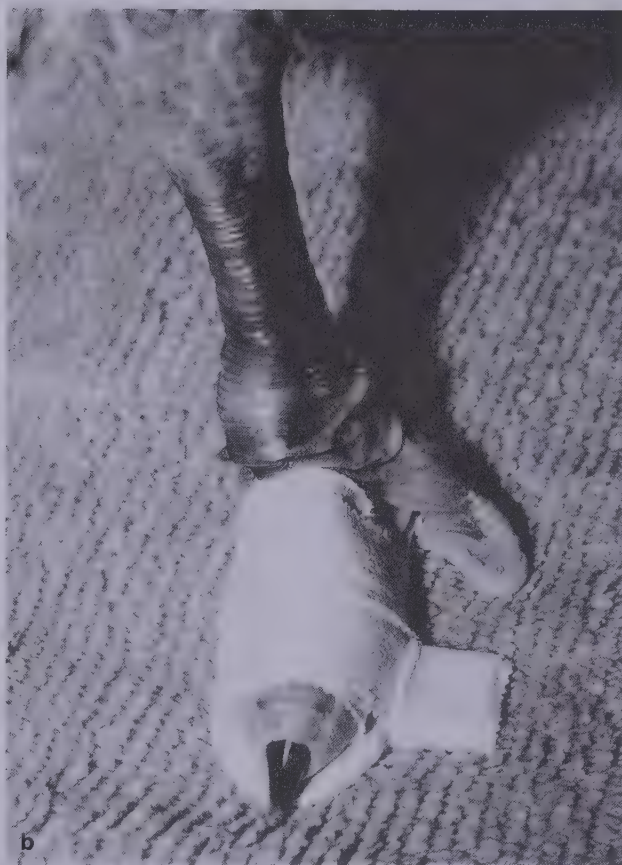#### Spraddle Leg

Spraddle leg is caused by a deformity in the coxofemoral joint that prevents the legs from being adducted. This condition, usually associated with edematous chicks, is manifested by the legs being directed laterally resulting in the inability to stand. Hobbling the legs with a self-adherent bandage or placing the chick in a restrictive box that forces the legs together is usually effective if initiated immediately after the problem is noted. The problem can be prevented by ensuring proper weight loss of the egg during incubation.<sup>61</sup>





**FIG 48.26** Rolled toe deformity **a)** before and **b)** after applying a splint (courtesy of James Stewart).



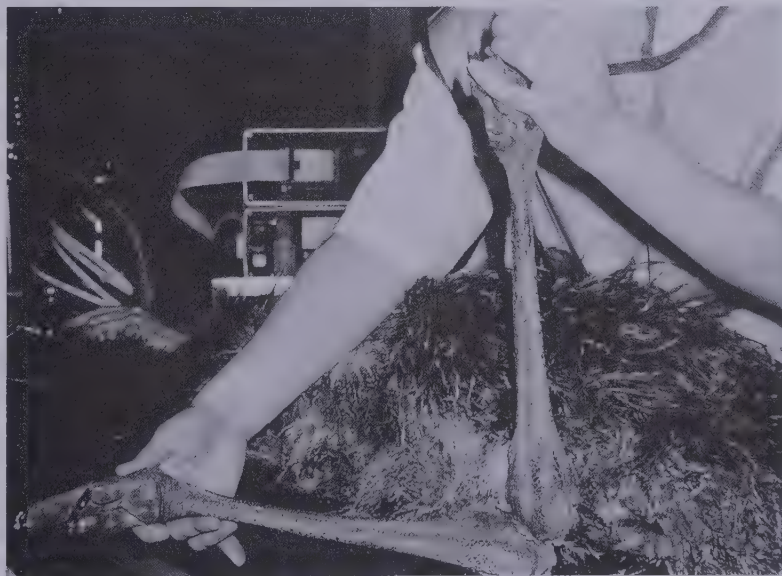### Ruptured or Slipped Achilles Tendon

Rupture or slippage of the Achilles tendon may occur secondary to valgus or varus deformities of the leg. Manganese deficiency has been suggested as a possible predisposing factor. Management practices must be scrutinized if multiple cases occur in a flock. Feed analysis, feeding frequency, exercise programs, concurrent rotations or angular deformities are areas to evaluate. Surgical repair can be attempted (see Chapter 46).

Septic arthritis is frequently seen in ratites. Numerous gram-negative bacteria, *Mycoplasma* spp., *Staphylococcus* spp. and some fungi have been recovered from affected joints (Color 48.21). These infections may originate from traumatic injuries or can be secondary to septicemia.

### Acknowledgements

Portions of this chapter have been taken in part, with permission, from Fowler ME: *Clinical anatomy of ratites*. Proc Assoc Avian Vet, 1992, pp 307-309; Blue-McLendon AR: *Clinical examination of ratites*. Proc Assoc Avian Vet, 1992, pp 313-315; Hicks KD: *Ratite production*. Proc Assoc Avian Vet, 1992, pp 318-325; Wade JR: *Ratite pediatric medicine and surgery*. Proc Assoc Avian Vet, 1992, pp 340-353.



**FIG 48.27** Left-sided valgus deformity of the tibiotarsal bone. All angular limb deformities should be considered an indication of management-related problems that need correcting (courtesy of Louise Bauck).

## References and Suggested Reading

1. **Bertram BCR, Burger AE:** Aspects of incubation in ostriches. *Ostrich* 52:36-43, 1981.
2. **Bezuidenhout AJ:** The topography of the thoraco-abdominal viscera in the ostrich (*Struthio camelus*). *Onderstepoort J Vet Res* 53:111-117, 1986.
3. **Blue-McLendon AR, et al:** Cerebrospinal nematodiasis in emus. *Proc Assoc Avian Vet*, 1992, pp 326-327.
4. **Blue-McLendon AR:** Clinical examination of ratites. *Proc Assoc Avian Vet* 1992, pp 313-315.
5. **Brown LH, Urban ER, Newman K:** The Birds of Africa. Academic Press, 1982.
6. **Bruning D:** Breeding and rearing rheas in captivity. *Intl Zoo Yearbook* 13:163-167, 1973.
7. **Bruning DF, Dolensek EP:** Ratites. In Fowler ME (ed): *Zoo and Wildlife Medicine* 2nd ed. Philadelphia, WB Saunders Co, 1986, pp 277-291.
8. **Burger AE, Bertram BCR:** Ostrich eggs in artificial incubators: Could their hatching success be improved? *S Afr J Sci* 77:188-189, 1981.
9. **Calle PP, Dierenfeld ES, Robert ME:** Serum alpha-tocopherol in raptors fed vitamin E-supplemented diets. *J Zoo Wildl Med* 20:62-67, 1989.
10. **Cambre RC:** Husbandry, medical and surgical management of ratites. Part III. *Proc Am Assoc Zoo Vet* 1989, pp 123-126.
11. **Cho P:** Comparative gross anatomy of ratites. *Zoo Biol* 3:133-144, 1984.
12. **Cornick JL, Jensen J:** Anesthetic management of ostriches. *J Am Vet Med Assoc* 200:1661-1666, 1992.
13. **Dierenfeld ES:** Vitamin E deficiency in zoo reptiles, birds and ungulates. *J Zoo Wildl Med* 10:3-11, 1989.
14. **Dierenfeld ES, Sandfort CE, Satterfield WC:** Influence of diet on plasma vitamin E in captive peregrine falcons. *J Wildl Manag* 53(1):160-164, 1989.
15. **Dolensek EP, Bruning DF:** Ratites. In Fowler, ME (ed): *Zoo and Wild Animal Medicine*. Philadelphia, WB Saunders Company, 1978, pp 165-180.
16. **Flieg GM:** Nutritional problems in young ratites. *Intl Zoo Yearbook* 13:158-163, 1973.
17. **Fockema A, et al:** Anthelmintic efficacy of fenbendazole against *Libyosstrongylus douglassi* and *Houttuynia struthionis* in ostriches. *J S Afr Vet Assoc* 56:47-48, 1985.
18. **Fowler JD, et al:** Surgical correction of tibiotarsal rotation in an emu. *Comp Anim Pract* 1:26-30, 1987.
19. **Fowler ME:** Comparative clinical anatomy of ratites. *J Zoo Wildl Med* 22:204-227, 1991.
20. **Fowler ME:** Clinical anatomy of ratites. *Proc Assoc Avian Vet*, 1992, pp 307-309.
21. **Frank RK, Carpenter JW:** Coronaviral enteritis in an ostrich (*Struthio camelus*) chick. *J Zoo Wildl Med* 23(1):103-107, 1992.
22. **Gambel GC, Honnas CM:** Surgical correction of impaction of the proventriculus in ostriches. *Compend Cont Educ* 15(2):235-245, 1993.
23. **Gandini GCM, Keffin RH:** Preliminary investigation into the nutrition of ostrich chicks (*Struthio camelus*) under intensive conditions. *J S Afr Vet Assoc* 57:39-42, 1986.
24. **Gandini GCM, et al:** An anesthetic combination ketamine, xylazine and alfaxalone-alphadolone in ostriches. *Vet Rec* 118:729-730, 1986.
25. **Gandini GCM, Keffin RH:** Sex determination of the South African ostrich (*Struthio camelus*). *J S Afr Vet Assoc* 56:209-210, 1985.
- 25a. **Grimes J, Wigle WL, Arizmendi F:** Naturally occurring chlamydial infections of ratites. *Texas Vet*, Aug, 1993, pp 17-18.
26. **Herd RM, Dawson TJ:** Fiber digestion in the emu, a large bird with a simple gut and high rate of passage. *Physio Zoo* 57:70-84, 1984.
27. **Hicks KD:** Ratite production. *Proc Assoc Avian Vet*, 1992, pp 318-325.
28. **Honnas C, et al:** Proventriculotomy to relieve foreign body impaction in ostriches. *J Am Vet Med Assoc* 199:461-465, 1991.
29. **Hoover JP, et al:** Quill mites in an ostrich with rhinitis, sinusitis and air sacculitis. *Companion Anim Pract* 2:23-26, 1988.
30. **Jensen JM, Westerman E:** Amikacin pharmacokinetics in ostrich. *Proc Assoc Zoo Vet*, 1991, pp 238-242.
31. **Jensen JM:** Husbandry, medical and surgical management of ratites: Part I. *Proc Am Assoc Zoo Vet*, 1989, pp 113-118.
32. **Jensen JM, Johnson JH, Weiner ST:** Husbandry and Medical Management of Ostriches, Emus and Rheas. *Wildlife and Exotic Animal Tele Consultants*, 1992.
33. **Julian RJ:** Poisons and toxins. In Calnek BW, et al (eds): *Diseases of Poultry* 9th ed. Ames, Iowa State University Press, 1991, pp 863-884.
34. **Kirkwood JK, Kember NF, Spratt DJ:** The dynamics of bone growth in birds. *Proc Assoc Avian Vet*, 1987, pp 406-407.
35. **Leeds EB:** Tibial fracture repair in a double-waddled cassowary. *J Vet Orthoped* 1(1):21-27, 1979.
36. **Levi A, et al:** Haematological parameters of the ostrich (*Struthio camelus*). *Avian Pathol* 18:321-327, 1989.
37. **Levy A, et al:** Reference blood chemical values in ostriches (*Struthio camelus*). *Am J Vet Res* 50:1548-1550, 1989.
38. **Ley DH, et al:** Mortality of chicks and decreased fertility and hatchability of eggs from a captive breeding pair of ostriches. *J Am Vet Med Assoc* 189:1124-1126, 1986.
39. **Matthews NS, Burba DJ, Cornick JL:** Premature ventricular contractions and apparent hypertension during anesthesia in an ostrich. *J Am Vet Med Assoc* 198:1959-1961.
40. **Mertins JW, Schlater JL:** Exotic ectoparasites of ostriches recently imported into the United States. *J Wildl Dis* 27:180-182, 1991.
41. **Okotie-Eboh G, et al:** Reference serum biochemical values for emus and ostriches. *Am J Vet Res* 53:1765-1768, 1992.
42. **O'Malley P:** Emu farming. *Aust Soc Anim Prod Fed Newsletter* 56:4-6, 1990.
43. **Page CD:** Hand-rearing ostriches in a restricted enclosure. *Assoc Avian Vet Today* 1(4):171-172, 1987.
44. **Perelman B:** Proc 3rd Ann Conf Ostrich Med and Surgery. *Texas AM University*, 1991.
45. **Perelman B, et al:** Pox in ostriches. *Avian Pathol* 17:735-739, 1988.
46. **Puls R:** *Veterinary Trace Mineral Deficiency and Toxicity Information*. Publication 5139, Provincial Veterinary Diagnostic Laboratory, Abbotsford, BC, Canada, 1981, p 194.
47. **Roe M:** Degenerative myopathy in ratites. *Proc Assoc Avian Vet*, 1992, pp 328-335.
48. **Somberg Y, et al:** Newcastle disease in ostriches (*Struthio camelus*): Field case and experimental infection. *Avian Pathol* 18:221-226, 1989.
49. **Smit DJZ:** Ostrich farming in the Little Karoo. Department of Agricultural Technical Services, Republic of South Africa, *Bulletin* 358, 1963.
50. **Speer BL:** An introduction to ratite birds for the avian technician. *Proc Assoc Avian Vet*, 1991, pp 321-327.
51. **Stewart JS:** A simple proventriculotomy technique for the ostrich. *J Assoc Avian Vet* 5(3):139-141, 1991.
52. **Stewart JS:** Hatchery management in ostrich production. In Fowler ME (ed): *Zoo and Wild Animal Medicine* 3rd ed. Philadelphia, WB Saunders Co, 1993.
53. **Stewart JS:** Husbandry and medical management of ostriches. *Proc Assoc Avian Vet*, 1989, pp 208-212.
54. **Stewart JS:** Husbandry, medical and surgical management of ratites: Part II. *Proc Am Assoc Zoo Vet*, 1989, pp 119-122.
55. **Stewart JS:** Overview of the ratite industry: Past, present & future. *Proc Assoc Avian Vet*, 1992, pp 304-306.
56. **Stewart JS:** Ratite incubation. *Proc Assoc Avian Vet*, 1992, pp 336-339.
57. **Tully TN, Shane SM:** Eastern equine encephalomyelitis in emus. *Proc Assoc Avian Vet*, 1992, pp 316-317.
58. **Van Heerden J, et al:** Blood chemical and electrolyte concentrations in the ostrich *Struthio camelus*. *J S Afr Vet Assoc* 56(2):75-79, 1985.
59. **VanDerHeyden N, et al:** Lymphoma in an ostrich. *Proc Assoc Avian Vet*, 1992, pp 310-312.
60. **Von Rutenfeld B, Budras KD:** The bursa cloacae of Struthioniformes in comparison with the bursa of other birds. *J Morph* 172:123-138, 1982.
61. **Wade JR:** Ratite pediatric medicine and surgery. *Proc Assoc Avian Vet*, 1992, pp 340-353.
62. **Wallach JD, Boever WJ:** *Diseases of Exotic Animals*. Philadelphia, WB Saunders Co, 1983, pp 947-850.





## **I HEMATOLOGY AND BIOCHEMISTRY**

Conversions

Psittaciformes

Various Species

Columbiformes

Galliformes

Anseriformes

Ratites

## **II CLASS AVES:**

A LIST OF ORDERS, COMMON  
AND SCIENTIFIC NAMES

## **III DETERMINATION OF METABOLIC SCALING**



# **APPENDIX**

# Hematology and Biochemistry

## CONVERSIONS

### Conversion Factors: SI Units/ Gravimetric Units

Analyte	To convert		Multiply by	To convert		Multiply by
	From	To		From	To	
Albumin	g/dl	g/l	10.0	g/l	g/dl	0.1
Ammonia	μg/dl	μmol/l	0.5871	μmol/l	μg/dl	1.7
Bilirubin	mg/dl	μmol/l	17.1	μmol/l	mg/dl	0.059
Calcium	mg/dl	mmol/l	0.25	mmol/l	mg/dl	4.0
Chloride	mEq/l	mmol/l	1.0	mmol/l	mEq/l	1.0
Chloride	mg/dl	mmol/l	0.272	mmol/l	mg/dl	3.5
Cholesterol	mg/dl	mmol/l	0.02586	mmol/l	mg/dl	38.7
Corticosterone	μg/dl	nmol/l	28.9	nmol/l	mg/dl	0.0346
Cortisol	μg/dl	nmol/l	27.59	nmol/l	mg/dl	0.0362
Creatinine	mg/dl	μmol/l	88.4	μmol/l	mg/dl	0.0113
Globulin	mg/dl	g/l	10.0	g/l	mg/dl	0.1
Glucose	mg/dl	mmol/l	0.05551	mmol/l	mg/dl	18.0
Insulin	μU/ml	pmol/l	7.175	pmol/l	μU/ml	0.1296
Iron	μg/dl	μmol/l	0.1791	μmol/l	μg/dl	5.58
Lead	μg/dl	μmol/l	0.04826	μmol/l	μg/dl	20.72
Magnesium	mEq/l	mmol/l	0.5	mmol/l	mEq/l	2.0
Magnesium	mg/dl	mmol/l	0.4114	mmol/l	mg/dl	2.43
Phosphate (inorganic)	mg/dl	mmol/l	0.3229	mmol/l	mg/dl	3.097
Potassium	mEq/l	mmol/l	1.0	mmol/l	mEq/l	1.0
Pressure	mmHg	Pa (pascal)	0.1333	Pa (pascal)	mmHg	7.5
Progesterone	ng/dl	nmol/l	0.032	nmol/l	ng/dl	31.25
Protein	g/dl	g/l	10.0	g/l	g/dl	1.0
Sodium	mEq/l	mmol/l	1.0	mmol/l	mEq/l	1.0
Thyroxine	μg/dl	nmol/l	12.87	nmol/l	μg/dl	0.0777
Triglycerides	mg/dl	mmol/l	0.01129	mmol/l	mg/dl	88.5
Urea	mg/dl	mmol/l	0.167	mmol/l	mg/dl	6.0
Urea nitrogen (BUN)	mg/dl	mmol/l	0.7140	mmol/l	mg/dl	1.4
Urea nitrogen (BUN)	mg/dl	mmol urea/l	0.3670	mmol urea/l	mg/dl	2.72
Uric acid	mg/dl	mmol/l	59.48	mmol/l	mg/dl	0.0168

With the increasing exchange of knowledge between the United States, Europe and other parts of the world with regard to avian clinical chemistry, it is imperative that a uniform system of units be used to avoid confusion. The World Health Assembly recommended the International System of Units (SI, Systeme International d'Unites) for the health professions in 1977. The SI is the result of many decades of international efforts to develop a universally acceptable system. In many countries and many scientific journals, the use of the SI system is mandatory. It seems that the SI has gained more acceptance in European countries than in the USA. Many American veterinary journals still use conventional units (Journal of the Association of Avian Veterinarians) or a mixture of conventional and SI units (Avian Dis-

eases) while European journals use the SI system (Avian Pathology). Until the SI system is used in all scientific papers and handbooks conversion factors are indispensable.

This table is not complete and further information may be obtained from: Units, Symbols and Abbreviations. London, Royal Society of Medicine Services, 1988, ISBN 0905958780.

In the American veterinary literature the units of weight, temperature and pressure used are often different from SI (derived) units and therefore conversion factors for these quantities will also be given.

## PSITTACIFORMES

### Reference Values for Selected Psittacine Species

Parameter	Budgerigar	African Grey Parrot	Amazon Parrot	Cockatoo	Macaw
TP g/100ml	2.0-3.0	2.6-4.9	3.3-5.3	2.8-4.3	2.5-4.4
Ca mg/100ml	6.4-11.2	7.0-9.5	7.5-9.7	7.6-8.9	6.8-9.9
P mmol/l	0.9-1.9	1.0-5.2	0.8-3.4	1.0-3.6	1.3-4.8
Uric acid mg/100ml	3.0-8.6	3.1-7.0	1.3-5.6	3.5-9.3	2.9-8.5
Crea mg/100ml	0.1-0.4	0.1-0.4	0.1-0.4	0.1-0.4	0.1-0.4
AST U/l	55-154	28-200	35-200	32-180	45-125
ALT U/l	5-20	2-21	4-13	5-12	5-15
LDH U/l	154-271	105-420	65-420	130-353	65-400
CK U/l	54-252	71-408	64-322	27-253	39-384
AP U/l	54-326	24-94	93-311	32-171	25-152
Amyl U/l	187-582	211-519	106-524		276-594
Glu mg/100ml	254-399	224-308	221-300	209-318	230-326
Chol mg/100ml	172-286	217-330	181-310		108-200
Trig mg/100ml	109-271	51-140	59-200		67-125
K mmol/l	2.2-3.7	2.2-3.5	2.1-3.3		2.1-4.5
Na mmol/l	139-159	146-167	127-158		133-160
Cl mmol/l	95-144	110-128	97-127		97-126

Kodak Ektachem®-25°C

Hochleithner M: Reference values for selected psittacine species using a dry chemistry system. J Assoc Avian Vet 3(4):207-209, 1989.

### Reference Values in Psittaciformes

Parameter	African Grey Parrot	Amazon Parrot	Cockatoo	Macaw
Urea mmol/l	0.7-2.4	0.9-4.6	0.8-2.1	0.3-3.3
Creatinine $\mu$ mol/l	23-40	19-33	21-36	20-59
Uric acid $\mu$ mol/l	93-414	72-312	190-327	109-231
Urea:Uric acid ratio	2.4:15.6	4.4:33	2.7:8.9	5:28
Osmolality mOsm/kg	320-347	316-373	317-347	319-378
Sodium mmol/l	154-164	149-164	152-164	150-175
Potassium mmol/l	2.5-3.9	2.3-4.2	3.2-4.9	1.9-4.1
Ca mmol/l	2.1-2.6	2.0-2.8	2.2-2.7	2.2-2.8
Glucose mmol/l	11.4-16.1	12.6-16.9	12.8-17.6	12.0-17.9
AST U/l	54-155	57-194	52-203	58-206
ALT U/l	12-59	19-98	12-37	22-105
GGT U/l	1-3.8	1-10	2-5	<1-5
LDH U/l	147-348	46-208	203-442	66-166
CPK U/l	123-875	45-265	34-204	61-531
Bile acids $\mu$ mol/l	18-71	19-144	23-70	25-71
TP g/l	32-44	33-50	35-44	33-53
Albumin:Globulin ratio	1.4:4.7	2.6:7.0	1.5:4.3	1.4:3.9

Recommendations of the German Society for Clinical Chemistry Enzymes 30°C

Lumeij JT, Overduin LM: Plasma chemistry reference values in psittaciformes. Avian Pathol 19:235-244, 1990.

### Serum Biochemical Methods (37°C) Used in Determining Reference Values in Psittaciformes

Parameter	Method
Albumin	Modified Doumas Method (Bovine Standard)
ALP	Mod. Bowers and McComb
ALT	Mod. IFCC
AST	Mod. IFCC
T. Bili	Mod. Walters and Gerarde
BUN	Mod. Talke and Schubert
Calcium	Mod. Connerty and Briggs
Chloride	Mod. Schoenfeld and Lewellen
Cholesterol	Enzymatic Method
CK	Mod. Oliver and Rosalki
Creatinine	Kinetic Jaffe
GGT	Mod. Szasz
Glucose	Trinder Glucose (Gilford Reagent)
LDH	Mod. Wacker
Phosphorus	Mod. Daly and Ertingshausen
Total CO <sub>2</sub>	Enzymatic PEPC
Total Protein	Mod. Biuret
Triglyceride	Mod. Fossati and Prencipe
Uric Acid	Mod. Fossati
Sodium	Ion Selective Electrode
Potassium	Ion Selective Electrode

From Clubb SL, et al: J Assoc Avian Vet 4(4):222, 1990.

### Serum Biochemical Values for Juvenile Eclectus Parrots

Parameter	30-day Mean (SD)	90-day Mean (SD)	All Mean (SD)
NA (mEq/L)	141 (2)	154 (3)	148 (6)
K (mEq/L)	2.9 (1.0)	2.7 (0.6)	2.8 (0.7)
CL (mEq/L)	105 (3)	115 (3)	111 (5)
CA (mg/dl)	9.5 (0.5)	9.1 (0.4)	9.3 (0.4)
PHOS (mg/dl)	7.9 (0.8)	5.7 (0.9)	6.8 (1.2)
UREA (mg/dl)	1.5 (2.3)	2.0 (3.1)	1.7 (2.4)
CREAT (mg/dl)	0.3 (0.1)	0.4 (0.1)	0.4 (0.1)
UA (mg/dl)	0.8 (0.9)	3.9 (1.5)	2.0 (1.6)
CHOL (mg/dl)	181 (43)	300 (69)	268 (80)
GLUCOSE (mg/dl)	249 (16)	265 (19)	258 (18)
LDH (IU/L)	235 (145)	268 (70)	228 (101)
AST (IU/L)	85 (21)	216 (47)	140 (58)
ALT (IU/L)	4 (3)	7 (3)	4 (3)
ALP (IU/L)	421 (85)	565 (217)	489 (159)
GGT (IU/L)	5 (2)	2 (1)	4 (2)
CK (IU/L)	555 (164)	643 (262)	616 (472)
TP (g/dl)	2.6 (0.4)	2.9 (0.4)	2.9 (0.5)
ALB (g/dl)	1.2 (0.2)	1.3 (0.2)	1.3 (0.3)
GLOB (g/dl)	1.3 (0.3)	1.6 (0.3)	1.5 (0.3)
A:G (ratio)	0.9 (0.1)	0.8 (0.1)	0.9 (0.2)
ALB (Elect) (g/dl)	1.8 (0.5)	2.1 (0.4)	2.2 (0.4)
GLOB (Elect) (g/dl)	0.7 (0.2)	0.7 (0.2)	0.8 (0.2)

From Clubb SL, et al: J Assoc Avian Vet, 4(4):224, 1990.

### Hematology Values for Juvenile Eclectus Parrots

Parameter	30-day Mean (SD)	90-day Mean (SD)	All Mean(SD)
RBC (x 10 <sup>6</sup> /μl)	1.95 (0.28)	3.22 (0.51)	2.69 (0.67)
HB (g/dl)	8.83 (1.15)	15.42 (2.38)	12.46 (3.01)
HCT (%)	33.7 (4.4)	53.8 (3.0)	43.8 (8.4)
MCV (fl)	174 (25)	169 (27)	166 (26)
MCH (pg)	43.9	49.1 (9.9)	45.5 (10.7)
MCHC (g/dl)	261.(2.5)	28.7 (4.1)	27.7 (5.0)
WBC (cells/μl)	18500 (6900)	10900 (3700)	13700 (6300)
WBC Est (cells/μl)	17000 (6000)	10500 (4000)	13500 (6000)
BANDS (%)	0.2 (1.1)	0.4 (0.9)	0.5 (1.5)
HET (%)	62.8 (7.7)	52.1 (10.2)	53.9 (11.4)
LYMPH (%)	30.4 (6.3)	40.8 (10.4)	39.5 (11.5)
MONO (%)	5.5 (3.0)	5.2 (2.7)	5.0 (2.7)
EOS (%)	0.0 (0.0)	0.1 (0.4)	0.1 (0.3)
BASO (%)	1.2 (1.0)	1.5 (1.0)	1.1 (1.0)
BAND # (cells/μl)	34 (188)	48 (111)	70 (221)
HET # (cells/μl)	11800 (5400)	5900 (2800)	7700 (4800)
LYMPH # (cells/μl)	5500 (2100)	4200 (1200)	5100 (2000)
MONO # (cells/μl)	930 (520)	532 (331)	639 (428)
EOS # (cells/μl)	0	9 (43)	8 (44)
BASO # (cells/μl)	209 (199)	175 (158)	152 (169)
HET: LYMPH (ratio)	2.2 (0.8)	1.4 (0.6)	1.6 (0.8)
PP (Refrac) (g/dl)	2.8 (0.6)	3.9 (0.6)	3.5 (0.8)

From Clubb SL, et al: J Assoc Avian Vet 4(4):223, 1990.



## Hematology Values for Juvenile Cockatoos

Parameter	30-day Mean (SD)	90-day Mean (SD)	All Mean (SD)
RBC # (x 10 <sup>6</sup> /μl)	196.0(22) <sup>a</sup>	2.84 (0.49) <sup>b</sup>	2.53 (0.63)
HB (g/dl)	8.12 (0.83) <sup>a</sup>	14.04 (1.23) <sup>c</sup>	11.43 (2.90)
HCT (%)	30.1 (2.8) <sup>a</sup>	47.6 (4.1) <sup>c</sup>	39.7 (9.0)
MCV (fl)	155 (17) <sup>a</sup>	172 (28) <sup>b</sup>	160 (23)
MCH (pg)	38.9 (11.7) <sup>a</sup>	49.0 (12.9) <sup>b</sup>	43.8 (10.8)
MCHC (g/dl)	24.6 (7.9) <sup>a</sup>	28.5 (6.2) <sup>bc</sup>	27.2 (6.1)
WBC# (cells/μl)	13700 (7400) <sup>a</sup>	10000(2800) <sup>b</sup>	12900(6300)
WBC Est (cells/μl)	13200 (6700) <sup>a</sup>	10400 (2800) <sup>b</sup>	13100 (5900)
BAND (%)	1.3 (2.3) <sup>ab</sup>	1.3 (2.3) <sup>ab</sup>	1.3 (2.3)
HET (%)	54.8 (9.7) <sup>a</sup>	49.0 (8.1) <sup>b</sup>	50.8 (11.7)
LYMPH (%)	36.4 (8.1) <sup>a</sup>	43.6 (8.4) <sup>b</sup>	41.2 (11.9)
MONO (%)	6.9 (3.4) <sup>a</sup>	4.9 (3.4) <sup>bc</sup>	5.8 (3.4)
EOS (%)	0 (0)	0 (0.2)	0 (0)
BASO (%)	0.6 (0.9) <sup>ac</sup>	1.2 (1.1) <sup>b</sup>	0.9 (1.1)
BAND # (cells/μl)	150 (275) <sup>a</sup>	130 (290) <sup>a</sup>	160 (325)
HET # (cells/μl)	7800 (5000) <sup>a</sup>	4400 (2200) <sup>b</sup>	6500 (4500)
LYMPH # (cells/μl)	4900 (2600) <sup>a</sup>	3900 (2000) <sup>a</sup>	4900 (2500)
MONO # (cells/μl)	880 (530) <sup>a</sup>	440 (450) <sup>a</sup>	690 (525)
EOS # (cells/μl)	0 (0)	0 (0)	0 (0)
BASO # (cells/μl)	67 (130) <sup>a</sup>	115 (130) <sup>a</sup>	100 (140)
HET: LYMPH (ratio)	1.6 (0.6) <sup>a</sup>	1.2 (0.4) <sup>b</sup>	1.4 (0.8)
PP Est (Refrac) (g/dl)	2.3 (0.5) <sup>a</sup>	4.0 (0.8) <sup>b</sup>	3.2 (0.9)

a,b,c = Values for parameters are statistically different (P<0.05) when letters are different.

From Clubb SL, et al: J Assoc Avian Vet 5(1):20, 1991.

## Hematology Values for Juvenile Umbrella Cockatoos

Parameter	30-day Mean (SD)	90-day Mean (SD)	All Mean
RBC #(x 10 <sup>6</sup> /μl)	1.98 (0.51) <sup>n</sup>	2.75 (0.49) <sup>n</sup>	2.54
HB (g/dl)	7.9 (1.64) <sup>n</sup>	14 (0.92) <sup>n</sup>	11.6
HCT (%)	29.5 (5.65) <sup>n</sup>	46.9 (2.92) <sup>n</sup>	39.3
MCV (fl)	151 (25.6) <sup>n</sup>	175 (28.5) <sup>n</sup>	158.0
MCH (pg)	35.3 (10.03) <sup>n</sup>	51.9 (8.57) <sup>n</sup>	43.6
MCHC (g/dl)	21.8 (10.5) <sup>n</sup>	29.9 (1.1) <sup>n</sup>	27.0
WBC # (cells/μl)	20311 (5717) <sup>s</sup>	10238 (3368) <sup>n</sup>	16567.0
WBC Est (cells/μl)	19190 (5127) <sup>s</sup>	10500 (3184) <sup>n</sup>	16412.0
BAND (%)	1 (2.57) <sup>n</sup>	1.93 (2.76) <sup>n</sup>	1.31
HET (%)	58.4 (11.4) <sup>s</sup>	50 (9.7) <sup>n</sup>	54.1
LYMPH (%)	34.4 (11.5) <sup>n</sup>	41.2 (9.9) <sup>n</sup>	38.1
MONO (%)	5.77 (3.1) <sup>n</sup>	5.29 (3.27) <sup>n</sup>	5.35
EOS (%)	0(0.14) <sup>n</sup>	0.07 (0.27) <sup>n</sup>	0.02
BASO (%)	0.45 (1.05) <sup>n</sup>	1.43 (0.94) <sup>n</sup>	1.03
BAND # (cells/μl)	185 (331) <sup>n</sup>	192 (368) <sup>n</sup>	202.0
HET # (cells/μl)	12041 (4993) <sup>s</sup>	4465 (2595) <sup>n</sup>	8917.0
LYMPH # (cells/μl)	6893 (2581) <sup>s</sup>	3663 (2076) <sup>n</sup>	5695.0
MONO # (cells/μl)	1118 (624) <sup>s</sup>	492 (529) <sup>n</sup>	843.0
EOS # (cells/μl)	0 (0) <sup>n</sup>	0 (0) <sup>n</sup>	0.00011
BASO # (cells/μl)	83 (181) <sup>n</sup>	137 (135) <sup>n</sup>	143.0
HET: LYMPH (ratio)	1.83 (1.05) <sup>n</sup>	1.33 (0.54) <sup>n</sup>	1.64
PP Est (Refrac) (g/dl)	2.69 (0.71) <sup>s</sup>	4.26 (0.55) <sup>n</sup>	3.56

s = Mean is statistically different (P<0.05) from the same parameter in all juvenile cockatoos.

n = Mean is not statistically different (P<0.05) from the same parameter in all juvenile cockatoos.

From: Clubb SL, et al: J Assoc Avian Vet 5(1):20, 1991.

Serum Biochemical Values for Juvenile Cockatoos

Parameter	30-day Mean (SD)	90-day Mean (SD)	All Mean (SD)
NA (mEq/l)	139 (3) <sup>a</sup>	150 (3) <sup>c</sup>	145 (6)
K (mEq/l)	4.0 (0.8) <sup>a</sup>	3.1 (0.4) <sup>b</sup>	3.6 (0.7)
CL (mEq/l)	105 (4) <sup>a</sup>	115 (4) <sup>c</sup>	110 (6)
CA (mg/dl)	9.2 (0.6) <sup>a</sup>	9.5 (1.0) <sup>ab</sup>	9.6 (0.7)
PHOS (mg/dl)	7.0 (0.6) <sup>a</sup>	5.1 (1.0) <sup>c</sup>	6.1 (1.1)
UREA (mg/dl)	1.6 (1.9) <sup>a</sup>	2.6 (2.5) <sup>b</sup>	2.0 (2.2)
CREAT (mg/dl)	0.31 (0.06) <sup>a</sup>	0.42 (0.07) <sup>ab</sup>	0.4 (0.1)
UA (mg/dl)	1.2 (0.9) <sup>a</sup>	5.1 (1.8) <sup>c</sup>	2.9 (2.3)
CHOL (mg/dl)	165 (32) <sup>a</sup>	350 (122) <sup>b</sup>	251 (105)
GLU (mg/dl)	247 (20) <sup>a</sup>	249 (29) <sup>a, b</sup>	253 (24)
LDH (U/l)	393 (348) <sup>a</sup>	367 (218) <sup>a</sup>	371 (285)
AST (U/l)	98 (54) <sup>a</sup>	195 (73) <sup>c</sup>	143 (79)
ALT (U/l)	2 (2) <sup>a</sup>	3 (3) <sup>ab</sup>	2 (3)
ALP (U/l)	593 (202) <sup>a</sup>	478 (167) <sup>c</sup>	579 (239)
GGT (U/l)	2.35 (1.75) <sup>a</sup>	2.79 (1.54) <sup>ac</sup>	2.55 (1.67)
CK (U/l)	595 (205) <sup>a</sup>	368 (156) <sup>b</sup>	510 (235)
TP (g/dl)	2.2 (0.4) <sup>a</sup>	3.1 (0.6) <sup>b</sup>	2.8 (0.7)
ALB (g/dl)	0.8 (0.2) <sup>a</sup>	1.2 (0.3) <sup>b</sup>	1.1 (0.3)
GLOB (g/dl)	1.3 (0.4) <sup>a</sup>	1.9 (0.4) <sup>b</sup>	1.7 (0.5)
A:G (ratio)	0.6 (0.2) <sup>ab</sup>	0.6 (0.1) <sup>b</sup>	0.6 (0.2)
PRE ALB (g/dl)	0.4 (0.1) <sup>a</sup>	0.5 (0.2) <sup>b</sup>	0.5 (0.2)
ALB (Elect) (g/dl)	1.1 (0.3) <sup>a</sup>	1.7 (0.5) <sup>bc</sup>	1.5 (0.5)
ALPHA GLOB (g/dl)	0.2 (0.1) <sup>a</sup>	0.3 (0.2) <sup>c</sup>	0.2 (0.1)
BETA GLOB (g/dl)	0.3 (0.2) <sup>a</sup>	0.3 (0.1) <sup>a</sup>	0.3 (0.1)
GAMMA GLOB (g/dl)	0.2 (0.1) <sup>a</sup>	0.3 (0.1) <sup>b</sup>	0.3 (0.1)

a,b,c = Values for parameters are statistically different (P) when letters are different.

From Clubb SL, et al: J Assoc Avian Vet 5(1):23, 1991.

Serum Biochemical Values for Juvenile Umbrella Cockatoos

Parameter	30-day Mean (SD)	90-day Mean (SD)	All Mean
NA (mEq/l)	139 (1.78) <sup>s</sup>	149 (2.33) <sup>n</sup>	145
K (mEq/l)	4.23 (0.57) <sup>n</sup>	3.13 (0.44) <sup>n</sup>	3.54
CL (mEq/l)	107 (2.8) <sup>s</sup>	115 (3.2) <sup>n</sup>	111
CA (mEq/l)	9.64 (0.39) <sup>s</sup>	9.43 (1.28) <sup>n</sup>	9.77
PHOS (mg/dl)	6.5 (0.44) <sup>s</sup>	4.7 (0.87) <sup>n</sup>	5.55
UREA (mg/dl)	1 (1.78) <sup>n</sup>	1.94 (2.41) <sup>s</sup>	1.61
CREAT (mg/dl)	0.34 (0.07) <sup>n</sup>	0.33 (0.04) <sup>s</sup>	0.37
UA (mg/dl)	0.83 (0.36) <sup>s</sup>	4.95 (1.68) <sup>n</sup>	2.73
CHOL (mg/dl)	180 (37.1) <sup>s</sup>	427 (70.3) <sup>s</sup>	291
GLU (mg/dl)	244 (18.03) <sup>n</sup>	236 (28.24) <sup>s</sup>	244
LDH (U/l)	326 (394) <sup>n</sup>	341 (174) <sup>n</sup>	325
AST (U/l)	84 (17.7) <sup>n</sup>	187 (39.2) <sup>n</sup>	136
ALT (U/l)	1.8 (1.7) <sup>n</sup>	2.69 (1.58) <sup>n</sup>	2.11
ALP (U/l)	426 (100) <sup>s</sup>	404 (104) <sup>s</sup>	440
GGT (U/l)	1.95 (1.73) <sup>n</sup>	2.81 (1.33) <sup>n</sup>	2.66
CK (U/l)	629 (193) <sup>n</sup>	395 (115) <sup>n</sup>	517
TP (g/dl)	2.47 (0.41) <sup>s</sup>	3.25 (0.59) <sup>n</sup>	3.03
A:G (ratio)	0.6 (0.1)	0.62 (0.08)	0.64
PRE ALB (g/dl)	0.43 (0.12) <sup>n</sup>	0.49 (0.13) <sup>n</sup>	0.45
ALB (Elect)(g/dl)	1.27 (0.27) <sup>s</sup>	1.86 (0.35) <sup>n</sup>	1.69
ALPHA GLOB (g/dl)	0.17 (0.05) <sup>n</sup>	0.29 (0.19) <sup>n</sup>	0.26
BETA GLOB (g/dl)	0.39 (0.16) <sup>n</sup>	0.34 (0.14) <sup>n</sup>	0.38
GAMMA GLOB (g/dl)	0.23 (0.06) <sup>n</sup>	0.31 (0.11) <sup>n</sup>	0.29

s = Mean is statistically different ( $\geq$ ) from the same parameter in all juvenile cockatoos.

n = Mean is not statistically different ( $\leq$ ) from the same parameter in all juvenile cockatoos.

From Clubb SL, et al: J Assoc Avian Vet 5(1):22, 1991.

## Hematology Values for Juvenile Macaws

Parameter	30-day Mean (SD)	90-day Mean (SD)	All Mean (SD)
RBC# (x 10 <sup>6</sup> /μl)	1.9 (0.3) <sup>a</sup>	3.7 (0.5) <sup>c</sup>	2.9 (0.8)
HB (g/dl)	7.7 (0.9) <sup>a</sup>	15.4(1.0) <sup>c</sup>	12.3(3.3)
HCT (%)	30.9(3.3) <sup>a</sup>	49.5(2.5) <sup>c</sup>	41.7(8.4)
MCV (fl)	165.5(25.4) <sup>a</sup>	137(19.2) <sup>c</sup>	149 (24.7)
MCH (pg)	41.7 (6.1) <sup>a</sup>	42.8(5.8) <sup>a</sup>	42.3 (6.2)
MCHC (g/dl)	25.1 (1.9) <sup>a</sup>	31.1(1.3) <sup>b</sup>	28.7 (2.9)
WBC (cells/μl)	19300 (8300) <sup>ab</sup>	17700 (4900) <sup>b</sup>	19200 (6900)
WBC Est (cells/μl)	17700 (5100) <sup>ab</sup>	18300 (4500) <sup>ab</sup>	18600 (5880)
BANDS (%)	0.8 (1.6) <sup>a</sup>	0.3(1.2) <sup>a</sup>	0.6 (1.7)
HET (%)	58.9 (11.1) <sup>a</sup>	53.9 (9.4) <sup>ab</sup>	55.3 (10)
LYMPH (%)	33.8(9.7) <sup>a</sup>	41.6 (9.6) <sup>bc</sup>	39.0 (10)
MONO (%)	5.9 (3.3) <sup>a</sup>	3.6 (2.0) <sup>b</sup>	4.4 (2.9)
EOS (%)	0 (0) <sup>a</sup>	0.1 (0.2) <sup>a</sup>	0 (0.2)
BASO (%)	0.7 (0.9) <sup>a</sup>	0.6 (1.2) <sup>ab</sup>	0.5 (1.0)
BANDS # (cells/μl)	134 (344) <sup>a</sup>	59(230) <sup>a</sup>	110 (313)
HET # (cells/μl)	10200 (7600) <sup>ab</sup>	9400 (4000) <sup>bc</sup>	10100 (5800)
LYMPH # (cells/μl)	5500 (3100) <sup>a</sup>	7000 (2500) <sup>b</sup>	6800 (3200)
MONO # (cells/μl)	910 (643) <sup>a</sup>	627 (418) <sup>b</sup>	750 (545)
EOS # (cells/μl)	0 (0) <sup>a</sup>	9.3 (51) <sup>a</sup>	4.6 (35)
BASO # (cells/μl)	115 (190) <sup>a</sup>	75 (165) <sup>ab</sup>	91 (175)
HET: LYMPH (ratio)	2.0 (1.0) <sup>ab</sup>	1.4 (0.6) <sup>bc</sup>	1.6 (0.8)
PP (refrac) (g/dl)	1.8 (0.40) <sup>a</sup>	3.5 (0.4) <sup>c</sup>	2.9 (0.8)

a,b,c = Values for parameters are statistically different (P<0.05) when letters are different.

From Clubb SL, et al: J Assoc Avian Vet 5(3):159, 1991.

## Hematology Values for Juvenile Blue and Gold Macaws

Parameter	30-day Mean (SD)	90-day Mean (SD)	All Mean (SD)
RBC # (x 10 <sup>6</sup> /μl)	1.9 (0.3) <sup>an</sup>	3.5 (0.4) <sup>cn</sup>	2.7 (0.7)
HB (g/dl)	7.9 (0.9) <sup>an</sup>	15 (0.9) <sup>cs</sup>	11 (2.9)
HCT (%)	30 (2.7) <sup>an</sup>	48 (2.0) <sup>cs</sup>	40 (7.7)
MCV (fl)	163 (27) <sup>an</sup>	137 (14) <sup>bn</sup>	149 (22)
MCH (pg)	43 (7.1) <sup>an</sup>	41 (3.7) <sup>an</sup>	38 (13)
MCHC (g/dl)	26 (1.6) <sup>an</sup>	31 (1.4) <sup>cn</sup>	25 (9.5)
WBC # (cells/μl)	19200 (5600) <sup>an</sup>	16600 (4300) <sup>bn</sup>	18928 (5561)
WBC Est (cells/μl)	18300 (5600)	16800 (4300)	18300 (5600)
BAND (%)	0.36 (1.3) <sup>an</sup>	0 (0) <sup>an</sup>	0.12 (0.7)
HET (%)	57 (11.6) <sup>an</sup>	48 (11) <sup>an</sup>	52 (10)
LYMPH (%)	37 (10) <sup>an</sup>	47 (11) <sup>cn</sup>	42 (10)
MONO (%)	5.3 (2.9) <sup>an</sup>	3.8 (2.2) <sup>an</sup>	4.3 (2.7)
EOS (%)	0 (0) <sup>an</sup>	0 (0) <sup>an</sup>	0 (0)
BASO (%)	0.9 (1.1) <sup>an</sup>	1.1 (1.7) <sup>an</sup>	0.9 (1.3)
BANDS # (cells/μl)	0.36 (1.3) <sup>an</sup>	0 (0) <sup>an</sup>	0.12 (0.7)
HET # (cells/μl)	11000 (4600) <sup>an</sup>	8100 (3000) <sup>an</sup>	10000 (3800)
LYMPH # (cells/μl)	7000 (2600) <sup>an</sup>	7700 (2600) <sup>bn</sup>	8000 (3100)
MONO # (cells/μl)	949 (498) <sup>an</sup>	639 (421) <sup>an</sup>	756 (446)
EOS # (cells/μl)	0 (0) <sup>an</sup>	0 (0) <sup>an</sup>	0 (0)
BASO # (cells/μl)	194 (245) <sup>an</sup>	156 (256) <sup>an</sup>	154 (229)
HET: LYMPH (ratio)	1.75 (0.85) <sup>an</sup>	1.19 (0.77) <sup>an</sup>	1.38 (0.69)
PP Est (refrac) (g/dl)	1.87 (0.2) <sup>an</sup>	3.62 (0.5) <sup>cn</sup>	2.86 (0.8)

a,b,c = Values for parameters are statistically different (P<0.05) when letters are different.

s = Mean is statistically different (P<0.05) from the same parameter in all juvenile macaws.

n = Mean is not statistically different (P<0.05) from the same parameter in all juvenile macaws.

From: Clubb SL, et al: J Assoc Avian Vet 5(3):159, 1991.

## Serum Biochemistry Values for Juvenile Macaws

Parameter	30-day Mean (SD)	90-day Mean (SD)	All Mean (SD)
NA (mEq/L)	137 (1.4) <sup>a</sup>	151.1 (2.5) <sup>c</sup>	145 (6.2)
K (mEq/L)	3.3 (0.5) <sup>a</sup>	2.7 (1.0) <sup>b</sup>	2.9 (0.8)
CL (mEq/L)	101 (4) <sup>a</sup>	112 (3) <sup>c</sup>	106 (5.5)
CA (mg/dl)	9.5 (0.5) <sup>a</sup>	10 (0.5) <sup>b</sup>	9.9 (0.5)
PHOS (mg/dl)	7.3 (0.6) <sup>a</sup>	5.6 (0.6) <sup>c</sup>	6.5 (1.0)
UREA (mg/dl)	1.0 (1.7) <sup>a</sup>	3.4 (2.2) <sup>c</sup>	2.4 (2.3)
CREAT (mg/dl)	0.4 (0.1) <sup>a</sup>	0.4 (0.1) <sup>a</sup>	0.4 (0.1)
UA (mg/dl)	0.6 (0.4) <sup>a</sup>	3.9 (1.2) <sup>c</sup>	2.3 (2.1)
CHOL (mg/dl)	119 (37.2) <sup>a</sup>	231 (48.9) <sup>c</sup>	165 (62.0)
GLU (mg/dl)	264 (32) <sup>a</sup>	290 (27) <sup>b</sup>	281 (30)
LDH (U/l)	131 (75) <sup>a</sup>	114 (55) <sup>a</sup>	138 (84)
AST (U/l)	84 (17) <sup>a</sup>	127 (36) <sup>b</sup>	104 (31)
ALT (U/l)	3 (2) <sup>a</sup>	4 (2) <sup>a</sup>	3 (2)
ALP (U/l)	1072 (346) <sup>a</sup>	786 (276) <sup>b</sup>	970 (397)
GGT (U/l)	2.0 (1.0) <sup>a</sup>	1.2 (1.2) <sup>b</sup>	1.8 (1.2)
CK (U/l)	596 (330) <sup>ab</sup>	442 (280) <sup>b</sup>	550 (312)
TP (g/dl)	1.7 (0.3) <sup>a</sup>	3.0 (0.3) <sup>c</sup>	2.6 (0.6)
ALB (g/dl)	0.7 (0.2) <sup>a</sup>	1.4 (0.2) <sup>c</sup>	1.2 (0.3)
GLOB (g/dl)	0.8 (0.4) <sup>a</sup>	1.5 (0.4) <sup>c</sup>	1.3 (0.6)
A:G (ratio)	0.7 (0.4) <sup>a</sup>	0.9 (0.1) <sup>b</sup>	0.8 (0.3)
PRE ALB (g/dl)	0.2 (0.1) <sup>a</sup>	0.5 (0.1) <sup>c</sup>	0.3 (0.1)
ALB (Elect) (g/dl)	1.0 (0.3) <sup>a</sup>	1.8 (0.3) <sup>c</sup>	1.5 (0.4)
ALPHA GLOB (g/dl)	0.2 (0.1) <sup>a</sup>	0.3 (0.1) <sup>a</sup>	0.3 (0.1)
BETA GLOB (g/dl)	0.3 (0.1) <sup>a</sup>	0.4 (0.1) <sup>a</sup>	0.3 (0.2)
GAMMA GLOB (g/dl)	0.2 (0.1) <sup>a</sup>	0.3 (0.2) <sup>a</sup>	0.3 (0.1)

a, b, c = Values for parameters are statistically different (P<0.05) when letters are different.

Clubb SL, et al: J Assoc Avian Vet 5(3):159-160, 1991.

## Serum Biochemical Values for Juvenile Blue and Gold Macaws

Parameter	30-day Mean (SD)	90-day Mean (SD)	All Mean (SD)
NA (mEq/l)	136 (1.25) <sup>an</sup>	150 (2.44) <sup>cn</sup>	142 (6.07)
K (mEq/l)	3.20 (0.49) <sup>an</sup>	2.20 (0.15) <sup>bn</sup>	2.71 (0.64)
CL (mEq/l)	98.8 (2.31) <sup>as</sup>	111 (1.90) <sup>cn</sup>	104 (5.37)
CA (mg/dl)	9.7 (0.24) <sup>an</sup>	10.2 (0.25) <sup>bn</sup>	10 (0.47)
PHOS (mg/dl)	7.2 (0.64) <sup>an</sup>	5.6 (0.50) <sup>cn</sup>	6.6 (0.85)
UREA (mg/dl)	1.2 (1.78) <sup>an</sup>	2.5 (2.07) <sup>an</sup>	1.9 (2.18)
CREAT (mg/dl)	0.3 (0.06) <sup>an</sup>	0.4 (0.07) <sup>bn</sup>	0.4 (0.07)
UA (mg/dl)	0.6 (0.4) <sup>an</sup>	3.4 (0.9) <sup>bn</sup>	1.9 (2.5)
CHOL (mg/dl)	114 (30) <sup>an</sup>	251 (64) <sup>cn</sup>	164 (66.6)
GLUCOSE (mg/dl)	266 (33) <sup>an</sup>	299 (22) <sup>bn</sup>	288 (31)
LDH (U/l)	136 (69) <sup>an</sup>	97 (21) <sup>an</sup>	144 (98)
AST (U/l)	88 (19) <sup>an</sup>	127 (18) <sup>bn</sup>	101 (24)
ALT (U/l)	3 (2) <sup>an</sup>	4 (2) <sup>abn</sup>	4 (3)
ALP (U/l)	1225 (300) <sup>as</sup>	950 (315) <sup>cs</sup>	1200 (390)
GGT (U/l)	2.0 (0.9) <sup>an</sup>	0.9 (0.9) <sup>bn</sup>	1.7 (1.2)
CK (U/l)	498 (162) <sup>an</sup>	330 (85) <sup>an</sup>	540 (267)
TP (g/dl)	1.7 (0.2) <sup>an</sup>	2.9 (0.4) <sup>bn</sup>	2.5 (0.7)
ALB (g/dl)	0.7 (0.1) <sup>an</sup>	1.4 (0.2) <sup>bn</sup>	1.2 (0.3)
GLOB (g/dl)	0.8 (0.3) <sup>an</sup>	1.4 (0.5) <sup>bn</sup>	1.3 (0.6)
A:G (ratio)	0.8 (0.1) <sup>an</sup>	0.9 (0.1) <sup>an</sup>	0.8 (0.2)
PRE ALB (g/dl)	0.2 (0.1) <sup>an</sup>	0.5 (0.1) <sup>cn</sup>	0.3 (0.1)
ALB (Elect) (g/dl)	1.0 (0.3) <sup>an</sup>	1.8 (0.3) <sup>bn</sup>	1.5 (0.4)
ALPHA GLOB (g/dl)	0.2 (0.1) <sup>a</sup>	0.3 (0.1) <sup>a</sup>	0.3 (0.1)
BETA GLOB (g/dl)	0.3 (0.1) <sup>a</sup>	0.4 (0.1) <sup>a</sup>	0.3 (0.2)
GAMMA GLOB (g/dl)	0.2 (0.1) <sup>a</sup>	0.3 (0.2) <sup>a</sup>	0.3 (0.1)

a, b, c = Values for parameters are statistically different (P<0.05) when letters are different.

s = Mean is statistically different (P<0.05) from the same parameter in all juvenile macaws.

n = Mean is not statistically different (P<0.05) from the same parameter in all juvenile macaws.

From Clubb SL: J Assoc Avian Vet 5(3):161, 1991.

## VARIOUS SPECIES

### The Determination of Several Enzymes of Blood Plasma in Different Bird Species

Species	AST	ALT	LDH	AP
Green-cheeked Amazon Parrot	107.96 ± 22.66	9.15 ± 2.34	266.54 ± 75.03	122.3 ± 51.68
Blue-fronted Amazon Parrot	130.48 ± 19.75	15.9 ± 4.3	244.42 ± 76.32	129.48 ± 24.48
African Grey Parrot	63.23 ± 14.46	9.77 ± 3.33	209.19 ± 33.66	47.6 ± 14.12
Budgerigar	101.89 ± 15.2	14.96 ± 4.48	104.7 ± 28.43	194.12 ± 62.92
Homing Pigeon (Male)	46.01 ± 10.94	18.12 ± 3.51	65.51 ± 27.92	196.48 ± 56.35
Homing Pigeon (Female)	33.29 ± 11.44	16.95 ± 2.37	105.3 ± 60.32	225.07 ± 98.96

Monotest Boeringer Mannheim, Temperature not specified. From Baron HW: Vet Diss, München, 1980.

### Uric Acid Concentrations in Blood Plasma

Species	Uric Acid in mmol/l
Budgerigar	0.284 ± 0.056
Blue-fronted Amazon Parrot	0.54 ± 0.057
Green-cheeked Amazon Parrot	0.280 ± 0.052
African Grey Parrot	0.315 ± 0.088
Pigeon	0.239 ± 0.029
Eagle	0.514 ± 0.044
Goshawk	0.498 ± 0.050
Common Buzzard	0.526 ± 0.049

Urica-quant®, Boeringer Mannheim. From Baumann CR: Vet Diss, München, 1980.

### Protein Electrophoresis in Raptors

Parameter	Red Kite	American Kestrel	Montagu's Harrier	Barn Owl
Albumin	1.6 ± 0.5	1.6 ± 0.3	1.8 ± 0.31	1.6 ± 0.6
Alpha 1	0.26 ± 0.14	0.06 ± 0.06	0.50 ± 0.13	0.43 ± 0.24
Alpha 2	0.22 ± 0.12	0.06 ± 0.06		
Beta	0.21 ± 0.16	0.33 ± 0.01	0.24 ± 0.06	0.18 ± 0.07
Gamma	0.43 ± 0.24	0.58 ± 0.12	0.29 ± 0.04	0.42 ± 0.06
A:G Ratio	1.50 ± 0.73	1.34 ± 0.29	1.95 ± 0.37	1.95 ± 0.38

Hernandez, M. Blood chemistry in raptors. Proc European Assoc Avian Vet 1991, 411-419.

### Normal Hematologic and Biochemical Values in Toucans

Cornelissen H.

Parameter	Value
RBC (10 <sup>3</sup> /mm <sup>3</sup> )	2.5-4.5
WBC 10 <sup>3</sup> /mm <sup>3</sup> )	4.0-10.0
PCV (%)	45-60
Buffy Coat (%)	0-1
Hets (%)	35-65
Lymphs (%)	25-50
Basos (%)	0-5
Eosins (%)	0-4
Thromb	present
Calcium (mg/dl)	10-15
Glucose (mg/dl)	220-350
LDH (U/l)	200-400
AST (U/l)	130-330
TP (g/l)	30-50
UA (mg/dl)	4-14
Iron (µg/dl)	<350
TIBC (µg/dl)	<550

## Reference Values from Various Species

Parameter	Captive Bald Eagle	Cuban Amazon Parrot	Quaker Parrots	Blue & Gold Macaw	Hyacinth Macaw
AST (U/l)	101 ± 4.7	201 ± 79		197-297	87-160
ALT (U/l)	10.1 ± 1.5		0-21	99-263	
AP (U/l)		41 ± 21	219-823	162-580	
CK (U/l)	32.9 ± 1.9	217 ± 130			260-563
LDH (U/l)	120 ± 7.2	237 ± 155		183-664	62-89
Cholinesterase	663 ± 32				
Creatinine (mg/dl)				0.3-0.5	0.3-0.5
Uric acid (mg/dl)		2.8 ± 1.5		4-10.1	3.4-10.4
Cholesterol (mg/dl)				139-202	88-109
Glucose (mg/dl)		251 ± 43		286-332	255-324
TP (g/dl)		3.9 ± 0.7	3.8-5.0	3.3-5.6	2.7-3.6
Sodium (mEq/l)		149 ± 7		138-153	144-152
Potassium (mEq/l)		2.7 ± 0.7		5.0-10.4	2.3-6.2
Calcium (mg/dl)		9 ± 0.7		8.8-12.3	
Ionized Calcium (mg/dl)				4.6-6.2	
Phosphor (mg/dl)		2.0 ± 0.9		1.9-2.6	
Iron (µg/dl)				79-135	
BUN (mg/dl)		1.7 ± 2.0		1-5	
Bilirubin (mg/dl)				0.1-0.2	

See references 12, 18, 23, 60, 67 from Chapter 11.

## Blood Chemistry in Canary Finches

Parameter	Mean Value	SD	P <sub>2.5</sub> -P <sub>97.5</sub>
Ca (mg/dl)	7.99	1.84	5.1-13.4
P (mg/dl)	3.28	1.21	1.6-5.6
Na (mmol/l)	139.2	8.18	125-154
Cl (mmol/l)	108.88	8.85	93-123
K (mmol/l)	3.58	0.69	2.7-4.8
Gluc (mg/dl)	345.88	30.27	291-391
Trig (mg/dl)	184.78	55.46	120-312
Crea (mg/dl)	0.48	0.25	0.1-1
NH <sub>3</sub> (mmol/l)	221.18	110.42	87-467
ALT (U/l)	11.58	7.92	2-30
AST (U/l)	98.93	34.73	45-170
LDH (U/l)	1582.63	325.72	1580-1816 <sup>male</sup> 1300-1632 <sup>female</sup>
AP (U/l)	265.05	79.62	146-397
Chol (mg/dl)	165.45	44.52	110-286
Amyl (U/l)	481.78	141.84	277-787
CK (U/l)	302.1	106.94	177-556
TP (g/dl)	2.84	0.75	2.0-4.4
Uric (mg/dl)	8.93	3.31	4.3-14.8

Kodak Ektachem@-25°C. From Schöpf A, Vasicek L: Proc Europ Assoc Avian Vet, Vienna, 1991, pp 437-439.

## COLUMBIFORMES

### Plasma Chemistry Reference Values for Racing Pigeons

Parameter	P2.5-P97.5
Sodium (mmol/l)	141-149
Potassium (mmol/l)	3.9-4.7
Calcium (mmol/l)	1.9-2.6
Magnesium (mmol/l)	1.1-1.8
Inorganic phosphorus (mmol/l)	0.57-1.33
Chloride (mmol/l)	101-113
Plasma iron (μmol/l)	11-33
Iron binding capacity (μmol/l)	30-45
Osmolality (mOsm/kg)	297-317
Glucose (mmol/l)	12.9-20.5
Creatinine (μmol/l)	23-36
Urea (mmol/l)	0.4-0.7
Uric acid (μmol/l)	150-765
Urea:Uric acid (ratio)	1.8 ± 1.8 (mean ± sd)
CPK (U/l)	110-480
AP (U/l)	160-780
AST (U/l)	45-123
ALT (U/l)	19-48
GLDH (U/l)	0-1
LDH (U/l)	30-205
Bile acids (μmol/l)	22-60
GGT (U/l)	0-2.9
Total protein (g/l)	21-33
Albumin:Globulin (ratio)	1.5-3.6
Prealbumin (g/l)	1-4
Alpha globulin (g/l)	2-3
Beta globulin (g/l)	3-6
Gamma globulin (g/l)	1-3

Thyroxine before and 16 h after stimulation with 2 U/kg TSH, 6-35/100-300 nmol/l  
 Corticosterone before and 90 min after stimulation with 250 μg/kg ACTH,  
 0.2-1.24/2.22-11.2 μg/dl  
 Recommendations of the German Society for Clinical Chemistry, Enzymes 30°C.  
 From: Lumeij JT: PhD Thesis, Utrecht University, 1987.

### Blood Cells of Domestic Pigeons

Type Cell	Number
Erythrocytes (x 10 <sup>12</sup> /l)	3.1-4.5
Leukocytes (x 10 <sup>9</sup> /l)	13.0-22.3 morning<evening
Heterophils (x 10 <sup>9</sup> /l)	4.3-6.2
Eosinophils (x 10 <sup>9</sup> /l)	0.1-0.3
Basophils (x 10 <sup>9</sup> /l)	0.1-0.5
Lymphocytes (x 10 <sup>9</sup> /l)	10.9-12.2
Monocytes (x 10 <sup>9</sup> /l)	0.4-1.1
Thrombocytes (x 10 <sup>9</sup> /l)	7.0-27.0
Hemoglobin (mmol/l)	8.1-9.9
Hematocrit (vol %)	42.5

## Plasma Enzyme Activities from Clinically Normal Domestic Pigeons

Vogel C.

Breed	LDH	MDH	AST	ALT	AP	CPK
Racing Pigeon (Male)*	161.4 ± 6.6	85.7 ± 21.9	29.3 ± 9.4	5.8 ± 1.9	47.0 ± 36.3	27.8 ± 13.8
Racing Pigeon (Female)*	121.2 ± 36.2	67.4 ± 14.6	26.7 ± 8.3	5.7 ± 1.7	41.0 ± 13.8	19.1 ± 3.3
Cologne Tumbler (Male)*	142.9 ± 20.1	103.0 ± 0.1	26.4 ± 11.6	6.2 ± 1.5	43.0 ± 1.4	40.5 ± 7.1
Cologne Tumbler (Female)*	119.2 ± 12.2	100.2 ± 19.0	24.8 ± 4.3	5.9 ± 1.4	36.1 ± 0.1	30.9 ± 15.6
Modenas (Male)*	155.6 ± 29.4	83.6 ± 26.3	64.1 ± 15.4	36.1 ± 4.3	6.1 ± 1.4	41.9 ± 9.0
Modenas (Female)*	147.2 ± 49.0			35.6 ± 0.6	6.0 ± 2.8	40.0 ± 12.7
Lynx (Male)**	105.3 ± 60.3	105.6 ± 19.7	33.3 ± 11.4	16.9 ± 2.4	225.1 ± 99.0	24.4 ± 3.9
Lynx (Female)**	65.3 ± 32.5	78.7 ± 9.6	46.1 ± 10.9	18.1 ± 3.5	196.5 ± 56.4	32.4 ± 11.9

\* mU/ml

\*\* U/l

## Blood Parameters for Non-domestic Pigeons

Vogel C.

Parameter	Rock Pigeon	Eastern Turtle Dove
Erythrocytes (10 <sup>6</sup> /mm <sup>3</sup> )	3.7	3.0-4.1
PCV (%)	50.0	
Hb (g %)	16.5	13.9
Leukocytes (mm <sup>3</sup> )		11.1
Heterophils (%)	39.0	17.9
Lymphocytes (%)	53.0	70.8
Monocytes (%)	5.0	4.9
Eosinophils (%)	1.0	2.6
Basophils (%)	2.0	3.8
Thrombocytes (mm <sup>3</sup> )		19.1

## GALLIFORMES

## Hematology of Selected Gallinaceous Birds, Differential

Schales C., Schales K.

Species	Heterophils (%)	Lymphocytes (%)	Monocytes (%)	Basophils (%)	Eosinophils (%)
Domestic Fowl	19.8-32.6	45.0-75.0	8.1-16.5	1.7-4.3	1.5-2.7
Domestic Turkey	43.4	50.6	1.9	3.2	0.9
Pheasant	48.0	34.0	8.0	10.0	1.0
Guineafowl	43.5	36.2	8.4	4.5	7.4
Common Quail	33.8-50.0	40.0-46.0	1.0-2.0	0.8-3.0	1.0-4.0
Japanese Quail	20.8-52.0	40.0-73.6	1.0-2.7	0.2-3.0	1.0-4.3

Note: In both, Curassows and Guans, hemolysis occurs in EDTA tubes. It is not known whether or not this in vitro hemolysis exists in other gallinaceous birds. From: Gylstorff I: Handbuch der Geflügelphysiologie, 1983, pp 280-393; Wallach JD, Boever WJ: Diseases of Exotic Animals, 1983, pp 830-889.



**Hematology of Selected Gallinaceous Birds, Blood Parameters**

Schales C., Schales K.

Species	RBC ( $10^6/ml$ )	PCV (%)	Hb (g %)	MCV ( $\mu m^3$ )	WBC ( $10^3/ml$ )
Domestic Fowl	2.2-3.3	24-43	8.9-13.5	120-137	19.8-32.6
Domestic Turkey	2.3-2.8	36-41	10.3-15.2	129	23.5-26.8
Pheasant	2.2-3.6	28-42	8.0-18.9	104-150	
Guineafowl	1.7-2.8	39-48	11.4-14.9		15.5
Peafowl	2.1	33-41	12.0		
Common Partridge	1.8-3.3	28-34	7.4-11.8	117-155	
Rock Partridge	2.6	37	11.1		
Bobwhite Quail	3.4-5.4	38	11.6-15.8		
Common Quail	3.8-5.4	40-53	12.9-15.8		16.2-24.0
Japanese Quail	3.3-4.1	37-46	10.7-15.8		19.7-25.0
Chachalaca	2.7	35-45			

RBC = Red blood cells, PCV = Packed cell volume, hematocrit, Hb = Hemoglobin, MCV = Mean cell volume (erythrocytes), WBC = White blood cells

From Gylstorff I: Handbuch der Geflügelphysiologie, 1983, pp 280-393; Gylstorff I, Grimm F: Vogelkrankheiten, 1987; Vollmerhaus B, Sinowatz F: Anatomie der Vögel, 1992, pp 159-175.

**Blood Chemistry of Selected Gallinaceous Birds**

Species	Total Protein (g %)	Albumin (g %)	Globulin (g %)	Creatine (mg %)	Uric Acid (mg %)	Glucose (mg %)	Cholesterin (mg %)	Ca (mg %)	P (mg %)	Na (mEq/l)	K (mEq/l)
Domestic Fowl	3.3-5.5	1.3-2.8	1.5-4.1	0.9-1.8	2.5-8.1	227-300	86-211	13.2-23.7	6.2-7.9	131-171	3.0-7.3
Domestic Turkey	4.9-7.6	3.0-5.9	1.7-1.9	0.8-0.9	3.4-5.2	275-425	81-129	11.7-38.7	5.4-7.1	149-155	6.0-6.4
Pheasant	6.9	5.2	1.7		2.3-3.7	335-397			164-172		
Guineafowl	3.5-4.4				2.9-5.1					149-157	
Common Quail	3.4-3.6									180	1.4
Bobwhite Quail								14.1-15.4			
Japanese Quail		1.2-1.9									
Peafowl					1.8-3.7	273-357				154-162	
Rock Partridge					2.5-4.2	270-312				145-163	
Chachalaca					3.7-7.9	235-345				158-164	

From Gylstorff I: Handbuch der Geflügelphysiologie, 1983, pp 280-393; Gylstorff I, Grimm F: Vogelkrankheiten, 1987; Vollmerhaus B, Sinowatz F: Anatomie der Vögel, 1992, pp 159-175.

**Dimension of Erythrocytes in Galliformes**

Species	Long Diameter ( $\mu m$ )	Short Diameter ( $\mu m$ )	Thickness ( $\mu m$ )
Domestic Fowl	10.7-13.0	6.5-7.9	2.4-3.8
Domestic Turkey	15.0-15.5	7.0-7.5	
Pheasant	10.6-11.0	4.0-6.8	
Guineafowl	12.0	6.0	
Peafowl	12.5	7.0	
Common Quail	11.2	6.2	
Rock Partridge	11.3	6.4	

From: Gylstorff I: Handbuch der Geflügelphysiologie, 1983, pp 280-393; Sturkie P: Avian Physiology, 1986, pp 102-121.

**Sedimentation Rate of Erythrocytes of Selected Gallinaceous Birds (mm) Tubes Slanted**

Species	10 min	30 min	60 min	120 min
Domestic Fowl	0.80-1.35	2.06-5.30	3.86-10.5	7.0-18.05
Pheasant			17.2	32.6

Sturkie P: Avian Physiology, 1986, pp 102-121.

## ANSERIFORMES

All tables in this section compiled by Olsen J.

Leukocyte Percentages in Adult Mallards during Different Reproductive States (Mean  $\pm$  SD)\*

Reproductive State	Lymphocytes	Heterophils	Basophils	Monocytes	Eosinophils
<b>Females</b>					
PE	60 $\pm$ 1.4	35 $\pm$ 1.5	2.2 $\pm$ 0.2	2.2 $\pm$ 0.3	0.7 $\pm$ 0.15
EL	58 $\pm$ 3.0	37 $\pm$ 3.0	3.2 $\pm$ 0.5	1.8 $\pm$ 0.2	0.8 $\pm$ 0.30
INC	62 $\pm$ 1.5	33 $\pm$ 1.7	3.0 $\pm$ 0.4	1.9 $\pm$ 0.2	0.2 $\pm$ 0.07
MOLT	68 $\pm$ 2.1	28 $\pm$ 2.4	2.1 $\pm$ 0.5	1.8 $\pm$ 0.5	0.1 $\pm$ 0.08
PR	57 $\pm$ 1.6	37 $\pm$ 1.4	3.2 $\pm$ 0.3	3.2 $\pm$ 0.3	0.2 $\pm$ 0.06
<b>Males</b>					
PE	58 $\pm$ 1.8	36 $\pm$ 1.9	3.4 $\pm$ 0.4	1.9 $\pm$ 0.2	0.9 $\pm$ 0.18
EL	59 $\pm$ 3.0	36 $\pm$ 3.1	2.6 $\pm$ 0.4	1.9 $\pm$ 0.2	0.6 $\pm$ 0.18
INC	66 $\pm$ 1.4	29 $\pm$ 1.4	2.2 $\pm$ 0.3	2.5 $\pm$ 0.3	0.2 $\pm$ 0.17
MOLT	67 $\pm$ 1.9	27 $\pm$ 2.0	2.9 $\pm$ 0.4	2.9 $\pm$ 0.4	0.3 $\pm$ 0.10
PR	54 $\pm$ 1.6	38 $\pm$ 1.5	3.6 $\pm$ 0.3	3.6 $\pm$ 0.3	0.4 $\pm$ 0.10

\* PE (Pre-egg laying); EL (Laying); INC (Incubating); MOLT (Molting); PR (Postreproductive). Males were classified in the same reproductive state as the female with whom they were paired until they began the post-reproductive molt.  
Modified from: Fairbrother A, O'Loughlin D: J Wildl Dis 26(1):78-82, 1990.

## Hematology of Selected Anseriformes (Mean±SD)

Species	RBC (10 <sup>6</sup> /mm <sup>3</sup> )	PCV (%)	Hg (g/dl)	MCV (μ <sup>3</sup> )	MCH (μg)	MCHC (%)	RBC size (μ)	WBC (10 <sup>3</sup> /mm <sup>3</sup> )	Heterophil x10 <sup>3</sup> /mm <sup>3</sup>	Lymph x10 <sup>3</sup> /mm <sup>3</sup>	Monocytes x10 <sup>3</sup> /mm <sup>3</sup>	Basophil x10 <sup>3</sup> /mm <sup>3</sup>	Eosinophil x10 <sup>3</sup> /mm <sup>3</sup>
American Black Duck	2.78 ± 0.22	40.24 ± 4.21	12.96 ± 1.36	144.68 ± 9.96	46.60 ± 3.00	32.23 ± 1.16		19.70 ± 6.60	4.86 ± 1.37	13.03 ± 1.53	1.46 ± 0.99	0.16 ± 0.15	0.22 ± 0.16
Wood Duck	2.79 ± 0.28	45.54 ± 3.41	14.95 ± 1.22	164.24 ± 14.43	54.08 ± 6.74	32.99 ± 3.7		23.58 ± 5.72	8.45 ± 2.59	13.28 ± 1.77	1.05 ± 0.68	0.41 ± 0.23	0.51 ± 0.06
Canvas-back*	2.5-2.6 2.61-3.51 2.61 ± 0.4	51.4-53.0 46.3-60.4 47.0 ± 6.2	13.8-18.1 15.2 ± 2.0	165-209	47-63	28-31	6.6x12.7						
Red Head	2.78 ± 0.3	44.0 ± 7.1	13.5 ± 1.8										
Lesser Scaup*	2.4-2.5 2.45 ± 0.13 2.84	56.5-58.0 57.1 ± 3.1 47.0	16.0				7.5x13.0						
Greater Scaup	2.27 ± 0.7	43.0 ± 1.4	15.9 ± 2.0										
Ring-necked Duck*	2.50 2.54	49.1 47.0	14.3										
Bufflehead*	2.6-2.7 2.64	53.9-54.7 54.3											
Ruddy Duck	2.30 ± 0.3	43.0 ± 3.4	14.6 ± 1.7										
Canada Goose*	1.6-2.6 2.15-2.82	38-58 41.7-56	12.7-19.1	145-174 168.1-229.5	53.7-70	28-29 27.6-34.7	6.9x13.2	13.0-18.5	23.0-42.8	47.8	5.1	2.4	1.9
Aleutian Canada Goose**	2.6±0.4	42±3	(M)13.48±2.01 (F)12.8±1.81		(M)32±5.4 (F)30.6±3.9	(M)5.2±0.8 (F)4.6±0.7							
Snow Goose white phase blue phase	2.24 2.25	45.7 46	14.5 14.0					20.1±4.71	7	12.3	0.2	0.1	0.5
Nene Goose**	2.6±0.2	46±2	(M)15.25±0.74 (F)15.72±0.60		(M)32.5±2.7 (F)34.7±1.7	(M)5.6±0.3 (F)6.3±0.5							
Emden Goose**	2.6±0.3	38±3	(M)12.30±2.23 (F)10.49±1.22		(M)32.2±6.4 (F)29.0±2.9	(M)5.0±0.9 (F)4.2±0.7							
Tule White-fronted Goose**	2.9±0.2	43±2	(M)14.76±1.54 (F)15.43±0.76		(M) 34.6±1.2 (F) 35.6±0.6	(M)4.9±0.4 (F)5.6±0.4							
Trumpeter Swan		41.6±2.6				32.6-36.4							

\* Variations in reference values have resulted from different studies. See Chapter 46, Anseriformes. 61,62,78,79,100,113

\*\* (M) male, (F) female.

## Serum Chemistry Values of Selected Anseriformes (Mean±SD)

	American Black Duck	Canada Goose*	Aleutian Canada Goose**	Tule White-fronted Goose**	Nene Goose**	Embden Goose**	Canvas-back	Lesser Scaup	Ringneck Duck	Bufflehead	Trumpeter Swan
Total Protein (g/dl)	4.32±0.42	5.36±0.27 4.26±0.13	4.80±0.7	4.4±0.4	4.4±0.7	4.4±1.0	3.6-6.8 4.2-4.6	4.2-4.5	3.2-4.0	3.6-4.1	4.5±0.49
Albumin (g/dl)	3.10±0.36 3.04±0.30	2.18±0.13 1.53±0.05	2.1±0.2 2.0±0.2	1.7±0.2 1.8±0.2	1.7±0.2 1.9±0.2	1.5±0.2 1.9±0.7	2.08	1.89	1.68	1.72	
Globulin (g/dl)	1.21±0.52		2.8±0.6	2.7±0.3	2.6±0.5						
A/G ratio	2.71±0.77		0.76±0.13	0.64±0.08	0.71±0.09						
Glucose (mg/dl)	175.83±26.5	219.5±12.39 320.33±28.4	210±31 236±41	221±28 249±30	185±10 192±12	230±31 215±43	180-549				
Calcium (mg/dl)		9.22±0.27 10.57±0.69	10.2±0.7 10.4±0.5	10.1±0.6 10.3±0.4	10.0±0.6 10.5±0.5	10.1±0.6 10.8±1.8					
Phosphorous (mg/dl)	3.23±1.15		2.8±0.9 2.9±0.6	3.6±0.6 3.4±0.8	2.4±0.7 2.4±0.7	3.3±1.3 3.5±0.7					
Sodium (mEq/l)			142±4	146±5	146±3	140					
Chloride (mEq/l)			105±4	112±23	99±4	101					
Potassium (mEq/l)			3.4±0.6	3.3±0.6	2.5±0.4	3.1					
Uric acid (mg/dl)		6.05±0.59 5.75±0.39	8.3±2.3	10.8±1.0	8.0±1.6	7.5±1.9					
Creatinine (mg/dl)			0.8±0.3	0.9±0.2	0.8±0.2	0.8					
Blood urea nitrogen (mg/dl)	1.49±0.36		3±2	3±1	2±1	4±1					
AAT (U/l)	55.9±29.7 18.6±8.2		75±19	98±18	45±17	106±62					
ALP (U/l)	20.9±11.7 131.8±36.7		72±43	78±44	33±8	33±14					
LDH (U/l)	312.8±83.5 244.7±81.8		301±80	361±196	256±68	659±319					
GGT (U/l)			2±3	1±1	2±2	1					
SGPT (U/l)			43±11	50±9	37±7						
SGOT (U/l)			75±17 76±21	104±15 89±19	40±13 49±18	125±82 91±39					
Amylase (U/l)			570±184	454±201	824±32	653					
Total Bilirubin (mg/dl)			0.20±0.07	0.51±0.30	0.12±0.04	0.19±0.14					
Iron µg/dl			234±72	276±90		261					
Total lipids (g/dl)	1.43±0.18		1.38±0.67	1.69±0.64	1.45±0.48						
Triglyceride (mg/dl)		258±60.83 145.2±25.37	151±28	215±51	163±42						
Total cholesterol		239.25±9.91 307±30.9	172±28 172±29	134±14 130±10	230±33 233±23	123±24 162±94	260 - 366				

\* Line 1 = spring; Line 2 = fall

\*\*Line 1 = male; Line 2 = female

Modified from references: 15,27,32,61,75,79,111

## Serum Chemistry and Enzyme Values, Non-reproductive Adult Mallards

Assay	Male		Female	
	Mean	SD	Mean	SD
TPR (g/dl)	3.8	0.7	4.2	0.5
ALB (g/dl)	1.5	0.4	1.7	0.2
GLU (mg/dl)	185.0	47.0	215.0	34.0
AMY (U/l)	2631.0	630.0	2766.0	684.0
CHE (U/l)	794.0	249.0	812.0	197.0
ALT (U/l)	26.3	8.0	29.9	9.9
AST (U/l)	16.2	4.3	15.8	4.7
GGT (U/l)	7.7	4.2	8.0	4.8
ALP (U/l)	26.3	8.0	44.2	22.7
LDH (U/l)	199.0	83.0	147.0	80.0
CA (mg/dl)	9.4	1.9	9.8	1.1
MG (mEq/l)	1.8	0.4	1.8	0.3
PHOS (mg/dl)	2.9	1.0	3.0	1.0
UA (mg/dl)	4.0	1.3	4.5	1.8
CRN (mg/dl)	0.25	0.08	0.28	0.07
BITO (mg/dl)	0.16	0.05	0.16	0.04
BIDI (mg/dl)	0.07	0.01	0.07	0.01

Modified from: Fairbrother A: J Wildl Dis 26(1):67-77, 1990.

## Abbreviations for Anseriforme Appendix Table

TPR (total protein), ALB (albumin), GLU (glucose), AMY (amylase), CHE (cholinesterase), ALT (alanine aminotransferase), AST (aspartate aminotransferase), ALP (alkaline phosphatase), LDH (lactic dehydrogenase), CA (calcium), MG (magnesium), PHOS (phosphorus), UA (uric acid), CRN (creatinine), BITO (total bilirubin), BIDI (direct bilirubin).

## Serum Chemistry and Enzyme Values for Adult Female Mallards of Differing Reproductive States

Assay	Pre-egg laying		Egg laying		Incubating		Molt	
	Mean	SD	Mean	SD	Mean	SD	Mean	SD
TPR (g/dl)	5.6	2.9	6.3	1.2	4.4	0.6	4.5	1.2
ALB (g/dl)	2.0	0.3	2.3	0.2	1.6	0.2	1.7	0.2
GLU (mg/dl)	238.0	21.0	258.0	51.0	211.0	53.0	199.0	30.0
AMY (U/l)	3058.0	527.0	3821.0	741.0	2700.0	626.0	2346.0	1012.0
CHE (U/l)	1337.0	280.0	1563.0	592.0	1002.0	266.0	894.0	219.0
ALT (U/l)	31.0	10.3	34.2	19.4	30.6	13.1	41.1	17.1
AST (U/l)	18.0	3.4	23.7	6.7	22.1	7.4	22.6	12.6
GGT (U/l)	19.8	19.8	199.6	283.0	7.5	4.7	20.8	36.9
ALP (U/l)	63.6	56.8	124.9	56.7	34.3	15.8	36.0	18.1
LDH (U/l)	165.0	50.0	177.0	57.0	215.0	107.0	268.0	2.2
CA (mg/dl)	14.0	4.1	21.9	5.6	10.3	2.0	10.6	4.2
MG (mEq/l)	2.3	0.5	3.6	0.8	1.6	0.3	1.6	0.5
PHOS (mg/dl)	4.6	1.7	8.1	2.4	3.7	1.0	4.1	2.2
UA (mg/dl)	5.2	1.1	9.1	5.1	5.5	1.7	4.9	1.7
CRN (mg/dl)	0.34	0.06	0.33	0.15	0.42	0.15	0.33	0.08
BITO (mg/dl)	0.23	0.08	0.43	0.28	0.20	0.11	0.21	0.05
BIDI (mg/dl)	0.07	0.04	0.15	0.22	0.06	0.04	0.06	0.01

Modified from: Fairbrother A, O'Loughlin D: J Wildl Dis 26(1):78-82, 1990.

**Serum Chemistry and Enzyme Values for Adult Male Mallards of Differing Reproductive States**

Assay	Pre-egg laying		Egg laying		Incubating		Molt	
	Mean	SD	Mean	SD	Mean	SD	Mean	SD
TPR (g/dl)	4.6	0.6	4.5	0.8	4.2	0.5	3.9	0.8
ALB (g/dl)	1.8	0.2	1.6	0.2	1.7	0.3	1.5	0.3
GLU (mg/dl)	234.0	33.0	233.0	32.0	199.0	26.0	185.0	29.0
AMY (U/l)	3123.0	583.0	2869.0	614.0	3203.0	785.0	2991.0	748.0
CHE (U/l)	1326.0	344.0	1380.0	399.0	984.0	470.0	983.0	452.0
ALT (U/l)	34.6	9.4	35.8	13.1	27.6	12.1	28.4	19.2
AST (U/l)	17.3	4.0	20.5	8.0	20.8	15.7	18.1	8.1
GGT (U/l)	8.5	7.6	10.6	12.6	9.3	6.0	16.5	36.0
ALP (U/l)	40.2	25.3	44.1	44.8	38.4	48.0	35.3	44.2
LDH (U/l)	168.0	66.0	219.0	107.0	263.0	203.0	202.0	152.0
CA (mg/dl)	10.9	1.0	11.0	1.9	9.9	1.0	9.3	2.2
MG (mEq/l)	2.0	0.2	2.0	0.4	1.8	0.4	1.8	0.9
PHOS (mg/dl)	3.7	0.9	3.6	0.9	2.8	0.5	3.1	1.4
UA (mg/dl)	5.2	1.2	5.2	1.5	5.7	1.9	4.7	2.3
CRN (mg/dl)	0.35	0.08	0.36	0.10	0.34	0.12	0.30	0.12
BITO (mg/dl)	0.22	0.09	0.20	0.09	0.18	0.04	0.20	0.08
BIDI (mg/dl)	0.07	0.02	0.06	0.01	0.07	0.02	0.08	0.05

Modified from: Fairbrother A: J Wildl Dis 26(1):67-77, 1990.

**Serum Chemistry and Enzyme Values for Juvenile Mallards**

Assay	Age 5 days		Age 18 days		Age 42 days		Age 58 days	
	Mean	SD	Mean	SD	Mean	SD	Mean	SD
TPR (g/dl)	3.4	0.6	4.3	1.3	4.0	0.8	3.2	1.0
ALB (g/dl)	1.4	0.2	1.5	0.3	1.6	0.4	1.4	0.4
GLU (mg/dl)	239.0	54.0	215.0	93.0	189.0	27.0	186.0	45.0
AMY (U/L)	3230.0	760.0	3984.0	1297.0	3005.0	302.0	2395.0	699.0
CHE (U/L)	1423.0	696.0	984.0	559.0	827.0	253.0	818.0	248.0
ALT (U/L)	21.3	9.1	30.5	10.5	26.1	7.0	23.9	7.1
AST (U/L)	22.3	7.4	88.5	54.1	9.4	5.1	17.4	5.7
GGT (U/L)	1.2	2.8	4.6	3.6	5.3	5.7	6.1	3.6
ALP (U/L)	411.0	89.0	386.0	194.0	217.0	32.0	185.0	47.0
LD-L (U/L)	425.0	153.0	629.0	251.0	169.0	70.0	233.0	83.0
CA (mg/dl)	13.0	10.3	9.6	1.7	10.9	1.6	8.4	1.8
MG (mEq/L)	2.8	0.8	1.8	0.7	2.0	0.2	1.6	0.5
PHOS (mg/dl)	7.9	2.8	7.6	1.3	6.2	1.3	5.0	1.7
UA (mg/dl)	12.2	5.4	10.9	3.8	4.0	0.7	4.0	1.8
CRN (mg/dl)	0.47	0.42	0.55	0.65	0.28	0.10	0.21	0.11
BITO (mg/dl)	0.40	0.11	0.43	0.31	0.20	0.0	0.17	0.05
BIDI (mg/dl)	0.08	0.02	0.10	0.04	0.06	0.0	0.06	0.02

Modified from: Fairbrother A: J Wildl Dis 26(1):67-77, 1990.

# RATITES

**Hematological and Biochemical Values for Ratites**
*Stewart J.*

Parameter	Ostrich		Emu		Cassowary	
	Mean	SD	Mean	SD	Mean	SD
WBC ( $\times 10^3/\mu\text{l}$ )	5.5	1.9			18.0	4.5
Heterophils (%)	62.6	7.6			77.7	25.8
Lymphocytes (%)	34.1	7.0			19.7	10.4
Monocytes (%)	2.8	1.3			2.4	2.4
Eosinophils (%)	0.3	0.5				
Basophils (%)	0.2	0.5				
PCV (%)	32.0	3.0			50.8	3.7
RBC ( $\times 10^6/\mu\text{l}$ )	1.7	0.4			2.1	0.3
Hb (g/dl)	12.2	2.0			14.5	0.5
MCV (fl)	174.0	42.0			245.0	41.0
MCHC (g/dl)	33.0	5.0			28.5	1.6
MCH (pg)	61.0	16.0			70.0	11.5
Total protein (g/dl)	3.7	0.7	4.2	0.5	6.1	0.5
Osmolality (mOsm/kg)	286.0	49.0				
Glucose (mg/dl)	250.0	70.0	158.0	22.0	208.0	47.4
Triglycerides (mg/dl)	90.0	45.0	325.0	591.0	180.0	72.0
Cholesterol (mg/dl)	97.0	45.0	104.0	31.0	80.0	16.0
BUN (mg/dl)	2.4	0.6	2.5	0.9	9.3	0.6
Uric acid (mg/dl)	8.2	2.7	4.7	2.0	6.0	0.6
Calcium (mg/dl)	9.2	2.4	10.5	1.3	11.4	0.2
Phosphorus (mg/dl)	4.8	1.2	5.4	1.0	5.0	0.1
Sodium (mEq/l)	147.0	34.0			149.0	2.1
Potassium (mEq/l)	3.0	0.8			4.1	1.0
Chloride (mEq/l)	100.0	16.0			108.0	0.0
Magnesium (mEq/l)	2.2	0.8			2.3	0.3
ALP (U/l)	575.0	248.0	84.0	44.0		
ALT (U/l)	2.0	1.7	15.4	4.3	80.0	21.0
AST (U/l)	131.0	31.0	104.0	24.0	698.0	532.0
GGT (U/l)	1.5	2.9	4.4	3.4		
LDH (U/l)	1565.0	660.0	240.0	91.0	1060.0	516.0
CK (U/l)	688.0	208.0	264.0	170.0		

## Class Aves:

# A List of Orders, Common and Scientific Names

### APTERYGIFORMES

Kiwi *Apteryx* sp.

### STRUTHIONIFORMES

Cassowary *Casuarius* spp.  
Emu *Dromiceius novaehollandiae*  
Greater Rhea *Rhea americana*  
Lesser Rhea *Pterocnemia pennata*  
Ostrich *Struthio camelus*

### TINAMINIFORMES

Tinamou *Eudromia* spp.  
Bustard (Houbara) *Chlamydotis undulata*

### GRUIFORMES

Blue Crane *Tetrapteryx paradisea*  
Brolga *Grus rubicunda*  
Crowned Crane *Balearica pavonina*  
Demoiselle Crane *Anthropoides virgo*  
Hooded Crane *Grus monacha*  
Manchurian Crane *Grus japonensis*  
Sandhill Crane *Grus canadensis*  
Sarus Crane *Grus antigone*  
White-naped Crane *Grus vipio*

### RALLIFORMES

Coot (European) *Fulica atra*

### CHARADRIIFORMES

Sanderling (eroliinae) *Crocetha ulba*  
Turnstone *Arenaria interpres*

### LARIFORMES

Black-headed Gull *Chroicocephalus ridibundus*  
Herring Gull *Larus argentatus*  
Kittiwake (Black-legged) *Rissa tridactyla*

### ALCIFORMES

Black Guillemot *Cephus grylle*

### SPHENISCIFORMES

Fairy Blue (Little) Penguins *Eudyptula minor*  
Humboldt penguin *Spheniscus humboldti*  
Jackass Penguin *Spheniscus demersus*

### PELECANIFORMES

Brandt's Cormorant *Phalacrocorax penicillatus*  
White Pelican *Pelecanus onocrotalus*

### COLUMBIFORMES

#### Pigeons

Crowned (Blue) Pigeon *Goura cristata*  
Nicobar Pigeon *Caloenas nicobarica*  
Pheasant Pigeon *Otidiphaps nobilis*  
Rock-Pigeon (Racing, King) *Columba livia*  
Tooth-billed Pigeon *Didunculus strigirostris*  
Wood-Pigeon *Palumbus palumbus*

#### Doves

African Collared Dove *Streptopelia roseogrisea*  
Collard (African) Dove *Streptopelia roseogrisea*  
Emerald Dove *Chalcophaps indica*  
Galapagos Dove *Nesopelia galapagoensis*  
Luzon Bleeding-heart *Galliculomba luzonica*  
Mourning Dove *Zenaidura macroura*  
Namaqua Dove *Oena capensis*  
Plain-breasted Ground Dove *Columbigallina minuta*  
Turtle-Dove *Streptopelia turtur*

### PSITTACIFORMES

#### Lovebirds

Black-cheeked Lovebird *Agapornis nigrigenis*  
Black-collared Lovebird *Agapornis swindermanus*

Black-winged Lovebird *Agapornis taranta*

Fischer's Lovebird *Agapornis fischeri*  
Grey-headed Lovebird *Agapornis canus*  
Lilian's (Nyassa) Lovebird *Agapornis lilianae*  
Masked Lovebird *Agapornis personatus*  
Red-faced Lovebird *Agapornis pullarius*  
Rosy-faced Lovebird *Agapornis roseicollis*

#### Macaws

Blue and Yellow (Gold) Macaw *Ara ararauna*  
Buffon's Macaw *Ara ambigua*  
Green-winged Macaw *Ara chloroptera*  
Hyacinth Macaw *Anodorhynchus hyacinthinus*  
Illiger's Macaw *Ara maracana*  
Military Macaw *Ara militaris*  
Red-shouldered Macaw *Diopsittaca nobilis*  
Scarlet Macaw *Ara macao*  
Yellow-collared Macaw *Ara auricollis*

#### Conures

Australian Conure *Enicognathus ferrugineus*  
Blue-crowned Conure *Thectocercus acuticaudatus*  
Brown-throated Conure *Eupsittula pertinax*  
Cactus Conure *Eupsittula cactorum*  
Dusky-headed Conure *Eupsittula weddellii*  
Finsch's Conure *Psittacara finschi*  
Golden Conure *Guaruba guarouba*  
Green-cheeked Conure *Pyrhura molinae*  
Green Conure *Psittacara holochlora*  
Maroon-bellied Conure *Pyrhura frontalis*  
Mitre Conure *Psittacara mitrata*  
Nanday Conure *Nandayus nenday*  
Painted Conure *Pyrhura picta*  
Patagonian Conure *Cyanoliseus patagonus*  
Peach-fronted Conure *Eupsittula aurea*  
Pearly Conure *Pyrhura perla*  
Slender-billed Conure *Enicognathus leptorhynchus*  
Sun Conure *Aratinga solstitialis*  
White-eyed Conure *Psittacara leucophthalma*

#### Parakeets

Alexandrine Parakeet *Psittacula eupatria*  
Blossom-headed Parakeet *Psittacula roseata* Biswas  
Blyth's Parakeet *Psittacula caniceps*  
Derbyan Parakeet *Psittacula derbiana*  
Grey-cheeked Parakeet *Brotogeris pyrrhoptera*  
Monk (Quaker) Parakeet *Myiopsitta monachus*  
Moustached Parakeet *Psittacula alexandria*  
Orange-chinned Parakeet *Brotogeris jugularis*  
Red-fronted (Kakariki) Parakeet *Cyanoramphus novaezelandiae*  
Rose-ringed Parakeet *Psittacula krameri*  
Yellow-fronted (Kakariki) Parakeet *Cyanoramphus auriceps*  
Black-headed Caique *Pionites melanocephalus*  
White-bellied Caique *Pionites leucogaster*

#### Parrots

African Grey Parrot *Psittacus erithacus*  
Amboina King Parrot *Alisterus amboinensis*  
Australian King Parrot *Alisterus scapularis*

Barraband's Parrot *Gypopsitta barrabandi*

Black Parrot *Coracopsis nigra*  
Blue-bonnet *Psephotus haematogaster*  
Blue-winged Parrot *Neophema chrysostoma*  
Bourke's Parrot *Neopsephotus bourkii*  
Budgerigar *Melopsittacus undulatus*  
Eastern Rosella *Platycercus eximius*  
Eclectus Parrot *Eclectus oratus*  
Elegant Parrot *Neophema elegans*  
Golden-shouldered Parrot *Psephotus chrysopterygius*  
Great-billed Parrot *Tanygnathus megalorhynchus*  
Green Rosella *Platycercus caledonicus*  
Green-winged King Parrot *Alisterus chloropterus*  
Ground Parrot *Pezoporus wallicus*  
Hawk-headed Parrot *Derophtus accipitrinus*  
Kakapo *Strigops habroptilus*  
Mulga Parrot *Psephotus varius*  
Night Parrot *Geopsittacus occidentalis*  
Northern Rosella *Platycercus venustus*  
Orange-bellied Parrot *Neophema chrysoptera*  
Paradise Parrot *Psephotus pulcherrimus*  
Pennant's Rosella *Platycercus elegans*  
Pileated Parrot *Pionopsitta pileata*  
Princess Parrot *Spathopterus alexandrae*  
Red-capped Parrot *Purpureicephalus spurius*  
Red-rumped Parrot *Psephotus haematonotus*  
Red-winged Parrot *Aprosmictus erythropterus*  
Regent Parrot *Spathopterus anthopeplus*  
Ringneck Parrot *Barnardius zonarius*  
Scarlet-chested Parrot *Neophema splendida*  
Short-tailed Parrot *Graydidascalus brachyurus*  
Superb Parrot *Polytelis swainsonii*  
Thick-billed Parrot *Rhynchopsitta pachyrhyncha*  
Turquoise-Parrot *Neophema pulchella*  
Vasa Parrot *Coracopsis vasa* greater  
Western Rosella *Platycercus icterotis*

#### Amazon parrots

Blue-fronted Amazon *Amazona aestiva*  
Cuban Amazon *Amazona leucocephala*  
Festive Amazon *Amazona festiva*  
Green-cheeked Amazon *Amazona viridigenalis*  
Hispaniolan Amazon *Amazona ventralis*  
Lilac-crowned Amazon *Amazona finschi*  
Mealy Amazon *Amazona farinosa*  
Orange-winged Amazon *Amazona amazonica*  
Puerto Rican Amazon *Amazona vittata*  
Red-spectacled Amazon *Amazona pretrei*  
Red-lore Amazon *Amazona autumnalis*  
Tucuman Amazon *Amazona tucumana*  
Vinaceous Amazon *Amazona vinacea*  
White-fronted Amazon *Amazona albifrons*  
Yellow-lore Amazon *Amazona xanholora*  
Yellow-crowned Amazon *Amazona ochrocephala*  
Yellow-billed (Jamaican) Amazon *Amazona collaria*  
Yellow-shouldered Amazon *Amazona barbadensis*  
Yellow-faced Amazon *Amazona xanithops*

#### Fig parrots

Desmarest's Fig Parrot *Psittaculirostris desmarestii*  
Double-eyed Fig Parrot *Opsittia diophthalma*  
Edward's Fig Parrot *Psittaculirostris edwardsii*  
Salvador's Fig Parrot *Psittaculirostris salvadorii*

#### Pionus parrots

Blue-headed Parrot *Pionus menstus*  
Bronze-winged Parrot *Pionus chalcopterus*  
Dusky Parrot *Pionus fuscus*  
Plum-crowned Parrot *Pionus tumultuosus*  
Red-billed Parrot *Pionus sordidus*  
Scaly-headed Parrot *Pionus maximiliani*  
White-capped Parrot *Pionus senilis*  
White-headed Parrot *Pionus seniloides*

#### Poicephalus parrots

Brown-headed Parrot *Poicephalus cryptoxanthus*  
Cape Parrot *Poicephalus robustus*  
Jardine's Parrot *Poicephalus guillemi*  
Meyer's Parrot *Poicephalus meyeri*  
Niannian Parrot *Poicephalus crassus*  
Red-bellied Parrot *Poicephalus rufiventris*  
Ruppell's Parrot *Poicephalus rueppellii*  
Senegal Parrot *Poicephalus senegalus*  
Yellow-faced Parrot *Poicephalus flavifrons*

#### Lories

Black-capped Lory *Lorius lory*  
Black Lory *Chalcopsitta atra*  
Blue-streaked Lory *Eos reticulata*  
Cardinal-Lory *Chalcopsitta cardinalis*  
Chattering Lory *Lorius garrulus*  
Dusky Lory *Pseudeos fuscata*  
Duyvenbode's Lory *Chalcopsitta duivenbodei*  
Ornate Lory *Trichoglossus ornatus*  
Purple-bellied Lory *Lorius hypoinchrous*  
Purple-naped Lory *Lorius domicella*  
Rainbow-Lory *Trichoglossus haematodus*  
Red Lory *Eos bornea*  
Violet-necked Lory *Eos squamata*  
Yellow-streaked Lory *Chalcopsitta sinitillata*

#### Lorikeets

Goldie's Lorikeet *Psitteuteles goldiei*  
Little Lorikeet *Glossopsitta pusilla*  
Scaly-breasted Lorikeet *Trichoglossus chlorolepidotus*  
Varied Lorikeet *Psitteuteles versicolor*

#### Cockatoos

Black Cockatoo *Calyptorhynchus funereus*  
Blue-eyed Cockatoo *Cacatua ophthalmica*  
Ducorps's Cockatoo *Cacatua ducorps*  
Galah *Eolophus roseicapillus*  
Gang-gang Cockatoo *Callocephalon fimbriatum*  
Glossy Cockatoo *Calyptorhynchus lathami*  
Goffin's Cockatoo *Cacatua goffini*  
Lesser Sulfur-crested Cockatoo *Cacatua sulphurea*  
Little (Slender-bill) Corella *Cacatua sanguinea*  
Long-billed Corella *Cacatua tenuirostris*  
Mitchell's Cockatoo *Cacatua leadbeateri*  
Palm Cockatoo *Probosciger aterrimus*  
Red-vented Cockatoo *Cacatua haematurpygia*  
Red-tailed Cockatoo *Calyptorhynchus magnificus*



## CLASS AVES: A LIST OF ORDERS, COMMON AND SCIENTIFIC NAMES

Salmon-crested Moluccan Cockatoo  
*Cacatua moluccensis*  
Sulfur-crested Cockatoo *Cacatua galerita*  
White Umbrella Cockatoo *Cacatua alba*  
Cockatiel *Nymphicus hollandicus*  
Kaka *Nestor meridionalis*  
Kea *Nestor notabilis*

## ANSERIFORMES

## Subfamily Anseranatinae

## Tribe Anseranatini

Cuban (Black-billed) Whistling (tree) Duck *Dendrocygna arborea*  
Eyton's (Plumed) (Grass) Whistling Duck *Dendrocygna eytoni*  
Fulvous Whistling Duck *Dendrocygna bicolor*  
Javan (Lesser) Whistling Duck *Dendrocygna javanica*  
Magpie Goose *Anseranas semipalmata*  
Northern Black-billed (Red-billed) Whistling Duck *Dendrocygna autumnalis*  
Spotted Whistling Duck *Dendrocygna guttata*  
Wandering (East Indian) Whistling Duck *Dendrocygna arcuata*  
White-Backed(African) Whistling Duck *Thalassornis*  
White-faced Whistling Duck *Dendrocygna viduata*

## Leucanotus

## Tribe Anserini

## (Swans and True Geese)

Bar-headed Goose *Eulabeia indica*  
Barnacle Goose *Branta leucopsis*  
Bewick's Swan *Olor bewickii*  
Black-necked Swan *Stenelides melanocoryphus*  
Black Swan *Chenopis atrata*  
Brent (Russian) (Dark-Bellied) Brant *bernica*  
Canada (Atlantic) Goose *Branta canadensis*  
Coscoroba Swan *Coscoroba coscoroba*  
Emperor Goose *Phalacrocorax canaliculatus*  
Freckled (Monkey) Duck *Stictonetta naevosa*  
Graylag (Domestic) Goose (Western) *Anser anser*  
Lesser White-fronted Goose *Anser erythropus*  
Mute Swan *Cygnus olor*  
Nene (Hawaiian) Goose *Branta sandvicensis*  
Pink-footed Goose *Anser brachyrhynchus*  
Red-breasted Goose *Rufibrenta ruficollis*  
Ross's Goose *Chen rossii*  
Snow (Lesser) (Blue) Goose *Chen caerulescens*  
Swan Goose *Anser cygnoides*  
Trumpeter Swan *Olor buccinator*  
Western (Yellow-billed) Bean Goose *Anser fabalis*  
Whistling Swan *Olor columbianus*  
White-fronted (European) Goose *Anser albifrons*  
Whooper Swan *Olor cygnus*

## Sub-Family Anatinae

## Tribe Tadomini

## (Shelducks and Sheldgeese)

Abyssinian Blue-winged Goose *Cyanochen cyanopterus*  
Andean Goose *Chloephaga melanoptera*  
Ashy-headed Goose *Chloephaga poliocephala*  
Australian Shelduck *Casarca tadornoides*  
Cape Barren (Cereopsis) Goose *Cereopsis novehollandiae*  
Common (European) Shelduck *Tadorna tadorna*  
Crested Shelduck *Pseudotadorna cristata*  
Egyptian Goose *Alopochen aegyptiacus*  
Kelp (Patagonian) (Lesser) Goose *Chloephaga hybrida*

Magellan (Lesser) (Upland) Goose *Chloephaga picta*  
Orinoco Goose *Neochen jubatus*  
Paradise (New Zealand) Shelduck *Casarca variegata*  
Radjah Shelduck (Moluccan) (Black-Backed) *Radjah radjah*  
Ruddy-headed Goose *Chloephaga rubidiceps*  
Ruddy Shelduck *Casarca ferruginea*  
South African (Cape) Shelduck *Casarca cana*  
Spur-winged (Gambian) Goose *Plectropterus gambensis*

## Tribe Cairini (Perching Ducks)

African (South) Black Duck *Melananassa sparsa*  
African Pygmy Goose *Nettapus auritus*  
American (Baldpate) Wigeon *Mareca americana*  
Austrian Shoveler *Spatula rhynchotis*  
Australian Wood Duck (Maned Goose) *Chenonetta jubata*  
Bahama (Lesser) (Northern) White-Cheeked Pintail *Paeilonetta bahamensis*  
Baikal Teal *Nettion formosum*  
Blue-winged (Prairie) Teal *Spatula discors*  
Brazilian (Lesser) Teal *Amazonetta brasiliensis*  
Brown (Chilian) Pintail *Dafila georgica*  
Brown (New Zealand) Teal *Nettion aucklandicum*  
Cape (South African) Shoveler *Spatula capensis*  
Cape Teal *Nettion capense*  
Chestnut Teal *Nettion castaneum*  
Chiloe Wigeon *Mareca sibilatrix*  
Cinnamon (Northern) Teal *Spatula cyanoptera*  
Common (European Green-Winged) Teal *Nettion crecca*  
Common (Northern) Shoveler *Spatula clypeata*  
Common (Northern) Pintail *Dafila acuta*

Cotton (Indian) Pygmy Goose (Cotton) Teal *Nettapus coromandelianus (albigennis)*  
European (Eurasian) Wigeon *Mareca penelope*  
Falcated Duck *Eunetta falcata*  
Gadwall (Gray Duck) *Chaulelasmus streperus*  
Garganey *Querquedula querquedula*  
Green Pygmy Goose *Nettapus pulchellus*  
Grey Teal (East Indian) *Nettion gibberifrons*  
Hartlaub's Duck *Pteronetta hartlaubii*  
Hottentot Teal *Punanetta hottentota*  
Knob-billed (Old World Comb) Duck *Sarkidiornis melanotos*  
Madagascan (Bernier's) Teal *Nettion bernieri*  
Mandarin Duck *Dendrocygna galericulata*  
Muscovy Duck *Cairina moschata*  
Red (Argentine) Shoveler *Spatula platalea*  
Red-billed Pintail *Paeilonetta erythrorhyncha*  
Ringed Teal *Callonetta leucophrys*  
Silver (Northern) (Versicolor) Teal *Punanetta versicolor*  
South American (Chilean Speckled) Teal *Nettion flavirostre*  
White-winged Wood Duck *Asarcornis scutulatus*  
Wood Duck (North American) (Carolina Duck) *Aix sponsa*

## Tribe Anatini (Dabbling Ducks)

American (North) Black Duck *Anas fulvigula*  
Blue (Mountain) Duck *Hymenolaimus malacorhynchus*  
Bronze-winged (Spectacled) Duck *Specularnas specularis*  
Crested (Patagonian) Duck *Lophonetta specularioides*

Falkland Flightless Steamer-Duck *Tachyeres brachypterus*  
Flying Steamer Duck *Tachyeres patachonicus*  
Grey Duck (New Zealand) *Anas superciliosa*  
Hawaiian Duck (Koloa) *Anas wyvilliana*  
Laysan Teal *Anas laysanensis*  
Magellanic Flightless Steamer-Duck *Tachyeres pteneres*  
Mallard (Northern) (Domestic) Duck *(Anas platyrhynchos)*  
Marbled Teal *Marmaronetta angustirostris*  
Meller's Duck *Anas melleri*  
Philippine Duck *Anas luzonica*  
Pink-eared (Zebra) Duck *(Malacorhynchus membranaceus)*  
Salvadori's Duck *Salvadorina waigiuenis*  
Spot-billed (Indian) Duck *Anas poecilorhyncha*  
Torrent (Chilean) Duck *Merganetta armata*  
Yellow-billed (South African) Duck *Anas undulata*

## Tribe Aythya (Pochards)

Australasian (White-Eye) (Hardhead) Pochard *Aythya australis*  
Baer's Pochard (Siberian White-Eye) *Aythya baeri*  
Canvasback *Aythya valisineria*  
Common (Ferruginous) (White-Eyed) Pochard *Aythya nyroca*  
European (Eurasian) Pochard *Aythya ferina*  
Greater (European) Scaup *Aythya marila*  
Lesser Scaup *Aythya affinis*  
Madagascan (White-Eye) Pochard *Aythya innotata*  
New Zealand Scaup (Black Teal) *Aythya novaeseelandiae*  
Pink-headed Duck *Rhodonessa caryophyllace*  
Red-Crested Pochard *Netta rufina*  
Redhead Duck *Aythya americana*  
Ring-necked Duck *Aythya collaris*  
Rosy-bill (Rosy-billed) Pochard *(Metopiana peposaca)*  
Southern (South American) Pochard *Phaeoaythya erythroptalma*  
Tufted Duck *Aythya fuligula*

## Tribe Somateria (Eiders)

Common (European) Eider *Somateria mollissima*  
King Eider *Somateria spectabilis*  
Spectacled (Fischer's) Eider *Somateria fischeri*  
Steller's Eider *Polysticta stelleri*

## Tribe Mergina (Sea Ducks)

Auckland Island Merganser *Mergus australis*  
Barrow's Goldeneye *Glaucionetta islandica*  
Black (European) Scoter *Melanitta nigra*  
Brazilian Merganser *Mergus octosetaceus*  
Bufflehead *Bucephala albeola*  
Common (European) Goldeneye *Glaucionetta clangula*  
Goosander (Curasian) Merganser *Mergus merganser*  
Harlequin (Atlantic) Duck *Histrionicus histrionicus*  
Hooded Merganser *Lophodytes cucullatus*  
Labrador Duck *Camptorhynchus labradorius*  
Long-tailed (Oldsquaw) Duck *Clangula hyemalis*  
Red-breasted (Common) Merganser *Mergus serrator*  
Scaly-sided (Chinese) Merganser *Mergus squamatus*  
Smew *Mergellus albellus*  
Surf Scoter *Melanitta perspicillata*  
White-winged (European) (Velvet) Scoter *Melanitta fusca*

## Tribe Oxyurini (Stiff-Tailed Ducks)

Black-headed Duck *Heteronetta atricapilla*  
Blue-billed (Australian) Duck *Oxyura australis*  
Lake (Argentine) (Ruddy) (Blue-billed) Duck *Oxyura vittata*  
Maccoa Duck *Oxyura maccoa*  
Masked Duck *Oxyura dominica*  
Musk Duck *Biziura lobata*  
Ruddy Duck (North American) *Oxyura jamaicensis*  
White headed Duck *Oxyura leucocephala*

## RAPTORS

American Kestrel (Sparrow Hawk) *Tinnunculus sparverius*  
Bald Eagle *Haliaeetus leucocephalus*  
Barn Owl *Tyto alba*  
Common (European) (Rock) Kestrel *Tinnunculus tinnunculus*  
Common Buzzard *Buteo buteo*  
Eagle Owl *Bubo bubo*  
Eastern Turkey Vulture *Cathartes aura*  
European Sparrow Hawk *Accipiter nisus*  
Forest Eagle Owl *Bubo nipalensis*  
Golden Eagle *Aquila chrysaetos*  
Goshawk *Accipiter gentilis*  
Great Horned Owl *Bubo virginianus*  
Grey Eagle Buzzard *Geranoaetus melanoleucus*  
Griffon Vulture *Gyps fulvus*  
Little Owl *Athene noctua*  
Long-eared Owl *Asio otus*  
Merlin (Pigeon) Hawk *Aesalon columbarius*  
Peregrine Falcon *Hierofalco peregrinus*  
Prairie Falcon *Hierofalco mexicanus*  
Red Kite *Milvus milvus*  
Red-necked Falcon *Chiquera chiquera*  
Rough-legged Buzzard *Buteo lagopus*  
Saker Falcon *Hierofalco cherrug*  
Screech Owl *Megascops asio*  
Short-eared Owl *Asio flammeus*  
Snowy Owl *Nyctale scandiaca*  
South American Black-collared Hawk (Fishing Buzzard) *Busarellus nigricollis*  
Striped Owl *Asio clamator*  
Tengmalm's Owl *Aegolius funereus*  
Ural Owl *Strix uralensis*

## CICONIIFORMES

Black Stork *Ciconia nigra*  
Cattle Egret *Bubulcus ibis*  
Greater Adjutant Stork *Leptoptilos dubius*  
Grey Heron *Ardea cinerea*  
Hermit Ibis *Geronticus eremita*  
Marabou Stork *Leptoptilos crumeniferus*  
Night Heron (Black-Crowned) *Nycticorax nycticorax*  
Striated Heron *Butorides striatus*  
White Stork *Ciconia ciconia*  
Yellow-crowned Night Heron *Nyctanassa violacea*

## GALLIFORMES

Brush-Turned *Alectura lathami*

## Numidinae

Crested Guinea fowl *Guttera pucherani*  
Domestic Guinea fowl *Numida meleagris forma domestica*  
Helmeted Guinea fowl *Numida meleagris*  
Plumed Guinea fowl *Guttera plumifera*  
Vulturine Guinea fowl *Acyrtium vulturinum*

## Pavoninae

Congo Peafowl *Afropavo congensis*  
Green Peafowl *Pavo muticus*  
Indian Peafowl *Pavo cristatus*

## Meleagridinae

Common Turkey *Meleagris gallopavo*  
Domestic Turkey *Meleagris gallopavo forma domestica*  
Oscillated Turkey *Meleagris ocellata*

**Argusianinae**

Bronze-tailed Peacock-Pheasant  
*Polyplectron chalcurum*  
Crested Argus *Rheinardia ocellata*  
Great Argus *Argusianus argus*  
Grey Peacock-Pheasant *Polyplectron bicalcaratum*  
Palawan Peacock-Pheasant  
*Polyplectron emphanum*

**Phasianinae**

Bar-tailed Pheasant *Calophasis humiae*  
Blue-eared Pheasant *Crossoptilon auritum*  
Brown-eared Pheasant *Crossoptilon mantchuricum*  
Bulwer's Watted Pheasant *Lophura bulweri*  
Cheer Pheasant *Catreus wallichii*  
Common (Ring-necked) Pheasant  
*Phasianus colchicus*  
Copper Pheasant *Graphephasianus soemmeringii*  
Elliot's Pheasant *Calophasis ellioti*  
Golden Pheasant *Chrysolophus pictus*  
Lady Amherst's Pheasant  
*Chrysolophus amherstiae*  
Mikado Pheasant *Calophasis mikado*  
Reeve's Pheasant *Syrnaticus reevesii*  
Salvadori's Pheasant *Lophura inornata*  
Siamese Fireback *Lophura diardi*  
Silver Pheasant *Lophura nycthemera*  
Swinhoe's Pheasant *Lophura swinhoii*

**Lophophorinae**

Himalayan Monal Lophophorus  
*impejanus*

**Pucrasiniinae**

Koklass Pucrasia *macrolopha*

**Ithagininae**

Blood Pheasant *Ithaginis cruentus*

**Gallinae**

Domestic Fowl *Gallus gallus formadomestica*  
Red Junglefowl *Gallus gallus*

**Tragopaninae**

Satyr Tragopan *Tragopan satyra*

**Philopachinae**

Stone Partridge *Ptilopachus petrosus*

**Percidinae**

Black Francolin *Francolinus francolinus*  
Chinese Bamboo Partridge  
*Bambusicola thoracica*  
Chukar Partridge *Alectoris chukar*  
Common Partridge *Perdix perdix*  
Common Quail *Coturnix coturnix himalayensis*  
Japanese Quail *Coturnix japonica*  
Jungle Bush Quail *Perdica asiatica*  
Painted Quail *Coturnix chinensis*  
Redlegged Partridge *Alectoris rufa*  
Rock Partridge *Alectoris graeca*  
Roulroul (Crested Wood Partridge)  
*Rollulus roulroul*

**Odontophorinae**

Bobwhite Quail *Colinus virginianus*  
California Quail *Callipepla californica*  
Gambel's Quail *Callipepla gambelii*  
Scaled Quail *Callipepla squamata*

**Tetraoninae**

Black Grouse *Lyrurus tetrix*  
Blue Grouse *Dendragapus obscurus*  
Common Capercaillie *Tetrao urogallus*  
Hazelhen (Common) *Tetrastes bonasia*  
Prairie Chicken *Tympanuchus cupido*  
Red Grouse *Lagopus lagopus scoticus*  
Ruffed Grouse *Bonasa umbellus*  
Sage Grouse *Centrocercus urophasianus*  
Sharp-tailed Grouse *Tympanuchus phasianellus*  
Spruce Grouse *Falcipennis canadensis*  
Willow Ptarmigan (-Grouse) *Lagopus lagopus*

**Cracidae**

Black-billed Turaco *Tauraco schuetti*  
Common Piping Guan *Aburria pipile*  
Great Curassow *Crax rubra*  
Guinea Turaco *Tauraco persa*  
Helmeted (Northern) Curassow *Pauxi pauxi*  
Lady Ross's Turaco *Musophaga rossae*  
Purple-crested Turaco *Tauraco porphyreolophus*  
Razor-billed Curassow *Mitu mitu*  
Wattled Curassow *Crax globulosa*  
White-crested Turaco *Tauraco leucolophus*

**UPUPIFORMES**

Hoopoe *Upupa epops*

**CAPRIMULGIFORMES**

Indian Edible-nest Swiftlet *Collocalia unicolor*  
Quetzal *Pharomachus mocinno*  
Tawny Frogmouth *Podargus strigoides*

**PASSERIFORMES**

African Silverbill *Euodice cantans*  
American Bare-eyed Thrush  
*Planesticus nudigenis*  
American Goldfinch *Spinus tristis*  
American Tree-Sparrow *Spizella arborea*  
Antbirds and gnateaters *Formicariidae*  
Apostle-bird *Struthidea cinerea*  
Ashy (Brown-eared) Bulbul *Hemixos flavala*  
Australian Magpie *Gymnorhina tibicen*  
Avadavat (Strawberry-Finch, Red Munia) *Amandava amandava*  
Barn-Swallow *Hirundo rustica*  
Bearded Manakin *Manacus manacus*  
Bengalese (Society) Finch *Lonchura domestica*  
Birds of Paradise *Paradisaeidae*  
Black (Pied) (Pied Bell-Magpie)  
Currawong *Strepera graculina*  
Black-eared Wheatear *Oenanthe hispanica*  
Black-faced Cuckoo-Shrike *Coracina novaeollandiae*  
Black-faced Babbler *Turdoides melanops*  
Black-throated Grass-(Parson)-Finch  
*Poephila cincta*  
Blackbird (Common) *Merula merula*  
Blue jay *Cyanocitta cristata*  
Blue Tit *Cyanistes caeruleus*  
Blue Waxbill (Angola Cordon-bleu)  
*Uraeginthus angolensis*  
Broad-tailed (Long-tailed) Paradise  
Whydah *Steganura interjecta*  
Brown-headed Cowbird *Molothrus ater*  
Brown Tree-Creeper *Climacteris picumnus*  
Bushlark (Horsfield's, Cinnamon)  
*Mirafrava javanica*  
Canary *Serinus canaria*  
Cape May Warbler *Dendroica tigrina*  
Cardinal (Crested) *Paroaria coronata*  
Catbird *Dumetella carolinensis*  
Cedar Waxwing *Bombycilla cedrorum*  
Chaffinch *Fringilla coelebs*  
Chatham Islands Robin (-Flycatcher)  
*Miro traversi*  
Common Bullfinch *Pyrrhula pyrrhula*  
Common Cardinal *Cardinalis cardinalis*  
Common Raven *Corvus corax*  
Cowbird *Molothrus aeneus*  
Crested Lark *Galerida cristata*  
Crested Oropendola *Psarocolius decumanus*  
Crimson Finch *Neochmia phaeton*  
Cuban (Grassquit) Finch *Tiaris canora*  
Cutthroat Finch *Amadina fasciata*  
Diamond Firetail (Diamond Sparrow)  
*Stagonopleura guttata*  
Double-barred Finch *Stizoptera bichenovii*  
Eastern Bluebird *Sialia sialis*  
European Goldfinch *Carduelis carduelis*  
European Robin *Erithacus rubecula*  
Fox Sparrow *Passerella iliaca*  
Glossy (Superb) Starling *Lamprospere superbus*  
Golden-collared Manakin *Manacus vitellinus*  
Golden-headed Manakin *Pipra erythrocephala*  
Goldfinch *Carduelis carduelis*  
Gouldian Finch *Chloebia gouldiae*  
Great Tit *Parus major*  
Green Avadavat *Stictospiza formosa*  
Green Catbird *Ailuroedus crassirostris*  
Greenfinch *Carduelis chloris*  
Greenfinch *Chloris chloris*  
Grey-headed Wheatear *Oenanthe moesta*  
Hawaiian Crow *Corvus tropicus*  
Hawfinch *Coccothraustes coccothraustes*  
Hooded Siskin *Spinus magellanicus*  
House Sparrow *Passer domesticus*  
Jackdaw *Coleus monedula*  
Java Sparrow (Rice Bird) *Padda oryzivora*  
Large-billed Seed Finch (Suriname Finch, Twa twa's) *Oryzoborus crassirostris*  
Long-tailed (Shaft-tailed) Grass-Finch  
*Poephila acuticauda*

Magpie *Pica pica*  
Melba Finch (Grey-naped) *Pytilia pytilia melba*  
Mockingbird *Mimus polyglottos*  
Mynah (Hill) birds *Gracula religiosa*  
Nutmeg Mannikin (Spice-Finch)  
(Spotted Munia) (Rice-bird)  
*Lonchura punctulata*  
Orange-cheeked Waxbill *Estrilda melpada*  
Painted Firetail *Emblema picta*  
Pekin Robin *Leiothrix lutea*  
Pied wagtail *Motacilla alba*  
Pin-tailed Parrot-Finch *Erythrura prasina*  
Purple Grackle *Quiscalus quiscula*  
Red (hooded) Siskin *Spinus cucullatus*  
Red-breasted Flycatcher *Erythrosterna parva*  
Red-capped Manakin *Pipra mentalis*  
Red-cheeked (Cordon-blue) Blue  
Waxbill *Uraeginthus bengalus*  
Red-headed Barbet *Eubucco bourcierii*  
Red Wattlebird *Anthochaera carunculata*  
Red-winged *Pytilia* (American Aurora finch, Crimson-winged Waxbill)  
*Pytilia phoenicotera*  
Rock Robin *Petroica archboldi*  
Rook (European) *Corvus frugilegus*  
Rothschild's (Bali) Myna *Leucosparr rothschildi*  
Rufous-sided Towhee *Pipilo erythrophthalmus*  
Rufous-tailed Weaver *Histurgops ruficauda*  
Siberian Rubythroat *Calliope calliope*  
Silvereye *Zosterops lateralis*  
Siskin (Euroasian) *Spinus spinus*  
Sky-lark *Alauda arvensis*  
Spotted Pardalote *Pardalotus punctatus*  
Starling (Common) *Sturnus vulgaris*  
Super Lyrebird *Menura novaeollandiae*  
Swainson's (Olive-backed) Thrush  
*Catharus ustulatus*  
Tree Sparrow (Eurasian) *Passer montanus*  
Ultramarine Grosbeak *Cyanoloxia cyanea*  
Vesper Sparrow *Poocetes gramineus*  
Violaceous Euphonia *Euphonia violacea*  
Waxwing (Bohemian) *Bombycilla garrulus*  
Weebill *Smicornis brevirostris*  
Welcome Swallow *Hirundo neaxena*  
White-rumped Canary *Ochrospiza leucopygia*  
White-throated Sparrow *Zonotrichia albicollis*  
Wood Thrush *Hylocichla mustelina*  
Yellow-backed (Orange-winged) *Pytilia*  
(Red-faced Waxbill) *Pytilia afra*  
Yellow-tufted (Helmeted) honeyeater  
*Lichenostomus melanops race cassidex*  
Zebra Finch *Taeniopygia guttata*

## II

# Determination of Metabolic Scaling

### Step-by-step Technique for Determining Metabolic Scaling

Harrison G.

One may determine the quantity of enteral nutritional product for a bird from information supplied in Chapter 15. This mathematical calculation requires a scientific calculator. The following is offered to assist one not familiar with such calculations.

#### Required Data and Formulas

$BMR = K(W_{kg})^{0.75}$  = Basic Metabolic Rate.

K = a theoretical constant for kcal required per 24 hours and varies with the species of bird. K is 129 for passerines and 78 for non-passerines.

$MER = 1.5 \times BMR$  = Metabolizable Energy Rate.

$W_{kg}$  is the weight of the bird in kg.

#### To determine the BMR:

1. Divide the bird's weight in grams by 1000 to determine the  $W_{kg}$ .
2. With this number entered in the calculator, press the  $y^x$  function key.
3. Input 0.75. Then push =.
4. Multiply the number determined in step 3 by the K value for the bird (78 if it is a psittacine bird).
5. This number is the BMR for the patient in kcal/day.

#### To determine the quantity of enteral nutrient required;

1. Multiply the calculated BMR by 1.5.
2. This number is the MER in kcal per day.
3. Determine the total kcal/day of nutrients required, by multiplying the MER by the stress factor (see Table 15.4).
4. Determine the mls/day of enteral nutrient to use (see Table 15.5), by dividing the value determined in line 3 by the Calories (kcal)/ml in the enteral formula selected.
  - a. Example: ISO cal contains 1 kcal/ml. The value determined in line 3 would be divided by 1 and the resulting number would be the ml/day of this product that the patient should receive.
  - b. Example: ISO cal HCN contains 2 kcal/ml. The value determined in line 3 would be divided by 2 and the resulting number would be the ml/day of this product that the patient should receive.
5. The volume of enteral formula/feeding is determined by dividing the total number of mls required (answer from line 4) by the number of feedings per day (generally four to six).

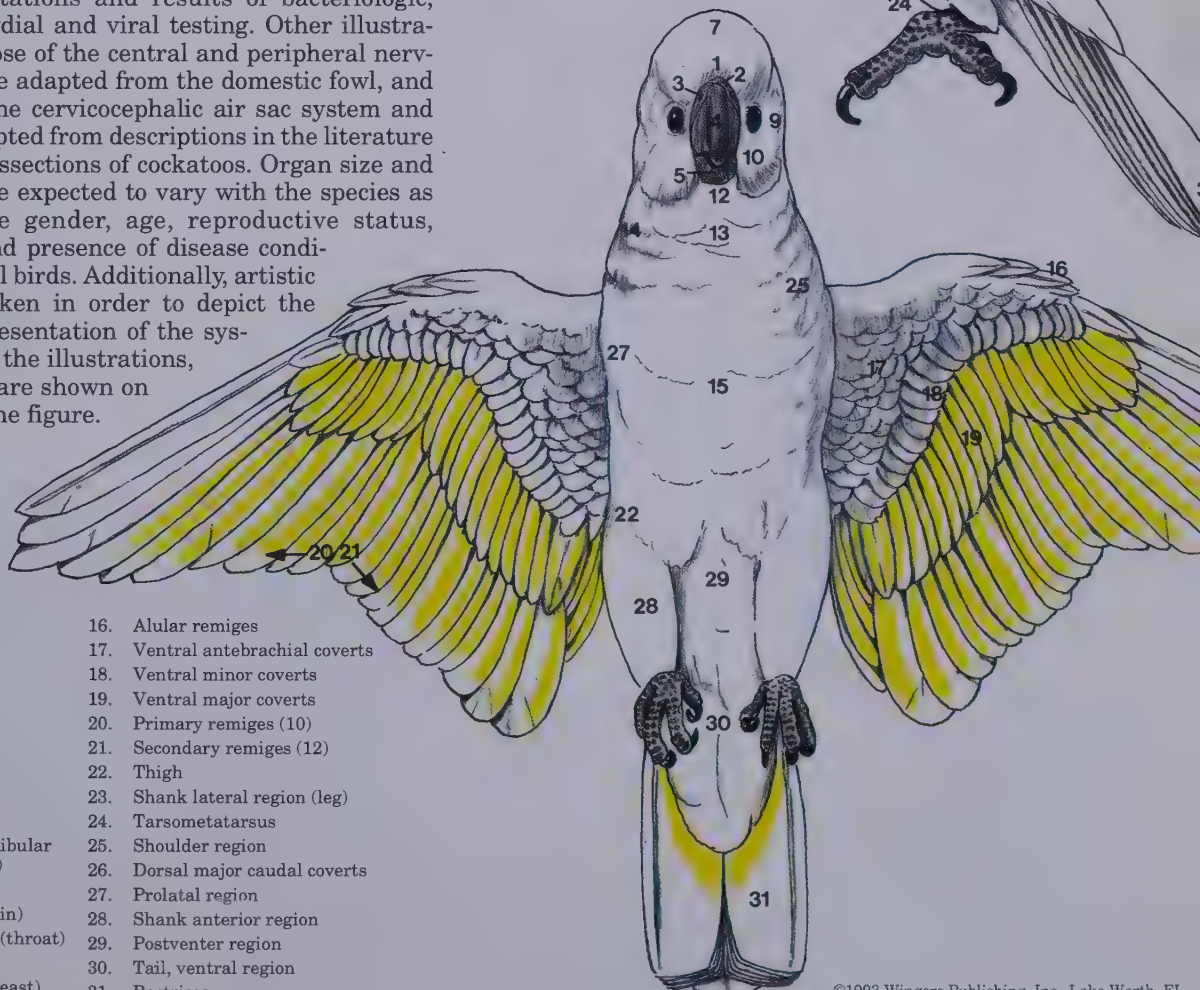
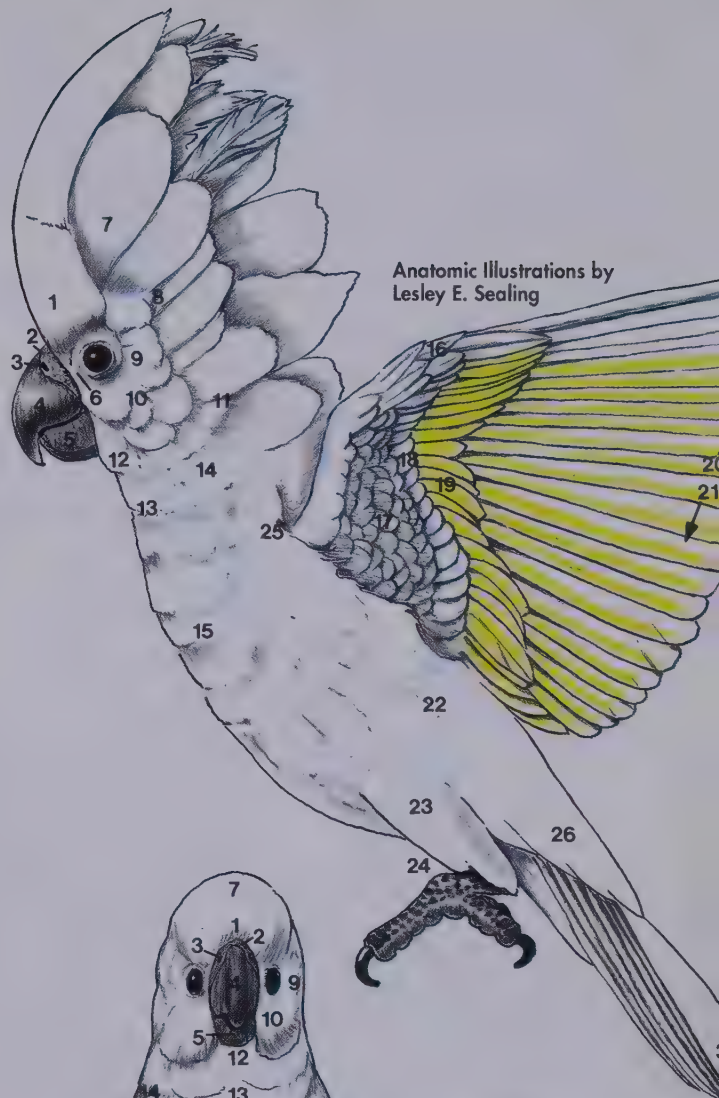


# Anatomy of the Umbrella Cockatoo

An artist's concept of the lateral and ventrodorsal views of the anatomy of a cockatoo are presented in a clear overlay system. When two or more pages are viewed together, the drawings represent the relative position and relationship of important anatomic structures. By inserting white paper behind a page, that page can be viewed separately.

This format is particularly useful as a reference to general anatomic sites during radiographic, endoscopic or necropsy evaluation of companion birds. Additionally, the format should provide an easy-to-visualize method for discussing a patient's problem and management techniques with clients.

Most of the illustrations were developed from dissections and radiographs. The primary radiographic model was an average-sized female Umbrella Cockatoo. The bird was believed to be a normal, healthy individual based on clinical assessment, diet evaluation, hematologic and biochemical laboratory test values, radiographic interpretations and results of bacteriologic, parasitic, chlamydial and viral testing. Other illustrations, such as those of the central and peripheral nervous systems, were adapted from the domestic fowl, and parameters for the cervicocephalic air sac system and sinuses were adapted from descriptions in the literature combined with dissections of cockatoos. Organ size and location should be expected to vary with the species as well as with the gender, age, reproductive status, prandial state and presence of disease conditions in individual birds. Additionally, artistic liberties were taken in order to depict the most logical representation of the systems. To simplify the illustrations, some body parts are shown on only one side of the figure.



- |   |                                  |
|---|----------------------------------|
| 1. Forehead                                       | 16. Alular remiges               |
| 2. Cere   | 17. Ventral antebrachial coverts |
| 3. Naris  | 18. Ventral minor coverts        |
| 4. Rhinotheca                                     | 19. Ventral major coverts        |
| 5. Gnathotheca                                    | 20. Primary remiges (10)         |
| 6. Lore   | 21. Secondary remiges (12)       |
| 7. Crest  | 22. Thigh                        |
| 8. Crown  | 23. Shank lateral region (leg)   |
| 9. Postorbital region                             | 24. Tarsometatarsus              |
| 10. Maxillary and mandibular malar region (cheek) | 25. Shoulder region              |
| 11. Dorsal neck region                            | 26. Dorsal major caudal coverts  |
| 12. Submalar region (chin)                        | 27. Prolatal region              |
| 13. Ventral neck region (throat)                  | 28. Shank anterior region        |
| 14. Lateral neck region                           | 29. Postventer region            |
| 15. Proventer region (breast)                     | 30. Tail, ventral region         |
|   | 31. Rectrices                    |

# Lateral View

## Muscular System

1. *M. orbicularis palpebrarum*
2. Sclerotic ossicle
3. *M. adductor mandibulae externus*
4. External ear canal
5. *M. branchiomandibularis*
6. *M. intermandibularis ventralis (mylohyoideus)*
7. Zygomatic arch
8. *M. rectus capitis ventralis pars lateralis*
9. *M. rectus capitis ventralis pars medialis*
10. *M. longus colli ventralis*
11. *M. sternohyoideus*
12. *M. biventer cervicis*
13. *M. tensor propatagialis*
14. *M. flexor alulae*
15. *M. abductor alulae*
16. *M. adductor alulae*
17. Radius
18. *M. flexor digitorum superficialis*
19. *M. flexor digitorum profundus*
20. Ulna
21. *M. interosseus ventralis*
22. Fascial plane overlying *M. flexor digiti minoris*
23. *M. ulnometacarpalis dorsalis*
24. *M. ulnometacarpalis ventralis*
25. *M. extensor longus digiti majoris*
26. *M. extensor metacarpi radialis*
27. *M. pronator profundus*
28. *M. pronator superficialis*
29. *M. flexor carpi ulnaris*
30. *M. brachialis*
31. *A. radialis*
32. *A. ulnaris*
33. *V. basilica*
34. *M. triceps brachii*
35. *M. biceps brachii*
36. Medianoulnaris nerve
37. Clavicle (*furcula*)
38. *M. pectoralis superficialis*
39. Keel projecting from sternum
40. *M. serratus superficialis*
41. *M. intercostales externi*
42. *M. latissimus dorsi*
43. *M. expansor secundariorum*
44. *M. iliofibularis*
45. *M. levator caudae*
46. *M. flexor cruris medialis*
47. *M. depressor caudae*
48. *M. iliobtibialis cranialis*
49. *M. iliobtibialis lateralis*
50. *M. pubo-ischio-femoralis pars lateralis*
51. *M. tibialis cranialis*
52. *M. fibularis longus*
53. *M. flexor perforans et perforatus digiti III*
54. *M. flexor perforans et perforatus digiti II*
55. *M. extensor digitorum longus*
56. Digit 1
57. Digit 2
58. Digit 3
59. Digit 4

60. *A. and V. metatarsalis dorsalis*
61. *M. gastrocnemius pars lateralis*

## Inset: Infraorbital Sinus and Cervicocephalic Air Sac

62. Nares
63. Rostral diverticulum of infraorbital sinus (IS)
64. Maxillary chamber of IS
65. Preorbital diverticulum of IS
66. Infraorbital diverticulum of IS
67. Suborbital chamber of IS
68. Postorbital diverticulum of IS
69. Preauditory diverticulum of IS
70. Mandibular diverticulum of IS
71. Cranial portion cervicocephalic air sac
72. Cervical portion cervicocephalic air sac

## Respiratory System

73. Larynx
74. Laryngeal mound
75. Cervical air sac
76. Trachea
77. Pneumatic diverticulum of clavicular air sac into clavicle
78. Pneumatic diverticulum of clavicular air sac into scapula
79. Pneumatic diverticulum of clavicular air sac into coracoid
80. Pneumatic diverticulum of clavicular air sac into humerus (light blue)
81. Clavicular air sac (blue)
82. Pneumatic diverticulum of clavicular air sac into sternum (light blue)
83. Cranial thoracic air sac (striated)
84. Caudal thoracic air sac (light blue)
85. Ventral hepatic peritoneal cavity (stippled)
86. Pneumatic diverticulum of abdominal air sac into femur (light blue)
87. Abdominal air sac (blue)
88. Lung (impression of 6th rib)
89. Syrinx

## Inset: Cut-away of Skull

90. Cere
91. Nasal cavity
92. *M. genioglossus*
93. Cranial nerve II (optic)
94. Antevestibular recess

## Circulatory System

95. Left internal carotid artery
96. Left external carotid artery
97. Left jugular vein
98. Left brachiocephalic trunk
99. Left subclavian artery
100. Left axillary artery and vein
101. Brachial artery
102. Superficial ulnar artery
103. Radial artery
104. Recurrent ulnar artery
105. Ulnar artery
106. Left thyroid gland

107. Left parathyroid gland
108. Left ultimobranchial gland
109. Right brachiocephalic trunk
110. Area of pectoralis muscle
111. Left cranial vena cava
112. Pulmonary trunk
113. Auricle of left atrium
114. Left pulmonary veins
115. Left pulmonary arteries
116. Right hepatic portal veins
117. Left lobe of liver
118. Thoracic aorta
119. Left pectoral artery and vein
120. Intercostal arteries
121. Celiac artery
122. Cranial mesenteric artery
123. Caudal vena cava
124. Left external iliac artery
125. Left femoral artery
126. Left internal iliac artery
127. Median caudal artery
128. Left external iliac vein
129. Left ischiatic vein
130. Left ischiatic artery
131. Left internal iliac vein
132. Left caudal tibial artery
133. Left cranial tibial artery
134. Left dorsal metatarsal artery

## Inset: Digestive Portion of Head

135. Palatine salivary glands (medial)
136. Angularis oris salivary glands
137. Maxillary salivary glands
138. Roof of oropharynx
139. Tongue
140. Rostral mandibular salivary glands
141. Lingual salivary glands
142. Caudal mandibular salivary glands
143. Choanae (not seen)
144. Sphenopterygoid salivary glands
145. Esophageal opening
146. Cricopharyngeal salivary glands
147. Esophagus

## Central Nervous System and Digestive System

148. Cerebral hemisphere
149. Optic lobe
150. Cerebellum
151. Medulla oblongata
152. Cranial nerve I
153. Pituitary gland
154. Spinal cord
155. Cervical spinal nerve
156. Cervical esophagus
157. Crop
158. Brachial plexus
159. *N. radialis*
160. Thoracic esophagus
161. Intercostal spinal nerve
162. Proventriculus
163. Isthmus
164. Ventriculus
165. Medianoulnar nerve

166. Lumbar plexus
167. Sacral plexus
168. Pudendal plexus
169. Caudal plexus
170. Ischiatic nerve (branches to fibular and tibial nerves)
171. Intestines
172. Pancreas
173. Obturator nerve
174. Femoral nerve

## Inset: Cut-away of Skull

175. Cranial nerve III
176. Cranial nerve IV
177. Cranial nerve V
178. Cranial nerve VI
179. Cranial nerve VII
180. Cranial nerve IX
181. Cranial nerve X
182. Cranial nerve XI
183. Cranial nerve XII
184. Supraorbital nerve
185. Lacrimal gland nerve
186. Sphenopalatine ganglion
187. Chorda tympani
188. Nasopalatine nerve

## Skeletal and Urogenital System

189. Vertebral canal
190. Cervical vertebra
191. Clavicle
192. Radial carpal bone
193. Alular digit
194. Major metacarpal bone
195. Minor metacarpal bone
196. Major digit
197. P1
198. P2
199. Minor digit
200. Ulnar carpal bone
201. Humerus (partially shown)
202. Thoracic vertebra
203. Synsacrum
204. Cranial division of kidney
205. Middle division of kidney
206. Caudal division of kidney
207. Vertebral ribs
208. Uncinate process
209. Sternal ribs
210. Caudal vertebrae
211. Pygostyle
212. Cloaca
213. Rectum
214. Left adrenal gland
215. Left testicle
216. Ductus deferens
217. Cranial cnemial crest
218. Ischium
219. Fibula
220. Tibiotarsus
221. Pubis
222. Tarsometatarsal 2,3,4
223. P1
224. P2
225. P3
226. P4
227. P5

Muscular System



# Ventrodorsal View

## Muscular System

1. M. orbicularis palpebrarum
2. Sclerotic ossicle
3. M. adductor mandibulae externus
4. M. intermandibularis (mylohyoideus)
5. Zygomatic arch
6. M. sternohyoideus
7. Coracoid
8. Clavicle (furcula)
9. M. tensor proptagialis
10. M. flexor alulae
11. M. abductor alulae
12. M. adductor alulae
13. Radius
14. M. flexor digitorum profundus
15. M. flexor digitorum superficialis
16. M. extensor longus digiti majoris
17. M. interosseus ventralis
18. M. ulnometacarpalis dorsalis
19. M. ulnometacarpalis ventralis
20. M. extensor metacarpi radialis
21. Tensor proptagialis pars brevis tendon
22. Tensor proptagialis pars longus tendon
23. M. pronator profundus
24. M. pronator superficialis
25. M. flexor carpi ulnaris
26. M. brachialis
27. A. radialis
28. A. ulnaris
29. V. basilica
30. Medianoulnar nerve
31. M. triceps brachii
32. M. biceps brachii
33. M. pectoralis superficialis
34. M. supracoracoideus
35. M. ambiens
36. M. femorotibialis internus
37. M. iliobtibialis cranialis
38. Area of M. ulnometacarpus ventralis
39. M. pubo-ischio-femoralis pars medialis
40. M. tibialis cranialis
41. M. fibularis brevis
42. M. fibularis longus
43. M. flexor perforans et perforatus digiti III
44. M. extensor digitorum longus
45. Digit 1
46. Digit 2
47. Digit 3
48. Digit 4
49. A. and V. metatarsalis dorsalis
50. M. gastrocnemius (medial head)
51. Vent
52. Extensor retinaculum
53. M. rectus abdominis
54. M. obliquus abdominis externus
55. M. flexor cruris medialis
56. Sternum
57. Rib 8 (dotted area = ribs and sternum)

## Inset: Gastrointestinal Tract

58. Thoracic esophagus
59. Right lobe of liver
60. Left lobe of liver
61. Proventriculus
62. Isthmus
63. Ventriculus
64. Descending duodenum
65. Ascending duodenum
66. Pancreas
67. Ascending loop of colon

## Respiratory System

68. Preorbital diverticulum of infraorbital sinus (IS)
69. Infraorbital diverticulum of IS
70. Rostral diverticulum of IS
71. Nares
72. Maxillary chamber of IS
73. Larynx
74. Mandibular diverticulum of IS
75. Cervical portion of cervicocephalic air sac (light blue)
76. Trachea
77. Cervical air sac (blue)
78. Clavicular air sac (blue)
79. Pneumatic diverticulum of clavicular air sac into clavicle (dashed outline)
80. Pneumatic diverticula of clavicular air sac into the coracoid (dashed outline)
81. Right cranial thoracic air sac (striated)
82. Left cranial thoracic air sac (striated)
83. Right caudal thoracic air sac (light blue)
84. Left caudal thoracic air sac (light blue)
85. Pneumatic diverticula of clavicular air sac into the humerus (dashed outline)
86. Right ventral hepatic peritoneal cavity (stippled)
87. Left ventral hepatic peritoneal cavity (stippled)
88. Right abdominal air sac (blue)
89. Left abdominal air sac (blue)
90. Pneumatic diverticula of abdominal air sacs into the femur (dashed outline)

## Inset: Male Urogenital System

91. Lung
92. Rib 7
93. Caudal vena cava
94. Aorta
95. Left testicle
96. Left adrenal gland
97. Cranial division of kidney
98. Middle division of kidney
99. Caudal division of kidney
100. Left common iliac vein
101. Left external iliac artery and vein
102. Right caudal renal vein
103. Right ureter
104. Right vas deferens
105. Left femoral artery and vein
106. Ilioischial foramen

107. Left ischiatic artery and vein
108. Caudal mesenteric artery and vein
109. Left internal iliac artery
110. Median caudal artery
111. Rectum
112. Cloaca

## Circulatory and Central Nervous System

113. Cerebral hemisphere
114. Cranial nerve II
115. Optic chiasm
116. Pituitary gland
117. Cerebellum
118. Optic lobe
119. Spinal cord
120. Mandible
121. Hyoid bone
122. Right internal carotid artery
123. Left internal carotid artery
124. Right jugular vein
125. Left jugular vein
126. Right thyroid gland
127. Left thyroid gland
128. Right parathyroid gland
129. Left subclavian artery and vein
130. A. and V. axillaris
131. A. collateralis radialis
132. A. and V. radialis
133. A. and V. ulnaris
134. A. and V. recurrent ulnaris
135. V. collateralis ulnaris
136. A. pectoralis
137. Area of pectoral muscles (dashed outline)
138. Auricle of left atrium
139. Right lobe of liver
140. Left lobe of liver
141. Left popliteal artery and vein
142. Left cranial tibial artery and vein
143. Left caudal tibial artery and vein
144. Left dorsal metatarsal artery and vein
145. Left cranial vena cava
146. Aorta
147. Pulmonary trunk
148. Pulmonary artery and vein
149. Right cranial vena cava
150. Auricle of right atrium
151. Right ventricle
152. Left ventricle
153. Coronary arteries and veins
154. Right femoral artery and vein
155. Right external iliac artery and vein
156. Right ischiatic artery and vein
157. Right ultimobranchial gland
158. Right and left brachiocephalic trunks
159. Left fibular artery
160. Left internal iliac artery
161. Caudal mesenteric artery and vein
162. Right caudal renal vein

## Inset: Mature Ovary

163. Immature follicles
164. Mature follicle
165. Post-ovulatory follicle (calix)
166. Infundibulum
167. Stigma
168. Magnum
169. Dorsal ligament of oviduct
170. Oviductal blood vessels
171. Isthmus
172. Ventral ligament of oviduct
173. Uterus
174. Vagina
175. Sphincter vaginae

## Digestive System

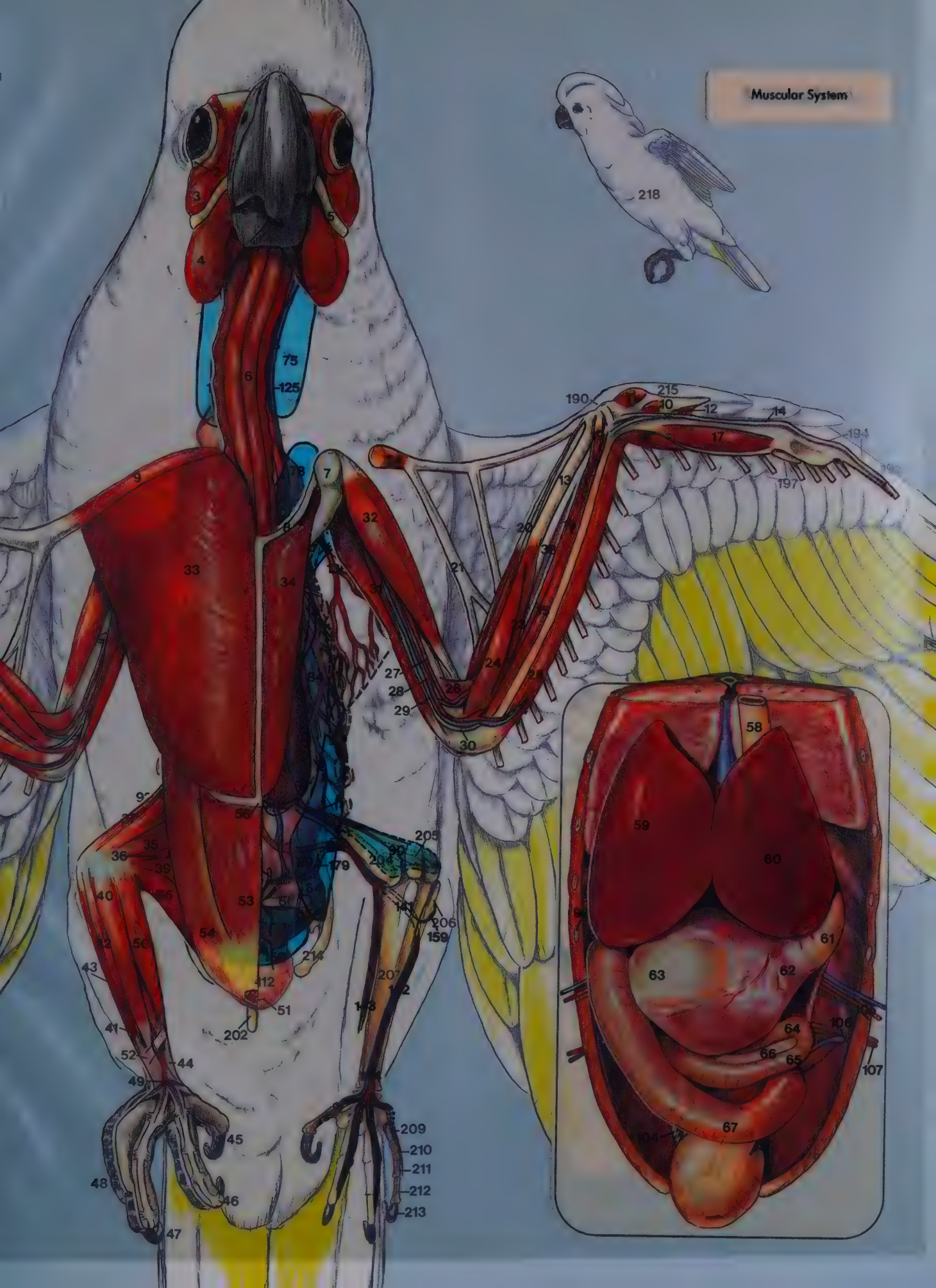176. Tongue
  177. Cervical esophagus
  178. Ingluvies (crop)
  179. Supraduodenal loop
- ### Inset: Immature Ovary
180. Ovary
  181. Oviduct
  182. Coprodeum
  183. Urodeum
  184. Proctodeum

## Skeletal, Urogenital Systems

185. Cervical vertebra
186. Syrinx
187. Scapula
188. Primary bronchus
189. Left humerus
190. Radial carpal bone
191. Ulna
192. Minor metacarpal bone
193. Major metacarpal bone
194. Major digit
195. P1
196. P2
197. Minor digit
198. Ulnar carpal bone
199. Ostium for caudal thoracic air sac
200. Synsacrum
201. Ischium
202. Pygostyle
203. Coccygeal vertebrae
204. Femur
205. Patella
206. Fibula
207. Tibiotarsus
208. Tarsometatarsus 2,3,4
209. P1
210. P2
211. P3
212. P4
213. P5
214. Pubic bone
215. Alular digit
216. Rostrum mandibulare (gnathotheca)
217. Rostrum maxillare (rhinotheca)
218. Miniature lateral perspective of ventrodorsal model.



Muscular System



## Lateral View

**Muscular System** The muscles of the trunk, neck, head and appendages are displayed. The vessels of the greatest clinical importance and their relationship to the muscles and bones are also shown. Stubs of the rachis from the primary and secondary flight feathers are depicted from their origin on the dorsal surface of the wing.

The inset shows a composite drawing of information available concerning the sinuses and cervicocephalic air sac system of psittacine birds.

**Respiratory System** A composite drawing provides the clinician with insight into the avian respiratory system. The ventral hepatic peritoneal cavity is also represented in this view. This layer has been specially designed so that all underlying structures are clearly visible. The individual layer can be segregated for study by placing a sheet of white paper under the acetate.

The relationship of the bones of the head and sinuses in an Umbrella Cockatoo are shown in the inset.

**Circulatory System** This layer depicts the clinically relevant portions of the circulatory system, along with the liver, thyroid and parathyroid glands. The relative posi-

tion of the pectoralis muscle is indicated with dotted lines for comparative purposes. Other dotted areas indicate that vessels are passing under or into anatomic structures.

The digestive portion of the head is depicted in the inset, including the tongue, palate, esophagus and salivary glands.

**Digestive System and CNS** The lateral orientation of the digestive system and portions of the central nervous system are depicted. The humerus is represented with a dotted line for orientation purposes.

The inset shows an enlargement of a representation of the orientation of the nerves with respect to the bones of the head and neck. Note the location and degree of innervation in the beak.

**Skeletal, Urogenital Systems** The skeletal and urogenital systems are superimposed over the exterior of the bird. The lateral body wall has been darkened to enhance the color of overlying anatomic structures. The bird has been transected sagittally to allow visualization of the spinal cord and kidneys.

## Ventrodorsal View

The ventrodorsal view illustrates a live bird in normal perching position (the femur, tibiotarsus, tarsus and metatarsus have been foreshortened); therefore, the drawing does not represent radiographic positioning of the legs. The primary emphasis is on the torso.

**Muscular System** The superficial pectoralis muscle has been removed from the left side of the bird to expose part of the coracoid bone and the clavicle. The tendon of the supercoracoidius is barely visible. The left portion of the abdominal muscle has also been removed. It should be noted that the pectoralis muscle fills the space between the coracoids, holding the crop centrally and away from the bones. The cranial extension of this muscle is clear in photographs, but has not been accurately depicted in many previous drawings of Psittaciformes. The rachis of the transected primary and secondary feathers are depicted from their origin on the dorsal surface of the wing.

The inset is an enlargement of the abdominal cavity depicting the relationship of the liver, thoracic esophagus, proventriculus, ventriculus and intestines.

**Respiratory System** The lungs were not included in the ventrodorsal drawing of the respiratory system so that the relative position of the air sacs could be clearly depicted. For clarity purposes, the trachea is depicted in an unnatural position lying over the esophagus and crop. The artist's concept of a composite of information on pneumatized avian bones is also provided. The ventral hepatic peritoneal cavity and cranial thoracic air sacs have been visually enhanced with textures for improved visualization.

A transection of a male cockatoo is shown in the inset. The liver and gastrointestinal tract have been removed to reveal the organs associated with the dorsal body wall. Note the melanistic testicles, which commonly occur in cockatoos.

**Circulatory System** The complex system of vessels has been simplified in order to facilitate identification of those structures that are most clinically applicable for venipuncture, cannulation and surgery.

The position of the lungs and pectoral muscles are represented by dotted lines. This layer includes the liver, thyroid glands, parathyroid glands and ultimobranchial glands (for position only, as the parathyroid and ultimobranchial glands are difficult to visualize. A transected view of the brain, skull, mandible and hyoid bones are visible in this view.

The position of the mature ovary and oviduct are illustrated in the inset.

**Digestive System** The esophagus and crop are shown as solid structures for clarity. In reality, these organs are thin, translucent membranes. The break in the thoracic esophagus indicates the point where the organ courses dorsally to the syrinx and primary bronchi.

The inset shows a view of the urogenital system of a developing female. The cloaca is opened ventrally to reveal the positions of the rectum, ureters and oviduct.

**Skeletal, Urogenital Systems** Shown are the skeleton and dorsal body wall of a female cockatoo with the heart, liver and gastrointestinal tract removed. An end-on view of the ribs is provided for reference purposes. Note the melanistic ovary, which is common in cockatoos.

## Nomenclature References

- Baumel JJ (ed): *Nomina Anatomica Avium*. New York, Academic Press, 1979.  
King AS, McLelland J: *Form and Function in Birds*. Vols 1-4. New York, Academic Press, 1979, 1981, 1985, 1989.

# Index

Letters following page numbers indicate the following:  
c=color figure, t=table, f=figure.

- A** Abdominal  
air sacs, 351 (see anatomy overlay)  
effusion, causes, of, 255  
mass, 255, 302, 735, 1132  
Abdominal distention, 168, 665c, 516f,  
821, 890, 1136  
in ratites, 1292c  
in hens, 768, 771, 774  
Abdominal hernia, 316, 518, 1132  
and egg binding, 761, 763f  
Abdominocentesis, 201f, 518, 770, 771,  
1076, 1221  
Abducent nerve (CN VI), 726  
Abscesses, 684, 1113  
Acanthocephalan, 1013, 1193, 1232  
Accipitridae, 106  
Acepromazine, cardiac effects of, 711  
Acetic acid, for papillomas, 887  
Acetylcholine, 740, 741  
inhibitors, 737, 740  
Acetylcholinesterase, 740, 741, 1050,  
1051  
Acetylcysteine, 458, 686  
Acetylsalicylic acid, 458  
Achilles tendon, medial luxation of, 164,  
1258f, 1324  
Acholeplasma, 1053  
Achromatosis, 74, 617, 626, 847  
Acid-fast organisms, 222t, 973, 974,  
detection of, 484t  
Acinar atrophy, zinc toxicosis, 1265  
*Acinetobacter*, 964  
Acrylic, dental, 1148  
ACTH, adrenal corticotrophic hormone,  
458, 584, 598  
*Actinobacillus*, 961, 963, 991  
and ocular disease, 686  
in Galliformes, 1232  
Activated charcoal, 415, 458  
*Acuaria*, in Passeriformes, 1195  
Acute dyspnea, cause, 409  
Acyclovir, 458, 537, 579, 862  
for herpesvirus, 878, 943  
Adenine arabinoside, 1185  
Adenocarcinoma, 770  
Adenoma, 770  
in Galliformes, 904, 905, 1232  
Adenovirus, 903-908  
control of, 940t  
diagnosis of, 907  
gross lesions with, 904  
Group I, 904  
Group III, 907  
in pigeons, 905  
in Psittaciformes, 869c, 906  
in waterfowl, 906  
inclusion bodies of, 125, 903, 904, 908  
latent, subclinical, 904  
species-specific considerations, 904  
transmission, 903  
unclassified, 908  
Adhesion, and egg binding, 760  
Adjuvants, and muscle necrosis, 113, 127  
paramunity inducers, 113  
Adrenal gland, 597, 598  
Adrenal insufficiency, ACTH, 458  
Adrenalin, 1214  
Advertising, 132  
*Aedes* spp. and togavirus, 915  
*Aegyptianella*, rule-out list, 1063  
in Galliformes, 1232  
in Passeriformes, 191, 1192, 1193  
*Aeromonas*, 958  
in Galliformes, 1232  
in Ramphastidae, 1282  
vs *Clostridium* dermatitis, 978  
Aerophagia, treatment of, 825  
Aflatoxin, 50, 69, 553, 784, 787, 910,  
1043, 1266 (see mycotoxin)  
follicular atresia and, 749  
in Anseriformes, 536, 1265  
Aflatoxin B1, hepatotoxin, 1043  
clinical pathology with, 1043  
preventing, 1043  
and breeding, 787  
African Black Ostrich, 1297  
African Grey Parrot, 438, 459, 464, 592  
biochemistry values, 1329t  
ECGs, 703f, 704f, 705, 706f, 707f, 708f  
cardiomegaly and, 710  
constricted toes, 831  
feather picking and, 635  
hypocalcemic syndrome, treatment, 411  
papillomas in, 886  
regurgitation and, 827  
seizures in, 706, 857  
viral diseases in, 824, 886, 890, 895, 911,  
927  
vitamin D<sub>3</sub>, caution, 469  
AG ratio (see albumin/globulin ratio)  
Age  
in Anseriformes, 1244t, 1252  
of birds, 30  
Agencies, regulatory, United States, 143  
Aggression, 465, 1179, 1204, 1230  
in Anseriformes, 1252  
in Galliformes, 1230  
in Passeriformes, 1179  
in relationship to enclosure, 1179  
Air  
bronchograms, 252  
cell, 754  
conditioners, diseases and, 58  
drill, 1161  
filtration systems, 37, 137  
pressure, 1204  
Air sac, 252, 294, 304-306, 333, 351, 361,  
365, 567, 572, 579, 1105  
air flow entering, 570f  
anesthesia, 1074t, 1108, 1118  
cannula, 396, 1108, 1118, 1272  
esophageal, in Galliformes, 1222  
in canaries, 1187  
in Galliformes, 1221  
in Psittaciformes vs Passeriformes, 1174  
rupture, 409 (see emphysema,  
subcutaneous)  
Air sac mite, 1180, 1215  
Air sacculitis, 253, 317, 352, 390, 571f,  
576, 885, 1189  
treatment of, 390, 579  
with chlamydia, 989  
with influenza virus, 930  
with mycoplasma, 1054, 1058  
Airlines, cargo bins, temperature of, 136  
Airplane wing, in waterfowl, 848  
AIV (see avian influenza virus)  
ALAD (see delta-aminolevulinic acid  
dehydratase)  
Alanine aminotransferase (ALT, GPT),  
228, 1244, 1335t  
Albumin (ALB), 530, 589, 1244  
and egg production, 754  
Albumin/globulin (AG) ratio, 238  
with coronavirus, 915  
*Alcaligenes*, 959, 982  
Alcohol, 458  
Aldosterone, 597, 712  
Alfalfa, 68 (see hay)  
for ratites, 1306  
for ducklings, 1250  
Algae, blue-green, 1265 (see spirulina)  
and feather coloration, 847  
hepatotoxin, 1033  
in Anseriformes, 1265  
Alimentary tract, cytology of, 209  
disorders, neonate, 825  
in Galliformes, 1221  
and disease, 482  
Alkali poisoning, 1263  
Alkaline phosphatase (AP), 524, 1335t  
for diagnosis of polyomavirus, 890  
Alkaline water, *C. botulinum* in, 1263  
Allometric scaling, 437  
Allopurinol, 458, 554  
in Red-tailed Hawks causing gout, 239  
Almonds, toxicity, 1198  
Aloe vera, 458, 464, 623  
Alpha-chloralose, in Anseriformes, 1260  
Alpha-tocopherol, 84 (see vitamin E)  
Altricial, young, 506, 802, 805, 1172  
Aluminum hydroxide, 113  
Aluminum sulfate, 1038  
Alveolitis, allergic, 1202  
*Alysiella filiformis*, 210, 218c  
Amazon foot necrosis, 631c, 966f  
Amazon parrot  
biochemistry values, 1329t, 1335t  
drugs and, 443, 448  
ECG in, 705, 707  
epilepsy in, 410, 738  
herpesvirus in, 878  
human bonding with, 29  
*Mycobacterium* in, 975  
obesity in, 844  
papillomas in, 886, 887  
poxvirus and, 872  
*Streptococcus* in, 970

- viral disease in, 872, 875, 876, 878, 890, 911
- Amazon punctate keratitis, 687
- Amazon tracheitis virus, 875-877
- Amikacin, 390, 447, 458  
toxicity of, 1046
- Amino acid  
feather picking and, 846  
protein and, 81, 82  
profile, formulated diets, 76  
solution, 393  
synthesis, in Galliformes, 1223  
vitamin interactions, 67
- Amino-nicotinamide, 746
- Aminoglycoside, 438, 446, 447  
therapeutic dose of, 442  
pharmacology of, 437  
toxicity of, 446, 1046  
renal damage from, 442, 446, 553
- Aminoloid, 458
- Amitriptyline HCL, 458
- Ammonia, 530, 542  
immune response, 1048  
lymphocyte function, 1048  
aspergillosis and, 1001
- Ammonium solution, 458
- Amoxicillin, 458, 1187
- Amphotericin B, 455, 459, 1003, 1005, 1134, 1189, 1282  
for *Candida*, 999  
pharmacology of, 451  
toxicity of, 1004, 1046
- Ampicillin, 445, 459  
for treatment of *Salmonella*, 955
- Ampromium, 459, 1191
- Amputation  
of comb, wattle, 1233  
of leg, toe, wing, 1133
- Amylase, 231, 232, 485, 1244
- Amyloidosis, 120, 362, 536, 552  
in Anseriformes, 536, 1263
- Amyloidosis, in Passeriformes, 1198
- Anabaena* algae, 1265
- Anaerobic bacteria, 462, 466
- Anafranil, 461
- Analgesic, 459, 463, 1094, 1095
- Anamnesis (medical history), 145
- Anastomosis, circumferential, 1097
- Anatidae (see Anseriformes)
- Anatiformes, and viral diseases, 922, 933
- Anatomy (see anatomy overlay)  
abnormalities in male, 774  
digestive, in ratites, 1292c  
endoscopic, 328  
in Anseriformes, 1241t  
in Columbiformes, 1202  
in Galliformes, 1219  
in Passeriformes, 1173  
in Ramphastidae, 1277  
in ratites, 1286  
reproductive, 755  
skin, 612f
- Ancobon, 463
- Anemia, 188, 398, 399, 461, 464, 535, 542  
adenovirus and, 904, 908  
dietary management of, 858  
hypochromic, regenerative, 1035  
in ducks, 936, 1251  
in Passeriformes, 1188, 1193, 1196  
non-regenerative and PBFV virus, 899  
viral diseases and, 911, 915, 916  
with zinc toxicosis, 1039  
with organochlorine, 1050  
with *Aegyptianella*, 1062  
with *Chlamydia*, 989
- Anesthesia, 383, 1066 (see isoflurane, halothane, methoxyflurane)  
agents, 138, 1066-1068  
equipment, 1067, 1070, 1071, 1072f, 1073f  
cardiac effects of, 711  
in Anseriformes, 1260, 1262t  
in Columbiformes, 1213  
blood collection, 1074  
blood solubility, 1068  
coagulopathy, 1075  
contraindications for, 1067, 1076  
delivery of inhalant, 1073  
doxapram hydrochloride, 1080  
effects with isoflurane, 1074  
emergencies, 1073, 1074, 1079, 1080  
endoscopy, 1074  
fasting, 851, 1077  
field use, 1067  
fluid therapy, 1074f, 1076, 1077  
hepatic damage from, 1068  
hyperventilation, 1079  
induction, 1073  
injectable, 1066, 1069, 1070, 1260, 1262  
intubation, 1068  
IPPV, 401, 1068  
ketamine, 1069  
long-term general, 1074  
minimum alveolar concentration, 1068  
monitoring, 1074, 1078t, 1079  
nitrous oxide, 1069  
nosocomial infections, 1071  
obesity and, 1076  
open system, 1068  
out-of-circuit, 1070  
paCO<sub>2</sub> levels, 1074  
patient evaluation, 1074, 1075t, 1076  
physiologic effects of inhalant, 248, 1067  
pre-anesthetic, 1069, 1079  
recovery, 1067  
respiratory and cardiac arrest, 1068, 1080  
respiratory rate, 1077t, 1079  
risk classifications, 1075  
scavenging system, 1068, 1072  
short-term restraint, 1074  
sinus bradycardia, causes of, 706  
tank systems, 1071f  
temperature, effects of, 1074
- Angel wing in Anseriformes, 1257f
- Angiography, 260, 698f
- Angiotensin, converting enzyme, inhibitors, 714  
I, cardiac effects, 712  
II, cardiac effects, 712, 714
- Angular limb deformity, in ratites, 1161, 1298, 1324
- Anhimidae, screamers, 1238
- Animal bites, emergency treatment, 412, 414
- Animal protein, and Anseriformes, 1246
- Anisocytosis, 194c  
hemorrhagic conure syndrome with, 934
- Anisodactyl foot, 1172
- Ankyloblepharon, 679, 822
- Ankylosis, postsurgical, 1139
- Anophthalmia, 822
- Anseranatinae (Magpie Goose), 1238
- Anseriformes, 345, 508, 609, 1160, 1237-1275  
air sac cannulation of, 1272  
algal toxins, 1265  
amyloidosis in, 1263  
anesthesia in, 1260, 1262  
artificial insemination of, 776  
beak repair of, 1272  
body weight data of, 1240t  
botulism in, 1263  
bumblefoot in, 1262  
capture myopathy in, 1263  
castration of, 1274  
chick management, 1253, 1254  
clinical pathology and, 1211, 1341t-1344t  
diagnostic facilities for, 1262t  
defenses of, 1244  
disease in, 1262-1266, 1264t, 1267t, 1268t  
ducklings, diet for, 1248t  
egg-related peritonitis, 1266  
endocarditis, 714  
energy requirements in, 1249  
fertilizers and, 1266  
frostbite in, 1243  
gender determination, 778  
growth rate, egg production in, 1243  
hatching of, 1253  
heart rate in, 1243  
hematology in, 1340t, 1341t  
housing for, 1244  
incubation of, 1240-1243t, 1253  
joint ankylosis, 1269  
lead poisoning in, 1035, 1264  
lymphocytes, 1244  
*Mycobacterium* in, 972  
mycotoxicity in, 1264  
myopathy, 1263  
neonatal problems, 1255, 1256  
nutrition of, 1250-1258, 1252t  
ocular disease and, 685  
oil-contamination of, 1263  
parasites and, 769, 1253  
phallus, 756  
pipping in, 1253  
pododermatitis in, 1262  
procaine penicillin in, 467  
proventricular dilatation, 1269  
reproductive status of, 1243, 1244, 1252  
respiration rates, 1243  
*Salmonella* sp. in, 1257  
stress in, 1257  
surgery of, 1269-1274, 1270f-1272f, 1275f  
toxin exposure, 1266  
tumors, 1266  
viral disease and, 744  
zinc toxicosis, 1264
- Ant, 459, 624f, 720
- Anterior chamber, of eye, 673, 676f
- Anthelmintics, 1045
- Anthrax, in ratites, 1309
- Antibiotic, 1114 (see antimicrobial therapy)  
aspergillosis and, 1001  
bacteria, resistance and, 442, 443  
beta lactam, safety of, 442  
blood levels and, 388  
*Candida* infections and, 999  
condition at site of infection, 437

- flora, alimentary, adverse effects on, 442  
 food-based, 439  
 indiscriminate use of, 50  
 inhibiting immune systems, 114  
 intramuscular injection, 440  
 intraosseous injection, advantages, 440, 441  
 intravenous injection, 440  
 minimal inhibitory concentration (MIC), 435  
 nebulization, 441  
 oral administration, 439  
 over-the-counter (OTC), 442  
 resistant organism, 435  
 septicemia and, 388  
 subcutaneous injections, 440  
 susceptibility of bacteria, 435, 436f, 455  
 tissue penetration and, 437  
 topical medications, 441  
 toxicity, 441, 442, 1046  
 treatment failure, 442  
 vitamin deficiencies, 852  
 water-based, 438
- Antibodies, 115, 121, 754  
 Anticoagulant, 177, 178, 224, 230, 771, 1135  
 Antifungal therapy, 450-456, 999t, 1114  
 Antigen detection, chlamydia, 992t  
 Antigen ELISA, 121  
 Antigen-expressing tumors, 127  
 Antigens, 114  
 Antigout, 461  
 Antihistamines, 637  
 Anti-inflammatory, 461, 463  
 Antimalarial drugs, 1193  
 Antimicrobial therapy, 127, 434-456 (see antibiotics, specific agents)  
 resistance to, 434  
 routes of administration of, 438-441  
 selection of, 435t  
 spectrum of, 435-437  
 susceptibility to, 455t  
 toxicity of, 441-442
- Antineoplastic therapy, prednisolone, 600  
 Anting, 608  
 Antioxidant, 77, 84  
 Antipyretic, 463, 465, 467  
 Antisense RNA therapy, 127  
 Antitoxin, for treatment of botulism, 1264  
 Antitussive, 459  
 Aortic rupture, 859  
 in ratites, 1295c, 1307  
 malnutrition and, 849
- AP (see alkaline phosphatase)  
 Aplastic anemia, human, 450  
 Apnea, 1073, 1074, 1079, 1080  
 Apomorphine, 503  
 Appetite stimulant, 465  
 Apple cider vinegar, 511  
 Apteris, 614f  
 Aquatic environments, 460  
 Aqueous flare, 673  
 Aracaric, 957, 1279  
 Arachidonic acid, 81  
 Arachnoid, 724  
 Arborvirus, 915, 916  
 zoonotic potential of, 919t  
 Arginine deficiency, 633  
 Arginine vasotocin (AVT), 583, 752  
 and egg binding, 760  
 Argus pheasant, 1231  
 Arrhythmia, 401, 705, 714, 715t, 1044  
 adrenalin-induced, 713  
 atrioventricular node and, 709  
 in pigeons, 461  
 ventricular, 708
- Arsenic (Ar) toxicosis, signs of, 536, 1040  
 Arthritis, 251, 982  
 in ratites, 1309, 1310c  
 postsurgical, 1138  
 with mycoplasma, 1054
- Arthropod  
 as disease vector, 1061, 1062  
 in Galliformes, 1232  
 in Passeriformes, 1195
- Arthus phenomenon, 120  
 Articular gout, 214, 221c, 540, 547, 651, 850  
 Artificial insemination, 757, 776, 777, 1231  
 electroejaculation for, 776  
 in Anseriformes, 1253  
 in Columbiformes, 1211  
 in Psittaciformes, 776
- Ascariid, 769, 1011f, 1021, 1283  
 in Passeriformes, 1194  
 piperazine for, 467
- Ascites, 515-517, 523, 537, 1197  
 adenovirus and, 907  
 diets, low-sodium for, 518  
 heart and, 710, 713  
 in Ramphastidae, 1280  
 malnutrition and, 849  
 reproductive disease and, 770
- Ascorbic acid, 82, 88 459 (see vitamin C)  
 Aspartate aminotransferase (AST, GOT), 229, 890, 911, 916, 1244, 1298, 1335t  
*Chlamydia* and, 989  
 polyomavirus and, 890  
 infectious disease and, 890, 911, 915, 916, 989
- Aspergilloma, in thoracic air sac, 1003f  
 Aspergillosis, 309, 345, 366, 459, 462, 463, 464, 526c, 535f, 544, 565, 599, 625, 997, 1001  
 air sac hyperinflation and, 1002  
 brooder pneumonia, 1000  
 clinical findings with, 450, 684, 1002t  
 clinical pathology, 1002t  
 CNS signs with, 741  
 cytology of, 212c, 218c  
 diagnosis of, 1003  
 heart and, 704  
 histopathology and, 1002t  
 in Anseriformes, 1257, 1266  
 in Passeriformes, 1189  
 in ratites, 1314  
 malnutrition and, 849  
 prevention of, 452, 1004  
 sinusitis and, 558  
 therapy for, 452-455t, 1003, 1004t
- Aspergillus*, 575, 1000, 1043  
 in Galliformes, 1232  
 ochratoxin and, 1044
- Asphyxiation, malnutrition and, 846  
 Aspiration, sample collection, 200, 407, 565, 828  
 Aspirin, 458, 1095  
 anticoagulant, 771
- Association of Avian Veterinarians (AAV), 131  
 AST (see aspartate aminotransferase)  
 Astrovirus vs rotavirus, 913  
 AT (see Amazon tracheitis virus)  
 Atabrine, 468  
 Ataxia, 736-738  
 CNS toxins and, 739, 740, 1035, 1042, 1044, 1050  
 hemorrhagic conure syndrome and, 934  
 in Anseriformes, 1265, 1266  
 manganese and, 859  
 parasites and, 742  
 viral disease and, 743, 744, 890, 916, 930
- Atelectasis, 252  
 Atherosclerosis, 252, 371, 495, 707, 710, 718-720  
 clinical signs of, 720  
 dietary fat and, 851  
 ECG, 707f  
 malnutrition, 849  
 neurologic signs of, 736  
 retrospective study of, 718t
- Atoxoplasma*, 191, 194c, 529, 533, 1016  
 in Passeriformes, 1190, 1191t  
 in chicks, 825  
 cytology of, 221c
- Atresia (see choanal atresia)  
 congenital, of oviduct, 772  
 of ovary, 749
- Atrial arrhythmias, 707  
 fibrillation, 707, 714  
 flutter, 708  
 tachycardia, 707, 708
- Atrioventricular dissociation, 709  
 heart block, 709, 710  
 nodal escape, ducks, 707  
 node arrhythmias, 709  
 valve, 695, 712
- Atrophic rhinitis, 57, 160, 558, 577 (see granuloma, rhinolith)  
 Atropine, 459, 711  
 antidote for organophosphate toxicity, 711, 1051  
 for heart block, 706, 709, 710
- Auditory evoke potentials, 723  
*Augustifolia purpurea*, 462  
 Auscultation, respiratory sounds and, 571
- Australian Grass Finch, 1186  
 Autochthonous flora, 111, 465, 965, 968, 976, 978, 980  
 Autoimmune reaction, 119, 940  
 Automated cell counters, use of, 179  
 Autonomic nervous system, 727f  
 Avesm list of names, 1346  
 Aviadenovirus (see adenovirus)  
 Avian encephalomyelitis (AE), 937  
 Avian influenza virus (AIV), fowl plague, 707, 776, 929, 931, 1237, 1309  
 vs *Chlamydia*, 990  
 Avian reticuloendotheliosis virus, 936  
 Avian viral serositis (see viral serositis)  
 Aviary, 37  
 bully bird removal from, 37  
 design, 51-54f  
 disease management in, 52, 60, 137, 1176  
 emergency care of birds, 59  
 for Columbiformes, 1207  
 free flight, in Passeriformes, 1178

- health maintenance program, 52, 56  
 mixed species, 37  
 nest boxes, 52  
 ventilation fans, 53  
 visitors, biosecurity of, 46, 47  
 water, 52
- Aviculture, veterinary services for, 46  
 Aviculturist, breeder vs hobbyist, 46  
 first aid kit for, 59, 60t
- Avihepadnavirus, oncogenic properties, 910
- Avipoxvirus (see poxvirus)
- Avipro, 459
- Avocado toxicity, 38, 1041, 1198
- Avulsion  
 of brachial plexus, 734, 735f  
 of bronchi, 1108
- Azithromycin, 449, 450, 459
- Azole antifungals, 451-452, 1004
- Azomycin, 461
- B** B vitamins, 462, 545, 856  
 with renal disease, 850
- B-cell, 113, 117, 118
- Bacillus*, 978
- Bacteremia (see bacterial infections)
- Bacteria, 119, 979t, 949-1006 (see specific bacteria)  
 characteristics of, 979t  
 clinically significant, 979t  
 control and therapeutics, 980t  
 differential diagnosis of, 982t  
 disinfectants for, 979t  
 endotoxins and, 1033  
 gram-negative, significant, 950-964, 954t  
 gram-positive, significant, 965-982  
 in Anseriformes, 1267t  
 in chicks, 823  
 in Columbiformes, 1208, 1215t  
 in crop, 826  
 in Galliformes, 1232t  
 in Ramphastidae, 1282  
 in Passeriformes, 1187  
 in ratites, 1303t  
 in respiratory tract, 575  
 in seed, 951  
 incubation periods of, 979t  
 shedding of, 954t  
 transmission of, 979t  
 zoonotic potential of, 972t
- Bacterial  
 infections (bacteremia), 393, 550, 950  
 neuropathies, 744  
 taxonomy, 949
- Bacteroides, 953
- Bailey's hexaxial system, 700, 701t
- Baldness, in canaries, 637
- Ball bandage, technique, 431, 432t
- Banamine, 463
- Band, leg  
 closed, 41, 49  
 injuries from, 422-423  
 removal of, 40, 42, 43f  
 metal, frostbite and, 413
- Bandage  
 figure-of-eight, 428f, 429f  
 interdigitating, 432f  
 layers, 420-422  
 Robert-Jones, 1140  
 splint and external coaptation, 1145
- Barium (see contrast media)
- Barbules, 615f
- Basal metabolic rate (BMR), 394, 1083  
 in Passeriformes, 1173
- Basophilic rubricyte (see rubricyte)
- Basophils, 112, 190, 193
- Bathing, 39, 1224
- Bauer's and Gridley stains, 1005
- Baylisascaris*, 742, 1022, 1315
- Baypamun, as viral therapy, 943
- Beak, 161, 164, 166, 484, 485f, 523, 609-611, 618, 743, 728, 1220  
 anatomy, physiology of, 484, 609-611, 777  
 defects of, 293, 590, 789, 837, 891, 1164f  
 flaking, causes of, 161, 846  
 growth of, 610f  
 in Anseriformes, 1272  
 injury, repair of, 1162  
 neonate, problems with, 611, 836, 837, 1165  
 rubber, 590  
 trimming of, 41f, 1224
- Bees, 624
- Behavior, 74, 96-107  
 biting, 106, 849  
 breeding, 97, 98f, 99f, 100, 782, 787, 1129, 1209  
 communal nesters, 100  
 diet and, 74, 104  
 favoring one person, 107  
 feather picking, 106, 635f  
 house training, 104  
 in Columbiformes, 1204  
 masturbatory, 772, 775, 778  
 mimicking ability of, 1174  
 model-rival training, 101-102  
 modification, 29, 104-105, 464, 772  
 negative reinforcement, 102  
 ostriches, 1301  
 positive reinforcement, 102  
 problems, 101, 104-107, 775  
 screaming, 106  
 steps to modification of, 106t  
 training, 101-107  
 weaning, begging, natural, 101
- BELISA test, for chlamydia, 993
- Beltsville poultry semen extender, 1253
- Benadryl, 462
- Benzene hexachloride, 1316
- Benzoin, 1262
- Beta carotene, 83, 618, 1113
- Biatrial enlargement, 704
- Bicarbonate, 241, 389, 1077
- Bigeminy, 708
- Bile acids, 232, 522, 525, 530, 737, 1057  
 indication for liver biopsy, 347
- Bile duct  
 carcinoma of, 352, 657  
 cystic dilatation of, 362c  
 in Galliformes, 1223  
 hyperplasia, 658
- Bile salts, 81, 523, 525
- Bilirubin, 232, 243
- Biliverdinuria, 150, 173c, 523, 549, 905, 1001
- Bill tip organ, 609, 611f
- Biochemistry, 223-245, 1328t-1345t (see specific parameter)  
 acid phosphatase, 241  
 analytic accuracy, 223-225  
 anticoagulant, lithium heparin, 224  
 bicarbonate, 241
- bile acids, 232  
 blood collection, 239  
 blood gases, 241  
 calcium, 233  
 cholesterol, 233  
 copper, 241, 242  
 creatinine, 224, 225, 234  
 creatinine kinase, CK (CPK), 229  
 delta-aminolevulinic acid dehydratase, 241  
 diagnostic tests, specifics, 223  
 electrolytes, 227, 239  
 electrophoresis, 237  
 enzyme activity, elevated, 228t  
 enzymology, 226  
 gamma glutamyl transferase (GGT), 230  
 glucose, 234, 243  
 glutamate dehydrogenase (GLDH), 230  
 heparin (GGT), effect on, 230  
 histology, relationship to, 225-226  
 hormones, 227  
 international system of units (SI), 226, 1328t  
 interpretation guides for, 225, 226  
 iron, 235  
 ketones, 243  
 lactate dehydrogenase (LDH), 230  
 lipase, 236  
 metabolic increases, causes, 231t  
 metabolites, 227  
 phosphorous, 235  
 plasma ammonia, 231  
 plasma dye clearance test, 242  
 plasma vs serum, 224  
 potassium, 224, 240  
 reference intervals, 225, appendix sodium, 240  
 specific gravity, 242  
 samples for, 228t  
 total iron binding capacity (TIBC), 236  
 total protein, 236  
 triglycerides, 238  
 urea, 239  
 uric acid, 239  
 urinalysis, 242-244
- Biopsy, 325, 346-354, 532, 1116
- Biotin, 72, 87, 536, 857, 1251, 1298  
 feather picking and, 846  
 skeletal deformities and, 848, 857
- Bipolar radiosurgery (see radiosurgery)
- Bird (see companion bird, free-ranging bird)
- Bird's nest soup, 485
- Birnavirus, infectious bursal disease, 914, 1232
- Bismuth subsalicylate, 459
- Bite, from cats (see cat bite)
- Biting lice, in Passeriformes, 1197
- Biting birds, 106, 849
- Biting midges, *Culicoides* spp., 1192
- Black flies, 1193
- Black locust, 1041
- Black spot in Passeriformes, 1192
- Black Stork, herpesvirus in, 875, 884
- Blackbird, as disease vector, 958, 1005
- Blastoderm, 764c, 775
- Blastodisc, 764c, 775
- Blastomyces, fluconazole and, 454
- Bleeding (see hemorrhage)
- Blepharodema, with PMV-1 pigeon, 926
- Blindness, 587, 689, 728, 736, 1001

## INDEX

- causes of, 689  
 CNS toxins and, 739, 1035, 1050  
 cryptococcosis and, 1004  
 mycoplasmosis and, 1056  
 listeriosis and, 976  
 toxoplasmosis and, 688, 742
- Blood**  
 ammonia, 737  
 bacteria in, 950  
 cell, 181, 186 (see hematology)  
 cell count, reproduction and, 753t  
 chemistry, 1328t-1345t (see biochemistry, enzymology)  
 collection, 177f, 178f, 179f, 180f, 239, 385f, 1181, 1204  
 culture, 697, 950  
 feather, 38, 399  
 feces (see hematochezia)  
 fluke, 742, 1194  
 gas, 241, 1079  
 glucose level in, 738  
 in urine, 243  
 loss, 398, 399, 400, 414  
 parasites, diagnosis of, 190, 194, 533, 1010, 1018t, 1019, 1192  
 Passeriformes and, 1192  
 pressure, depressed, 1266  
 ring, 764  
 spot, 764c, 767c  
 transfusion, 400, 401, 1040  
 viral diseases and, 824  
 volume, 176, 400, 1204
- Blowflies and botulism, 739**
- Blue-necked Ostrich, 1297**
- BMR (see basal metabolic rate)**
- Body temperature, 1203, 1243**
- Body weight, in Anseriformes, 1241t**  
 in Galliformes, 1128  
 in Psittaciformes, 818t
- Bollinger bodies, 486, 679, 865, 873, 1185**
- Bond, human-animal, 18, 19**
- Bone**  
 congenital, abnormalities, 250  
 cutter, 1133  
 disease, 251, 324, 1144  
 graft, 1145  
 healing, 1140f  
 neoplasia, characterized by, 251  
 ossification, 1142  
 scanning, 325
- Bone marrow**  
 biopsy aspiration, needles for, 191  
 suppression in humans, 460  
 suppression, with mycotoxin, 1044  
 with *Mycobacterium*, 973
- Border Canaries, 1179**
- Bordetella, 959**  
 in Galliformes, 1232
- Borrelia, in Galliformes, 1232**
- Botulism, 739, 977, 1264 (see Clostridium)**  
 diagnosis of, 977-978  
 in Anseriformes, 1263  
 in ratites, 1309  
 therapy of, 740  
 vs lead toxicity, 1035
- Bougienage, 1113**
- Boutons, for diagnosis of Clostridium, 977**
- Bowed legs, in ducklings, 1251**
- Bowel, fluid-filled, radiology, 255**
- Bowls, food and water, 58**
- Bowman's layer, 676**
- Brachial plexus, 374, 726, 735f**
- Bradycardia, 702, 706, 711, 740**
- Bragmathism, 611, 1166**
- Brain, 369, 372, 465, 724f, 725f**
- Brazil nuts, 536, 1043, 1266**
- Breathing, shallow and labored (see dyspnea)**
- Breeders**  
 culled, 47  
 fancy pigeons, 1201  
 periodic, equatorial climates, 752
- Breeding (see theriogenology, 748-804)**  
 aflatoxin and, 787  
 age in ducks, 1252  
 aggressive behavior, 781  
 average clutch size, 775  
 behavioral characteristics, 47, 775, 778, 783  
 causes of infertility, 786  
 dimetridazole toxicity and, 1045  
 disease and, 1054f  
 enclosures, 783  
 environment and, 775f, 780-784, 788  
 fertility, 775, 785  
 hatchability, 775, 786  
 in Columbiformes, 463, 1209  
 in Passeriformes, 1176t  
 in ducks, 1252  
 incubation and, 788, 789  
 lighting effects in, 1175  
 mate preference, 781  
 nests, 783  
 nutrition, 72, 784, 788  
 pair-bonding, 782, 1209  
 parental factors, 787  
 physical and medical characteristics, 784  
 pre-incubation factors, egg storage, 788  
 record-keeping, 785  
 sexual maturity, 779  
 underproduction, 775  
 visual stimuli, 781
- Brewer's yeast, in ducklings, 1251**
- Bristles, 615**
- Brodifacoum toxin, 1051**
- Bromsulphalein, 242**
- Bronchitis virus, infectious, 768**
- Bronchograms, air, 252**
- Bronchi, 561, 567**
- Brood box, for Anseriformes, 1254f**
- Brooder pneumonia (see aspergillosis)**
- Brooder room management, 1253**
- Brood patch, 608, 634, 1219**
- Brooding behavior, 584**
- Brotogeris, with Mycobacterium, 973**
- Brown-eared Pheasant, 1231, 1235**
- Bruising, 169**
- Brush Turkey, 1229**
- Budgerigar, 20, 75, 235, 462, 464, 465, 518, 782, 807, 1329t**  
 feather duster, 873  
 goiter in, 846  
 fledgling disease (BFD), 885, 888, 890  
 herpesvirus in, 875, 878, 880, 882  
 obesity in, 844  
 papillomas in, 886  
 paramyxovirus, 927-928  
 PBFD in, 895  
 poxvirus in, 873  
 reovirus in, 912
- Bufflehead Duck, breeding in, 1252**
- Bulk laxative (see hemicellulose)**
- Bull Finch, toxin in, 464**
- Bumblefoot, 164, 425-427, 462, 631c**  
 cardiac effects of, 714  
 classification and causes, 425-427, 426t, 632  
 in Anseriformes, 1244, 1250, 1262  
 malnutrition and, 425f, 848f  
 prevention of, 426  
 treatment, 426-427  
*Staphylococcus* in, 967
- Bundle branch block, left and right, 710**
- Bunyamwera group, 919**
- Bupivacaine, 1133**
- Buprenorphine hydrochloride, 1095**
- Burlap (hessian), 1176**
- Burn, 412-414, 623, 626, 628c**
- Bursa of Fabricius, cloacal bursa, 509**
- Butorphanol tartrate, 459**
- C** Cachexia, emergency treatment, 414  
 CaEDTA (see calcium disodium ethylene diamine tetracetate)  
 Caffeine, 1044  
 Cage (see housing)  
 Caique, 30, 886  
 Calamus, 158, 619, 1245  
 Calcitonin (CT), 587  
 Calcium (Ca), 75, 89, 90, 233, 459, 461, 462, 1244  
 abnormal eggs and, 773  
 absorption, bone mobilization, 753  
 blood levels of, 75, 1252  
 body stores and, 737  
 chronic egg laying and, 772  
 dietary, 250, 811, 850, 854, 857, 1046  
 egg binding and, 75, 758, 759, 849  
 excess, renal effects of, 850, 858, 1046  
 feather quality and, 846  
 hemorrhagic conure syndrome and, 934  
 metabolic disease, 758  
 metabolism and, 587, 753, 789f  
 nephropathy and, 592  
 phosphorous, ratio of, 66, 858  
 skeletal deformities and, 848  
 supplementation, in Anseriformes, 1258
- Calcium carbonate, 72**
- Calcium disodium ethylene diamine tetracetate (CaEDTA), 400, 1037-1038**
- Calcium disodium versenate, 459, 1037**
- Calcium gluconate, 542, 737**
- Calcium oxalate crystals, with ethylene glycol toxicity, 1044**
- Calcium-binding proteins, 75**
- California encephalitis virus, 919**
- Callus formation, 1140**
- Caloenadidae, 1201**
- Caloric requirements, and supportive care, 394**
- Camphor spirits, 1262**
- Campylobacter, 514, 959-960, 1189**  
 in Galliformes, 1232  
 in Passeriformes, 1179  
 in ratites, 1309
- Canada Goose, 1257**  
 disease in, 872, 928, 1269
- Canary, 74, 463, 758, 762, 1183, 1185, 1186, 1189, 1193, 1195**  
 atoxoplasma in, 1191

- bacteria in, 957, 970, 976  
*Candida* in, 999  
 color varieties, 1183  
 cross-fostering, 806  
 dominant white lethal factor, 1184  
 feather cysts, 1098  
 feathers in, 846, 1184  
 fungal disease in, 1005  
 malnutrition in, 1177f  
 megabacteria in, 982  
 mycotoxins in, 1043  
 myocarditis and encephalopathy in, 909  
 nutrition, 1177  
 ocular disease and, 687, 688  
 parasites in, 1191, 1194, 1196, 1197  
 plant toxicity in, 1042  
 poxvirus vaccine in, 872  
 reproduction in, 768, 1175, 1176t  
 toxoplasmosis and, 688, 742  
 viral disease in, 164, 872, 873, 875, 927, 931, 933, 1059, 1185
- Cancer, liposomes, 127  
 human lung, 1202
- Candida*, 1186  
 clinical signs of, 999  
 culture media for, 999  
 cytology of, 218c  
 in Galliformes, 1232  
 in Passeriformes, 1188, 1189  
 in Ramphastidae, 1282  
 in ratites, 1314  
 secondary to antibiotic therapy, 999  
 treatment, 452-454, 467, 999t
- Candling, 785, 791, 795
- Canker, 491
- Cannibalism, 1233, 1279
- Cannon nets, 1260
- Canthexanthin, 1178
- Canthoplasty, inferior ectropion, 1100
- Canvasback Duck, 1239, 1246
- Cape Barren Goose, 1239, 1252
- Capercaillie, 1220
- Capillaria, 463, 464, 465, 496, 1012f, 1023, 1283  
 clinical signs of, 486  
 in Passeriformes, 1188, 1194
- Caprillic acid, 459
- Capsicum annuum*, 1041
- Captive breeding, reintroduction, 22
- Captopril, 714
- Capture myopathy, in Anseriformes, 1263
- Capture nets, 1260
- Carbamate, toxicosis, 737, 1051
- Carbaryl, 59, 459, 1050, 1316 (see Sevin dust)
- Carbofuran, toxicity, 1051
- Carbohydrate, 78, 851, 603t
- Carbon dioxide  
 in incubation, 1229  
 laser, 1131
- Carbon monoxide, 1049, 1198
- Cardiac  
 arrest, 711, 1080  
 arrhythmias (see arrhythmias)  
 depressants, 711  
 disease, evaluation of (see cardiology)  
 glycosides, 714  
 monitoring, in Anseriformes, 1261 (see anesthesia)  
 silhouette, 252, 697
- Cardiac-induced ascites, 696
- Cardiogenic shock vs congestive heart failure, 712
- Cardiohepatic syndrome, 716
- Cardiology, 695-722
- Cardiomegaly, 252, 313, 401, 696, 710, 717t
- Cardiomyopathy, 518, 716, 717
- Cardiopulmonary resuscitation (CPR), 401
- Cardiovascular  
 diseases, 711-713  
 effects of conditions or agents, 705t  
 system, 252 (see anatomy overlay)
- Carnidazole, 459, 1209
- Carotene, 846
- Carotenoid pigments, 83, 523, 1177, 1178
- Carpometacarpus, surgical approach to, 1153
- Carrot, as an undigestible cellulose, 1178
- Cartilage, 1143
- Caryospora, 1012f
- Cassia occidentalis*, 1307
- Cassowary, 506, 1284, 1286, 1291, 1320  
 artificial insemination in, 776  
 characteristics of, 1285, 1345t  
 digestive anatomy of, 1289  
 plant toxicity in, 1042
- Cast, cellular, 549 (see urinalysis)
- Casting material, 1148
- Castration, in waterfowl, 1274
- Cat, as disease vector, 741, 984, 1191, 1194, 1207
- Cat bite, *Pasteurella* and, 412, 459, 962, 1189
- Cataract, 687, 688, 1101-1103  
 canaries and, 1184  
 familial and, 822  
 in ratites, 1292c, 1316  
 removal of, 1102f
- Catecholamine, 597  
 cardiac effects of, 711
- Catheter, Foley, 1108
- Cave Swiftlet, 485
- Cebocephaly, 746
- Ceca, 509, 953, 1202  
 in Galliformes, 1223  
 in ratites, 1289
- cecal tonsil, 116, 506
- Cefotaxime, 446, 459
- Cefoxitin, 460
- Ceftriaxone, 460
- Celiotomy, 1118f, 1121, 1129
- Cell, 181 (see cytology)  
 hemic, 205  
 inflammatory, 206  
 macrophages, 206  
 manual counter, use of, 179  
 mesenchymal, 206  
 respiratory epithelial, cytology of, 218c  
 sertoli, 756
- Cellulose, undigestible fiber, 81
- Central European tick-borne encephalitis virus, 919
- Central nervous system (see CNS)
- Centrorhynchus, 1012f
- Cephalalexin, 460
- Cephalosporin, pharmacology of, 446, 1046
- Cephalothin, 460
- Cephradine, 460
- Cephulac, 465
- Cere, 160, 609, 770, 1202, 1221
- Cere, color changes in, 774  
 brown hypertrophy of, 609, 631c, 651f, 653f  
 gender determination and, 778
- Cerebellum, 724
- Cerebrovascular accidents, 736
- Cerelose, 496
- Cereopsis Geese, 1243, 1257
- Ceroid, 856
- Certificate of Veterinary Examination, 136
- Cervical spinal cord lesion, clinical signs of, 729
- Cervicocephalic air sac, 558, 1107 (see anatomy overlay)
- Cessation of ovarian activity, 465
- Cestodes, 468  
 in Galliformes, 1232  
 in Passeriformes, 1194  
 in ratites, 1314t
- Chalazae, 754
- Chandelerela, 742, 1315
- Channel-billed Toucan, 1276, 1277f
- Charcoal, activated, 38, 1038, 1265
- Chelation therapy, 459, 1035, 1037, 1038t (see lead, zinc)  
 toxicosis, signs of, 1037
- Chemical cautery, 1113
- Chemistry (see biochemistry)
- Chemosterilant, temporary, 784
- Cherries, 1042
- Chewing lice, in Passeriformes, 1197
- Chick (see neonatology)
- Chicken (see Galliformes)
- Chicken anemia agent, 895
- Chicken, obese strain, 119
- Chicken splenomegaly virus, adenovirus, 903
- Chlamydia*, 313, 352, 459, 462, 529, 532, 533, 984, 989c, 1215  
 antibody tests, 992  
 antigen detection systems, 991, 992t  
 cardiac effects of, 718  
 chicks and, 823  
 clinical pathology of, 989t  
 clinical signs of, 989  
 cloacal swabs for, 991  
 CNS signs and, 745  
 control of, 46, 47, 995 (see doxycycline, tetracycline)  
 cytology of liver and, 215, 221c  
 decreased A/G ratio, 238  
 disinfectants for, 987  
 hepatomegaly, radiographs, 991f  
 histopathology, differential diagnosis, 990  
 in Columbiformes, 1216f  
 in Galliformes, 1232  
 in Passeriformes, 1187  
 in Ramphastidae, 1282  
 in ratites, 989, 1303t, 1314  
 incubation period, 988  
 infection cycle, 985, 986f  
 mycoplasma and, 1058  
 ocular disease and, 683c, 685  
 pancreatic necrosis and, 990  
 PMV-1 pigeon, 926  
 reovirus and, 911  
 serovar, 985



## INDEX

- treatment of, 50, 467, 993, 994  
vs aspergillosis, 1003  
vs influenza virus, 931  
vs mycoplasma, 1060  
zoonotic potential and, 995
- Chlamydiazyme test, 992
- Chloramphenicol, 437, 450, 460, 1046, 1187
- Chlorhexidine, 439, 460, 759, 912, 1003, 1190
- Chloride, 239-240, 849
- Chlorinated biphenyl, 518
- Chlorine, 92, 460, 1061
- Chlorine dioxide, 940
- Chloromycetin succinate, 1262
- Chloroquine phosphate, 460, 1192
- Chlortetracycline (CTC), 439, 447, 448, 460, 994t
- Choana, 344, 485, 487 (see anatomy overlay)
- Choanal atresia, 163f, 297, 576, 577, 684, 823
- Chocolate toxicity, 38, 1044
- Cholecalciferol, 83
- Cholera antiserum, human, 960
- Cholesterol, 233, 234, 465  
cardiac effects of, 270
- Choline chloride, 66, 67, 88, 536, 857  
high fat diet and, 88  
in Pekin ducklings, 1251  
in Anseriformes, 1246  
malnutrition and, 857  
skeletal deformities and, 848
- Cholinesterase, (CHE), 741, 1243  
inhibitor toxicosis, 467
- Chorioallantoic membrane, 792
- Chromaffinoma, 601
- Chromosomal abnormalities, 787, 792
- Chronic ulcerated dermatitis (CUD) (see dermatology)
- Ciconiiformes (bitterns, herons), 933, 1238
- Cigarette smoke, 576, 1001
- Cimetidine, 460
- Ciprofloxacin, 444, 461
- Circadian rhythm, 225, 235, 752
- Circling, 72, 689, 739, 742, 745, 928, 1035
- Circovirus, 894-903, 1232
- Circulatory disorders, 535 (see cardiology)
- Cisterna magna, 724
- CITES (see Convention on International Trade in Endangered Species)
- Citreoviridin, 741
- Citrobacter, 955, 1188
- CK levels, 229, 743
- Claforan, 459
- Clamazolam, 1214
- Clarithromycin, 449
- Claviceps purpurea*, in Anseriformes, 1265
- Clavicular air sac, 1272 (see anatomy overlay)
- Clavulinic acid, penicillin, 445
- Clazuril, 461
- Clearview chlamydia, latex agglutination test, 992
- Clematis, 1041
- Client communication, 132, 134
- Clinafarm, 462
- Clindamycin, 449, 461
- Clinical chemistry values, 1243, 1328t-1345t
- Clips, hemostatic, 1131
- Cloaca, 150, 211, 347, 657, 760  
anatomy of, 762f  
constriction, 1125  
distended, causes of, radiology, 255, 317  
impaction of, 495c, 511  
in ostrich, 1290f  
malnutrition and, 769  
problems in chicks, 769  
prolapse, 404, 495c, 510, 762, 769, 886, 1125  
papular lesions, with poxvirus, 872  
Vasa Parrot and, 769
- Cloacal  
bursa, 116, 368, 509, 1211, 1290  
gland, 757  
lips, in Columbiformes, 1210  
papillomas, 404, 461, 495c, 536, 657f, 769, 886f, 887 (see papillomas)  
promontory, in Passeriformes, 1178  
stricture, 511, 769
- Cloacitis, 510, 769  
with mycoplasma, 1057
- Cloacolith, 769  
with papilloma, 887
- Cloacopexy, 1125f, 1127
- Clomipramine HCl, 461
- Clonic leg twitches, 736
- Clorox, 460, 1048
- Clorsulon, 460
- Clostridium*, 362, 496, 851, 976  
*C. botulinum*, 739, 740, 976, 978, 1263, 1035  
*C. botulinum* in Anseriformes, 1263  
*C. perfringens*, in Passeriformes, 1188  
in Galliformes, 884, 1263  
in ratites, 363c, 1310c
- Clotrimazole, 452
- Clubs, bird, 132
- Clutch  
double, 772  
size, 775, 1209, 1227t  
synchronization, in Galliformes, 1228
- CNS signs, 976, 982t  
herpesvirus in pigeons, 881  
in oil-contaminated Anseriformes, 1263  
viral diseases and, 904, 927  
with salt toxicity, 1044
- CO<sub>2</sub> level and hatching, 795
- Coagulopathy, 638, 687, 1075
- Coal tar products, 518
- Coastal sulci, 561
- Cobactin, 974
- Cobalt, malnutrition, 858
- Coccidia, 459, 461, 464, 466, 468, 507, 551, 852, 883, 1015, 1023, 1190, 1283  
in chicks, 825  
in Columbiformes, 1208  
in Passeriformes, 1191  
in Ramphastidae, 466, 468
- Coccidioides, fluconazole and, 454
- Cocciostat, 1225
- Cochlosoma, 1173, 1179, 1190
- Cockatiel, 20, 75, 462, 465  
color mutations of, 30  
development of, 764  
*Giardia* and, 732  
megabacteria in, 982  
papillomas in, 886  
paralysis syndrome in, 732  
spirochetes in, 961  
stifle luxation in, 836f  
viral disease in, 878, 895, 927
- Cockatoo, 38, 75, 437, 448, 453, 462, 463, 465, 558f, 1331t  
aggression of, 757f  
biochemistry values in, 1329t, 1332t  
drug sensitivity in, 468  
feather picking, 635  
viral disease in, 875, 878, 890, 894, 895, 923, 938
- Cockroach, as disease vector, 742, 1195
- Cod liver oil, in ducklings, 1251
- Codiostomum*, 1011f
- Coelomic cavity, 514t
- Colchicine, 461, 536
- Coligranulomatosis, Hjarre's disease, 508, 951
- Colinus, herpesvirus in, 875, 883, 884
- Colitis, 492c
- Collagen production, inhibitors of, 461
- Collapsing globe, 1103
- Collared Aracarid, 1282
- Colloid solutions, 384
- Collyriculum*, in Passeriformes, 1194
- Color flow doppler, 697, 713
- Color mutations, 30
- Colored foods, problems of, 1177
- Columbidae, 1201
- Columbiformes, 465, 468, 1200-1217 (see pigeon)  
*Aegyptianella* in, 1062  
artificial insemination in, 776  
biochemistry values in, 1337t, 1338t  
gender determination in, 778  
*Mycobacterium* in, 972  
parasitic infections in, 825  
hematology of, 1337t, 1338t  
poxvirus in, 872  
reproduction in, 751, 756  
retrovirus in, 933  
rickettsia in, 1061
- Coma, 411, 414
- Comb, 1219
- Commercial food products (see formulated diets, nutrition)
- Communication, parrot, 96
- Companion bird, characteristics of, 29t, 30  
common diseases of, 22, 32t  
misguided reasons for choosing, 27t  
selection of, 27  
taming, 29 (see behavior modification)
- Complement fixation, diagnosis of aspergillosis, 1003
- Compounding pharmacist, 462
- Compresses, moist, 1097
- Compressive lesions of CNS, 734
- Compulsive obsessive behavior, 464
- Computed tomography (CT), 246, 250, 326, 723, 726, 734
- Conchae, 557, 1105
- Concussion, 733
- Congenital abnormalities, 684, 745, 822, 1321, 1324
- Congestive heart disease, 706, 711, 714, 715t, 715f  
vs cardiogenic shock, 712
- Conjunctival flora, 685t
- Conjunctival scrapings, 675

- Conjunctivitis, 683c, 685-686  
   in Passeriformes, 214f, 1186  
   parasites and, 686, 742  
   sinusitis and, 1106  
   toxins and, 1047  
   viral disease and, 881, 905, 908, 912, 921, 927, 931  
   with *Chlamydia*, 989, 990f  
   with mycoplasma, 1054, 1058  
 Conservation, veterinarian's role, 17  
 Constipation, renal, 850  
 Constricted toe syndrome, 632, 831, 832c, 1097f-1098  
 Constricting fibers, 631, 1097  
 Contraecacum, 1011f  
 Contrast media, 257, 258, 260, 403, 1038  
   enema, 507  
   for gastric foreign bodies, 828  
   transit time delayed, 258  
 Conure, 74, 75, 635, 669, 875, 878, 886, 934  
 Conure bleeding syndrome (erythemic myelosis), 75, 400, 669, 934  
   treatment of, 75  
 Convention on International Trade in Endangered Species (CITES), 22, 49  
 Conversion factors, 469t, 1328t  
 Convolutions, 724  
 Convulsions, 229, 587, 733, 736, 860, 906, 920, 930 (see seizures, tremors)  
   CNS toxins and, 741, 1035, 1050  
   in Anseriformes, 1265  
 Coordination of movement, 724  
 Copper (Cu), 72, 93, 241, 461, 462, 859  
   toxicosis, 504, 774, 1039-1040, 1265  
   and feather quality, 847  
   deficiency, 849, 1038, 1307  
 Copper Pheasant, 1231  
 Coprodeum, 509, 1211 (see anatomy overlay)  
 Copulation, 1129  
 Coracid, 1156, 1158f (see anatomy overlay)  
 Cormorant, 465  
 Cornea, 213, 686  
 Corneal  
   edema, 1103  
   keratinization, salt, 860  
   ulcers, 679, 686, 1100, 1282 (see keratitis)  
 Coronavirus, 914-915  
 Creosol, 518  
 Crimean-Congo hemorrhagic fever virus, 919  
 Crop, 167, 202, 482, 490  
   anatomy 489, 490, 1203  
   bra, 391, 827f  
   burn, 401, 497, 812f, 826, 835c, 1113, 1114f, 1116  
   burn, repair of, 826, 1116f  
   cytology, 218c, 482  
   emptying, delayed, 732-809, 890  
   emptying, increased, 998  
   impaction, causes of, 496, 845, 998  
   in Columbiformes, 1203, 1209  
   in Galliformes, 1222  
   inflation of, 167, 825  
   lavage of, 403, 414  
   milk, 115, 490, 584, 751, 1058, 1209  
   pendulous, 496  
   peristalsis of, 167, 809  
   pH of, 150, 211  
   sour, ingluvititis, 825, 998, 1216  
   stasis, 740, 825, 826, 827c, 845  
   surgery of, 1113  
   wall, thickened, 1210  
 Cross-fostering, 785, 806, 1179, 1180  
 Crow, as disease vector, 920, 959  
 Crown vetch, 1042t  
 Crustaceans, 464, 1045  
 Cryopreservation, of semen, 777  
 Cryosurgery, 887, 1113  
*Cryptococcus*, 452, 454, 456, 463, 464, 466, 575, 1004  
   ocular disease and, 684  
   in Passeriformes, 1189  
   zoonosis and, 1005  
 Cryptophthalmus, 684, 822  
*Cryptosporidia*, 576, 1016t  
   conjunctivitis and, 686  
   in Passeriformes, 1190, 1192, 1198  
   viral diseases and, 897, 910  
 CT scan (see computed tomography)  
*Culex annulirostis*, as disease vector, 915, 917, 934  
*Culicoides* spp., biting midges, 912, 1192, 1315  
*Culiceta melanura*, with togavirus, 915  
 Culling, of breeding birds, 47, 61  
 Culmen, 484  
 Culture  
   deficiencies of, 121 (see bacteria)  
   for *Chlamydia*, 992  
 Cuprimine, 462 (see D-penicillamine)  
 Curassow (see Galliformes)  
 Curled toe syndrome, 733, 789, 1251  
   riboflavin deficiency, 856  
   in ratites, 1292c  
 Cushing pattern, 1124  
 Cushing's syndrome, 598  
 Customs service, 143  
 Cuticle, 754  
 Cuttlefish bone, consumption of, 38  
 Cyanide, poisoning, 1042, 1198  
 Cyanocobalamin (see vitamin B<sub>12</sub>)  
 Cyanosis, 1039, 1265  
 Cyclophosphamide, as CNS toxin, 746  
 Cyclopia, 746  
 Cystadenocarcinoma, cytology of, 218c  
 Cystic follicular degeneration, 798c  
 Cystic ovaries, 769, 770  
 Cystine, in Anseriformes, 1250  
 Cyst, feather (see feather cyst)  
*Cytodites nudus*, 1195  
 Cytology, 199-222 (see cells)  
   abdominal fluid, 208  
   abdominocentesis, 201c  
   acid-fast stain, procedures, 222t  
   air sacs, 212  
   alimentary tract, 209-211  
   aspergillosis, 212f  
   bacterial abscess, 210  
   centrifugation, distortion of cells, 201  
   classification of cellular responses, 205  
   goblet cell, 218c  
   cloacal, 211  
   corneal, 213  
   crop, 210, 218c, 482  
   esophagus, 210  
   flow charts, 216, 217  
   hemoperitoneum, 218c  
   heterophilic inflammation, 218c  
   heterophils, degenerate, definition of, 210  
   hyperplasia, squamous, example of, 210  
   infection vs neoplasia, 206f  
   inflammation, 206, 207  
   internal organs, 214  
   intestine, 211  
   kidney, 215  
   lung, 212, 218c  
   mesothelial, 218c  
   mynah bird, 218c  
   neoplasia, 207, 213, 215, 221c  
   oral cavity, 218c  
   pericardial or peritoneal effusions, 697  
   peritonitis, egg-related, 218c  
   pox, 213, 221c  
   respiratory tract, normal, 211  
   sedimentation devices, 201f  
   septic inflammation, 218c  
   sinus, 202f, 211, 218c  
   skin, 212  
   smears, spreading, 201  
   smears, contact, 204  
   spleen, 215, 221c  
   stains, 205t  
   synovial fluid, 214  
   techniques, squash-preparation, 200  
   tissue hyperplasia, examples of, 207  
   tissue imprints, 376  
   tracheal wash, 211, 221c  
   uterus, 211  
 Cytomegalovirus, 1186  
*Cytophaga*, new duck disease, 964

- D** D-penicillamine, 461, 462, 1037, 1038  
 D-tubocurarine, 674, 728, 1101  
 Dacryocystitis, 684  
 Dactylaria, 741, 1232  
 Dancing, in Passeriformes, 1178  
 Dandelion, 1226  
 DDE, toxin, 1050  
 DDT, toxin, 1050  
 Dead-in-shell, 733, 774, 801  
 Deafness, CN VIII and, 728  
 Debeaking, 916, 1226, 1233  
 Defense (see immune system)  
   nonspecific, 110  
   specific, 114-116  
 Deflighting, Anseriformes, 1269  
 Degenerative joint disease, 424, 1146f  
 Dehydration, 384t, 402t, 698f, 738  
 Deletocephalus, 1011f  
 Delta-aminolevulinic acid dehydratase (ALAD), 241, 1034, 1037  
 Demineralization, 737 (see rickets)  
 Demyelination, EMG, 730  
*Dendritobilharzia*, 742, 1266  
 Denervation, EMG and, 730  
 Department of the Interior, 143  
 Dependovirus, 908  
 Depigmentation, of feather, lysine and, 74  
 Depluming mange, in canaries, 1197  
 Depo-medrol, 465  
 Depolarization wave, ECG, 697  
 Depression, 739, 743, 824, 890  
 Dermacenter, as disease vector, 1061  
*Dermamyssus gallinae*, 59, 808, 1193, 1196  
 Dermatitis, 462, 625-627, 632, 982t  
   bacterial disease and, 624, 625f

- fungal disease and, 607, 609, 610, 611, 624, 625  
 gangrenous, with *Clostridium*, 977  
 granulomas, with *Mycobacterium*, 975  
 in Galliformes, 1219, 1251  
 malnutrition and, 846, 848  
 nicotine and, 1033  
 pantothenic acid and, 856  
 parasitic disease and, 624, 631c  
 periocular, 680c  
 riboflavin and, 856  
 stress-related, 626  
 viral disease and, 623, 632  
 zinc and, 859
- Dermatology**, 11, 605-639 (see feather, integument)  
 achromia, malnutrition, 617  
 aerofoil, effect of, 615  
 alular patagium, 611  
 beak, 609-611  
 biopsy and diseased feathers, survey of  
   histologic lesions, 633t  
 bumblefoot, causes of, 631c, 632  
 burns, 626, 628c  
 canary, male baldness, 637  
 chronic ulcerative dermatitis (CUD),  
   164c, 626f, 627f, 631c, 632, 635  
 collar, use of, 637f  
 constricted toe syndrome, 632  
 database, 622t  
 digits, necrotic, 631c  
 disease, investigation of, 621  
 lipids, dermal sources of, 611  
 liver disease, 637  
 malnutrition, 607, 615, 617, 625f, 626,  
   627  
 molt, 620, 621  
 mutilation, flock, mate, 634  
 pathological terms used in, 633t  
 PBFD virus, 628c  
 polyfolliculitis, 638  
 regions of body, 612f  
 self-mutilation, 631c, 636, 637f  
 skin, 608, 609, 611  
 stress marks, 628c, 633, 634f  
 uropygial gland, 613f, 614  
 wasp, stings from, 624, 631c
- Dermatomycoses in Passeriformes**, 1005, 1189
- Dermoplasty**, 1115
- Detergent, oil exposure and**, 413
- Determinate layers**, 783
- Devocalization**, 1111
- Dewlap**, 607, 1219
- Dexamethasone**, 386, 461, 599, 600, 1262  
 neuromuscular disease and, 734, 736  
 peritonitis and, 771  
 suppression test, 598
- Dextran**, 384
- Dextrose solution**, 393, 461, 738
- Diabetes insipidus**, 584
- Diabetes mellitus**, 235, 771, 1283
- Diagnostic test, limitations of**, 121 (see specific test)
- Diaphragm**, 567
- Diaphysis**, 1142
- Diarrhea**, 149, 150, 404, 465, 740, 742, 744  
 cryptococcosis and, 1004  
 database, 404  
 emergency treatment for, 414
- hemorrhagic conure syndrome and, 934  
 in Anseriformes, 1266  
 in Passeriformes, 1188-1190  
 lead poisoning and, 1264  
 malnutrition and, 845  
 parasites and, 1062, 1194  
 viral disease and, 877, 906, 908, 911-913,  
   922, 926, 927, 931, 935, 938, 942
- Diathesis, exudative**, 855 (see vitamin E)
- Diazepam**, 411, 461, 737, 738, 1038, 1213
- Diazinon, toxin**, 1050
- Dicheilonema**, in ratites, 1314
- Dichlorvos pest strip**, 1050, 1195, 1197
- Dicrocoelid**, 1011f
- Didunculidae**, 1201
- Diet**, 534, 788, 842, 1043, 1178, 1233, 1246 (see feed)  
 antflagellates, 1225  
 Arctic circle waterfowl, 1257  
 bacterial contamination of, 57, 951  
 changing, 78  
 coccidiostat, in Galliformes, 1225  
 deficiency of seeds, 842  
 dyspnea and, 1001f  
 energy content and, 66  
 formulated (see formulated diets)  
 grit, in Galliformes, 1225, 1226  
 hand-feeding neonate, 811t  
 hepatopathies, 845  
 high-carbohydrate, 737  
 high-fat, low calcium, 753  
 high-protein, effects of, 849  
 high-quality protein, 737  
 in Anseriformes, 814, 1247  
 in Columbiformes, 1206t  
 in ducklings, 1248t  
 in Galliformes, 1225  
 in ratites, 1289  
 leg problems and, 1324  
 organic vs conventional, 842, 1049  
 pesticides in, 773  
 storage of, 57
- Dietary guidelines, need for** 70
- Diethylstilbestrol**, 461
- Diff-Quik stain**, 221c, 999
- Diffenbachia**, 1041
- Digit necrosis**, 1187, 1243
- Digitalis, toxicity**, 714
- Digits**, 1187, 1221, 1243
- Digoxin**, 461, 518, 706, 713, 714, 718  
 toxicity and, 709
- Dihydrocholecalciferol**, 587
- Dihydrostreptomycin**, 461
- Dilated cardiomyopathy**, 705t
- Dimercaprol (British Anti-Lewisite - BAL)**, 461, 1038
- Dimethyl sulfoxide (DMSO)**, 46, 419, 461, 469, 762, 1262, 1264  
 semen preservation and, 777
- Dimetridazole**, 461, 741, 1187, 1190, 1193, 1209  
 toxicity and, 1045
- Dimorphism, in ducks**, 1239
- Dinoprost tromethamine**, 462
- Diphenhydramine HCl**, 462
- Diphtheroid lesions (wet pox)**, 873, 881, 908
- Diplotrianena* sp., 1193
- Direct bilirubin (BIDI)**, 1244
- Disease management (see aviary)**
- Dish-washing machine**, 58, 135
- Disinfectant**, 37, 59, 135, 138, 403, 594, 809, 887, 1048, 1073, 1208  
 for bacteria, 979t  
 for *Chlamydia*, 987  
 fumes and aspergillosis, 1001  
 fumes and respiratory damage, 111f  
 in ratites, 1318  
 nursery and, 809
- Dispharnyx*, 59, 496, 1023, 1195
- Diuretic therapy**, 463, 537, 1076
- Diverticulum, in Galliformes**, 1222
- DNA, cell production**, 127  
 fingerprinting, bird identification, 43, 44
- DNA probes**, 122-124f  
 false positive results, 124  
 PBFD virus, positive, 123f  
 polyomavirus negative response, 123f  
 sensitivity, 122, 125  
 specificity, 122, 124  
 use in histology, 124
- Dog, as vector for disease**, 960, 984
- Domestic pigeon (see pigeon)**
- Domoic acid**, 741
- Domoso (see dimethyl sulfoxide)**
- Doppler flow probe**, 1261
- Dopram**, 462
- Dorisiella*, 1191
- Double buff**, 1193
- Double clutching**, 772
- Dove (see Columbiformes)**
- Down**, 616 (see feather down, powder down)
- Doxapram HCl**, 462
- Doxepin HCl**, 462
- Doxycycline**, 437, 448, 460, 462, 784, 827, 1063, 1193  
 for *Chlamydia*, 994  
 medicated food, 994-995t  
 vomiting and, 1046
- Doyle technique**, 1150f
- Dressing, hydroactive**, 1097, 1099, 1133
- Droncit**, 467
- Droppings (see excrement)**
- Drought, effect on reproduction**, 752
- Drowning, in Anseriforme chicks**, 1254, 1260
- Drug doses, conversions and formulas**, 469t
- Dry chemistry**, 227
- DTPA**, 1264
- Duck**, 106, 282, 461, 485, 1265  
 ataxia in, 1265  
 bacteria in, 939, 955, 959, 964, 975  
 beak and, 1249f  
 breeding in, 1252  
 cardiac rhythm in, 1262  
*Chlamydia* in, 985, 987, 989, 995  
 clinical pathology in, 1264, 1341t-1344t  
 convulsions in, 1265  
 dabbling vs diving, 1246  
 diet, pellets vs mash, 1249  
 dimorphic, exceptions, 1239  
 duck hepatitis virus, 532, 537  
 dyspnea in, 718f  
 fungal disease in, 1006  
 gender determination of, 1252  
 heart and, 707  
 lead in, 1036  
 muscular dystrophy in, 1250  
 mycoplasma in 1054, 1057  
 mycotoxins in, 1043

- obesity in, 1248  
 ocular disease and, 685  
 parasites and, 1062, 1265  
 peritonitis in, 1131  
 syringeal bulla in, 1239  
 viral diseases in, 744, 884, 875, 882, 903-938, 1237
- Duck plague, 372, 875, 877, 1237  
 Duck viral enteritis, vaccine, 744  
 Duckling, 938, 1246, 1253  
 Duclidae, 1201  
 Ductus deferens, relation to ureter, 334, 756  
 Duodenal feeding tube, 392, 403, 1124  
 Duodenum, 516 (see anatomy overlay)  
 Dura mater, 724  
 Dwarfism, 586  
 Dyschondroplasia, 848, 860  
 Dysphagia, 872, 887, 1255  
 Dyspnea, 408, 557, 704, 846, 1136, 492c  
 aspergillosis and, 1001f  
 cardiac effects, 713, 714, 718f  
 causes of, 557, 566, 575  
*Chlamydia* and, 989  
 egg binding and, 758  
 emergency treatment for, 414  
 in neonates, 821  
 in Passeriformes, 1188, 1195, 1197  
 liver disease and, 829  
 pericardial effusion and, 708  
 viral diseases and, 744, 872, 884, 887, 890, 911-930
- Dystocia (see egg binding)
- E** *E. coli*, 466, 748  
 cardiac effects of, 705t, 715, 718  
 coronavirus and, 915  
 in ratites 1292c, 1309, 1310c  
 metritis and, 768  
 orchitis and, 774  
 peritonitis and, 772  
 yolk sacculitis and, 1256  
 vs paramyxovirus, 928
- Ear, 344, 352, 838f
- Earthworm, as disease vector, 1194
- Eastern equine encephalomyelitis, 825, 915, 919, 1309
- Eat, reluctance to (see dysphagia)
- ECG (see electrocardiogram)
- Echidnophaga gallinacea*, 624
- Echinacea, 462
- Echinura uncinata*, 496
- Echocardiography, 252, 697, 713
- Eclectus Parrot, 74, 831, 890, 1330t
- Eclipse plumage, 1239
- Ectoparasite, in Columbiformes, 1209, 1215t
- Edema, 302, 848, 855, 1233 (see effusion)  
 of nictitating membrane, 884, 1266
- EDTA, 461, 462
- Edwardsiella*, 951
- EEG (see electroencephalogram)
- Effusion, abdominal, 325
- Egg  
 abnormal, 773  
 adherence to uterine tissue, 408  
 anatomy of, 754f  
 blood clots, meat spots, 773  
 blood spot, 764c, 767c  
 calcium deficient, 787  
 candling, 791, 792f  
 components, 754f  
 dead-in-shell, 733, 801c  
 decreased hatchability, 856  
 double-yolked, 773  
 ectopic, 771  
 evaluation, 785, 792  
 evaporative water loss, in ratites, 1319  
 formation of, 749, 750f  
 fungal infection, 801c  
 handling of, 788c  
 hatch, normal, 786c  
 incubation, 767c, 792, 794, 1229  
 malnutrition and, 859, 860  
 manipulation, 792, 794, 1229  
 marked for identification, 791  
 microbiology of, 794  
 morphology of, 755f  
*Mycobacterium* and, 972  
 mycoplasma and, 1058  
 necropsy of, 792  
 parasites of, 769  
 peritonitis (see egg-related peritonitis)  
 physiology, in ratites, 1320  
 recession of blood vessels, 795  
 repairs, 794  
 retention of, 751, 798c  
 rough-shelled, uterine infections, 773  
 shell, 755, 846, 854, 859, 1292c  
 soft-shelled, 256, 752, 801c, 769, 773, 1050  
 storage of, 788  
 structure and physiology, 753  
 therapeutics, 759, 794, 795  
 tooth, 610, 808  
 toxins and, 1051  
 ultraviolet light exposure, 787  
 viral diseases and, 914, 928, 937  
 washing, in ratites, 1318  
 weight formulas, 792t, 1319  
 xeroradiograph of, 1319f  
 yolk, 764c
- Egg binding, 406, 407, 758, 759f, 760f, 761f, 768, 770, 771f, 772, 787, 801c  
 and neuromuscular disease, 733, 736  
 dystocia, 758  
 in ostriches, 1301  
 treatment of 407f, 414, 759, 760, 761f, 801c
- Egg laying, 407f, 462, 772, 784, 1129  
 chronic, 772  
 frequency of, 807  
 in Anseriformes, 1241, 1244t  
 in Passeriformes, 1176t  
 in Ramphastidae, 1279
- Egg-related peritonitis, 147, 200, 235, 238, 315, 408, 465, 771, 914, 752, 758, 768, 771c, 798  
 in Anseriformes, 1266  
 in Passeriformes, 1188  
 in ratites, 1304, 1322f
- Eimeria*, 1012f, 1015, 1191
- Einthoven's triangle, ECG, 702f
- Ejaculatory papillae, 756
- Elavil, 458
- Electrical fencing, predator control, 1245
- Electrical current stimulation, 1142
- Electrocardiogram (ECG), 553, 696 700, 702  
 African Grey Parrot, normal, 703f  
 anesthetic effects on, 699, 1078  
 atherosclerosis and, 707f  
 auricular T-wave, 700  
 cardiomyopathy and, 717  
 congestive heart failure, 706f, 715f  
 halothane recovery and, 713f  
 in Anseriformes, 1261  
 interpretation of, 701  
 lead II, normal, 700f  
 measurements on lead II rhythm strip, 704  
 P-wave, 700, 704  
 pericardial effusion and, 708f, 718  
 pigeon, 697, 700, 703f, 1204  
 PR-segment, 700  
 Q-wave, 700  
 QRS-wave, 700  
 R-wave, 700  
 recording of ECG, 699  
 reference values, 699t  
 S-wave, 700  
 ST-segment, 700  
 T-wave, 700
- Electrodiagnostics, neurology, 729
- Electroencephalogram (EEG), 723, 731-738
- Electrolytes, 239
- Electromyogram (EMG), 720, 723, 730
- Electron microscopy, 121, 864
- Electrophoresis, 237, 864
- Electrophysiology, 696
- Electrosurgery (see radiosurgery)
- Elementary bodies, 985
- ELISA test, for *Chlamydia*, 991, 992
- Embolicisms, yolk, 458
- Embryo  
 adhesions to CAM, 793  
 assisting hatch, 797f  
 development, 767c  
 lethal rings, 787  
 malposition, 791, 793t, 801c  
 management, 1253  
 monitoring, candling, 791  
 viral diseases and, 926
- Embryonal nephromas, 735
- Embryonic death, 463, 768, 774, 787t, 789, 791t, 792, 855, 890  
 hemorrhage, vitamin E and K, 787  
 in Passeriformes, 1187  
 in ratites, 1319  
 structures and physiologic function, 755t
- Emerald Toucanets, 1278
- Emergency equipment, 415t
- Emergency therapy, 392-416
- Emetics, 503
- EMG (see electromyogram)
- Emollient cathartics, 1038
- Emphysema, 341, 529, 1107, 1137
- Emtryl, 461
- Emu, 499, 506, 543, 916, 1288-1289, 1308-1320, 1345t
- Enalapril, congestive heart failure, and 714
- Encephalin, 584
- Encephalitis, 372, 1054
- Encephalocele, 746
- Encephalomalacia, 731, 732, 937
- Encephalomyelitis, 741, 744, 915, 916, 919, 1309
- Enclosure (see housing)
- Endocarditis, 518, 535, 714, 716f  
 in ratites, 714
- Endocrinology, 582-606

- ACTH stimulation test, use of 598  
 Addison's disease, 598  
 adrenal gland, 597-598  
 adrenocortical disorders, 598  
 $\beta$ - and  $\gamma$ -lipoprotein ( $\beta$ - and  $\gamma$ -LPH), 584  
 $\beta$ -endorphin, 584  
 $\beta$ -melanocyte stimulating hormone ( $\alpha$ - and  $\beta$ -MSH), 584  
 behavior and, 584  
 calcitonin (CT), 587  
 calcium metabolism, 587-589f  
 carbohydrate, metabolism, 603t  
 corticosterone, 597  
 Cushing's syndrome, 598  
 daylight and, 584  
 dexamethasone, screening test, 598  
 Fanconi's syndrome, 605  
 feather formation, endocrine control, 601, 602  
 feather picking, 596f  
 goiter and, 593-594, 596  
 Graves' disease, hyperthyroidism, man, 596  
 Hashimoto's thyroiditis, 596  
 hyperestrogenemia, 592f  
 hyperostosis, 589f  
 hyperparathyroidism, 582, 590, 591f  
 hyperthyroidism, 593, 596  
 hypoadrenocorticism, 598, 601  
 hypothyroidism, 582, 593, 595  
 immunity and, 599  
 insulin, in birds vs mammals, 603  
 Jod-Basedow phenomenon, 596  
 lipoma, relation to thyroid, 595f  
 luteinizing hormone (LH), 583  
 mineralocorticoid activity, 600  
 neurohypophyseal hormones, 583  
 PU/PD, 587, 604, 605f  
 parathyroid hormone (PTH), 587  
 pituitary gland, 583, 586, 587  
 plasma  $T_3$  and  $T_4$ , 595  
 prolactin and proopiomelanocortin (POMC), 584  
 pseudohyperparathyroidism, 590  
 reproductive physiology, and 589  
 stress and, 600f  
 thyroid gland, 584, 593-596, 602  
 thyroxine induced molt, sensitivity to, 597  
 TSH stimulation test, 595  
 water deprivation test, 586  
 Endoscopy, 327-354, 1117, 1124, 1210, 1231, 1264  
 anatomy, 328f, 330f, 333c  
 approaches, 330f  
 biopsy and, 346-354, 348t, 505  
 choana, 344, 352c  
 cloaca, 347  
 collecting fluid, pericardial effusion, 718  
 contraindications, 340, 341  
 crop evaluation and, 352c, 1116  
 ear canal, 344, 352c  
 esophagus, 345, 352c  
 equipment manufacturers, 349t, 354  
 gonads, 334, 343, 349  
 in Passeriformes, 1178  
 landmarks, 331f, 333c  
 liver biopsy, 352c  
 Menghini or Jamshidi needle, 349  
 oral cavity, 352c  
 palate, 352c  
 patient preparation, 339, 341  
 proventriculus, 345, 352c  
 renal disease and, 347  
 respiratory tract and, 341, 342, 346, 348, 352c  
 spleen and, 348  
 sterilization of equipment, 338  
 surgical sexing, 341  
 ventral hepatic peritoneal cavities, 346, 351c  
 Endotoxins (bacteria), 1033  
 Energy requirements, 74, 1249  
 Enilconazole, 454, 455, 462, 1004  
 Enrofloxacin, 436, 443, 460, 462, 1060, 1187  
 articular cartilage and, 821, 1046  
 medicated food for *Chlamydia*, 995  
 oral vs parenteral, 438  
 plasma concentrations of, 435f  
 Enteral nutrition, 390, 394, 395, 1086, 1125  
 Enteritis, 174, 464, 466, 483, 492c, 507, 845, 906, 940f, 952, 982t  
 in Galliformes, 1233  
 necrotic vs ulcerative, 977  
 viral, 912-915, 938  
*Enterobacter*, 715, 951  
 Enterobacteriaceae, 484, 950, 990, 1188  
 abnormal hosts and, 951t  
 lactobacilli, 111, 980  
*Enterococcus*, 968-971, 1187  
 Enterotomy, 1124  
 Enterovirus, in cockatoos, 938  
 Entropion, 679  
 Enucleation, 689, 1103f  
 Environmental responsibility, domestic raised birds, 142  
 Enzyme inhibitors, 67  
 Enzymes, damaged cell release, 226, 525  
 digestive, 844, 845  
 Enzymology, 226, 523-536  
 Eosin-nigrosin stain, for semen evaluation, 757  
 Eosinophilic inclusion bodies (Cowdry A type), 878  
 Eosinophils, 112, 186, 190-194  
 Epicardial diseases, 718  
 Epididymis, 334, 756, 757  
*Chlamydia* and, 990  
 Epinephrine, 463  
 Epiphora, 576, 684, 885, 905, 931, 1101  
 Epiphysis, 1142  
 Episiotomy, 760, 1129  
 Epistaxis, 934, 1051  
 Epithelial surfaces, nonspecific immunity, 110  
 Epithelioid cells, with *Chlamydia*, 987  
 Epitopes, 114  
 Equatorial birds, photoperiod of, 752  
 Ergocalciferol, 83  
 Ergonovine maleate, 463  
 Ergotism, 1265, 1282  
*Erysipelothrix*, 535, 715, 975, 1183, 1232  
 Erythremic myelosis, 669, 934  
 Erythroblastosis, 933, 1197  
 Erythrocytes, 183, 188  
 iron in, 530  
 life span of, 399  
 protoporphyrin levels, free, 1037  
 values, in vitamin C, 1251  
 Erythroleukosis, 934  
 Erythromycin, 438, 442, 449, 459, 463, 1060, 1189  
 Erythropoiesis, 183, 196  
*Escherichia coli*, 814, 951-953, 1188  
 in Galliformes, 1232  
 in Ramphastidae, 1281  
 Esophageal  
 air sac, in Galliformes, 1222  
 stethoscope, 1078, 1261  
 strictures, 497, 1113  
 thermometer, 1261  
 Esophagus, 352, 345, 489-492, 1265  
 Estrogen, 753  
 Ethambutol, 463  
 Ethanol, 1044, 1198  
 Ethoxyquin toxicity, 1045  
 Ethylene glycol, 538, 1044  
 Eucalyptus, 573  
 Euthanasia, 61, 357, 822, 1138  
 Euthyroid, 597  
 Evoked potentials, 730  
 Examination (see physical examination)  
 hospitalized, daily assessment, 135  
 initial, forms, 135  
 post-purchase, 132  
 resident bird, 61  
 veterinary certificate of, 136  
 Excrement, 149, 150, 169, 172c, 495, 769f, 819, 887, 943, 989, 1044, 1189  
 blood in (see hematochezia)  
 consistency, changes in, 743  
 evaluation of, 60, 172c  
 pericloacal accumulation, 168  
 Excretory urogram, 307  
 Exercise, 1178, 1207, 1221, 1324  
 intolerance to, 1136  
 Extrahepatic biliary cysts, 822  
 Exertional rhabdomyolysis, 550, 855, 1263  
 Exocrine pancreatic insufficiency, 507, 513  
 Exophthalmos, 684, 736  
 Expirations, respiratory, audible, 557  
 Extensor carpi radialis, 1235 (see anatomy overlay)  
 External coaptation, 1145  
 External fixator, 1141  
 Kirschner-Ehmer (KE), 1148  
 Extraluminal masses, radiology, 255  
 Exuberant granulation, in ratites, 1310c  
 Exudative diathesis, 732, 859  
 Eye  
 anatomy of, 675f, 678f  
 blink, 728, 732  
 canthoplasty, 1100-1101f  
 chronic lesions in, 1184  
*Mycoplasma* and, 1056  
 parasites in, 1195  
 surgery of, 687  
 Eyelid malformation, neonate, 838  
 Eyelids, swollen, 885  
**F** Facial nerve (CN VII), 726  
 Falconiformes, 19, 508, 557, 773, 873, 875, 880, 882, 973, 933, 1001  
 Falling from perch, and neuromuscular disease, 737  
 Fasting periods, 852, 1077  
 Fat  
 dietary considerations of, 76, 81, 855, 1202, 1248

- disease of, 851, 856
- Fatty acids, malnutrition, 851
- Fatty liver degeneration, 311, 526, 533, 536, 828, 844, 851, 857, 1198, 1246, 1251
- Fatty liver hemorrhagic syndrome (FLHS), 851
- Feather
- abnormalities, 144, 159, 463, 625, 824, 837, 846 (see feather picking, dermatology)
  - anatomy, 614f, 615, 616t, 616-621
  - barbules, 614, 615f, 621
  - bristles, 616
  - color, 74, 617t-618, 847f, 626
  - cyst (*Hypopteronosis cystica*), 628c, 638, 673, 1098, 1099, 1183
  - depigmentation, 74 (see depigmentation, feather)
  - development, 619f
  - down, 616
  - dysplasia, 837, 846
  - dystrophy, 463, 616, 625f, 628c, 638, 890, 926
  - filoplumes, 616
  - follicle, inactive, 637
  - folliculitis, 625
  - growth, in neonates, 819f
  - hemorrhage, with polyomavirus, 890
  - hepatic dysfunction and, 632
  - hydrophilic compounds and, 623
  - hyperkeratosis and, 609, 618f, 632
  - hypothyroidism, 637
  - interlocking nature of, 628f
  - loss of, 772, 1246, 1317
  - malcolored, from hepatic dysfunction, 632
  - malnutrition and, 628f, 846
  - mites, in Passeriformes, 1196
  - molt (see molt)
  - pin, 143, 159, 618, 628c, 634
  - removal, 1084f
  - secondary, 615
  - in ratites, 1295c
  - semiplumes, 616
  - sheath, retention of, 159, 846
  - types, 615, 616, 1139
  - waterproof, 615
  - curling of, in ratites, 1298
- Feather picking, 38, 461, 462, 464, 466, 468, 523, 572, 631c, 634, 636, 637, 846, 1233
- tobacco smoke and, 1047
- cannibalism and, 916
- malnutrition and, 596, 810, 847f, 857
- Feather duster, budgerigar, 873, 880
- Feces (see excrement)
- Fecal
- examination for parasites, 150, 379, 1009 (see parasites)
  - sex steroid determination, 779
- Food and Drug Administration (FDA), extra-label drug use, 142
- Feed
- consumption, pigeons, 1206
  - for Galliformes, 1233
  - for aviary birds, 50
  - for Passeriformes, 1178
  - general recommendations, 50
  - gram-negative pathogens in, 57, 149
  - growth additives in, 1246
  - storage of, 57f, 57, 1178, 1233
  - passing undigested, 483, 855, 887, 940 (see passing whole seeds)
  - mycotoxins in, 1043
  - mites, 1206
- Feeding
- response, and neurologic disease, 728
  - seasonal, 1178
  - techniques, 37-38, 393, 1255
  - tubes, 1086, 1111, 1124
- Femur (see anatomy overlay)
- in egg laying hens, 753
  - surgical approach to, 1163f
- Fenbendazole, 463, 1314, 1194, 1195
- toxicity of, 1046
- Fence, for ratites, 1300, 1301
- Fennel leaf pond weed, 1247
- Ferric subsulfate, 399, 463
- Fertility, 732, 785, 1039, 1225
- Fertilizers, and Anseriformes, 1266
- Fiber, crude, in formulated diets, 76
- Fibrillation potentials, 730
- Fibrinous air sacculitis, 885
- Fibrohistiosarcoma, 486
- Fibrosarcoma, REV, 934
- Figure-of-eight bandage (see bandage)
- Filaridea, 371, 1024f, 1315
- Filoplumes, 616
- Finch, 97, 154c, 372, 450, 464, 465, 1173, 1186, 1188, 1190, 1193, 1336t
- amyloidosis in, 1198
  - bacteria and, 956, 973, 1060
  - characteristics of, 1174t
  - Chlamydia* in, 989
  - megabacteria in, 982
  - ocular disease and, 685
  - parasites and, 467, 1192, 1194
  - praziquantel toxicity in, 467
  - reproduction and, 752, 756, 780, 1175
  - straw feathers in, 1184
  - toxicities in, 1050
  - toxoplasmosis in, 742
  - twirling syndrome in, 928, 939
  - vasectomy of, 1178
  - viral diseases and, 875, 884, 889, 891, 912, 916, 927, 955
- Fish and Wildlife Service, 143
- Fish
- feed for Anseriformes, 1246
  - meal, ventricular ulceration and, 851
  - toxicity, 464, 468
  - eating birds, *Erysipelothrix* in, 975
- Fistula, crop, 116, 826, 1113
- Fixation
- external 1141-1148f, 1141, 1147t,f
  - intramedullary, 1148
  - types of, 1138t
- Fixatives, 378t
- Flaccid paralysis, 978
- Flagellates, 1013
- Flagyl, 466
- Flamingos, 550, 1237
- Flatulence, 887
- Flavivirus, 915, 918-919
- Flea, 154, 624c, 1024
- collars, toxic, 1051
- Fledging
- of Anseriformes, 775, 1253
  - of Columbiformes, 1210t
  - of Passeriformes, 1176t
- Flies, as disease vector, 624, 739, 742, 977
- Flights, training, in Columbiformes, 1204
- Flock
- acclimation of, 50
  - acquisition of, 47
  - behavior, 806
  - disease testing, subclinical, 46, 48
  - health of, 45, 48
  - identification of, 49
  - preventive medicine, 46-59
  - pre-sale testing, 47
  - quarantine of, 48
  - screening techniques, 48
- Flooring, padded, in Anseriformes, 1244
- FLSH (see fatty liver hemorrhagic syndrome)
- Fluconazole, 454, 455, 463, 999
- Flucytosine, 452, 459, 463, 999, 1004, 1005
- toxicity of, 1046
- Fluid, 821
- deficit, estimation of, 384
  - dehydration, findings, 384t
- Fluid therapy, 384, 385f, 386f, 387, 611, 1026, 1074f
- requirements for, 383
  - sodium retention, 712
- Flukes, 463, 769, 1021, 1215, 1282 (see trematodes)
- in ratites, 1316
- Flunixin meglumine, 413, 463, 836, 1095
- Fluorescein dye, for corneal ulcers, 674, 686
- Fluoroquinolones, 442-443
- Fluoroscopy, 260
- Flying, 729, 1178, 1207, 1221, 1239
- Foley catheter, 393
- Folic acid, 72, 87, 857, 1251
- feather picking and, 846
  - malnutrition and, 87, 857, 858
- Follicle stimulating hormone (FSH), 583, 584, 751, 753, 757
- Follicular atresia, aflatoxicosis, 749
- Folliculitis, 625
- Food (see feed)
- Foot
- baths, 58
  - cracking of, 632
  - lesions, 625, 632, 743, 1265f
  - pads, 608f
- Foreign body, 488f, 686, 503f
- in Galliformes, 1222f
  - ingestion, in ratites, 1305
  - ingestion, neonate, 828
- Formaldehyde, ingestion vs *Candida*, 999, 1048, 1061
- Formulary, 457-479
- Formulated diets, 38, 63, 65, 76, 132, 389, 469, 814, 845, 848, 849, 851, 854, 1030, 1046, 1133 (see diets)
- Formulator, 476-477
- Foster parents, 785, 788, 806
- Fovea, 677
- Fowl
- adenovirus (FAV) in, 903
  - cholera, 961
  - domestic, 757, 773
  - favus, 1005
  - plague, avian influenza A (AIV), 929, 930
- Fowlpox vaccine, in ostriches, 874

## INDEX

- Fox, 1207  
 Foxglove, 1041  
 Fracture, 591, 1164 (see orthopedic surgical technique)  
   electrical stimulation, 1142  
   diagnosis of, 246, 250  
   in Galliformes, 1233  
   in ratites, 1306  
   malunion of, 1142  
   mandibular, 1164  
   tarsometatarsal, 1160f  
   types of, 1141  
 Fracture stabilization, 428, 1138, 1146-1148  
   principles of, 1138t  
*Francisella*, 964, 1232  
 Free flight, in aviaries, 1178  
 Free radicals, 84  
 Free-ranging birds  
   captive birds vs dietary fat, 851  
   disease in, 906, 929, 962  
   *Mycobacterium* and, 972  
   orthopedic surgery of, 1138  
   poisoning of, 1051  
   vs captive, 847  
   waterfowl, loss of weight in, 1253  
 French moult, causes of, 623, 869c, 890, 899  
 Frostbite, 413, 414, 715, 775  
   in Anseriformes, 1243  
   in Galliformes, 1233  
 Frounce, 491  
 Fruits, in Galliformes, 1225  
 FSH (see follicle stimulating hormone)  
 Fumes, household, 576, 1049  
 Functional ileus (see ileus)  
 Fungal dermatitis, STA solution and, 468  
 Fungal infections, treatment of (see mycoses)  
 Fungizone, 459  
 Funnel nets, 1260  
 Furacin, 1187  
 Furazolidone, 463, 518, 1307  
 Furcula, wishbone, 1221  
 Furosemide, 413, 458, 463, 518, 554  
   brain swelling and, 411  
   heart disease and, 706, 713  
   side effects of, 714  
 Fusariotoxicosis, 1265  
*Fusarium*, 1043, 1044, 1265
- G** Gadwall, 1247  
 Gaggling, 1190  
 Gall bladder, 522, 1202, 1223, 1290  
 Galliformes, 465, 1194, 1195, 1218-1236, 1248, 1338, 1339  
   aspergillosis in, 1000  
   bacterial diseases in, 959, 960, 964t, 973, 977  
   *Campylobacter* in, 959  
   cardiomyopathy and, 717  
   clutch size, 1227  
   coccidia and, 459, 461, 466  
   diseases of, 1232  
   Enterobacteriaceae in, 484  
   families and subfamilies, 1220t  
   hypovitaminosis A and, 487  
   incubation times and, 1227  
   levamisole toxicity and, 1045  
   longevity and, 1223t  
   megabacteria in, 982  
   parasites and, 769, 1061, 1265  
   physiology of, 1221  
   streptomycin and, 468  
   vent sexing and, 778  
   viral diseases and, 744, 776, 872, 875, 884, 903, 907, 912, 914, 916, 919, 922, 923, 926, 929, 932, 934, 935, 937, 1054, 1056  
*Gallus gallus, forma domestica*, 1218  
 Galvanized wire, 54  
 Gamebirds, 1218  
 Gander, castration of, 1274  
 Gangrenous dermatitis, 967, 1187  
 Ganglioneuritis, 501, 939 (see NGD)  
 Gapeworm, 464, 574, 1195  
 Gas chromatography, toxin detection, 1050  
 Gas exchange, 569  
 Gastric acid secretion, inhibitor of, 460  
 Gastric  
   impaction, 501, 503  
   lavage, 828, 1038, 1264  
   ulceration, 460, 504  
 Gastroenterology, 482-521  
   ascites, 516-517  
   bacterial inhabitants of, 484  
   beak and, 484, 485f  
   ceca, 506  
   choanal papillae, hypovitaminosis A and, 487  
   cloaca, anatomy and physiology, 495c, 509f,t, 510c, 511  
   cloacal bursa, bursa of Fabricius, 495, 509c  
   coelomic cavities in birds, 514t  
   colon strangulation, 495c  
   crop, diseases of, 489, 489f, 490, 491, 495c, 496  
   diagnostic tools, techniques for, 482  
   differential diagnosis of, 483t  
   dilatation of, 495c  
   duodenum, 506  
   esophageal disorders, 490, 492  
   esophagus, anatomy and physiology, 489  
   foreign bodies, 488, 503f  
   gall bladder, 522  
   gastrointestinal diseases, upper, 487t  
   gastrointestinal neoplasias, 505t  
   gastrointestinal perforation, 508  
   ileus, 507  
   ingluviolith, 495c, 497f  
   intestinal obstruction, causes of 503, 508  
   intestines, anatomy and physiology, 506  
   maldigestion, 514  
   motility, 465, 1203  
   neoplasia of, 505  
   neuropathic gastric dilatation, 500, 500t, 501, 502f  
   oropharynx, anatomy and physiology, 485, 486f  
   palatine beak necrosis, 488f  
   pancreas, 512-513  
   papilloma, 512f  
   peritoneal cavities, 515  
   proctodeum, 509  
   proventriculus, 492, 492c, 498-499  
   rectum, 506  
   regurgitation and, 490f  
   rhinotheca, 484  
   Smadel's disease, 486  
   stomatitis, 488  
   tongue, 489  
   traumatic gastritis, 503  
   ultrasonography, ascites in, 517  
   urodeum, 509  
   ventriculus, 499, 503  
   vitamins and, 504, 514  
   volvulus, 508  
   vomiting, 492c  
   zinc toxicosis and, 1039  
 Gastrointestinal tract  
   displacement of, 258  
   normal flora of, 484  
 Gender determination, 148t, 154, 344, 499, 756, 757, 778, 779, 1231, 1277  
   in Anseriformes, 1239, 1252  
   in Columbiformes, 1210  
   in Galliformes, 1228  
   in Passeriformes, 1178  
   in Ramphastidae, 1277t  
   in ratites, 1291  
   sexual dimorphism and, 77, 779t  
 Genetic  
   and chick, 805  
   disease, 720, 784, 1182, 1226  
   selection, for heart disease, 713  
 Genital tract, and mycoplasma, 1054  
 Gentamicin, 239, 446, 463  
 Gentian violet, 464  
 Geothermal energy and incubation, 1229  
 Geriatric birds, nutrition in, 72  
 Germinal disc, description, 754  
 GGT (see alanine aminotransferase)  
 GI blockage, 887 (see gastrointestinal blockage, ileus)  
 Giardia, 174c, 461, 464, 466, 495c, 631c, 1014, 1283  
   cockatiel, paralysis and, 732, 845  
   hypovitaminosis E and selenium, 852, 855  
   in finches, 1190  
   in Ramphastidae, 1282  
   in ratites, 1314  
   lid paralysis and, 680c, 686  
   nestling mortality and, 807  
 Giemsa stain, 987  
*Gigantobilharzia*, 1194  
 Gizzerosine, ventricular ulceration, 851  
 Glands, 608, 675, 1129, 1221, 1245  
 Glauber's salts (sodium sulfate), 1038  
 Glaucoma, 687  
 Glomerulonephritis, 352c  
 Glossopharyngeal nerve (CN IX), 726  
 Glucagon, birds vs mammals, 603  
 Glucocorticoid, 600t  
 Glucose (GLU), 234, 243, 1244  
   effect of, 542  
   kidney filtration of, 539  
   relationship to hepatic dysfunction, 235  
 Glucosuria, 243, 464, 539, 548, 636  
 Glue traps, rodents, 413  
 Glutamate dehydrogenase (GLDH), 230  
 Glutathione peroxidase (GSHp), 84  
 Glycerol, semen storage, 777  
 Glycogen body, 726  
 Glycopyrrolate, 1261  
 Gnathotheca, 484  
 Goblet cells, cytology of, 218c  
 Going light syndrome, megabacteria, 982  
 Goiter, 594-596, 461, 464-465, 495c, 594-596, 860  
 Goldfinch, ivermectin in, 464

- Gonadotrophin, suppression of, 584  
 Gonads, 343, 1131  
 functional relationship of, 758  
 Gongylonema ingluvicola, 496  
 Goose, 501, 875, 907-908, 910, 912, 934, 936, 1243  
 aggressiveness in, 1243  
 bacterial diseases of, 950, 956, 959, 975, 963, 973, 1054, 1057, 1060  
*Candida* in, 998  
 danger to children, 1243  
 Derzsy's disease, parvovirus in, 908  
 diets of, 1249  
 fatty liver in, 851  
 fungal disease in, 1006  
 mebendazole in, 465  
*Neisseria*, sexually transmitted, 774  
 nutrition in, 1247  
 pair bond in, 1252  
 parasitic diseases of, 960, 1062, 1266  
 respiratory rate of, 1243  
 sexual maturity in, 1252  
 viral diseases of, 875, 877, 907, 908, 910, 912, 920, 929, 931, 934, 936, 939  
 Goose-stepping, pyroindixine and, 856  
 Goslings, nephroenteritis, 943  
*Gossitis gelatinosa circumscripta*, in Anseriformes, 489  
 Gouridae, 1201  
 Gout, 458, 461, 540, 547, 829, 849  
 allopurinol and, 458  
 articular, 850  
 causes of, 850  
 in ratites, 1295c  
 visceral, 850  
 Grackles, as disease vector, 1315  
 Graft (see bone)  
 Graft rejection, 120  
 Grains, in Galliformes, 1225  
 Gram scale, 136f  
 Gram's stain, 1187  
 antibiotics, and, 436f, 437, 442, 443, 807  
 monitoring chicks and, 412, 824  
*Candida* and, 999  
 yeast, and treatment, 436  
 Gram-negative bacteria, 436f, 437, 443, 807  
 Gram-positive bacteria, 437, 443  
 Granulocytic leukemia, 186, 669  
 Granuloma, 683c, 745, 952  
 CNS signs and, 745  
*Mycobacterium* and, 973, 975  
 Granulomatous  
 dermatitis, 955, 962  
 ingluvitis, 1188  
 sinusitis, amphotericin B and, 459  
 Granulosa cell tumor, 770  
 Green foods, 1178  
 Grey-cheeked Parakeet, 30, 656  
 Grid keratotomy, 687  
 Griseofulvin, 1190  
 Grit, 38, 77, 496, 846, 1038  
 in Anseriformes, 1247f  
 in Galliformes, 1225  
 shell vs, 846  
 Grooming, excessive, 1269  
 Grouse, 960, 977, 1220, 1229  
 Growth hormone (GH), 584  
 Growth plate, 1142  
 Growth rate, 815, 829, 1243  
 Gruber-Widal method of antibody titration, 959  
 Gruiformes (see cranes)  
 Guinea pig, *Chlamydia* in, 984  
 Guineafowl (see Galliformes)  
*Gymnodinium breve*, 1266
- H** Habronema, 1011f  
 Haecaputeus, 1019  
*Haemophilus*, 221c, 961, 963, 1189  
 clinical disease and, 964t  
 differential diagnosis of, 982t  
 in Galliformes, 1232  
*Haemoproteus*, 190, 194c, 468, 1176, 1192  
 Hafnia, pathogenicity of, 951  
 Halodol (see haloperidol)  
 Halofuginone, 1225  
 Haloperidol, 464, 637  
 Halothane, 569, 1068, 1261  
 cardiac effects of, 705t, 709, 711, 713f  
 Haloxon, 464  
 Hand-feeding, 468, 806f, 808, 812, 813  
 diet, 395, 812, 813t, 814f, 846  
 feeding amounts and frequency, 813  
 in Columbiformes, 1210  
 methods of, 812  
 percent solids, cooking effects, 812  
 species differences, 822  
 tubes, 813  
 Haptens, 114  
 Harderian gland, 116, 675  
 Hardware disease in ratites, 1313c  
 Harvesting free-ranging birds, 21-22  
 Hatchability, 72, 856, 890, 1253  
 decreased, from malnutrition, 849, 855  
 in ratites, 1318  
 pesticides and, 1051  
 mycoplasma and, 1054  
 Hatching, 786f, 793  
 in Anseriformes, 1253  
 in ratites, 1320  
 muscle, 793  
 records, 793  
 Hawk-headed Parrot, 30, 886, 911  
 Hay, aflatoxin in, 69  
 Head  
 and neck extension, schistosomiasis, 742  
 trauma, 410, 414, 465  
 tremor, 689, 743, 744, 1035, 1264  
 Head tilt, 742, 745, 1035  
 CN VIII defect, 728  
 heavy metal toxicosis, 739, 1035  
 twirling syndrome, in finches, 928  
 Healing process, of bone, 1140  
 Health  
 certificate, 31, 133, 136  
 exam, new bird, 31  
 factors in, 65f  
 guides for choosing a new bird, 31  
 Heart, 695 (see cardiology, cardiac)  
 anesthetic effects on, 1077  
 arrhythmias, 705  
 auscultation of, 1078  
 AV blocks, 709, 710  
 disease, clinical signs of, 371, 696  
 electrically vertical, 702, 704f  
 electrophysiology, 696  
 failure, right-sided, 713  
 imaging, 697, 698f  
 lesions, common causes of, 717t  
 surgery of, 718  
 ventricular septal defect, neonate, 816f  
 Heart rate  
 determination of, 148t, 701  
 ECG (see electrocardiogram)  
 in Anseriformes, 1243  
 in Columbiformes, 1204  
 in Galliformes, 1221t  
 Heat loss, in Anseriformes, 1243  
 Heaters, fumes, toxicity, 1049  
 Heavy metal toxicity, 173c, 248, 349, 468, 739, 937, 1038t (see lead, zinc, toxin)  
 CNS signs and, 739  
 myocardial lesions and, 717  
 renal damage and, 553  
 shell and, 846  
 Helmeted Curassow, trachea, 560 (see Galliformes)  
 Helmeted Guineafowl, 1218  
 Helminths, 532, 1021, 1208  
 Helper cells, 118  
 Hemacolor, stain, *Campylobacter* and, 484  
 Hematochezia, 149, 164c, 172c, 404, 483t, 887, 982  
 Hematology, 176-198, 1330t-1345t  
 anemia, causes of, 188t  
 basophil development, 190, 193c  
 blood cells, characteristics of, 186t  
 blood film, 178  
 blood parasites, identification of, 190  
 bone marrow, collection of, 191  
 cells, identification of, 181, 186  
 corpuscular hemoglobin concentration, mean (MCHC), 180  
 corpuscular volume, mean (MCV), 180  
 EDTA, 177, 178  
 eosinophil, 189, 190, 193c, 194  
 erythrocyte, 183c, 188, 196  
 erythropoiesis, 183c, 196  
 granulopoiesis, 196  
 hematologic stains, 179  
 hemogram, 188, 194c  
 heparin, 177  
 heterophil, 189, 193c  
 leukocyte, 180  
 leukocytosis, 188, 189, 194c  
 leukogram, interpretation of normals, 188  
 leukopenia, causes of, 189  
 lymphocytes, reactive, 194c  
 lymphocytosis, causes of, 189  
 manual cell counter, use of, 179  
 methylene blue stain, 180  
 monocyte development, 184c  
 monocytosis, causes of, 189  
 myeloblast, 193c  
 Natt and Herrick's method, 180  
 packed cell volume (PCV), 179  
 polycythemia, causes of, 188  
 polymphocyte, differentiation of, 197  
 prorubricyte, basophilic erythroblast, 196  
 red blood cell count (RBC), 179  
 reticulocyte count, 180  
 rubricyte, hemogram, 194c  
 thrombocyte, interpretation of, 190  
 thrombocytopoiesis, 183c, 196  
 toxic heterophils, 194c  
 Unopette system, cell counting technique, 179



## INDEX

- white blood cell counts (WBC), 181t  
Wright's stain, standard, 179
- Hematuria, 150, 890, 1040
- Hemicellulose, 458, 464, 536, 844, 1038  
(see psyllium)
- Hemochromatosis, 209, 409, 464, 517,  
526c, 534, 713, 849, 1198, 1281f  
in Passeriformes, 1197  
in Ramphastidae, 1281  
renal, 547c  
treatment of, 530, 536
- Hemoglobin values, vitamin C and, 179,  
1251
- Hemoglobinuria, 1035
- Hemogram, 176, 1330t-1345t  
normal cockatoo hen and, 753t
- Hemolysis, glucose, effect on, 234
- Hemoparasites, 1019
- Hemopericardium, 718
- Hemoperitoneum, 218c
- Hemorrhage, 398, 399, 464, 526, 890,  
916, 927, 934, 1051, 1087-1089,  
1233, 1265  
control, 39, 399, 463, 1113, 1269
- Hemorrhagic  
conure syndrome, 934  
enteritis, EEE, emu, 916  
nasal discharge, PMV-3, 927  
syndrome, with sulfa antibiotics, 1045
- Hemosiderosis, 366
- Hemostatic clip, 1034f, 1086, 1103, 1129,  
1131, 1135
- Hen, reproductive  
anatomy, 749 (see anatomy overlay,  
endoscopy)  
disorders, 758  
hormones, 751
- Henle, loops of, 539
- Hepadnavirus, orthohepadnavirus,  
909-910
- Heparin, 1135
- Heparinized flushes, 387
- Hepatic  
anesthesia and, 1068  
damage, 73, 632 (see hepatitis, liver)  
dysfunction, relationship to glucose  
level, 235  
encephalopathy, 525, 736  
fibrosis, 461, 530, 537  
lipidosis, 88, 215, 221c, 828, 829f, 1198  
stenosis, 533
- Hepatitis, 148, 154, 221c, 405, 462,  
526c, 529, 714, 798c, 982t, 312,  
1054, 1062c  
black, *Plasmodium*, 529c  
granulomatous, mycobacteriosis, 529c  
relationship to glucose level, 235  
viral, 904, 906, 909, 916
- Hepatocellular carcinoma, 1197
- Hepatocellular necrosis, 889, 529c
- Hepatology, 522-537 (see liver)  
ammonia tolerance test, 530  
ascites and, 523, 530, 537  
aspergillosis and, 535f, 526c  
beak, overgrowth and, 523  
bile acids, 525, 530  
bile salts in skin, pruritus, 523  
biliverdin reductase, 523  
biliverdinuria, 523, 526c  
chlamydiosis and, 537  
colchicine and, 537  
corticosteroid and, 537  
enzymology, 523-530  
enzyme activities, 463, 523-530  
enzyme activities, liver vs muscle  
disease, 525t  
fatty liver, 526c, 529c, 533, 534  
hepatic encephalopathy, 525  
hepatic fibrosis, 531f, 537  
hepatomegaly, 523, 533f, 529c  
icterus and, 523  
jaundice and, 523  
malnutrition and, 526, 533, 536  
neoplasia and, 536  
parasitic disease and, 529-533, 529c,  
536, 537  
portal hypertension, 536  
radiology, 530  
serum iron concentration, 530  
toxins and, 529, 530, 535-537  
traumatic rupture, 536  
ultrasonography, 536  
viral diseases and, 527, 532, 537
- Hepatomas, 829
- Hepatomegaly, 523, 529, 533f, 719, 823,  
1121, 1197  
differential diagnosis of, 254t  
cardiac disease and, 697
- Hepatopancreatitis, with coronavirus,  
914
- Hepatopathies, 485f, 858, 1075
- Hepatosplenomegaly, 532
- Hepatotoxins, 335-337, 529, 1043
- Herbst's corpuscles, 609, 1249
- Hernias, abdominal, 1132
- Herniorrhaphy, 1132
- Hérons, 910, 1238
- Herpesvirus, 874-885  
*Chlamydia* vs, 990  
CNS signs and, 687  
cross-reactions, 876t  
differential diagnosis of, 871t  
in Galliformes, 1232  
in Passeriformes, 1186  
in Ramphastidae, 1282  
inclusion bodies and, 874  
ocular disease and, 687  
PMV-1 pigeon vs, 926  
survey of hosts, 875t  
treatment of, 878, 879
- Hetastarch, 384
- Heterakis*, 361, 367, 644, 1023  
in Galliformes, 1235f
- Heterogametic gender, 779
- Heterophil, 111, 112, 186, 189, 194, 1206  
(see hematology)  
left shift, 111
- Heterophilia, 915, 934, 1003, 1063 (see  
hematology)
- Hexamita*, 459, 462, 466, 732, 1015
- Hind limb paresis, progressive, 736
- Hippoboscid flies (*Ornithomyia  
avicularia*), 190, 1010f, 1197
- Histology, relation to biochemical  
changes, 226
- Histomonas*, 366, 459, 461, 464, 1015  
in ratites, 1314
- Histopathology, problems of, 121
- Histoplasma, 454, 1005
- Hjarre's disease, coligranulomatosis, 951
- Hock, enlarged, zinc deficiency, 848, 859  
enlarged, vitamin E, 855
- Holocrine secretion, in Columbiformes,  
1210
- Homogametic gender, 779
- Hoarding, 1233
- Hopping, and neurologic disease, 728
- Hormonal cycle, diminishing exposure to  
light, 772
- Hormone (see endocrinology)  
measurement, 584  
parathyroid (PTH), 587  
follicular, 1211
- Hornbills, 499, 1282
- Horner's syndrome, 689, 728
- Horse, as disease vector, 929, 984
- Hospital management, 133, 135-137,  
138, 248
- Hospitalization, 398, 1244
- House Sparrow, as disease vector, 916,  
919, 926, 929, 955, 1054, 1195
- Housing, 34f, 35, 54f, 146, 1176, 1207,  
1223, 1233, 1244 (see aviary)  
crowded, 1179  
galvanized wire toxicity and, 54  
hygiene, 37  
in Anseriformes, 1244, 1269  
in Columbiformes, 1207  
in Galliformes, 1223, 1228, 1233  
in ratites, 1300, 1301  
indoor environment, 146  
nest box size, 54t  
suspended flights, 53
- Humerus (see anatomy overlay)  
in egg laying, 753  
surgical repair of, 1156f
- Humidity, 792, 1097
- Hunting, falconry, 19
- Husbandry, 50, 61  
in Galliformes, 1223  
in Passeriformes, 1175
- Hyclate, 462
- Hydrated collagen, 687
- Hydroactive (HAD) dressing, use of, 412,  
420, 1099
- Hydrocephalus, 746, 822
- Hydrochloric acid, 464
- Hydrocolloid dressing, 420
- Hydrogen peroxide, use in bleeding, 399,  
987
- Hydropericardium, causes of, 371, 717t,  
904, 1198
- Hydroxyzine hydrochloride, 636
- Hyperactivity, 732, 1044
- Hypercalcemia, 407, 589, 769
- Hypercholesterolemia, 464
- Hyperestrogenism, 256, 314, 518, 592,  
637
- Hyperexcitability, 743
- Hyperglobulinemia, with reovirus, 897,  
911
- Hyperglycemia, 234, 605, 915, 1039
- Hyperkalemia, 542, 705t, 706, 915
- Hyperkeratosis, 164c, 558, 609, 618,  
632, 859, 1001, 1196  
in ratites, 1298, 1310c  
malnutrition and, 852, 859, 1173, 1196
- Hypernatremia, in waterfowl, 1245
- Hyperostosis, 406, 407f, 769
- Hyperparathyroidism, 371, 373, 582,  
590, 591  
secondary nutritional, 590, 857-858, 1258
- Hypersensitivity responses, 114, 119, 120

- Hyperthermia, 463, 1203  
 clinical signs of, 413, 829  
 emergency treatment of, 414
- Hyperthyroidism, 593, 596
- Hyperuricemia, 554
- Hypervitaminosis A, 852, 1046
- Hypervitaminosis D, 74, 551f, 592, 845, 855, 1046  
 high-protein diets and, 850  
 renal damage and, 239
- Hypoadrenocorticism, 598-601
- Hypoalbuminemia, 911, 915
- Hypocalcemia, 411, 464, 592  
 cardiac effects of, 705t  
 dietary management of, 858  
 hemorrhagic conure syndrome with, 934  
 in African Grey Parrots, 411  
 neuromuscular disease and, 737  
 seizures and, 857-858
- Hypochromasia, 188
- Hypoglossal nerve (CN XII), 726
- Hypoglycemia, 234, 389, 738, 821, 852, 934
- Hypokalemia, cardiac effects of, 705t, 709, 710, 714
- Hyponatremia, 554
- Hypopennae, 1220
- Hypoproteinemia, 1310c
- Hypopteronosis cystica* (see feather cyst)
- Hypopyon, 911
- Hypothalamus, 583
- Hypothyroidism, 465, 595, 637, 844  
 iodine and, 860
- Hypovitaminosis A, 166, 487, 552, 558, 845, 853, 1250, 1298  
 aspergillosis and, 1001  
*Candida* vs, 999  
 embryo death and, 787  
 ocular disease and, 679, 680c  
 syringeal granuloma, 853f
- Hypovitaminosis B<sub>1</sub> (thiamine), 733
- Hypovitaminosis B<sub>2</sub> (riboflavin), 733
- Hypovitaminosis B<sub>6</sub> (pyridoxine), 733
- Hypovitaminosis D, skeletal disorders, 250, 845, 848, 853, 1257
- Hypovitaminosis E, 731, 854, 1298
- Hypoxia, cardiac effects, 709
- Hysterectomy, 407, 408, 760, 770-772, 1129 (see salpingohysterectomy)
- I**atrogenic intoxications, 1045
- Ibuprofen, 1113
- Icterus, 523, 1062
- IDEA test, for *Chlamydia*, 992
- Identification systems, 40, 49, 611, 810
- Idiopathic epilepsy, 410, 738
- Ileus, 255, 826, 1035, 1039  
 radiology of, 255, 258
- Iliotibialis, 1213
- Illness, increased metabolic rate, 73
- Imaging, 246-346 (see radiography)  
 air sacculitis, 317f  
 air sacculography, 294f  
 alternative, 260  
 Amazon, 262f, 264f, 265f, 267f, 268f, 269f  
 Amazon, head, 266f  
 Amazon, pelvic limb, 720f, 721f  
 Amazon wing, 269f  
 bone lesions and, 324f  
 cardiomegaly, 313f  
 cloacal distention, 317f  
 cockatiel, 272f, 273f, 274f  
 contrast studies and, 318f, 319f, 321f, 322f, 330f  
 duck, 275f, 276f, 277f  
 duck, head, 279f, 280f, 281f  
 duck, pelvic limb, 282f  
 duck, wing, 283f  
 egg-binding, 315f  
 egg-related peritonitis, 315f  
 femoral head necrosis, 324f  
 fibrosing cellulitis, 292f  
 goose, head, 279f  
 hepatitis, 312f  
 Hyacinth Macaw, 291f  
 hyperestrogenism, 314f  
 lipidosis, 311f  
 liver herniation, 316f  
 mass and, 298f, 302f  
 microhepatia, 310f  
 nephromegaly, 308f, 309f  
 ovary, 314f  
 peafowl, 290f  
 pigeon, neonate, 323f  
 pneumonia, 301f, 303f  
 quail, 284f, 286f  
 quail, head, 287f, 288f  
 quail, wing, 289f  
 quail, pelvic limb, 290f  
 renal calcification, urogram, 307f  
 respiratory tract and, 298f, 304f, 305f, 306f  
 restraint and positioning, 248  
 rhinogram, 294f  
 round cell tumor, 302f  
 sinography, 295f, 296f, 297f  
 splenomegaly, nephromegaly, 313f  
 tracheal mass, 299f, 300f  
 Trumpeter Swan, 278f
- Imaging technique, 246 (see radiographic technique)
- Imidazole antifungals, 459
- Immune complex reactions, 120
- Immune response, 114, 119, 754, 849  
 cell-mediated, 118
- Immune stimulant, 389, 462, 465
- Immune system, 110-119  
 disturbance of, 119  
 humeral system, 115  
 immunoglobulins, IgM, IgG, IgA, 115  
 in Anseriformes, 1244  
 lymphocyte activity, 116  
 macrophage, 112t  
 mechanisms of the avian host, 109  
 myeloid system, 111  
 pH, low intestinal environment, 111  
 weakened from inbreeding, 110f
- Immunodiffusion assays, problems of, 121
- Immunogenic glomerulonephritis, 120
- Immunoglobulins, 115, 754
- Immunoregulin, 464
- Immunosuppression, 119, 461, 468, 772, 870, 897, 910, 914, 931, 1001, 1017, 1256  
 in Columbiformes, 1208  
 in Passeriformes, 1189  
 in waterfowl, 1265
- Impaction  
 in Columbiformes, 361, 828, 1205f  
 in ratites, 1313c  
 in neonates, 828f  
 in Anseriformes, 1254
- Impregnated pellets, CTC, 460
- Imprinting, 97, 772, 775, 783, 1180, 1243, 1301
- Inbreeding, 713, 784, 792
- Inclusion bodies, 125, 878, 882, 889, 906, 1016  
 differentiation of, 890  
 hepatitis, 878, 882
- Incoordination, 462  
 viral disease and, 774, 881, 911, 937  
 vitamin E and, 855  
 NGD with, 942
- Incubation, 757, 788, 796, 1227, 1229  
 artificial, 788, 1227t  
 chicks and, 62, 790, 791t, 805  
 common problems with, 790-795  
 embryonic death and, 790, 792  
 in Anseriformes, 1241t, 1253  
 in Columbiformes, 1210t  
 in Galliformes, 1227t  
 in Passeriformes, 1176t  
 in Psittaciformes, 789t  
 in Ramphastidae, 1279  
 in ratites, 1303, 1318, 1320, 1324  
 natural, 785  
 parameters for, 792-794  
 periods of, for common species, 789t  
 requirements of, 788, 789
- Incubator management, 790, 791
- Indeterminate layers, 752, 783
- Indian Hill Mynah, 858, 872, 929, 1197
- Indocyanine green, 242
- Indolent corneal ulcers, 1100
- Infectious  
 disease outbreak, 60, 807  
 esophagitis, 880  
 laryngotracheitis virus, 579, 875  
 neuropathies, 741  
 salpingitis, adenovirus, 903  
 stunting syndrome (ISS), 507, 513
- Infertility, 460, 784, 786t, 792  
 malnutrition and, 849, 855
- Influenza A virus (see avian influenza)
- Influenza C, 929
- Influenza virus, 704, 705t, 707, 709, 924, 1057  
 in ratites, 1309  
 in Anseriformes, 1237
- Infra-acoustic waves, 1204
- Infraorbital  
 air sac, inflation, 1105 (see anatomy overlay)  
 diverticulum, flushing of, 203f  
 sinus, 160, 558, 905, 1106f (see anatomy overlay)
- Infrared heat lamp, in brooder boxes, 1254
- Infundibular cleft, 485
- Infundibulum, 561, 749
- Ingluvies (see crop)
- Ingluviolith, 495c, 497f
- Ingluviotomy, 414, 828, 1115, 1117f
- Injacom, 469
- Injectable anesthetics, in Anseriformes, 1262
- Injections, 1203, 1212, 1213, 1221
- Inscticide (see pesticide)
- Insectivore, low-protein diet for, 851
- Insectivorous Passeriformes, 558, 1173

- Insects, as viral vectors, 912, 916, 1215  
 Insemination, artificial (see artificial insemination)  
 Inspiration, fresh air, 569  
 Inspiratory strider, 711f  
 Instincts, avian behavior and, 724  
 Insulin, 603  
 Insurance, ratites and, 1309  
 Integument (see dermatology)  
 anatomy of, 608-611f, 615f  
 diseases of, 621t, 622t  
 in Columbiformes, 1202  
 in Galliformes, 1219, 1233  
 lesions, general therapy for, 622  
 physiology of, 608  
 Interdigitating bandage (see bandage)  
 Interferon, antiviral, 862  
 Interleukin 1, 112  
 Interleukin 2, antiviral, 932  
 International Chick Units (ICU), 83  
 International Racing Pigeon Association, 1201  
 International System of Units, 226, 1328t  
 Interosseus metacarpal artery, 1269  
 Interstitial cell tumors, 774  
 Intervertebral discs, 734  
 Intestinal  
 disease, 904, 942, (see gastroenterology)  
 microflora, in Galliformes, 1225  
 peritoneal cavity (IPC), 346  
 surgery, 1124  
 Intestinal tract  
 gas in, 255  
 length of, in Columbiformes, 1203  
 in ratites, 1313c  
 Intracranial pressure, 465  
 Intraductal PMM, 1149  
 Intramuscular injection, 388, 440, 1181  
 Intranuclear inclusion bodies, 125, 881, 906  
 Intraocular  
 pressure, 465  
 tumors, 689  
 Intraosseous cannula, 386-387, 1133f, 1134, 1181  
 Intraventricular conduction  
 disturbances, 710  
 Intubation, 1068f  
 Intussusception, 507, 828  
 Iodide, 93  
 Iodine, 461, 464, 860, 1190  
 Ionophore coccidiostat, 1307  
 Iothalamate sodium, radiography, 259  
 Iprnidazole (Ipropran), 464  
 Iris, 676, 728  
 Iron, 72, 92, 235, 462, 858  
 deficiency of, 188  
 dextran, 464  
 diet low in, 713  
 diet high in, 1197  
 oxide, in Columbiformes, 1204  
 Iron storage disease (see hemochromatosis)  
 Iron storage protein ferritin, 530  
 Ischemic infarction, 736  
 Ischiatic plexuses, 727  
 Isoelectrical lead, 701f  
 Isoflurane, 135, 705, 1066, 1213 (see anesthesia)  
 in Anseriformes, 1270  
 in Ramphastidae, 1280  
 recovery from overdose, 711  
 Isolation areas, for new or sick birds, 60  
 Isoniazid, 464, 468  
*Ispora*, 1015, 1191t, 1012f  
 Israel turkey meningoencephalitis (ITM), 918, 919  
 ISS (see infectious stunting syndrome)  
 Isthmus, 498f, 749, 1121, 1123  
 Itraconazole, 451, 453-455, 464, 999, 1004  
 Ivermectin, 464, 499, 1196, 1314, 1316  
 environmental toxicity of, 464, 1045
- J** Japanese B-encephalitis, (JBE), 919  
 Jaundice, 523, 1193  
 Jaw tone, reduced, 686, 732  
 Joint abnormalities, 463, 982, 1054, 1146  
 in Anseriformes, 1269  
 Junctional tachycardia, differentiation, 707  
 Junglefowl, 1231
- K** Kanteling, in ostriches, 1302  
 Kaolin, activated charcoal, 458  
 Kaprycidin A, 459  
 KE apparatus (see external fixator)  
 Keel, abscesses of, 1258  
 Keel-billed Toucan, 1276, 1282  
 Kelp, 87  
 Keratin, in Columbiformes, 1202  
 Keratinocytes, 611  
 Keratitis, 679, 686, 687, 1101  
 in ratites, 1295c  
 Keratoconjunctivitis, with *Chlamydia*, 989  
 Keratogenic cysts, 487  
 Keratomas, 632  
 Kerosene fumes, toxic, 1049  
 Ketamine hydrochloride, 462, 711, 1213, 1214  
 Ketoconazole, 455, 459, 464, 1005, 1189, 1190  
 Ketones, presence of, 150  
 Ketonuria, 549, 843  
 Ketosis, 843  
 Kidney, 74, 539, 851 (see nephrology)  
 anatomy, physiology, 539 (see anatomy overlay)  
 calcification of, 74  
 Kinky back, with *Staphylococcus*, 967  
 Kirschner wires, 1146  
 Kirschner-Ehmer (KE) device (see external fixator)  
 Kiwi, 1284, 1285  
*Klebsiella*, 956, 1189  
 in Galliformes, 1232  
 in Ramphastidae, 1281  
 in ratites, 1309  
 Knee web, 611, 1118  
*Knemidokoptes*, 40, 464, 631c, 1026  
 ocular disease and, 680c, 684  
 in Passeriformes, 1196  
 Knob, 607  
 Knuckling over, 728  
 Koilin membrane, 1289 (see ventriculus)
- L** L-form bacteria, 459, 955, 967, 969  
 Laboratories  
 fax, security of, 141  
 samples, submission of, 138, 140-142  
 Laboratory tests, not diagnostic alone, 226  
 Lacrimal gland, 675  
 Lacrimal sac abscesses, 684  
 Lacrimation, 905, 931  
 LaCrosse fever virus, 919  
 Lactate dehydrogenase (LDH), 231, 890, 911, 916, 989, 1243  
 Lactated Ringer's solution (LRS), 384, 464  
 Lactobacillus, 111, 465, 575, 978, 980, 955  
 Lactophenol cotton blue, fungal and, 999, 1003  
 Lactose, 78  
 Lactulose, 439, 464, 465, 467, 536, 953  
 Lady Amherst's Pheasant, 1231  
 Lafora body neuropathy, 738  
 Lake Victoria Cormorant herpesvirus, 875, 883  
 Lamellae, 1238, 1249  
 Lameness, 935, 942, 999, 1001  
 Laparoscopy, in Passeriformes, 1178  
 (see endoscopy)  
 Laparotomy, 770, 771 (see celiotomy)  
 Larynx, 560  
 Lasalocid, 1307  
 Laser surgery, 1113  
 Lasix, 463  
 Latex agglutination, aspergillosis and, 1003  
 Latitude, effects on, Anseriformes, 1243  
 Laxative, mineral oil, 466  
 Laying ducks, nutrient requirements for, 1250  
 Laying process, calcium levels, 753  
 Lead  
 ALAD levels and, 1037  
 analysis for, 1036  
 blood levels and, 1036t  
 cardiac effects of, 709  
 CNS signs, 739, 1038  
 ECG and, 701  
 in Anseriformes, 1263  
 intoxications vs picornavirus, 937  
 muscle tissue and, 1034  
 sources of, 1034t  
 testing kit, 1035  
 toxicosis, 258, 459, 550, 1033, 1034, 1035, 1198  
 treatment for, 458, 1038  
 Left lateral, celiotomy, 1120  
 Left-to-right (LeRtL) view, radiograph and, 248  
 Leg  
 band, injury, 42f (see band, leg)  
 chains, warning against use, 36f  
 deformities, 823, 830, 850, 858, 1161, 1165f, 1298, 1310c, 1324  
 paresis, 724, 743, 1035, 1264  
 surgical approach to, 1159f  
 weakness, with NGD, 942  
 Leiomyomas, 770  
 Leiomyosarcomas, 770  
 Lember pattern, 1124  
 Lens luxation, cataract and, 687  
 Lens removal, 1100  
 LeRtL, left-to right lateral view, radiograph and, 248  
*Leucocytozoon*, 190, 194c, 533, 1020

- in Passeriformes, 1193
  - in ratites, 1314
  - Leucopenia, 189, 882, 911
  - Leukemia virus (SLV), 931
  - Leukemic blood panel, and neoplasia, 668
  - Leukocyte morphology, 111, 186t
  - Leukocytosis, 189, 194, 942, 1188
  - Leukosis, 553, 587, 774, 933
    - in Passeriformes, 1187
  - Leuprolide, 465
  - Levamisole, 465, 499, 1004, 1193-1195
    - toxicity of, 1045
  - Levinthal-Cole-Lillie (LCL) bodies, 985
  - Levothyroxine sodium, 465
  - LH (see luteinizing hormone)
  - Libyostrongylus*, in ratites, 1314
  - Lice, 464, 1197
  - Lid paresis, 686
  - Lidocaine, 1133, 1214
  - Ligament, dorsal of uterus, 749
  - Light
    - for Arctic circle waterfowl, 1257
    - relationship to breeding, 51, 584, 853, 1175, 1233
  - Limberneck (see *C. botulinum*)
  - Lincomycin, 450, 465, 686
  - Lincosamides, pharmacology, 449
  - Lipase, 236
  - Lipemia, 234, 465, 844
  - Lipid production by keratinocytes, 611
  - Lipid solution, 393
  - Lipogenesis, 851
  - Lipoma, 213, 221c, 595f, 640, 642, 662
    - breeding and, 784
    - treatment of, 1133
  - Liposomes, 127
  - Liquid diets, 1125
  - Lissencephalic, 724
  - Listeria*, 718, 744, 976, 1188
    - CNS signs and, 744
    - in Galliformes, 1232
  - Live yeast cell derivatives, wounds and, 419
  - Liver, 522, 536 (see hepatology)
    - biopsy of, 530, 532
    - cirrhosis of, 530, 1265
    - damage, 362, 524, 526, 772
    - disease of, 405, 414, 465, 530, 532-536, 853, 1280
    - enlargement, hemorrhages, 878
    - enzymes and, 524
    - fatty infiltration of, 828, 849, 851, 856
    - flukes, 460
    - function, 524
    - hemorrhagic syndrome and, 851, 1186
    - herpesvirus lesions, 882
    - in oil-contaminated birds, 1263
    - in ratites, 1308
    - Mycobacterium* and, 973
    - mycotoxins and, 1043
    - neonates and, 506, 828, 832c
    - normal, 526c
    - posthepatic septum, 515
    - rupture, 526c
    - specific enzyme for, 524
    - tumors, classification, 536
  - Local inflammation, 120
  - Loft, pigeons and, 1206t, 1207
  - Longevity
    - in Anseriformes, 1244t
    - in companion birds, 30t
    - in Galliformes, 1223t
  - Lorelco, 465
  - Lory, 463, 878, 977
  - Louping Ill virus, 919
  - Lovebird, eye disease of, 679
  - LRS (see lactated Ringer's solution)
  - Lugol's solution, 464
  - Lumbar plexuses, 727
  - Lumbosacral spinal cord lesion, 729
  - Lung
    - cancer, risk of, human, 37
    - movement of, 167
    - normal, 362
    - parenchyma, radiograph, 252
    - pigeon breeder's, 1202
    - resistance to disease, 112
  - Lupine, 1041
  - Lutalyse, 462
  - Luteinizing hormone (LH), 583, 751, 753
  - Luxations, repair of, 1161
  - Lymph follicles, 116
  - Lymphatic erection, 756
  - Lymphocytes, in Anseriformes, 1244 (see hematology)
  - Lymphocytic blood differential, in
    - Columbiformes, 1204
  - Lymphocytosis, 189
  - Lymphoid leukosis, 587, 774, 933
  - Lymphoid neoplasia, 116, 221c
  - Lymphokines, 118
  - Lymphomatosis, 770
  - Lymphopenia, 599
  - Lymphoresis, 184c, 197
  - Lymphoproliferative disease (LPD), in
    - turkeys, 931, 932
  - Lymphosarcoma, 352, 529, 1197
  - Lysine, 72-74
    - in Anseriformes, 1250
  - Lysozyme activity, 1251
- M**
- M response, 730
  - M. avium*, (see *Mycobacterium*)
  - M. flexor cruris medialis*, 342
  - MAC, 1068
  - Macaw, 29, 75, 97, 462, 523, 886-888, 927
    - beak deformities, 836
    - biochemistry values in, 1329t, 1334t, 1336t
    - constricted toes, 831
    - doxycycline dose, 448
    - drug susceptibility, 449, 1046
    - effects of aging, 149t
    - hematology values, 1333t
    - hepatic lipidosis, 829
    - regurgitation and, 827
    - vitamin D toxicity in, 51, 74, 469, 829
  - Macchiavello's stain, 532, 987
  - Macrolide, 449
  - Macrophages, complement factors, 112t, 113
  - Maggots, 739, 1263
  - Magnesium, 91, 858, 1244
    - feather quality and, 846, 848
  - Magnetic field, and flight orientation, 1204
  - Magnetic resonance imaging (MRI), 723, 734, 736
  - Magnum, 749
  - Malabsorption, 149, 173c, 845, 969
  - Malaria, 460, 467, 936, 1192
  - Malathion, 1316
  - Male
    - behavioral abnormalities, 775
    - courtship, in Passeriformes, 1178
    - imprinted on humans, 775
    - reproductive disorders, 774, 777
  - Mallard Duck, 927, 1039, 1243, 1247, 1255, 1257
  - Malnutrition, 842-861, 1030, 1224
    - biotin, 857
    - calcium to phosphorus ratio, 858
    - carbohydrate, 851
    - cardiac effects, 713
    - choline, 857
    - clinical conditions associated with, 843-849
    - copper, 859
    - fatty liver, 844
    - feather changes, 846f
    - folic acid, 857
    - formulated diet and, 849f
    - in Anseriformes, 1257
    - in Passeriformes, 1189, 1196
    - infectious disease and, 1001
    - insectivore, low-protein diet, 851
    - iodine, 859-860
    - iron, anemia, 858
    - magnesium, 858
    - manganese, 859
    - minerals, 857-860
    - neurologic signs and, 848
    - niacin, 856
    - nutrient deficiencies, 849
    - obesity and, 843, 844f
    - ocular lesions and, 679
    - pantothenic acid and, 856
    - potassium, 860
    - protein and, 850
    - pyridoxine, perosis, 856
    - reproduction and, 762, 772, 774, 792, 849
    - riboflavin, 856
    - selenium, 859
    - skeletal disorders and, 848
    - skin changes and, 848
    - sodium and chloride, 860
    - symptoms of, 146f
    - thiamine, seizures, 856
    - vitamins, 852-857
    - water, 860
    - zinc, 859
  - Malunion, types, 1142t
  - Mammography, 247
  - Managing disease outbreaks,
    - histopathology, 60
  - Mandible, 558, 609, 728, 837, 891
  - Manganese, 72, 93, 859
    - feather quality and, 846
    - in ratites, 1298
    - in Anseriformes, 1258
  - Mannitol, 411, 413, 465
  - Marble spleen disease, 903
  - Marek's disease virus, 645, 653, 744, 874, 884
  - Marijuana, 1047
  - Marine diatoms, 741
  - Mast cell tumor, 645
  - Mastadenovirus, 903
  - Masturbatory behavior, 772, 775
  - Maternal immunity, 754
  - Maxitrol, 688
  - Maxilla, 609

## INDEX

- Mealworms, 1225  
 Mean corpuscular hemoglobin concentration, (MCHC), 180  
 Mean corpuscular volume (MCV), 180  
 Mean electrical axis, 696-702f  
 Measurement, units of Systeme International d'Unites (SI), 226, 1328t  
 Mebendazole, 465  
 Mechanical ileus, radiography, 258  
 Meckel's diverticulum, 116  
 Medroxyprogesterone acetate, 465, 621, 636  
   egg binding and, 761  
   peritonitis and, 771  
 Medullary calcification, 251, 753 (see hyperostosis)  
 Megabacterium, 174, 372, 464, 499, 978, 980f, 982c, 1188  
 Megapodes, 611, 1219, 1225, 1228  
 Meglumine diatrizoate, radiography, 259  
 Meibomian glands, 675  
 Melanin, and feather quality, 847  
*Meleagris gallopavo, forma domestica* (see Galliformes, turkey)  
 Melena, 149, 404, 656, 908 (see hematochezia)  
 Menace reflex, 728  
 Meningeal cryptococcosis, 453  
 Meninges, 724  
 Meningocele, 746  
 Meningoencephalitis, 741, 881  
 Mental status, and neurologic disease, 728  
 Mercury, toxicity of, 774, 1040  
 Merganser, 363c, 1246  
 Mesotocin, 583  
 Metabolic  
   acidosis, 389  
   disease, 813f, 1076  
   rate (BMR), in Passeriformes, 1173  
   scaling, 1349  
   tests, causes of increases in, 231  
 Metabolizable energy (ME), 74, 78  
 Metal toxicities, chelating agents for, 1038t  
   picornavirus vs, 937  
 Metamucil, 464  
 Metapatagium, 611  
 Metaphysis, 1142  
 Metazoal parasites, 1232  
 Methionine, 72, 846, 1250  
 Methomidate, 1213  
 Methomyl, toxin, 1050  
 Methoxyflurane, 711, 1068, 1261  
 Methoxymol, use in ducks, 1260  
 Methridine, *Capillaria* in raptors, 465  
 Methylcellulose, 464  
 Methylene blue, diagnosis of  
   aspergillosis, 999, 1003  
 Methylprednisolone acetate, 465  
 Metoclopramide HCl, 403, 465  
 Metomidate, 1260  
 Metritis, 462, 760, 768  
   in ratites, 1318  
 Metronidazole, 406, 466, 686, 741, 1209, 1282  
   toxicity in finches, 466  
 Mibolerone, 466  
 Miconazole, 452, 466, 999, 1004  
 Microbiology, courier service for, 377  
 Microcardia, causes of, radiograph, 697f  
 Microchips, 42-43, 49, 810, 1300f  
 Microfilaria, 463, 576, 1193  
 Microhepatia, 153c, 254, 310, 531, 739f  
 Microphthalmia, 684, 746  
*Microsporium*, 625, 1189  
 Microwave oven, 401, 1114  
 Mid-tibiotarsus, cast repair, 431f  
 Midbrain, 724  
 Migration, fat reserves, 1248  
 Migratory Bird Treaty Act, 1237  
 Mikado Pheasant, 1228  
 Milk, crop, 1210 (see crop milk)  
 Mimicking, talking ability, 27t, 1174  
 Mine wastes, in waterfowl, 1264  
 Mineral, 89  
   antagonists, 68  
   mixture for pigeons, 1206  
   oil, 466  
   requirements, 1252t  
 Mineralization, soft tissue, 84 (see gout, hypervitaminosis D<sub>3</sub>)  
 Mineralized eggs, radiography, 256  
 Mineralocorticoid, 600  
 Minimal inhibitory concentration (MIC), 435  
 Mink, influenza virus in, 929  
 Minocycline, 448  
 Mirrors, 36  
 Mist nets, 1260  
 Misting, 1178  
 Mite, 59, 459, 464, 916, 1026f, 1176  
   egg of, 1012f  
   protectors, 38, 1027, 1051  
   in Passeriformes, 1196  
   in ratites, 1317  
   tracheal vs *Streptococcus*, 970  
 Moist dermatitis, 464  
 Mollicutes, 1215  
 Molt, 618  
   cycle, 159, 547, 618-620, 926, 1220  
   in raptors, aminoloid, 458  
   in Anseriformes, 1239, 1244  
 Monensin, 459, 461, 466, 1307  
 Monistat, 466  
 Monk Parakeet, 28, 30, 714  
 Monoclonal antibodies, 127, 864  
 Monocular vision, 724  
 Monocytosis, 189, 976, 1188 (see hematology)  
 Monogamy, 781, 1209  
 Monsel's solution, 39, 463, 1269 (see hemorrhage)  
*Moraxella*, 964  
 Morbillivirus, 920  
 Morphine, 466  
 Mosquito, as disease vector, 624, 924, 934, 960, 1192, 1193  
 Motion sickness, 107  
 Mourning Dove (see Columbiformes)  
 MRI (see magnetic resonance imaging)  
 Mucoid tracheitis, with PMV-3, 927  
 Mucolytic agents, 390, 458  
*Mucor*, 625, 1003, 1005  
 Mucormycosis, 456, 575, 1005  
 Multifocal ventricular rhythms, in Anseriformes, 1262  
 Murexide test, 542  
 Murray Valley Encephalitis virus (MVE), 919  
 Muscle  
   cell necrosis, 229  
   pectoralis, 1213  
 Muscular dystrophy, 732, 1250  
 Muscularis complexus, hatching muscle, 793  
 Musculoskeletal disorders, 829  
 Muskgrass, 1247  
 Mute Swans, 1257  
*Mycobacterium*, 352, 363c, 437, 463, 486, 518, 971-975  
   aspergillosis vs, 1003  
   cytology and, 221c  
   in Columbiformes, 1211  
   in Galliformes, 1236  
   in Passeriformes, 1188  
   in Ramphastidae, 1282  
   ocular disease and, 684c  
   paratuberculous form, 973  
   viral diseases and, 883  
 Mycoplasma, 437, 443, 450, 469, 574, 718, 795, 1053  
   avian hosts, clinical signs, 1053t, 1060  
   *Chlamydia* vs, 990  
   diagnosis of, 1060  
   egg transmission and, 1058  
   in Anseriformes, 1057  
   in Columbiformes, 1058  
   in Galliformes, 1056, 1057f, 1232  
   in Passeriformes, 1059, 1187  
   in ratites, 1303t, 1314  
   influenza vs, 931  
   metritis and, 768  
   ocular disease and, 685  
   parvovirus vs, 909  
   treatment, 1060  
 Mycoses, 997-1006  
   antifungal agents, 999t, 1003-1004  
   in Columbiformes, 1215t  
   in Galliformes, 1232t  
   in Ramphastidae, 1282  
   in ratites, 1303t  
   neuropathies with, 741  
   treatment of, 437, 466, 741  
 Mycotoxins, 69t, 68, 553, 857, 1004, 1033, 1043, 1206 (see aflatoxin)  
   breeding and, 784  
   CNS signs and, 741  
   formulated diets certified free of, 1043  
   in Anseriformes, 1265, 1267t  
   in Galliformes, 1232  
   in Ramphastidae, 1282  
   sources and pathology, 69t  
   treatment of, 1043  
 Mydriasis, 674, 1101, 1266  
 Myeloblastosis, 933  
 Myelography, 260, 734  
 Myenteric plexus, 942  
 Myeloblast, 193  
*Myrialgae*, pruritus and, 1028  
 Mynah bird, 366, 459, 464, 713, 738, 1172, 1189, 1195  
   blood parasites in, 1192  
   hemochromatosis in, 1197  
   keratitis and, 687  
   ocular disease and, 679  
   parasites in, 1196  
   reproductive characteristics of, 1176t  
 Myocardial degeneration, Psittaciforme, 717  
 hypoxia, 705, 711f

infarction, heavy metal poisoning, 717  
 Myocarditis, 518  
   causes of, 717t, 912f  
 Myoglobinuria, 550  
 Myopathy  
   degenerative in ratites, 1307  
   primary, 730  
 Myoventricular dysgenesis, 504  
 Myxedema, 595  
 Myxomatous, glandular tissue  
   proliferation, 575  
 Myxosarcoma, REV, 934

## N

Nail  
   bleeding, treatment for, 39  
   clipping, 38f  
   overgrowth and liver disease, 523f  
 Naloxone, 466, 734  
 Naphthalene, toxicity, 1051  
 Naprosyn, 1113  
 Nasal  
   aspergillosis, 1002f  
   discharge, 160, 877, 912, 1190, 1266  
   salt gland, 240, 860, 1245  
   septum, 559  
   sinuses, in Passeriformes, 1173  
 Nasolacrimal ducts, 680c  
 National Animal Poison Control Center, 1033  
 Nebulization, 390, 441, 573  
 Neck braces, 1094, 1125  
 Neck stretching, in Passeriformes, 1190  
 Necropsy, 355-379  
   air sacs, 361c, 365  
   antibody, fluorescent, 377  
   bone, 375  
   brachial plexus, 374  
   brain, 369, 372c  
   communication with pathologist, 357  
   brain, encephalitis, Amazon, 372c  
   cloacal bursa, 368  
   crop, 372c  
   fecal material, fixative solutions for, 379t  
   fixatives for tissue, 378t  
   form, 356f, 357  
   heart, 371c  
   histopathology, tissues routinely  
     collected, 376t  
   instruments, disinfected, 357  
   ischiatric nerve, 374  
   kidney, 362c, 368  
   lung, 362c, 368  
   normal organs, 371c  
   oviduct, 368  
   pancreas, duodenum, relation to, 360c  
   parasite, 377, 379t  
   pericarditis, 371c  
   procedure, 359-363f  
   proventriculitis, Anseriformes, 372c  
   sacral plexus, 374  
   spleen, 367  
   staining, 377  
   thymus, 372c  
   thyroid gland, 370c, 370c  
   tissue for histopathology and electron  
     microscopy, 357  
   toxicology, samples for, 377  
   urate crystals, 375  
   vaccine reaction, 372c  
   ventriculus, 368  
   vertebral column, 362c, 369  
   viral isolation, tissue to collect, 377  
   zoonotic precautions, 357  
 Necrotic enteritis, *Clostridium* and, 977  
 Necrotic tracheitis, 1234f  
*Neisseria*, 774  
 Nematodes, 464, 465, 486, 507, 1194  
   in Galliformes, 1232, 1236  
   in Passeriformes, 1194  
   in ratites, 1314t  
 Neomycin, 466, 1103  
 Neonate, 805-839  
   abandoned, 807  
   abdominal distention, 821  
   abnormal urine, 829  
   anorexia, 821  
   beak problems, 836, 837  
   body weight charts, 818t, 829  
   bone deformities, 823  
   clinical signs of illness, 822t  
   congenital abnormalities, 822  
   critical care of, 821  
   crop and, 809, 819, 825, 826, 828, 835c  
   developmental characteristics of, 816  
   diagnostic procedures, 819-820  
   diets, hand-feeding, 808, 811t, 850  
   disease outbreak, handling procedures,  
     822t  
   droppings, 819  
   ear, membrane of, 838f  
   edema, in ratites, 1324  
   egg tooth, 808f  
   endoscopy of, 820  
   eyes, 817, 838  
   feather plucked, 807  
   feeding, 808, 811-814, 812f, 835c  
   fetal monster, 832c  
   foreign body ingestion or impaction, 828  
   fostering, 806  
   gout, vitamin D<sub>3</sub>, toxicosis, 829  
   hand-raising, 806, 808-820  
   hepatic lipidosis, 828  
   hepatomas, 829  
   ileus, 826  
   infectious diseases, 807, 814, 823-825  
   integument, 819, 837  
   leg deformities, 807, 816f, 830f, 831f,  
     832c  
   liver, 832  
   management, in Anseriformes, 1253,  
     1255, 1256  
   management, in Galliformes, 1226  
   management, in ratites, 1320, 1324  
   manufacturers of diets, 811t  
   microbial flora, 808, 820, 823  
   musculoskeletal disorders, 829  
   nestling posture, 817  
   nursery management, 809, 810t,f, 1135  
   omphalitis, 835  
   parasitic infections, 807, 808, 825  
   parent-raising, problems with, 807t-808t  
   pharyngeal trauma, 825  
   pipping muscle, 820f  
   pneumonia, aspiration, 828  
   problems of, 807, 820-838  
   radiographic characteristics, 249, 820,  
     832  
   regurgitation, case report, 827, 835c  
   stunting, 821, 822f  
   surgery in, 1135  
   ventricular septal defect, 816f  
   weaning, 813  
 Neoplasia, 505, 640 (see oncology)  
   in Passeriformes, 1198  
   in ratites, 1308  
   reproductive tract and, 650, 770, 774  
 Neoplasms  
   circulatory system and, 646  
   differentiation of, 670t  
   feminization or masculinization, 651  
   nervous system and, 736  
   NGD vs, 942  
   of muscles, 647  
   of urogenital system, 650-654  
   specific treatment for, 670t  
 Neopulmonic, 1174  
 Nephritis, 541f, 547, 551, 914  
 Nephroblastoma, 553  
 Nephrons, 539  
 Nephrocalcinosis, 84, 551f, 855  
 Nephroenteritis, 909, 943  
 Nephrology, 538-558  
   amyloidosis, 552  
   anatomy, physiology of kidney, 539  
   cellular cast, 549  
   chemical test and strips, 549  
   electrolyte changes and, 542, 554  
   endoscopy of, 550  
   Fanconi's syndrome, 549  
   flow-osmol factor, definition of, 548  
   glucose, urine and, 548, 549  
   gout, 539, 540f, 544c, 547c  
   granular cast, 549  
   infectious diseases, 550  
   ketonuria, 549  
   kidneys, normal, 544c  
   malnutrition and, 551  
   metabolic disorders, 551  
   neoplasia and, 544c, 547c  
   nephritis, 547c, 551  
   nephrons, 539  
   nephropathy, 554  
   non-nephrotoxic antibodies, 554  
   pathophysiology, 539  
   Ponceau S method, 548  
   porphyrin, urine test for, 550  
   postrenal renal failure, 541, 553  
   prerenal renal failure, 541, 553  
   prerenal azotemia, definition of, 541-542  
   radiography, 550  
   renal hemorrhage, 547c, 553  
   renal dysfunction, clinicopathologic  
     diagnosis, 541-543  
   renal, agenesis, 552f  
   renal output, 539  
   renal failure, 541, 553, 554  
   therapeutic considerations, 553-555  
   toxic, nephropathies, 553  
   ureteral obstruction, 553  
   uric acid, 540, 542  
   urinalysis, 543t, 547c-549  
   urinary enzymes, 549  
   urine concentration ability, 543  
   urine water, reabsorbed from colon, 539  
   urography, 551  
   water deprivation, 548  
 Nephromegaly, 74, 245t, 256, 308, 309, 313, 362  
 Nephropathies, 904, 906  
 Nephrotoxicity, 444, 458, 463, 538, 1046  
 Nerve conduction velocities, (NCV), 730  
 Nerve injury, 734

## INDEX

- Nervous system, disease of, 723, 877, 904f, 922, 999, 1044, 1264
- Nest  
behavior in, 1129  
box, 54t-56, 58, 783, 788, 806, 807  
building, 757, 1178  
material, problems, 56, 807
- Neurapraxia, 734
- Neurocalcinosis, 1251
- Neurologic examination, 727
- Neurology, 723-748  
diagnostic technique, data base, 729
- Neuromuscular disease, vitamin E, selenium, 469, 728, 737
- Neuropathic gastric dilatation (NGD), 154, 348, 500f,t, 501, 502f, 704f, 743, 825, 924, 1123, 1269  
case report, 869c  
diagnosis of, 258, 501, 942f, 981f  
leukocytosis with, 942  
viral serositis vs, 917
- Neuropathies, 727, 731  
bacterial, 744  
infectious, 741  
metabolic, 736  
toxic, 739  
traumatic, 733  
viral, 743
- Neurohypophyseal hormone, 583
- New bird kit, contents of, 134
- New duck disease, duck septicemia, 964
- New wire disease, 1198 (see galvanized wire)
- New World Psittacines, 886, 895, 911
- Newcastle disease, 143, 562c, 709, 768, 920-925  
cardiac effects of, 705t  
host susceptibility, 922t  
in Anseriformes, 1237, 1267t  
in Ramphastidae, 1282  
in ratites, 1309  
pathology, 924t-925t  
*Chlamydia* vs, 990
- NGD (see neuropathic gastric dilatation)
- Niacin, 86, 856, 858, 1251
- Niclosamide, 466
- Nicotine toxicity, 966f, 1033, 1047
- Nidifugous young, 1228, 1253
- Nitrates, toxicosis, 1041
- Nitric acid, 542
- Nitrofurazone, 438, 466
- Nitromidazole, 496
- Nitrothiazole, toxicity in finches, 466
- Nizoral, 464
- Nocardia, 575, 978, 1005
- Nodules, miliary, with *Mycobacterium*, 973
- Nolvasan, 460
- Non-breeding season, 1209
- Non-determinant layers, 1228
- Non-selective angiography, 260
- Non-steroidal anti-inflammatory medications, 1113
- Non-stick cookware, toxicity, 1047
- Northern fowl mites, 808, 1209, 1215t
- Nortriptyline HCl, 466
- Nosocomial infection, 412
- Nuclear scintigraphy, 325
- Nucleic acid, 125
- Numida meleagris, forma domestica*, 1218
- Nuptial, 1239
- Nursery management, 808, 809t, 814f, 815, 823t (see neonate)
- Nuttallia* spp., in Passeriformes, 1192
- Nutrient  
allowances, recommended, 71t  
antagonists, 67  
density, effect on energy level, 66t  
debilitation needs, 73t  
essential, biological functions, 78  
interrelationships, 66  
potential toxic effects, 75t  
requirements, 69-72, 842, 1206  
toxic potential, 75t
- Nutrition, 63-95 845, 850, 1177  
bird health and, 64  
chicks and, 805  
energy, 78  
energy nutrient density, 66t  
essential nutrient and functions, 78-94  
fatty acids, 81  
fertility and, 786, 787  
food sources, nutrient content, 79t, 80t  
formulated diets, 76, 77  
free-ranging birds and, 63  
in Anseriformes, 1246, 1257  
in Columbiformes, 1205  
in Galliformes, 1224  
labeling, commercial products, 76, 77  
minerals, 75, 89-94  
mycotoxins, 68, 69t  
neuromuscular disease and, 731  
oxidation, control of, 77t  
plumage abnormalities and, 846  
protein, 73, 74, 81, 82  
research potential, 64  
respiratory disorders and, 846  
vitamins, 74, 82-89  
water, 65
- Nutritional  
deficiencies vs paramyxovirus, 928  
deficiency, neonates, 811  
support, sick birds, 390-396  
hyperparathyroidism (see hyperparathyroidism)
- Nystagmus, 728
- Nystatin, 451, 454, 455, 466, 824, 999, 1189
- O** Oak toxicosis, 1042
- Obesity, 75, 164, 173c, 582, 596, 637, 844, 1121, 1133, 1248  
anesthesia and, 1076  
dyspnea and, 557  
egg binding and, 758  
hypothyroidism and, 582  
in Galliformes, 1225  
in ratites, 1301, 1313c  
reproductive failure and, 775  
species predisposition, 844
- Obstruction, tracheal/syringeal, 1107
- Obstruction, GI, 361
- Occluded ear openings, 838
- Ochratoxin, 533, 1044
- Ocular lubricants, 679
- Ocular prosthesis, 1103
- Oculomotor nerve (CN III), 725
- Oculonasal discharge, chicks, 823
- Oil-contamination, 413, 598, 623, 628c, 1263
- Old World Psittacines, 742, 878, 895, 911
- Oleander toxicity, 1041, 1266
- Olfactory center, 724
- Olfactory navigation, in Columbiformes, 1204
- Olfactory nerve (CN I), 725
- Oliguria, 541 (see nephrology, renal failure)
- Omphalitis, 821, 835c, 1187, 1256  
in ratites, 1309
- Onciola canis*, 496
- Onciola pomatostomi*, 1193
- Oncology, 640-672  
adenocarcinoma, 605c, 644, 646  
adrenal gland, 661  
astrocytoma, 661  
basal cell tumors, 644  
bile duct hyperplasia, 658  
biliary cyst, 658  
bone cyst, 649f  
bone neoplasia, 251, 649, 650f, 665c  
carcinoma, 644, 662c  
cartilage and bone, neoplasms of, 649  
cholangiocarcinoma, bile duct carcinoma, 658  
chondroma, 649  
choroid plexus papilloma, 666  
circulatory system, neoplasms of, 646  
cloacal neoplasia, 657  
cyst, ultimobranchial, 644, 646  
digestive system, neoplasms of, 655  
ectopic pulmonary ossification, 645  
embryonal nephroma, 651  
feather folliculoma, 644  
fibroplasia, reactive, 644  
fibrosarcoma, 643f, 645, 655c 662c, ganglioneuroma, 666  
glioblastoma, 666  
granulosa cell tumors, 653  
hemangioma, 645, 647, 648f  
hepatocellular neoplasia, 658  
hibernoma, 642  
integumentary system, neoplasms of, 641, 644, 655, 662c  
interstitial cell tumor, 653  
intestinal carcinoma, 657  
islet cell carcinoma, 661  
leiomyoma, 647, 657  
lymphoid neoplasms, 645, 647, 662c, 667, 668, 653  
malignant medulloepithelioma, 667  
malignant melanoma, 667  
malignant schwannoma, 667  
mast cell tumor, 645  
meningioma, 665c, 666  
myeloblastosis, retrovirus and, 669  
myelocytomas, 669  
myxoma, 643  
neoplasia, definition of, 640  
neoplasms and feminization or masculinization, 651  
neoplasms, differentiation of, 670t  
neoplasms of muscles, 647  
neoplasms of urogenital system, 650-654  
neoplasms, specific treatment, 670t  
nodular hyperplasia, hepatic, 658  
oligodendroglioma, 666  
pancreatic neoplasia, 659f  
papilloma, 640, 644, 655c, 662  
pheochromocytoma, 661  
pinealoma, 660  
pituitary neoplasia, 659, 660

- proventricular neoplasia, 656  
 pseudoneoplasia, 641f  
 renal neoplasia, 652f, 662c  
 respiratory system, neoplasms of, 645  
 rhabdomyomas, 648, 667  
 sarcomatosis, 654  
 schwannoma, 666  
 thymoma, 669  
 thyroid neoplasia, 660  
 uropygial neoplasia, 644, 645f, 665c  
 ventricular neoplasia, 656  
 xanthoma, 642, 665c
- Oophoritis, 769  
 Open bands, 49  
 Open vs closed reduction, advantages, 1139 (see orthopedic surgical techniques)
- Operculum, 160, 1105  
 Ophthalmoscope, 673  
 Opisthotonus, 1045, 1265  
   chlamydia and, 745, 989  
   CNS toxins and, 740, 741  
   bacteria and, 744  
   viral diseases and, 743, 873, 906, 922
- Oposin, 112  
 Ophthalmology, 673-694  
   blindness, 689  
   congenital disorders, 684  
   conjunctiva, 685  
   eye anatomy, 675  
   in ratites, 1316  
   keratitis, 687  
   lids and periorbital, 677  
   lovebird eye disease, 679  
   malnutrition, 679  
   mycoplasma, 1054  
   ocular examination, 674  
   periorbital, 676  
   periorbital abscesses, 684  
   retinal disease, 688  
   tumors, 689  
   uvea, 687  
   viral diseases, 678, 872, 911, 937
- Optic nerve (CN II), 725  
 Optic nerve glioma, 684  
 Oral cavity, 352, 462  
   in Anseriformes, 1266  
   malnutrition and, 845  
   poxvirus and, 872  
   white plagues and *Candida*, 998
- Oral ulcers, trichothecene, 1044  
 Orbital abscesses, 684  
 Orbital round cell sarcoma, 684  
 Orbivirus, 912  
 Orchidectomy, 1131  
 Orchipedium, 1011f  
 Orchitis, 774, 990  
 Orchratoxin, 1044  
 Organ function, measure of, 226 (see biochemistry)
- Organic iodine, 464  
 Organochlorine, toxicity, 773, 1050  
 Organophosphate, toxicity, 459, 706, 737, 1050
- Ornithosis (see *Chlamydia psittaci*)  
*Ornitysluss sylviarum*, 808  
 Oropharyngeal papillomas, 1113  
 Orthohepadnavirus (see hepadnavirus)  
 Orthomyxoviridae, 929-931  
   in Galliformes, 1232  
 Oropharynx, 486
- Orthomyxovirus, 929  
 Orthopedic surgical techniques, 1137-1169  
 Orthoreovirus, 910, 911  
 Osmoregulation, in oil-contaminated Anseriformes, 1263  
 Osmotic diuretic, 465  
 Ossification, 1142, 1144f (see biochemistry)
- Osteoblast vs osteoclast, 197  
 Osteoconduction, 1114  
 Osteodystrophy, 591, 1046  
 Osteogenesis, 1144  
 Osteoinduction, 1144  
 Osteomalacia, 591  
 Osteomyelitis, 650, 745, 967f, 1139, 1141  
 Osteomyelosclerosis, 406  
 Osteopetrosis, 649, 933  
 Osteoporosis, 591  
 Osteotomy, dome, 1161  
 Ostium, smooth muscles, 566  
 Ostrich, 565c, 821, 1283, 1284, 1302f, 1309, 1314, 1316, 1320 (see ratite)
- anesthesia in, 1070  
   aspergillosis in, 1001  
   bacteria and, 956, 978, 982  
   characteristics of, 1285  
   *Chlamydia* in, 989  
   cloaca of, 1290f  
   *Clostridium* in, 977  
   digestive system of, 499, 501, 845, 1288f  
   egg binding and, 1301  
   eggs of, 1319f  
   hematology, 1345t  
   male anatomy, 775, 1291, 1296  
   management, 1300, 1301  
   maturity in, 1301  
   mycotoxins in, 1043  
   ocular disease and, 683c, 686  
   parasites and, 1062, 1314, 1316f  
   reproductive system, 798, 1131, 1296f, 1302t, 1304  
   thoracoabdominal anatomy of, 1289f  
   viral disease and, 874, 915
- Otidiphabidae, 1201  
 Otitis, 154, 372, 745  
 Ototoxicity, 463  
 Ovarian growth, enhanced, 784  
 Ovarian neoplasm, 173c, 770, 798c (see oncology)
- Ovary  
   cystic, 173c, 770  
   melanistic, 749, 798c  
   persistence of, 773
- Overcrowding  
   aspergillosis and, 1001  
   in Galliformes, 1233
- Oviduct, 334, 368f, 749, 768, 770, 1129, 1210  
   anatomic abnormalities and, 773  
   cystic hyperplasia of, 770  
   flushing of, 768  
   growth and secretory activity of, 752  
   impaction of, 768  
   in ratites, 1304  
   masses, radiography, 256  
   ovulation, preventing, 465  
   prolapse of, 759, 762  
   ruptured, 771  
   stretch stimulus of, 752  
   surgery of, 769
- Oviposition, 752 (see egg laying)  
 Ovocentesis, 407f, 760, 801c  
 Ovotomy, 796  
 Ovulation, inhibition of, 465  
 Owl, 145, 463, 773, 875, 882, 884, 914, 960  
   ear, 353c  
   esophagus, 353c  
   mast cell tumor in, 645  
   ocular characteristics and, 353c, 676f
- Oxfenbendazole, 466, 1194  
 Oxygen, 395, 396  
   flow rate with anesthesia, 1069  
   saturation, 1074, 1079  
   toxicity, 396, 1047
- Oxypurinol, 554  
*Oxyspirura*, 464, 686, 1023, 1195  
 Oxytetracycline, 448, 466, 994, 1046  
 Oxytocin, 406, 467, 752, 759  
   complications of, 760  
 Ozone, toxicity, 1048
- P** P mitrale, 704  
 P on T phenomenon, 707  
 P-wave, 700, 704  
 PA, 1264  
 Pacemaker, wandering, 706  
 Pacheco's disease virus, 173c, 875, 878, 879f  
   treatment of, 458  
   vaccine, 879f, 880
- Packed cell volume, 179 (see hematology, CBC)
- Pain  
   control, 1094, 1095  
   perception and neurologic disease, 729
- Pair bond, in Anseriformes, 1252  
 Palate, 352, 488  
 Paleopulmonic parabronchi, 1174  
 Palpation, of abdomen, 770  
 Panacur, 463  
 Pancreas, 255, 859, 1043, 1263  
   adenovirus and, 904, 906  
   *Chlamydia* and, 990  
   enzymes and, 467  
   tumors and, 363, 514  
   zinc toxicosis and, 859, 1039, 1264
- Pancreatic exocrine insufficiency, 173c  
 Pancreatitis, 405, 513, 771  
 Pancuronium bromide, 467  
 Pantothenic acid, 72, 846, 849, 856  
 Papillae, 756, 1210  
 Papilloma, 512f, 640, 644, 655, 656, 798, 886, 887, 1113  
   affect on urine pH, 243  
   autogenous vaccines for, 887  
   bile duct carcinomas and, 887  
   cause of, 640  
   clinical changes of, 887t  
   diagnosis of, 169, 511, 887  
   feet and, 885f  
   herpesvirus and, 875, 885  
   in ratites, 1300  
   malnutrition and, 887  
   oral, 1113  
   species predilection, 886
- Papillomavirus  
   in African Grey Parrot, 886  
   in finches, 886, 1186  
   internal, clinical signs, 887t
- Papovavirus, 885-894



- Para-chlormetazymol, mite protector, toxicity, 1051
- Para-dichlorobenzene, toxicity, 1051
- Parabronchi, 561
- Paracentesis, 770
- Parainfluenza-2-virus, in humans, 928
- Paralysis, 411, 467, 733  
bacteria and, 976, 978  
*Chlamydia* and, 989  
CNS toxins and, 739, 1035  
cryptococcosis and, 1004  
flaccid, with *Corynebacterium*, 978  
in Passeriformes, 1188  
malnutrition and, 469, 845, 848  
viral diseases and, 744, 873, 881, 922, 926, 927
- Paramunity inducers, 114, 862
- Paramyxovirus (PMV), 501, 514, 743, 920-928, 1232  
*Chlamydia* vs, 990  
control of, 940t  
hosts, 921t  
in Columbiformes, 1208, 1216f  
in Passeriformes, 1186  
in ratites, 1304
- Paranasal lymphatic tissue, 116
- Paranasal sinus, 558
- Parasites  
blood, 1010, 1016, 1018t  
*Capillaria*, 1023  
coccidia, 1015  
companion birds and, 1008t  
*Cryptosporidium*, 1016t  
diagnosis of, 377t, 379, 1009t, 1011f, 1012f  
diagnostic stages, 1012f  
external, in ratites, 1314t  
fecal examination, 1009t  
*Giardia*, 1014f  
helminths, 1021  
hemoparasites, 1019  
Hippoboscidae, 1010f  
in Anseriformes, 1253, 1267t  
in Columbiformes, 1208, 1215t  
in Galliformes, 1232t  
in Ramphastidae, 1282  
in ratites, 1303t, 1314t  
leg swelling, 1025f  
mites, 1026f  
neonates and, 825  
neuropathies and, 741  
ocular, 684  
preserving, 1012  
protozoa, 1008, 1009, 1013-1015, 1017  
reproductive disease and, 769, 1007-1029  
*Sarcocystis*, in psittacines, 1017t  
*Syngamus*, 1024f  
tapeworms, 1013f  
treatment of, 1008t  
*Trypanosoma*, 1021
- Parathion, toxicity, 1050
- Parathyroid glands, 366, 737
- Parathyroid hormone, 587, 857
- Parconazole, 467, 1004
- Parent-raised, 806, 807
- Parenteral alimentation, sites for, 391, 393, 827
- Paresis, 732, 735  
bacteria and, 976  
*Chlamydia* and, 989  
CNS toxins and, 739, 740, 1035  
egg binding and, 758  
in Passeriformes, 1188  
in Ramphastidae, 1278f  
neoplasia and, 774  
viral diseases and, 744, 873, 916, 920
- Paroxysmal, supraventricular tachycardia, 707
- Parsley toxicity, in ratites, 1043, 1317
- Parvoviral hepatitis, 943
- Parvovirus, 904, 908-909, 1232
- Passeriformes, 1172-1199  
air sacs in, 1174  
diseases of, 1183t  
dyspnea in, 1195  
gender determination and, 778, 1178  
hydropericardium in, 1198  
intramuscular injections, 1181  
jaundice in, 1193  
liver disease and, 1197, 1198  
malnutrition in, 1196  
*Mycobacterium* and, 972  
neoplastic diseases in, 1198  
nutrition in, 1177  
ocular disease and, 689  
parasites and, 1192-1195  
pneumonia in, 1186  
pruritus in, 1197  
reproduction in, 756  
respiratory distress in, 1193, 1195  
sexing of, 1178  
toxicosis in, 776, 1198  
viral diseases and, 870, 872, 884, 914, 921, 927, 933, 1185, 1198
- Passing whole seeds, 483t, 1190 (see pancreatitis, enteritis, neuropathic gastric dilatation)
- Pasteurella*, 232, 361, 412, 459, 961, 982, 1189  
heart disease and, 715  
metritis and, 768  
ocular disease and, 684  
orchitis and, 774
- Patagiotomy, in geese, 1269
- Patagium, 611, 626
- PBFD (see psittacine beak and feather disease)
- PCR amplification of nucleic acid, 125f
- PCV, 753, 934 (see hematology)
- PD (see polydipsia)
- Peafowl, 366, 875, 1057, 1220, 1230
- Peanuts, aflatoxin, 50, 69, 1043, 1265
- Pecten, 677
- Pectoral crest, 1270
- Pectoral muscle atrophy, and NGD, 743
- Pendulous crop (see crop, pendulous)
- Penetran, 458
- Penicillin, 412, 444, 445  
toxicity, of, 1046
- Penicillium fungi, 625, 1044  
aspergillosis vs, 1003  
in Ramphastidae, 1282
- Penny ingestion, in Anseriformes, 1264
- Penrose drains, 1086, 1131
- Pentobarbital sodium, 1260
- Pepper tree, 1041
- Pepto-Bismol, 459
- Perches, 35, 39, 55, 1094, 1223
- Perching ability, and neurologic disease, 728
- Perforation, esophageal, 1113
- Pericardial effusion, 697, 704, 706f, 709f, 718, 719f
- Pericardial sac, 695
- Pericarditis, 371, 518, 547, 709, 711, 718, 999  
causes of, 717t
- Pericardium, surgery of, 718
- Periodic acid-Schiff stain, 1005
- Periorbital, 558, 673  
masses, 558, 684, 1106  
disease, 677
- Periosteum, 1139
- Peripheral nervous system, trauma, 734
- Peristaltic waves, 490, 940
- Peritoneal hernia, in ratites, 1304
- Peritoneum, yolk, effect on, 771
- Peritonitis, 218c, 515, 518, 769, 771, 798c, 1131 (see egg-related peritonitis)  
clinical signs of, 771  
in ratites, 1313c  
yolk-related, 1129
- Perosis, 848, 856, 857, 859,  
in Anseriformes, 1251, 1258  
species predisposition, 848  
surgical repair of, 1259f
- Peroxidation, 84
- Peroxide levels, rancid fat, 851
- Peru's Manu Biosphere Reserve, 96
- Pessulus, 1107
- Pest control, 59
- Pesticide, 740, 1033, 1049  
Anseriformes and, 1266  
CNS signs and, 740  
egg production, hatchability and, 1051  
food contamination and, 773  
poisoning, 1049-1057  
prophylactic use of, 808  
treatment for toxicity, 458, 741
- Petechiation  
rodenticide and, 1051
- Petro-chemicals, and migratory bird populations, 1050
- Petroleum distillates, as CNS toxins, 746
- Peyer's patches, 116
- pH  
of crop, 150, 827  
with megabacteria, 499, 980  
with papilloma, 887
- Phacoemulsification, 688, 1101
- Phagocytosis, 112
- Phallus, 756  
in Anseriformes, 1253f  
with mycoplasma, 1057  
prolapse of, 511, 774  
ratites, 1290f, 1291, 1304  
types of, 509
- Pharmaceutical use in birds, 142, (see formulary)
- Pharmacokinetics, 437
- Pharyngostomy tube, 392, 1112f
- Phasianiformes (see Galliformes)
- Pheasant, 1229, 1230 (see Galliformes)
- ocular disease in, 686, 689  
*Borrelia* in, 960
- Phenobarbital, 411, 467, 736, 738, 741
- Phenol, as disinfectant, 1061
- Phenylbutazone, 467

- Phenylephrine, 689  
 Phenylmercuric acetate, 746  
 Pheochromocytoma, chromaffinoma, 601  
 Philodendron, 1041  
 Philophthalmus, 686  
 Phosphorus, 90, 235, 811, 857  
 deficiencies and skeletal disorders, 848  
 protein in diet, 850  
 vitamin D<sub>3</sub> and, 854  
 Photoperiod, in equatorial birds, 752  
 Photophobia, 877  
 Photorefractoriness, 752  
 Photosensitization, 485, 1317  
 Physical examination, 144-175  
 abdomen palpation, 168  
 abdominal muscles, in Passeriformes, 168  
 aging, effects of, in macaws, 149t  
 Amazon, anorectic excrement, 173c  
 anamnesis, 145t  
 auscultation, 167f  
 beak, normal appearance of, 161  
 behavior, 147, 148  
 Blue and Gold Macaw, normal, 153c  
 cere, color of, 160, 161  
 choana, 163  
 cloaca, 150, 151f, 168, 170  
 cockatiel, 154c  
 crop, 167  
 dermis, 157  
 diet, effect on skin and feathers, 158  
 ear, 154c, 160  
 environment, evaluation of, 147  
 feathers, 157-159, 170  
 feet, abnormalities, in 154c, 170, 171f  
 frequency of, 147  
 glottis, 163c  
 Gram's stain, 151t, 174  
 head, 160, 166f  
 heart rate, 148t  
 house-training, 150  
 hydration evaluation, 170  
 minimum database, 171  
 molting, seasonal, 159  
 nail length, 171  
 nares, 160  
 odors, 151  
 oral cavity, 161, 166  
 palpation, 167  
 prepatagium, tattoo ink, 164c  
 regurgitation in, 151  
 respiratory, tract, 147-148t, 166  
 restraint, 156f, 158f  
 speculum, oral, 167f  
 sternal muscle mass, 168f  
 sternal necrosis, 164c  
 thermometer, tympanic, 169  
 toxins, 146  
 translucent skin, 159f  
 urates, normal, 149, 174c  
 uropygial gland, 169  
 vomiting, 150, 151  
 weak grip, cause of, 171  
 weight in comparison with condition, 168f  
 Physical therapy, postsurgical, 1140  
 Physiology  
 of Anseriformes, 1244t  
 of Columbiformes, 1203  
 of Galliformes, 1219  
 of Passeriformes, 1173  
 of ratites, 1286  
 Physis, 1142  
 Pia mater, 724  
 Piciformes (see Ramphastidae)  
 Picornavirus, 744, 913, 937-938  
 Pigeon, 459, 461-465, 742, 1204, 1218  
 (see Columbiformes)  
 bacterial diseases in, 910, 913, 920, 923, 956, 959, 960, 961, 962, 964, 969, 970, 977, 1054, 1060, 1062, 1212  
 breeding season in, 1208  
*Chlamydia* in, 985, 989, 995  
*Cryptococcus* in, 1004  
 diseases, 1215t  
 drug susceptibility to, 1046  
 ECG, 697, 714f  
 fledgling age of, 1210  
 grit and, 77  
 health certificate for, 1208  
 heart, 710, 711f, 717  
 housing requirements, 1207  
 incubation period, 1210  
 ketoconazole in, 453  
 lead in, 1035, 1037  
 parasites in, 466, 715, 962, 1005, 1061, 1209, 1215  
 racing season, 1208  
 stones, 1206t  
 susceptibility, disease, 1208  
 special management, 1208  
 urine, reference values, 543t  
 varieties, 1200  
 viral diseases in, 743, 875, 881, 895, 911, 921  
 Pigment changes, in feathers, 523, 617  
 Pigs, influenza virus in, 929  
 Pin feathers, 38, 159, 618  
 Pinioning, 1235, 1245, 1269f  
 Pinning, for fracture repair, 1149 (see orthopedic surgical techniques)  
 Pins, positive-profile threaded, 1146  
 Piperacillin, 445, 467, 554  
 Piperazine, 467, 1194  
 Pipping, 795, 1253  
 Pipping muscle, 820, 1292c  
 Piroplasmosis, in Passeriformes, 1193  
 Pituitary  
 adenoma syndrome, 736  
 chromophobe syndrome, 736  
 chromophobe tumors, 684  
 gland, 583, 660  
 Plants, toxic, 536, 741, 1041t, 1042t, 1224, 1266  
 in Anseriformes, 1266  
 Plasma ammonia, 231  
 Plasma bile acid (PBAC), 525  
 Plasma cells, differentiation of, 197  
 Plasmodium, 194c, 460, 467, 529, 936, 1020, 1176, 1192, 1282  
 characteristics of disease, 190, 191  
 Plates, bone, 1150  
 Pleuro-peritoneum, anatomy and physiology, 514  
 Pleuromutilin, 1060  
 Plexus subcutaneous collaris, 926, 1203f  
 Plexuses, lumbar, ischiatic, pudendal, 727  
 Ploceidae, 912  
 PMSG (gonadotrophin serum), 776  
 PMV-1 pigeon, 921, 926  
 PMV-3 to PMV-9, 927-928  
 Pneumatic, bones, 1138  
 Pneumonectomy, 1111  
 Pneumonia, 301, 303, 872, 927, 1054, 1186, 1189  
 aspiration, 562, 828  
 Pneumonology, 556-581  
 air capillaries, 566  
 air sac, 565f, 567, 568f, 572, 579  
 air sacculitis, 576, 579  
 aspergillosis, 565c  
 aspiration, with hand-feeding, 562c  
 auscultation, 571  
 bacteria in, 575  
 bronchi, 561, 567f  
 caudal air sacculitis, 568  
 cervical air sac inflation, 580f  
 cervicocephalic air sacs, 566  
 choana, 575, 576  
 conjunctivitis and, 576  
 coughing, 557  
 dermatitis, 576  
 dyspnea, 557, 566f, 575  
 endoscopy, 571, 572  
 epithelium, trachea, type of, 561  
 facial swelling, 562c  
 feather picking, air sac problems and, 572  
 feathers over nares, stained or matted, 557  
 foreign body inhalation, 579  
 gas exchange, efficiency of, 569  
 infraorbital air sacs on expiration, insufflation of, 577  
 infraorbital sinus, 558  
 infraorbital sinusitis, 574  
 inhalation, toxicosis, 576, 1048  
 lung biopsy, 573  
 lung, changes in the size or position of, 561  
 malnutrition and, 557, 574, 576  
 muscles, expiratory, 568  
 muscles, inspiratory, 568  
 nares, 557  
 nasal concha, 557, 558  
 nasolacrimal ducts, lack of, 557f  
 nebulization therapy, 574t  
 neoplumonic parabronchi, 566, 569  
 operculum, 557, 577  
 palatine salivary glands, 574  
 paleopulmonic parabronchi, 566, 569  
 parabronchi, surfactant, 566  
 parasites, 557, 562c, 575, 576  
 periorbital depression (sunken sinus syndrome), 577  
 pharyngitis, 565c  
 pneumonia, 565c  
 pneumonitis, severe allergic, 576  
 respiratory cycles, two, 569  
 respiratory disease, 559t, 560t, 578t  
 respiratory imaging, 571  
 respiratory problems, database for, 572  
 respiratory rate, influences on, 569t  
 respiratory recovery time, 571  
 respiratory system, avian vs mammal, 561t  
 respiratory tract, 557-567  
 rhinogram, 576  
 rhinorrhea, 574  
 septum, oblique, 567  
 sinus aspirate, 572  
 sinusitis, 562c

- sunken sinus syndrome, 562c  
 syrinx, classification of, 560, 561  
 tail-bob, 557, 568  
 trachea, 560, 567  
 tracheal lavage, 572  
 tracheitis, 562c, 565c  
 tracheitis, proliferative, 579  
 transtracheal injection, 574  
 zinc toxicosis, acute, 557
- Pneumoviruses, 929
- Pododermatitis  
 in Anseriformes, 1262  
 in Passeriformes, 1187  
 malnutrition and, 632, 848 (see  
 bumblefoot)  
 nicotine toxicity and, 1047
- Polarized light, toxic fumes, 1049, 1204
- Polychlorinated biphenyl, cardiac, 706
- Polychromasia, 194c, 196  
 hemorrhagic conure syndrome with, 934
- Polyclonal antibodies, virus  
 identification, 864
- Polycythemia, 188, 590, 713
- Polydipsia (PD), 586, 604, 845, 860  
 malnutrition and, 845  
 plant toxicity and, 1042  
 salt toxicity and, 1044  
 viral diseases and, 877, 905, 908, 916,  
 926, 942
- Polyfolliculitis, 638
- Polyglactin, 910, 1092, 1093
- Polymerase chain reaction (PCR), 125
- Polymethylmethacrylate, in orthopedic  
 repair, 1148
- Polymorphonuclear granulocytes, 111
- Polymyxin B, 467
- Polyomavirus, 46, 47, 361, 526, 718, 790,  
 808, 826, 869c, 885-894, 1186  
 CNS signs and, 744  
 anemia, 399  
 antemortem vs postmortem diagnosis,  
 869c, 893  
 gross lesions, 892t  
 histologic lesions, 892t  
 in Passeriformes, 1198  
 vaccine and, 891f, 894  
 viral-specific antibodies, 866c  
*Mycoplasma* vs, 1058
- Polyostotic hyperostosis, 251, 256, 753
- Polyphagia, 844, 845
- Polymer rods, orthopedics, 1149
- Polypropylene welding rods, orthopedics,  
 1149
- Polyserositis, 930, 952, 964
- Polytetrafluoroethylene (PTFE) gas,  
 1047, 1198
- Polyunsaturated fatty acids, 851
- Polyurates, with *Chlamydia*, 989
- Polyuria (PU), 463, 541, 543, 586, 604,  
 605  
 causes of, 149, 150, 173c, 547c, 890, 905,  
 926, 942, 1035  
 egg laying and, 772  
 in Passeriformes, 1188  
 intermittent, 934  
 malnutrition and, 845, 850  
 neonates, 819  
 physiologic, 539  
 salt toxicity, 1044  
 zinc toxicosis, 1039
- Pons, 724
- Pool, transmission of disease in  
 Anseriformes, 1246f
- Popcorn stool, 1189
- Porcine circovirus, (PCV), 895
- Porrocaecum*, 1011f, 1194
- Portal hypertension, 536
- Portomicrons, birds vs mammals, 516
- Positive pressure ventilation, 1068,  
 1261, 1288
- Positive sharp waves, 730
- Post-capture gastrolavage, in  
 Anseriformes, 1260
- Posterior chamber, of eye, 676f
- Posterior umbilicus, 614
- Postoperative care, 1139
- Postorbital, 558
- Post-patagium, 611
- Postventer, 627
- Potassium, 91, 240, 407, 706, 840
- Powder down, 608, 616, 1202
- Pox ulcerations, 166
- Poxvirus, 114, 344, 462, 865t-874f, 866c,  
 967, 999, 1216t, 1232c  
 acyclovir and, 458  
 cross-reactions, 871t  
 cytology of, 221f  
 diagnostic techniques, 865t  
 differential diagnosis, 873t  
 free-ranging birds and, 872f  
 host spectrum, 871t  
 in Columbiformes, 1208  
 in Galliformes, 1234f  
 in Passeriformes, 1176, 1185  
 in ratites, 1309  
 infectivity, 870f  
 ocular lesions, 678, 679, 680c  
 species susceptibility, 871t  
 stage of infectivity, 870f  
 survey of hosts, 871t  
 vaccine reactions and immunity of flock,  
 874f
- PR interval, normal findings, 704
- Practice dynamics, 131-143
- Practice management, 130
- Pralidoxime hydrochloride, toxin  
 antidote, 741, 1051
- Praziquantel, 467, 1194, 1283  
 toxicity of, 1046
- Precocial birds, 802, 805, 1324
- Predators, of Anseriformes, 1245
- Prednisolone, 389, 461, 467, 600, 632  
 feet sores and, 632
- Prednisone, 600
- Preening, 92, 159, 781, 782
- Prepatagium, 611
- Preservatives, wood, 1033
- Preventive medicine, future of, 121
- Primaquine phosphate, 467
- Primary feathers, 615
- Probes, contamination, problems of, 126
- Probiocin, 465
- Probucof, 1099
- Procaine penicillin, 467, 1046, 1214
- Proctodeal glands, 756
- Proctodeum, 509, 757
- Profuse hemorrhagic diarrhea, 744
- Progesterone, 752
- Prognathism, mandible, 1165
- Prognosis, postsurgical, 1139
- Progressive paresis, in geese, 1266
- Prolactin, 84, 584, 751, 753, 783, 1210
- Prolapse of the nictitans, 740
- Pronate, 1139
- Propatagium, 1153, 1213
- Propranolol, 467
- PU/PD (see polyuria, polydipsia)
- Propylene glycol, 464, 1045  
 toxicity of, 1190
- Prostaglandin, 406, 462, 597, 752  
 egg binding and, 759
- Prosthetic beaks, 1272 (see acrylic, beak)
- Prosthogonimus*, 769, 1194
- Protamine zinc insulin, 1283 (see insulin)
- Protein  
 amino acids and, 81-82  
 breeding and, 72  
 calcium and, relationship between, 589  
 chicks, 811  
 crude, in Galliformes, 1225  
 determination, 548  
 energy and, 66t  
 in Anseriformes, 1247, 1257  
 in Columbiformes, 1206  
 in ratites, 1297, 1298  
 labeling and, 76  
 leg deformities and, 1324  
 levels, 71t, 73, 530, 850  
 quality of, 76, 82  
 slow growth rate species, 1257  
 total, in egg development, 753  
 urinalysis and, 543
- Proteinuria, 548
- Proteus*, 951, 1309
- Prothrombin time, in Columbiformes,  
 1204
- Protoporphyrin, for diagnosis of lead,  
 1037
- Protozoa, 1013, 1215  
 in Galliformes, 1232  
 in ratites, 1314t, 1315
- Proventricular dilatation, geese, 1269  
 (see neuropathic gastric dilatation)
- Proventriculotomy, 828, 1038, 1121
- Proventriculus, 74, 345, 352, 372, 492,  
 498, 499, 656, 887, 1023, 1195, 1265  
 flushing, cautions of, 345  
 impaction of, 940, 1037, 1195  
 in ratites, 499, 1288, 1310c, 1313c
- Pseudochylous, cause of, 516
- Pseudomonas*, 460, 462, 463, 468, 565,  
 958, 1189  
 heart disease and, 715  
 in Galliformes, 1232  
 in ratites, 1295c, 1309
- Pseudohyperparathyroidism, 590
- Psittacine beak and feather disease  
 (PBFD), 30, 46, 47, 790, 808, 822,  
 824f, 837, 894-903  
 diagnosis of, 866c, 885f, 897, 902  
 HI titer data, 898t  
 incubation, 897f  
 stability, 902  
 susceptibility, 895t, 897  
 transmission, 895f  
 vaccination, 866c, 902, 903t
- Psittacosis, ornithosis, 984 (see  
*Chlamydia*)
- Psyllium, 81, 384, 415, 464, 1038 (see  
 hemicellulose)
- Ptarmigan, 1220, 1229
- Pterylae, 614
- PTH, parathyroid hormone, 587

- Ptyalism, and CNS toxins, 740  
 PU (see polyuria)  
 Pudendal plexuses, 727  
 Puerto Rican Amazon Parrot, 96  
 Pullorum disease, 769 (see pneumonology, salmonella)  
 Pulmonary silicosis, 1049  
 Pulviplumes, in Columbiformes, 1202  
 Pupil, 676, 728  
   dilation of, 467  
 Pupillary light reflexes, 676, 728  
 Pruritus, 160, 523, 1026, 1197 (see dermatology)  
 Purkinje fibers, conduction of, 696  
 Pygmy Goose, 1239  
 Pyrantel pamoate, 467  
 Pyrethrin, toxicity, 467, 808, 1050f, 1195-1197  
 Pyridoxine, 72, 86, 856, 858  
 Pyridoxine anemia, 858  
 Pyrimethamine, 467, 1192
- Q** Quill mite, 1215  
 Q-fever, 1061-1062  
 Q-wave, 700  
 QRS complex, 700, 704  
 QT interval, 705  
 Quail, 1219, 1225, 1229 (see Galliformes)  
   bacterial disease in, 970, 977  
   mycoplasma in, 1054, 1056  
   parasites in, 466, 1062  
   viral diseases in, 872, 875, 905, 910, 915, 930, 932, 935, 937  
 Quaker Parakeet, 461, 464, 886 (see Monk Parakeet)  
   digoxin dosage in, 714  
 Quarantine, 33, 48, 60, 143  
   bands, USDA, 143  
 Quaternary ammonium, for *Chlamydia*, 987 (see disinfectant)  
 Quetzal, iron storage disease in, 534  
 Quill mites, 1196, 1316
- R** R-waves, 700  
 Rabies virus, 920  
 Raccoon ascarid, (see *Baylisascaris*)  
 Rachis, 158, 614f, 619, 1245  
 Racing pigeon (see Columbiformes)  
   EEG lead II, 700f  
   impaired cardiac function, 697  
   race basket, 1207  
 Radiation safety, hospital personnel, 248  
 Radiation therapy, 736  
 Radiocautery (see radiosurgery)  
 Radiography, (see imaging techniques)  
   anatomy, 249-251, 697, 698f, 720  
   anatomy, cardiovascular, 252  
   anatomy, coelomic cavity, 253-255  
   anatomy, gastrointestinal system, 253-255  
   anatomy, respiratory system, 252  
   arthritis, acute septic, 251  
   barium sulfate transit times, 256-258, 257t  
   bone, marbled appearance, 251  
   CNS disease and, 733  
   contrast procedures, dehydration and, 698f  
   contrast procedures, indications for, 256  
   dilated proventriculus, 942, 982  
   egg binding and, 761  
   gastrointestinal motility and, 248  
   heavy metal and, 248, 1035  
   hepatomegaly, 254, 255  
   hyperestrogen syndrome, 256  
   hypovitaminosis D<sub>3</sub> imbalances, 250  
   in Passeriformes, 247  
   interpretation, 249-256  
   intravenous excretory urography, 257, 259  
   left-to-right (LeRtL) position, 248  
   lung architecture, inspiration, 253  
   metritis and, 768  
   *Mycobacterium*, diagnosis of, 974  
   neonatal, 249  
   nephromegaly, causes of, 256  
   pancreas, 255  
   pericardial effusion, 718  
   presurgical, 1139  
   reproductive tract, 769, 1128  
   respiratory disorders and, 253  
   rhinosinography, 259  
   risk and benefit, 246  
   screen, film, 247  
   skeletal disorders and, 250-251  
   splenomegaly, 254  
   sternal/rib distance, (SR), 254  
 Radioimmunoassay (RIA), hormone measurement, 584  
 Radiosurgery, 39, 1103, 1113  
   bipolar, 399, 1106, 1138  
 Radius, 1139  
   surgical repair of, 1155  
 Rafoxanide, 468  
*Raillietina*, 1011f  
 Rales, 922, 989 (see auscultation)  
 Ramphastidae, 534, 777, 1276-1283  
   anesthesia in, 1280f  
   atherosclerosis in, 720  
   bacterial infections in, 1281-1282  
   biochemistry values in, 1335t  
   diabetes mellitus and, 1282-1283  
   gender dimorphism, 1277t  
   GI, neoplasia of, 505t  
   hemochromatosis, 526, 530, 534, 1281f  
   liver disease in, 1280-1281  
   radiographs, 1278f  
   reproduction in, 756, 1279  
 Ranching, free-ranging birds, 21  
 Rancid fat, 851, 855  
 Rape seed, and canaries, 536, 1043  
 Raptor, 687, 710, 749, 870, 910, 923, 1207  
   free-ranging vs captive, 987  
   gender determination in, 778  
   ocular characteristics in, 677  
   protein electrophoresis, 1335t  
   rabies in, 920  
 Ratite, 1174, 1284-1326, 1345t (see ostrich, emu, cassowary, rhea)  
   anatomy and physiology, 1286f, 1287f, 1288f, 1290f, 1291f  
   aorta, ruptured, 1307  
   blood collection in, 1297f  
   characteristics of, 1285  
   chick management, 1318, 1322  
   *Clostridium perfringens* in, 363c  
   congenital disorders of, 1322-1324  
   dermatology of, 1317  
   egg production in, 755, 768  
   fracture repair, 1150, 1161-1162, 1306-1307  
   gender determination in, 778  
   gout in, 547c  
   incubation, 1319-1320  
   infectious disease, 989, 992, 998, 1303t, 1314, 1308  
   liver, ruptured in, 363c  
   medical disorders, 716f, 720, 848, 1303-1304  
   microchip, 1300f  
   musculoskeletal disorders, 717, 850, 858, 1298, 1324  
   neoplasms in, 1308  
   neural diseases in, 1317  
   ocular problems in, 1316  
   parasites in, 1314t  
   peritonitis, 1313c  
   reproduction in, 509, 757, 768, 1303-1305  
   respiratory problems in, 1316  
   sinusitis in, 678f  
   transportation, 1300  
   yolk-related problems in, 1135, 1321, 1322f, 1323f  
 Rats, vectors of disease, 938, 961, 1207  
 Raw fish, *Erysipelothrix* in, 975  
 Records, medical, 135  
 Rectal thermometer, 1261  
 Rectrice, 615, 1220  
 Red blood cell count, 179 (see hematology, CBC)  
 Red factor, in canaries, 1177  
 Red mites, *Ornithonyssus*, 1196, 1209  
 Red tide, 978, 1266  
 Reference intervals, 225  
 Reference values, 225, 1329t-1345t  
 Reglan, 465  
 Regurgitation, 150, 414, 490, 497, 743, 775 (see vomiting)  
   crop pH and, 150, 827  
   egg laying and, 772  
   in adults, differential, 483t  
   in chicks, 824  
   in Passeriformes, 1190  
   malnutrition and, 849  
   sexual, 36  
   undigested seeds in feces and, 500  
 Rehabilitation, wildlife, native birds, 19  
 Reintroduction to wild, 806, 1229  
 Remige, 615  
 Renal, 538-581 (see kidney, nephrology, urine)  
   adenocarcinomas, and neuromuscular disease, 735  
   calcification in, 1046 (see hypervitaminosis D<sub>3</sub>)  
   damage, in oil-contaminated Anseriformes, 1263  
   disease, diets for, 850  
   dysfunction, 446, 758  
   excretion of calcium, increased, 737  
   failure, causes of, 408, 890, 1247  
   glucosuria, 605  
   neoplasia, 553  
   portal system, 539  
   toxicity, 444  
 Renografin, 464  
 Reovirus, 718, 744, 904, 910-913, 943, 1232  
 Reproduction (see theriogenology)  
   cessation of, 771  
   daylight length and intervals in, 1174  
   disorders, evaluation of, 748, 758, 774, 787

- E. coli* in, 951  
 failures, evaluation of, 61t  
 genetic abnormalities, 1226  
 in Anseriformes, 1243, 1252  
 in Columbiformes, 1209  
 in Galliformes, 1226  
 in Passeriformes, 1174  
 in Ramphastidae, 1279  
 in ratites, 1290, 1302t, 1304  
 neoplasia and, 770  
 salt and, 860  
 stimulation in Psittaciformes, 782  
 surgery and, 1128
- Respiratory (see pneumonology)  
 arrest, 711, 1080  
 cycles, two, 569  
 disease, 144, 558, 559t, 560t, 578t, 677t, 770, 828, 904, 908, 915, 927, 982, 1190  
 imaging, 571  
*E. coli* and, 951  
 in Passeriformes, 1187, 1193, 1195  
 in ratites, 1316  
 malnutritional disorders and, 846, 860  
 mycoplasma and, 1054  
 problems, database for, 572  
 radiographic lesions and, 252t  
 recovery time, 571  
 system, avian vs mammal, 561t  
 tract, 557-567  
 toxic fumes and, 1049  
 viral disease and, 905, 922, 928
- Respiratory rate  
 in Anseriformes, 1243  
 in birds, formula, 148t, 166  
 in Columbiformes, 1204  
 in Galliformes, 1221t  
 influences on, 569t
- Respiratory stimulant, 462
- Restraint, 156, 157f (see physical exam)  
 in Anseriformes, 1258, 1260f  
 in Columbiformes, 1211f, 1211t  
 in Galliformes, 1233  
 in Passeriformes, 1181
- Restraint board, plexiglass, 248
- Retarded growth (see stunting)
- Rete testis, 756
- Reticulate body, 985
- Reticulocyte, 934
- Reticuloendotheliosis virus, 934-935
- Retinal disease, 688
- Retrovirus, 931-936, 1185, 1232
- Rhabdomyolysis, exertional, vitamin E, 855
- Rhabdovirus, 920, 1232
- Rhamphotheca, 484, 609, 618, 1220
- Rhea, 685, 973, 1049, 1284-1286, 1288, 1290, 1298, 1308, 1320 (see ratite)  
 digestive anatomy in, 1288  
 reproduction in, 1303  
 testicle in, 1290f
- Rhinitis, 160, 562c, 576, 680c, 881, 930, 963, 1106  
 mycoplasma and, 1054
- Rhinogram, 294-297, 576, 577f
- Rhinolith, 577, 683c, 1105f
- Rhinorrhoea, 560t, 574, 912, 1106
- Rhinosinography, 259
- Rhinosporidiosis, 575, 1005
- Rhinotheca, deformed, 485f, 562c
- Rhizopus*, from sprouted seed, 1005
- Rhododendron, 1041
- Riboflavin, 72, 85, 849, 856, 1251  
 deficiencies in, 848, 1298
- Rickets, 854f, 858  
 in Anseriformes, 590, 1252, 1258  
 rubber beak, 484, 590
- Rickettsia*, 1053, 1061, 1215, 1232
- Rifamate, 464
- Rifampin, 452, 464, 468, 1005
- Right jugular vein, catheter, 385f
- Right ovary, persistent, 773
- Roaches, pest control, 59
- Robert Jones bandage, 430f (see bandage)
- Rocket nets, 1260
- Rocky Mountain Spotted Fever (RMSF), 1061
- Rodenticide, toxin, 1051
- Rodent, as disease vector, 59, 917, 961-964, 1061, 1188, 1281
- Rolled toes, in ratites, 1324f
- Roller Canary, 1174
- Ronidazole, 1190, 1209
- Rose-breasted Cockatoo (see cockatoo)
- Rostral, 558
- Rotating skin flap, 1115
- Rotational deformity, in ratites, 1310c
- Rotavirus, 913
- Round heart disease, 717
- Roundworms, 1021f, 1194, 1215
- Rubber band, tourniquet, 1007
- Rubber bill, 484 (see rickets)
- Rubivirus, German measles, 918
- Rubriblast, proerythroblast, characteristics of, 196
- Rubricyte, 188, 196
- Ruddy Shelduck, 1239
- Ruffed Grouse, 1229
- Runners, budgerigars, 623  
 polyomavirus in, 890
- Ruptured aorta, 1307
- Russian spring-summer encephalitis virus, 919
- S** *Struthio*  
*S. camelus australis*, 1285  
*S. massaicus*, characteristics of, 1285  
*S. molybdophanes*, characteristics of, 1285
- S-wave, 700
- Sabouraud  
 dextrose agar, 1003, 1005  
 cornmeal agar, 999
- Saccopleural membrane, 514
- Safflower seeds, dietary fat, 851
- Sagittal saw, 1133
- Salinomycin, 1307
- Salivary ducts, swelling, 845
- Salivary glands, 485
- Salivation, in Anseriformes, 1266
- Salmonella*, 59, 466, 718, 953-955, 982, 1208  
*Chlamydia* vs, 990  
 control of, 955  
 in Anseriformes, 1237, 1257  
 in Columbiformes, 1212  
 in Galliformes, 1232  
 in ratites, 1309  
 metritis and, 768  
 mycoplasma and, 1058  
 paramyxovirus vs, 928  
 reproduction and, 768, 774, 1256  
*S. typhimurium var copenhagen*, 1188
- Salpingeal orifice, 1211
- Salpingitis, 462, 768-769, 793c  
 heart disease and, 714
- Salpingohysterectomy, 772, 1129
- Salt (NaCl), 553  
 feather quality and, 846  
 in Galliformes, 1221  
 polydipsia and, 845  
 toxicosis, 38, 553
- Sandpaper perches, warning, 39
- Sarcocystis*, 59, 362, 742, 808, 826, 1017  
 in Passeriformes, 1190  
 susceptible species, 1017t  
 treatment for, 467
- Sarcoma/leukosis virus (SLV), 931-934
- Scaly mites (see *Knemidokoptes*)
- Schirmer tear test, results in, 674
- Schistosomiasis, 742, 1266
- Schroeder-Thomas splint, indications, 430f
- Scintigraphy, 734
- Scissors beak, 789, 1165f
- Screamers (Anhimidae), 1238
- Sea ducks, 1246
- Sebaceous secretions, irradiation, 83
- Secondary feathers (see feathers)
- Seed, 842, 951 (see feed)  
 amino acids in, 851  
 calcium deficiency of, 858  
 undigested in droppings, 855, 887
- Segmental reflex, 729
- Seizure, 410, 461-462, 739 (see convulsion, tremor, epilepsy)  
 causes of, 738t  
*Chlamydia* and, 745  
 CNS toxins and, 740, 1038-1039, 1044, 1047  
 emergency treatment for, 411, 414  
 idiopathic epilepsy and, 738  
 recording of, 738  
 viral diseases and, 744
- Selective breeding, in Columbiformes, 1204
- Selenidera* spp., 1277
- Selenium, 71t, 84, 94, 469, 848, 859 (see vitamin E)  
 deficiency of, 504, 848, 937, 1298  
 degenerative myopathy in ostriches, 1307, 1308  
 egg binding and, 759  
 feather quality and, 846  
 food sources of, 80t  
 immune response and, 849  
 malabsorption and, 845  
 requirement in ducklings, 1251  
 toxicosis, 75t, 1041
- Self-adherent bandages, 422
- Self-mutilation, 424f, 461, 464, 846
- Semen, 757, 780, 1211 (see artificial insemination)  
 extender, 757, 1231  
 in ratites, 1305  
 preservation of, 777, 1253  
 volume and concentration, 757t
- Seminal glomus, 756, 857, 1178
- Seminal papilla, 757
- Seminoma, 774
- Semiplume, 615, 1202
- Sentinel birds, for viral monitoring, 916

- Septicemia, 362c, 459, 826, 982t, 1187  
 Septum, horizontal, 514, 515  
 Serofibrinous pericarditis, 709f  
*Serratia*, 951  
*Serratospiculum amaculata*, 1193  
 Sertoli cells, 756  
   tumors in, 251, 774  
 Sexing (see gender determination)  
 Sexual characteristics, 770, 778, 1175  
 Sexual maturity, age of, 779, 1210, 1229, 1252, 1301  
 Sexual orientation, 1180  
 Sheep, *Chlamydia* in, 984  
 Sheldgoose, 1239, 1252  
 Shellduck, 1239  
 Shell gland, 1129  
 Shell vs grit, 846  
*Shigella*, 951  
 Shock, 389, 414  
 Shock molt, 1233  
 Shoe splint, 431  
 Shuttle pins, 1149  
 SI Unit System, 226, 1328  
 Sialolith, in Columbiformes, 487, 881  
 Siberian tick encephalitis virus, 919  
 Silicosis, silicone/sulfur ratio, 1049  
 Silkie chickens, as foster brooders, 788  
 Silver nitrate, 39, 113, 1269  
 Silver sulfadiazine, for burns, 412, 424  
 Singing  
   in Passeriformes, 1178  
   testosterone-induced, 1175  
 Sinoatrial block, 706  
 Sinuses, heart  
   arrest, 705  
   arrhythmias, 705  
   bradycardia, 706-707  
   tachycardia, differentiation, 708  
 Sinuses, respiratory, 558, 160, 905, 1106  
   (see anatomy overlay)  
   inflation, 680c  
   infraorbital, 558, 931  
 Sinusitis, 558, 562, 572, 678f, 680c, 683c  
   *Chlamydia* and, 989  
   cytology of, 202f, 218c  
   from airborne toxins, 1048  
   mycoplasma and, 1054, 1058  
   radiograph, 251  
   rhinorrhea, 459, 1106  
 Skeletal deformities, 848, 918f, 1324  
 Skeleton, ostrich, 1287f  
 Skin, 1097, 1197  
   discoloration, with *Clostridium*, 977  
   leg scales, in Passeriformes, 1097, 1197  
 Skull, radiography, 249 (see imaging)  
 Slide agglutination test, for  
   *Mycobacterium*, 974  
 Slipped tendon, 1258, 1324  
 Slit lamp, 674f  
 Smuggled birds, 47  
 Snail, aquatic, 769, 1194  
 Snake, pest control, 59  
 Sneezing, 905, 1048, 1058, 1106  
 Snood, 1219  
 Snowshoe splint, 432f  
 Sodium, 91, 240, 712, 850, 1252  
   toxicity of, 714, 1044  
 Sodium diatrizoate, radiography, 259  
 Sodium fluoride, 234  
 Sodium hypochlorite, toxicity, 1048  
 Sodium polyanetholsulfate, for blood  
   cultures, 950  
 Sodium sulfate (Glauber's salt), 415,  
   458, 468, 1038  
 Soft tissue mineralization, 84 (see renal  
   calcification)  
 Soft tissue surgery, 1096-1136, (see  
   surgery)  
 Soft-shelled eggs, 256, 752, 1336 (see  
   egg, soft-shelled)  
 Solar heat, 1229  
 Somatotropin, 584  
 Sour crop, 825, 1216 (see ingluvies)  
 Sparrow, 20, 461  
   as disease vector, 1191-1194  
 Sparatrix, 459  
 Specific gravity, urine, 242, 548  
 Spectinomycin, 438, 468, 686, 1060  
 Speculum, canine vaginal, 1108  
*Speleognathus*, 1195  
 Sperm, 174c, 756 (see semen)  
   in Anseriformes, production, 1265  
 Spermatocrit, 757  
 Spermatogenesis, 458, 757, 784  
 Spermatozoa, blood clotting agents, 757  
 Sphenisciformes (penguins), 933  
*Spherophorus*, 953  
 Spica splint, 431, 1161  
 Spinal  
   abnormalities, 734  
   accessory nerve (CN XI), 726  
   autonomic nervous system, 727f (see  
     anatomy overlay)  
   surgery, 734  
 Spiramycin, toxicity, 1060  
*Spirillum pulli*, 489  
 Spirochaetaceae, 960  
 Spirulina, 87, 1177  
 Spiruroid, 486, 1011f, 1023, 1195  
 Splay leg (see spraddle leg)  
 Spleen, 116, 882, 907, 973, 1043, 1173  
 Spleen necrosis virus, 934  
*Splendidofilaria*, 1193  
 Splenomegaly, 117f, 254, 907-909, 930,  
   1054  
   *Chlamydia* and, 990  
   differential diagnosis, 254t, 313  
 Splints, 431, 1182  
   spica-type, 1161  
 Spondylolisthesis, 734  
 Spontaneous cardiomyopathy, in  
   broilers, 713  
 Spraddle leg, 732, 830f, 855, 1324  
 Spring-loaded nets, 1260  
 Sprouts, source of pathogens, 57  
 Sputum solvents, for *Mycobacterium*, 974  
 Squab, 821, 880, 1046  
 Squamous metaplasia, 344, 558, 850,  
   852, 1108, 1113  
 Squamous plaque, 655  
 St. Louis encephalitis virus (SLE), 919  
 ST-segment, 700, 704  
 STA solution, 468  
 Stains (see hematology, cytology)  
 Stamp stain, 532, 987  
 Stanazolol, 468  
*Staphylococcus*, 535, 965-967, 1187,  
   1232, 1281, 1309  
   Amazon foot necrosis and, 966f  
   *Chlamydia* and, 991  
   dermatitis and, 460  
   heart disease and, 715  
   ocular disease and, 685  
   peritonitis and, 772  
   spinal deformities and, 968f  
 Star gazing, 1251  
 Starling, as disease vector, 28, 872, 960,  
   1054, 1195  
 Starvation, effects on glucose, 234  
 Starveout, in Anseriformes, 1255  
 Steatitis, vitamin E, 855  
 Steatorrhea, 514, 846  
 Steinmann pins, 1146  
*Sternostoma tracheacolum*, in  
   Passeriformes, 464, 575, 1026, 1195  
 Sticky chick, in ratites, 1321  
 Stifle subluxation, neonate, 831, 836f  
 Stool (see excrement)  
 Stomatis, 488  
 Strabismus, 684, 728  
 Straw feathers, 1184  
*Streptococcus*, 535, 820, 968-971  
   cardiac effects and, 715, 718  
   in Galliformes, 1232  
   in Ramphastidae, 1281  
   infection from children, 970  
   metritis and, 768  
*Streptomyces*, 978  
 Streptomycin sulfate, 468  
 Stress, 72, 394t, 850, 1257, 1323  
 Stress marks, feather, 601, 628, 633-634,  
   837, 846  
 Strictures, esophageal, 1113  
*Strigeid*, 1011f  
*Struthio camelus*, characteristics of, 1285  
 Struthioniformes (see ostrich, ratites)  
 Stunting, neonates, 822f, 1233  
 Stupor, 976, 1188  
 Sturnidae, 534  
 Subcutaneous edema, 1198  
 Subcutaneous fluids, 384  
 Subcutaneous injections, 388, 611  
 Suborbital diverticulum, 204f  
 Substrates, *Aspergillus* in, 1001  
 Sucralfate, 468, 857  
 Sulfa drug, 442, 1046  
 Sulfachlorpyridazine, 438, 468  
 Sulfadiazine, 468  
 Sulfamethoxale, 1187  
 Sulfur amino acids, 72  
 Sunburn, 50  
 Sunflower seeds, dietary fat, 851  
 Sunken sinus syndrome, 562c, 577, 1316  
 Superficial pectoralis muscle, 127  
 Superoxide dismutase, 112  
 Supinate, 1139  
 Supportive care, 382-416  
   air sac rupture, 409  
   air sac tube, 396, 397f  
   anemia, 398-399  
   animal bites, 412  
   blood volume, 400  
   burns, 412  
   caloric requirements, 394  
   cardiovascular system, 398, 401  
   cloacal prolapse, 404  
   coma, 411  
   conure bleeding syndrome, 404  
   corticosteroid, 389-390  
   crop flushing, 403  
   dehydration, 384t  
   diarrhea, database, 404

- duodenal feeding tube, 403  
 dyspnea, 408  
 egg binding, 406, 407f  
 egg-related peritonitis, 408  
 emergency problems, 383, 398-416  
 emergency quick referencing, 414t  
 enteral nutrition, 345t, 394, 395t  
 equipment, 415t  
 fluid requirements, 383-388  
 frostbite, 413  
 gastrointestinal stasis, 402  
 head trauma, database, 410  
 heat, 398  
 heavy metal, GI stasis, 403  
 hemorrhage, treatment of, 399  
 hepatitis, database, 405  
 housing, 398  
 hyperthermia, 413  
 hypoglycemia, common in, 389, 410  
 hysterectomy, 407, 408  
 liver disease, treatment for, 405  
 maintenance energy requirement (MER), 394  
 metabolic scaling, example, 394t  
 neurologic system, 410  
 nutritional support, 390, 396, 1082  
 oil, 413  
 oxygen, 395t  
 pancreatitis, 405  
 paralysis of acute onset, 411-412  
 renal failure, 408  
 respiratory system, 408-410  
 seizures, 410  
 shock, 401  
 stress maintenance, 394t  
 toxins, 415  
 tube feeding, 392t  
 urogenital system, 406  
 uterine prolapse, 407  
 vascular perfusion, 401  
 vomiting, 403, 404  
 Supracoracoideus muscle, 1271  
 Supraventricular tachycardia, 708  
 SureCell, for *Chlamydia*, 992  
**Surgery**  
   antibiotics and, 1084  
   basal metabolic rate and, 1082  
   bipolar forceps, 1088f, 1103  
   celiotomy, 1118, 1119f  
   cloacopexy, 1126f, 1127f  
   considerations, 1081  
   constricted digits, 1098f  
   controlling hemorrhage, 1087  
   crop burns, 1116f  
   drapes, 1084  
   egg-related peritonitis, 1131  
   eye, 1100-1105  
   feather cyst, 1098  
   feather removal, 1083  
   gastrointestinal, 1111  
   ingluviotomy, 1117f  
   instruments, 1085  
   integument, 1097  
   microsurgery, 1086, 1090, 1091f, 1097  
   orchidectomy, 1131  
   oviduct, 769  
   patient preparation, 1082, 1094  
   postoperative management, in ratites, 1094-1111  
   proventriculotomy, 1121, 1122f, 1123f  
   radiosurgery, 1087f, 1090, 1097  
   reproductive, 1128-1131  
   respiratory, 1105f  
   salpingohysterectomy, 1130f  
   scalpel blades, 1097  
   skin incisions, 1088f, 1090, 1097  
   soft tissue, 1096  
   suture, 1092, 1093, 1097, 1123, 1125  
   thoracic, 1107  
   tissue adhesives, 1093, 1099  
   toe amputation, 1134f  
   trachea, 1109f, 1110f  
   urophygeal gland, 1099  
   vasospasm, 1089  
   wing, 1099, 1133, 1136, 1154f  
   wound healing, 1084f, 1085  
**Surgical sexing** (see gender determination)  
**Suspended flights**, 53  
**Swallowing**, and neurologic disease, 728  
**Swallow**, as disease vector, 1193  
**Swans**, 452, 742, 908, 1049, 1039, 1238, 1252, 1257  
   herpesvirus in, 875, 877, 884  
   lead in, 1035, 1038  
   trachea in, 1107  
**Swollen head syndrome**, influenza virus and, 929  
**Synchronization of hatch**, in Galliformes, 1228  
**Syncope**, 706f, 712, 849, 1197  
**Syngamus**, 468, 576, 1011f, 1024t,f, 1024f, 1198, 1295c  
**Synovitis**, 982t, 1058  
**Syringeal bulla**, ducks, 1239 (see imaging)  
**Syringeal foreign body**, removal of, 1108  
**Syrinx**, 561, 1108  
  
**T**  
**T-cell**, 117  
**T-lymphocytes**, 113, 118f  
**T-wave**, 700, 705  
**T<sub>2</sub> intoxication**, 1265  
**T<sub>3</sub>**, fat metabolism and, 595, 851  
**T<sub>4</sub>**, reproduction and molt, 851  
**Tachycardia**, 702, 1266  
   propranolol and, 467  
   with P-wave, 704  
**Tachypnea**, 590, 715, 1266  
**Tagamet**, 460  
**Tags**, bird identification, 41  
**Tahyna virus**, 919  
**Tannin**, 1042  
**Tapeworms**, 460, 466, 1021, 1194, 1215f, 1011f, 1013f, 1314t (see cestodes)  
**Tarsometatarsus**, 1121, 1157  
**Tarsorrhaphy**, 686  
**Tasselfoot**, in canaries, 1026, 1196  
**Tattoos**, bird identification, 42, 611  
**Taxonomy**, pigeons, 1201  
**Technician**, duties of, 131  
**Teflon stent**, 1107  
**Teflon toxicity**, 1047  
**Tellurium**, toxicity, CNS signs and, 746  
**Telmintic**, 465  
**Temperate species**, 1174, 1257  
**Temperature in birds**, 169, 792, 1203, 1220, 1221t  
**Tendonectomy**, in Anseriformes, 1269  
**Tenesmus**, 461, 483t  
**Tensor propatagialis**, 1271  
**Territorial defense**, 782, 1129  
  
**Testicle**  
   atrophy of, 776  
   color and variables, 332c, 343, 348t, 349, 755, 756, 774f, 756  
   degeneration of, 774, 855  
   in Galliformes, 1223  
   masses of, 256  
   mature, 335c  
   melanistic, 332c  
   neoplasia of, 774  
**Testosterone**, 465, 468, 637, 757, 770, 775, 776, 1175, 1211  
   peritonitis and, 771  
**Tetanus**, 978  
**Tetracycline**, 447, 459, 824, 1187, 1189  
   for *Chlamydia*, 993  
   in toucans, 462  
   in water, 439, 442  
   toxicity of, 1046  
**Thelazia** and ocular disease, 686c, 683, 1023  
**Theophylline**, and chocolate toxicity, 1044  
**Therapeutic agents of choice**, 462, 1181  
**Theriogenology**, 748-804  
   artificial incubation, 788-804  
   artificial insemination, 776-777  
   calcium metabolism, 753  
   egg formation, structure, 750f, 753-754f  
   female hormonal factors, 751-752  
   female reproductive anatomy, 749 (see anatomy overlay)  
   female reproductive disorders, 774-777  
   male hormone factors, 757-758  
   male reproductive anatomy, 755-756f  
   male reproductive disorders, 774-777  
   non-disease factors affecting reproduction, 777-778  
   semen, 757  
**Thermogradient**, in brooder, 1254f  
**Thermometer**, 1261  
**Thiabendazole**, 468  
**Thiaminase**, fish diet, 468  
**Thiamine**, 73, 468, 856, 1251  
   deficiency, 1292c, 705t, 706, 709  
**Thiopental sodium**, 1260  
**Third degree AV block**, 710  
**Thoracic air sacs**, 342 (see anatomy overlay)  
**Thoracic surgery**, 1107, 1198  
**Thoracoabdominal cavity**, fluid in, 366  
**Thoracolumbar spinal cord lesion**, 729  
**Thrombocytes**, 112, 183, 187, 196 (see hematology)  
**Thymus**, 118f, 372  
**Thyroglobulin**, 593  
**Thyroid**, gland, 370, 594, 1210  
   stimulation testing, TSH, 468, 584  
   tumors, 594, 860  
**Thyroiditis**, 119, 593  
**Thyrototoxicosis**, 596  
**Thyrotropin releasing hormone**, for spinal trauma, 734  
**Thyroxine**, 637  
**Tibia**, in egg laying, 753  
**Tibiotarsus**, 1142, 1161  
   surgical approach to, 1160, 1162f  
**Ticarcillin**, 445, 468  
**Tick** (as disease vector), 916, 960, 1061-1063, 1192-1193  
**Tinamous**, 1285

- Tissue adhesives, 1093, 1099  
Tobacco products, toxicity, 1047  
Tobramycin, dose, 447, 468  
Toe  
  amputation, 1134f  
  constriction, malposition, neonate, 830-831  
  neonate, 831  
  necrosis, 1097  
  picking in Galliformes, 1233  
Togavirus, 915, 917  
  CNS signs and, 744  
  in chicks, 825  
  in Galliformes, 1232  
  picornavirus vs, 937  
Tomia, 484  
Tongue, 728, 732, 743, 1173  
Tonometry, 675  
Tophi, 540  
Tortricollis  
  bacterial, 953f, 976  
  *Chlamydia* and, 745  
  correction of, 816f  
  in Passeriformes, 928, 1188  
  in pigeons, 881, 1216f  
  parasites and, 742  
  viral disease and, 743, 744, 881, 906, 916, 922, 930  
  vitamin E and, 855  
Total iron binding capacity (TIBC), 236, 530  
Total parental nutrition (TPN), 393  
Total protein, 236  
Toucan, 334, 459, 464, 1279, 1280-1282  
  (see Ramphastidae)  
  coccidia in, 468  
  liver disease in, 858  
  tetracycline in, 468  
  *Yersinia* in, 957  
Tourniquet, 1097  
Toxiban, 458  
Toxicologic analysis, 1033, 1051  
Toxin, 1030-1052  
  antifungal, 999  
  antimicrobial therapy, 442  
  automobile lubricant, 1035  
  birds vs mammals, 1033  
  brodifacoum, 1051  
  carbamate, 1051  
  carbaryl, 1050, 1051  
  carbon monoxide (CO), 1049  
  chelating agents, 1038t  
  CNS diseases and, 723  
  commonly encountered, 1032t  
  copper, 1039  
  crown vetch, 1042t  
  DDE, DDT, 1050  
  diazinon, 1050  
  dichlorvos, 1050  
  emergency treatment of, 414  
  environmental, 460  
  ethylene glycol, 1044  
  exposure, 414  
  fertility and, 786  
  flea collars, 1051  
  formaldehyde fumes, 1048  
  fungus, 1043  
  gases, in Galliformes, 1233  
  harmful foods, 1044  
  household compounds, toxic potential, 1031t, 1032t  
  iatrogenic, 1045-1047  
  in Anseriformes, 1266  
  insecticides, 1049  
  lead, blood levels, normal, 1036t  
  lead, sources of, 1034t  
  lily of the valley, 1041  
  malnourished birds and, 1033  
  mercury, 1040  
  methomyl, 1050  
  mite protector, 1051  
  mycotoxin, 1041  
  naphthalene, 1051  
  natural gas, 1049  
  natural plant, 68  
  nitrate, 1041  
  normal household compounds, 1031t, 1032  
  nutrients, effects of, 75t  
  oil, 1040  
  organochlorine, 1050  
  organophosphate, 1050  
  oxygen, prolonged exposure, 1047  
  para-dichlorobenzene, 1051  
  parathion, 1050  
  permethrin, 1050  
  pesticide vapors, 1049, 1051  
  petro-chemicals, migratory bird, 1050  
  plants, 741, 1041t  
  polytetrafluoroethylene (PTFE) gas, 1047  
  reproductive disorders and, 774  
  rodenticide, 1051  
  selenium, 1041  
  tobacco products, smoke, 1047  
  vitamin K, antidote, 1051  
  warfarin 1051  
  zinc, 1038-1039  
*Toxoplasma*, 467, 1017, 1190, 1191, 1314  
  clinical signs of, 741, 742  
Toys, safe, unsafe, 36f  
TPN solution, 383  
Trachea, 567, 1107, 1221, 1238, 1295  
  bull, 1238f  
  coiled, 1107  
  diameter, 1108  
  diverticulum, in emus, 1288, 1292c  
  in ratites, 1295c  
  mites, 970  
  obstruction, 704  
  surgery of, 1107, 1108  
  worms, in ratites, 1314  
Tracheitis  
  adenovirus and, 579, 906, 1234  
  in Passeriformes, 1187  
  in ratites, hemorrhagic, 1314  
  influenza virus and, 930  
  mycoplasma and, 1054  
Tracheobronchial syrxinx, in Galliformes, 1221  
Tracheotomy, 1109f  
Tragopans, 1219  
Training, behavior, 101-107, 1204  
  in Columbiformes, 1204  
Tramisol, 465  
Transfusions, neonates, 829  
Transportation, 31, 33, 133, 136, 1208  
Transtracheal illumination, 576  
Trauma  
  band injuries, 422-424  
  feather, toenail, beak injuries, 423  
  fractures, nonsurgical immobilization, 428  
  frostbite, 424  
  hydrocolloid dressing splints, 421f  
  injuries, management of, 422-433  
  lacerations, 422  
  medicine, 417-433, 419f  
  neuropathies, 733  
  self-mutilation, 423  
Trematodes, 468, 576, 1194, 1232 (see flukes)  
Tremor, 689, 740, 743, 744, 745, 906, 976, 989, 1045, 1188  
Trepination, 1106, 1107  
*Treponema*, 961, 1232  
Triamcinolone, 1100  
Tribromoethanol, 1260  
*Trichobilharzia*, in geese, 1266  
*Trichomonas*, 113e, 166, 210, 344, 459, 461, 464, 486, 489, 491t, 575, 882, 915, 973, 825, 1013, 1209  
  *Candida* vs, 999  
  cytology of, 218c  
  in Columbiformes, 715, 881, 1207  
  in Passeriformes, 1190  
  in ratites, 1314  
  resistant strains of, 496  
*Trichophyton*, 625, 1005  
  in Galliformes, 1232  
  in Passeriformes, 1189  
  zoonosis, 1005  
Trichosporonosis, 575, 1005  
Trichostrongylus, 1011f  
Trichothecenes (T<sub>2</sub>), 485, 489, 1044, 1265  
Tricyclic antidepressant, 461, 462, 636  
Trigeminal nerve (CN V), 724  
Trigeminy, 708  
Triglycerides, 238  
Trimethoprim, 468, 824, 1187, 1322  
TRIS lysozyme solution, 462  
Trochlear nerve (CN IV), 725  
True geese, 1239  
*Trypanosoma*, 1021, 1193  
TSH, 468  
  stimulation test, 595, 729  
Tube feeding, 391, 1115  
Tubercle bacilli, 464, 468  
Tuberculin test, false-negative results, 974  
Tuberculosis (see *Mycobacterium*)  
  cytology of liver, 215  
  decreased A/G ratio in, 238  
  in ratites, 1309  
Tularemia, 964  
Tumescence, 509  
Tumors, 251, 689, 774 (see oncology)  
  abdominal, 1133  
  granulosa cell, 770  
  in waterfowl, 1266  
  poxvirus with, 872  
  viral-induced, 936  
Turacos, 957, 1282  
Turkey (see Galliformes)  
  aortic rupture, 720  
  hemorrhagic enteritis, antibody, 903  
  herpesvirus, 875  
  meningoencephalitis virus in, 918  
  Twiehaus-type strains, 935  
  Twirling syndrome, in finches, 939  
Tylosin, 449, 686, 1060  
  eggs and, 795  
  in canaries, 1187



## INDEX

- Type C retrovirus, leukosis-related viruses, 931-932
- Type C toxin, 1263
- Tyrosine, and feather quality, 847
- U** Ulcer, sucralfate, 468, 851
- Ulceration, corneal, 1100
- Ulcerative dermatitis, 461, 462
- Ulna, 1139 (see anatomy overlay)
- surgical repair of, 1155
- Ultrasonography, 260, 325
- anechoic and, 325
- hyperechoic and, 325
- pericardial effusion and, 718
- Ultrasound, 260, 325, 697, 706f
- abdominal, 256
- for reproductive evaluation, 768
- guided biopsy, 325
- in ostriches, 1301, 1304
- soft-shelled eggs vs egg-related peritonitis, 325
- Ultraviolet light, 1204
- Ultraviolet Wood's lamp, 686
- Underbite, mandibular prognathism, 837
- Urates, 150, 1132
- Urea, 238, 239, 539, 542
- Ureaplasma, 1053, 1232
- Ureter, relation to ductus deferens, 756
- Uric acid (UA), 239, 539, 850, 916, 1223, 1335t
- postprandial effects of, 542
- Uricotelic, 539, 850
- Urinalysis, 150, 242, 543t, 547, 548
- bacteria and, 244
- casts and, 244
- color of, 523, 845
- in Anseriformes, 242
- in ratites, 242
- osmolality of, 586
- white and red blood cells in, 244
- Urine water, 539
- Urination, in ratites, 1290
- Urodeum, 509
- Urogenital system, anatomy and physiology, 255-256
- Urography, 256
- Urolithiasis, 553, 914
- Uropygial gland, 169, 613-614, 784
- impaction, 644, 665, 1099, 1219
- in Columbiformes, 1202
- Uropygial teat, 1219
- Uterus, 749, 1129 (see anatomy overlay)
- contractions of, 463
- emergency treatment of prolapse, 414, 762
- flushing of, 760, 762
- increased tone of, 462
- infections, rough-shelled eggs, 773
- prolapse of, 407, 801c
- rupture, 768
- stasis and, oxytocin, 467
- Uukuniemi virus, 919
- Uveitis, 194, 673, 687, 1100
- viral diseases and, 744, 911
- in ratites, 1309
- Pacheco's virus disease, 50
- Pasteurella*, 963
- Salmonella*, 50
- subunit, 126
- viral, 126, 939t
- Vagina, 749
- examination of, 760f
- prolapse of, 801c
- relaxation of, 462
- Vagus nerve (CN X), 706, 726
- Valgus deformity, 250, 830, 831f, 832c, 1161, 1165f
- in ratites, 1307f, 1325f
- Valvular endocarditis, 717f
- Vapor permeable (MVP) dressings, 420
- Varieties, pigeons, 1212
- Vas deferens, in Columbiformes, 1210
- Vasa Parrot, cloacal swelling, 509
- Vascular access device, 388, 1133
- Vascular clips, 1111
- Vasectomy, 777, 1178
- Vasotocin, 583, 760
- Vector leads, augmented, 701
- Vecuronium bromide, 674
- Vegetable oils, essential fatty acids, 81
- Vegetative endocarditis, 414, 716f
- Venereal disease, and mycoplasma, 1054
- in ganders, 511
- Venezuela equine encephalomyelitis, (VEE), 917
- Venous sinus, 724
- Vent
- gleet, 510
- opening, narrowing, 1125
- picking, in Galliformes, 1233
- response, and neurologic disease, 729
- sexing, 778
- Ventilation, poor, 1001
- Ventral hepatic peritoneal cavity, 346, 351
- Ventral ligament, of oviduct, 1129
- Ventricular
- arrhythmias, 708
- bigeminy, 122
- fibrillation, 1262
- hypertrophy, 710f
- premature contractions, 708, 709
- septal defect, 816
- tachycardia/atrioventricular dissociation, 707
- digitalis, 714
- Ventriculotomy, 1121
- Ventriculus, 345, 499, 503, 851, 1121, 1203, 1288
- aflatoxin in, 1265
- atonic, 845
- atrophy of, 940
- biopsies, 942, 1123
- erosions in, 851
- in Galliformes, 1222f
- in Passeriformes, 1173
- in ratites, 1288, 1289
- treatment of, 499, 1121
- Veratrum californium*, 746
- Vertebrae, varying number, 726
- Vertebral fracture, radiograph, 251
- Vesicular dermatitis, with *Staphylococcus*, 967
- Vestibulocochlear nerve (CN VIII), 726
- Vetisulid, toxicity, 1045
- VHPC, 346 (see endoscopy, ventral hepatic peritoneal cavity)
- Vibramycin, 463
- Vibravenös, 462
- Vibrio, 960
- Videotapes, 131f
- Vinyl turf-type mat, for Anseriformes, 1254
- Viral serositis, (AVS), 371, 501, 507f, 917
- ascites and, 869c
- ileus and, 918f
- pathologic changes and, 917t
- Virginia creeper, 1041
- Virus, 862-948
- Agar-gel diffusion test, 864f
- common, reference data, 939t
- complement-fixation test, 863
- control, 939-940t
- cultures, 863-865
- diagnosis of, 863, 865t
- egg-transmitted, 119
- ELISA test, 863
- HA titer, hemagglutination inhibition (HI), 864f
- identification, 863f, 864, 865
- in Anseriformes, 1267t
- in Columbiformes, 1212, 1215t
- in Galliformes, 1232t
- in Ramphastidae, 1282
- in ratites, 1303t, 1308
- interferon, for treatment, 862
- neuropathies, 743
- neutralization test, 863
- ocular, 678
- radioimmunoassay test, 863
- specific treatment for, 943t
- supportive care for, 862
- transmission, 862
- tumors, 872
- Viscera, posthepatic septum, 515
- Visceral gout, cardiac effects, 718, 914
- Visceral lymphomatosis, with REV, 934
- Visual deficits, 736, 937
- Vitamin A, 72, 82, 83, 574, 738, 852, 1250
- egg laying and, 773
- feather quality and, 846
- dyspnea and, 846
- gout and, 850
- immune response and, 849
- parental administration of, 1113
- supplements of, 1262
- toxicity of, 1046, 1047
- vitamin D<sub>3</sub> and toxicosis, 855f
- Vitamin antagonists, 68
- Vitamin B complex, 73, 469
- Vitamin B<sub>12</sub>, 72, 85, 87, 88, 461, 846
- Vitamin B<sub>6</sub>, 1298
- Vitamin C, 73, 88, 459, 857
- debilitated birds and, 852
- for viral infections, 862
- hemoglobin values and, 1251
- immune response and, 849
- in Galliformes, 1233
- Vitamin D, 82, 83, 853
- egg binding, and, 759, 773
- toxicity of, 51
- Vitamin D<sub>3</sub>, 72, 73, 75, 587, 589, 852, 1252
- egg laying and, 753
- embryo death and, 787
- dyspnea and, 846

- relation to phosphorous and calcium, 67  
sunlight, 83  
toxicity of, 829, 1046
- Vitamin E, 72, 469, 504, 855  
angel wing and, 1257  
egg binding and, 759, 849  
embryo death, 787  
malabsorption and, 845  
ocular disease and, 686  
deficiencies and, 705t, 706, 709, 784, 1298  
deficiency vs picornavirus, 937  
neurologic signs with, 848  
immune response and, 849
- Vitamin H, 82
- Vitamin K, 73, 856  
embryo death and, 787  
hemorrhage control and, 802  
antidote for, 1051  
viral therapy and, 916  
malnutrition and, 856
- Vitamin K<sub>1</sub>, 349, 389, 469
- Vitamin M, 82
- Vitamin precursors, 83
- Vitamin requirements  
in Anseriformes, 1251t  
fat-soluble, 82, 86  
in Galliformes, 1223  
in Columbiformes, 1206  
water-soluble, 856
- Vitelline diverticulum, Merkel's  
diverticulum, 506
- Vitelogenin, 237
- Vocalization  
changes in, 576, 732, 1001  
emus and, 1288  
neurologic disease and, 728
- Volvulus  
in ratites, 1292c  
mesenterialis, 508  
nodosus, 508
- Vomer bone, 559
- Vomiting, 403, 492, 905, 926, 940, 1004, 1044 (see regurgitation)  
adults and, 483  
*Candida* and, 998  
doxycycline and, 1046  
in Passeriformes, 1189  
myocardial degeneration and, 504f  
papillomas and, 887
- VPC's, 708
- W** Warfarin, 1051
- Warts (see papilloma)
- Wasting disease,  
with *Mycobacterium*, 973 (see neuropathic gastric dilatation  
in Passeriformes, 1188  
with enterovirus, 938
- Water  
contamination of, 65, 860  
deprivation test, 586  
for Arctic circle waterfowl, 1257  
in Anseriformes, 1247, 1265  
in Columbiformes, 1204, 1206  
intake, variance of, 383t  
malnutrition, 860  
quality, and *C. botulinum*, 1263  
vitamins in, 57, 65
- Water bottle, 55f
- Waterfowl, 805, 850, 856, 1237, 1266  
(see Anseriformes)  
*Actinobacillus* in, 962  
airplane wing in, 848  
botulism and, 739, 978  
aspergillosis in, 1000, 1001  
*Candida* in, 999  
*Cryptococcus* in, 1004  
free-ranging, as disease vector, 921, 958  
bacterial disease and, 959, 960, 961, 975  
viral disease and, 872, 929, 934, 937  
gender determination in, 778  
immunosuppression in, 1265  
lead in, 1035, 1037  
migration and elevations of, 1239  
mine wastes in, 1264  
neonatal management in, 1253  
oil-contaminated, 599  
pinioning in, 1269  
restraint of, 1258, 1260f  
surgical techniques in, 1269  
tumors in, 1266  
zinc toxicosis in, 1039
- Watering techniques, 37-38
- Wattles, 1219
- WBC, white blood cell, count, 180, 916, 1181 (see hematology)  
formula for determining, 181t
- Weakness, 720, 732, 739, 1039, 1251, 1266
- Weaning, 101, 812, 827  
natural eating habits, 997  
regurgitation, in neonate, 827
- Weasels, 1207
- WEE virus, 919
- Weight loss  
in chicks, 824  
in free-ranging waterfowl, 1253  
zinc toxicosis and, 1039
- Wenckebach phenomenon, 710
- Wenyonella*, in Passeriformes, 1190
- West-Nil virus, 919
- Western duck sickness, 1263
- Wet chemistry, 227
- Wheat, aflatoxin, 69
- Wheezing, 887, 1001, 1197
- White lethal factor, in canary, 1184
- White muscle disease, 859
- Wild bird  
Conservation Act, 23  
harvesting, 22  
ranching, 21  
reintroduction, 22
- Wing  
balance, use of, 728  
body wrap, 429  
clipping, 38, 40f, 1224, 1225  
droop, 728, 743, 1035, 1264  
feather, 616f  
flaccid paralysis, 1044  
flapping and CNS signs, 736, 741  
slipped, 1257  
surgical approach to, 1153  
withdrawal, and neurologic disease, 728
- Winter plumage, 1239
- Wires, interfragmentary, cerclage, 1149
- Wolf-Parkinson-White syndrome, 710
- Wood chips, and fungus, 741
- Wood's lamp, ultraviolet, 696
- Wound healing, 418f, 419, 637, 1084  
sutures and, 1092
- Wright's stain, 179 (see hematology)
- Wry neck, 789
- X** Xanthoma, 642, 665, 1099  
cytology of, 213, 221c  
Xanthophyll, and feather pigmentation, 846, 1177
- Xenografts, 1145
- Xylazine, 462, 709, 711, 1213
- Xylocaine gel, 510
- Y** Yeast, 152, 436, 820, 823  
cell derivatives, 469  
in chicks, 152, 814, 823, 826
- Yersinia*, 575, 772, 957-958, 1188  
in Galliformes, 1232  
in Ramphastidae, 1281
- Yew, 1041
- Yolk (see egg)
- Yolk sac, 506, 821  
in Anseriformes, 1256  
infection of, 820  
percent body weight, 802  
removal, 1135, 1256, 1323  
retained, in ratites, 1292c, 1321  
retraction, 795
- Yolk sacculitis, bacterial, 969f, 1256  
in ratites, 1320
- Z** Zearalenone (F<sub>2</sub>), 1265
- Zinc, 72, 73, 93, 459, 513, 557, 848, 859, 1039  
feather quality and, 846  
immune response and, 849  
liver levels in Anseriformes, 1264  
new wire disease, 1038-1039  
monocytosis and, 189  
nutrition, 93  
protoporphyrin levels, 1037  
serum levels in Anseriformes, 1264  
toxicosis and, 739, 1039, 1198, 1264  
vitamin A and, 853
- Zoalene (DOT) toxicosis, 504
- Zoonoses, 357, 921, 929, 955, 1061  
bacterial diseases, 964, 971, 972t  
*Chlamydia* and, 995  
fungal diseases, 1005  
viral diseases, 930
- Zovirax, 458
- Zygapophyseal joint, 734
- Zygomycosis, 1189
- Zyloprim, 458
- Zythromax, 459
- 2-PAM, 467
- 5-fluorocytosine, 463







ISBN 0-9636996-0-1